

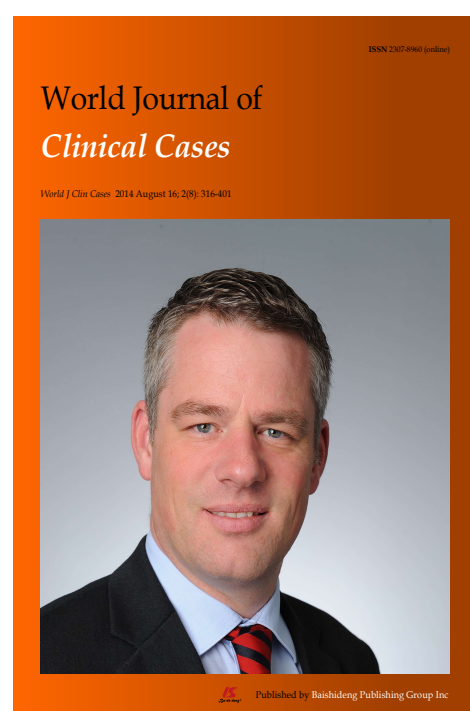




# World Journal of *Clinical Cases*

2014 Bound Volume 2 Issue 1-12: 1-942



## Editorial Board

2012-2016

The *World Journal of Clinical Cases* Editorial Board consists of 519 members, representing a team of worldwide experts in clinical medical research. They are from 55 countries, including Albania (1), Australia (8), Bangladesh (3), Belgium (3), Botswana (1), Brazil (10), Bulgaria (1), Canada (11), China (24), Colombia (2), Croatia (4), Cuba (1), Czech (2), Egypt (5), France (5), Germany (14), Greece (15), Hungary (1), India (56), Indonesia (1), Iran (11), Iraq (1), Ireland (1), Israel (5), Italy (56), Japan (33), Lebanon (3), Malaysia (2), Mexico (1), Morocco (2), Netherlands (3), New Zealand (1), Nigeria (1), Oman (1), Pakistan (1), Peru (2), Poland (4), Portugal (3), Qatar (1), Romania (3), Saudi Arabia (4), Serbia (6), Singapore (3), Slovakia (2), Slovenia (1), South Korea (27), Spain (11), Sudan (1), Taiwan (21), Thailand (2), Trinidad and Tobago (1), Tunisia (1), Turkey (28), United Kingdom (26), and United States (82).

### EDITORS-IN-CHIEF

Giuseppe Di Lorenzo, *Naples*  
Jan Jacques Michiels, *Rotterdam*  
Sandro Vento, *Gaborone*  
Shuhei Yoshida, *Boston*

### GUEST EDITORIAL BOARD MEMBERS

Hung-Yang Chang, *Hsinchu*  
Ning-Chia Chang, *Kaohsiung*  
Yao-Lung Chang, *Taoyuan*  
Chang-Han Chen, *Kaohsiung*  
Shao-Tsu Chen, *Hualien*  
Yen-Hsu Chen, *Kaohsiung*  
Kuen-Bao Chen, *Taichung*  
Yi-Ming Chen, *Taipei*  
Chih-Chien Chin, *Taoyuan*  
I-Ching Chou, *Taichung*  
Jun-Te Hsu, *Taoyuan*  
Shu-Pin Huang, *Kaohsiung*  
Chi-Wen Juan, *Taichung*  
Chih-Yuan Lin, *Taipei*  
Chiung-Chyi Shen, *Taichung*  
Jim Jinn-Chyuan Sheu, *Taichung*  
Bing-Wen Soong, *Taipei*  
Hwei-Fang Tien, *Taipei*  
Rong Kung Tsai, *Hualien*  
Han-Ping Wu, *Taichung*  
Hsu-Heng Yen, *Changhua*

### MEMBERS OF THE EDITORIAL BOARD



**Albania**

Ridvan Hamid Alimehmeti, *Tirana*



**Australia**

Roy Gary Beran, *Sydney*  
Jian Cheng, *Melbourne*  
Devang Jitendra Desai, *Brisbane*  
Manuel B Graeber, *Sydney*  
Finlay Alistair Macrae, *Victoria*  
Harrison Scott Weisinger, *Victoria*  
Harunor Rashid, *Sydney*



**Bangladesh**

Forhad Hossain Chowdhury, *Dhaka*  
Md Jafrul Hannan, *Chittagong*  
Aliya Naheed, *Dhaka*



**Belgium**

Guy Cheron, *Brussels*  
Yves Jacquemyn, *Edegem*  
Jean-Yves Luc Reginster, *Angleur*



**Botswana**

Guy Cheron, *Brussels*



**Brazil**

Everson Luiz De Almeida Artifon, *Sao Paulo*  
Juliano Julio Cerci, *Curitiba*

Luciano Pamplona de Góes, *Fortaleza*  
Márcio Ajudarte Lopes, *Piracicaba*  
Jose Mario Franco de Oliveira, *Rio de Janeiro*  
Daniel Cesar de Araujo Santos, *Rio de Janeiro*  
Hélio Afonso Ghizoni Teive, *Curitiba*  
Eduardo Neubarth Trindade, *Porto Alegre*  
Fabio Francesconi do Valle, *Manaus*  
Flavia Mariana Valente, *Sao Jose do Rio Preto*



**Bulgaria**

Plamen Kostov Nedev, *Varna*



**Canada**

Mark Otto Baerlocher, *Barrie*  
Kunihiko Hiraiwa, *Vancouver*  
Ali Izadpanah, *Quebec*  
Gang Li, *Vancouver*  
Habib-Ur-Rehman, *Regina*  
Abdul Qayyum Rana, *Toronto*  
Consolato Sergi, *Alberta*  
Rashmi Singh, *Vancouver*  
Jennifer L Spratlin, *Alberta*  
Ted L Tewfik, *Montreal*  
Sam Wiseman, *Vancouver*



**China**

Shiu-Yin Cho, *Hong Kong*  
Lian Duan, *Beijing*  
Lee Fung Yee Janet, *Hong Kong*  
David Harolo Garfield, *Shanghai*



Yong-Song Guan, *Chengdu*  
 Guo-Rong Han, *Nanjing*  
 Bin Jiang, *Beijing*  
 Alice Pik Shan Kong, *Hong Kong*  
 Jian-Jun Li, *Beijing*  
 De-Zhi Mu, *Chengdu*  
 Simon Siu-Man Ng, *Hong Kong*  
 Shi-Su Sheng, *Beijing*  
 Huai-Yin Shi, *Beijing*  
 Xue-Ying Sun, *Harbin*  
 Xue-Rui Tan, *Shantou*  
 Gang Wang, *Chengdu*  
 Feng Wang, *Shanghai*  
 Nian-Song Wang, *Shanghai*  
 Ge Xiong, *Beijing*  
 Zheng-Feng Yin, *Shanghai*  
 Qing Zhang, *Jingzhou*  
 Ming-Hua Zheng, *Wenzhou*  
 Jun Zhong, *Shanghai*  
 Yan-Ming Zhou, *Xiamen*



#### Colombia

Iván Darío Vélez Bernal, *Medellín*  
 Carlos Alberto Calderón-Ospina, *Bogota*



#### Croatia

Iva Brcic, *Zagreb*  
 Srđana Čulić, *Spinciceva*  
 Tomislav Kulis, *Zagreb*  
 Zvonimir Lovrić, *Zagreb*



#### Cuba

Alain Cruz Portelles, *Holguin*



#### Czech

David Bludovský, *Plzen*  
 Antonin Marik, *Prague*



#### Egypt

Farid Mohammed Sabry El-Askary, *Cairo*  
 Reda Abd Elhady Hemida, *Mansoura*  
 Sherifa Ahmad Hamed, *Assiut*  
 Ahmad Abd-Elgawad Nofal, *Zagazig*  
 Mohamed Ismail Seleem, *Cairo*



#### France

I Alain Braillon, *Amiens*  
 Jean-François Bosset, *Besançon*  
 Isabelle Andrée Chemin, *Lyon*  
 Emile Jean-François, *Boulogne*  
 Christophe Martinaud, *Clamart*



#### Germany

Sebastian Decker, *Hannover*  
 Andreas Martin Fette, *Weissach im Tal*  
 Michael Froehner, *Dresden*  
 Wolf Christoph Mueller, *Leipzig*  
 Andres Hao Ming Neuhaus, *Berlin*  
 Arndt Hartmann, *Erlangen*  
 Dirk M Hermann, *Essen*  
 Karl-Anton Kreuzer, *Berlin*  
 Ingo Stefan Nölte, *Mannheim*  
 Andreas G Schreyer, *Regensburg*  
 Crispin Schneider, *Bristol*  
 Hans-Joachim Schmoll, *Halle*  
 Martin Paul Schencking, *Witten*  
 Mathias Z Strowski, *Berlin*



#### Greece

Andrew P Andonopoulos, *Patras*  
 Dimitrios Daoussis, *Patras*  
 Ioanna Dimopoulou, *Athens*  
 Moses S Elisaf, *Ioannina*  
 Costas Fourtounas, *Rio-Patras*  
 Olga-Elpis Kolokitha, *Thessaloniki*  
 Sophia Lionaki, *Athens*  
 Marilita M Moschos, *Athens*  
 Michail N Varras, *Athens*  
 Nikolaos Papanas, *Alexandroupolis*  
 Athanasios Papatsoris, *Athens*  
 Zervoudis Stephane, *Athens*  
 Konstantinos Tepetes, *Larissa*  
 Apostolos Tsapas, *Thessaloniki*  
 Dimitrios Vavilis, *Thessaloniki*



#### Hungary

Tibor Hortobágyi, *Debrecen*



#### India

Subrat Kumar Achaya, *New Delhi*  
 Amit Arvind Agrawal, *Nasik*  
 Hena A Ansari, *Aligarh*  
 MS Ansari, *Lucknow*  
 Laxminarayan Bhadrani, *Calicut*  
 Ashu Seith Bhalla, *New Delhi*  
 Sachin Anil Borkar, *New Delhi*  
 Bhuvan Chanana, *New Delhi*  
 Kanishka Das, *Bangalore*  
 Reena Das, *Chandigarh*  
 Nilay Kanti Das, *Kolkata*  
 Deep Dutta, *Kolkata*  
 Mimi Gangopadhyay, *Siliguri*  
 Rakesh Garg, *New Delhi*  
 Sandeep Grover, *Chandigarh*  
 Mahendra Singh Hada, *Rajasthan*  
 P Hazarika, *Manipal*  
 Sachin Bhalchandra Ingle, *Latur*  
 Parwez Sajad Khan, *Srinagar*  
 Pradeep Kumar, *Bangalore*  
 Amol Lunkad, *Pune*

Dale A Maharaj, *Trinidad*  
 Nikhil Marwah, *Rajasthan*  
 Meena Gupta, *New Delhi*  
 Amit Kumar Mishra, *Indore*  
 Soma Mukherjee, *Mumbai*  
 Deb Sanjay Nag, *Jamshedpur*  
 Kushal Naha, *Karnataka*  
 Janardhanan C Narayanaswamy, *Bangalore*  
 Soubhagya Ranjan Nayak, *Nadia*  
 Narendra Pamidi, *Karnataka*  
 Murali Prabhakaran Vettath, *Kerala*  
 Samir Kumar Praharaj, *Karnataka*  
 Peralam Yegneswaran Prakash, *Manipal*  
 C S Pramesh, *Mumbai*  
 Kishore Puthezhath, *Kerala*  
 Harbans Singh Randhawa, *Delhi*  
 M Rangarajan, *Coimbatore*  
 Sayantan Ray, *Kolkata*  
 Bharat Rekhi, *Maharashtra*  
 S Sharija, *Thiruvananthapuram*  
 Dhananjaya Sabat, *New Delhi*  
 Sachin Chakradhar Sarode, *Pune*  
 Ashish Sharma, *Coimbatore*  
 Hakim Irfan Showkat, *Srinagar*  
 Rikki Singal, *Mullana*  
 Deepak Kumar Singh, *Lucknow*  
 Yashpal Singh, *Meerut*  
 Naorem Gopendro Singh, *New Delhi*  
 Shyam Sundar, *Varanasi*  
 Naveen S Tahasildar, *Hubli*  
 Devinder Mohan Thappa, *Pondicherry*  
 Pradeep Vaideeswar, *Mumbai*  
 Mukul Vij, *Kanpur*  
 Rajesh Vijayvergiya, *Chandigarh*  
 B Viswanatha, *Bangalore*



#### Indonesia

Coen Pramono, *Surabaya*



#### Iran

Masoud Amiri, *Shahrekord*  
 Mostafa Ghanei, *Tehran*  
 Mahdi Malekpour, *Tehran*  
 Setareh Mamishi, *Tehran*  
 Afshin Mohammadi, *Urmia*  
 Seyyed Amin Ayatollahi Mousavi, *Kerman*  
 Mohammad Taher Rajabi, *Tehran*  
 Amin Saburi, *Tehran*  
 Maryam Sahebari, *Mashhad*  
 Payman Vahedi, *Mashad*  
 Amir Reza Vosoughi, *Shiraz*



#### Iraq

Bassim Irheim Mohammad, *Al-Qadisiya*



#### Ireland

Robbie Seton Rowan Woods, *Dublin*

**Israel**

Nimer Najib Assy, *Safed*  
 Gil Bar-Sela, *Haifa*  
 Itzhak Braverman, *Hadera*  
 Eyal Itshayek, *Jerusalem*  
 Gary Michael Ginsberg, *Jerusalem*

**Italy**

Giovanni Addolorato, *Rome*  
 Piero Luigi Almasio, *Palermo*  
 Francesco Angelico, *Rome*  
 Marialuisa Appetecchia, *Rome*  
 Valeria Barresi, *Messina*  
 Gabrio Bassotti, *Roma Sisto*  
 Paolo Boffano, *Turin*  
 Maria Luisa Brandi, *Florence*  
 Michelangelo Buonocore, *Pavia*  
 Giovanni Cammarota, *Rome*  
 Isidoro Di Carlo, *Catania*  
 Andrea Ciorba, *Ferrara*  
 Lucio Cocco, *Bologna*  
 Carlo Colosimo, *Rome*  
 Alfredo Conti, *Messina*  
 Giovanni Conzo, *Naples*  
 Gennaro Cormio, *Bari*  
 Alessandro Federico, *Naples*  
 Gabriella Maria Ferrandina, *Rome*  
 Davide Firinu, *Cagliari*  
 Caterina Foti, *Bari*  
 Gennaro Galizia, *Naples*  
 Silvio Garattini, *Milan*  
 Giampietro Gasparini, *Roma*  
 Luigi De Gennaro, *Rome*  
 Giorgio Ghilardi, *Milano*  
 Domenico Girelli, *Verona*  
 Biondi Zoccai Giuseppe, *Latina*  
 Carlo Lajolo, *Rome*  
 Alessandro Landi, *Rome*  
 Salvatore Leonardi, *Catania*  
 Carmela Loguercio, *Naples*  
 Marianna Luongo, *Potenza*  
 Zippi Maddalena, *Rome*  
 Roberto Manfredini, *Ferrara*  
 Annunziato Mangiola, *Roma*  
 Elia De Maria, *Carpi*  
 Marco Mazzocchi, *Perugia*  
 Roberto Luca Meniconi, *Rome*  
 Marco Milone, *Naples*  
 Paolo Nozza, *Genoa*  
 Pier Paolo Panciani, *Brescia*  
 Desire' Pantalone, *Firenze*  
 Raffale Pezzilli, *Bologna*  
 Giorgina Barbara Piccoli, *Torino*  
 Roberto Pola, *Rome*  
 Marco Romano, *Napoli*  
 Gianantonio Saviola, *Castel Goffredo*  
 Stefania Scala, *Naples*  
 Leonardo A Sechi, *Udine*  
 Matteo Tebaldi, *Ferrara*  
 Riccardina Tesse, *Bari*

Tiziano Testori, *Milano*  
 Gian Vincenzo Zuccotti, *Milan*

**Japan**

Ukei Anazawa, *Ichikwa-shi*  
 Junichi Asaumi, *Okayama*  
 Takashi Asazuma, *Saitama-ken*  
 Norihiro Furusyo, *Fukuoka*  
 Masaru Ishida, *Yokohama*  
 Tatsuaki Ishiguro, *Tokyo*  
 Hajime Isomoto, *Nagasaki*  
 Yokoyama Junkichi, *Sendai*  
 Keita Kai, *Saga*  
 Terumi Kamisawa, *Tokyo*  
 Tatsuo Kanda, *Niigata*  
 Shigeyuki Kawa, *Matsumoto*  
 Kazushi Kishi, *Wakayama-city*  
 Satoru Kyo, *Ishikawa*  
 Nozomi Majima, *Osaka*  
 Kenji Miki, *Tokyo*  
 Atsushi Nakajima, *Tokyo*  
 Rui Niimi, *Tsu city*  
 Masaharu Nomura, *Tokyo*  
 Kenoki Ohuchida, *Fukuoka*  
 Morishita Ryuichi, *Osaka*  
 Yosuke Sato, *Niigata*  
 Mitsushige Sugimoto, *Hamamatsu*  
 Haruhiko Sugimura, *Hamamatsu*  
 Keisuke Uehara, *Nagoya*  
 Manabu Watanabe, *Tokyo*  
 Takayuki Yamamoto, *Yokkaichi*  
 Yoshihito Yokoyama, *Hiroaki*  
 Junkichi Yokoyama, *Tokyo*  
 Han-Seung Yoon, *Nagano*  
 Kiyoshi Yoshino, *Osaka*  
 Yuichi Kasai, *Tsu city*  
 Yuzuru Niibe, *Sagamihara-shi*

**Lebanon**

Maroun Miled Abou-Jaoude, *Beirut*  
 Kassem A Barada, *Beirut*  
 Raja Sawaya, *Beirut*

**Malaysia**

Iman Salahshourifar, *Kubang Kerian*  
 Mohamad Nasir Shafiee, *Kuala Lumpur*

**Mexico**

Ernesto Roldan-Valadez, *Mexico*

**Morocco**

Alae El Koraichi, *Rabat*  
 Faycal Lakhdar, *Rabat*

**Netherlands**

Sijens Paul Eduard, *Groningen*  
 Paul E Sijens, *Groningen*

**New Zealand**

Rita Rita Krishnamurthi, *Auckland*

**Nigeria**

Shamsideen Abayomi Ogun, *Lagos*

**Oman**

Itrat Mehdi, *Muscat*

**Pakistan**

Sabiha Anis, *Karachi*

**Peru**

Eduardo Gotuzzo, *Lima*  
 Eduardo Salazar-Lindo, *Lima*

**Poland**

Łukasz Stanisław Matuszewski, *Lublin*  
 Tadeusz Robak, *Ciolkowskiego*  
 Adam Wysokiński, *Lodz*  
 Witold Antoni Zatoński, *Warsaw*

**Portugal**

Jorge Alves, *Braga*  
 Gustavo Marcondes Rocha, *Porto*  
 Zacharoula Sidiropoulou, *Barreiro*

**Qatar**

Fahmi Yousef Khan, *Doha*

**Romania**

Simona Gurzu, *Targu-Mures*  
 Doina Piciu, *Cluj-Napoca*  
 Mugurel Constantin Rusu, *Bucharest*

**Saudi Arabia**

Ahmed Alkhani, *Riyadh*  
 Iqbal Abdulaziz Bukhari, *Alkhobar*  
 Mohamed Fahmy Ibrahim, *Riyadh*

Jyothi Tadakamadla, *Hyderabad*



#### **Serbia**

Ivona Milorad Djordjevic, *Nis*  
Jelena Lazar Lazic, *Belgrade*  
Djordje Radak, *Beograd*  
Boban Stanojevic, *Belgrade*  
Mihailo Ilija Stjepanovic, *Belgrade*  
Momcilo Pavlovic, *Subotica*



#### **Singapore**

Wei-Sheng Chong, *Singapore*  
Khek-Yu Ho, *Singapore*  
Yong Kuei Lim, *Singapore*



#### **Slovakia**

Michal Mego, *Bratislava*  
Ivan Varga, *Bratislava*



#### **Slovenia**

Pavel Skok, *Maribor*



#### **South Korea**

Young-Seok Cho, *UiJeongbu*  
Tae Hyun Choi, *Seoul*  
Yeun-Jun Chung, *Seoul*  
Ki-Baik Hahm, *Seoul*  
Seung-Jae Hyun, *Seongnam*  
Soo Bin Im, *Bucheon*  
Soung Won Jeong, *Seoul*  
Choun-Ki Joo, *Seoul*  
Chang Moo Kang, *Seoul*  
Seung Taik Kim, *Chungbuk*  
Byung-Wook Kim, *Incheon*  
Myoung Soo Kim, *Seoul*  
Gwi Eon Kim, *Seoul*  
Gyeong-Moon Kim, *Seoul*  
Hahn Young Kim, *Seoul*  
Won Seog Kim, *Seoul*  
Yoon Jun Kim, *Seoul*  
Yun-Hee Kim, *Seoul*  
Sun-Young Lee, *Seoul*  
Sang Chul Lim, *Hwasun-gun*  
Seung Sam Paik, *Seoul*  
Jae Yong Park, *Daegu*  
Jong-Ho Park, *Goyang*  
Jun-Beom Park, *Seoul*  
Songhae Hae Ryong, *Seoul*  
Chan Sup Shim, *Seoul*  
Hwaseung Yoo, *Daejeon*



#### **Spain**

Adrià Arboix, *Barcelona*

FJA Artiles, *Las Palmas de Gran Canaria*

Manuel Benito, *Madrid*

Vicente Carreño, *Madrid*

Rosa Corcoy, *Barcelona*

Exuperio Díez-Tejedor, *Madrid*

Luis Ignacio González Granado, *Madrid*

Carlos Alberto Dussan Luberth, *Torre Vieja*

Juan de Dios Molina Martín, *Madrid*

Sergio Fernández-Pello Montes, *Gijón*

Tomás Sobrino, *Santiago de Compostela*



#### **Sudan**

Samir MH Shaheen, *Khartoum*



#### **Thailand**

Sarunyou Chusri, *Songkhla*

Weekitt Kittisupamongkol, *Bangkok*



#### **Trinidad and Tobago**

Dale Andrew Maharaj, *Port of Spain*



#### **Tunisia**

Makram Koubaa, *Sfax*



#### **Turkey**

Sami Akbulut, *Diyarbakir*

Tamer Akça, *Mersin*

Cengiz Akkaya, *Bursa*

Ahmet Baydin, *Samsun*

Hasan Belli, *Istanbul*

Serbüent Gökhan Beyaz, *Sakarya*

GK Cakmak, *Kozlu Zonguldak*

Turgay Celik, *Ankara*

Yasemin Benderli Cihan, *Kayseri*

Ömür Dereci, *Ankara*

Mehmet Doganay, *Kayseri*

F Neslihan İnal Emiroğlu, *İzmir*

Aylin Türel Ermercan, *Manisa*

Kadir Ertem, *Malatya*

Aydın Gulses, *Canakkale*

Mustafa Koray Gumus, *Kayseri*

Ramazan Kahveci, *Kırıkkale*

Saadettin Kiliçkap, *Ankara*

Fatih Kucukdurmaz, *Istanbul*

Ashhan Küçükler, *Ankara*

Nuray Bayar Muluk, *Ankara*

Orhan Veli Ozkan, *Sakarya*

Zeynep Özkurt-Kayahant, *Istanbul*

Mustafa Sahin, *Ankara*

İbrahim Sakçak, *Ankara*

Feyzi Birol Sarica, *Adana*

Selim Sözen, *Kayseri*

Murat Ugurlucan, *Istanbul*



#### **United Kingdom**

Henry Dushan Atkinson, *London*

Ioannis G Baraboutis, *Cambridgeshire*

I Beegun, *London*

Ricky Harminder Bhogal, *Birmingham*

Kuntal Chakravarty, *Romford*

Deyaa Elsandabese, *Harlow*

Radwan Faraj, *Moorgate Road-Rotherham*

Babatunde Abiodun Gbolade, *Leeds*

Sanju George, *Birmingham*

David Julian Alexander Goldsmith, *London*

Nadey S Hakim, *London*

Koshy Jacob, *Boston*

Anastasios Koulaouzidis, *Edinburgh*

Andrew Richard Lisle Medford, *Bristol*

Panagiotis Peitsidis, *Southend Essex*

Rahul Tony Rao, *London*

Francis Paul Rugman, *Preston*

Khaled Maher Sarraf, *London*

Yousef Shahin, *Hull*

Alexa Shipman, *Birmingham*

Badri Man Shrestha, *Sheffield*

Herrick J Siegel, *Birmingham*

Leonello Tacconi, *London*

Jagdeep Singh Virk, *Harrow*

James Chiun Lon Wong, *Manchester*

Kimia Ziahosseini, *Liverpool*



#### **United States**

Doru Traian Alexandrescu, *San Diego*

Naim Alkhouri, *Cleveland*

Mohammad M Alsolaiman, *Orem Utah*

Bhupinder S Anand, *Houston*

Suresh J Antony, *Oregon*

Normadeane Armstrong, *Rockville Centre*

Wilbert Solomon Aronow, *Valhalla*

Hossam M Ashour, *Detroit*

Rajendra Badgaiyan, *Buffalo*

Joseph Robert Berger, *Lexington*

Dennis A Bloomfield, *New York*

Neil Box, *Denver*

Jeffrey Alan Breall, *Indianapolis*

Susana M Campos, *Boston*

Robert Carter III, *San Antonio*

Kaisorn Lee Chaichana, *Baltimore*

Antonio Joseph Chamoun, *Coatesville*

Vince Clark, *Albuquerque*

C Donald Combs, *Norfolk*

Suzanne Marie Crumley, *Houston*

Parakkal Deepak, *Evanston*

Yuchuan Ding, *Detroit*

Konstantin Hristov Dragnev, *Lebanon*

Cecilia Luminita Dragomir, *New York*

Konstantinos P Economopoulos, *Boston*

James M Ford, *Stanford*

Yun Gong, *Houston*

Zeba Hasan Hafeez, *Novato*

Ardeshtir Hakam, *Tampa*

Jaclyn Frances Hechtman, *New York*

T Patrick Hill, *New Brunswick*

Hitoshi Hirose, *Philadelphia*

Elias Jabbour, *Houston*

Robert Thomas Jensen, *Bethesda*

Huanguang Jia, *Florida*  
Zhong Jiang, *Worcester*  
Theodoros Kelesidis, *Los Angeles*  
Kusum K Kharbanda, *Omaha*  
Praveen Kumar, *Chicago*  
Julius Gene Silva Latorre, *Syracuse*  
Guojun Li, *Houston*  
Yaling Liu, *Rochester*  
Marios-Nikolaos Lykissas, *New York*  
Kenneth Maiese, *Newark*  
Serge Peter Marinkovic, *Lafayette*  
Charles Christian Matouk, *New Haven*  
Kapil Mehta, *Houston*  
Zaher Merhi, *Burlington*  
Ayse Leyla Mindikoglu, *Baltimore*  
Roberto Nicolas Miranda, *Houston*

Majaz Moonis, *Worcester*  
Assad Movahed, *Greenville*  
Mohammad Reza Movahed, *Tucson*  
Saleh A Naser, *Orlando*  
Srinivasan Paramasivam, *New York*  
Edwin Melencio Posadas, *Los Angeles*  
Xiaofa Qin, *Newark*  
Michel Elias Rivlin, *Jackson*  
Jae Y Ro, *Houston*  
Bruce Samuel Rudy, *Hershey*  
Abdulaziz Sachedina, *Charlottesville*  
Ravi Prakash Sahu, *Indiana*  
Michael William Schlund, *Baltimore*  
Eric Lee Scott, *Indianapolis*  
Volney Leo Sheen, *Boston*  
Ilke Sipahi, *Cleveland*

Subbaya Subramanian, *Minneapolis*  
Jessica D Sun, *South San Francisco*  
Ulas Sunar, *Buffalo*  
Scott Tenner, *Brooklyn*  
Diana Olguta Treaba, *Providence*  
Richard Gary Trohman, *Chicago*  
Ming C Tsai, *New York*  
Vassiliy Tsytsarev, *Baltimore*  
Howard J Worman, *New York*  
Jun Yao, *Naperville*  
Shahram Yazdani, *Los Angeles*  
Panitan Yossuck, *Morgantown*  
Stanley Zaslau, *Morgantown*  
Sheng Zhang, *New Haven*  
Xinmin Zhang, *Philadelphia*



# World Journal of *Clinical Cases*

*World J Clin Cases* 2014 January 16; 2(1): 1-26





### CASE REPORT

- 1 Dellen-like keratopathy associated with glaucoma drainage devices  
*Fenzl CR, Moshirfar M, Gess AJ, Muthappan V, Goldsmith J*
- 5 Rare presentation of self-resolving multifocal inflammatory pseudo-tumour of liver  
*Puri Y, Lytras D, Luong TV, Fusai GK*
- 9 Resection of giant gastric GIST with a new generation ultrasonic scalpel device  
*Schneider C, Hewin DF*
- 12 Epilepsy triggered by mefloquine in an adult traveler to Uganda  
*Gobbi F, Rossanese A, Buonfrate D, Angheben A, Postiglione C, Bisoffi Z*
- 16 Two rare cases of benign hyperlipasemia in children  
*Lionetti E, Francavilla R, Leonardi S, Tomarchio S, Gennaro A, Franzonello C, La Rosa M*
- 20 Left atrial thrombosis in an anticoagulated patient after bioprosthetic valve replacement: Report of a case  
*Rosa GM, Parodi A, Dorigi U, Carbone F, Mach F, Quercioli A, Montecucco F, Vuilleumier N, Balbi M, Brunelli C*
- 24 Retrograde jejuno gastric intussusception following Braun's jejunojejunostomy  
*Gopal R, Elamurugan TP, Hage S, Muthukumarassamy R, Kate V*

## Contents

*World Journal of Clinical Cases*  
Volume 2 Number 1 January 16, 2014

**APPENDIX** I-V Instructions to authors

**ABOUT COVER** Editorial Board Member of *World Journal of Clinical Cases*, Devinder Mohan Thappa, Professor and Head, Department of Dermatology and STD, Jawaharlal Institute of Postgraduate Medical Education and Research (JIPMER), Pondicherry 605006, India

**AIM AND SCOPE** *World Journal of Clinical Cases* (*World J Clin Cases*, *WJCC*, online ISSN 2307-8960, DOI: 10.12998) is a peer-reviewed open access academic journal that aims to guide clinical practice and improve diagnostic and therapeutic skills of clinicians.

The primary task of *WJCC* is to rapidly publish high-quality Autobiography, Case Report, Clinical Case Conference (Clinicopathological Conference), Clinical Management, Diagnostic Advances, Editorial, Field of Vision, Frontier, Medical Ethics, Original Articles, Clinical Practice, Meta-Analysis, Minireviews, Review, Therapeutics Advances, and Topic Highlight, in the fields of allergy, anesthesiology, cardiac medicine, clinical genetics, clinical neurology, critical care, dentistry, dermatology, emergency medicine, endocrinology, family medicine, gastroenterology and hepatology, geriatrics and gerontology, hematology, immunology, infectious diseases, internal medicine, obstetrics and gynecology, oncology, ophthalmology, orthopedics, otolaryngology, pathology, pediatrics, peripheral vascular disease, psychiatry, radiology, rehabilitation, respiratory medicine, rheumatology, surgery, toxicology, transplantation, and urology and nephrology.

**INDEXING/ABSTRACTING** *World Journal of Clinical Cases* is now indexed in PubMed Central, PubMed, Digital Object Identifier.

**FLYLEAF** I-V Editorial Board

## EDITORS FOR THIS ISSUE

Responsible Assistant Editor: *Xin-Xin Che*  
Responsible Electronic Editor: *Cai-Hong Wang*  
Proofing Editor-in-Chief: *Lian-Sheng Ma*

Responsible Science Editor: *Ling-Ling Wen*

**NAME OF JOURNAL**  
*World Journal of Clinical Cases*

**ISSN**  
ISSN 2307-8960 (online)

**LAUNCH DATE**  
April 16, 2013

**FREQUENCY**  
Monthly

**EDITORS-IN-CHIEF**  
**Giuseppe Di Lorenzo, MD, PhD, Professor**, Genitourinary Cancer Section and Rare-Cancer Center, University Federico II of Napoli, Via Sergio Pansini, 5 Ed. 1, 80131, Naples, Italy

**Jan Jacques Michiels, MD, PhD, Professor**, Primary Care, Medical Diagnostic Center Rijnmond Rotterdam, Bloodcoagulation, Internal and Vascular Medicine, Erasmus University Medical Center, Rotterdam, Goodheart Institute and Foundation, Erasmus Tower, Veennos 13, 3069 AT, Erasmus City, Rotterdam, The Netherlands

**Sandro Vento, MD**, Department of Internal Medicine,

University of Botswana, Private Bag 00713, Gaborone, Botswana

**Shuhei Yoshida, MD, PhD**, Division of Gastroenterology, Beth Israel Deaconess Medical Center, Dana 509, Harvard Medical School, 330 Brookline Ave, Boston, MA 02215, United States

**EDITORIAL OFFICE**  
Jin-Lei Wang, Director  
Xiu-Xia Song, Vice Director  
*World Journal of Clinical Cases*  
Room 903, Building D, Ocean International Center, No. 62 Dongsihuan Zhonglu, Chaoyang District, Beijing 100025, China  
Telephone: +86-10-85381891  
Fax: +86-10-85381893  
E-mail: [bpgoffice@wjnet.com](mailto:bpgoffice@wjnet.com)  
<http://www.wjnet.com>

**PUBLISHER**  
Baishideng Publishing Group Co., Limited  
Flat C, 23/F., Lucky Plaza,  
315-321 Lockhart Road, Wan Chai,  
Hong Kong, China  
Fax: +852-6555-7188  
Telephone: +852-3177-9906

E-mail: [bpgoffice@wjnet.com](mailto:bpgoffice@wjnet.com)  
<http://www.wjnet.com>

**PUBLICATION DATE**  
January 16, 2014

**COPYRIGHT**  
© 2014 Baishideng Publishing Group Co., Limited. Articles published by this Open Access journal are distributed under the terms of the Creative Commons Attribution Non-commercial License, which permits use, distribution, and reproduction in any medium, provided the original work is properly cited, the use is non commercial and is otherwise in compliance with the license.

**SPECIAL STATEMENT**  
All articles published in this journal represent the viewpoints of the authors except where indicated otherwise.

**INSTRUCTIONS TO AUTHORS**  
Full instructions are available online at [http://www.wjnet.com/2307-8960/g\\_info\\_20100722180909.htm](http://www.wjnet.com/2307-8960/g_info_20100722180909.htm)

**ONLINE SUBMISSION**  
<http://www.wjnet.com/esp/>

## Dellen-like keratopathy associated with glaucoma drainage devices

Carlton Robert Fenzl, Majid Moshirfar, Adam John Gess, Valliammai Muthappan, Jason Goldsmith

Carlton Robert Fenzl, Department of Ophthalmology, Jamaica Hospital Medical Center/NYMC, Jamaica, NY 11418, United States

Majid Moshirfar, Adam John Gess, Valliammai Muthappan, Jason Goldsmith, Moran Eye Center, University of Utah, Salt Lake City, UT 84132, United States

Author contributions: Fenzl CR, Moshirfar M and Gess AJ performed the initial data collection, paper design, and first draft; Muthappan V and Goldsmith J performed significant revisions as well as reevaluation of the data.

Correspondence to: Majid Moshirfar, MD, Moran Eye Center, University of Utah, 65 Mario Capecchi Drive, Salt Lake City, UT 84132, United States. [majid.moshirfar@hsc.utah.edu](mailto:majid.moshirfar@hsc.utah.edu)

Telephone: +1-801-5873020 Fax: +1-801-9479286

Received: October 17, 2013 Revised: December 21, 2013

Accepted: January 6, 2014

Published online: January 16, 2014

### Abstract

To report the first case of dellen-like keratopathy with superior corneal thinning associated with implantation of glaucoma drainage devices. A 70-year-old male with a history of primary open angle glaucoma and dry eye disease underwent placement of glaucoma drainage devices with antimetabolite application in both eyes. Prior to placement, minimal refractive error was noted on manifest refraction. Several years later, the patient was referred for decreased vision and corneal irregularity. Examination showed pathologic corneal curvature, superior corneal thinning, and epithelial demarcation lines immediately anterior to the glaucoma drainage devices in both eyes. The epithelium remained intact with no evidence of limbal stem cell deficiency. Manifest refraction revealed a large change in both eyes. Topography was used to confirm the presence of irregular corneal curvature anterior to the glaucoma drainage devices. Dellen-like keratopathy with superior thinning is a rare sequela after implantation of a glaucoma drainage device that must be considered in elderly patients who undergo glaucoma surgery. It is likely related to a

combination of tear film alteration related to previously large anterior blebs, antimetabolite application, and aqueous humor flow patterns around the drainage devices. Treatment should focus on lubrication.

© 2014 Baishideng Publishing Group Co., Limited. All rights reserved.

**Key words:** Dellen-like keratopathy; Delle; Glaucoma drainage device; Corneal thinning

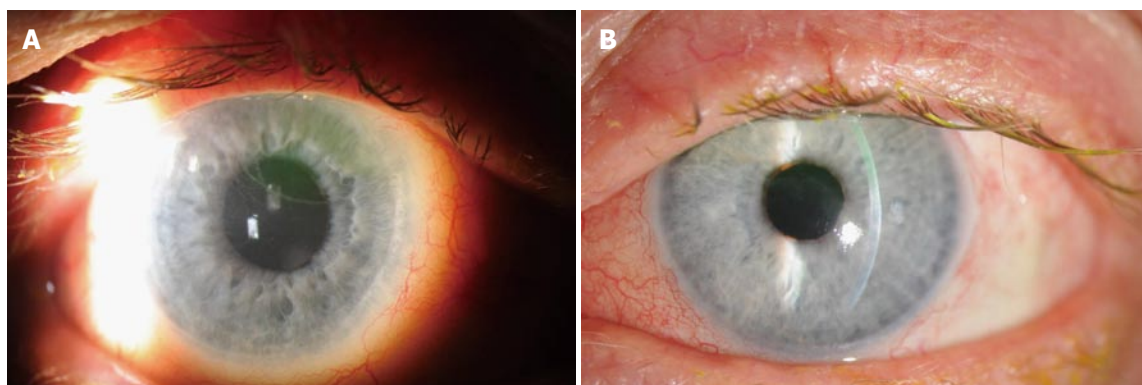
**Core tip:** Corneal abnormalities are not uncommon findings in patients with longstanding glaucoma. Topical medication-related and antimetabolite-related keratopathies are conditions that have been well documented. This case report identifies an entity related to glaucoma drainage devices. Dellen-like keratopathy is a condition similar in appearance to that of a delle, but larger in size. Early identification is important in preventing excessive corneal thinning and irregular corneal curvature.

Fenzl CR, Moshirfar M, Gess AJ, Muthappan V, Goldsmith J. Dellen-like keratopathy associated with glaucoma drainage devices. *World J Clin Cases* 2014; 2(1): 1-4 Available from: URL: <http://www.wjgnet.com/2307-8960/full/v2/i1/1.htm> DOI: <http://dx.doi.org/10.12998/wjcc.v2.i1.1>

### INTRODUCTION

Dellen keratopathy is characterized by localized thinning and dryness in the cornea. It often develops adjacent to areas of ocular surface changes and elevation, such as pterygia. Chronic dellen formation can lead to diffuse thinning. This is the first reported case of delle-like keratopathy with superior corneal thinning resulting from the implantation of glaucoma drainage devices.





**Figure 1** Photograph of right eye demonstrating epithelial demarcation line, fluorescein pooling, and ExPRESS shunt immediately below superior eyelid margin (A) and photograph of left eye showing epithelial demarcation line, superior stromal thinning, fluorescein pooling, and Ahmed valve immediately below superior eyelid margin (B).

## CASE REPORT

A 70-year-old male was referred by his glaucoma specialist for gradual worsening of vision in both eyes. The patient had a history of primary open angle glaucoma for ten years for which he underwent multiple surgeries. He also suffered from moderate dry eye disease for which he was being treated with frequent topical lubrication. The right eye had placement of ExPRESS shunt (Alcon Laboratories, Fort Worth, TX) with use of mitomycin-C (MMC), which required two subsequent revisions in the right eye, both of which also used MMC. The left eye underwent a trabeculectomy with MMC, followed by Ahmed tube shunt (New World Medical, Rancho Cucamonga, CA). The patient was also pseudophakic in both eyes and denied any history of refractive surgery, excessive eye rubbing, bleb massage, and collagen vascular disease.

Eleven months prior to presentation he had stable best corrected visual acuity of 20/40 in the right eye and 20/50 in the left eye. Manifest refraction was  $-1.25 + 1.50 \times 010$  and  $-0.75 + 0.75 \times 080$  respectively.

At the time of presentation, the patient was being treated with brinzolamide twice daily, brimonidine/timolol combination twice daily, latanoprost once daily, and preservative free artificial tears three times per hour in both eyes. The patient's best-corrected visual acuity was 20/70 in the right eye and 20/100 in the left eye with significantly increased astigmatism on manifest refraction:  $-6.25 + 7.75 \times 060$  in the right eye and  $+2.25 + 2.50 \times 047$  in the left eye. Intraocular pressure was 34 mmHg in the right eye and 18 mmHg in the left eye. Central corneal thickness was 511 microns in the right eye and 533 microns in the left eye.

Externally, no eyelid pathology was present. Anterior segment examination revealed thinning of the superior one-third of the corneal stroma with an clear epithelial demarcation line in each eye (Figure 1). The epithelium was intact bilaterally. A slight elevation of the conjunctiva was present posterior to the limbus in each eye, but no perilimbal bleb was identified. The glaucoma drainage device tubes inside each anterior chamber were in appro-

priate posterior position with no corneal contact. Topographic analysis with Pentacam (Optikgerate GmbH, Wetzlar, Germany) revealed diffuse corneal thinning as well as irregular corneal curvatures adjacent to the glaucoma drainage devices. At the thinnest point, the right cornea was 421 microns and the left cornea was 450 microns (Figure 2).

## DISCUSSION

Corneal dellen are localized areas of drying and thinning in the peripheral cornea, usually adjacent to an area of ocular surface abnormality. With chronic dellen, a keratopathy mimicking ectasia can occur with a combination of drying, thinning, and a reduced corneal tensile strength.

Keratopathy resulting from glaucoma surgery is exceedingly rare. To our knowledge, only two cases of keratopathy after glaucoma surgery have been documented in the literature, both following trabeculectomy (there are no reported cases after tube shunt surgery). One reported case utilized MMC<sup>[1]</sup> and the other used 5-Fluorouracil (5-FU)<sup>[2]</sup>. In one bilateral case of superior corneal changes observed 15 years after surgery, the cause was thought to be due to either bleb compression from prominent avascular blebs or chronic corneal toxicity from MMC application<sup>[1]</sup>. The other case of keratopathy following trabeculectomy was attributed to excessive eye rubbing<sup>[2]</sup>.

MMC and 5-FU have long been used adjunctively in trabeculectomy to improve surgical outcomes. Resultant epitheliopathy is common due to the effect of antimetabolites on actively replicating tissue<sup>[3]</sup>, and effects are seen well beyond the time of surgery<sup>[4]</sup>. Stromal keratocytes are also affected by antimetabolite medications; in an *in vitro* human cornea model, Rajan *et al.*<sup>[5]</sup> documented a significant delay in keratocyte repopulation as well as decreased anterior stromal thickness four weeks after photorefractive keratectomy combined with MMC.

In our patient, thinning and significant alteration in the corneal curvature were present in a location immediately anterior to each drainage device. Given this patient's history of multiple glaucoma surgeries, it is likely that dellen

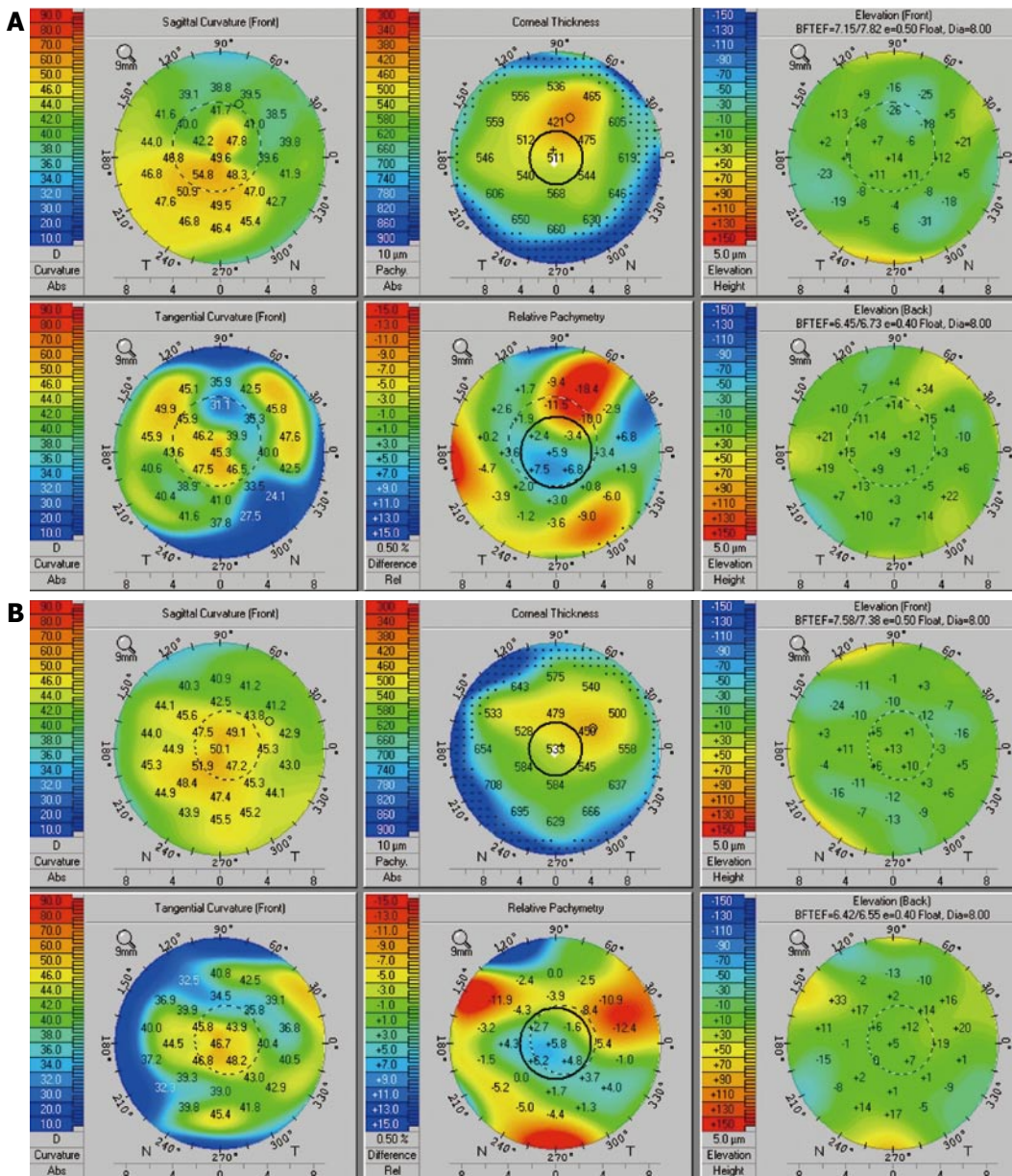


Figure 2 Oculus Pentacam of right eye (A), left eye (B) showing corneal thinning and irregular curvature.

formed at some stage in each eye. This may have been the result of previously large, anterior blebs causing tear film alteration<sup>[6]</sup>. In the left eye, a tissue allograft placed adjacent to the limbus during the Ahmed valve placement may have provided a nidus for dellen formation. The antimetabolite use during these surgeries may have accelerated this process. It is also possible that the fluid dynamics of the aqueous humor at the opening of the drainage device may play a role in inducing thinning superiorly through low grade inflammation that may impair normal corneal healing, repair, and maintenance functions. Retrograde flow of inflammatory cells has also been postulated as a source of corneal complications<sup>[7]</sup>, and focal endothelial irregularities related to drainage devices have been reported<sup>[8]</sup>.

A combination of chronic dellen formation and low grade inflammation in the posterior cornea likely led

to the diffuse superior corneal thinning and resultant astigmatism in this patient. We term this a dellen-like keratopathy, rather than a dellen keratopathy, due to the diffuse nature of the thinning that covered nearly 50% of the superior cornea and encroached into the visual axis, mimicking a superior keratoconus. To the patient, we recommended continued use of frequent lubrication and fitting for rigid gas-permeable contact lenses to maximize his visual potential. He has not followed up with us since his initial visit.

This is the first reported case of glaucoma drainage device associated keratopathy, a rare but serious complication of glaucoma surgery. Keratopathy resulting directly from device placement cannot be proven, and is likely multifactorial. The focal thinning immediately adjacent to both drainage devices suggests a causal relationship. Glaucoma and cornea specialists should be aware of this

possibility in patients presenting with worsening vision and corneal changes after glaucoma surgery.

## COMMENTS

### Case characteristics

The main symptom was blurry vision.

### Clinical diagnosis

The main clinical findings include corneal thinning, epithelial demarcation lines, and pathologic corneal curvature.

### Differential diagnosis

The differential diagnosis focuses on potential causes of corneal thinning and change in corneal curvature including dellen-like phenomena, antimetabolite complications, and aqueous humor fluid dynamics at the opening of the drainage devices.

### Laboratory diagnosis

No laboratory testing was performed.

### Imaging diagnosis

Imaging revealed dramatic change in refraction as well as irregular corneal curvature identified by topography.

### Pathological diagnosis

No specimens were obtained for pathology.

### Treatment

Treatment includes frequent lubrication and gas-permeable contact lenses.

### Related reports

Similar reports are included as references one and two.

### Term explanation

A dellen is an area of localized thinning and dryness of the cornea adjacent to an elevated area.

### Experiences and lessons

Dellen-like areas of corneal thinning can occur anterior to glaucoma drainage implants and should be treated in a similar manner as dellen.

### Peer review

Strengths include evidence of change in manifest refraction as well as significant

corneal curvature abnormalities on topographic imaging.

## REFERENCES

- 1 Lin CP, Liu YT, Chen CW. Corneal ectasia after trabeculectomy with mitomycin C application. *Br J Ophthalmol* 1999; **83**: 629 [PMID: 10917683 DOI: 10.1136/bjo.83.5.628b]
- 2 Baldassare RD, Brunette I, Desjardins DC, Amyot M. Corneal ectasia secondary to excessive ocular massage following trabeculectomy with 5-fluorouracil. *Can J Ophthalmol* 1996; **31**: 252-254 [PMID: 8872380]
- 3 Yoon PS, Singh K. Update on antifibrotic use in glaucoma surgery, including use in trabeculectomy and glaucoma drainage implants and combined cataract and glaucoma surgery. *Curr Opin Ophthalmol* 2004; **15**: 141-146 [PMID: 15021227 DOI: 10.1097/00055735-200404000-00015]
- 4 Tanihara H, Yokoi N, Komuro A, Honda Y, Kinoshita S. Prolonged impairment of peripheral corneal epithelium barrier function after successful trabeculectomy. *Am J Ophthalmol* 1997; **123**: 487-493 [PMID: 9124245]
- 5 Rajan MS, O'Brart DP, Patmore A, Marshall J. Cellular effects of mitomycin-C on human corneas after photorefractive keratectomy. *J Cataract Refract Surg* 2006; **32**: 1741-1747 [PMID: 17010877 DOI: 10.1016/j.jcrs.2006.05.014]
- 6 Soong HK, Quigley HA. Dellen associated with filtering blebs. *Arch Ophthalmol* 1983; **101**: 385-387 [PMID: 6830488 DOI: 10.1001/archophth.1983.01040010385006]
- 7 Topouzis F, Coleman AL, Choplin N, Bethlehem MM, Hill R, Yu F, Panek WC, Wilson MR. Follow-up of the original cohort with the Ahmed glaucoma valve implant. *Am J Ophthalmol* 1999; **128**: 198-204 [PMID: 10458176 DOI: 10.1016/S0002-9394(99)00080-X]
- 8 Kim CS, Yim JH, Lee EK, Lee NH. Changes in corneal endothelial cell density and morphology after Ahmed glaucoma valve implantation during the first year of follow up. *Clin Experiment Ophthalmol* 2008; **36**: 142-147 [PMID: 18352870 DOI: 10.1111/j.1442-9071.2008.01683.x]

P- Reviewers: Ghaffarieh A, Jhanji V, Shih YF S- Editor: Cui XM  
L- Editor: A E- Editor: Wang CH





## Rare presentation of self-resolving multifocal inflammatory pseudo-tumour of liver

Yogesh Puri, Dimitrios Lytras, Tu Vihn Luong, Giuseppe Kito Fusai

Yogesh Puri, Dimitrios Lytras, Clinical Fellow HPB and Liver Transplant Unit, Royal Free Hospital, London NW32QG, United Kingdom

Tu Vihn Luong, Department of Cellular Pathology, Royal Free London NHS Foundation Trust, London NW3 2QG, United Kingdom

Giuseppe Kito Fusai, Honorary Senior Lecturer University College London, HPB and Liver Transplant Unit, Royal Free Hospital, London NW32QG, United Kingdom

Author contributions: Puri Y contributed basic research, reviewing of literature, formatting and designing article; Lytras D critical reviewed of article in formatting and language; Luong TV provided histopathology pictures and reviewed article; Fusai GK guided throughout the article.

Correspondence to: Yogesh Puri, MS, MRCS, Ed, Clinical Fellow HPB and Liver Transplant Unit, Royal Free Hospital, Pond Street, London NW32QG, United Kingdom. [dryspuri@gmail.com](mailto:dryspuri@gmail.com)

Telephone: +44-20-77940500 Fax: +44-20-74726226

Received: October 15, 2013 Revised: December 21, 2013

Accepted: January 6, 2014

Published online: January 16, 2014

liver; Spontaneous regression

**Core tip:** Inflammatory pseudo-tumour (IPT) is extremely rare pre-operative diagnosis. It's a benign condition which does not require surgical management and it rarely self resolves. Our case so unique in appearance that IPT generally are solitary and if multiple generally confined on lobe of liver. In our case this tumour mimicked metastasis and presented in bilobar presentation. It resolved in 5 wk something which is never reported in medical literature.

Puri Y, Lytras D, Luong TV, Fusai GK. Rare presentation of self-resolving multifocal inflammatory pseudo-tumour of liver. *World J Clin Cases* 2014; 2(1): 5-8 Available from: URL: <http://www.wjgnet.com/2307-8960/full/v2/i1/5.htm> DOI: <http://dx.doi.org/10.12998/wjcc.v2.i1.5>

### Abstract

Inflammatory pseudo-tumour (IPT) of the liver is a rare condition with the appearance of a tumour-like space occupying lesion. Aetiology and natural history is not known for these benign lesions, as they are commonly diagnosed as malignant lesions and frequently undergo surgical resection since spontaneous resolution is very rare. Multifocal IPT involving both lobes of liver are rarely reported. Here we report a unique case of multifocal IPT of the liver which resolved spontaneously within 5 wk period.

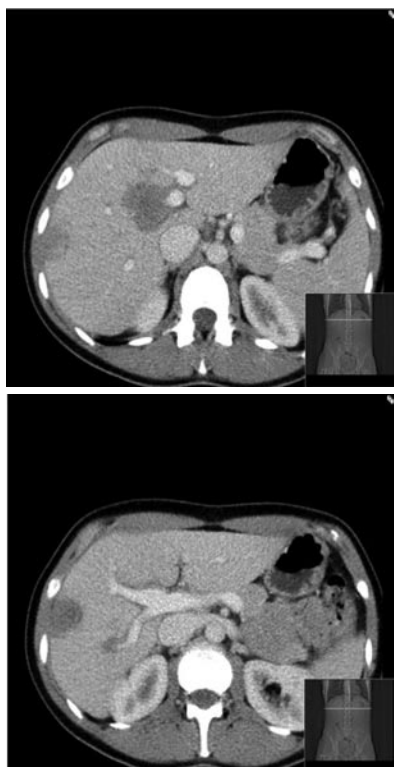© 2014 Baishideng Publishing Group Co., Limited. All rights reserved.

**Key words:** Multifocal; Inflammatory pseudo-tumour of

### INTRODUCTION

Inflammatory pseudo-tumours (IPTs) represent a challenging clinico-pathologic entity due to their similarity with malignant lesions. Histo-pathologically these tumours are inflammatory myofibroblastic tumours or plasma cell granulomas. They were initially observed in the lung by Brunn *et al* in 1939, and subsequently in the liver by Pack *et al*<sup>[1]</sup> in 1953. Although in the liver they may rarely lead to biliary obstruction, portal hypertension and even cirrhosis, their clinical importance is primarily related to the difficult differential diagnosis from malignant tumours<sup>[2]</sup>. For this reason the main pattern of diagnosis is on post-resection histopathological processing. However, spontaneous resolution of these lesions has been reported as well. Here we present a case of multifocal liver IPT, which spontaneously resolved without any type of therapeutic intervention.



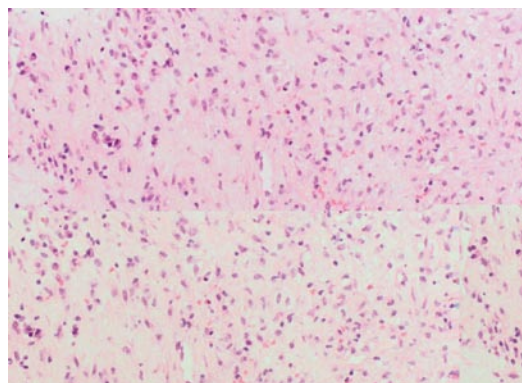


**Figure 1** Computed tomography at presentation demonstrating multiple liver lesions.

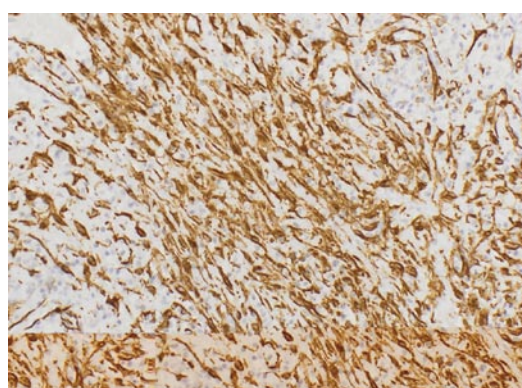
## CASE REPORT

A 37-year-old Caucasian female was referred to our tertiary hepatopancreatobiliary surgical unit with symptoms of weight loss and malaise since one month. There are no pre-existing medical co-morbidities. Bloods results showed derangement of liver function tests with alkaline phosphatase of 174 U/L (normal range: 38-126), aspartate transaminase of 40 U/L (9-36), alanine transaminase of 43 U/L (10-28), and normal bilirubin. Regarding inflammatory markers only erythrocyte sedimentation rate was raised at 58 mm/h (2-12). Abdominal ultrasound revealed multiple bilobar lesions in the liver with maximum size of 3.5 cm adjacent to the porta hepatis. Multidetector computed tomography with a liver protocol demonstrated 5 lesions, non-enhancing and of low attenuation highly suspicious of metastatic origin (Figure 1). According to decision of the multidisciplinary team meeting, the patient was considered harbouring metastatic diseases of unknown primary and she underwent detailed investigations with upper gastrointestinal endoscopy, positron emission tomography (PET) scan, mammography, chest computed tomography scan and tumour markers as well. Apart from an abnormal uptake in the right lobe of the liver on PET scan there was no pathology revealed in any other study.

After failure in locating the primary, a percutaneous biopsy of a liver lesion was decided as next step in the diagnostic workup. Histopathology revealed a parenchyma of normal architecture but replaced by collagenous stroma admixed with inflammation. The stroma was composed of dense areas of fibrosis, myofibroblasts and



**Figure 2** Lesional area composed of cytologically bland, spindle- or stellate-shaped cells arranged in a collagenous stroma with scattered inflammatory cells with predominance of plasma cells.



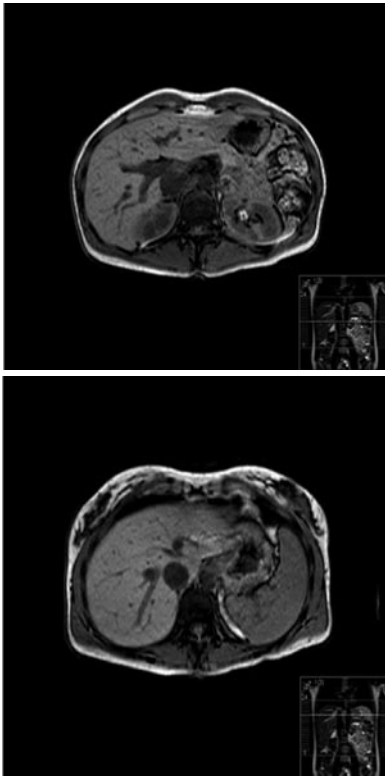
**Figure 3** Immunostaining for smooth muscle actin shows that many of the spindled cells are myofibroblasts.

fibroblasts. The inflammation consisted of a mixture of plasma cells, lymphocytes and eosinophils. Aggregates of xanthomatous histiocytes were also seen. There was mild portal inflammation. Also few epithelioid granulomas were seen. Immunohistochemistry showed positivity of the spindle cells for smooth muscle actin and negativity for ALK-1 (Figures 2 and 3). Epstein barr virus and cytomegalovirus immunostains were negative as well. Ziel-Neelsen showed no evidence of acid-fast bacilli in specimen. The tissue sample was considered as highly suggestive of inflammatory pseudo-tumour.

Based on the existed evidence and according to patient's consent, a wait and watch policy with follow-up imaging in 3 wk was decided. Magnetic resonance imaging (MRI) demonstrated significant reduction in the size of all liver lesions, measuring a maximum diameter of 1.5 cm as compared to the previous 3.5 cm. Follow-up MRI at two months showed almost complete resolution of the lesions. She was put on annual follow up with liver MRI and she remains asymptomatic and without evidence of any lesions on 2 year follow-up (Figure 4).

## DISCUSSION

An IPT is a benign, tumour like lesion characterised by



**Figure 4** Magnetic resonance imaging of the liver at 2 year follow up demonstrating complete resolution of liver lesions.

presence of certain chronic inflammatory cells namely plasma cells, lymphocytes and eosinophils. Although uncommon in presentation, they represent a challenge in differential diagnosis since they might lead to unnecessary surgical interventions if they are interpreted as malignant disease<sup>[3]</sup>.

Their aetiology remains unclear. IPTs are known to be associated with chronic inflammatory conditions like Crohn's disease<sup>[4]</sup>, autoimmune disorders related to IgG4<sup>[5]</sup> or infective agents like *Escherichia coli*<sup>[6]</sup>. The main location in the liver is the right lobe but multifocal IPTs although extremely rare have been described as well<sup>[7]</sup>. In the present case, there was multifocal, bi-lobe distribution of these lesions while there was no association with any chronic condition. This is first of its kind case report from our unit who performs around 100 liver resections per year.

Diagnosis of IPT is considered quite difficult since the radiological features of these tumours are often mistaken as of malignant origin<sup>[1,8]</sup>. Definitive diagnosis is only possible following fine needle aspiration cytology or core biopsy<sup>[9]</sup>. Histologically, these tumours appear as densely hyalinised structures with dense collagen matrix and a whorl like pattern infiltrated by chronic inflammatory cells<sup>[10]</sup>. Similar histological pattern was observed in the present case.

Natural history of IPT is not well defined since the current evidence is mainly after an incidental radiological diagnosis which often leads to surgical resection. However complete spontaneous resolution of these lesions has been also observed within months<sup>[10]</sup>. Raised values

of tumour markers as CA19-9 might confuse further the final diagnosis, but this was not observed in our case.

In conclusion, IPT might represent a considerable diagnostic challenge requiring high index of suspicion. The characteristic of spontaneous resolution highlights the necessity of regular, short-term, imaging follow-up in order to avoid aggressive unnecessary interventions.

## COMMENTS

### Case characteristics

A 37-years-old female without any medical co morbidities presented with short term history of weight loss and malaise and diagnosed with multiple liver lesions.

### Clinical diagnosis

Multiple liver lesions.

### Differential diagnosis

Metastatic disease in liver, multifocal hepatocellular carcinoma, inflammatory pseudotumour.

### Laboratory diagnosis

Bloods results showed derangement of liver function tests with alkaline phosphatase of 174 U/L (normal range: 38-126), aspartate transaminase of 40 U/L (9-36), alanine transaminase of 43 U/L (10-28), and normal Bilirubin. Erythrocyte sedimentation rate was raised at 58 mm/h (2-12). Other blood tests including tumour were normal.

### Imaging diagnosis

Multidetector computed tomography with a liver protocol demonstrated 5 lesions, non-enhancing and of low attenuation highly suspicious of metastatic origin.

### Pathological diagnosis

Histopathology revealed a parenchyma of normal architecture but replaced by collagenous stroma admixed with inflammation. The stroma was composed of dense areas of fibrosis, myofibroblasts and fibroblasts. Immunohistochemistry showed positivity of the spindle cells for smooth muscle actin.

### Treatment

This patient did not require any treatment as inflammatory pseudo-tumour self-resolved completely and patient was completely asymptomatic even at 2 years follow up.

### Related reports

There are very case reports of this particular condition but these lesions are more frequently diagnosed because of routine use of cross sectional imaging. It is important to be aware of this particular condition to spare patient of major surgical procedure.

### Experiences and lessons

The biology pathophysiology and disease history of this particular condition is not completely known. This case report highlights importance of serial radiological examinations and unique place of fine-needle aspiration cytology in diagnosis of inflammatory pseudo tumours.

### Peer review

This is a brief, easy to read and interesting case report in which the authors show a patient with a usual clinical presentation.

## REFERENCES

- 1 **PACK GT, BAKER HW.** Total right hepatic lobectomy; report of a case. *Ann Surg* 1953; **138**: 253-258 [PMID: 13066016 DOI: 10.1097/0000658-195308000-00012]
- 2 **Papachristou GI, Wu T, Marsh W, Plevy SE.** Inflammatory pseudotumor of the liver associated with Crohn's disease. *J Clin Gastroenterol* 2004; **38**: 818-822 [PMID: 15365413 DOI: 10.1097/00004836-200410000-00020]
- 3 **Yamaguchi J, Sakamoto Y, Sano T, Shimada K, Kosuge T.** Spontaneous regression of inflammatory pseudotumor of the liver: report of three cases. *Surg Today* 2007; **37**: 525-529 [PMID: 17522777 DOI: 10.1007/s00595-006-3433-0]
- 4 **Amankonah TD, Strom CB, Vierling JM, Petrovic LM.** Inflammatory pseudotumor of the liver as the first manifesta-

- tion of Crohn's disease. *Am J Gastroenterol* 2001; **96**: 2520-2522 [PMID: 11513216 DOI: 10.1111/j.1572-0241.2001.04079.x]
- 5 **Agaimy A**, Märkl B. Inflammatory angiolipoma of the liver: an unusual case suggesting relationship to IgG4-related pseudotumor. *Int J Clin Exp Pathol* 2013; **6**: 771-779 [PMID: 23573326]
- 6 **Kim YW**, Lee JG, Kim KS, Yoon DS, Lee WJ, Kim BR, Shin EA, Park YN, Choi JS. Inflammatory pseudotumor of the liver treated by hepatic resection: a case report. *Yonsei Med J* 2006; **47**: 140-143 [PMID: 16502497 DOI: 10.3349/ymj.2006.47.1.140]
- 7 **Mortelé KJ**, Wiesner W, de Hemptinne B, Elewaut A, Praet M, Ros PR. Multifocal inflammatory pseudotumor of the liver: dynamic gadolinium-enhanced, ferumoxides-enhanced, and mangafodipir trisodium-enhanced MR imaging findings. *Eur Radiol* 2002; **12**: 304-308 [PMID: 11870426 DOI: 10.1007/s003300101015]
- 8 **Schmid A**, Jänig D, Bohuszlavizki A, Henne-Bruns D. Inflammatory pseudotumor of the liver presenting as incidentaloma: report of a case and review of the literature. *Hepato-gastroenterology* 1996; **43**: 1009-1014 [PMID: 8884330]
- 9 **Sari A**, Tunakan M, Ünsal B, Ekinci N, Rezanko T, Elçin F, Aydoğdu Z. Inflammatory pseudotumor of the liver diagnosed by needle biopsy: report of three cases (one with neuroendocrine tumor of the rectum and lung). *Turk J Gastroenterol* 2010; **21**: 308-312 [PMID: 20931439]
- 10 **Rosa B**, Moutinho-Ribeiro P, Pereira JM, Fonseca D, Lopes J, Amendoeira I, Cotter J. Ghost tumor: an inflammatory pseudotumor of the liver. *Gastroenterol Hepatol (N Y)* 2012; **8**: 630-633 [PMID: 23483864]

**P- Reviewers:** Ong HT, Velayos B **S- Editor:** Cui XM  
**L- Editor:** A **E- Editor:** Wang CH



## Resection of giant gastric GIST with a new generation ultrasonic scalpel device

Crispin Schneider, David F Hewin

Crispin Schneider, Division of Surgery and Interventional Science, University College London, Bloomsbury Campus, London WC1E 6AU, United Kingdom

Crispin Schneider, David F Hewin, Department of General Surgery, Gloucestershire Royal Hospital, Gloucester GL1 3NN, United Kingdom

**Author contributions:** Schneider C collected images, literature search, writing the manuscript; Hewin DF reviewed and edited the manuscript.

**Author contributions:** Crispin Schneider, MRCS, MD, Division of Surgery and Interventional Science, University College London, Bloomsbury Campus, Medical School Building, 4<sup>th</sup> Floor, 74 Huntley Street, London WC1E 6AU, United Kingdom. [crispin.schneider.13@ucl.ac.uk](mailto:crispin.schneider.13@ucl.ac.uk)

Telephone: +44-207-6796490 Fax: +44-207-6796470

Received: November 19, 2013 Revised: December 24, 2013

Accepted: January 7, 2014

Published online: January 16, 2014

### Abstract

Gastrointestinal stroma tumours (GIST) are the most common mesenchymal tumour in the digestive tract and commonly found in the stomach. The patient described in this report presented with collapse and a palpable abdominal mass. He was found to have a large gastric GIST that penetrated through the mesocolon. Resection of the GIST was technically challenging but facilitated by a new generation ultrasonic scalpel device. In resection of gastric cancer the use of ultrasonic scalpels has been shown to reduce operating time, blood loss and length of stay. We feel that in technically challenging cases of gastric GIST the use of an ultrasonic scalpel device may be justified as well.

© 2014 Baishideng Publishing Group Co., Limited. All rights reserved.

**Key words:** Gastrointestinal stroma tumours; Ultrasonic scalpel; Harmonic; Giant tumour; Stomach

**Core tip:** This case report about a giant gastric gastrointestinal stroma tumours focuses on surgical technique. Because of its bulk the giant tumour was penetrating through the transverse mesocolon. Dissecting the tumour of the mesocolon and avoiding a concomitant colectomy was facilitated by using a new generation ultrasonic scalpel device.

Schneider C, Hewin DF. Resection of giant gastric GIST with a new generation ultrasonic scalpel device. *World J Clin Cases* 2014; 2(1): 9-11 Available from: URL: <http://www.wjgnet.com/2307-8960/full/v2/i1/9.htm> DOI: <http://dx.doi.org/10.12998/wjcc.v2.i1.9>

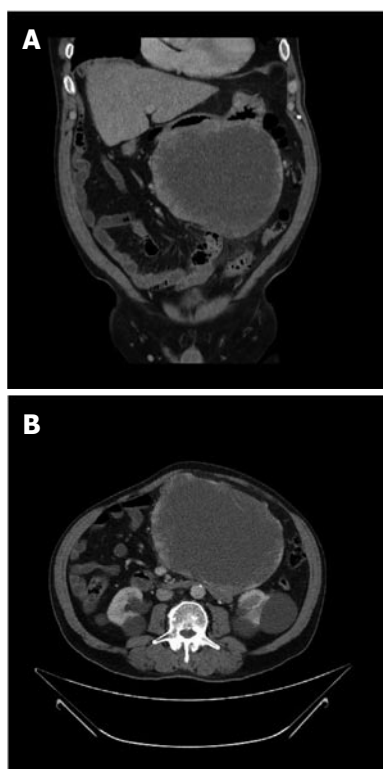
### INTRODUCTION

Gastrointestinal stromal tumours (GISTs) are the most common mesenchymal tumour of the digestive tract. Most GISTs are found in the stomach and although bleeding is a frequent complication, they usually present with non-specific symptoms<sup>[1]</sup>. We present a case of a giant gastric GIST in a patient presenting with collapse and a palpable abdominal mass. Intra-operatively the tumour was found to penetrate the transverse mesocolon. Resection of the GIST without requiring a colectomy was facilitated using a new generation ultrasonic scalpel device (HARMONIC ACE<sup>®</sup> +).

### CASE REPORT

This 71-year-old man with a past medical history of hypertension and peptic ulcer disease was admitted to the local Emergency Department with a sudden onset of abdominal pain followed by collapse. Clinical examination revealed a large epigastric abdominal mass. The patient was haemodynamically stable and initial full blood count and biochemistry tests were unremarkable. The patient



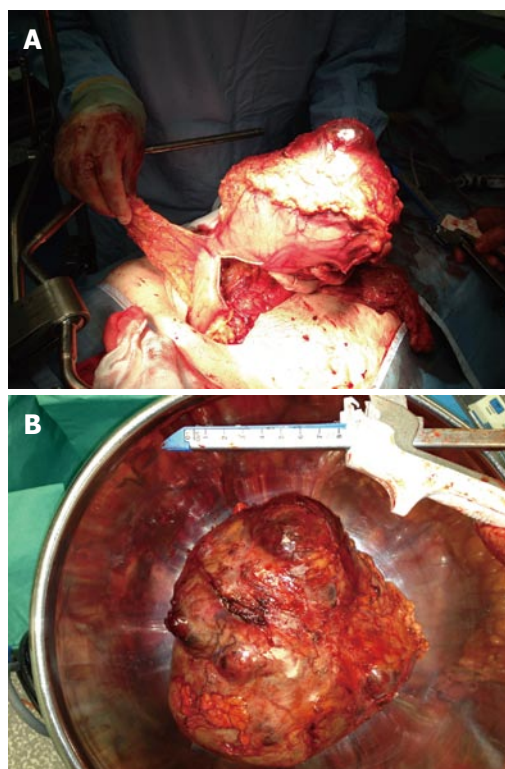


**Figure 1** Preoperative computed tomography scan of the abdomen and pelvis showing a large mass inseparable from the greater curve of the stomach. A: Coronal view; B: Axial view.

was discharged home and booked in for an ultrasound scan (USS), which revealed a large heterogeneous soft tissue mass extending from the epigastrium into the pelvis. CT scan of the abdomen and pelvis was performed immediately, revealing a large mass inseparable from the greater curve of the stomach and the body of the pancreas. A large proportion of the tumour had low attenuation indicating cystic change or necrosis. The Radiology report concluded that the differential diagnosis should include cystadenocarcinoma of the pancreas, neuroendocrine tumour and GIST (Figure 1). The patient was urgently referred to the oesophago-gastric department. After multi-disciplinary discussion and outpatient review the patient was scheduled for surgery.

### Surgery

The operation was performed *via* a midline laparotomy. Intraoperative findings were that of a large tumour arising from the greater curve of the stomach. The tumour was firmly attached and penetrating completely through the mid-portion of the transverse mesocolon, without invading it. It was difficult to establish a safe plane of dissection between tumour and colonic vessels. At this stage the HARMONIC ACE®+ proved valuable as it aided in the careful separation of tumour and mesocolon. A novel feature added to the latest generation of the device is the audible “tissue sensing” feedback. As the device is activated a constant tone starts, similar to older versions. The dissecting shears “sense” when tissues have been divided and the quality of tone changes which signals to



**Figure 2** Fully mobilised gastrointestinal stroma tumours attached to the distal stomach (A) and Resected specimen (B).

the surgeon to stop activation of the device. In our view the main benefits of this feature were reduced heat dissipation thereby enabling us to dissect the tumour off the transverse mesocolon without inadvertently damaging the colonic blood supply. There was also a marked increase in speed of dissection as the audible feedback reduced the overall activation time during dissection.

The gastro-colic omentum was divided and the tumour dissected from the mesocolon where possible. Several densely adherent branches of the middle colic vessels were sacrificed and the transverse colon checked for viability. The tumour was carefully dissected from its attachments to the duodenum and pancreas. A standard distal gastrectomy with a retrocolic Roux-en-Y reconstruction was carried out.

The patient made an unremarkable recovery and was discharged on the seventh postoperative day. He was re-admitted on the 19<sup>th</sup> postoperative day with haematemesis. Gastroscopy was performed and showed ulcerations around the staple line of the gastro-jejunal anastomosis but no active bleeding was found. The patient remained haemodynamically stable throughout his second admission and was discharged after two days.

### Postoperative outcome

Histopathological macroscopic examination revealed a greyish, pale, soft tumour with cystic haemorrhagic and necrotic areas. Tumour weight was measured at 2.6 kg and dimensions were 19 cm × 18 cm × 16 cm (Figure 2). A massive central area of haemorrhage was noted. On

immunostaining the tumour stained positive for KIT (CD 117) and CD 34. Mitotic rate was seven out of ten and immunostaining for Ki-67 showed an increased proliferation index of seven percent. Microscopic examination and immunostaining were compatible with a GIST of the spindle cell type. Resected lymph nodes did not show any metastatic spread. All of the above histopathological findings were congruent with a completely excised GIST with high risk for malignant potential. Following further multidisciplinary team discussion the patient was referred to oncology services for adjuvant chemotherapy.

## DISCUSSION

This case highlights an unusual clinical presentation of a Gastrointestinal Stromal Tumour and a successful approach to the intraoperative challenges.

The patient presented with acute collapse and an abdominal mass. Only a small number of GIST presenting as a palpable abdominal mass have been reported in the world literature<sup>[2]</sup>. The patient's collapse was probably a result of an acute bleed into the tumour; however no clinical or haematological signs of haemodynamic compromise were evident on presentation to emergency services.

The challenges of the operation described above were the large size of the tumour and the penetration of its bulk through the transverse mesocolon. The tissue sensing properties of the HARMONIC ACE<sup>®</sup> enabled us to preserve most of the middle colic vessels, thereby avoiding the added trauma of a concomitant colectomy.

To our knowledge, use of an ultrasonic scalpel has not been reported in open surgery for gastric GIST, however its benefits have been reported in the open resection of gastric cancer. One group found the device to decrease operating time, blood loss and operator stress during lymphadenectomy<sup>[3]</sup>. These findings were recently confirmed in a trial that, in addition to the above, showed a shorter length of hospital stay and a higher number of lymph nodes harvested in the group undergoing gastrectomy with an ultrasonic scalpel<sup>[4]</sup>. Overall hospitalisation costs were found to be equal between the traditional and ultrasonic scalpel surgery groups.

This technically challenging case demonstrates that utilisation of the new generation ultrasonic scalpel in the open resection of giant GIST of the stomach is feasible. The device's tissue sensing technology may help in preserving vital structures and therefore may lessen the extent of resection, reducing morbidity.

## COMMENTS

### Case characteristics

A technically challenging case of a giant gastric gastrointestinal stromal tumours (GIST) resection facilitated by the HARMONICACE<sup>®</sup> ultrasonic scalpel.

### Clinical diagnosis

A giant gastric GIST presenting with collapse and a palpable abdominal mass.

### Differential diagnosis

The main differential diagnosis in a patient presenting with collapse and an abdominal mass is an abdominal aortic aneurysm rupture.

### Laboratory diagnosis

Routine blood tests performed on admission included a full blood count, liver function tests, urea and electrolytes and C-reactive protein; all of which were unremarkable.

### Imaging diagnosis

The abdominal ultrasound scan showed a large abdominal mass and computer tomography revealed a large tumour inseparable from the greater curve of the stomach with a central necrotic area.

### Pathological diagnosis

Histopathological macroscopic examination revealed a greyish, pale, soft tumour which on microscopic examination and immunostaining was compatible with a GIST.

### Treatment

Resection of the GIST was performed via a midline laparotomy and following multidisciplinary team discussion adjuvant treatment with Imatinib was commenced.

### Term explanation

GIST. Ultrasonic scalpel - a surgical device that cuts and coagulates tissues by generating friction.

### Experiences and lessons

Dissection in proximity to vulnerable structures may be facilitated by the HARMONICACE<sup>®</sup> ultrasonic scalpel.

### Peer review

Authors describe a case of a giant gastric GIST respected by HARMONIC ACE+ (as stated in the title). The manuscript is well written. Gastric GISTs are very well known entity.

## REFERENCES

- 1 Rossi CR, Mocellin S, Mencarelli R, Foletto M, Pilati P, Nitti D, Lise M. Gastrointestinal stromal tumors: from a surgical to a molecular approach. *Int J Cancer* 2003; **107**: 171-176 [PMID: 12949790 DOI: 10.1002/ijc.11374]
- 2 Patil S, Jain S, Kaza RC, Chamberlain RS. Giant gastrointestinal stromal tumor presenting as a palpable abdominal mass: an unusual presentation. *ISRN Surg* 2011; **2011**: 894829 [PMID: 22084785 DOI: 10.5402/2011/894829]
- 3 Inoue K, Nakane Y, Michiura T, Yamada M, Mukaide H, Fukui J, Miki H, Ueyama Y, Nakatake R, Tokuhara K, Iwamoto S, Yanagimoto H, Toyokawa H, Satoi S, Kwon AH. Ultrasonic scalpel for gastric cancer surgery: a prospective randomized study. *J Gastrointest Surg* 2012; **16**: 1840-1846 [PMID: 22833440 DOI: 10.1007/s11605-012-1970-y]
- 4 Huang Y, Mu GC, Qin XG, Lin JL, Liu C, Chen ZB, Zeng YJ. The application of ultrasonic harmonic scalpel in the radical surgery of gastric cancer. *Clin Transl Oncol* 2013; **15**: 932-937 [PMID: 23519537 DOI: 10.1007/s12094-013-1026-0]

P- Reviewers: Beegun I, Brcic I, Desai DJ S- Editor: Qi Y  
L- Editor: A E- Editor: Wang CH



## Epilepsy triggered by mefloquine in an adult traveler to Uganda

Federico Gobbi, Andrea Rossanese, Dora Buonfrate, Andrea Angheben, Chiara Postiglione, Zeno Bisoffi

Federico Gobbi, Andrea Rossanese, Dora Buonfrate, Andrea Angheben, Zeno Bisoffi, Department of Tropical Diseases, Sacro Cuore-Don Calabria Hospital, 37024 Verona, Italy  
Chiara Postiglione, Prevention Department, ULSS 20 Verona, 37122 Verona, Italy

**Author contributions:** Gobbi F wrote the manuscript; Rossanese A and Postiglione C managed the patient; Buonfrate D and Angheben A performed the literature search; Bisoffi Z revised the manuscript; all authors have read and approved the final version to be published.

**Correspondence to:** Federico Gobbi, MD, PhD, Department of Tropical Diseases, Sacro Cuore-Don Calabria Hospital, Via Don A Sempredoni 5, Negrar, 37024 Verona, Italy. [federico.gobbi@sacrocuore.it](mailto:federico.gobbi@sacrocuore.it)

Telephone: +39-45-6013563 Fax: +39-45-6013694

Received: September 25, 2013 Revised: November 7, 2013

Accepted: December 12, 2013

Published online: January 16, 2014

### Abstract

We report a case of a traveler who visited Uganda for 8 d, and took mefloquine one tablet/week for malaria prophylaxis. After the second dose, he suffered from two episodes of loss of consciousness with seizures, therefore mefloquine was discontinued. During the flight back after full recovery, seizures reoccurred while he was on board, he was disembarked in Addis Ababa and then transferred to Nairobi. After repatriation to Italy, he experienced four other similar episodes. The patient was still on full dose anticonvulsant therapy one year and a half after, as any attempt at reduced dose was unsuccessful. Currently, three agents (mefloquine, atovaquone/proguanil, and doxycycline) are recommended for malaria chemoprophylaxis, with similar efficacy but different adverse event profiles, regimens, and prices. Considering that mefloquine is associated with a higher risk of neurologic and psychiatric adverse events than the alternative regimens, we suggest considering mefloquine as a second line choice after atovaquone/progua-

nil and doxycycline for short-term travelers.

© 2014 Baishideng Publishing Group Co., Limited. All rights reserved.

**Key words:** Mefloquine; Neuropsychiatric disorders; Epilepsy; Antimalarial chemoprophylaxis; Side effects

**Core tip:** We report a case of epilepsy due to mefloquine chemoprophylaxis. Considering that mefloquine is associated with a higher risk of neurologic and psychiatric adverse events than the alternative regimens, we suggest considering mefloquine as a second line choice after atovaquone/proguanil and doxycycline for short-term travelers.

Gobbi F, Rossanese A, Buonfrate D, Angheben A, Postiglione C, Bisoffi Z. Epilepsy triggered by mefloquine in an adult traveler to Uganda. *World J Clin Cases* 2014; 2(1): 12-15 Available from: URL: <http://www.wjgnet.com/2307-8960/full/v2/i1/12.htm> DOI: <http://dx.doi.org/10.12998/wjcc.v2.i1.12>

### INTRODUCTION

According to most international guidelines<sup>[1-4]</sup>, atovaquone/proguanil, doxycycline and mefloquine are all indicated as the first choice for the chemoprophylaxis of *Plasmodium falciparum* malaria. The efficacy of the three drugs seems to be comparable<sup>[5]</sup>, but side effects and costs are different. Although a causal relationship between the drug intake and a severe side effect is usually difficult to demonstrate, it is well known that mefloquine is associated with a high risk of neurologic and psychiatric disorders (NPD). Weinke *et al*<sup>[6]</sup> estimated that one of 13000 travelers receiving mefloquine chemoprophylaxis suffers from serious central nervous system reactions. Barrett *et al*<sup>[7]</sup>, in a postal and telephone survey, reported that 0.7% of



travelers taking mefloquine had disabling NPD.

Adverse events related to mefloquine mostly occur in people with a past history of seizures or manic-depressive illness<sup>[8]</sup>, but in literature there are reports of cases of seizures in travelers, with no previous personal or family history of epilepsy, after taking mefloquine for treatment<sup>[9]</sup> or prophylaxis<sup>[10]</sup>.

## CASE REPORT

A 40-year-old Italian traveler visited Uganda for 8 d, and took mefloquine one tablet/week for malaria prophylaxis. His weight was 70 kg. His clinical history was unremarkable and he had no history of alcohol or tobacco abuse. He was vaccinated against yellow fever, hepatitis A and tetanus-diphtheria. Upon arrival in Kampala, after the second dose of mefloquine, he suffered from two subsequent episodes of grand mal seizure, therefore mefloquine was discontinued. The duration of the two episodes was about 5 min and the patient remained unconscious for 10 min. During the flight back after full recovery, seizures reoccurred while he was on board, so he was disembarked in Addis Ababa. One further episode occurred at the airport and another one upon urgent admission to the hospital. He was then transferred to Kenya Nairobi Hospital under suspicion of meningitis or cerebral malaria (both were later ruled out), where he started on phenytoin 100 mg twice a day.

After repatriation to Italy, two weeks after the first crisis, an electroencephalogram showed diffuse epileptiform abnormalities, while a brain-RM was negative. Then, he experienced four similar episodes and was treated with diazepam. Moreover, phenytoin was replaced by levetiracetam 500 mg twice a day. Levetiracetam was stopped after 6 mo, but subsequent seizure episodes required another course of anticonvulsant prophylaxis, with sodium valproate 500 mg twice a day. The patient was still on full dose anticonvulsant therapy one year later, as any attempt at dose reduction was unsuccessful.

## DISCUSSION

Currently, three drugs (mefloquine, atovaquone/proguanil, and doxycycline) are recommended for malaria chemoprophylaxis, with similar efficacy but different adverse event profiles, regimens, and prices<sup>[5]</sup>. The choice of the different drugs depends on the levels of malaria transmission and presence of drug resistance in the destination area, on specific characteristics of the traveler (*e.g.*, underlying health conditions, possible pregnancy, compliance to daily/weekly therapies), on the duration and purpose of travel and on costs. Jacquerioz *et al.*<sup>[11]</sup>, in a review of drugs for preventing malaria in travelers, conclude that atovaquone-proguanil and doxycycline are the best tolerated agents and mefloquine is associated with

adverse NPD. NPD includes two categories of symptoms: central and peripheral nervous system disorders (including headache, dizziness, vertigo, seizures) and psychiatric disorders (including major psychiatric disorders, anxiety and sleep disturbances)<sup>[12]</sup>. Controlled studies have shown a significant excess of NPD in mefloquine users<sup>[5,13-16]</sup>. Moreover, in a recent study, van Essen *et al.*<sup>[17]</sup> suggest that mefloquine disturbs motor learning skills. Considering NPD as potentially severe and dangerous adverse side effects and the availability of drugs with equivalent efficacy, the new Italian indications for malaria prophylaxis<sup>[18]</sup> proposed mefloquine as a second line choice after atovaquone/proguanil and doxycycline for short-term travelers. However, mefloquine keeps playing a fundamental role for specific groups of travelers: pregnant and breastfeeding women, long-term travelers, adults and children visiting friends and relatives (VFR)<sup>[19]</sup>. Travelling to malaria endemic areas during pregnancy is contraindicated because this disease is an important cause of stillbirth, spontaneous abortion or maternal death<sup>[20]</sup>. However, for pregnant women who cannot defer their travel (mostly VFR), mefloquine is the only option, as doxycycline is contraindicated in pregnancy and, although proguanil is considered safe and no teratogenicity has been observed in animal studies using atovaquone, there are no sufficient data about safety of atovaquone/proguanil. In fact, mefloquine has been proved to be safe in the first trimester: according to Schlagenhauf *et al.*<sup>[21]</sup>, birth defect prevalence and fetal loss after mefloquine exposure in pregnancy were comparable in prospectively monitored cases to background rates. For long-term travelers (nonimmunized travelers who visit malaria endemic areas for a period of six mo or longer), malaria chemoprophylaxis is controversial. Although the risk of malaria increases with longer stays, the adherence to chemoprophylaxis decreases over time. Steffen *et al.*<sup>[22]</sup> reported that compliance with chemoprophylaxis was reported by 57.0% of travellers who spent less than 3 mo in Africa, compared with 29.2% who stayed for 3-12 mo. In case chemoprophylaxis is recommended, mefloquine, if well tolerated, remains a good option in alternative to doxycycline: the weekly dose facilitates a good adherence. Long-term atovaquone/proguanil is now registered in Italy, but a long-term chemoprophylaxis is too expensive. van Riemsdijk *et al.*<sup>[16]</sup> found that NPD occurred more frequently in females and were more common in first-time users. Usually females weigh less than males, so we suggest to modulate the mefloquine dosage by body weight (*i.e.*, people weighing between 40 and 60 kg should take 75% of the tablet)<sup>[4]</sup>. For a traveler who takes mefloquine for the first time, it is advisable to start chemoprophylaxis 3 wk before travelling, because adverse effects usually appear at the first dose. Lobel *et al.*<sup>[23]</sup> found that the frequency of these events declined with the increasing duration of prophylaxis. Travelers who have taken mefloquine before and had no NPD can usually take this drug again. For many VFR families,



who stay long in high-risk areas, mefloquine represents a good option because of its low cost and weekly administration. Moreover, mefloquine is effective and well tolerated in children weighing < 20 kg<sup>[24]</sup>. Considering that mefloquine is often the only drug that can be prescribed for young children VFR, because doxycycline is contraindicated in children < 8 years and atovaquone/proguanil is generally too expensive, mefloquine is considered the best option for VFR families.

In conclusion, we suggest considering mefloquine as a second choice for short-term (less than one mo) travelers; however, mefloquine remains a good option, in alternative to doxycycline, for long-term travelers and the first choice for pregnant women and VFR families.

## COMMENTS

### Case characteristics

Grand mal seizures after taking mefloquine for malaria prophylaxis.

### Clinical diagnosis

The duration of each of the two episodes of grand mal seizures was about 5 min and the patient remained unconscious for 10 min.

### Differential diagnosis

Epilepsy due to other causes.

### Imaging diagnosis

Electroencephalogram showed diffuse epileptiform abnormalities, while a brain-RM was negative.

### Treatment

The patient was treated with phenytoin 100 mg twice a day, then with levetiracetam 500 mg twice a day, and then with sodium valproate 500 mg twice a day.

### Related reports

Adverse events related to mefloquine mostly occur in people with a past history of seizures or manic-depressive illness, but in literature there are also reports of cases of seizures in travelers who had no previous personal or family history of epilepsy, after taking mefloquine for treatment or prophylaxis.

### Experiences and lessons

Authors suggest considering mefloquine as a second choice for short-term (less than one mo) travelers; however, mefloquine remains a good option, in alternative to doxycycline, for long-term travelers and the first choice for pregnant women and visiting friends and relatives families.

### Peer review

This article highlights possible severe side effects of mefloquine and suggest to consider other drugs as a first choice for malaria chemoprophylaxis.

## REFERENCES

- 1 **World Health Organization.** International Travel and Health. Available from: URL: <http://www.who.int/ith>
- 2 **Centers for Disease Control and Prevention.** Health Information for International Travel 2012. The yellow book. Available from: URL: <http://www.cdc.gov/yellowbook>
- 3 **Lalloo DG, Shingadia D, Pasvol G, Chiodini PL, Whitty CJ, Beeching NJ, Hill DR, Warrell DA, Bannister BA.** UK malaria treatment guidelines. *J Infect* 2007; **54**: 111-121
- 4 **Deutsche Gesellschaft für Tropenmedizin und Internationale Gesundheit (DTG).** Empfehlungen zur Malaravorbereitung. Available from: URL: <http://www.dtg.org>
- 5 **Schlagenhauf P, Tschopp A, Johnson R, Nothdurft HD, Beck B, Schwartz E, Herold M, Krebs B, Veit O, Allwinn R, Steffen R.** Tolerability of malaria chemoprophylaxis in non-immune travellers to sub-Saharan Africa: multicentre, randomised, double blind, four arm study. *BMJ* 2003; **327**: 1078 [PMID: 14604928 DOI: 10.1136/bmj.327.7423.1078]
- 6 **Weinke T, Trautmann M, Held T, Weber G, Eichenlaub D, Fleischer K, Kern W, Pohle HD.** Neuropsychiatric side effects after the use of mefloquine. *Am J Trop Med Hyg* 1991; **45**: 86-91 [PMID: 1867351]
- 7 **Barrett PJ, Emmins PD, Clarke PD, Bradley DJ.** Comparison of adverse events associated with use of mefloquine and combination of chloroquine and proguanil as antimalarial prophylaxis: postal and telephone survey of travellers. *BMJ* 1996; **313**: 525-528 [PMID: 8789977]
- 8 **Bem JL, Kerr L, Stuerchler D.** Mefloquine prophylaxis: an overview of spontaneous reports of severe psychiatric reactions and convulsions. *J Trop Med Hyg* 1992; **95**: 167-179 [PMID: 1597872]
- 9 **Schiemann R, Coulaud JP, Bouchaud O.** Seizures after anti-malarial medication in previously healthy persons. *J Travel Med* 2000; **7**: 155-156 [PMID: 11179947]
- 10 **Pous E, Gascón J, Obach J, Corachan M.** Mefloquine-induced grand mal seizure during malaria chemoprophylaxis in a non-epileptic subject. *Trans R Soc Trop Med Hyg* 1995; **89**: 434 [PMID: 7570889]
- 11 **Jacquerioz FA, Croft AM.** Drugs for preventing malaria in travellers. *Cochrane Database Syst Rev* 2009; **(4)**: CD006491 [PMID: 19821371 DOI: 10.1002/14651858.CD006491.pub2]
- 12 **Schlagenhauf P, Adamcova M, Regep L, Schaerer MT, Rhein HG.** The position of mefloquine as a 21st century malaria chemoprophylaxis. *Malar J* 2010; **9**: 357 [PMID: 21143906 DOI: 10.1186/1475-2875-9-357]
- 13 **Meier CR, Wilcock K, Jick SS.** The risk of severe depression, psychosis or panic attacks with prophylactic antimalarials. *Drug Saf* 2004; **27**: 203-213 [PMID: 14756582]
- 14 **Overbosch D, Schilthuis H, Bienze U, Behrens RH, Kain KC, Clarke PD, Toovey S, Knobloch J, Nothdurft HD, Shaw D, Roskell NS, Chulay JD.** Atovaquone-proguanil versus mefloquine for malaria prophylaxis in nonimmune travelers: results from a randomized, double-blind study. *Clin Infect Dis* 2001; **33**: 1015-1021 [PMID: 11528574 DOI: 10.1086/322694]
- 15 **van Riemsdijk MM, Sturkenboom MC, Ditters JM, Ligthelm RJ, Overbosch D, Stricker BH.** Atovaquone plus chloroquine versus mefloquine for malaria prophylaxis: a focus on neuropsychiatric adverse events. *Clin Pharmacol Ther* 2002; **72**: 294-301 [PMID: 12235450 DOI: 10.1067/mcp.2002.127113]
- 16 **van Riemsdijk MM, Ditters JM, Sturkenboom MC, Tulen JH, Ligthelm RJ, Overbosch D, Stricker BH.** Neuropsychiatric events during prophylactic use of mefloquine before travelling. *Eur J Clin Pharmacol* 2002; **58**: 441-445 [PMID: 12242605 DOI: 10.1007/s00228-002-0492-z]
- 17 **van Essen TA, van der Giessen RS, Koekkoek SK, Vanderwerf F, Zeeuw CI, van Genderen PJ, Overbosch D, de Jeu MT.** Anti-malaria drug mefloquine induces motor learning deficits in humans. *Front Neurosci* 2010; **4**: 191 [PMID: 21151372 DOI: 10.3389/fnins.2010.00191]
- 18 **Bisoffi Z, Gobbi F, Calleri G.** Mefloquine restrictions, anti-malarial drug safety and the new Italian recommendations for malaria prophylaxis. *Travel Med Infect Dis* 2013; Epub ahead of print [PMID: 24332760 DOI: 10.1016/j.tmaid.2013.09.009].
- 19 **Dubey JP, Lindsay DS.** Fatal *Neospora caninum* infection in kittens. *J Parasitol* 1989; **75**: 148-151 [PMID: 2493087 DOI: 10.1128/jcmr.00059-07]
- 20 **Desai M, ter Kuile FO, Nosten F, McGready R, Asamoia K, Brabin B, Newman RD.** Epidemiology and burden of malaria in pregnancy. *Lancet Infect Dis* 2007; **7**: 93-104 [PMID: 17251080 DOI: 10.1016/s1473-3099(07)70021-x]
- 21 **Schlagenhauf P, Blumentals WA, Suter P, Regep L, Vital-Durand G, Schaerer MT, Boutros MS, Rhein HG, Adamcova M.** Pregnancy and fetal outcomes after exposure to mefloquine in the pre- and periconception period and during pregnancy. *Clin Infect Dis* 2012; **54**: e124-e131 [PMID: 2242605 DOI: 10.1007/s00228-002-0492-z]

22495078 DOI: 10.1093/cid/cis215]

- 22 **Steffen R**, Heusser R, Mächler R, Bruppacher R, Naef U, Chen D, Hofmann AM, Somaini B. Malaria chemoprophylaxis among European tourists in tropical Africa: use, adverse reactions, and efficacy. *Bull World Health Organ* 1990; **68**: 313-322 [PMID: 2393977]
- 23 **Lobel HO**, Miani M, Eng T, Bernard KW, Hightower AW,

Campbell CC. Long-term malaria prophylaxis with weekly mefloquine. *Lancet* 1993; **341**: 848-851 [PMID: 8096560]

- 24 **Schlagenhauf P**, Adamcova M, Regep L, Schaerer MT, Bansod S, Rhein HG. Use of mefloquine in children - a review of dosage, pharmacokinetics and tolerability data. *Malar J* 2011; **10**: 292 [PMID: 21981927 DOI: 10.1186/1475-2875-10-292]

**P- Reviewers:** Cavanna AE, Juan DS **S- Editor:** Gou SX  
**L- Editor:** Ma JY **E- Editor:** Wang CH



## Two rare cases of benign hyperlipasemia in children

Elena Lionetti, Ruggiero Francavilla, Salvatore Leonardi, Stefania Tomarchio, Alessia Gennaro, Chiara Franzonello, Mario La Rosa

Elena Lionetti, Salvatore Leonardi, Stefania Tomarchio, Alessia Gennaro, Chiara Franzonello, Mario La Rosa, Department of Medical and Pediatric Science, University of Catania, 95123 Catania, Italy

Ruggiero Francavilla, Department of Paediatrics, University of Bari, 70100 Bari, Italy

**Author contributions:** Lionetti E, Francavilla R, Leonardi S, Tomarchio S, Gennaro A, Franzonello C and La Rosa M contributed to the acquisition of data; Lionetti E, Leonardi S, Tomarchio S, Gennaro A and Franzonello C drafted the report; all authors contributed to the revision of the report.

**Correspondence to:** Elena Lionetti, MD, Department of Medical and Pediatric Science, University of Catania, Via Santa Sofia 78, 95123 Catania, Italy. [elenalionetti@inwind.it](mailto:elenalionetti@inwind.it)

Telephone: +39-95-3782939 Fax: +39-95-3782385

Received: October 6, 2013 Revised: November 5, 2013

Accepted: December 9, 2013

Published online: January 16, 2014

### Abstract

Gullo's syndrome is a newly identified condition characterized by a chronic elevation of pancreatic amylase and/or lipase in the absence of pancreatic disease. Until now, only one case of benign isolated hyperlipasemia in children has been recorded. We describe two children with benign and not familial increase of serum lipase. Case 1: a six year old girl presented with occasional discovery of serum lipase elevation. Medical history was silent for pancreatic hyperenzymemia. The screening for possible causes for elevated lipase (genetic, autoimmune and infectious diseases) was normal. The serum lipase increased three fold over the upper limit (193 U/L; reference range 0-60 U/L), with daily fluctuation of values. Both ultrasound scan and magnetic resonance imaging were normal. The genetic mutation associated with chronic pancreatitis was negative. We followed up this patient for two years with blood tests every six months and she did not show any signs or symptoms of pancreatic disease, except for the high level of lipase serum. Case 2: an eight year old girl complained of nausea, vomiting and severe abdominal pain in the

epigastric region after eating for the last two weeks. Full blood count, electrolytes, C-reactive protein, liver and renal function were normal. Serum lipase was 96 U/L (reference range 0-60 U/L). The screening for the possible causes of pancreatic disease was negative. Endoscopy of the upper gastrointestinal tract, ultrasound, computed tomography scan and magnetic resonance imaging were normal. One year after the presentation of the symptoms, the patient became asymptomatic although the level of serum lipase continued to be high.

© 2014 Baishideng Publishing Group Co., Limited. All rights reserved.

**Key words:** Amylase; Lipase; Pancreatic hyperenzymemia; Gullo's syndrome; Benign hyperlipasemia

**Core tip:** Benign hyperlipasemia is a rare condition in children. The identification of this condition could be very useful for pediatricians in the diagnosis and management of hyperlipasemia. The cause of pancreatic hyperenzymemia seems to be related to a defected pathway from the trans-Golgi network to basolateral cell membrane. It has been hypothesized that a defect in this pathway could be responsible for the increased passage of enzymes into circulation. "Gullo's syndrome" remains a diagnosis of exclusion and clinicians still need to be vigilant of the wide-ranging conditions that can manifest initially with elevations in lipase/amylase.

Lionetti E, Francavilla R, Leonardi S, Tomarchio S, Gennaro A, Franzonello C, La Rosa M. Two rare cases of benign hyperlipasemia in children. *World J Clin Cases* 2014; 2(1): 16-19 Available from: URL: <http://www.wjgnet.com/2307-8960/full/v2/i1/16.htm> DOI: <http://dx.doi.org/10.12998/wjcc.v2.i1.16>

### INTRODUCTION

Gullo first described in adults a new syndrome character-

ized by a benign chronic increase of serum pancreatic enzymes in the absence of pancreatic or other pathologies<sup>[1]</sup>. This condition is often familial, although sporadic cases have also been described<sup>[2]</sup>. In another study, the same investigator found that this syndrome can also be present in children. In the majority of cases (95%), the hyperenzymemia concerns all pancreatic enzymes; in 5% of cases it is possible to observe an increase of only the amylase and rarely of only the lipase<sup>[3]</sup>. In this report, we describe two pediatric cases of the rare form of benign hyperlipasemia.

## CASE REPORT

### Case 1

A six year old girl came to our outpatient department for the occasional discovery of serum lipase elevation with normal amylase level during routine blood tests. She was third born by normal delivery of non-consanguineous parents. Her medical history was silent except for a surgery because of funicular hernia when she was one year old. There was no familial history of pancreatic hyperenzymemia or of other relevant diseases. At physical exam, her weight, height and body mass index were 20.8 kg, 123.5 cm and 14 kg/m<sup>2</sup> (10<sup>th</sup> centile), respectively; there was no clinical sign of pancreatic or other diseases. Routine blood tests were normal (full blood count, serum glucose, liver and renal function tests, total and fractioned blood bilirubin, blood iron subset and immunoglobulin). In order to assess a possible cause for the elevated lipase level, the following tests were done: lipid subset, cytomegalovirus serology and cultures, Epstein-Barr, toxoplasma, rubella, parvo and herpes virus serology, autoimmunity profile, including anti-transglutaminase antibodies, perinuclear antibodies, antineutrophil cytoplasm and anti-Saccharomyces cerevisiae antibodies, C-peptide and islet cell antibodies, fecal elastase, serum trypsinogen, IgG4 and sweat analysis; they all were within the normal range. Amylase and pancreatic isoamylase as well as serum lipase concentrations were determined by an enzymatic colorimetric method (Beckman Instruments, Fullerton, CA) and the only abnormal parameter was the serum lipase, increased three fold over the upper limit (193 U/L, reference range: 0-60 U/L), with daily fluctuating values. Due to the persistence of increased lipase, abdominal ultrasound scan and magnetic resonance imaging were also performed and did not show any pathological signs. The genetic mutations associated with chronic pancreatitis, including mutations for autosomal recessive cystic fibrosis transmembrane conductance regulator (CFTR) [by two validated commercial kits (INNO-LiPA CFTR 19 and INNOLiPA CFTR 17 Tn polymorphism, Innogenetics N.V., Ghent, Belgium), which simultaneously detect 36 mutations and the Tn polymorphism], autosomal dominant PRSS1 and pancreatic trypsin SPINK1, were also negative, such as the familial screening for pancreatic hyperenzymemia. Having ruled out all the common causes of hyperlipasemia, we decided to follow up this patient with blood tests every six months. For the entire 2 years

of follow up, the child did not show signs or symptoms of pancreatic or other diseases, and blood tests as well as the ultrasound morphology of her pancreas continued to be normal, except for blood lipase levels that fluctuated widely during the whole period of follow up [lipase median value: 194 U/L (reference range: 0-60 U/L) (range: 179-218 U/L); mean  $\pm$  SD: 195.8  $\pm$  12.9 U/L. Pancreatic isoamylase median value: 34.5 U/L (reference range) (0-46 U/L) (range: 30-43 U/L); mean  $\pm$  SD: 35.2  $\pm$  4.5 U/L].

### Case 2

An eight year old girl was referred to our outpatient clinic for abdominal pain for the last two weeks. She complained of nausea, vomiting and severe abdominal pain of short duration localized at the epigastric region, occurring mainly after eating; there was no history of abdominal trauma. On medical examination, she was afebrile, the abdomen was slightly distended and tender; her weight, height and body mass index were 25 kg, 130 cm and 14.8 (25<sup>th</sup> centile), respectively. No weight loss preceded the onset of pain. To exclude organic causes, the following investigations were performed and were normal: full blood count, liver and renal function tests, serum glucose and electrolytes, total cholesterol and fractions, erythrocyte sedimentation rate and C-reactive protein. Serum amylase and lipase concentrations were 124 U/L (reference range 0-46 U/L) and 96 U/L (reference range 0-60 U/L), respectively. Salivary isoamylase and urinary amylase were normal. Amylase became normal in the following five days, while lipase concentrations remained elevated (4-5 fold above the reference value). The diagnostic work-up for pancreatic diseases was started and all the following tests returned within normal range: serology for infective diseases, autoimmunity, fecal elastase, serum trypsinogen, IgG4, sweat test and genetic markers for chronic pancreatitis. Endoscopy of the upper gastrointestinal tract with antral and duodenal biopsies did show any alteration to the esophagus, stomach and duodenal bulb. Morphological assessment (ultrasound scan and magnetic resonance imaging) showed normal pancreatic parenchyma and biliary and pancreatic tree. Familial screening for pancreatic hyperenzymemia was also negative.

During hospitalization, the child recovered from the abdominal pain in the following two days; however, the serum level of lipase remained elevated although it fluctuated. One year after presentation, the patient became asymptomatic although the serum lipase remained elevated [lipase median value: 240 U/L (reference range: 0-60 U/L) (range: 96-480 U/L); mean  $\pm$  SD: 264  $\pm$  166.6 U/L. Pancreatic isoamylase median value: 41.5 U/L (reference range 0-46 U/L) (range: 37-124); mean  $\pm$  SD: 264  $\pm$  166.6 U/L].

## DISCUSSION

Pancreatic hyperenzymemia is a rare finding in children; it can be due to different pathological conditions, the most frequent being acute or chronic pancreatitis<sup>[4,5]</sup>. Other causes of serum lipase elevation have been identified in a



**Table 1 Principal causes for increased serum levels of pancreatic enzymes**

Causes	Suggested work-up
Pancreatic diseases	Full blood count, erythrocyte sedimentation rate, PCR, immunoglobulin
Drugs	Liver function tests
Infections	Fecal elastase
Tumors	Serum trypsinogen
Autoimmunity	IgG4
Trauma	Cytomegalovirus serology and cultures, Epstein-Barr, toxoplasma, rubella, parvo and herpes virus serology
Anatomic anomalies	Sweat analysis
Gene mutation	Genetic analysis (CFTR, PRSS1, SPINK1)
Cystic fibrosis	US
Viral hepatitis	CT scan
Surgery	
Biliary diseases	Full blood count, erythrocyte sedimentation rate, PCR, immunoglobulin
Biliary lithiasis	US scan
Anatomic anomalies	Cholangio-pancreatographic MRI
Tumors	
Sphincter Oddi dysfunction	
Macroenzymemia	Full blood count, erythrocyte sedimentation rate, PCR, immunoglobulin
Celiac disease	Liver function tests
Inflammatory bowel disease	Autoimmune profile: anti-transglutaminase, perinuclear, antineutrophil cytoplasm and anti-Saccharomyces cerevisiae, and islet cell antibodies.
Autoimmune diseases	US scan
Liver diseases	
Lymphoma	
Thyroid cancer	
Renal diseases	Full blood count, erythrocyte sedimentation rate, PCR, immunoglobulin
Inflammatory	Renal function tests
Neoplastic	US scan
Impaired renal function	
Others	Full blood count, erythrocyte sedimentation rate, PCR, serum glucose
Peptic ulcer	Serum cholesterol and triglycerides
Paravaterian diverticulum	US scan
Intestinal obstruction	EGDS
Dyslipidemia	
Diabetic ketoacidosis	
Malignancy	

US: Ultrasound; CT: Computed tomography; CFTR: Cystic fibrosis transmembrane conductance regulator; MRI: Magnetic resonance imaging; EGDS: Esophagogastroduodenal endoscopy; PCR: Polymerase chain reaction.

number of conditions, such as acute cholecystitis, Gilbert syndrome, hypertriglyceridemia, intestinal infarction, duodenal ulcer, obstruction or inflammatory bowel disorders, liver diseases, abdominal trauma<sup>[6]</sup>, diabetes ketoacidosis<sup>[7]</sup> and renal insufficiency (Table 1)<sup>[8]</sup>.

Interestingly, Gullo *et al*<sup>[2]</sup> have recently shown the existence of a benign pancreatic hyperenzymemia defined as an abnormal increase in serum pancreatic enzymes that occurs in healthy adults or children in the absence of pancreatic or other disease; it is asymptomatic and persists over time with considerable fluctuation in serum enzyme concentrations. At least 1-2 years must pass after the initial finding of the hyperenzymemia before it can be considered benign. It can be familial (when the patient has at least one family member with the same anomaly) or sporadic. The authors studied this condition in 15 children with hyperenzymemia. Among them, 13 were found with high levels of all pancreatic enzymes, one with normal range of enzymes, and only one was found with an increased level of the only lipase. The condition was familial in 12 children and sporadic in three of them. To our knowledge, there are no other studies in children re-

porting the isolate benign increase of serum lipase, while two studies recorded one case each of familial hyperamylasemia<sup>[9,10]</sup>.

In this report, we described the second two cases in the literature of benign hyperlipasemia. During the whole period of follow-up, the two children did not present with any signs or symptoms of pancreatic or other diseases, and blood tests as well as the ultrasound morphology and the imaging study of their pancreas remained normal, showing the benign nature of this abnormality. A limitation of the present case report may be the non-availability of the nasal potential difference test for the diagnosis of subclinical form of cystic fibrosis, although genetic screening and sweat analysis were negative. In the second case, initial elevations of both amylase and lipase with ongoing persistence in lipase may suggest a pancreatic origin, but not detectable based on limitations of current available tests. It is important to point out that, even if rarely (1%-2% of cases), an apparently benign pancreatic hyperenzymemia can be the first clinical sign of a pancreatic tumor, which may declare itself in the following years<sup>[2]</sup>.

In our experience, these cases were sporadic, considering that familial enzymes were normal. The cause of pancreatic hyperenzymemia and the reason for its fluctuating behavior is not known. It has been shown that there is a direct, constitutive-like pathway from the trans-Golgi network to the basolateral cell membrane, by which newly synthesized enzymes reach the circulation. It has been hypothesized that a defect in this pathway could be responsible for the increased passage of enzymes into circulation<sup>[2]</sup>.

The fluctuating behavior could depend on the degree of the cellular defect, with the passage of enzymes being sporadic when the defect is mild and more frequent when it is more severe or extensive<sup>[2]</sup>.

“Gullo’s syndrome” remains a diagnosis of exclusion and clinicians still need to be vigilant of the wide-ranging conditions that can manifest initially with elevations in lipase/amylase. However, clinicians should be aware that failing to diagnose the cause, the condition of idiopathic hyperlipasemia (or hyperamylasemia) can be diagnosed and is usually associated with a benign course. According to Gullo, we believe that the knowledge of this condition should be helpful to the pediatrician in diagnosis and management, assuring the clinician and alleviating the concern of the child’s parents<sup>[1]</sup>. A larger cohort of patients and longer follow-up are needed to evaluate the exact proportion of this clinical chemical constellation and to better understand the etiology, natural history and the real benign nature of this condition.

## COMMENTS

### Case characteristics

The two cases of benign hyperlipasemia have a different clinical presentation; while the first case was asymptomatic, the second case showed nausea, vomiting and severe abdominal pain at the epigastric region.

### Clinical diagnosis

Medical examination was silent for pancreatic diseases.

### Laboratory diagnosis

The screening for possible causes for elevated lipase and amylase (genetic, autoimmune and infectious diseases) was normal.

### Pathological diagnosis

In the second case, endoscopy of the upper gastrointestinal tract with antral

and duodenal biopsies did show any alteration to the esophagus, stomach and duodenal bulb.

### Related reports

It is very important to know this condition because an apparently benign pancreatic hyperenzymemia can be the first clinical sign of a different pathological condition.

### Experiences and lessons

Benign hyperlipasemia remains a diagnosis of exclusion and clinicians still need to be vigilant of the wide-ranging conditions that can manifest initially with elevations in lipase/amylase.

### Peer review

This report describes the second two cases in the literature of benign hyperlipasemia but a larger cohort and longer follow-up are needed to better understand the natural history of this condition.

## REFERENCES

- 1 **Gullo L.** Benign pancreatic hyperenzymemia or Gullo’s syndrome. *JOP* 2006; **7**: 241-242; author reply 243-244 [PMID: 16525212]
- 2 **Gullo L.** Benign pancreatic hyperenzymemia. *Dig Liver Dis* 2007; **39**: 698-702 [PMID: 17531557 DOI: 10.1016/j.dld.2007.03.005]
- 3 **Gullo L, Migliori M.** Benign pancreatic hyperenzymemia in children. *Eur J Pediatr* 2007; **166**: 125-129 [PMID: 16977437 DOI: 10.1007/s00431-006-0264-3]
- 4 **Lowe ME.** Pancreatitis in childhood. *Curr Gastroenterol Rep* 2004; **6**: 240-246 [PMID: 15128492 DOI: 10.1007/s11894-004-0014-5]
- 5 **Stringer MD, Davison SM, McClean P, Rajwal S, Puntis JW, Sheridan M, Ramsden W, Woodley H.** Multidisciplinary management of surgical disorders of the pancreas in childhood. *J Pediatr Gastroenterol Nutr* 2005; **40**: 363-367 [PMID: 15735494 DOI: 10.1097/01.MPG.0000153007.38363.37]
- 6 **Tetrault GA.** Lipase activity in serum measured with Ektachem is often increased in nonpancreatic disorders. *Clin Chem* 1991; **37**: 447-451 [PMID: 1706233]
- 7 **Haddad NG, Croffie JM, Eugster EA.** Pancreatic enzyme elevations in children with diabetic ketoacidosis. *J Pediatr* 2004; **145**: 122-124 [PMID: 15238920 DOI: 10.1016/j.jpeds.2004.03.050]
- 8 **Frank B, Gottlieb K.** Amylase normal, lipase elevated: is it pancreatitis? A case series and review of the literature. *Am J Gastroenterol* 1999; **94**: 463-469 [PMID: 10022647]
- 9 **Cuckow PM, Foo AY, Jamal A, Stringer MD.** Familial hyperamylasaemia. *Gut* 1997; **40**: 689-690 [PMID: 9203953]
- 10 **Koda YK, Vidolin E.** Familial hyperamylasemia. *Rev Hosp Clin Fac Med Sao Paulo* 2002; **57**: 77-82 [PMID: 11981589 DOI: 10.1590/S0041-87812002000200006]

**P- Reviewers:** Kouraklis G, Nardone G, Schneider R  
**S- Editor:** Qi Y **L- Editor:** Roemmele A **E- Editor:** Wang CH



## Left atrial thrombosis in an anticoagulated patient after bioprosthetic valve replacement: Report of a case

Gian Marco Rosa, Antonello Parodi, Ulrico Dorigi, Federico Carbone, François Mach, Alessandra Quercioli, Fabrizio Montecucco, Nicolas Vuilleumier, Manrico Balbi, Claudio Brunelli

Gian Marco Rosa, Antonello Parodi, Ulrico Dorigi, Manrico Balbi, Claudio Brunelli, Clinic of Cardiovascular Diseases, Internal Medicine Department, San Martino Hospital and University of Genoa, 16143 Genoa, Italy

Federico Carbone, François Mach, Alessandra Quercioli, Fabrizio Montecucco, Division of Cardiology, Department of Internal Medicine, Foundation for Medical researches, University of Geneva, 1211 Geneva, Switzerland

Fabrizio Montecucco, the First Medical Clinic, Laboratory of Phagocyte Physiopathology and Inflammation, Department of Internal Medicine, University of Genoa, 16143 Genoa, Italy

Nicolas Vuilleumier, Division of Laboratory Medicine, Department of Genetics and Laboratory Medicine, Geneva University Hospitals, 1211 Geneva, Switzerland

**Author contributions:** Rosa GM, Balbi M and Brunelli C designed the report; Parodi A and Dorigi U collected the patient's clinical data; Rosa GM, Carbone F, Mach F, Quercioli A, Montecucco F and Vuilleumier N analyzed the data and wrote the paper.

Supported by Swiss National Science Foundation, No. 310030\_118245 and No. 32003B\_134963/1

Correspondence to: Fabrizio Montecucco, MD, PhD, Division of Cardiology, Department of Internal Medicine, Foundation for Medical Researches, University of Geneva, 6 viale Benedetto XV, 1211 Geneva, Switzerland. [fabrizio.montecucco@unige.ch](mailto:fabrizio.montecucco@unige.ch)

Telephone: +41-22-3827238 Fax: +41-22-3827245

Received: October 28, 2013 Revised: November 29, 2013

Accepted: December 17, 2013

Published online: January 16, 2014

disease, VKA was re-established with hemodynamic and liver enzymes normalization and atrial thrombus resolution. Caution has to be used when considering fondaparinux as an alternative strategy to VKA in patients with multiple thrombotic risk factors.

© 2014 Baishideng Publishing Group Co., Limited. All rights reserved.

**Key words:** Mitral valve; Thrombus; Prosthetic valve; Atrium; Hepatotoxicity

**Core tip:** Thromboembolism represents an important complication following heart valve replacement. This case report shows that although vitamin K antagonist (VKA) treatment represents the elective therapy in patients with left atrial thrombosis without mitral valve dysfunction, it may not be sufficient to avoid thromboembolism. We also recommend that the discontinuation of VKA during the first three months after mitral valve surgery has to be carefully considered, especially in high thromboembolic risk patients.

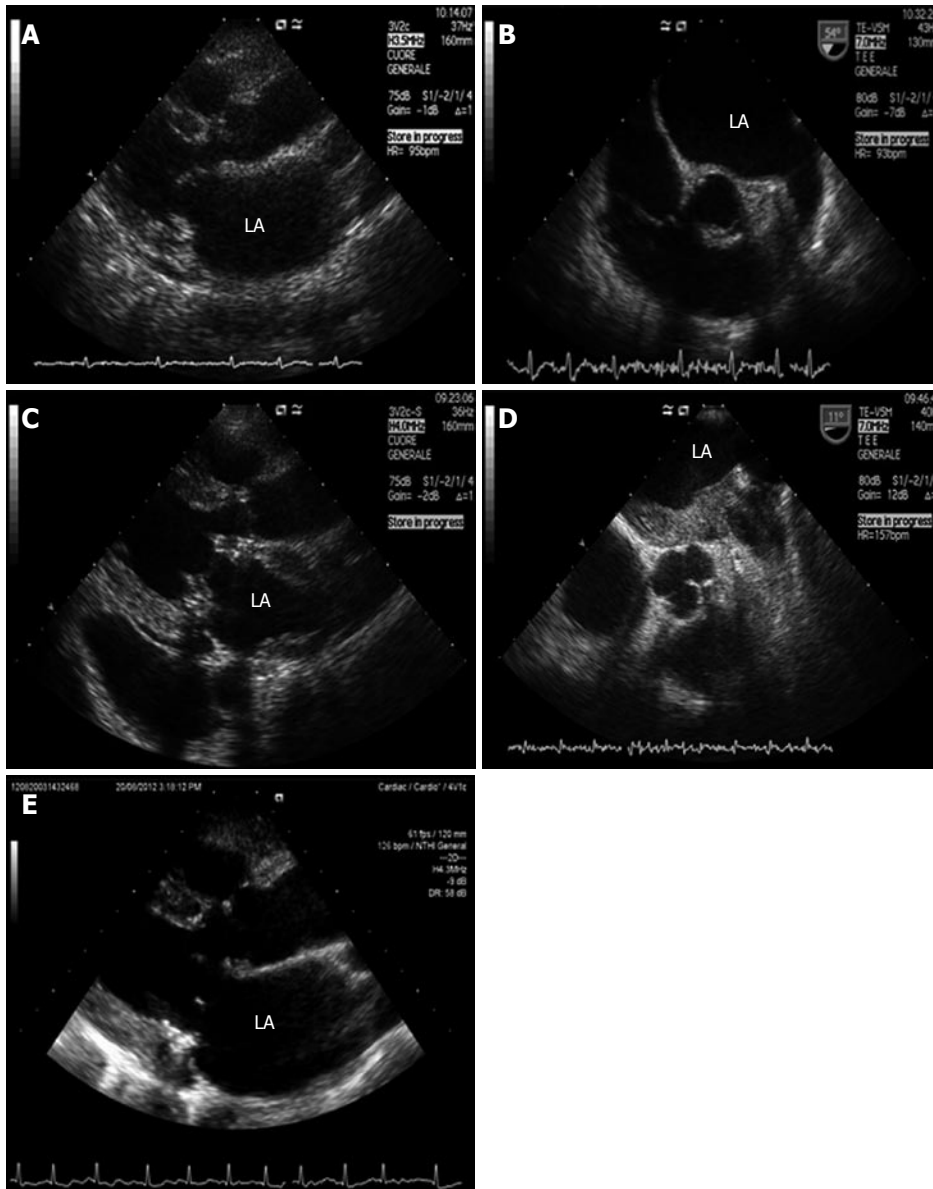
Rosa GM, Parodi A, Dorigi U, Carbone F, Mach F, Quercioli A, Montecucco F, Vuilleumier N, Balbi M, Brunelli C. Left atrial thrombosis in an anticoagulated patient after bioprosthetic valve replacement: Report of a case. *World J Clin Cases* 2014; 2(1): 20-23 Available from: URL: <http://www.wjgnet.com/2307-8960/full/v2/i1/20.htm> DOI: <http://dx.doi.org/10.12998/wjcc.v2.i1.20>

### Abstract

We present the case of a 74 year old woman suffering from severe mitral valve incompetence and rapid atrial fibrillation. After an appropriate vitamin K antagonist (VKA) therapy, the patient underwent mitral valve replacement by bioprosthesis. Then, the patient was re-hospitalized for jaundice. Suspecting hepatotoxicity, VKA was discontinued and fondaparinux was started. During this treatment, the patient developed a symptomatic atrial thrombus. After exclusion of a hepatic

### INTRODUCTION

Thromboembolism represents an important complication following heart valve replacement. The international guidelines on the management of valvular heart disease recommend postoperative anticoagulation therapy (AT)<sup>[1]</sup>.



**Figure 1 Echocardiographic image.** A: Left parasternal long axis transthoracic echocardiography; B: Upper transesophageal views of the aortic valve in short axis; C: Left parasternal long axis transthoracic echocardiography; D: Upper transesophageal views of the aortic valve in short axis; E: Left parasternal long axis transthoracic echocardiography. LA: left atrium.

While mechanical valves require lifelong anticoagulation therapy, bioprosthetic valve (BV) recipients can avoid long-term use. Owing to the higher frequency of thromboemboli in the first 3 mo after BV insertion, three months of AT is recommended for patients not receiving antithrombotic therapy, especially for those who undergo bioprosthetic mitral valve replacement<sup>[2]</sup>. However, in the presence of atrial fibrillation (AF), heart failure and impaired LV function (ejection fraction < 30%), AT has to be continued for life.

## CASE REPORT

A 74 year old woman with a history of valvular rheumatic disease, acute myocardial infarction, autoimmune thrombocytopenia and paroxysmal atrial fibrillation presented

with palpitations and rapid worsening of dyspnea. She was on antithrombotic therapy with acetylsalicylic acid. EKG showed rapid atrial fibrillation. Transthoracic echocardiography (TTE) demonstrated severe mitral valve incompetence and mild stenosis, enlarged left atrium and right chambers, and severe tricuspid regurgitation (Figure 1A). Appropriate vitamin K antagonist (VKA) therapy was administered.

Transesophageal echocardiography (TEE) showed no thrombus in the left atrium (LA) or in the left atrial appendage (Figure 1B). Since the pharmacological therapy was unable to control the rhythm, the patient was successfully submitted to electrical cardioversion. Five weeks later, the patient underwent mitral valve replacement by Carpentier-Edwards Perimount Magna bioprosthesis (Edwards Lifesciences, Irvine, CA, United States) and tri-



cuspid valve annuloplasty.

In June 2012, the patient was re-admitted because of jaundice and abdominal pain. EKG showed atrial fibrillation. Liver and biliary tract diseases were ruled out despite hyperbilirubinemia and cholestasis indexes (bilirubin was 15.63 mg/dL,  $\gamma$ -glutamyltransferase 1638 U/L, alkaline phosphatase 621 U/L, aspartate aminotransferase 30 U/L, alanine aminotransferase 63 U/L). VKA was discontinued due to suspected hepatotoxicity and fondaparinux was subcutaneously administered (5.0 mg/d). Due to peripheral edema, jugular turgor and hepatomegaly, TTE was repeated over the following days. We found a mass stratified on all the atrial walls (Figure 1C). TEE confirmed that the image was suggestive of thrombus (Figure 1D). Diagnostic workup excluded a thrombophilic state, viral/autoimmune liver disease, cancer or biliary duct pathology. In the first days of July 2012, VKA treatment was re-started and fondaparinux was stopped. In August 2012, the patient showed hemodynamic stability and normalization of the liver function and enzymes, while TTE excluded the presence of a thrombus in the left atrium (LA) (Figure 1E). During 5 mo of follow up, the patient remained asymptomatic.

## DISCUSSION

Unlike mechanical heart valves, BV insertion is associated with a very low rate of thrombosis (approximately 0.03% per year)<sup>[3]</sup>. After BV implantation, AT is recommended for the first 3 mo and for life only in the presence of atrial fibrillation, heart failure, impaired left ventricular function or history of thromboembolism. Currently, the only oral drugs approved for AT are VKAs.

There is no scientific evidence that the new oral anti-thrombotic agents (*e.g.*, dabigatran, rivaroxaban and apixaban) are effective in these patients. Nevertheless, these drugs could represent a new interesting option because of their elevated safety and efficacy due to their pharmacodynamic profile and the absence of drug-to-drug interactions. The only possible alternatives to VKAs are unfractionated heparin (UFH) and low molecular weight heparins (LMWHs), but they must be administered intravenously or subcutaneously<sup>[1]</sup>. Our patient was admitted nearly 40 d after mitral valve surgery when anticoagulation therapy is considered mandatory. Since she was at high thrombotic risk (*e.g.*, age, left ventricular dysfunction, atrial fibrillation, left atrial enlargement with atrial contractile failure), on the basis of the current guidelines, she should have continued AT indefinitely. This treatment strategy is mandatory for the primary prevention of cardioembolic ischemic stroke in patients with cardiac disorders (such as atrial fibrillation). Cardioembolic stroke is considered a high-risk complication and it represents the subtype of ischemic infarct with the highest in-hospital mortality (20%)<sup>[4]</sup>.

Clinical practice shows that VKA therapy is very effective but long-term administration may be difficult, especially in elderly patients due to the variability in drug

metabolism, drug-drug and drug-food interactions, patient compliance and risk of bleeding events.

The beginning of VKA therapy is burdened by a pro-thrombotic state, so we associated LMWH for few days until reaching the international normalized ratio (INR target), as recommended by international guidelines to avoid thromboembolism.

Our case confirmed this aspect: INR was 4.6 following heart surgery and 1.5 at re-hospitalization after four weeks of therapy at home. Thus, we had to improve anticoagulation by VKA therapy but our concern was related to the increased bilirubin levels and cholestatic indexes suggestive of an acute hepatitis with liver damage.

First of all, we excluded the most frequent causes of acute liver disease. No evidence of viral hepatitis, cholelithiasis and no use of hepatotoxic drugs or toxin ingestion were found. Thus, we theorized that the cause of increased bilirubinemia and cholestatic index levels could be related to the right heart failure with hepatic blood stasis and secondary liver dysfunction.

On the other hand, in accordance with previous reports<sup>[5]</sup>, we did not continue administering VKAs. Furthermore, we could not administer UFH or LMWH due to the history of immune thrombocytopenia and, moreover, we found some reports of LMWH-induced hepatotoxicity. Thus, we decided to administer fondaparinux. We found little evidence (two experimental models<sup>[6,7]</sup> and a case report<sup>[8]</sup>) supporting the administration of fondaparinux (7.5 mg once per day) to prevent thrombosis in patients with mechanical heart valves. At that time, we speculated on the potential usefulness of a concomitant antiplatelet therapy (APT). However, we excluded this option considering that there was no evidence of improved efficacy and only an increased hemorrhagic risk.

During an echocardiogram that was carried out to investigate the clinical signs of right heart failure, we found a giant left atrial thrombosis.

These findings, together with the normalization of the hepatobiliary function indexes, suggested to us to discontinue fondaparinux and re-start VKA treatment. Another issue supporting this therapeutic strategy was represented by the concomitant presence of atrial thrombosis without valve dysfunction.

After one month of correct VKA therapy (INR target: 2-3), we not surprisingly found a normally functioning prosthetic valve, accompanied by the resolution of atrial thrombosis. Whether oral anticoagulation may result in the lysis of a thrombus is not clear. Studies carried out for cardioversion in atrial fibrillation have shown that 3-4 wk of warfarin therapy leads to complete resolution of atrial thrombi in 80%-90% of cases without evidence of clinical thromboembolism or residual organized adherent thrombus<sup>[9]</sup>. In our patient, this thrombus remodeling may have favored its re-absorption.

Although VKA treatment represents the elective therapy in patients with left atrial thrombosis without mitral valve dysfunction, this case shows that it may be not suit-

able for avoiding thrombogenesis. This case shows that in very high thromboembolic risk patients, VKA therapy never must be discontinued.

This case also suggests that discontinuation of VKAs during the first three months after mitral valve surgery has to be carefully considered, especially in high thromboembolic risk patients. Although we used fondaparinux as an alternative strategy, the efficacy of this drug requires further validation in larger clinical trials.

## COMMENTS

### Case characteristics

A 74 year old woman with high thromboembolic risk (including atrial fibrillation and previous mitral valve replacement) presented with peripheral edema, jugular turgor and hepatomegaly after withdrawal of the vitamin K antagonist, replaced by fondaparinux.

### Clinical diagnosis

Left atrial thrombus and right heart failure.

### Differential diagnosis

Left atrial thrombus spontaneous formation or promoted by vitamin K antagonist withdrawal.

### Laboratory diagnosis

The metabolic panel that led to the vitamin K antagonist withdrawal showed an increase of bilirubinemia (total bilirubin 15.63/dL),  $\gamma$ -glutamyltransferase (1638 U/L), alkaline phosphatase (621 U/L), aspartate aminotransferase (30 U/L) and alanine aminotransferase (63 U/L).

### Imaging diagnosis

Transthoracic echocardiography found a left atrial mass consistent with a thrombus. Transesophageal echocardiography confirmed this insight.

### Treatment

The re-initiation of therapy with the vitamin K antagonist led to complete thrombus resolution.

### Related reports

Potential liver toxicity induced by the vitamin K antagonist should be considered in clinical practice due to the wide distribution of this drug.

### Experiences and lessons

In expectation of new oral antithrombotic agents, the vitamin K antagonist remains the first choice for preventing thrombotic event in high-risk patients. In addition, these patients require a long-term therapy.

### Peer review

This article recommends a long-term anticoagulant therapy in high-risk patients and identifies the vitamin K antagonist as the most effective drug.

## REFERENCES

- 1 **Vahanian A**, Alfieri O, Andreotti F, Antunes MJ, Barón-Esquivias G, Baumgartner H, Borger MA, Carrel TP, De Bonis M, Evangelista A, Falk V, Jung B, Lancellotti P, Pierard L, Price S, Schäfers HJ, Schuler G, Stepinska J, Swedberg K, Takkenberg J, Von Oppell UO, Windecker S, Zamorano JL, Zembala M. Guidelines on the management of valvular heart disease (version 2012). *Eur Heart J* 2012; **33**: 2451-2496 [PMID: 22922415 DOI: 10.1093/eurheartj/ehs109]
- 2 **Ionescu MI**, Smith DR, Hasan SS, Chidambaram M, Tandon AP. Clinical durability of the pericardial xenograft valve: ten years experience with mitral replacement. *Ann Thorac Surg* 1982; **34**: 265-277 [PMID: 7114945 DOI: 10.1016/S0003-4975(10)62496-4]
- 3 **Grunkemeier GL**, Li HH, Naftel DC, Starr A, Rahimtoola SH. Long-term performance of heart valve prostheses. *Curr Probl Cardiol* 2000; **25**: 73-154 [PMID: 10709140]
- 4 **Arboix A**, Alió J. Cardioembolic stroke: clinical features, specific cardiac disorders and prognosis. *Curr Cardiol Rev* 2010; **6**: 150-161 [PMID: 21804774 DOI: 10.2174/157340310791658730]
- 5 **Adler E**, Benjamin SB, Zimmerman HJ. Cholestatic hepatic injury related to warfarin exposure. *Arch Intern Med* 1986; **146**: 1837-1839 [PMID: 3753126 DOI: 10.1001/archinte.1986.0360210235037]
- 6 **Schlitt A**, Buerke M, Hauroeder B, Peetz D, Hundt F, Bickel C, Schaefer I, Meyer J, Rupperecht HJ. Fondaparinux and enoxaparin in comparison to unfractionated heparin in preventing thrombus formation on mechanical heart valves in an ex vivo rabbit model. *Thromb Haemost* 2003; **90**: 245-251 [PMID: 12888871]
- 7 **Schlitt A**, Hamilton K, Maegdefessel L, Dahm M, Theis C, Eichler M, Brockmann O, Steinseifer U, Hauroeder B, Hitzler WE, Rupperecht HJ. Comparison of fondaparinux, low molecular-weight heparin and unfractionated heparin in preventing thrombus formation on mechanical heart valves: results of an in-vitro study. *J Heart Valve Dis* 2006; **15**: 809-814 [PMID: 17152789]
- 8 **Corbett TL**, Elher KS, Garwood CL. Successful use of fondaparinux in a patient with a mechanical heart valve replacement and a history of heparin-induced thrombocytopenia. *J Thromb Thrombolysis* 2010; **30**: 375-377 [PMID: 20571919 DOI: 10.1007/s11239-010-0494-0]
- 9 **Corrado G**, Tadeo G, Beretta S, Tagliagambe LM, Manzillo GF, Spata M, Santarone M. Atrial thrombi resolution after prolonged anticoagulation in patients with atrial fibrillation. *Chest* 1999; **115**: 140-143 [PMID: 9925075 DOI: 10.1378/chest.115.1.140]

**P- Reviewers:** Arboix A, Amiri M, Biondi-Zoccai G  
**S- Editor:** Qi Y **L- Editor:** Roemmele A **E- Editor:** Wang CH



## Retrograde jejuno gastric intussusception following Braun's jejunojejunoscopy

Raj Gopal, Thirthar Palanivelu Elamurugan, Sunny Hage, Rajakannu Muthukumarassamy, Vikram Kate

Raj Gopal, Thirthar Palanivelu Elamurugan, Sunny Hage, Rajakannu Muthukumarassamy, Vikram Kate, Department of Surgery, Jawaharlal Institute of Postgraduate Medical Education and Research, Puducherry 605006, India

**Author contributions:** All the authors contributed to the acquisition of data, drafting the article and final approval of the version to be published.

**Correspondence to:** Vikram Kate, MS, FRCS (Eng.), FRCS (Ed.), FRCS (Glasg.), PhD, FACS, FACG, Professor, Department of Surgery, Jawaharlal Institute of Postgraduate Medical Education and Research, Dhanvantri Nagar, Puducherry 605006, India. [drvikramkate@gmail.com](mailto:drvikramkate@gmail.com)

Telephone: +91-984-3058013

Received: October 12, 2013 Revised: October 31, 2013

Accepted: December 9, 2013

Published online: January 16, 2014

© 2014 Baishideng Publishing Group Co., Limited. All rights reserved.

**Key words:** Retrograde; Intussusception; Billroth II gastrectomy; Jejunojejunoscopy

**Core tip:** Retrograde jejunojejunal and jejuno gastric intussusceptions are rare. The occurrence of retrograde intussusception across two anastomoses has not been reported in the literature. A high index of suspicion and timely investigations like an esophagogastroscope or a computed tomography scan will help to clinch the diagnosis early. Emergency surgical intervention can help to prevent clinical deterioration and save the life of the patient. We would like to emphasize the fact that a high index of clinical suspicion should be maintained in patients with gastroenteric anastomosis who present with hematemesis for the possibility of a retrograde jejuno gastric intussusception; the results can be gratifying.

### Abstract

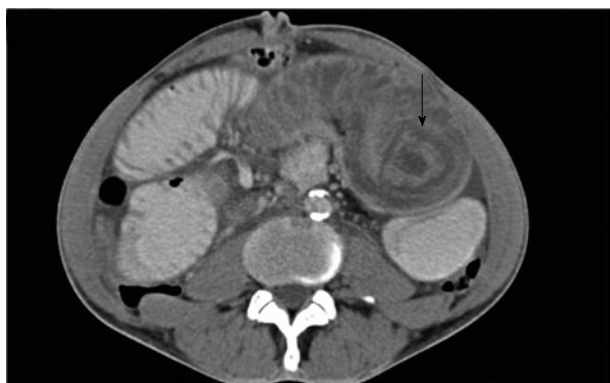Jejunogastric intussusception is a rare long term complication of Billroth II gastrectomy. The case reported here is a 50 year old man with history of a Billroth II gastrectomy and Braun's side-to-side jejunojejunal anastomosis who presented with hematemesis. On abdominal examination, there was a mass in the left iliac fossa. Computed tomography scan showed a retrograde jejuno gastric intussusception across the gastrojejunoscopy. On laparotomy, a retrograde intussusception of the distal jejunum through the jejunojejunal anastomosis and across the gastrojejunoscopy with a gangrenous intussusceptum was found. The jejunojejunal anastomosis was taken down, the gangrenous segment was resected and bowel continuity was restored with two jejunojejunal anastomoses, proximal and distal to the gastrojejunoscopy. The gastrojejunoscopy was preserved. This case brings out an unusual type of retrograde gangrenous intussusception which occurred at two points of a previous anastomosis, *i.e.*, jejunojejunoscopy and gastrojejunoscopy simultaneously, which could be managed with jejunal resection.

Gopal R, Elamurugan TP, Hage S, Muthukumarassamy R, Kate V. Retrograde jejuno gastric intussusception following Braun's jejunojejunoscopy. *World J Clin Cases* 2014; 2(1): 24-26 Available from: URL: <http://www.wjgnet.com/2307-8960/full/v2/i1/24.htm> DOI: <http://dx.doi.org/10.12998/wjcc.v2.i1.24>

### INTRODUCTION

Retrograde jejuno gastric intussusception is a potentially fatal complication of Billroth II gastrectomy<sup>[1,2]</sup>. It is a rare complication of this procedure, with only just over 200 cases reported<sup>[2]</sup>. Retrograde jejuno gastric intussusception can present with varied clinical presentations, like abdominal pain, vomiting, hematemesis, gastric outlet or intestinal obstruction and gangrene gut<sup>[1,3-6]</sup>. There are limited case reports of jejunojejunal intussusception through a Braun's jejunojejunoscopy in cases of total gastrectomy<sup>[7]</sup>. To the best of our knowledge, there are



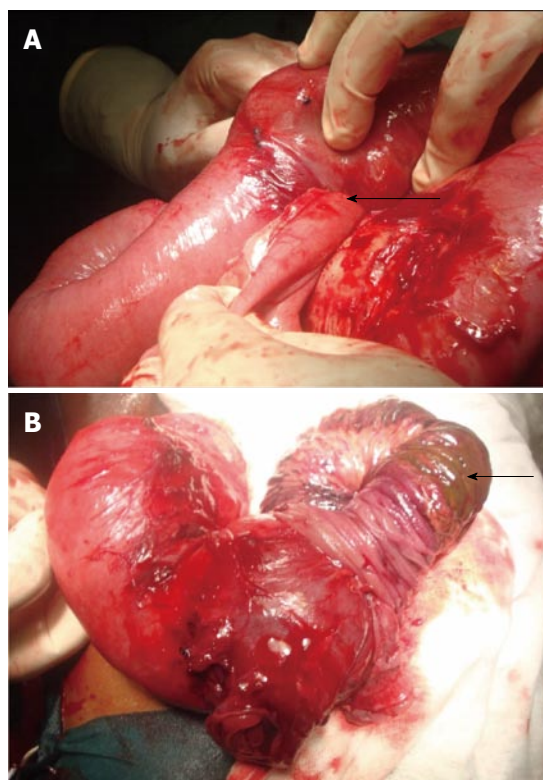


**Figure 1** Computed tomography scan of the abdomen showing the intussusceptions of jejunum into the stomach via the gastrojejunostomy.

no reported cases of hematemesis presenting in a patient with retrograde jejuno gastric intussusception through a Braun's jejunojejunostomy. We present a case that brings out an unusual type of retrograde gangrenous intussusception which occurred across two points of previous anastomosis, *i.e.*, jejunojejunostomy and gastrojejunostomy simultaneously, and presented with hematemesis.

## CASE REPORT

A 50 year old gentleman who had undergone a Billroth II gastrectomy and Braun's side-to-side jejunojejunal anastomosis five years ago for gastric outlet obstruction presented to our emergency department with a one day history of hematemesis. He had five episodes of vomiting altered blood. He gave no history of anything similar in the past. The patient was hemodynamically stable. Abdominal examination did not show any peritoneal signs. An 8 cm × 8 cm mass was palpable in his left iliac fossa. There was no palpable hepatosplenomegaly. An upper gastrointestinal endoscopy was attempted but visualization was poor due to the pooled altered blood. An emergency computed tomography (CT) scan of the abdomen revealed a retrograde intussusception of the jejunum into the stomach across the gastrojejunostomy (Figure 1). The patient was stabilized and taken up for emergency laparotomy. The findings of the CT scan were confirmed intraoperatively. The patient had a gastrojejunostomy and a diverting Braun's side-to-side jejunojejunal anastomosis. The efferent limb of the jejunum distal to the jejunojejunal anastomosis was seen telescoping across the jejunojejunostomy (Figure 2A) into the stomach through the gastrojejunostomy. Schematic representation of the normal anatomy and the retrograde intussusception is shown in Figure 3. The intussuscepted segment was gangrenous (Figure 2B) and there was around 500 mL of altered blood in the stomach but there was no obvious peritoneal contamination. The rest of the bowel, including the intussuscepting segment, appeared viable. The jejunojejunal anastomosis was taken down and the contents reduced. The gangrenous segment of the jejunum was resected and the gastrojejunostomy was preserved. The bowel



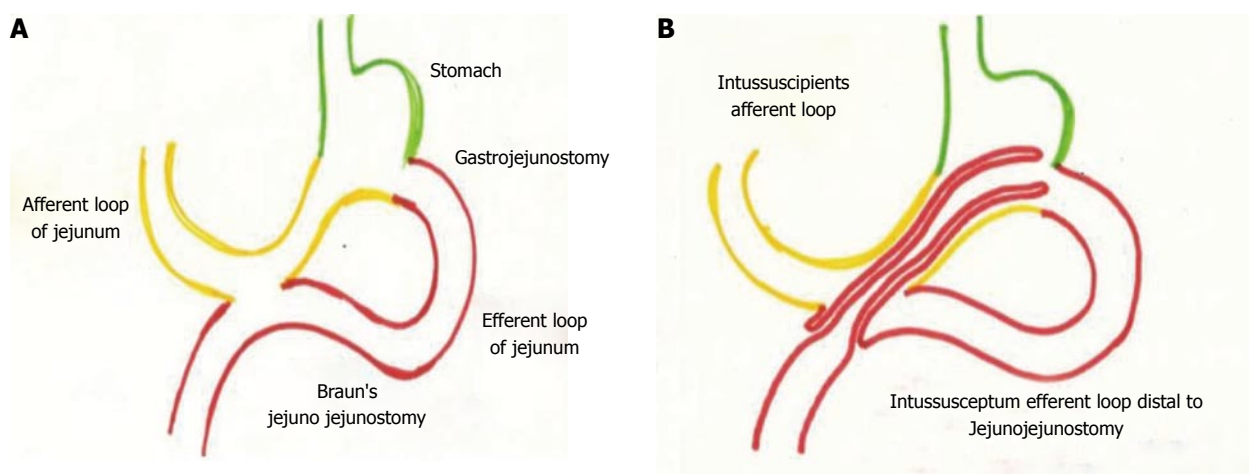
**Figure 2** Intraoperative pictures. A: Showing the distal jejunum telescoping into the proximal limb across the Braun's jejunojejunal anastomosis; B: Showing the gangrenous intussusceptum after it was reduced from the proximal jejunum.

continuity was restored with two jejunojejunal anastomoses, one proximal and one distal to the gastrojejunostomy. A Witzel's type of feeding jejunostomy was placed distal to the second anastomotic line in the efferent loop. The postoperative period was uneventful. The patient's bowel activity returned to normal on the fourth postoperative day. He was initially started on jejunostomy feeds on the fifth postoperative day, on oral diet in the second postoperative week and discharged from hospital after removal of the feeding jejunostomy tube. The patient was asymptomatic at the first and second month follow-up visits.

## DISCUSSION

Retrograde jejunojejunal and jejuno gastric intussusceptions are rare but dangerous long term complications of Billroth II gastrectomy and gastrojejunostomy. Jejuno gastric intussusception is more common than the jejunojejunal variety<sup>[8]</sup>. There have also been reports of retrograde intussusception in patients who have undergone Roux-Y gastrointestinal anastomosis after gastrectomy<sup>[9]</sup> but the occurrence of retrograde intussusception across two anastomoses has not been reported in the literature. A high index of suspicion and timely investigations like an esophagogastroscope or a CT scan will help to clinch the diagnosis early. Emergency surgical intervention can help to prevent clinical deterioration and save the life of the patient<sup>[2]</sup>. All the reported cases of retrograde intussusceptions of jejunum into the stomach through a gastroje-





**Figure 3 Schematic representation.** A: The original anastomotic status of the patient; B: Intussusceptions across the jejunojejunostomy and the gastrojejunostomy.

junostomy have been managed by emergency laparotomy and appropriate resection procedures. In our case also, the relatively early presentation, the clinical suspicion and timely imaging helped in the early diagnosis and proper management and survival of the patient. We would like to emphasize the fact that a high index of clinical suspicion should be maintained in patients with gastroenteric anastomosis who present with hematemesis for the possibility of a retrograde jejuno gastric intussusception; the results can be gratifying.

## COMMENTS

### Case characteristics

A 50 year old man with history of a Billroth II gastrectomy and Braun's side-to-side jejunojejunal anastomosis presented with hematemesis and mass in the left iliac fossa.

### Clinical diagnoses

Unusual type of retrograde gangrenous intussusception which occurred at two points of previous anastomosis, *i.e.*, jejunojejunostomy and gastrojejunostomy simultaneously.

### Differential diagnosis

Clinical examination, upper gastrointestinal endoscopy and imaging methods can help in arriving at the diagnosis.

### Imaging diagnosis

Computed tomography scan showed a retrograde jejuno gastric intussusception across the gastrojejunostomy.

### Treatments

The jejunojejunal anastomosis was taken down, the gangrenous segment of jejunum was resected and bowel continuity was restored with two jejunojejunal anastomoses, proximal and distal to the gastrojejunostomy.

### Term explanation

Braun's gastrojejunostomy: gastrojejunostomy with diverting jejunojejunal anastomosis.

### Experiences and lessons

A high index of clinical suspicion should be maintained in patients with gas-

troenteric anastomosis who present with hematemesis for the possibility of a retrograde jejuno gastric intussusception.

### Peer review

This is an interesting subject with very good pictures.

## REFERENCES

- 1 **Miah AG**, Imam NA, Joarder RH, Talukder SI, Hossain MS. Retrograde jejuno gastric intussusception (JGI) with strangulation following previous gastrojejunostomy. *Mymensingh Med J* 2006; **15**: 99-101 [PMID: 16467773]
- 2 **Tauro LF**, Roshan M, Aithala PS, Hegde BR, Anand IP, John SK. A rare cause of haematemesis: retrograde jejuno gastric intussusception. *J Assoc Physicians India* 2006; **54**: 333-335 [PMID: 16944621]
- 3 **Edwards JL**, Aubrey DA. Retrograde jejuno gastric intussusception: report of 2 cases. *Br J Surg* 1977; **64**: 177-179 [PMID: 890259 DOI: 10.1002/bjs.1800640307]
- 4 **Bapaye M**, Kolte S, Pai K, Godse A, Pardeshi A, Bhav A, Kumar A. Jejuno gastric intussusception presenting with outlet obstruction. *Indian J Gastroenterol* 2003; **22**: 31-32 [PMID: 12617456]
- 5 **Gupta S**, Singh G. Retrograde jejuno gastric intussusception: an unusual cause of hematemesis (a case report). *J Postgrad Med* 1986; **32**: 105-106 [PMID: 3761208]
- 6 **Wolukau-Wanambwa PP**. An uncommon cause of haematemesis--retrograde jejuno-gastric intussusception. *Br J Clin Pract* 1979; **33**: 53-54, 58 [PMID: 497101]
- 7 **Jang WI**, Kim ND, Bae SW, Kim WT, Kwon SO, Yoon KS, Kim SY. Intussusception into the enteroanastomosis after Billroth II gastric resection; diagnosed by gastroscopy. *J Korean Med Sci* 1989; **4**: 51-54 [PMID: 2789738]
- 8 **Kwak JM**, Kim J, Suh SO. Anterograde jejunojejunal intussusception resulted in acute efferent loop syndrome after subtotal gastrectomy. *World J Gastroenterol* 2010; **16**: 3472-3474 [PMID: 20632454 DOI: 10.3748/wjg.v16.i27.3472]
- 9 **Goverman J**, Greenwald M, Gellman L, Gadaleta D. Antiperistaltic (retrograde) intussusception after Roux-en-Y gastric bypass. *Am Surg* 2004; **70**: 67-70 [PMID: 14964552]

**P-Reviewer:** Andrei S **S-Editor:** Wen LL  
**L-Editor:** Roemmele A **E-Editor:** Wang CH





## INSTRUCTIONS TO AUTHORS

### GENERAL INFORMATION

*World Journal of Clinical Cases* (*World J Clin Cases*, *WJCC*, online ISSN 2307-8960, DOI: 10.12998) is a peer-reviewed open access (OA) academic journal that aims to guide clinical practice and improve diagnostic and therapeutic skills of clinicians.

#### Aim and scope

The primary task of *WJCC* is to rapidly publish high-quality Autobiography, Case Report, Clinical Case Conference (Clinicopathological Conference), Clinical Management, Diagnostic Advances, Editorial, Field of Vision, Frontier, Medical Ethics, Original Articles, Clinical Practice, Meta-Analysis, Minireviews, Review, Therapeutics Advances, and Topic Highlight, in the fields of allergy, anesthesiology, cardiac medicine, clinical genetics, clinical neurology, critical care, dentistry, dermatology, emergency medicine, endocrinology, family medicine, gastroenterology and hepatology, geriatrics and gerontology, hematology, immunology, infectious diseases, internal medicine, obstetrics and gynecology, oncology, ophthalmology, orthopedics, otolaryngology, pathology, pediatrics, peripheral vascular disease, psychiatry, radiology, rehabilitation, respiratory medicine, rheumatology, surgery, toxicology, transplantation, and urology and nephrology.

*WJCC* is edited and published by Baishideng Publishing Group (BPG). BPG has a strong professional editorial team composed of science editors, language editors and electronic editors. BPG currently publishes 42 OA clinical medical journals, including 41 in English, has a total of 15 471 editorial board members or peer reviewers, and is a world first-class publisher.

#### Columns

The columns in the issues of *WJCC* will include: (1) Editorial: The editorial board members are invited to make comments on an important topic in their field in terms of its current research status and future directions to lead the development of this discipline; (2) Frontier: The editorial board members are invited to select a highly cited cutting-edge original paper of his/her own to summarize major findings, the problems that have been resolved and remain to be resolved, and future research directions to help readers understand his/her important academic point of view and future research directions in the field; (3) Diagnostic Advances: The editorial board members are invited to write high-quality diagnostic advances in their field to improve the diagnostic skills of readers. The topic covers general clinical diagnosis, differential diagnosis, pathological diagnosis, laboratory diagnosis, imaging diagnosis, endoscopic diagnosis, biotechnological diagnosis, functional diagnosis, and physical diagnosis; (4) Therapeutics Advances: The editorial board members are invited to write high-quality therapeutic advances in their field to help improve the therapeutic skills of readers. The topic covers medication therapy, psychotherapy, physical therapy, replacement therapy, interventional therapy, minimally invasive therapy, endoscopic therapy, transplantation therapy, and surgical therapy; (5) Field of Vision: The editorial board members are invited to write commentaries on classic articles, hot topic articles, or latest articles to keep readers at the forefront of research and increase their levels of clinical research. Classic articles refer to papers that are included in Web of Knowledge and have received a large number of citations (ranking in the top 1%) after being published for more

than years, reflecting the quality and impact of papers. Hot topic articles refer to papers that are included in Web of Knowledge and have received a large number of citations after being published for no more than 2 years, reflecting cutting-edge trends in scientific research. Latest articles refer to the latest published high-quality papers that are included in PubMed, reflecting the latest research trends. These commentary articles should focus on the status quo of research, the most important research topics, the problems that have now been resolved and remain to be resolved, and future research directions. Basic information about the article to be commented (including authors, article title, journal name, year, volume, and inclusive page numbers); (6) Minireviews: The editorial board members are invited to write short reviews on recent advances and trends in research of molecular biology, genomics, and related cutting-edge technologies to provide readers with the latest knowledge and help improve their diagnostic and therapeutic skills; (7) Review: To make a systematic review to focus on the status quo of research, the most important research topics, the problems that have now been resolved and remain to be resolved, and future research directions; (8) Topic Highlight: The editorial board members are invited to write a series of articles (7-10 articles) to comment and discuss a hot topic to help improve the diagnostic and therapeutic skills of readers; (9) Medical Ethics: The editorial board members are invited to write articles about medical ethics to increase readers' knowledge of medical ethics. The topic covers international ethics guidelines, animal studies, clinical trials, organ transplantation, etc.; (10) Clinical Case Conference or Clinicopathological Conference: The editorial board members are invited to contribute high-quality clinical case conference; (11) Original Articles: To report innovative and original findings in clinical research; (12) Clinical Practice: To briefly report the novel and innovative findings in clinical practice; (13) Meta-Analysis: Covers the systematic review, mixed treatment comparison, meta-regression, and overview of reviews, in order to summarize a given quantitative effect, e.g., the clinical effectiveness and safety of clinical treatments by combining data from two or more randomized controlled trials, thereby providing more precise and externally valid estimates than those which would stem from each individual dataset if analyzed separately from the others; (14) Case Report: To report a rare or typical case; (15) Letters to the Editor: To discuss and make reply to the contributions published in *WJCC*, or to introduce and comment on a controversial issue of general interest; (16) Book Reviews: To introduce and comment on quality monographs of clinical medicine; and (17) Autobiography: The editorial board members are invited to write their autobiography to provide readers with stories of success or failure in their scientific research career. The topic covers their basic personal information and information about when they started doing research work, where and how they did research work, what they have achieved, and their lessons from success or failure.

#### Name of journal

*World Journal of Clinical Cases*

#### ISSN

ISSN 2307-8960 (online)

#### Launch date

April 16, 2013

## Instructions to authors

### Frequency

Monthly

### Editors-in-Chief

**Giuseppe Di Lorenzo, MD, PhD, Professor,** Genitourinary Cancer Section and Rare-Cancer Center, University Federico II of Napoli, Via Sergio Pansini, 5 Ed. 1, 80131, Naples, Italy

**Jan Jacques Michiels, MD, PhD, Professor,** Primary Care, Medical Diagnostic Center Rijnmond Rotterdam, Bloodcoagulation, Internal and Vascular Medicine, Erasmus University Medical Center, Rotterdam, Goodheart Institute and Foundation, Erasmus Tower, Veenmos 13, 3069 AT, Erasmus City, Rotterdam, The Netherlands

**Sandro Vento, MD,** Department of Internal Medicine, University of Botswana, Private Bag 00713, Gaborone, Botswana

**Shuhei Yoshida, MD, PhD,** Division of Gastroenterology, Beth Israel Deaconess Medical Center, Dana 509, Harvard Medical School, 330 Brookline Ave, Boston, MA 02215, United States

### Editorial office

Jin-Lei Wang, Director

Xiu-Xia Song, Vice Director

*World Journal of Clinical Cases*

Room 903, Building D, Ocean International Center,  
No. 62 Dongsihuan Zhonglu, Chaoyang District,  
Beijing 100025, China

Telephone: +86-10-85381891

Fax: +86-10-85381893

E-mail: [wjcc@wjnet.com](mailto:wjcc@wjnet.com)

<http://www.wjnet.com>

### Publisher

Baishideng Publishing Group Co., Limited

Flat C, 23/F, Lucky Plaza, 315-321 Lockhart Road,

Wan Chai, Hong Kong, China

Telephone: +852-58042046

Fax: +852-31158812

E-mail: [bpgoffice@wjnet.com](mailto:bpgoffice@wjnet.com)

<http://www.wjnet.com>

### Production center

Beijing Baishideng BioMed Scientific Co., Limited

Room 903, Building D, Ocean International Center,

No. 62 Dongsihuan Zhonglu, Chaoyang District,

Beijing 100025, China

Telephone: +86-10-85381892

Fax: +86-10-85381893

### Representative office

USA Office

8226 Regency Drive,

Pleasanton, CA 94588-3144, United States

### Instructions to authors

Full instructions are available online at [http://www.wjnet.com/2307-8960/g\\_info\\_20100722180909.htm](http://www.wjnet.com/2307-8960/g_info_20100722180909.htm).

### Indexed and Abstracted in

Digital Object Identifier.

## SPECIAL STATEMENT

All articles published in this journal represent the viewpoints of the authors except where indicated otherwise.

### Biostatistical editing

Statistical review is performed after peer review. We invite an expert in Biomedical Statistics to evaluate the statistical method used in the paper, including *t*-test (group or paired comparisons), chi-

squared test, Redit, probit, logit, regression (linear, curvilinear, or stepwise), correlation, analysis of variance, analysis of covariance, *etc.* The reviewing points include: (1) Statistical methods should be described when they are used to verify the results; (2) Whether the statistical techniques are suitable or correct; (3) Only homogeneous data can be averaged. Standard deviations are preferred to standard errors. Give the number of observations and subjects (*n*). Losses in observations, such as drop-outs from the study should be reported; (4) Values such as ED50, LD50, IC50 should have their 95% confidence limits calculated and compared by weighted probit analysis (Bliss and Finney); and (5) The word 'significantly' should be replaced by its synonyms (if it indicates extent) or the *P* value (if it indicates statistical significance).

### Conflict-of-interest statement

In the interests of transparency and to help reviewers assess any potential bias, *WJCC* requires authors of all papers to declare any competing commercial, personal, political, intellectual, or religious interests in relation to the submitted work. Referees are also asked to indicate any potential conflict they might have reviewing a particular paper. Before submitting, authors are suggested to read "Uniform Requirements for Manuscripts Submitted to Biomedical Journals: Ethical Considerations in the Conduct and Reporting of Research: Conflicts of Interest" from International Committee of Medical Journal Editors (ICMJE), which is available at: [http://www.icmje.org/ethical\\_4conflicts.html](http://www.icmje.org/ethical_4conflicts.html).

Sample wording: [Name of individual] has received fees for serving as a speaker, a consultant and an advisory board member for [names of organizations], and has received research funding from [names of organization]. [Name of individual] is an employee of [name of organization]. [Name of individual] owns stocks and shares in [name of organization]. [Name of individual] owns patent [patent identification and brief description].

### Statement of informed consent

Manuscripts should contain a statement to the effect that all human studies have been reviewed by the appropriate ethics committee or it should be stated clearly in the text that all persons gave their informed consent prior to their inclusion in the study. Details that might disclose the identity of the subjects under study should be omitted. Authors should also draw attention to the Code of Ethics of the World Medical Association (Declaration of Helsinki, 1964, as revised in 2004).

### Statement of human and animal rights

When reporting the results from experiments, authors should follow the highest standards and the trial should conform to Good Clinical Practice (for example, US Food and Drug Administration Good Clinical Practice in FDA-Regulated Clinical Trials; UK Medicines Research Council Guidelines for Good Clinical Practice in Clinical Trials) and/or the World Medical Association Declaration of Helsinki. Generally, we suggest authors follow the lead investigator's national standard. If doubt exists whether the research was conducted in accordance with the above standards, the authors must explain the rationale for their approach and demonstrate that the institutional review body explicitly approved the doubtful aspects of the study.

Before submitting, authors should make their study approved by the relevant research ethics committee or institutional review board. If human participants were involved, manuscripts must be accompanied by a statement that the experiments were undertaken with the understanding and appropriate informed consent of each. Any personal item or information will not be published without explicit consents from the involved patients. If experimental animals were used, the materials and methods (experimental procedures) section must clearly indicate that appropriate measures were taken to minimize pain or discomfort, and details of animal care should be provided.

## SUBMISSION OF MANUSCRIPTS

Manuscripts should be typed in 1.5 line spacing and 12 pt. Book Antiqua with ample margins. Number all pages consecutively, and start each of the following sections on a new page: Title Page,



Abstract, Introduction, Materials and Methods, Results, Discussion, Acknowledgements, References, Tables, Figures, and Figure Legends. Neither the editors nor the publisher are responsible for the opinions expressed by contributors. Manuscripts formally accepted for publication become the permanent property of Baishideng Publishing Group Co., Limited, and may not be reproduced by any means, in whole or in part, without the written permission of both the authors and the publisher. We reserve the right to copy-edit and put onto our website accepted manuscripts. Authors should follow the relevant guidelines for the care and use of laboratory animals of their institution or national animal welfare committee. For the sake of transparency in regard to the performance and reporting of clinical trials, we endorse the policy of the ICMJE to refuse to publish papers on clinical trial results if the trial was not recorded in a publicly-accessible registry at its outset. The only register now available, to our knowledge, is <http://www.clinicaltrials.gov> sponsored by the United States National Library of Medicine and we encourage all potential contributors to register with it. However, in the case that other registers become available you will be duly notified. A letter of recommendation from each author's organization should be provided with the contributed article to ensure the privacy and secrecy of research is protected.

Authors should retain one copy of the text, tables, photographs and illustrations because rejected manuscripts will not be returned to the author(s) and the editors will not be responsible for loss or damage to photographs and illustrations sustained during mailing.

#### Online submissions

Manuscripts should be submitted through the Online Submission System at: <http://www.wjnet.com/esps/>. Authors are highly recommended to consult the ONLINE INSTRUCTIONS TO AUTHORS ([http://www.wjnet.com/2307-8960/g\\_info\\_20100722180909.htm](http://www.wjnet.com/2307-8960/g_info_20100722180909.htm)) before attempting to submit online. For assistance, authors encountering problems with the Online Submission System may send an email describing the problem to [wjcc@wjnet.com](mailto:wjcc@wjnet.com), or by telephone: +86-10-85381892. If you submit your manuscript online, do not make a postal contribution. Repeated online submission for the same manuscript is strictly prohibited.

### MANUSCRIPT PREPARATION

All contributions should be written in English. All articles must be submitted using word-processing software. All submissions must be typed in 1.5 line spacing and 12 pt. Book Antiqua with ample margins. Style should conform to our house format. Required information for each of the manuscript sections is as follows:

#### Title page

**Title:** Title should be less than 12 words.

**Running title:** A short running title of less than 6 words should be provided.

**Authorship:** Authorship credit should be in accordance with the standard proposed by ICMJE, based on (1) substantial contributions to conception and design, acquisition of data, or analysis and interpretation of data; (2) drafting the article or revising it critically for important intellectual content; and (3) final approval of the version to be published. Authors should meet conditions 1, 2, and 3.

**Institution:** Author names should be given first, then the complete name of institution, city, province and postcode. For example, Xu-Chen Zhang, Li-Xin Mei, Department of Pathology, Chengde Medical College, Chengde 067000, Hebei Province, China. One author may be represented from two institutions, for example, George Sgourakis, Department of General, Visceral, and Transplantation Surgery, Essen 45122, Germany; George Sgourakis, 2nd Surgical Department, Korgialenio-Benakio Red Cross Hospital, Athens 15451, Greece

**Author contributions:** The format of this section should be: Author contributions: Wang CL and Liang L contributed equally

to this work; Wang CL, Liang L, Fu JF, Zou CC, Hong F and Wu XM designed the research; Wang CL, Zou CC, Hong F and Wu XM performed the research; Xue JZ and Lu JR contributed new reagents/analytic tools; Wang CL, Liang L and Fu JF analyzed the data; and Wang CL, Liang L and Fu JF wrote the paper.

**Supportive foundations:** The complete name and number of supportive foundations should be provided, *e.g.*, Supported by National Natural Science Foundation of China, No. 30224801

**Correspondence to:** Only one corresponding address should be provided. Author names should be given first, then author title, affiliation, the complete name of institution, city, postcode, province, country, and email. All the letters in the email should be in lower case. A space interval should be inserted between country name and email address. For example, Montgomery Bissell, MD, Professor of Medicine, Chief, Liver Center, Gastroenterology Division, University of California, Box 0538, San Francisco, CA 94143, United States. [montgomery.bissell@ucsf.edu](mailto:montgomery.bissell@ucsf.edu)

**Telephone and fax:** Telephone and fax should consist of +, country number, district number and telephone or fax number, *e.g.*, Telephone: +86-10-85381892 Fax: +86-10-85381893

**Peer reviewers:** All articles received are subject to peer review. Normally, three experts are invited for each article. Decision on acceptance is made only when at least two experts recommend publication of an article. All peer-reviewers are acknowledged on Express Submission and Peer-review System website.

#### Abstract

There are unstructured abstracts (no less than 200 words) and structured abstracts. The specific requirements for structured abstracts are as follows:

An informative, structured abstract should accompany each manuscript. Abstracts of original contributions should be structured into the following sections: AIM (no more than 20 words; Only the purpose of the study should be included. Please write the Aim in the form of "To investigate/study/..."), METHODS (no less than 140 words for Original Articles; and no less than 80 words for Brief Articles), RESULTS (no less than 150 words for Original Articles and no less than 120 words for Brief Articles; You should present *P* values where appropriate and must provide relevant data to illustrate how they were obtained, *e.g.*,  $6.92 \pm 3.86$  vs  $3.61 \pm 1.67$ ,  $P < 0.001$ ), and CONCLUSION (no more than 26 words).

#### Key words

Please list 5-10 key words, selected mainly from *Index Medicus*, which reflect the content of the study.

#### Core tip

Please write a summary of less than 100 words to outline the most innovative and important arguments and core contents in your paper to attract readers.

#### Text

For articles of these sections, original articles and brief articles, the main text should be structured into the following sections: INTRODUCTION, MATERIALS AND METHODS, RESULTS and DISCUSSION, and should include appropriate Figures and Tables. Data should be presented in the main text or in Figures and Tables, but not in both.

#### Illustrations

Figures should be numbered as 1, 2, 3, *etc.*, and mentioned clearly in the main text. Provide a brief title for each figure on a separate page. Detailed legends should not be provided under the figures. This part should be added into the text where the figures are applicable. Keeping all elements compiled is necessary in line-art image. Scale bars should be used rather than magnification factors, with the length of



## Instructions to authors

the bar defined in the legend rather than on the bar itself. File names should identify the figure and panel. Avoid layering type directly over shaded or textured areas. Please use uniform legends for the same subjects. For example: Figure 1 Pathological changes in atrophic gastritis after treatment. A: ...; B: ...; C: ...; D: ...; E: ...; F: ...; G: ...*etc.* It is our principle to publish high resolution-figures for the E-versions.

### Tables

Three-line tables should be numbered 1, 2, 3, *etc.*, and mentioned clearly in the main text. Provide a brief title for each table. Detailed legends should not be included under tables, but rather added into the text where applicable. The information should complement, but not duplicate the text. Use one horizontal line under the title, a second under column heads, and a third below the Table, above any footnotes. Vertical and italic lines should be omitted.

### Notes in tables and illustrations

Data that are not statistically significant should not be noted. <sup>a</sup>*P* < 0.05, <sup>b</sup>*P* < 0.01 should be noted (*P* > 0.05 should not be noted). If there are other series of *P* values, <sup>c</sup>*P* < 0.05 and <sup>d</sup>*P* < 0.01 are used. A third series of *P* values can be expressed as <sup>e</sup>*P* < 0.05 and <sup>f</sup>*P* < 0.01. Other notes in tables or under illustrations should be expressed as <sup>1</sup>F, <sup>2</sup>F, <sup>3</sup>F; or sometimes as other symbols with a superscript (Arabic numerals) in the upper left corner. In a multi-curve illustration, each curve should be labeled with ●, ○, ■, □, ▲, △, *etc.*, in a certain sequence.

### Acknowledgments

Brief acknowledgments of persons who have made genuine contributions to the manuscript and who endorse the data and conclusions should be included. Authors are responsible for obtaining written permission to use any copyrighted text and/or illustrations.

## REFERENCES

### Coding system

The author should number the references in Arabic numerals according to the citation order in the text. Put reference numbers in square brackets in superscript at the end of citation content or after the cited author's name. For citation content which is part of the narration, the coding number and square brackets should be typeset normally. For example, "Crohn's disease (CD) is associated with increased intestinal permeability<sup>[1,2]</sup>". If references are cited directly in the text, they should be put together within the text, for example, "From references<sup>[19,22-24]</sup>, we know that..."

When the authors write the references, please ensure that the order in text is the same as in the references section, and also ensure the spelling accuracy of the first author's name. Do not list the same citation twice.

### PMID and DOI

Please provide PubMed citation numbers to the reference list, *e.g.*, PMID and DOI, which can be found at <http://www.ncbi.nlm.nih.gov/sites/entrez?db=pubmed> and <http://www.crossref.org/SimpleTextQuery/>, respectively. The numbers will be used in E-version of this journal.

### Style for journal references

Authors: the name of the first author should be typed in bold-faced letters. The family name of all authors should be typed with the initial letter capitalized, followed by their abbreviated first and middle initials. (For example, Lian-Sheng Ma is abbreviated as Ma LS, Bo-Rong Pan as Pan BR). The title of the cited article and italicized journal title (journal title should be in its abbreviated form as shown in PubMed), publication date, volume number (in black), start page, and end page [PMID: 11819634 DOI: 10.3748/wjg.13.5396].

### Style for book references

Authors: the name of the first author should be typed in bold-faced letters. The surname of all authors should be typed with the initial letter capitalized, followed by their abbreviated middle and first initials. (For example, Lian-Sheng Ma is abbreviated as Ma LS, Bo-

Rong Pan as Pan BR) Book title. Publication number. Publication place: Publication press, Year: start page and end page.

### Format

#### Journals

*English journal article (list all authors and include the PMID where applicable)*

- 1 **Jung EM**, Clevert DA, Schreyer AG, Schmitt S, Rennert J, Kubale R, Feuerbach S, Jung F. Evaluation of quantitative contrast harmonic imaging to assess malignancy of liver tumors: A prospective controlled two-center study. *World J Gastroenterol* 2007; **13**: 6356-6364 [PMID: 18081224 DOI: 10.3748/wjg.13.6356]

*Chinese journal article (list all authors and include the PMID where applicable)*

- 2 **Lin GZ**, Wang XZ, Wang P, Lin J, Yang FD. Immunologic effect of Jianpi Yishen decoction in treatment of Pixu-diarhoea. *Shijie Huaren Xiaobua Zazhi* 1999; **7**: 285-287

*In press*

- 3 **Tian D**, Araki H, Stahl E, Bergelson J, Kreitman M. Signature of balancing selection in Arabidopsis. *Proc Natl Acad Sci USA* 2006; In press

*Organization as author*

- 4 **Diabetes Prevention Program Research Group**. Hypertension, insulin, and proinsulin in participants with impaired glucose tolerance. *Hypertension* 2002; **40**: 679-686 [PMID: 12411462 PMID:2516377 DOI:10.1161/01.HYP.0000035706.28494.09]

*Both personal authors and an organization as author*

- 5 **Vallancien G**, Emberton M, Harving N, van Moorselaar RJ; Alf-One Study Group. Sexual dysfunction in 1, 274 European men suffering from lower urinary tract symptoms. *J Urol* 2003; **169**: 2257-2261 [PMID: 12771764 DOI:10.1097/01.ju.0000067940.76090.73]

*No author given*

- 6 21st century heart solution may have a sting in the tail. *BMJ* 2002; **325**: 184 [PMID: 12142303 DOI:10.1136/bmj.325.7357.184]

*Volume with supplement*

- 7 **Geraud G**, Spierings EL, Keywood C. Tolerability and safety of frovatriptan with short- and long-term use for treatment of migraine and in comparison with sumatriptan. *Headache* 2002; **42** Suppl 2: S93-99 [PMID: 12028325 DOI:10.1046/j.1526-4610.42.s2.7.x]

*Issue with no volume*

- 8 **Banit DM**, Kaufer H, Hartford JM. Intraoperative frozen section analysis in revision total joint arthroplasty. *Clin Orthop Relat Res* 2002; (**401**): 230-238 [PMID: 12151900 DOI:10.1097/00003086-200208000-00026]

*No volume or issue*

- 9 Outreach: Bringing HIV-positive individuals into care. *HRS-A Careaction* 2002; 1-6 [PMID: 12154804]

### Books

*Personal author(s)*

- 10 **Sherlock S**, Dooley J. Diseases of the liver and biliary system. 9th ed. Oxford: Blackwell Sci Pub, 1993: 258-296

*Chapter in a book (list all authors)*

- 11 **Lam SK**. Academic investigator's perspectives of medical treatment for peptic ulcer. In: Swabb EA, Azabo S. Ulcer disease: investigation and basis for therapy. New York: Marcel Dekker, 1991: 431-450

*Author(s) and editor(s)*

- 12 **Breedlove GK**, Schorfeide AM. Adolescent pregnancy. 2nd ed. Wiczorek RR, editor. White Plains (NY): March of Dimes Education Services, 2001: 20-34

*Conference proceedings*

- 13 **Harnden P**, Joffe JK, Jones WG, editors. Germ cell tumours V. Proceedings of the 5th Germ cell tumours Conference; 2001 Sep 13-15; Leeds, UK. New York: Springer, 2002: 30-56

*Conference paper*

- 14 **Christensen S**, Oppacher F. An analysis of Koza's computational effort statistic for genetic programming. In: Foster JA,

Lutton E, Miller J, Ryan C, Tettamanzi AG, editors. Genetic programming. EuroGP 2002: Proceedings of the 5th European Conference on Genetic Programming; 2002 Apr 3-5; Kinsdale, Ireland. Berlin: Springer, 2002: 182-191

#### Electronic journal (list all authors)

- 15 Morse SS. Factors in the emergence of infectious diseases. Emerg Infect Dis serial online, 1995-01-03, cited 1996-06-05; 1(1): 24 screens. Available from: URL: <http://www.cdc.gov/ncidod/eid/index.htm>

#### Patent (list all authors)

- 16 Pagedas AC, inventor; Ancel Surgical R&D Inc., assignee. Flexible endoscopic grasping and cutting device and positioning tool assembly. United States patent US 20020103498. 2002 Aug 1

#### Statistical data

Write as mean  $\pm$  SD or mean  $\pm$  SE.

#### Statistical expression

Express *t* test as *t* (in italics), *F* test as *F* (in italics), chi square test as  $\chi^2$  (in Greek), related coefficient as *r* (in italics), degree of freedom as *v* (in Greek), sample number as *n* (in italics), and probability as *P* (in italics).

#### Units

Use SI units. For example: body mass, *m* (B) = 78 kg; blood pressure, *p* (B) = 16.2/12.3 kPa; incubation time, *t* (incubation) = 96 h; blood glucose concentration, *c* (glucose)  $6.4 \pm 2.1$  mmol/L; blood CEA mass concentration, *p* (CEA) = 8.6  $24.5 \mu\text{g/L}$ ; CO<sub>2</sub> volume fraction, 50 mL/L CO<sub>2</sub>, not 5% CO<sub>2</sub>; likewise for 40 g/L formaldehyde, not 10% formalin; and mass fraction, 8 ng/g, *etc.* Arabic numerals such as 23, 243, 641 should be read 23 243 641.

The format for how to accurately write common units and quantum numbers can be found at: [http://www.wjgnet.com/2307-8960/g\\_info\\_20100725073806.htm](http://www.wjgnet.com/2307-8960/g_info_20100725073806.htm).

#### Abbreviations

Standard abbreviations should be defined in the abstract and on first mention in the text. In general, terms should not be abbreviated unless they are used repeatedly and the abbreviation is helpful to the reader. Permissible abbreviations are listed in Units, Symbols and Abbreviations: A Guide for Biological and Medical Editors and Authors (Ed. Baron DN, 1988) published by The Royal Society of Medicine, London. Certain commonly used abbreviations, such as DNA, RNA, HIV, LD50, PCR, HBV, ECG, WBC, RBC, CT, ESR, CSF, IgG, ELISA, PBS, ATP, EDTA, mAb, can be used directly without further explanation.

#### Italics

Quantities: *t* time or temperature, *c* concentration, *A* area, *l* length, *m* mass, *V* volume.

Genotypes: *gyrA*, *arg 1*, *c myc*, *c fos*, *etc.*

Restriction enzymes: *EcoRI*, *HindI*, *BamHI*, *Kbo I*, *Kpn I*, *etc.*

Biology: *H. pylori*, *E. coli*, *etc.*

#### Examples for paper writing

All types of articles' writing style and requirement will be found in the link: <http://www.wjgnet.com/esps/NavigationInfo.aspx?id=15>

## RESUBMISSION OF THE REVISED MANUSCRIPTS

Authors must revise their manuscript carefully according to the revision policies of Baishideng Publishing Group Co., Limited. The revised version, along with the signed copyright transfer agreement, responses to the reviewers, and English language Grade A certificate (for non-native speakers of English), should be submitted to the online system *via* the link contained in the e-mail sent by the editor. If you have any questions about the revision, please send e-mail to [esps@wjgnet.com](mailto:esps@wjgnet.com).

#### Language evaluation

The language of a manuscript will be graded before it is sent for revision. (1) Grade A: priority publishing; (2) Grade B: minor language polishing; (3) Grade C: a great deal of language polishing needed; and (4) Grade D: rejected. Revised articles should reach Grade A.

#### Copyright assignment form

Please download a Copyright assignment form from [http://www.wjgnet.com/2307-8960/g\\_info\\_20100725073726.htm](http://www.wjgnet.com/2307-8960/g_info_20100725073726.htm).

#### Responses to reviewers

Please revise your article according to the comments/suggestions provided by the reviewers. The format for responses to the reviewers' comments can be found at: [http://www.wjgnet.com/2307-8960/g\\_info\\_20100725073445.htm](http://www.wjgnet.com/2307-8960/g_info_20100725073445.htm).

#### Proof of financial support

For papers supported by a foundation, authors should provide a copy of the approval document and serial number of the foundation.

## STATEMENT ABOUT ANONYMOUS PUBLICATION OF THE PEER REVIEWERS' COMMENTS

In order to increase the quality of peer review, push authors to carefully revise their manuscripts based on the peer reviewers' comments, and promote academic interactions among peer reviewers, authors and readers, we decide to anonymously publish the reviewers' comments and author's responses at the same time the manuscript is published online.

## PUBLICATION FEE

WJCC is an international, peer-reviewed, OA online journal. Articles published by this journal are distributed under the terms of the Creative Commons Attribution Non-commercial License, which permits use, distribution, and reproduction in any medium and format, provided the original work is properly cited. The use is non-commercial and is otherwise in compliance with the license. Authors of accepted articles must pay a publication fee. Publication fee: 600 USD per article. All invited articles are published free of charge.

# World Journal of *Clinical Cases*

*World J Clin Cases* 2014 February 16; 2(2): 27-51





## Contents

Monthly Volume 2 Number 2 February 16, 2014

### MINIREVIEWS

- 27 Unilateral peripheral neuropathic pain: The role of neurodiagnostic skin biopsy  
*Buonocore M*

### CASE REPORT

- 32 Surgical removal of a large mobile left ventricular thrombus *via* left atriotomy  
*Tanaka D, Unai S, Diehl JT, Hirose H*
- 36 Unexpected anomaly of the common bile duct and pancreatic duct  
*Chavalitdhamrong D, Draganov PV*
- 39 Severe isolated sciatic neuropathy due to a modified lotus position  
*Bosma JW, Wijntjes J, Hilgevoord TA, Veenstra J*
- 42 Utility of diffusion-weighted imaging in the diagnosis of inguinal lymph node metastasis with malignant melanoma  
*Bayraktutan U, Kantarci M, Pirimoglu B, Ogul H, Okur A, Gursan N*
- 45 Baastrup's disease: The kissing spine  
*Singla A, Shankar V, Mittal S, Agarwal A, Garg B*
- 48 Ameloblastic carcinoma: Report of a rare case  
*Srikanth MD, Radhika B, Metta K, Renuka NV*



**APPENDIX** I-V Instructions to authors

**ABOUT COVER** Editorial Board Member of *World Journal of Clinical Cases*, Michelangelo Buonocore, MD, Unit of Clinical Neurophysiology, Fondazione Salvatore Maugeri, Via Maugeri 10, 27100 Pavia, Italy

**AIM AND SCOPE** *World Journal of Clinical Cases* (*World J Clin Cases*, *WJCC*, online ISSN 2307-8960, DOI: 10.12998) is a peer-reviewed open access academic journal that aims to guide clinical practice and improve diagnostic and therapeutic skills of clinicians.

The primary task of *WJCC* is to rapidly publish high-quality Autobiography, Case Report, Clinical Case Conference (Clinicopathological Conference), Clinical Management, Diagnostic Advances, Editorial, Field of Vision, Frontier, Medical Ethics, Original Articles, Clinical Practice, Meta-Analysis, Minireviews, Review, Therapeutics Advances, and Topic Highlight, in the fields of allergy, anesthesiology, cardiac medicine, clinical genetics, clinical neurology, critical care, dentistry, dermatology, emergency medicine, endocrinology, family medicine, gastroenterology and hepatology, geriatrics and gerontology, hematology, immunology, infectious diseases, internal medicine, obstetrics and gynecology, oncology, ophthalmology, orthopedics, otolaryngology, pathology, pediatrics, peripheral vascular disease, psychiatry, radiology, rehabilitation, respiratory medicine, rheumatology, surgery, toxicology, transplantation, and urology and nephrology.

**INDEXING/ABSTRACTING** *World Journal of Clinical Cases* is now indexed in PubMed Central, PubMed, Digital Object Identifier.

**FLYLEAF** I-V Editorial Board

**EDITORS FOR THIS ISSUE** Responsible Assistant Editor: *Xin-Xin Che* Responsible Science Editor: *Xiu-Xia Song*  
Responsible Electronic Editor: *Huan-Liang Wu*  
Proofing Editor-in-Chief: *Lian-Sheng Ma*

**NAME OF JOURNAL**  
*World Journal of Clinical Cases*

**ISSN**  
ISSN 2307-8960 (online)

**LAUNCH DATE**  
April 16, 2013

**FREQUENCY**  
Monthly

**EDITORS-IN-CHIEF**  
**Giuseppe Di Lorenzo, MD, PhD, Professor**, Genitourinary Cancer Section and Rare-Cancer Center, University Federico II of Napoli, Via Sergio Pansini, 5 Ed. 1, 80131, Naples, Italy

**Jan Jacques Michiels, MD, PhD, Professor**, Primary Care, Medical Diagnostic Center Rijnmond Rotterdam, Bloodcoagulation, Internal and Vascular Medicine, Erasmus University Medical Center, Rotterdam, Goodheart Institute and Foundation, Erasmus Tower, Veenmos 13, 3069 AT, Erasmus City, Rotterdam, The Netherlands

**Sandro Vento, MD**, Department of Internal Medicine,

University of Botswana, Private Bag 00713, Gaborone, Botswana

**Shuhei Yoshida, MD, PhD**, Division of Gastroenterology, Beth Israel Deaconess Medical Center, Dana 509, Harvard Medical School, 330 Brookline Ave, Boston, MA 02215, United States

**EDITORIAL OFFICE**  
Jin-Lei Wang, Director  
Xiu-Xia Song, Vice Director  
*World Journal of Clinical Cases*  
Room 903, Building D, Ocean International Center, No. 62 Dongsihuan Zhonglu, Chaoyang District, Beijing 100025, China  
Telephone: +86-10-85381891  
Fax: +86-10-85381893  
E-mail: [bpgoffice@wjgnet.com](mailto:bpgoffice@wjgnet.com)  
<http://www.wjgnet.com>

**PUBLISHER**  
Baishideng Publishing Group Co., Limited  
Flat C, 23/F, Lucky Plaza,  
315-321 Lockhart Road, Wan Chai,  
Hong Kong, China  
Fax: +852-6555-7188  
Telephone: +852-3177-9906

E-mail: [bpgoffice@wjgnet.com](mailto:bpgoffice@wjgnet.com)  
<http://www.wjgnet.com>

**PUBLICATION DATE**  
February 16, 2014

**COPYRIGHT**  
© 2014 Baishideng Publishing Group Co., Limited. Articles published by this Open Access journal are distributed under the terms of the Creative Commons Attribution Non-commercial License, which permits use, distribution, and reproduction in any medium, provided the original work is properly cited, the use is non commercial and is otherwise in compliance with the license.

**SPECIAL STATEMENT**  
All articles published in this journal represent the viewpoints of the authors except where indicated otherwise.

**INSTRUCTIONS TO AUTHORS**  
Full instructions are available online at [http://www.wjgnet.com/2307-8960/g\\_info\\_20100722180909.htm](http://www.wjgnet.com/2307-8960/g_info_20100722180909.htm)

**ONLINE SUBMISSION**  
<http://www.wjgnet.com/esp/>

## Unilateral peripheral neuropathic pain: The role of neurodiagnostic skin biopsy

Michelangelo Buonocore

Michelangelo Buonocore, Unit of Clinical Neurophysiology and Neurodiagnostic Skin Biopsy, Fondazione Salvatore Maugeri, Scientific Institute of Pavia, 27100 Pavia, Italy

Author contributions: Buonocore M contributed to the manuscript.

Correspondence to: Michelangelo Buonocore, MD, Clinical Neurophysiology Unit, "Salvatore Maugeri" Foundation-Scientific Institute of Pavia, Via Maugeri 10, 27100 Pavia, Italy. [michelangelo.buonocore@fsm.it](mailto:michelangelo.buonocore@fsm.it)

Telephone: +39-382-592392 Fax: +39-382-592020

Received: October 3, 2013 Revised: December 9, 2013

Accepted: December 17, 2013

Published online: February 16, 2014

### Abstract

According to the current definition of neuropathic pain ("pain arising as a direct consequence of a lesion or disease affecting the somatosensory system"), the demonstration of a lesion or disease involving the somatosensory system is mandatory for the diagnosis of definite neuropathic pain. Although several methods are currently available for this aim, none is suitable for every type of disease (or lesion). Neurodiagnostic skin biopsy (NSB) is a relatively new technique for the diagnosis of peripheral nerve lesions. It is an objective method, completely independent from the patient's complaining, based on immunohistochemical staining techniques that allow measurement of the density of the epidermal nerve fibers, currently considered the free nerve endings of small diameter (A-delta and C) afferent fibers. NSB has the important property of being used to investigate the skin, allowing obtaining a diagnosis of small fiber axonal neuropathy of peripheral nerves supplying every body part covered by skin. This feature appears to be very important, particularly in cases of unilateral nerve lesions, because it allows going beyond the possibilities of neurophysiological tests which are available only for a limited number of peripheral nerves. All these characteristics make NSB a precious instrument for the diagnosis of peripheral uni-

lateral neuropathic pain.

© 2014 Baishideng Publishing Group Co., Limited. All rights reserved.

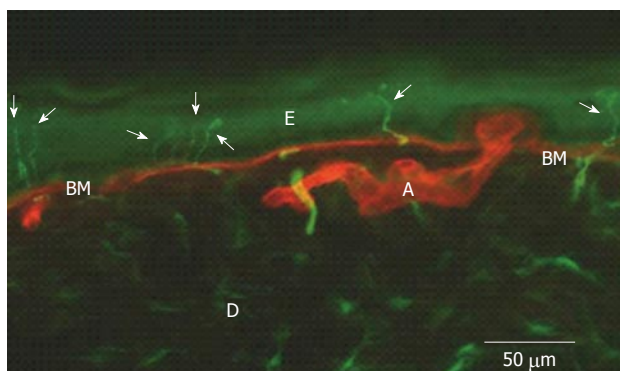
**Key words:** Skin biopsy; Neuropathic pain; Diagnosis; Peripheral nerve lesion; Innervation

**Core tip:** The demonstration of a lesion or disease involving the somatosensory system is mandatory for the diagnosis of definite neuropathic pain. Unfortunately, none of the currently available methods is suitable for every type of nerve lesion. Neurodiagnostic skin biopsy (NSB) is an objective method to measure the density of epidermal sensory small fibers. In case of unilateral nerve lesions, it goes beyond the diagnostic possibilities of neurophysiological tests, allowing the diagnosis of axonal neuropathies of peripheral nerves supplying every body part covered by skin. For these reasons, NSB represents a precious tool for the diagnosis of peripheral unilateral neuropathic pain.

Buonocore M. Unilateral peripheral neuropathic pain: The role of neurodiagnostic skin biopsy. *World J Clin Cases* 2014; 2(2): 27-31 Available from: URL: <http://www.wjgnet.com/2307-8960/full/v2/i2/27.htm> DOI: <http://dx.doi.org/10.12998/wjcc.v2.i2.27>

### UNILATERAL NEUROPATHIC PAIN

In 2008, the special interest group for neuropathic pain of the International Association for the Study of Pain (IASP) proposed a new definition of neuropathic pain: "pain arising as a direct consequence of a lesion or disease affecting the somatosensory system"<sup>[1]</sup>. This new definition was accepted by the IASP and is now largely used all over the world. According to it, neuropathic pain conditions have several possible mechanisms which ex-



**Figure 1** Epidermal nerve fibers (arrows) identified by immunofluorescence in the distal leg of a normal subject (in green, PGP 9.5 staining of nerve fibers; in red, type IV collagen staining of basement membrane and blood vessels). E: Epidermis; D: Dermis; BM: Basement Membrane; A: Artery.

press different phenotypes and clinical presentations. On this basis, neuropathic pain has to be divided into at least central and peripheral neuropathic pain, depending on which part of the nervous system is involved. Peripheral neuropathic pain is sustained by peripheral nerve lesions that can have various types of presentation<sup>[2]</sup>. In particular, among the multiform pathophysiological expressions, one of the main differences is based on symmetrical or asymmetrical pathology sustaining the painful clinical syndromes. Nerve lesions associated with neuropathic pain can indeed be symmetrical, *e.g.*, polyneuropathies, or asymmetrical, *e.g.*, herpes zoster neuropathy. Although there are well-documented contralateral effects following a painful lesion<sup>[3]</sup>, only asymmetrical nerve lesions sustain the so-called unilateral neuropathic pain.

Several forms of unilateral peripheral nerve lesions are possible<sup>[2,4]</sup>. They can be roughly divided into mononeuropathies, radiculopathies and plexopathies. The most common clinical presentation is mononeuropathy, *i.e.*, a lesion involving only one peripheral nerve, such as the median nerve lesion in the carpal tunnel syndrome. Another common clinical presentation of unilateral peripheral nerve lesion is radiculopathy, a frequent consequence of an intervertebral disk herniation or other pathologies of the lumbar or cervical spine. Plexopathies are rarer than other unilateral nerve lesions, the most frequent being brachial plexopathy, commonly caused by trauma or disorders involving neighboring structures.

## CLINICAL NEUROPHYSIOLOGICAL TESTS FOR THE DIAGNOSIS OF UNILATERAL PERIPHERAL NERVE LESIONS

In cases of suspected peripheral unilateral neuropathic pain, in order to demonstrate the presence of a peripheral nerve lesion sustaining the painful condition, the first diagnostic step following the clinical examination is usually the execution of neurophysiological tests, in particular electromyography (EMG) and electroneurography (ENG or nerve conduction studies)<sup>[5-8]</sup>. Unfortunately,

those tests have two major limitations. The first is the impossibility of using them in every part of the body (*e.g.*, the trunk) and the second is the fact that they investigate only large diameter fiber functions, part of the lemniscal system which is only one of the two tracts of the somatosensory system, the lesion (or disease) of which is mandatory for the diagnosis of neuropathic pain<sup>[1]</sup>. Another possible tool to test the function of peripheral large diameter/lemniscal fibers are somatosensory evoked potentials<sup>[7,9,10]</sup> that can be useful to study the proximal parts of the peripheral nervous system, but substantially share the same limitations of EMG and ENG. The small diameter fibers' functions can be neurophysiologically investigated by Laser Evoked Potentials<sup>[10-12]</sup>, although this test is still confined to specialized neurophysiological labs, is time consuming and currently is not used for routine diagnostic evaluation.

Finally, another test for evaluating small fiber afferent function is Quantitative Sensory Testing<sup>[13-15]</sup>. The controlled application of thermal stimuli indeed allows investigating the spinothalamic functions, both in its A-delta (cold stimuli) and C component (warm stimuli). The major limit of this method is the necessity for the patient's cooperation. On the other hand, the most important advantage is the possibility of studying the entire body surface and above all to identify and measure hypersensitivity phenomena, such as thermal allodynia and hyperalgesia.

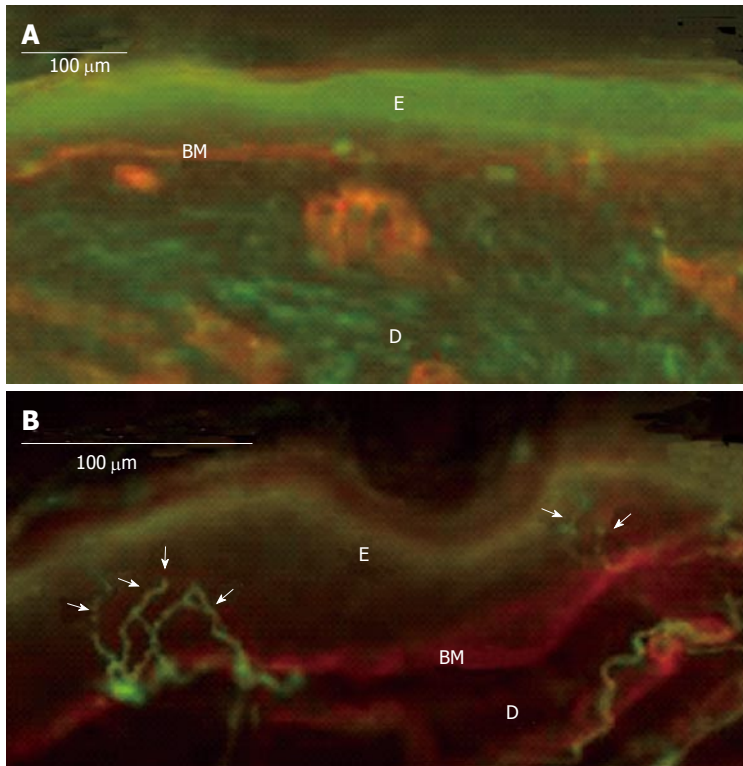
## NEURODIAGNOSTIC SKIN BIOPSY

Neurodiagnostic skin biopsy (NSB) is a relatively new technique for the diagnosis of peripheral neuropathies<sup>[16-18]</sup>. It is an objective method based on a skin biopsy performed by a circular punch, usually 3 mm diameter, and on immunohistochemical staining techniques that allow identifying the epidermal nerve fibers. To this aim, both bright-field and immunofluorescence (Figure 1) can be used, allowing calculation of the Epidermal Nerve Fiber Density (ENFD)<sup>[19]</sup>. It is important to underline that epidermal nerve fibers are currently exclusively considered the free nerve endings of small diameter (A-delta and C) afferent fibers<sup>[20]</sup>, a part of the spinothalamic tract physiologically conveying thermal and painful sensations from the periphery to the brain. Interestingly, among all the nerve fibers present in a peripheral nerve, the great majority are just small diameter fibers<sup>[21]</sup>.

## NSB FOR THE DIAGNOSIS OF PERIPHERAL NEUROPATHIES IN BODY PARTS IMPOSSIBLE TO INVESTIGATE BY CLINICAL NEUROPHYSIOLOGICAL TESTS

Due to the continuous advances in knowledge that have occurred in the last ten years, NSB is currently considered an important diagnostic tool for neurologists<sup>[22,23]</sup>.

NSB has the important property of being used to in-



**Figure 2 Complete denervation of epidermis (and dermis) in an 82-year-old patient with a severe post-herpetic neuralgia (A), normal, contralateral, mirror skin innervation (13 fibers/mm) (B).** Immunofluorescence method: In green, PGP 9.5 staining of nerve fibers; in red, type IV collagen staining of basement membrane and blood vessels; Arrows: Epidermal nerve fibers; E: Epidermis; D: Dermis; BM: Basement Membrane.

investigate the skin, allowing obtaining a diagnosis of small fiber axonal neuropathy of peripheral nerves innervating every body part covered by skin<sup>[24,25]</sup>.

This feature appears to be very important because it allows going beyond the possibilities of neurophysiological tests which are available only for a limited number of peripheral nerves. It follows on that NSB allows reaching a diagnosis of neuropathy for “difficult” nerves, such as those of the trunk or occipital nerves frequently (and irregularly) involved in post-herpetic neuralgia<sup>[26]</sup>. An example of NSB clinical use is given in Figure 2 which shows a severe, unilateral decrease of ENFD in the neck skin of a patient with post-herpetic neuralgia.

Another important property of NSB is the ability to identify lesions involving small branches of peripheral nerves which cannot be investigated by neurophysiological tests. This feature of NSB appears to be particularly important in post-traumatic peripheral nerve lesions where one lesion is different from another.

In this context, it is important to highlight a recent paper where NSB showed a significant asymmetry in a spinal cord injury patient complaining of a bilateral burning and pricking pain at the level of injury<sup>[27]</sup>. Interestingly, NSB not only allowed demonstration of the presence of two different mechanisms leading to identical symptoms, but also to justify a different efficacy of the same treatment in the two sides. Continuing to talk of possible pain mechanisms, in a very recent paper, NSB findings suggested skin hyperinnervation as a possible cause for the development of dynamic mechanical allodynia following finger amputation<sup>[28]</sup>.

Another recent study confirmed that NSB can allow getting information from the skin of several parts of the body. In that study, the epidermal innervation was studied

in burn patients with unilateral injuries, allowing to suggest a possible correlation between the residual cutaneous innervation and the development of chronic pain<sup>[29]</sup>.

NSB can also be useful in other clinical contexts. For example, it can also be used in differentiating neuropathic from referred pain, as demonstrated in a very recent paper in patients with endometriosis and unilateral thigh pain<sup>[30]</sup>. Moreover, it has been used for assessing the involvement of the peripheral nervous system in a dermatological manifestation of neurological disease, such as a dyshidrotic eczema in a patient with ulnar neuropathy or a unilateral pruritus on the paretic side of a stroke patient<sup>[31]</sup>. Finally, NSB can also be used to exclude a neuropathic pathophysiology of a clinical pain, as demonstrated in Parry-Romberg syndrome, a rare painful condition characterized by progressive hemifacial atrophy and unilateral facial pain<sup>[32]</sup>.

Considering the current evidence on NSB and the well-known specific diagnostic properties of neurophysiological tests, it is possible to suggest a diagnostic sequence that can be useful to confirm the diagnosis of unilateral peripheral neuropathic pain (Figure 3).

## EPIDERMAL INNERVATION SYMMETRY RATIO

One of the main disadvantages of NSB is that it is very difficult to obtain robust normative data for any part of the body because of their different epidermal innervation patterns. This problem can be elegantly solved in cases of unilateral peripheral nerve lesions by comparing the neuropathic skin ENFD with the contralateral, normal side ENFD. To this aim, a bilateral biopsy is necessary



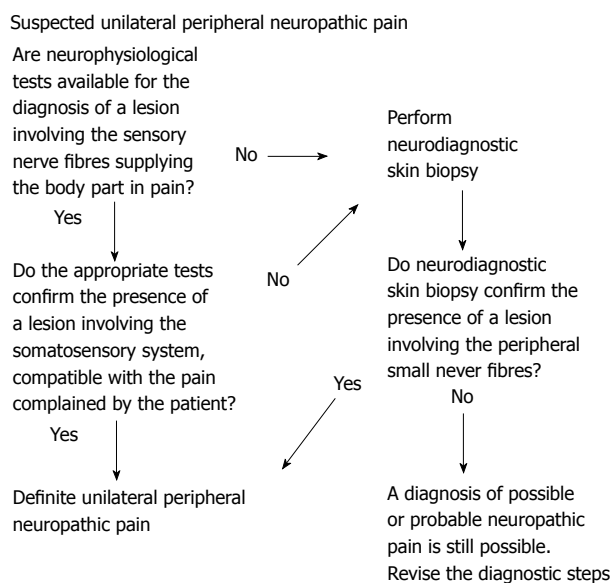


Figure 3 Suggested diagnostic sequences for the confirmation of a peripheral nerve lesion sustaining a definite, peripheral, unilateral neuropathic pain.

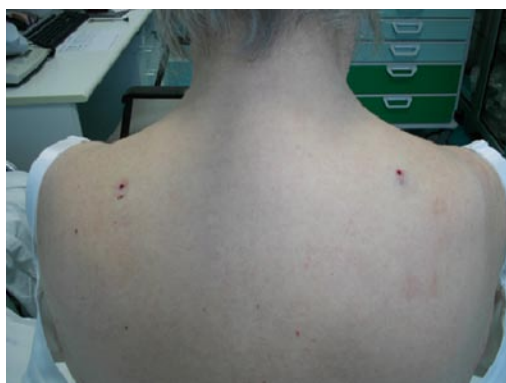

Figure 4 Figure exemplifies the bilateral biopsy needed for comparing the epidermal nerve fiber density of two symmetrical, mirror skin parts.

(Figure 4). It is well known that the two sides of the body of a normal subject are only theoretically symmetrical and a significant asymmetry can be frequently found in several types of biological measures. NSB is not an exception. For this reason, a ratio (the Epidermal Innervation Symmetry Ratio) was developed to compare the epidermal innervation of two symmetrical, mirror parts of the body in normal subjects. Preliminary data were obtained from 133 normal subjects<sup>[33]</sup>. In particular, when comparing the ENFD of the right with the left side, the ratio showed a normal distribution (mean 1.02; median 1.01; standard deviation 0.21; asymmetry 1.86, kurtosis -0.97). Moreover, when confronting the lower with the higher (contralateral) ENFD, the ratio was quite constant and surprisingly reproducible, also considering different parts of the body (Figure 5).

## LIMITATIONS

As with any other diagnostic method, the use of NSB for investigation of the peripheral nerve system has some

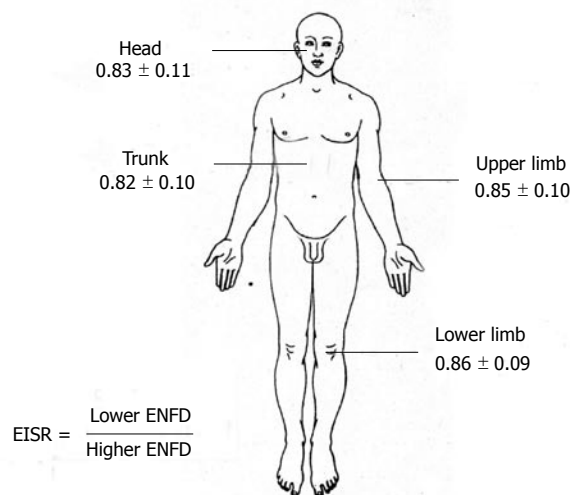


Figure 5 Figure shows the values of epidermal innervation symmetry ratio obtained for different body parts in 133 normal subjects. ENFD: Epidermal Nerve Fiber Density.

limitations. First of all, it is important to mention that NSB is surely not useful for the diagnosis of entrapment neuropathies, particularly in their early phases when only large diameter fibers are involved. Another important limitation is that NSB is a time-consuming method; calculating the time for specimen processing and the manual counting of two blinded investigators and the time for obtaining a reliable medical report, it is usually not less than two weeks. Finally, NSB is currently confined to a small number of specialized diagnostic units.

## CONCLUSION

The demonstration of a lesion or a disease involving the somatosensory system is mandatory for the diagnosis of definite neuropathic pain and objective diagnostic tools play an important role to reach the aim. To this end, several methods are currently available but none is suitable for every disease (or lesion). NSB can be an important diagnostic method for the demonstration of peripheral nervous system involvement, with a special reference to small fiber neuropathies and to peripheral nerves not evaluated by other tests. For these characteristics, NSB can be considered a precious instrument for the diagnosis of peripheral unilateral neuropathic pain.

## ACKNOWLEDGMENTS

The author would like to thank the neuropathophysiology technicians Michela Canti and Rosa Bagnasco for their essential role in drafting the paper and Dr. Anna Maria Gatti for helping with the preparation of figures.

## REFERENCES

- 1 Treede RD, Jensen TS, Campbell JN, Cruccu G, Dostrovsky JO, Griffin JW, Hansson P, Hughes R, Nurmikko T, Serra J. Neuropathic pain: redefinition and a grading system for clinical and research purposes. *Neurology* 2008; **70**: 1630-1635

- [PMID: 18003941 DOI: 10.1212/01.wnl.0000282763.29778.59]
- 2 **Dick PJ**, Thomas PK. Peripheral neuropathy, 4<sup>th</sup> edition. Philadelphia: Elsevier Saunders, 2005
- 3 **Koltzenburg M**, Wall PD, McMahon SB. Does the right side know what the left is doing? *Trends Neurosci* 1999; **22**: 122-127 [PMID: 10199637 DOI: 10.1016/S0166-2236(98)01302-2]
- 4 **Bromberg MB**. An approach to the evaluation of peripheral neuropathies. *Semin Neurol* 2010; **30**: 350-355 [PMID: 20941667 DOI: 10.1055/s-0030-1267278]
- 5 **Jillapalli D**, Shefner JM. Electrodiagnosis in common mononeuropathies and plexopathies. *Semin Neurol* 2005; **25**: 196-203 [PMID: 15937735 DOI: 10.1055/s-2005-871328]
- 6 **Dumitru D**. Electrodiagnostic Medicine. Philadelphia: Hanley and Belfus, 1995
- 7 **Aminoff MJ**. Electrodiagnosis in clinical neurology, 4th edition. Philadelphia: Churchill livingstone, 1999
- 8 **Ross MA**. Electrodiagnosis of peripheral neuropathy. *Neurol Clin* 2012; **30**: 529-549 [PMID: 22361373 DOI: 10.1016/j.ncl.2011.12.013]
- 9 **Chiappa KH**. Evoked potential in clinical medicine, 3rd edition. Philadelphia: Lippincott-Raven, 1997
- 10 **Cruccu G**, Aminoff MJ, Curio G, Guerit JM, Kakigi R, Mauguere F, Rossini PM, Treede RD, Garcia-Larrea L. Recommendations for the clinical use of somatosensory-evoked potentials. *Clin Neurophysiol* 2008; **119**: 1705-1719 [PMID: 18486546 DOI: 10.1016/j.clinph.2008.03.016]
- 11 **Bromm B**, Treede RD. Laser-evoked cerebral potentials in the assessment of cutaneous pain sensitivity in normal subjects and patients. *Rev Neurol (Paris)* 1991; **147**: 625-643 [PMID: 1763252]
- 12 **Treede RD**, Lorenz J, Baumgärtner U. Clinical usefulness of laser-evoked potentials. *Neurophysiol Clin* 2003; **33**: 303-314 [PMID: 14678844 DOI: 10.1016/j.neucli.2003.10.009]
- 13 Quantitative sensory testing: a consensus report from the Peripheral Neuropathy Association. *Neurology* 1993; **43**: 1050-1052 [PMID: 8388089 DOI: 10.1212/WNL.43.5.1050]
- 14 **Lindblom U**. Analysis of Abnormal Touch, Pain, and Temperature Sensation in Patients. In: Boivie J, Hansson P, Lindblom U. Touch, Temperature, and Pain in Health and Disease: Mechanisms and Assessments. Seattle: IASP Press, 1994: 63-84
- 15 **Pfau DB**, Geber C, Birklein F, Treede RD. Quantitative sensory testing of neuropathic pain patients: potential mechanistic and therapeutic implications. *Curr Pain Headache Rep* 2012; **16**: 199-206 [PMID: 22535540 DOI: 10.1007/s11916-012-0261-3]
- 16 **Kennedy WR**. Opportunities afforded by the study of unmyelinated nerves in skin and other organs. *Muscle Nerve* 2004; **29**: 756-767 [PMID: 15170608]
- 17 **Lauria G**, Hsieh ST, Johansson O, Kennedy WR, Leger JM, Mellgren SI, Nolano M, Merkies IS, Polydefkis M, Smith AG, Sommer C, Valls-Solé J. European Federation of Neurological Societies/Peripheral Nerve Society Guideline on the use of skin biopsy in the diagnosis of small fiber neuropathy. Report of a joint task force of the European Federation of Neurological Societies and the Peripheral Nerve Society. *Eur J Neurol* 2010; **17**: 903-12, e44-9 [PMID: 20642627 DOI: 10.1111/j.1468-1331.2010.03023.x]
- 18 **Sommer C**. Skin biopsy as a diagnostic tool. *Curr Opin Neurol* 2008; **21**: 563-568 [PMID: 18769250 DOI: 10.1097/WCO.0b013e328309000c]
- 19 **Walk D**. Role of skin biopsy in the diagnosis of peripheral neuropathic pain. *Curr Pain Headache Rep* 2009; **13**: 191-196 [PMID: 19457279 DOI: 10.1007/s11916-009-0033-x]
- 20 **McCarthy BG**, Hsieh ST, Stocks A, Hauer P, Macko C, Cornblath DR, Griffin JW, McArthur JC. Cutaneous innervation in sensory neuropathies: evaluation by skin biopsy. *Neurology* 1995; **45**: 1848-1855 [PMID: 7477980 DOI: 10.1212/WNL.45.10.1848]
- 21 **Griffin JW**, McArthur JC, Polydefkis M. Assessment of cutaneous innervation by skin biopsies. *Curr Opin Neurol* 2001; **14**: 655-659 [PMID: 11562579]
- 22 **Lauria G**, Lombardi R. Skin biopsy in painful and immune-mediated neuropathies. *J Peripher Nerve Syst* 2012; **17**: 38-45 [DOI: 10.1111/j.1529-8027.2012.00430.x]
- 23 **Di Stefano G**, La Cesa S, Biasiotta A, Leone C, Pepe A, Cruccu G, Truini A. Laboratory tools for assessing neuropathic pain. *Neurol Sci* 2012; **33**: 5-7 [DOI: 10.1007/s10072-012-1033-x]
- 24 **Lauria G**, Lombardi R, Camozzi F, Devigili G. Skin biopsy for the diagnosis of peripheral neuropathy. *Histopathology* 2009; **54**: 273-285 [PMID: 18637969 DOI: 10.1111/j.1365-2559.2008.03096.x]
- 25 **Myers MI**, Peltier AC. Uses of skin biopsy for sensory and autonomic nerve assessment. *Curr Neurol Neurosci Rep* 2013; **13**: 323 [PMID: 23250768 DOI: 10.1007/s11910-012-0323-2]
- 26 **Buonocore M**, Gatti AM, Amato G, Aloisi AM, Bonezzi C. Allodynic skin in post-herpetic neuralgia: histological correlates. *J Cell Physiol* 2012; **227**: 934-938 [PMID: 21503891 DOI: 10.1002/jcp.22804]
- 27 **Westermann A**, Krumova EK, Pennenkamp W, Horch C, Baron R, Maier C. Different underlying pain mechanisms despite identical pain characteristics: a case report of a patient with spinal cord injury. *Pain* 2012; **153**: 1537-1540 [DOI: 10.1016/j.pain.2012.02.031]
- 28 **Buonocore M**, Gagliano MC, Bonezzi C. Dynamic mechanical allodynia following finger amputation: Unexpected skin hyperinnervation. *World J Clin Cases* 2013; **1**: 197-201 [PMID: 24303500 DOI: 10.12998/wjcc.v1.i6.197]
- 29 **Hamed K**, Giles N, Anderson J, Phillips JK, Dawson LF, Drummond P, Wallace H, Wood FM, Rea SM, Fear MW. Changes in cutaneous innervation in patients with chronic pain after burns. *Burns* 2011; **37**: 631-637 [DOI: 10.1016/j.burns.2010.11.010]
- 30 **Pacchiarotti A**, Milazzo GN, Biasiotta A, Truini A, Antonini G, Frati P, Gentile V, Caserta D, Moscarini M. Pain in the upper anterior-lateral part of the thigh in women affected by endometriosis: study of sensitive neuropathy. *Fertil Steril* 2013; **100**: 122-126 [DOI: 10.1016/j.fertnstert.2013.02.045]
- 31 **Wallengren J**, Tegner E, Sundler F. Cutaneous sensory nerve fibers are decreased in number after peripheral and central nerve damage. *J Am Acad Dermatol* 2002; **46**: 215-217 [PMID: 11807432 DOI: 10.1067/mjd.2002.118540]
- 32 **Falla M**, Biasiotta A, Fabbrini G, Cruccu G, Truini A. Cutaneous innervation and trigeminal pathway function in a patient with facial pain associated with Parry-Romberg syndrome. *J Headache Pain* 2012; **13**: 497-499 [PMID: 22623073 DOI: 10.1007/s10194-012-0459-0]
- 33 **Buonocore M**, Gatti AM, Demartini L. Epidermal innervation symmetry ratio (EISR) for the diagnosis of unilateral neuropathic pain. Abstract Book of the "4<sup>th</sup> International Congress on Neuropathic Pain"; 2013 May 23-26; Toronto: On USB key, 2013: 740

**P- Reviewers:** Alimehmeti R, Cho SY, Trohman RG

**S- Editor:** Qi Y **L- Editor:** Roemmele A **E- Editor:** Wu HL



## Surgical removal of a large mobile left ventricular thrombus *via* left atriotomy

Daizo Tanaka, Shinya Unai, James T Diehl, Hitoshi Hirose

Daizo Tanaka, Shinya Unai, James T Diehl, Hitoshi Hirose, Division of Cardiothoracic Surgery, Department of Surgery, Thomas Jefferson University, Philadelphia, PA 19107, United States  
Author contributions: Tanaka D, Unai S, Diehl JT and Hirose H were all contributed to the patient care, surgery and writing the manuscript.

Correspondence to: Hitoshi Hirose, MD, Division of Cardiothoracic Surgery, Department of Surgery, Thomas Jefferson University, 1025 Walnut Street Room 605, Philadelphia, PA 19107, United States. [Hitoshi.Hirose@jefferson.edu](mailto:Hitoshi.Hirose@jefferson.edu)

Telephone: +1-215-955-5654 Fax: +1-215-955-6010

Received: November 12, 2013 Revised: December 14, 2013

Accepted: January 15, 2014

Published online: February 16, 2014

### Abstract

Left ventricular (LV) thrombus is a life-threatening complication of severe LV dysfunction. Ventriculotomy has been a commonly performed procedure for LV thrombus; however, it often further decrease LV function after surgery. We present an alternative approach to thrombectomy in order to minimize the postoperative LV dysfunction. A 37-year-old female with a postpartum cardiomyopathy found to have poor LV function and a large left ventricular apical thrombus (3 cm × 3 cm) attached to the apex by a narrow stalk. Given her severe LV dysfunction, the LV thrombus was approached *via* left atriotomy under cardiopulmonary bypass. The LV thrombus was easily extracted with gentle traction *via* the mitral valve. Postoperatively, the patient was discharged home without any embolization event or inotropic support. LV thrombectomy *via* left atriotomy through the mitral valve could be an alternative option for the patients with poor LV function with a mobile LV thrombus.

© 2014 Baishideng Publishing Group Co., Limited. All rights reserved.

**Key words:** Left ventricular thrombus; Atriotomy; Car-

diomyopathy; Surgical thrombectomy; Pedunculated thrombus

**Core tip:** We successfully treated the patient of a large pedunculated left ventricular (LV) thrombus with poor LV function *via* left atriotomy. Compared to conventional ventriculotomy, left atrial approach would be more suitable for emergency LV thrombectomy for highly mobile thrombi because the left atriotomy may not further decrease the LV function and would preserve the LV apex for future ventricular assist device placement.

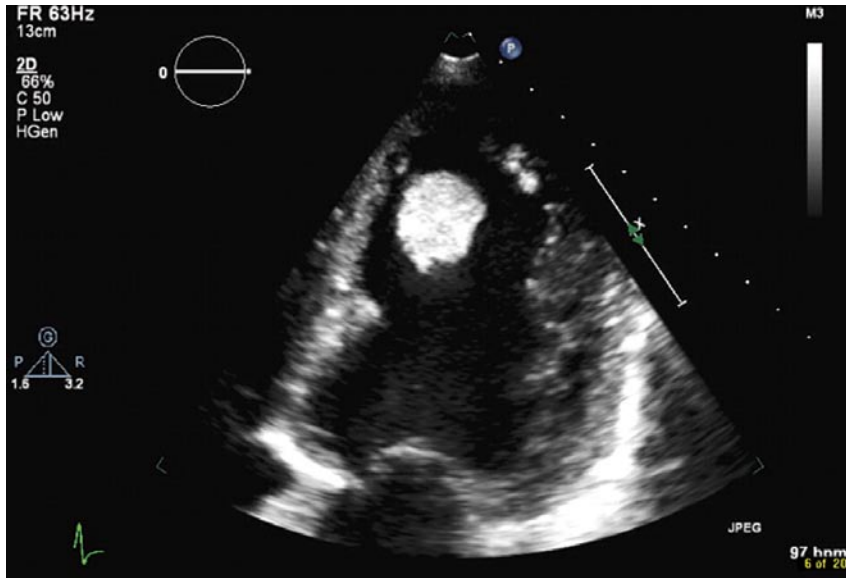
Tanaka D, Unai S, Diehl JT, Hirose H. Surgical removal of a large mobile left ventricular thrombus *via* left atriotomy. *World J Clin Cases* 2014; 2(2): 32-35 Available from: URL: <http://www.wjgnet.com/2307-8960/full/v2/i2/32.htm> DOI: <http://dx.doi.org/10.12998/wjcc.v2.i2.32>

### INTRODUCTION

Left ventricular (LV) thrombus is a life-threatening complication of severe left ventricular dysfunction. Possible treatment options include anticoagulation, thrombolysis and surgical thrombectomy<sup>[1,2]</sup>. Small immobile thrombi can be safely managed with anticoagulation; however, treatment for large mobile thrombi is often problematic. LV thrombus is usually associated with poor LV function<sup>[3]</sup>. Therefore, surgical approaches such as left ventriculotomy, which potentially cause further deterioration of LV function, should be avoided if possible. We present an alternative approach of LV thrombectomy in order to preserve the remaining LV function.

### CASE REPORT

A 37-year-old female with a history of postpartum cardiomyopathy and multiple pulmonary embolisms in the



**Figure 1** Transthoracic echocardiogram demonstrated a large left ventricular thrombus. It was highly mobile and the risk of embolization was considered to be high.

past presented to an outside hospital with worsening dyspnea on exertion and fatigue 3 mo after her second delivery. She stated that she ran out of her medications for several weeks including rivaroxaban which was prescribed for her possible hypercoagulable state. At the outside hospital she complained of chest pain and underwent right and left heart catheterization, which disclosed a cardiac index of 1.5 L/min per square meter and non-obstructive coronary disease. She was initiated on inotropic support for low output cardiac failure. Her transthoracic echocardiogram followed by transesophageal echocardiogram showed worsening LV function with an ejection fraction of 10%, which was previously 20%, and a large apical pedunculated LV thrombus measuring 3 cm × 3 cm (Figure 1). She was therefore transferred to our hospital for further management.

Considering a narrow stalk and large size of the LV thrombus, the risk of embolization was considered to be high. Emergent surgery was thus undertaken. Under cardioplegic cardiac arrest and cardiopulmonary support, the left atrium was opened at Waterson's groove. A Cosgrove retractor was placed to optimize the exposure of the mitral valve. The LV thrombus was visualized through the mitral valve and was located at the apex connected to the ventricular wall only with a small stalk, which was divided at the base of the papillary muscle. The thrombus was extracted with gentle traction through the mitral valve without difficulty. The LV cavity was extensively irrigated, and then the left atrium was closed. The cross clamp time was 20 min and there was no issue weaning from cardiopulmonary bypass. Postoperatively, the patient was on minimal inotropic support which was successfully weaned off by postoperative day 4. She developed transient atrial fibrillation on postoperative day 3, which was converted to sinus rhythm by medical therapy. The postoperative echocardiogram revealed a small residual mural thrombus measuring 3 mm × 4 mm with left ventricular function of 40% (Figure 2). Hematology was consulted for workup of a possible hypercoagulable state, however

all studies were negative. She was placed on coumadin therapy for the residual LV thrombus and was discharged home on postoperative day 10 without an embolic event. Pathologic workup of the mass revealed a large thrombus without any malignant component. Throughout her postoperative course, she has remained symptom free 6 mo after surgery.

## DISCUSSION

First line of treatment for a LV thrombus is anticoagulation; however, a large mobile thrombus as is in this case often requires urgent surgical thrombectomy. The concern with surgical removal of a large LV thrombus is ventricular function, since it is often seen in patients with poor LV function. The conventional approach to LV thrombus is left ventriculotomy<sup>[4,5]</sup>. Ventriculotomy provides direct visualization of the thrombus; thus it has been considered the standard approach for complete removal of the thrombus. This may be best utilized for mural thrombus which is adhered to the ventricular wall. However, LV ventriculotomy often causes further deterioration of the LV function<sup>[6]</sup>, and should be avoided in cases of poor LV function if possible. Furthermore, if once the left ventriculotomy was performed, future placement of the ventricular assist device in case of further deterioration of the LV function would be more complicated. Another possible approach is thrombus extraction *via* aortotomy. This trans-aortic approach has been reported in conjunction with the video-assisted thoracoscopy to facilitate visualization<sup>[7]</sup>. However, the size of the thrombus is often the limiting factor in this approach and was too large to pass through the aortic valve in this case.

A left atrial approach does not require incision to the LV, thus theoretically preserves the remaining LV function. This approach also provides adequate visualization of the thrombus and trans-mitral valve extraction allows extraction of a larger thrombus than the trans-aortic ap-



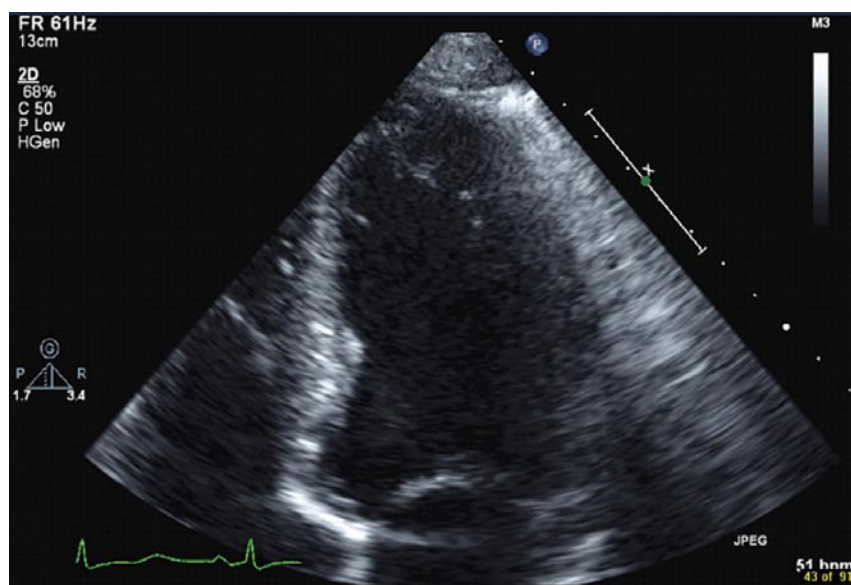


Figure 2 Postoperative transthoracic echocardiogram demonstrated only minimally remaining mural thrombus.

proach<sup>[8-10]</sup>. The potential disadvantage of the left atrial approach would be limited room for maneuvering of the thrombus and should be reserved only for one that is loosely connected to the ventricular wall with a narrow stalk, which is exactly the case that emergent thrombectomy is usually indicated. When surgical thrombectomy is indicated for mural thrombi, which can usually be managed with anticoagulation, the left atrial approach should not be selected because extensive debridement is expected. These cases should be operated semi-electively with a standby left ventricular assist device since further deterioration of the LV function is expected after ventriculotomy. Therefore, we advocate left atriotomy as an alternative approach for emergent LV thrombectomy.

## COMMENTS

### Case characteristics

A 37-year-old female with a history of postpartum cardiomyopathy presented with chest pain and dyspnea 3 mo after her second delivery.

### Clinical diagnosis

Echocardiogram showed worsening left ventricular (LV) dysfunction (ejection fraction of 10%) with a large left ventricular apical thrombus (3 cm × 3 cm) attached to the apex with a narrow stalk.

### Differential diagnosis

Differential diagnosis included intracardiac thrombus, primary or metastatic tumor and cardiac myxoma.

### Laboratory diagnosis

The patient's cardiac index was 1.5 L/min per square meter and ejection fraction of 10%.

### Imaging diagnosis

Echocardiogram showed a large left ventricular apical thrombus (3 cm × 3 cm) attached to the apex with a narrow stalk.

### Pathological diagnosis

The removed mass was found to be a thrombus.

### Treatment

The left ventricular thrombus was removed via the right-sided left atrium though the mitral valve.

### Related reports

Conventional LV thrombectomy by left ventriculotomy; may this decrease the left ventricular function after surgery.

## Experiences and lessons

Compared to conventional ventriculotomy, left atrial approach would be more suitable for emergency LV thrombectomy for highly mobile thrombi because the left atriotomy may not have any effect on the left ventricular function and would preserve the left ventricular apex for future ventricular assist device placement.

## Peer review

Left ventricular thrombectomy *via* the left atrium though the mitral valve would be most feasible for the thrombus connected to the left ventricle with a narrow stalk.

## REFERENCES

- 1 Lee JM, Park JJ, Jung HW, Cho YS, Oh IY, Yoon CH, Suh JW, Chun EJ, Choi SI, Youn TJ, Lim C, Cho GY, Chae IH, Park KH, Choi DJ. Left ventricular thrombus and subsequent thromboembolism, comparison of anticoagulation, surgical removal, and antiplatelet agents. *J Atheroscler Thromb* 2013; **20**: 73-93 [PMID: 22986555 DOI: 10.5551/jat.13540]
- 2 Leick J, Szardien S, Liebetrau C, Willmer M, Fischer-Rasokat U, Kempfert J, Nef H, Rolf A, Walther T, Hamm C, Möllmann H. Mobile left ventricular thrombus in left ventricular dysfunction: case report and review of literature. *Clin Res Cardiol* 2013; **102**: 479-484 [PMID: 23584757 DOI: 10.1007/s00392-013-0565-2]
- 3 Stratton JR, Lighty GW, Pearlman AS, Ritchie JL. Detection of left ventricular thrombus by two-dimensional echocardiography: sensitivity, specificity, and causes of uncertainty. *Circulation* 1982; **66**: 156-166 [PMID: 7083502 DOI: 10.1161/01.CIR.66.1.156]
- 4 Yadava OP, Yadav S, Juneja S, Chopra VK, Passey R, Ghadiok R. Left ventricular thrombus sans overt cardiac pathology. *Ann Thorac Surg* 2003; **76**: 623-625 [PMID: 12902125 DOI: 10.1016/S0003-4975(03)00198-X]
- 5 Suzuki R, Kudo T, Kurazumi H, Takahashi M, Shirasawa B, Mikamo A, Hamano K. Transapical extirpation of a left ventricular thrombus in Takotsubo cardiomyopathy. *J Cardiothorac Surg* 2013; **8**: 135 [PMID: 23705797 DOI: 10.1186/1749-8090-8-135]
- 6 DiBernardo LR, Kirshbom PM, Skaryak LA, Quarterman RL, Johnson RL, Davies MJ, Gaynor JW, Ungerleider RM. Acute functional consequences of left ventriculotomy. *Ann Thorac Surg* 1998; **66**: 159-165 [PMID: 9692457 DOI: 10.1016/S0003-4975(98)00376-2]
- 7 Tsukube T, Okada M, Ootaki Y, Tsuji Y, Yamashita C. Trans-aortic video-assisted removal of a left ventricular thrombus. *Ann Thorac Surg* 1999; **68**: 1063-1065 [PMID: 10510010 DOI: 10.1053/ats.1999.10510010]

- 10.1016/S0003-4975(99)00662-1]
- 8 **Kuh JH**, Seo Y. Transatrial resection of a left ventricular thrombus after acute myocarditis. *Heart Vessels* 2005; **20**: 230-232 [PMID: 16160906 DOI: 10.1007/s00380-004-0811-7]
- 9 **Lutz CJ**, Bhamidipati CM, Ford B, Swartz M, Hauser M, Kyobe M, Dilip K. Robotic-assisted excision of a left ventricular thrombus. *Innovations (Phila)* 2007; **2**: 251-253 [PMID: 22437135 DOI: 10.1097/IML.0b013e31815cea73]
- 10 **Early GL**, Ballenger M, Hannah H, Roberts SR. Simplified method of left ventricular thrombectomy. *Ann Thorac Surg* 2001; **72**: 953-954 [PMID: 11565702 DOI: 10.1016/S0003-4975(00)02607-2]

**P- Reviewers:** Paraskevas KI, Satoh S, Said SAM, Vermeersch P

**S- Editor:** Gou SX **L- Editor:** A **E- Editor:** Wu HL



## Unexpected anomaly of the common bile duct and pancreatic duct

Disaya Chavalitdhamrong, Peter V Draganov

Disaya Chavalitdhamrong, Peter V Draganov, Division of Gastroenterology, Hepatology, and Nutrition, University of Florida, Gainesville, FL 32608, United States

Author contributions: Chavalitdhamrong D had involved in drafting the manuscript; Draganov PV had involved in critical revision of the manuscript.

Correspondence to: Peter V Draganov, MD, Professor of Medicine, Division of Gastroenterology, Hepatology, and Nutrition, University of Florida, 1329 SW 16<sup>th</sup> Street Suite 5251, Gainesville, FL 32608, United States. [dragapv@medicine.ufl.edu](mailto:dragapv@medicine.ufl.edu)

Telephone: +1-352-2739472 Fax: +1-352-6279002  
Received: November 12, 2013 Revised: December 20, 2013  
Accepted: January 15, 2014

Published online: February 16, 2014

**Core tip:** Drainage of the main pancreatic and bile duct as two separate orifices is a recognized, but very rare anatomical variant. It is also referred to as double major papillae.

Chavalitdhamrong D, Draganov PV. Unexpected anomaly of the common bile duct and pancreatic duct. *World J Clin Cases* 2014; 2(2): 36-38 Available from: URL: <http://www.wjgnet.com/2307-8960/full/v2/i2/36.htm> DOI: <http://dx.doi.org/10.12998/wjcc.v2.i2.36>

### Abstract

Variations in the bile duct and pancreatic duct opening are related to the process of rotation and recanalization during embryologic development. Complete non-union of distal common bile duct and pancreatic duct gives rise to double papillae of Vater. The separation of the drainage of the main pancreatic duct and bile duct can be appreciated by careful assessment at the time of endoscopic retrograde cholangiopancreatography. The cranial orifice is a bile duct opening, whereas the caudal orifice is a pancreatic duct opening. The separate orifice finding can be confirmed by cholangiogram and pancreatogram with no communication between the two orifices. Endoscopists should be aware of this rare variant because late recognition can result in unnecessary manipulation and contrast injections of the main pancreatic duct and biliary cannulation failure.

© 2014 Baishideng Publishing Group Co., Limited. All rights reserved.

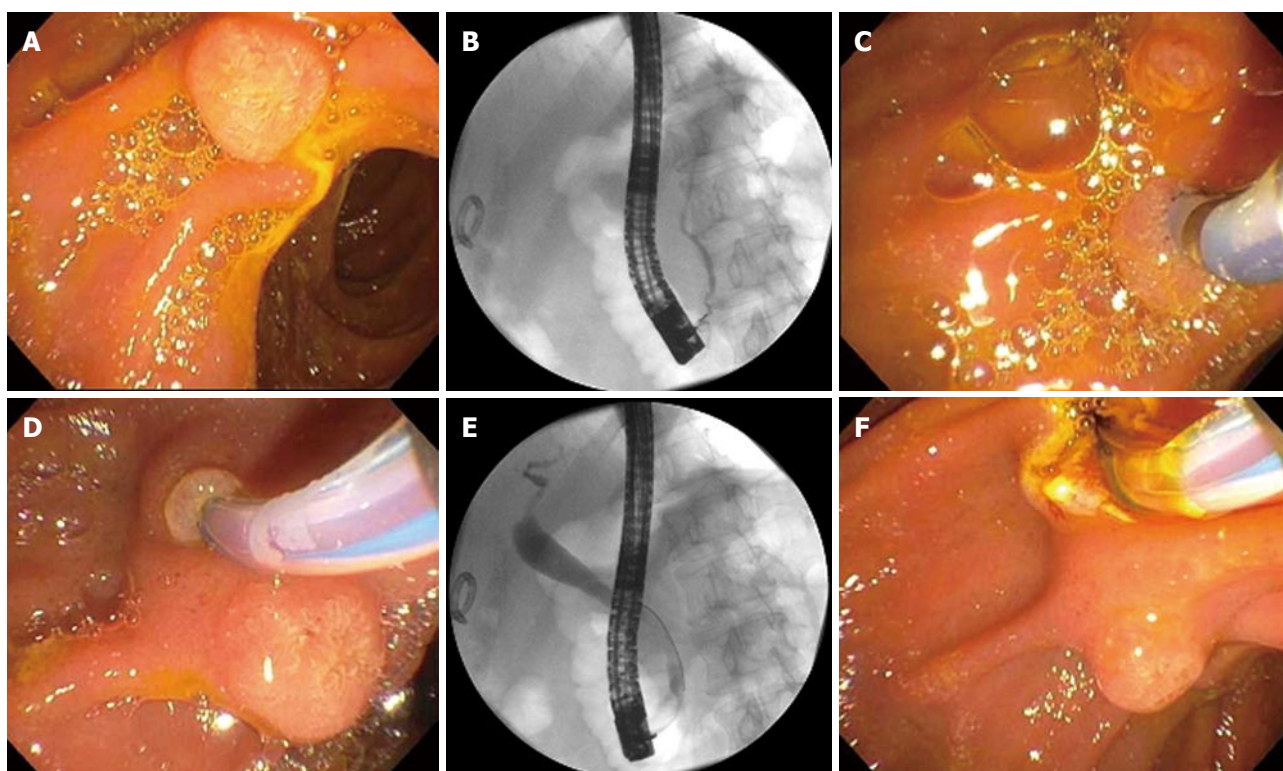
**Key words:** Double major papillae; Double orifices; Cannulation; Bile duct; Endoscopic retrograde cholangiopancreatography

### INTRODUCTION

The common bile duct and the pancreatic duct coalesce into one duct at the level of the ampulla, before they open into the duodenum *via* a single orifice. A variation in the bile duct and pancreatic duct opening causing two separate orifices is a rare anatomical variant as they fail to coalesce (also known as double papillae). This variant does not predispose to any pancreatobiliary disease, but recognition at the time of endoscopic retrograde cholangiopancreatography (ERCP) is crucial to ensure the procedures technical success. We present a case of a patient with separate drainage orifices of the bile and pancreatic duct which initially was not appreciated. This resulted in obtaining unnecessary pancreatograms, a prolonged procedure and increased risk for post-ERCP pancreatitis.

### CASE REPORT

A 27-year-old presented 3 wk post-partum with acute right upper quadrant abdominal pain associated with elevated liver function tests (aspartate aminotransferase of 396 U/L, alanine aminotransferase of 364 U/L, total bilirubin of 1.5 mg/dL, and alkaline phosphatase of 510 U/L). Abdominal ultrasonography revealed a dilated common bile duct of 12 mm and mild intrahepatic ductal



**Figure 1** The patient underwent an endoscopic retrograde cholangiopancreatography for stone removal. A: The major papilla appeared normal; B: Normal pancreatogram; C: The major papilla was re-examined; D: Cannulation of the bile duct through the second orifice; E: Biliary tract with biliary stone within the distal common bile duct; F: Biliary sphincterotomy.

dilatation. Magnetic resonance cholangiopancreatography showed a four millimeter stone in the distal common bile duct.

The patient underwent an ERCP for stone removal. The major papilla appeared normal (Figure 1A). Multiple cannulation attempts resulted in repeat pancreatograms (Figure 1B). The major papilla was re-examined, and what originally was thought to be the minor papilla was found to be located at the roof of the major papilla (Figure 1C). This appearance raised the possibility of two separated orifices of the bile duct and the main pancreatic duct, which independently drain with a separation of 10 mm. Indeed, that was confirmed after cannulation of the bile duct through the second orifice (Figures 1D and E). Biliary sphincterotomy was preformed (Figure 1F) and the biliary stone was easily extracted. Rectal indomethacin was given as a prophylactic measure for prevention of post-ERCP pancreatitis<sup>[1]</sup>. The patient later underwent a cholecystectomy, and her hospital course was uneventful.

## DISCUSSION

Drainage of the main pancreatic and bile duct as two separate orifices is a recognized, but very rare anatomical variant. It is also referred to as double major papillae. The two separate openings are usually not apparent without close inspection<sup>[2]</sup>. The cranial orifice communicates with the common bile duct and the caudal orifice communicates with the duct of Wirsung<sup>[3]</sup>. Double papilla of Vater cannulation of the common bile duct and pancreatic duct

could be accomplished through either orifice independently<sup>[4,5]</sup>. Endoscopists should be aware of this rare variant because late recognition can result in unnecessary manipulation and contrast injections of the main pancreatic duct. Fortunately, our patient did not develop post-ERCP pancreatitis. Furthermore, inability to recognize this anatomic variant can lead to biliary cannulation failure.

## COMMENTS

### Case characteristics

This case demonstrates a rare endoscopic finding of papilla during endoscopic retrograde cholangiopancreatography.

### Clinical diagnosis

A non-union of the bile duct and pancreatic duct opening causes two separate orifices.

### Differential diagnosis

The confirmation of two separate ampullary structures can differentiate double major papillae of Vater from other diagnoses.

### Laboratory diagnosis

Cannulation of both orifices can prove that they are the openings of the common bile duct and the pancreatic duct.

### Imaging diagnosis

Cannulation of the cranial orifice shows cholangiogram, whereas cannulation of the caudal orifice shows pancreatogram.

### Pathological diagnosis

Cannulation of each orifice can evaluate the biliary or pancreatic abnormality.

### Treatment

Therapeutic interventions by endoscopic retrograde cholangiopancreatography (ERCP) can be performed after proper cannulation.

### Related reports

A literature search revealed only a few documented cases of double papillae of Vater.



### Term explanation

Double major papillae of Vater are separate drainages of the common bile duct and the pancreatic duct. The cannulation of the common bile duct and pancreatic duct can be achieved through either orifice independently.

### Experiences and lessons

The unnecessary pancreatograms are associated with increased risk for post-ERCP pancreatitis. Fortunately, the patient did not develop post-ERCP pancreatitis.

### Peer review

Careful inspection of the ampulla finding the two openings can lead to appropriate cannulation of the common bile duct and pancreatic duct through either orifice independently.

## REFERENCES

- 1 **Yaghoobi M**, Rolland S, Waschke KA, McNabb-Baltar J, Martel M, Bijarchi R, Szego P, Barkun AN. Meta-analysis: rectal indomethacin for the prevention of post-ERCP pancreatitis. *Aliment Pharmacol Ther* 2013; **38**: 995-1001 [PMID: 24099466 DOI: 10.1016/j.gie.2013.04.095]
- 2 **Katsinelos P**, Chatzimavroudis G, Fasoulas K, Katsinelos T, Pilpilidis I, Lazaraki G, Terzoudis S, Kokonis G, Patsis I, Zavos C, Kountouras J. Double major papilla of Vater -a rare endoscopic finding during endoscopic retrograde cholangiopancreatography: a case report. *Cases J* 2009; **2**: 163 [PMID: 19946474 DOI: 10.1186/1757-1626-2-163]
- 3 **Francis JM**, Kadakia SC. Anomalous double orifice of a single major papilla of Vater. *Gastrointest Endosc* 1994; **40**: 524-525 [PMID: 7926559 DOI: 10.1016/S0016-5107(94)70237-3]
- 4 **Rajnakova A**, Tan WT, Goh PM. Double papilla of Vater: a rare anatomic anomaly observed in endoscopic retrograde cholangiopancreatography. *Surg Laparosc Endosc* 1998; **8**: 345-348 [PMID: 9799141]
- 5 **Ratanalert S**, Soontrapornchai P. Double orifices of a single major papilla of vater: a rare case report. *Gastroenterol Nurs* 2007; **30**: 243-244 [PMID: 17568267 DOI: 10.1097/01.SGA.0000278177.07221.bc]

**P- Reviewers:** Assimakopoulos SF, Gassler N, Sandblom G, Xu Z  
**S- Editor:** Gou SX **L- Editor :** A **E- Editor:** Wu HL



## Severe isolated sciatic neuropathy due to a modified lotus position

Jacob Wycher Bosma, Juerd Wijntjes, Ton Antonius Hilgevoord, Jan Veenstra

Jacob Wycher Bosma, Jan Veenstra, Department of Internal Medicine, Sint Lucas Andreas Hospital, 1061AE Amsterdam, The Netherlands

Juerd Wijntjes, Ton Antonius Hilgevoord, Department of Neurology, Sint Lucas Andreas Hospital, 1061 Amsterdam, The Netherlands

**Author contributions:** Bosma JW contributed to conception and design case history, drafting case history, final approval of the version to be published; Wijntjes J contributed to conception and design case history, performing and interpretation of electromyography, drafting case history, final approval of the version to be published; Hilgevoord TA contributed to performing and interpretation of electromyography, revising article for intellectual content, final approval of the version to be published; Veenstra J contributed to design case history, revising article for intellectual content, final approval of the version to be published.

**Correspondence to:** Jacob Wycher Bosma, MD, Department of Internal Medicine, Sint Lucas Andreas Hospital, Jan Tooropstraat 164, 1061AE Amsterdam,

The Netherlands. [jacob.bosma@slaz.nl](mailto:jacob.bosma@slaz.nl)

Telephone: +31-20-5108770 Fax: +31-20-5108955

Received: September 28, 2013 Revised: December 18, 2013

Accepted: January 15, 2014

Published online: February 16, 2014

© 2014 Baishideng Publishing Group Co., Limited. All rights reserved.

**Key words:** Sciatic neuropathy; Lotus neuropathy; Sciatic nerve

**Core tip:** In this case history we report on a patient with a severe isolated sciatic neuropathy with a foot drop, a complication of prolonged sitting in a modified lotus position. Although rare, similar reports of sciatic nerve injury due to external compression as a result of prolonged or repeated sitting in the same position have been reported. A so-called "lotus neuropathy" should be included in the differential diagnosis in patients presenting with a isolated sciatic neuropathy.

Bosma JW, Wijntjes J, Hilgevoord TA, Veenstra J. Severe isolated sciatic neuropathy due to a modified lotus position. *World J Clin Cases* 2014; 2(2): 39-41 Available from: URL: <http://www.wjgnet.com/2307-8960/full/v2/i2/39.htm> DOI: <http://dx.doi.org/10.12998/wjcc.v2.i2.39>

### Abstract

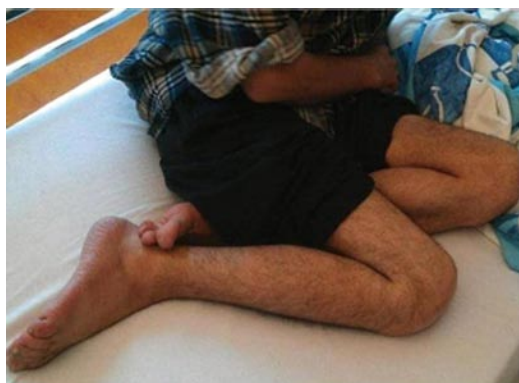A 51-year-old man presented to our hospital with progressive pain and weakness in his right leg. Neurological examination revealed atrophy of all muscles of the right leg, unilateral foot drop and paralysis of the anterior tibial and gastrocnemius muscles. Electromyography confirmed a severe isolated sciatic neuropathy in the thigh. For unclear reasons, our patient habitually used to sit in a modified lotus position. We concluded that this position, in literature known as "lotus neuropathy" had resulted in the sciatic neuropathy. After more than a year our patient was referred again to our outpatient clinic. At that time there was only minimal improvement, now with an achilles tendon contracture and pes equinus due to immobility.

### INTRODUCTION

Isolated sciatic nerve injury is a common clinical situation. Several mechanisms are responsible for sciatic neuropathies. In this case report we describe a patient with complete paralysis of the right leg due to prolonged sitting in a modified lotus position.

### CASE REPORT

A 51-year-old male fugitive from Iran with post-traumatic stress disorder and schizophrenia presented to our hospital with progressive pain and weakness in the right lower extremity and with difficulty in walking. The symptoms had been present for 6 mo and there was no history of a trauma. The patient denied back pain, bowel or bladder



**Figure 1** Photograph of our patient sitting in a modified lotus position. We hypothesized that repeated sitting in this position, with the right thigh on the heel of the left foot, had lead to compression and subsequent injury of the right sciatic nerve.

incontinence or sexual dysfunction. He drank alcohol occasionally.

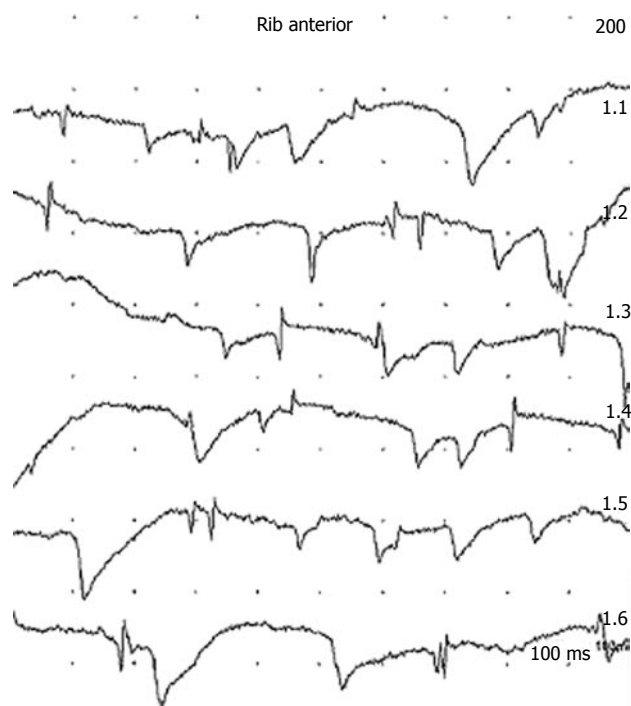
General physical examination was unremarkable. Neurological examination demonstrated atrophy of all muscles of the right lower extremity. He ambulated with a steppage gait associated with an unilateral foot drop and ankle instability. Patient complained of dysesthetic pain, described as a constant burning sensation in the distal sciatic nerve distribution. Pinprick sensation was diminished in the distribution of the right peroneal nerve. The anterior tibial and gastrocnemius muscles were paralysed (grade 0 MRC scale). Strength was normal in the more proximal sciatic innervated muscles. The right ankle reflex was absent.

His general practitioner mentioned that, for unclear reasons, our patient habitually used to sit in a modified lotus position (Figure 1). We hypothesized that repeated sitting in this position, with the right thigh on the heel of the left foot, had lead to compression and subsequent injury of the right sciatic nerve. Magnetic resonance imaging of the spine was normal. Electromyography and nerve conduction studies confirmed a severe isolated sciatic neuropathy in the thigh of the right lower extremity (Figure 2).

## DISCUSSION

The causes of sciatic mononeuropathy can be divided into those occurring in the hip and the thigh region. Only the minority of sciatic neuropathies are localised in the thigh and several mechanisms can lead to sciatic nerve damage in this region<sup>[1]</sup>. Most frequently the nerve injury is the result of a femur fracture, posterior thigh compartment syndrome, laceration, nerve infarction, mass lesions or acute external compression. Prolonged external compression of the sciatic nerve results in nerve damage from ischemia or from direct mechanical laceration of the nerve.

In literature similar cases with development of sciatic nerve injury due to external compression as a result of prolonged or repeated sitting in the same position have been reported. Sciatic neuropathy occurring as an intra-operative pressure palsy is a well-known complication of



**Figure 2** Needle electromyography revealed spontaneous muscle fibre activity due to denervation in the paralysed right tibial anterior muscle.

surgery<sup>[2]</sup>. “Toilet seat” sciatic neuropathy as a complication of gluteal compartment syndrome has been reported in alcoholic intoxicated people falling asleep on a toilet<sup>[3]</sup>. Furthermore, injury of the sciatic nerve after yoga meditation is a known entity, called “lotus neuropathy”<sup>[4,5]</sup>.

Our patient was managed conservatively and subsequently failed to follow up after discharge, but was finally referred again to our outpatient department after more than a year. At that moment there was a minimal improvement of neurologic function of the leg. Additionally, an achilles tendon contracture and pes equinus had developed due to immobility.

In conclusion, in this paper we report a patient with an isolated sciatic neuropathy due to compression of the thigh as a result of sitting in a modified lotus position.

## COMMENTS

### Case characteristics

This patient complained of progressive pain and a 6-mo history of weakness in the right lower extremity and with difficulty in walking.

### Clinical diagnosis

Further examination revealed a complete and isolated sciatic neuropathy due to compression of the thigh as a result of sitting in a modified lotus position.

### Differential diagnosis

The differential diagnostic considerations were nerve injury as a result of a femur fracture, posterior thigh compartment syndrome, laceration, nerve infarction, mass lesions or acute external compression.

### Imaging diagnosis

Magnetic resonance imaging of the spine was normal. Electromyography and nerve conduction studies confirmed a severe isolated sciatic neuropathy in the thigh of the right lower extremity.

### Treatment

The patient was managed conservatively and referred to a physiotherapist, but

subsequently failed to follow up.

### Term explanation

"Lotus neuropathy" is an entity due to injury of the sciatic nerve after yoga meditation.

### Experiences and lessons

Although rare, a so-called "lotus neuropathy" should be included in the differential diagnosis in patients presenting with a isolated sciatic neuropathy.

### Peer review

The authors report an interesting clinical case with a novel clinical entity. Presentation is extremely clear.

## REFERENCES

- 1 Yuen EC, So YT, Olney RK. The electrophysiologic features

of sciatic neuropathy in 100 patients. *Muscle Nerve* 1995; **18**: 414-420 [PMID: 7715627 DOI: 10.1002/mus.880180408]

- 2 Stewart JD, Angus E, Gendron D. Sciatic neuropathies. *Br Med J (Clin Res Ed)* 1983; **287**: 1108-1109 [PMID: 6313118 DOI: 10.1136/bmj.287.6399.1108]
- 3 Tyrrell PJ, Feher MD, Rossor MN. Sciatic nerve damage due to toilet seat entrapment: another Saturday night palsy. *J Neurol Neurosurg Psychiatry* 1989; **52**: 1113-1115 [PMID: 2795087 DOI: 10.1136/jnnp.52.9.1113-a]
- 4 Chusid J. Yoga foot drop. *JAMA* 1971; **217**: 827-828 [PMID: 4327519 DOI: 10.1001/jama.1971.03190060065025]
- 5 Vogel CM, Albin R, Alberts JW. Lotus footdrop: sciatic neuropathy in the thigh. *Neurology* 1991; **41**: 605-606 [PMID: 2011269 DOI: 10.1212/WNL.41.4.605]

**P- Reviewers:** Hadianamrei R, Maheshwari AV, Posadas EM

**S- Editor:** Ma YJ **L- Editor:** A **E- Editor:** Wu HL





## Utility of diffusion-weighted imaging in the diagnosis of inguinal lymph node metastasis with malignant melanoma

Ummugulsum Bayraktutan, Mecit Kantarci, Berhan Pirimoglu, Hayri Ogul, Aylin Okur, Nesrin Gursan

Ummugulsum Bayraktutan, Mecit Kantarci, Berhan Pirimoglu, Hayri Ogul, Aylin Okur, Department of Radiology, School of Medicine, Atatürk University, 25240 Erzurum, Turkey  
Nesrin Gursan, Department of Pathology, School of Medicine, Atatürk University, 25240 Erzurum, Turkey

**Author contributions:** Bayraktutan U, Kantarci M and Pirimoglu B designed the research and wrote the paper; Kantarci M, Pirimoglu B and Ogul H performed the research; Kantarci M, Okur A and Gursan N analyzed the data.

**Correspondence to:** Mecit Kantarci, MD, PhD, Department of Radiology, School of Medicine, Atatürk University, 200 Evler Mah, 14, Sok No 5 Dadaskent, 25240 Erzurum, Turkey. [akkanrad@hotmail.com](mailto:akkanrad@hotmail.com)

Telephone: +90-442-2361212 Fax: +90-442-2361301

Received: September 30, 2013 Revised: December 23, 2013

Accepted: January 7, 2014

Published online: February 16, 2014

metastases correlation with pathological findings.

© 2014 Baishideng Publishing Group Co., Limited. All rights reserved.

**Key words:** Diffusion-weighted imaging; Magnetic resonance imaging; Inguinal lymph node; Malignant melanoma; Metastasis; Apparent diffusion coefficient

**Core tip:** Diffusion-weighted magnetic resonance imaging (DW-MRI) measures differences in tissue microstructure based on the random displacement of water molecules. The differences in water mobility are quantified using the apparent diffusion coefficient which has an inverse relationship with tissue cellularity. As such, the technique is able to differentiate between tumoral tissue and normal or necrotic tissue. In this paper, we present an inguinal lymph node metastasis of malignant melanoma after surgery, with DW-MRI findings.

### Abstract

Malignant melanoma is a malignancy of pigment-producing cells (melanocytes) located predominantly in the skin. Nodal metastases are an adverse prognostic factor compromising long term patient survival. Therefore, accurate detection of regional nodal metastases is required for optimization of treatment. Computed tomography (CT) and magnetic resonance imaging (MRI) remain the primary imaging modalities for regional staging of malignant melanoma. However, both modalities rely on size-related and morphological criteria to differentiate between benign and malignant lymph nodes, decreasing the sensitivity for detection of small metastases. Surgery is the primary mode of therapy for localized cutaneous melanoma. Patients should be followed up for metastases after surgical removal. We report here a case of inguinal lymph node enlargement with a genital vesicular lesion with a history of surgery for malignant melanoma on her thigh two years ago. CT and diffusion weighted-MRI (DW-MRI) were applied for the lymph node identification. DW-MRI revealed malignant lymph nodes due to malignant melanoma

Bayraktutan U, Kantarci M, Pirimoglu B, Ogul H, Okur A, Gursan N. Utility of diffusion-weighted imaging in the diagnosis of inguinal lymph node metastasis with malignant melanoma. *World J Clin Cases* 2014; 2(2): 42-44 Available from: URL: <http://www.wjgnet.com/2307-8960/full/v2/i2/42.htm> DOI: <http://dx.doi.org/10.12998/wjcc.v2.i2.42>

### INTRODUCTION

Malignant melanoma is located predominantly in the skin but also found in the eyes, ears, gastrointestinal tract, leptomeninges and oral and genital mucous membranes. Melanoma accounts for only 4% of all skin cancers; however, it causes the greatest number of skin cancer-related deaths worldwide. Early detection of thin cutaneous melanoma is the best means of reducing mortality<sup>[1]</sup>. We present a case with inguinal lymph node enlargement with a genital vesicular lesion with a history of surgery

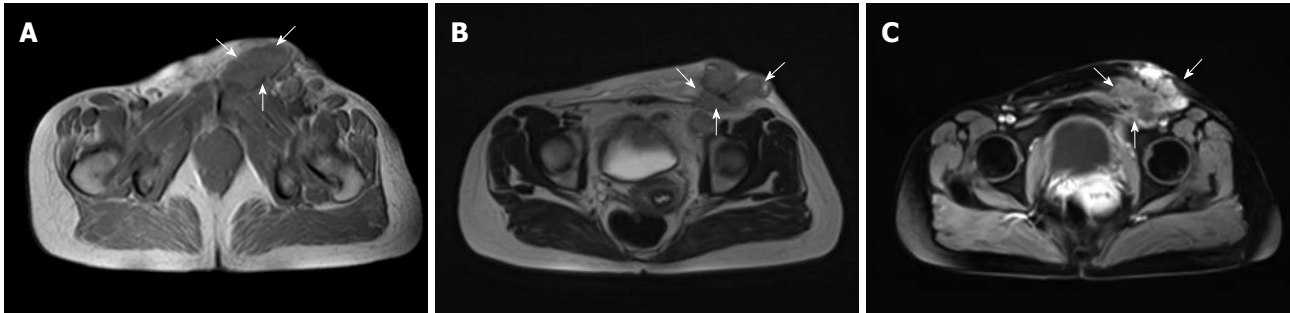

Figure 1 Axial T1 weighted image (A), T2 weighted image (B) and contrast enhanced fat saturated T1 image (C) showing contrast enhancing inguinal conglomerated lymph node enlargement (arrows).

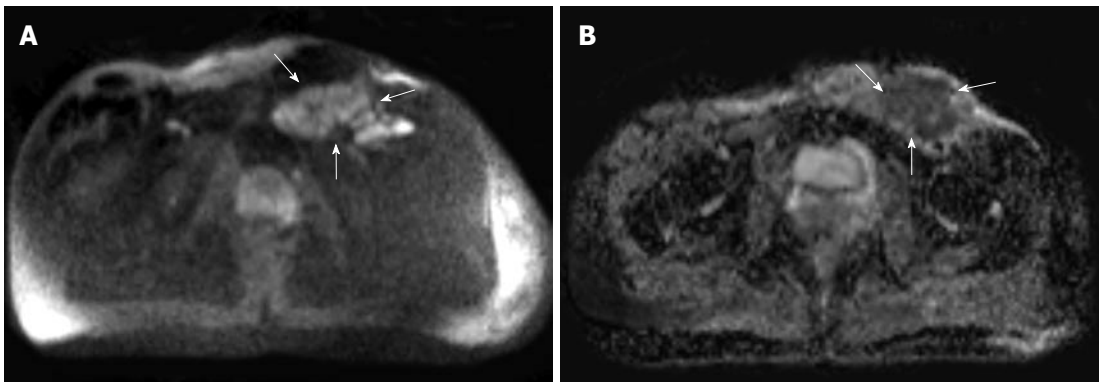


Figure 2 Diffusion weighted images b800 (A) and apparent diffusion coefficient map (B) showing diffusion restriction in inguinal conglomerated lymph nodes (arrows).

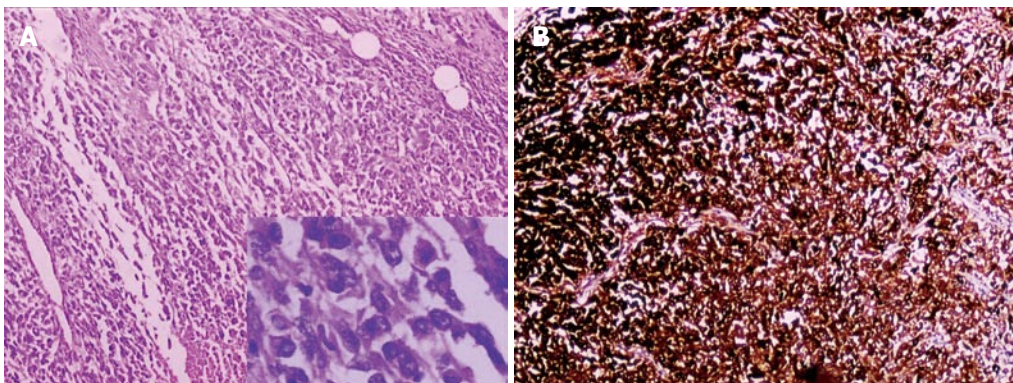


Figure 3 Pathological examination. A: Photomicrograph of metastatic malignant melanoma in the inguinal lymph node (HE, × 50). The bottom right corner HE, × 100; B: Immunohistochemical study shows that the spindle cells are positive for HMB-45.

for malignant melanoma two years ago.

## CASE REPORT

A 38-year-old woman was admitted to our hospital complaining of a mass on her left inguinal region for about 1 mo. On physical examination there was left inguinal lymph node swelling and a genital vesicular lesion. The patient had a history of malignant melanoma on her thigh 2 years ago. Computed tomography (CT) scans showed inguinal conglomerated lymph node enlargement that may be inflammatory due to a genital lesion or malig-

nant melanoma metastases. Magnetic resonance imaging (MRI) also showed inguinal conglomerated lymph node enlargement (Figure 1). Diffusion-weighted MRI revealed reduced apparent diffusion coefficient (ADC) values in these lymph nodes consistent with malignancy (Figure 2). After removal of the mass by surgery, histopathological examination showed evidence of malignant melanoma metastases (Figure 3).

## DISCUSSION

Malignant melanoma arises from melanocytes, the cells

that give skin its color, and can spread to nearby lymph nodes and, eventually, distant sites in the body. Approximately 50000 new cases of malignant melanoma occur in the United States every year and about 8000 people die from this most lethal form of skin cancer. If untreated, malignant melanomas can spread rapidly, sometimes causing death within months of diagnosis. However, the five year cure rate of early, superficial lesions is nearly 100%<sup>[1,2]</sup>.

Melanomas can occur on mucous membranes of the mouth, genital regions and anus. Sun-exposed areas are at higher risk than shielded areas. Although melanomas can occur anywhere on the body, and some types are more likely to be found in some areas than others, women tend to develop more melanomas on their legs, while men's arise more frequently on the torso<sup>[2]</sup>.

Risk factors for malignant melanoma are sun exposure, white race, first degree relatives with a history of melanoma (may increase one's risk by up to eight times), personal history of previous melanoma, dysplastic nevus syndrome, large congenital melanocytic nevi, lentigo maligna ("Hutchinson's freckle"), history of other non-melanoma skin cancers, immunosuppression and higher numbers of melanocytic nevi (moles)<sup>[3]</sup>.

Surgical removal of melanomas that have not metastasized or penetrated to deeper layers of skin is often curative. Metastatic disease is generally inoperable. Lymph node dissection, immunotherapy, vaccine therapy, chemotherapy and hyperthermia are among the modalities used to treat metastases<sup>[4]</sup>. Current the National Comprehensive Cancer Network guidelines do not recommend surveillance laboratory or imaging studies for asymptomatic patients with stage I A, I B and II A melanoma (*i.e.*, tumors  $\leq$  4 mm depth). Imaging studies (chest radiograph, CT and/or positron emission tomography-CT) should be obtained as clinically indicated for confirmation of suspected metastasis or to delineate the extent of disease and may be considered to screen for recurrent/metastatic disease in patients with stage II B-IV disease, although this latter recommendation remains controversial. Routine laboratory or radiological imaging in asymptomatic melanoma patients of any stage is not recommended after 5 years of follow-up<sup>[5]</sup>.

CT and MRI facilitate detection of lymph nodes; however, both modalities rely on size-related and morphological criteria to differentiate between benign and malignant lymph nodes. Diffusion-weighted imaging measures differences in tissue microstructure based on the random displacement of water molecules. The magnitude of water molecule movement is expressed as an ADC value. Its usefulness in the diagnosis of malignant tumors has gained interest. The technique is able to dif-

ferentiate between tumoral tissue and normal or necrotic tissue<sup>[5,6]</sup>. The improved nodal identification may aid treatment planning and further nodal characterization<sup>[7]</sup>. In conclusion, DWI is recommended for evaluation of lymph node metastasis in patients with malignant melanoma.

## COMMENTS

### Case characteristics

A 38-year-old woman was admitted to the hospital with complaint of a mass on her left inguinal region for about 1 mo ago.

### Clinical diagnosis

On physical examination there were left inguinal lymph node swelling and a genital vesicular lesion.

### Imaging diagnosis

Computed tomography (CT) scans showed inguinal conglomerated lymph node enlargement, may be inflammatory due to genital lesion or malignant melanoma metastases.

### Treatment

CT and diffusion weighted-magnetic resonance imaging (DW-MRI) were applied for the lymph node identification, DW-MRI revealed malignant lymph nodes due to malignant melanoma metastases correlation with pathological findings.

### Experiences and lessons

DWI is recommended for evaluation of lymph node metastasis in patients with malignant melanoma.

### Peer review

Presentation and readability of the manuscript is good, the paper is brief, concise, the text is clear and easily comprehensible, adequately describes the course of the disease, its diagnostics and treatment of the patient.

## REFERENCES

- 1 **Jemal A**, Siegel R, Ward E, Hao Y, Xu J, Thun MJ. Cancer statistics, 2009. *CA Cancer J Clin* 2009; **59**: 225-249 [PMID: 19474385 DOI: 10.3322/caac.20006]
- 2 **Parkin DM**, Bray F, Ferlay J, Pisani P. Global cancer statistics, 2002. *CA Cancer J Clin* 2005; **55**: 74-108 [PMID: 15761078 DOI: 10.3322/canjclin.55.2.74]
- 3 **Friedman GD**, Tekawa IS. Association of basal cell skin cancers with other cancers (United States). *Cancer Causes Control* 2000; **11**: 891-897 [PMID: 11142523]
- 4 **Demierre MF**, Nathanson L. Chemoprevention of melanoma: an unexplored strategy. *J Clin Oncol* 2003; **21**: 158-165 [PMID: 12506185 DOI: 10.1200/JCO.2003.07.173]
- 5 **Gershenwald JE**, Soong SJ, Balch CM. 2010 TNM staging system for cutaneous melanoma...and beyond. *Ann Surg Oncol* 2010; **17**: 1475-1477 [PMID: 20300965 DOI: 10.1245/s10434-010-0986-3]
- 6 **Vandecaveye V**, De Keyser F, Hermans R. Diffusion-weighted magnetic resonance imaging in neck lymph adenopathy. *Cancer Imaging* 2008; **8**: 173-180 [PMID: 18824423 DOI: 10.1102/1470-7330.2008.0025]
- 7 **Mir N**, Sohaib SA, Collins D, Koh DM. Fusion of high b-value diffusion-weighted and T2-weighted MR images improves identification of lymph nodes in the pelvis. *J Med Imaging Radiat Oncol* 2010; **54**: 358-364 [PMID: 20718916 DOI: 10.1111/j.1754-9485.2010.02182.x]

**P- Reviewers:** Kimyai-Asadi A, Negosanti L, Zamurovic M  
**S- Editor:** Zhai HH **L- Editor:** Roemmele A **E- Editor:** Wu HL





## Baastrup's disease: The kissing spine

Amit Singla, Vivek Shankar, Samarth Mittal, Abhinav Agarwal, Bhavuk Garg

Amit Singla, Vivek Shankar, Samarth Mittal, Abhinav Agarwal, Bhavuk Garg, Department of Orthopaedics, All India Institute of Medical Sciences, New Delhi 110039, India

Author contributions: Singla A wrote and finalized the manuscript and reviewed the literature; Shankar V, Agarwal A contributed to the manuscript and finalized it; Garg B provided the case and finalized the manuscript; Mittal S did the literature search, contributed to the manuscript and finalized it.

Correspondence to: Dr. Samarth Mittal, MS, Senior Resident, Department of Orthopaedics, All India Institute of Medical Sciences, Teaching Block, 5<sup>th</sup> floor AIIMS, New Delhi 110039, India. [samarthmittal@gmail.com](mailto:samarthmittal@gmail.com)

Telephone: +91-901-3562489 Fax: +11-26-583441

Received: September 27, 2013 Revised: November 13, 2013

Accepted: January 15, 2014

Published online: February 16, 2014

### Back pain

**Core tip:** Baastrup's disease, although not a rare entity, is often misdiagnosed and wrongly treated due to poor knowledge. Complete evaluation and a detailed examination of radiographic images are crucial for a proper diagnosis and to avoid mismanagement of the condition, including a hasty surgical intervention.

Singla A, Shankar V, Mittal S, Agarwal A, Garg B. Baastrup's disease: The kissing spine. *World J Clin Cases* 2014; 2(2): 45-47 Available from: URL: <http://www.wjgnet.com/2307-8960/full/v2/i2/45.htm> DOI: <http://dx.doi.org/10.12998/wjcc.v2.i2.45>

### Abstract

A 67-year-old male presented with a gradually progressive low back pain of 2 years duration. The patient was leading a retired life and there was no history of chronic fever or significant trauma. There was no radiation of pain or any features suggestive of claudication. There was no history of any comorbidity. The pain was aggravated with extension of the spine and relieved with flexion. There was no swelling or neurological deficit, but muscle spasm was present. Radiographs of the spine revealed degenerative changes in the lumbosacral spine, along with articulation of spinous processes at in lumbar spine at all levels level suggestive of Baastrup's disease, commonly known as "kissing spine". Routine blood investigations were within normal limits. The patient was managed conservatively. He was given a week's course of analgesics and muscle relaxants and then started on spinal flexion exercises, with significant improvement being noted at 6 months follow up.

© 2014 Baishideng Publishing Group Co., Limited. All rights reserved.

**Key words:** Baastrup's disease; Neoarthrosis; Spinous process; Kissing spine; Osteophytes; Low back ache;

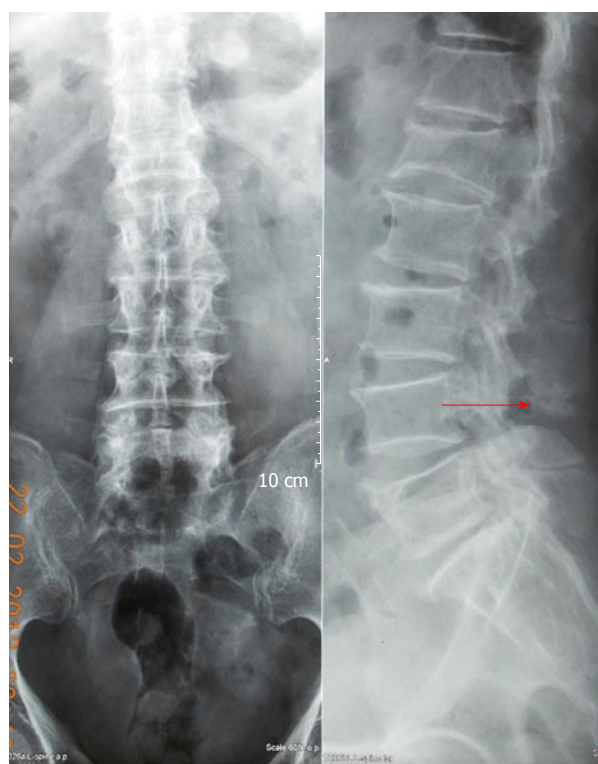### INTRODUCTION

Baastrup's disease (kissing spine) is a relatively common entity characterized by degenerative changes of spinous processes and inter-spinous soft tissues. It involves the formation of hypertrophic spinous processes, an important cause of mechanical back pain, and accompanying degenerative disc disease. Most of the cases previously described in the literature were managed either surgically or with fluoroscopy image guided steroid injections. To the best of our knowledge, this is the first case showing significant improvement with only conservative management.

### CASE REPORT

A 67-year-old male presented with gradually progressing low back pain of 2 years duration. The pain was aggravated with extension of the spine and relieved with flexion. There was no evidence suggestive of radiation of pain or any clinical features suggestive of claudication. The patient had no additional comorbidity. There was no history of chronic fever or significant trauma. Radiographs of the spine revealed degenerative changes involving the lumbosacral spine, along with articulation of spinous processes at at multiple levels level (Figure 1),





**Figure 1** Radiographs of lumbar spine in anterior-posterior and lateral views showing Baastrup's disease at multiple lumbar level.

commonly known as “kissing spine” and strongly suggestive of Baastrup's disease in the absence of any other features. The patient was managed conservatively with muscle relaxants and analgesics for one week and, once the pain subsided, was started on physiotherapy with spinal flexion exercises. The treatment plan involved conservative management with a close follow up. The option of intralesional steroid injections and bursal excision was to be considered if conservative treatment failed. The patient was monitored at the outpatient department at regular intervals and at 6 mo follow up was found to have significant improvement with physiotherapy alone and hence was asked to continue the exercises.

## DISCUSSION

This condition was first described as a neoarthrosis between adjacent spinous processes by Mayer<sup>[1]</sup>. Brailsford<sup>[2]</sup> demonstrated the same entity and labeled it “kissing spines”. Baastrup<sup>[3]</sup> described this condition again in detail and subsequently this condition came to be known as Baastrup's disease. It was noted clinically in 6.3% of college athletes<sup>[4]</sup>, most commonly gymnasts, and was thought to be related to the repetitive flexion and extension attributed to the sport. In a recent study by Kwong *et al*<sup>[5]</sup>, Baastrup's disease was found in 413 (41.0%) patients (diagnostic criteria being close approximation and contact between apposing spinous processes and sclerosis of the superior and inferior portions of adjacent processes on computed tomography) with an incidence of 81.3% among patients older than 80 years, whereas Maes *et al*<sup>[6]</sup>

reported an overall incidence of 8.2% with the presence of a bursa between spinous process as a diagnostic criteria based on magnetic resonance imaging.

Two cohort studies have demonstrated conflicting reports of clinical improvement following surgical intervention. This included one early study of 10 patients by Franck<sup>[7]</sup> in 1944 in which the patients undergoing surgical excision of the spinous process for Baastrup's disease demonstrated improvement. A later study by Beks *et al*<sup>[8]</sup> in 1989 in which 64 patients who underwent either partial or total surgical excision of the lumbar spinous processes demonstrated that surgery does not always alleviate the patient's pain. Their research suggested that “kissing spine” might not be a disease entity itself but an additional pathology, specifically spondylosis with osteophyte formation. A case has been reported of atrophy and fatty replacement of the paraspinal musculature in a patient with Baastrup's disease on X-ray<sup>[8]</sup>. Pain can be attributed to multiple factors in Baastrup's disease, including mechanical pain secondary to the hypertrophic spinous processes coming into contact with each other, secondary to degenerative disc disease, and interspinous bursal fluid collections extending through the ligamentum flavum, leading to central canal stenosis<sup>[9]</sup>. In 2004, Pinto *et al*<sup>[10]</sup> reported 2 cases of spinous process fractures in patients with Baastrup's disease and proposed that close proximity of the spinous processes resulted in its fracture and hence pain. Management includes decompression and posterior spinal instrumentation surgery or fluoroscopically guided interspinous steroid injections<sup>[11]</sup>.

In conclusion, Baastrup's disease is not a rare cause of back pain in the elderly but it is frequently missed on radiographs due to lack of knowledge about the disease on the part of physician and overexposure of spinous processes in most X rays. Most of the management suggested in the literature is invasive, *i.e.*, surgery or intralesional injections. However, conservative management can also produce good results. Hence, it is imperative that the treating physician must attempt a conservative line of management before moving onto invasive modalities. Since this condition is one of the few treatable causes of back pain in the vast spectrum of spinal conditions, one must be aware of the condition to correctly diagnose and institute a line of treatment most beneficial to the patient.

## COMMENTS

### Case characteristics

A 67-year-old male presented with a gradually progressive low back pain of 2 years duration.

### Clinical diagnosis

Baastrup's disease is not a rare cause of back pain in elderly, with pain aggravated on extension and relieved on bending forward.

### Differential diagnosis

Common differential diagnoses include lumbar spondylosis, muscle strain, spondylolisthesis, fracture of the spinous process, vertebral compression fractures and infectious etiologies of the spine.

### Imaging diagnosis

Radiographs showing articulation of spinous processes, *i.e.*, the kissing spine.

**Peer review**

The authors present a nice case report.

**REFERENCES**

- 1 **Mayer O.** Ueber zwei neu entdeckte Gelenke an der Wirbelsäule des menschlichen Körpers. *Z Physiol* 1825; **2**: 29-35
- 2 **Brailsford JF.** Deformities of the lumbo-sacral regions of the spine. *Br J Surg* 1929; **16**: 562-627
- 3 **Baastруп CL.** On the spinous processes of the lumbar vertebrae and the soft tissue between them and on pathological changes in the region. *Acta Radiol* 1933; **14**: 52-54
- 4 **Mann DC, Keene JS, Drummond DS.** Unusual causes of back pain in athletes. *J Spinal Disord* 1991; **4**: 337-343 [PMID: 1839364]
- 5 **Kwong Y, Rao N, Latief K.** MDCT findings in Baastруп disease: disease or normal feature of the aging spine? *AJR Am J Roentgenol* 2011; **196**: 1156-1159 [PMID: 21512085 DOI: 10.2214/AJR.10.5719]
- 6 **Maes R, Morrison WB, Parker L, Schweitzer ME, Carrino JA.** Lumbar interspinous bursitis (Baastруп disease) in a symptomatic population: prevalence on magnetic resonance imaging. *Spine (Phila Pa 1976)* 2008; **33**: E211-E215 [PMID: 18379391 DOI: 10.1097/BRS.0b013e318169614a]
- 7 **Franck S.** Surgical treatment of intraspinal osteoarthritis (kissing spine). *Acta Orthop Scand* 1944; **14**: 127-152
- 8 **Beks JW.** Kissing spines: fact or fancy? *Acta Neurochir (Wien)* 1989; **100**: 134-135 [PMID: 2589119]
- 9 **Chen CK, Yeh L, Resnick D, Lai PH, Liang HL, Pan HB, Yang CF.** Intraspinal posterior epidural cysts associated with Baastруп's disease: report of 10 patients. *AJR Am J Roentgenol* 2004; **182**: 191-194 [PMID: 14684538 DOI: 10.2214/ajr.182.1.1820191]
- 10 **Pinto PS, Boutin RD, Resnick D.** Spinous process fractures associated with Baastруп disease. *Clin Imaging* 2004; **28**: 219-222 [PMID: 15158230 DOI: 10.1016/S0899-7071(03)00156-6]
- 11 **Mitra R, Ghazi U, Kirpalani D, Cheng I.** Interspinous ligament steroid injections for the management of Baastруп's disease: a case report. *Arch Phys Med Rehabil* 2007; **88**: 1353-1356 [PMID: 17908582 DOI: 10.1016/j.apmr.2007.05.033]

**P- Reviewers:** Kutscha-Lissberg F, Serhan H    **S- Editor:** Gou SX  
**L- Editor:** Roemmele A    **E- Editor:** Wu HL



## Ameloblastic carcinoma: Report of a rare case

Mandadi Dakshinamurthy Srikanth, Besta Radhika, Kiran Metta, Nukala Valli Renuka

Mandadi Dakshinamurthy Srikanth, Besta Radhika, Department of Oral Medicine and Radiology, MNR Dental College and Hospital, Sangareddy 502001, India

Kiran Metta, Department of Conservative Dentistry and Endodontics, Midsr Dental College and Hospital, Latur, Maharashtra 413512, India

Nukala Valli Renuka, Department of Periodontics, Army College of Dental Sciences, Secunderabad 500087, India

**Author contributions:** Srikanth MD and Radhika B carried out the extra oral and intra oral examinations, the radiological investigations and the writing of the case report; Kiran M carried out the pre-surgical endodontics; Renuka NV carried out the pre-surgical oral prophylaxis and necessary periodontal investigations.

**Correspondence to:** Mandadi Dakshinamurthy Srikanth, Senior Lecturer, Department of Oral Medicine and Radiology, MNR Dental College and Hospital, MNR Nagar Fasalwadi, Sangareddy 502001, India. [drsrikanthmd@rediffmail.com](mailto:drsrikanthmd@rediffmail.com)

Telephone: +91-984-9207997 Fax: +91-984-9207997

Received: September 19, 2013 Revised: November 30, 2013

Accepted: January 7, 2014

Published online: February 16, 2014

© 2014 Baishideng Publishing Group Co., Limited. All rights reserved.

**Key words:** Ameloblastic carcinoma; Squamous metaplasia

**Core tip:** Clinically, ameloblastic carcinoma is more aggressive than most typical ameloblastomas, with extensive local destruction, perforation of the cortical plate, extension into surrounding soft tissues, numerous recurrent lesions and metastasis, usually to cervical lymph nodes. Histologically, the tumor cells resemble cells seen in ameloblastoma but show cytological atypia, cellular pleomorphism, nuclear hyperchromatism, mitoses and vascular and neural invasion. These identifying features of ameloblastic carcinoma must be known and recognized by dental practitioners. It is probable that ameloblastoma, like other tumors (such as carcinoid tumors and epithelial tumors of the ovary), shows a spectrum of histological and biological behavior, ranging from benignity at one end to frank malignancy at the other.

### Abstract

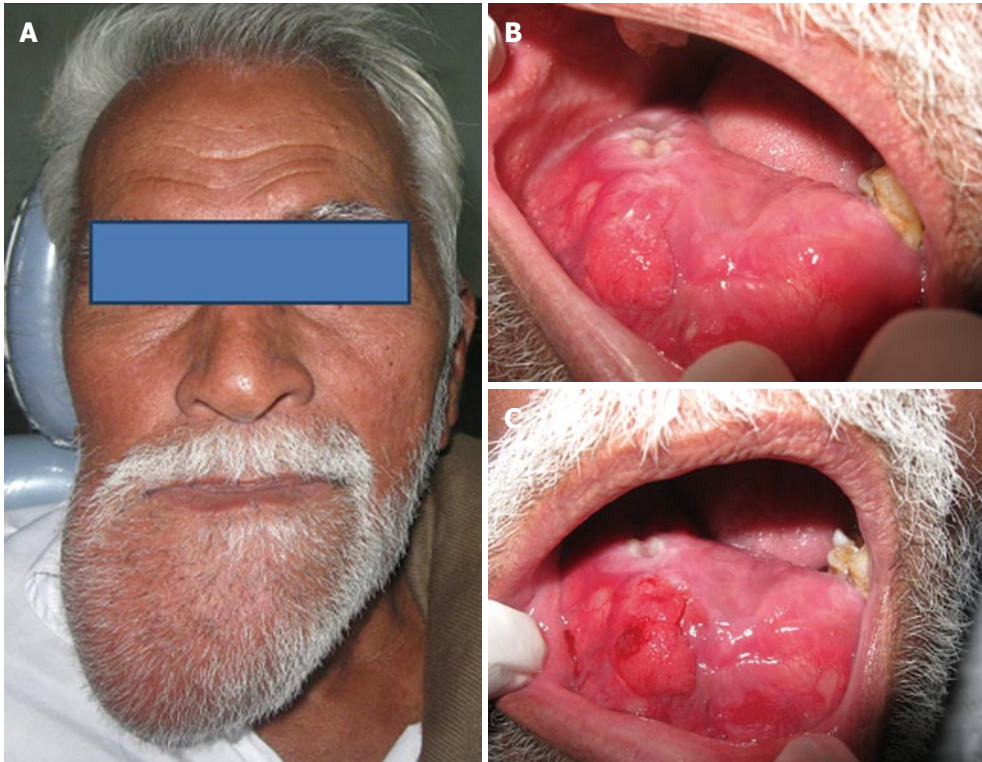Ameloblastic carcinoma is a rare odontogenic tumor exhibiting histological evidence of malignancy in the primary or recurrent tumor. It is characterized by rapid, painful expansion of the jaw, unlike conventional ameloblastomas. The tumor most frequently involves the mandible. The expanding lesion causes perforation of the buccal and lingual plates of the jaw and invades the surrounding soft tissue. Rapidly growing large tumor mass may cause tooth mobility. A mandibular tumor involving the mental nerve leads to paresthesia of the nerve. A maxillary tumor can produce a fistula in the palate and paresthesia of the infraorbital nerve. Most ameloblastic carcinomas are presumed to have arisen de novo with a few cases of malignant transformation of ameloblastomas. Although rare, these lesions have been known to metastasize, mostly to the regional lymph nodes or lungs. A case of ameloblastic carcinoma in a 60-year-old man is reported here and its clinical, radiological and histological features are discussed.

Srikanth MD, Radhika B, Metta K, Renuka NV. Ameloblastic carcinoma: Report of a rare case. *World J Clin Cases* 2014; 2(2): 48-51 Available from: URL: <http://www.wjgnet.com/2307-8960/full/v2/i2/48.htm> DOI: <http://dx.doi.org/10.12998/wjcc.v2.i2.48>

### INTRODUCTION

Malignant odontogenic tumors are very uncommon and ameloblastic carcinoma is a rare odontogenic carcinoma, with very few such cases being reported so far. The frequency of malignant change in ameloblastomas is difficult to establish but probably may be less than 1% among all cases of ameloblastomas<sup>[1]</sup>.

The terminology for these lesions is somewhat controversial. The term malignant ameloblastoma should be used for a tumor that shows the histopathological



**Figure 1** Extra (A) and intra oral photograph of swelling with labial, buccal and lingual cortical expansion (B, C).

features of ameloblastoma, both in the primary tumor and in the metastatic deposits<sup>[2]</sup>. However, the term ameloblastic carcinoma should be reserved for an ameloblastoma that has cytological features of malignancy in the primary tumor, in a recurrence, or in any metastatic deposit<sup>[3]</sup>. These lesions may follow a markedly aggressive local course but metastases do not necessarily occur<sup>[4]</sup>.

Odontogenic carcinoma signifies the primary malignant epithelial tumors of the terms that are so poorly differentiated that they bear little or no resemblance to any of the odontogenic apparatus. With the presence of many clear cells in conjunction with the other patterns and histological features considered to be indicative of malignancy in these lesions and in keeping with the guidelines of World Health Organization (WHO) classification of odontogenic tumors, some authors even prefer to designate these tumors as clear cell ameloblastic carcinoma or ameloblastic carcinoma, clear cell variant.

## CASE REPORT

A 60-year-old male patient came to the department of oral medicine and radiology with a chief complaint of swelling over the right side of the face for 10 years (Figure 1A). History revealed that he first noticed a small intra oral swelling at the labial aspect of lower right canine region which gradually increased in size. Initially he noticed pain in that region but subsequently but there was no pain and the swelling increased progressively to the present size. The patient also noticed development of paresthesia of the lower lip with pain over the swelling.

On examination, a huge extra oral swelling was found, measuring around 23 cm × 11.5 cm in size, extending from the right side of mandible and crossing the midline with well defined margins, hard in consistency, with tenderness over the swelling. Intra oral examination revealed complete obliteration of the buccal and labial vestibule on the right side, with the swelling extending in to the anterior region of the floor of the mouth (Figure 1B). It had a normal mucosal color and 31-33 and 41-47 teeth were missing. The intra oral swelling was hard in consistency and tenderness was present on palpation (Figure 1C).

In light of the above findings and the nature and duration of the lesion, a provisional diagnosis of ameloblastoma was considered and odontogenic myxoma and osteosarcoma were considered for a differential diagnosis.

The patient had an orthopantomograph (OPG), computed tomography (CT) mandible and magnetic resonance imaging. OPG showed huge multilocular radiolucency with the septa giving an appearance of a soap bubble or honeycomb extending from the ramus molar region on right side, crossing the midline to the lower left premolar region (Figure 2A). CT dental scan showed an enlarged tumor extending from the ramus region of 48 to the 35 region (Figure 2B). The tumor caused severe expansion of the buccal and lingual cortical plates with a multilocular appearance.

Excisional biopsy revealed numerous epithelial follicles spread out in a scanty connective tissue stroma. The epithelial nests showed typical (tall) columnar peripheral cells with apically placed nuclei and vacuolated cytoplasm. The central cells showed squamous metaplasia



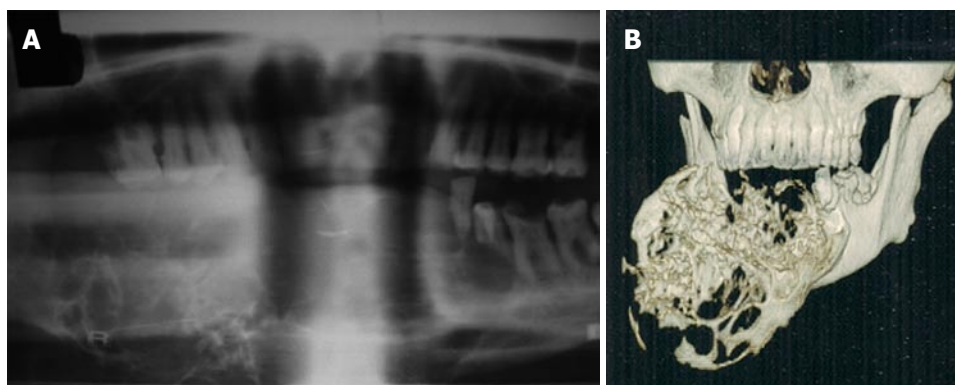


Figure 2 Orthopantomograph (A) and 3D computed tomography (B) showing honeycomb lesion.

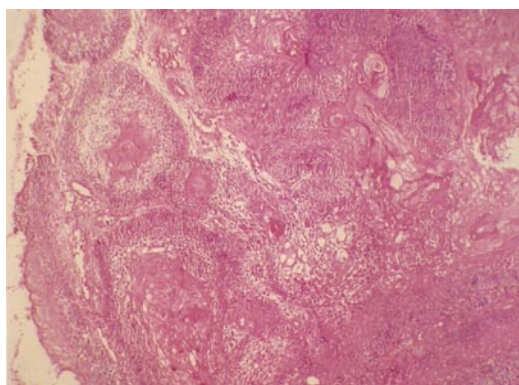


Figure 3 Histopathology specimen showing epithelial follicles with squamous metaplasia and numerous keratin pearls.

and numerous keratin pearls. A few cells showed features of dysplasia, such as irregular aggregation, cellular and nuclear pleomorphism with nuclear hyperchromasia (Figure 3).

The histological features were consistent with ameloblastic carcinoma. Myxomas radiologically show honeycomb variant and fine trabeculations within the small lobules not present in ameloblastoma. Osteosarcoma is a common primary malignant tumor affecting the jaw and radiologically a sunray appearance is present. Hence, they were excluded and a final diagnosis of ameloblastic carcinoma was made. The patient underwent surgical resection of the tumor by microvascular reconstructive surgery with complete resection of the mandible and reconstruction of the mandible was done by fibula graft (Figure 4). The patient is being followed up closely.

## DISCUSSION

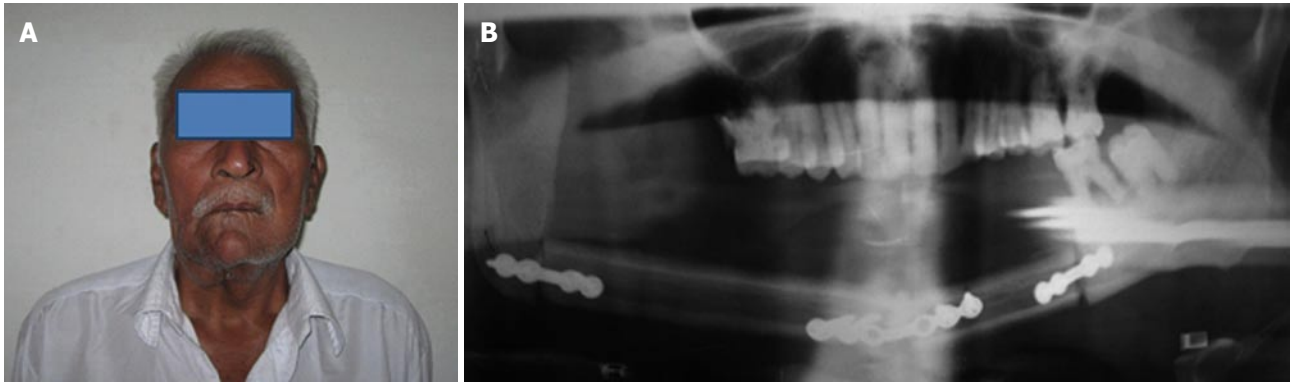
Ameloblastic carcinoma is a rare neoplasm that represents a challenge in its diagnosis, treatment and prognosis. Information regarding its clinical features is scanty<sup>[5]</sup>. The demographic data of ameloblastic carcinoma reported in the literature suggests that it is more common in males (M:F 1.5:1) and the site of distribution is in the mandible, particularly in the posterior mandible<sup>[1]</sup>. The age range of occurrence shows a large variation with an average age of

39.8 years. However, a few authors have stated that the sixth decade is the predominant age group. Ameloblastic carcinoma has been reported to arise either *de novo* or from a preexisting odontogenic cyst or ameloblastoma<sup>[5]</sup>. The common clinical signs and symptoms include swelling, pain, trismus and dysphonia<sup>[6]</sup> and there are several classifications: (1) WHO classification of odontogenic carcinomas: malignant ameloblastoma; primary intraosseous carcinoma; malignant variants of other odontogenic tumors; and malignant changes in odontogenic cysts; (2) Classification of odontogenic carcinomas according to Slootweg and Muller: primary intraosseous carcinoma, *e.g.*, odontogenic cyst (Type I); malignant ameloblastoma (type II A); ameloblastoma carcinoma, arising *de novo*, *e.g.*, ameloblastoma, or *e.g.*, odontogenic tumor (type II B); and primary intraosseous carcinoma arising *de novo* (type III A: non keratinizing; type III B: keratinizing); and (3) IJ Slater, Oral and Maxillofacial Clinics of North America - odontogenic carcinomas: metastasizing ameloblastoma; ameloblastic carcinoma; carcinoma, *e.g.*, ameloblastoma; primary intraosseous carcinoma; solid; cystic (*e.g.*, odontogenic cyst); central mucoepidermoid carcinoma; ghost cell odontogenic carcinoma; and clear cell odontogenic carcinoma.

### Odontogenic sarcoma: Ameloblastic fibrosarcoma

The diagnostic criteria of an ameloblastic carcinoma that differentiate from ameloblastoma are based on cytological atypia and an increased mitotic index<sup>[5]</sup>. The histological changes should include a higher proliferative index emphasized by higher mitotic activity, higher proliferating cell nuclear antigen expression and higher ki67, atypia such as nuclear pleomorphism and basilar hyperplasia, hyperchromatic nuclei of basaloid cells, and other features of malignancy, such as peripheral or perivascular invasion. This should be correlated with the clinical features. The four important characteristics include<sup>[5]</sup> growth rate, the propensity for ameloblastic carcinoma to perforate the cortex, pain, as a third of patients with ameloblastic carcinoma experience pain or discomfort, and sensory disturbance, such as paresthesia which is rare with ameloblastoma.

Ameloblastic carcinoma is an aggressive neoplasm



**Figure 4** Post-op photograph (A) and orthopantomograph (B) of patient after surgical resection of the tumor by microvascular reconstructive surgery and reconstruction with a fibula graft.

that is locally invasive and can spread to regional lymph nodes or distant metastatic sites such as long bones. It is managed with wide local excision, elective or therapeutic neck dissection and post operative radiation therapy<sup>[5]</sup>. Radiotherapy and chemotherapy seem to be of limited value. The prognosis is poor and hence close follow up of the patient is needed.

Although the reported cases of ameloblastic carcinoma are scarce, the above features can be applied to diagnose an ameloblastic carcinoma at an early stage to enable early intervention and better treatment<sup>[7]</sup>.

## COMMENTS

### Case characteristics

A case of ameloblastic carcinoma in a 60-year-old man is reported here and its clinical, radiological and histological features are discussed.

### Imaging diagnosis

The patient had an orthopantomograph (OPG), computed tomography mandible and magnetic resonance imaging. OPG showed huge multilocular radiolucency with the septa giving an appearance of a soap bubble or honeycomb extending from the ramus molar region on right side, crossing the midline to the lower left premolar region.

### Pathological diagnosis

Excisional biopsy revealed numerous epithelial follicles spread out in a scanty connective tissue stroma.

### Treatment

The patient underwent surgical resection of the tumor by microvascular reconstructive surgery with complete resection of mandible and the reconstruction of the mandible was done by a fibula graft.

## Experiences and lessons

It is probable that ameloblastoma, like other tumors (such as carcinoid tumors and epithelial tumors of the ovary), shows a spectrum of histological and biological behavior, ranging from benignity at one end to frank malignancy at the other.

### Peer review

Ameloblastic carcinoma is a rare malignant tumor. This report is very interesting.

## REFERENCES


- 1 **Rajendran R.** Shafer's textbook of oral pathology. 6<sup>th</sup> ed. India: Elsevier publisher, 2009
- 2 **Neville BW, Damm DD, Allen CM, Bouquot JE.** Odontogenic cysts and tumors. Oral and maxillofacial pathology. Philadelphia: Saunders, 2002: 589
- 3 **Wood ND, Goaz PW.** Differential diagnosis of oral and maxillofacial region. 5<sup>th</sup> ed. St.Louis: The CV Mosby Company, 1997
- 4 **Hall JM, Weathers DR, Unni KK.** Ameloblastic carcinoma: an analysis of 14 cases. *Oral Surg Oral Med Oral Pathol Oral Radiol Endod* 2007; **103**: 799-807 [PMID: 17448710]
- 5 **Akrish S, Buchner A, Shoshani Y, Vered M, Dayan D.** Ameloblastic carcinoma: report of a new case, literature review, and comparison to ameloblastoma. *J Oral Maxillofac Surg* 2007; **65**: 777-783 [PMID: 17368379 DOI: 10.1016/j.joms.2005.11.116]
- 6 **Suomalainen A, Hietanen J, Robinson S, Peltola JS.** Ameloblastic carcinoma of the mandible resembling odontogenic cyst in a panoramic radiograph. *Oral Surg Oral Med Oral Pathol Oral Radiol Endod* 2006; **101**: 638-642 [PMID: 16632277]
- 7 **Lau SK, Tideman H, Wu PC.** Ameloblastic carcinoma of the jaws. A report of two cases. *Oral Surg Oral Med Oral Pathol Oral Radiol Endod* 1998; **85**: 78-81 [PMID: 9474619]

**P- Reviewers:** Abu El-Naaj I, Asaumi J **S- Editor:** Zhai HH  
**L- Editor:** Roemmele A **E- Editor:** Wu HL



# World Journal of *Clinical Cases*

*World J Clin Cases* 2014 March 16; 2(3): 52-85





### BRIEF ARTICLE

- 52 Retrospective chart review of skin cancer presence in the wide excisions  
*Yuan Y, Duff ML, Sammons DL, Wu S*

### CASE REPORT

- 57 Multilevel oblique corpectomies as an effective surgical option to treat cervical chordoma in a young girl  
*Delfini R, Marruzzo D, Tarantino R, Marotta N, Landi A*
- 62 Can a polymorphism in the thalassemia gene and a heterozygote *CFTR* mutation cause acute pancreatitis?  
*Löhr JM, Haas S*
- 67 Clinical and radiographic features of Hutchinson-Gilford progeria syndrome: A case report  
*Alves DB, Silva JM, Menezes TO, Cavaleiro RS, Tuji FM, Lopes MA, Zaia AA, Coletta RD*
- 72 Additional responsibility for physicians caring for cardiac patients: Insight from a case series  
*Ajmal M*
- 75 Homozygous factor V Leiden mutation in type IV Ehlers-Danlos patient  
*Refaat M, Hotaït M, Winston B*
- 78 Successful recanalization with multimodality endovascular interventional therapy in acute ischemic stroke  
*Jongsathapongpan A, Raumthanthong A, Muengtaweepongsa S*



**APPENDIX** I-V Instructions to authors

**ABOUT COVER** Editorial Board Member of *World Journal of Clinical Cases*, Ömür Dereci, DDS, Department of Oral and Maxillofacial Surgery, Faculty of Dentistry, Ankara University, 06560 Ankara, Turkey

**AIM AND SCOPE** *World Journal of Clinical Cases* (*World J Clin Cases*, *WJCC*, online ISSN 2307-8960, DOI: 10.12998) is a peer-reviewed open access academic journal that aims to guide clinical practice and improve diagnostic and therapeutic skills of clinicians.

The primary task of *WJCC* is to rapidly publish high-quality Autobiography, Case Report, Clinical Case Conference (Clinicopathological Conference), Clinical Management, Diagnostic Advances, Editorial, Field of Vision, Frontier, Medical Ethics, Original Articles, Clinical Practice, Meta-Analysis, Minireviews, Review, Therapeutics Advances, and Topic Highlight, in the fields of allergy, anesthesiology, cardiac medicine, clinical genetics, clinical neurology, critical care, dentistry, dermatology, emergency medicine, endocrinology, family medicine, gastroenterology and hepatology, geriatrics and gerontology, hematology, immunology, infectious diseases, internal medicine, obstetrics and gynecology, oncology, ophthalmology, orthopedics, otolaryngology, pathology, pediatrics, peripheral vascular disease, psychiatry, radiology, rehabilitation, respiratory medicine, rheumatology, surgery, toxicology, transplantation, and urology and nephrology.

**INDEXING/ABSTRACTING** *World Journal of Clinical Cases* is now indexed in PubMed Central, PubMed, Digital Object Identifier.

**FLYLEAF** I-V Editorial Board

**EDITORS FOR THIS ISSUE** Responsible Assistant Editor: *Xiang Li* Responsible Science Editor: *Xiu-Xia Song*  
Responsible Electronic Editor: *Huan-Liang Wu*  
Proofing Editor-in-Chief: *Lian-Sheng Ma*

**NAME OF JOURNAL**  
*World Journal of Clinical Cases*

**ISSN**  
ISSN 2307-8960 (online)

**LAUNCH DATE**  
April 16, 2013

**FREQUENCY**  
Monthly

**EDITORS-IN-CHIEF**  
**Giuseppe Di Lorenzo, MD, PhD, Professor**, Genitourinary Cancer Section and Rare-Cancer Center, University Federico II of Napoli, Via Sergio Pansini, 5 Ed. 1, 80131, Naples, Italy

**Jan Jacques Michiels, MD, PhD, Professor**, Primary Care, Medical Diagnostic Center Rijnmond Rotterdam, Bloodcoagulation, Internal and Vascular Medicine, Erasmus University Medical Center, Rotterdam, Goodheart Institute and Foundation, Erasmus Tower, Veenmos 13, 3069 AT, Erasmus City, Rotterdam, The Netherlands

**Sandro Vento, MD**, Department of Internal Medicine,

University of Botswana, Private Bag 00713, Gaborone, Botswana

**Shuhei Yoshida, MD, PhD**, Division of Gastroenterology, Beth Israel Deaconess Medical Center, Dana 509, Harvard Medical School, 330 Brookline Ave, Boston, MA 02215, United States

**EDITORIAL OFFICE**  
Jin-Lei Wang, Director  
Xiu-Xia Song, Vice Director  
*World Journal of Clinical Cases*  
Room 903, Building D, Ocean International Center, No. 62 Dongsihuan Zhonglu, Chaoyang District, Beijing 100025, China  
Telephone: +86-10-85381891  
Fax: +86-10-85381893  
E-mail: [bpgoffice@wjgnet.com](mailto:bpgoffice@wjgnet.com)  
<http://www.wjgnet.com>

**PUBLISHER**  
Baishideng Publishing Group Co., Limited  
Flat C, 23/F, Lucky Plaza,  
315-321 Lockhart Road, Wan Chai,  
Hong Kong, China  
Fax: +852-6555-7188  
Telephone: +852-3177-9906

E-mail: [bpgoffice@wjgnet.com](mailto:bpgoffice@wjgnet.com)  
<http://www.wjgnet.com>

**PUBLICATION DATE**  
March 16, 2014

**COPYRIGHT**  
© 2014 Baishideng Publishing Group Co., Limited. Articles published by this Open Access journal are distributed under the terms of the Creative Commons Attribution Non-commercial License, which permits use, distribution, and reproduction in any medium, provided the original work is properly cited, the use is non commercial and is otherwise in compliance with the license.

**SPECIAL STATEMENT**  
All articles published in this journal represent the viewpoints of the authors except where indicated otherwise.

**INSTRUCTIONS TO AUTHORS**  
Full instructions are available online at [http://www.wjgnet.com/2307-8960/g\\_info\\_20100722180909.htm](http://www.wjgnet.com/2307-8960/g_info_20100722180909.htm)

**ONLINE SUBMISSION**  
<http://www.wjgnet.com/esp/>

## Retrospective chart review of skin cancer presence in the wide excisions

Ye Yuan, Michelle L Duff, Dawn L Sammons, Shiyong Wu

Ye Yuan, Shiyong Wu, Edison Biotechnology Institute and Department of Chemistry and Biochemistry, Ohio University, Athens, OH 45701, United States

Michelle L Duff, Dawn L Sammons, Department of Specialty Medicine, Heritage College of Osteopathic Medicine, Ohio University, Athens, OH 45701, United States

**Author contributions:** Sammons DL initiated the project; Sammons DL and Wu S designed the report; Duff ML extracted the data; Yuan Y analyzed the data and organized the results; Wu S, Duff ML and Yuan Y wrote the paper.

**Supported by** NIH RO1CA086928 to Wu S; and Graduate assistantship to Yuan Y from the Department of Chemistry and Biochemistry, Ohio University

**Correspondence to:** Dawn L Sammons, DO, Assistant Professor, Department of Specialty Medicine, Heritage College of Osteopathic Medicine, Ohio University, Athens, 75 Hospital Drive, Athens OH, 45701, United States. [drdawn@oakviewderm.com](mailto:drdawn@oakviewderm.com)

Telephone: +1-740-5664621

Received: October 11, 2013 Revised: February 18, 2014

Accepted: February 20, 2014

Published online: March 16, 2014

### Abstract

**AIM:** To investigate cancer cell absence or presence in wide excision after biopsy of squamous cell carcinoma (SCC) and basal cell carcinoma (BCC) patients.

**METHODS:** 200 patients (100 BCC and 100 SCC) from the same dermatology clinic, who had positive margin upon biopsy, were selected from a computer generated randomized report. All selected patients had wide excision following biopsy. To determine the correlation of gender, age distribution and cancer absence, BCC and SCC cases were separated based on excision-cancer absent or present after wide excision.  $\chi^2$  tests, Fisher's exact tests were used to analyze the ratio of male to female between excision-cancer absent and excision-cancer present patients, while Mann-Whitney *U* test were used to compare the age distribution in the two groups. Statistical analyses were performed using SPSS version

16.0 for Windows.

**RESULTS:** Our retrospective chart review of the patients showed that cancer cells were absent in 49% of BCC patients ( $n = 100$ ) and 64% of SCC patients ( $n = 100$ ) who had previously had positive margins upon biopsy. Gender analysis showed the ratio of male to female (M/F) in the BCC arm was significantly higher compared with the SCC arm in those with excision-cancer absent (2.06 vs 0.66;  $P = 0.004$ ;  $\chi^2$  test). But M/F of excision-cancer absent and excision-cancer present in neither BCC nor SCC patients was statistically significant. Age adjustment showed no significant difference between excision-cancer absent and excision-cancer present in BCC and SCC patients. Nevertheless, in excision-cancer absent cases, the age distribution showed that the BCC patients were younger than SCC patients (average age 67 vs 74;  $P < 0.001$ ; Mann-Whitney *U* test). In addition, our data also indicated that in the patient group of 71-80 years old, there were more SCC patients who showed excision-cancer absence (67.6% vs 39.4%;  $P = 0.02$ ;  $\chi^2$  test).

**CONCLUSION:** Our study indicates that approximately 50% or more of BCC and SCC patients with positive margins found on biopsies did not have cancer cells present at the time of wide excisions.

© 2014 Baishideng Publishing Group Co., Limited. All rights reserved.

**Key words:** Biopsy; Histology; Positive margin; Skin cancer; Wide excision

**Core tip:** Wide excisions are performed for skin cancers when malignant cells extend to the margins of biopsy. It is expected that cancer cells will appear in the excised tissue at the time of wide excision. However, an analysis of wide excision tissue samples from 200 patients revealed that approximately 50% or more basal and squamous cell carcinoma patients with cancer cells that extended to the margins in biopsy did not have

cancer cells present on wide excision. This finding suggests that the wound caused by the biopsy itself may trigger a body response to eliminate cancer cells.

Yuan Y, Duff ML, Sammons DL, Wu S. Retrospective chart review of skin cancer presence in the wide excisions. *World J Clin Cases* 2014; 2(3): 52-56 Available from: URL: <http://www.wjgnet.com/2307-8960/full/v2/i3/52.htm> DOI: <http://dx.doi.org/10.12998/wjcc.v2.i3.52>

## INTRODUCTION

The incidence and mortality rates of skin cancer are increasing in the United States and many other countries<sup>[1]</sup>. Of these skin cancers basal cell carcinoma (BCC) is the most common type followed closely by squamous cell carcinoma (SCC)<sup>[2]</sup>. The incidence of BCC is 200/100000 in men and 100/100000 in women<sup>[3]</sup>. BCC incidence increases with age; the median age for diagnosis is 68 years old<sup>[4]</sup>. SCC incidence is 100/100000 in men and 50/100000 in women<sup>[3]</sup>. Clinically if skin cancer is suspected, a biopsy is taken. The biopsy shows a small sample of the lesion, which can be looked at microscopically by a pathologist. The pathology report will describe the type of cancer and if the cancer extends to the border (positive margin) or is completely excised (negative margin) in the tissue sample<sup>[5]</sup> (Figure 1). If the lesion is completely removed, no further surgery is needed. For lesions with a positive margin, a wide excision surgery is done to remove the remaining cancer. This wide excision is a common and essential way to treat skin cancer, and incomplete excision may lead to cancer recurrence<sup>[6-8]</sup>. Theoretically, all the tissue samples from wide excision should contain cancer cells. However, pathological analyses of tissue samples from wide excision in our clinic often only show evidence of scar with no cancer cells remaining. All lesions had photos to ensure the correct lesion was excised. This observation has not been reported. In this study, we systematically analyzed the cancer cells absence or presence in wide excision after biopsy by subtype as well as sex and age from 100 SCC and 100 BCC patients. Our results will provide guidance for future determination of potential mechanism that leads to the disappearance of cancer cells in surrounding tissues of biopsies.

## MATERIALS AND METHODS

### Patients' data extraction

Chart review of 200 patients (100 BCC and 100 SCC) was obtained from a single dermatology office. The patients were selected from a computer generated randomized report of those who had SCC and a separate list for those who had BCC. Only patients who had a positive margin at the time of biopsy were included. Patients were excluded if pathology was unavailable for either biopsy

**Table 1 Patients characteristics**

	BCC	SCC	Total patients
No. of cases	100	100	200
Sex			
Male	62	43	105
Female	38	57	95
Male/female	1.63	0.75	1.11 <sup>1</sup>
Median age (range)	69 (42-92)	77 (45-95)	73 (42-95) <sup>2</sup>
Biopsy margins positive	100	100	200
Excision-cancer absent	49	64	113 <sup>3</sup>

P value (BCC vs SCC): <sup>1</sup>P = 0.007; <sup>2</sup>P = 0.003; <sup>3</sup>P = 0.032. BCC: Basal cell carcinoma; SCC: Squamous cell carcinoma.

or wide excision. In cases where patients with more than one biopsy or wide excision, the first lesion from the list was chosen, this was the case unless there was no corresponding wide excision; or location of biopsy and wide excision did not match. There was no exclusion of patients who had SCC and BCC.

### Statistical analysis

In this chart review,  $\chi^2$  tests were used to compare the difference of gender distribution and excision-cancer absent percentage in assigned groups. When the sample size was less than 40, Fisher's exact tests were used instead. All the difference of age distribution was evaluated by Mann-Whitney U test.  $P < 0.05$  was considered as statistically significant. These statistical analyses were performed using SPSS version 16.0 for Windows.

## RESULTS

### Clinical characteristics

First, the characteristics of the selected patients were analyzed (Table 1). Among the 200 cases that were reviewed, including 100 BCC and 100 SCC patients, SCC was more common than BCC among female patients (57% vs 38%;  $P = 0.007$ ;  $\chi^2$  test) while BCC was more common than SCC among male patients (62% vs 43%;  $P = 0.007$ ;  $\chi^2$  test). Despite a similar age range, the average age of SCC patients were 8 years older than BCC patients (77 years vs 69 years old;  $P = 0.003$ ; Mann-Whitney U test). All skin cancer patients showed a positive margins upon biopsy. However, cancer cells were found to be absent in excised tissue of 49% of the BCC patients and 64% of the SCC patients. In addition, excision-cancer absent percentage in SCC patients was significantly greater than that in BCC patients (64% vs 49%;  $P = 0.032$ ;  $\chi^2$  test). Analyses of the excision-cancer absent in the different subtypes of BCC and SCC indicated that there was no statistic significant difference in percentage among the analyzed subtypes of BCC or SCC (Table 2).

### Gender distribution of excision-cancer absence with positive margins

To evaluate if cancer cells absence or presence after wide excision was associated with gender, BCC and

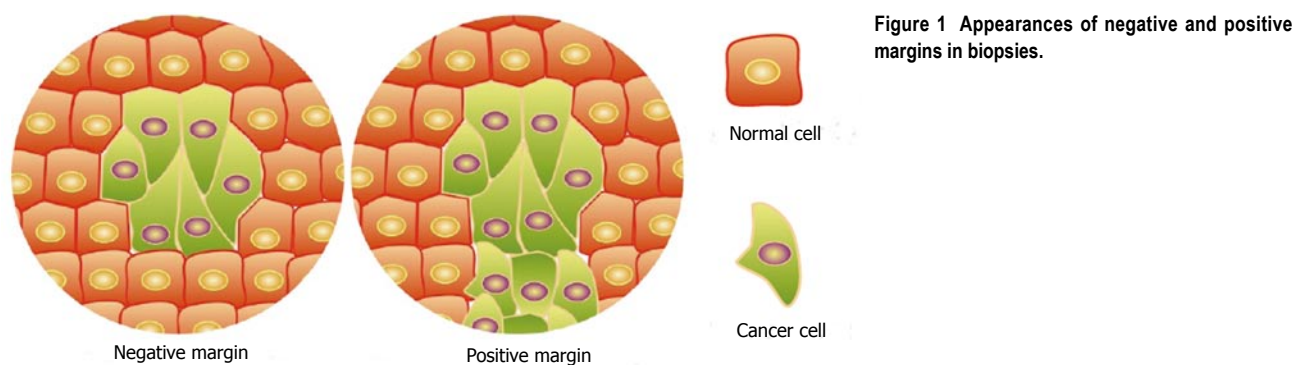


Figure 1 Appearances of negative and positive margins in biopsies.

Table 2 Skin cancer subtype distribution *n* (%)

Subtype	No. of patients	Excision-cancer absent
BCC		
Nodular	53	26 (49.1)
Infiltrative	11	6 (54.5)
Nodular and superficial	25	15 (60)
Nodular and infiltrative	10	2 (20)
Infiltrative and superficial	1	0 (0)
SCC		
<i>In situ</i>	45	26 (57.8)
Keratoacanthoma type	12	9 (75)
Moderately-differentiated	4	3 (75)
Well-differentiated	16	12 (75)
Invasive	12	6 (50)
Other types <sup>1</sup>	11	6 (54.5)

<sup>1</sup>Include following complex subtypes, intraepidermal epithelioma pattern, *in situ*-intraepidermal epithelioma pattern, *in situ* and invasive, *in situ*-well differentiated, moderately to poor differentiated, *in situ* acantholytic and focally invasive, *in situ* and focally superficial invasive, keratinizing well differentiated, and unknown types. BCC: Basal cell carcinoma; SCC: Squamous cell carcinoma.

SCC patients were grouped based on excision-cancer absence/presence and then the ratio of male to female was calculated respectively (Table 3). Despite the fact that a higher ratio of male to female was found in excision-cancer absent BCC patients than that in excision-cancer present BCC patients, the difference was not statistically significant (2.06 *vs* 1.32;  $P = 0.28$ ;  $\chi^2$  test). A close ratio of male to female SCC patients was observed in excision-cancer absent and present groups (0.66 *vs* 0.95;  $P = 0.382$ ;  $\chi^2$  test). However, in excision-cancer absent cases, the ratio of male to female in BCC was significantly higher compared with SCC (2.06 *vs* 0.66;  $P = 0.004$ ;  $\chi^2$  test).

#### Age distribution of excision-cancer absence with positive margins

To evaluate if the malignancy presence after excision was associated with age, BCC and SCC patients were grouped based on cancer presence/absence, and then the median and average ages for the patients in each group were calculated (Table 4). Our data indicated that while there was no statistically significant difference in ages for excision malignancy present and absent patients in both BCC ( $P = 0.191$ ) and SCC ( $P = 0.534$ ), the patients' ages of excision-cancer absent cases for SCC were 8 years older than that for BCC (74 years *vs* 67 years old;  $P < 0.001$ ; Mann-Whitney *U* test), which is similar to the difference

Table 3 Gender distribution between excision-cancer absent and excision-cancer present cases of basal cell carcinoma and squamous cell carcinoma *n* (%)

		M	F	Total	M/F	<i>P</i> value
BCC	Excision-cancer absent	33 (67.3)	16 (32.7)	49	2.06	0.280 <sup>1</sup>
	Excision-cancer present	29 (56.9)	22 (43.1)	51	1.32	
SCC	Excision-cancer absent	25 (39.7)	38 (60.3)	63	0.66	0.382 <sup>1</sup>
	Excision-cancer present	18 (48.6)	19 (51.4)	37	0.95	
Excision-cancer absent cases	BCC	33 (67.3)	16 (32.7)	49	2.06	0.004 <sup>2</sup>
	SCC	25 (39.7)	38 (60.3)	63	0.66	

*P* value: <sup>1</sup>In BCC or SCC cases, the percentage of male (female) patients in excision-cancer absent *vs* present groups; <sup>2</sup>In excision-cancer absent cases, the percentage of male (female) patients in BCC *vs* SCC. BCC: Basal cell carcinoma; SCC: Squamous cell carcinoma; M: Male; F: Female.

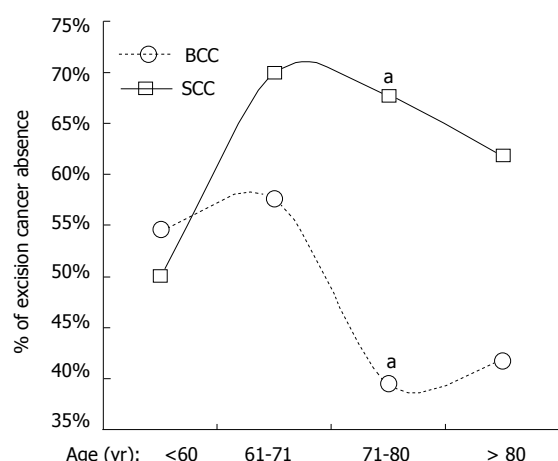
between average age of SCC and BCC patients (Table 2). Further evaluation of the percentage of excision-cancer absence in BCC and SCC based on age distributions (< 60, 61-70, 71-80 and > 80 years old) revealed that while the percentage of excision-cancer absence cases among the elderly SCC patients was increased, the percentage among the elderly BCC patients was decreased (Figure 2). Our data indicated that in the patient group of 71-80 years old, SCC showed significantly higher percentage compared with BCC (67.6% *vs* 39.4%;  $P = 0.02$ ;  $\chi^2$  test).

## DISCUSSION

While currently there are limited reports linking local immune response and cutaneous carcinoma regression after biopsy, it is noteworthy that the local immune cells might contribute to eliminating residual skin cancer cells. For instance, dendritic cells (DCs), the typical antigen-presenting immune cells which consist dermal DCs, Langerhans cells and plasmacytoid DCs, are abundant in both epidermal and dermal tissues and play central role in initiating immune response<sup>[9-11]</sup>.

Despite DCs being present in human carcinomas, the potential to initiate an immune response is largely diminished by tumor environment<sup>[12,13]</sup>. Tumors suppress the function of DCs significantly by exploiting different cytokines, including interleukin-6 (IL-6), macrophage colony-stimulating factor, IL-10 and IL-13<sup>[14-16]</sup>. It was reported that the number of Langerhans cells decreased in





**Figure 2** Age distribution and percentage of excision-cancer absence in basal cell carcinoma and squamous cell carcinoma. Basal cell carcinoma (BCC) and squamous cell carcinoma (SCC) cases were divided into four groups based on age, including cases younger than 60, 61-70, 71-80 and older than 80 years old. The percentage of excision-cancer absence in each group is shown as squares (SCC) and circles (BCC). <sup>a</sup> $P = 0.02$ , percentage of excision-cancer absence in BCC vs SCC in 71-80 years old group.

SCC, though the mechanism is not fully understood<sup>[17-19]</sup>. In addition, SCC-associated DCs have much lower potential to stimulate proliferation of T-cells compared with DCs derived from normal tissue<sup>[20]</sup>. In view of this tumor mediated suppression of DCs, stimulating their function becomes a promising way to fight against skin cancer, as a limited number of DCs are sufficient to induce an immune response<sup>[21,22]</sup>.

During the original biopsy of the SCC or BCC, a substantial part of the cancer tissue, as well as adjacent tumor-associated DCs and macrophages, were removed. This “tissue injury” would cause inflammation, accompanied with both innate and adaptive immune responses in the wound healing process<sup>[23-25]</sup>. Neutrophils, followed by monocytes, infiltrate the wound where monocytes would differentiate into DCs or macrophages. On the one hand, the immune cells which were either suppressed by the tumor or benefit the tumor growth were removed so that local immune suppression is relieved. Fresh healthy immune cells would then enter the wound area to “clean” the environment. Macrophages are the most abundant cells before fibroblast proliferation, which induced cancer cell apoptosis by producing nitric oxide or inducing nitric oxide production in tumor cells<sup>[26-30]</sup>. It is possible that the residual cancer cells were killed by these immune responses during the initial wound healing, leading to excision-cancer absence. Further research is needed to understand the underlying mechanism.

In a conclusion, wide excisions from nearly 50% or more BCC and SCC patients with positive margins at biopsy appeared to be absent of cancer cells. The excision-cancer absence is more frequently observed in SCC than BCC patients. No significant correlation between gender and cancer absence is found. However, while the percentage of excision-cancer absence was increased in elder

**Table 4** Age distribution between excision-cancer absent and excision-cancer present cases of basal cell carcinoma and squamous cell carcinoma

		Median age (range), yr	Average age, yr	P Value
BCC	Excision-cancer absent	66 (45-92)	67	0.191 <sup>1</sup>
	Excision-cancer present	72 (42-90)	70	
SCC	Excision-cancer absent	76 (48-95)	74	0.534 <sup>1</sup>
	Excision-cancer present	78 (45-91)	75	
Excision-cancer absent	BCC	66 (45-92)	67	< 0.001 <sup>2</sup>
	SCC	76 (48-95)	74	

P value: <sup>1</sup>In BCC or SCC cases, age distribution of excision-cancer absent vs present cases; <sup>2</sup>In excision-cancer absent cases, age distribution of BCC vs SCC. BCC: Basal cell carcinoma; SCC: Squamous cell carcinoma.

SCC patients, it was decreased in elder BCC patients. These findings might provide evidence for a study on the specific mechanism of cancer cell absence resulting from a biopsy induced immune response.

## ACKNOWLEDGMENTS

The authors would like to thank Mr. Rui Zhang (Nanjing University) for his assistance in statistic analysis.

## COMMENTS

### Background

When examining patients for suspected cancer, biopsies are performed to confirm that the lesion is in fact cancer, which type of cancer, as well as to determine if the cancer is confined to the biopsy or extends to the margins (positive margins). For biopsies which show positive margins, wide excision will be performed. It is expected that cancer cells will appear in the excised tissues of wide excisions. However, clinically this is not always the case.

### Research frontiers

As the classic treatment for skin cancer, the wide excision is necessary after the positive margin is confirmed in biopsy. Biopsy is indispensable to define the risk factors of skin cancer. The research hotspot in this field is how to determine the excision margins of different types of skin cancer based on result of biopsy.

### Innovations and breakthroughs

This retrospective chart review provided evidences that 49% basal cell carcinoma (BCC) and 64% squamous cell carcinoma (SCC) patients did not have cancer cells left in the original location where the positive margin was reported in biopsy. Although the correlation between excision-cancer absence and gender or age distribution was excluded in both SCC and BCC patients, the analysis revealed that in excision-cancer absent cases, there were more male patients in BCC than that in SCC while SCC patients were older than BCC patients.

### Applications

The data provided in this study suggests a potential role of immune response caused by biopsy in removing residual cancer cells. The high percentage of excision-cancer absence might cushion the SCC and BCC patients against the fear of biopsy and promote compliance of them with biopsy demanded by dermatologists.

### Terminology

Excision-cancer present SCC or BCC patient means that cancer cells were found in the widely excised tissue which contained positive margin which had been reported previously in biopsy. Excision-cancer absent SCC or BCC means no cancer cells were found in wide excision containing previously defined positive margin.

### Peer review

The work is well written and focuses on an interesting aspect of skin cancer surgery.

## REFERENCES

- 1 **Marks R.** An overview of skin cancers. Incidence and causation. *Cancer* 1995; **75**: 607-612 [PMID: 7804986]
- 2 **Dubas LE, Ingraffea A.** Nonmelanoma skin cancer. *Facial Plast Surg Clin North Am* 2013; **21**: 43-53 [PMID: 23369588 DOI: 10.1016/j.fsc.2012.10.003]
- 3 **Sterry W, Paus R, Burgdorf W.** Dermatology (Thieme Clinical Companions). 1 ed. New York, NY: Thieme, 2006: 419-433
- 4 **Bolognia JL, Jorizzo JL, Schaffer JV, Callen JP, Cerroni L, Heymann WR, Hruza GJ.** Dermatology. 3 ed. Philadelphia, PA: Saunders, 2012: Chapter 108
- 5 **Weinstein MC, Brodell RT, Bordeaux J, Honda K.** The art and science of surgical margins for the dermatopathologist. *Am J Dermatopathol* 2012; **34**: 737-745 [PMID: 23000878 DOI: 10.1097/DAD.0b013e31823347cb]
- 6 **Tan PY, Ek E, Su S, Giorlando F, Dieu T.** Incomplete excision of squamous cell carcinoma of the skin: a prospective observational study. *Plast Reconstr Surg* 2007; **120**: 910-916 [PMID: 17805118 DOI: 10.1097/01.prs.0000277655.89728.9f]
- 7 **Pugliano-Mauro M, Goldman G.** Mohs surgery is effective for high-risk cutaneous squamous cell carcinoma. *Dermatol Surg* 2010; **36**: 1544-1553 [PMID: 21053415 DOI: 10.1111/j.1524-4725.2010.01576.x]
- 8 **Leibovitch I, Huilgol SC, Richards S, Paver R, Selva D.** Scalp tumors treated with Mohs micrographic surgery: clinical features and surgical outcome. *Dermatol Surg* 2006; **32**: 1369-1374 [PMID: 17083590 DOI: 10.1111/j.1524-4725.2006.32308.x]
- 9 **Valladeau J, Saeland S.** Cutaneous dendritic cells. *Semin Immunol* 2005; **17**: 273-283 [PMID: 15953735 DOI: 10.1016/j.smim.2005.05.009]
- 10 **Zaba LC, Krueger JG, Lowes MA.** Resident and "inflammatory" dendritic cells in human skin. *J Invest Dermatol* 2009; **129**: 302-308 [PMID: 18685620 DOI: 10.1038/jid.2008.225]
- 11 **Hunger RE, Sieling PA, Ochoa MT, Sugaya M, Burdick AE, Rea TH, Brennan PJ, Belisle JT, Blauvelt A, Porcelli SA, Modlin RL.** Langerhans cells utilize CD1a and langerin to efficiently present nonpeptide antigens to T cells. *J Clin Invest* 2004; **113**: 701-708 [PMID: 14991068 DOI: 10.1172/JCI19655]
- 12 **Gabrilovich D.** Mechanisms and functional significance of tumour-induced dendritic-cell defects. *Nat Rev Immunol* 2004; **4**: 941-952 [PMID: 15573129 DOI: 10.1038/nri1498]
- 13 **Vicari AP, Caux C, Trinchieri G.** Tumour escape from immune surveillance through dendritic cell inactivation. *Semin Cancer Biol* 2002; **12**: 33-42 [PMID: 11926410 DOI: 10.1006/scbi.2001.0400]
- 14 **Chomarat P, Banchereau J, Davoust J, Palucka AK.** IL-6 switches the differentiation of monocytes from dendritic cells to macrophages. *Nat Immunol* 2000; **1**: 510-514 [PMID: 11101873 DOI: 10.1038/82763]
- 15 **Steinbrink K, Wölfl M, Jonuleit H, Knop J, Enk AH.** Induction of tolerance by IL-10-treated dendritic cells. *J Immunol* 1997; **159**: 4772-4780 [PMID: 9366401]
- 16 **Aspord C, Pedroza-Gonzalez A, Gallegos M, Tindle S, Burton EC, Su D, Marches F, Banchereau J, Palucka AK.** Breast cancer instructs dendritic cells to prime interleukin 13-secreting CD4<sup>+</sup> T cells that facilitate tumor development. *J Exp Med* 2007; **204**: 1037-1047 [PMID: 17438063 DOI: 10.1084/jem.20061120]
- 17 **Galan A, Ko CJ.** Langerhans cells in squamous cell carcinoma vs. pseudoepitheliomatous hyperplasia of the skin. *J Cutan Pathol* 2007; **34**: 950-952 [PMID: 18001421 DOI: 10.1111/j.1600-0560.2007.00741.x]
- 18 **Gibson GE, O'Grady A, Kay EW, Leader M, Murphy GM.** Langerhans cells in benign, premalignant and malignant skin lesions of renal transplant recipients and the effect of retinoid therapy. *J Eur Acad Dermatol Venereol* 1998; **10**: 130-136 [PMID: 9553909]
- 19 **Gatter KC, Morris HB, Roach B, Mortimer P, Fleming KA, Mason DY.** Langerhans' cells and T cells in human skin tumours: an immunohistological study. *Histopathology* 1984; **8**: 229-244 [PMID: 6233213]
- 20 **Bluth MJ, Zaba LC, Moussai D, Suárez-Fariñas M, Kaporis H, Fan L, Pierson KC, White TR, Pitts-Kiefer A, Fuentes-Duculan J, Guttman-Yassky E, Krueger JG, Lowes MA, Carucci JA.** Myeloid dendritic cells from human cutaneous squamous cell carcinoma are poor stimulators of T-cell proliferation. *J Invest Dermatol* 2009; **129**: 2451-2462 [PMID: 19387481 DOI: 10.1038/jid.2009.96]
- 21 **Yanofsky VR, Mitsui H, Felsen D, Carucci JA.** Understanding dendritic cells and their role in cutaneous carcinoma and cancer immunotherapy. *Clin Dev Immunol* 2013; **2013**: 624123 [PMID: 23606870 DOI: 10.1155/2013/624123]
- 22 **Figdor CG, de Vries IJ, Lesterhuis WJ, Melief CJ.** Dendritic cell immunotherapy: mapping the way. *Nat Med* 2004; **10**: 475-480 [PMID: 15122249 DOI: 10.1038/nm1039]
- 23 **Tsirogianni AK, Moutsopoulos NM, Moutsopoulos HM.** Wound healing: immunological aspects. *Injury* 2006; **37** Suppl 1: S5-S12 [PMID: 16616753 DOI: 10.1016/j.injury.2006.02.035]
- 24 **DiPietro LA.** Wound healing: the role of the macrophage and other immune cells. *Shock* 1995; **4**: 233-240 [PMID: 8564549]
- 25 **Park JE, Barbul A.** Understanding the role of immune regulation in wound healing. *Am J Surg* 2004; **187**: 11S-16S [PMID: 15147986 DOI: 10.1016/S0002-9610(03)00296-4]
- 26 **Rieder J, Jahnke R, Schloesser M, Seibel M, Czechowski M, Marth C, Hoffmann G.** Nitric oxide-dependent apoptosis in ovarian carcinoma cell lines. *Gynecol Oncol* 2001; **82**: 172-176 [PMID: 11426981 DOI: 10.1006/gyno.2001.6242]
- 27 **Binder C, Schulz M, Hiddemann W, Oellerich M.** Induction of inducible nitric oxide synthase is an essential part of tumor necrosis factor-alpha-induced apoptosis in MCF-7 and other epithelial tumor cells. *Lab Invest* 1999; **79**: 1703-1712 [PMID: 10616218]
- 28 **Reveneau S, Arnould L, Jolimoy G, Hilpert S, Lejeune P, Saint-Giorgio V, Belichard C, Jeannin JF.** Nitric oxide synthase in human breast cancer is associated with tumor grade, proliferation rate, and expression of progesterone receptors. *Lab Invest* 1999; **79**: 1215-1225 [PMID: 10532585]
- 29 **Binder C, Schulz M, Hiddemann W, Oellerich M.** Caspase-activation and induction of inducible nitric oxide-synthase during TNF alpha-triggered apoptosis. *Anticancer Res* 1999; **19**: 1715-1720 [PMID: 10470105]
- 30 **Kwak JY, Han MK, Choi KS, Park IH, Park SY, Sohn MH, Kim UH, McGregor JR, Samlowski WE, Yim CY.** Cytokines secreted by lymphokine-activated killer cells induce endogenous nitric oxide synthesis and apoptosis in DLD-1 colon cancer cells. *Cell Immunol* 2000; **203**: 84-94 [PMID: 11006006 DOI: 10.1006/cimm.2000.1682]

P- Reviewers: LadoyanniE, Negosanti L S- Editor: Wen LL

L- Editor: A E- Editor: Wu HL



## Multilevel oblique corpectomies as an effective surgical option to treat cervical chordoma in a young girl

Roberto Delfini, Daniele Marruzzo, Roberto Tarantino, Nicola Marotta, Alessandro Landi

Roberto Delfini, Daniele Marruzzo, Roberto Tarantino, Nicola Marotta, Alessandro Landi, Department of Neurology and Psychiatry, Division of Neurosurgery, University of Rome "Sapienza", 00168 Rome, Italy

Author contributions: Delfini R, Landi A, Marotta N, Marruzzo D and Tarantino R performed the surgery; Marruzzo D and Landi A contributed to the conception and design, acquisition, analysis and interpretation of data; Delfini R and Landi A drafted the article and revised it critically for important intellectual content; Delfini R and Landi A approved the final version to be published. Correspondence to: Alessandro Landi, MD, PhD, Department of Neurology and Psychiatry, Division of Neurosurgery, University of Rome Sapienza, Viale del Policlinico 155, 00168 Rome, Italy. [dott.alessandro.landi@gmail.com](mailto:dott.alessandro.landi@gmail.com)

Telephone: +39-06-49979105 Fax: +39-06-49979105

Received: October 30, 2013 Revised: January 2, 2014

Accepted: January 17, 2014

Published online: March 16, 2014

**Core tip:** In young patients, chordomas are rare and unpredictable. Despite this, the treatment of choice remains the total resection, as much as possible, followed by proton beam radiation. When there is a precarotid and retrocarotid extension, the removal by a multilevel oblique corpectomy seems to be a feasible and safe surgical technique.

Delfini R, Marruzzo D, Tarantino R, Marotta N, Landi A. Multilevel oblique corpectomies as an effective surgical option to treat cervical chordoma in a young girl. *World J Clin Cases* 2014; 2(3): 57-61 Available from: URL: <http://www.wjgnet.com/2307-8960/full/v2/i3/57.htm> DOI: <http://dx.doi.org/10.12998/wjcc.v2.i3.57>

### Abstract

Chordomas are malignant tumors arising from notochordal remnants. They are the most frequent tumors of the spine after plasmacytomas. Only 6% of chordomas are localized to the cervical level. In young patients, chordomas are rare and unpredictable. Despite this, the treatment of choice remains the total resection, as much as possible, followed by proton beam radiation. This case was managed using a precarotid and retrocarotid approach at the same time. The tumor was completely resected with the edges free from disease. The cervical spine was stabilized with an anterior plating C2-C4. Eighteen months after surgery the patient is still free from illness. Multilevel oblique corpectomies are an available and safe option for the treatment of upper cervical chordomas.

© 2014 Baishideng Publishing Group Co., Limited. All rights reserved.

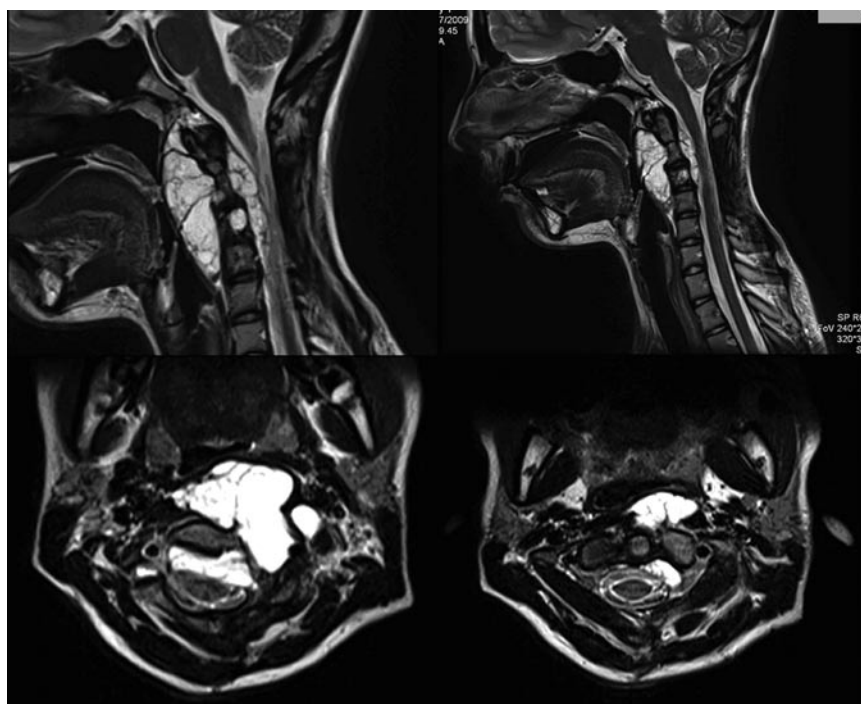
**Key words:** Cervical chordoma; Multilevel oblique corpectomy; Surgery; RXT; Retrocarotid approach

### INTRODUCTION

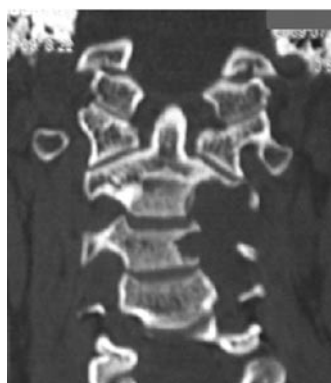Chordomas are malignant tumors arising from notochordal remnants and are the most frequent tumors of the spine after plasmacytomas. Only 6% of chordomas are localized at cervical level<sup>[1,2]</sup>. The treatment of choice is total resection, or removing as much as possible of the tumor, followed by proton beam radiation. As emphasized in previous studies, total resection and, in particular, *en bloc* removal are not always possible, especially in the upper cervical localization and when the tumor englobes the epidural space (as in our case). This is a consequence both of the fact that the cervical chordoma infiltrates the nearby structures and that the margins of the total resection include unresectable structures. In young patients, chordomas are rare and unpredictable. We describe a rare case of an extensive cervical chordoma in a 14-year-old girl treated simultaneously by a precarotid and retrocarotid approach.

### CASE REPORT

A 14-year-old girl was referred to our institution with cervical pain, dysphagia, hyperreflexia and weakness of



**Figure 1** Sagittal and axial T2-weighted magnetic resonance imaging showed diffuse increased signal of a lesion of C2-C3-C4 with important retropharyngeal portion.



**Figure 2** Preoperative coronal computed tomography of the cervical spine demonstrating an osteolytic process involving vertebral body of C2, C3 and C4.

the four limbs for 8 mo. The preoperative magnetic resonance imaging (MRI) showed a lesion of C2-C3-C4 with marked retropharyngeal and epidural space involvement (Figure 1). The tumor extended from the C1 anterior tuberculum as far as the C5 superior plate. Since biopsy had been performed in another institute *via* C2-C3-C4 interhemilaminectomy, the definitive result of the biopsy was not available.

A pre-operative CT showed erosion of the C2-C3-C4 vertebral bodies (Figure 2). An angio-MRI with gadolinium administration pointed out that the left vertebral artery (VA) was encapsulated and displaced without reduction of the vessel diameter. The tumor showed a spare contrast enhancement with gadolinium and in DWI was hyperintense in DWI sequences. Relating to the clinical and radiological features, there were two diagnostic hypotheses, either an epidermoid cyst or chordoma. The tumor was classified IB according to the Enneking clas-

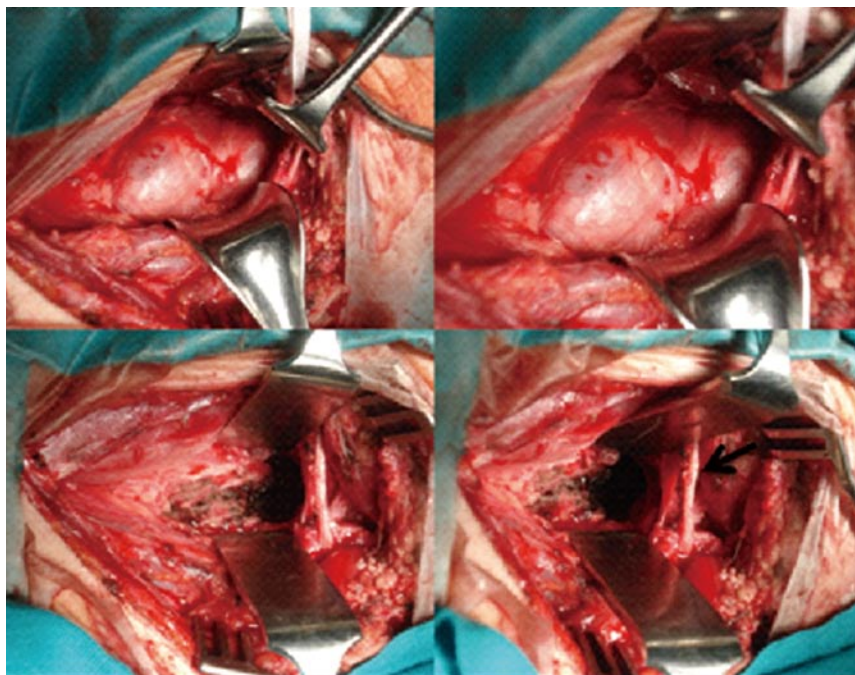
sification<sup>[3]</sup>. It was distributed to layers A-F and sectors 4-7 according to the Weinstein Boriani Biagini Classification<sup>[4]</sup>.

### **Surgical procedure**

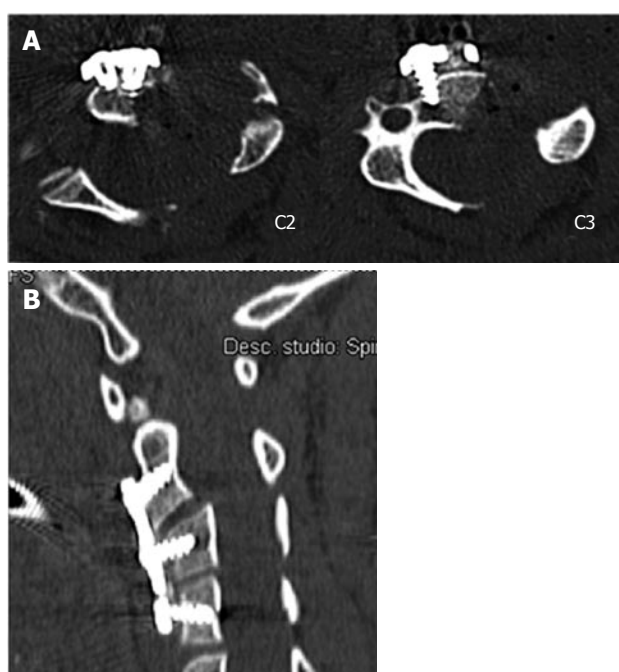
Surgical strategy consisted of a precarotid and retrocarotid approach during a single operation. The patient was positioned in the supine position with her head rotated 30° to the right. A presternocleidomastoid longitudinal skin incision was performed starting from left mastoid process. Firstly, the precarotid approach was performed through which the retropharyngeal portion was removed (Figure 3). Infiltrated bone, the portion around VA and the epidural space component were removed *via* the second approach, *via* multilevel oblique corpectomies. During surgery we employed ecodoppler monitoring to control the vertebral artery, as well as the operative microscope and the cavitron ultrasonic surgical aspirator, to remove the epidural component of the tumor. The retropharyngeal component was removed by an *en bloc* excision, while an intralesional excision was performed to remove the residual tumor. The tumor was completely resected together with the disease-free borders. A C2-C3 and C3-C4 discectomy with apposition of synthetic bone was performed to improve and speed up fusion and the cervical spine was stabilized by means of C2-C4 anterior plating.

A post-operative computed tomography (CT)-scan confirmed the correct position of the plate and the screws (Figure 4). The second day after surgery, the patient was free of any neurological deficit and was able to stand up and started to walk. The patient was discharged from hospital the seventh day after surgery. Twenty days after surgery, a post-operative MRI showed total resection of the tumor. A Shantz cervical collar was fitted for 45 d. Forty days after surgery, the patient received postoperative





**Figure 3** Intraoperative photos shows before (above) and after (below) *en bloc* excision of the retropharyngeal portion. The arrow points to the hypoglossal nerve.



**Figure 4** Postoperative axial (A) and sagittal (B) reconstructed computed tomography scans of the cervical spine shows the oblique corpectomies and a fixation with an anterior plating C2-C4.

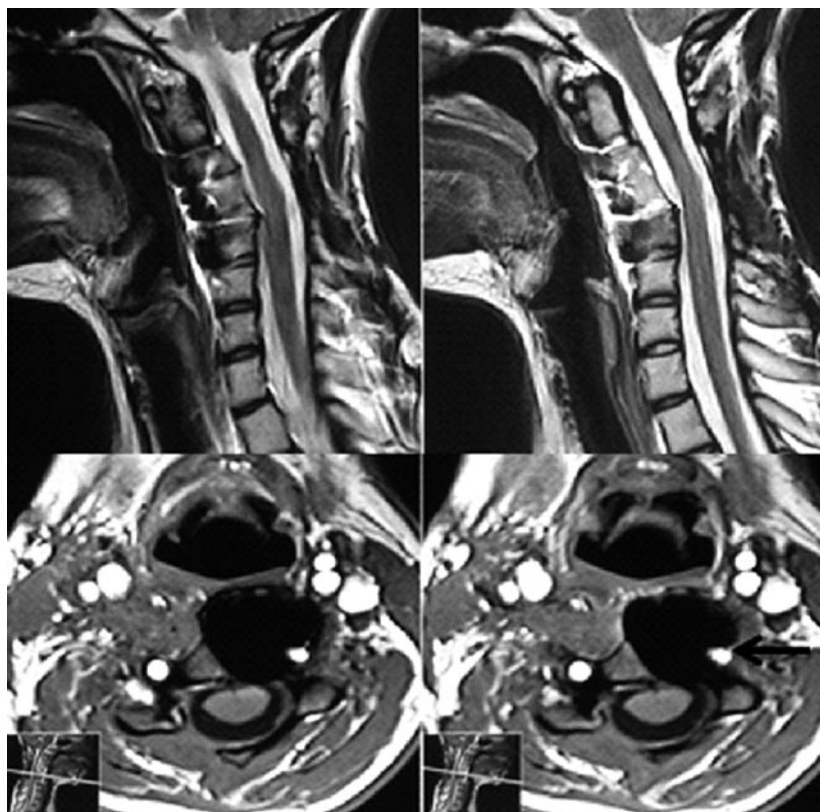
proton beam radiation therapy. A clinical and radiological control, consisting of cervical MRI with gadolinium, was performed every 6 mo. Twenty days after surgery, the patient returned to school and at present leads a normal life. Fusion was documented at 40 d. No recurrence or metastasis was observed 48 mo after the operation (Figure 5).

## DISCUSSION

Chordoma is a low-grade malignant tumor which is

rare (incidence of 0.51 cases/million), and is generally slow-growing, radioresistant and has a high tendency of recurrence<sup>[4]</sup>. Chordomas arise from remnants of the notochord, especially at the two end portions. 32% of chordomas arise from the clivus, 33% from the spinal cord, 29% from the sacrococcygeal region and just 6% from the cervical spine<sup>[1]</sup>. The treatment of choice is *en bloc* total resection followed by radiation therapy. The chordoma is sensitive to a high dose of “standard” radiation. However, the Bragg peak effect of a proton beam is useful for delivering a high radiation dose without damaging the tissue around the tumor and the spinal cord<sup>[1,5]</sup>. Total resection and, above all, *en bloc* removal are not always possible, especially in the upper cervical localization and when the tumor englobes the epidural space (as in our case). This is a consequence of the fact that the cervical chordoma infiltrates the nearby structures; moreover, the margins of the total resection include non-resectable structures like the vertebral artery. However, as pointed out by Boriani *et al*<sup>[6]</sup>, “*en bloc* removal of a bone tumor is possible for a tumor arising in the scapula (scapulectomy) and tibia (above knee amputation), but it is absolutely impossible for a spinal tumor. In this sense, even if the spinal cord is sectioned above and below, the epidural space represents a compartment extending from the skull to the coccyx. A trial of aggressive chemotherapy is warranted in patients with metastatic chordomas. In the literature<sup>[7-9]</sup>, two protocols were primarily used, consisting of ifosfamide or imatinib mesylate. Several approaches for treating upper cervical chordoma have been described in the literature: the anterior precarotid cervical approach (bilateral or not); the anterolateral retrocarotid approach; the transoral approach<sup>[10]</sup>; and anterior fixation or anterior and posterior fixation<sup>[11]</sup>.”

In the case described here, an anterior precarotid and an anterolateral retrocarotid (presteronocleidomastoid) ap-



**Figure 5** T2 (above) and T1 with gadolinium contrast (below) magnetic resonance imaging shows total resection of the tumor. The arrow underlines the left vertebral artery.

proach were performed at the same time. The advantages of this technique were good control of the left vertebral artery, multilevel oblique corpectomies, removal of the epidural space component of the chordoma and the possibility of anterior plating. It was impossible to perform an *en bloc* excision for the epidural space component because the tumor enclosed the left VA<sup>[1]</sup>. The procedure that we performed avoided binding of the VA and injuring the cervical roots, with a better outcome in comparison to some recent works<sup>[10,12]</sup>. Moreover, only anterior fixation was necessary because we performed multilevel oblique corpectomies, thus sparing the posterior structures of the cervical spine. This procedure made it possible to avoid occipitocervical fixation in a 14-year-old girl and the consequent limitations in movement.

In our opinion, a more aggressive strategy (multiple spondylectomy), which has a high morbidity, is justified for the treatment of cervical chordoma because chordomas are tumors whose biological behavior is difficult to predict. Despite this, the most recent publications<sup>[1,10-19]</sup> have shown that there are no important differences between patients operated on using an aggressive strategy (spondylectomy) and those submitted to corpectomies. So in our opinion, multilevel oblique corpectomies seem to be a feasible and safe surgical technique to treat a cervical chordoma.

## COMMENTS

### Case characteristics

A 14-year-old girl was referred to our institution with cervical pain, dysphagia, hyperreflexia and weakness of the four limbs for 8 mo.

### Imaging diagnosis

The preoperative magnetic resonance imaging showed a lesion of C2-C3-C4 with marked retropharyngeal and epidural space involvement.

### Treatment

Surgical strategy consisted of a precarotid and retrocarotid approach during a single operation.

### Experiences and lessons

Multilevel oblique corpectomies seems to be a feasible and safe surgical technique to treat a cervical chordoma.

### Peer review

This is well written case report presenting a rare condition which is explained well.

## REFERENCES

- 1 **Barrenechea JJ**, Perin NI, Triana A, Lesser J, Costantino P, Sen C. Surgical management of chordomas of the cervical spine. *J Neurosurg Spine* 2007; **6**: 398-406 [PMID: 17542504 DOI: 10.3171/spi.2007.6.5.398]
- 2 **Currier BL**, Papagelopoulos PJ, Krauss WE, Unni KK, Yaszemski MJ. Total en bloc spondylectomy of C5 vertebra for chordoma. *Spine (Phila Pa 1976)* 2007; **32**: E294-E299 [PMID: 17450062 DOI: 10.1097/01.brs.0000261411.31563.37]
- 3 **Enneking WF**, Spanier SS, Goodman MA. A system for the surgical staging of musculoskeletal sarcoma. *Clin Orthop Relat Res* 1980; (153): 106-120 [PMID: 7449206]
- 4 **Greenberg MS**. Handbook of Neurosurgery. New York: Thieme Medical Publishers, 2006
- 5 **Noël G**, Feuvret L, Ferrand R, Boissier G, Mazeron JJ, Habrand JL. Radiotherapeutic factors in the management of cervical-basal chordomas and chondrosarcomas. *Neurosurgery* 2004; **55**: 1252-1260; discussion 1260-1262 [PMID: 15574207]
- 6 **Boriani S**, Weinstein JN, Biagini R. Primary bone tumors of the spine. Terminology and surgical staging. *Spine (Phila Pa 1976)* 1997; **22**: 1036-1044 [PMID: 9152458 DOI: 10.1097/00007632-199705010-00020]
- 7 **Chambers PW**, Schwinn CP. Chordoma. A clinicopathologic

- study of metastasis. *Am J Clin Pathol* 1979; **72**: 765-776 [PMID: 389031]
- 8 **Fleming GF**, Heimann PS, Stephens JK, Simon MA, Ferguson MK, Benjamin RS, Samuels BL. Dedifferentiated chordoma. Response to aggressive chemotherapy in two cases. *Cancer* 1993; **72**: 714-718 [PMID: 8334623 DOI: 10.1002/1097-0142(19930801)72]
- 9 **Casali PG**, Stacchiotti S, Sangalli C, Olmi P, Gronchi A. Chordoma. *Curr Opin Oncol* 2007; **19**: 367-370 [PMID: 17545801]
- 10 **Jiang L**, Liu ZJ, Liu XG, Ma QJ, Wei F, Lv Y, Dang GT. Upper cervical spine chordoma of C2-C3. *Eur Spine J* 2009; **18**: 293-298; discussion 298-300 [PMID: 19221808 DOI: 10.1007/s00586-009-0907-y]
- 11 **Leitner Y**, Shabat S, Boriani L, Boriani S. En bloc resection of a C4 chordoma: surgical technique. *Eur Spine J* 2007; **16**: 2238-2242 [PMID: 17713796 DOI: 10.1007/s00586-007-0468-x]
- 12 **Suchomel P**, Buchvald P, Barsa P, Froehlich R, Choutka O, Krejzar Z, Sourkova P, Endrych L, Dzan L. Single-stage total C-2 intralesional spondylectomy for chordoma with three-column reconstruction. Technical note. *J Neurosurg Spine* 2007; **6**: 611-618 [PMID: 17561755 DOI: 10.3171/spi.2007.6.6.17]
- 13 **Fujita T**, Kawahara N, Matsumoto T, Tomita K. Chordoma in the cervical spine managed with en bloc excision. *Spine (Phila Pa 1976)* 1999; **24**: 1848-1851 [PMID: 10488517 DOI: 10.1097/00007632-199909010-00016]
- 14 **George B**, Zerah M, Lot G, Hurth M. Oblique transcorporeal approach to anteriorly located lesions in the cervical spinal canal. *Acta Neurochir (Wien)* 1993; **121**: 187-190 [PMID: 8512017 DOI: 10.1007/BF01809273]
- 15 **Chibbaro S**, Mirone G, Bresson D, George B. Cervical spine lateral approach for myeloradiculopathy: technique and pitfalls. *Surg Neurol* 2009; **72**: 318-324; discussion 324 [PMID: 19608245 DOI: 10.1016/j.surneu.2009.04.026]
- 16 **Lim JJ**, Kim SH, Cho KH, Yoon DH, Kim SH. Chordomas involving multiple neuraxial bones. *J Korean Neurosurg Soc* 2009; **45**: 35-38 [PMID: 19242569 DOI: 10.3340/jkns.2009.45.1.35]
- 17 **Bruneau M**, Cornelius JF, George B. Microsurgical cervical nerve root decompression by anterolateral approach. *Neurosurgery* 2006; **58**: ONS108-ONS13; discussion ONS108-ONS13 [PMID: 16543867 DOI: 10.1227/01.NEU.0000193521.98836.C5]
- 18 **Bruneau M**, Cornelius JF, George B. Multilevel oblique corpectomies: surgical indications and technique. *Neurosurgery* 2007; **61**: 106-112; discussion 112 [PMID: 17876240]
- 19 **Kelley SP**, Ashford RU, Rao AS, Dickson RA. Primary bone tumours of the spine: a 42-year survey from the Leeds Regional Bone Tumour Registry. *Eur Spine J* 2007; **16**: 405-409 [PMID: 16865376 DOI: 10.1007/s00586-006-0188-7]

**P- Reviewers:** Dereci O, Huang JP, Maharaj D, Muluk NB, Shipman A  
**S- Editor:** Song XX **L- Editor:** Roemmele A **E- Editor:** Wu HL





## Can a polymorphism in the thalassemia gene and a heterozygote *CFTR* mutation cause acute pancreatitis?

J-Matthias Löhr, Stephan Haas

J-Matthias Löhr, Stephan Haas, Gastrocentrum, Karolinska Institutet and University Hospital, SE-141 86 Stockholm, Sweden  
J-Matthias Löhr, Stephan Haas, Division of Molecular Gastroenterology, Department of Medicine II, Medical Faculty Mannheim, University of Heidelberg, 69117 Heidelberg, Germany

Author contributions: Löhr JM and Haas S contributed to this manuscript.

Correspondence to: J-Matthias Löhr, MD, Professor of Gastroenterology and Hepatology, Gastrocentrum, Karolinska Institutet and University Hospital, CLINTEC, K53, SE-141 86 Stockholm, Sweden. [matthias.lohr@ki.se](mailto:matthias.lohr@ki.se)

Telephone: +46-8-58582431 Fax: +46-8-58582340

Received: November 11, 2013 Revised: December 10, 2013

Accepted: January 15, 2014

Published online: March 16, 2014

conductance regulator; Hereditary persistence of fetal hemoglobin

**Core tip:** This is a discussion case with two genetic alterations, one in a pancreatitis-related gene and one in an unrelated gene that might influence the oxygenation in the pancreas.

Löhr JM, Haas S. Can a polymorphism in the thalassemia gene and a heterozygote *CFTR* mutation cause acute pancreatitis? *World J Clin Cases* 2014; 2(3): 62-66 Available from: URL: <http://www.wjgnet.com/2307-8960/full/v2/i3/62.htm> DOI: <http://dx.doi.org/10.12998/wjcc.v2.i3.62>

### Abstract

The case of a 32-year-old black woman of African descent who suffered from repeated episodes of acute pancreatitis, initially triggered when flying on airplanes, is reported. She did not drink alcohol or smoke. Genetic analysis was negative for cationic trypsinogen, serine protease inhibitor Kazal type 1 and chymotrypsin C. However, hemoglobin F was elevated. Sequencing of the thalassemia gene revealed a novel alteration in the 5' region indicative of a functional abnormality of the molecule. Sequencing the cystic fibrosis transmembrane conductance regulator (*CFTR*) gene revealed a heterozygote sequence variant. The combination of a hemoglobin gene mutation known for thalassemia in conjunction with the hitherto undescribed *CFTR* mutation is suggested to pave the road for initial and repetitive pancreatitis attacks. This will be discussed.

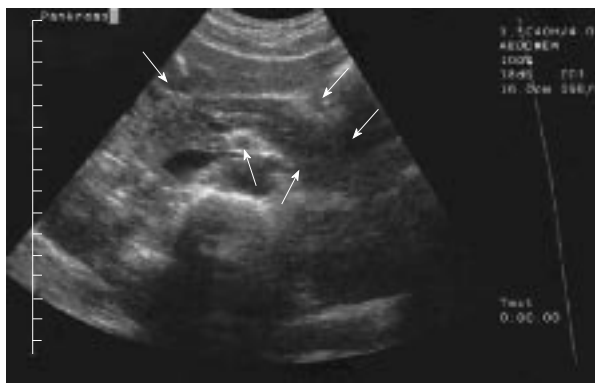
© 2014 Baishideng Publishing Group Co., Limited. All rights reserved.

**Key words:** Acute pancreatitis; Hypoxia; Flying; Thalassemia; Hemoglobin; Cystic fibrosis transmembrane

### INTRODUCTION

Within the group of younger patients suffering from recurrent episodes of acute pancreatitis, those not drinking alcohol impose a special diagnostic challenge. Many of these patients, who were coined to suffer from idiopathic pancreatitis even without a family history, may have mutations in the genes known to be associated with this disease<sup>[1]</sup>. Among genes identified to convey the risk of developing pancreatitis are cationic trypsinogen (PRSS1)<sup>[2]</sup>, serine protease inhibitor Kazal type 1 (SPINK1)<sup>[3]</sup>, chymotrypsin C (CTRC)<sup>[4]</sup> and cystic fibrosis transmembrane conductance regulator (*CFTR*)<sup>[5]</sup>, whereas mutations in the anionic trypsinogen gene<sup>[6]</sup> appear to be protective. Some who may be negative for genetic factors may have anatomical abnormalities, such as pancreas divisum or other branching disorders<sup>[7]</sup>. Still then, a small subgroup is left with no identifiable reason. Those may suffer from rare metabolic conditions or syndromes, however, normally present with other symptoms indicative of the underlying disease. Beyond those conditions, there are rather exotic reasons for suffering from acute pancreatitis. We here report on the combination of two hitherto undescribed mutations in both an extrapancreatic and a





**Figure 1** Transabdominal ultrasound depicting a pancreas (arrows) of normal size with slightly enhanced echogenicity.

pancreatic gene that might explain the repetitive attacks of pancreatitis.

## CASE REPORT

### Previous history

The 31-year-old black woman, who was brought up in Kenya but had been living in Germany for the last 8 years, presented with repeated episodes of acute abdominal pain which started in the middle epigastric region and would eventually radiate into the back, suggestive of acute pancreatitis. These episodes initially occurred after flying on regular commercial aircrafts. She was hospitalized eight years prior to this attack when 23 years old for cystitis and pyelonephritis when a diagnosis of acute pancreatitis was established *via* computer tomography. At that time, she also suffered from iron-deficient anemia [hemoglobin (Hb) 10.7 g/dL, mean corpuscular volume 69.4  $\mu$ m, iron 28 mg/dL, ferritin 23 ng/mL].

**Recent history prior to referral**

Abdominal ultrasound and computed axial tomography scan were reported to be normal; endoscopic retrograde cholangiopancreatography showed a slightly irregular main pancreatic duct (grade 0); however, no pancreas divisum and no papillary abnormalities. No overt gallstones, microlithiasis or sludge was present. After the last episode, when the diagnosis of acute pancreatitis was established by laboratory tests (elevated serum amylase and lipase) and abdominal ultrasound (swollen pancreas), the patient was referred to our outpatient pancreas clinic about one week after the last episode.

### Current presentation

The patient denied any abdominal pain or discomfort, fever or occasional night sweating. Appetite was normal. Bowel movements were reported to be regular with normal stool consistency and she reported no weight loss. There was no family history of pancreatitis or unclear abdominal pain. The patient denied any alcohol intake, smoking or experience with other drugs. There were no known allergies, prescription medicine or over-the-counter

ter drugs. The patient is a graduate student.

The patient was in no apparent distress. The physical exam was completely normal, vital signs stable and specifically, the abdomen was not tender. Bowel sounds were normal.

### Laboratory tests

In the blood, amylase and lipase were elevated (Table 1). All other parameters were within normal limits (Table 1). Infectious pathogens known to be associated with pancreatitis (cytomegalovirus, Epstein-Barr virus, mumps, adenovirus, varicella zoster virus, rubella, human immunodeficiency syndrome, Coxsackie, Legionella, leptospira, echinococcus, filariasis, fasciolosis, toxocara, bilharzia) could be excluded by serology. She did not have and had no history of malaria. Autoantibodies against nuclei, mitochondria and smooth muscle were negative, as were rheumatoid factors. All immunoglobulins, especially total immunoglobulin G (IgG) and IgG4, were within normal limits. Fecal elastase-1 (985 µg/g) and fecal chymotrypsin (14.7 U/g) were well within the normal range.

## Imaging

The pancreas appeared almost normal on ultrasound. Notably, the echogenicity was slightly elevated towards a so-called “white pancreas”<sup>[8]</sup> (Figure 1). There was a normal arterial blood supply to the pancreas. As the patient was slender, the transabdominal ultrasound had a good visibility: no gallstones, sludge or microlithiasis could be detected in the gallbladder or the bile duct all the way down into the pancreas.

### Hematological and genetic tests

Since the history of present illness together with the ethnic background of the patient was pressing, we performed further analysis with regard to a possible hemoglobinopathy. The ordinary complete blood count with blood smear was normal.

Hemoglobin F was slightly elevated at 0.92%, suggesting a “hereditary persistence of fetal hemoglobin” (HPFH). Molecular analysis of the hemoglobins resulted in the finding of a heterozygous transition at -158 C → T within the 5' non-coding region of the <sup>G</sup>gamma globulin gene (HPFH Swiss)<sup>[9,10]</sup>. Sequencing of the <sup>A</sup>gamma globulin gene did not reveal any abnormalities. Other genetic abnormalities associated with HPFH [HPFH-1 (black), HPFH-2 (Ghana), HPFH-3 (Indian), HPFH-7 (Kenya)] could not be detected. Sequencing of the  $\beta$ -thalassemia gene revealed no abnormalities. Sequencing the *CFTR* gene revealed a heterozygote sequence variant (c.2882T>C; p.M961T (ATG>ACC). Sequencing of *PRSS1*<sup>[2]</sup>, *SPINK1*<sup>[3]</sup> and *CTRC*<sup>[4]</sup> did not reveal any additional mutations in these pancreatitis genes.

### Further course

During a six year follow-up, the patient did not develop any further episodes of pancreatitis. According to our recommendation, she resisted from flying.

**Table 1** Laboratory values upon presentation to the pancreas outpatient clinic

Parameter	Unit	Value	Range
WBC	10E9/L	4.5	3.6-11.0
RBC	10E12/L	4.73	3.8-5.2
Hb	g/dL	14.8	12-16
Hct		43.9	35%-47%
MCV	fL	92.9	80-100
Na	mmol/L	139	135-144
K	mmol/L	4.28	3.5-5.2
Ca	mol/L	2.18	2.25-2.60
Albumin	g/L	36.4	35-52
Blood glucose	mg/dL	74	70-115
Bilirubin (total)	mg/dL	0.31	0.2-1.4
Uric acid	mg/dL	3.2	2.5-5.7
Cholesterol	mg/dL	173	130-260
Triglycerides	mg/dL	36	< 200
BUN	mg/dL	18.8	16.7-45.8
Creatinine	mg/dL	0.7	0.6-1.1
Alkaline phosphatase	U/L	80	55-160
γGT	U/L	9	4-18
GPT/ASAT	U/L	5	5-19
GOT/ALAT	U/L	13	5-15
Cholinesterase	U/L	4238	2800-7400
HbA1C		1.51	1.2-4.6
Zinc	mmol/L	34	16-50
Amylase	U/L	183	25-115
Lipase	U/L	202	114-286
Chymotrypsin	U/g	14.7	> 6
Elastase-1	μg/g	985	> 200
HbF		0.92	< 0.5%
HbA		92.73	87%-94%
HbA2		2.14	1.6%-3.1%
Anomalous Hb		Not detectable	
ALA	μmol/d	24	2-49
Porphobilinogen	μmol/d	6.6	0.5-7.5
Total porphyrines	μg/d	41.7	< 145

WBC: White blood cells; RBC: Red blood cells; Hb: Hemoglobin; Hct: Hematocrit; MCV: Mean corpuscular volume; BUN: Blood urea nitrogen; GOT/ASAT: Glutamic oxaloacetic transaminase; GPT/ALAT: Glutamic pyruvic transaminase; HbA1c: Hemoglobin A1c; ALA: Alpha lipoic acid.

## DISCUSSION

In adolescent and young adult patients presenting with signs of pancreatitis, associations with genetic abnormalities are pressing<sup>[1]</sup>. Even in sporadic cases, mutations in the genes known to cause hereditary pancreatitis such as PRSS1 have been reported. More recently, mutations in SPINK1 and CTFR have been reported in patients with idiopathic pancreatitis. Those were all normal/negative in this patient. The earlier history of present illness with flying to and from Kenya triggering the episodes of pancreatitis made us suspicious of other mechanisms underlying the etiology of her pancreatitis. The ethnic background led to further analysis of hemoglobinopathies, which revealed elevated hemoglobin F. Elevated fetal hemoglobin is not uncommon: it has been detected in around 10% of teenage high school students<sup>[11]</sup>, a few of them with abnormalities. Amongst these, the <sup>G</sup>gamma-globulin gene (HPFH Swiss) alteration is most frequent amongst females, all of them described as of Caucasian origin<sup>[11]</sup>. Detailed studies of our young black female patient re-

**Table 2** Summary of key findings

Etiology	Parameter	Negative/ Positive normal	Finding
Metabolic parameters	TSH, PTH, α-AT, lipids	X	
Immunological parameters	IgG/IgG4, AMA, ANA, ASMA, RF	X	
Pancreatotropic virus	Adenovirus, Coxsackie, CMV, EBV, hepatitis, HIV, measles, mumps, Rubella, VZV	X	
Pancreatitis genetics-acinar	PRSS1, CTFR, SPINK1	X	
Pancreatitis genetics-ductal	CFTR	X	c.2882T > C; p.M961T (ATG > ACC)
Hemoglobin	HBs	X	Elevated
HPFH	<sup>G</sup> gamma-hemoglobin gene	X	-158 C → T (HPFH Swiss)
	<sup>A</sup> gamma-hemoglobin gene	X	

HIV: Human immunodeficiency syndrome; ANA: Autoantibodies against nuclei; AMA: Autoantibodies against mitochondria; ASMA: Autoantibodies against smooth-muscle; CMV: Cytomegalovirus; EBV: Epstein-Barr virus; VZV: Varicella zoster virus; PTH: Parathyroid hormone; TSH: Thyroid-stimulating hormone; IgG: Immunoglobulin G; RF: Rheumatoid factor; PRSS1: Pancreatitis cationic trypsinogen; SPINK1: Serine protease inhibitor Kazal type 1; CTFR: Chymotrypsin C; CFTR: Cystic fibrosis transmembrane conductance regulator; HBs: Hepatitis B surface; HPFH: Hereditary persistence of fetal hemoglobin.

vealed this heterozygous transition at -158 C → T within the 5' non-coding region of the <sup>G</sup>gamma-globulin gene (HPFH Swiss) (Table 2). No other abnormalities could be detected. Notably, the patient did not suffer from clinically overt thalassemia, not having the typical mutations in the hemoglobin A (β-chain). Since this particular variant is considered to be minor<sup>[12]</sup>, this could not have been expected. Nevertheless, associations with rather complex hereditary traits have been described in these hemoglobinopathies<sup>[13]</sup>.

Classical thalassemia is reported to be associated with acute pancreatitis; however, the etiology is biliary as gallstones are typical in these patients. Indeed, in a series of 43 juvenile patients with acute pancreatitis, 30 suffered from choledocholithiasis caused by thalassemia<sup>[14]</sup>.

Sequencing the *CFTR* gene revealed a heterozygote sequence variant that has not been described previously (Table 2). The pathophysiological meaning, especially in relation to pancreatitis, is therefore unknown.

Whereas neither of these heterozygote mutations per se might have been sufficient to cause or contribute to pancreatitis, it is suggestive that the minor alterations in two genes, one pancreatic (*CFTR*) and one extrapancreatic (hemoglobin), might have culminated in a two-step mechanism leading to pancreatitis: impaired hemoglobin,

causing a certain degree of oxygen deficiency which is known to cause pancreatitis, *e.g.*, during iatrogenic ischemia or heart-lung machine usage, imposed on a heterozygote mutation in the *CFTR* gene. This two-hit hypothesis is speculative as we did not investigate the functional changes imposed by such a transition in the non-coding region in the hemoglobin and the *CFTR* mutation alone or in combination.

There is only one study reporting on a small series of patients with clinically overt thalassemia, gallstones and biliary pancreatitis<sup>[14]</sup>; however, our patient did not have overt thalassemia or gallstones/sludge or microlithiasis.

The pathological oxygen saturation of hemoglobin in thalassemia has been described<sup>[15,16]</sup>. Hypoxemia and ischemia have been demonstrated to be able to induce experimental pancreatitis<sup>[17]</sup>. Microcirculatory disturbances are today considered to play an important role in the exacerbation of acute pancreatitis<sup>[18]</sup>. Reduced perfusion of the pancreatic gland leading to hypoxia and ischemia is a well-described mechanism causing<sup>[19]</sup> or worsening pancreatitis<sup>[20]</sup>. Even in sickle-cell anemia, the acute pancreatitis is considered to be caused by microvascular occlusion<sup>[21]</sup>. Conversely, hyperbaric oxygen therapy has been demonstrated to ameliorate acute pancreatitis<sup>[22]</sup>. The combination of an alteration in a gene altering oxygen saturation with a gene altering pancreatic secretion represents the rendezvous of two genes, each in itself not sufficient to induce thalassemia or pancreatitis, an extrapancreatic and an intrapancreatic. This is supported by the finding in our patient during the initial, most severe acute pancreatitis when she was also found to have anemia (Hb 10.7 g/dL). We speculate that such combinations may be responsible for a number of hitherto undefined causes of juvenile pancreatitis. This has been observed in patients with pancreas divisum with *CFTR* or *SPINK1* mutations, also conditions that on their own might not be sufficient to cause pancreatitis<sup>[23]</sup>.

## ACKNOWLEDGMENTS

We thank the patient for permission to publish her case and to conduct the genetic analyses. We thank Heiko Witt, Munich and Jonas Rosendahl, Leipzig, for performing the genetic analyses.

## COMMENTS

### Case characteristics

The case of a 32-year-old black woman of African descent who suffered from repeated episodes of acute pancreatitis, initially triggered when flying on air-planes, is reported.

### Laboratory diagnosis

Genetic analysis was negative for cationic trypsinogen, serine protease inhibitor Kazal type-1 and chymotrypsin C. However, hemoglobin F was elevated.

### Pathological diagnosis

The combination of a hemoglobin gene mutation known for thalassemia in conjunction with the hitherto undescribed *CFTR* mutation is suggested to pave the road for initial and repetitive pancreatitis attacks.

### Treatment

Sequencing of the thalassemia gene revealed a novel alteration in the 5' region

indicative of a functional abnormality of the molecule.

## Experiences and lessons

Sequencing the cystic fibrosis transmembrane conductance regulator (*CFTR*) gene revealed a heterozygote sequence variant.

## Peer review

This is indeed an interesting case that needs to be published to increase awareness of more uncommon causes.

## REFERENCES

- 1 Witt H, Apte MV, Keim V, Wilson JS. Chronic pancreatitis: challenges and advances in pathogenesis, genetics, diagnosis, and therapy. *Gastroenterology* 2007; **132**: 1557-1573 [PMID: 17466744 DOI: 10.1053/j.gastro.2007.03.001]
- 2 Whitcomb DC, Gorry MC, Preston RA, Furey W, Sossenheimer MJ, Ulrich CD, Martin SP, Gates LK, Amann ST, Toskes PP, Liddle R, McGrath K, Uomo G, Post JC, Ehrlich GD. Hereditary pancreatitis is caused by a mutation in the cationic trypsinogen gene. *Nat Genet* 1996; **14**: 141-145 [PMID: 8841182 DOI: 10.1038/ng1096-141]
- 3 Witt H, Luck W, Hennies HC, Classen M, Kage A, Lass U, Landt O, Becker M. Mutations in the gene encoding the serine protease inhibitor, Kazal type 1 are associated with chronic pancreatitis. *Nat Genet* 2000; **25**: 213-216 [PMID: 10835640 DOI: 10.1038/76088]
- 4 Rosendahl J, Witt H, Szmola R, Bhatia E, Ozsvári B, Landt O, Schulz HU, Gress TM, Pfützer R, Löhr M, Kovacs P, Blüher M, Stumvoll M, Choudhuri G, Hegyi P, te Morsche RH, Drenth JP, Truninger K, Macek M, Puhl G, Witt U, Schmidt H, Büning C, Ockenga J, Kage A, Groneberg DA, Nickel R, Berg T, Wiedenmann B, Bödeker H, Keim V, Mössner J, Teich N, Sahin-Tóth M. Chymotrypsin C (CTRC) variants that diminish activity or secretion are associated with chronic pancreatitis. *Nat Genet* 2008; **40**: 78-82 [PMID: 18059268 DOI: 10.1038/ng.2007.44]
- 5 Malats N, Casals T, Porta M, Guarner L, Estivill X, Real FX. Cystic fibrosis transmembrane regulator (*CFTR*) DeltaF508 mutation and 5T allele in patients with chronic pancreatitis and exocrine pancreatic cancer. PANKRAS II Study Group. *Gut* 2001; **48**: 70-74 [PMID: 11115825 DOI: 10.1136/gut.48.1.70]
- 6 Witt H, Sahin-Tóth M, Landt O, Chen JM, Kähne T, Drenth JP, Kukor Z, Szepessy E, Halangk W, Dahm S, Rohde K, Schulz HU, Le Maréchal C, Akar N, Ammann RW, Truninger K, Bargetzi M, Bhatia E, Castellani C, Cavestro GM, Cerny M, Destro-Bisol G, Spedini G, Eiberg H, Jansen JB, Koudova M, Rausova E, Macek M, Malats N, Real FX, Menzel HJ, Moral P, Galavotti R, Pignatti PF, Rickards O, Spicak J, Zarnescu NO, Böck W, Gress TM, Friess H, Ockenga J, Schmidt H, Pfützer R, Löhr M, Simon P, Weiss FU, Lerch MM, Teich N, Keim V, Berg T, Wiedenmann B, Luck W, Groneberg DA, Becker M, Keil T, Kage A, Bernardova J, Braun M, Güldner C, Halangk J, Rosendahl J, Witt U, Treiber M, Nickel R, Férec C. A degradation-sensitive anionic trypsinogen (PRSS2) variant protects against chronic pancreatitis. *Nat Genet* 2006; **38**: 668-673 [PMID: 16699518 DOI: 10.1038/ng1797]
- 7 Dinter D, Löhr JM, Neff KW. Bifid tail of the pancreas: benign bifurcation anomaly. *AJR Am J Roentgenol* 2007; **189**: W251-W253 [PMID: 17954620 DOI: 10.2214/AJR.05.1453]
- 8 Schneider K, Harms K, Fendel H. The increased echogenicity of the pancreas in infants and children: the white pancreas. *Eur J Pediatr* 1987; **146**: 508-511 [PMID: 3315685 DOI: 10.1007/BF00441605]
- 9 Dubart A, Testa U, Musumeci S, Vainchenker W, Beuzard Y, Henri A, Schirilo G, Romeo MA, Russo G, Rochant H, Rosa J. Elevated Hb F associated with beta-thalassaemia trait: haemoglobin synthesis in reticulocytes and in blood BFU-E. *Scand J Haematol* 1980; **25**: 339-346 [PMID: 6163196 DOI: 10.1111/j.1600-0609.1981.tb01412.x]

- 10 **Indrak K**, Indrakova J, Kutlar F, Pospisilova D, Sulovska I, Baysal E, Huisman TH. Compound heterozygosity for a beta zero-thalassemia (frameshift codons 38/39; -C) and a nondeletional Swiss type of HPFH (A----C at NT -110, G gamma) in a Czechoslovakian family. *Ann Hematol* 1991; **63**: 111-115 [PMID: 1716997 DOI: 10.1007/BF01707283]
- 11 **Leonova JYe EG**, Smetanina NS, Adekile AD, Efremov GD, Huisman TH. Variability in the fetal hemoglobin level of the normal adult. *Am J Hematol* 1996; **53**: 59-65 [PMID: 8892728]
- 12 **Kohne E**. Hemoglobinopathies: clinical manifestations, diagnosis, and treatment. *Dtsch Arztebl Int* 2011; **108**: 532-540 [PMID: 21886666]
- 13 **Losekoot M**, Fodde R, Gerritsen EJ, van de Kuit I, Schreuder A, Giordano PC, Vossen JM, Bernini LF. Interaction of two different disorders in the beta-globin gene cluster associated with an increased hemoglobin F production: a novel deletion type of (G) gamma + ((A) gamma delta beta)(0)-thalassemia and a delta(0)-hereditary persistence of fetal hemoglobin determinant. *Blood* 1991; **77**: 861-867 [PMID: 1704267]
- 14 **Cosentini A**, Stranieri G, Capillo S, Notarangelo L, Madonna L, Iannini S, Ferro V, Defilippo V, Defilippo RG, Rubino R. Acute pancreatitis in the paediatric age group: a personal experience. *Eur Rev Med Pharmacol Sci* 2005; **9**: 33-40 [PMID: 15850142]
- 15 **Rachmilewitz EA**, Tamari H, Liff F, Ueda Y, Nagel RL. The interaction of hemoglobin O Arab with Hb S and beta+ thalassemia among Israeli Arabs. *Hum Genet* 1985; **70**: 119-125 [PMID: 3859465 DOI: 10.1007/BF00273069]
- 16 **Imai K**, Tientadakul P, Opartkiattikul N, Luene P, Wini-chagoon P, Svasti J, Fucharoen S. Detection of haemoglobin variants and inference of their functional properties using complete oxygen dissociation curve measurements. *Br J Haematol* 2001; **112**: 483-487 [PMID: 11167851 DOI: 10.1046/j.1365-2141.2001.02598.x]
- 17 **Su KH**, Cuthbertson C, Christophi C. Review of experimental animal models of acute pancreatitis. *HPB (Oxford)* 2006; **8**: 264-286 [PMID: 18333137 DOI: 10.1080/13651820500467358]
- 18 **Cuthbertson CM**, Christophi C. Disturbances of the micro-circulation in acute pancreatitis. *Br J Surg* 2006; **93**: 518-530 [PMID: 16607683 DOI: 10.1002/bjs.5316]
- 19 **Sakorafas GH**, Tsiotos GG, Sarr MG. Ischemia/Reperfusion-Induced pancreatitis. *Dig Surg* 2000; **17**: 3-14 [PMID: 10720825 DOI: 10.1159/000018793]
- 20 **Toyama MT**, Lewis MP, Kusske AM, Reber PU, Ashley SW, Reber HA. Ischaemia-reperfusion mechanisms in acute pancreatitis. *Scand J Gastroenterol Suppl* 1996; **219**: 20-23 [PMID: 8865466 DOI: 10.3109/00365529609104994]
- 21 **Ahmed S**, Siddiqui AK, Siddiqui RK, Kimpo M, Russo L, Mattana J. Acute pancreatitis during sickle cell vaso-occlusive painful crisis. *Am J Hematol* 2003; **73**: 190-193 [PMID: 12827657 DOI: 10.1002/ajh.10344]
- 22 **Cuthbertson CM**, Christophi C. Potential effects of hyperbaric oxygen therapy in acute pancreatitis. *ANZ J Surg* 2006; **76**: 625-630 [PMID: 16813630 DOI: 10.1111/j.1445-2197.2006.03793.x]
- 23 **Bertin C**, Pelletier AL, Vullierme MP, Bienvenu T, Rebours V, Hentic O, Maire F, Hammel P, Vilgrain V, Ruszniewski P, Lévy P. Pancreas divisum is not a cause of pancreatitis by itself but acts as a partner of genetic mutations. *Am J Gastroenterol* 2012; **107**: 311-317 [PMID: 22158025 DOI: 10.1038/ajg.2011.424]

**P- Reviewers:** Barreto S, Drewes AM **S- Editor:** Gou SX  
**L- Editor:** Roemmele A **E- Editor:** Wu HL





## Clinical and radiographic features of Hutchinson-Gilford progeria syndrome: A case report

Daniel Berretta Alves, Juliana Melo Silva, Tatiany Oliveira Menezes, Rosely Santos Cavaleiro, Fabrício Mesquita Tuji, Marcio Ajudarte Lopes, Alexandre Augusto Zaia, Ricardo Della Coletta

Daniel Berretta Alves, Department of Radiology, Esperança Institute of Higher Learning, Santarém-Pará 68040-100, Brazil  
Juliana Melo Silva, Department of Endodontics, Federal University of Pará, Belém-Pará 66055-240, Brazil

Tatiany Oliveira Menezes, Rosely Santos Cavaleiro, Department of Dentistry for Patients with Special Needs, Federal University of Pará, Belém-Pará 66055-240, Brazil

Fabrício Mesquita Tuji, Department of Oral and Maxillofacial Pathology, Federal University of Pará, Belém-Pará 66055-240, Brazil

Marcio Ajudarte Lopes, Ricardo Della Coletta, Department of Oral Diagnosis, School of Dentistry, State University of Campinas, Piracicaba-São Paulo 13083-970, Brazil

Alexandre Augusto Zaia, Department of Restorative Dentistry, School of Dentistry, State University of Campinas, Piracicaba-São Paulo 13083-970, Brazil

**Author contributions:** Alves DB, Silva JM and Zaia AA designed the report; Alves DB and Coletta RD performed the genetic analyses; Silva JM, Menezes TO, Cavaleiro RS and Tuji FM collected the patient's clinical data; Alves DB, Lopes MA and Coletta RD analyzed the data and wrote the paper.

**Supported by** The State University of Campinas, Piracicaba-São Paulo

**Correspondence to:** Daniel Berretta Alves, DDS, MSc, Department of Radiology, Esperança Institute of Higher Learning, Av. Coaracy Nunes, 3315, Caranazal Santarém, Santarém-Pará 68040-100, Brazil. [danielberretta@hotmail.com](mailto:danielberretta@hotmail.com)

Telephone: +55-93-35291760 Fax: +55-93-35291761

Received: October 18, 2013 Revised: December 27, 2013

Accepted: February 18, 2014

Published online: March 16, 2014

### Abstract

Hutchinson-Gilford progeria syndrome (HGPS) is a rare dysmorphic syndrome characterized by several features of premature aging with clinical involvement of the skin, bones, and cardiovascular system. HGPS has an estimated incidence of one in four million to one in eight million births. The main clinical features of HGPS include short stature, craniofacial dimorphism, alopecia,

bone fragility, and cardiovascular disorders. The most frequent cause of death is myocardial infarction at a mean age of 13 years old. Dental manifestations include delayed development and eruption of teeth, discoloration, crowding and rotation of teeth, and displaced teeth. Cone beam computed tomography images revealed the absence of the sphenoid, frontal, and maxillary sinus, flattening of the condyles and glenoid fossa, and bilateral hypoplasia of the mandibular condyles. The disease is caused by mutations in lamin A/C (*LMNA*). Here, we present a case report of an 11-year-old boy with classical features of HGPS, which was caused by a *de novo* germ-line mutation (C1824T, G608G) in exon 11 of the *LMNA* gene. Some uncommon HGPS-associated features in our patient, such as alterations in the facial sinuses and hypoplasia of the condyles, contributed to the expansion of the phenotypic spectrum of this syndrome from a dentomaxillofacial perspective.

© 2014 Baishideng Publishing Group Co., Limited. All rights reserved.

**Key words:** Cone beam computed tomography; *LMNA* mutation; Craniofacial anomalies; Temporomandibular joint

**Core tip:** Hutchinson-Gilford progeria syndrome (HGPS) is a rare genetic syndrome characterized by the accelerated appearance of aging in children. We report a case of an 11-year-old boy with HGPS with uncommon HGPS-associated dentomaxillofacial features. Alterations in the facial sinuses and hypoplasia of the condyles were recognized in our patient, expanding the phenotypic spectrum of this syndrome.

Alves DB, Silva JM, Menezes TO, Cavaleiro RS, Tuji FM, Lopes MA, Zaia AA, Coletta RD. Clinical and radiographic features of Hutchinson-Gilford progeria syndrome: A case report. *World J*

*Clin Cases* 2014; 2(3): 67-71 Available from: URL: <http://www.wjgnet.com/2307-8960/full/v2/i3/67.htm> DOI: <http://dx.doi.org/10.12998/wjcc.v2.i3.67>

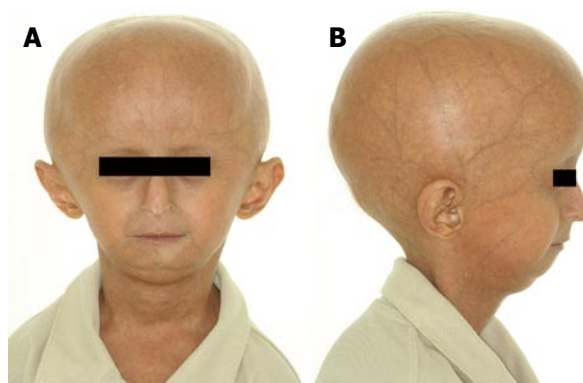
## INTRODUCTION

Hutchinson-Gilford progeria syndrome (HGPS; OMIM #176670) is an uncommon genetic disorder characterized by accelerated aging with clinical involvement of the skin, bones, and cardiovascular system<sup>[1,2]</sup>. The prevalence of HGPS is one in four million to one in eight million live births; males are more frequently affected than females, and the intellect of the affected children is unimpaired<sup>[3]</sup>. Clinically, individuals with HGPS demonstrate short stature, prominent eyes, micrognathia, craniofacial disproportion, loss of subcutaneous fat, alopecia, beaked nose, coxa valga, pathologic bone fractures, radiolucent terminal phalanges, hearing loss, photophobia, hypertension, hyperlipidemia, atherosclerosis, and cardiovascular disorders. The most frequent cause of death is myocardial infarction at a mean age of 13 years old<sup>[4-11]</sup>. Oral alterations include high rates of tooth decay, crowding, delayed tooth development and eruption, tooth discoloration, hypodontia, maxillary and mandibular hypoplasia, and small mouth opening<sup>[5-7,12,13]</sup>. Recognition of dentomaxillofacial features of HGPS may allow oral health problems to be readily identified and aid in implementation of preventative treatment plans to improve quality of life<sup>[14,15]</sup>. Although HGPS demonstrates both autosomal dominant and autosomal recessive modes of inheritance, most cases are due to sporadic mutations<sup>[16]</sup>. Mutations in the lamin A/C (*LMNA*) gene are responsible for HGPS<sup>[17-19]</sup>.

Here we report a case of HGPS in an 11-year-old boy with an uncommon phenotype and a *de novo* heterozygous silent mutation at amino acid 608 (G608G) of the *LMNA* gene.

## CASE REPORT

An 11-year-old boy with a clinical diagnosis of HGPS was referred to the Clinical Department, School of Dentistry, Federal University of Pará, Brazil for oral health care. He was suffering from angina, peptic ulcer disease, and limited joint mobility. His current medications were pravastatin (5 mg/d) to prevent cardiovascular disease and ranitidine (150 mg/d) for the treatment of the peptic ulcer. The patient had normal neurodevelopment and showed the classical clinical features of HGPS, including short stature, low weight/height ratio, thin and inelastic skin, eyes slightly open when sleeping, photophobia, osteoporosis in the femur region, generalized alopecia, prominent scalp veins, small face with a beaked nose, and high-pitched voice (Figure 1). The patient had no apparent hearing loss. Echocardiogram and electrocardiogram results, blood pressure, pulse, and oxygen saturation were within normal limits. A hand-wrist radiograph showed radiolucencies of the terminal phalanges and the skeletal



**Figure 1** Clinical features of the patient at 11 years of age. A: Facial features were characterized by a deformed head, generalized alopecia, a small face, a beaked nose, and thin and inelastic skin; B: In the lateral view, prominent scalp veins and micrognathia are evident.

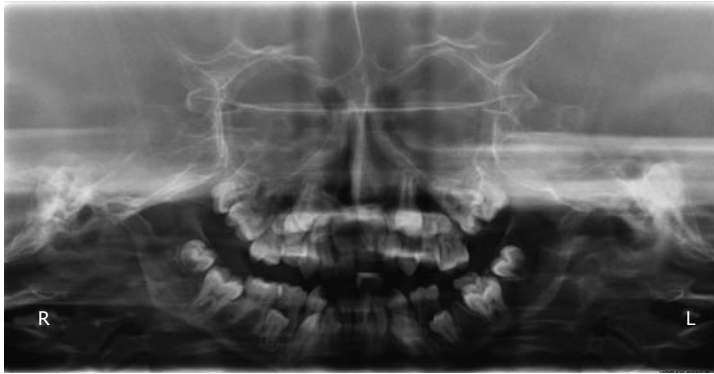maturity of a 14-year-old boy with a chronological age of 11 years and 8 mo.

His height and weight were 1.1 m and 17.4 kg, respectively, which is well below the 3<sup>rd</sup> percentile for his age and only 4.4 kg greater than expected for a normal 4.5-year-old boy. Oral examination revealed micrognathia, class II malocclusion, and chronic trimus. Erupted teeth were of normal size, shape and color, but the permanent incisors were lingually erupted. The patient had gingivitis and low salivary flow, but had no dental caries and brushed his teeth while supervised by the mother. An orthopantomographic radiograph showed reduced dimensions of both arches with consequent lack of space for the correct positioning of the permanent teeth, mandible with a steep mandibular angle, eruption of the permanent teeth, and congenitally missing left upper second premolar and both lower second premolars (Figure 2). To better visualize the craniofacial features, cone beam computed tomography (CBCT) was performed. CBCT images revealed the absence of the sphenoid, frontal, and maxillary sinuses (Figure 3A and B), flattening of the condyles and glenoid fossa, and bilateral hypoplasia of the mandibular condyles (Figure 3C). Panoramic and axial images confirmed the dental alterations (Figure 3D-F).

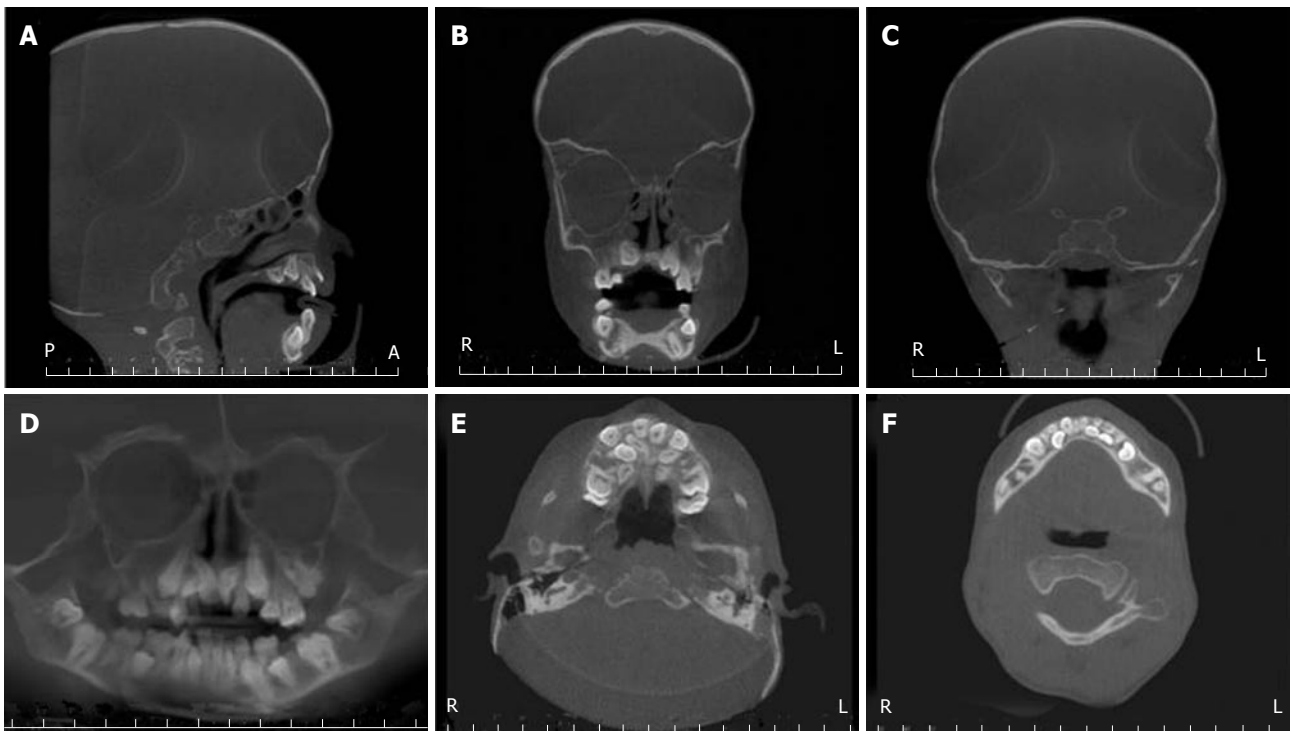
To confirm the clinical diagnosis of HGPS, DNA sequence analysis was performed. The parents gave informed consent before the genetic study began. Mutation analysis of the *LMNA* gene with genomic DNA extracted from oral mucosa cells was performed according to a published protocol<sup>[20]</sup>. The patient demonstrated a heterozygous C-to-T transition at nucleotide 1824 in exon 11 of *LMNA*, which created a silent point mutation at codon 608 (GGC>GGT, G608G) (Figure 4). A similar mutation was not observed in the patient's parents or sister.

## DISCUSSION

This case highlights some common and uncommon dentomaxillofacial features associated with HGPS. Tooth size was essentially normal but the eruption sequence was complicated by both incomplete mandibular and



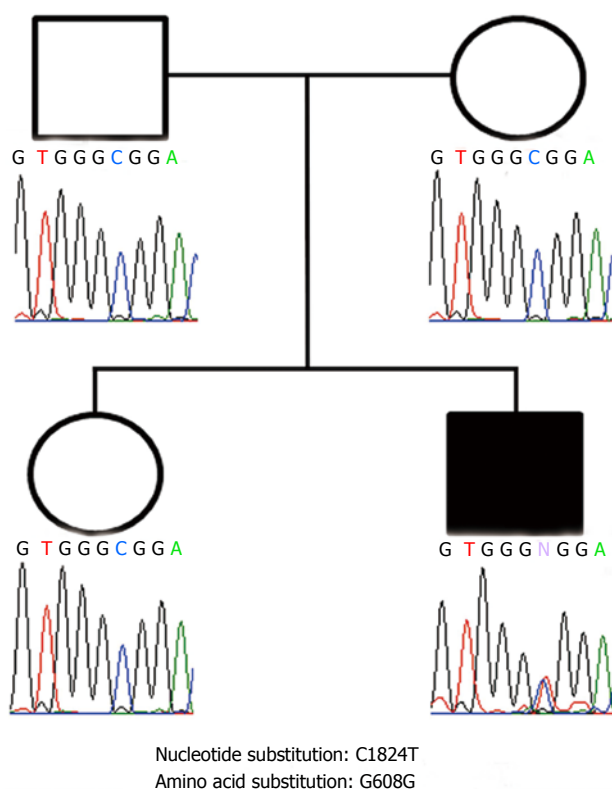
**Figure 2** Panoramic radiograph showing delayed eruption of the permanent teeth, hypodontia of the left upper second premolar and both lower second premolars, and temporomandibular joint malformation.



**Figure 3** Craniofacial features of the Hutchinson-Gilford progeria syndrome patient detected by cone beam computed tomography. A, B: On sagittal (A) and coronal (B) images, hypoplasia of the sphenoid, frontal and maxillary sinuses was evident; C: This view depicts the temporomandibular joint alteration, which was characterized by flattening of the condyle and glenoid fossa and bilateral hypoplasia of the condyles; D: Panoramic view of the cone beam computed tomography (CBCT) revealing impaction of several permanent molars and hypodontia of the premolars; E, F: Axial slices of the CBCT showed malocclusion and lingual eruption of permanent teeth.

maxillary growth and micrognathia, which contributed to dental impactions. Despite radiographic evidence of normal root development, tooth eruption appeared to be delayed by three years. In addition, the permanent incisors had erupted lingually, and two premolars were absent (hypodontia). Delayed eruption, malocclusion associated with lower anterior dentition crowding, and hypodontia are consistent findings in patients with HGPS, as well as enamel hypoplasia and discoloration<sup>[15,20-22]</sup>. The permanent teeth in the current case were macroscopically normal in shape and color. Patients who do not present alterations in the joints of the hands can carry out oral hygiene perfectly, but adult supervision is required along with the use of a toothbrush with a small head due to the small oral cavity and limited mouth opening. Interestingly, CBCT images revealed the absence of the sphenoid,

frontal and maxillary sinuses, shallow glenoid fossae, and bilateral hypoplasia of the mandibular condyles and articular eminences. After evaluating radiographs of 21 children aged newborn to 14.6 years old, Gordon *et al*<sup>[14]</sup> concluded that articulation deformities are not a common feature of HGPS. Chen *et al*<sup>[11]</sup> reported a similar case to ours and highlighted that craniofacial anomalies of HGPS contribute to increased number of caries, severe malocclusion, and problems with swallowing, feeding, and speech. However, Ullrich *et al*<sup>[23]</sup> evaluated 25 patients with HGPS and identified short mandibular rami in combination with flattened mandibular condyles, shallow glenoid fossae, and hypoplastic or absent articular eminences. The significance of the sinus alterations was unclear; however, patient- and parent-related chronic trismus can occur after a long period of regular dental



**Figure 4** Detection of the *LMNA* mutation in the Hutchinson-Gilford progeria syndrome patient. Shown here are portions of the DNA-sequence electropherogram of the *LMNA* exon 11 of the affected patient, his parents and older sister. Compared to the normal sequence, the affected patient has a heterozygous C-to-T substitution at nucleotide position 1824 in the *LMNA* gene, which does not change the amino acid (G608G).

treatment. Thus, HGPS patients should be evaluated for temporomandibular joint (TMJ) disorders, and dentists need to be aware of the possible TMJ complications after a long period of regular dental treatment.

Despite the reported clinical characteristics, HGPS may be confused with other syndromes that include some features of premature aging, including neonatal progeroid syndrome (Weidemann-Rautenstrauch syndrome), acrogeria, Cockayne syndrome, Hallermann-Streif syndrome, geroderma osteodysplastica, Berardinelli-Seip congenital lipodystrophy (congenital generalized lipodystrophy), Petty-Laxova-Weidemann progeroid syndrome, Ehlers-Danlos syndrome, progeroid form, and Werner syndrome<sup>[10,21]</sup>. Since an overlap in the clinical features of the patients affected by progeroid syndromes is common, the diagnosis of HGPS is based on the recognition of common clinical features and the detection of mutations in the *LMNA* gene and eventually in the *ZMPSTE2* gene, a metalloproteinase involved in processing of lamin A. *LMNA* mutations are present in more than 95% of cases, and genetic testing should start with analysis of the p.G608G mutation at exon 11, in which 62% of the defects reside<sup>[12]</sup>. DNA sequencing from the patient reported here revealed the p.G608G silent mutation. Although this mutation does not change the encoded amino acid, it results in the activation of a cryptic splice site and causes a truncated lamin A protein (50 amino acids shorter than

normal), which is essential for the conversion of normal lamin A from prelamin A<sup>[18]</sup>. Since HGPS patients develop severe atherosclerosis and death usually occurs as a result of the complications of cardiac or cerebrovascular diseases during adolescence, early diagnosis of HGPS is important. To promote survival of HGPS patients, annual analysis of the vascular status is recommended using baseline electrocardiogram, echocardiogram, and carotid duplex scans to evaluate stenosis and intimal thickness. Additional tests include a skeletal X-ray to evaluate common associated features (*e.g.*, acroosteolysis, clavicular resorption, and coxa valga), dual-energy X-ray absorptiometry to assess bone mineral density, standard goniometry to assess global joint mobility, and nutritional assessment to optimize caloric intake<sup>[24]</sup>.

In summary, we report one patient affected by HGPS who demonstrated unusual features, including the absence of the sphenoid, frontal and maxillary sinuses and bilateral hypoplasia of the mandibular condyles. Proper characterization of the clinical features and genetic defects is of utmost importance for correct diagnosis and timely clinical management. Furthermore, early intervention by a multidisciplinary team can increase the quality of life and survival of HGPS patients.

## COMMENTS

### Case characteristics

An 11-year-old boy with a diagnosis of Hutchinson-Gilford progeria syndrome (HGPS) presented with a need for oral health care.

### Clinical diagnosis

The patient exhibited classical clinical features of HGPS, including short stature, low weight/height ratio, thin and inelastic skin, eyes slightly open when sleeping, photophobia, generalized alopecia, prominent scalp veins, small face with a beaked nose, and high-pitched voice.

### Differential diagnosis

Differential diagnosis included neonatal progeroid syndrome (Weidemann-Rautenstrauch syndrome), acrogeria, Cockayne syndrome, Hallermann-Streif syndrome, geroderma osteodysplastica, Petty-Laxova-Weidemann progeroid syndrome, and Werner syndrome.

### Imaging diagnosis

Cone beam computed tomography (CBCT) images revealed absence of the sphenoid, frontal and maxillary sinuses, flattening of the condyles and glenoid fossa, and bilateral hypoplasia of the mandibular condyles.

### Pathological diagnosis

DNA sequence analysis and mutation analysis of the lamin A/C (*LMNA*) gene was performed with genomic DNA extracted from oral mucosa cells. The patient demonstrated a heterozygous C-to-T transition at nucleotide 1824 in exon 11 of *LMNA*, which created a silent point mutation at codon 608 (GGC>GGT, G608G).

### Treatment

The patient received medical and dental treatment to improve his quality of life.

### Related reports

Recognition of dentomaxillofacial features of HGPS may allow for early identification of oral health problems and for the development of preventive treatment plans to improve quality of life.

### Term explanation

Hutchinson-Gilford progeria syndrome is an uncommon genetic disorder characterized by accelerated aging with clinical involvement of the skin, bones, and cardiovascular system.

### Experiences and lessons

Proper characterization of the clinical features and genetic defects of HGPS is of utmost importance for correct diagnosis and initiation of timely clinical man-



agement; early intervention by a multidisciplinary team can increase the quality of life and survival of these patients.

### Peer review

This article reports a case of Hutchinson-Gilford progeria syndrome in an 11-year-old boy with an uncommon phenotype and a *de novo* heterozygous silent mutation at amino acid 608 (G608G) in the LMNA gene.

## REFERENCES

- 1 **Badame AJ.** Progeria. *Arch Dermatol* 1989; **125**: 540-544 [PMID: 2649013 DOI: 10.1001/archderm.1989.01670160088018]
- 2 **Brown WT, Zebrower M, Kieras FJ.** Progeria, a model disease for the study of accelerated aging. *Basic Life Sci* 1985; **35**: 375-396 [PMID: 4062819]
- 3 **Capell BC, Collins FS.** Human laminopathies: nuclei gone genetically awry. *Nat Rev Genet* 2006; **7**: 940-952 [PMID: 17139325 DOI: 10.1038/nrg1906]
- 4 **Hennekam RC.** Hutchinson-Gilford progeria syndrome: review of the phenotype. *Am J Med Genet A* 2006; **140**: 2603-2624 [PMID: 16838330 DOI: 10.1002/ajmg.a.31346]
- 5 **Russo-Menna I, Arancibia C.** The Hutchinson-Gilford Progeria Syndrome: a case report. *Minerva Anestesiol* 2010; **76**: 151-154 [PMID: 20150858]
- 6 **The Progeria Handbook: A Guide for Families and Health Care Providers of Children with Progeria.** Accessed January 25, 2011. Available from: URL: [http://www.progeriaresearch.org/patient\\_care.html](http://www.progeriaresearch.org/patient_care.html)
- 7 **Cleveland RH, Gordon LB, Kleinman ME, Miller DT, Gordon CM, Snyder BD, Nazarian A, Giobbie-Hurder A, Neuberger D, Kieran MW.** A prospective study of radiographic manifestations in Hutchinson-Gilford progeria syndrome. *Pediatr Radiol* 2012; **42**: 1089-1098 [PMID: 22752073 DOI: 10.1007/s00247-012-2423-1]
- 8 **Gordon CM, Gordon LB, Snyder BD, Nazarian A, Quinn N, Huh S, Giobbie-Hurder A, Neuberger D, Cleveland R, Kleinman M, Miller DT, Kieran MW.** Hutchinson-Gilford progeria is a skeletal dysplasia. *J Bone Miner Res* 2011; **26**: 1670-1679 [PMID: 21445982 DOI: 10.1002/jbmr.392]
- 9 **Zhang H, Chen X, Guo Y, Liang J, Tang L, Yu H, Yao Z.** Hutchinson-Gilford progeria syndrome: report of 2 cases and a novel LMNA mutation of HGPS in China. *J Am Acad Dermatol* 2013; **69**: e175-e176 [PMID: 24034385 DOI: 10.1016/j.jaad.2011.07.002]
- 10 **Pereira S, Bourgeois P, Navarro C, Esteves-Vieira V, Cau P, De Sandre-Giovannoli A, Lévy N.** HGPS and related premature aging disorders: from genomic identification to the first therapeutic approaches. *Mech Ageing Dev* 2008; **129**: 449-459 [PMID: 18513784 DOI: 10.1016/j.mad.2008.04.003]
- 11 **Chen CP, Lin SP, Lin DS, Liu YP, Hsu LJ, Wang W.** Clinical imaging findings in a girl with Hutchinson-Gilford progeria syndrome. *Genet Couns* 2012; **23**: 1-7 [PMID: 22611635]
- 12 **Merideth MA, Gordon LB, Clauss S, Sachdev V, Smith AC, Perry MB, Brewer CC, Zalewski C, Kim HJ, Solomon B, Brooks BP, Gerber LH, Turner ML, Domingo DL, Hart TC, Graf J, Reynolds JC, Gropman A, Yanovski JA, Gerhard-Herman M, Collins FS, Nabel EG, Cannon RO, Gahl WA, Introne WJ.** Phenotype and course of Hutchinson-Gilford progeria syndrome. *N Engl J Med* 2008; **358**: 592-604 [PMID: 18256394 DOI: 10.1056/NEJMoa0706898]
- 13 **Yu QX, Zeng LH.** Progeria: report of a case and review of the literature. *J Oral Pathol Med* 1991; **20**: 86-88 [PMID: 2016699 DOI: 10.1111/j.1600-0714.1991.tb00895.x]
- 14 **Gordon LB, McCarten KM, Giobbie-Hurder A, Machan JT, Campbell SE, Berns SD, Kieran MW.** Disease progression in Hutchinson-Gilford progeria syndrome: impact on growth and development. *Pediatrics* 2007; **120**: 824-833 [PMID: 17908770 DOI: 10.1542/peds.2007-1357]
- 15 **Domingo DL, Trujillo MI, Council SE, Merideth MA, Gordon LB, Wu T, Introne WJ, Gahl WA, Hart TC.** Hutchinson-Gilford progeria syndrome: oral and craniofacial phenotypes. *Oral Dis* 2009; **15**: 187-195 [PMID: 19236595 DOI: 10.1111/j.1601-0825.2009.01521.x]
- 16 **Mazereeuw-Hautier J, Wilson LC, Mohammed S, Smallwood D, Shackleton S, Atherton DJ, Harper JJ.** Hutchinson-Gilford progeria syndrome: clinical findings in three patients carrying the G608G mutation in LMNA and review of the literature. *Br J Dermatol* 2007; **156**: 1308-1314 [PMID: 17459035 DOI: 10.1111/j.1365-2133.2007.07897.x]
- 17 **Coutinho HD, Falcão-Silva VS, Gonçalves GF, da Nóbrega RB.** Molecular ageing in progeroid syndromes: Hutchinson-Gilford progeria syndrome as a model. *Immun Ageing* 2009; **6**: 4 [PMID: 19379495 DOI: 10.1186/1742-4933-6-4]
- 18 **Eriksson M, Brown WT, Gordon LB, Glynn MW, Singer J, Scott L, Erdos MR, Robbins CM, Moses TY, Berglund P, Dutra A, Pak E, Durkin S, Csoka AB, Boehnke M, Glover TW, Collins FS.** Recurrent *de novo* point mutations in lamin A cause Hutchinson-Gilford progeria syndrome. *Nature* 2003; **423**: 293-298 [PMID: 12714972 DOI: 10.1038/nature01629]
- 19 **De Sandre-Giovannoli A, Bernard R, Cau P, Navarro C, Amiel J, Boccaccio I, Lyonnet S, Stewart CL, Munnich A, Le Merrer M, Lévy N.** Lamin A truncation in Hutchinson-Gilford progeria. *Science* 2003; **300**: 2055 [PMID: 12702809 DOI: 10.1126/science.1084125]
- 20 **Moulson CL, Fong LG, Gardner JM, Farber EA, Go G, Passariello A, Grange DK, Young SG, Miner JH.** Increased progerin expression associated with unusual LMNA mutations causes severe progeroid syndromes. *Hum Mutat* 2007; **28**: 882-889 [PMID: 17469202 DOI: 10.1002/humu.20536]
- 21 **Liessmann CD.** Anaesthesia in a child with Hutchinson-Gilford progeria. *Paediatr Anaesth* 2001; **11**: 611-614 [PMID: 11696128 DOI: 10.1046/j.1460-9592.2001.00721.x]
- 22 **Wesley RK, Delaney JR, Litt R.** Progeria: clinical considerations of an isolated case. *ASDC J Dent Child* 1979; **46**: 487-492 [PMID: 290644]
- 23 **Ullrich NJ, Silvera VM, Campbell SE, Gordon LB.** Craniofacial abnormalities in Hutchinson-Gilford progeria syndrome. *AJNR Am J Neuroradiol* 2012; **33**: 1512-1518 [PMID: 22460337 DOI: 10.3174/ajnr.A3088]
- 24 **Gordon LB, Brown WT, Collins FS.** Hutchinson-Gilford progeria syndrome. 2003 Dec 12 [Updated 2011 Jan 6]. In: Pagon RA, Adam MP, Bird TD, editors. *GeneReviews*™ [Internet]. Seattle (WA): University of Washington, Seattle; 1993-2014. Available from: URL: <http://www.ncbi.nlm.nih.gov/books/NBK1121/>

**P- Reviewers:** Franco AL, Rattan V, Worman HJ  
**S- Editor:** Ma YJ **L- Editor:** A **E- Editor:** Wu HL



## Additional responsibility for physicians caring for cardiac patients: Insight from a case series

Muhammad Ajmal

Muhammad Ajmal, Department of Anaesthesia, Coombe Women and Infants University Hospital, Dublin 8, Ireland  
Muhammad Ajmal, Department of Anaesthesia, Sligo General Hospital, Sligo, Ireland

Author contributions: Ajmal M solely contributed to this paper.  
Correspondence to: Muhammad Ajmal, MBBS, DA, Department of Anaesthesia, Coombe Women and Infants University Hospital, Cork Street, Dublin 8, Ireland. [ajmal\\_c@hotmail.com](mailto:ajmal_c@hotmail.com)  
Telephone: +353-1-4085200 Fax: +353-1-4536033

Received: October 13, 2013 Revised: February 14, 2014

Accepted: February 18, 2014

Published online: March 16, 2014

### Abstract

Resuscitation measures performed at the scene of the event have the ultimate impact on the outcome of a cardiac arrest. We analysed six case histories of those sudden cardiac arrest patients who were revived in the field and were subsequently admitted to the intensive care unit during a six-month period. All were known cardiac patients and were under the care of healthcare providers. Four of those were discharged home from the hospital and did not suffer any residual damage where as one died of multi-organ failure and the other was declared brain dead. The outcome was good in patients who received early intervention in the form of basic life support. The family members of non-survivors witnessed the cardiac arrest at home but were not familiar with the concept or procedures of basic life support. We propose that physicians who care for cardiac patients should undertake the task of increasing family member awareness and knowledge in the techniques of basic life support.

© 2014 Baishideng Publishing Group Co., Limited. All rights reserved.

**Key words:** Heart disease; Cardiac arrest; Cardiopulmonary resuscitation; Physicians; Family members; Education and training

**Core tip:** Resuscitation measures performed at the scene of the event have a major impact on the outcome of cardiac arrest. There is no specific strategy in place to motivate family members of cardiac patients to learn life-saving basic life support techniques. We propose that the physicians who care for cardiac patients should undertake the task of increasing family member awareness and knowledge of basic life support.

Ajmal M. An additional responsibility for physicians caring for cardiac patients: Insight from a case series. *World J Clin Cases* 2014; 2(3): 72-74 Available from: URL: <http://www.wjgnet.com/2307-8960/full/v2/i3/72.htm> DOI: <http://dx.doi.org/10.12998/wjcc.v2.i3.72>

### INTRODUCTION

Successful revival following sudden cardiac arrest depends on patient characteristics and resuscitation measures<sup>[1]</sup>. Heart disease is the most common cause of sudden cardiac arrest, and its risk can be reduced by long-term efforts initiated by patients and their healthcare providers. However, “resuscitation measures” performed at the scene of the event have a major impact on the outcome of cardiac arrest<sup>[2]</sup>. Recently, we reviewed a series of out-of-hospital adult cardiopulmonary resuscitations carried out in the communities served by our regional hospital. An insight of the outcome of that case series is reported.

### CASE REPORT

We analysed six case histories of cardiac arrest patients who were revived in the field and were subsequently admitted to the intensive care unit during a six-month period. The patient characteristics and resuscitation measures are shown in Table 1.

In this series, cases 5 and 6 did not survive. Case 5

**Table 1 Patient characteristics and resuscitation measures**

Case	Age (yr)	Gender	Cardiac disease	Initial diagnosis	BLS/ACLS	Initial treatment	In-hospital management
1	68	Male	Yes	VFib	Immediate	BLS, ACLS	Ventilation antiarrhythmic inotropes
2	58	Male	Yes	VFib	Immediate	BLS, ACLS	ventilation thrombolytic inotropes
3	79	Male	Yes	PEA	Immediate	BLS, ACLS	ventilation thrombolytic inotropes
4	64	Male	Yes	VFib	Immediate	BLS, ACLS	ventilation antiarrhythmic
5	74	Male	Yes	VFib	Delayed	ACLS	ventilation antiarrhythmic hemofiltration
6	56	Female	Yes	VFib	Delayed	ACLS	ventilation antiarrhythmic therapeutic hypothermia

ACLS: Advanced cardiac life support; BLS: Basic life support; PEA: Pulseless electrical activity; VFib: Ventricular fibrillation.

died of multi-organ failure, and case 6 was declared brain dead. The other four patients were discharged home and did not suffer any residual damage. Though limited in number, this series reveals some patterns with regard to characteristics and resuscitation measure outcome: (1) all were known cardiac patients under the care of healthcare providers; (2) in five of the six patients, cardiac arrest was due to ventricular fibrillation, which is a shockable rhythm and requires the immediate use of a defibrillator, such as automated external defibrillator; (3) the outcome was good in patients who received early intervention in the form of “basic life support” (BLS); and (4) the family members of cases 5 and 6 witnessed the cardiac arrest at home but were not familiar with the concept or procedures of BLS. Two of the four patients who survived suffered from cardiac arrest while they were enjoying in a pub/bar and were able to receive BLS or even defibrillation immediately. One patient who collapsed on his own street was taken care of by paramedical professionals employed at the local hospital who happened to be passing by, and one victim suffered cardiac arrest at a doctor's appointment and was resuscitated by his primary care physician. One of the patients who did not survive was the youngest (56 years old) in this case series but did not receive cardiopulmonary resuscitation until an ambulance arrived twenty minutes later. We asked the families of the survivors about their awareness and ability to provide BLS, and three of the four families acknowledged that they did not know how to implement these measures.

## DISCUSSION

Many social organizations actively promote public and community awareness about BLS. Healthcare employees and those that work at public facilities (e.g., airports, restaurants/pubs) are required to complete BLS training.

However, there is no specific strategy in place to motivate family members of cardiac patients to learn life-saving BLS techniques<sup>[3]</sup>. We propose that physicians who care for cardiac patients should undertake the task of increasing family member awareness and knowledge of BLS<sup>[4]</sup>. Anesthesiologists can motivate families of cardiac patients who undergo anesthesia or intensive care unit admission. This can be accomplished through direct communication with individual families or in the form of combined educational sessions with multiple families<sup>[5]</sup>. This strategy is especially important in remote areas where ambulance response times are long.

## ACKNOWLEDGMENTS

A special “thank you” goes to Niall Fanning, Anesthesiologist, St. James's Hospital, Dublin, Ireland and Michael Carey, Anesthesiologist and Director Perioperative Medicine, Coombe Women and Infants University Hospital, Dublin, Ireland, for their ongoing support and encouragement for the author to continue academic activities in the field of Anesthesiology and Acute Care Medicine.

## COMMENTS

### Case characteristics

A series of six out-of-hospital sudden witnessed cardiac arrests in cardiac patients.

### Clinical diagnosis

Return of spontaneous circulation following sudden cardiac arrest.

### Differential diagnosis

Intact cerebral function, cerebral damage, and brain death.

### Laboratory diagnosis

Post cardiac arrest.

### Imaging diagnosis

Post cardiac arrest in five cases, severe cerebral damage (brain death) in one case.

### Pathological diagnosis

Post cardiac arrest.

### Experiences and lessons

Family members of cardiac patients should learn life saving basic life support techniques and health care providers involved in their care should motivate family members to learn these techniques.

### Peer review

The author who analysed six case histories of cardiac arrest victims proposes that physicians who care for cardiac patients should undertake the task of increasing family member awareness and knowledge of “basic life support”. The cases are not rare but the content is worth publishing.

## REFERENCES

- 1 Bobrow BJ, Spaite DW, Berg RA, Stolz U, Sanders AB, Kern KB, Vadeboncoeur TF, Clark LL, Gallagher JV, Stapczynski JS, LoVecchio F, Mullins TJ, Humble WO, Ewy GA. Chest compression-only CPR by lay rescuers and survival from out-of-hospital cardiac arrest. *JAMA* 2010; **304**: 1447-1454 [PMID: 20924010 DOI: 10.1001/jama.2010.1392]
- 2 Ajmal M. Incidence of aspiration of gastric contents in out-of-hospital successfully revived adult cardiac arrests - a series of six cases. *Can J Anesth* 2010; **57**: S37
- 3 Sayre MR, Berg RA, Cave DM, Page RL, Potts J, White RD. Hands-only (compression-only) cardiopulmonary resuscita-

tion: a call to action for bystander response to adults who experience out-of-hospital sudden cardiac arrest: a science advisory for the public from the American Heart Association Emergency Cardiovascular Care Committee. *Circulation* 2008; **117**: 2162-2167 [PMID: 18378619 DOI: 10.1161/CIRCULATIONAHA.107.189380]

- 4 **Vukmir RB**. Witnessed arrest, but not delayed bystander

cardiopulmonary resuscitation improves prehospital cardiac arrest survival. *Emerg Med J* 2004; **21**: 370-373 [PMID: 15107387 DOI: 10.1136/emj.2003.008383]

- 5 **Dracup K**, Heaney DM, Taylor SE, Guzy PM, Breu C. Can family members of high-risk cardiac patients learn cardiopulmonary resuscitation? *Arch Intern Med* 1989; **149**: 61-64 [PMID: 2912416 DOI: 10.1001/archinte.1989.00390010079008]

**P- Reviewers:** Kounis GN, Masahiro K, Muengtawepong S

**S- Editor:** Wen LL **L- Editor:** A **E- Editor:** Wu HL





## Homozygous factor V Leiden mutation in type IV Ehlers-Danlos patient

Marwan Refaat, Mostafa Hotait, Brion Winston

Marwan Refaat, Mostafa Hotait, Brion Winston, Department of Cardiology, American University Medical Center, Beirut 110 72020, Lebanon

Brion Winston, Capital Cardiology Associates, 7 Southwoods Blvd. Albany, NY 12211, United States

Author contributions: Refaat M, Hotait M and Winston B reviewed, designed, edited, and organized the report.

Correspondence to: Marwan Refaat, MD, FACC, FAHA, FHRS, FASE, FESC, FACP, Assistant Professor of Medicine, Department of Cardiology, American University Medical Center, Cairo St, Beirut 110 72020, Lebanon. [mr48@aub.edu.lb](mailto:mr48@aub.edu.lb)

Telephone: +961-78-929290 Fax: +961-78-929290

Received: November 12, 2013 Revised: January 2, 2014

Accepted: February 20, 2014

Published online: March 16, 2014

**Key words:** Ehlers-Danlos syndrome; Factor V Leiden; Platelets; Coagulopathy

**Core tip:** Hemostatic abnormalities that have already been described in Ehlers-Danlos syndrome patients include platelet abnormalities (release defects,  $\delta$ -storage pool disease) as well as clotting factor deficiencies that increase the bleeding tendencies of patients. The co-existence of platelet  $\delta$ -storage pool disease and factor V Leiden mutation in our patient manifested as having aneurysms of the splenic, renal, hepatic, gastric, mesenteric arteries and diffuse aneurysms of the upper and lower extremities as well as bilateral lower extremity deep vein thromboses and pulmonary emboli. This propensity to both bleeding and clotting made the management of our patient challenging on this presentation with acute anterolateral myocardial infarction.

### Abstract

Ehlers-Danlos syndrome (EDS) is a group of inherited connective tissue disorders caused by collagen synthesis defects. Several hemostatic abnormalities have been described in EDS patients that increase the bleeding tendencies of these patients. This case report illustrates a patient with an unusual presentation of a patient with type IV EDS, platelet  $\delta$ -storage pool disease and factor V Leiden mutation. Young woman having previous bilateral deep vein thrombosis and pulmonary emboli coexisting with ruptured splenic aneurysm and multiple other aneurysms now presented with myocardial infarction. Presence of factor V Leiden mutation raises the possibility that the infarct was due to acute coronary thrombosis, although coronary artery aneurysm and dissection with myocardial infarction is known to occur in vascular type EDS. This is the first report in the medical literature of factor V Leiden mutation in an EDS patient which made the management of our patient challenging with propensity to both bleeding and clotting.

© 2014 Baishideng Publishing Group Co., Limited. All rights reserved.

Refaat M, Hotait M, Winston B. Homozygous factor V Leiden mutation in type IV Ehlers-Danlos patient. *World J Clin Cases* 2014; 2(3): 75-77 Available from: URL: <http://www.wjgnet.com/2307-8960/full/v2/i3/75.htm> DOI: <http://dx.doi.org/10.12998/wjcc.v2.i3.75>

### INTRODUCTION

Ehlers-Danlos syndrome (EDS) is a group of heterogeneous heritable diseases that cause hyperextensibility of the skin, hypermobility of the large joints and easy bruising. It is classified in regard to main symptoms, the causative gene and the inheritance pattern. Among the eleven described types of EDS, type IV EDS known as vascular form, is a rare autosomal dominant inherited disorder with a 100% phenotypic penetrance caused by a mutation of the *COL3A1* gene encoding type III collagen. EDS has an estimated prevalence of 1:5000 to 1:250000 births, and among all, vascular type accounts for 5%-10% of cases<sup>[1,2]</sup>. The vascular type is the most severe because

of vascular system complications as type III collagen rich systemic arteries may undergo dissection, aneurysm, or rupture. Vascular rupture or other organ rupture are the presenting signs in 70% of patients with vascular EDS and the mean age for first major arterial or gastrointestinal complication is 23 years<sup>[1]</sup>. As for the hemostatic abnormalities previously reported in EDS, patients have more tendency to bleed due to platelet abnormalities (release defects,  $\delta$ -storage pool disease) and clotting factors deficiencies. We report a case of a 40-year-old female with type IV EDS, platelet  $\delta$ -storage pool disease and factor V Leiden mutation. Patient who had multiple previous complications including rupture splenic aneurysm and multiple other aneurysms in addition to coexisting bilateral deep vein thrombosis and pulmonary emboli, presented with acute myocardial infarction.

## CASE REPORT

The patient is a 40-year-old woman previously diagnosed with Ehlers-Danlos syndrome type IV and aneurysms of the splenic, renal, hepatic, gastric, and mesenteric arteries as well as diffuse aneurysms of the upper and lower extremities. She was transferred emergently from an outside hospital with nausea, vomiting, chest pain, shortness of breath, productive cough, and fever of two days duration. Her history was significant for coagulopathy associated with platelet storage pool defect, factor V Leiden with large bilateral lower extremity deep vein thromboses and pulmonary emboli, and diet controlled diabetes mellitus. Further history obtained from the patient and medical record revealed a healthy childhood and generally good health in early adulthood. The patient noted that she had always been "double jointed" in her hands. She had excessive bleeding after cesarean section and deep vein thrombosis in her twenties that prompted hematologic evaluation. This revealed a prolonged bleeding time and platelet storage defect, and factor V Leiden homozygous mutation. The patient denied a tobacco smoking history.

At the age of 33 she was hospitalized for abdominal pain and underwent appendectomy for presumed appendicitis. Approximately one month later she presented again with further abdominal pain and was found to have a ruptured splenic artery aneurysm and multiple aneurysms of the hepatic, renal, gastric, and mesenteric arteries. She underwent emergent splenectomy. Extensive vascular adhesions were found on laparotomy at that time. Four days later she developed a left arm compartment syndrome due to an automated sphygmomanometer and underwent emergent vascular reconstruction of her brachial artery. That hospitalization was further complicated by post-op intrabdominal bleeding requiring repeat laparotomy and Jackson-Pratt drainage placement, and hematochezia due to anal fissures. During recovery from these acute events she developed thigh pain and pleuritic chest pain and was found with large bilateral deep vein thromboses and small pulmonary emboli. Surgical pathological examination of the splenic artery aneurysm with molecular and biochemical analysis were diagnostic of Ehlers-Danlos syndrome type IV.

Initial examination was significant for a woman in moderate distress, pulse of 115 bpm, blood pressure of 80/40 mmHg, respiratory rate of 24 per minute with 96% oxygen saturation on 15 L/min non-rebreather, and temperature of 101.7 F. She had elevated jugular venous pressure to 6 cm above the angle of Louis, and diminished breath sounds in the right lung with right basilar rales. Her cardiac exam revealed no visible heave, a diminished point of maximum intensity, a rapid regular rhythm, and a normal first and second heart sound with no audible S3. She had a holosystolic II/VI murmur loudest at the left sternal border that did not vary with respiration, and she had no pericardial rub. Her extremities were warm, and distal pulses were normal except for a diminished left radial pulse. She had a large surgical scar running the medial length of her left arm from axilla to distal forearm. She had no peripheral edema. Further physical examination was notable for prominent veins of the extremities with a transparent appearance of the skin. Her finger, hand, and wrist joints were hypermobile with passive range of motion.

Electrocardiogram revealed sinus tachycardia with 2 mm ST elevations and Q waves in the antero-lateral leads consistent with acute antero-lateral myocardial infarction. Initial laboratory evaluation was significant for troponin I of 189 ng/mL. Chest X-ray was significant for bilateral hazy infiltrates. The patient was offered emergent cardiac catheterization but declined. She also declined all antiplatelet and anticoagulant medications. Echocardiogram was performed revealing severely decreased systolic function with severe hypokinesis of the anterior wall, septum, apex and inferior wall. The remaining segments were hypokinetic. Right ventricular size and function and estimated pulmonary artery pressures were normal, and mild to moderate mitral regurgitation was present. Her mental status, blood pressure, and chest pain improved with supportive measures including empiric antibiotics for community acquired pneumonia.

The patient's recovery from anterolateral myocardial infarction and pneumonia was complicated by parapneumonic effusion. She tolerated percutaneous pleural drainage well and was discharged home.

## DISCUSSION

Among the eleven described types of EDS, type IV EDS, also known as vascular form, is a rare autosomal inherited disorder of connective tissue due to a mutation of the *COL3A1* gene encoding type III collagen. It presents a decreased amount of type III collagen and therefore an increased vascular friability and fragility. The vascular morbidity this patient has experienced is typical of patients with vascular EDS type IV who do not express the typical hyperextensible skin and joints<sup>[3]</sup>. In fact, it is the most severe form and leads to premature death due to hemorrhage from the rupture of the major and visceral arteries. Besides the connective pathology responsible for the bleeding tendency, several hemostatic abnormalities have been described in EDS patients. These include platelet abnormalities (release defects,  $\delta$ -storage pool

disease) as well as clotting factor VIII, IX, XI and XIII deficiencies<sup>[4-6]</sup>. However, cause of the acute anterolateral myocardial infarction remains unclear in this unfortunate young woman with the combination of platelet storage pool defect with coagulopathy and factor V Leiden mutation with history of deep vein thromboses and pulmonary emboli. Coronary artery aneurysm and dissection with myocardial infarction is known to occur in vascular type EDS<sup>[7-14]</sup>. The coexistence of factor V Leiden mutation further raises the possibility that the infarct was due to acute coronary thrombosis, although a clear association between MI and factor V Leiden in non-smokers has not been established<sup>[15]</sup>. Coronary artery aneurysm with or without dissection as an anatomic substrate for acute coronary thrombosis in this individual with factor V Leiden is one possibility that could tie together her vascular and hematologic abnormalities that resulted in acute anterolateral myocardial infarction. This patient had an unusual combination of pathologies. This rare association of EDS type IV, platelet  $\delta$ -storage pool disease and factor V mutation is not previously described. As our patient illustrates, this association predisposes to bleeding and clotting tendencies. While there is no therapy for EDS, desmopressin acetate reduces the bleeding time in patients with EDS type IV and platelet  $\delta$ -storage pool disease<sup>[16]</sup>.

## COMMENTS

### Case characteristics

A 40-years-old female diagnosed with Ehlers-Danlos syndrome (EDS) type IV presented with chest pain, shortness of breath and productive cough.

### Clinical diagnosis

Diminished breath sounds in the right lung, holosystolic II/VI murmur loudest at left sternal border and elevated jugular venous pressure to 6 cm above the angle of Louis.

### Differential diagnosis

Myocardial infarction, pulmonary embolism, pneumonia.

### Laboratory diagnosis

Troponin I 189 ng/mL.

### Imaging diagnosis

Electrocardiogram (ECG): 2 mm ST elevations and Q waves in anterolateral leads; chest X-ray: Bilateral hazy infiltrates; echocardiogram: Decreased systolic function with severe hypokinesis of anterior wall, septum, apex and inferior wall.

### Pathological diagnosis

ECG and troponin suggestive of anterolateral myocardial infarction.

### Treatment

Patient declined both emergent cardiac catheterization and antiplatelet/anticoagulation medications.

### Related reports

Patients with type IV Ehler-Danlos are reported to have increased tendency to bleed rather than having hypercoagulability state.

### Experiences and lessons

This case report shows unusual coexistence of platelet storage disease and factor V Leiden mutation in EDS, predisposing our patient to bleeding and clotting tendencies.

### Peer review

This article reports an interesting factor V Leiden mutation in an Ehlers-Danlos patient.

## REFERENCES

- Beridze N, Frishman WH. Vascular Ehlers-Danlos syndrome: pathophysiology, diagnosis, and prevention and treatment of its complications. *Cardiol Rev* 2012; **20**: 4-7 [PMID: 22143279 DOI: 10.1097/CRD.0b013e3182342316]
- Nakamura M, Yajima J, Oikawa Y, Ogasawara K, Uejima T, Abe K, Aizawa T. Vascular Ehlers-Danlos syndrome--all three coronary artery spontaneous dissections. *J Cardiol* 2009; **53**: 458-462 [PMID: 19477391 DOI: 10.1016/j.jcc.2008.09.007]
- Oderich GS, Panneton JM, Bower TC, Lindor NM, Cherry KJ, Noel AA, Kalra M, Sullivan T, Gloviczki P. The spectrum, management and clinical outcome of Ehlers-Danlos syndrome type IV: a 30-year experience. *J Vasc Surg* 2005; **42**: 98-106 [PMID: 16012458 DOI: 10.1016/j.jvs.2005.03.053]
- Kashiwagi H, Riddle JM, Abraham JP, Frame B. Functional and ultrastructural abnormalities of platelets in ehlers-danlos syndrome. *Ann Intern Med* 1965; **63**: 249-254 [PMID: 14322851 DOI: 10.7326/0003-4819-63-2-249]
- Bertin P, Treves R, Julia A, Gaillard S, Desproges-Gotteron R. Ehlers-Danlos syndrome, clotting disorders and muscular dystrophy. *Ann Rheum Dis* 1989; **48**: 953-956 [PMID: 2512864 DOI: 10.1136/ard.48.11.953]
- Anstey A, Mayne K, Winter M, Van de Pette J, Pope FM. Platelet and coagulation studies in Ehlers-Danlos syndrome. *Br J Dermatol* 1991; **125**: 155-163 [PMID: 1911298 DOI: 10.1111/j.1365-2133.1991.tb06063.x]
- Di Mario C, Zanchetta M, Maiolino P. Coronary aneurysms in a case of Ehlers-Danlos syndrome. *Jpn Heart J* 1988; **29**: 491-496 [PMID: 3184455 DOI: 10.1536/ihj.29.491]
- Eriksen UH, Aunsholt NA, Nielsen TT. Enormous right coronary arterial aneurysm in a patient with type IV Ehlers-Danlos syndrome. *Int J Cardiol* 1992; **35**: 259-261 [PMID: 1572746 DOI: 10.1016/0167-5273(92)90185-6]
- Eltchaninoff H, Cribier A, Letac B. Multiple spontaneous coronary artery dissections in young woman. *Lancet* 1995; **346**: 310-311 [PMID: 7630265 DOI: 10.1016/S0140-6736(95)92196-6]
- Catanese V, Venot P, Lemesle F, Delille F, Runge I, Kuchly B. Myocardial infarction by spontaneous dissection of coronary arteries in a subject with type IV Ehlers-Danlos syndrome. *Presse Med* 1995; **24**: 1345-1347 [PMID: 7494846]
- Athanassiou AM, Turrentine MA. Myocardial infarction and coronary artery dissection during pregnancy associated with type IV Ehlers-Danlos syndrome. *Am J Perinatol* 1996; **13**: 181-183 [PMID: 8688112 DOI: 10.1055/s-2007-994321]
- Zied ME, Khalil MN, Wilson MF. Assessment of myocardial perfusion by cardioline stress testing in a young woman with Ehler-Danlos syndrome and coronary dissection. *Am J Med* 1999; **107**: 295-296 [PMID: 10492330 DOI: 10.1016/S0002-9343(99)00180-1]
- Trichon BH, Zidar JP, Bashore TM, Donahue M, Sketch MH. Acute myocardial infarction in a young female. *J Invasive Cardiol* 2001; **13**: 597-59, discussion 597-59, [PMID: 11481510]
- Dieter RS, Murtaugh T, Black J, Russell DC. Coronary arteriomegaly in a patient with Ehlers-Danlos syndrome and multiple aneurysms--a case report. *Angiology* 2003; **54**: 733-736 [PMID: 14666965 DOI: 10.1177/000331970305400616]
- Rosendaal FR, Siscovick DS, Schwartz SM, Beverly RK, Psaty BM, Longstreth WT, Raghunathan TE, Koepsell TD, Reitsma PH. Factor V Leiden (resistance to activated protein C) increases the risk of myocardial infarction in young women. *Blood* 1997; **89**: 2817-2821 [PMID: 9108400]
- Español I, Hernández A, Pujol RM, Urrutia T, Pujol-Moix N. Type IV Ehlers-Danlos syndrome with platelet delta-storage pool disease. *Ann Hematol* 1998; **77**: 47-50 [PMID: 9760152]

P- Reviewers: Aviner S, Sahu RP S- Editor: Gou SX  
L- Editor: A E- Editor: Wu HL



## Successful recanalization with multimodality endovascular interventional therapy in acute ischemic stroke

Amorn Jongsathapongpan, Anuchit Raumthanthong, Sombat Muengtaweepongsa

Amorn Jongsathapongpan, Department of Cardiology, Phyathai 2 Hospital (Bangkok Hospital Group), Bangkok 10400, Thailand  
Anuchit Raumthanthong, Department of Radiology, Pramongkutklao Hospital, Bangkok 10400, Thailand

Sombat Muengtaweepongsa, Department of Medicine, Thammasat University, PathumThani 12120, Thailand

**Author contributions:** Jongsathapongpan A and Muengtaweepongsa S designed the report, collected data and wrote the report; Jongsathapongpan A and Raumthanthong A performed the procedure; Muengtaweepongsa S set up the protocol for patient selection; Raumthanthong A performed the angiogram and imaging diagnosis. Supported by The National Research University Project of Thailand Office of Higher Education Commission, Thammasat University, Thailand

**Correspondence to:** Sombat Muengtaweepongsa, MD, Department of Medicine, Thammasat University, Rangsit Campus, 99 Moo 18, Paholyothin Road, KlongNueng, KlongLuang, Pathumthani 12120, Thailand. sombatm@hotmail.com

Telephone: +66-29-269794 Fax: +66-29-269793

Received: November 9, 2013 Revised: January 7, 2014

Accepted: January 17, 2014

Published online: March 16, 2014

in acute large vessel stroke from a single stroke center in Thailand. Patient screening and selection with multimodal imaging protocol and multimodality methods of endovascular interventional therapy are described.

© 2014 Baishideng Publishing Group Co., Limited. All rights reserved.

**Key words:** Acute ischemic stroke; Intra-arterial thrombolysis; Endovascular therapy; Mechanical thrombectomy

**Core tip:** We report seven patients with successful recanalization after endovascular treatment in acute large vessel stroke from a single stroke center in Thailand. Patient screening and selection with multimodal imaging protocol and multimodality methods of endovascular interventional therapy are described.

Jongsathapongpan A, Raumthanthong A, Muengtaweepongsa S. Successful recanalization with multimodality endovascular interventional therapy in acute ischemic stroke. *World J Clin Cases* 2014; 2(3): 78-85 Available from: URL: <http://www.wjgnet.com/2307-8960/full/v2/i3/78.htm> DOI: <http://dx.doi.org/10.12998/wjcc.v2.i3.78>

### Abstract

Stroke is an important cause of death and disability in adults. However, effective treatments for patients with acute ischemic stroke are limited. Intravenous recombinant tissue plasminogen activator (*iv* rtPA) within 4.5 h after onset has been approved as a standard treatment for patients with acute ischemic stroke. However, due to time constraints, less than one percent of acute ischemic stroke patients in Thailand are able to obtain *iv* rtPA. Although endovascular interventional therapy has not yet been approved as standard treatment in acute ischemic stroke, it is the one of the potentially effective treatment options. There are several reliable methods of endovascular therapy for acute ischemic stroke patients. Endovascular interventional therapy has rarely been done in Thailand. We report seven patients with successful recanalization after endovascular treatment

### INTRODUCTION

Stroke is the leading cause of adult disability, particularly in the elderly, and remains the third most common cause of death in the developing world, as well as in Thailand<sup>[1,2]</sup>. Despite improving the quality of stroke management, morbidity and mortality related to stroke remain significant<sup>[3]</sup>. Intravenous recombinant tissue plasminogen activator (*iv* rtPA) is a standard treatment for patients with acute ischemic stroke<sup>[4]</sup>. The NINDS study shows that *iv* rtPA given within 3 h of stroke onset improves the modified Rankin Scale (mRS) at 90 d<sup>[5]</sup>. The recent



**Table 1** Summary of clinical presentation, treatment provided and clinical outcome

	Sex	Age	Location	NIHSS	Onset (h)	AF	<i>iv</i> rtPA (mg)	<i>ia</i> rtPA(mg)	Solitaire	Penumbra	Carotid stent	Final mRS	Any ICH	sICH
1	F	56	ICA	20	3	-	59	8	Y	-	-	2	N	N
2	F	80	BA	NA	5.5	Y	-	-	-	032"	-	4	N	N
3	M	64	ICA, M1	10	5.5	-	-	-	-	-	Wall stent	1	N	N
4	M	81	BA	30	13	Y	-	-	Y	-	-	0	N	N
5	M	61	M1	9	6	-	-	5	-	-	-	0	Y	N
6	F	87	BA	NA	5	Y	-	5	-	041"	-	4	N	N
7	M	70	M1	NA	5	-	-	5	-	041"	-	2	Y	N

F: Female; M: Male; ICA: Internal carotid artery; BA: Basilar artery; NIHSS: National Institutes of Health Stroke Scale; *iv* rtPA: Intravenous recombinant tissue plasminogen activator; *ia* rtPA: Intra-arterial recombinant tissue plasminogen activator; NA: Not available; Y: Yes; N: Not.

ECASS3 trial expands indication of intravenous rtPA to 4.5 h<sup>[6]</sup>. Clinical benefit from *iv* rtPA to Thai stroke patients has been shown in studies<sup>[7,8]</sup>. However, most stroke patients are still not able to get *iv* rtPA due to delayed arrival and tight exclusion criteria<sup>[9]</sup>.

Identification of ischemic penumbra with diffusion-perfusion mismatch by magnetic resonance imaging (MRI) may have a role in patient selection for further treatment in acute ischemic stroke<sup>[10,11]</sup>. However, the benefit on clinical outcomes of this imaging selection for endovascular treatment in patients with acute ischemic stroke is still controversial<sup>[12]</sup>.

Intra-arterial thrombolysis is a viable option to some patients who arrive after the 3 h<sup>[13]</sup>. The PROACT II trial showed that recanalization rate and functional outcomes are better with intra-arterial thrombolysis<sup>[14]</sup>. Mechanical thromboembolism in acute ischemic stroke has received intense interest in recent years. The multi MERCI trial shows that clot removal with the device, which can be done up to 8 h after stroke onset, raises the recanalization rate up to 60%<sup>[15]</sup>. The Penumbra Pivotal trial shows that continuous thrombus aspiration with a Penumbra catheter can improve the recanalization rate to more than 80%<sup>[16]</sup>. The SWIFT trial shows that clot extraction with the Solitaire device in large vessel occlusion, including internal carotid artery (ICA), middle cerebral artery part 1 (M1), middle cerebral artery part 2 (M2) and basilar artery (BA), also provides a recanalization rate of up to 80%<sup>[17]</sup>. Unfortunately, the two most recent trials published in a landmark journal do not show any benefit in functional outcomes from endovascular treatment in acute ischemic stroke<sup>[18,19]</sup>.

In Thailand, endovascular interventional therapy rarely has been performed in patients with acute ischemic stroke. Intra-arterial recombinant tissue plasminogen activator (*ia* rtPA) is an option in some medical centers. Imaging selection is also optional for decision making in some centers. Recently, Solitaire and Penumbra devices have been available for commercial use. We report our initial experiences with these procedures.

Phyathai 2 is a private hospital located in central of Bangkok. This 200 bed hospital provides 20 intensive care unit beds for medical intensive conditions, including acute ischemic stroke. The medical records of patients who received endovascular interventional therapy

for acute large vessel occlusion (ICA, M1, M2 and BA) in Phyathai 2 Hospital during February 2010 to January 2013 were reviewed.

### Endovascular interventional therapy protocol

Acute ischemic stroke patients who were not eligible for *iv* rtPA or who still had significant deficits after *iv* rtPA were evaluated by the stroke neurologist (SM). A stroke interventional team (Jongsathapongpan A, Raumthan-thong A) was alerted. Multimodal MRI (conventional MRI with MRA and MR perfusion) was done on an emergency basis. If the diffusion-perfusion mismatch was more than 20%, the patient would be transferred to the catheterization lab for endovascular treatment. The anesthesiologist was standing by in the catheterization lab.

The right femoral artery was cannulated with an 8 F sheath. Selective angiography of the carotid or vertebral artery was done with a 5 F Simmon 1 or a 5 F JR4 catheter. The aortic arch angiogram and 4 vessel DSA were not routinely performed. If an occluded artery was confirmed, a 6 F 90 cm sheath was placed as far as a distal cervical ICA or a distal V2 segment. A 018 microcatheter was advanced over the guidewire to the occlusion site. Low dose *ia* rtPA (less than 5 mg) was given. If no clot lysis was seen, continuous clot aspiration using a Penumbra device or clot extraction with a Solitaire device was performed.

## CASE REPORT

We identified 7 cases. Age ranged from 56-87 years. National Institutes of Health Stroke Scale (NIHSS) ranged from 9-30. Multimodal MRI was done in 6 of 7 cases (86%). There were 2 patients with ICA occlusion, 2 with middle cerebral artery (MCA) occlusion and 3 with BA occlusion. Carotid stenting was performed in one case. *ia* rtPA, mechanical thrombectomy and combined treatment were done in 4, 5 and 3 cases, respectively. Solitaire and Penumbra devices were used in 2 and 3 cases, respectively. Only 1 patient received intervention after intravenous thrombolysis. Case presentation and treatment are summarized in Table 1.

### Case 1

Left distal ICA occlusion opened with *ia* rtPA and

**Solitaire device:** A 56-year-old female presented with right hemiparesis and aphasia. She arrived at hospital 1 h after onset. Emergency computed tomography (CT) brain showed cord sign in left MCA and distal ICA. Initial NIHSS was 20. Electrocardiography (EKG) showed normal sinus rhythm. Echocardiography showed no intracardiac thrombus. *iv* rtPA was given 90 min after onset. No neurological improvement was noted. Two hours after *iv* rtPA, angiography was done. We found distal ICA occlusion. Balloon inflation with a 2.0 mm  $\times$  15 mm coronary balloon was attempted without success. Eight milligrams of *ia* rtPA was infused. No clot lysis was seen. Then, a 4.0  $\times$  15 Solitaire device was deployed 5 h after onset. Immediate angiography showed thrombolysis in cerebral infarction (TICI) 2 flow. The Solitaire was slowly pulled back and a large thrombus was removed. Residual stenosis of mid M1 persisted but it resolved after 1 mg of nimodipine. Final angiography showed TICI 3 in M1 and anterior cerebral artery part 1 (A1). Occlusion of anterior cerebral artery part 2 (A2) was noted. No further intervention was attempted. Six months after the procedure, mRS was 2 (Figure 1A and B).

### Case 2

**BA occlusion opened with *ia* rtPA and Penumbra device:** An 80-year-old female presented with alteration of consciousness. She had hypertension and chronic AF. Warfarin had been discontinued during the last month for unknown reasons. Immediate CT brain showed hyperdense basilar artery. MRI and MRA brain revealed small right cerebellar infarction and occlusion of mid basilar artery. Patent bilateral fetal type posterior cerebral artery was noted. Echocardiography showed no intracardiac thrombus. She was transferred to the catheterization lab 5.5 h after onset. Angiogram showed near occlusion of mid BA. Continuous thrombus aspiration with a 032 Penumbra catheter was done. TICI 3 was seen from proximal to mid basilar artery and bilateral superior cerebellar artery. Occluded distal basilar artery could not be opened. MRI brain on the next day showed bilateral superior cerebellar infarction. No intracranial hemorrhage was seen. After 3 mo mRS was only 4. Four months later, she suffered from a left MCA stroke despite dabigatran maintenance. No thrombolytic drug was given because of late presentation (Figure 1C and D).

### Case 3

**Tandem ostial left ICA and distal M1 occlusion opened with carotid stent:** A 64-year-old male was admitted for prostate surgery. Two days after the operation, he developed a right hemiparesis and dysphasia. Initial NIHSS was 10. MRI and MRA brain showed small left MCA infarction and severe ostial left ICA stenosis. Because of symptom fluctuation, *iv* rtPA was not given. Endovascular treatment was done because of a large diffusion-perfusion mismatch ( $> 20\%$ ). Angiography was done 5.5 h after onset. Critical ostial ICA stenosis and oc-

clusion of supraclinoid ICA were seen. After deployment of a distal protection device, carotid stenting was done using 7.0 mm  $\times$  30 mm WALLSTENT™. Angiogram showed good flow of left ICA. Occluded distal M1 was noted. No further intervention was attempted because of good collateral flow. Two days after the procedure, NIHSS was 1 and mRS was 1 (Figure 1E and F).

### Case 4

#### Basilar artery occlusion opened with Solitaire device:

An 81-year-old male presented with left hemiparesis. He arrived at hospital 7 h after onset. He had hypertension, dyslipidemia and chronic atrial fibrillation. Echocardiography revealed no intracardiac thrombus. MRI and MRA brain showed small right cerebellar infarction and mid basilar artery occlusion. He was transferred to the catheterization lab 13 h after onset. Angiography showed tortuous left vertebral artery and occluded proximal BA. We failed to advance a 5 F hydrophilic catheter over the left vertebral artery. Then, a homemade 90 cm shortened JR 7 F guiding catheter was placed at the proximal vertebral artery. A 4.0 mm  $\times$  15 mm Solitaire was deployed at the basilar artery. After thrombus extraction, TICI 3 flow of basilar was noted. Some residual thrombus remained in the basilar artery. No further intervention was attempted. He regained full consciousness the next day. Final NIHSS was 1 and mRS was 0 (Figure 1G and H).

### Case 5

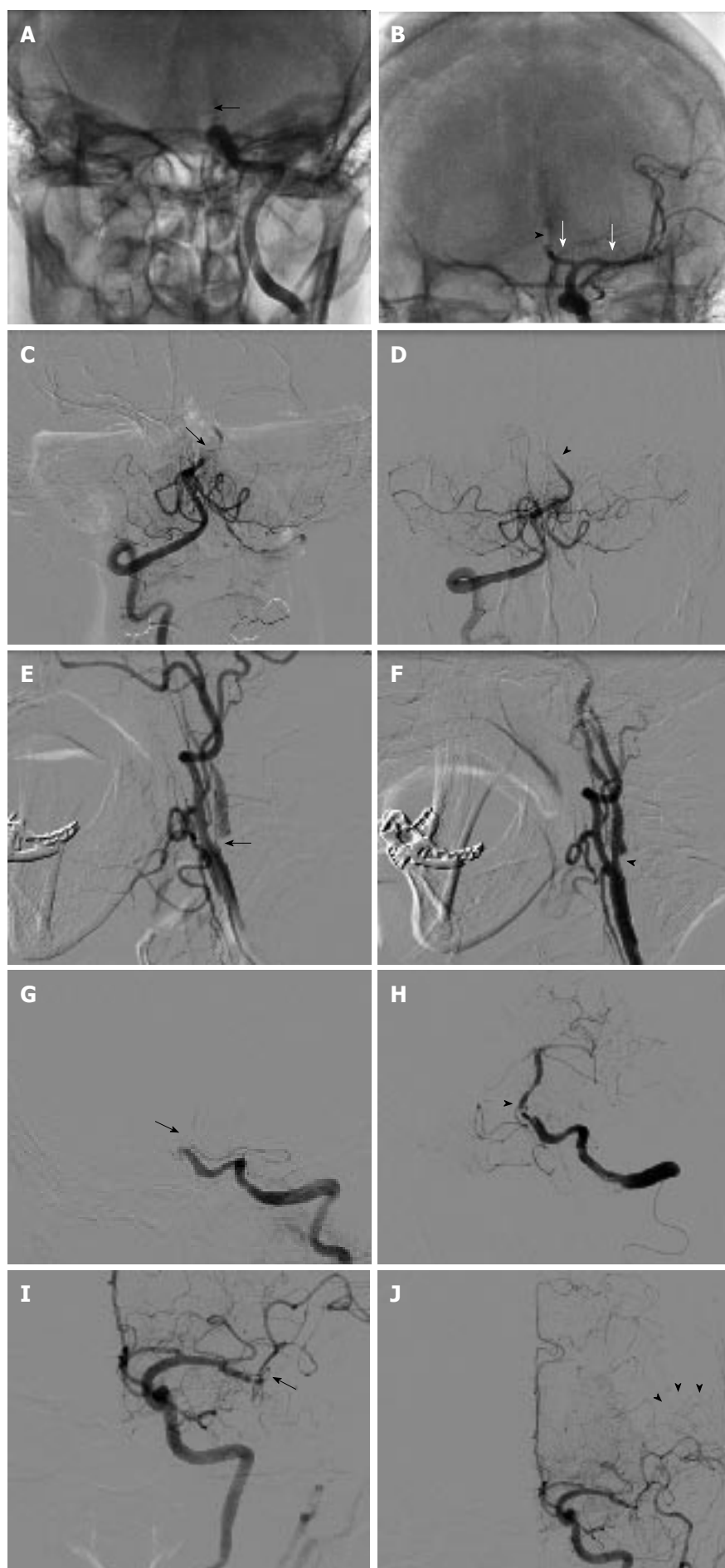
#### Left distal M1 occlusion opened with *ia* rtPA:

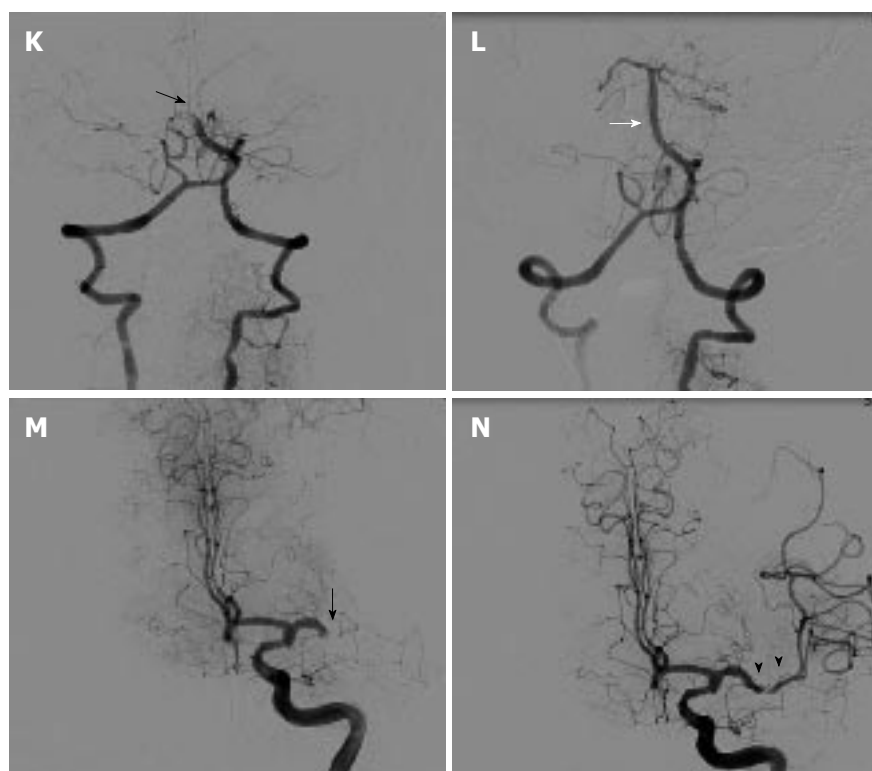
A 61-year-old male presented with right arm weakness and dysphasia. He arrived at hospital 1 h after onset. Initial NIHSS was 9. EKG was sinus rhythm. Echocardiography showed no intracardiac thrombus. MRI and MRA brain revealed small infarction in the left MCA area and left distal M1 occlusion. A large diffusion-perfusion mismatch was seen. He was transferred to the catheterization lab 4 h after onset. Angiography showed occlusion of superior M2 and slowed flow in the inferior M2 branch. Good pial collateral flow to the left superior M2 area was seen. Five milligrams of *ia* rtPA was given. TICI 3 flow of M1 and inferior M2 was noted. The superior M2 branch was still occluded. No further intervention was attempted. CT brain on the next day showed small spot hemorrhage in the left temporal lobe and small infarction of the left corona radiata. Right hemiparesis improved after the procedure. Three months later, he had only mild dysphasia and mRS was 0 (Figure 1I and J).

### Case 6

#### BA occlusion opened with *ia* rtPA and Penumbra device:

An 87-year-old female patient was referred to our hospital because of loss of consciousness. Initial CT scan showed no significant hypodense area. EKG showed atrial fibrillation. MRI and MRA brain showed left pontine infarction and small bilateral cerebellar infarction. She was transferred to the catheterization lab 5 h after onset.





**Figure 1 Case angiogram.** A: Pre-procedure imaging showed occlusion of distal left internal carotid artery (black arrow); B: Post-procedure imaging showed good flow of middle cerebral artery (MCA) and A1 (white arrow), occlusion of A2 (arrowhead) was noted; C: Pre-procedure imaging showed near total occlusion of mid basilar artery (BA) (black arrow); D: Post-procedure imaging showed improved in mid BA, distal BA (arrowhead) still occluded; E: Pre-procedure imaging showed critical stenosis of ostial left including internal carotid artery (ICA) (black arrow); F: Post-procedure imaging showed mild residual stenosis of proximal ICA after carotid stenting (arrowhead); G: Pre-procedure imaging showed proximal BA occlusion (black arrow); H: Post-procedure imaging showed patent BA with some residual thrombus in proximal part (arrowhead); I: Pre-procedure imaging showed thrombotic occlusion of superior M2 branch and slow flow of inferior M2 branch (black arrow); J: Post-procedure imaging showed good flow of inferior M2 branch, superior M2 branch still occluded and that area was supplied from pial collateral (arrowhead); K: Pre-procedure imaging showed occlusion of distal BA (black arrow); L: Post-procedure imaging showed patent BA (white arrow) and right posterior cerebral artery (PCA), with left PCA still occluded (arrowhead); M: Pre-procedure imaging showed occlusion of distal left M1 (black arrow); N: Post-procedure imaging showed good flow of left MCA (arrowhead) and all branches.

Angiogram showed occlusion of distal BA. *ia* rtPA 5 mg was given without improvement. Four minutes of continuous thrombus aspiration with a Penumbra 041 catheter was done. Complete clot removal was seen. FU CT brain on the next day showed no intracranial hemorrhage but a new right occipital lobe infarction was seen. Despite the good angiographic outcome, she only had mRS 4 on the final visit (Figure 1K and L).

### Case 7

**Left M1 occlusion opened with *ia* rtPA and Penumbra device:** A 70-year-old male patient was referred to our hospital because of stupor, right hemiplegia and aphasia. He had diabetes, hypertension and was post coronary artery bypass surgery. EKG showed normal sinus rhythm. Echocardiography showed no intracardiac thrombus. Initial CT scan showed old cerebral infarction and so *iv* rtPA was not given. MRI and MRA brain showed occlusion of left M1. DWI showed no acute infarction. He was transferred to the catheterization lab 5 h after onset. Angiogram showed occlusion of left distal M1. *ia* rtPA 5 mg was given via a Rebar microcatheter without success. Three minutes of continuous aspiration

with Penumbra 041 catheter was done. Complete clot removal was seen. CT brain on the next day showed small subarachnoid hemorrhage in the left sylvian fissure. No new infarction was seen. Three months later, he had only mild weakness of the right arm and mRS was 2 (Figure 1M and N).

## DISCUSSION

We described 7 cases of endovascular treatment with successful recanalization in acute ischemic stroke patients. Good outcome, defined by mRS less than 2, were found in 5 of 7 cases (71%). When mechanical thromboembolism devices were used, successful recanalization rate and good outcome were found in 80% and 60%, respectively, which are comparable to 81% and 25%, respectively in the PENUMBRA pivotal trial and 61% and 58%, respectively in the SWIFT trials. There was no mortality in our series, compared to 38% in the PENUMBRA pivotal trial and 17% in the SWIFT trial. In our series, intracranial hemorrhage and symptomatic intracranial hemorrhage were found in 28% and 0%, respectively, which is comparable to 28% and 11%, respectively in the



PENUMBRA pivotal trial and 17% and 2%, respectively in the SWIFT trial<sup>[16,17]</sup>. In our case series, younger (less than 80 years old) patients and good collateral supply were good prognostic indicators. We observed that in patients under 80 years old, all patients had good outcome (4 of 4) and in the presence of collateral supply (case 3 and case 5) a good outcome may be achieved even if the direct flow cannot be restored.

Multimodal MRI is the most reliable study to select the patients<sup>[20,21]</sup>. Patients with a small infarct core but large diffusion-perfusion mismatch are more likely to have better outcomes<sup>[21-23]</sup>. There is evidence that multimodal CT is also able to identify the infarct core and penumbra area<sup>[21,24]</sup>. However, high dose of iodinated contrast usage during CT may be contra-indicated in some patients<sup>[25]</sup>. Application of the ASPECT score with multimodal CT may be helpful for patient selection and outcome prediction<sup>[26,27]</sup>.

Intra-arterial thrombolysis is one of preferred treatments in some centers<sup>[13,28]</sup>. Based on the PROACT trial, patency rate (TICI 2, 3) was 66% and mRS less than 2 at the 90<sup>th</sup> day was 40%, but in our case series, no clot lysis was found in any case<sup>[14]</sup>. It might be due to the limited dose of rtPA we used (less than 5 mg) and that the waiting time was too short (average 10-20 min). Anyway, we believed that *ia* rtPA still had a role in some patients, such as patients with small thrombus burden and patients with very tortuous neck arteries. However, it is likely that the role of *ia* rtPA will be surpassed by high efficacy mechanical devices in the near future<sup>[29]</sup>.

Recently, mechanical thrombectomy devices in acute stroke have received intense interest<sup>[29,30]</sup>. High patency rate (61%-86%) and improved clinical outcome were reported in the SWIFT, PENUMBRA and TREVO trials<sup>[16,17,31]</sup>. However, individual devices may have their own technical issues. A stent based device, using a dragging method, may cause thrombus embolization into new territory. The possible solutions for this problem are to allow the device to “ingest” the thrombus for few minutes, to slowly pull back (1 cm/min) and to add aspiration force through the sheath or guide catheter. The advantage points of stent based devices are small delivery profile and speed of recanalization<sup>[32]</sup>.

Continuous thrombus aspiration using a Penumbra device has one inherited problem, that is “profile”<sup>[33]</sup>. Because of a larger profile, it may require delivery in triaxial fashion over the guidewire and microcatheter. The strong advantage of a Penumbra device is more complete clot removal and less embolization into new territory<sup>[33]</sup>. This could benefit the patients with large thrombus burden and in the situation with residual thrombus after the dragging method. The aspiration method, compared to the dragging method, is perceived to result in less vessel trauma. Clinical trials reported no difference in intracranial hemorrhage, compared to the Solitaire device<sup>[29,30,33]</sup>.

We plan to reduce time to recanalization in our center. Focused stroke MRI protocol may shorten it by a

few minutes in this critical condition. Using multimodal CT instead of MRI may also be a time saver. An interventionist should be available 24/7. Activation of the interventional team during the imaging study is crucial. Using mechanical thromboembolism as a first line treatment, instead of intra-arterial thrombolysis, should be of benefit.

## COMMENTS

### Case characteristics

The authors report seven patients with successful recanalization after endovascular treatment in acute large vessel stroke from a single stroke center in Thailand.

### Clinical diagnosis

There were 2 patients with internal carotid artery occlusion, 2 with middle cerebral artery occlusion and 3 with basilar artery (BA) occlusion.

### Imaging diagnosis

Multimodal magnetic resonance imaging was done in 6 of 7 cases (86%).

### Treatment

Carotid stenting was performed in one case. Intra-arterial recombinant tissue plasminogen activator, mechanical thrombectomy and combined treatment were done in 4, 5 and 3 cases, respectively. Solitaire and Penumbra devices were used in 2 and 3 cases, respectively.

### Related reports

Multimodal magnetic resonance imaging (MRI) is the most reliable study to select the patients.

### Experiences and lessons

Focused stroke MRI protocol may reduce time by a few minutes in this critical condition. Using multimodal computer tomography instead of MRI may also be a time saver.

### Peer review

The manuscript is a nicely written collection of 7 cases of acute ischemic stroke that were treated with various endovascular techniques. The report is worthy of being published.

## REFERENCES

- 1 **Lopez AD**, Mathers CD, Ezzati M, Jamison DT, Murray CJ. Global and regional burden of disease and risk factors, 2001: systematic analysis of population health data. *Lancet* 2006; **367**: 1747-1757 [PMID: 16731270 DOI: 10.1016/S0140-6736(06)68770-9]
- 2 **Hanchaiphoboolkul S**, Pongvarin N, Nidhinandana S, Suwanwela NC, Puthkhao P, Towanabut S, Tantirittisak T, Suwantamee J, Samsen M. Prevalence of stroke and stroke risk factors in Thailand: Thai Epidemiologic Stroke (TES) Study. *J Med Assoc Thai* 2011; **94**: 427-436 [PMID: 21591527]
- 3 **Pongvarin N**. Burden of stroke in Thailand. *Int J Stroke* 2007; **2**: 127-128 [PMID: 18705969 DOI: 10.1111/j.1747-4949.2007.00104.x]
- 4 **Adams HP**, del Zoppo G, Alberts MJ, Bhatt DL, Brass L, Furlan A, Grubb RL, Higashida RT, Jauch EC, Kidwell C, Lyden PD, Morgenstern LB, Qureshi AI, Rosenwasser RH, Scott PA, Wijdicks EF. Guidelines for the early management of adults with ischemic stroke: a guideline from the American Heart Association/American Stroke Association Stroke Council, Clinical Cardiology Council, Cardiovascular Radiology and Intervention Council, and the Atherosclerotic Peripheral Vascular Disease and Quality of Care Outcomes in Research Interdisciplinary Working Groups: the American Academy of Neurology affirms the value of this guideline as an educational tool for neurologists. *Stroke* 2007; **38**: 1655-1711 [PMID: 17431204]
- 5 **Tissue plasminogen activator for acute ischemic stroke**. The National Institute of Neurological Disorders and Stroke

- rt-PA Stroke Study Group. *N Engl J Med* 1995; **333**: 1581-1587 [PMID: 7477192]
- 6 **Hacke W**, Kaste M, Bluhmki E, Brozman M, Dávalos A, Guidetti D, Larrue V, Lees KR, Medeghri Z, Machnig T, Schneider D, von Kummer R, Wahlgren N, Toni D. Thrombolysis with alteplase 3 to 4.5 hours after acute ischemic stroke. *N Engl J Med* 2008; **359**: 1317-1329 [PMID: 18815396]
- 7 **Muengtaweepongsa S**, Dharmasaroja P, Kummark U. Outcomes of intravenous thrombolytic therapy for acute ischemic stroke with an integrated acute stroke referral network: initial experience of a community-based hospital in a developing country. *J Stroke Cerebrovasc Dis* 2012; **21**: 42-46 [PMID: 22225863 DOI: 10.1016/j.jstrokecerebrovasdis.2010.03.017]
- 8 **Suwanwela NC**, Phanthumchinda K, Likitjaroen Y. Thrombolytic therapy in acute ischemic stroke in Asia: The first prospective evaluation. *Clin Neurol Neurosurg* 2006; **108**: 549-552 [PMID: 16289309]
- 9 **Kasner SE**, Gorelick PB. Prevention and Treatment of Ischemic Stroke: Blue Books of Practical Neurology Series. Oxford: Butterworth-Heinemann, 2004: 267-281
- 10 **Davis SM**, Donnan GA, Parsons MW, Levi C, Butcher KS, Peeters A, Barber PA, Bladin C, De Silva DA, Byrnes G, Chalk JB, Fink JN, Kimber TE, Schultz D, Hand PJ, Frayne J, Hankey G, Muir K, Gerraty R, Tress BM, Desmond PM. Effects of alteplase beyond 3 h after stroke in the Echoplanar Imaging Thrombolytic Evaluation Trial (EPITHET): a placebo-controlled randomised trial. *Lancet Neurol* 2008; **7**: 299-309 [PMID: 18296121 DOI: 10.1016/S1474-4422(08)70044-9]
- 11 **Albers GW**, Thijs VN, Wechsler L, Kemp S, Schlaug G, Skalabrín E, Bammer R, Kakuda W, Lansberg MG, Shuaib A, Coplin W, Hamilton S, Moseley M, Marks MP. Magnetic resonance imaging profiles predict clinical response to early reperfusion: the diffusion and perfusion imaging evaluation for understanding stroke evolution (DEFUSE) study. *Ann Neurol* 2006; **60**: 508-517 [PMID: 17066483 DOI: 10.1002/ana.20976]
- 12 **Kidwell CS**, Jahan R, Gornbein J, Alger JR, Nenov V, Ajani Z, Feng L, Meyer BC, Olson S, Schwamm LH, Yoo AJ, Marshall RS, Meyers PM, Yavagal DR, Wintermark M, Guzy J, Starkman S, Saver JL. A trial of imaging selection and endovascular treatment for ischemic stroke. *N Engl J Med* 2013; **368**: 914-923 [PMID: 23394476 DOI: 10.1056/NEJMoa1212793]
- 13 **Nguyen TN**, Babikian VL, Romero R, Pikula A, Kase CS, Jovin TG, Norbash AM. Intra-arterial treatment methods in acute stroke therapy. *Front Neurol* 2011; **2**: 9 [PMID: 21516256]
- 14 **Furlan A**, Higashida R, Wechsler L, Gent M, Rowley H, Kase C, Pessin M, Ahuja A, Callahan F, Clark WM, Silver F, Rivera F. Intra-arterial prourokinase for acute ischemic stroke. The PROACT II study: a randomized controlled trial. *Prolyse in Acute Cerebral Thromboembolism. JAMA* 1999; **282**: 2003-2011 [PMID: 10591382 DOI: 10.1001/jama.282.21.2003]
- 15 **Smith WS**, Sung G, Saver J, Budzik R, Duckwiler G, Liebeskind DS, Lutsep HL, Rymer MM, Higashida RT, Starkman S, Gobin YP, Frei D, Grobelny T, Hellinger F, Huddle D, Kidwell C, Koroshetz W, Marks M, Nesbit G, Silverman IE. Mechanical thrombectomy for acute ischemic stroke: final results of the Multi MERCI trial. *Stroke* 2008; **39**: 1205-1212 [PMID: 18309168 DOI: 10.1161/STROKEAHA.107.497115]
- 16 **Penumbra Pivotal Stroke Trial I**. The penumbra pivotal stroke trial: safety and effectiveness of a new generation of mechanical devices for clot removal in intracranial large vessel occlusive disease. *Stroke* 2009; **40**: 2761-2768 [PMID: 19590057 DOI: 10.1161/STROKEAHA.108.544957]
- 17 **Saver JL**, Jahan R, Levy EI, Jovin TG, Baxter B, Nogueira RG, Clark W, Budzik R, Zaidat OO. Solitaire flow restoration device versus the Merci Retriever in patients with acute ischaemic stroke (SWIFT): a randomised, parallel-group, non-inferiority trial. *Lancet* 2012; **380**: 1241-1249 [PMID: 22932715 DOI: 10.1016/S0140-6736(12)61384-1]
- 18 **Ciccone A**, Valvassori L, Nichelatti M, Sgoifo A, Ponzio M, Sterzi R, Boccardi E. Endovascular treatment for acute ischemic stroke. *N Engl J Med* 2013; **368**: 904-913 [PMID: 23387822 DOI: 10.1056/NEJMoa1213701]
- 19 **Broderick JP**, Palesch YY, Demchuk AM, Yeatts SD, Khatri P, Hill MD, Jauch EC, Jovin TG, Yan B, Silver FL, von Kummer R, Molina CA, Demaerschalk BM, Budzik R, Clark WM, Zaidat OO, Malisch TW, Goyal M, Schonewille WJ, Mazighi M, Engelter ST, Anderson C, Spilker J, Carrozzella J, Ryckborst KJ, Janis LS, Martin RH, Foster LD, Tomsick TA. Endovascular therapy after intravenous t-PA versus t-PA alone for stroke. *N Engl J Med* 2013; **368**: 893-903 [PMID: 23390923 DOI: 10.1056/NEJMoa1214300]
- 20 **Chaturvedi S**, Selim M. Multimodal imaging for acute stroke: when is it worth it? *Neurology* 2013; **81**: 608-609 [PMID: 23851961 DOI: 10.1212/WNL.0b013e3182a08f98]
- 21 **Fisher M**, Albers GW. Advanced imaging to extend the therapeutic time window of acute ischemic stroke. *Ann Neurol* 2013; **73**: 4-9 [PMID: 23378323 DOI: 10.1002/ana.23744]
- 22 **Lansberg MG**, Straka M, Kemp S, Mlynash M, Wechsler LR, Jovin TG, Wilder MJ, Lutsep HL, Czartoski TJ, Bernstein RA, Chang CW, Warach S, Fazekas F, Inoue M, Tipirneni A, Hamilton SA, Zaharchuk G, Marks MP, Bammer R, Albers GW. MRI profile and response to endovascular reperfusion after stroke (DEFUSE 2): a prospective cohort study. *Lancet Neurol* 2012; **11**: 860-867 [PMID: 22954705 DOI: 10.1016/S1474-4422(12)70203-X]
- 23 **Lemmens R**, Mlynash M, Straka M, Kemp S, Bammer R, Marks MP, Albers GW, Lansberg MG. Comparison of the response to endovascular reperfusion in relation to site of arterial occlusion. *Neurology* 2013; **81**: 614-618 [PMID: 23851962 DOI: 10.1212/WNL.0b013e3182a08f07]
- 24 **Campbell BC**, Christensen S, Levi CR, Desmond PM, Donnan GA, Davis SM, Parsons MW. Comparison of computed tomography perfusion and magnetic resonance imaging perfusion-diffusion mismatch in ischemic stroke. *Stroke* 2012; **43**: 2648-2653 [PMID: 22858726 DOI: 10.1161/STROKEAHA.112.660548]
- 25 **Tarlov N**, Nien YL, Zaidat OO, Nguyen TN. Periprocedural management of acute ischemic stroke intervention. *Neurology* 2012; **79**: S182-S191 [PMID: 23008396 DOI: 10.1212/WNL.0b013e31826958d3]
- 26 **Kent DM**, Hill MD, Ruthazer R, Coutts SB, Demchuk AM, Dzialowski I, Wunderlich O, von Kummer R. "Clinical-CT mismatch" and the response to systemic thrombolytic therapy in acute ischemic stroke. *Stroke* 2005; **36**: 1695-1699 [PMID: 16002756]
- 27 **Yaghi S**, Bianchi N, Amole A, Hinduja A. ASPECTS is a predictor of favorable CT perfusion in acute ischemic stroke. *J Neuroradiol* 2013; Epub ahead of print [PMID: 24156874]
- 28 **Kirmani JF**, Alkawi A, Panezai S, Gizzi M. Advances in thrombolytics for treatment of acute ischemic stroke. *Neurology* 2012; **79**: S119-S125 [PMID: 23008386 DOI: 10.1212/WNL.0b013e3182695882]
- 29 **Taqi MA**, Vora N, Callison RC, Lin R, Wolfe TJ. Past, present, and future of endovascular stroke therapies. *Neurology* 2012; **79**: S213-S220 [PMID: 23008401 DOI: 10.1212/WNL.0b013e31826959e5]
- 30 **Hennerici MG**, Kern R, Szabo K. Non-pharmacological strategies for the treatment of acute ischaemic stroke. *Lancet Neurol* 2013; **12**: 572-584 [PMID: 23684083]
- 31 **Nogueira RG**, Lutsep HL, Gupta R, Jovin TG, Albers GW, Walker GA, Liebeskind DS, Smith WS. Trevo versus Merci retrievers for thrombectomy revascularisation of large vessel occlusions in acute ischaemic stroke (TREVO 2): a randomised trial. *Lancet* 2012; **380**: 1231-1240 [PMID: 22932714 DOI: 10.1016/S0140-6736(12)61299-9]
- 32 **Novakovic RL**, Toth G, Narayanan S, Zaidat OO. Retrievable stents, "stentriever," for endovascular acute ischemic stroke

therapy. *Neurology* 2012; **79**: S148-S157 [PMID: 23008390 DOI: 10.1212/WNL.0b013e3182697e9e]

- 33 **Hussain SI**, Zaidat OO, Fitzsimmons BF. The Penumbra

system for mechanical thrombectomy in endovascular acute ischemic stroke therapy. *Neurology* 2012; **79**: S135-S141 [PMID: 23008388 DOI: 10.1212/WNL.0b013e31826958a8]

**P- Reviewers:** Rafay M, Sharma V, Zhang M

**S- Editor:** Zhai HH **L- Editor:** Roemmele A **E- Editor:** Wu HL



# World Journal of *Clinical Cases*

*World J Clin Cases* 2014 April 16; 2(4): 86-119







### CASE REPORT

- 86 Rectal ulcers and massive bleeding after hemorrhoidal band ligation while on aspirin  
*Patel S, Shahzad G, Rizvon K, Subramani K, Viswanathan P, Mustacchia P*
- 90 Left ventricular pseudoaneurysm: A case report and review of the literature  
*Alapati L, Chitwood WR, Cahill J, Mehra S, Movahed A*
- 94 Varicocele repair in severe oligozoospermia: A case report of post-operative azoospermia  
*Milone M, Musella M, Sosa Fernandez ME, Maietta P, Sasso A, Sosa Fernandez LM, Sosa Fernandez LV, Milone F*
- 97 Transcatheter aortic valve implantation in a 54-year-old patient with aggressive HIV  
*Salizzoni S, D'Ascenzo F, Moretti C, Bonora S, Calcagno A, Omedè P, Montrucchio C, Cerrato E, Colaci C, Sheiban I, Marra S, Rinaldi M, Gaita F*
- 100 Elective thoracotomy for pedicle screw removal to prevent severe aortic bleeding  
*Decker S, Omar M, Krettek C, Müller CW*
- 104 Osteoid osteoma of the elbow mimicking hemophilic arthropathy  
*van den Bekerom MPJ, van Hooft MAA, Eygendaal D*
- 108 Spontaneous rupture of the renal pelvis presenting as an urinoma in locally advanced rectal cancer  
*Garg PK, Mohanty D, Rath V, Jain BK*
- 111 Rare case of an abdominal mass: Reactive nodular fibrous pseudotumor of the stomach encroaching on multiple abdominal organs  
*Yi XJ, Chen CQ, Li Y, Ma JP, Li ZX, Cai SR, He YL*

**APPENDIX** I-V Instructions to authors

**ABOUT COVER** Editorial Board Member of *World Journal of Clinical Cases*, Sebastian Decker, MD, Department of Trauma, Hannover Medical School, Carl-Neuberg-Straße 1, 30625 Hannover, Germany

**AIM AND SCOPE** *World Journal of Clinical Cases* (*World J Clin Cases*, *WJCC*, online ISSN 2307-8960, DOI: 10.12998) is a peer-reviewed open access academic journal that aims to guide clinical practice and improve diagnostic and therapeutic skills of clinicians.

The primary task of *WJCC* is to rapidly publish high-quality Autobiography, Case Report, Clinical Case Conference (Clinicopathological Conference), Clinical Management, Diagnostic Advances, Editorial, Field of Vision, Frontier, Medical Ethics, Original Articles, Clinical Practice, Meta-Analysis, Minireviews, Review, Therapeutics Advances, and Topic Highlight, in the fields of allergy, anesthesiology, cardiac medicine, clinical genetics, clinical neurology, critical care, dentistry, dermatology, emergency medicine, endocrinology, family medicine, gastroenterology and hepatology, geriatrics and gerontology, hematology, immunology, infectious diseases, internal medicine, obstetrics and gynecology, oncology, ophthalmology, orthopedics, otolaryngology, pathology, pediatrics, peripheral vascular disease, psychiatry, radiology, rehabilitation, respiratory medicine, rheumatology, surgery, toxicology, transplantation, and urology and nephrology.

**INDEXING/ABSTRACTING** *World Journal of Clinical Cases* is now indexed in PubMed Central, PubMed, Digital Object Identifier.

**FLYLEAF** I-V Editorial Board**EDITORS FOR THIS ISSUE**

Responsible Assistant Editor: *Xiang Li*  
Responsible Electronic Editor: *Su-Qing Liu*  
Proofing Editor-in-Chief: *Lian-Sheng Ma*

Responsible Science Editor: *Xiu-Xia Song*

**NAME OF JOURNAL**  
*World Journal of Clinical Cases*

**ISSN**  
ISSN 2307-8960 (online)

**LAUNCH DATE**  
April 16, 2013

**FREQUENCY**  
Monthly

**EDITORS-IN-CHIEF**  
**Giuseppe Di Lorenzo, MD, PhD, Professor**, Genitourinary Cancer Section and Rare-Cancer Center, University Federico II of Napoli, Via Sergio Pansini, 5 Ed. 1, 80131, Naples, Italy

**Jan Jacques Michiels, MD, PhD, Professor**, Primary Care, Medical Diagnostic Center Rijnmond Rotterdam, Bloodcoagulation, Internal and Vascular Medicine, Erasmus University Medical Center, Rotterdam, Goodheart Institute and Foundation, Erasmus Tower, Veenmos 13, 3069 AT, Erasmus City, Rotterdam, The Netherlands

**Sandro Vento, MD**, Department of Internal Medicine,

University of Botswana, Private Bag 00713, Gaborone, Botswana

**Shuhei Yoshida, MD, PhD**, Division of Gastroenterology, Beth Israel Deaconess Medical Center, Dana 509, Harvard Medical School, 330 Brookline Ave, Boston, MA 02215, United States

**EDITORIAL OFFICE**  
Jin-Lei Wang, Director  
Xiu-Xia Song, Vice Director  
*World Journal of Clinical Cases*  
Room 903, Building D, Ocean International Center, No. 62 Dongsihuan Zhonglu, Chaoyang District, Beijing 100025, China  
Telephone: +86-10-85381891  
Fax: +86-10-85381893  
E-mail: [bpgoffice@wjgnet.com](mailto:bpgoffice@wjgnet.com)  
<http://www.wjgnet.com>

**PUBLISHER**  
Baishideng Publishing Group Co., Limited  
Flat C, 23/F, Lucky Plaza,  
315-321 Lockhart Road, Wan Chai,  
Hong Kong, China  
Fax: +852-6555-7188  
Telephone: +852-3177-9906

E-mail: [bpgoffice@wjgnet.com](mailto:bpgoffice@wjgnet.com)  
<http://www.wjgnet.com>

**PUBLICATION DATE**  
April 16, 2014

**COPYRIGHT**  
© 2014 Baishideng Publishing Group Co., Limited. Articles published by this Open Access journal are distributed under the terms of the Creative Commons Attribution Non-commercial License, which permits use, distribution, and reproduction in any medium, provided the original work is properly cited, the use is non commercial and is otherwise in compliance with the license.

**SPECIAL STATEMENT**  
All articles published in this journal represent the viewpoints of the authors except where indicated otherwise.

**INSTRUCTIONS TO AUTHORS**  
Full instructions are available online at [http://www.wjgnet.com/2307-8960/g\\_info\\_20100722180909.htm](http://www.wjgnet.com/2307-8960/g_info_20100722180909.htm)

**ONLINE SUBMISSION**  
<http://www.wjgnet.com/esp/>

## Rectal ulcers and massive bleeding after hemorrhoidal band ligation while on aspirin

Shruti Patel, Ghulamullah Shahzad, Kaleem Rizvon, Krishnaiyer Subramani, Prakash Viswanathan, Paul Mustacchia

Shruti Patel, Department of Internal Medicine, Nassau University Medical Center, New York, NY 11554, United States  
Ghulamullah Shahzad, Kaleem Rizvon, Krishnaiyer Subramani, Prakash Viswanathan, Paul Mustacchia, Department of Gastroenterology, Nassau University Medical Center, New York, NY 11554, United States

**Author contributions:** Patel S performed an extensive literature review and drafted the case report; Shahzad G had substantial contributions in literature review and primary revision; Rizvon K, Subramani K and Viswanathan P revised it critically for important intellectual content; Mustacchia P provided the final revisions, supervised the process and gave the final approval of the version to be published.

**Correspondence to:** Shruti Patel, MD, Department of Internal Medicine, Nassau University Medical Center, East Meadow, New York, NY 11554, United States. [drshrutipatel88@yahoo.com](mailto:drshrutipatel88@yahoo.com)

Telephone: +1-516-5726501 Fax: +1-516-5725609

Received: January 18, 2013 Revised: March 8, 2014

Accepted: March 17, 2014

Published online: April 16, 2014

### Abstract

Endoscopic hemorrhoidal band ligation is a well-established nonoperative method for treatment of bleeding internal hemorrhoids (grade 1 to 3). It is a safe and effective technique with a high success rate. Complications with this procedure are uncommon. Although rectal ulceration due to band ligation is a rare complication, it can cause life-threatening hemorrhage especially when patients are on medications which impair hemostasis like aspirin or non steroidal anti-inflammatory drugs. We present 2 cases of massive lower gastro-intestinal bleeding in patients who had a band ligation procedure performed 2 wk prior to the presentation and were on aspirin at home. Both the patients were hemodynamically unstable requiring resuscitation. They required platelet and blood transfusions and were found to have rectal ulcers on colonoscopy done subsequently. The rectal ulcers corresponded to the site of band ligation. The use of aspirin by these

patients would have caused defects in the hemostasis and may have predisposed them to massive bleeding in the presence of rectal ulcers occurring after the band ligation procedure. Managing aspirin before and after the ligation may be difficult especially since adequate guidelines are unavailable. Stopping aspirin in all the cases might not be safe and the decision should be individualized.

© 2014 Baishideng Publishing Group Co., Limited. All rights reserved.

**Key words:** Hemorrhoids; Rubber band ligation; Rectal ulcers; Massive bleeding; Aspirin

**Core tip:** Rubber band ligation is known to be a relatively safe procedure. Massive bleeding and rectal ulceration is a very rare complication of this procedure. We came across two cases of severe, life-threatening lower gastrointestinal hemorrhage following endoscopic hemorrhoidal band ligation in patients on aspirin. The use of aspirin and other non-steroidal anti-inflammatory drugs can predispose to massive hemorrhage. The case report aims at creating awareness about these complications and that it may be advisable to avoid aspirin and non steroidal anti-inflammatory drugs immediately after band ligation.

Patel S, Shahzad G, Rizvon K, Subramani K, Viswanathan P, Mustacchia P. Rectal ulcers and massive bleeding after hemorrhoidal band ligation while on aspirin. *World J Clin Cases* 2014; 2(4): 86-89 Available from: URL: <http://www.wjgnet.com/2307-8960/full/v2/i4/86.htm> DOI: <http://dx.doi.org/10.12998/wjcc.v2.i4.86>

### INTRODUCTION

Hemorrhoids are dilated or bulging veins in the rectum

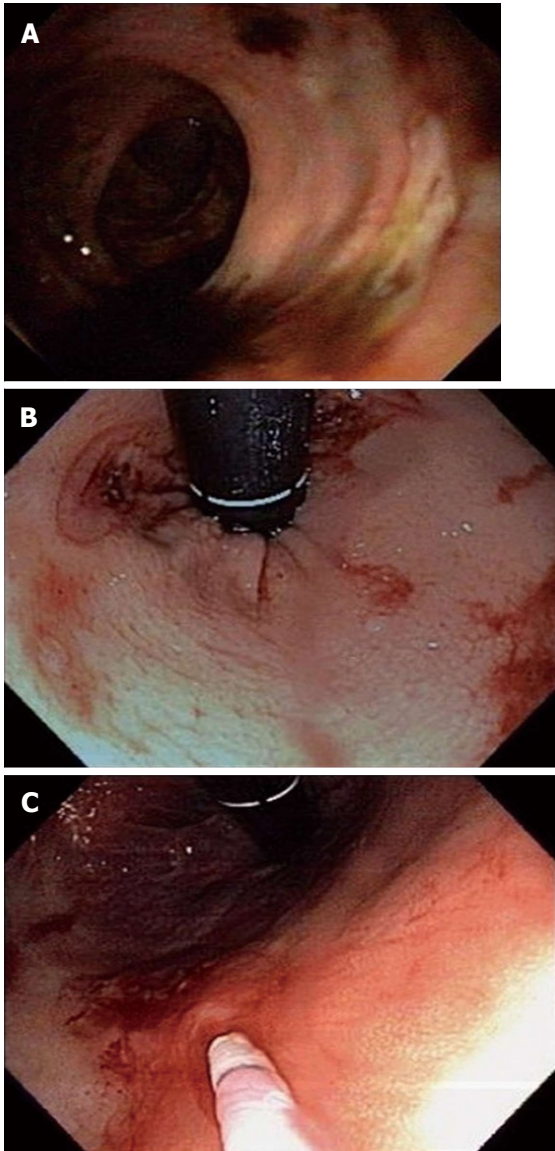


Figure 1 Endoscopic pictures of the rectal ulcers.

and/or anus caused by increased pressure in the rectal veins. They are believed to be normal anatomic structures, as demonstrated by their presence in babies<sup>[1]</sup>. Frequently, they can become a source of significant morbidity if they get inflamed or swollen. The estimated prevalence rate of symptomatic hemorrhoids in the United States is 4.4% of the adult population. More than one million individuals are affected annually by hemorrhoidal conditions<sup>[2,3]</sup>. The prevalence peaks between the ages of 45-65 and declines thereafter. It is more commonly found in whites more than blacks and the rates are higher in people from higher socioeconomic background<sup>[2]</sup>.

Elastic band ligation is a well-established nonoperative method for treatment of bleeding internal hemorrhoids (stages II-III). Usually, one or two bands are placed at a single session by using rigid instruments. Endoscopic hemorrhoidal band ligation is a safe and effective technique used in the management of hemorrhoids, with a high success rate<sup>[4]</sup>. Blaisdell<sup>[5]</sup> and Barron<sup>[6]</sup> described and

refined the band ligation therapy. Complications with this procedure are uncommon.

Massive bleeding and rectal ulceration due to band ligation is a very rare complication. The use of aspirin (acetylsalicylic acid, ASA) and other non-steroidal anti-inflammatory drugs (NSAID) can predispose to massive hemorrhage. We came across two cases of severe, life-threatening lower gastrointestinal hemorrhage following endoscopic hemorrhoidal band ligation in patients on aspirin.

## CASE REPORT

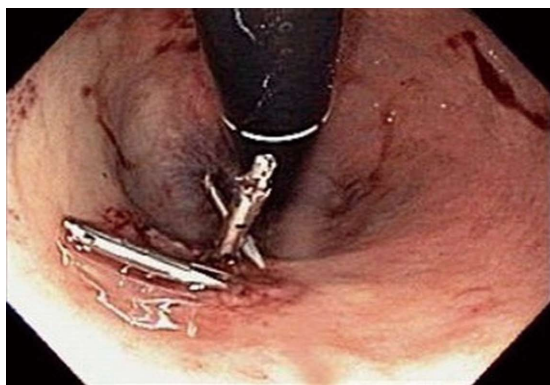
### Patient 1

A 52-year-old white man with a past medical history of anxiety and a recent band ligation for hemorrhoids 15 d prior to presentation came to the emergency room (ER) complaining of bleeding from his rectum for 2 h. He was in his usual state of health when he suddenly had a large bowel movement with bright red blood and clots. He had no other complaints such as abdominal pain, coffee ground vomiting or black stools. His medications included aspirin (81 mg/d) for preventing cardiovascular disease and Sertraline for his anxiety. His blood pressure (BP) was 130/76 mmHg, temperature was 98.3 F, respiratory rate was 16/min and the heart rate (HR) was 96/min. His abdomen was soft, with normal bowel sounds and no tenderness or guarding. His rectal exam revealed reduced sphincter tone and bright red blood. His BP subsequently dropped to 80/40 mmHg with a HR of 140/min within an hour. He became unresponsive and was subsequently intubated for airway protection in the ER. His initial blood work revealed a hemoglobin of 12 g/dL and platelets of 199000. Due to hemodynamic collapse and the large volume of blood seen in the stool, he received fluids, 2 units of packed red blood cells and 1 unit of platelets after which his vital signs stabilized. ASA was discontinued. He underwent a colonoscopy (Figure 1A) which showed two clean based rectal ulcers measuring 3 cm and 1cm with overlying exudates 7 cm from the anal verge. The location of the rectal ulcers corresponded to the site of band ligation. The rectal ulcer biopsy revealed active chronic inflammation with surface exudates and attached fragment of granulation tissue. Bleeding subsequently stopped and the patient was extubated on day 2 of admission and later discharged after an otherwise uncomplicated hospital course.

### Patient 2

A 67-year-old white man presented to the ER with complaints of bleeding from his rectum for 4 h. He was known to have symptomatic hemorrhoids for which he underwent band ligation 2 wk prior to the presentation. He denied abdominal pain, nausea, vomiting, black stools or any other complaints. His past medical history was significant for hypertension, hyperlipidemia, coronary artery disease for which he underwent Coronary Artery Bypass Graft surgery in 2004 and stroke with no residual





**Figure 2** Status post Endoscopic clip placement of the hemorrhoidal ulcer.

neurological deficits in 2005. His medications included Aggrenox (aspirin/Dipyridamole -25/200 mg twice a day for stroke prevention), Amlodipine, Metoprolol, Atorvastatin and Ezetimibe. On arrival, he was afebrile with a BP of 80/50 mmHg and a HR of 62 beats per minute. The absence of tachycardia was presumed to be due to the beta blockade. His abdomen was soft, with normal bowel sounds and no tenderness or guarding. The rectal exam revealed bright red blood with clots, normal sphincter tone and no palpable masses. His initial hemoglobin was 14 g/dL and platelet count was 187000. His hemoglobin decreased to 10 g/dL over 10 h and he continued to have rectal bleeding. Due to ongoing bleeding and hemodynamic instability he received fluids, 2 units of packed red blood cells and 1 unit of platelets. An emergent colonoscopy was then performed which showed a solitary rectal ulcer (Figure 1B and C) of 1 cm size with a visible vessel proximal to the dentate line. The visible vessel was successfully clipped endoscopically (Figure 2). The location of the rectal ulcer corresponded to the site of band ligation. No further bleeding was noted and the patient was subsequently discharged home.

## DISCUSSION

Initial treatment for mild to moderate hemorrhoidal disease consists of increased fiber intake<sup>[7]</sup>, oral hydration, use of NSAIDs for pain, avoidance of straining during defecation, and sitz baths<sup>[8]</sup>. Hemorrhoids that fail to respond to medical management may be treated with rubber band ligation, sclerosis, and thermotherapy by using infrared beam, electric current, CO<sub>2</sub> laser, or ultrasonic energy. Surgery is reserved for those who fail to improve with conservative measures.

Rubber band ligation is found to be the most effective method to treat symptomatic internal hemorrhoids (grade 1 to 3) that have failed to respond to conservative management<sup>[4,9-11]</sup>. Complications associated with ligation are uncommon (< 2%) and usually benign which may include pain, rectal bleeding from early dislodgment, vasovagal response or infection<sup>[12,13]</sup>. Bleeding after ligation may occur immediately after the procedure or 3-10 d after the rubber band and the ligated tissue fall off. Rectal

ulcers after the band ligation are extremely rare complication. The exact incidence is unknown. These ulcers can lead to massive life threatening bleeding especially in the patients taking antiplatelet agents like aspirin. ASA and other NSAIDs inhibit platelet production of thromboxane A<sub>2</sub>. ASA irreversibly acetylates the platelet enzyme so that a single dose impairs hemostasis for five to seven days hence causing hemostasis defects<sup>[14]</sup>. Recovery of the platelets after discontinuing these drugs is slow and is equivalent to the lifespan of the platelets. The other NSAIDs are competitive and reversible inhibitors with more transient effects.

A prospective study of 512 patients by Bat *et al*<sup>[15]</sup> who underwent hemorrhoidal rubber band ligation over a seven-year period were followed up for any complications. Most of the patients, who had hemorrhoidal band ligation, had a successful event free outcome (82%). Minor complications were found in 24 patients (4.7%) including painful, thrombosed hemorrhoids, slippage of bands, minor rectal bleeding, chronic longitudinal ulcers and priapism. Major complications were noted in 13 patients (2.5%) who had either delayed massive bleeding or severe complicated thrombosis of the hemorrhoids. Five of the six patients who had massive bleeding, had the onset of symptoms 10 d or more after the procedure similar to our 2 patients. Three of the six patients with massive bleeding required transfusions. Two of the three patients who were transfused were taking aspirin regularly.

Both our cases developed massive bleeding 2 wk following the banding procedure requiring platelet and blood transfusions. The use of aspirin by these patients would have caused defects in the hemostasis and may have predisposed them to massive life-threatening hemorrhage in the presence of rectal ulcers occurring after the band ligation procedure. The first patient was taking ASA for preventing cardiovascular diseases and aspirin could have been safely stopped atleast 1 wk prior to the procedure. On the contrary, the second patient had a history of coronary artery bypass graft and a stroke, stopping ASA in him abruptly might have caused more harm. Managing ASA before and after the ligation may be difficult especially since adequate guidelines are unavailable. Stopping ASA in all the cases might not be safe and the decision should be individualized.

The cases we report are an example of a rare and life threatening complication of a procedure known to be relatively safe. Use of aspirin may have been a coincidence or would have predisposed the patient to a massive bleeding. It may be advisable to avoid ASA and NSAIDs immediately after band ligation.

## COMMENTS

### Case characteristics

Two men, age 52 and 67, on aspirin at home came to the emergency room with bright red blood per rectum 2 wk after a hemorrhoidal band ligation.

### Clinical diagnosis

The authors came across two cases of severe, life-threatening lower gastrointestinal hemorrhage following endoscopic hemorrhoidal band ligation in patients

on aspirin.

### Differential diagnosis

Diverticular disease, hemorrhoids, colitis, bleeding ulcers.

### Laboratory diagnosis

Patient one had a hemoglobin of 12 g/dL and platelets of 199000 on admission. Patient 2 had a hemoglobin of 14 g/dL and a platelet count of 187000 initially. Both patients were losing blood rapidly leading to drop in the hemoglobin subsequently.

### Imaging diagnosis

Colonoscopy was performed in both the cases which showed two clean based rectal ulcers measuring 3 cm and 1 cm with overlying exudates 7 cm from the anal verge in the first case and a solitary rectal ulcer of 1 cm size with a visible vessel proximal to the dentate line in the second case.

### Pathological diagnosis

In the first case, rectal ulcer biopsy revealed active chronic inflammation with surface exudates and attached fragment of granulation tissue. No biopsy was performed in the second patient.

### Treatment

Treatment mainly included platelet and blood transfusions. The second patient had a rectal ulcer with a visible vessel which was endoscopically clipped.

### Related reports

There are a very few case reports which have described massive bleeding after hemorrhoidal band ligation in patients on aspirin.

### Term explanation

Rubber band ligation is a procedure performed endoscopically in which rubber bands are tied off at the base of the hemorrhoids hence, cutting off the blood flow to the hemorrhoids.

### Experiences and lessons

Massive bleeding is a rare but life threatening complication of a fairly safe procedure which may be avoided if we attempt to tailor the use of aspirin pre and post band ligation according to individual patient conditions.

### Peer review

This is an easy to read, well written and an interesting case report worth highlighting in the surgical community since rubber band ligation is a very commonly performed procedure.

## REFERENCES

- 1 Thomson WH. The nature of haemorrhoids. *Br J Surg* 1975; **62**: 542-552 [PMID: 1174785 DOI: 10.1002/bjs.1800620710]
- 2 Johanson JF, Sonnenberg A. The prevalence of hemorrhoids and chronic constipation. An epidemiologic study. *Gastroenterology* 1990; **98**: 380-386 [PMID: 2295392]
- 3 Bleday R, Pena JP, Rothenberger DA, Goldberg SM, Buls JG. Symptomatic hemorrhoids: current incidence and complications of operative therapy. *Dis Colon Rectum* 1992; **35**: 477-481 [PMID: 1568400 DOI: 10.1007/BF02049406]
- 4 MacRae HM, McLeod RS. Comparison of hemorrhoidal treatment modalities. A meta-analysis. *Dis Colon Rectum* 1995; **38**: 687-694 [PMID: 7607026 DOI: 10.1007/BF02048023]
- 5 Blaisdell PC. Prevention of massive hemorrhage secondary to hemorrhoidectomy. *Surg Gynecol Obstet* 1958; **106**: 485-488 [PMID: 13529526]
- 6 Barron J. Office ligation treatment of hemorrhoids. *Dis Colon Rectum* 1963; **6**: 109-113 [PMID: 13969562 DOI: 10.1007/BF02633461]
- 7 Moesgaard F, Nielsen ML, Hansen JB, Knudsen JT. High-fiber diet reduces bleeding and pain in patients with hemorrhoids: a double-blind trial of Vi-Siblin. *Dis Colon Rectum* 1982; **25**: 454-456 [PMID: 6284457 DOI: 10.1007/BF02553653]
- 8 Dodi G, Bogoni F, Infantino A, Pianon P, Mortellaro LM, Lise M. Hot or cold in anal pain? A study of the changes in internal anal sphincter pressure profiles. *Dis Colon Rectum* 1986; **29**: 248-251 [PMID: 3948615 DOI: 10.1007/BF02553028]
- 9 Templeton JL, Spence RA, Kennedy TL, Parks TG, Mackenzie G, Hanna WA. Comparison of infrared coagulation and rubber band ligation for first and second degree haemorrhoids: a randomised prospective clinical trial. *Br Med J (Clin Res Ed)* 1983; **286**: 1387-1389 [PMID: 6404471 DOI: 10.1136/bmj.286.6375.1387]
- 10 Walker AJ, Leicester RJ, Nicholls RJ, Mann CV. A prospective study of infrared coagulation, injection and rubber band ligation in the treatment of haemorrhoids. *Int J Colorectal Dis* 1990; **5**: 113-116 [PMID: 2358736 DOI: 10.1007/BF00298482]
- 11 Johanson JF, Rimm A. Optimal nonsurgical treatment of hemorrhoids: a comparative analysis of infrared coagulation, rubber band ligation, and injection sclerotherapy. *Am J Gastroenterol* 1992; **87**: 1600-1606 [PMID: 1442682]
- 12 O'Hara VS. Fatal clostridial infection following hemorrhoidal banding. *Dis Colon Rectum* 1980; **23**: 570-571 [PMID: 7460695 DOI: 10.1007/BF02988999]
- 13 Russell TR, Donohue JH. Hemorrhoidal banding. A warning. *Dis Colon Rectum* 1985; **28**: 291-293 [PMID: 3888558 DOI: 10.1007/BF02560424]
- 14 Handin RI. Disorders of the platelet and vessel wall. In: Fauci AS, Braunwald E, Isselbacher KJ, Wilson JD, Martin JB, Kasper DL, Hauser SL, Longo DL. *Harrison's Principles of Medicine*, 14th ed. New York: McGraw-Hill Companies Inc., 1998: 730-736
- 15 Bat L, Melzer E, Koler M, Dreznick Z, Shemesh E. Complications of rubber band ligation of symptomatic internal hemorrhoids. *Dis Colon Rectum* 1993; **36**: 287-290 [PMID: 8449135 DOI: 10.1007/BF02053512]

P- Reviewers: Botaitis BC, Burke D S- Editor: Zhai HH

L- Editor: A E- Editor: Liu SQ



## Left ventricular pseudoaneurysm: A case report and review of the literature

Lavanya Alapati, W Randolph Chitwood, John Cahill, Sanjay Mehra, Assad Movahed

Lavanya Alapati, W Randolph Chitwood, John Cahill, Sanjay Mehra, Assad Movahed, Department of Cardiovascular Sciences, East Carolina University, Brody School of Medicine, East Carolina Heart Institute, Greenville, NC 27834, United States  
Author contributions: Alapati L, Chitwood WR, Cahill J, Mehra S and Movahed A contributed to the manuscript writing and revision.

Supported by The "East Carolina Heart Institute"  
Correspondence to: Assad Movahed, MD, Department of Cardiovascular Sciences, East Carolina University, Brody School of Medicine, East Carolina Heart Institute, 115 Heart Drive, Mail Stop 651, Greenville, NC 27834, United States. [movaheda@ecu.edu](mailto:movaheda@ecu.edu)  
Telephone: +1-832-7444400 Fax: +1-252-7447724  
Received: October 9, 2013 Revised: January 12, 2014  
Accepted: March 13, 2014  
Published online: April 16, 2014

### Abstract

Left ventricular (LV) pseudoaneurysm is a rare complication that is reported in less than 0.1% of all patients with myocardial infarction. It is the result of cardiac rupture contained by the pericardium and is characterized by the absence of myocardial tissue in its wall unlike true aneurysm which involves full thickness of the cardiac wall. The clinical presentation of these patients is nonspecific, making the diagnosis challenging. Transthoracic echocardiogram and cardiac magnetic resonance imaging are the noninvasive modalities whereas coronary arteriography and left ventriculography are invasive modalities used for the diagnosis. As this condition is lethal, prompt diagnosis and timely management is vital.

© 2014 Baishideng Publishing Group Co., Limited. All rights reserved.

**Key words:** Chest pain; Myocardial infarction; Transthoracic echocardiogram; Left ventricular aneurysm; Left ventricular pseudoaneurysm

**Core tip:** Left ventricular pseudoaneurysm is a rare and lethal condition. It can be challenging to diagnose as it has an ambiguous clinical presentation. Timely recognition and management is critical and can be lifesaving.

Alapati L, Chitwood WR, Cahill J, Mehra S, Movahed A. Left ventricular pseudoaneurysm: A case report and review of the literature. *World J Clin Cases* 2014; 2(4): 90-93 Available from: URL: <http://www.wjgnet.com/2307-8960/full/v2/i4/90.htm> DOI: <http://dx.doi.org/10.12998/wjcc.v2.i4.90>

### INTRODUCTION

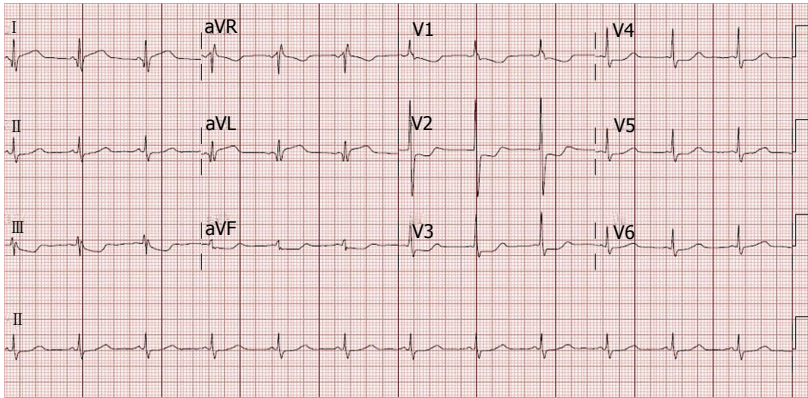
Left ventricular (LV) pseudoaneurysm is a lethal condition, but the diagnosis and differentiation from LV true aneurysm is challenging as the clinical presentation of LV pseudoaneurysm is non-specific. We describe a 75-year-old patient who presented with symptoms and signs of myocardial infarction and was diagnosed to have LV pseudoaneurysm.

### CASE REPORT

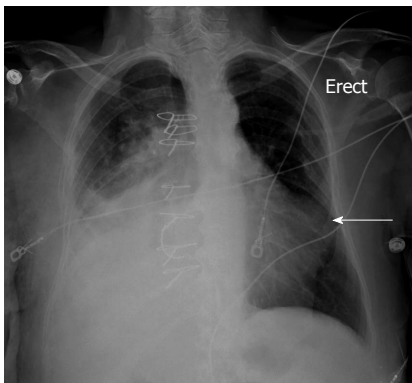
A 75-year-old african american female with hypertension, diabetes, hyperlipidemia, peripheral vascular disease, gout, status post coronary artery bypass graft and aortic valve replacement with bio-prosthetic valve performed a year ago, presented to the emergency department two weeks after mitral and tricuspid valve repair surgery, with shortness of breath, cough and chest pain for 2-3 d.

Her medications included aspirin, hydrochlorothiazide, irbesartan, simvastatin, verapamil and metformin. Vital signs on presentation were heart rate 74/min, blood pressure 127/56 mmHg, respiratory rate 16/min, temperature of 97.4 F and oxygen saturation of 98% on room air. On physical examination, patient had normal S1 and S2, grade 2/6 systolic murmur heard over the aortic area, no

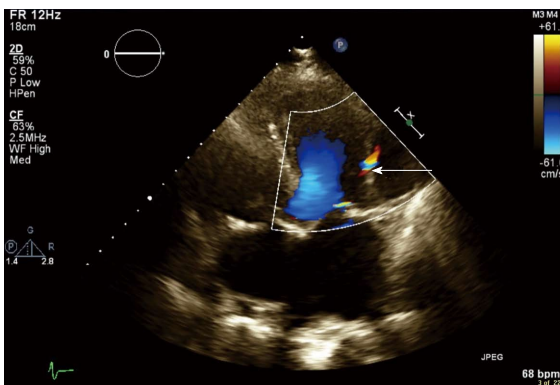




**Figure 1** Electrocardiogram shows 1.5 to 2 mm ST elevation in I , aVL, 1 to 2 mm ST depression in II , aVF, V1 to V4, and R/S ratio > 1 in V1 and V2.



**Figure 2** Chest X-ray: Convexity on the lateral wall of the cardiac silhouette (white arrow).



**Figure 3** Transthoracic echocardiogram: Apical modified 4/5 chamber view showing bidirectional shunt through the left ventricular wall (white arrow).

gallops, no rub, and no jugular venous distension. There were diminished breath sounds in the mid and lower right lung fields and crackles over the left lower lung field. Trace bilateral lower extremity edema was present. Her white blood cell count: 13.50 k/ $\mu$ L, hemoglobin: 10.2 g/dL, hematocrit: 31.2%, platelets: 334 k/ $\mu$ L, creatinine: 0.74 mg/dL, troponin: 4.00 ng/mL, total creatinine phosphokinase: 75 U/L, creatinine kinase myocardial band: 10.4 ng/dU. An electrocardiogram showed 1.5 to 2 mm ST elevation in I , aVL, 1 to 2 mm ST depression in II , aVF, V1 to V4, and R/S ratio > 1 in V1 and V2 (Figure 1). A chest radiograph showed right sided consolidation

and pleural effusion and a convex out pouching along the left heart border (Figure 2).

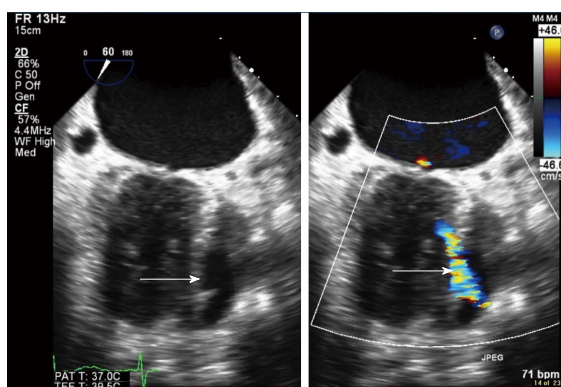
The patient was started on nitroglycerin drip but continued to have chest pain. Transthoracic echocardiogram (TTE) showed dyskinesis and marked thinning of mid and basal anterior-lateral segments consistent with infarction in the distribution of the left circumflex artery. It also showed a ruptured ventricular wall with a large pericardial effusion adjacent to the dyskinetic segment. On doppler, a bidirectional shunt across the lateral left ventricle is seen, indicative of LV aneurysm (Figure 3). The width of the neck is 5.8 mm and the maximal internal diameter of the aneurysmal sac is 48 mm with the neck to sac ratio of less than 0.5 (about 0.12) which is strongly suggestive of pseudoaneurysm. Coronary angiography showed left anterior descending artery free of angiographic disease, left circumflex with 90% disease ostially and proximally. The right coronary artery (RCA) was 100% occluded ostially. Saphenous vein graft to RCA was patent with normal flow. Saphenous vein graft to the first obtuse marginal (OM1) with a jump graft to second obtuse marginal (OM2) were patent but there was distal disease in both the OM1 and OM2 up to 80%.

Subsequently, transesophageal echocardiogram (TEE) and cardiac magnetic resonance imaging (MRI) were done and the diagnosis of LV pseudoaneurysm was confirmed (Figures 4 and 5). Intra-operatively, the patient was found to have a LV lateral pseudoaneurysm with approximately 1.5 cm diameter free wall perforation; the LV pseudoaneurysm contained a thrombus and was communicating with the LV cavity. The LV pseudoaneurysm was repaired with a bovine pericardial patch. She was discharged to a rehabilitation center on post-operative day 7. Four weeks post operatively, she was discharged from the rehabilitation center and was performing very well.

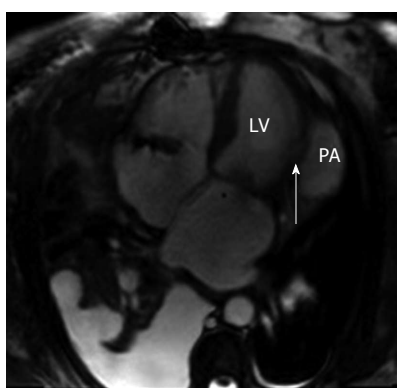
## DISCUSSION

LV pseudoaneurysm also referred to as contained LV wall rupture is a rare complication that is reported in less than 0.1% of all myocardial infarction patients. It is catastrophic causing death in 48% of patients without surgical intervention<sup>[1]</sup>. LV pseudoaneurysm is a result of cardiac rupture contained by the pericardium and is characterized by the absence of myocardial tissue in its wall





**Figure 4** Transesophageal echocardiogram: 2 chamber view confirming the to and fro flow between left ventricle and the pseudo aneurysm (white arrow).



**Figure 5** Cardiac magnetic resonance imaging: 4 chamber view showing the connection between the left ventricular cavity and the left ventricular pseudo aneurysm (white arrow). LV: Left ventricular; PA: Pseudoaneurysm.

unlike true aneurysm which involves the full thickness of the cardiac wall.

Frances *et al*<sup>[2]</sup> in 1998 reviewed data from 290 patients and reported the most common etiology of LV pseudoaneurysm to be myocardial infarction followed by cardiac surgery. The risk factors for the LV pseudoaneurysms are older age, female sex, hypertension and inferior and lateral wall myocardial infarction. The common location for LV pseudoaneurysm is postero-inferior followed by postero-lateral and anterior, in contrast to true LV aneurysm which is more commonly located in the anterior and apical walls<sup>[2]</sup>. The patients with LV pseudoaneurysm usually present within 2 mo of a myocardial infarction<sup>[3]</sup>.

The clinical presentation of patients with LV pseudoaneurysm is not specific and can mimic myocardial infarction or heart failure. Patients could be asymptomatic (12%) or could have persistent or recurrent chest pain (30%), shortness of breath (25%) or non-specific symptoms like dizziness or altered mental status, and 3% of the patients could have sudden death as a presenting symptom<sup>[4]</sup>.

The physical examination is nonspecific with soft heart sounds, pericardial friction rub and a new systolic murmur. Electrocardiogram changes in most cases include sinus bradycardia, junctional rhythm and changes

reflecting ischemia or infarction. A convexity or a mass adjacent to the cardiac silhouette can be present on the chest radiograph in more than half of the cases (Figure 2). None of these findings are specific for LV pseudoaneurysm which brings the focus to the cardiac imaging modalities.

It can be challenging to diagnose LV pseudoaneurysm with the ambiguity in its clinical presentation and the nonspecific physical findings. However, prompt diagnosis is essential as LV pseudoaneurysm is associated with a cardiac rupture risk of 30%-45%<sup>[4]</sup>. Therefore, cardiac imaging plays a very significant role in the diagnosis of LV pseudoaneurysm. Currently, various cardiac imaging modalities are available for diagnosis of LV pseudoaneurysm.

TTE has increased the number of diagnosed LV pseudoaneurysm cases. Being a noninvasive technique, TTE is routinely used for initial assessment in suspected patients as it helps in diagnosing LV pseudoaneurysm and also in determining the infarction. A ratio of < 0.5 between the width of the neck and the maximal internal diameter of the aneurysmal sac<sup>[5]</sup> or the presence of bi-directional turbulent flow through the neck by color and pulsed Doppler study<sup>[6]</sup>, are suggestive of a LV pseudoaneurysm. TEE further assists in improving the accuracy of diagnosing LV pseudoaneurysm because in TTE there can be field of view limitation for visualization of the LV inferior wall.

Cardiac MRI is a non-invasive modality that enables the diagnosis of LV pseudoaneurysm. It is useful in identification of the pericardium, detection of thrombi, and in distinguishing between necrotic and normal myocardium. It provides morphological definition of a LV pseudoaneurysm location, extension and relation to adjacent structures. Delayed enhancement enables accurate assessment of the location and extent of the infarcted area and of viable myocardium, all of which are essential to determine optimal management. Cardiac MRI being a non invasive modality without risk of radiation exposure, has an enormous value in differentiating between LV aneurysms and LV pseudoaneurysms, with the ability to obtain cross sectional views in any plane. Cardiac MRI has a sensitivity of 100% and a specificity of 83%<sup>[7]</sup>.

Cardiac computed tomography is another non invasive imaging modality used for acquiring the three-dimensional anatomical and functional information on the myocardium and pericardium<sup>[8]</sup>. However, the limited temporal resolution, the usage of iodinated contrast and exposure of the patient to ionizing radiation, makes it less favorable.

Left ventriculography demonstrates the narrow neck connecting the ventricle to the cavity in which contrast liquid remains for several beats following the injection. Though left ventriculography is considered the gold standard modality with a diagnostic accuracy of about 85%<sup>[9]</sup>, it is seldom used because of the concern for thrombus dislodgement.

Once the diagnosis is confirmed, urgent surgical in-

intervention is necessary in acute LV pseudoaneurysm<sup>[10]</sup> as the risk of rupture outweighs the risk of surgery. Small retrospective studies have shown that patients with incidental finding of chronic small LV pseudoaneurysm less than 3 cm in size<sup>[10]</sup> and patients with increased surgical risk<sup>[11]</sup> can be managed conservatively. But until large studies confirm the favorable outcomes of medical management over surgical intervention, the preferred approach would remain surgical management.

In conclusion, since it is challenging to diagnose LV pseudoaneurysm because of the ambiguity in its presentation, diagnosis in a timely manner is crucial. High clinical suspicion and early utilization of the non-invasive modalities for detection of LV pseudoaneurysm are essential to improve the outcome in these patients.

## COMMENTS

### Case characteristics

A 75-year-old female patient with history of coronary artery bypass graft and aortic valve replacement presenting with cough, shortness of breath and chest pain.

### Clinical diagnosis

Grade 2/6 systolic murmur over the aortic area, no gallops, no rub, and no jugular venous distension. Diminished breath sounds in the mid and lower right lung fields and crackles over the left lower lung field and trace bilateral lower extremity edema.

### Differential diagnosis

Myocardial infarction, congestive heart failure, left ventricular (LV) aneurysm, LV pseudoaneurysm, pericarditis.

### Laboratory diagnosis

White blood cell count: 13.50 k/ $\mu$ L, hemoglobin: 10.2 g/dL, hematocrit: 31.2%, platelets: 334 k/ $\mu$ L, creatinine: 0.74 mg/dL, troponin: 4.00 ng/mL, total creatinine phosphokinase: 75 U/L, creatinine kinase myocardial band: 10.4 ng/dU.

### Imaging diagnosis

Transthoracic echocardiogram with doppler showed a bidirectional shunt across the ruptured lateral left ventricle. The width of the neck is 5.8 mm and the maximal internal diameter of the aneurysmal sac is 48 mm.

### Treatment

Surgical repair of LV pseudoaneurysm.

### Related reports

The diagnosis of LV pseudoaneurysm is challenging requiring high clinical suspicion for timely diagnosis and management.

### Experiences and lessons

This case report presents a rare case of pseudoaneurysm and the use of advanced imaging modalities in the diagnosis.

## Peer review

LV pseudoaneurysms are a rare finding mainly in patients after myocardial infarction; difficult to diagnose and are associated with a high mortality. The case report demonstrates very nicely the main diagnostic findings in this setting.

## REFERENCES

- 1 **Hoey DR**, Kravitz J, Vanderbeek PB, Kelly JJ. Left ventricular pseudoaneurysm causing myocardial infarction and cerebrovascular accident. *J Emerg Med* 2005; **28**: 431-435 [PMID: 15837025 DOI: 10.1016/j.jemermed.2004.12.013]
- 2 **Frances C**, Romero A, Grady D. Left ventricular pseudoaneurysm. *J Am Coll Cardiol* 1998; **32**: 557-561 [PMID: 9741493]
- 3 **Yeo TC**, Malouf JF, Reeder GS, Oh JK. Clinical characteristics and outcome in postinfarction pseudoaneurysm. *Am J Cardiol* 1999; **84**: 592-595, A8 [PMID: 10482162]
- 4 **Contuzzi R**, Gatto L, Patti G, Goffredo C, D'Ambrosio A, Covino E, Chello M, Di Sciascio G. Giant left ventricular pseudoaneurysm complicating an acute myocardial infarction in patient with previous cardiac surgery: a case report. *J Cardiovasc Med (Hagerstown)* 2009; **10**: 81-84 [PMID: 19145118]
- 5 **Gatewood RP**, Nanda NC. Differentiation of left ventricular pseudoaneurysm from true aneurysm with two dimensional echocardiography. *Am J Cardiol* 1980; **46**: 869-878 [PMID: 7435399]
- 6 **Sutherland GR**, Smyllie JH, Roelandt JR. Advantages of colour flow imaging in the diagnosis of left ventricular pseudoaneurysm. *Br Heart J* 1989; **61**: 59-64 [PMID: 2917100]
- 7 **Gill S**, Rakhit DJ, Ohri SK, Harden SP. Left ventricular true and false aneurysms identified by cardiovascular magnetic resonance. *Br J Radiol* 2011; **84**: e35-e37 [PMID: 21257833 DOI: 10.1259/bjr/25590962]
- 8 **Ghersin E**, Kerner A, Gruberg L, Bar-El Y, Abadi S, Engel A. Left ventricular pseudoaneurysm or diverticulum: differential diagnosis and dynamic evaluation by catheter left ventriculography and ECG-gated multidetector CT. *Br J Radiol* 2007; **80**: e209-e211 [PMID: 17928490]
- 9 **Figueras J**, Cortadellas J, Domingo E, Soler-Soler J. Survival following self-limited left ventricular free wall rupture during myocardial infarction. Management differences between patients with or without pseudoaneurysm formation. *Int J Cardiol* 2001; **79**: 103-111; discussion 111-112 [PMID: 11461727]
- 10 **Prêtre R**, Linka A, Jenni R, Turina MI. Surgical treatment of acquired left ventricular pseudoaneurysms. *Ann Thorac Surg* 2000; **70**: 553-557 [PMID: 10969679]
- 11 **Yeo TC**, Malouf JF, Oh JK, Seward JB. Clinical profile and outcome in 52 patients with cardiac pseudoaneurysm. *Ann Intern Med* 1998; **128**: 299-305 [PMID: 9471934]

**P- Reviewers:** Kettering K, Wu CC **S- Editor:** Wen LL  
**L- Editor:** A **E- Editor:** Liu SQ



## Varicocele repair in severe oligozoospermia: A case report of post-operative azoospermia

Marco Milone, Mario Musella, Miguel Emilio Sosa Fernandez, Paola Maietta, Annarita Sasso, Loredana Maria Sosa Fernandez, Laura Virginia Sosa Fernandez, Francesco Milone

Marco Milone, Mario Musella, Paola Maietta, Francesco Milone, Department of Advanced Biomedical Science, University of Naples "Federico II", 80131 Naples, Italy  
Miguel Emilio Sosa Fernandez, Annarita Sasso, Loredana Maria Sosa Fernandez, Laura Virginia Sosa Fernandez, Embryos, IVF Center in Battipaglia, 84100 Salerno, Italy  
Author contributions: Milone M and Musella M contributed to the conception and design; Sosa Fernandez ME contributed to drafting the article and revising it critically for important intellectual content; Maietta P, Sasso A, Sosa Fernandez LM and Sosa Fernandez LV contributed to the acquisition, analysis and interpretation of data; Milone F contributed to the final approval of the version to be published.

Correspondence to: Marco Milone, MD, Department of Advanced Biomedical Science, University of Naples "Federico II", Via Pansini 5, 80131 Naples, Italy. milone.marco@alice.it  
Telephone: +39-81-7463067 Fax: +39-81-7462896  
Received: October 31, 2013 Revised: February 10, 2014  
Accepted: February 20, 2014  
Published online: April 16, 2014

### Abstract

Varicocele has been implicated as a cause in 35%-50% of patients with primary infertility and up to 81% of men with secondary infertility. Although a large number of reports have shown improvement in the semen parameters after correction of varicocele, other studies have suggested no benefit. We report the first case of azoospermia after surgery in a young infertile male patient with left-sided varicocele and severe oligozoospermia undergoing laparoscopic varicocelectomy. A pregnancy was only achieved with assisted reproductive technology because semen cryopreservation was performed before surgery. In the light of the above, the deterioration of sperm count after varicocele repair in patients with severe oligozoospermia could be due to irreversible impairment of spermatogenesis of such patients, together with the possible temporary damage of the surgical repair. This possible complication

could therefore turn the severe oligozoospermia into an indication to perform cryopreservation before surgery, on both clinical and medico-legal grounds. Further research is needed before drawing definitive conclusions regarding the management of varicocele-related severe oligozoospermia.

© 2014 Baishideng Publishing Group Co., Limited. All rights reserved.

**Key words:** Varicocele; Fertility; Semen; Cryopreservation; Oligozoospermia

**Core tip:** We report a case of deterioration of sperm count after varicocele repair in a patient with severe oligozoospermia. This possible complication could therefore turn severe oligozoospermia into an indication to perform cryopreservation before surgery, on both clinical and medico-legal grounds.

Milone M, Musella M, Sosa Fernandez ME, Maietta P, Sasso A, Sosa Fernandez LM, Sosa Fernandez LV, Milone F. Varicocele repair in severe oligozoospermia: A case report of post-operative azoospermia. *World J Clin Cases* 2014; 2(4): 94-96 Available from: URL: <http://www.wjgnet.com/2307-8960/full/v2/i4/94.htm> DOI: <http://dx.doi.org/10.12998/wjcc.v2.i4.94>

### INTRODUCTION

Varicocele has been implicated as a cause in 35%-50% of patients with primary infertility and up to 81% of men with secondary infertility. Numerous studies have shown that varicocele is associated with testicular hypotrophy, impaired spermatogenesis, increased apoptosis of germ cells at the seminiferous tubules, oxidative stress pattern and a progressive damage to testicular biology over time<sup>[1]</sup>. Although a large number of reports have shown

improvement in the semen parameters after correction of varicocele, other studies have suggested no benefit<sup>[2]</sup>.

## CASE REPORT

We reported a case of a 34-year-old infertile male patient with left-sided varicocele. On physical examination, the patient's varicocele was categorized as grade 3 according to a three grade scale (grade 1: detectable during Valsalva maneuver only; grade 2: palpable at rest; grade 3: visible at rest). The reflux during color Doppler ultrasound, classified into three grades (slight and brief reflux, ending before the Valsalva maneuver was completed; lasting throughout the Valsalva maneuver; and severe reflux, already present with the patient supine at rest) was detected as severe with reflux at rest.

A basic infertility evaluation including a detailed history and a complete physical examination was undertaken and the infertility was defined on the basis of a failure to establish a pregnancy within 1 year with unprotected intercourse. No history of smoking, drug abuse or other systemic disease was reported. Hormonal parameters before and after surgery were normal. Semen analysis, conducted according to the World Health Organization recommendations, showed a severe oligozoospermia. The median value of the percentage of progressive motile sperm was 18%, while the median value of the percentage of normal forms was 11%. Nevertheless, the woman was normal, based on history, hormonal levels and hysterosalpingogram.

The surgical approach used was laparoscopic ligation of the spermatic vein. The spermatic cord at the internal ring was identified and then the parietal peritoneum overlying the spermatic cord was incised with scissors. The engorged internal spermatic veins were then identified, dissected, ligated and divided. The venous ligation was performed by a freehand intracorporeal knot-tying technique with 3-0 silk ligature. The lymphatic vessels and testicular artery were meticulously identified and preserved. The post-operative course was uneventful and the patient was discharged after 24 h. The patient underwent physical examination 1 mo after surgery and spermatic color Doppler and semen analysis 6 mo after surgery.

The size of the left testis before and after surgery was 3.2 cm and 3.3 cm respectively. Although no complications or recurrence were noted, a deterioration in sperm concentration was recorded and the patient became azoospermic. A pregnancy has only been achieved with assisted reproductive technology because semen cryopreservation was performed before surgery.

The patient underwent another semen analysis 1 year after surgery but it was not necessary to perform a testis biopsy before varicocelectomy.

## DISCUSSION

The Practice Committee of the American Society for Reproductive Medicine recently published recommenda-

tions for the evaluation and treatment of varicoceles<sup>[3,4]</sup>. This report was previously published as a peer-reviewed consensus jointly with the Male Infertility Best Practice Policy Committee of the American Urological Association. The committee concluded that varicocelectomy should be offered to the male partner in couples attempting to conceive only when all of the following conditions were present: a palpable varicocele, documented couple infertility, a female partner with normal fertility or potentially correctable infertility, and a male partner with one or more abnormal semen parameters or test results showing abnormal sperm function.

Concerning the operative technique, data in the literature do not show significant differences in seminal parameter improvements comparing the different surgical, microsurgical or interventional radiological techniques. According to the main international guidelines, currently it is not possible to identify a gold-standard treatment and the most appropriate technique is the one that the surgeon is most confident with or that is the easiest to perform in each hospital setting. Furthermore, it is demonstrated that accidental ligation or injury of the testicular artery during primary varicocele repair has no deleterious effect on post-operative semen and pregnancy outcomes<sup>[5]</sup>. The predictors of varicocele repair outcome are high-grade varicocele, normal serum FSH, total motility > 60% and total motile sperm count >  $5 \times 10^6$  before varicocelectomy. These good prognostic indicators may only help in identifying those men with a better prognosis for varicocelectomy<sup>[6]</sup>. Nevertheless, such predictors cannot be evaluated as a contraindication of performing a varicocelectomy. In fact, in the past 10 years, some studies have shown that also nonobstructive azoospermic patients with varicocele identified on physical examination may benefit from varicocele repair<sup>[7]</sup>.

We reported, to the best of our knowledge, the first case of azoospermia after laparoscopic varicocele repair in a young infertile male patient with left-sided varicocele and severe oligozoospermia.

Few studies have shown deterioration or azoospermia after surgery. Moreover, they do not analyze the characteristics of the patients with semen deterioration or justify this complication<sup>[8,9]</sup>.

In our case, all of the indications to perform varicocelectomy were present and therefore, in such a case, malpractice cannot be a cause of this complication. Moreover, there were no complications with intercourse and no reflux was identified with the echographic evaluation after surgery.

The reason for a deterioration after varicocelectomy is not clear as it is not reported in the literature at all. In the light of the above, the deterioration of sperm count after varicocele repair in patients with severe oligozoospermia could be due to irreversible impairment of spermatogenesis of such patients, together with the possible temporary damage of the surgery repair. This possible complication could therefore turn the severe oligozoospermia



into indications to perform cryopreservation before surgery, on both clinical and medico-legal grounds. Further research is needed before drawing definitive conclusions regarding management of varicocele-related severe oligozoospermia. A randomized clinical trial on these patients with severe oligozoospermia and varicocele would be useful to evaluate the effectiveness of varicocelectomy.

## COMMENTS

### Case characteristics

Young infertile man with varicocele and severe oligozoospermia.

### Clinical diagnosis

Asymptomatic patient.

### Laboratory diagnosis

Semen analysis showed a severe oligozoospermia and the median value of the percentage of progressive motile sperm was 18%, while the median value of the percentage of normal forms was 11%.

### Imaging diagnosis

The reflux during color Doppler ultrasound was detected severe with reflux at rest.

### Treatment

A pregnancy has only been achieved with assisted reproductive technology because semen cryopreservation was performed before surgery.

### Experiences and lessons

In the light of the above, the deterioration of sperm count after varicocele repair in patients with severe oligozoospermia could turn the severe oligozoospermia into an indication to perform cryopreservation before surgery, on both clinical and medico-legal grounds.

### Peer review

The manuscript reported the first case of azoospermia after laparoscopic varicocelectomy in a young infertile patient with left-sided varicocele and severe oligozoospermia, which is contrary to most others that have been published in the literature.

## REFERENCES

- 1 **Rodriguez Peña M**, Alescio L, Russell A, Lourenco da Cunha J, Alzu G, Bardoneschi E. Predictors of improved seminal parameters and fertility after varicocele repair in young adults. *Andrologia* 2009; **41**: 277-281 [PMID: 19737275 DOI: 10.1111/j.1439-0272.2009.00919.x]
- 2 **Marmar JL**, Agarwal A, Prabakaran S, Agarwal R, Short RA, Benoff S, Thomas AJ. Reassessing the value of varicocelectomy as a treatment for male subfertility with a new meta-analysis. *Fertil Steril* 2007; **88**: 639-648 [PMID: 17434508]
- 3 **Jarow JP**, Sharlip ID, Belker AM, Lipshultz LI, Sigman M, Thomas AJ, Schlegel PN, Howards SS, Nehra A, Damewood MD, Overstreet JW, Sadovsky R. Best practice policies for male infertility. *J Urol* 2002; **167**: 2138-2144 [PMID: 11956464]
- 4 **Sharlip ID**, Jarow JP, Belker AM, Lipshultz LI, Sigman M, Thomas AJ, Schlegel PN, Howards SS, Nehra A, Damewood MD, Overstreet JW, Sadovsky R. Best practice policies for male infertility. *Fertil Steril* 2002; **77**: 873-882 [PMID: 12009338]
- 5 **Salem HK**, Mostafa T. Preserved testicular artery at varicocele repair. *Andrologia* 2009; **41**: 241-245 [PMID: 19601936 DOI: 10.1111/j.1439-0272.2009.00926.x]
- 6 **Cocuzza M**, Cocuzza MA, Bragais FM, Agarwal A. The role of varicocele repair in the new era of assisted reproductive technology. *Clinics (Sao Paulo)* 2008; **63**: 395-404 [PMID: 18568252]
- 7 **Pasqualotto FF**, Pasqualotto EB, Sobreiro BP, Hallak J, Me-deiros F, Lucon AM. Clinical diagnosis in men undergoing infertility investigation in a university hospital. *Urol Int* 2006; **76**: 122-125 [PMID: 16493211]
- 8 **Segenreich E**, Israilov SR, Shmueli J, Niv E, Servadio C. Correlation between semen parameters and retrograde flow into the pampiniform plexus before and after varicocelectomy. *Eur Urol* 1997; **32**: 310-314 [PMID: 9358219]
- 9 **Senbanjo RO**, Lawani J, Nkposong EO. Changes in seminal quality following varicocelectomy in infertile Nigerian males. *Afr J Med Med Sci* 1986; **15**: 63-71 [PMID: 3031963]

**P- Reviewers:** Chen SS, Li ZX **S- Editor:** Gou SX  
**L- Editor:** Roemmele A **E- Editor:** Liu SQ



## Transcatheter aortic valve implantation in a 54-year-old patient with aggressive HIV

Stefano Salizzoni, Fabrizio D'Ascenzo, Claudio Moretti, Stefano Bonora, Andrea Calcagno, Pierluigi Omedè, Chiara Montrucchio, Enrico Cerrato, Chiara Colaci, Imad Sheiban, Sebastiano Marra, Mauro Rinaldi, Fiorenzo Gaita

Stefano Salizzoni, Mauro Rinaldi, Division of Cardiac Surgery, Città della Salute e della Scienza, 10126 Turin, Italy

Fabrizio D'Ascenzo, Claudio Moretti, Pierluigi Omedè, Enrico Cerrato, Chiara Colaci, Imad Sheiban, Sebastiano Marra, Fiorenzo Gaita, Department of Internal Medicine, Division of Cardiology, University of Turin, S. Giovanni Battista "Molinette" Hospital, 10126 Turin, Italy

Stefano Bonora, Andrea Calcagno, Chiara Montrucchio, Division of Infectious Disease, Amedeo di Savoia Hospital, 10126 Turin, Italy

**Author contributions:** Salizzoni S and D'Ascenzo F contributed equally to this work; Salizzoni S, Moretti C, Bonora S, Calcagno A, Omedè P, Montrucchio C, Cerrato E, Colaci C, Sheiban I, Marra S, Rinaldi M and Gaita F were involved in the clinical management of the patient and contributed to the discussion.

**Correspondence to:** Dr. Fabrizio D'Ascenzo, MD, Department of Internal Medicine, Division of Cardiology, University of Turin, S. Giovanni Battista "Molinette" Hospital, Corso Bramante 88-90, 10126 Turin, Italy. [fabrizio.dascenzo@gmail.com](mailto:fabrizio.dascenzo@gmail.com)  
Telephone: +39-33-33992707 Fax: +39-1-16336769

Received: October 14, 2013 Revised: January 14, 2014

Accepted: February 20, 2014

Published online: April 16, 2014

### Abstract

We report a case of a 54-year-old patient who was denied surgical replacement for severe aortic stenosis because of complicated acquired immunodeficiency syndrome and who successfully underwent transcatheter aortic valve implantation at our institution.

© 2014 Baishideng Publishing Group Co., Limited. All rights reserved.

**Key words:** Severe aortic stenosis; Acquired immunodeficiency syndrome; Transcatheter aortic valve implantation; Heart team; Periprocedural complications

**Core tip:** The present case report describes the feasibility and safety of transcatheter aortic valve implantation for patients with acquired immunodeficiency syndrome, evaluated after the heart team decision.

ity and safety of transcatheter aortic valve implantation for patients with acquired immunodeficiency syndrome, evaluated after the heart team decision.

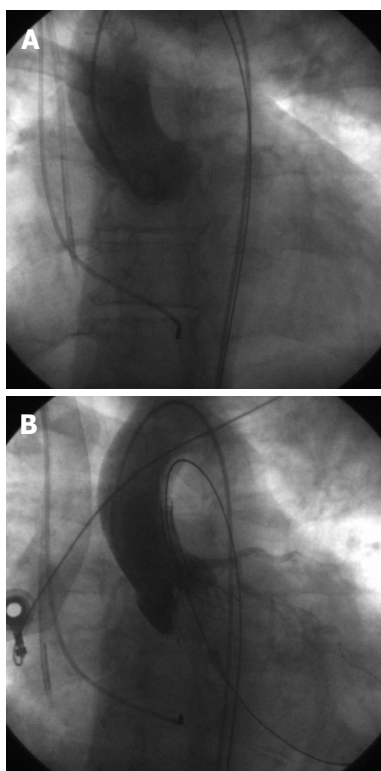
Salizzoni S, D'Ascenzo F, Moretti C, Bonora S, Calcagno A, Omedè P, Montrucchio C, Cerrato E, Colaci C, Sheiban I, Marra S, Rinaldi M, Gaita F. Transcatheter aortic valve implantation in a 54-year-old patient with aggressive HIV. *World J Clin Cases* 2014; 2(4): 97-99 Available from: URL: <http://www.wjgnet.com/2307-8960/full/v2/i4/97.htm> DOI: <http://dx.doi.org/10.12998/wjcc.v2.i4.97>

### INTRODUCTION

The transcatheter aortic valve implantation (TAVI) procedure is currently considered a valid alternative to surgery in patients with severe aortic stenosis not eligible for valve replacement or with high operative risk, as demonstrated by the recent PARTNER<sup>[1]</sup> trial, which showed similar results between surgery and TAVI. For this reason, it may represent an attractive option for patients whose surgical risk is difficult to assess, like immunocompromised ones.

### CASE REPORT

We report the case of a 54-year-old male (82 kg, 178 cm) with a diagnosis of post-transfusion HIV infection in 1990, who had taken six different antiretroviral drugs because of a virus with several resistances. In October 2009, the patient was hospitalized for *Listeria* meningitis and he suffered from several episodes of acute heart failure, after which severe aortic stenosis was diagnosed by transthoracic echocardiography (TTE), with a mean gradient of 55 mmHg and an ejection fraction of 50% without coronary disease at the angiography. The patient was



**Figure 1 Positioning image.** A: Pig tail positioning before transcatheter aortic valve implantation; B: Valve after positioning.

consequently referred to cardiac surgeons who refused to do the procedure due to a high operative risk, with a Cd4 cell count of 400 cell/cc and low count of platelets. Nevertheless, from December 2010 he became symptomatic (NYHA III) and had several syncopal episodes, the last of which led to a leg fracture.

The patient was referred again to our surgeons who considered him for TAVI, despite his age and low risk detected by common scores (Logistic EuroSCORE 1.51%, STS 3%). Multidisciplinary discussion, including the infectious diseases specialist who foresaw at least a 2-year survival and a high risk of potential life threatening peri-intervention infections at the same time, led to the decision of a percutaneous transfemoral approach to minimize all potential sites of infection, both for the patient and the operators. He was successfully treated with a 29 mm CoreValve and discharged uneventfully on post-operative day nine (Figure 1). His TTE showed a mean gradient of 12 mmHg and mild paraprothetic aortic insufficiency. His cardiovascular therapy consisted of aspirin, clopidogrel and furosemide 25 mg.

Two weeks after discharge, he presented to the emergency department because of angina (CCS II) and repeated episodes of gingival bleeding and melena. ECG was unchanged but important anemia (Hb 8 g/dL) was detected, so clopidogrel was stopped.

At the 12 mo follow-up, he was in NYHA I and had no further syncope or angina. Ejection fraction was 51%, with a mean transprosthetic gradient of 12 mmHg and still mild paraprothetic aortic insufficiency on echocardiography.

## DISCUSSION

The numbers of immunocompromised patients with aortic stenosis will increase because of longer survival for HIV patients<sup>[2-4]</sup>.

Despite some encouraging reports from patients with uncomplicated HIV<sup>[5]</sup>, their management can be really tricky: for patients, because of a high infective risk, high prevalence of renal disease and consequently a risk of bleeding or thrombosis<sup>[4-6]</sup>, and for surgeons, due to contamination risk<sup>[7]</sup>. Moreover, accurate tools to correctly assess risk in immunocompromised patients (not appraised by EuroSCORE and only partially by the STS score<sup>[8,9]</sup>) are lacking and no data are reported about in hospital and midterm follow up complications. This medical issue will become more and more relevant due to the increase in survival of patients with immunodeficiency (both HIV or after transplant). It must be remembered that in some countries, such as the United States, the TAVI procedure is still considered to be in an initial phase and this can affect the lack of data regarding this population. To the best of our knowledge, this is the first HIV patient with severe aortic stenosis treated by TAVI, which was chosen mainly due to the infective risk. TAVI, with an accurate treatment of in-hospital complications, may represent a feasible choice for those with HIV/AIDS.

## COMMENTS

### Case characteristics

Aggressive acquired immunodeficiency syndrome (AIDS) in a patient referred for invasive cardiac surgery to improve his life expectancy.

### Clinical diagnosis

NYHA III: reduced second heart sound with systolic murmur heard. Electrocardiogram (ECG) with left ventricle hypertrophy and echocardiogram confirming severe stenosis.

### Differential diagnosis

After syncope, ECG monitoring did not show any atrioventricular block.

### Laboratory diagnosis

The lymphocyte typing detected a significant reduction in the lymphocyte subpopulation of CD3<sup>+</sup>, CD4<sup>+</sup> and CD19<sup>+</sup>.

### Imaging diagnosis

Transthoracic echocardiography showed the left ventricle with concentric hypertrophy and FE of 55%; severe aortic stenosis with AVA 0.8 cm<sup>2</sup> and mean transvalvular gradient of 55 mmHg without coronary disease at angiography.

### Pathological diagnosis

HIV-positive patient treated with anti-retroviral therapy, suffering from symptomatic severe aortic stenosis.

### Treatment

Transfemoral transcatheter aortic valve implantation (TAVI).

### Term explanation

Core Valve is a valve prosthesis, comprised of 3 porcine pericardial tissue leaflets mounted in a self-expanding nitinol frame. This valve has only been used in a retrograde approach, either via transfemoral, subclavian or direct aortic access.

### Experiences and lessons

TAVI can be considered a therapeutic option for severe aortic stenosis in a severe immunosuppressed status, as for patients with AIDS treated with antiretroviral therapy.

### Peer review

The argument could be considered a strong point because in the literature, this is not treated; in fact, this was the first TAVI procedure on a patient affected by

AIDS at high risk for valve surgical replacement. So, this case report represents an example for an alternative therapeutic option, giving an opportunity for these patients to be cured despite their important comorbidity.

## REFERENCES

- 1 **Smith CR**, Leon MB, Mack MJ, Miller DC, Moses JW, Svensson LG, Tuzcu EM, Webb JG, Fontana GP, Makkar RR, Williams M, Dewey T, Kapadia S, Babaliaros V, Thourani VH, Corso P, Pichard AD, Bavaria JE, Herrmann HC, Akin JJ, Anderson WN, Wang D, Pocock SJ. Transcatheter versus surgical aortic-valve replacement in high-risk patients. *N Engl J Med* 2011; **364**: 2187-2198 [PMID: 21639811 DOI: 10.1056/NEJMoa1103510]
- 2 **D'Ascenzo F**, Cerrato E, Biondi-Zoccai G, Moretti C, Omedè P, Sciuto F, Bollati M, Modena MG, Gaita F, Sheiban I. Acute coronary syndromes in human immunodeficiency virus patients: a meta-analysis investigating adverse event rates and the role of antiretroviral therapy. *Eur Heart J* 2012; **33**: 875-880 [PMID: 22187508 DOI: 10.1093/eurheartj/ehr456]
- 3 **Biondi-Zoccai G**, D'Ascenzo F, Modena MG. Novel insights on HIV/AIDS and cardiac disease: shedding light on the HAART of Darkness. *Eur Heart J* 2012; **33**: 813-815 [PMID: 22108832 DOI: 10.1093/eurheartj/ehr413]
- 4 **Achouh P**, Jemel A, Chaudesurge A, Redheuil A, Zegdi R, Fabiani JN. Aortic biological valve thrombosis in an HIV positive patient. *Ann Thorac Surg* 2011; **91**: e90-e91 [PMID: 21619956 DOI: 10.1016/j.athoracsur.2011.01.099]
- 5 **Trachiotis GD**, Alexander EP, Benator D, Gharagozloo F. Cardiac surgery in patients infected with the human immunodeficiency virus. *Ann Thorac Surg* 2003; **76**: 1114-1118; discussion 1118 [PMID: 14529996]
- 6 **Sims DB**, Uriel N, González-Costello J, Deng MC, Restaino SW, Farr MA, Takayama H, Mancini DM, Naka Y, Jorde UP. Human immunodeficiency virus infection and left ventricular assist devices: a case series. *J Heart Lung Transplant* 2011; **30**: 1060-1064 [PMID: 21515076 DOI: 10.1016/j.healun.2011.03.004]
- 7 **van Wagenberg FS**, Lehr EJ, Rehman A, Bonatti J. Is there a role for robotic totally endoscopic coronary artery bypass in HIV positive patients? *Int J Med Robot* 2010; **6**: 465-467 [PMID: 20886464 DOI: 10.1002/rcs.356]
- 8 **Roques F**, Michel P, Goldstone AR, Nashef SA. The logistic EuroSCORE. *Eur Heart J* 2003; **24**: 881-882 [PMID: 12727160]
- 9 Online STS risk calculator. Available from: URL: <http://risk-calc.sts.org/STSTWebRiskCalc273/de.aspx>

**P- Reviewers:** Kasai Y, Muluk NB, Simmons RG

**S- Editor:** Ma YJ **L- Editor:** Roemmele A **E- Editor:** Liu SQ





## Elective thoracotomy for pedicle screw removal to prevent severe aortic bleeding

Sebastian Decker, Mohamed Omar, Christian Krettek, Christian W Müller

Sebastian Decker, Mohamed Omar, Christian Krettek, Christian W Müller, Trauma Department, Hannover Medical School, 30625 Hannover, Germany

Author contributions: Decker S and Omar M contributed to the writing, follow-up examinations and analysis; Krettek C contributed to the revision and analysis; Müller CW contributed to the surgery, revision and follow-up examinations.

Correspondence to: Dr. Sebastian Decker, Trauma Department, Hannover Medical School, Carl-Neuberg-Str. 1, 30625 Hannover, Germany. [decker.sebastian@mh-hannover.de](mailto:decker.sebastian@mh-hannover.de)

Telephone: +49-511-5322050 Fax: +49-511-5325877

Received: October 29, 2013 Revised: January 27, 2014

Accepted: February 16, 2014

Published online: April 16, 2014

### Abstract

We present a case of a 33-year-old female who sustained multiple injuries of her spine, including spinous process fractures of C5 to C7 and a lamina fracture of C6 and C7. Her thoracic spine showed transverse process fractures of T4 to T10, a compression fracture and lamina fracture of T3, spinous process and transverse process fractures of T4 and T5, a rotation injury of T6, as well as a compression fracture of L1. Thirteen months after posterior thoracic spinal instrumentation, a pedicle screw was suspected to be in contact with the aorta, which was proved by computed tomography angiograms. Consequently, implant removal was planned with direct exposure of the aorta in order to allow for immediate repair if needed. So far, studies that compare different techniques to remove pedicle screws that are suspected to penetrate the aorta are missing. However, different techniques have been described in case reports, mainly minimally invasive endovascular techniques vs open techniques such as thoracotomy.

© 2014 Baishideng Publishing Group Co., Limited. All rights reserved.

**Key words:** Spine; Pedicle screw; Aorta; Bleeding; Im-

plant removal; Hemorrhage

**Core tip:** Large vessel damage is described during spinal surgery and can lead to perforation of the aorta by misplaced pedicle screws. However, misplaced pedicle screws are often seen within postoperative computed tomography scans, only resulting in elective pedicle screw removal/exchange. Different techniques are available. We describe the use of a thoracotomy to prevent lethal hemorrhage. The importance of preoperative planning is highlighted, including pondering the advantages and disadvantages.

Decker S, Omar M, Krettek C, Müller CW. Elective thoracotomy for pedicle screw removal to prevent severe aortic bleeding. *World J Clin Cases* 2014; 2(4): 100-103 Available from: URL: <http://www.wjgnet.com/2307-8960/full/v2/i4/100.htm> DOI: <http://dx.doi.org/10.12998/wjcc.v2.i4.100>

### INTRODUCTION

Damage to large vessels like the aorta is a major complication in spinal surgery. This is a rare but life-threatening event. It is not uncommon that pedicle screws can penetrate the anterior cortex, therefore posing a risk of trauma to the aorta<sup>[1]</sup>. The anterior vertebral body is convex which increases the risk of penetration by the pedicle screws. As there is no biomechanical benefit from penetration of the anterior cortex with a pedicle screw, spinal surgeons generally do not strive for it<sup>[2]</sup>.

Research has shown that the posterior spinal approach poses less risk for severe aortic bleeding than that of anterior surgery. Liljenqvist *et al*<sup>[3]</sup> reported 99 patients of whom only one underwent pedicle screw exchange because of its proximity to the aorta<sup>[4-6]</sup>.

Major arterial bleeding has also been reported after lumbar disc surgery<sup>[7]</sup>. In particular, aortic damage has been reported after pedicle screw instrumentation. Most

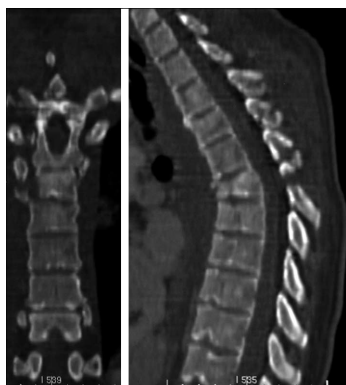

Figure 1 Severe rotation injury of T6 in the coronal and sagittal plane.

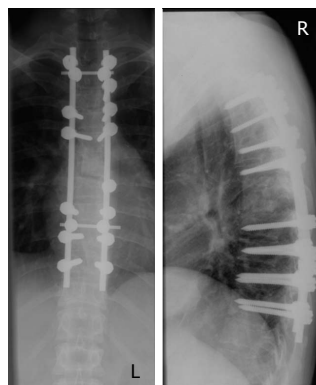


Figure 2 Postoperative X-ray after posterior fusion.

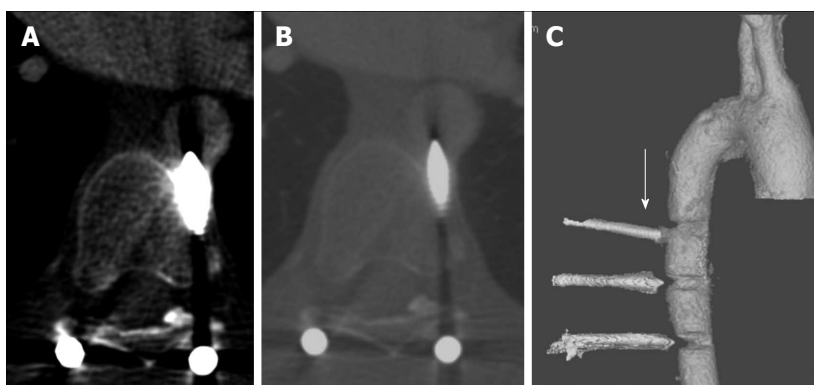


Figure 3 The left pedicle screw of T7 seems to perforate the aorta. A and B: Transversal view; C: 3D image, the left T7 pedicle screw is marked by the arrow.

authors favor minimally invasive endovascular treatment using a femoral artery approach to implant a stent for a misplaced pedicle screw that penetrates the aorta before implant removal<sup>[8-11]</sup>.

In the event of aortic bleeding during the removal of pedicle screws, the patient is at a particularly high risk for exsanguination. Different invasive strategies are available to protect the patient from life-threatening bleeding, of which thoracotomy with direct visualization of the aorta and endovascular approaches with the use of stents are the main strategies.

Whilst there are several reports on endovascular treatment of aortic damage due to spinal instrumentation, reports regarding thoracotomy are rare<sup>[12,13]</sup>. We present a case of a displaced pedicle screw with a concern of penetration of the aorta. Elective thoracotomy was performed during implant removal for best visualization and to give the opportunity for immediate aortic clamping in case of severe bleeding.

## CASE REPORT

A 33-year-old woman was admitted to our emergency department with multiple injuries during a roll-over accident with her car. Endotracheal intubation was performed at the site of the accident without complications. No neurological deficit was reported. She suffered from severe thoracic trauma with several rib fractures on both sides, lung contusions, a hemopneumothorax, as well as a left forearm fracture. She also suffered from multiple severe

spinal injuries. Her cervical spine had spinous process fractures of C5-C7 and a lamina fracture of C6-C7. Her thoracic spine showed transverse process fractures from T4 to T10, a compression fracture and lamina fracture of T3, spinous process and transverse process fractures of T4 and T5, a rotation injury of T6 (Figure 1), as well as a compression fracture of L1. We performed pedicle screw instrumentation from T2 to T10, as well as a laminectomy of T6 and posterior fusion on the day of injury (Figure 2). Three weeks later, an anterior interbody fusion of T5 to T7 was performed with an autologous iliac crest bone graft using a thoracoscopic approach. The postoperative computed tomography (CT) showed correct positioning of all pedicle screws, as well as the bone graft. Wound healing was regular without complications. She was discharged 23 d after admission and directly started rehabilitation. The patient stayed on our intensive care unit during the complete hospital stay. We allowed full weight-bearing. Follow-up care was performed by resident physicians. Thirteen months after anterior fusion, she presented in our outpatient clinic and a CT scan was performed to evaluate fracture healing as well as integration of the bone graft. There was a concern that the left pedicle screw of T7 was in contact with or could potentially perforate the aorta. This was not seen on the previous CT scan (Figure 3). Transesophageal sonography could not exclude an intraaortic position of the tip of the pedicle screw. Consequently, we planned the implant removal which was performed two weeks after the CT scan. This was done with the help of the vascular

surgeons.

The patient was placed in the right lateral position. Using a median approach, we first removed the cross connector, the rod as well as all the pedicle screws on the right side. A thoracotomy was then performed through the 6<sup>th</sup> and 7<sup>th</sup> intercostal space. Anterior preparation of the T7 left pedicle screw, which penetrated the anterior cortex of the corpus vertebrae, was done for optimal visualization before implant removal; the screw did not penetrate the aorta. The aorta was pulled across using a retractor so that it did not cover the screw of T7. We then removed the left rod as well as all the pedicle screws. No bleeding was observed with removal of the T7 pedicle screw. The incision was closed in layers after irrigation and placement of a chest tube and drains at the back. One month later, the patient needed revision surgery because of a seroma at the back. The seroma had been apparent since discharge from the hospital after implant removal and was punctured in our outpatient clinic three times before revision surgery. Afterwards, to our knowledge no further complication occurred. However, wound healing was monitored by a resident physician between the initial surgery and the implant removal.

## DISCUSSION

When surgeons suspect that a pedicle screw affects the aorta, one should keep in mind that implant removal should not be performed with the patient in a prone position without further precautions. Instead, intensive preoperative planning is needed and vascular surgeons should be contacted in advance if the trauma or orthopedic surgeon is not qualified to manage large vessel damage. Preoperative planning should include good visualization of the spatial relationships of the tip of the screw as well as the involved vessels. Different techniques are available, mainly minimally invasive endovascular techniques as well as a thoracotomy<sup>[8-13]</sup>. Clear guidelines as to which technique is best are missing so far. In this case, we decided to perform a thoracotomy to directly visualize the left T7 pedicle screw as we were afraid of not being able to control bleeding in case of aortic rupture using an endovascular approach. Although this is a very invasive technique, it provides the best visualization as well as access for a fast intervention like aortic clamping in the event of aortic injury. Nevertheless, alternatives such as preoperative implantation of femoral arterial access for quick endovascular intervention have to be considered and extensively discussed with the patient and the team preoperatively. When pedicle screw removal is planned because of its proximity to the aorta, the patient should be clearly informed about the risk of bleeding, as well as the various options to prevent life-threatening bleeding. We recommend a multi-disciplinary discussion of these surgeries to evaluate which technique is best. Generally, surgeons should decide depending on two main aspects. First, the technique has to be safe to prevent lethal hemorrhage and surgeons have to feel safe. Second, the sur-

gery should be as minimally invasive as possible. *E.g.*, a thoracotomy<sup>[12,13]</sup> is very invasive and should be avoided whenever possible. In conclusion, this is a very subjective decision. Clear data that help to decide which technique is best in which situation is missing and, in contrast, the decision-making process depends on individual surgical competence and experience.

## COMMENTS

### Case characteristics

The patient described did not show any symptoms 13 mo after posterior instrumentation of multiple spinal fractures. However, a computed tomography (CT) scan did raise suspicion that a pedicle screw could perforate the aorta.

### Clinical diagnosis

Like in the CT, intraaortic positioning of the pedicle screw could not be excluded by transesophageal sonography.

### Treatment

The authors planned implant removal using a thoracotomy for direct visualization of the aorta which did not appear to be perforated.

### Related reports

Thoracotomy is a very invasive technique that provides the best visualization during surgery but there have also been reports that described minimally invasive endovascular treatment.

### Term explanation

The authors experienced the importance of intensive preoperative planning, as well as a multidisciplinary approach to discuss all available treatment options to reduce the risk of lethal hemorrhage during surgery.

### Experiences and lessons

The strength of this case report is that it describes a rare situation that can, however, be seen by every spine surgeon. Although the authors describe a very invasive technique, other techniques have also been described. Nevertheless, the decision of which technique to use is very subjective as experience with this specific topic is low.

### Peer review

The study reported how a 33-year-old patient underwent a thoracotomy for pedicle screw removal due to suspected contact with the aorta. It is an unusual but not unheard of occurrence which is valuable to review.

## REFERENCES

- 1 **Vaccaro AR**, Rizzolo SJ, Balderston RA, Allardice TJ, Garfin SR, Dolinskas C, An HS. Placement of pedicle screws in the thoracic spine. Part II: An anatomical and radiographic assessment. *J Bone Joint Surg Am* 1995; **77**: 1200-1206 [PMID: 7642665]
- 2 **Könings P**, Böhmer G. Verletzungen des thorakolumbalen Übergangs. *Trauma und Berufskrankheit* 2000; **2**: 162-166 [DOI: 10.1007/PL00010931]
- 3 **Liljenqvist U**, Lepsien U, Hackenberg L, Niemeyer T, Halm H. Comparative analysis of pedicle screw and hook instrumentation in posterior correction and fusion of idiopathic thoracic scoliosis. *Eur Spine J* 2002; **11**: 336-343 [PMID: 12193995 DOI: 10.1007/s00586-002-0415-9]
- 4 **Ohnishi T**, Neo M, Matsushita M, Komeda M, Koyama T, Nakamura T. Delayed aortic rupture caused by an implanted anterior spinal device. Case report. *J Neurosurg* 2001; **95**: 253-256 [PMID: 11599848]
- 5 **Woolsey RM**. Aortic laceration after anterior spinal fusion. *Surg Neurol* 1986; **25**: 267-268 [PMID: 3945907 DOI: 10.1016/0090-3019(86)90237-5]
- 6 **Matsuzaki H**, Tokuhashi Y, Wakabayashi K, Kitamura S. Penetration of a screw into the thoracic aorta in anterior spinal instrumentation. A case report. *Spine (Phila Pa 1976)* 1993; **18**: 2327-2331 [PMID: 8278856]
- 7 **Brewster DC**, May AR, Darling RC, Abbott WM, Moncure

- AC. Variable manifestations of vascular injury during lumbar disk surgery. *Arch Surg* 1979; **114**: 1026-1030 [PMID: 485831 DOI: 10.1001/archsurg.1979.01370330048008]
- 8 **Minor ME**, Morrissey NJ, Peress R, Carroccio A, Ellozy S, Agarwal G, Teodorescu V, Hollier LH, Marin ML. Endovascular treatment of an iatrogenic thoracic aortic injury after spinal instrumentation: case report. *J Vasc Surg* 2004; **39**: 893-896 [PMID: 15071460 DOI: 10.1016/j.jvs.2003.10.056]
  - 9 **Freyrie A**, Gasbarrini A, Simoes CE, Gallitto E, Gargiulo M. Delayed presentation of a thoracic aortic injury with a vertebral pedicle screw. *Ann Vasc Surg* 2013; **27**: 499.e1-499.e3 [PMID: 23541778 DOI: 10.1016/j.avsg.2012.07.025]
  - 10 **Iyer MH**, Engoren M, Martin MW. Echo rounds: Transesophageal echocardiography: identification and management of a misplaced pedicle screw in the descending thoracic aorta after posterior spinal fusion. *Anesth Analg* 2013; **116**: 303-306 [PMID: 23302974 DOI: 10.1213/ANE.0b013e318275341d]
  - 11 **Carmignani A**, Lentini S, Acri E, Vazzana G, Campello M, Volpe P, Acri IE, Spinelli F. Combined thoracic endovascular aortic repair and neurosurgical intervention for injury due to posterior spine surgery. *J Card Surg* 2013; **28**: 163-167 [PMID: 23294480 DOI: 10.1111/jocs.12052]
  - 12 **Fukuda W**, Aoki C, Daitoku K, Taniguchi S, Fukuda I. Screw in the aorta: minimally invasive graft replacement for chronic aortic erosion by spinal instrument. *Ann Thorac Cardiovasc Surg* 2013; **19**: 320-322 [PMID: 23232300]
  - 13 **Tschoeke SK**, Gahr P, Krug L, Kasper AS, Heyde CE, Ertel W. Late diagnosis of pedicle screw malplacement with perforation of the thoracic aorta after posterior stabilization in a patient with multiple myeloma: case report. *Spine (Phila Pa 1976)* 2011; **36**: E886-E890 [PMID: 21343868 DOI: 10.1097/BRS.0b013e318202e4d1]

**P- Reviewers:** Camm EJ, Karmy-Jones R, Paraskevas KI  
**S- Editor:** Song XX **L- Editor:** Roemmele A **E- Editor:** Liu SQ





## Osteoid osteoma of the elbow mimicking hemophilic arthropathy

Michel P J van den Bekerom, Martijn A A van Hooft, Denise Eygendaal

Michel P J van den Bekerom, Department of Orthopaedic Surgery, OLVG, 1090 HM, Amsterdam, The Netherlands

Martijn A A van Hooft, Denise Eygendaal, Department of Orthopaedic Surgery, Amphibia Hospital, 4818 CK, Breda, The Netherlands

**Author contributions:** Van den Bekerom MPJ, van Hooft MAA and Eygendaal E contributed equally to this work; Eygendaal D designed the research; van Hooft MAA performed the research; and van den Bekerom MPJ wrote the paper.

**Correspondence to:** Denise Eygendaal, MD, PhD, Department of Orthopaedic Surgery, Amphibia Hospital, Molengracht 21, 4818 CK, Breda, The Netherlands. [deygendaal@amphibia.nl](mailto:deygendaal@amphibia.nl)

Telephone: +31-76-5953378 Fax: +31-76-955000

Received: October 22, 2013 Revised: December 27, 2013

Accepted: February 18, 2014

Published online: April 16, 2014

philia; Diagnosis

**Core tip:** Two issues are emphasized by reporting this case. Firstly, it is important to recognize the possibility of osteoid osteoma in a young adult patient with persistent chronic and nocturnal elbow pain which is alleviated with nonsteroidal anti-inflammatory drugs. Secondly, histopathological confirmation is not always possible and necessary to establish the diagnosis of osteoid osteoma.

van den Bekerom MPJ, van Hooft MAA, Eygendaal D. Osteoid osteoma of the elbow mimicking hemophilic arthropathy. *World J Clin Cases* 2014; 2(4): 104-107 Available from: URL: <http://www.wjgnet.com/2307-8960/full/v2/i4/104.htm> DOI: <http://dx.doi.org/10.12998/wjcc.v2.i4.104>

### Abstract

A case of osteoid osteoma of the elbow in a patient with hemophilia A is described. This male patient presented with chronic and nocturnal pain of the left elbow which was alleviated with acetaminophen. Besides pain, he also complained of stiffness. Before these complaints, he had recurrent bleedings in the elbow because of hemophilia. A delayed diagnosis of osteoid osteoma in the proximal part of the left ulna was established by a bone scan and a multislice spiral computed tomography (CT) scan. The lesion was surgically removed under CT-guidance. The histopathological analyses did not show specific features of osteoid osteoma. Two months after the operation, the complaints decreased and the range of motion of the left elbow improved. A diagnosis of osteoid osteoma of the elbow should be considered in young adult patients with persistent elbow pain and histological confirmation is not always necessary.

© 2014 Baishideng Publishing Group Co., Limited. All rights reserved.

**Key words:** Elbow; Osteoid osteoma; Surgery; Hemo-

### INTRODUCTION

Osteoid osteoma is a benign tumor in young adults and is relatively common, accounting for approximately 10%-12% of all benign skeletal neoplasms<sup>[1-3]</sup>. Jaffe<sup>[4]</sup> first described this entity in 1935 as a distinct osteoblastic skeletal tumor. It usually occurs in the second and third decade of life and the male/female sex ratio is approximately 3:1<sup>[1,3]</sup>. This tumor is curable by surgical excision. About 50% to 60% of osteoid osteomas occur in the long bones of the lower extremities and the femoral neck is the single most frequent anatomic site. In these cases, the diagnosis is usually typical. However, in the upper extremities where the bones of the elbow are the most frequent anatomic site, the clinical and imaging picture may be misleading, often mimicking other entities. This poses a challenge to the diagnosis which is often delayed, resulting in a significantly negative impact on the patient's quality of life<sup>[3,5]</sup>. Making the diagnosis is especially difficult when the patient is known to have other joint pathology. We describe a case of osteoid osteoma mimicking

arthropathy of the elbow in a patient with hemophilia.

## CASE REPORT

A 29-year-old man presented with chronic pain of the left elbow that was alleviated with painkillers. The pain had started suddenly 1.5 years ago after lifting a weight. The patient had locking complaints, nocturnal pain and pain at rest. He also had hemophilia A with recurrent bleedings in the elbow and progressive extension deficit of the elbow. A previous arthroscopy was performed but without improving the range of motion and diminishing pain. Physical examination of the left elbow revealed mild crepitus and no hydrops of the joint. Flexion of the elbow was possible until 110 degrees and there was an extension deficiency of 30 degrees. Pronation and supination was possible until 60 and 80 degrees respectively. Palpation of the lateral epicondyle and the proximal ulna was painful. There were no neurological or vascular abnormalities.

A plain radiograph (Figure 1) and a computed tomography (CT) scan performed in April 2007 revealed only osteoarthrotic changes without visualization of a nidus. A magnetic resonance imaging (MRI) scan showed a synovitis and hydrops and therefore a synovectomy was performed, without improvement in motion and pain.

A bone scan showed a circumscribed hyperemic and metabolic active focus in the proximal part of the left ulna. These findings match the diagnosis of osteoid osteoma, cartilage lesion, osteomyelitis and a fissure or fracture. In December 2007, a multislice spiral CT scan showed early degenerative changes of the left elbow joint with signs of arthritis. It also confirmed the diagnosis of osteoid osteoma in the proximal ulna with a clearly calcified central nidus just distal from the proximal radioulnar joint and with surrounding periost reaction. The measurement of the lesion was 12 mm × 8 mm.

The patient was given clotting factor VIII preoperatively and a CT-guided surgical excision of the lesion was performed (Figure 2). The histological analyses showed cancellous bone with sclerotic changes without specific features. A second opinion was sought from the national committee on bone tumors at Leiden University medical center and by consensus they confirmed the diagnosis osteoid osteoma, although histological analyses did not establish it.

Two months after the operation, the pain had decreased and the function of the elbow had improved. Flexion was possible until 120 degrees and there was an extension deficiency of 20 degrees. A plain radiograph of the left elbow performed after the operation showed a decrease of sclerotic changes in the proximal ulna. One year after surgical excision of the lesion the patient was discharged from follow up.

## DISCUSSION

The general clinical presentation is the persistence of a

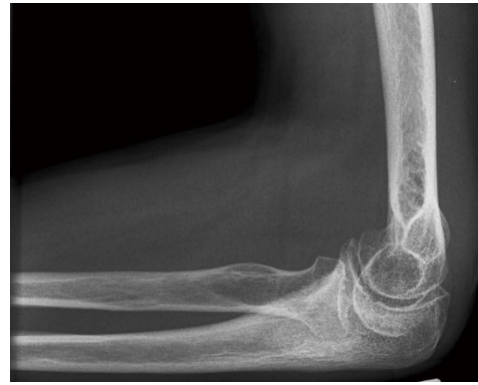

Figure 1 A plain radiograph revealed osteoarthrotic changes without visualization of a nidus.

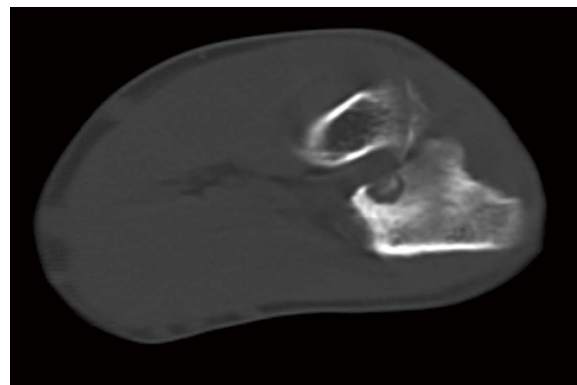


Figure 2 The nidus is computed tomography-guided surgically removed.

dull, diffuse, aching pain of increasing severity. The pain is frequently worse at night and is alleviated by nonsteroidal anti-inflammatory agents<sup>[1,3,5]</sup>. Because clinical features precede imaging, there is frequently a delay in the diagnosis and patients are often treated for and suspected of having other conditions. Osteoid osteoma of the elbow may masquerade as a non-specific synovitis. However, the possibility of osteoid osteoma must be considered in the presence of persistent pain with diminished range of movement of unknown etiology<sup>[2,5]</sup>.

Osteoid osteoma is a benign tumor that consists of a well-demarcated osteoblastic mass called a nidus that is surrounded by a distinct zone of reactive bone sclerosis. The zone of sclerosis is not an integral part of the tumor and represents a secondary reversible change that gradually disappears after the removal of the nidus. The nidus tissue has a limited local growth potential and usually is less than 1 cm in diameter<sup>[3]</sup>. The elbow is a rare location in which to find osteoid osteoma. Bruguera *et al*<sup>[6]</sup> identified only four osteoid osteomas among all primary tumors of the elbow in the Leeds Regional Bone Tumour Registry.

Our patient had a history of hemophilia A. This is an X-linked inherited bleeding disorder characterized by a deficiency of clotting factor VIII<sup>[7,8]</sup>. Arthropathy caused by recurrent intra-articular hemorrhages is a common complication of severe hemophilia. The elbow joint is

the second most common site of arthropathy in the hemophilic patient. Severe arthropathy of the elbow is complicated by pain, stiffness, reduced range of motion and chronic synovitis<sup>[9,10]</sup>. This comorbidity complicated and delayed the diagnosis of osteoid osteoma in the described case.

The radiological features of osteoid osteoma of the elbow include the following triad: (1) osteosclerosis, usually a dominant feature at initial imaging and typically enveloping the nidus; (2) joint effusion; and (3) a periosteal reaction that can involve both the bone in which the osteoid osteoma arises and adjacent bones. Awareness of these features will facilitate making the correct diagnosis, thereby facilitating timely and appropriate treatment<sup>[2]</sup>. About a quarter of osteoid osteomas are not detected on plain radiographs. CT scan, bone scintigraphy and MRI are useful to make an early and correct diagnosis. Although MRI is not very helpful in diagnosing osteoid osteoma, it can be beneficial in showing the inflammatory reaction produced by osteoid osteoma and in excluding other associated pathologies<sup>[1,3,11]</sup>.

In the described case the nidus was not observed on plain radiographs. Because of persisting complaints and clinical symptoms with normal radiographic examination, a bone scintigram was performed which showed an increased uptake of radioisotope. Additionally, a multislice CT scan was performed which localized the nidus, accurately disclosing its relationship with the surrounding anatomical structures, thus beneficial for the pre-operative planning<sup>[5]</sup>.

The histology of osteoid osteoma in the elbow is indistinguishable from that in typical locations<sup>[2]</sup>. The lesion is usually smaller than 1.5 cm in diameter and is composed of a central core of vascular osteoid tissue (nidus) surrounded by a peripheral zone of reactive sclerotic bone. The nidus appears as a distinct oval or round reddish area that can be easily separated from its bed. Microscopically, the nidus consists of thin bone trabeculae uniformly distributed in loose stromal vascular connective tissue. The trabeculae are usually thin and their size varies from lesion to lesion and in different areas of the same nidus. The central portion of the nidus is heavily ossified and less cellular compared with the more cellular but less mineralized peripheral portion<sup>[3,5]</sup>.

The diagnosis of osteoid osteoma in the described case was based on history, physical examination and radiology and was not confirmed by the pathology examination but by consensus of the national bone tumor committee. The complaints decreased and the range of motion improved after surgical excision of the tumor. In nearly 20% of patients surgical exploration fails to uncover the nidus, according to the Mayo clinic data<sup>[3]</sup>. Persistence of typical symptoms after surgery may mean that the nidus was not (completely) removed and that only surrounding reactive bone was excised. Some patients obtained complete postoperative relief of symptoms without histopathological confirmation of an osteoid osteoma nidus. This was possibly because the nidus may have been so small in relationship to the abundant surround-

ing sclerotic bone that it was removed but not recognized by the surgeon and thus not delivered for pathological examination; or the nidus may have been present in the specimens but was missed on histological survey; or the nidus may not have been found on pathological examination because of damage to the friable tissue or separation of the nidus<sup>[12]</sup>.

A conservative treatment for osteoid osteoma described in the literature is management with anti-inflammatory drugs for 30 to 40 mo which can induce permanent relief of symptoms and regression of the nidus observed on radiographs<sup>[13]</sup>. However, given the tendency for synovitis and loss of motion with a prolonged period of symptoms from osteoid osteoma of the elbow, the indicated treatment is total excision of the nidus, either by open surgery or by radio-frequency percutaneous ablation<sup>[3,5,11]</sup>.

Two issues were emphasized by reporting this case. Firstly, it is important to recognize the possibility of osteoid osteoma in a young adult patient with persistent chronic and nocturnal pain in the elbow which is alleviated with nonsteroidal anti-inflammatory drugs. Secondly, histopathological confirmation is not always possible and necessary to establish the diagnosis osteoid osteoma.

## ACKNOWLEDGMENTS

There are no financial or non-financial (political, personal, religious, ideological, academic, intellectual, commercial or any other) competing interests of the authors or a member of their immediate families to declare in relation to this manuscript. This case was also described in Dutch in the national orthopedic (non-indexed) journal.

## COMMENTS

### Case characteristics

A case of osteoid osteoma of the elbow in a patient with hemophilia A is described. This male patient presented with chronic and nocturnal pain of the left elbow which was alleviated with acetaminophen. Besides pain, he also complained of stiffness. Before these complaints he had recurrent bleedings in the elbow because of hemophilia.

### Clinical diagnosis

Physical examination of the left elbow revealed mild crepitus and no hydrops of the joint. Flexion of the elbow was possible until 110 degrees and there was an extension deficiency of 30 degrees. Pronation and supination was possible until 60 and 80 degrees respectively.

### Differential diagnosis

The possibility of osteoid osteoma must be considered in the presence of persistent pain with diminished range of movement of unknown etiology.

### Imaging diagnosis

A delayed diagnosis of osteoid osteoma in the proximal part of the left ulna was established by a bone scan and a multislice spiral computed tomography (CT) scan.

### Treatment

The lesion was surgically removed under CT-guidance. The histopathological analyses did not show specific features of osteoid osteoma.

### Experiences and lessons

Firstly, it is important to recognize the possibility of osteoid osteoma in a young adult patient with persistent chronic and nocturnal pain in the elbow which is alleviated with nonsteroidal anti-inflammatory drugs. Secondly, histopathological

confirmation is not always possible and necessary to establish the diagnosis osteoid osteoma.

### Peer review

This manuscript illustrates a unique case of osteoid osteoma of the elbow in a patient with hemophilia. The article is well-written and does not require modifications.

## REFERENCES

- 1 **Franceschi F**, Marinozzi A, Papalia R, Longo UG, Gualdi G, Denaro E. Intra- and juxta-articular osteoid osteoma: a diagnostic challenge : misdiagnosis and successful treatment: a report of four cases. *Arch Orthop Trauma Surg* 2006; **126**: 660-667 [PMID: 16927097 DOI: 10.1007/s00402-006-0203-9]
- 2 **Moser RP**, Kransdorf MJ, Brower AC, Hudson T, Aoki J, Berrey BH, Sweet DE. Osteoid osteoma of the elbow. A review of six cases. *Skeletal Radiol* 1990; **19**: 181-186 [PMID: 2333555 DOI: 10.1007/BF00204092]
- 3 **Dorfman HD**, Czerniak B. Benign osteoblastic Tumors. In: Dorfman HD, Czerniak B, editors. *Bone Tumors*, 3rd ed. St Louis: Mosby, 1998: 85-127
- 4 **Jaffe HL**. Osteoid-osteoma. *Proc R Soc Med* 1953; **46**: 1007-1012 [PMID: 13120827 DOI: 10.1001/archsurg.1935.01180170034003]
- 5 **Themistocleous GS**, Chloros GD, Benetos IS, Efstathopoulos DG, Gerostathopoulos NE, Soucacos PN. Osteoid osteoma of the upper extremity. A diagnostic challenge. *Chir Main* 2006; **25**: 69-76 [PMID: 16841767 DOI: 10.1016/j.main.2006.02.001]
- 6 **Bruguera JA**, Newman RJ. Primary tumors of the elbow: a review of the Leeds Regional Bone Tumour Registry. *Orthopedics* 1998; **21**: 551-553 [PMID: 9606695]
- 7 **Luck JV**, Silva M, Rodriguez-Merchan EC, Ghalambor N, Zahiri CA, Finn RS. Hemophilic arthropathy. *J Am Acad Orthop Surg* 2004; **12**: 234-245 [PMID: 15473675]
- 8 **Heyworth BE**, Su EP, Figgie MP, Acharya SS, Sculco TP. Orthopedic management of hemophilia. *Am J Orthop (Belle Mead NJ)* 2005; **34**: 479-486 [PMID: 16304795]
- 9 **Malhotra R**, Gulati MS, Bhan S. Elbow arthropathy in hemophilia. *Arch Orthop Trauma Surg* 2001; **121**: 152-157 [PMID: 11262781 DOI: 10.1007/s004020000201]
- 10 **Utukuri MM**, Goddard NJ. Haemophilic arthropathy of the elbow. *Haemophilia* 2005; **11**: 565-570 [PMID: 16236105 DOI: 10.1111/j.1365-2516.2005.01146.x]
- 11 **Weber KL**, Morrey BF. Osteoid osteoma of the elbow: a diagnostic challenge. *J Bone Joint Surg Am* 1999; **81**: 1111-1119 [PMID: 10466643]
- 12 **Sim FH**, Dahlin CD, Beabout JW. Osteoid-osteoma: diagnostic problems. *J Bone Joint Surg Am* 1975; **57**: 154-159 [PMID: 1112841]
- 13 **Kneisl JS**, Simon MA. Medical management compared with operative treatment for osteoid-osteoma. *J Bone Joint Surg Am* 1992; **74**: 179-185 [PMID: 1541612]

**P- Reviewers:** Fette AM, Hirose H, Matuszewski L, Mazzocchi M, Mazzocchi M, Ortmaier R

**S- Editor:** Ma YJ **L- Editor:** Roemmele A **E- Editor:** Liu SQ





## Spontaneous rupture of the renal pelvis presenting as an urinoma in locally advanced rectal cancer

Pankaj Kumar Garg, Debajyoti Mohanty, Vinita Rath, Bhupendra Kumar Jain

Pankaj Kumar Garg, Debajyoti Mohanty, Bhupendra Kumar Jain, Department of Surgery, University College of Medical Sciences and Guru Teg Bahadur Hospital, Delhi 110095, India  
Pankaj Kumar Garg, Department of Surgical Oncology, All India Institute of Medical Sciences, New Delhi 110029, India  
Vinita Rath, Department of Radiology, University College of Medical Sciences and Guru Teg Bahadur Hospital, Delhi 110095, India

Author contributions: Garg PK and Mohanty D designed the report; all the authors actively managed the patient; Garg PK and Mohanty D collected the patient's clinical data; all the authors analyzed the case, drafted the manuscript and finally approved it. Correspondence to: Dr. Pankaj Kumar Garg, Assistant Professor, Department of Surgery, University College of Medical Sciences and Guru Teg Bahadur Hospital, Dilshad Garden, Delhi 110095, India. [dr.pankajgarg@gmail.com](mailto:dr.pankajgarg@gmail.com)

Telephone: +91-11-22692536 Fax: +91-11-22590495

Received: December 25, 2013 Revised: January 26, 2014

Accepted: February 20, 2014

Published online: April 16, 2014

reserved.

**Key words:** Colorectal cancer; Urinoma; Spontaneous rupture of the renal pelvis; Percutaneous nephrostomy; Pigtail catheter drainage

**Core tip:** A recent development of a loin swelling in a patient with a malignant pelvic tumor should alert the clinician to the possibility of a urinoma due to spontaneous rupture of the obstructed renal pelvis. Early imaging for confirmation of diagnosis and decompression of the renal pelvicalyceal system help to arrest a further downhill course of the patients.

Garg PK, Mohanty D, Rath V, Jain BK. Spontaneous rupture of the renal pelvis presenting as an urinoma in locally advanced rectal cancer. *World J Clin Cases* 2014; 2(4): 108-110 Available from: URL: <http://www.wjgnet.com/2307-8960/full/v2/i4/108.htm> DOI: <http://dx.doi.org/10.12998/wjcc.v2.i4.108>

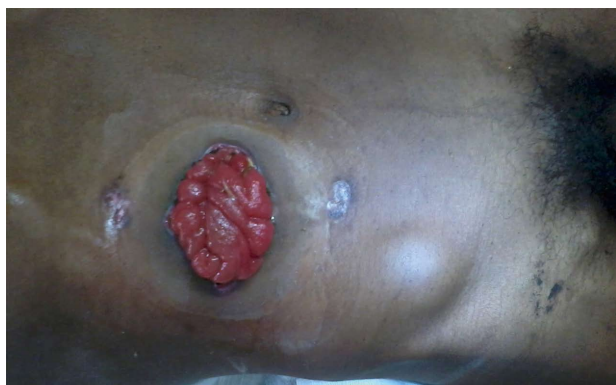### Abstract

A 29-year-old gentleman underwent a transverse colostomy for intestinal obstruction caused by advanced rectal carcinoma. On the 5<sup>th</sup> postoperative day, the patient developed a painful swelling on the right side of the abdomen. The contrast enhanced computed tomography of the abdomen revealed a right sided hydronephrosis, a large rent in the renal pelvis, and a large retroperitoneal fluid collection on the right side. Percutaneous nephrostomy and pigtail catheter drainage of the urinoma led to resolution of abdominal swelling. Development of a urinoma as a consequence of rectal carcinoma is highly unusual. Prompt imaging for confirmation of diagnosis, decompression of the renal pelvicalyceal system, and drainage of the urinoma limits morbidity.

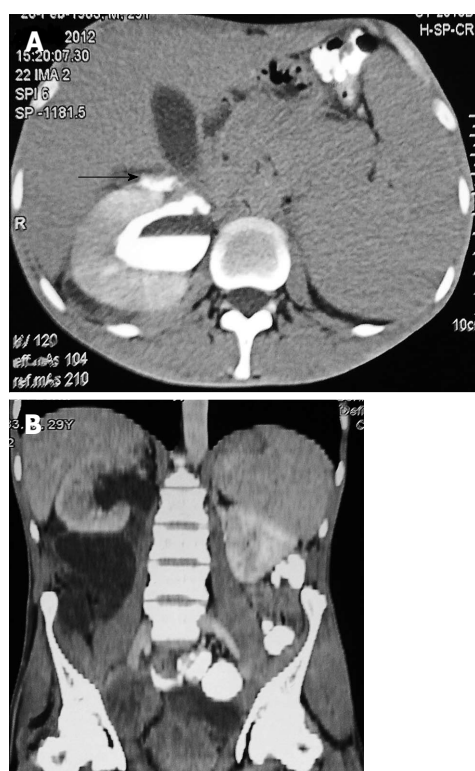
© 2014 Baishideng Publishing Group Co., Limited. All rights

### INTRODUCTION

A urinoma may be defined as a localized collection of urine within the retroperitoneum but outside the urinary system following a breach in the urothelium. Blunt abdominal trauma and iatrogenic injuries account for most urinomas. Pelvic malignancies have been less frequently implicated in the development of a urinoma. Infiltration of the lower ureter by the malignant pelvic growth causes persistent obstruction to urine flow and progressive dilatation of the upper urinary tract. The mounting pressure inside the pelvicalyceal system may lead to rupture of the renal pelvis and urinary extravasation<sup>[1]</sup>. We, herein, report a young patient suffering from locally advanced rectal adenocarcinoma who developed a urinoma following rupture of the obstructed right renal pelvis due to malignant infiltration of the lower ureter.



**Figure 1** Clinical photograph of the patient shows lump in right iliac fossa and diversion transverse colostomy.



**Figure 2** Computed tomography imaging. A: Axial contrast enhanced computed tomography (CT) of the abdomen shows a leak of contrast from the hydronephrotic right renal pelvis into the perinephric space (black arrow); B: CT coronal reconstruction shows a large retroperitoneal urinoma below the right kidney.

## CASE REPORT

A 29-year-old gentleman presented as a surgical emergency with features of intestinal obstruction. Abdominal examination revealed distention of the abdomen, palpable bowel loops and increased bowel sounds. Digital rectal examination coupled with proctoscopy revealed an encircling ulceroproliferative growth in the distal rectum, 5 cm proximal to the anal verge. The growth was fixed to the pelvis. A plain radiograph of the abdomen revealed dilated small and large bowel loops. Transverse colostomy was performed to relieve intestinal obstruction.

Endoscopic biopsy of the rectal growth revealed adenocarcinoma. On the 5<sup>th</sup> postoperative day, the patient developed a painful swelling on the right side of the abdomen (Figure 1). He did not report any urinary and bowel symptoms. Ultrasonography of the abdomen showed a large hypoechoic collection along the right abdominal wall extending from the right kidney to the right iliac fossa. Contrast enhanced computed tomography (CECT) of the abdomen demonstrated right hydronephrosis, a large rent in the renal pelvis, perinephric stranding and a large retroperitoneal fluid collection on the right side (Figure 2). Ultrasound guided percutaneous nephrostomy and pigtail catheter drainage of the fluid collection was performed along with administration of intravenous antibiotics. Two liters of blood tinged urine was drained and the swelling subsided within the next two days. The pigtail catheter was removed after five days. The patient was advised to have definitive chemoradiation therapy for the rectal adenocarcinoma; however, he opted for alternative medicine and did not come for further treatment.

## DISCUSSION

Ureters can be easily obstructed by pelvic malignancies by virtue of their thin wall and narrow caliber lumen. Unrelieved progressive urinary obstruction in the presence of a functional kidney can disrupt the pelvicalyceal system, leading to formation of a urinoma<sup>[2]</sup>. The renal pelvis, least supported by the parenchymal mass of kidney, is vulnerable for rupture in such scenarios. Carcinoma of the rectum, cervix, ovary, urinary bladder, and metastatic pelvic lymphadenopathy have been implicated in causation of spontaneous urinary rupture and urinoma formation<sup>[3-5]</sup>. Carcinoma of the rectum in particular has an unrelenting course in young individuals, characterized by advanced stage and higher-grade tumors at diagnosis<sup>[6]</sup>. The incidence of extra-intestinal complications is also more frequent in these patients. Apart from malignancies, mechanical obstruction secondary to congenital anomalies, calculus, prostatomegaly and pregnancy can also lead to disruption of the pelvicalyceal integrity and formation of a urinoma.

Urinomas exhibit gradual enlargement in size until the whole retroperitoneum is filled with the cystic mass. Since the contained urine is sterile, pain is not an early and prominent symptom. The patients usually present with an asymptomatic loin lump that requires imaging to confirm the diagnosis. Development of pain suggests infection of the extravasated urine or compression on the adjacent structures by the expanding urinoma. Pain may also be related to the primary disease. Ipsilateral loin pain, ileus and low grade pyrexia constitute the characteristic manifestations of a symptomatic urinoma<sup>[7]</sup>. If treatment is delayed, blood urea nitrogen and serum creatinine may rise due to re-absorption of urine from the urinoma. The level of creatinine in the urinoma fluid is 10 times higher than the creatinine level in the patient's serum<sup>[8]</sup>. Ultrasonography, intravenous urogram and CECT have been used for confirmation of the diagnosis. CECT can

identify the underlying cause, the location of the breach in the urothelial lining, the dimension of the collection and its relationship with the adjacent structures.

Asymptomatic, small and non expanding urinomas can be managed with close observation. Active management of urinomas includes decompression of the kidneys by means of a double J ureteral stent or percutaneous nephrostomy tube and prophylactic broad spectrum antibiotics<sup>[9]</sup>. Endoscopic placement of a ureteral stent is difficult in patients with obstruction of the lower ureter due to malignant infiltration. Percutaneous drainage of the urinoma should be considered if it persists despite satisfactory diversion of urine flow or if the extravasated urine becomes infected. Percutaneous drainage of the urinoma alone is unhelpful as the urinoma rapidly refills unless the primary pathology is tackled expeditiously. Delay in the management predisposes to the development of complications like perinephric abscess, peritonitis, sepsis, urinary stricture and, rarely, obstructive nephropathy and secondary hypertension due to compression on the upper urinary tract<sup>[10]</sup>. Correction of the underlying pathology is of paramount importance for the improved survival of patients. Nephrostomy/a ureteric stent should be retained until the ureteric obstruction is relieved.

A recent development of a loin swelling in a patient with a malignant pelvic growth should alert the clinician regarding the possibility of spontaneous rupture of the renal pelvis. Early confirmation of diagnosis by imaging and decompression of the renal pelvicalyceal system helps to arrest a further downhill course of patients.

## COMMENTS

### Case characteristics

A 29-year-old gentleman underwent a transverse colostomy for intestinal obstruction caused by advanced rectal carcinoma. On the 5<sup>th</sup> postoperative day, the patient developed a painful swelling on the right side of the abdomen.

### Clinical diagnosis

Tender swelling in the right iliac fossa.

### Differential diagnosis

Clinical examination and imaging methods can help to arrive at the diagnosis.

### Imaging diagnosis

The contrast enhanced computed tomography of the abdomen revealed a right

sided hydronephrosis, a large rent in the renal pelvis, and a large retroperitoneal fluid collection on the right side.

### Treatment

Ultrasound guided percutaneous nephrostomy and pigtail catheter drainage of the fluid collection was performed along with administration of intravenous antibiotics.

### Experiences and lessons

A recent development of a loin swelling in a patient with a malignant pelvic growth should alert the clinician regarding the possibility of spontaneous rupture of the renal pelvis.

### Peer review

This is a concise and clearly written case report which helps understanding of an unusual complication of malignant pelvic growth.

## REFERENCES

- 1 **Sayed R**, Nyamekye I, Kinder R. Unsuspected rectal adenocarcinoma causing a urinoma. *Int J Urol* 1997; **4**: 99-100 [PMID: 9179678 DOI: 10.1111/j.1442-2042.1997.tb00151.x]
- 2 **Morano JU**, Burkhalter JL. Percutaneous catheter drainage of post-traumatic urinoma. *J Urol* 1985; **134**: 319-321 [PMID: 4020986]
- 3 **Spurlock JW**, Burke TW, Dunn NP, Heller PB, Collins HS, Park RC. Calyceal rupture with perirenal urinoma in a patient with cervical carcinoma. *Obstet Gynecol* 1987; **70**: 511-513 [PMID: 3627616]
- 4 **Angulo JC**, Lopez JL, Lopez-Arregui E, Flores N. Urinoma formation secondary to ureteral obstruction by metastatic squamous cell carcinoma of the appendix. Case report. *Tumori* 1993; **79**: 447-449 [PMID: 8171749]
- 5 **Zunarelli E**, Pollastri CA, Calo M, Migaldi M, Galizia G, Criscuolo M. Metastatic breast carcinoma presenting as urinoma. *Pathologica* 1995; **87**: 712-714 [PMID: 8927439]
- 6 **O'Connell JB**, Maggard MA, Liu JH, Etzioni DA, Livingston EH, Ko CY. Do young colon cancer patients have worse outcomes? *World J Surg* 2004; **28**: 558-562 [PMID: 15366745]
- 7 **McAleer IM**, Kaplan GW. Pediatric genitourinary trauma. *Urol Clin North Am* 1995; **22**: 177-188 [PMID: 7855953]
- 8 **Goldfarb DA**, Poggio ED. Etiology, Pathogenesis, and Management of Renal Failure. In: Kavoussi LR, Novick AC, Partin AW, Peters CA, eds. *Campbell-Walsh Urology*. 10th ed. Philadelphia: Elsevier Saunders, 2012: 1193-1225
- 9 **Inoue K**, Nishimura K, Isogawa Y, Ohmori K. [Two cases of delayed ureteral fistulas following rectal amputation]. *Hinyokika Kyo* 1998; **44**: 285-288 [PMID: 9617627]
- 10 **Tenisch E**, Uldry E, Meuwly JY, Becce F. Bilateral subcapsular urinomas: an uncommon cause of Page kidney with renal failure. *Ultraschall Med* 2012; **33**: 113-116 [PMID: 22639761 DOI: 10.1055/s-0031-1274824]

**P- Reviewers:** Kobayashi N, Stanojevic GZ, Xu JM

**S- Editor:** Gou SX **L- Editor:** Roemmele A **E- Editor:** Liu SQ



## Rare case of an abdominal mass: Reactive nodular fibrous pseudotumor of the stomach encroaching on multiple abdominal organs

Xiao-Jiang Yi, Chuang-Qi Chen, Yin Li, Jin-Ping Ma, Zhi-Xun Li, Shi-Rong Cai, Yu-Long He

Xiao-Jiang Yi, Chuang-Qi Chen, Yin Li, Jin-Ping Ma, Shi-Rong Cai, Yu-Long He, Department of Gastrointestinal Surgery and Colorectal Surgery, the First Affiliated Hospital, Sun Yat-Sen University, Guangzhou 510080, Guangdong Province, China  
Zhi-Xun Li, Department of Pathology, the First Affiliated Hospital, Sun Yat-Sen University, Guangzhou 510080, Guangdong Province, China

**Author contributions:** Yi XJ and Chen CQ conducted the literature review, drafted and revised the manuscript, and approved the final submitted draft; Li Y performed the gastroscopy in the patient and provided the gastroscopic report and pictures; Li ZX conducted the gastroscopic and postoperative pathological evaluation of the biopsy and provided the pathological reports and pictures; Ma JP, Cai SR and He YL revised the manuscript and approved the final submitted draft.

**Correspondence to:** Chuang-Qi Chen, MD, PhD, Professor of Surgery, Department of Gastrointestinal Surgery and Colorectal Surgery, the First Affiliated Hospital, Sun Yat-Sen University, No. 58, Zhongshan 2<sup>nd</sup> Road, Guangzhou 510080, Guangdong Province, China. ccqsums@gmail.com

Telephone: +86-20-87755766 Fax: +86-20-87333122

Received: October 7, 2013 Revised: March 2, 2014

Accepted: March 13, 2014

Published online: April 16, 2014

### Abstract

Reactive nodular fibrous pseudotumor (RNFP), which presents abdominal clinical manifestations and malignant radiographic results, usually requires radical resection as the treatment. However, RNFP has been recently described as an extremely rare benign post-inflammatory lesion of a reactive nature, which typically arises from the sub-serosal layer of the digestive tract or within the surrounding mesentery in association with local injury or inflammation. In addition, a postoperative diagnosis is necessary to differentiate it from the other reactive processes of the abdomen. Furthermore, RNFP shows a good prognosis without signs of recur-

rence or metastasis. A 16-year-old girl presented with a 3-mo history of epigastric discomfort, and auxiliary examinations suggested a malignant tumor originating from the stomach; postoperative pathology confirmed RNFP, and after a 2-year follow-up period, the patient did not display any signs of recurrence. This case highlights the importance of preoperative pathology for surgeons who may encounter similar cases.

© 2014 Baishideng Publishing Group Co., Limited. All rights reserved.

**Key words:** Reactive nodular fibrous pseudotumor; Post-inflammatory lesion; Digestive tract; Mesentery; Good prognosis

**Core tip:** Our case report describes a rare benign tumor originating from the gastrointestinal tract. To date, this lesion has been reported in 20 cases worldwide. The most significant and important insights are that these diseases possess fairly good prognosis with opposite radiographic and clinical findings. Pathologically, reactive nodular fibrous pseudotumor (RNFP) was recently described arising from the sub-serosal layer or within the surrounding mesentery. However, the veracity of the pathological examination results and the etiology are still controversial. We will describe the complete diagnostic and therapeutic process of a young girl with RNFP and will retrospectively analyze the previously reported cases, particularly the microscopic and immunohistochemical characteristics.

Yi XJ, Chen CQ, Li Y, Ma JP, Li ZX, Cai SR, He YL. Rare case of an abdominal mass: Reactive nodular fibrous pseudotumor of the stomach encroaching on multiple abdominal organs. *World J Clin Cases* 2014; 2(4): 111-119 Available from: URL: <http://www.wjgnet.com/2307-8960/full/v2/i4/111.htm> DOI: <http://dx.doi.org/10.12998/wjcc.v2.i4.111>



## INTRODUCTION

Reactive nodular fibrous pseudotumor (RNFP) is a recently reported lesion that may arise from the gastrointestinal tract or the mesentery. It was first described by Yantiss *et al.*<sup>[1]</sup> in 2003. To date, 20 cases (8 cases in Czech Republic<sup>[2]</sup>, 7 cases in the United States<sup>[1,3,4]</sup>, 2 cases in France<sup>[5,6]</sup>, and 1 case each in Australia<sup>[7]</sup>, Turkey<sup>[8]</sup> and Italy<sup>[9]</sup>) have been reported in the literature. We described the first case in China. All the cases require surgical interventions with or without preoperative pathological examinations because of their typically malignant radiographic results. However, this lesion presents an encouraging prognosis during follow-up. Here we present a case in a young female patient.

## CASE REPORT

A 16-year-old girl from Jiangxi Province with no surgical history or abdominal injury history presented to a local medical institution with an approximately 3-mo history of progressive epigastric discomfort. Gastroscopy suggested a highly suspicious malignant tumor of the gastric cardia and fundus, chronic erythematous exudative antral gastritis and a duodenal bulbar ulcer. For further treatment, the patient was admitted to our hospital. Her abdominal examination revealed light tenderness in the epigastric region. A computed tomography (CT) scan showed a mass (5.8 cm × 3.8 cm × 7.9 cm) in the lesser curvature of the fundus attached to the left adrenal gland with obscure boundaries, and gastrointestinal stromal tumor (GIST) was suspected (Figure 1). Gastroscopy revealed a protruding lesion on the back wall of the gastric cardia and fundus with a coarse surface, and an approximately 1.0 cm × 1.0 cm ulcer was located in the middle of the lesion (Figure 2). Gastroscopic pathological biopsy findings demonstrated an ulcer-forming chronic gastritis without evidence of carcinoma (Figure 3); immunohistochemically, the biopsy specimen was positive for CK and M-CEA in the glandular epithelium, positive for CD31 and CD34 in the vascular endothelium, and positive for CD3 and L26 in the small lymphocytes. Therefore, lymphoma and gastric cancer were excluded (Figure 4), and additional immunohistochemical diagnostic evidence was needed to differentiate GIST from other differential diagnoses (Figure 5). Further gastroscopic ultrasonography showed an immense mass (approximately 4.8 cm × 3.1 cm) that did not penetrate the serosa with an uneven hypoechoic appearance and blood flow on the back wall of the lesser curvature of the fundus. Approximately 6-7 lymph nodes were found next to the mass, and the largest one was 0.6 cm in size. Based on these findings, the patient was sent to the operating room with a presumptive diagnosis of malignant tumor of the fundus (GIST). Upon exploratory laparotomy, a small nodule (1.0 cm × 1.0 cm) in the lesser omentum was detected, and the main mass (approximately 8.0 cm × 6.0 cm × 5.0 cm) was located in the lesser curvature of the gastric cardia and fundus transmurally infiltrating the stomach and encroaching on the pancreatic body

**Table 1 Antibodies and dilutions used in the evaluation of reactive nodular fibrous pseudotumor**

Antibody	Dilution	Source	Antigen retrieval
CK	0.181	Dako	Heat
Actin	0.181	Dako	Heat
CD34	Working solution	Novocastra	Heat
CD117	0.181	Dako	Heat
S-100	0.736	Novocastra	Heat
Desmin	Working solution	Zsjobio	Heat
DOG-1	0.389	Zsjobio	Heat
PDGFR	0.181	SANTA CRUI	Heat
Ki-67	0.181	Zsjobio	Heat
CD3	Working solution	Zsjobio	Heat
L26	0.736	Dako	Heat
ALK	0.111	Dako	Heat
β-Catenin	0.181	Maixinbio	Heat
CD31	Working solution	Novocastra	Heat
M-CEA	Working solution	Novocastra	Heat

and tail, spleen, and left adrenal gland; several swollen perigastric lymph nodes were also visible. Based on the above findings, a total resection of the stomach, pancreatic body and tail, spleen, and left adrenal gland was performed. An esophagojejunal Roux-en-Y anastomosis was used to reconstruct the digestive tract. Postoperative pathologic evaluation revealed a mass (approximately 8.0 cm × 6.0 cm) with a coarse surface transmurally infiltrating the stomach. The gross gastric specimen (15.0 cm × 11.0 cm × 5.0 cm in size) revealed a small depressed region 2.0 cm in size below the main mass. Microscopically, ulcers were detected on the mucosa; the sub-mucosa was composed of mature spindle cells embedded in a dense collagenic hyalinized stroma containing abundant infiltrative lymphocytes, plasmocytes, and hyperplastic lymphoid follicles. No mitosis, necrosis, or nuclear atypia was identified. Other sections including the pancreatic body and tail, spleen, and left adrenal gland and lymph nodes did not reveal any carcinoma tissue, and the staple line also appeared to be microscopically free of tumor. The immunohistochemistry findings of the spindle cells were as follows: actin focally (+), CD34 focally (+), CD117 (-), S-100 (-), desmin (-), DOG-1 (-), PDGFR (-), Ki-67 approximately 2% (+); the immunohistochemistry findings of the lymphocytes were as follows: CD3 (+), L26 (+). Combining the Hematoxylin Eosin (HE) stain and immunohistochemistry, the lesion was diagnosed as RNFP (Figure 6). Postoperatively, the patient's laboratory evaluation revealed elevated white blood cells and platelets. Accordingly, antibiotics, dipyrindamole, and bayaspirin were administered as symptomatic treatment. The patient did well after these interventions and was discharged from the hospital on postoperative day 11. Then, 10 mo later, a follow-up CT scan examination was clear of signs of recurrence and metastatic disease (Figure 7). After more than 2 years of follow-up, the patient did not complain of any discomfort and no signs of recurrence have been found.

HE stained 4-mm slides were cut from paraffin embedded tissue that was processed with 10% buffered formalin. A panel of antibodies (Table 1) was used to evaluate the tumors for the presence of smooth muscle,

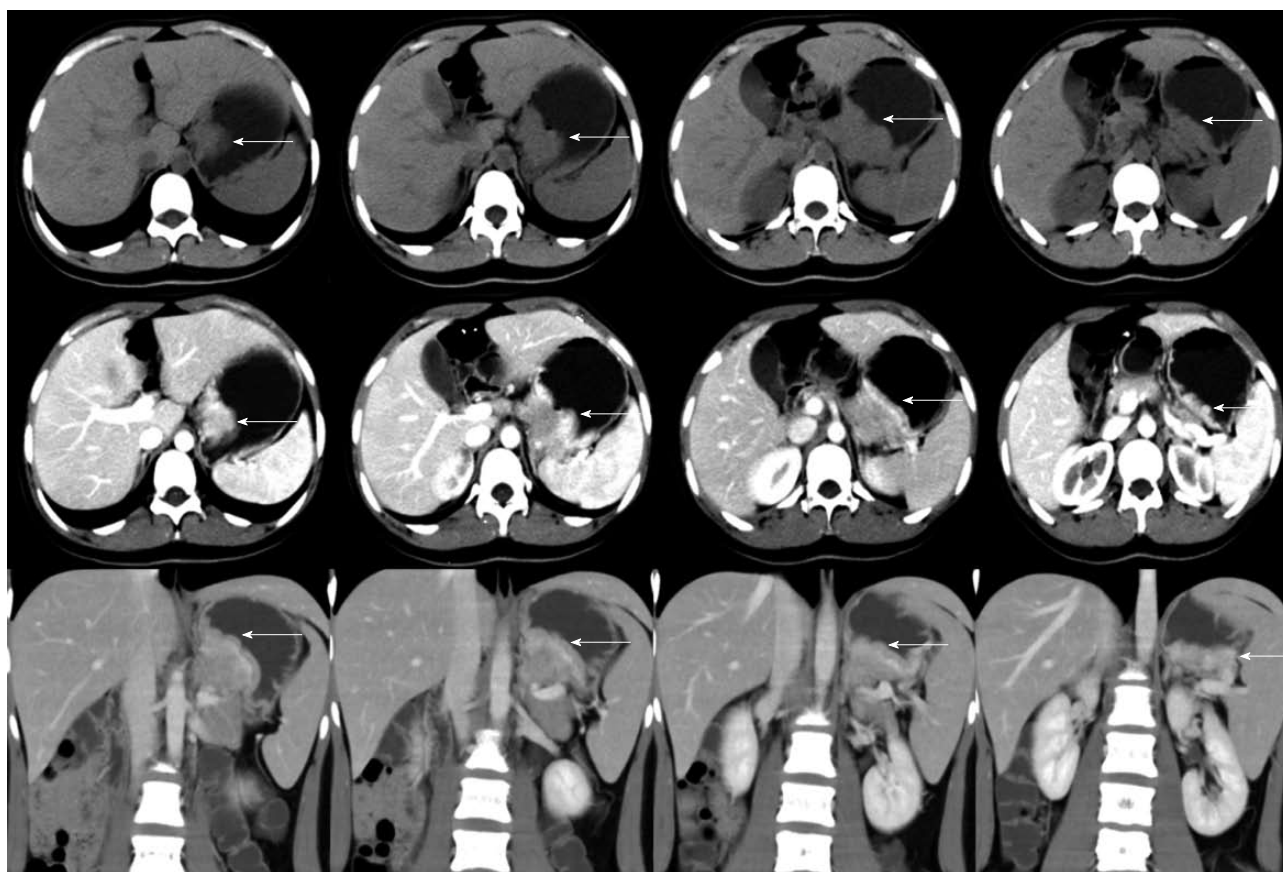


Figure 1 A computed tomography scan showing a mass (5.8 cm × 3.8 cm × 7.9 cm) in the lesser curvature of the fundus attached to the left adrenal gland with obscure boundaries (white arrows).

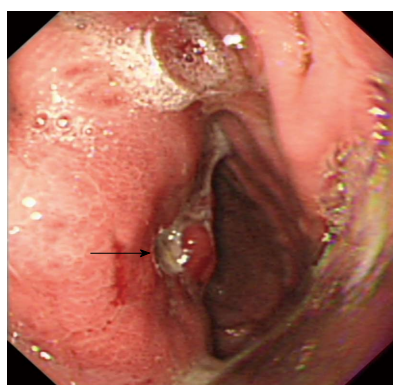


Figure 2 Gastroscopy revealing a protruding lesion on the back wall of the gastric cardia and fundus with a coarse surface, and an approximately 1.0 cm × 1.0 cm ulcer was located in the middle of the lesion (black arrow).

fibroblasts, myofibroblasts, glandular epithelium, vascular endothelium and lymphocytic classification. Several pivotal markers expressed in GISTs (CD117, CD34, DOG-1, PDGFR) and inflammatory myofibroblastic tumors [anaplastic lymphoma kinase (ALK)] were used as well.

## DISCUSSION

The first 5 RNFP cases were reported in adults by Yantiss *et al*<sup>[1]</sup>. The original pathological description was consid-

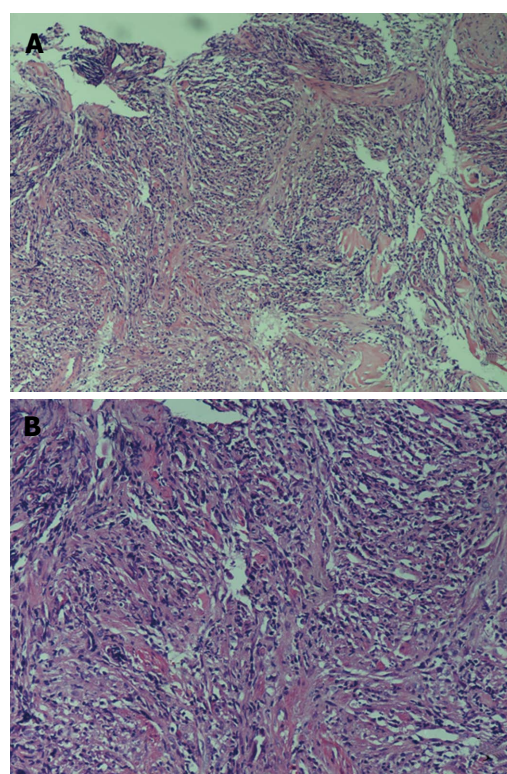
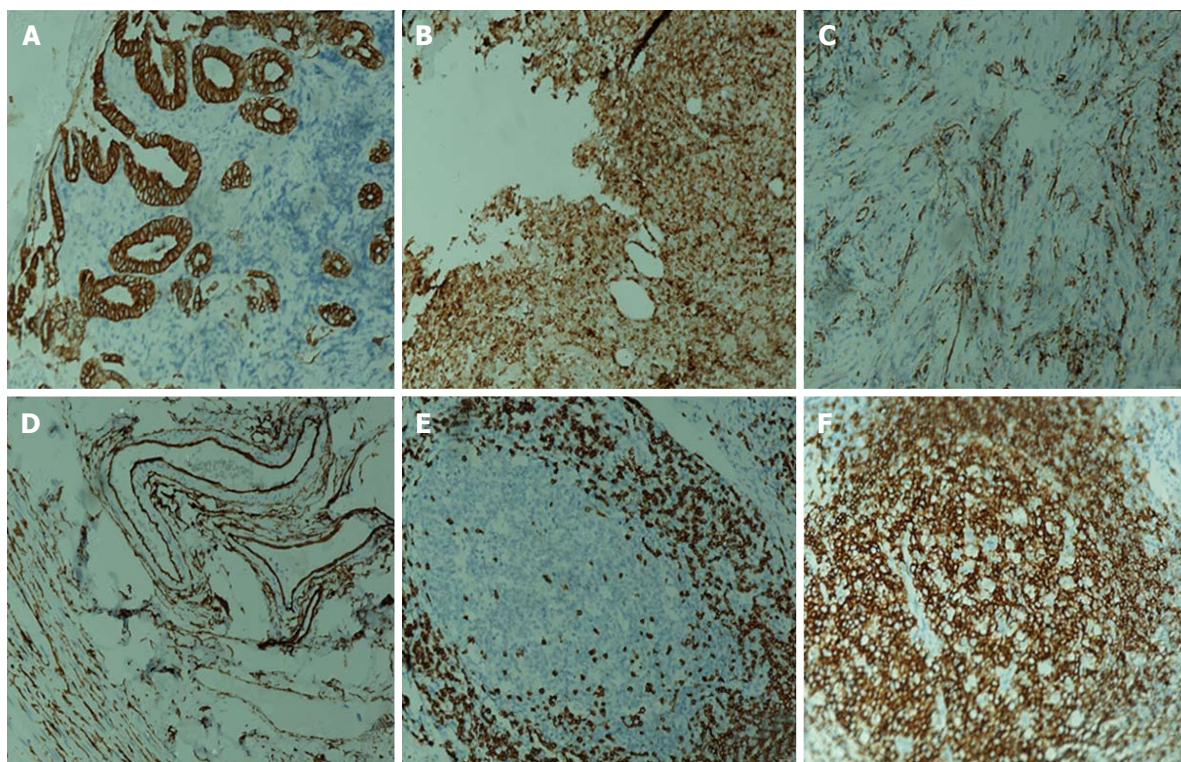


Figure 3 Gastroscopic pathological biopsy findings (Hematoxylin eosin stain) demonstrating an ulcer-forming chronic gastritis without evidence of carcinoma. [Magnification: A (10 × 10); B (10 × 20)].





**Figure 4** Immunohistochemistry of gastroscopic pathological biopsy. A: Glandular epithelium CK (+); B: Glandular epithelium M-CEA (+); C: Vascular endothelium CD31 (+); D: Vascular endothelium CD34 (+); E: Small lymphocyte CD3 (+); F: Small lymphocyte L26 (+). Magnification: 10 × 20.

ered a landmark in the short history of this disease. More recent cases have been reported, and our case represents the 21<sup>st</sup> report of this lesion worldwide in the English literature.

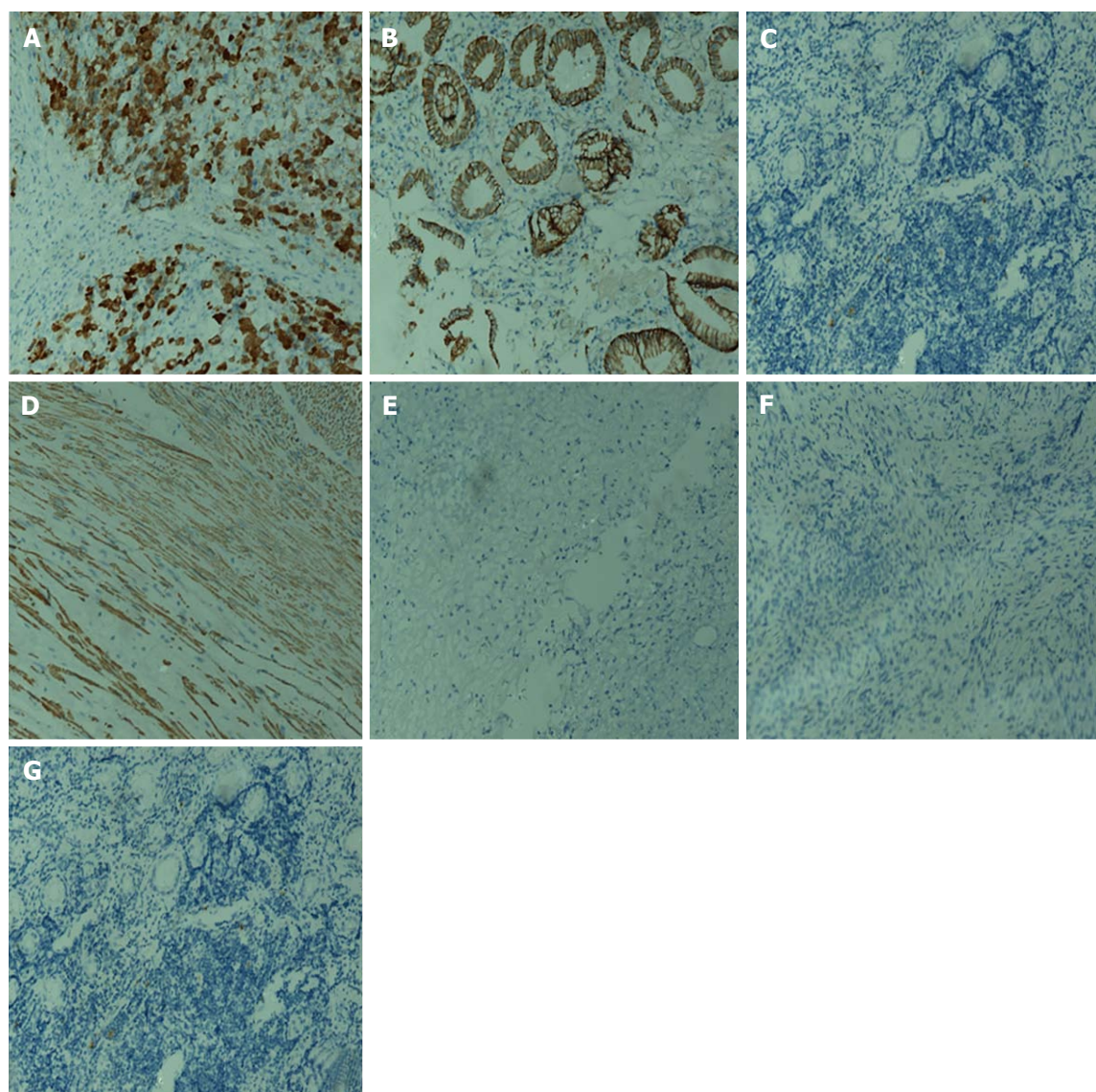
The adult population appears to be the main target in terms of the age distribution. A total of 18 adult cases (85.7%, age range, 22-72 years) have been reported compared to 1 case in a 1-year-old boy, 2 cases in a 13-year-old girl and our case of a 16-year-old girl. The average age is 46.1 years old (male: 49.6; female: 39.1). The sexual distribution ratio is 2:1 (male to female) consisting of 14 males (66.7%) and 7 females (33.3%). Unquestionably, males are more predisposed to this disease. The leading clinical characteristics can be summarized as follows: 11 patients including our case presented with abdominal symptoms, among which 4 patients had acute abdominal pain while 3 had chronic abdominal discomfort. Past medical history revealed that 5 patients (23.8%) had a history of abdominal surgery. One patient had undergone a left hemicolectomy 17 years previously for stage pT-3N0MO-II A colon cancer according to the 7<sup>th</sup> American Joint Committee on Cancer<sup>[9]</sup>. Yantiss *et al*<sup>[11]</sup> reported a patient with a history of alcoholism and recurrent pancreatitis, complicated by necrotizing pancreatitis, which required multiple surgical debridements. Another patient had a history of MEN-1 syndrome and multiple abdominal surgeries, including resections of an endocrine tumor of the pancreatic tail and an adrenal adenoma 23 and 21 years previously, respectively; one patient had a history of a laparoscopic cholecystectomy and resection of a

duodenal gastrinoma 1 year before the development of this tumor-like mass. The fifth patient's surgical history included a cholecystectomy some years prior for cholecystitis and an operation in 2001 for a strangulated hernia<sup>[7]</sup>. A significant abdominal medical history was noted in 9 cases (42.9%), including the following: a peptic ulcer in 3 cases (containing our case); a perforated duodenal diverticulum in a 32-year-old man; endometriosis together with ergotamine use for migraine in a 28-year-old woman; chronic bowel obstruction complicated by an external fistula in a 30-year-old woman; ileus caused by a tumor of the ileum in a 22-year-old man; and ingestion of a foreign body in 2 cases (in one case, it was an iron pin, and in the other, it was a small abscess cavity containing foreign bodies). Hence, in 14 patients (66.7%), a medical or surgical abdominal history appears to play a vital role in the development of RNFP.

In 2004, Daum *et al*<sup>[2]</sup> first suggested that RFNP originated from multipotent subserosal progenitor cells rather than myofibroblasts; therefore, some scholars had addressed the importance of investigating a patient's past abdominal surgery and medical history because such conditions could more or less trigger the occurrence of these lesions' and illustrated its reactive nature. The general findings were that these lesions represented an exuberant inflammatory response rather than a true tumor. However, our case was similar to the minority of RNFs without a previous abdominal surgery or injury.

RNFP presented with multiple masses or, a bit more frequently, as a single mass (13 cases, 61.9%). All of the





**Figure 5** More immunohistochemistry of endoscopic pathological biopsy. A: Anaplastic lymphoma kinase (+); B:  $\beta$ -catenin (+); C: Desmin (-); D: Actin (+); E: CD117 (-); F: DOG-1 (-); G: S-100 (-). Magnification:  $10 \times 20$ .

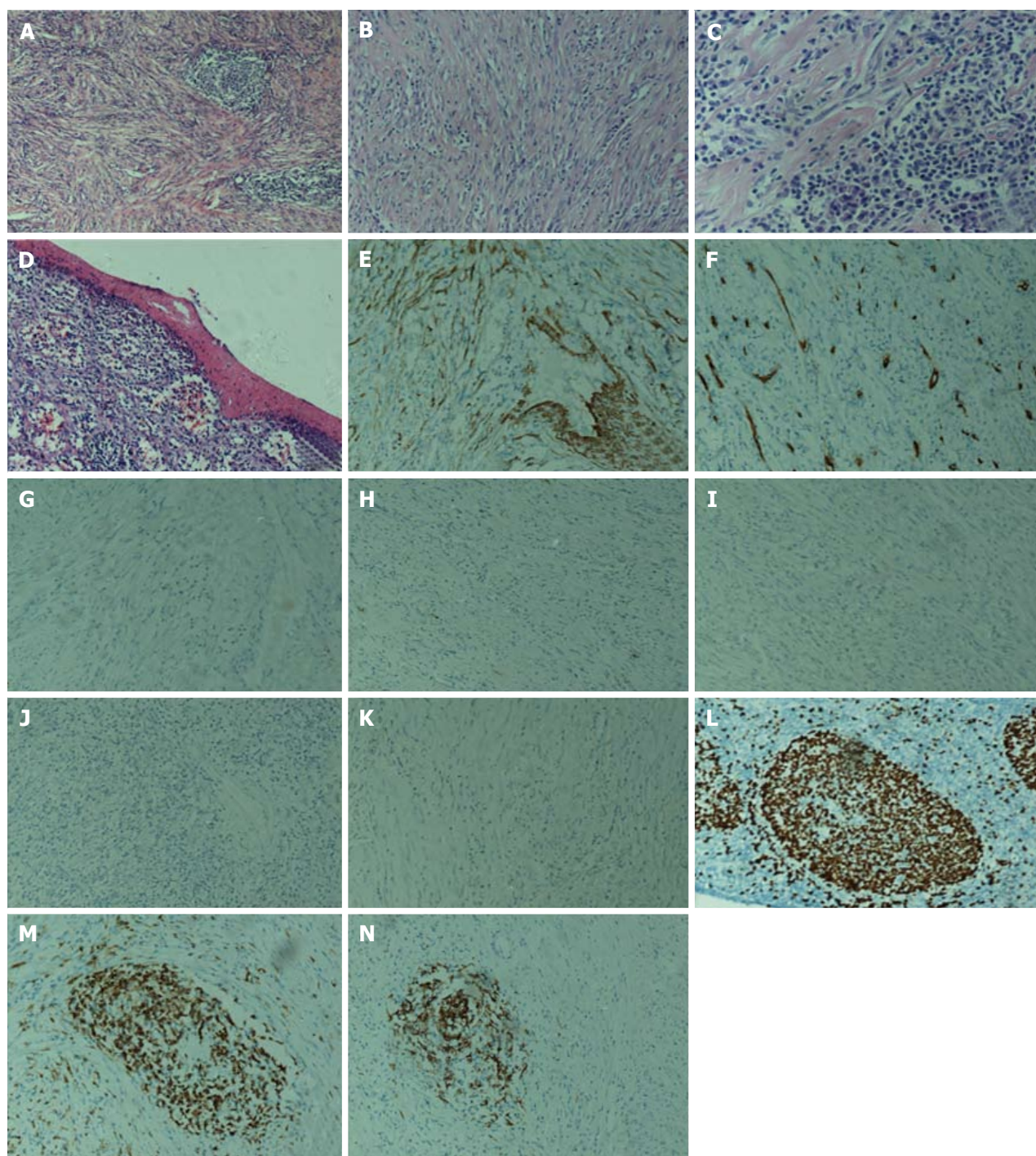
cases underwent complete resections (18 cases, 85.7%) except 3 cases in which incomplete resections were performed because of too many masses or nodules. One patient was a 71-year-old man with multiple hepatic deposits<sup>[9]</sup>, and in a 28-year-old woman, numerous nodules presenting on the surface of the ovaries, appendix, the bowel mesentery, the abdominal peritoneal wall, and the omentum were detected<sup>[8]</sup>. The anatomic site of the main lesions most commonly involved the colon with the appendix (7 patients) followed by the mesentery and the small bowel (especially the terminal ileum) (7 cases each), omentum (2 cases), the peritoneal wall (3 cases), the hepatic capsule, the gastric wall, and the peripancreas (1 case each). Our case was the first to be diagnosed as RNFP transmurally infiltrating the stomach, encroaching on the pancreatic body and tail, the spleen, and the left adrenal gland. Commonly, RNFP lesions are depicted as firm and of light colors from whitish to tan or gray; rarely, calcifications are present in the lesions (3 cases, 14.3%)

(Table 2).

Microscopically, all of the lesions shared the same feature consisting of a paucicellular proliferation of spindle or stellate cells embedded in a hyalinized matrix and sometimes surrounded by inflammatory cells (mostly in the form of mononuclear lymphoid cells) or lymphoid aggregates. If a lesion contains foreign bodies, dispersed giant cell granulomas are observed. Characteristically, the lesions do not show mitosis, necrosis, or nuclear atypia.

Ultra-structural examination of 3 cases by Daum *et al*<sup>[2]</sup> revealed spindle or stellate-shaped cells with rare intercellular junctions and irregular nuclei, prominent rough endoplasmic reticulum, sparse pinocytotic vesicles, bundles of microfilaments attached to dense bodies, and focal investment by external lamina. These features were typical of myofibroblastic differentiation. In addition, genetic investigations revealed no substitutions, deletions, or insertions occurring in exon 11 of the c-kit in 7 specimens. Likewise, no deletions or insertions in part of





**Figure 6 Hematoxylin Eosin stain.** A-D: Microscopically, sub-mucosa composing of mature spindle cells embedded in a dense collagenic hyalinized stroma containing abundant infiltrative lymphocytes, plasmocytes, and hyperplastic lymphoid follicles with incomplete capsule. No mitosis, necrosis, or nuclear atypia was identified; E-N: Immunohistochemistry, spindle cells: E: Actin focally (+); F: CD34 focally (+); G: CD117 (-); H: S-100 (-); I: desmin (-); J: DOG-1 (-); K: PDGFR (-); L: Ki-67 approximately 2% (+); lymphocytes: M: CD3 (+); N: L26 (+). Magnification: A ( $10 \times 10$ ); B, D-N ( $10 \times 20$ ); C ( $10 \times 40$ ).

exon 9 were observed. As above, ultra-structural analysis was performed by Yantiss *et al*<sup>[1]</sup> in 1 case, and the spindle or stellate-shaped cells were shown to contain abundant rough endoplasmic reticulum, aggregates of filaments associating with dense bodies, which are characteristic of fibroblastic and myofibroblastic differentiation.

Immunohistochemical staining demonstrated that all of the lesions stained positively for vimentin, (17/18) SMA, (8/15) CK, (10/13) MSA, except 4 cases that

stained positively for CD117 reported by Yantiss *et al*<sup>[1]</sup> and 1 case reported by Chatelain *et al*<sup>[5]</sup>; most cases are negative for CD117. The vast majority of the lesions stained negatively for desmin, CD34, S-100 protein, and anaplastic lymphoma kinase-1. The immunohistochemical features of our case showed actin focally (+), CD34 focally (+), CD117 (-), S-100 (-), desmin (-), DOG-1 (-), PDGFR (-), Ki-67 approximately 2% (+). Thus, based on these observations, our case is consistent with a diagnosis

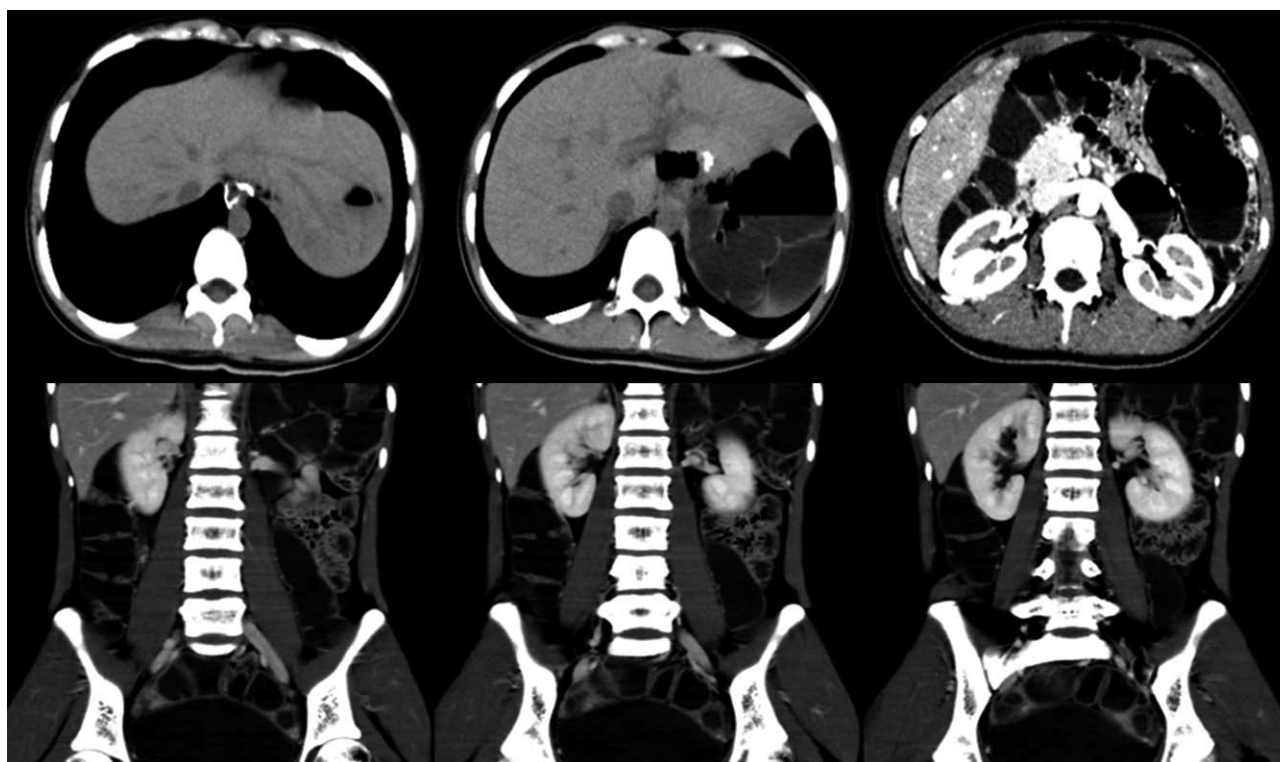


Figure 7 Follow-up abdominal computed tomography scan after 10 mo showing no signs of recurrence and metastatic disease.

**Table 2** Gross anatomopathological characteristic of reactive nodular fibrous pseudotumor reported previously

Ref.	Number of lesion	Size of main lesion (cm)	Morphology	Method of resection	Site of main lesion
<sup>2</sup> Yantiss <i>et al</i> <sup>[1]</sup>	Multiple	6.5 in diameter	Firm, tan-white	Complete resection	Mesentery of small intestine
	Single	4.3 in diameter	Ditto	Complete resection	Peripancreas
	Multiple	5.5 in diameter	Ditto	Complete resection	Mesentery of small intestine and large bowel
<sup>3</sup> Daum <i>et al</i> <sup>[2]</sup>	Multiple	6.5 in diameter	Ditto	Incomplete resection	Mesentery of small intestine
	Single	2.8 in diameter	Ditto	Complete resection	Mesentery of large bowel
	Single	3.0 in diameter	<sup>1</sup>	Complete resection	Small intestine
	Single	<sup>1</sup>	White fibrous, containing an iron pin	Complete resection	Large bowel
	Single	3.0 × 3.0	Fibrous	Complete resection	Large bowel
	Single	10.0 in diameter	Containing a coprolith	Complete resection	Large bowel
	Single	8.0 × 3.0	<sup>1</sup>	Complete resection	Small intestine
	Single	8.0 in diameter	Yellow-white, elastic	Complete resection	Subserosa and mesentery of large bowel
	Single	4.0 × 7.0 × 2.0	Hard fibrous, containing minute calcifications	Complete resection	Small intestine
	Single	3.0 × 4.0 × 6.0	A small abscess cavity containing foreign bodies	Complete resection	Subserosa of large bowel
Chatelain <i>et al</i> <sup>[5]</sup>	Single	9.0 in diameter	Firm, white	Complete resection	Mesentery of large bowel
Zardawi <i>et al</i> <sup>[7]</sup>	Multiple	0.5 × 2.2	Firm, white, containing two gray cord-like structures	Complete resection	Small intestine and the omentum
Saglam <i>et al</i> <sup>[8]</sup>	Multiple	0.6-6.0 in diameter	Firm, tan to white	Incomplete resection	The pelvic and abdominal peritoneum
Gauchotte <i>et al</i> <sup>[6]</sup>	Multiple	1.9-2.2 in diameter	Firm, grayish white	Complete resection	Stomach
Yin <i>et al</i> <sup>[3]</sup>	Single	2.0-3.0 in diameter <sup>4</sup>	Tan, white, containing calcifications	Complete resection	Mesentery of small intestine
Virgilio <i>et al</i> <sup>[9]</sup>	Multiple	6.0 × 4.0 × 3.0	Firm, white, containing calcifications	Incomplete resection	Small intestine, hepatic capsule the left paracolic gutter
McAteer <i>et al</i> <sup>[4]</sup>	Single	8.8 × 3.8 × 2.0	Firm, tan-gray	Complete resection	Mesentery of small intestine

<sup>1</sup>No mention in the above articles; <sup>2</sup>Containing 5 patients; <sup>3</sup>Containing 8 patients; <sup>4</sup>The data from computed tomography scan.

Table 3 Immunohistochemical findings of reactive nodular fibrous pseudotumor reported previously

Ref.	Vimentin	SMA	Cytokeratin (AE1/AE3)	MSA	Desmin	S-100	CD34	CD117	ALK-1	CK5/6	EMA	CAM5.2	34βE12	CD68	PI
<sup>1</sup> Yantiss <i>et al</i> <sup>[1]</sup>	(+) (5/5)	(+) (3/5)	(-) (0/5)	(+) (4/5)	(+) (3/5)	(-) (0/5)	(-) (0/5)	(+) (4/5)	(-) (0/5)	(-)	(-)	(-) (0/5)	(-)	(-)	<1.0%
<sup>2</sup> Daum <i>et al</i> <sup>[2]</sup>	(+)	Focally (+)	Focally (+)	(-)	(-)	(-)	(-)	(-)	(-)	(-)	(-)	(-)	(-)	(-)	0%
	(+)	(+)	(+)	(+)	(-)	(-)	(-)	(-)	(-)	(-)	(-)	(-)	(-)	(-)	3.70%
	(+)	Focally (+)	(-)	(-)	(-)	(-)	(-)	(-)	(-)	(-)	(-)	Focally (+)	(-)	(-)	<1.0%
	(+)	(+)	Focally (+)	(+)	(-)	(-)	(-)	(-)	(-)	(-)	(-)	(-)	(-)	(-)	<1.0%
	(+)	(+)	Focally (+)	(+)	(-)	(-)	(-)	(-)	(-)	(-)	(-)	(-)	(-)	(-)	<1.0%
	(+)	(+)	Focally (+)	(+)	(-)	(-)	(-)	(-)	(-)	(-)	(-)	(-)	(-)	(-)	3.50%
	NM	Focally (+)	NM	NM	(-)	(-)	NM	(-)	(-)	NM	NM	NM	NM	NM	<1.0%
<sup>3</sup> Chatelain <i>et al</i> <sup>[3]</sup>	(+)	Focally (+)	Focally (+)	Focally (+)	(-)	(-)	(-)	(-)	(-)	(-)	(-)	(-)	(-)	(-)	<1.0%
<sup>4</sup> Zardawi <i>et al</i> <sup>[7]</sup>	(+)	(+)	(-)	(-)	(-)	(-)	(-)	(-)	(-)	(-)	(-)	(-)	(-)	(-)	
<sup>5</sup> Saglam <i>et al</i> <sup>[8]</sup>	(+)	(+)	(-)	(-)	(-)	(-)	(+)	(+)	(-)	(-)	(-)	(-)	(-)	(-)	
<sup>6</sup> Gauchotte <i>et al</i> <sup>[6]</sup>	(+)	(+)	(+)	(-)	(-)	(-)	(-)	(-)	(-)	(-)	(-)	(-)	(-)	(-)	
<sup>7</sup> Virgilio <i>et al</i> <sup>[9]</sup>	(+)	Focally (+)	(+)	(+)	(-)	(-)	(-)	(-)	(-)	(-)	(-)	(-)	(-)	(-)	
<sup>8</sup> McAteer <i>et al</i> <sup>[4]</sup>	(+)	(+)	(+)	Focally (+)	(-)	(-)	(-)	(-)	(-)	(-)	(-)	(-)	(-)	(-)	

<sup>1</sup>Containing 5 patients; <sup>2</sup>Containing 8 patients; <sup>3</sup>A few stained positive for actin; <sup>4</sup>Positive for cytokeratin, focally positive with estrogen and progesterone receptors, negative for H-caldesmon; <sup>5</sup>Negative for neurofilament, synapto-physin, calretinin, caldesmon; <sup>6</sup>Negative for β-catenin nuclear staining; NM: No mention; SMA: Smooth muscle actin; MSA: Muscle-specific actin; ALK-1: Anaplastic lymphoma kinase-1; EMA: Epithelial membrane antigen; PI: Proliferative index.

Table 4 General information and clinical feature of reactive nodular fibrous pseudotumor reported previously

Ref.	Gender	Age	Presenting symptoms	Medical history	Follow up
Yantiss <i>et al</i> <sup>[1]</sup>	Male	48	<sup>1</sup>		No residual disease following surgical resection (mean follow-up 16.3 mo) and one patient who had an incomplete surgical resection had stable disease at 26 mo
	Female	50	<sup>1</sup>	Abdominal surgical history	
Daum <i>et al</i> <sup>[2]</sup>	Male	53	Acute abdominal pain	<sup>1</sup>	4 patients are available, without signs of recurrence and metastatic disease 5, 5, 6, and 7 yr, respectively
	Male	57	Acute abdominal pain	<sup>1</sup>	
	Male	71	<sup>1</sup>	Abdominal surgical history	
	Male	59	Abdominal symptoms	<sup>1</sup>	
	Male	46	<sup>1</sup>		
	Male	1	Abdominal symptoms		
	Male	68	<sup>1</sup>		
	Female	30	Abdominal symptoms		
	Female	65	<sup>1</sup>		
	Male	22	Abdominal symptoms		
Chatelain <i>et al</i> <sup>[3]</sup>	Male	41	<sup>1</sup>	<sup>1</sup>	1
Zardawi <i>et al</i> <sup>[7]</sup>	Female	72	<sup>1</sup>	Abdominal surgical history	1
Saglam <i>et al</i> <sup>[8]</sup>	Female	28	<sup>1</sup>	Abdominal history	1
Gauchotte <i>et al</i> <sup>[6]</sup>	Male	60	<sup>1</sup>	Abdominal history	No evidence of disease 4 mo later
Yin <i>et al</i> <sup>[3]</sup>	Male	65	<sup>1</sup>	No abdominal surgical history	1
Virgilio <i>et al</i> <sup>[9]</sup>	Male	71	<sup>1</sup>	Abdominal surgical history	No signs of recurrent 4 yr later
Mcateer <i>et al</i> <sup>[4]</sup>	Female	13	<sup>1</sup>	No abdominal surgical history	1

<sup>1</sup>No mention in the above articles.



of RNFP (Table 3).

Importantly, RNFP must be distinguished from the other reactive processes of the abdomen [such as calcifying fibrous pseudotumor, Vanek's tumor, retroperitoneal fibrosis, sclerosing mesenteritis, nodular fascitis, intra-abdominal fibromatosis] and more aggressive mesenchymal tumors, such as GIST, intraabdominal inflammatory myofibroblastic tumors, and inflammatory fibrosarcoma; such a differentiation may have strict requirement for pathologists.

Of the 21 patients, almost all cases underwent complete resections (18 cases, 85.7%); incomplete resections were performed in 3 cases because of too many masses or nodules. Surgical resection is currently the definitive method in these patients, and no chemotherapy treatment has been reported. Follow-up of 11 patients was available, without signs of recurrence and metastasis regardless of the *modus operandi* (Table 4).

## COMMENTS

### Case characteristics

A 16-year-old girl presented to the hospital with an approximately 3-mo history of progressive epigastric discomfort.

### Clinical diagnosis

Approximately 3-mo history of progressive epigastric discomfort.

### Differential diagnosis

Gastric cancer, colon cancer, acute pancreatitis.

### Laboratory diagnosis

Laboratory tests were within normal limits.

### Imaging diagnosis

A computed tomography scan showed a mass (5.8 cm × 3.8 cm × 7.9 cm) in the lesser curvature of the fundus attached to the left adrenal gland with obscure boundaries.

### Pathological diagnosis

Gastroscopic pathological biopsy demonstrated chronic ulcer-forming gastritis without evidence of carcinoma; immunohistochemically, the biopsy specimen was positive for CK and M-CEA in the glandular epithelium, positive for CD31 and CD34 in the vascular endothelium, and positive for CD3 and L26 in small lymphocytes, therefore, lymphoma and gastric cancer were excluded.

### Treatment

A total resection of the stomach, pancreatic body and tail, spleen, and left adrenal gland was performed, and an esophagojejunal Roux-en-Y anastomosis was performed to reconstruct the digestive tract.

### Related reports

The lesion is not very well understood and did not have predictive biomarkers to indicate reactive nodular fibrous pseudotumor.

### Term explanation

Actin, CD34, CD117, S-100, desmin, DOG-1, PDGFR, CD3 and L26 are immunohistochemical methods that are used for differentiating other tumors.

### Experiences and lessons

In the future, more microscopic and immunohistochemical methods should be developed, and more molecular level studies of these lesions to elucidate the etiology are needed.

### Peer review

This case presented in this article is well documented and interesting as it describes a rare pathology.

## REFERENCES

- 1 Yantiss RK, Nielsen GP, Lauwers GY, Rosenberg AE. Reactive nodular fibrous pseudotumor of the gastrointestinal tract and mesentery: a clinicopathologic study of five cases. *Am J Surg Pathol* 2003; **27**: 532-540 [PMID: 12657940]
- 2 Daum O, Vanecek T, Sima R, Curik R, Zamecnik M, Yamanaka S, Mukensnabl P, Benes Z, Michal M. Reactive nodular fibrous pseudotumors of the gastrointestinal tract: report of 8 cases. *Int J Surg Pathol* 2004; **12**: 365-374 [PMID: 15494862 DOI: 10.1177/106689690401200409]
- 3 Chatelain D, Manaouil D, Levy P, Joly JP, Sevestre H, Regimbeau JM. Reactive nodular fibrous pseudotumor of the gastrointestinal tract and mesentery. *Am J Surg Pathol* 2004; **28**: 416; author reply 417 [PMID: 15104309]
- 4 Zardawi IM, Catterall N, Cox SA. Reactive nodular fibrous pseudotumor of the gastrointestinal tract and mesentery. *Am J Surg Pathol* 2004; **28**: 276-277 [PMID: 15043323]
- 5 Saglam EA, Usubütün A, Kart C, Ayhan A, Küçükali T. Reactive nodular fibrous pseudotumor involving the pelvic and abdominal cavity: a case report and review of literature. *Virchows Arch* 2005; **447**: 879-882 [PMID: 16021510 DOI: 10.1007/s00428-005-0027-y]
- 6 Gauchotte G, Bressenot A, Serradori T, Boissel P, Plénat F, Montagne K. Reactive nodular fibrous pseudotumor: a first report of gastric localization and clinicopathologic review. *Gastroenterol Clin Biol* 2009; **33**: 1076-1081 [PMID: 19762186 DOI: 10.1016/j.gcb.2009.04.012]
- 7 Yin SS, Zhang L, Cziffer-Paul A, Divino CM, Chin E. Reactive nodular fibrous pseudotumor presenting as a small bowel obstruction. *Am Surg* 2011; **77**: 790-791 [PMID: 21679652]
- 8 Virgilio E, Pucci E, Pillozzi E, Mongelli S, Cavallini M, Ferri M. Reactive nodular fibrous pseudotumor of the gastrointestinal tract and mesentery giving multiple hepatic deposits and associated with colon cancer. *Am Surg* 2012; **78**: E262-E264 [PMID: 22691322]
- 9 McAteer J, Huaco JC, Deutsch GH, Gow KW. Torsed reactive nodular fibrous pseudotumor in an adolescent: case report and review of the literature. *J Pediatr Surg* 2012; **47**: 795-798 [PMID: 22498399 DOI: 10.1016/j.jpedsurg.2012.01.001]

P- Reviewers: Lu YW, Tanase CP S- Editor: Wen LL

L- Editor: A E- Editor: Liu SQ





[illegible]



## Contents

Monthly Volume 2 Number 5 May 16, 2014

<b>REVIEW</b>	120	Nutritional deficiencies in the pediatric age group in a multicultural developed country, Israel <i>Haimi M, Lerner A</i>
<b>MINIREVIEWS</b>	126	Animal models of atherosclerosis <i>Kapourchali FR, Surendiran G, Chen L, Uitz E, Bahadiri B, Moghadasian MH</i>
<b>CASE CONTROL STUDY</b>	133	Cesarean scar endometrioma: Case series <i>Çöl C, Yılmaz EE</i>
<b>SYSTEMATIC REVIEWS</b>	137	Systematic review of noninvasive treatments to arrest dentin non-cavitated caries lesions <i>Assunção IV, Costa GF, Borges BC</i>
<b>CASE REPORT</b>	142	Atrium of stone: A case of confined left atrial calcification without hemodynamic compromise <i>Jones C, Lodhi AM, Cao LB, Chagarlamudi AK, Movahed A</i>
	146	Primary colonic lymphoma: An incidental finding in a patient with a gallstone attack <i>Gigli S, Buonocore V, Barchetti F, Glorioso M, Di Brino M, Guerrisi P, Buonocore C, Giovagnorio F, Giraldi G</i>
	151	Parathyroid carcinoma in pregnancy <i>Baretić M, Tomić Brzac H, Dobrenić M, Jakovčević A</i>
	157	X-ray diagnosis with a bloating agent for foreign object ingestion <i>Tomishige H, Morise Z, Suzuki T, Hara F, Hibi M, Kato T, Hashimoto T</i>
	160	Vasculitis with renal involvement in essential mixed cryoglobulinemia: Case report and mini-review <i>Anis S, Abbas K, Mubarak M, Ahmed E, Bhatti S, Muzaffar R</i>
	167	Pancreatic tuberculosis mimicking pancreatic carcinoma during anti-tuberculosis therapy: A case report <i>Yang YJ, Li YX, Liu XQ, Yang M, Liu K</i>



**LETTERS TO  
THE EDITOR**

- 170    Pneumomediastinum after acute lymphoblastic leukemia and chemotherapy?  
*Cruz-Portelles A*

## Contents

*World Journal of Clinical Cases*  
Volume 2 Number 5 May 16, 2014

**APPENDIX** I-V Instructions to authors

**ABOUT COVER** Editorial Board Member of *World Journal of Clinical Cases*, Jorge Alves, PhD, Neuropsychophysiology Lab, CIPsi, School of Psychology, University of Minho, 4710-057 Braga, Portugal

**AIM AND SCOPE** *World Journal of Clinical Cases* (*World J Clin Cases*, *WJCC*, online ISSN 2307-8960, DOI: 10.12998) is a peer-reviewed open access academic journal that aims to guide clinical practice and improve diagnostic and therapeutic skills of clinicians.

The primary task of *WJCC* is to rapidly publish high-quality Autobiography, Case Report, Clinical Case Conference (Clinicopathological Conference), Clinical Management, Diagnostic Advances, Editorial, Field of Vision, Frontier, Medical Ethics, Original Articles, Clinical Practice, Meta-Analysis, Minireviews, Review, Therapeutics Advances, and Topic Highlight, in the fields of allergy, anesthesiology, cardiac medicine, clinical genetics, clinical neurology, critical care, dentistry, dermatology, emergency medicine, endocrinology, family medicine, gastroenterology and hepatology, geriatrics and gerontology, hematology, immunology, infectious diseases, internal medicine, obstetrics and gynecology, oncology, ophthalmology, orthopedics, otolaryngology, pathology, pediatrics, peripheral vascular disease, psychiatry, radiology, rehabilitation, respiratory medicine, rheumatology, surgery, toxicology, transplantation, and urology and nephrology.

**INDEXING/ABSTRACTING** *World Journal of Clinical Cases* is now indexed in PubMed Central, PubMed, Digital Object Identifier.

**FLYLEAF** I-V Editorial Board

## EDITORS FOR THIS ISSUE

Responsible Assistant Editor: *Xiang Li*  
Responsible Electronic Editor: *Su-Qing Liu*  
Proofing Editor-in-Chief: *Lian-Sheng Ma*

Responsible Science Editor: *Xiu-Xia Song*

**NAME OF JOURNAL**  
*World Journal of Clinical Cases*

**ISSN**  
ISSN 2307-8960 (online)

**LAUNCH DATE**  
April 16, 2013

**FREQUENCY**  
Monthly

**EDITORS-IN-CHIEF**  
**Giuseppe Di Lorenzo, MD, PhD, Professor**, Genitourinary Cancer Section and Rare-Cancer Center, University Federico II of Napoli, Via Sergio Pansini, 5 Ed. 1, 80131, Naples, Italy

**Jan Jacques Michiels, MD, PhD, Professor**, Primary Care, Medical Diagnostic Center Rijnmond Rotterdam, Bloodcoagulation, Internal and Vascular Medicine, Erasmus University Medical Center, Rotterdam, Goodheart Institute and Foundation, Erasmus Tower, Veenmos 13, 3069 AT, Erasmus City, Rotterdam, The Netherlands

**Sandro Vento, MD**, Department of Internal Medicine, University of Botswana, Private Bag 00713, Gaborone,

Botswana

**Shuhei Yoshida, MD, PhD**, Division of Gastroenterology, Beth Israel Deaconess Medical Center, Dana 509, Harvard Medical School, 330 Brookline Ave, Boston, MA 02215, United States

**EDITORIAL OFFICE**  
Jin-Lei Wang, Director  
Xiu-Xia Song, Vice Director  
*World Journal of Clinical Cases*  
Room 903, Building D, Ocean International Center, No. 62 Dongsihuan Zhonglu, Chaoyang District, Beijing 100025, China  
Telephone: +86-10-85381891  
Fax: +86-10-85381893  
E-mail: [bpgoffice@wjnet.com](mailto:bpgoffice@wjnet.com)  
Help desk: <http://www.wjnet.com/csp/helpdesk.aspx>  
<http://www.wjnet.com>

**PUBLISHER**  
Baishideng Publishing Group Inc  
8226 Regency Drive,  
Pleasanton, CA 94588, USA  
Telephone: +1-925-223-8242  
Fax: +1-925-223-8243  
E-mail: [bpgoffice@wjnet.com](mailto:bpgoffice@wjnet.com)  
Help desk: <http://www.wjnet.com/csp/helpdesk.aspx>

<http://www.wjnet.com>

**PUBLICATION DATE**  
May 16, 2014

**COPYRIGHT**  
© 2014 Baishideng Publishing Group Inc. Articles published by this Open Access journal are distributed under the terms of the Creative Commons Attribution Non-commercial License, which permits use, distribution, and reproduction in any medium, provided the original work is properly cited, the use is non commercial and is otherwise in compliance with the license.

**SPECIAL STATEMENT**  
All articles published in journals owned by the Baishideng Publishing Group (BPG) represent the views and opinions of their authors, and not the views, opinions or policies of the BPG, except where otherwise explicitly indicated.

**INSTRUCTIONS TO AUTHORS**  
Full instructions are available online at [http://www.wjnet.com/2307-8960/g\\_info\\_20100722180909.htm](http://www.wjnet.com/2307-8960/g_info_20100722180909.htm)

**ONLINE SUBMISSION**  
<http://www.wjnet.com/csp/>



## Nutritional deficiencies in the pediatric age group in a multicultural developed country, Israel

Motti Haimi, Aaron Lerner

Motti Haimi, Children's Health Center, Clalit Health Services, Bruce and Ruth Rappaport School of Medicine, Technion-Israel Institute of Technology, 34369 Haifa, Israel

Aaron Lerner, Pediatric Gastroenterology and Nutrition Unit, Carmel Medical Center, Bruce and Ruth Rappaport School of Medicine, Technion- Israel Institute of Technology, 34369 Haifa, Israel

Author contributions: Lerner A designed the research; Haimi M performed the computer search; Haimi M and Lerner A wrote the paper; both authors contributed equally to the work.

Correspondence to: Dr. Motti Haimi, MD, Senior Pediatrician, Children's Health Center, Clalit Health Services, Bruce and Ruth Rappaport School of Medicine, Technion-Israel Institute of Technology, Armon Tower, Neveim 18, 34369 Haifa, Israel. [mottiha@clalit.org.il](mailto:mottiha@clalit.org.il)

Telephone: +972-4-8351644 Fax: +972-4-8351650

Received: November 12, 2013 Revised: January 15, 2014

Accepted: March 17, 2014

Published online: May 16, 2014

© 2014 Baishideng Publishing Group Inc. All rights reserved.

**Key words:** Nutrient deficiencies; Type 2 diabetes; Obesity; Israel

**Core tip:** In view of the wide nutritional deficiencies in Israel, we encourage local health, education and industrial ministries to expand efforts to study and document those deficiencies with the vision of fortifying basic commonly used foods in order to fight the deficiencies and prevent their occurrence in the future.

Haimi M, Lerner A. Nutritional deficiencies in the pediatric age group in a multicultural developed country, Israel. *World J Clin Cases* 2014; 2(5): 120-125 Available from: URL: <http://www.wjgnet.com/2307-8960/full/v2/i5/120.htm> DOI: <http://dx.doi.org/10.12998/wjcc.v2.i5.120>

### Abstract

Nutrient deficiencies are prevalent worldwide. Diseases and morbid conditions have been described to result from nutritional deficiencies. It is essential to address nutrient deficiencies as these may lead to chronic long-term health problems such as rickets, iron deficiency anemia, goiter, obesity, coronary heart disease, type 2 diabetes, stroke, cancer and osteoporosis. In the present review we surveyed the extent and severity of nutritional deficiencies in Israel through a selective and comprehensive Medline review of previous reports and studies performed during the last 40 years. Israeli populations have multiple nutritional deficiencies, including iron, calcium, zinc, folic acid, and vitamins B12, C, D and E, spanning all age groups, several minorities, and specific regions. In Israel, some of the nutrients are mandatorily implemented and many of them are implemented voluntarily by local industries. We suggest ways to prevent and treat the nutritional deficiencies, as a step to promote food fortification in Israel.

### INTRODUCTION

Despite some reductions in world income-related poverty in recent years, malnutrition remains widespread. Nutrient deficiencies of iron, vitamin A, folic acid and zinc are prevalent worldwide, especially in children from low income areas<sup>[1]</sup>.

The lack of sufficient amounts of micronutrients affects health, function, and physical and cognitive development throughout the life cycle<sup>[1-4]</sup>. Many diseases and morbid conditions have been described to result from nutritional deficiencies. These include developmental defects, such as birth defects, physical and cognitive development delays, increased risk of infectious diseases, as well as increased risk of poor health in adulthood. Almost two-thirds of deaths of young children around the world are related to nutritional deficiencies<sup>[5-7]</sup>.

The discovery of essential nutrients and their roles in disease prevention has been instrumental in reducing

nutritional deficiency diseases such as goiter, rickets, pellagra and others in many places such as the United States, Canada, European countries and third world regions. In Israel, a state of massive immigration, where a substantial part of the population lives below the poverty line, there is a relatively high percentage of unemployment, and also aging of the population. These aspects contribute to the relatively high prevalence of essential nutrient deficiencies in various parts of the Israeli population, including iron-deficiency anemia, goiter and vitamin D deficiency<sup>[8-11]</sup>. Low vitamin B12 levels, low folic acid levels and consequently high homocysteine levels, and increased risk of coronary heart disease have also been observed in the Israeli population<sup>[12,13]</sup>. The regulatory authorities in Israel have been planning to implement food fortification for many years. Few of the nutrients are mandatorily implemented, and many are implemented voluntarily by local industries.

The goal of the present review was to survey the severity of nutritional deficiencies in Israel, and to suggest ways to prevent and treat this problem. Our hypothesis is that, in view of the special characteristics of Israel, despite being a developed country, with massive immigration, poverty and low social conditions, a high rate of nutritional deficiencies exist.

The present review is also aimed to summarize the subject, as a step to promote food fortification in Israel.

## RESEARCH

The extent and severity of nutritional deficiencies in Israel were reviewed through a selective and targeted Medline survey of previous reports and studies performed during the last 40 years.

The key words for the Medline search were combinations of the words: children, pediatrics, Israel, nutrients, nutrition, deficiency, fortification, as well as of specific nutrients such as iron, vitamins A, B, C, D, E, B12, Folic acid, calcium, phosphorus, magnesium, zinc and iodine.

## NUTRITIONAL DEFICIENCIES IN THE MODERN WORLD: CAUSES AND OUTCOME

The food consumption habits of the children changed during the last few decades, and they now consume too much fat, especially saturated fats, and sweetened beverages. They do not eat enough fruits or vegetables and consequently do not consume enough fiber. Most schoolchildren of low socioeconomic families consume less milk, cheese, meat, vegetables and fruits. Only a fifth of children consume the recommended daily amount of fruits and vegetables<sup>[5-8]</sup>. The calcium and iron intake among children is also low. One of the main reasons for the pediatric pandemic of obesity is the consumption of large amounts of soft drinks rich in sugar, accompanied by a lack of physical activity. It is essential to address nutrient and activity deficiencies as these may lead to chron-

ic long-term health problems, such as obesity, coronary heart disease, type 2 diabetes, stroke, cancer, and osteoporosis. It is well documented that overweight children are more likely to become obese adults<sup>[1-3,5]</sup>. The most common nutrient deficiencies among school children are: calcium, fiber, folate, iron, magnesium, potassium and vitamin E. It has been reported that the 2 most common deficiencies seen in generally healthy children are iron and vitamin D deficiencies<sup>[3]</sup>. Classical nutrient deficiencies lead to stunting (energy, protein and zinc), rickets (vitamin D) and other bone abnormalities (copper, zinc, vitamin C)<sup>[7,8]</sup>. Iron deficiency anemia, as a public health problem, has been well recognized in recent years in developing countries and even in developed ones, and has received considerable attention by the World Health Organization (WHO)<sup>[2,8]</sup>. Vitamin D deficiency and osteoporosis are common in northern climates, but even in sunny countries such as Israel, Australia and southern Europe. It is especially common among the elderly, veiled, dark skinned, and other at-risk population groups, who are also regularly warned to avoid sunlight to prevent skin cancers<sup>[7-9,11]</sup>.

The prevalence of endemic goiter and other iodine deficiencies has been reduced since the use of iodination of salt<sup>[8]</sup>. MacDonald<sup>[14]</sup> has reported that zinc deficiency in animals is characterized by growth inhibition and decreased food intake. Liu *et al.*<sup>[15]</sup> indicated that malnutrition predisposes to neurocognitive deficits, which in turn predispose to persistent externalizing behavior problems throughout childhood and adolescence. Their findings suggest that reducing early malnutrition may help reduce later antisocial and aggressive behavior.

## NUTRITIONAL DEFICIENCIES IN ISRAEL

In Israel, nutritional deficiencies have been documented throughout the last years in many reports.

### Deficiencies in special ethnic minorities

In the Bedouin population<sup>[16-29]</sup>, short stature, iron deficiency, vitamin A deficiency (15%-26% of infants), B12 deficiency, and vitamin E deficiency have been reported. In Ethiopians living in Israel, there are several reports of vitamin D deficiency and rickets<sup>[30,31]</sup>.

### Regional deficiencies

There were several reports on nutritional deficiencies in specific regions in Israel, including iron deficiency in children from central regions such as Hadera<sup>[32]</sup>; iron deficiency in Jewish children from a new immigrant town<sup>[33]</sup>; anemia in Jewish and Arab children from Akko<sup>[34]</sup>; iron deficiency anemia in infants from southern Israel<sup>[35]</sup>; and iron and folate deficiencies in children from a city in the North of Israel (Kyriat-Shmona)<sup>[36]</sup>.

### Special populations have demonstrated specific nutritional deficiencies

In adolescents, several deficiencies were reported, includ-

**Table 1 Summary of the main nutritional deficiencies in the Israeli population**

Israeli sub-population	Nutritional deficiency	Ref.
Bedouins	Iron, vitamin A, vitamin B12, vitamin E	[16-29]
Ethiopians	Vitamin D	[30,31]
Specific regions	Iron, folic acid, vitamin B12	[32,36,69]
Adolescents	Iron, vitamin D, calcium, phosphorus, magnesium, zinc	[9,38-40]
Toddlers	Vitamin D, Iron, Calcium	[41,42]
Overweight children	Iron, vitamin B12, folic acid, phosphorus, calcium, vitamin D	[43-45]
Military recruits	Iron, magnesium	[46-48]
Infants	Iron	[32,49-53]
Vegetarians	Vitamin D, vitamin B12, vitamin B1, iron, zinc	[54-57]
Pregnant women	Iron	[58,59]
<i>Helicobacter pylori</i> gastritis	Iron	[60]
Celiac disease patients	Vitamin D	[10,61]
Gaucher patients	Vitamin B12	[68]
Anorexia nervosa patients	Zinc	[70,71]

ing iron deficiency (especially in athletes)<sup>[37]</sup>, and deficiencies in vitamin D<sup>[9,38,39]</sup>, calcium, phosphorus, magnesium and zinc<sup>[40]</sup>. Toddlers and adolescents in Israel, as in other Western countries, are using “energy drinks”, which can cause nutritional deficiencies such as vitamin D and iron<sup>[41]</sup>. A study of children from central Israel<sup>[42]</sup> revealed a lack of calcium in their food and decreased bone density. Children with overweight demonstrated iron deficiency<sup>[43]</sup> and vitamin B12 deficiency<sup>[44]</sup>. In bariatric surgery candidates, deficiencies in iron, folic acid, ferritin, B12, phosphorus, calcium and vitamin D were reported<sup>[45]</sup>.

In military recruits and in soldiers, iron deficiency<sup>[46,47]</sup>, and low magnesium levels<sup>[48]</sup> were noted.

A high percentage of the infant population in Israel has iron deficiency anemia<sup>[32,49-52]</sup>. It can badly affect their learning achievements and behavior<sup>[53]</sup>.

In the vegetarian population, there was a lack of calories and proteins, rickets, osteoporosis, B12 and B1 deficiencies, iron and zinc deficiencies, and increased risk of infections<sup>[54-57]</sup>. A high incidence of iron deficiency was noted in pregnant women<sup>[58,59]</sup>. Iron deficiency anemia was reported also in people with *Helicobacter pylori* (*H. Pylori*) gastritis<sup>[60]</sup>. Children with celiac disease had low bone mineral density. Their average serum vitamin D level was 25.6 ng/L, suggestive of osteopenia<sup>[10,61]</sup>.

### Specific deficiencies

Iron deficiency anemia has been extensively documented in Israel, especially in infants<sup>[8,33,35,49-52]</sup>, adolescents<sup>[47]</sup>, pregnant women<sup>[58]</sup>, adults and the elderly<sup>[8]</sup>.

Vitamin D deficiency is common in the Israeli population. In 2009, 87% of the adult population and 52% of the pediatric population had low vitamin D levels<sup>[11,62-65]</sup>. Rickets in infants is attributable to inadequate vitamin D intake and decreased exposure to sunlight. It seems that vitamin D leading to osteoporosis is common in the elderly even in sunny countries such as Israel<sup>[63]</sup>. Vitamin D

deficiency is also associated with autoimmune diseases<sup>[64]</sup>. Orthodox mothers after delivery had low levels of vitamin D<sup>[66]</sup>.

Vitamin B12 and folate deficiencies have been noted in Israeli children, especially as a result of low intake of vegetables<sup>[44,67]</sup>; 22% of Ashkenazi Jews and 40% of Gaucher patients in Israel were reported to have B12 deficiency<sup>[68]</sup>. In Beer Sheva, a city in the south of Israel, 37% of the population had B12 deficiency<sup>[69]</sup>. Recent reports by Kark *et al.*<sup>[12]</sup> have shown high homocysteine levels among Israelis, and despite vast reductions in mortality rates, the rates of coronary heart disease are still very high. Folic acid, as an antagonist to homocysteine, is increasingly accepted as a major preventive factor in coronary heart disease<sup>[13]</sup>.

Zinc deficiency was noted, among other nutrient deficiencies, in anorexia nervosa patients in Israel<sup>[70,71]</sup>. Zinc deficiency was also reported in children<sup>[72]</sup>, and in attention deficit hyperactivity disorder patients<sup>[73]</sup>. Table 1 summarizes the nutritional deficiencies in Israel described in our study.

In summary, Israeli populations have multiple nutritional deficiencies including iron, calcium, zinc, folic acid, and vitamins B12, C, D and E, spanning all age groups, several minorities, and specific regions. The most common nutritional deficiencies in the pediatric age group in Israel are iron and vitamin D. These deficiencies are mostly common in special populations, such as Bedouins, vegetarians, Ethiopians, obese children, pregnant women and their babies, gluten-sensitive populations, children with *H. Pylori*, children with behavioral problems and anorexia, diabetics, but deficiencies span the whole Israeli population.

## FOOD FORTIFICATION

Fortification of commonly eaten foods with micronutrients offers a cost-effective solution that can reach large populations<sup>[74]</sup>.

It is the responsibility of public health authorities to ensure that the general population, and especially those under in poverty are assured of an adequate basic daily intake of minerals and vitamins. This can only be achieved through appropriate vitamin and mineral enrichment of basic foods. Food fortification can reach many people who either do not or cannot comply with the individual approach of health education and healthy diet, due to its higher cost, or due to a lack of knowledge or access<sup>[75,76]</sup>. The addition of micronutrients to food for health reasons has been known for many years<sup>[8,77,78]</sup>.

Food fortification was adopted in the United States during the 1920s and the 1930s, by enriching flour in order to eliminate pellagra in the southern states. In 1942, a program to enrich flour with vitamins and iron was adopted by the United States government<sup>[76]</sup>. In the beginning it included enriching flour with vitamin B1 (thiamin) to prevent beriberi, niacin to prevent pellagra, riboflavin for efficient use of vitamin B6, and iron to prevent anemia. Later, it was decided to also add vitamin

D and calcium, and it was expanded to enrich corn flour in 1943, pasta in 1946, and rice in 1958. The success of this program led to additional fortification of breakfast cereals with B-vitamins and iron in 1969<sup>[75]</sup>.

In Canada, food fortification has been mandatory since 1979, including iodine in salt, iron and vitamin B complex in flour, and vitamin A and D in milk products. In 1998, folic acid was additionally added to flour, with positive effects in reduction of neural tube defects within 2 years<sup>[79]</sup>. Fortification of flour and grains with folate was adopted also in the United States in 1998, and was followed by a decline in the total prevalence of neural tube defects<sup>[80]</sup>.

In Europe, food fortification has encountered considerable opposition over the past 2 decades (especially in Scandinavian countries). Nevertheless, it has recently been put into practice, with most countries fortifying salt with iodine to prevent iodine deficiency<sup>[81]</sup>.

In 1996, the WHO has renewed its call for the universal iodization of salt, since iodine deficiency was considered the greatest cause of preventable brain damage and mental retardation worldwide<sup>[82]</sup>. In addition, the WHO also promotes fortification and supplementation for reduction of iron deficiency anemia, vitamin A deficiency and others, although referring usually to developing countries.

Regarding vitamin D deficiency, it has been widely recognized, not only with reference to infants and children, but also for other age groups, including adolescents and older age groups. In 2003, the American Academy of Pediatrics emphasized the importance of milk fortification with vitamin D supplementation throughout childhood and adolescence, with consideration of subclinical vitamin D deficiency in many population groups<sup>[83]</sup>.

Israel is working towards food fortification, but it is on a voluntary basis for some vitamins and minerals, while mandatory for others, such as fortification of salt, milk products and flour. Nevertheless, most salt sold to the Israeli population is still un-iodized<sup>[78]</sup>. As previously mentioned, although Israel is a sunny country, vitamin D deficiency is well recognized among the elderly<sup>[10,19,66]</sup>, partly related to the advice to avoid sunlight exposure for fear of skin cancer. This fact makes vitamin D fortification of milk products a necessity.

The successful experience of food fortification in many countries emphasizes the safety and efficacy of this approach. Food fortification is vital in prevention of chronic diseases, and its implementation will bring long-term economic savings in health costs and will contribute to the health and nutritional habits of the population. In addition to fortification of breakfast cereals and some milk products, the recommendations of health ministries should include fortification of basic foods with iodine, iron, folic acid, vitamin A, vitamin B complexes (including B12), and vitamin D, in order to prevent birth defects as well as chronic diseases. National school feeding programs can be one of the means for nutritional education and food fortification as well as a means of alleviating

food insecurity among children.

The limitations of our study are embedded in the methodology of the literature search, since some publications could have been missed or were unavailable in Medline. There is also a possibility of publication bias since negative or non-significant studies tend not to be published.

In summary, in view of the wide nutritional deficiencies in Israel, we encourage local health, education and industrial ministries to expand efforts to study and document these deficiencies with a view to fortifying basic commonly used foods in order to combat the deficiencies and prevent their occurrence in the future.

## REFERENCES

- 1 **Lutter CK.** Iron deficiency in young children in low-income countries and new approaches for its prevention. *J Nutr* 2008; **138**: 2523-2528 [PMID: 19022983 DOI: 10.3945/jn.108.095406]
- 2 **ACC/SCN.** Fourth report on the world nutrition situation. Switzerland: United Nations ACC/SCN in collaboration with IFPRI, 2000
- 3 **Suskind DL.** Nutritional deficiencies during normal growth. *Pediatr Clin North Am* 2009; **56**: 1035-1053 [PMID: 19931062 DOI: 10.1016/j.pcl.2009.07.004]
- 4 Prevention of neural tube defects: results of the Medical Research Council Vitamin Study. MRC Vitamin Study Research Group. *Lancet* 1991; **338**: 131-137 [PMID: 1677062 DOI: 10.1016/0140-6736(91)90133-A]
- 5 **Caballero B.** Global patterns of child health: the role of nutrition. *Ann Nutr Metab* 2002; **46** Suppl 1: 3-7 [PMID: 12428075]
- 6 **Bhaskaram P.** Micronutrient malnutrition, infection, and immunity: an overview. *Nutr Rev* 2002; **60**: S40-S45 [PMID: 12035857 DOI: 10.1301/00296640260130722]
- 7 **Gat-Yablonski G, Yackobovitch-Gavan M, Phillip M.** Nutrition and bone growth in pediatrics. *Endocrinol Metab Clin North Am* 2009; **38**: 565-586 [PMID: 19717005 DOI: 10.1016/j.ecl.2009.07.001]
- 8 **Tulchinsky TH.** Vitamin enrichment of basic foods: the case-for-action in Israel. *Isr J Med Sci* 1993; **29**: 58-61 [PMID: 8454455]
- 9 **Ish Shalom S, Rozen GS, Lerner A.** In: "Pediatric Nutrition", Eds. Reifen RM, Lerner A, Branski D, Heymans ASA. Osteoporosis: An Emerging Problem in Pediatrics. Karger: Basel, 1998: 110-121
- 10 **Lerner A, Shapira Y, Agmon-Levin N, Pacht A, Ben-Ami Shor D, López HM, Sanchez-Castanon M, Shoenfeld Y.** The clinical significance of 25OH-Vitamin D status in celiac disease. *Clin Rev Allergy Immunol* 2012; **42**: 322-330 [PMID: 21210250 DOI: 10.1007/s12016-010-8237-8]
- 11 **Oren Y, Shapira Y, Agmon-Levin N, Kivity S, Zafrir Y, Altman A, Lerner A, Shoenfeld Y.** Vitamin D insufficiency in a sunny environment: a demographic and seasonal analysis. *Isr Med Assoc J* 2010; **12**: 751-756 [PMID: 21348404]
- 12 **Kark JD, Sinnreich R, Rosenberg IH, Jacques PF, Selhub J.** Plasma homocysteine and parental myocardial infarction in young adults in Jerusalem. *Circulation* 2002; **105**: 2725-2729 [PMID: 12057985 DOI: 10.1161/01.CIR.0000017360.99531.26]
- 13 **Anderson JL, Jensen KR, Carlquist JF, Bair TL, Horne BD, Muhlestein JB.** Effect of folic acid fortification of food on homocysteine-related mortality. *Am J Med* 2004; **116**: 158-164 [PMID: 14749159 DOI: 10.1016/j.amjmed.2003.10.024]
- 14 **MacDonald RS.** The role of zinc in growth and cell proliferation. *J Nutr* 2000; **130**: 1500S-1508S [PMID: 10801966]
- 15 **Liu J, Raine A, Venables PH, Mednick SA.** Malnutrition at age 3 years and externalizing behavior problems at ages 8, 11, and 17 years. *Am J Psychiatry* 2004; **161**: 2005-2013 [PMID: 15514400 DOI: 10.1176/appi.ajp.161.11.2005]



- 16 **Forman MR**, Guptill KS, Chang DN, Sarov B, Berendes HW, Naggan L, Hundt GL. Undernutrition among Bedouin Arab infants: the Bedouin Infant Feeding Study. *Am J Clin Nutr* 1990; **51**: 343-349 [PMID: 2309641]
- 17 **Costeff H**, Breslaw Z. Rickets in southern Israel. Some epidemiologic observations. *J Pediatr* 1962; **61**: 919-924 [PMID: 14023307 DOI: 10.1016/S0022-3476(62)80206-6]
- 18 **Harlap S**, Prywes R, Grover NB, Davies AM. Maternal, perinatal and infant health in Bedouin and Jews in southern Israel. *Isr J Med Sci* 1977; **13**: 514-528 [PMID: 873768]
- 19 **Groen JJ**, Eshchar J, Ben-ishay D, Alkan WJ, Benassa BI. Osteomalacia among the bedouin of the negev desert; clinical and biochemical observations. *Arch Intern Med* 1965; **116**: 195-204 [PMID: 14318477 DOI: 10.1001/archinte.1965.03870020035010]
- 20 **Levy A**, Fraser D, Rosen SD, Dagan R, Deckelbaum RJ, Coles C, Naggan L. Anemia as a risk factor for infectious diseases in infants and toddlers: results from a prospective study. *Eur J Epidemiol* 2005; **20**: 277-284 [PMID: 15921046 DOI: 10.1007/s10654-004-6515-6]
- 21 **Weisman Y**. Vitamin D deficiency rickets and osteomalacia in Israel. *Isr Med Assoc J* 2003; **5**: 289-290 [PMID: 14509137]
- 22 **Berlyne GM**, Ben-Ari J, Nord E, Shainkin R. Bedouin osteomalacia due to calcium deprivation caused by high phytic acid content of unleavened bread. *Am J Clin Nutr* 1973; **26**: 910-911 [PMID: 4727748]
- 23 **Sasson A**, Etzion Z, Shany S, Berlyne GM, Yagil R. Growth and bone mineralisation as affected by dietary calcium, phytic acid and vitamin D. *Comp Biochem Physiol A Comp Physiol* 1982; **72**: 43-48 [PMID: 6124364]
- 24 **Shany S**, Hirsh J, Berlyne GM. 25-Hydroxycholecalciferol levels in bedouins in the Negev. *Am J Clin Nutr* 1976; **29**: 1104-1107 [PMID: 973599]
- 25 **Shany S**, Biale Y, Zuili I, Yankowitz N, Berry JL, Mawer EB. Feto-maternal relationships between vitamin D metabolites in Israeli Bedouins and Jews. *Am J Clin Nutr* 1984; **40**: 1290-1294 [PMID: 6334437]
- 26 **Biale Y**, Shany S, Levi M, Shainkin-Kestenbaum R, Berlyne GM. 25 Hydroxycholecalciferol levels in Beduin women in labor and in cord blood of their infants. *Am J Clin Nutr* 1979; **32**: 2380-2382 [PMID: 506960]
- 27 **Coles CL**, Levy A, Gorodischer R, Dagan R, Deckelbaum RJ, Blaner WS, Fraser D. Subclinical vitamin A deficiency in Israeli-Bedouin toddlers. *Eur J Clin Nutr* 2004; **58**: 796-802 [PMID: 15116083 DOI: 10.1038/sj.ejcn.1601879]
- 28 **Gorodischer R**, Sarov B, Gazala E, Hershkovitz E, Edwardson S, Sklan D, Katz M. Differences in cord serum retinol concentrations by ethnic origin in the Negev (southern Israel). *Early Hum Dev* 1995; **42**: 123-130 [PMID: 7588157 DOI: 10.1016/0378-3782(95)01644-I]
- 29 **Masalha R**, Rudoy I, Volkov I, Yusuf N, Wirguin I, Herishanu YO. Symptomatic dietary vitamin B(12) deficiency in a nonvegetarian population. *Am J Med* 2002; **112**: 413-416 [PMID: 11904118 DOI: 10.1016/S0002-9343(02)01031-8]
- 30 **Ginat-Israeli T**, Dranitzki Z, Straus U. Nutritional rickets in infants immigrating to Israel from Ethiopia. *Isr Med Assoc J* 2003; **5**: 291-292 [PMID: 14509138]
- 31 **Fogelman Y**, Rakover Y, Luboshitzky R. High prevalence of vitamin D deficiency among Ethiopian women immigrants to Israel: exacerbation during pregnancy and lactation. *Isr J Med Sci* 1995; **31**: 221-224 [PMID: 7721559]
- 32 **Lavon B**, Tulchinsky TH, Preger M, Said R, Kaufman S. Iron deficiency anemia among Jewish and Arab infants at 6 and 12 months of age in Hadera, Israel. *Isr J Med Sci* 1985; **21**: 107-112 [PMID: 3980188]
- 33 **Yodfat Y**. Iron deficiency anemia in children in a new-immigrant town in Israel. *Isr J Med Sci* 1967; **3**: 890-893 [PMID: 5587580]
- 34 **Shehab S**, Nutenko K, Koren A, Ron M, Salahov E, Tulchinsky T. [Hemoglobin level among infants in Akko sub-district]. *Harefuah* 2001; **140**: 1002-1005, 1120 [PMID: 11759370]
- 35 **Bilenko N**, Yehiel M, Inbar Y, Gazala E. The association between anemia in infants, and maternal knowledge and adherence to iron supplementation in southern Israel. *Isr Med Assoc J* 2007; **9**: 521-524 [PMID: 17710783]
- 36 **Levy S**, Rachmilewitz M, Grossowicz N, Reshef Y, Izak G. Nutritional survey in an iron- and folate-deficient population. *Am J Clin Nutr* 1975; **28**: 1454-1457 [PMID: 803008]
- 37 **Constantini NW**, Eliakim A, Zigel L, Yaaron M, Falk B. Iron status of highly active adolescents: evidence of depleted iron stores in gymnasts. *Int J Sport Nutr Exerc Metab* 2000; **10**: 62-70 [PMID: 10939876]
- 38 **Stoffman N**, Gordon CM. Vitamin D and adolescents: what do we know? *Curr Opin Pediatr* 2009; **21**: 465-471 [PMID: 19502985 DOI: 10.1097/MOP.0b013e32832da096]
- 39 **Huh SY**, Gordon CM. Vitamin D deficiency in children and adolescents: epidemiology, impact and treatment. *Rev Endocr Metab Disord* 2008; **9**: 161-170 [PMID: 18175220 DOI: 10.1007/s11154-007-9072-y]
- 40 **Rozen GS**, Rennert G, Rennert HS, Diab G, Daud D, Ish-Shalom S. Calcium intake and bone mass development among Israeli adolescent girls. *J Am Coll Nutr* 2001; **20**: 219-224 [PMID: 11444417 DOI: 10.1080/07315724.2001.10719035]
- 41 **Carvalho NE**, Kenney RD, Carrington PH, Hall DE. Severe nutritional deficiencies in toddlers resulting from health food milk alternatives. *Pediatrics* 2001; **107**: E46 [PMID: 11335767 DOI: 10.1542/peds.107.4.e46]
- 42 **Prais D**, Diamond G, Kattan A, Salzberg J, Inbar D. The effect of calcium intake and physical activity on bone quantitative ultrasound measurements in children: a pilot study. *J Bone Miner Metab* 2008; **26**: 248-253 [PMID: 18470665 DOI: 10.1007/s00774-007-0814-4]
- 43 **Pinhas-Hamiel O**, Newfield RS, Koren I, Agmon A, Lilos P, Phillip M. Greater prevalence of iron deficiency in overweight and obese children and adolescents. *Int J Obes Relat Metab Disord* 2003; **27**: 416-418 [PMID: 12629572 DOI: 10.1038/sj.ijo.0802224]
- 44 **Pinhas-Hamiel O**, Doron-Panush N, Reichman B, Nitzan-Kaluski D, Shalitin S, Geva-Lerner L. Obese children and adolescents: a risk group for low vitamin B12 concentration. *Arch Pediatr Adolesc Med* 2006; **160**: 933-936 [PMID: 16953016 DOI: 10.1001/archpedi.160.9.933]
- 45 **Schweiger C**, Weiss R, Berry E, Keidar A. Nutritional deficiencies in bariatric surgery candidates. *Obes Surg* 2010; **20**: 193-197 [PMID: 19876694 DOI: 10.1007/s11695-009-0008-3]
- 46 **Israeli E**, Merkel D, Constantini N, Yanovich R, Evans RK, Shahar D, Moran DS. Iron deficiency and the role of nutrition among female military recruits. *Med Sci Sports Exerc* 2008; **40**: S685-S690 [PMID: 18849865 DOI: 10.1249/MSS.0b013e31818946ae]
- 47 **Rachmilewitz EA**, Blank D, Rohash Z, Polliack A. [Thalassemia minor and iron deficiency anemia among Israeli soldiers]. *Harefuah* 1986; **110**: 437-441 [PMID: 3758857]
- 48 **Dolev E**, Burstein R, Wishnitzer R, Lubin F, Chetriet A, Shefi M, Deuster PA. Longitudinal study of magnesium status of Israeli military recruits. *Magnes Trace Elem* 1992; **10**: 420-426 [PMID: 1669024]
- 49 **Meyerovitch J**, Sherf M, Antebi F, Barhoum-Noufi M, Horev Z, Jaber L, Weiss D, Koren A. The incidence of anemia in an Israeli population: a population analysis for anemia in 34,512 Israeli infants aged 9 to 18 months. *Pediatrics* 2006; **118**: e1055-e1060 [PMID: 16940163 DOI: 10.1542/peds.2006-0024]
- 50 **Palti H**, Adler B, Wolf N. An epidemiological study of haemoglobin levels in infancy in Jerusalem. The effect of social factors and the relation to physical growth. *Acta Paediatr Scand* 1977; **66**: 513-517 [PMID: 899769 DOI: 10.1111/j.1651-2227.1977.tb07936.x]
- 51 **Tulchinsky TH**, Tamirab D, Sebanab AJ. Changing pattern of anemia among Jerusalem infants between 1977 and 1987. *Early Child Dev Care* 1991; **66**: 75-83 [DOI: 10.1080/030044391

- 0660107]
- 52 **Lev B.** Prevention of micronutrient deficiency conditions: the Israeli approach. *Public Health Rev* 2000; **28**: 13-21 [PMID: 11411266]
- 53 **Palti H,** Meijer A, Adler B. Learning achievement and behavior at school of anemic and non-anemic infants. *Early Hum Dev* 1985; **10**: 217-223 [PMID: 3987574 DOI: 10.1016/0378-3782(85)90052-0]
- 54 **Zmora E,** Gorodischer R, Bar-Ziv J. Multiple nutritional deficiencies in infants from a strict vegetarian community. *Am J Dis Child* 1979; **133**: 141-144 [PMID: 105630]
- 55 **Abu-Kishk I,** Rachmiel M, Hoffmann C, Lahat E, Eshel G. Infantile encephalopathy due to vitamin deficiency in industrial countries. *Childs Nerv Syst* 2009; **25**: 1477-1480 [PMID: 19585126 DOI: 10.1007/s00381-009-0942-3]
- 56 **Ashkenazi S,** Weitz R, Varsano I, Mimouni M. Vitamin B12 deficiency due to a strictly vegetarian diet in adolescence. *Clin Pediatr (Phila)* 1987; **26**: 662-663 [PMID: 3677536 DOI: 10.1177/000992288702601211]
- 57 **Shinwell ED,** Gorodischer R. Totally vegetarian diets and infant nutrition. *Pediatrics* 1982; **70**: 582-586 [PMID: 6812012]
- 58 **Palgi A.** Ethnic differences in hemoglobin distribution of Asian and European Jewish women in Israel, both pregnant and nonpregnant. *Am J Public Health* 1981; **71**: 847-851 [PMID: 7258448 DOI: 10.2105/AJPH.71.8.847]
- 59 **Edet EE.** Prevalence of anaemia among pregnant women in a Jewish community in Jerusalem according to selected socio-demographic characteristics. *Public Health* 1990; **104**: 457-463 [PMID: 2274649 DOI: 10.1016/S0033-3506(05)80088-5]
- 60 **Hershko C,** Hoffbrand AV, Keret D, Souroujon M, Maschler I, Monselise Y, Lahad A. Role of autoimmune gastritis, Helicobacter pylori and celiac disease in refractory or unexplained iron deficiency anemia. *Haematologica* 2005; **90**: 585-595 [PMID: 15921373]
- 61 **Hartman C,** Hino B, Lerner A, Eshach-Adiv O, Berkowitz D, Shaoul R, Pacht A, Rozenenthal E, Tamir A, Shamaly H, Shamir R. Bone quantitative ultrasound and bone mineral density in children with celiac disease. *J Pediatr Gastroenterol Nutr* 2004; **39**: 504-510 [PMID: 15572890 DOI: 10.1097/00005176-200411000-00011]
- 62 **Nehama H,** Wientroub S, Eisenberg Z, Birger A, Milbauer B, Weisman Y. Seasonal variation in paired maternal-newborn serum 25-hydroxyvitamin D and 24,25-dihydroxyvitamin D concentrations in Israel. *Isr J Med Sci* 1987; **23**: 274-277 [PMID: 3497905]
- 63 **Meller Y,** Kestenbaum RS, Galinsky D, Shany S. Seasonal variation in serum levels of vitamin D metabolites and parathormone in geriatric patients with fractures in Southern Israel. *Isr J Med Sci* 1986; **22**: 8-11 [PMID: 3485617]
- 64 **Shoenfeld N,** Amital H, Shoenfeld Y. The effect of melanism and vitamin D synthesis on the incidence of autoimmune disease. *Nat Clin Pract Rheumatol* 2009; **5**: 99-105 [PMID: 19182816 DOI: 10.1038/ncprheum0989]
- 65 **Weisman Y.** Osteoporosis and vitamin D deficiency in Israel. *Public Health Rev* 2000; **28**: 59-65 [PMID: 11411278]
- 66 **Mukamel MN,** Weisman Y, Somech R, Eisenberg Z, Landman J, Shapira I, Spirer Z, Jurgenson U. Vitamin D deficiency and insufficiency in Orthodox and non-Orthodox Jewish mothers in Israel. *Isr Med Assoc J* 2001; **3**: 419-421 [PMID: 11433634]
- 67 **Allen LH.** Causes of vitamin B12 and folate deficiency. *Food Nutr Bull* 2008; **29**: S20-S34; discussion S35-S37 [PMID: 18709879]
- 68 **Gielchinsky Y,** Elstein D, Green R, Miller JW, Elstein Y, Algur N, Lahad A, Shinar E, Abrahamov A, Zimran A. High prevalence of low serum vitamin B12 in a multi-ethnic Israeli population. *Br J Haematol* 2001; **115**: 707-709 [PMID: 11736958 DOI: 10.1046/j.1365-2141.2001.03156.x]
- 69 **Volkov I,** Rudoy I, Machagna M, Glezer I, Ganel U, Orenstein A, Press Y. Modern society and prospects of low vitamin B12 intake. *Ann Nutr Metab* 2007; **51**: 468-470 [PMID: 18025821 DOI: 10.1159/000111168]
- 70 **Aloufy A,** Latzer Y. [Diet or health--the linkage between vegetarianism and anorexia nervosa]. *Harefuah* 2006; **145**: 526-531, 549 [PMID: 16900745]
- 71 **Tannhauser PP.** Anorexia nervosa: a multifactorial disease of nutritional origin? *Int J Adolesc Med Health* 2002; **14**: 185-191 [PMID: 12467193 DOI: 10.1515/IJAMH.2002.14.3.185]
- 72 **Naveh Y.** [Zinc deficiency in children]. *Harefuah* 1995; **128**: 728-732 [PMID: 7557676]
- 73 **Toren P,** Eldar S, Sela BA, Wolmer L, Weitz R, Inbar D, Koren S, Reiss A, Weizman R, Laor N. Zinc deficiency in attention-deficit hyperactivity disorder. *Biol Psychiatry* 1996; **40**: 1308-1310 [PMID: 8959299 DOI: 10.1016/S0006-3223(96)00310-1]
- 74 **Tulchinsky TH,** Kaluski DN, Berry EM. Food fortification and risk group supplementation are vital parts of a comprehensive nutrition policy for prevention of chronic diseases. *Eur J Public Health* 2004; **14**: 226-228 [PMID: 15369023 DOI: 10.1093/eurpub/14.3.226]
- 75 **Centers for Disease Control and Prevention (CDC).** Safer and healthier foods. *MMWR Morb Mortal Wkly Rep* 1999; **48**: 905-913 [PMID: 12432905]
- 76 **Park YK,** Sempos CT, Barton CN, Vanderveen JE, Yetley EA. Effectiveness of food fortification in the United States: the case of pellagra. *Am J Public Health* 2000; **90**: 727-738 [PMID: 10800421]
- 77 **Kaluski DN,** Tulchinsky TH, Haviv A, Averbuch Y, Rachmiel S, Berry EM, Leventhal A. Addition of essential micro-nutrients to foods--implication for public health policy in Israel. *Isr Med Assoc J* 2003; **5**: 277-280 [PMID: 14509134]
- 78 **Israeli A,** Shemer J. It is time to fortify basic foods in Israel according to the Canadian model. *Isr Med Assoc J* 2004; **6**: 323-325 [PMID: 15214455]
- 79 **Ray JG,** Meier C, Vermeulen MJ, Boss S, Wyatt PR, Cole DE. Association of neural tube defects and folic acid food fortification in Canada. *Lancet* 2002; **360**: 2047-2048 [PMID: 12504403 DOI: 10.1016/S0140-6736(02)11994-5]
- 80 **Honein MA,** Paulozzi LJ, Mathews TJ, Erickson JD, Wong LY. Impact of folic acid fortification of the US food supply on the occurrence of neural tube defects. *JAMA* 2001; **285**: 2981-2986 [PMID: 11410096 DOI: 10.1001/jama.285.23.2981]
- 81 **Vitti P,** Delange F, Pinchera A, Zimmermann M, Dunn JT. Europe is iodine deficient. *Lancet* 2003; **361**: 1226 [PMID: 12686067]
- 82 **World Health Organization.** Iodine Deficiency disorders. Fact Sheet No. 121. Geneva: WHO, 1990
- 83 **Gartner LM,** Greer FR. Prevention of rickets and vitamin D deficiency: new guidelines for vitamin D intake. *Pediatrics* 2003; **111**: 908-910 [PMID: 12671133 DOI: 10.1542/peds.111.4.908]

**P- Reviewers:** Koch TR, Ramos S **S- Editor:** Gou SX  
**L- Editor:** Cant MR **E- Editor:** Liu SQ



## Animal models of atherosclerosis

Fatemeh Ramezani Kapourchali, Gangadaran Surendiran, Li Chen, Elisabeth Uitz, Babak Bahadori, Mohammed H Moghadasian

Fatemeh Ramezani Kapourchali, Mohammed H Moghadasian, International Nutrition Research Inc., Winnipeg, MB R3T2G4, Canada

Gangadaran Surendiran, Mohammed H Moghadasian, Department of Human Nutritional Sciences and Canadian Centre for Agri-food Research in Health and Medicine, St. Boniface Hospital Research Centre and University of Manitoba, Winnipeg, MB R2H 2A6, Canada

Li Chen, College of Food Science and Technology, Huazhong Agricultural University, Wuhan 430000, Hubei Province, China

Li Chen, Canadian Centre for Agri-food Research in Health and Medicine, St. Boniface Hospital Research Centre, Winnipeg, MB R2H 2A6, Canada

Elisabeth Uitz, Babak Bahadori, Karl Landsteiner Private University of Health and Life Sciences, State Clinic St. Poelten, Department of Internal Medicine 2, 3100, St. Poelten, Austria

**Author contributions:** Kapourchali FR, Surendiran G, Chen L and Uitz E collection of data and preparation of the manuscript; Bahadori B and Moghadasian MH supervised the preparation of manuscript.

**Correspondence to:** Mohammed H Moghadasian, Professor, Department of Human Nutritional Sciences and Canadian Centre for Agri-food Research in Health and Medicine, St. Boniface Hospital Research Centre and University of Manitoba, 351 Tache Ave, Winnipeg, MB, R2H 2A6, Canada. [mmoghadasian@sbr.ca](mailto:mmoghadasian@sbr.ca)

Telephone: +1-204-2353934 Fax: +1-204-2374018

Received: December 21, 2013 Revised: March 15, 2014

Accepted: April 17, 2014

Published online: May 16, 2014

### Abstract

In this mini-review several commonly used animal models of atherosclerosis have been discussed. Among them, emphasis has been made on mice, rabbits, pigs and non-human primates. Although these animal models have played a significant role in our understanding of induction of atherosclerotic lesions, we still lack a reliable animal model for regression of the disease. Researchers have reported several genetically modified and transgenic animal models that replicate human atherosclerosis, however each of current animal models have some limitations. Among these animal models, the apolipoprotein (apo) E-knockout (KO)

mice have been used extensively because they develop spontaneous atherosclerosis. Furthermore, atherosclerotic lesions developed in this model depending on experimental design may resemble humans' stable and unstable atherosclerotic lesions. This mouse model of hypercholesterolemia and atherosclerosis has been also used to investigate the impact of oxidative stress and inflammation on atherogenesis. Low density lipoprotein (LDL)-r-KO mice are a model of human familial hypercholesterolemia. However, unlike apo E-KO mice, the LDL-r-KO mice do not develop spontaneous atherosclerosis. Both apo E-KO and LDL-r-KO mice have been employed to generate other relevant mouse models of cardiovascular disease through breeding strategies. In addition to mice, rabbits have been used extensively particularly to understand the mechanisms of cholesterol-induced atherosclerosis. The present review paper details the characteristics of animal models that are used in atherosclerosis research.

© 2014 Baishideng Publishing Group Inc. All rights reserved.

**Key words:** Atherosclerosis; Dyslipidemia; Disease; Animal models

**Core tip:** This mini-review provides the essential information obtained from a number of animal models in the field of cardiovascular research. Such information can help researchers design their studies for understanding the pathophysiology of atherosclerosis.

Kapourchali FR, Surendiran G, Chen L, Uitz E, Bahadori B, Moghadasian MH. Animal models of atherosclerosis. *World J Clin Cases* 2014; 2(5): 126-132 Available from: URL: <http://www.wjgnet.com/2307-8960/full/v2/i5/126.htm> DOI: <http://dx.doi.org/10.12998/wjcc.v2.i5.126>

### INTRODUCTION

Atherosclerosis is still a leading cause of mortality and



morbidity worldwide<sup>[1]</sup>. Several modifiable and non-modifiable risk factors have been identified for the disease. Many clinical and experimental attempts have been made to understand the pathophysiology of the disease. Among them, a number of animal models have been used for understanding the mechanisms involved in both induction and regression of atherosclerotic lesions. It was first in 1908 that Ignatowski reported atherogenesis in a rabbit model<sup>[2]</sup>. Subsequent studies documented a significant relationship between elevated levels of serum cholesterol and development of atherosclerotic lesions in experimental animals<sup>[3-6]</sup>. That was the basis of cholesterol-feeding trials in experimental models of atherosclerosis. However, later a naturally defective rabbit model namely Watanabe Heritable Hyperlipidemic (WHHL) rabbits was discovered and used in most of experimental settings<sup>[7-13]</sup>. Recent technology has allowed generation of a number of genetically-modified animal models in this field of research.

Overall, one may think that an ideal animal model for studying human disease should possess several features including availability, affordability and close resemblance to human conditions. In particular, an optimal animal model of atherosclerosis should develop various stages of the disease including fatty streaks, accumulation of foam cells, vulnerable and stable plaques as well as relevant complications such as calcification, ulceration, hemorrhage, plaque rupture, thrombosis and stenosis and the formation of aneurysms. Efforts are being made to develop animal models that replicate human atherosclerosis, however each of current animal models have some limitations. In this paper, attempts have been made to summarize the important features of the common animal models of atherosclerosis.

## MICE

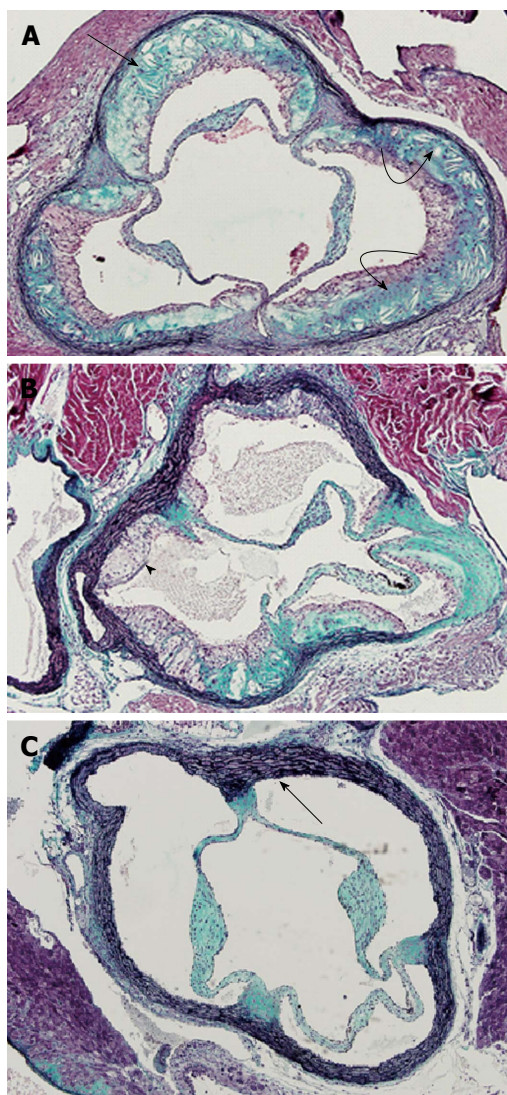
The mouse has been used in medical research for decades. Well-known genetic background, easy to breed and low cost of maintenance are among advantages of this model. However, small size and some physiological characteristics may be considered as limiting factors. For example, the plasma lipoprotein profile in mice is very different from that in humans. The circulating cholesterol is mainly in high density lipoprotein (HDL) particles in the mouse, while it is in low density lipoprotein (LDL) particles in humans. This is probably the main reason that wild-type mice do not develop atherosclerosis, but humans do. One reason for this lipoprotein profile differences is the absence of cholesterol-ester transfer protein (CETP) in the mouse<sup>[14]</sup>. Another difference between the mouse and the man is their response to dietary cholesterol. The mouse does not absorb dietary cholesterol significantly<sup>[15]</sup>, while the man absorbs approximately 50% of dietary cholesterol. This may also be seen as a limiting factor for cholesterol-induced atherogenesis in wild-type mice (C57BL/6J).

To overcome these limitations, researchers have used

DNA technology to generate a number of genetically modified mouse models. It was in 1992 that the very first line of such genetically modified mouse model was introduced to our research community. Zhang *et al*<sup>[3]</sup> reported a successful deletion of mouse apolipoprotein (apo) E gene. Further research led to generation of other genetically modified mouse models suitable for studying human dyslipidemia and atherosclerosis. Among them, LDL receptor-knockout (KO)<sup>[16]</sup>, hepatic lipase-KO<sup>[17]</sup>, human apo B<sub>100</sub> expression<sup>[18]</sup> and human CETP expression<sup>[19]</sup> can be named.

Of these genetically modified mouse models, apo E-KO mice develop spontaneous atherosclerosis. This is associated with elevated levels of circulating cholesterol-rich very LDL (VLDL) particles. This feature makes this animal model to be very robust for both induction and prevention of the disease. Several studies have reported that hypercholesterolemia and atherosclerosis can be prevented by dietary plant sterols in this animal model<sup>[20-22]</sup>. Unlike apo E-KO mice, LDL-r-KO mice need dietary cholesterol to develop hypercholesterolemia and atherosclerosis<sup>[16,23]</sup>. Morphological features of atherosclerotic lesions in apo E-KO and LDLr-KO mice are illustrated on Figure 1. Another mouse model which develops hypercholesterolemia and atherosclerosis on high fat/high cholesterol diets is apo E\*3-Leiden transgenic mice<sup>[24-26]</sup>. Furthermore, a number of breeding experiments have been carried out to generate additional mouse models of human dyslipidemia and atherosclerosis. For example, cross breeding of human apo B<sub>100</sub> transgenic mice with LDL receptor deficient mice produced a highly susceptible strain (HuBTg<sup>+/+</sup>Ldlr<sup>-/-</sup>) with severe hypercholesterolemia and atherosclerosis<sup>[16]</sup>. Furthermore, Föger *et al*<sup>[19]</sup> reported that when human lecithin cholesterol acyl transferase (LCAT) transgenic mice were cross-bred with CETP transgenic mice they produce offspring with low total cholesterol levels and reduced atherosclerosis burden. Similarly, Lweis *et al*<sup>[27]</sup> generated apoE/GPx1 double KO (ApoE<sup>-/-</sup>GPx1<sup>-/-</sup>), by cross breeding GPx1-deficient mice with apo E-deficient mice. This model features combined hyperlipidemia and hyperglycemia with increased oxidative stress. Chen *et al*<sup>[28]</sup> reported a mouse model that develops unstable/ruptured atherosclerotic plaques. They used surgical procedures to introduce a tandem stenosis in the carotid artery of apo E<sup>-/-</sup> mice fed a high fat diet, in order to develop unstable plaques in these mice. Atherosclerosis is known to be an inflammatory disease. We know that there are major differences in immune system between mice and humans<sup>[29]</sup>. This is another reason for questioning the mouse model for studying human atherosclerosis. Several inflammatory markers have been detected in both atherosclerotic plaques and in circulation of subjects or animals with atherosclerosis. Several strategies have been implemented to understand the role of inflammatory pathways in the progression of the disease and its complications. One of such experimental strategies was application of bone marrow transplant. Ishibashi and colleagues used bone marrow





**Figure 1** Representative photomicrographs taken at aortic root from apolipoprotein E-knockout (A), low density lipoprotein-r-knockout (B) and their wild-type background C57BL/6J (C) mice. A: Advanced atherosclerosis lesions in all 3 valves of the aortic root (arrow); these lesions are composed of numerous cholesterol clefts (curved arrows); B: Illustrating lipid-rich atherosclerotic lesions in the aortic root; the arrow head points to an atherosclerotic plaque primarily composed of apparent foam cells. No cholesterol cleft is visible in B; C: Demonstrating an atherosclerosis-lesion-free aortic root with normal-looking vascular wall (arrow) with apparent intact elastic lamina and endothelium. Trichrome staining;  $\times 40$ .

transplant procedures to produce apo E-KO mice with and without deficiency of chemoattractant protein-1 receptor, CCR2<sup>[30]</sup>. Results from their studies suggest that CCR2 plays a crucial role in vascular inflammation and atherosclerosis. In another study, bone marrow transplant procedures were used to investigate the effects of macrophage-derived apo E on atherogenesis in apo E-KO mice<sup>[31]</sup>. Transplantation of bone marrow from wild-type mice to apo E-KO mice resulted in significant reductions in the formation of atherosclerotic lesions in apo E-KO mice.

Although we have significantly advanced our knowledge in understanding the process of induction of atherosclerotic lesions using various mouse model, our

knowledge on regression of these lesions is still very limited. In an attempt to regress atherosclerotic lesions we used apo E-KO mice. Over a 42-wk of low-fat diet and diets enriched phytosterols, we were unable to regress atherosclerotic lesions in this animal model<sup>[32]</sup>. Similarly, literature search did not show any significant evidence for a successful regression of advanced atherosclerotic lesions.

## RABBITS

The rabbit has been used in many research facilities as an animal model of diet induced atherosclerosis. This species shares several aspects of lipoprotein metabolism with humans. These include composition of apo B containing lipoproteins<sup>[33]</sup>, production of apo B<sub>100</sub> containing VLDL by the liver<sup>[34]</sup> plasma CETP activity<sup>[35]</sup>, and high absorption rate of dietary cholesterol<sup>[35]</sup>. However, the lack of hepatic lipase makes the rabbit to be different from man<sup>[36]</sup>. Dietary approach is a common method to induce atherogenesis in rabbits. Under these conditions, the animals develop atherosclerotic lesions in the aortic arch and thoracic aorta rather than abdominal aorta which is almost always affected in humans<sup>[36]</sup>.

Two strains of rabbits, namely WHHL and St. Thomas' Hospital (STH) rabbits are naturally defective and relevant models for human hyperlipidemia<sup>[7-13,37-39]</sup>. The WHHL rabbits are deficient in LDL receptors and therefore resemble human familial hypercholesterolemia<sup>[7-13,37]</sup>, while STH rabbits are used as a model for human hypertriglyceridemia and combined hyperlipidemia<sup>[38,39]</sup>. Recent advances in gene technology have allowed generation of transgenic rabbits. For example, New Zealand White rabbits have been used to produce human apo B<sub>100</sub> transgenic rabbits; these animals manifest combined hyperlipidemia with reduced HDL-cholesterol concentrations<sup>[33]</sup>. On the other hand, over expression of human apo AI or human LCAT in rabbits was associated with elevated HDL-cholesterol levels and reduced atherosclerosis<sup>[34,35]</sup>.

## PIGS

Pigs have been used for induction of coronary atherosclerosis by several different laboratories<sup>[40-42]</sup>. However, induction of advanced atherosclerotic lesions required high levels of dietary cholesterol (up to 4% w/w)<sup>[41,43,44]</sup>. A strain of pigs has been discovered with three lipoprotein-associated mutations (designated Lpb5, Lpr1, and Lpu1) developing hypercholesterolemia and atherosclerosis without dietary cholesterol<sup>[43,44]</sup>. In addition to coronary arteries, iliac and femoral arteries also develop atherosclerotic lesions which become complicated by 2 years of age<sup>[44]</sup>.

## NON-HUMAN PRIMATES

Spontaneous atherosclerosis has been reported in squirrel monkeys, baboons, wooly and spider monkeys<sup>[45]</sup>. Similar to humans, monkeys can be divided into "hyper-

**Table 1** Animal models and their features

Model	Features	Ref.
Mice		
Apo E <sup>-/-</sup> mice	Develops spontaneous atherosclerosis, associated with elevated levels of circulating cholesterol-rich VLDL particles	Zhang <i>et al</i> <sup>[3]</sup>
LDL receptor deficient KO mice	This model needs dietary cholesterol to develop hypercholesterolemia and atherosclerosis- associated with elevated levels of circulating cholesterol-rich LDL and VLDL particles	Sanan <i>et al</i> <sup>[16]</sup>
Apo E*3-Leiden transgenic mice	This model needs dietary cholesterol to develop hypercholesterolemia and atherosclerosis-associated with elevated levels of circulating cholesterol	Groot <i>et al</i> <sup>[24]</sup>
Hepatic lipase-KO mice	This model lacks hepatic lipase and develops elevated levels of plasma cholesterol, phospholipids, and HDL cholesterol and can be used for the study of HDL metabolism.	van Vlijmen <i>et al</i> <sup>[25]</sup> Homanics <i>et al</i> <sup>[17]</sup>
Human apo B <sub>100</sub> transgenic mice	This mouse model, associated with substantial increased level of LDL cholesterol level and useful for studying various aspects of lipoprotein metabolism and for further delineating the role of LDL in atherogenesis.	Greeve <i>et al</i> <sup>[18]</sup>
Human CETP transgenic mice	This model has reported to have decreased HDL cholesterol levels with variable degree of atherosclerosis	Föger <i>et al</i> <sup>[19]</sup>
Cross breeding of human apo B <sub>100</sub> transgenic mice with LDL receptor deficient mice	This model develops severe hypercholesterolemia and atherosclerosis	Sanan <i>et al</i> <sup>[16]</sup>
Cross breeding of human LCAT transgenic mice with CETP transgenic mice.	A mouse model with low total cholesterol levels and reduced atherosclerosis burden.	Föger <i>et al</i> <sup>[19]</sup>
Apo E/GPx1 double knockout (apo E <sup>-/-</sup> GPx1 <sup>-/-</sup> )	This model features combined hyperlipidemia and hyperglycemia with increased oxidative stress	Lewis <i>et al</i> <sup>[27]</sup>
Surgical model of apo E <sup>-/-</sup> mice	A mouse model for studying unstable/ruptured atherosclerotic plaques	Chen <i>et al</i> <sup>[28]</sup>
Animal model developed using bone marrow technique	Apo E-KO mice model with and without deficiency of CCR2	Ishibashi <i>et al</i> <sup>[30]</sup>
Rabbits		
WHHL	Naturally deficient in LDL receptors resembling human familial hypercholesterolemia	Watanabe <sup>[10]</sup>
STH	Rabbit model for human hypertriglyceridemia and combined hyperlipidemia	Beatty <i>et al</i> <sup>[38]</sup>
NZW-human apo B <sub>100</sub> transgenic rabbits	Transgenic animal model manifesting combined hyperlipidemia with reduced HDL-cholesterol concentrations	Fan <i>et al</i> <sup>[33]</sup>
NZW-human apo AI or human LCAT transgenic rabbits	Rabbit model with elevated HDL-cholesterol levels and reduced atherosclerosis	Duverger <i>et al</i> <sup>[34]</sup>
Pigs		
Lipoprotein-associated mutations (designated Lpb5, Lpr1, and Lpu1)	This pig model develops hypercholesterolemia and atherosclerosis without dietary cholesterol. In addition to coronary arteries, iliac and femoral arteries also develop atherosclerotic lesions which become complicated by 2 year of age.	Prescott <i>et al</i> <sup>[44]</sup>
Non-human primates		
Rhesus monkeys	Develops spontaneous atherosclerosis. This animal model develops majority of atherosclerotic lesions in the anterior descending and circumflex branches of the left coronary artery	Carey <sup>[45]</sup>
Cebus monkeys	Develops spontaneous atherosclerosis. This animal model develops atherosclerotic lesions in their carotid bifurcation and coronary arteries	Carey <sup>[45]</sup>
Cynomolgus monkeys and African green monkeys	These monkeys develop spontaneous atherosclerosis. Atherosclerotic lesions being developed in coronary arteries and abdominal aorta, respectively	Hollander <i>et al</i> <sup>[49]</sup>
Others		
Dogs	These animal models have significant amount of limitations that have not extensively used	Geer <i>et al</i> <sup>[50]</sup>
Hamsters		Nistor <i>et al</i> <sup>[52]</sup>
Guinea pigs		Fernandez <i>et al</i> <sup>[54]</sup>
Birds		Wagner <i>et al</i> <sup>[56]</sup>

Apo E<sup>-/-</sup>: Apolipoprotein E deficient; KO: Knockout; VLDL: Very low density lipoprotein; LDL: Low density lipoprotein; HDL: High density lipoprotein; CETP: Cholesterol-ester transfer protein; LCAT: Lecithin cholesterol acyl transferase; CCR2: Chemoattractant protein-1 receptor, CCR2; WHHL: Watanabe Heritable Hyperlipidemic; STH: St. Thomas' Hospital; NZW: New Zealand White.

responders" and "hypo-responders"<sup>[46,47]</sup>. Anatomical locations of atherosclerotic lesions vary among different strains of monkeys. For example, majority of atherosclerotic lesions are found in the anterior descending and circumflex branches of the left coronary artery in rhesus monkeys, while cebus monkeys develop such lesions in their carotid bifurcation and coronary arteries<sup>[45,48]</sup>. The cynomolgus monkeys and African green monkeys also

vary from each other in the location of atherosclerotic lesions being developed in coronary arteries and abdominal aorta, respectively<sup>[49]</sup>.

## OTHER ANIMAL MODELS

Dogs<sup>[50,51]</sup>, hamsters<sup>[52,53]</sup>, guinea pigs<sup>[54]</sup>, and birds<sup>[55,56]</sup> have been also used in experimental atherosclerosis. However,

these animals have shown a significant amount of limitations that has not allowed popularity for the use of such animals extensively.

## CONCLUSION

This mini-review aims to summarize the features of the most commonly used animal models of atherosclerosis. Despite many advances in medical research, we still do not have specific animal models for specific human conditions. Every animal model has its own advantages and disadvantages. For example, while non-human-primates are the closest animals to humans, variability in lesion development, high cost, availability, possible hazard, ethical issues and handling matters are among major limitations in the use of these animals. Mice and rabbits also vary from humans in regard to lipoprotein metabolism and development of atherosclerotic lesions. However, these species have been the most common animal models used so far. Among these species, either naturally defective animals such as WHHL and STH rabbits<sup>[7-13,37-39,57-59]</sup>, or genetically modified mice have been used extensively in atherosclerosis research. In particular, LDL-r-KO mice<sup>[23,60]</sup>, apo E-KO mice<sup>[61-63]</sup>, Cystathionine  $\gamma$ -lyase-KO mice<sup>[64]</sup> have contributed to our understanding of the disease pathophysiology. Furthermore, surgical procedures and infectious agents have been also used in a number of animal models to study the postoperative injuries such as neointimal hyperplasia<sup>[65]</sup>, atherosclerotic plaque instability<sup>[28]</sup> or the role of *Chlamydia pneumoniae*<sup>[66,67]</sup> in disease development. The use of these animal models has certainly advanced our knowledge of the induction of atherosclerotic lesions. However, there is no reliable animal model for regression of atherosclerotic lesions. Further research and development is needed to generate such animal models. The list of animal model and their characteristic are summarized in Table 1.

## ACKNOWLEDGMENTS

Dr. Moghadasian's research program currently is supported by Natural Sciences and Engineering Research Council of Canada. SG is a recipient of Manitoba Health Research Council post-doctoral fellowship.

## REFERENCES

- 1 **World Health Organization.** Cardiovascular diseases (CVDs). 2013. Available from: URL: <http://www.who.int/mediacentre/factsheets/fs317/en/>
- 2 **Ignatowski AC.** Influence of animal food on the organism of rabbits. *S Peterb Izvies Imp Voyenno-Med Akad* 1908; **16**: 154-173
- 3 **Zhang SH, Reddick RL, Piedrahita JA, Maeda N.** Spontaneous hypercholesterolemia and arterial lesions in mice lacking apolipoprotein E. *Science* 1992; **258**: 468-471 [PMID: 1411543 DOI: 10.1126/science.1411543]
- 4 **Véniant MM, Zlot CH, Walzem RL, Pierotti V, Driscoll R, Dichek D, Herz J, Young SG.** Lipoprotein clearance mechanisms in LDL receptor-deficient "Apo-B48-only" and "Apo-B100-only" mice. *J Clin Invest* 1998; **102**: 1559-1568 [PMID: 9788969 DOI: 10.1172/JCI4164]
- 5 **Mezdour H, Jones R, Dengremont C, Castro G, Maeda N.** Hepatic lipase deficiency increases plasma cholesterol but reduces susceptibility to atherosclerosis in apolipoprotein E-deficient mice. *J Biol Chem* 1997; **272**: 13570-13575 [PMID: 9153204 DOI: 10.1074/jbc.272.21.13570]
- 6 **Purcell-Huynh DA, Farese RV, Johnson DF, Flynn LM, Pierotti V, Newland DL, Linton MF, Sanan DA, Young SG.** Transgenic mice expressing high levels of human apolipoprotein B develop severe atherosclerotic lesions in response to a high-fat diet. *J Clin Invest* 1995; **95**: 2246-2257 [PMID: 7738190 DOI: 10.1172/JCI117915]
- 7 **Kondo T, Watanabe Y.** A heritable hyperlipemic rabbit. *Jikken Dobutsu* 1975; **24**: 89-94 [PMID: 1238262]
- 8 **Watanabe Y, Ito T, Kondo T.** Breeding of a rabbit strain of hyperlipidemia and characteristics of the strain. *Exp Anim* 1977; **26**: 35-42
- 9 **Watanabe Y.** Studies on characteristics of spontaneously hyperlipemic rabbits and development of the strain with such property. *Bull Azabu Vet Coll* 1977; **2**: 99-124
- 10 **Watanabe Y.** Serial inbreeding of rabbits with hereditary hyperlipidemia (WHHL-rabbit). *Atherosclerosis* 1980; **36**: 261-268 [PMID: 7406953 DOI: 10.1016/0021-9150(80)90234-8]
- 11 **Tanzawa K, Shimada Y, Kuroda M, Tsujita Y, Arai M, Watanabe H.** WHHL-rabbit: a low density lipoprotein receptor-deficient animal model for familial hypercholesterolemia. *FEBS Lett* 1980; **118**: 81-84 [PMID: 7409195 DOI: 10.1016/0014-5793(80)81223-3]
- 12 **Raymond TL, Reynolds SA, Swanson JA, Patnode CA, Bell FP.** The effect of oral l-carnitine on lipoprotein composition in the Watanabe Heritable Hyperlipidemic Rabbit (*Oryctolagus cuniculus*). *Comp Biochem Physiol A Comp Physiol* 1987; **88**: 503-506 [PMID: 2892624 DOI: 10.1016/0300-9629(87)90071-5]
- 13 **Szeto A, Rossetti MA, Mendez AJ, Noller CM, Herderick EE, Gonzales JA, Schneiderman N, McCabe PM.** Oxytocin administration attenuates atherosclerosis and inflammation in Watanabe Heritable Hyperlipidemic rabbits. *Psychoneuroendocrinology* 2013; **38**: 685-693 [PMID: 22998949 DOI: 10.1016/j.psyneuen.2012.08.009]
- 14 **Barter PJ, Brewer HB, Chapman MJ, Hennekens CH, Rader DJ, Tall AR.** Cholesteryl ester transfer protein: a novel target for raising HDL and inhibiting atherosclerosis. *Arterioscler Thromb Vasc Biol* 2003; **23**: 160-167 [PMID: 12588754 DOI: 10.1161/01.ATV.0000054658.91146.64]
- 15 **Carter CP, Howles PN, Hui DY.** Genetic variation in cholesterol absorption efficiency among inbred strains of mice. *J Nutr* 1997; **127**: 1344-1348 [PMID: 9202089]
- 16 **Sanan DA, Newland DL, Tao R, Marcovina S, Wang J, Mooser V, Hammer RE, Hobbs HH.** Low density lipoprotein receptor-negative mice expressing human apolipoprotein B-100 develop complex atherosclerotic lesions on a chow diet: no accentuation by apolipoprotein(a). *Proc Natl Acad Sci USA* 1998; **95**: 4544-4549 [PMID: 9539774 DOI: 10.1073/pnas.95.8.4544]
- 17 **Homanics GE, de Silva HV, Osada J, Zhang SH, Wong H, Borensztajn J, Maeda N.** Mild dyslipidemia in mice following targeted inactivation of the hepatic lipase gene. *J Biol Chem* 1995; **270**: 2974-2980 [PMID: 7852377]
- 18 **Greeve J, Altkemper I, Dieterich JH, Greten H, Windler E.** Apolipoprotein B mRNA editing in 12 different mammalian species: hepatic expression is reflected in low concentrations of apoB-containing plasma lipoproteins. *J Lipid Res* 1993; **34**: 1367-1383 [PMID: 8409768]
- 19 **Föger B, Chase M, Amar MJ, Vaisman BL, Shamburek RD, Paigen B, Fruchart-Najib J, Paiz JA, Koch CA, Hoyt RF, Brewer HB, Santamarina-Fojo S.** Cholesteryl ester transfer protein corrects dysfunctional high density lipoproteins and reduces aortic atherosclerosis in lecithin cholesterol acyltransferase transgenic mice. *J Biol Chem* 1999; **274**: 36912-36920 [PMID: 10601244 DOI: 10.1074/jbc.274.52.36912]



- 20 **Moghadasian MH**, McManus BM, Pritchard PH, Frohlich JJ. "Tall oil"-derived phytosterols reduce atherosclerosis in ApoE-deficient mice. *Arterioscler Thromb Vasc Biol* 1997; **17**: 119-126 [PMID: 9012646 DOI: 10.1161/01.ATV.17.1.119]
- 21 **Moghadasian MH**, McManus BM, Godin DV, Rodrigues B, Frohlich JJ. Proatherogenic and antiatherogenic effects of probucol and phytosterols in apolipoprotein E-deficient mice: possible mechanisms of action. *Circulation* 1999; **99**: 1733-1739 [PMID: 10190884 DOI: 10.1161/01.CIR.99.13.1733]
- 22 **Xu Z**, Le K, Moghadasian MH. Long-term phytosterol treatment alters gene expression in the liver of apo E-deficient mice. *J Nutr Biochem* 2008; **19**: 545-554 [PMID: 18155511 DOI: 10.1016/j.jnutbio.2007.06.012]
- 23 **Surendiran G**, Goh C, Le K, Zhao Z, Askarian F, Othman R, Nicholson T, Moghadasian P, Wang YJ, Aliani M, Shen G, Beta T, Moghadasian MH. Wild rice (*Zizania palustris* L.) prevents atherogenesis in LDL receptor knockout mice. *Atherosclerosis* 2013; **230**: 284-292 [PMID: 24075758 DOI: 10.1016/j.atherosclerosis.2013.07.042]
- 24 **Groot PH**, van Vlijmen BJ, Benson GM, Hofker MH, Schiffelers R, Vidgeon-Hart M, Havekes LM. Quantitative assessment of aortic atherosclerosis in APOE\*3 Leiden transgenic mice and its relationship to serum cholesterol exposure. *Arterioscler Thromb Vasc Biol* 1996; **16**: 926-933 [PMID: 8696955 DOI: 10.1161/01.ATV.16.8.926]
- 25 **van Vlijmen BJ**, Pearce NJ, Bergö M, Staels B, Yates JW, Gribble AD, Bond BC, Hofker MH, Havekes LM, Groot PH. Apolipoprotein E\*3-Leiden transgenic mice as a test model for hypolipidaemic drugs. *Arzneimittelforschung* 1998; **48**: 396-402 [PMID: 9608883]
- 26 **Lutgens E**, Daemen M, Kockx M, Doeveendans P, Hofker M, Havekes L, Wellens H, de Muinck ED. Atherosclerosis in APOE\*3-Leiden transgenic mice: from proliferative to atheromatous stage. *Circulation* 1999; **99**: 276-283 [PMID: 9892595 DOI: 10.1161/01.CIR.99.2.276]
- 27 **Lewis P**, Stefanovic N, Pete J, Calkin AC, Giunti S, Thallas-Bonke V, Jandeleit-Dahm KA, Allen TJ, Kola I, Cooper ME, de Haan JB. Lack of the antioxidant enzyme glutathione peroxidase-1 accelerates atherosclerosis in diabetic apolipoprotein E-deficient mice. *Circulation* 2007; **115**: 2178-2187 [PMID: 17420349 DOI: 10.1161/CIRCULATIONAHA.106.664250]
- 28 **Chen YC**, Bui AV, Diesch J, Manasseh R, Hausding C, Rivera J, Haviv I, Agrotis A, Htun NM, Jowett J, Hagemeyer CE, Hannan RD, Bobik A, Peter K. A novel mouse model of atherosclerotic plaque instability for drug testing and mechanistic/therapeutic discoveries using gene and microRNA expression profiling. *Circ Res* 2013; **113**: 252-265 [PMID: 23748430 DOI: 10.1161/CIRCRESAHA.113.301562]
- 29 **Mestas J**, Hughes CC. Of mice and not men: differences between mouse and human immunology. *J Immunol* 2004; **172**: 2731-2738 [PMID: 14978070]
- 30 **Ishibashi M**, Egashira K, Zhao Q, Hiasa K, Ohtani K, Ihara Y, Charo IF, Kura S, Tsuzuki T, Takeshita A, Sunagawa K. Bone marrow-derived monocyte chemoattractant protein-1 receptor CCR2 is critical in angiotensin II-induced acceleration of atherosclerosis and aneurysm formation in hypercholesterolemic mice. *Arterioscler Thromb Vasc Biol* 2004; **24**: e174-e178 [PMID: 15331433 DOI: 10.1161/01.ATV.0000143384.69170.2d]
- 31 **Boisvert WA**, Spangenberg J, Curtiss LK. Treatment of severe hypercholesterolemia in apolipoprotein E-deficient mice by bone marrow transplantation. *J Clin Invest* 1995; **96**: 1118-1124 [PMID: 7635947 DOI: 10.1172/JCI118098]
- 32 **Moghadasian MH**, Godin DV, McManus BM, Frohlich JJ. Lack of regression of atherosclerotic lesions in phytosterol-treated apo E-deficient mice. *Life Sci* 1999; **64**: 1029-1036 [PMID: 10210285 DOI: 10.1016/S0024-3205(99)00029-6]
- 33 **Fan J**, McCormick SP, Krauss RM, Taylor S, Quan R, Taylor JM, Young SG. Overexpression of human apolipoprotein B-100 in transgenic rabbits results in increased levels of LDL and decreased levels of HDL. *Arterioscler Thromb Vasc Biol* 1995; **15**: 1889-1899 [PMID: 7583569 DOI: 10.1161/01.ATV.15.11.1889]
- 34 **Duverger N**, Kruth H, Emmanuel F, Caillaud JM, Viglietta C, Castro G, Tailleux A, Fievet C, Fruchart JC, Houdebine LM, Deneffe P. Inhibition of atherosclerosis development in cholesterol-fed human apolipoprotein A-I-transgenic rabbits. *Circulation* 1996; **94**: 713-717 [PMID: 8772693 DOI: 10.1161/01.CIR.94.4.713]
- 35 **Hoeg JM**, Santamarina-Fojo S, Bérard AM, Cornhill JF, Herderick EE, Feldman SH, Haudenschild CC, Vaisman BL, Hoyt RF, Demosky SJ, Kauffman RD, Hazel CM, Marcovina SM, Brewer HB. Overexpression of lecithin: cholesterol acyltransferase in transgenic rabbits prevents diet-induced atherosclerosis. *Proc Natl Acad Sci USA* 1996; **93**: 11448-11453 [PMID: 8876155 DOI: 10.1073/pnas.93.21.11448]
- 36 **Warren RJ**, Ebert DL, Mitchell A, Barter PJ. Rabbit hepatic lipase cDNA sequence: low activity is associated with low messenger RNA levels. *J Lipid Res* 1991; **32**: 1333-1339 [PMID: 1770315]
- 37 **Aliev G**, Burnstock G. Watanabe rabbits with heritable hypercholesterolaemia: a model of atherosclerosis. *Histol Histopathol* 1998; **13**: 797-817 [PMID: 9690137]
- 38 **Beatty TH**, Prenger VL, Virgil DG, Lewis B, Kwiterovich PO, Bachorik PS. A genetic model for control of hypertriglyceridemia and apolipoprotein B levels in the Johns Hopkins colony of St. Thomas Hospital rabbits. *Genetics* 1992; **132**: 1095-1104 [PMID: 1459430]
- 39 **Nordestgaard BG**, Lewis B. Intermediate density lipoprotein levels are strong predictors of the extent of aortic atherosclerosis in the St. Thomas's Hospital rabbit strain. *Atherosclerosis* 1991; **87**: 39-46 [PMID: 1872923 DOI: 10.1016/0021-9150(91)90230-Z]
- 40 **Stout LC**. Pathogenesis of diffuse intimal thickening (DIT) in aortas and coronary arteries of 2 1/2-year-old miniature pigs. *Exp Mol Pathol* 1982; **37**: 427-432 [PMID: 6759158 DOI: 10.1016/0014-4800(82)90054-5]
- 41 **Griggs TR**, Bauman RW, Reddick RL, Read MS, Koch GG, Lamb MA. Development of coronary atherosclerosis in swine with severe hypercholesterolemia. Lack of influence of von Willebrand factor or acute intimal injury. *Arteriosclerosis* 1986; **6**: 155-165 [PMID: 3485423 DOI: 10.1161/01.ATV.6.2.155]
- 42 **Holvoet P**, Theilmeier G, Shivalkar B, Flameng W, Collen D. LDL hypercholesterolemia is associated with accumulation of oxidized LDL, atherosclerotic plaque growth, and compensatory vessel enlargement in coronary arteries of miniature pigs. *Arterioscler Thromb Vasc Biol* 1998; **18**: 415-422 [PMID: 9514410 DOI: 10.1161/01.ATV.18.3.415]
- 43 **Rapacz J**, Hasler-Rapacz J, Taylor KM, Checovich WJ, Attie AD. Lipoprotein mutations in pigs are associated with elevated plasma cholesterol and atherosclerosis. *Science* 1986; **234**: 1573-1577 [PMID: 3787263 DOI: 10.1126/science.3787263]
- 44 **Prescott MF**, McBride CH, Hasler-Rapacz J, Von Linden J, Rapacz J. Development of complex atherosclerotic lesions in pigs with inherited hyper-LDL cholesterololemia bearing mutant alleles for apolipoprotein B. *Am J Pathol* 1991; **139**: 139-147 [PMID: 1853929]
- 45 **Carey KD**. Non-human primate models of atherosclerosis. In: Strong WB, ed. *Atherosclerosis: Its Pediatric Aspects*. Orlando Grune and Stratton, 1978: 41-83
- 46 **Bullock BC**, Lehner ND, Clarkson TB, Feldner MA, Wagner WD, Lofland HB. Comparative primate atherosclerosis. I. Tissue cholesterol concentration and pathologic anatomy. *Exp Mol Pathol* 1975; **22**: 151-175 [PMID: 803901 DOI: 10.1016/0014-4800(75)90060-X]
- 47 **Clarkson TB**, Lofland HB, Bullock BC, Goodman HO. Genetic control of plasma cholesterol. Studies on squirrel monkeys. *Arch Pathol* 1971; **92**: 37-45 [PMID: 4997068]
- 48 **Bullock BC**, Clarkson TB, Lehner ND, Lofland HB, St Clair RW. Atherosclerosis in Cebus albifrons monkeys. [Clinical



- and pathologic studies. *Exp Mol Pathol* 1969; **10**: 39-62 [PMID: 4975562 DOI: 10.1016/0014-4800(69)90047-1]
- 49 **Hollander W**, Kirkpatrick B, Paddock J, Colombo M, Nagraj S, Prusty S. Studies on the progression and regression of coronary and peripheral atherosclerosis in the cynomolgus monkey. I. Effects of dipyridamole and aspirin. *Exp Mol Pathol* 1979; **30**: 55-73 [PMID: 217724 DOI: 10.1016/0014-4800(79)90081-9]
  - 50 **Geer JC**, Guitry MA. Experimental canine atherosclerosis. In: Roberts JC, Straus R, eds. *Comparative atherosclerosis*. Hoeber, Harper and Row, New York, 1965: 170-185
  - 51 **Mahley RW**, Weisgraber KH, Innerarity T. Canine lipoproteins and atherosclerosis. II. Characterization of the plasma lipoproteins associated with atherogenic and nonatherogenic hyperlipidemia. *Circ Res* 1974; **35**: 722-733 [PMID: 4138629 DOI: 10.1161/01.RES.35.5.722]
  - 52 **Nistor A**, Bulla A, Filip DA, Radu A. The hyperlipidemic hamster as a model of experimental atherosclerosis. *Atherosclerosis* 1987; **68**: 159-173 [PMID: 3689479 DOI: 10.1016/0021-9150(87)90106-7]
  - 53 **Dillard A**, Matthan NR, Lichtenstein AH. Use of hamster as a model to study diet-induced atherosclerosis. *Nutr Metab (Lond)* 2010; **7**: 89 [PMID: 21143982 DOI: 10.1186/1743-7075-7-89]
  - 54 **Fernandez ML**, Volek JS. Guinea pigs: a suitable animal model to study lipoprotein metabolism, atherosclerosis and inflammation. *Nutr Metab (Lond)* 2006; **3**: 17 [PMID: 16566831 DOI: 10.1186/1743-7075-3-17]
  - 55 **Horlick L**, Katz LN. Retrogression of atherosclerotic lesions on cessation of cholesterol feeding in the chick. *J Lab Clin Med* 1949; **34**: 1427-1442 [PMID: 18143607]
  - 56 **Wagner WD**, Clarkson TB, Feldner MA, Prichard RW. The development of pigeon strains with selected atherosclerosis characteristics. *Exp Mol Pathol* 1973; **19**: 304-319 [PMID: 4763632]
  - 57 **Brousseau ME**, Hoeg JM. Transgenic rabbits as models for atherosclerosis research. *J Lipid Res* 1999; **40**: 365-375 [PMID: 10064724]
  - 58 **Moghadasian MH**, Frohlich JJ, McManus BM. Advances in experimental dyslipidemia and atherosclerosis. *Lab Invest* 2001; **81**: 1173-1183 [PMID: 11555665 DOI: 10.1038/labinvest.3780331]
  - 59 **Konya A**. Animal models for atherosclerosis, restenosis, and endovascular aneurysm repair. In: Conn PM (Ed). *Sourcebook of models for biomedical research*. Springer-Verlag New York, LLC, 2008: 369-384
  - 60 **Bombo RP**, Afonso MS, Machado RM, Lavrador MS, Nunes VS, Quintão ER, Koike M, Catanozi S, Lin CJ, Nakandakare ER, Lottenberg AM. Dietary phytosterol does not accumulate in the arterial wall and prevents atherosclerosis of LDLr-KO mice. *Atherosclerosis* 2013; **231**: 442-447 [PMID: 24267264 DOI: 10.1016/j.atherosclerosis.2013.10.015]
  - 61 **Zhao R**, Moghadasian MH, Shen GX. Involvement of NADPH oxidase in up-regulation of plasminogen activator inhibitor-1 and heat shock factor-1 in mouse embryo fibroblasts induced by oxidized LDL and in apolipoprotein E-deficient mice. *Free Radic Res* 2011; **45**: 1013-1023 [PMID: 21651452 DOI: 10.3109/10715762.2011.587419]
  - 62 **Tan Z**, Le K, Moghadasian M, Shahidi F. Enzymatic synthesis of phytosteryl docosahexaneates and evaluation of their anti-atherogenic effects in apo-E deficient mice. *Food Chem* 2012; **134**: 2097-2104 [PMID: 23442661 DOI: 10.1016/j.foodchem.2012.04.009]
  - 63 **Cleverley K**, Du X, Premecz S, Le K, Zeglinski M, Nicholson T, Goh CY, Lu Y, Anderson HD, Moghadasian MH, Jassal DS. The effects of fish oil consumption on cardiovascular remodeling in ApoE deficient mice. *Can J Physiol Pharmacol* 2013; **91**: 960-965 [PMID: 24117264 DOI: 10.1139/cjpp-2013-0077]
  - 64 **Mani S**, Li H, Untereiner A, Wu L, Yang G, Austin RC, Dickhout JG, Lhoták Š, Meng QH, Wang R. Decreased endogenous production of hydrogen sulfide accelerates atherosclerosis. *Circulation* 2013; **127**: 2523-2534 [PMID: 23704252 DOI: 10.1161/CIRCULATIONAHA.113.002208]
  - 65 **Reis ED**, Roque M, Dansky H, Fallon JT, Badimon JJ, Cordon-Cardo C, Shiff SJ, Fisher EA. Sulindac inhibits neointimal formation after arterial injury in wild-type and apolipoprotein E-deficient mice. *Proc Natl Acad Sci USA* 2000; **97**: 12764-12769 [PMID: 11027305 DOI: 10.1073/pnas.210394497]
  - 66 **Saikkku P**, Leinonen M, Mattila K, Ekman MR, Nieminen MS, Mäkelä PH, Huttunen JK, Valtonen V. Serological evidence of an association of a novel Chlamydia, TWAR, with chronic coronary heart disease and acute myocardial infarction. *Lancet* 1988; **2**: 983-986 [PMID: 2902492]
  - 67 **Deniset JF**, Cheung PK, Dibrov E, Lee K, Steigerwald S, Pierce GN. Chlamydia pneumoniae infection leads to smooth muscle cell proliferation and thickening in the coronary artery without contributions from a host immune response. *Am J Pathol* 2010; **176**: 1028-1037 [PMID: 20019196 DOI: 10.2353/ajpath.2010.090645]

**P- Reviewers:** Carlos F, Prosser HC, Ramji DP, Tzortzis N

**S- Editor:** Ji FF **L- Editor:** A **E- Editor:** Liu SQ



## Cesarean scar endometrioma: Case series

Cavit Çöl, Edip Erdal Yilmaz

Cavit Çöl, Edip Erdal Yilmaz, Department of General Surgery, Abant İzzet Baysal University Medical Faculty, 14000 Bolu, Turkey

Author contributions: All authors contributed equally to this work.

Correspondence to: Cavit Çöl, Professor, Department of General Surgery, Abant İzzet Baysal University Medical Faculty, Kültür Mh., 14000 Bolu, Turkey. [cavitcol@yahoo.com](mailto:cavitcol@yahoo.com)  
Telephone: +90-542-6238162 Fax: +90-374-2534559

Received: December 5, 2013 Revised: January 24, 2014

Accepted: April 11, 2014

Published online: May 16, 2014

© 2014 Baishideng Publishing Group Inc. All rights reserved.

**Key words:** Scar endometrioma; Endometriosis; Cesarean

**Core tip:** This is a case series about endometrioma located at cesarean scar. We present 6 patients who have painful abdominal mass of endometrioma. Medical data of 6 patients who admitted to our institution with abdominal wall endometrioma were evaluated respectively in this study. The diagnostic approaches and treatment is discussed and recommended.

### Abstract

**AIM:** To evaluate endometrioma located at cesarean scar.

**METHODS:** Medical data of 6 patients who presented to our institution with abdominal wall endometrioma were evaluated retrospectively and reviewed literature in this case series. The diagnostic approaches and treatment is discussed.

**RESULTS:** All patients had a painful mass located at abdominal scars with history of cesarean section. The ages ranged from 31 to 34 and Doppler ultrasonography (US) detected hypoechoic mass with a mean diameter of 30 mm. Initial diagnosis was endometrioma in 4 and incisional hernia in 2 of 6 patients. Treatment was achieved with surgical excision in 5 patients, and one is followed by hormone suppression therapy with gonadotropin.

**CONCLUSION:** Malignant or benign tumors of abdominal wall and incisional hernias should be kept in mind for diagnosis of endometrioma. Imaging methods like doppler US, computed tomography and magnetic resonance imaging should be used for differential diagnosis. Definitive diagnosis can only be made histopathologically. The treatment should be complete surgical excision and take care against intraoperative auto-inoculation of endometrial tissue in order to prevent recurrences.

Çöl C, Yılmaz EE. Cesarean scar endometrioma: Case series. *World J Clin Cases* 2014; 2(5): 133-136 Available from: URL: <http://www.wjgnet.com/2307-8960/full/v2/i5/133.htm> DOI: <http://dx.doi.org/10.12998/wjcc.v2.i5.133>

### INTRODUCTION

Endometriosis is defined as extrauterine localization of ectopic functional endometrial gland and stroma. Cystic or solid tumoral masses caused by endometriosis are named as endometrioma. Although this pathologic condition is mostly encountered in ligaments of uterus, ovaries, Douglas pouch and pelvic peritoneum; endometriosis has also been reported in nose, breast, lung, spleen, gastrointestinal tractus, kidney, abdominal wall, but scar endometrioma is extremely rare<sup>[1,2]</sup>. Endometriosis is seen in 8%-15% of young fertile women with regular menstrual cycles, and its frequency varies between 0.03%-1.08% on incision scar following gynecologic operations and caesarean sections (C/S)<sup>[3-5]</sup>. Endometrioma is a disease with symptoms such as a cyclic painful mass. Endometrioma should be remembered in patients who have the history of C/S and a painful mass on scar tissue and in whom both pain and mass size differ during menstrual period and imaging methods like doppler ultrasonography (US), computed tomography (CT), magnetic resonance imaging (MRI) and fine needle aspiration cytology should be benefited for diagnosis.

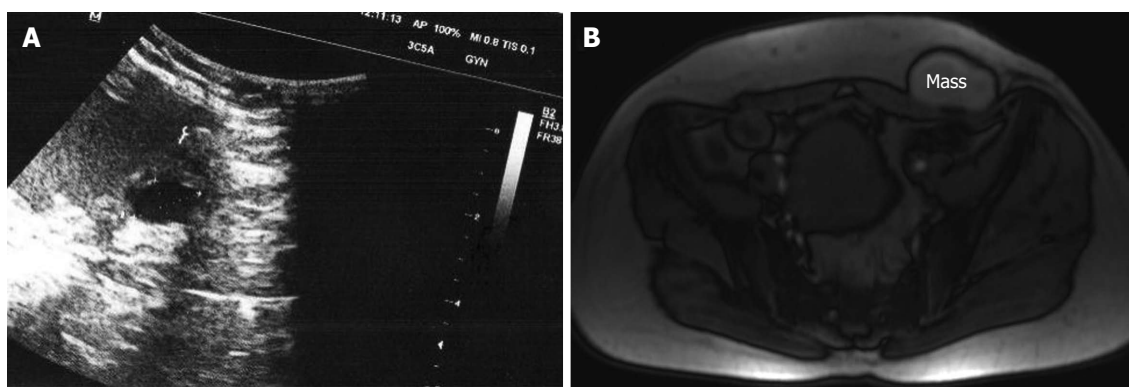


Figure 1 Ultrasonographic view (A) and magnetic resonance imaging (B) of scar endometrioma.

Table 1 Medical data of patients who were diagnosed with scar endometrioma in caesarean sections site

Age, yr	C/S	Recurrent disease	Years after C/S	Interval to symptoms onset, yr	Pain type	Weight of lesion (g)	Size (cm)	Initial diagnosis
34	1	No	3	1	Cyclic	54	3 × 2	Incisional hernia
32	2	No	7	4	Non-cyclic	60	3 × 3	Incisional hernia
32	1	No	3	1/2	Cyclic	58	3 × 3	Incisional hernia
31	2	No	3	1	Cyclic	48	2 × 2	Incisional hernia
33	2	No	4	1	Cyclic	70	4 × 4	Endometrioma
31	1	No	6	2	Cyclic	62	3 × 5	Endometrioma

## MATERIALS AND METHODS

This is a small case series and retrospective study on patients with abdominal wall C/S endometrioma. In this study, we presented clinical and laboratory findings of six consecutive patients with scar endometrioma (Figure 1) who admitted to our department between 2009 and 2012 and reviewed the literature. There were 28 patients with incisional hernias and 36 benign abdominal wall tumors like lipomas, *etc.* in this period. Medical data of the patients were evaluated, and presented our experience with scar endometrioma consequently by this case series.

## RESULTS

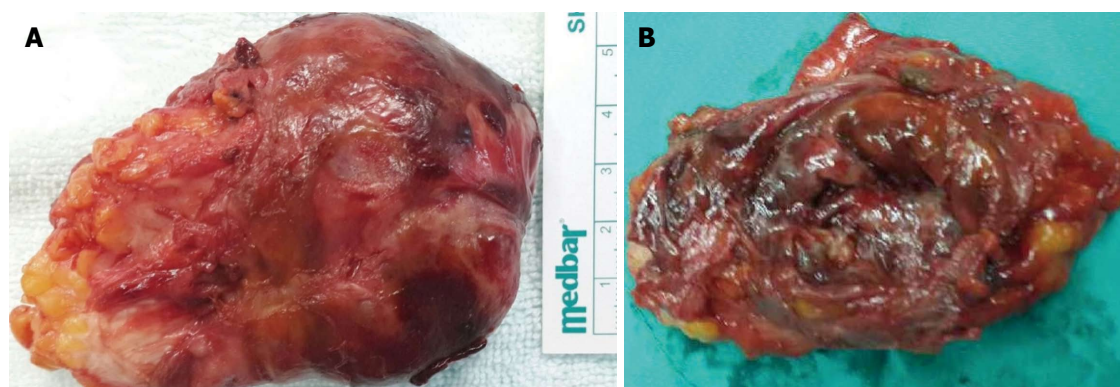
Routine hematological and biochemical examinations were done following medical history and physical examination of patients who have a painful mass in their C/S site. Main complaint of our cases on admission was a palpable mass on incision site and cyclic pain. Abdominal pain was non-cyclic unusually in one patient. As you seen in Table 1, all patients were in third decade and aged between 31-34 years. Parity was 1 in three and 2 in other three patients and all deliveries were C/S's. While caesarean incision was Pfannenstiel in 5 patients and there was a subumbilical midline incision in one. Duration between the last C/S and hospital admission varied between 2-7 years and duration between emergence of a painful mass on scar site and hospital admission varied between 6 mo and 4 years. There were not abdominal endometriosis and scar endometrioma in previous history. There were 28 patients with incisional hernias and 36 benign abdominal wall tumors like lipomas, *etc.* during three years

period. Initial diagnosis were incisional hernia in four and endometrioma in two of our six patients. Definite diagnosis was made by histopathological evaluation of excised materials. Prediagnosis was irreducible incisional hernia in 4 out of 6 patients (66.6%) and endometrioma in 2 patients (33.3%). There were four patients diagnosed in first five years after C/S, and two patients more than five years. Doppler US was done to make a definite diagnosis successfully in five patients. Final diagnosis was made with USG and abdominal CT in one patient. The weight of resected materials were min 48 g, max 70 g and ultrasonographical size of the palpable mass in scar tissue varied between 2 to 5 cm (Table 1).

Treatment was achieved with complete surgical resection in 5 of six patients. One patient did not accept surgical intervention and she was followed up with medical treatment by using hormone suppressor drugs. Painful scar endometrioma were excised with undamaged borders and without making endometrial tissue implantation into the neighboring tissue in five patients who accepted surgical treatment. The glandular structure of endometrium and stroma were seen microscopically in fibrocollagenous tissue and that the mass belonged to endometrioma (Figure 2).

## DISCUSSION

Common use of laparoscopy has enabled more frequent detection of intraabdominal endometriosis. Dysmenorrhea, irregular menstrual cycles and infertility are the most common symptoms seen in endometriosis. A palpable mass on C/S incision site and a cyclic pain are pathognomonic in patients with endometrioma<sup>[2-6]</sup>.



**Figure 2** External view of resected endometrioma (A), cut surface of specimen showed semi-solid and soft tumor (B).

Two different theories are available to explain endometrioma development. According to the first hypothesis, multipotent mesenchymal cells differentiate to endometrial tissues in their site after puberty and show physiological changes, like proliferation, hemorrhage as response to hormonal functions. And second hypothesis; endometrial cells are transported to extrauterine areas in some instances and similarly endometrioma develops by being affected from hormonal changes<sup>[5]</sup>. Endometrioma development in C/S scar tissue on abdominal wall seems more consistent with the second hypothesis. An increase has been reported in endometrioma frequency in parallel with the increase in number of C/S in recent years<sup>[7,8]</sup>. Procedure responsible for endometrioma development on incision site is iatrogenic inoculation of endometrial tissue into incision site<sup>[9]</sup>. Three of our cases underwent one C/S, three cases twice C/S. Endometrioma usually emerges during a ten year period following C/S<sup>[10]</sup>.

Scar endometrioma are not frequently met more than 5 years after C/S, but we have two patients with relatively late diagnosed scar endometrioma in our series. Basic and the most commonly detected complaints of the patients were a palpable mass in C/S scar tissue and cyclic pain<sup>[11]</sup>. These symptoms have begun within a 6 mo-4 year period following C/S operation. Abdominal pain or painful mass were seen cyclic usually, but there were one patient with non-cyclic painful endometrioma in our case series.

Definitive diagnosis of endometrioma is not possible without histopathological examination. They are some published parameters on clinical and ultrasonographic findings for differential diagnosis of abdominal wall endometrioma near cesarean section<sup>[12]</sup>. Lipomas, sebaceous cysts, hemangiomas and lymphangiomas, desmoid tumors among common benign tumors of abdominal wall<sup>[13,14]</sup>. It is recommended to keep in mind that these tumors may be a metastatic lesion arising from a malignant focus and to make diagnosis of endometrioma definite through US-guided fine needle aspiration cytology in patients who do not accept surgical treatment<sup>[5,12,13]</sup>. Imaging methods like doppler US, CT and MRI should absolutely be benefited for differential diagnosis of suspected masses. Definitive diagnosis can only be made histopathologically.

In a conclusion, the soft tissue tumors and endometrioma are probable diagnosis besides incisional hernia in patients who have a palpable mass on C/S scar following some obstetric and gynecologic interventions. A detailed medical history, physical examination findings and imaging methods in suspected cases are significant diagnostic tools to investigate the features of the pain and relationship with menstrual cycle. Radical treatment should be complete surgical excision for patients who receive pre-diagnosis of endometrioma and one should take care against intraoperative auto-inoculation of endometrial tissue in order to prevent recurrences. Combined oral contraceptives, progestagens and hormone suppression therapy with gonadotropin releasing hormone analogues should be used for medical treatment of patients who don't want surgery and whose diagnosis of endometrioma was verified through fine needle aspiration cytology.

## COMMENTS

### Background

Endometriosis and/or endometrioma is defined as ectopic occurrence of endometrium. Cystic or solid tumoral masses located at extrauterine organs caused by endometriosis are named as endometrioma.

### Innovations and breakthroughs

Abdominal endometriosis was seen often but cesarean scars endometrioma is rare and difficult to diagnose preoperatively.

### Peer review

This manuscript is worth to publish for increasing the awareness of incisional endometrioma possibility among patients with endometriosis.

## REFERENCES

- 1 Akbulut S, Sevinc MM, Bakir S, Cakabay B, Sezgin A. Scar endometriosis in the abdominal wall: a predictable condition for experienced surgeons. *Acta Chir Belg* 2010; **110**: 303-307 [PMID: 20690511]
- 2 Bektaş H, Bilsel Y, Sari YS, Ersöz F, Koç O, Deniz M, Boran B, Huq GE. Abdominal wall endometrioma; a 10-year experience and brief review of the literature. *J Surg Res* 2010; **164**: e77-e81 [PMID: 20855082 DOI: 10.1016/j.jss.2010.07.043]
- 3 Teng CC, Yang HM, Chen KF, Yang CJ, Chen LS, Kuo CL. Abdominal wall endometriosis: an overlooked but possibly preventable complication. *Taiwan J Obstet Gynecol* 2008; **47**: 42-48 [PMID: 18400581 DOI: 10.1016/S1028-4559(08)60053-4]
- 4 Gunes M, Kayikcioglu F, Ozturkoglu E, Haberal A. Incisional endometriosis after cesarean section, episiotomy and other



- gynecologic procedures. *J Obstet Gynaecol Res* 2005; **31**: 471-475 [PMID: 16176520 DOI: 10.1111/j.1447-0756.2005.00322.x]
- 5 **Hensen JH**, Van Breda Vriesman AC, Puylaert JB. Abdominal wall endometriosis: clinical presentation and imaging features with emphasis on sonography. *AJR Am J Roentgenol* 2006; **186**: 616-620 [PMID: 16498086 DOI: 10.2214/AJR.04.1619]
- 6 **Chang Y**, Tsai EM, Long CY, Chen YH, Kay N. Abdominal wall endometriomas. *J Reprod Med* 2009; **54**: 155-159 [PMID: 19370900]
- 7 **Brimienė V**, Brimas G, Strupas K. Differential diagnosis between chronic pancreatitis and pancreatic cancer: a prospective study of 156 patients. *Medicina (Kaunas)* 2011; **47**: 154-162 [PMID: 21822037]
- 8 **Zhu Z**, Al-Beiti MA, Tang L, Liu X, Lu X. Clinical characteristic analysis of 32 patients with abdominal incision endometriosis. *J Obstet Gynaecol* 2008; **28**: 742-745 [PMID: 19065373 DOI: 10.1080/01443610802463744]
- 9 **Horton JD**, Dezee KJ, Ahnfeldt EP, Wagner M. Abdominal wall endometriosis: a surgeon's perspective and review of 445 cases. *Am J Surg* 2008; **196**: 207-212 [PMID: 18513698 DOI: 10.1016/j.amjsurg.2007.07.035]
- 10 **Nominato NS**, Prates LF, Lauar I, Morais J, Maia L, Geber S. Cesarean section greatly increases risk of scar endometriosis. *Eur J Obstet Gynecol Reprod Biol* 2010; **152**: 83-85 [PMID: 20510495 DOI: 10.1016/j.ejogrb.2010.05.001]
- 11 **Lipscomb GH**, Givens VM, Smith WE. Endometrioma occurring in abdominal wall incisions after cesarean section. *J Reprod Med* 2011; **56**: 44-46 [PMID: 21366126]
- 12 **Francica G**. Reliable clinical and sonographic findings in the diagnosis of abdominal wall endometriosis near cesarean section scar. *World J Radiol* 2012; **4**: 135-140 [PMID: 22590667]
- 13 **Savelli L**, Manuzzi L, Di Donato N, Salfi N, Trivella G, Cecaroni M, Seracchioli R. Endometriosis of the abdominal wall: ultrasonographic and Doppler characteristics. *Ultrasound Obstet Gynecol* 2012; **39**: 336-340 [PMID: 21793086 DOI: 10.1002/uog.10052]
- 14 **Ozel L**, Sagiroglu J, Unal A, Unal E, Gunes P, Baskent E, Aka N, Titiz MI, Tufekci EC. Abdominal wall endometriosis in the cesarean section surgical scar: a potential diagnostic pitfall. *J Obstet Gynaecol Res* 2012; **38**: 526-530 [PMID: 22381104 DOI: 10.1111/j.1447-0756.2011.01739.x]

**P- Reviewers:** Kahyaoglu S, Wang CC **S- Editor:** Wen LL

**L- Editor:** A **E- Editor:** Liu SQ



## Systematic review of noninvasive treatments to arrest dentin non-cavitated caries lesions

Isauremi Vieira de Assunção, Giovanna de Fátima Alves da Costa, Boniek Castillo Dutra Borges

Isauremi Vieira de Assunção, Giovanna de Fátima Alves da Costa, Boniek Castillo Dutra Borges, Department of Dentistry, Federal University of Rio Grande do Norte, Natal, 59056-000, Brazil

**Author contributions:** Assunção IV and Costa GF performed the literature research and wrote the introduction and result sections; Borges BC established the experimental design, wrote the discussion and conclusion sections, and reviewed the paper.

**Correspondence to:** Dr. Boniek Castillo Dutra Borges, Professor, Department of Dentistry, Federal University of Rio Grande do Norte, Av. Sen. Salgado Filho, 1787, Natal, 59056-000, Brazil. [boniek.castillo@gmail.com](mailto:boniek.castillo@gmail.com)

Telephone: +55-84-32154111 Fax: +55-84-32154111

Received: December 07, 2013 Revised: February 16, 2014

Accepted: March 11, 2014

Published online: May 16, 2014

based sealant may arrest the progression of non-cavitated occlusal dentinal caries. Further clinical trials with longer follow-up times should be performed to increase scientific evidence.

© 2014 Baishideng Publishing Group Inc. All rights reserved.

**Key words:** Dentin; Dental caries; Fissure sealants; Preventive therapy; Dental restoration

**Core tip:** Occlusal fissure sealing with a resin-based sealant may arrest the progression of non-cavitated occlusal dentinal caries.

Assunção IV, Costa GF, Borges BC. Systematic review of non-invasive treatments to arrest dentin non-cavitated caries lesions. *World J Clin Cases* 2014; 2(5): 137-141 Available from: URL: <http://www.wjgnet.com/2307-8960/full/v2/i5/137.htm> DOI: <http://dx.doi.org/10.12998/wjcc.v2.i5.137>

### Abstract

**AIM:** To systematically review the literature on the efficacy of noninvasive methods of arresting the progression of non-cavitated occlusal carious lesions in dentin.

**METHODS:** The Medline/PubMed, LILACS, SciELO and Scopus databases were searched to identify relevant publications through to November 2013. Only clinical trials evaluating the ability of noninvasive methods to arrest the progression of occlusal non-cavitated carious lesions in dentin were included. Screening, data extraction and quality assessment were conducted independently and in duplicate.

**RESULTS:** Of 167 citations identified, nine full text articles were screened and five were included in the analysis. All papers reported on occlusal fissure sealing using a self-curing glass ionomer ( $n = 1$ ) or resin-based ( $n = 4$ ) sealant. Only the use of resin-based sealant to obliterate occlusal fissures arrested the progression of non-cavitated occlusal carious lesions in dentin.

**CONCLUSION:** Occlusal fissure sealing with a resin-

### INTRODUCTION

Pit and fissure sealing is a noninvasive approach that has been used since the 1960s to prevent occlusal caries by providing a physical barrier that inhibits the accumulation of microorganisms and food particles. The efficacy and clinical safety of this preventive approach have been well established<sup>[1,2]</sup>.

In restorative dentistry, the treatment of carious lesions has been reviewed many times. Minimally invasive dentistry, the goal of which is to preserve the greatest amount possible of tooth structure, is intended to replace conventional procedures<sup>[1]</sup>. When an open cavity is diagnosed, the option of restoration tends to be unquestionable. However, it should be noted that caries involving dentine may be present in non-cavitated lesions and that there may be a layer of intact enamel<sup>[2]</sup>.

The use of pit and fissure sealant to seal fissures has

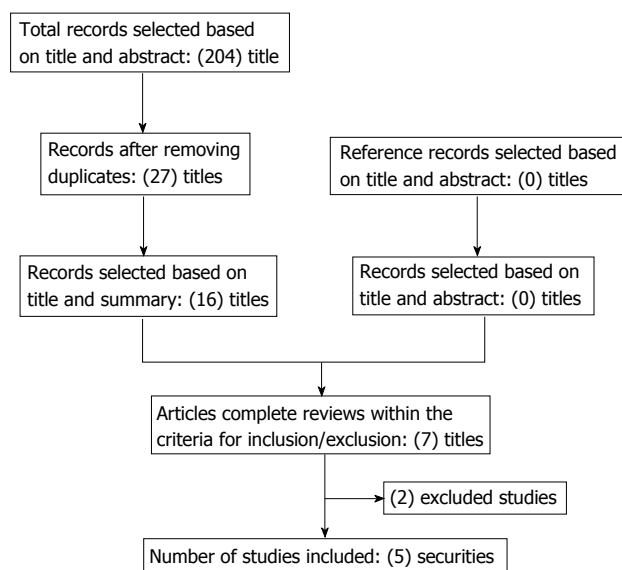


Figure 1 Flow chart of studies through the review.

been investigated as a secondary preventive approach to the management of non-cavitated occlusal carious lesions in dentin since it arrested their progression<sup>[3-7]</sup>. This non-invasive method may replace the traditional restorative approach as it can be performed with a shorter chair time in the absence of anesthesia. Moreover, it can conserve tooth structure by delaying intervention or minimizing the operative procedure<sup>[8]</sup>. Although several clinical trials have examined this use of pit and fissure sealants, a systematic analysis of their results is needed to provide scientific evidence for its effectiveness as a secondary preventive approach. Thus, we systematically reviewed the literature on the efficacy of noninvasive methods in arresting the progression of non-cavitated occlusal carious lesions in dentin.

## MATERIALS AND METHODS

### Focused question

The focused question addressed in this review was: “Can noninvasive treatments arrest the progression of non-cavitated occlusal carious lesions in dentin?”.

### Search strategy

The Medline/PubMed, LILACS, SciELO and Scopus databases were searched to identify relevant studies published through to November 2013. The search strategy employed the following keywords related to the intervention method, type of carious lesion and outcome.

**Intervention:** “Sealing” or “fissure sealing” or “sealant” or “glass ionomer cement” or “nonoperative” or “non-operative” or “noninvasive” or “non-invasive” or “non-surgical” or “non-surgical”.

**Type of caries lesion:** [(“dentin” or “dental”) and “caries”] and (“occlusal” or “pit and fissure” or “pits and

fissures”) and (“non-cavitated” or “noncavitated”).

**Outcome:** “Progression” or “regression” or “arrest” or “arrested” or “arrestment” or “arresting”.

### Inclusion and exclusion criteria

The selection was limited to clinical trials published in English that evaluated the efficacy of any noninvasive approach in treating non-cavitated occlusal carious lesions in dentin. Review articles, *in vitro* studies and those reporting only on proximal carious lesions or those in enamel were excluded. Studies that evaluated cavitated lesions were also excluded.

### Screening methods and data extraction

Two independent reviewers (Assunção IV and Costa GF) selected studies using a two stage screening process. In the first stage, titles and abstracts were screened to eliminate irrelevant articles and those that did not meet the inclusion criteria. In the second stage, the reviewers independently verified study eligibility after reading full texts and data extraction and quality assessment were performed for included studies. Disagreements about the inclusion or exclusion of a study were resolved by consensus and, when necessary, consultation with a third reviewer (Borges BCD). In the analysis of these included studies, the following questions were addressed: (1) Does pit and fissure sealing effectively arrest the progression of non-cavitated occlusal carious lesions in dentin?; (2) Is the noninvasive treatment of non-cavitated occlusal carious lesions in dentin effective in permanent and deciduous teeth?; and (3) Which materials should clinicians use to seal pits and fissures in the management of non-cavitated occlusal carious lesions in dentin? What are the perspectives on the use of alternative sealing materials and techniques?

## RESULTS

The initial search identified 204 articles (156 articles in Medline/PubMed, 22 articles in LILACS, 8 articles in SciELO and 18 articles in Scopus). Thirty-seven duplicate publications were excluded, leaving 167 potentially eligible articles. First stage screening of titles and abstracts identified nine articles that were qualified for full text screening. The second stage of screening identified five articles that met the inclusion criteria (two studies evaluating cavitated lesions, one article reporting on an invasive treatment and one review article were excluded) (Figure 1).

The content of selected studies is summarized in Table 1.

All five studies analyzed in this review were performed on similar samples of teeth with visually non-cavitated occlusal lesions between the dentin-enamel junction and middle third of dentin. The extent of carious lesions was confirmed by bite-wing radiographic analysis. The similar samples allow precise comparison of

Table 1 Summary of studies included in the analysis

Author/yr	Study design	Sample characteristics	Analyzed variables and evaluation methods	Tested treatments	Follow up	Results/conclusions
Borges <i>et al.</i> <sup>(3)</sup> (2010)	Randomized controlled clinical trial	Sixty permanent molars in 35 individuals (12-19.5 years old) with non-cavitated carious lesions radiographically located between the dentin-enamel junction and middle third of dentin	Caries progression and sealant loss; clinical and radiographic examinations	Experimental ( <i>n</i> = 30): oral hygiene instruction and fissure sealing (Fluorshield, Dentsply); control ( <i>n</i> = 30): oral hygiene instruction	4-mo intervals for 1 year; control group was followed for only 8 mo due to signals of caries progression	Eight teeth (four per group) were lost at 1-year follow up. Clinical and radiographic caries progression was significantly more frequent in control than in experimental teeth. Sealant loss occurred in three cases and resulted in caries progression. Pit and fissure sealant effectively arrested caries progression, suggesting that this intervention may replace traditional invasive treatment of non-cavitated dental caries
Borges <i>et al.</i> <sup>(4)</sup> (2012)	Randomized controlled clinical trial	Sixty permanent molars in 35 individuals (12-19.5 years old) with non-cavitated carious lesions radiographically located between the dentin-enamel junction and middle third of dentin	Caries progression and sealant loss; clinical and radiographic examinations	Experimental ( <i>n</i> = 30): oral hygiene instruction and fissure sealing (Fluorshield, Dentsply); control ( <i>n</i> = 30): oral hygiene instruction	4-mo intervals for 1 year, then 12-mo intervals to 36 mo; control group was followed for only 8 mo due to signals of caries progression	Eight teeth (four per group) were lost at 1-year follow up; no tooth was lost subsequently. Clinical and radiographic caries progression was significantly more frequent in the control than in the experimental group. Three teeth lost sealant and showed caries progression at the 12-mo follow up. No sealant loss or caries progression was observed at 24 or 36 mo. Pit and fissure sealant effectively arrested carious lesions for a 36-mo period
Borges <i>et al.</i> <sup>(5)</sup> (2012)	Randomized controlled split-mouth clinical trial	Sixty deciduous molars in 30 schoolchildren (5-9 years old) with non-cavitated carious lesions radiographically located between the dentin-enamel junction and middle third of dentin	Experimental group: caries progression and sealant loss; control group: secondary caries emergence and clinical failure of composite restorations	Experimental ( <i>n</i> = 30): fissure sealing (Fluorshield, Dentsply); control ( <i>n</i> = 30): composite restoration (Ice, SDI)	4-mo intervals for 1 year	No tooth was lost to follow up. The treatment modalities were similarly effective in managing non-cavitated occlusal carious lesions in dentin of primary molars. Three teeth showed partial sealant retention and caries progression after 1 year. The invasive approach can be replaced with non-drilling fissure sealing techniques for the management of these lesions
da Silveira <i>et al.</i> <sup>(6)</sup> (2012)	Randomized controlled clinical trial	Fifty-one permanent molars in 38 individuals (± 12.78 years old) with non-cavitated carious lesions radiographically located between the dentin-enamel junction and middle third of dentin	Caries progression and sealant loss; clinical and radiographic examinations	Experimental ( <i>n</i> = 27): oral hygiene instruction and sealing with self-curing glass ionomer cement (Vidrión-R, SS White)	4-mo intervals for 1 year; control group was followed for only 8 mo due to signals of caries progression	No tooth was lost to follow up. Clinical examination showed no significant difference between groups, but radiographic examination showed less caries progression in sealed teeth
Bakhshandeh <i>et al.</i> <sup>(7)</sup> (2012)	Clinical trial	Five premolars and 67 molars in 52 individuals (± 28 years old) lesions in need of restoration. The maximum depth of the lesions, radiographically assessed, was limited to the middle third of the dentin	Experimental group: caries progression and sealant loss; control group: secondary caries emergence and clinical failure of composite restorations	Control ( <i>n</i> = 24): oral hygiene instruction; experimental ( <i>n</i> = 60): resin-based fissure sealing (Delton, Dentsply) Control ( <i>n</i> = 12): composite restoration (Filtek Supreme XT, 3M ESPE)	6-12-mo intervals for 25-38 (mean, 33) mo	Eleven sealed teeth were lost to follow up; no restored tooth was lost. All restorations and sealants functioned well; seven sealants were repaired/replaced due to failure and three sealed lesions were restored due to caries progression. Sealants arrested most (44/49) lesions; expansion of criteria for therapeutic sealing of occlusal carious lesions in adults will improve dental health

study outcomes.

## DISCUSSION

### Does pit and fissure sealing effectively arrest the progression of non-cavitated occlusal carious lesions in dentin?

Four<sup>(3,5,7)</sup> of five studies analyzed reported that sealing arrested the progression of carious lesions when the sealant was intact and tight. These authors used only resin-based fissure sealants and analyzed caries progression by clinical and radiographic examinations. The blockade of the nutritional supply by the mechanical barrier created by the sealant



seems to be the most plausible explanation for the lack of caries progression observed in those studies. Because total retention is an integral requirement for sealant success, attempts should be made to increase the mechanical strength of sealing materials and their adhesion potential to enamel.

In contrast, de Silveira *et al.*<sup>[6]</sup> reported that a self-curing glass ionomer fissure sealant did not arrest caries progression in molars with non-cavitated occlusal dentinal lesions. Although sealed teeth showed no sign of caries progression on radiographic examination, they exhibited visible cavitation after 12 mo of follow up. The rapid macroscopic loss of self-curing glass ionomer sealant may render fissures susceptible to biofilm adhesion and further acid attack, leading to the emergence of cavitations on occlusal enamel<sup>[6]</sup>.

Some points reported by Borges *et al.*<sup>[3,4]</sup> should be emphasized. The authors commented that possible limitations of their studies included the absence of power calculation, the sample size of 60 teeth and the loss of some of the sample at 12 mo, which may have reduced the internal and external validity of these investigations. However, they argued that the remarkable difference in caries progression observed between the sealed and unsealed groups at the 12 mo recall appointments indicated that the sample size was satisfactory for the analysis and that the observation period was appropriate to detect distinct differences in outcomes. The authors further emphasized that the lack of caries progression at 12, 24 and 36 mo recall appointments in teeth with intact sealant clearly confirmed that the sample size was satisfactory.

One should consider that only papers published in the English language were included in this systematic review. In fact, the most relevant papers are published in English language since it can be read worldwide. For this reason, we believe that data loss due to the exclusion of papers wrote in other languages could not generate a negative impact to the present results.

The minimally invasive approach to carious lesions in dentistry is based on the principle that nonsurgical treatments are preferable to invasive treatments as the former increase tooth longevity. Invasive interventions initiate a cycle of treatment and re-treatment, often leading to the need for crowns and implants, regardless of the quality of the initial filling preparation<sup>[11]</sup>. Data from studies included in this review demonstrate the great positive impact of a noninvasive approach to the management of non-cavitated occlusal carious lesions in dentin. Further studies with longer follow-up times should be performed to improve the evidence provided by the present systematic review.

### **Is the noninvasive treatment of non-cavitated occlusal carious lesions in dentin effective in permanent and deciduous teeth?**

Borges *et al.*<sup>[5]</sup> compared the efficacy of pit and fissure sealing using a resin-based material with that of traditional tooth restoration in the treatment of non-cavitated

occlusal carious lesions in the dentin of primary molars. They concluded that the invasive restorative approach can be replaced with the fissure sealing technique that does not require drilling. Borges *et al.*<sup>[3,4]</sup> and Bakhshandeh *et al.*<sup>[7]</sup> reported that the same noninvasive fissure sealing treatment arrested caries in permanent molars. Thus, this approach appears to be effective in deciduous and permanent molars.

### **Which materials should clinicians use to seal pits and fissures in the management of non-cavitated occlusal carious lesions in dentin? What are the perspectives on the use of alternative sealing materials and techniques?**

The clinical effectiveness of fissure sealing for the management of non-cavitated occlusal carious lesions in dentin depends on complete maintenance of the sealant in fissures<sup>[3-7]</sup>. The self-curing glass ionomer cement tested by de Silveira *et al.*<sup>[6]</sup> showed high loss rates that prevented it from arresting caries progression, as determined by clinical examination. The authors observed the emergence of cavitations in enamel when the cement was lost. Resin-based fissure sealants showed higher complete retention rates, as reported by Borges *et al.*<sup>[3-5]</sup> and Bakhshandeh *et al.*<sup>[7]</sup>. These superior survival rates suggest that resin-based fissure sealant is preferable to self-curing glass ionomer cement.

Resin-based fissure sealants are adequate for the therapeutic sealing of non-cavitated occlusal carious lesions in dentin. However, the partial and total sealant losses observed by Borges *et al.*<sup>[3-5]</sup> and Bakhshandeh *et al.*<sup>[7]</sup> limit the effectiveness of this noninvasive therapeutic approach. Researchers have sought to improve sealant adhesion to enamel and/or the physical properties of polymeric networks as sealant adaptation and polymeric network strength may be related to the survival of sealants in tooth fissures<sup>[12]</sup>. Enamel conditioning with a casein phosphopeptide-amorphous calcium phosphate paste in association with adhesive system application improved the bond durability of a fissure sealant *in vitro*<sup>[13]</sup>, suggesting that this protocol could increase sealant retention.

*In vitro* studies have demonstrated the superiority of flowable composites to traditional fissure sealants in terms of physical properties related to polymeric network strength, such as the degree of conversion, hardness and crosslink density<sup>[12,14-16]</sup>. Moreover, preheating of flowable composites before photoactivation has been found to increase softening resistance to acid challenge *in vitro*<sup>[17]</sup>. In this context, further clinical trials should be performed to evaluate the efficacy of the above described protocols *in vivo*.

In conclusion, noninvasive therapeutic fissure sealing is effective for the management of non-cavitated occlusal carious lesions in dentin if a resin-based fissure sealant is used. Since only relatively short-time follow-up clinical trials were found, further randomized controlled clinical trials with longer follow-up times should be performed to provide more scientific evidence for the efficacy of therapeutic sealing in the management of these lesions.

## COMMENTS

**Background**

The use of pit and fissure sealant to seal fissures has been investigated as a secondary preventive approach to the management of non-cavitated occlusal carious lesions in dentin. Although several clinical trials have examined this use of pit and fissure sealants, a systematic analysis of their results is needed to provide scientific evidence for its effectiveness as a secondary preventive approach.

**Research frontiers**

Cariology, restorative dentistry, preventive dentistry.

**Innovations and breakthroughs**

Four of five studies analyzed in this systematic review reported that sealing occlusal fissures with a resin-based sealant arrested the progression of carious lesions when the sealant was intact and tight. Occlusal fissure sealing with a resin-based sealant may arrest the progression of non-cavitated occlusal dental caries.

**Applications**

The actual restorative approach to treat non-cavitated caries lesion in dentin may be replaced with a noninvasive method. In turn, this will contribute to save sound dental tissues which are lost during cavity preparation, increasing tooth longevity.

**Terminology**

Tooth demineralization refers to a process where an acidic environment leaches some of the mineral content (such as calcium) out of a tooth's calcified tissues (enamel and dentin). Non invasive treatment is when there is no cavity preparation involved and healthy tooth structure is preserved.

**Peer review**

The present manuscript is a focused and well performed systematic review.

## REFERENCES

- 1 Bader JD, Shugars DA. The evidence supporting alternative management strategies for early occlusal caries and suspected occlusal dentinal caries. *J Evid Based Dent Pract* 2006; **6**: 91-100 [PMID: 17138407 DOI: 10.1016/j.jebdp.2005.12.004]
- 2 Weerheijm KL, van Amerongen WE, Eggink CO. The clinical diagnosis of occlusal caries: a problem. *ASDC J Dent Child* 1989; **56**: 196-200 [PMID: 2723206]
- 3 Borges BC, Campos GB, da Silveira AD, de Lima KC, Pinheiro IV. Efficacy of a pit and fissure sealant in arresting dentin non-cavitated caries: a 1-year follow-up, randomized, single-blind, controlled clinical trial. *Am J Dent* 2010; **23**: 311-316 [PMID: 21344828]
- 4 Borges BC, de Souza Borges J, Braz R, Montes MA, de Assunção Pinheiro IV. Arrest of non-cavitated dentinal occlusal caries by sealing pits and fissures: a 36-month, randomised controlled clinical trial. *Int Dent J* 2012; **62**: 251-255 [PMID: 23106838 DOI: 10.1111/j.1875-595X.2012.00117]
- 5 Borges BC, De Souza Bezerra Araújo RF, Dantas RF, De Araújo Lucena A, De Assunção Pinheiro IV. Efficacy of a non-drilling approach to manage non-cavitated dentin occlusal caries in primary molars: a 12-month randomized controlled clinical trial. *Int J Paediatr Dent* 2012; **22**: 44-51 [PMID: 21718373 DOI: 10.1111/j.1365-263X.2011.01156.x]
- 6 da Silveira AD, Borges BC, de Almeida Varela H, de Lima KC, Pinheiro IV. Progression of non-cavitated lesions in dentin through a nonsurgical approach: a preliminary 12-month clinical observation. *Eur J Dent* 2012; **6**: 34-42 [PMID: 22229005]
- 7 Bakhshandeh A, Qvist V, Ekstrand KR. Sealing occlusal caries lesions in adults referred for restorative treatment: 2-3 years of follow-up. *Clin Oral Investig* 2012; **16**: 521-529 [PMID: 21479565 DOI: 10.1007/s00784-011-0549-4]
- 8 Borges BC, de Souza Borges J, de Araujo LS, Machado CT, Dos Santos AJ, de Assunção Pinheiro IV. Update on nonsurgical, ultraconservative approaches to treat effectively non-cavitated caries lesions in permanent teeth. *Eur J Dent* 2011; **5**: 229-236
- 9 Ahovuo-Saloranta A, Hiiri A, Nordblad A, Mäkelä M, Worthington HV. Pit and fissure sealants for preventing dental decay in the permanent teeth of children and adolescents. *Cochrane Database Syst Rev* 2008; **(4)**: CD001830 [PMID: 18843625 DOI: 10.1002/14651858.CD001830.pub3]
- 10 Ahovuo-Saloranta A, Forss H, Walsh T, Hiiri A, Nordblad A, Mäkelä M, Worthington HV. Sealants for preventing dental decay in the permanent teeth. *Cochrane Database Syst Rev* 2013; **3**: CD001830 [PMID: 23543512 DOI: 10.1002/14651858.CD001830.pub4]
- 11 ten Cate JM. Remineralization of deep enamel dentine caries lesions. *Aust Dent J* 2008; **53**: 281-285 [PMID: 18782376 DOI: 10.1111/j.1834-7819.2008.00063.x]
- 12 Borges BC, Bezerra GV, Mesquita Jde A, Pereira MR, Aguiar FH, Santos AJ, Pinheiro IV. Effect of irradiation times on the polymerization depth of contemporary fissure sealants with different opacities. *Braz Oral Res* 2011; **25**: 135-142 [PMID: 21537639 DOI: 10.1590/S1806-83242011000200007]
- 13 Borges BC, Catelan A, Sasaki RT, Ambrosano GM, Reis AF, Aguiar FH. Effect of the application of a casein phosphopeptide-amorphous calcium phosphate (CPP-ACP) paste and adhesive systems on bond durability of a fissure sealant. *Odontology* 2013; **101**: 52-59 [PMID: 22438086 DOI: 10.1007/s10266-012-0062-5]
- 14 Borges BC, Souza-Junior EJ, Catelan A, Lovadino JR, Santos PH, Paulillo LA, Aguiar FH. Influence of extended light exposure time on degree of conversion and plasticization of materials used as pit and fissure sealants. *J Invest Clin Dent* 2010; **1**: 151-155 [DOI: 10.1111/j.2041-1626.2010.00015.x]
- 15 Borges BC, Souza-Junior EJ, Catelan A, Ambrosano GM, Paulillo LA, Aguiar FH. Impact of extended radiant exposure time on polymerization depth of fluoride-containing fissure sealer materials. *Acta Odontol Latinoam* 2011; **24**: 47-51 [PMID: 22010406]
- 16 Borges BC, Bezerra GV, Mesquita Jde A, Silva TR, Alves-Júnior C, Pinheiro IV, Braz R, Montes MA. Filler morphology of resin-based low-viscosity materials and surface properties after several photoactivation times. *Acta Odontol Scand* 2013; **71**: 215-222 [PMID: 22283452 DOI: 10.3109/00016357.2012.654613]
- 17 Borges BC, Barreto AS, Gomes CL, Silva TR, Alves-Jr C, Pinheiro IV, Braz R, Montes MA. Preheating of resin-based flowable materials in a microwave device: a promising approach to increasing hardness and softening resistance under cariogenic challenge. *Eur J Esthet Dent* 2013; **8**: 558-568 [PMID: 24624378]

P- Reviewers: Alves J, Beegun I S- Editor: Song XX

L- Editor: Roemmele A E- Editor: Liu SQ



## Atrium of stone: A case of confined left atrial calcification without hemodynamic compromise

Christopher Jones, Aadil Mubeen Lodhi, Long Bao Cao, Arjun Kumar Chagarlamudi, Assad Movahed

Christopher Jones, Aadil Mubeen Lodhi, Long Bao Cao, Arjun Kumar Chagarlamudi, Assad Movahed, Department of Cardiovascular Sciences, East Carolina Heart Institute, Brody School of Medicine, East Carolina University, Greenville, NC 27858, United States

**Author contributions:** Jones C, Lodhi AM, Cao LB, Chagarlamudi AK and Movahed A contributed to the manuscript writing and revision.

Supported by The "East Carolina Heart Institute"

**Correspondence to:** Assad Movahed, MD, Department of Cardiovascular Sciences, East Carolina Heart Institute, Brody School of Medicine, East Carolina University, 115 Heart Drive, Mail Stop 651, Greenville, NC 27858, United States. [movaheda@ecu.edu](mailto:movaheda@ecu.edu)

Telephone: +1-832-3731447 Fax: +1-252-7447724

Received: October 23, 2013 Revised: March 4, 2014

Accepted: April 25, 2014

Published online: May 16, 2014

### Abstract

Dystrophic cardiac calcification is often associated with conditions causing systemic inflammation and when present, is usually extensive, often encompassing multiple cardiac chambers and valves. We present an unusual case of dystrophic left atrial calcification in the setting of end stage renal disease on hemodialysis diagnosed by echocardiography and computed tomography. Significant calcium deposition is confined within the walls of the left atrium with no involvement of the mitral valve, and no hemodynamic effects.

© 2014 Baishideng Publishing Group Inc. All rights reserved.

**Key words:** Left atrium calcification; Heart of stone; Atrial calcification; Dystrophic cardiac calcification; Renal failure

**Core tip:** Dystrophic cardiac calcification can often lead to complicated valvular stenosis, cardiac arrhythmias, cardiac block and abnormal cardiac hemodynamics by

effecting systolic and diastolic cardiac function, thus awareness, early detection and treatment of the underlying cause, and resulting complications is key to patient outcome.

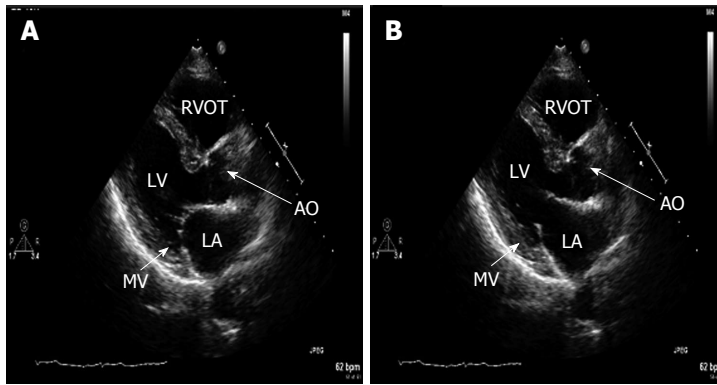
Jones C, Lodhi AM, Cao LB, Chagarlamudi AK, Movahed A. Atrium of stone: A case of confined left atrial calcification without hemodynamic compromise. *World J Clin Cases* 2014; 2(5): 142-145 Available from: URL: <http://www.wjgnet.com/2307-8960/full/v2/i5/142.htm> DOI: <http://dx.doi.org/10.12998/wjcc.v2.i5.142>

### INTRODUCTION

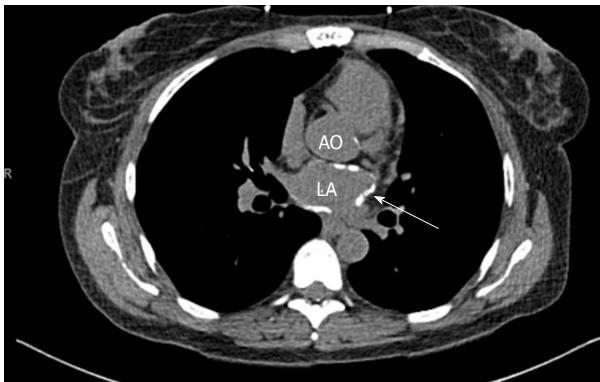Dystrophic cardiac calcification is often diffuse and occurs primarily in patients with chronic inflammatory diseases. Long term advancement of dystrophic calcification often lead to complicated valvular stenosis, cardiac arrhythmias, cardiac block and abnormal cardiac hemodynamic by effecting systolic and diastolic cardiac function, thus awareness, early detection and treatment of the underlying cause, and resulting complications is key to patient outcome.

### CASE REPORT

A 55-year-old African-American woman with past medical history of hypertension, endstage renal failure on dialysis with failure of previous renal transplant presented for cardiac risk stratification prior to renal transplant surgery. Previous work up for renal transplant had been unremarkable except for elevated intact parathyroid hormone of 1346 pg/mL. Electrocardiogram showed normal sinus rhythm. By Teichholtz equation, transthoracic echocardiography showed a left ventricular ejection fraction of 75%. In the parasternal long axis view, the interventricular septal diameter was 1 cm, the left ventricular



**Figure 1** Transthoracic 2D parasternal long axis. A: Systole shows diffuse echo dense signal significantly confined to the walls of the left atrium indicated by arrow. No mitral valve (MV) or mitral annulus involvement. Valve closes normally during systole; B: Diastole shows adequate MV opening. LA: Left atrium; AO: Aortic root.



**Figure 2** Cardiac computed tomography indicating calcium within the walls of the left atrium and mild calcification of the aortic root. LA: Left atrium; AO: Aortic root.

posterior wall diameter was 1.1 cm, the left ventricular end diastolic diameter was 4 cm, and the left ventricular mass index was greater than  $86 \text{ g/m}^2$ . There was concentric remodeling by relative wall thickness calculation. Grade 2 diastolic dysfunction with pseudonormalization mitral inflow pattern was observed. The E:A was 1.4, lateral  $e'$  of 8.68 cm/s, medial  $e'$  of 6.14 cm/s, and a deceleration time of 200 ms. The left atrial size and volume was in the upper limits of normal. (Normal left atrial size by index is  $< 29 \text{ cm/m}^2$ )<sup>[1]</sup>. The left atrial wall, however, showed diffuse hyper-echogenicity not observed in the left ventricular walls. This hyper-echogenicity did not restrict the movement of the mitral valve leaflets (Figure 1). Tricuspid annular plane systolic excursion was 2.1 cm/s. A transesophageal echocardiogram was not performed in this case. However, in order to confirm our suspicion and diagnosis, the patient underwent a non-enhanced computed tomography (CT) of the chest which noted increased attenuation of the left atrial wall, consistent with calcification of majority of the left atrium and mild calcification of the ascending aorta (Figure 2). The CT unfortunately did not show the aorto-mitral continuity well. The Calcium-phosphorous product at time of evaluation was within normal limits, and patient had no history of tuberculosis or a positive Purified Protein Derivative.

## DISCUSSION

Calcification seen in patients is typically either a product

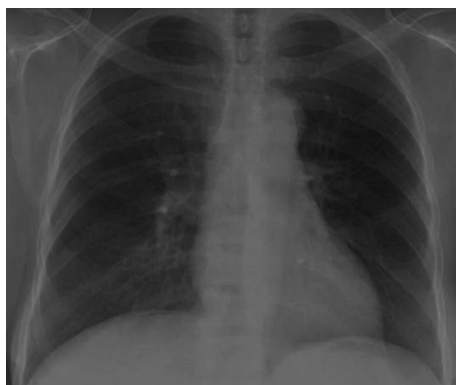of metastatic calcification or dystrophic calcification. Metastatic calcification is typically seen in patients with a disturbance of Calcium and Phosphorus metabolism, often due to renal dysfunction. In our patient, although the intact parathyroid hormone level was elevated on previous workup for renal transplant, the pattern of calcification was that of a dense, finely speckled pattern. This indicates that the calcification in the left atrium is a product of dystrophic calcification and not that of metastatic calcification.

Dystrophic myocardial calcification which is increased intracellular calcium deposition driven by high serum calcium, is a well described process associated with conditions that cause systemic inflammation such as renal failure, rheumatic disease or cardiac surgery<sup>[2-5]</sup>. Calcium deposition often involves the left atrial appendage, free wall and septal wall, and mitral valve as well. In severe cases the entire atrium is involved with significant mitral valve stenosis or malcoaptation<sup>[6]</sup>. In cases where an entire atrium is involved, it is often referred to as a “coconut”<sup>[7]</sup> or “porcelain atrium”<sup>[8]</sup>. Although calcification of parts or the whole left atrium have been well documented, calcium deposition confined to the left atrial walls without valvular involvement is a unique variant.

There are several genes that have been linked to dystrophic cardiac calcification, including but not limited to the ATP-binding cassette transporter subtype 6 gene which was recently found to mediate myocardial necrosis and calcification<sup>[9-11]</sup>, the Adiponectin gene which was linked to calcification of the aortic median<sup>[12,13]</sup>, the alpha2-HS-glycoprotein/fetuin gene which has been linked to calcification of coronary artery plaques in patients with type II diabetes<sup>[14,15]</sup>, the ectonucleotide pyrophosphatase/phosphodiesterase 1 gene which has been linked to increased aortic arch calcifications in patients with type II diabetes and higher coronary calcification scores in patients with End Stage Renal Disease<sup>[16-20]</sup>, and the Osteoprotegerin gene which has been linked to increased risk for coronary artery disease<sup>[21-25]</sup>.

Women in their fifth and sixth decades are most often affected<sup>[6]</sup> and can be classified into one of three types which are associated with prior mitral valve dysfunction<sup>[26]</sup>. Type A is caused by mitral stenosis with calcification confined to the left atrial appendage causing an increased occurrence of thrombi within the appendage. Type B is the result of advanced mitral stenosis with





**Figure 3** CXR shows a small amount of what appears to be pneumoperitoneum beneath the right hemidiaphragm that was present prior, otherwise, no change.

calcification confined to the left atrial free wall and the mitral valve. Type C is the confined calcification of the posterior wall of the left atrium. This particular pattern of left atrial calcium deposition is known as MacCallum's patch and is often the result of a regurgitant mitral jet<sup>[26]</sup>. The structure that is most often spared is the interatrial septum. When the septal wall is calcified as well, the term coconut atrium is used to describe the hyperdense white appearance of the complete left atrial calcification on imaging<sup>[6]</sup>. Multiple imaging techniques can be used to diagnose and assess the extent of calcification. On anterior-posterior chest radiograph mural calcification presents as a thin C shaped curvilinear density outlining the left atrium partially or completely with the opening of the C anterior to mitral annulus. Hyper-echogenicity within the walls of the left atrium, Restriction in atrial wall motion and mitral valve abnormalities can be well visualized with transthoracic and transesophageal echocardiography, however, CT is superior to all other imaging modalities for determining extent of calcification<sup>[20,27]</sup>.

Dystrophic calcification of the left atrium can cause significant complications which can lead to hemodynamic compromise or even collapse. A common complication is the occurrence of mitral stenosis as the mitral leaflets become restricted due to calcification<sup>[20]</sup>. In cases of significant calcium deposition Arrhythmias can present especially if calcification occurs outside the left atrium involving the SA node, AV node or other points along the cardiac conduction system. Over time increased left atrial pressure can develop due to decreased compliance of the left atrial walls and can be transmitted through pulmonary veins resulting in derangements in right heart hemodynamics (Figure 3)<sup>[7,28]</sup>.

The accepted surgical treatment for left atrial calcification is endoatrioectomy with mitral valve replacement as the calcification usually does not extend beyond the endocardium<sup>[25]</sup>. Total endoatrioectomy of a calcified left atrium has been shown to be a technique with limited morbidity, however, not much follow up of atrial compliance has been done in patients who undergo this procedure in order to quantify improvement<sup>[29]</sup>. The two major contraindications to endoatrioectomy are calcification of

the left atrial septal wall and mitral annulus. Septal calcification makes repair difficult and increases mortality due to the septum serving as a cleavage plane during surgery which helps prevent hemorrhage and embolization if thrombus is present. Caseous necrosis is known to cause mitral calcification, usually occurring along the posterior annulus<sup>[28,30]</sup>.

Our case presentation is unique in that all of the walls of the left atrium are heavily calcified including the septal wall and left atrial appendage with minimal presence in the ascending aorta, however, there is no calcification of the mitral valve and no resultant mitral stenosis, mitral regurgitation, arrhythmias or hemodynamic compromise.

## COMMENTS

### Case characteristics

In a preoperative evaluation for renal transplant of an asymptomatic patient with a prior history of end stage renal disease (ESRD) and hypertension, there were no significant clinical or exam findings.

### Clinical diagnosis

However, upon routine echocardiogram and chest X-ray, findings of dystrophic calcification was seen in the heart.

### Differential diagnosis

Findings of dystrophic calcification lead to further concerns of tuberculosis, sarcoidosis, and other rare systemic inflammatory diseases.

### Laboratory diagnosis

Calcium-phosphorous product at time of evaluation was within normal limits, and patient had no history of tuberculosis or a positive Purified Protein Derivative.

### Imaging diagnosis

Further evaluation by computed tomography (CT) imaging confirmed a calcified left atrium and made sarcoidosis, and other more rare inflammatory disease less likely.

### Pathological diagnosis

No further pathological studies were done, but the additional imaging studies confirmed dystrophic calcification in an individual with ESRD, a systemic inflammatory disease equivalent.

### Treatment

The patient is at risk for complicated valvular stenosis, cardiac arrhythmias, cardiac block and abnormal cardiac hemodynamics due to this dystrophic calcification; thus close follow-up, and early treatment of these resulting complications are the key to the patient's outcome.

### Term explanation

An "atrium of stone", thus refers to this dystrophic calcification almost isolated to the left atrium.

### Experiences and lessons

ESRD patients often carry a higher mortality and morbidity than previous thought, which may not always be present on initial clinical and exam assessment.

### Peer review

The authors present an unusual case of dystrophic left atrial calcification in the setting of end stage renal disease on hemodialysis diagnosed by echocardiography and CT. Calcium deposition is significantly confined within the walls of the left atrium with no involvement of the mitral valve or untoward effects on hemodynamics. This is an interesting case report for the clinical practice.

## REFERENCES

1. Lang RM, Bierig M, Devereux RB, Flachskampf FA, Foster E, Pellikka PA, Picard MH, Roman MJ, Seward J, Shanewise JS, Solomon SD, Spencer KT, Sutton MS, Stewart WJ. Recommendations for chamber quantification: a report from the American Society of Echocardiography's Guidelines and Standards Committee and the Chamber Quantification Writing Group, developed in conjunction with the European As-

- sociation of Echocardiography, a branch of the European Society of Cardiology. *J Am Soc Echocardiogr* 2005; **18**: 1440-1463 [PMID: 16376782]
- 2 **Kuzela DC**, Huffer WE, Conger JD, Winter SD, Hammond WS. Soft tissue calcification in chronic dialysis patients. *Am J Pathol* 1977; **86**: 403-424 [PMID: 836675]
  - 3 **Lee CJ**, Ramirez C, Thomson LE. A stone heart: fatal cardiac microcalcification. *Eur Heart J* 2007; **28**: 2312 [PMID: 17483106 DOI: 10.1093/eurheartj/ehm100]
  - 4 **Tom CW**, Talreja DR. Heart of stone. *Mayo Clin Proc* 2006; **81**: 335 [PMID: 16529137 DOI: 10.4065/81.3.335]
  - 5 **Lee HU**, Youn HJ, Shim BJ, Lee SJ, Park MY, Jeong JU, Gu GM, Jeon HK, Lee JE, Kwon BJ. Porcelain heart: rapid progression of cardiac calcification in a patient with hemodialysis. *J Cardiovasc Ultrasound* 2012; **20**: 193-196 [PMID: 23346289 DOI: 10.4250/jcu.2012.20.4.193]
  - 6 **Leacock K**, Duerinckx AJ, Davis B. Porcelain atrium: a case report with literature review. *Case Rep Radiol* 2011; **2011**: 501396 [PMID: 22606546 DOI: 10.1155/2011/501396]
  - 7 **Del Campo C**, Weinstein P, Kunnelis C, DiStefano P, Ebers GM. Coconut atrium: transmural calcification of the entire left atrium. *Tex Heart Inst J* 2000; **27**: 49-51 [PMID: 10830629]
  - 8 **Edwards JM**, Chisholm RJ. Porcelain atrium: rheumatic heart disease. *Can J Cardiol* 2006; **22**: 267 [PMID: 16520861]
  - 9 **Ivancic BT**, Qiao JH, Machleder D, Liao F, Drake TA, Lusis AJ. A locus on chromosome 7 determines myocardial cell necrosis and calcification (dystrophic cardiac calcinosis) in mice. *Proc Natl Acad Sci USA* 1996; **93**: 5483-5488 [PMID: 8643601]
  - 10 **Meng H**, Vera I, Che N, Wang X, Wang SS, Ingram-Drake L, Schadt EE, Drake TA, Lusis AJ. Identification of Abcc6 as the major causal gene for dystrophic cardiac calcification in mice through integrative genomics. *Proc Natl Acad Sci USA* 2007; **104**: 4530-4535 [PMID: 17360558]
  - 11 **Aherrahrou Z**, Doehring LC, Ehlers EM, Liptau H, Depping R, Linsel-Nitschke P, Kaczmarek PM, Erdmann J, Schunkert H. An alternative splice variant in Abcc6, the gene causing dystrophic calcification, leads to protein deficiency in C3H/He mice. *J Biol Chem* 2008; **283**: 7608-7615 [PMID: 18201967]
  - 12 **Luo XH**, Zhao LL, Yuan LQ, Wang M, Xie H, Liao EY. Development of arterial calcification in adiponectin-deficient mice: adiponectin regulates arterial calcification. *J Bone Miner Res* 2009; **24**: 1461-1468 [PMID: 19257834]
  - 13 **Wassel CL**, Pankow JS, Rasmussen-Torvik LJ, Li N, Taylor KD, Guo X, Goodarzi MO, Palmas WR, Post WS. Associations of SNPs in ADIPOQ and subclinical cardiovascular disease in the multi-ethnic study of atherosclerosis (MESA). *Obesity* (Silver Spring) 2011; **19**: 840-847 [PMID: 20930713]
  - 14 **Lehtinen AB**, Burdon KP, Lewis JP, Langefeld CD, Ziegler JT, Rich SS, Register TC, Carr JJ, Freedman BI, Bowden DW. Association of alpha2-Heremans-Schmid glycoprotein polymorphisms with subclinical atherosclerosis. *J Clin Endocrinol Metab* 2007; **92**: 345-352 [PMID: 17062776]
  - 15 **Jahnen-Dechent W**, Schinke T, Trindl A, Müller-Esterl W, Sablitzky F, Kaiser S, Blessing M. Cloning and targeted deletion of the mouse fetuin gene. *J Biol Chem* 1997; **272**: 31496-31503 [PMID: 9395485]
  - 16 **Rutsch F**, Ruf N, Vaingankar S, Toliat MR, Suk A, Höhne W, Schauer G, Lehmann M, Roscioli T, Schnabel D, Epplen JT, Knisely A, Superti-Furga A, McGill J, Filippone M, Sinaiko AR, Vallance H, Hinrichs B, Smith W, Ferre M, Terkeltaub R, Nürnberg P. Mutations in ENPP1 are associated with 'idiopathic' infantile arterial calcification. *Nat Genet* 2003; **34**: 379-381 [PMID: 12881724]
  - 17 **Hosoda Y**, Yoshimura Y, Higaki S. A new breed of mouse showing multiple osteochondral lesions--twy mouse. *Ryumachi* 1981; **21** Suppl: 157-164 [PMID: 7344126]
  - 18 **Lorenz-Depiereux B**, Schnabel D, Tiosano D, Häusler G, Strom TM. Loss-of-function ENPP1 mutations cause both generalized arterial calcification of infancy and autosomal-recessive hypophosphatemic rickets. *Am J Hum Genet* 2010; **86**: 267-272 [PMID: 20137773]
  - 19 **Lee JE**, Choi YK, Seo HA, Jeon JH, Jeong JY, Moon SS, Kim JG, Kim BW, Kim SW, Min Yoo JY, Lee IK. Impact of ENPP1 and MMP3 gene polymorphisms on aortic calcification in patients with type 2 diabetes in a Korean population. *Diabetes Res Clin Pract* 2010; **88**: 87-96 [PMID: 20092902]
  - 20 **Gedgudas E**, Kieffer SA, Erickson C. Left atrial calcification. *Am J Roentgenol Radium Ther Nucl Med* 1968; **102**: 293-296 [PMID: 5635682 DOI: 10.2214/ajr.102.2.293]
  - 21 **Bucay N**, Sarosi I, Dunstan CR, Morony S, Tarpley J, Caparelli C, Scully S, Tan HL, Xu W, Lacey DL, Boyle WJ, Simonet WS. osteoprotegerin-deficient mice develop early onset osteoporosis and arterial calcification. *Genes Dev* 1998; **12**: 1260-1268 [PMID: 9573043]
  - 22 **Mizuno A**, Amizuka N, Irie K, Murakami A, Fujise N, Kanno T, Sato Y, Nakagawa N, Yasuda H, Mochizuki S, Gomi-buchi T, Yano K, Shima N, Washida N, Tsuda E, Morinaga T, Higashio K, Ozawa H. Severe osteoporosis in mice lacking osteoclastogenesis inhibitory factor/osteoprotegerin. *Biochem Biophys Res Commun* 1998; **247**: 610-615 [PMID: 9647741]
  - 23 **Orita Y**, Yamamoto H, Kohno N, Sugihara M, Honda H, Kawamata S, Mito S, Soe NN, Yoshizumi M. Role of osteoprotegerin in arterial calcification: development of new animal model. *Arterioscler Thromb Vasc Biol* 2007; **27**: 2058-2064 [PMID: 17615383]
  - 24 **Soufi M**, Schoppet M, Sattler AM, Herzum M, Maisch B, Hofbauer LC, Schaefer JR. Osteoprotegerin gene polymorphisms in men with coronary artery disease. *J Clin Endocrinol Metab* 2004; **89**: 3764-3768 [PMID: 15292302]
  - 25 **Lee WJ**, Son CW, Yoon JC, Jo HS, Son JW, Park KH, Lee SH, Shin DG, Hong GR, Park JS, Kim YJ. Massive left atrial calcification associated with mitral valve replacement. *J Cardiovasc Ultrasound* 2010; **18**: 151-153 [PMID: 21253366 DOI: 10.4250/jcu.2010.18.4.151]
  - 26 **Shaw DR**, Chen JT, Lester RG. X-ray appearance and clinical significance of left atrial wall calcification. *Invest Radiol* 1976; **11**: 501-507 [PMID: 1002404 DOI: 10.1097/00004424-197611000-00001]
  - 27 **Seltzer RA**, Harthorne JW, Austen WG. The appearance and significance of left atrial calcification. *Am J Roentgenol Radium Ther Nucl Med* 1967; **100**: 307-311 [PMID: 6025199 DOI: 10.2214/ajr.100.2.307]
  - 28 **Montes L**, Rodriguez JE, Carnero M. Giant right atrial dilation and left atrial calcification. *Ann Thorac Surg* 2011; **91**: e80 [PMID: 21524439 DOI: 10.1016/j.athoracsur.2011.02.085]
  - 29 **Vallejo JL**, Merino C, González-Santos JM, Bastida E, Albertos J, Riesgo MJ, González de Diego F. Massive calcification of the left atrium: surgical implications. *Ann Thorac Surg* 1995; **60**: 1226-1229 [PMID: 8526604]
  - 30 **Harthorne JW**, Seltzer RA, Austen WG. Left atrial calcification. Review of literature and proposed management. *Circulation* 1966; **34**: 198-210 [PMID: 5969353 DOI: 10.1161/01.CIR.34.2.198]

**P- Reviewers:** Letsas K, Martí-Carvajal A, Sakabe K, Trohman R  
**S- Editor:** Ma YJ **L- Editor:** A **E- Editor:** Liu SQ



## Primary colonic lymphoma: An incidental finding in a patient with a gallstone attack

Silvia Gigli, Valeria Buonocore, Flavio Barchetti, Marianna Glorioso, Martina Di Brino, Pietro Guerrisi, Chiara Buonocore, Francesco Giovagnorio, Guglielmo Giraldi

Silvia Gigli, Valeria Buonocore, Flavio Barchetti, Marianna Glorioso, Martina Di Brino, Pietro Guerrisi, Francesco Giovagnorio, Department of Radiological Sciences, "Sapienza" University of Rome, Umberto I Hospital, 00161 Rome, Italy  
Chiara Buonocore, Department of Nursing Science, "Sapienza" University of Rome, 00185 Rome, Italy

Guglielmo Giraldi, Department of Public Health and Infectious Diseases, Sanarelli Building, "Sapienza" University of Rome, 00185 Rome, Italy

**Author contributions:** Gigli S and Buonocore V designed and wrote the manuscript; Barchetti F collected the patient's clinical data and selected the case; Glorioso M and Di Brino M selected images and assisted the composition of the manuscript; Guerrisi P and Buonocore C examined the patient; Giovagnorio F performed CT and US exams; Giraldi G supervised all phases of the drafting of this manuscript.

**Correspondence to:** Guglielmo Giraldi, MD, Department of Public Health and Infectious Diseases, Sanarelli Building, "Sapienza" University of Rome, P.le Aldo Moro 5, 00185 Rome, Italy. [guglielmo.giraldi@uniroma1.it](mailto:guglielmo.giraldi@uniroma1.it)

Telephone: +39-06-49914489 Fax: +39-06-4454845

Received: December 5, 2013 Revised: March 18, 2014

Accepted: April 11, 2014

Published online: May 16, 2014

dence of the palpable mass, an extended concentric thickening of the colic wall. CT scan was performed and confirmed a widespread and concentric thickening of the wall of the ascending colon and cecum. In addition, revealed signs of microperforation of the colic wall. Numerous large lymphadenopathies were found in the abdominal, pelvic and thoracic cavity and there was a condition of splenomegaly, with some ischemic outcomes in the context of the spleen. No metastasis in the parenchymatous organs were found. These imaging findings suggest us the diagnosis of lymphoma. Patient underwent to surgery, and right hemicolectomy and cholecystectomy was performed. Histological examination confirmed our diagnosis, revealing a diffuse large B-cell lymphoma. The patient underwent to Cyclophosphamide, Hydroxydaunorubicin, Oncovin, Prednisone chemotherapy showing only a partial regression of the lymphadenopathies, being in advanced stage at the time of diagnosis.

© 2014 Baishideng Publishing Group Inc. All rights reserved.

**Key words:** Primary colonic lymphoma; Gastrointestinal lymphoma; Diffuse large B-cell lymphoma; Gallstone attack; Computed tomography

### Abstract

We report a case of primary colonic lymphoma incidentally diagnosed in a patient presenting a gallbladder attack making particular attention on the diagnostic findings at ultrasound (US) and total body computed tomography (CT) exams that allowed us to make the correct final diagnosis. A 85-year-old Caucasian male patient was referred to our department due to acute pain at the upper right quadrant, spreaded to the right shoulder blade. Patient had nausea and mild fever and Murphy's maneuver was positive. At physical examination a large bulky mass was found in the right flank. Patient underwent to US exam that detected a big stone in the lumen of the gallbladder and in correspon-

**Core tip:** The authors report their experience with a largely primary colonic lymphoma (PCL) incidentally detected in a patient presenting a gallbladder attack. PCL is a rare disease (less than 1% of all colorectal malignancies). Symptoms are unspecific and it is usually quite advanced by the time diagnosis is made. In this case, patient showed symptoms of gallbladder disease and presented a large bulky mass at physical exam. The authors pay particular attention in describing clinic and diagnostic findings which suggested the correct final diagnosis of PCL. The role of ultrasound and computed tomography exams with the respective radiological features are described.



Gigli S, Buonocore V, Barchetti F, Glorioso M, Di Brino M, Guerrisi P, Buonocore C, Giovagnorio F, Giraldi G. Primary colonic lymphoma: An incidental finding in a patient with a gallstone attack. *World J Clin Cases* 2014; 2(5): 146-150 Available from: URL: <http://www.wjgnet.com/2307-8960/full/v2/i5/146.htm> DOI: <http://dx.doi.org/10.12998/wjcc.v2.i5.146>

## INTRODUCTION

Lymphomas are haematological malignancies which could have extranodal manifestations in approximately 40% of cases. The gastro-intestinal tract is the most common extranodal localization of non-Hodgkin lymphomas (NHLs) with a rare involvement of large bowel. The diagnostic criteria were firstly described by Barbaryan *et al*<sup>[1]</sup> in 1961.

Overall, primary colonic lymphoma (PCL) accounts for 1.4% of all cases of NHLs and represents only the 0.2%-0.6% of all large-bowel malignancies<sup>[2]</sup>. The most common histological types, in according with the Ann-Arbor classification, were: diffuse large B-cell lymphomas with frequency rate ranging from 47% to 81%, Mantle-cell lymphomas and Burkitt's lymphomas<sup>[3-5]</sup>. We report a case of PCL in a patient presenting with a gallbladder attack.

## CASE REPORT

A 85-year-old Caucasian male patient came to our Department of Radiological Sciences complaining of acute pain at the right flank, spreading to the back right shoulder blade area. The patient had nausea and mild fever. The pain arose during the night. At physical examination, the patient appeared pale. Murphy's maneuver was positive. Patient referred at least other two similar attacks of pain during the past 3 years.

Abdominal palpation revealed a voluminous bulky mass with a maximum diameter of about 8 cm in the right flank, fixed in the deep layers. Moreover, the patient referred weight loss in the last six months, persistent low-grade fever in the evening and loss of appetite.

The blood investigations revealed microcytic anemia (HB 8.8 mg/dL), slight increase of gamma-glutamyl transpeptidase and alkaline phosphatase (187 U/L). It was also observed an increase of erythrocyte sedimentation rate (30 mm/s) and of the C-reactive protein (128 mg/L). No further significant changes were found in the laboratory exams.

Therefore, it was performed an ultrasound (US) examination that detected a stone containing slightly thick walled gallbladder (maximum diameter of about 1.5 cm). Intra and extra-hepatic bile ducts were not dilated. The liver presented regular shape, normal size and no solid pathologic lesions were found. In the upper right quadrant, in correspondence of the palpable mass, there was a concentric thickening of the wall of the ascending colon, which assumed the appearance of a solid mass of 10 mm

in maximum diameter (Figure 1).

We decided to perform a total body computed tomography (CT) scan which confirmed, close to the hepatic flexure, a widespread and concentric thickening of the wall of the ascending colon (maximum thickness 40 mm) extended in cranio-caudal direction for 10 cm.

In the submucosa, there were signs of microperforation with millimetric air bubbles in the context of the colic wall. The perivisceral and omental fatty tissue was inhomogeneous.

On the medial side of the lesion there was a great necrotic enlarged lymph node (dimensions: 45 mm of longitudinal diameter and 66 mm of transverse diameter).

Numerous lymphadenopathies were found in the abdominal and pelvic cavity, the most numerous of them lying in the inter-aorto-caval space and along the course of the splenic vein and the iliac vessels bilaterally. In addition, the spleen was enlarged (longitudinal diameter of 18 cm) with some parenchymal hypodense areas in the context that could be indicative of ischemic outcomes (Figures 2 and 3).

Not further significant alterations were found in the liver and in the other parenchymatous organs.

Some lymphadenopathies were found also in the thoracic cavity, located in the pretracheal and para-esophageal space (maximum diameter 14 mm).

In the cardio-phrenic space, bilaterally, there were other small pathologic lymph nodes.

Considering the morphology of the colonic thickening, which seemed to be expansive rather than infiltrative, the presence of multiple lymphadenopathies, the condition of splenomegaly and the absence of involvement of the liver and peritoneum, the diagnosis of lymphoma was suspected.

The patient was sent to surgery and a right hemicolectomy associated with loco-regional lymphadenectomy and cholecystectomy was performed.

Histological examination of the surgical specimen revealed a diffuse large B-cell lymphoma, CD19, CD20, CD22, CD79A, and BCL6 positive.

The patient underwent six cycles of chemotherapy [Cyclophosphamide, Hydroxydaunorubicin, Oncovin, Prednisone (CHOP) regimen] and showed only a partial regression of the lymphadenopathies.

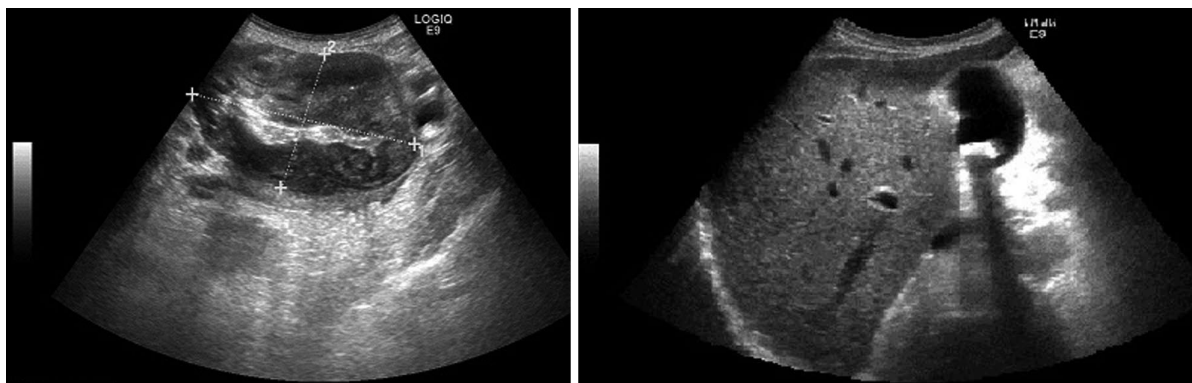
## DISCUSSION

PCL is extremely rare, but may be increasing in frequency; it represents less than 1% of all colorectal malignancies<sup>[6,7]</sup>. There is a male predominance for these tumors, (twice as often in males compared with females) and the maximal incidence is found in the 50-65 year age group, with a mean age of 55 years<sup>[2]</sup>.

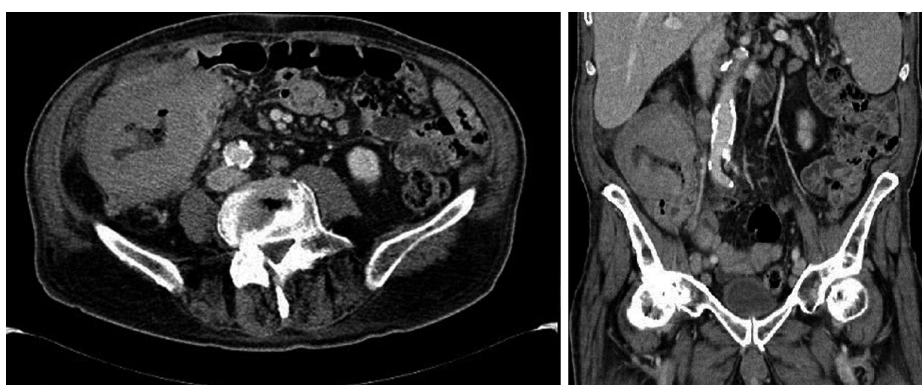There are not well-defined risk factors related with this disease and up to now the most common identified are: the immunosuppression (HIV or long-term corticosteroid therapy) and the inflammatory bowel diseases (IBD)<sup>[8]</sup>.

Therefore, PCL can be present for a long period of time without causing symptoms and the diagnosis often

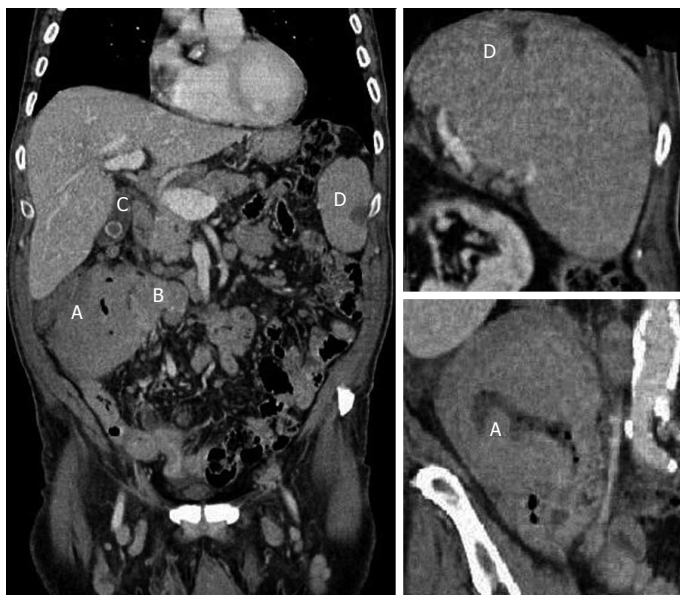



**Figure 1** Ultrasound exam findings. The images show the concentric thickening of the wall of the ascending colon, which assumed the appearance of a solid mass. In addition the big gallstone in the lumen of the gallbladder is displayed.



**Figure 2** Computed tomography exam in the axial and coronal planes. The images show the concentric thickening of the wall of the cecum and ascending colon. The millimetric air bubbles in the context of the colic wall are also depicted.



**Figure 3** Coronal computed tomography scan (portal venous phase). The images show the large colic lesion at the level of the hepatic flexure (A), the large necrotic lymphadenopathy close to the lesion (B), the stone in the lumen of the gallbladder (C) and the hypodense area in the context of the spleen indicative of the ischemic outcomes (D).

is made in an advanced stage.

The most common signs and symptoms are unspecific, such as: abdominal pain (66.8%), anorexia and weight loss (43%) and an abdominal palpable mass (41.3%). Less common presentations are: bloody stool (23%), acute abdomen, microcytic anemia and rectal bleeding<sup>[2,5]</sup>.

Our patient did not present any risk factors or spe-

cific symptoms for PCL, and diagnosis was incidental in occasion of a gallbladder attack.

Imaging methods were essential to perform a correct diagnosis, particularly US examination confirmed the presence of the large bulky mass found at physical exam and CT allowed us to suggest the diagnosis of lymphoma and to evaluate the disease extension.

Radiographic findings associated with PCL often could be nonspecific, sharing similarities with other types of colorectal disease, such as colorectal carcinoma and IBD<sup>[9]</sup>.

In our case, CT gave us a high suspicion of PCL showing regional and systemic lymph nodes involvement, spleen enlargement, and absence of metastasis. The lesion was located in the cecum-ascending colon. These locations are the most common sites for colorectal lymphoma (respectively 57% and 18% of cases) probably because more lymphoid tissue is present in this region. Other sites involved are the transverse, recto-sigmoid colon (10%) and the descending colon (5%)<sup>[10]</sup>.

The management of PCL is various, based on the extension of the disease and on clinical status of the patients at the time of diagnosis<sup>[11]</sup>. The treatment of PCL varies from chemotherapy alone to multimodal therapies combining surgery, chemotherapy, and even radiation therapy. The administration of chemotherapy and particularly the CHOP regimen remains the mainstay in the treatment management<sup>[12]</sup>.

According to many authors the surgical treatment may provide important prognostic information, including histology, tumor extent and stage<sup>[13,14]</sup>.

In the absence of disseminated disease, surgical resection is generally performed. The surgical approach may be used also as a therapy for local control in patients with aggressive lymphoma and to prevent complications like bleeding, perforation or intussusception. Diffuse large B cell lymphoma of the large bowel is generally treated with a uniform therapeutic approach: aggressive surgery followed by adjuvant chemotherapy<sup>[15]</sup>.

Our patient directly underwent to a surgical approach, in consideration of the large size of the tumoral mass and in order to avoid complications and particularly the risk of perforation, in fact the rate of spontaneous perforation in patients with PCL is 5%-11.5% suggested by the presence of air bubbles. In addition, since the patient had recurrent attack of pain due to the gallstones, cholecystectomy was performed.

After surgery which confirmed the suspected diagnosis of lymphoma, he underwent CHOP scheme chemotherapy with a partial remission of disease. This outcome can be explained by the fact that, although resection plays an important role in the local control of the disease and in preventing bleeding and/or perforation, it rarely eradicates the lymphoma by itself.

Prognosis of PCL depends on numerous factors but the stage at diagnosis and the histological grade are the most important elements affecting survival rate<sup>[16]</sup>. Our patient showed advanced disease, in fact warning signs of lymphoma are so subtle that it may take some time before realizing that there is a serious problem. The age of the patient could have influenced the promptness of diagnosis, in fact ancient patients may underestimate symptoms for a long time<sup>[3,17]</sup>.

The median survival in cases of advanced disease is generally low, ranging from 24 to 36 mo. Unfortunately, relapses are frequent (rates range from 33% to 75%), and

most of them occur within the first 5 years after resection with diffuse disease<sup>[18,19]</sup>.

In conclusion PCL is a rare disease. Often it is diagnosed in advanced state. Diagnostic imaging modalities, and particularly CT, have a fundamental role in the diagnosis of lymphomas. If CT reveals an infiltrative tumor with enlarged lymph nodes in the abdomen or pelvis, lymphoma should be highly taken into account in the differential diagnosis. The prediction of prognosis and the planning of a suitable therapeutic approach is essential for the patients and CT allows an accurate staging of the disease<sup>[20]</sup>.

## COMMENTS

### Case characteristics

A 85-year-old male with acute pain at the right flank, presented a gallstone attack and a large bulky mass in the abdomen.

### Clinical diagnosis

Positivity to Murphy's maneuver, low-grade fever, weight loss and a palpable voluminous bulky mass in the right flank.

### Differential diagnosis

Colorectal carcinoma, Inflammatory bowel diseases.

### Laboratory diagnosis

HB 8.8 mg/dL, alkaline phosphatase 187 U/L, erythrocyte sedimentation rate 30 mm/s and C-reactive protein 128 mg/L.

### Imaging diagnosis

Ultrasound (US) examination detected a stone in the lumen of the gallbladder and a concentric thickening of the wall of the ascending colon; computed tomography (CT) confirmed the thickening of the wall of the cecum-ascending colon and revealed also signs of microperforation in the submucosa, numerous lymphadenopathies and a condition of splenomegaly.

### Pathological diagnosis

The histological examination of the surgical specimen revealed a diffuse large B cell lymphoma CD19, CD20, CD22, CD79A, and BCL6 positive.

### Treatment

The patient underwent to surgery (right hemicolectomy, loco-regional lymphadenectomy and cholecystectomy); in addition, underwent to six cycles of chemotherapy [Cyclophosphamide, Hydroxydaunorubicin, Oncovin, Prednisone (CHOP) regimen].

### Related reports

The latest studies confirmed that primary colonic lymphoma (PCL) is a very rare disease and that diagnosis is often incidental; in the authors' case report, diagnosis was made in advanced stage and we chose for a surgical approach before chemotherapy, according to some authors, for locoregional control of disease and to prevent complications.

### Term explanation

CHOP is the acronym of a chemotherapy scheme used in the treatment of non-Hodgkin lymphomas consisting of an alkylating agent (Cyclophosphamide), an intercalating agent (Hydroxydaunorubicin), a mitotic inhibitor (Oncovin) and a corticosteroid (Prednisone).

### Experiences and lessons

This case report describes the diagnostic features of PCL and the radiological findings of this rare colonic disease, that should be considered in order to make a correct differential diagnosis, particularly stressing the role of US and CT.

### Peer review

The strength of this article is that it well describes the radiological features of PCL and the case is really remarkable. The histological and immunochemical profile has been included.

## REFERENCES

1. Barbaryan A, Ali AM, Kwatra SG, Saba R, Prueksaritanond S, Hussain N, Mirrahimov AE, Vladimirovskiy N, Zdunek T,

- Gilman AD. Primary diffuse large B-cell lymphoma of the ascending colon. *Rare Tumors* 2013; **5**: 85-88 [PMID: 23888223 DOI: 10.4081/rt.2013.e23]
- 2 **Chang SC.** Clinical features and management of primary colonic lymphoma. *Formosan J Surg* 2012; **45**: 73-77 [DOI: 10.1016/j.fjs.2012.05.003]
- 3 **Dionigi G,** Annoni M, Rovera F, Boni L, Villa F, Castano P, Bianchi V, Dionigi R. Primary colorectal lymphomas: review of the literature. *Surg Oncol* 2007; **16** Suppl 1: S169-S171 [PMID: 18024019 DOI: 10.1016/j.suronc.2007.10.021]
- 4 **Bairey O,** Ruchlemer R, Shpilberg O. Non-Hodgkin's lymphomas of the colon. *Isr Med Assoc J* 2006; **8**: 832-835 [PMID: 17214096]
- 5 **Wong MT,** Eu KW. Primary colorectal lymphomas. *Colorectal Dis* 2006; **8**: 586-591 [PMID: 16919111]
- 6 **Wyatt SH,** Fishman EK, Hruban RH, Siegelman SS. CT of primary colonic lymphoma. *Clin Imaging* 1994; **18**: 131-141 [PMID: 8033006]
- 7 **She WH,** Day W, Lau PY, Mak KL, Yip AW. Primary colorectal lymphoma: case series and literature review. *Asian J Surg* 2011; **34**: 111-114 [PMID: 22208685 DOI: 10.1016/j.asjsur.2011.08.004]
- 8 **Stanojevic GZ,** Nestorovic MD, Brankovic BR, Stojanovic MP, Jovanovic MM, Radojkovic MD. Primary colorectal lymphoma: An overview. *World J Gastrointest Oncol* 2011; **3**: 14-18 [PMID: 21267399 DOI: 10.4251/wjgo.v3.i1.14]
- 9 **Ghai S,** Pattison J, Ghai S, O'Malley ME, Khalili K, Stephens M. Primary gastrointestinal lymphoma: spectrum of imaging findings with pathologic correlation. *Radiographics* 2007; **27**: 1371-1388 [PMID: 17848697 DOI: 10.1148/rg.275065151]
- 10 **Smith C,** Kubicka RA, Thomas CR. Non-Hodgkin lymphoma of the gastrointestinal tract. *Radiographics* 1992; **12**: 887-899 [PMID: 1529131]
- 11 **Beaton C,** Davies M, Beynon J. The management of primary small bowel and colon lymphoma--a review. *Int J Colorectal Dis* 2012; **27**: 555-563 [PMID: 21912877 DOI: 10.1007/s00384-011-1309-2]
- 12 **Hay AE,** Meyer RM. Balancing risks and benefits of therapy for patients with favorable-risk limited-stage Hodgkin lymphoma: the role of doxorubicin, bleomycin, vinblastine, and dacarbazine chemotherapy alone. *Hematol Oncol Clin North Am* 2014; **28**: 49-63 [PMID: 24287067 DOI: 10.1016/j.hoc.2013.10.001]
- 13 **Biondi A,** Motta S, Di Giunta M, Crisafi RM, Zappalà S, Rapisarda D, Basile F. [The use of laparoscopy for diagnosis and stadiation of the lymphomas]. *Ann Ital Chir* 2009; **80**: 445-447 [PMID: 20476676]
- 14 **Nakamura S,** Matsumoto T. Gastrointestinal lymphoma: recent advances in diagnosis and treatment. *Digestion* 2013; **87**: 182-188 [PMID: 23635497 DOI: 10.1159/00035005]
- 15 **Lai YL,** Lin JK, Liang WY, Huang YC, Chang SC. Surgical resection combined with chemotherapy can help achieve better outcomes in patients with primary colonic lymphoma. *J Surg Oncol* 2011; **104**: 265-268 [PMID: 21472731 DOI: 10.1002/jso.21927]
- 16 **Radić-Kristo D,** Planinc-Peraica A, Ostojić S, Vrhovac R, Kardum-Skelin I, Jakić B. Primary gastrointestinal non-Hodgkin lymphoma in adults: clinicopathologic and survival characteristics. *Coll Antropol* 2010; **34**: 413-417 [PMID: 20698111]
- 17 **De Luca d'Alessandro E,** Bonacci S, Giraldi G. Aging populations: the health and quality of life of the elderly. *Clin Ter* 2011; **162**: e13-e18 [PMID: 21448536]
- 18 **Stanojević GZ,** Stojanović MP, Stojanović MM, Krivokapić Z, Jovanović MM, Katić VV, Jeremić MM, Branković BR. Non-Hodgkin's lymphomas of the large bowel-clinical characteristics, prognostic factors and survival. *Acta Chir Iugosl* 2008; **55**: 109-114 [PMID: 19069702]
- 19 **Lee J,** Kim WS, Kim K, Ko YH, Kim JJ, Kim YH, Chun HK, Lee WY, Park JO, Jung CW, Im YH, Lee MH, Kang WK, Park K. Intestinal lymphoma: exploration of the prognostic factors and the optimal treatment. *Leuk Lymphoma* 2004; **45**: 339-344 [PMID: 15101721]
- 20 **Fishman EK,** Kuhlman JE, Jones RJ. CT of lymphoma: spectrum of disease. *Radiographics* 1991; **11**: 647-669 [PMID: 1887120]

**P- Reviewers:** Boffano P, Movahed A, Panciani PP  
**S- Editor:** Wen LL **L- Editor:** A **E- Editor:** Liu SQ



## Parathyroid carcinoma in pregnancy

Maja Baretić, Hrvojka Tomić Brzac, Margareta Dobrenić, Antonia Jakovčević

Maja Baretić, Division of Endocrinology, Department of Internal Medicine, University Hospital Centre Zagreb, 10000 Zagreb, Croatia

Hrvojka Tomić Brzac, Margareta Dobrenić, Clinical Department of Nuclear Medicine and Radiation Protection, University Hospital Centre Zagreb, 10000 Zagreb, Croatia

Antonia Jakovčević, Department of Pathology and Cytology, University Hospital Centre Zagreb, 10000 Zagreb, Croatia

**Author contributions:** Baretić M wrote and designed the report, was responsible for the patient treatment and follow up, analyzed the data and wrote the paper; Tomić Brzac H performed and commented on the ultrasound exam; Dobrenić M performed and commented on the nuclear medicine exam; and Jakovčević A performed the pathology report analysis and made comments.

**Correspondence to:** Maja Baretić, MD, PhD, Division of Endocrinology, Department of Internal Medicine, University Hospital Centre Zagreb, Zavod za endokrinologiju Kišpatićeva 12, 10000 Zagreb, Croatia. [maja.simek@zg.t-com.hr](mailto:maja.simek@zg.t-com.hr)

Telephone: +385-98-412284 Fax: +385-1-2376036

Received: December 24, 2013 Revised: March 20, 2014

Accepted: April 3, 2014

Published online: May 16, 2014

### Abstract

A 24-year-old female patient with parathyroid carcinoma, the rarest endocrine malignancy, had two pregnancies. In the first pregnancy, she had severe nausea and fatigue. Hypercalcemia and hyperparathyroidism were diagnosed in the postpartum period. Hyperemesis gravidarum masked a diagnosis of hypercalcemia. Neck ultrasound and Tc-99m sestamibi found an enlarged lower right parathyroid gland. The gland was surgically removed, and an initial pathology report described atypical adenoma. Shortly afterward, she became pregnant again. During the second pregnancy, her calcium level was frequently controlled but was always in the normal range. Normocalcemia is explained by the specific physiology of pregnancy accompanied by hemodilution, hypoalbuminemia and maternal hypercalciuria (mediated by increased glomerular filtration). During lactation, calcium levels rose, and a new

neck ultrasound showed a solitary mass in the area of prior surgery and an enlarged pretracheal lymph node. Fine needle aspiration of the solitary mass and node showed parathyroid carcinoma cells. The tumor mass was resected en bloc with the contiguous tissues and surrounding lymph nodes (pathology report; parathyroid carcinoma with metastases). Over the next five years, four consecutive surgeries were performed to remove malignant parathyroid tissue, lymph nodes and local metastases. Following the surgical procedures, no hypocalcemia was observed. More serious hypercalcemia recurred; the calcium level was difficult to control with a combination of pamidronate, cinacalcet and loop diuretic. No elements of multiple endocrine neoplasia were present.

© 2014 Baishideng Publishing Group Inc. All rights reserved.

**Key words:** Parathyroid carcinoma; Hypercalcemia; Hyperparathyroidism; Pregnancy; Hyperemesis gravidarum

**Core tip:** Parathyroid carcinoma is the rarest endocrine malignancy; it is extremely uncommon in pregnancy. Hyperemesis gravidarum can mask the symptoms of hypercalcemia. The calcium level can be lower during pregnancy due to its specific physiology. This is a case report of a 24-year-old female patient with parathyroid carcinoma and two consecutive pregnancies with good outcomes in the postnatal period despite poor prognosis due to malignant disease. In five years, four consecutive surgeries were performed to remove malignant parathyroid tissue, lymph nodes and local metastases. Hypercalcemia was difficult to control with a combination of pamidronate, cinacalcet and loop diuretic. There were no elements of multiple endocrine neoplasia.

Baretić M, Tomić Brzac H, Dobrenić M, Jakovčević A. Parathyroid carcinoma in pregnancy. *World J Clin Cases* 2014; 2(5): 151-156 Available from: URL: <http://www.wjgnet.com/2307-8960/full/v2/i5/151.htm> DOI: <http://dx.doi.org/10.12998/wjcc.v2.i5.151>



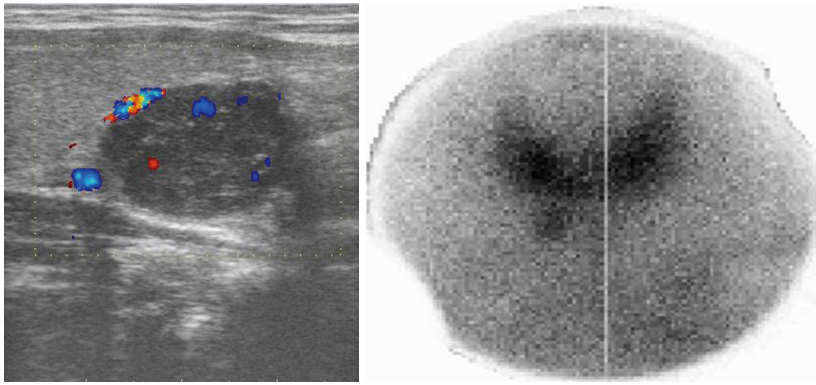
## INTRODUCTION

Parathyroid carcinoma is a rare malignant disease in the general population. The United States National Cancer Database Report indicates that in the time period from 1985 to 1995, only 1% of patients with primary hyperparathyroidism had parathyroid cancers<sup>[1]</sup>. Some European countries, such as Italy, reported even higher prevalence (up to 5%)<sup>[2]</sup>. The etiology of parathyroid cancer remains unidentified; some authors mention neck irradiation as a risk factor, while others suggest long-standing secondary hyperparathyroidism<sup>[3,4]</sup>. Familial occurrences, such as hyperparathyroidism-jaw tumor syndrome, multiple endocrine neoplasia type 1 and 2A and familial isolated hyperparathyroidism<sup>[5]</sup>, have been linked. It has been shown that mutations in the *HRPT2* gene (a tumor suppressor gene called parafibromin) are associated with the development of parathyroid carcinoma, both in sporadic types and in cases with some familial clustering<sup>[6]</sup>. Parathyroid adenomas occur rarely in pregnancy, with the risk to both the mother and child directly connected to the level of serum calcium<sup>[7,8]</sup>. Parathyroid carcinoma is even more rare<sup>[9]</sup>. A case report of a woman with two subsequent pregnancies and parathyroid carcinoma is presented in this paper.

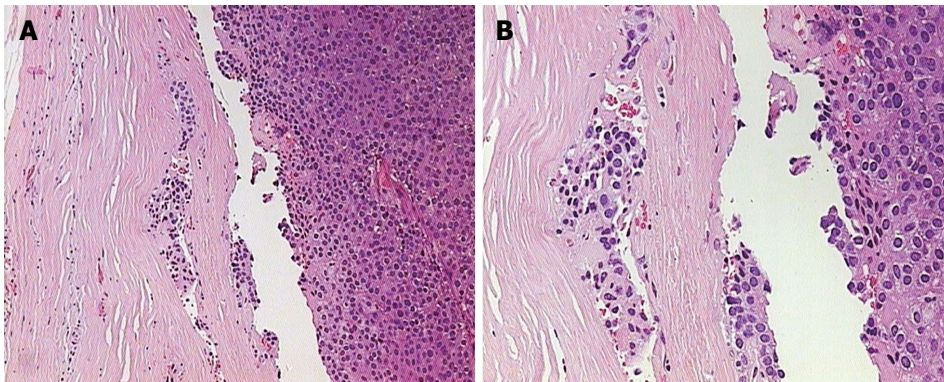
## CASE REPORT

A 24-year-old woman had severe hyperemesis gravidarum during pregnancy, with constant nausea and vomiting 3-4 times daily. Symptoms started in the 10<sup>th</sup> week and persisted until the end of pregnancy, sometimes accompanied by fatigue and weakness. Vaginal delivery was at 37 wk of pregnancy. Shortly after the birth, her infant had neonatal convulsions; laboratory tests showed severe prolonged hypocalcemia of the child, and the mother's calcium was checked. The mother's level of calcium was high, and she was referred to an endocrinologist. High parathyroid hormone (PTH) and low phosphorus pointed to hyperparathyroidism. Initial laboratory results confirmed that suspicion: calcium was 3.62 mmol/L (normal range, 2.14-2.53 mmol/L); ionized calcium, 1.87 mmol/L (normal range, 1.18-1.32); phosphorus, 0.53 mmol/L (normal range, 0.79-1.42 mmol/L); alkaline phosphatase, 187 U/L (normal range, 64-153 U/L); bone alkaline phosphatase, 133 U/L (normal range for premenopausal women, 14.2-42.7 U/L); and intact PTH, 36 pmol/L (normal range, 1-6.0 pmol/L). The patient had no previous history of familial hyperparathyroidism or other endocrine conditions, neck irradiation, chronic renal disease or kidney stones. There were no systemic manifestation of hypercalcemia, and later bone densitometry indicated osteoporosis (T score of the lumbar spine was -3.8) but without bone fractures. Neck Doppler ultrasound recognized an enlarged lower-right parathyroid gland, described as a well-defined mass hypoechoic to thyroid tissue with a homogenous echo pattern measuring 21 mm × 15 mm × 15 mm with few vascular structures (PTH in aspirate was higher than 150 pmol/L,

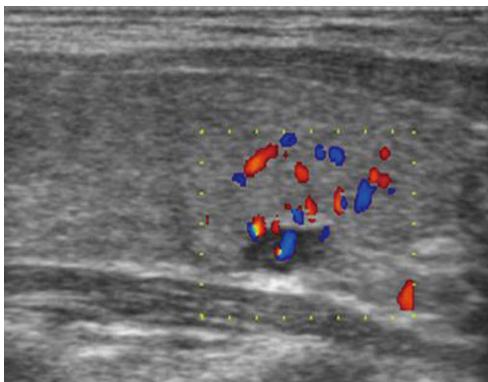
Figure 1). Tc-99m sestamibi planar scan showed an area of increased uptake on the right side of the neck, additional evidence of hyperfunctioning parathyroid tissue. A pinhole collimator was used to increase the resolution of scintigraphy. Fine needle aspiration showed epithelial cells with pronounced anisonucleosis (variation in the size of the cell nuclei). The cytoplasmic borders were not sharply defined; the described cells had many naked nuclei. Silver reaction (Grimelius) stained weekly positive. Hypercalcemia was treated by hydration with isotonic sodium chloride solution, loop diuretics and pamidronate. Two months after delivery, the patient underwent surgical removal of the described parathyroid gland. The removed gland measured 2 cm × 3 cm, and the pathological report noted tissue made up of main and oxyphil cell types. There was no significant remodeling of the stroma cells or polymorphism; tumor cells were monotonous, small cells with focal cytological atypia. Mitotic figures were not observed (Figure 2A). The tumor was surrounded by a thick capsule, with cells infiltrating the capsule without breaking through it (Figure 2B). There was no invasion of tumor cells in blood vessels and no invasion of the surrounding fat tissue. However, malignant cells surrounded blood vessels in the tumor tissue, and the final pathological diagnosis was atypical adenoma of the parathyroid gland. The patient was repeatedly followed after surgery: she was normocalcemic and became pregnant again. The time interval between the two pregnancies was 15 mo. During the second pregnancy, calcium levels were normal, and the patient had no nausea or sickness, but in the third trimester her TSH level dropped significantly (TSH < 0.05 mIU/L, normal range 0.4-4.5 mIU/L). Free T3 and T4 remained in the normal range; thus, she was not treated with thyrostatic drugs. After the second delivery, while lactating, her calcium level rose again (3.48 mmol/L). Other lab results suggested a recurrence of hyperparathyroidism (high alkaline phosphatase 158 IU and PTH 12 pmol/L). The second baby had no convulsions or hypocalcemia after birth, unlike the first. A new neck ultrasound described a solitary mass measuring 5 mm × 3 mm × 5 mm in the area of the previous surgery (Figure 3). An enlarged lymph node was present in the pretracheal region (lower third of neck) (Figure 4A). Fine needle aspiration of the solitary mass described naked nuclei and malignant cells with pronounced macronucleosis and intranuclear inclusions, leading to a diagnosis of carcinoma of the parathyroid gland. The same cytological description was found in an aspirate of a pretracheal node, confirming metastasis of the parathyroid carcinoma. Single photon emission computed tomography (SPECT) of the neck and mediastinum showed no significant focal uptake of Tc-99m sestamibi in the region of the neck and mediastinum. Shortly after delivery, thyrostatic drugs were introduced in therapy. The patient underwent a second surgery: the tumor mass was resected en bloc, together with contiguous tissues to which the tumor adhered. Other parathyroid glands were not removed. Tracheoesophageal, paratracheal, and upper mediastinal lymph nodes were excised; due to hyperthyroidism total thyroidectomy



**Figure 1** Doppler ultrasound of parathyroid gland showing well-defined hypoechoic mass with color signals of few surrounding vascular structures and Tc-99m sestamibi planar scan with pinhole collimator, 10 min post injection.

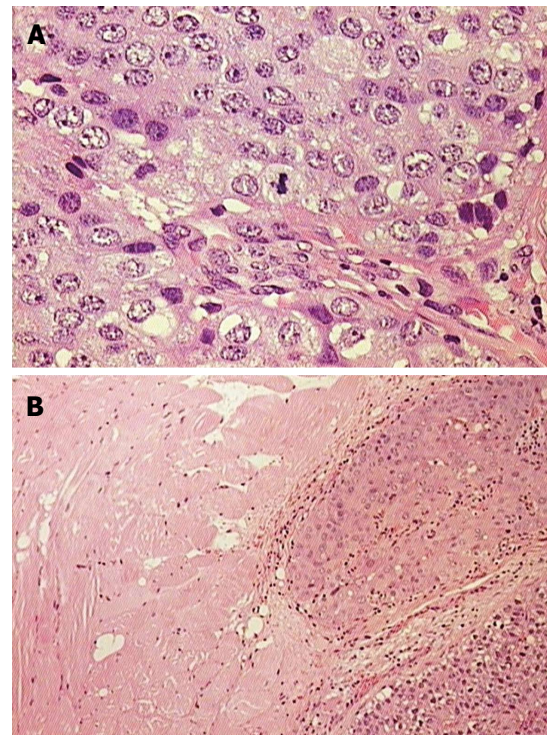


**Figure 2** Pathology image of atypical adenoma. A: No significant remodeling of stroma cells or polymorphism, tumor cells are monotonous, small cells with focal cytological atypia without mitotic figures; B: Pathology image of atypical adenoma with tumour cells infiltrating thick fibrous capsule.



**Figure 3** Doppler ultrasound of parathyroid carcinoma: small solitary mass in the area of previous surgery.

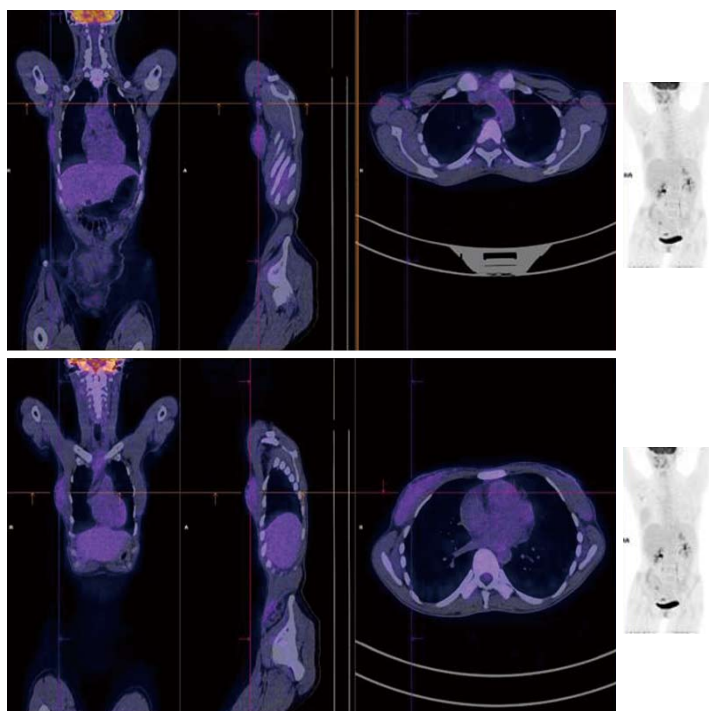
was performed as well. The pathology report described parathyroid carcinoma with mitotic figures, trabecular pattern and invasion of skeletal muscle (Figure 4). There were areas of tumor necrosis, and immunohistochemical results showed that the tissue was positive for PTH. Metastases of the parathyroid tumor were also found in the pretracheal lymph nodes. Postoperative hypocalcemia was prolonged but not severe. Patient received supplemental calcium and vitamin D, together with levothyroxine. In further evaluation, the levothyroxine dosage was modified according to the TSH level. Chromogranin A levels were normal (44 µg/L, normal levels < 100 µg/L), and there were no elements of multiple endocrine neoplasia.



**Figure 4** Pathology image of parathyroid carcinoma. A: Mitotic cells; B: Infiltrating skeletal muscle.

Gradually, the calcium level increased, and vitamin D and calcium supplementation were excluded from therapy. A





**Figure 5** Positron emission tomography/low-dose X-ray computed tomography (positron emission tomography/low-dose computed tomography) with F-18 FDG. Focal accumulation is observed in enlarged lymph nodes of the right axillary region and diffuse uptake is observed in the right breast.

year later, magnetic resonance imaging of the neck and mediastinum showed a lymph node enlarged to 12 mm, located dorsally from the right subclavia. The consulted oncologist advised that surgical treatment was an option (disease was not disseminated at that point), and a third surgery was performed, removing all tissue surrounding the malignant parathyroid gland, lymph nodes and local metastases. Following the surgery, hypercalcemia persisted. Early SPECT images performed 15 min after Tc-99m sestamibi injection showed two foci of radiopharmaceutical uptake anterior to the lower third of the neck region. Delayed tomographic images obtained 2 h after Tc-99m sestamibi injection showed no significant focal uptake of radiopharmaceutical in the neck and mediastinum region. Focal accumulation of fluorodeoxyglucose (F-18 FDG) was observed in several enlarged lymph nodes of the right axillary region, and diffuse F-18 FDG uptake was observed in the right breast (Figure 5). Additional ultrasonography and fine needle aspiration cytology of one of the enlarged axillary lymph nodes were obtained (inflammatory changes). Breast ultrasonography found no suspicious-looking lesions. During the last neck exploration (fourth surgery), the surgeon described tumor formation on the left side of the neck, with subcutaneous location and muscle infiltration. A right paratracheal tumorous mass was located behind the right carotid bifurcation. The pathology report of the tissue was identical to that described in prior surgeries. Hypercalcemia persisted and was difficult to control, even with a combination of pamidronate, cinacalcet and loop diuretic. Calcium is a tumor marker that indicates a persistence of small, disseminated, hormonally active metastases. Further F-18 FDG positron emission tomography-computed tomography (PET/CT) evaluation is planned, in addition to a test for the *HRPT2* mutation.

## DISCUSSION

Parathyroid cancer is a rare condition, and only few cases have been reported during pregnancy in the literature<sup>[9-13]</sup>. This condition is associated with significant neonatal morbidity and mortality, as well as maternal morbidity, and it is very difficult to treat<sup>[12,13]</sup>. In this case report, the described patient had two consecutive pregnancies with good outcomes both for mother and children, despite later poor prognosis for the mother due to malignant disease. Hyperemesis gravidarum, *e.g.*, nausea, fatigue and weakness, are non-specific symptoms in pregnancy, but they are also symptoms of an elevated calcium level. The first pregnancy obscured the diagnosis of hypercalcemia. During the second pregnancy, the patient was normocalcemic. This result could be explained by the specific physiology of pregnancy, including hemodilution, hypoalbuminemia and maternal hypercalciuria, caused by an increase of the glomerular filtration rate. Sickness and vomiting in pregnancy usually start before the 9<sup>th</sup> week and, in most cases, resolve by 16 wk of pregnancy. Otherwise, hypercalcemia is one possible cause. Nausea and vomiting are not the only clinical manifestation described in similar cases. Some of those patients have had hypertension, abdominal pain, pancreatitis and pre-eclampsia. For all of these patients, parathyroid carcinoma was diagnosed during pregnancy, and most of them underwent surgery in the third trimester<sup>[9-13]</sup>.

Tc-99m sestamibi scintigraphy has been used for the detection of hyperfunctioning parathyroid tissue, including parathyroid carcinoma<sup>[14]</sup>. Tc-99m sestamibi uptake correlates with parathyroid oxyphil cell content and the size of hyperfunctioning parathyroid tissue. False-negative sestamibi scans can occur with parathyroid glands that contain predominantly clear cells, small size of the

hyperfunctioning parathyroid tissue and rapid wash-out of the radiopharmaceutical from parathyroid cells<sup>[15]</sup>. A finding of focal accumulation of Tc-99m sestamibi in the lower third of the neck on early images and no significant uptake of radiopharmaceutical on delayed images is most likely due to rapid wash-out of Tc-99m sestamibi from the tumor cells.

Following the first surgery, the next scan was negative. F-18 FDG PET/CT is recognized as a powerful tool to detect tumors, especially malignant ones, due to the increased glucose metabolism of tumor cells<sup>[16]</sup>. FDG PET/CT is used in parathyroid carcinoma to detect recurrent disease. A negative finding on FDG PET/CT is most likely due to small tumor size.

There are no official guidelines for the treatment of hyperparathyroidism in pregnancy; even less is known about how to treat parathyroid carcinoma. The options are a conservative approach or surgery. Both approaches carry the risk of drug and procedure side effects, though the risk imposed by the elevated calcium level is sometimes greater. If surgery is an option, it should be performed in the third trimester of pregnancy. A literature analysis described 16 cases of primary hyperparathyroidism treated surgically after 27 wk of gestation, and carcinoma was found in a high percentage: 12.5% of cases. These patients had a low postoperative incidence of clinically significant complications for both the fetus and the mother<sup>[17]</sup>. When overt hyperparathyroidism is diagnosed in the postpartum period, surgery is the first choice of treatment. If parathyroid cancer is suspected (on the basis of the clinical picture and cytology, even before confirmation by pathology report), complete surgical resection with negative margins and removal of surrounding lymph nodes is the recommended course of action. In this case, the first pathological report was atypical adenoma. Atypical parathyroid adenomas have some histological findings that are suggestive of cancer but not enough to make the diagnosis. Atypical adenomas have a thick capsule, fibrous trabeculae, and a trabecular growth pattern with nuclear pleomorphism; they have no local or vascular invasion and no lymph node or distant metastasis<sup>[18]</sup>.

This case suggests that any unusual parathyroid histology should be reviewed, and re-resection should be performed if there is suspicion of carcinoma. In such cases, pregnancy should not be a reason for withholding aggressive surgery, especially in very young patients.

## COMMENTS

### Case characteristics

A 24-year-old female patient with parathyroid carcinoma and two consecutive pregnancies.

### Clinical diagnosis

Hypercalcemia, hyperparathyroidism.

### Differential diagnosis

Adenoma of the parathyroid gland.

### Laboratory diagnosis

Calcium, 3.62 mmol/L (normal range, 2.14-2.53 mmol/L); ionized calcium, 1.87 mmol/L (normal range, 1.18-1.32); phosphorus, 0.53 mmol/L (normal range, 0.79-1.42 mmol/L); alkaline phosphatase, 187 U/L (normal range, 64-153 U/L);

bone alkaline phosphatase, 133 U/L (normal range for premenopausal women, 14.2-42.7 U/L); intact parathyroid hormone (PTH), 36 pmol/L (normal range, 1-6.0 pmol/L). PTH in aspirate of right lower parathyroid gland higher than 150 pmol/L.

### Imaging diagnosis

Neck ultrasound; enlarged right lower parathyroid gland (well-defined mass hypoechoic to thyroid tissue with a homogenous echo pattern measuring 21 mm × 15 mm × 15 mm. Tc-99m sestamibi scan; an area of increased uptake on the right side of neck.

### Pathological diagnosis

Initial pathological diagnosis atypical adenoma of parathyroid gland; tissue made up of main and oxyphil cell-type, no significant remodeling of stroma cells or polymorphism, tumor cells monotonous, small cells with focal cytological atypia, mitotic figures not observed. Tumor is surrounded by thick capsule; cells infiltrate capsule, not breaking through. There is no invasion of tumor cells in blood vessels and no invasion of surrounding fat tissue. Next pathology report described a parathyroid carcinoma with mitotic figures, trabecular pattern and invasion of skeletal muscle.

### Treatment

In five years, four consecutive surgeries were performed to remove tissue surrounding the malignant parathyroid gland, lymph nodes and local metastases. Hypercalcemia was difficult to control with a combination of pamidronate, cinacalcet and loop diuretic.

### Term explanation

HRPT2 gene or parafibromin is a tumor suppressor gene associated with the development of parathyroid carcinoma in both sporadic types and some familial clustering cases.

### Experiences and lessons

This case report represents a patient with parathyroid carcinoma and two pregnancies. Pregnancy itself can obscure proper diagnosis of the disease, as the unique physiology of pregnancy can alter clinical findings. It is necessary to be aggressive during the surgical treatment of parathyroid carcinoma.

### Peer review

This is an interesting case report clarifying the clinical findings of a 24-year-old female patient with parathyroid carcinoma and two consequent pregnancies with good outcome, despite poor prognosis due to malignant disease. Generally, the manuscript was straight-forward and well-written on this topic. This article is of potential interest to the readers.

## REFERENCES

- 1 **Hundahl SA**, Fleming ID, Fremgen AM, Menck HR. Two hundred eighty-six cases of parathyroid carcinoma treated in the U.S. between 1985-1995: a National Cancer Data Base Report. The American College of Surgeons Commission on Cancer and the American Cancer Society. *Cancer* 1999; **86**: 538-544 [PMID: 10430265 DOI: 10.1002/(SICI)1097-0142(19990801)86:3<538::AID-CNCR25>3.0.CO;2-K ]
- 2 **Favia G**, Lumachi F, Polistina F, D'Amico DF. Parathyroid carcinoma: sixteen new cases and suggestions for correct management. *World J Surg* 1998; **22**: 1225-1230 [PMID: 9841748 DOI: 10.1007/s002689900549]
- 3 **Christmas TJ**, Chapple CR, Noble JG, Milroy EJ, Cowie AG. Hyperparathyroidism after neck irradiation. *Br J Surg* 1988; **75**: 873-874 [PMID: 3179662 DOI: 10.1002/bjs.1800750914]
- 4 **Boyle NH**, Ogg CS, Hartley RB, Owen WJ. Parathyroid carcinoma secondary to prolonged hyperplasia in chronic renal failure and in coeliac disease. *Eur J Surg Oncol* 1999; **25**: 100-103 [PMID: 10188867]
- 5 **Yoshimoto K**, Endo H, Tsuyuguchi M, Tanaka C, Kimura T, Iwahana H, Kato G, Sano T, Itakura M. Familial isolated primary hyperparathyroidism with parathyroid carcinomas: clinical and molecular features. *Clin Endocrinol (Oxf)* 1998; **48**: 67-72 [PMID: 9509070 DOI: 10.1046/j.1365-2265.1998.00354.x]
- 6 **Howell VM**, Haven CJ, Kahnoski K, Khoo SK, Petillo D, Chen J, Fleuren GJ, Robinson BG, Delbridge LW, Philips J, Nelson AE, Krause U, Hammje K, Dralle H, Hoang-Vu C, Gimm O, Marsh DJ, Morreau H, Teh BT. HRPT2 mutations are associated with malignancy in sporadic parathyroid tu-



- mours. *J Med Genet* 2003; **40**: 657-663 [PMID: 12960210 DOI: 10.1136/jmg.40.9.657]
  - 7 **Amaya García M**, Acosta Feria M, Soto Moreno A, Dios Fuentes E, Navarro González E, Quijada Thong D, Del Valle A, Acosta Delgado D, Astorga Jiménez R. Primary hyperparathyroidism in pregnancy. *Gynecol Endocrinol* 2004; **19**: 111-114 [PMID: 15624273 DOI: 10.1080/09513590400002334]
  - 8 **Díaz-Soto G**, Linglart A, Sénat MV, Kamenicky P, Chanson P. Primary hyperparathyroidism in pregnancy. *Endocrine* 2013; **44**: 591-597 [PMID: 23670708 DOI: 10.1007/s12020-013-9980-4]
  - 9 **Paul RG**, Elston MS, Gill AJ, Marsh D, Beer I, Wolmarans L, Conaglen JV, Meyer-Rochow GY. Hypercalcaemia due to parathyroid carcinoma presenting in the third trimester of pregnancy. *Aust N Z J Obstet Gynaecol* 2012; **52**: 204-207 [PMID: 22188427 DOI: 10.1111/j.1479-828X.2011.01391]
  - 10 **Montoro MN**, Paler RJ, Goodwin TM, Mestman JH. Parathyroid carcinoma during pregnancy. *Obstet Gynecol* 2000; **96**: 841 [PMID: 11094233 DOI: 10.1016/S0029-7844(00)00945-5]
  - 11 **Parham GP**, Orr JW. Hyperparathyroidism secondary to parathyroid carcinoma in pregnancy. A case report. *J Reprod Med* 1987; **32**: 123-125 [PMID: 3560072]
  - 12 **Hess HM**, Dickson J, Fox HE. Hyperfunctioning parathyroid carcinoma presenting as acute pancreatitis in pregnancy. *J Reprod Med* 1980; **25**: 83-87 [PMID: 7411530]
  - 13 **Panchani R**, Varma T, Goyal A, Tripathi S. Parathyroid carcinoma masquerading as morning sickness in pregnancy. *Indian J Endocrinol Metab* 2013; **17**: S198-S200 [PMID: 24251157 DOI: 10.4103/2230-8210.119570]
  - 14 **Abdelgadir Adam M**, Untch BR, Olson JA. Parathyroid carcinoma: current understanding and new insights into gene expression and intraoperative parathyroid hormone kinetics. *Oncologist* 2010; **15**: 61-72 [PMID: 20051478 DOI: 10.1634/theoncologist.2009-0185]
  - 15 **Westreich RW**, Brandwein M, Mechanick JL, Bergman DA, Urken ML. Preoperative parathyroid localization: correlating false-negative technetium 99m sestamibi scans with parathyroid disease. *Laryngoscope* 2003; **113**: 567-572 [PMID: 12616216 DOI: 10.1097/00005537-200303000-00032]
  - 16 **Evangelista L**, Sorgato N, Torresan F, Boschin IM, Pennelli G, Saladini G, Piotto A, Rubello D, Pelizzo MR. FDG-PET/CT and parathyroid carcinoma: Review of literature and illustrative case series. *World J Clin Oncol* 2011; **2**: 348-354 [PMID: 22022662 DOI: 10.5306/wjco.v2.i10.348]
  - 17 **Schnatz PF**, Thaxton S. Parathyroidectomy in the third trimester of pregnancy. *Obstet Gynecol Surv* 2005; **60**: 672-682 [PMID: 16186784 DOI: 10.1097/01.ogx.0000180889.23678.fb]
  - 18 **Fernandez-Ranvier GG**, Khanafshar E, Jensen K, Zarnegar R, Lee J, Kebebew E, Duh QY, Clark OH. Parathyroid carcinoma, atypical parathyroid adenoma, or parathyromatosis? *Cancer* 2007; **110**: 255-264 [PMID: 17559137 DOI: 10.1002/cncr.22790]
- P- Reviewers:** Kara PO, Olsha O, Wang CC, Xiao DL, Zampieri N  
**S- Editor:** Song XX **L- Editor:** A **E- Editor:** Liu SQ



## X-ray diagnosis with a bloating agent for foreign object ingestion

Hirokazu Tomishige, Zenichi Morise, Tatsuya Suzuki, Fujio Hara, Masahito Hibi, Takazumi Kato, Takashi Hashimoto

Hirokazu Tomishige, Zenichi Morise, Department of Surgery, Fujita Health University School of Medicine, Banbuntane Houtokukai Hospital, Nagoya, Aichi 454-8509, Japan

Tatsuya Suzuki, Fujio Hara, Masahito Hibi, Takazumi Kato, Takashi Hashimoto, Department of Pediatric Surgery, Fujita Health University School of Medicine, Toyoake, Aichi 470-1192, Japan

Author contributions: Tomishige H, Morise Z, Suzuki T, Hara F, Hibi M, Kato T and Hashimoto T performed the diagnosis and treatment of the patient, collected the data and assisted in writing the manuscript; Tomishige H wrote the manuscript.

Correspondence to: Zenichi Morise, MD, PhD, FACS, Department of Surgery, Fujita Health University School of Medicine, Banbuntane Houtokukai Hospital, 3-6-10, Otobashi Nakagawa-ku, Nagoya, Aichi 454-8509, Japan. [zmorise@aol.com](mailto:zmorise@aol.com)  
Telephone: +81-52-3218171 Fax: +81-52-3234502

Received: December 23, 2013 Revised: February 8, 2014

Accepted: April 11, 2014

Published online: May 16, 2014

### Abstract

The location of an ingested foreign object is often difficult to determine by X-ray if gastric air bubbles are not clear in the image. Methods that provide negative contrast can facilitate precise object localization, which is important for object retrieval and treatment of the patient. This case report describes a male child, 2 years and 2 mo of age, who accidentally swallowed a lithium battery while playing at home. A plain X-ray showed that the battery was in the abdomen, but it was unclear whether the object was still inside the stomach. A second X-ray examination performed after oral administration of a bloating agent to produce expansion of the stomach and provide negative contrast confirmed that the ingested battery was still in the stomach. The battery was then carefully removed using magnetic and balloon catheters under fluoroscopic guidance. This case report describes the successful use of an orally administered bloating agent without pain to the child in order

to determine the precise location of a foreign object in the abdomen.

© 2014 Baishideng Publishing Group Inc. All rights reserved.

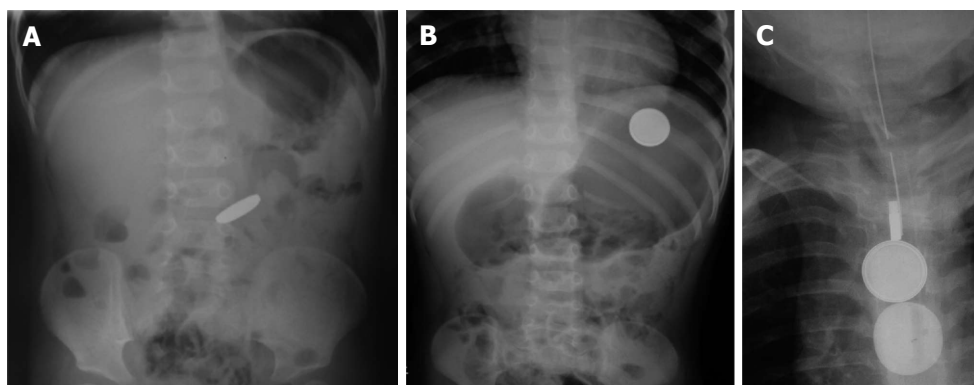
**Key words:** Accidental ingestion; Bloating agent; X-ray; Minimal invasion; Foreign object

**Core tip:** After ingestion of a foreign object, it is sometimes difficult to determine the object's exact location, which is important for successful retrieval and patient recovery. In the present case, an X-ray examination was performed after oral administration of a bloating agent to confirm that an ingested battery was still inside the stomach of a pediatric patient. This case demonstrates the successful and painless utilization of a bloating agent in a child for the diagnostic determination of an ingested foreign object location.

Tomishige H, Morise Z, Suzuki T, Hara F, Hibi M, Kato T, Hashimoto T. X-ray diagnosis with a bloating agent for foreign object ingestion. *World J Clin Cases* 2014; 2(5): 157-159 Available from: URL: <http://www.wjgnet.com/2307-8960/full/v2/i5/157.htm> DOI: <http://dx.doi.org/10.12998/wjcc.v2.i5.157>

### INTRODUCTION

It is often difficult to determine the precise location of a foreign ingested object in a plain X-ray if gastric air bubbles are not clear in the image. We experienced a case in which a child who had accidentally swallowed a lithium battery was brought to our emergency department. An initial X-ray examination was performed, and failed to reveal the precise location of the battery within the abdomen. A second X-ray examination performed after oral administration of a bloating agent to produce gastric carbon dioxide air bubbles resulted in sufficient exten-



**Figure 1 X-ray image.** A: Initial X-ray image showing the presence of a foreign object in the patient's abdomen; B: Abdominal X-ray image taken after oral administration of a bloating agent. Gastric air bubbles produced after administration of the bloating agent provided sufficient distension and negative contrast to confirm that the battery was inside the stomach; C: Chest X-ray image during removal of the foreign object. A magnetic catheter was used in combination with a balloon catheter to attract and remove the battery under fluoroscopic guidance.

sion of the stomach to indicate that the battery was still inside the stomach. Thus, we describe the successful use of a bloating agent that can be administered orally and without pain to a child, which is useful for determining the location of a foreign object in the stomach.

## CASE REPORT

A male child, 2 years and 2 mo of age, accidentally swallowed a battery while playing at home. He was first taken to a nearby hospital and then brought to our hospital approximately 4 h after the accident. The general condition of the patient was good without any symptoms. The foreign object was identified in abdominal plain X-ray images, but it was unclear whether the object was inside the stomach (Figure 1A). Therefore, a bloating agent (Baros Effervescent Granules-S 3.5 g, Horii Pharmaceutical Ind., Osaka, Japan) was orally administered to provide a negative contrast agent for X-ray imaging. The patient was provided with approximately one-fifth of one packet of the agent with a small amount of water by his mother. This produced gastric air bubbles that expanded the stomach. An abdominal plain X-ray examination then showed that the battery was inside the stomach (Figure 1B). A magnetic catheter was inserted from the mouth into the stomach without anesthesia. The battery was removed using the attraction of the magnet, with concomitant use of a 14 Fr. balloon catheter under fluoroscopic guidance (Figure 1C). The foreign object was confirmed to be a lithium battery, which was partially darkened due to stomach fluid. After removal of the battery, the general condition of the patient was good.

## DISCUSSION

Due to the possibility for serious complications, foreign objects such as button-type batteries require an emergency removal from the esophagus<sup>[1]</sup>, or the stomach. However, it is often difficult to determine whether the accidentally ingested foreign object is present in the

stomach based on plain X-ray images. In such instances, the site of the object is usually confirmed by instilling air through a nasogastric tube to induce stomach expansion. A bloating agent for contrast X-ray can also be used to confirm the site of a foreign object, as the agent can extend the stomach and duodenum wall by immediately producing carbon dioxide, which at the same time enhances the image contrast by increasing the difference in X-ray transmittance. The foaming ingredient within such bloating agents consists of sodium hydrogen carbonate and tartaric acid. Carbon dioxide produced in the stomach is excreted from the oral cavity by eructation, or absorbed into the digestive tract and excreted out of the body by gas exchange in the pulmonary alveoli<sup>[2]</sup>. Some reports have recommended the use of carbonated drinks such as cola and soda for stomach expansion<sup>[3]</sup>, however such drinks are not always appropriate for infants. Since the bloating agent used in our case was slightly sweet and sour, the child was able to take the agent without difficulty when given by his mother. Therefore, we suggest that a bloating agent for contrast X-ray is a suitable option to expand the stomach of a child who has swallowed a foreign object, since the approach is minimally invasive and does not require insertion of a nasogastric tube.

## COMMENTS

### Case characteristics

A two-year-old boy accidentally swallowed a lithium battery, which needed to be retrieved.

### Clinical diagnosis

The patient had swallowed a foreign object (a lithium battery), which was located in the stomach.

### Differential diagnosis

The foreign object (battery) may have been located in the intestine rather than the stomach.

### Imaging diagnosis

An X-ray performed after a bloating agent was administered allowed for stomach expansion and negative contrast to confirm that the foreign object (battery) was in the stomach and not the intestine.

### Treatment

A magnetic catheter and a 14 Fr. balloon catheter were used to remove the

magnet.

### Experiences and lessons

To treat a child who has swallowed a foreign object, we propose administration of boating agent prior to an X-ray, which expands the stomach and provides contrast while being minimally invasive and avoiding use of a nasogastric tube.

### Peer review

This paper describes a case in which an oral negative contrast media was used to localize a foreign body in the upper gastrointestinal tract. The diagnostic procedure presented in this case report is interesting and useful to other clinicians in need of a minimally invasive and painless technique to locate a swallowed foreign object.

## REFERENCES

- 1 **Yardeni D**, Yardeni H, Coran AG, Golladay ES. Severe esophageal damage due to button battery ingestion: can it be prevented? *Pediatr Surg Int* 2004; **20**: 496-501 [PMID: 15221361 DOI: 10.1007/s00383-004-1223-6]
- 2 **McIver MA**, Redfield AC, Benedict EB. Gaseous exchange between the blood and the lumen of the stomach and intestines. *Am J Physiol* 1926; **76**: 92-111
- 3 **Kurosawa T**. Foreign bodies in the digestive tract. *Jpn J Pediatric Med* 2009; **41**: 1333-1337

**P- Reviewers:** Montet X, Sali L    **S- Editor:** Wen LL  
**L- Editor:** A    **E- Editor:** Liu SQ





## Vasculitis with renal involvement in essential mixed cryoglobulinemia: Case report and mini-review

Sabiha Anis, Khawar Abbas, Mohammad Mubarak, Ejaz Ahmed, Sajid Bhatti, Rana Muzaffar

Sabiha Anis, Khawar Abbas, Rana Muzaffar, Department of Immunology and Molecular Biology, Dewan Farooq Medical Complex, Sindh Institute of Urology and Transplantation, Karachi 74200, Pakistan

Mohammad Mubarak, Department of Histopathology, Sindh Institute of Urology and Transplantation, Karachi 74200, Pakistan

Ejaz Ahmed, Sajid Bhatti, Department of Nephrology, Sindh Institute of Urology and Transplantation, Karachi 74200, Pakistan

**Author contributions:** Anis S and Abbas K performed the patient follow-ups for the immunological investigations; Anis S planned and analyzed the laboratory investigations and reports; Mubarak M performed the histopathological diagnosis; Ahmed E and Bhatti S were the attending physicians and finalized the diagnosis; Anis S wrote the initial manuscript; Abbas K edited the manuscript; Anis S, Mubarak M and Muzaffar R performed critical editing of the manuscript and prepared the final draft.

**Correspondence to:** Sabiha Anis, MCPS, FCPS, Assistant Professor, Department of Immunology and Molecular Biology, Dewan Farooq Medical Complex, Sindh Institute of Urology and Transplantation, M-9 N-5 Link Rd, Karachi 74200, Pakistan. [sabiha\\_anis@hotmail.com](mailto:sabiha_anis@hotmail.com)

Telephone: +92-21-32725543 Fax: +92-21-99215469

Received: November 22, 2013 Revised: February 13, 2014

Accepted: April 11, 2014

Published online: May 16, 2014

a proper diagnosis. We review the need for appropriate laboratory testing, which is often neglected in clinical practice and which can result in false negative results. This review also emphasizes the significance of an extended testing repertoire necessary for better patient management. Despite a strong association of MC with HCV infection and other causes that lead to cryoglobulin formation, EMC remains a separate entity. Correct diagnosis requires proper temperature regulation during sample handling, as well as characterization and quantification of the cryoprecipitate. Inclusion of rheumatoid factor activity and complement levels in the cryoglobulin test-panel promotes better patient management and monitoring. Consensus guidelines should be developed and implemented for cryoglobulin detection and the diagnosis of cryoglobulinemic syndrome, which will reduce variability in inter-laboratory reporting.

© 2014 Baishideng Publishing Group Inc. All rights reserved.

**Key words:** Cryoglobulin characterization; Cryoglobulin detection; Essential mixed cryoglobulinemia; Cryoglobulinemic glomerulonephritis; Hepatitis C virus; Renal manifestations

### Abstract

The discovery of a strong association between hepatitis C virus (HCV) infection and mixed cryoglobulinemia (MC) has led to an increasingly rare diagnosis of idiopathic essential MC (EMC). The incidence of EMC is high in regions where there is a comparatively low HCV infection burden and low in areas of high infection prevalence, including HCV. The diagnosis of EMC requires an extensive laboratory investigation to exclude all possible causes of cryoglobulin formation. In addition, although cryoglobulin testing is simple, improper testing conditions will result in false negative results. Here, we present a 46-year-old female patient with a case of EMC with dermatological and renal manifestations, highlighting the importance of extensive investigation to reach

**Core tip:** The diagnosis of essential mixed cryoglobulinemia (EMC) requires thorough laboratory investigation to exclude all possible causes of cryoglobulin formation. Although cryoglobulin testing is simple, it requires careful temperature regulation to avoid false negative results. The testing panel should also include cryoglobulin quantification and characterization, rheumatoid factor activity and complement levels, to better facilitate patient management. Furthermore, there is a need to develop and implement consensus guidelines for laboratory and clinical diagnoses of EMC.

Anis S, Abbas K, Mubarak M, Ahmed E, Bhatti S, Muzaffar R. Vasculitis with renal involvement in essential mixed cryoglobulinemia: Case report and mini-review. *World J Clin*

Cases 2014; 2(5): 160-166 Available from: URL: <http://www.wjgnet.com/2307-8960/full/v2/i5/160.htm> DOI: <http://dx.doi.org/10.12998/wjcc.v2.i5.160>

## INTRODUCTION

Cryoglobulins (CGs) are abnormal proteins/immunoglobulins (Igs) that precipitate out of serum at temperatures below 37 °C<sup>[1]</sup>. Initially identified by Winthrobe and Buell in 1933 and later named by Lerner *et al*<sup>[2]</sup>, CGs are found in many disorders ranging from autoimmune and infectious diseases to malignancies<sup>[3-5]</sup>. Cryoglobulinemia, the presence of CGs in blood, is significant only when the associated symptoms are present<sup>[6,7]</sup>. Mixed cryoglobulinemia (MC) is strongly associated with hepatitis C virus (HCV) infection<sup>[8-11]</sup>. Other causes, including autoimmune disorders and other infections, can lead to MC<sup>[12]</sup>. When the cause for MC cannot be identified, the disease is termed as idiopathic or essential mixed cryoglobulinemia (EMC)<sup>[13-15]</sup>. An extensive laboratory investigation is required to rule out the known conditions associated with cryoglobulinemic vasculitis to impart a proper diagnosis of EMC<sup>[3,4,16]</sup>. Here, we present a 46-year-old female patient with EMC and briefly review the current laboratory methods for diagnosing this syndrome.

## CASE REPORT

A 46-year-old female patient presented to the Department of Nephrology after suffering from anuria and renal failure for ten days. Prior to admission at our institute, the patient had already undergone four sessions of dialysis in another hospital. The only significant medical history for the patient was a laparoscopic cholecystectomy she received two months prior. The patient had no history of hypertension, diabetes mellitus or other renal disease.

Upon routine examination, the patient was pale, icteric, afebrile and normotensive, with facial and pedal edema. Palpable purpura was present on both hands. No other abnormalities were revealed during the remainder of the systemic examination. Laboratory investigations revealed normochromic and normocytic anemia, elevated total leukocyte counts with neutrophilia, and thrombocytopenia. Renal and liver functions were abnormal and proteinuria was present (+2 on a dipstick) (Table 1). A chest X-ray and an abdominal ultrasound were normal. There was no evidence of malignancy or infections upon bone marrow biopsy, and all requested cultures (blood, urine, and bone marrow) to rule out infections were negative. A provisional diagnosis of vasculitis was made.

In the absence of infections and malignancies, further examinations were carried out (Table 1). An immunological work-up showed low complement levels (C3 and C4) and a negative anti-nuclear antibody test, which remained negative at a 6-mo follow-up. Type II CGs were

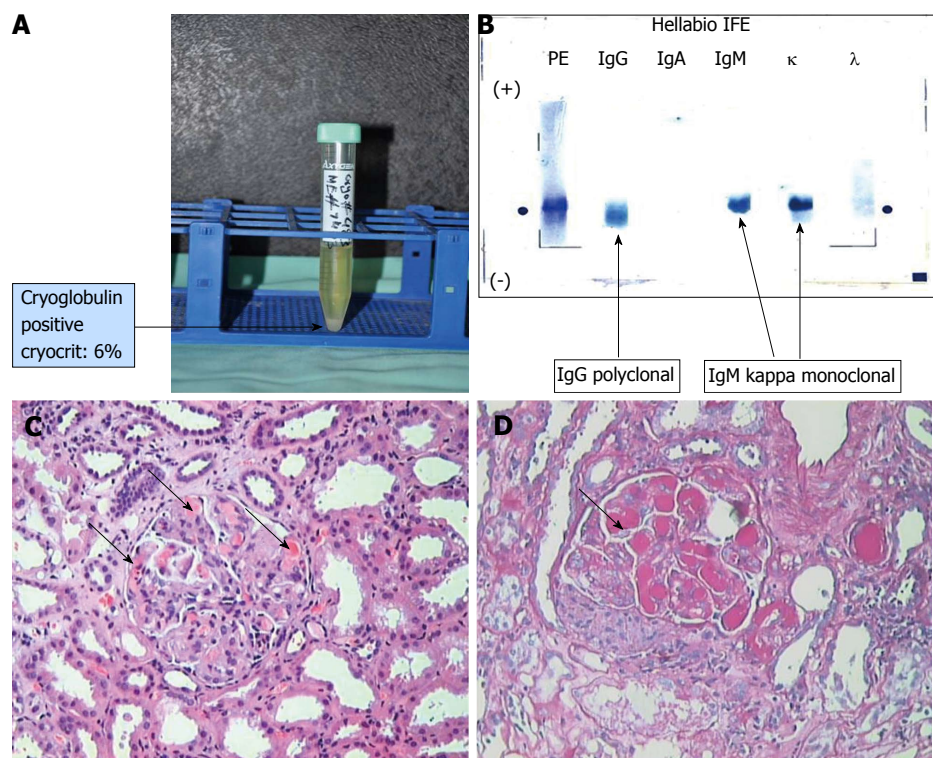
**Table 1 Laboratory results from a patient with essential mixed cryoglobulinemic syndrome**

Laboratory investigation	Test results (reference ranges)
Complete blood cell counts	
Hemoglobin	8.5 g/dL (11.5-15.4 g/dL)
White blood cell count	15200 × 10 <sup>9</sup> /L (4.0-11.0 × 10 <sup>9</sup> /L)
Neutrophils	87% (40%-80%)
Lymphocytes	10% (20%-40%)
Platelets	23000/L (150-400 × 10 <sup>9</sup> /L)
Coagulation profile	
APTT	28 s (25.8 s)
INR	1.98 (< 1.35)
Renal functions	
Urea	88 mg/dL (15-39 mg/dL)
Creatinine	6.2 mg/dL (0.5-1.5 mg/dL)
Liver functions	
Total bilirubin	6.1 mg/dL (0.2-1.0 mg/dL)
Direct bilirubin	3.2 mg/dL (0-0.25 mg/dL)
Alkaline phosphatase	202 U/mL (32-92 U/mL)
Alanine amino transferase	10 U/mL (10-40 U/mL)
Gamma glutamyl transferase	204 U/mL (7-64 U/mL)
Bone chemistry	
Calcium	7.5 mg/dL (8.4-10.2 mg/dL)
Phosphorus	4.4 mg/dL (2.5-4.0 mg/dL)
Albumin	2.2 mg/dL (3.5-5.0 mg/dL)
Urine detailed report	Anuric on admission, later showed +2 proteinuria; no red blood cells, no cast
Immunological work-up	
Complement 3	0.4 g/L (0.79-1.52 g/L)
Complement 4	0.01 g/L (0.16-0.38 g/L)
Anti-nuclear antibodies	Negative
ANCA	Negative
Rheumatoid factor activity	Positive: 859 IU/mL (cut off < 20 IU/mL)
Anti-cyclic citrullinated peptide	Negative
Anti-extractable nuclear antigens	Weakly positive for anti-Ro52
C-reactive protein	0.1 mg/dL (cut-off < 0.7 mg/dL)
Viral markers	
HBsAg	Negative
Anti-HCV	Negative
Anti-HIV	Negative
HCV RNA	Not detected

ANCA: Anti-neutrophil cytoplasmic antibodies; APTT: Activated partial thromboplastin time; HBsAg: Hepatitis B surface antigens; HCV: Hepatitis C virus; HIV: Human immunodeficiency virus; INR: International normalized ratio.

detected, with a cryocrit of 6% (Figure 1A and B). Tests for anti-HCV antibodies and HCV RNA were negative. Other tests to evaluate vasculitis were also negative (Table 1). Renal biopsy showed evidence of cryoglobulinemic glomerulonephritis (Figure 1C and D).

Before vasculitis was suspected, the patient was empirically managed with antibiotics and hemodialysis, but did not show improvement. After the diagnosis of cryoglobulinemic glomerulonephritis was made, the patient was treated with intravenous solumedrol (15 mg/kg body weight) for three days, monthly intravenous injections of cyclophosphamide (15 mg/kg body weight) for five months, and plasmapheresis. After 14 plasmapheresis sessions, the patient's renal functions normalized (serum creatinine 1.2 mg/dL) and the cryocrit decreased to 1%. Cryocrit levels subsequently decreased to less than 1% over a



**Figure 1** Detection of essential mixed cryoglobulinemic syndrome in a female patient. A: Precipitated cryoproteins from the cryoglobulin detection test are shown at the bottom of the tube, with a cryocrit measurement of approximately 6%; B: Immunotyping of cryoglobulins at 37 °C revealed a mixture of polyclonal immunoglobulin (Ig) G and monoclonal IgMκ (black arrows); C: Hematoxylin and eosin-stained renal biopsy showing diffuse moderate mesangial proliferation, numerous wireloop lesions and hyaline thrombi in capillary lumina (black arrows) (magnification × 200); D: Periodic acid-Schiff staining from the same biopsy showing extensive hyaline thrombi in the capillary lumina (arrow) (magnification × 200).

period of six months. Normal renal function was found to be maintained at the one-year follow-up examination.

## DISCUSSION

Brouet *et al*<sup>[17]</sup> immunochemically classified CGs into three types. Type I CGs are characterized by the presence of only a monoclonal component, mostly IgMκ, and are usually found in patients with lymphoid malignancies such as multiple myeloma. Mixed CGs are comprised of type II, characterized by the presence of polyclonal Igs with a monoclonal component, and type III, which contain only polyclonal Igs<sup>[17]</sup>. Mixed CGs are also associated with rheumatoid factor (RF) activity<sup>[17,18,19]</sup>.

### MC with or without HCV infection

Before the discovery of HCV infection, most cases of MC were defined as EMC, without an underlying identifiable cause<sup>[20]</sup>. In the early 1990s, HCV became recognized as the major cause of CG formation, with approximately 90% of MC patients having the virus<sup>[3]</sup>. It has been reported that approximately 50% of HCV-infected patients develop CGs in their blood<sup>[6]</sup>. The viral particles have also been detected in cryoprecipitates<sup>[21,22]</sup>. Since this discovery, the diagnosis of EMC has become rare<sup>[10,16,23]</sup>.

Autoimmune or connective tissue diseases<sup>[13,14,24,25]</sup>, lymphoproliferative disorders<sup>[26]</sup> and other infections such as bacterial, viral and parasitic<sup>[27]</sup> infections, have been at-

tributed to MC development. However, 5%-48% of cases with cryoglobulinemic syndrome have still been reported as EMC<sup>[28-30]</sup>. The incidence of EMC is higher in regions with a low prevalence of HCV infection, and lower in areas with high HCV prevalence<sup>[4]</sup>. In Pakistan, more than ten million people are infected with HCV<sup>[31,32]</sup> and there is a high burden of other infections, especially in immunocompromised populations<sup>[33]</sup>, which makes the risk for EMC lower. Therefore, an extensive and thorough examination is required to rule out other causes of cryoglobulinemia and properly assign an EMC diagnosis<sup>[34,35]</sup>.

### Symptomatic MC

Cryoglobulinemic syndrome was first described by Meltzer *et al*<sup>[18]</sup> in 1966 as a triad of symptoms including purpura, arthralgia and weakness. The syndrome may also involve the visceral organs, including hepatosplenomegaly<sup>[36]</sup>, glomerulonephritis<sup>[37]</sup> and lymphadenopathy<sup>[30]</sup>. The presence of CGs is not always associated with clinical features<sup>[24]</sup>, and low levels of CGs have been found in HCV-infected patients without associated symptoms<sup>[4,6,7]</sup>. During renal replacement therapy for end stage renal disease, low levels of CGs have been detected in a substantial number of non-infected and HCV-infected patients, with and without symptoms<sup>[33]</sup>.

### Renal manifestations in MC

The incidence and presentation of renal manifestations



in HCV-associated cryoglobulinemia is well documented<sup>[10,11]</sup>. In non-HCV cryoglobulinemia, including EMC, the evidence of renal manifestations is predominantly confined to case reports<sup>[29,38-42]</sup>. It is important to note that most of the data on renal manifestations in EMC have come from studies on French populations<sup>[16,28,30,34]</sup>. In a multicenter French study comprised of 20 HCV-negative patients with renal manifestations, 50% of the patients had EMC<sup>[16]</sup>. In this study, microscopic hematuria and hypertension were the most common presenting clinical features, followed by nephrotic range proteinuria and renal insufficiency. In a separate French study, which contained 33 patients with type II CGs, 13 (39%) of the patients had EMC. Of these patients, eight (62%) had renal involvement, with four of those suffering from renal insufficiency<sup>[34]</sup>. In a Dutch study of 22 non-HCV patients with type II CGs, seven (32%) were found to have EMC, of which six patients had renal involvement<sup>[35]</sup>.

### **CG detection and testing repertoire**

Detection of CGs requires stringent temperature control, a fact that cannot be stressed enough. It is imperative to maintain the sample temperature at 37 °C from the time the sample is collected until separation of the serum<sup>[43]</sup>. Failure to keep samples at 37 °C will result in false negative results<sup>[4,44,45]</sup>. In our own experience, centrifuges even those lacking a heater-with a wide temperature range (e.g., 0 °C-40 °C) can be used to separate serum at 37 °C. This can be achieved by preheating the instrument with an initial dry run at > 37 °C and then immediately transferring the samples from a 37 °C incubator to the centrifuge. Once centrifugation is complete, the samples should be immediately taken out of the centrifuge and placed in a 37 °C incubator until the supernatant can be separated. Adherence to this protocol helps to avoid red blood cell contamination, which can hinder the visibility of CGs.

Although cryoglobulinemic syndrome was first identified in 1933, the significance of a proper CG detection assay and awareness for the condition is still not fully recognized. A large European survey of 140 laboratories revealed that only 37 (26%) were following the appropriate standard procedure for CG detection<sup>[45]</sup>. The reporting of CG positive results should include quantification and characterization of these proteins, RF activity and complement (C3 and C4) levels<sup>[5,44,45]</sup>. Although CG concentration does not correlate well with disease activity, CG levels, along with RF activity and complement levels, are useful in monitoring the disease<sup>[5,19]</sup>.

This case report highlights the importance for proper and thorough investigation of a patient in order to diagnose cryoglobulinemic syndrome in the absence of infections (including HCV) and other known causes of MC. Furthermore, the quantification and characterization of CGs is important, as the decrease in cryocrit level in the present case correlated well with clinical remission. Although repeated anti-nuclear antibody tests were negative, there was a weak positivity for anti-Ro52 antibodies, which can be found in various conditions, including cryo-

globulinemia<sup>[46]</sup>. Similarly, a low C-reactive protein has also been observed in the serum of patients with MC, not related to systemic lupus erythematosus<sup>[19,47]</sup>.

CG quantification can be done in various ways, including total protein or immunoglobulin content of cryoprecipitates, cryocrit determination<sup>[45]</sup>, gel-based semi-quantitative tests<sup>[48]</sup> and other methods<sup>[49,50]</sup>. Determination of levels using a cryocrit is less cumbersome and more informative, though it should be noted that a cryocrit is less sensitive and specific than quantification of washed cryoproteins<sup>[44]</sup>. CG characterization provides valuable information that aids in long-term patient management<sup>[45,49]</sup>. Patients with type II CGs should be closely monitored for B cell lymphoma development, especially in patients that are difficult to treat<sup>[6,15]</sup>. Lack of standardization and an incomplete testing repertoire inadvertently lead to distrust of laboratory results by the treating physicians and undermine the significance of CG detection in suspected cases, which may poorly affect patient management<sup>[4,45,49,50]</sup>. This is very important given that better treatment options are increasingly becoming available to manage this rare yet troublesome disorder<sup>[41,51,52]</sup>.

### **Diagnosis of cryoglobulinemic syndrome: Diagnostic versus classification criteria**

Varied clinical presentation and insignificant correlation of CG concentration with clinical manifestations have made the diagnosis of cryoglobulinemic syndrome quite difficult. Thus, various diagnostic and classification criteria have been proposed to facilitate in the diagnosis of this condition<sup>[7,53,54]</sup>. Diagnostic criteria are based on major and minor laboratory and clinical features<sup>[54]</sup>, and preliminary classification criteria have been proposed, including a questionnaire regarding symptoms, laboratory findings (including CG types, complement levels, RF activity and HCV presence) and organ involvement<sup>[7]</sup>. Diagnostic and classification criteria indicate that the presence of CGs in serum is the gold standard for a cryoglobulinemic vasculitis diagnosis. Moreover, the presence of clinical features consistent with this syndrome in the absence of CGs warrants repeat testing for these proteins given the possibility for false negative results<sup>[7,53]</sup>.

In conclusion, despite a strong association of MC with HCV infection and other causes that can lead to CG formation, EMC remains a separate entity. Accurate diagnosis requires a thorough laboratory investigation to rule out the known causes of MC. Correct laboratory diagnosis not only requires proper handling of the samples for CG detection, but also quantification of the amount of cryoprecipitate and identification of the type of CGs present. Other tests, such as RF activity and complement levels (C3 and C4), should be included in the testing panel to ensure better patient management and monitoring. There is a need to develop and implement consensus guidelines for the detection of CGs and cryoglobulinemic syndrome to reduce variability in inter-laboratory reporting and to establish the diagnostic criteria for this clinical syndrome.



## COMMENTS

**Case characteristics**

A 46-year-old female presented with anuria, acute renal failure and palpable purpura.

**Clinical diagnosis**

The patient was diagnosed with essential mixed cryoglobulinemic syndrome.

**Differential diagnosis**

Vasculitis causing acute renal failure was ruled out.

**Laboratory diagnosis**

The following laboratory tests were acquired from the patient: negative cultures, anti-nuclear antibodies, anti-neutrophil cytoplasmic antibodies, anti-hepatitis C virus (HCV) and HCV RNA, and positive cryoglobulins (CGs) with low C3 and C4 levels and high rheumatoid factor (RF) activity.

**Imaging diagnosis**

The patient had normal chest X-ray and abdominal ultrasound reports.

**Pathological diagnosis**

Hematoxylin and eosin staining, in addition to periodic acid-Schiff stains from a renal biopsy, showed evidence of cryoglobulinemic glomerulonephritis.

**Treatment**

The patient was treated with intravenous injections of solumedrol and cyclophosphamide, and plasmapheresis, which improved her condition.

**Related reports**

Essential mixed cryoglobulinemia (EMC) is rare and requires a thorough examination to rule out other known causes. A complete work-up for cryoglobulinemic syndrome, including quantification and characterization of cryoprecipitates, complement levels and RF activity, is required for proper management and monitoring.

**Term explanation**

Cryoglobulinemia is a disorder in which CGs precipitate out of the blood at temperatures lower than 37 °C and is often associated with hepatitis C viral infection.

**Experiences and lessons**

Early recognition, extensive diagnostic work-up and proper patient management, including regular follow-ups and immunological monitoring, resulted in a favorable patient outcome in this study.

**Peer review**

This case report with a mini-review highlights the importance of a thorough investigation for the rare and often neglected diagnosis of EMC. This article will be of great benefit to clinicians as it increases the awareness regarding the clinical utility and proper testing and interpretation of cryoglobulin detection assays.

## REFERENCES

- Morra E. Cryoglobulinemia. *Hematology Am Soc Hematol Educ Program* 2005; 368-372 [PMID: 16304405 DOI: 10.1182/asheducation-2005.1.368]
- Lerner AB, Watson CJ. Studies of cryoglobulins; unusual purpura associated with the presence of a high concentration of cryoglobulin (cold precipitable serum globulin). *Am J Med Sci* 1947; **214**: 410-415 [PMID: 20266939]
- Ramos-Casals M, Stone JH, Cid MC, Bosch X. The cryoglobulinaemias. *Lancet* 2012; **379**: 348-360 [PMID: 21868085 DOI: 10.1016/S0140-6736(11)60242-0]
- Damoiseaux J, Cohen Tervaert JW. Diagnostics and Treatment of Cryoglobulinaemia: It Takes Two to Tango. *Clin Rev Allergy Immunol* 2013; Epub ahead of print [PMID: 24068540]
- Shihabi ZK. Cryoglobulins: an important but neglected clinical test. *Ann Clin Lab Sci* 2006; **36**: 395-408 [PMID: 17127726]
- Ferri C. Mixed cryoglobulinemia. *Orphanet J Rare Dis* 2008; **3**: 25 [PMID: 18796155 DOI: 10.1186/1750-1172-3-25]
- De Vita S, Soldano F, Isola M, Monti G, Gabrielli A, Tzioufas A, Ferri C, Ferraccioli GF, Quartuccio L, Corazza L, De Marchi G, Ramos Casals M, Voulgarelis M, Lenzi M, Saccardo F, Fraticelli P, Mascia MT, Sansonno D, Cacoub P, Tomsic M, Tavoni A, Pietrogrande M, Zignego AL, Scarpato S, Mazzaro C, Pioltelli P, Steinfeld S, Lamprecht P, Bombardieri S, Galli M. Preliminary classification criteria for the cryoglobulinaemic vasculitis. *Ann Rheum Dis* 2011; **70**: 1183-1190 [PMID: 21571735 DOI: 10.1136/ard.2011.150755]
- Lauletta G, Russi S, Contedua V, Sansonno L. Hepatitis C virus infection and mixed cryoglobulinemia. *Clin Dev Immunol* 2012; **2012**: 502156 [PMID: 22844322 DOI: 10.1155/2012/502156]
- Viganò M, Lampertico P, Rumi MG, Folli C, Maggioni L, Morabito A, Del Ninno E, Cicardi M, Colombo M. Natural history and clinical impact of cryoglobulins in chronic hepatitis C: 10-year prospective study of 343 patients. *Gastroenterology* 2007; **133**: 835-842 [PMID: 17678923]
- Fabrizi F. Hepatitis C virus, cryoglobulinemia, and kidney: novel evidence. *Scientifica (Cairo)* 2012; **2012**: 128382 [PMID: 24278667 DOI: 10.6064/2012/128382]
- Campise M, Tarantino A. Glomerulonephritis in mixed cryoglobulinaemia: what treatment? *Nephrol Dial Transplant* 1999; **14**: 281-283 [PMID: 10069172]
- Bryce AH, Kyle RA, Dispenzieri A, Gertz MA. Natural history and therapy of 66 patients with mixed cryoglobulinemia. *Am J Hematol* 2006; **81**: 511-518 [PMID: 16755564 DOI: 10.1002/ajh.20643]
- García-Carrasco M, Ramos-Casals M, Cervera R, Trejo O, Yagüe J, Sisó A, Jiménez S, de La Red G, Font J, Ingelmo M. Cryoglobulinemia in systemic lupus erythematosus: prevalence and clinical characteristics in a series of 122 patients. *Semin Arthritis Rheum* 2001; **30**: 366-373 [PMID: 11303309 DOI: 10.1053/sarh.2001.20265]
- Ostojic P. Cryoglobulinemic vasculitis in systemic sclerosis successfully treated with mycophenolate mofetil. *Rheumatol Int* 2014; **34**: 145-147 [PMID: 23271426 DOI: 10.1007/s00296-012-2640-9]
- De Vita S, Quartuccio L, Salvin S, Corazza L, Zabotti A, Fabris M. Cryoglobulinaemia related to Sjogren's syndrome or HCV infection: differences based on the pattern of bone marrow involvement, lymphoma evolution and laboratory tests after parotidectomy. *Rheumatology (Oxford)* 2012; **51**: 627-633 [PMID: 22210656 DOI: 10.1093/rheumatology/ker407]
- Matignon M, Cacoub P, Colombat M, Saadoun D, Broche-riou I, Mougnot B, Roudot-Thoraval F, Vanhille P, Moranne O, Hachulla E, Hatron PY, Fermand JP, Fakhouri F, Ronco P, Plaisier E, Grimbert P. Clinical and morphologic spectrum of renal involvement in patients with mixed cryoglobulinemia without evidence of hepatitis C virus infection. *Medicine (Baltimore)* 2009; **88**: 341-348 [PMID: 19910748 DOI: 10.1097/MD.0b013e3181c1750f]
- Brouet JC, Clauvel JP, Danon F, Klein M, Seligmann M. Biologic and clinical significance of cryoglobulins. A report of 86 cases. *Am J Med* 1974; **57**: 775-788 [PMID: 4216269]
- Meltzer M, Franklin EC, Elias K, McCluskey RT, Cooper N. Cryoglobulinemia--a clinical and laboratory study. II. Cryoglobulins with rheumatoid factor activity. *Am J Med* 1966; **40**: 837-856 [PMID: 4956871]
- Gorevic PD. Rheumatoid factor, complement, and mixed cryoglobulinemia. *Clin Dev Immunol* 2012; **2012**: 439018 [PMID: 22956968 DOI: 10.1155/2012/439018]
- Dammacco F, Sansonno D, Piccoli C, Tucci FA, Racanelli V. The cryoglobulins: an overview. *Eur J Clin Invest* 2001; **31**: 628-638 [PMID: 11454019 DOI: 10.1046/j.1365-2362.2001.00824.x]
- Barone M, Licinio R, Amoroso A, Viggiani MT, Larocca AM, Di Leo A. Lesson from an intriguing case of cryoglobulinemia. *World J Gastroenterol* 2013; **19**: 304-306 [PMID: 23345955 DOI: 10.3748/wjg.v19.i2.304]
- Della Rossa A, Baldini C, Tavoni A, Bombardieri S. How HCV has changed the approach to mixed cryoglobulinemia. *Clin Exp Rheumatol* 2009; **27**: S115-S123 [PMID: 19646357]
- Lauletta G, Russi S, Contedua V, Sansonno L, Dammacco F,

- Sansonno D. Impact of Cryoglobulinemic Syndrome on the Outcome of Chronic Hepatitis C Virus Infection: A 15-Year Prospective Study. *Medicine* (Baltimore) 2013; Epub ahead of print [PMID: 23982056]
- 24 **Monti G**, Saccardo F, Castelnovo L, Novati P, Sollima S, Riva A, Sarzi-Puttini P, Quartuccio L, De Vita S, Galli M. Prevalence of mixed cryoglobulinaemia syndrome and circulating cryoglobulins in a population-based survey: the Origio study. *Autoimmun Rev* 2014; **13**: 609-614 [PMID: 24418294 DOI: 10.1016/j.autrev.2013.11.005]
  - 25 **Zivanovic D**, Dobrosavljevic D, Nikolic M, Bonaci-Nikolic B. Cryoglobulins and multispecific antineutrophil cytoplasmic antibodies in propylthiouracil-induced necrotizing cutaneous vasculitis--a new association. *Eur J Dermatol* 2012; **22**: 707-709 [PMID: 22858991 DOI: 10.1684/ejd.2012.1810]
  - 26 **Merlini G**, Stone MJ. Dangerous small B-cell clones. *Blood* 2006; **108**: 2520-2530 [PMID: 16794250 DOI: 10.1182/blood-2006-03-001164]
  - 27 **Pagnoux C**, Cohen P, Guillevin L. Vasculitides secondary to infections. *Clin Exp Rheumatol* 2006; **24**: S71-S81 [PMID: 16859600]
  - 28 **Rieu V**, Cohen P, André MH, Mouthon L, Godmer P, Jarrousse B, Lhote F, Ferrière F, Dény P, Buchet P, Guillevin L. Characteristics and outcome of 49 patients with symptomatic cryoglobulinaemia. *Rheumatology* (Oxford) 2002; **41**: 290-300 [PMID: 11934966]
  - 29 **Rozin AP**, Lewin M, Braun-Moscovici Y, Itzhak OB, Bergman R, Balbir-Gurman A. Essential mixed cryoglobulinemia type II. *Clin Exp Rheumatol* 2006; **24**: 329-332 [PMID: 16870105]
  - 30 **Terrier B**, Krastinova E, Marie I, Launay D, Lacraz A, Belnotti P, de Saint-Martin L, Quemeneur T, Huart A, Bonnet F, Le Guenno G, Kahn JE, Hirschberger O, Rullier P, Diot E, Lazaro E, Bridoux F, Zénone T, Carrat F, Hermine O, Léger JM, Mariette X, Senet P, Plaisier E, Cacoub P. Management of noninfectious mixed cryoglobulinemia vasculitis: data from 242 cases included in the CryoVas survey. *Blood* 2012; **119**: 5996-6004 [PMID: 22474249 DOI: 10.1182/blood-2011-12-396028]
  - 31 **Khan A**, Tareen AM, Ikram A, Rahman H, Wadood A, Qasim M, Khan K. Prevalence of HCV among the young male blood donors of Quetta region of Balochistan, Pakistan. *Virol J* 2013; **10**: 83 [PMID: 23497435 DOI: 10.1186/1743-422X-10-83]
  - 32 **Ashfaq UA**, Javed T, Rehman S, Nawaz Z, Riazuddin S. An overview of HCV molecular biology, replication and immune responses. *Virol J* 2011; **8**: 161 [PMID: 21477382 DOI: 10.1186/1743-422X-8-16]
  - 33 **Anis S**, Muzaffar R, Ahmed E, Ali S, Nadir A, Naqvi A, Rizvi AH. Cryoglobulinaemia and autoimmune markers in hepatitis C virus infected patients on renal replacement therapy. *J Pak Med Assoc* 2007; **57**: 225-229 [PMID: 17571476]
  - 34 **Foessel L**, Besancenot JF, Blaison G, Magy-Bertrand N, Jaussaud R, Etienne Y, Maurier F, Audia S, Martin T. Clinical spectrum, treatment, and outcome of patients with type II mixed cryoglobulinemia without evidence of hepatitis C infection. *J Rheumatol* 2011; **38**: 716-722 [PMID: 21239761 DOI: 10.3899/jrheum.100898]
  - 35 **Tervaert JW**, Van Paassen P, Damoiseaux J. Type II cryoglobulinemia is not associated with hepatitis C infection: the Dutch experience. *Ann N Y Acad Sci* 2007; **1107**: 251-258 [PMID: 17804553]
  - 36 **Levo Y**, Gorevic PD, Kassab HJ, Tobias H, Franklin EC. Liver involvement in the syndrome of mixed cryoglobulinemia. *Ann Intern Med* 1977; **87**: 287-292 [PMID: 900672 DOI: 10.7326/0003-4819-87-3-287]
  - 37 **Cohen RA**, Bayliss G, Crispin JC, Kane-Wanger GF, Van Beek CA, Kyttaris VC, Avalos I, Yu CY, Tsokos GC, Stillman IE. T cells and in situ cryoglobulin deposition in the pathogenesis of lupus nephritis. *Clin Immunol* 2008; **128**: 1-7 [PMID: 18565470 DOI: 10.1016/j.clim.2008.04.004]
  - 38 **Takeda A**, Ootsuka Y, Suzuki T, Yamauchi Y, Tsujita M, Kawaguchi T, Horike K, Oikawa T, Goto N, Nagasaka T, Watarai Y, Uchida K, Morozumi K. A case report of recurrence of mixed cryoglobulinemic glomerulonephritis in a renal transplant recipient. *Clin Transplant* 2010; **24** Suppl 22: 44-47 [PMID: 20590694 DOI: 10.1111/j.1399-0012.2010.01281.x]
  - 39 **Tsuboi N**, Ichinose M, Kawamura T, Joh K, Utsunomiya Y, Hosoya T. Rapidly progressive cryoglobulinemic glomerulonephritis. *Clin Exp Nephrol* 2010; **14**: 492-495 [PMID: 20556460 DOI: 10.1007/s10157-010-0301-4]
  - 40 **Martina MN**, Solé M, Massó E, Pérez N, Campistol JM, Quintana LF. Mixed cryoglobulinaemia not related to hepatitis C virus, mesangiocapillary glomerulonephritis and lymphoplasmocytic lymphoma. *Nefrologia* 2011; **31**: 743-746 [PMID: 22130292 DOI: 10.3265/Nefrologia.pre2011]
  - 41 **Hirt-Minkowski P**, Trendelenburg M, Gröschl I, Fischer A, Heijnen I, Schifferli JA. A trial of complement inhibition in a patient with cryoglobulin-induced glomerulonephritis. *Case Rep Nephrol Urol* 2012; **2**: 38-45 [PMID: 23197954 DOI: 10.1159/000339403]
  - 42 **Okura T**, Jotoku M, Miyoshi K, Enomoto D, Kurata M, Irita J, Nagao T, Ohtsuka T, Higaki J. Case of membranoproliferative glomerulonephritis due to essential cryoglobulinemia without hepatitis C virus infection. *Geriatr Gerontol Int* 2009; **9**: 92-96 [PMID: 19260986 DOI: 10.1111/j.1447-0594.2008.00493.x]
  - 43 **Sargur R**, White P, Egner W. Cryoglobulin evaluation: best practice? *Ann Clin Biochem* 2010; **47**: 8-16 [PMID: 20040797 DOI: 10.1258/acb.2009.009180]
  - 44 **Motyckova G**, Murali M. Laboratory testing for cryoglobulins. *Am J Hematol* 2011; **86**: 500-502 [PMID: 21594887 DOI: 10.1002/ajh.22023]
  - 45 **Vermeersch P**, Gijbels K, Mariën G, Lunn R, Egner W, White P, Bossuyt X. A critical appraisal of current practice in the detection, analysis, and reporting of cryoglobulins. *Clin Chem* 2008; **54**: 39-43 [PMID: 17998269 DOI: 10.1373/clinchem.2007.090134]
  - 46 **Hervier B**, Rimbart M, Colonna F, Hamidou MA, Audrain M. Clinical significance of anti-Ro/SSA-52 kDa antibodies: a retrospective monocentric study. *Rheumatology* (Oxford) 2009; **48**: 964-967 [PMID: 19531627 DOI: 10.1093/rheumatology/kep145]
  - 47 **Weiner SM**, Prasauskas V, Lebrecht D, Weber S, Peter HH, Vaith P. Occurrence of C-reactive protein in cryoglobulins. *Clin Exp Immunol* 2001; **125**: 316-322 [PMID: 11529925]
  - 48 **Okazaki T**, Nagai T, Kanno T. Gel diffusion procedure for the detection of cryoglobulins in serum. *Clin Chem* 1998; **44**: 1558-1559 [PMID: 9665440]
  - 49 **Chan AO**, Lau JS, Chan CH, Shek CC. Cryoglobulinaemia: clinical and laboratory perspectives. *Hong Kong Med J* 2008; **14**: 55-59 [PMID: 18239245]
  - 50 **Müller RB**, Vogt B, Winkler S, Muñoz LE, Franz S, Kern P, Maihöfner C, Sheriff A, von Kempis J, Schett G, Herrmann M. Detection of low level cryoglobulins by flow cytometry. *Cytometry A* 2012; **81**: 883-887 [PMID: 22961692 DOI: 10.1002/cyto.a.22112]
  - 51 **De Vita S**, Quartuccio L, Isola M, Mazzaro C, Scaini P, Lenzi M, Campanini M, Naclerio C, Tavoni A, Pietrogrande M, Ferri C, Mascia MT, Masolini P, Zabotti A, Maset M, Roccatello D, Zignego AL, Pioltelli P, Gabrielli A, Filippini D, Perrella O, Migliaresi S, Galli M, Bombardieri S, Monti G. A randomized controlled trial of rituximab for the treatment of severe cryoglobulinemic vasculitis. *Arthritis Rheum* 2012; **64**: 843-853 [PMID: 22147661 DOI: 10.1002/art.34331]
  - 52 **Sanchez AP**, Cunard R, Ward DM. The selective therapeutic apheresis procedures. *J Clin Apher* 2013; **28**: 20-29 [PMID: 23420592 DOI: 10.1002/jca.21265]
  - 53 **Jennette JC**, Falk RJ, Bacon PA, Basu N, Cid MC, Ferrario F, Flores-Suarez LF, Gross WL, Guillevin L, Hagen EC, Hoffman GS, Jayne DR, Kallenberg CG, Lamprecht P, Langford CA, Luqmani RA, Mahr AD, Matteson EL, Merkel PA, Ozen

S, Pusey CD, Rasmussen N, Rees AJ, Scott DG, Specks U, Stone JH, Takahashi K, Watts RA. 2012 revised International Chapel Hill Consensus Conference Nomenclature of Vasculitides. *Arthritis Rheum* 2013; **65**: 1-11 [PMID: 23045170 DOI:

10.1002/art.37715]  
54 **Ferri C**, Zignego AL, Pileri SA. Cryoglobulins. *J Clin Pathol* 2002; **55**: 4-13 [PMID: 11825916]

**P- Reviewers:** Boffano P, Cho SY **S- Editor:** Qi Y  
**L- Editor:** A **E- Editor:** Liu SQ



## Pancreatic tuberculosis mimicking pancreatic carcinoma during anti-tuberculosis therapy: A case report

Yan-Jia Yang, Ya-Xin Li, Xiao-Qin Liu, Mei Yang, Kai Liu

Yan-Jia Yang, Ya-Xin Li, Xiao-Qin Liu, Mei Yang, Kai Liu, Center for Infectious Disease, West China Hospital, Sichuan University, Chengdu 610041, Sichuan Province, China

**Author contributions:** Yang YJ contributed to the study concept and design, collected and analyzed the data, and participated in drafting the manuscript; Li YX and Liu XQ contributed to data acquisition and assisted in drafting the manuscript; Yang M contributed to data acquisition and critically revised the article; Liu K conceived the study, participated in study design and coordination, and revised the manuscript critically; all authors read and approved the final manuscript.

**Correspondence to:** Kai Liu, MD, Center for Infectious Disease, West China Hospital, Sichuan University, No. 37 Guo Xue Xiang, Chengdu 610041, Sichuan Province, China. [liubusiness@163.com](mailto:liubusiness@163.com)

Telephone: +86-18-980601879 Fax: +86-28-85422650

Received: December 17, 2013 Revised: March 20, 2014

Accepted: April 16, 2014

Published online: May 16, 2014

contribution of pancreatic TB to pancreatic masses and obstructive jaundice.

© 2014 Baishideng Publishing Group Inc. All rights reserved.

**Key words:** Anti-tuberculosis therapy; Pancreatic head carcinoma; Pancreatic tuberculosis; Pancreatic mass; Tube cholecystostomy

**Core tip:** Pancreatic tuberculosis (TB) is rare in immunocompetent or immunosuppressed hosts. We report a case of a 40-year-old immunocompetent host with pancreatic TB that mimicked pancreatic head carcinoma with obstructive jaundice. The patient had previously been operated on for thoracic TB and was receiving anti-TB therapy. We report this case to emphasize rare causes of pancreatic masses and obstructive jaundice, and to discuss alternate treatments for pancreatic TB.

### Abstract

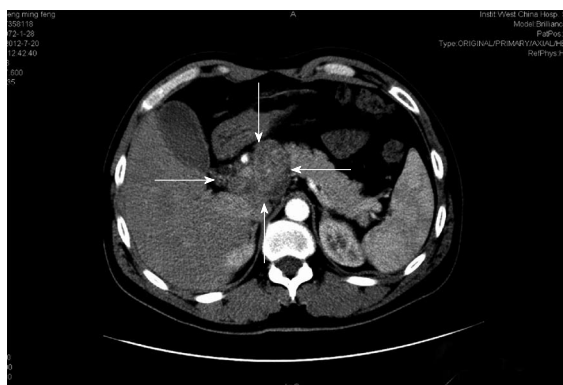
Pancreatic tuberculosis (TB) is a rare condition, even in immunocompetent hosts. A case is presented of pancreatic TB that mimicked pancreatic head carcinoma in a 40-year-old immunocompetent male patient. The patient was admitted to our hospital after suffering for nine days from epigastralgia and obstructive jaundice. Computed tomography revealed a pancreatic mass that mimicked a pancreatic head carcinoma. The patient had undergone an operation four months prior for thoracic TB and was undergoing anti-TB therapy. A previous abdominal ultrasound was unremarkable with the exception of gallbladder steroid deposits. The patient underwent surgery due to the progressive discomfort of the upper abdomen and a mass that resembled a pancreatic malignancy. A biopsy of the pancreas and lymph nodes was performed, revealing TB infection. The patient received a cholecystostomy tube and recovered after being administered standard anti-TB therapy for 15 mo. This case is reported to emphasize the rare

Yang YJ, Li YX, Liu XQ, Yang M, Liu K. Pancreatic tuberculosis mimicking pancreatic carcinoma during anti-tuberculosis therapy: A case report. *World J Clin Cases* 2014; 2(5): 167-169 Available from: URL: <http://www.wjgnet.com/2307-8960/full/v2/i5/167.htm> DOI: <http://dx.doi.org/10.12998/wjcc.v2.i5.167>

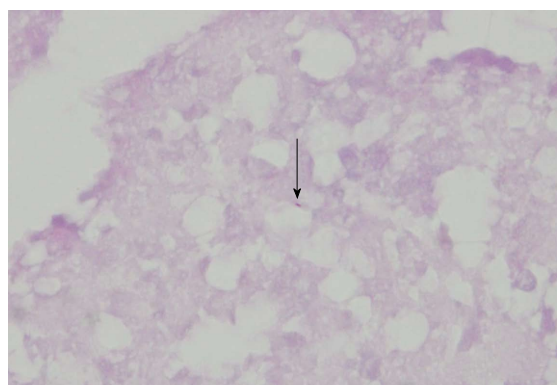
### INTRODUCTION

Pancreatic tuberculosis (TB) is a rare occurrence in either immunocompetent or immunosuppressed hosts; human immunodeficiency virus (HIV)-infected patients only have a 0.46% incidence<sup>[1]</sup>. Isolated pancreatic TB is predominantly observed in areas of widespread TB dissemination such as a military setting. Currently, there are few reports detailing pancreatic TB cases, and none of the patients were receiving anti-TB therapies at the time of diagnosis. Here, a case of pancreatic TB is presented in an immunocompetent host that was receiving anti-TB treatment. This article highlights the importance of understanding





**Figure 1** Computed tomography of a pancreatic tuberculosis lesion. Computed tomography revealed a necrotic and calcified cystic lesion (white arrows) with well-defined margins in the head of the pancreas; the lesion mimicked pancreatic head carcinoma.



**Figure 2** Histopathology of lymph node biopsies. Ziehl-Neelsen staining of a lymph node biopsy from the pancreatic region revealed granulomatous inflammation with necrosis and acid-fast bacilli (black arrow; magnification  $\times 400$ ).

this rare disease as a cause of pancreatic masses and obstructive jaundice.

## CASE REPORT

In July 2012, a 40-year-old male patient was admitted to our hospital after suffering from epigastralgia and jaundice for nine days. Upon eating, the patient complained of nausea and a worsening pain that radiated to his back. An abdominal examination revealed sensitivity in the upper abdomen without hepatosplenomegaly or ascites. The patient's medical history revealed that he had been previously diagnosed with thoracic TB and had undergone an operation for a thoracic abscess four months prior. Since his diagnosis, the patient was treated with a multi-drug anti-TB regimen that included 300 mg/d isoniazid, 600 mg/d rifampicin, and 750 mg/d ethambutol.

The patient did not present with signs of any immunosuppressive diseases and a serological test for HIV was negative. Laboratory tests revealed the following:  $9.75 \times 10^9$  white blood cells (WBC)/L [reference range (RR):  $4.0 - 10.0 \times 10^9$  WBC/L], 30.5  $\mu\text{mol/L}$  total bilirubin (RR: 5.0 - 28.0  $\mu\text{mol/L}$ ), 24.5  $\mu\text{mol/L}$  direct bilirubin (RR:  $< 8.8 \mu\text{mol/L}$ ), 135 U/L alanine aminotransferase (RR:  $< 55$  U/L), 64 U/L aspartate aminotransferase (RR:  $< 46$  U/L), 715 U/L gamma glutamyl transpeptidase (RR: 6 - 46 U/L), 335 U/L alkaline phosphatase (RR: 47 - 138 U/L), and 66.84 U/mL carbohydrate antigen 199 (RR:  $< 22$  U/mL).

Computed tomography (CT) revealed a soft tissue shadow in the head of the pancreas. The lesion, which was necrotic and calcified, measured 5.6 cm  $\times$  4.2 cm and mimicked a pancreatic head carcinoma. CT images also revealed upstream biliary dilatation and multiple lymphadenopathies surrounding the head of pancreas, the vena cava and the liver artery. The celiac trunk and descending part of duodenum could not be clearly identified in the lesion, suggesting that the above areas were involved. A pancreatic neoplasm with multiple lymph node metastases was suspected after CT (Figure 1). A chest CT revealed small nodes in the superior lobe of the left lung and in

the lower lobes of both lungs. As the patient had a medical history of TB, the abdominal ultrasound taken four months prior was reexamined, but found to be unremarkable with the exception of steroid deposits in the gallbladder. Progressive discomfort in the patient's upper abdomen and the identification of a potential malignancy *via* CT led to the decision to operate and perform a biopsy.

Caseous necrosis and lymphadenectasis was observed during the biopsy procedure. Subsequently, a cholecystostomy tube was placed. Samples from the lymph nodes and biopsies of the mass were obtained for histopathologic examination. Ziehl-Neelsen staining revealed caseous granulomatous inflammation and necrosis with acid-fast bacilli (Figure 2). The presence of *Mycobacterium tuberculosis* DNA was confirmed within the biopsy samples by polymerase chain reaction (PCR). The patient was therefore administered the standard anti-TB therapy of 300 mg/d isoniazid, 600 mg/d rifampicin, 1.5 g/d pyrazinamide, and 750 mg/d ethambutol for nine months followed by six months of 300 mg/d isoniazid, 600 mg/d rifampicin, and 1.5 g/d pyrazinamide. The patient recovered quickly and was without abdominal pain during the 15 mo of treatment.

## DISCUSSION

Pancreatic TB is extremely rare, even in immunocompromised hosts, and this rarity is attributed to the resistance provided by the pancreatic enzymes<sup>[1,2]</sup>. Despite its rarity, pancreatic TB can occur even when patients are undergoing the standard anti-TB drug (ATD) regimen, as was demonstrated by the case reported here. A diverse spectrum of symptoms can arise during pancreatic TB, ranging from abdominal discomfort, obstructive jaundice, fever, loss of appetite or nausea, to night sweats and weight loss<sup>[3,4]</sup>. Imaging of the pancreas by ultrasound or CT has demonstrated that pancreatic TB can mimic a pancreatic neoplasm<sup>[4-6]</sup>. When this is the case, pancreatic head carcinoma must also be considered during the operation. We report the present case to emphasize alternate, though more rare, causes of pancreatic masses and obstructive

jaundice.

According to the literature, endoscopic ultrasound-guided fine needle aspiration biopsy (FNAB) and a PCR-based approach are recommended for pancreatic TB diagnosis<sup>[7-9]</sup>. However, FNAB is not always employed due to the increased risk for pancreatitis and tumor dissemination. Thus, an operation with an incisional biopsy represents a more specific diagnostic modality and an effective therapy for pancreatic abscesses. Current literature also promotes the use of standard ATD therapy for six to twelve months as an effective strategy to treat pancreatic TB in a majority of cases<sup>[1,2,7,10]</sup>. As pancreatic TB can occur during treatment, however, ATD may be an insufficient therapy for patients. In the present case, we feel that an operation accompanied by cholecystostomy tube placement aided in treating the patient.

In conclusion, the case report emphasizes a rare cause of pancreatic mass and obstructive jaundice, and shows that an operation and tube cholecystostomy in combination with ATD therapy are an effective treatment for pancreatic TB.

## COMMENTS

### Case characteristics

A 40-year-old male patient with a history of thoracic tuberculosis (TB) presented with epigastralgia and jaundice while receiving anti-TB therapy.

### Clinical diagnosis

An abdominal examination revealed sensitivity in the upper abdomen without hepatosplenomegaly or ascites.

### Differential diagnosis

Pancreatic carcinoma and pancreatitis.

### Laboratory diagnosis

The following laboratory results were obtained:  $9.75 \times 10^9$  white blood cells/L; 30.5  $\mu\text{mol/L}$  total bilirubin; 24.5  $\mu\text{mol/L}$  direct bilirubin; 135 U/L alanine aminotransferase; 64 U/L aspartate aminotransferase; 715 U/L gamma glutamyl transpeptidase; 335 U/L alkaline phosphatase; 66.84 U/mL carbohydrate antigen 199.

### Imaging diagnosis

Computed tomography revealed a necrotic and calcified cystic lesion in the head of the pancreas that measured 5.6 cm  $\times$  4.2 cm and resembled a pancreatic malignancy.

### Pathological diagnosis

Biopsies of the lymph nodes and mass revealed caseous granulomatous inflammation and necrosis with acid-fast bacilli; a polymerase chain reaction-based approach confirmed the presence of *Mycobacterium tuberculosis* DNA.

### Treatment

After surgery, the patient was administered the standard anti-TB regimen of isoniazid, rifampicin, pyrazinamide, and ethambutol for nine months followed by a regimen of isoniazid, rifampicin, and pyrazinamide for an additional six months.

### Related reports

TB is most often observed as necrotic granulomas within the lungs. Extrapulmonary TB, however, accounts for approximately 10%-30% of all cases and more than 5% of patients have abdominal involvement. In the abdominal cavity, TB predominantly affects the peritoneum, gastrointestinal tract (especially the ileum and

cecum), liver, spleen, and lymph nodes. Pancreatic TB is extremely rare, likely due to resistance provided by pancreatic enzymes, and may occur as a result of bacterial dissemination from lymph nodes in the area. Pancreatic TB is often confused with pancreatic malignancy in clinical and radiological examinations.

### Term explanation

TB is a disease caused by *Mycobacterium tuberculosis* bacteria. While the bacteria predominantly affect the lungs, they can also damage other parts of the body. Pancreatic TB occurs when these bacteria affect the pancreas. Pancreatic TB is extremely rare and can mimic a carcinoma, lymphoma or cystic neoplasia.

### Experiences and lessons

This case report highlights pancreatic TB as a rare cause of pancreatic masses and obstructive jaundice that can mimic pancreatic head carcinoma and be treated *via* tube cholecystostomy in combination with anti-TB therapy.

### Peer review

This article presented with the case report of a pancreatic TB which mimicking pancreatic head carcinoma in an immunocompetent host. After anti-tuberculin therapy, the patient recovered soon. This report is interesting and informative that provides useful information of rare disease as a cause of pancreatic masses and obstructive jaundice.

## REFERENCES

- 1 Meesiri S. Pancreatic tuberculosis with acquired immunodeficiency syndrome: a case report and systematic review. *World J Gastroenterol* 2012; **18**: 720-726 [PMID: 22363146 DOI: 10.3748/wjg.v18.i7.720]
- 2 Raghavan P, Rajan D. Isolated pancreatic tuberculosis mimicking malignancy in an immunocompetent host. *Case Rep Med* 2012; **2012**: 501246 [PMID: 22761624 DOI: 10.1155/2012/501246]
- 3 Hellara O, Noomène F, Toumi O. A pseudotumoral presentation of pancreatic tuberculosis. *J Visc Surg* 2012; **149**: e282-e283 [PMID: 22609280 DOI: 10.1016/j.jvisurg.2012.04.004]
- 4 Ozkan F, Bulbuloglu E, Inci MF, Sayar H, Kahraman H, Yuksel M. Isolated pancreatic tuberculosis mimicking malignancy and causing obstructive jaundice. *J Gastrointest Cancer* 2013; **44**: 118-120 [PMID: 22528321 DOI: 10.1007/s12029-012-9374-5]
- 5 Arora A, Mukund A, Garg H. Isolated pancreatic tuberculosis: a rare occurrence. *Am J Trop Med Hyg* 2012; **87**: 1-2 [PMID: 22764282 DOI: 10.4269/ajtmh.2012.12-0054]
- 6 Lee WK, Van Tonder F, Tartaglia CJ, Dagia C, Cazzato RL, Duddalwar VA, Chang SD. CT appearances of abdominal tuberculosis. *Clin Radiol* 2012; **67**: 596-604 [PMID: 22212637 DOI: 10.1016/j.crad.2011.11.003]
- 7 Cheng J, Tadi K, Halpern M, Feurdean M, McNelis J, Brensilver J. Pancreatic tuberculosis in a human immunodeficiency virus positive patient: a case report. *World J Gastroenterol* 2008; **14**: 939-940 [PMID: 18240354 DOI: 10.3748/wjg.14.939]
- 8 Arroyo Martínez Q, DeCruz P, Murugananthan A, Desmond P, Chen R. Endoscopic ultrasound-guided fine needle aspirate: a useful method in the diagnosis of pancreatic tuberculosis. *ANZ J Surg* 2012; **82**: 282-283 [PMID: 22510191 DOI: 10.1111/j.1445-2197.2012.06006.x]
- 9 Chatterjee S, Schmid ML, Anderson K, Oppong KW. Tuberculosis and the pancreas: a diagnostic challenge solved by endoscopic ultrasound. A case series. *J Gastrointest Liver Dis* 2012; **21**: 105-107 [PMID: 22457868]
- 10 Yavuz A, Buluş H, Aydın A, Coşkun A. Pancreatic tuberculosis mimicking inoperable pancreatic cancer. *Turk J Gastroenterol* 2012; **23**: 95-97 [PMID: 22505394]

P- Reviewers: Kawa S, Seleem MI, Zippi M S- Editor: Song XX

L- Editor: A E- Editor: Liu SQ



## Pneumomediastinum after acute lymphoblastic leukemia and chemotherapy?

Alain Cruz-Portelles

Alain Cruz-Portelles, Critical Care Medicine Department, V I Lenin University General Hospital, Holguin 80100, Cuba  
Author contributions: Cruz-Portelles A solely contributed to this paper.

Correspondence to: Alain Cruz-Portelles, MD, Critical Care Medicine Department, V I Lenin University General Hospital, Lenin Ave., No. 2, Holguin 80100, Cuba. [acruz2014@gmx.es](mailto:acruz2014@gmx.es)  
Telephone: +53-5-3140445 Fax: +53-5-3140445

Received: November 11, 2013 Revised: February 21, 2014

Accepted: March 17, 2014

Published online: May 16, 2014

developed pneumomediastinum, pneumorachis and subcutaneous emphysema, apparently caused by ALL or chemotherapy in the author's opinion, and eventually died.

Cruz-Portelles A. Pneumomediastinum after acute lymphoblastic leukemia and chemotherapy? *World J Clin Cases* 2014; 2(5): 170-171 Available from: URL: <http://www.wjgnet.com/2307-8960/full/v2/i5/170.htm> DOI: <http://dx.doi.org/10.12998/wjcc.v2.i5.170>

### Abstract

Pneumomediastinum, pneumorachis and subcutaneous emphysema are frequently benign and most commonly result from air escaping from the upper respiratory tract, intrathoracic airways, or gastrointestinal tract. Gas can also be generated by certain infections or reach the mediastinal space from outside air after trauma or surgery. In the article presented by Showkat *et al* a 14-year-old male patient with acute lymphoblastic leukemia (ALL) under chemotherapy developed pneumomediastinum, pneumorachis and subcutaneous emphysema. In the author's opinion, these complications were caused by ALL or chemotherapy that progressed to severe respiratory failure until the patient finally died in the intensive care unit. I would like to underline some important points, which have been raised following a paper published in the October issue of World Journal of Clinical Cases.

© 2014 Baishideng Publishing Group Inc. All rights reserved.

**Key words:** Acute lymphoblastic leukemia; Pneumomediastinum; Pneumorachis; Chemotherapy; Case report

**Core tip:** In the article presented by Showkat *et al*, the authors reported a 14-year-old male with acute lymphoblastic leukemia (ALL) under chemotherapy who

### TO THE EDITOR

I read with interest the article presented by Showkat *et al*<sup>[1]</sup>, where the authors reported a 14-year-old male under chemotherapy for acute lymphoblastic leukemia (ALL) who developed pneumomediastinum, pneumorachis and subcutaneous emphysema of apparently unknown origin. In this case, the doctors assumed that the cause was chemotherapy or ALL, but there are some points I would like to consider.

Pneumomediastinum or mediastinal emphysema is characterized by the entry of air or other gas into the mediastinum most commonly resulting from air escaping from the upper respiratory tract, intrathoracic airways, or gastrointestinal tract. Gas can also be generated by certain infections or reach the mediastinal space from outside air after trauma or surgery (Table 1)<sup>[2]</sup>.

This particular patient could have been suffering from an idiopathic cause of pneumomediastinum (Hamman's syndrome)<sup>[3]</sup>, and there are different processes that can explain this condition apart from ALL or chemotherapy: (1) patients who receive chemotherapy frequently vomit and this is a recognized cause of pneumomediastinum; and (2) pneumomediastinum *per se* is frequently benign but oxygenation in this patient was progressively deteriorating. What was the etiology of his respiratory arrest?

**Table 1 Etiology of pneumomediastinum**

Upper respiratory tract
Head and neck infections
Facial bone fractures
Dental procedures
Mucosal disruption
Tracheotomy
Lower respiratory airways
Chest trauma
Foreign body
Neoplasm
Alveolar rupture: trauma, biopsy, surgery, pleurotomy
Wind instrument playing
Scuba diving
Mechanical ventilation
Gastrointestinal tract
Pneumoperitoneum
Pneumoretroperitoneum
Esophageal perforation (e.g., Boerhaave's syndrome)
Gas producing germs infection
Bacterial mediastinitis
Head and neck infections
Marijuana smoking and cocaine inhalation
Vomiting
Seizures
Coughing, sneezing, hiccupping
Heavy lifting
Air travel
Heimlich maneuver

Did he develop a tension pneumothorax that could explain the respiratory arrest and the deteriorating respiratory condition? What happened while the patient was in the intensive care unit? What was the cause of death in this patient?

Pneumothorax in the supine patient may be difficult to diagnose and must be considered or it will be missed. Occasionally, tension pneumomediastinum may occur, although this is usually of greater clinical likelihood in

pediatric patients. Concomitant pulmonary interstitial emphysema will result in further respiratory embarrassment secondary to compression of lung parenchyma by interstitial air, and decreases in both ventilation and perfusion, especially after mechanical ventilation. Tension pneumopericardium could complicate the presentation and impair venous return and cardiac function<sup>[4]</sup>. Air embolism or pneumocephalus are infrequent but could be ruled out<sup>[4,5]</sup>. No computed tomography scans or X-rays were mentioned later in the evaluation. Different investigations are not clear in this case that could help in the diagnosis.

In my opinion, chemotherapy or ALL *per se* does not explain the mechanism of production of pneumomediastinum, pneumorachis or subcutaneous emphysema. This association was possibly a coexisting condition instead of a complication of ALL or chemotherapy as the authors affirm. Unfortunately, there was no autopsy to establish the final diagnosis.

## REFERENCES

- 1 **Showkat HI**, Jan A, Sarmast AH, Bhat GM, Jan BM, Bashir Y. Pneumomediastinum, pneumorachis, subcutaneous emphysema: An unusual complication of leukemia in a child. *World J Clin Cases* 2013; **1**: 224-226 [PMID: 24340272]
- 2 **Park DR**, Vallières E, Pneumomediastinum and Mediastinitis. In: Mason RJ, Broadduss VC, editors. *Murray and Nadel's textbook of respiratory medicine*, 5th Edition. Philadelphia: Saunders, Elsevier, 2010: 1836-1844
- 3 **Hamman L**. Spontaneous interstitial emphysema of the lungs. *Tr Assoc Am Physicians* 1937; **52**: 311-319
- 4 **Maunder RJ**, Pierson DJ, Hudson LD. Subcutaneous and mediastinal emphysema. Pathophysiology, diagnosis, and management. *Arch Intern Med* 1984; **144**: 1447-1453 [PMID: 6375617]
- 5 **Beauchamp G**, Ouellette D. Spontaneous pneumothorax and pneumomediastinum]. *J Thoracic Surg* 2002; **2**: 1202-1206

**P- Reviewers:** Drut R, Pellier I **S- Editor:** Zhai HH

**L- Editor:** Cant MR **E- Editor:** Liu SQ





# World Journal of *Clinical Cases*

*World J Clin Cases* 2014 June 16; 2(6): 172-239





## Contents

Monthly Volume 2 Number 6 June 16, 2014

### REVIEW

- 172 Role of human papillomavirus in oropharyngeal squamous cell carcinoma: A review  
*Woods RSR, O'Regan EM, Kennedy S, Martin C, O'Leary JJ, Timon C*

### MINIREVIEWS

- 194 Therapeutic strategies for targeting the ovarian tumor stroma  
*Ko SY, Naora H*
- 201 Concurrent stenoses: A common etiology of stroke in Asians  
*Man BL, Fu YP*

### CASE REPORT

- 206 Case of early right ventricular pacing lead perforation and review of the literature  
*Nash G, Williams JM, Nekkanti R, Movahed A*
- 209 Perforated jejunal ulcer associated with gastric mucosa in a jejunal diverticulum  
*Bunni J, Barrett HL, Cook TA*
- 211 Abnormal electrocardiogram in a patient with amyotrophic lateral sclerosis mimicking myocardial ischaemia  
*Martínez J, Ramón C, Morís C, Pascual J, Morís G*
- 215 Pyonephrosis as a sign of sarcomatoid carcinoma of the renal pelvis  
*Fernández-Pello S, Venta V, González I, Gil R, Menéndez CL*
- 219 Two-level reconstruction of isolated fracture of the lesser tuberosity of the humerus  
*Nikolaou VS, Chytas D, Tyrpenou E, Babis GC*
- 224 Simultaneous bilateral robotic partial nephrectomy: Case report and critical evaluation of the technique  
*Giberti C, Gallo F, Schenone M, Cortese P*
- 228 Cabazitaxel in castration resistant prostate cancer with brain metastases: 3 case reports  
*De Placido S, Rescigno P, Federico P, Buonerba C, Bosso D, Puglia L, Izzo M, Policastro T, Di Lorenzo G*



- 232 Gastrointestinal perforation due to incarcerated Meckel's diverticulum in right femoral canal

*Yagmur Y, Akbulut S, Can MA*

**CLINICOPATHOLOGICAL  
CONFERENCE**

- 235 Facial nerve palsy, headache, peripheral neuropathy and Kaposi's sarcoma in an elderly man

*Daoussis D, Chroni E, Tsamandas AC, Andonopoulos AP*

## Contents

*World Journal of Clinical Cases*  
Volume 2 Number 6 June 16, 2014

**APPENDIX** I-V Instructions to authors

**ABOUT COVER** Editorial Board Member of *World Journal of Clinical Cases*, Robbie Seton Rowan Woods, BA, MB, BCh, BAO, Department of Surgery, St. James's Hospital, James's Street, Dublin 8, Ireland

**AIM AND SCOPE** *World Journal of Clinical Cases* (*World J Clin Cases*, *WJCC*, online ISSN 2307-8960, DOI: 10.12998) is a peer-reviewed open access academic journal that aims to guide clinical practice and improve diagnostic and therapeutic skills of clinicians.

The primary task of *WJCC* is to rapidly publish high-quality Autobiography, Case Report, Clinical Case Conference (Clinicopathological Conference), Clinical Management, Diagnostic Advances, Editorial, Field of Vision, Frontier, Medical Ethics, Original Articles, Clinical Practice, Meta-Analysis, Minireviews, Review, Therapeutics Advances, and Topic Highlight, in the fields of allergy, anesthesiology, cardiac medicine, clinical genetics, clinical neurology, critical care, dentistry, dermatology, emergency medicine, endocrinology, family medicine, gastroenterology and hepatology, geriatrics and gerontology, hematology, immunology, infectious diseases, internal medicine, obstetrics and gynecology, oncology, ophthalmology, orthopedics, otolaryngology, pathology, pediatrics, peripheral vascular disease, psychiatry, radiology, rehabilitation, respiratory medicine, rheumatology, surgery, toxicology, transplantation, and urology and nephrology.

**INDEXING/ABSTRACTING** *World Journal of Clinical Cases* is now indexed in PubMed Central, PubMed, Digital Object Identifier.

**FLYLEAF** I-V Editorial Board

## EDITORS FOR THIS ISSUE

Responsible Assistant Editor: *Xiang Li*  
Responsible Electronic Editor: *Huan-Liang Wu*  
Proofing Editor-in-Chief: *Lian-Sheng Ma*

Responsible Science Editor: *Ling-Ling Wen*  
Proofing Editorial Office Director: *Xiu-Xia Song*

**NAME OF JOURNAL**  
*World Journal of Clinical Cases*

**ISSN**  
ISSN 2307-8960 (online)

**LAUNCH DATE**  
April 16, 2013

**FREQUENCY**  
Monthly

**EDITORS-IN-CHIEF**  
**Giuseppe Di Lorenzo, MD, PhD, Professor**, Genitourinary Cancer Section and Rare-Cancer Center, University Federico II of Napoli, Via Sergio Pansini, 5 Ed. 1, 80131, Naples, Italy

**Jan Jacques Michiels, MD, PhD, Professor**, Primary Care, Medical Diagnostic Center Rijnmond Rotterdam, Bloodcoagulation, Internal and Vascular Medicine, Erasmus University Medical Center, Rotterdam, Goodheart Institute and Foundation, Erasmus Tower, Veenmos 13, 3069 AT, Erasmus City, Rotterdam, The Netherlands

**Sandro Vento, MD**, Department of Internal Medicine, University of Botswana, Private Bag 00713, Gaborone,

Botswana

**Shuhei Yoshida, MD, PhD**, Division of Gastroenterology, Beth Israel Deaconess Medical Center, Dana 509, Harvard Medical School, 330 Brookline Ave, Boston, MA 02215, United States

**EDITORIAL OFFICE**  
Jin-Lei Wang, Director  
Xiu-Xia Song, Vice Director  
*World Journal of Clinical Cases*  
Room 903, Building D, Ocean International Center, No. 62 Dongsihuan Zhonglu, Chaoyang District, Beijing 100025, China  
Telephone: +86-10-85381891  
Fax: +86-10-85381893  
E-mail: [editorialoffice@wjgnet.com](mailto:editorialoffice@wjgnet.com)  
Help Desk: <http://www.wjgnet.com/esp/helpdesk.aspx>  
<http://www.wjgnet.com>

**PUBLISHER**  
Baishideng Publishing Group Inc  
8226 Regency Drive,  
Pleasanton, CA 94588, USA  
Telephone: +1-925-223-8242  
Fax: +1-925-223-8243  
E-mail: [bpgoffice@wjgnet.com](mailto:bpgoffice@wjgnet.com)  
Help Desk: <http://www.wjgnet.com/esp/helpdesk.aspx>

<http://www.wjgnet.com>

**PUBLICATION DATE**  
June 16, 2014

**COPYRIGHT**  
© 2014 Baishideng Publishing Group Inc. Articles published by this Open Access journal are distributed under the terms of the Creative Commons Attribution Non-commercial License, which permits use, distribution, and reproduction in any medium, provided the original work is properly cited, the use is non commercial and is otherwise in compliance with the license.

**SPECIAL STATEMENT**  
All articles published in journals owned by the Baishideng Publishing Group (BPG) represent the views and opinions of their authors, and not the views, opinions or policies of the BPG, except where otherwise explicitly indicated.

**INSTRUCTIONS TO AUTHORS**  
Full instructions are available online at [http://www.wjgnet.com/2307-8960/g\\_info\\_20100722180909.htm](http://www.wjgnet.com/2307-8960/g_info_20100722180909.htm)

**ONLINE SUBMISSION**  
<http://www.wjgnet.com/esp/>



## Role of human papillomavirus in oropharyngeal squamous cell carcinoma: A review

Robbie SR Woods, Esther M O'Regan, Susan Kennedy, Cara Martin, John J O'Leary, Conrad Timon

Robbie SR Woods, Conrad Timon, Department of Otolaryngology, Royal Victoria Eye and Ear Hospital, Dublin 2, Ireland  
Esther M O'Regan, John J O'Leary, Department of Histopathology, St. James's Hospital, Dublin 8, Ireland  
Susan Kennedy, Department of Histopathology, Royal Victoria Eye and Ear Hospital, Dublin 2, Ireland  
Cara Martin, John J O'Leary, Molecular Pathology Research, Coombe Women and Infants University Hospital, Dublin 8, Ireland

Author contributions: Timon C initiated the project and contributed to the clinical aspects of the paper; O'Regan EM, Kennedy S, Martin C and O'Leary JJ designed the research and contributed to the separate headings in the paper; Woods RSR wrote the paper; Timon C, O'Regan EM, Kennedy S, Martin C and O'Leary JJ revised the article and approved the final version.

Correspondence to: Robbie SR Woods, BA, MB, BCh, BAO, MRCSI, MCh, Department of Otolaryngology, Royal Victoria Eye and Ear Hospital, Adelaide Road, Dublin 2, Ireland. [robbiewoods@rcsi.ie](mailto:robbiewoods@rcsi.ie)

Telephone: +353-1-6644600 Fax: +353-1-6761858

Received: March 2, 2014 Revised: April 21, 2014

Accepted: May 16, 2014

Published online: June 16, 2014

### Abstract

Human papillomavirus (HPV) has been implicated in the pathogenesis of a subset of oropharyngeal squamous cell carcinoma. As a result, traditional paradigms in relation to the management of head and neck squamous cell carcinoma have been changing. Research into HPV-related oropharyngeal squamous cell carcinoma is rapidly expanding, however many molecular pathological and clinical aspects of the role of HPV remain uncertain and are the subject of ongoing investigation. A detailed search of the literature pertaining to HPV-related oropharyngeal squamous cell carcinoma was performed and information on the topic was gathered. In this article, we present an extensive review of the current literature on the role of HPV in oropharyngeal squamous cell carcinoma, particularly in relation to epidemiology, risk factors, carcinogenesis, biomarkers and clinical

implications. HPV has been established as a causative agent in oropharyngeal squamous cell carcinoma and biologically active HPV can act as a prognosticator with better overall survival than HPV-negative tumours. A distinct group of younger patients with limited tobacco and alcohol exposure have emerged as characteristic of this HPV-related subset of squamous cell carcinoma of the head and neck. However, the exact molecular mechanisms of carcinogenesis are not completely understood and further studies are needed to assist development of optimal prevention and treatment modalities.

© 2014 Baishideng Publishing Group Inc. All rights reserved.

**Key words:** Human papillomavirus; Human papillomavirus; Oropharynx; Oropharyngeal; Squamous cell carcinoma; Head and neck; Oncology

**Core tip:** Human papillomavirus has been accepted as a causative agent in a subset of head and neck squamous cell carcinoma (SCC), particularly of the tonsils and base of tongue. Importantly, there is an increasing incidence of this subset of patients, who demonstrate improved prognosis and may respond more favourably to treatment. Similarities and differences are evident between cervical and oropharyngeal human papillomavirus-related SCCs and the comparison between these tumours warrants further investigation to better understand the disease process.

Woods RSR, O'Regan EM, Kennedy S, Martin C, O'Leary JJ, Timon C. Role of human papillomavirus in oropharyngeal squamous cell carcinoma: A review. *World J Clin Cases* 2014; 2(6): 172-193 Available from: URL: <http://www.wjgnet.com/2307-8960/full/v2/i6/172.htm> DOI: <http://dx.doi.org/10.12998/wjcc.v2.i6.172>

### INTRODUCTION

Head and neck squamous cell carcinoma (HNSCC) is

Epidemiology	Increasing incidence of HPV-related oropharyngeal SCC Most cases attributable to HPV-16
Risk factors	HPV-related SCCs associated with younger age at presentation, sexual behaviours, oral HPV infection immunodeficiency, male gender and higher socio-economic status
Carcinogenesis	Distinct molecular genetic alterations mediated by E6 and E7 oncoproteins, similar to cervical SCC Affected downstream pathways similar to non HPV-related SCC
Biomarkers	Controversy over the use of p16 as a surrogate biomarker Findings in many of the studies on biomarkers have been inconsistent or contradictory
Clinical implications	HPV-related oropharyngeal SCCs represent a different clinical entity with potential for de-escalation of therapy The effects of prophylactic HPV vaccination on oropharyngeal SCC remain unclear

**Figure 1 Summary of key points.** HPV: Human papillomavirus; SCC: Squamous cell carcinoma.

the sixth most common type of cancer worldwide with approximately 633000 new cases diagnosed and 355000 deaths annually<sup>[1]</sup>. Over the past 10-15 years, the traditional paradigms of HNSCC have been changing significantly. It has emerged as a heterogeneous group of diseases, with distinct molecular genetic changes<sup>[2,3]</sup>.

Human papillomavirus (HPV) has been linked to the pathogenesis of squamous cell carcinoma (SCC) since the 1970s<sup>[4]</sup> and, in 1995, it was recognised by the International Agency for Research on Cancer (IARC) that high risk HPV types 16 and 18 were carcinogenic in humans<sup>[5]</sup>. The role of HPV in cervical cancer is well described<sup>[6]</sup>, however high risk HPV types are also linked with other ano-genital tumours and with SCCs of the head and neck<sup>[7,8]</sup>, as well as potentially playing a role in cutaneous SCCs<sup>[9]</sup>. HPV accounts for roughly 4.8%-5.2% of the total global cancer burden, making it the highest among all viruses<sup>[10,11]</sup>.

Since it was first suggested in 1983<sup>[12]</sup> and first identified in 1985<sup>[13]</sup>, HPV infection has been increasingly recognized as a major aetiological factor for HNSCCs, particularly a subset that arise from the oropharynx, mostly the base of tongue and palatine tonsils<sup>[14-16]</sup>. This subset is seen as a distinct clinicopathological entity in comparison to the traditional smoking and alcohol related HNSCCs<sup>[16-20]</sup>. Specific genetic changes induced through HPV E6 and E7 protein expression define this subset<sup>[21-23]</sup>. In contrast, tobacco associated HNSCCs are usually more genetically diverse<sup>[24]</sup>. HPV-related tumours of the oropharynx display specificity of HPV to the tumour cell nuclei<sup>[16]</sup>, integration of HPV DNA into the host cell<sup>[16,25]</sup> and high viral copy numbers<sup>[26]</sup>, giving evidence for the functional role of HPV in the pathogenesis of these tumours.

HPV-related SCC tends to display unique histology characterized by poorly differentiated, non-keratinising morphology with a basaloid appearance<sup>[17,27]</sup>. Nevertheless, even some true basaloid squamous cell carcinomas

of the oropharynx have demonstrated HPV-positivity<sup>[28]</sup>, and other variants such as papillary SCC, adenosquamous carcinoma, lymphoepithelial carcinoma-like tumours and small cell carcinoma have been associated with HPV infection<sup>[29-34]</sup>.

It is estimated that the probability of a cancer of the oropharynx being attributable to HPV is five times higher than the oral cavity, larynx or hypopharynx<sup>[35]</sup>, with HPV-related oropharyngeal SCC being described as an epidemic<sup>[36-40]</sup>. Current data from studies that assessed *in situ* hybridization or HPV E6/E7 mRNA suggest that HPV-related HNSCC is rare in the oral cavity, larynx, hypopharynx and other HNSCC sites<sup>[35]</sup>, however the role of HPV in non-oropharyngeal sites remains unclear<sup>[41]</sup> and a causative relationship at these sites has not been established<sup>[42]</sup>.

We review the current literature regarding HPV-related oropharyngeal tumours with regard to epidemiology, risk factors, carcinogenesis, biomarkers and clinical implications. A summary is shown in Figure 1.

## HUMAN PAPILLOMAVIRIDIAE

HPV is an epitheliotropic, non-enveloped DNA virus measuring approximately 55 nm in diameter, and carries a single molecule of circular double-stranded DNA, consisting of approximately 8000 base pairs<sup>[43]</sup>. The genome is broken down into three regions which consist of a long control region (LCR), an early (E) region and a late (L) region. There are eight genes in the E region and two in the L region. These genes in E and L encode viral proteins while LCR is an upstream non-coding regulatory region containing the origin of viral DNA replication and transcriptional regulatory elements.

At present, over 200 different genotypes of papillomaviridae, characterized by at least 10% nucleotide divergence in capsid gene (*L1*)<sup>[44]</sup>, have been identified by various techniques<sup>[45]</sup>. These can be classified according to similarities in their DNA sequences. They have also been grouped into mucosal (mostly of the alpha genus) or cutaneous (mostly of the beta genus) types based on their tropism for specific epithelia and they can be classified into low and high risk types based on their capacity to promote malignant transformation in host cells. Of these, HPV 16, 18, 31, 33, 34, 35, 39, 45, 51, 52, 56, 58, 59, 66, 68, 73 and 82 are examples of those classified as high risk viruses, detectable in high grade squamous intraepithelial lesions in the cervix or in invasive cancer; while HPV 6, 11, 40, 42, 43, 44, 54, 61, 72, 81, and 89 can be considered as viruses with low oncogenic risk and can be isolated from low grade epithelial lesions of the cervix. There remain a number of HPV types that are potentially high risk with an unknown oncogenic potential. There exists some degree of intratypic variation<sup>[46,47]</sup>, which may also relate to pathogenesis<sup>[48-50]</sup>, as well as geographic variation in genotype prevalence<sup>[46,51]</sup>.

HPV is one of the most powerful human carcinogens. The E6 and E7 genes produce E6 and E7 oncoproteins,

which confer the virus with oncogenic potential through their inhibitory effects on p53 and retinoblastoma (Rb) proteins, more of which is discussed later.

## EPIDEMIOLOGY

HNSCC includes tumours from a number of subsites, of which the oropharynx accounts for approximately 10%<sup>[52]</sup>. Worldwide, there were an estimated 85000 new cases of oropharyngeal SCC in 2008, of which 25.6% (22000) were estimated to be HPV-related<sup>[53]</sup>. Of the HPV-related cases, more than three quarters (17000) were estimated to be male.

Genotypes of oncogenic HPV found in cervical cancer in order of prevalence are 16, 18, 58, 33, 45, 31, 52, 35, 59, 39, 51 and 56<sup>[54]</sup>. However, the distribution of HPV types differs somewhat in oropharyngeal when compared to cervical cancers<sup>[55]</sup>. A systematic review found that HPV-16 was present in 95.7% of HPV-related oropharyngeal SCC, but only 73.9% of HPV-positive non-oropharyngeal HNSCCs<sup>[56]</sup>, while only approximately 61% of cervical cancer display HPV-16<sup>[57]</sup>. While a significant number of other oncogenic HPV types are found in cervical cancer, only a small proportion of oropharyngeal cancers may be caused by additional HPV types such as 18, 31, 33, 35, 52 and 58<sup>[58,59]</sup>. HPV-16 is the commonest genotype found in oral cavity infection<sup>[60]</sup>, while it constitutes over 90% of the genotype distribution in tonsil cancers<sup>[61]</sup>.

Prevalence of oral high risk HPV infection in the general population is reported at 3.5%-3.7%<sup>[62,63]</sup>, with higher rates for those also infected with HIV<sup>[64]</sup>. A systematic review of the literature in 2005 reported detection of HPV DNA in 35.6% of oropharyngeal tumours<sup>[65]</sup>. However, there exists a wide geographic variation, with a reported prevalence as high as 72%<sup>[59]</sup> in North America compared to 17% in southern Europe<sup>[53]</sup>, 12.6% in Taiwan<sup>[66]</sup> and even as low as 4.4% reported in central Europe and Latin America<sup>[67]</sup>. Some of these figures are based on the assumption that detection of high-risk HPV DNA in tumour tissue signifies cancer attributable to HPV, however this does not delineate from the effects of tobacco exposure and alcohol in these cases. It has been recorded that HPV accounts for approximately 7.7% and 2.2% of all cancer cases in developing and developed countries, respectively<sup>[10]</sup>. The variations could partly be explained by geographic and temporal heterogeneity in sexual behaviours and tobacco exposure<sup>[41]</sup>. A more recent systematic review in 2012 reported a prevalence of HPV in oropharyngeal SCC of 59.9% in the United States, compared to 39.7% in Europe and 32.5% in the rest of the world<sup>[56]</sup>. There are limited data from less developed regions, but the incidence appears much lower.

Despite the variation in prevalence, case control studies conducted around the world show strong and consistent associations of markers of HPV exposure with risk of oropharyngeal cancers, even after adjustment for important HNSCC risk factors such as age, gender and

tobacco and alcohol use<sup>[41]</sup>.

While incidence of other HNSCCs has decreased over the past two decades, correlating with decreased tobacco use, the age-adjusted incidence of oropharyngeal SCC has been increasing in this same period<sup>[68,69]</sup>, particularly of the base of tongue and tonsil region<sup>[70]</sup>. Meanwhile the population-level incidence of HPV positive oropharyngeal SCC increased by 225% between 1988 and 2004, with a concomitant decline by 50% for HPV-negative oropharyngeal SCC<sup>[59]</sup>. A particularly steep rise of over 70% has been reported for prevalence of HPV-related oropharyngeal SCC in the past decade, with prevalence in Europe increasing at a faster rate than North America<sup>[56]</sup>. This rise further emphasises the predilection of HPV for the oropharynx and suggests that it plays a less significant role in other HNSCCs.

With the rise in HPV-related oropharyngeal SCC coupled with the decline of HPV-related cervical SCC, it has been suggested that the annual numbers of HPV-related oropharyngeal cases could soon surpass that of cervical cancer<sup>[41]</sup>.

## RISK FACTORS

HNSCCs, including those of the oropharynx, have traditionally been strongly associated with patients who have a long history of heavy smoking and alcohol consumption, with previous studies clearly showing a dose-response relationship with the frequency and duration of tobacco and alcohol exposure<sup>[71]</sup>. Age of onset is generally in an older age group (usually seventh decade) in these traditional HPV-negative oropharyngeal SCCs. Other risk factor associations with these tumours include poor oral hygiene<sup>[72,73]</sup>, a diet low in fruit and vegetable consumption<sup>[74,75]</sup> and chronic inflammatory disease in the oral cavity<sup>[76-78]</sup>.

### Age

The distinct subset of HPV-positive oropharyngeal SCCs generally present at a younger age, averaging a few years lower than HPV-negative tumours<sup>[39]</sup>. Although phenotypically similar to those in older patients, HNSCCs developing in younger patients are undoubtedly different at a genetic level with both germline and somatic differences seen<sup>[3,79-82]</sup>. One study showed that patients under 55 had a 3.4-fold higher risk of infection with carcinogenic HPV<sup>[83]</sup>, while a strong association has been demonstrated with HPV-16 infection and tonsillar cancer in males under 40 years old<sup>[84]</sup>. Increasing incidence of oropharyngeal SCC is seen in those aged under 60<sup>[85]</sup>, with a particularly steep rise seen between the ages of 50-59<sup>[86]</sup>, although it is possible this may be due to other risk factor exposures in this birth cohort.

### Sexual behaviours

HPV-related oropharyngeal SCCs also show strong associations with sexual behaviours, correlating with disease<sup>[87]</sup>. In a large number of studies, both HPV-positive



HNSCCs and oropharyngeal SCCs have been strongly associated in comparison to other HNSCCs with number of lifetime sexual partners, number of vaginal, oral and anal sexual partners, young age at first intercourse/earlier sexual contact and history of sexually transmitted diseases, including genital warts<sup>[27,83,87-93]</sup>. After adjusting for HPV-16 serology, the associations in a case-control series were no longer significant, suggesting that sexual behaviours can be seen as a surrogate for HPV-16 exposure<sup>[27]</sup>.

Data from a number of developed countries show that markers of high-risk sexual behaviours, such as earlier ages of sexual debut, practice of premarital sex, average number of lifetime partners, and practice of oral sex, have all increased among recent birth cohorts<sup>[94]</sup>.

### Oral HPV infection

Oral HPV is predominantly acquired *via* sexual transmission and oral HPV prevalence has been associated with some of the above sexual behaviours. Studies have demonstrated increased HPV acquisition around sexual debut with oral HPV prevalence of 1.5% in 12-15 year olds, 3.3% in 16-20 year olds and 4.5%-6.9% in healthy adults<sup>[62,63,89,95]</sup>. Higher oral HPV prevalence has been reported in women with cervical HPV infection<sup>[96,97]</sup>, and people infected with Human Immunodeficiency Virus (HIV)<sup>[96,98]</sup>. Several studies and some case reports have described concordant oral HPV infection between couples<sup>[99-102]</sup>, however preliminary results from the HPV oral transmission study in partners over time (HOTSPOT) have not backed up these findings.

It has even been suggested that non-sexual HPV transmission through kissing may be possible<sup>[95,103]</sup>, as well as intrapartum transmission<sup>[104]</sup> and transmission during laser surgery<sup>[105]</sup>. In itself, oral HPV-16 infection is a strong risk factor for oropharyngeal cancer, while the relationship is not necessarily clear for oral SCCs<sup>[106,107]</sup>. However, oral HPV prevalence is lower than cervical, perhaps explained by a lower proportion in oral-genital than genital-genital partners<sup>[55]</sup>, but the natural history of HPV infection in the oral cavity appears similar to cervical infections<sup>[108]</sup>. Although type-specific concordance is low, HPV infection of the cervix and oral cavity are not independent<sup>[109]</sup> and so cervical HPV infection could be considered a risk factor for oral cavity HPV infection. Although the full natural history of HPV infection in the oral cavity and oropharynx is not entirely understood, there is an estimated incidence of 4.4% per year with most infections being cleared within one year<sup>[110]</sup>. However, changing sexual practices are potentially leading to higher rates of infection that could become recalcitrant to immune responses.

### Tobacco and alcohol exposure

Evidence of a role for tobacco exposure and alcohol use in HPV-related oropharyngeal SCCs and in oral HPV infection is equivocal, with some studies reporting positive association and suggesting smoking-induced immunosuppression or potentiation of carcinogenesis could play a role, while others report no association<sup>[41]</sup>. A role for

tobacco smoking in cervical cancer, however, has been demonstrated, although this association becomes weak after adjustment for sexual and reproductive factors<sup>[111]</sup>. In comparison to traditional HNSCCs, these patients are less likely to have excessive tobacco exposure and alcohol use<sup>[16,88,112]</sup>, however HPV-related oropharyngeal SCCs do occur in both in those with tobacco exposure and alcohol use and in those without. It is highly plausible that tobacco exposure potentiates the effects of HPV carcinogenesis<sup>[113]</sup> but a role in the causation of HPV-related oropharyngeal SCCs has not been definitively determined from available evidence<sup>[35]</sup>. Marijuana use has also been associated with oropharyngeal SCCs<sup>[87,114]</sup>, however after adjustment for sexual behaviour variables in one study, this disappeared<sup>[62]</sup>.

### Gender

Both HPV-related and non HPV-related HNSCC exhibit male predominance at a ratio of approximately 3:1. In tobacco and alcohol related HNSCC, this difference has decreased particularly as trends in smoking have changed, with 43% of men and 30% of women smoking in 1974 compared to 26% of men and 21% of women in 2000<sup>[115]</sup>. Nonetheless, the difference still remains for HPV-related HNSCC and the reason for this is uncertain. The male predominance exhibited cannot be fully explained by difference in sexual behaviours, which suggests potential biologic differences between men and women<sup>[41,116]</sup>, or that some male characteristic preferentially predisposes to cancer of the oropharynx<sup>[117]</sup>. It has been suggested that hormonal differences<sup>[55,118]</sup> or the potential protective immunity from seroconversion in response to cervical HPV infections among women<sup>[119,120]</sup> may play a role. Although not all studies agree<sup>[63]</sup>, the majority of studies report that oral HPV infection is more common in men than women<sup>[62,121,122]</sup>. It has also been suggested that transmissibility of oral HPV may be higher for men performing oral sex on women, possibly due to a higher HPV copy number in the vagina/cervix<sup>[94]</sup>.

### Immunodeficiency

Immunodeficiency is a risk factor for a large number of tumours and HPV-related oropharyngeal SCC is included in that. For example, it is reported that patients infected with human immunodeficiency virus (HIV) have a 2-6 times increased risk of HPV-related HNSCC<sup>[123,124]</sup>, although they are at greater risk of ano-genital SCCs than oropharyngeal<sup>[125]</sup>. It has been demonstrated in cervical cancer patients that immunosuppression leads to HPV persistence and disease progression<sup>[126-128]</sup>. The association of a deficient immune system with increased HPV-related HNSCC may partly explain any potential association with tobacco exposure due to the immunosuppressive effects of smoking<sup>[129]</sup>, with one paper demonstrating a reduced antibody response in smokers<sup>[130]</sup>.

### Socio-economic status

HNSCCs have been associated with patients from a low socio-economic group for many years<sup>[131]</sup>. However, HPV-



related oropharyngeal SCCs are associated with patients who are from a higher socio-economic group and who have a better performance status<sup>[132,133]</sup>, although this has been refuted in one study<sup>[116]</sup>. Nonetheless, white males seem to be particularly at risk, with a rise in incidence reported in this group alone<sup>[59,85,116]</sup>. HPV positivity in oropharyngeal cancer is lower in African Americans than in other racial groups, with poorer survival in this racial group from oropharyngeal SCC, because a higher proportion is related to tobacco and alcohol exposure<sup>[134,135]</sup>.

### HPV serology

There is a strong association between serologic evidence of HPV infection and HNSCC risk, even after adjustment for other HNSCC risk factors<sup>[106]</sup>. One study has even shown a temporal association, with pre-diagnostic serum samples from ten years prior that were positive for HPV-16 capsid antibodies conferring an increased risk of oropharyngeal SCC of 14.4<sup>[136]</sup>, while patients with pre-diagnostic E6 seropositivity had a significantly higher risk of oropharyngeal cancer in another study<sup>[137]</sup>.

It is evident that a number of factors can facilitate or increase the risk of HPV-related oropharyngeal SCCs. This includes oral HPV infection, male gender, younger age, white race, immunosuppression and a variety of sexual behaviours. Differences in sexual behaviours across age and gender and consequent HPV exposure risk could account for the rapidly increasing incidence of HPV-related oropharyngeal SCCs among younger patients. Interestingly a separate specific subgroup of younger females with non HPV-related oral cavity SCCs has also been identified<sup>[138]</sup>.

## CARCINOGENESIS

The model for development of SCC involves exposure to carcinogens over time leading to progressive genetic and epigenetic changes that accumulate and lead to premalignant and eventually malignant lesions. However, HNSCC is a heterogeneous disease with a number of subtypes described, based on histological appearance, and supported by different gene expression profiles<sup>[139,140]</sup>. Squamous cell carcinomas from different sites in the body share a number of molecular characteristics but recent whole-exome sequencing<sup>[141-144]</sup> has helped to characterise the specific molecular pathogenesis of HNSCC with roles identified for tumour suppressor pathways including p53, Rb/INK4/ARF and NOTCH<sup>[145]</sup>. A role for cancer stem cells in HNSCC is likely, based on recent evidence<sup>[146-149]</sup>, and further study of these progenitor cells will help to elucidate mechanisms of carcinogenesis.

Recent deep-sequencing studies on the HNSCC on-genome have demonstrated a vast number of diverse genetic alterations, however most of these converge on four targetable molecular pathways<sup>[150]</sup>; mitogenic signalling and in particular amplification or up-regulation of epidermal growth factor receptor (EGFR) and the downstream pathway of phosphoinositide 3-kinase (PI3K)/mTOR as well as PTEN inactivation, each leading to

pathways involving proliferation, DNA repair, survival and spread; defective differentiation involving NOTCH signalling alterations; cell cycle de-regulation involving inactivation of CDKN2A (encoding p16 INK4A) tumour suppressor gene and CCND1 (encoding CYCLIN D1) amplification; genomic instability involving loss of TP53, which occurs in a large percentage of non HPV-related HNSCC and is the single most common mutational event, and other genes related to DNA damage recognition and repair. It is possible that smoking and alcohol affect distinct genes<sup>[151]</sup>, giving further evidence for a synergistic effect of tobacco and alcohol exposure in relation to HNSCC carcinogenesis.

HNSCC usually displays field cancerisation, a term first coined in 1953<sup>[152]</sup>, whereby specific genetic alterations can be widely distributed throughout the mucosa lining the aerodigestive tract even in the absence of overt histopathologic changes of malignancy<sup>[25]</sup>. Only a minority of precancerous fields in the oral cavity are recognised as leukoplakia or erythroplakia<sup>[153]</sup> and only 6%-36% of patients with leukoplakia or erythroplakia go on to develop oral SCC<sup>[154]</sup>, particularly those demonstrating aneuploidy<sup>[155,156]</sup>. The accumulation of further genetic changes in precancerous fields leads to the development of SCC, with presence of field change leading to a higher risk of multiple synchronous or metachronous primary tumours. Exposure to carcinogens bring about these field changes, however evidence for a field effect is lacking for HPV-related SCC<sup>[157]</sup> and the risk of second primary malignancy in oropharyngeal SCC has markedly decreased over time<sup>[158]</sup>, with the mutation rate of HPV-positive tumours only approximately half of that found in HPV-negative HNSCC<sup>[141,142]</sup>.

Specific differences in chromosomal alteration and gene transcription have been identified between HPV and non HPV-related HNSCCs<sup>[21,22,159,160]</sup>. TP53 mutations, loss of 9p21, hypermethylation of 14-3-3σ and RASS-F1A promoters and overexpression of cyclin D are all common in non HPV-related oropharyngeal SCCs, while pRb levels are normal and p16 is often decreased<sup>[161,162]</sup>.

In the cervix, after initial infection at the transformation zone, viral genomes are maintained as episomes in the basal layer, with viral gene expression being tightly controlled as the infected cells move toward the epithelial surface<sup>[163]</sup>. Subsequent high-grade neoplasia represents an abortive infection in which viral gene expression becomes deregulated and the normal life cycle of the virus cannot be completed. The squamous epithelium in the cervix and the head and neck derive embryologically from endoderm and are susceptible to metaplasia<sup>[164]</sup>. In the head and neck, there is a predilection for HPV-positive tumours to occur in the reticular crypt epithelium of palatine and lingual tonsils and head and neck sites with mucosa associated lymphoid tissue<sup>[25,165,166]</sup>. It is possible that this occurs due to the particular microanatomy of the crypts, where there are breaks in the non-keratinising squamous epithelium that could allow viral entry, while a microabrasion theory of entry to basal cells at other head and neck sites has been proposed. Entry may be facilitat-

ed by M-cells lining the crypt epithelium<sup>[167]</sup>, as with other viruses<sup>[168,169]</sup>. Another theory postulated is an influence on HPV carcinogenesis from increased cytokines related to nearby lymphoid tissue<sup>[170]</sup>. The recent observation of a distinct set of embryonic cells at the squamocolumnar junction of the cervix, which seem to confer a particularly high risk of malignancy, has led to a “top-down” theory of malignancy at this site, although it remains to be seen if this model translates to the oropharynx<sup>[171-173]</sup>. Despite being full of lymphatic tissue, the tonsils are known to harbour pathogenic viruses such as Epstein Barr virus, adenoviruses and herpes simplex virus<sup>[174]</sup>, and it is the mechanisms of immune evasion that allow persistent infection and carcinogenic potential at these sites, hence immunosuppressed individuals are particularly at risk.

From cervical models, we understand that most HPV infections last no more than a few months and are eliminated by the immune response, with 90% of infections cleared within two years, although high risk HPV tends to persist longer than low risk<sup>[175,176]</sup>. Once immune evasion is established, integration of HPV DNA into the cellular genome likely represents a critical step for malignant transformation in those individuals who harbour HPV in their tonsils<sup>[25]</sup>, with HPV integration representing a stochastic process resulting in clonal selection of aggressively expanding cells that display altered gene expression of integrated HPV genomes and potential perturbations of cellular genes at or near viral integration sites<sup>[177]</sup>. Viral integration can also lead to loss of E2-mediated inhibition of viral oncoprotein expression<sup>[178]</sup>. Furthermore, it has been shown that this HPV DNA integration is consistently centred on tonsil crypt epithelium<sup>[25]</sup>, however the factors allowing transformation from episomal HPV infection, whether active or latent, to DNA integration remain poorly understood. It has also been noted that much of the HPV that is detected in oropharyngeal cancers seems to be episomal.

Based on cervical cancer models, high-risk HPV can induce genetic changes in a small number of those with persistent infection which leads to precancerous lesions, a fraction of whom will develop cancer many years after the original infection. While HPV-related precursor lesions in the oral cavity have been identified<sup>[179]</sup>, there is an absence of detectable precancerous lesions in the oropharynx<sup>[41]</sup>, perhaps related to the difficulty in assessing and sampling deep tonsillar crypts, the predominant location of HPV-related SCCs<sup>[180,181]</sup>. Nevertheless, HPV-related oropharyngeal SCCs present with distinct molecular profiles, more comparable to cervical SCC than to non HPV-related HNSCC<sup>[55]</sup>. Infection with HPV is likely an early oncogenic event in HNSCCs. The viral oncoproteins E6 (151 amino acids) and E7 (98 amino acids) of high risk HPV types, particularly HPV-16, are implicated as the drivers of transformation in HPV-related oropharyngeal SCCs<sup>[182]</sup>. These proteins help to re-program postmitotic terminally differentiated epithelial cells to re-enter the cell cycle and express proteins that are required for viral genome replication<sup>[183]</sup>. They also disrupt a num-

ber of cellular mechanisms through a wide variety of downstream effects.

The E5 oncoprotein co-operates with E6 and E7 to promote proliferation of infected cells and is likely to facilitate malignant progression<sup>[184]</sup>, although this process is likely to take place in the early stages of carcinogenesis because viral integration frequently leads to loss of E5 gene expression<sup>[185]</sup>. Transcription of E6 and E7 viral oncogenes can occur when the virus is episomal however, in cervical SCC, alteration of E2 on integration may facilitate increased expression of E6 and E7 oncogenes, although this may not be the case in oropharyngeal SCC<sup>[186]</sup>. Viral integration is thought to play an important role in cervical SCC but the relevance of viral integration is not fully clear in oropharyngeal SCC<sup>[187]</sup>. Some studies suggest that viral integration in the tonsillar crypts plays an important role in carcinogenesis<sup>[165,188]</sup>, which may explain the predilection of HPV-related HNSCCs at this site, while other studies suggest that episomal HPV alone contributes to the development of most oropharyngeal SCCs in contrast to SCCs of the cervix<sup>[186,187]</sup>.

In cervical lesions, it is not possible to predict tumour progression based on HPV viral load<sup>[189]</sup>. It has been suggested that high HPV viral load (at least one HPV copy per tumour cell) in oropharyngeal SCC predicts active HPV infection<sup>[190-192]</sup>. The proportion of HPV-positive SCCs with high viral load varies between studies from 33%-77.5%<sup>[59,190]</sup>. It is possible that in cases of low viral load that HPV presence is coincidental and alternative mechanisms of carcinogenesis are implicated. However, gene expression varies widely and so a constitutive rather than a high expression of viral oncogenes may be all that is required for HPV-related oropharyngeal carcinogenesis<sup>[187]</sup>.

The major role of E6 oncoprotein is induction of ubiquitin-mediated proteolysis, through E6 associated protein, leading to degradation of tumour suppressor p53. As p53 usually facilitates repair to damaged host DNA by arresting cells in the G1 phase (or else inducing apoptosis), E6 expressing cells face increased mitotic stress and genomic instability<sup>[193]</sup>. E6 aids cellular proliferation by up-regulating transcription of telomerase<sup>[194]</sup> and also, through the presence of the PDZ binding motif, high risk HPV E6 proteins bind to a number of PDZ domain containing proteins with presumed tumour suppressor activity that have diverse functions<sup>[183,195]</sup>. E6 also targets the Wnt and Notch signalling pathways<sup>[183]</sup>.

The E7 oncoprotein causes cell cycle disruption by binding and inactivating tumour suppressor proteins of the retinoblastoma family (pRb) that regulate cellular senescence. E7 thereby causes cell proliferation through abnormal entry into the S-phase by the overexpression of released transcription factor E2F<sup>[196]</sup>. This functional inactivation of pRb also results in overexpression of p16 tumour suppressor protein, which is a CDK4A inhibitor, allowing the use of p16 as a surrogate marker for HPV-related oncogenesis<sup>[59,197-200]</sup>, which will be discussed further below. E7 proteins also alter cell cycle control through interactions with histone deacetylases, cyclins

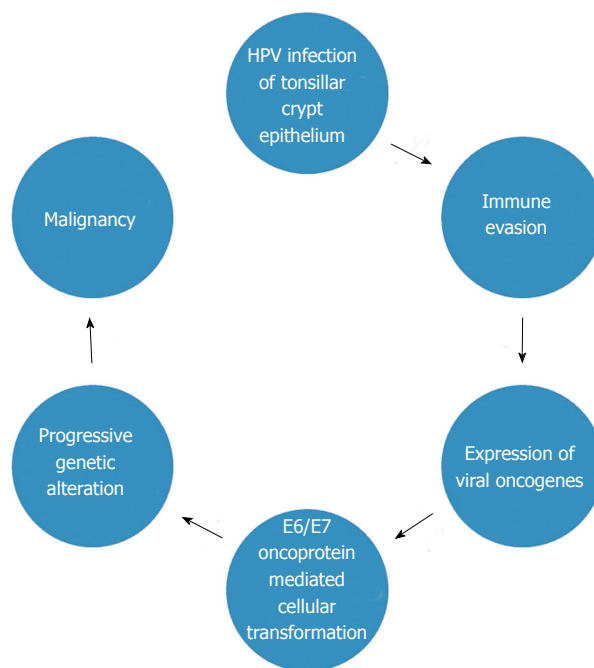
and cyclin-dependent kinase inhibitors<sup>[201]</sup>.

Animal models suggest that E7 is the dominant HPV oncoprotein in HNSCC<sup>[202]</sup>, but both E6 and E7 directly impact upon a number of apoptotic mechanisms; interaction with extracellular matrix adherence proteins to allow anchorage independent growth; interaction with cell surface receptors to resist cytokine induced extrinsic apoptosis; and interaction with proteins involved in interferon signalling and interleukin to allow immune evasion<sup>[201,203]</sup>.

Genomic instability underpins the development of dysplasia, malignancy, invasion, and metastasis in cancers<sup>[204]</sup>. While aberrant proliferation induced by E7 is facilitated by suppression of apoptosis by E6 mechanisms, it is the additional functions of E6 and E7 to induce genomic instability by multiple mechanisms that lead to chromosomal mutations. These include centrosome abnormalities or spindle checkpoint failure leading to polyploidy, aneuploidy and chromosomal rearrangement<sup>[205,206]</sup>, direct DNA damage<sup>[207]</sup> (which also occurs with viral integration<sup>[208]</sup>), variation in the Fanconi anaemia DNA repair pathway and induction of the ATM-ATR DNA damage repair pathway with concomitant disruption of checkpoint control mechanisms<sup>[201]</sup>. Tobacco exposure also causes genomic instability and so may help to induce malignancy on the background of E6 and E7 effects, allowing for a role of tobacco exposure in the potentiation of HPV-related HNSCC, which has been suggested from mouse models<sup>[209]</sup>.

Different patterns of DNA methylation have been demonstrated between HPV and non HPV-related HNSCCs, with methylation patterns in HPV-related HNSCCs more analogous to cervical SCC patterns than non HPV-related HNSCCs<sup>[210]</sup>. Excess DNA methylation could be recruited by the integrated viral genome rendering it invisible to host immune responses or it could be an attempted defence mechanism by the host cell<sup>[210]</sup>. HPV-related HNSCCs also have a distinct miRNA profile, also more analogous to cervical SCCs, in comparison with non HPV-related HNSCCs<sup>[211]</sup>. Furthermore, differences in DNA methylation rate have been identified between HNSCCs in tobacco users versus nonusers as well as specific mRNA and microRNA clusters<sup>[212]</sup>.

While distinct methods of carcinogenesis are evident between HPV-related and non HPV-related HNSCCs, the effects on downstream pathways are often the same, such as in the case of mTOR inhibition, either from TP53 mutations in tobacco related cases or from E6 induced degradation of p53 in HPV-related cases<sup>[150]</sup>. It is also important to note that E6 and E7 proteins expressed in low risk HPV types do not induce the same changes and that HPV present in some HNSCCs may exist as a latent passenger virus with no transcriptional activity<sup>[213,214]</sup>. New roles for HPV oncoproteins are continually being identified, offering many future potential therapeutic targets<sup>[215]</sup>. In any case, there is a distinct group of HPV-related tumours arising from the epithelium of lymphoid tissue characterised by viral oncoprotein expression, rather than SCCs that arise on a background of a long history of somatic mutations due to carcinogenic exposures. A



**Figure 2** Proposed Theory of human papillomavirus-related carcinogenesis. HPV: Human papillomavirus.

proposed model of carcinogenesis in HPV-related oropharyngeal SCC is shown in Figure 2.

## BIOMARKERS

Studies have had difficulty identifying clinically useful biomarkers in HNSCC<sup>[216]</sup>. A high degree of heterogeneity is evident in HNSCC, with different prognosis described for different subsets of tumours. This includes a favourable prognosis for the growing cohort of HPV-related SCCs, particularly oropharyngeal<sup>[217]</sup>, often despite a more advanced presentation. This is due to a number of factors including the sensitivity of this subset to chemoradiation<sup>[133]</sup>, the lower likelihood of loco-regional recurrence<sup>[217]</sup> and a younger cohort of patients with fewer comorbidities as well as a possible decreased risk of second primary tumours.

HPV status and p16 status have each proven useful as biomarkers in HNSCC. The tumour suppressor p16 binds to the cyclin D1 CDK4/CDK6 complex, thereby helping to keep the Rb protein in its active hypophosphorylated form. With pRb functionally inactivated by the binding of HPV E7 oncoprotein, p16 expression is upregulated by its corresponding gene being released from transcriptional inhibition. In non HPV-related HNSCC, downregulation or loss of p16 protein expression is a common early event and is associated with a worse prognosis, consistent with the tumour-suppressor role it has<sup>[204]</sup>, and oral cavity and hypopharyngeal SCC show lower levels of p16 positivity<sup>[218,219]</sup>. However, a strong correlation has been observed in numerous studies between integrated HPV detection and p16 protein overexpression. As such, p16 has been adopted as a surrogate biomarker for HPV-related HNSCC<sup>[39,197-200,220,221]</sup>, with



immunohistochemistry for p16<sup>INK4A</sup> now routinely performed in many laboratories and guides for interpretation have been described<sup>[199]</sup>.

Not only can p16 act as a surrogate biomarker for HPV status, with 46%-98% of HPV positive oropharyngeal SCCs demonstrating p16 positivity on pooled analysis<sup>[200]</sup>, but, with 3%-51% of HNSCCs being p16 positive and HPV negative<sup>[200]</sup>, p16 status can also act as an independent prognosticator, regardless of HPV status<sup>[222-225]</sup>, although not all studies agree on the specific effect<sup>[214]</sup>. Overexpression of p16 has been found in normal tonsillar tissue<sup>[25,226]</sup> and HPV negative tumours, with dysregulation of epigenetic control or multiple transcription factors being other mechanisms that lead to aberrant expression of p16<sup>[227]</sup>, some of which are associated with non HPV-related HNSCC carcinogenesis. The lack of clarity on p16 expression and discrepancies in interpretation of p16 IHC have led to controversy surrounding its use as a surrogate biomarker.

Overexpression of p16 is not evident in a subgroup of HNSCC with active HPV infection<sup>[228]</sup>, 2%-54% in pooled analysis<sup>[200]</sup>. With overexpression of p16<sup>INK4A</sup> thought to represent activity of viral oncogenes, it is possible that HPV positive/p16 negative may represent latent HPV infection, which could explain why HPV positive/p16 negative HNSCCs have a slightly worse prognosis<sup>[229,230]</sup>. Therefore, by combining testing for HPV DNA positivity and p16 overexpression, one can eliminate cases related to inactive infection, improving specificity of p16 a surrogate biomarker for detection of biologically relevant HPV infection<sup>[200]</sup>. This has been shown to be as reliable as detection of HPV E6/E7 mRNA expression by polymerase chain reaction, which is considered the gold standard of testing for transcriptionally active virus because HPV-negative HNSCCs and HPV-positive/E6 and E7 mRNA-negative HNSCCs show similar survival curves<sup>[191]</sup>; however E6/E7 mRNA is only used in a small number of centres and is mostly restricted to the research laboratory<sup>[231]</sup>. Equivalent detection may also be possible with HPV mRNA ISH and this may be of more practical clinical use<sup>[232,233]</sup>. However, there is currently a great degree of heterogeneity of HPV assessment techniques used in clinical practice depending on location<sup>[234]</sup>.

A large number of alternative prognostic or predictive biomarkers in HNSCC have been studied, such as EGFR, cyclin D1, Bcl-2, cyclin-dependent kinase inhibitor p27, MCM7, DSG3, vascular endothelial growth factor, p53, ERCC1, RRM1,  $\beta$ -catenin and MET<sup>[209,235-240]</sup>. Some examples of studies on biomarkers related to treatment response found MMP-7 and EGF to be predictive markers of, respectively, resistance to cisplatin and poor response to cetuximab<sup>[241-243]</sup>, while survivin overexpression predicted improved response to radiotherapy<sup>[244]</sup>. However, findings in many of the studies on biomarkers have been either inconsistent or often even contradictory. Some biomarkers have not been studied in sufficient detail to draw a firm association<sup>[216]</sup>. However, EGFR positivity has been associated with poor survival in HNSCC in a number of studies<sup>[245-247]</sup>, including in HPV-related

HNSCCs<sup>[167,235]</sup> (although these tumours generally tend not to overexpress EGFR<sup>[248]</sup>), and an EGFR-targeting antibody, cetuximab, has shown benefit in combination with radiotherapy for patients with HNSCC<sup>[249]</sup> so is approved for clinical use alone or in combination with radiotherapy or chemotherapy. Evidence suggests p16 may be useful in the context of analysing treatment response to cetuximab<sup>[250]</sup>. Besides EGFR inhibition, new molecular targeted therapies that have an effect on other activated molecular signalling pathways such as mTOR, Src kinase and IGF-1R inhibitors are being developed<sup>[251]</sup>.

In HPV-related oropharyngeal SCC, there is the potential for translation of cervical biomarkers given the similarities in carcinogenesis between these sites. New biomarkers are continually emerging from molecular biological research which are of as yet uncertain relevance, such as recently discovered distinct squamocolumnar junction-related biomarkers<sup>[171-173]</sup>.

It has been suggested that the programmed death 1 (PD-1):PD-L1 pathway plays a role in HNSCC, particularly in HPV-related oropharyngeal cases<sup>[252]</sup>, by facilitating HPV-related carcinogenesis in an immune-privileged site<sup>[253]</sup>. Furthermore, an investigation into a panel of serum cytokine and chemokine markers revealed significantly decreased IFN- $\gamma$  in HNSCC patients<sup>[254]</sup>, which may be caused by inhibition of T-cell regulation from increased expression of PD-1:PD-L1. Immune checkpoint blockade through a monoclonal antibody that inhibits the PD-1 receptor has the potential to play a big role in future therapy, because initiation of anti-tumour response is observed on PD-1 blockade in animal studies<sup>[255]</sup>.

Personalised therapy may be possible with robust biomarker panels and it is detailed molecular analysis, such as DNA profiling<sup>[204]</sup>, that may guide biomarker development. Limited success of individual markers to predict tumour behaviour has led to attempts to classify biomarker "signatures" such as panels of RNA or protein expression alterations<sup>[256]</sup>. It is possible that miRNA panels associated with HNSCC subsets may also act as biomarkers to improve diagnosis and management<sup>[257]</sup>. Some studies have investigated panels of predictive biomarkers in both HPV-related oropharyngeal SCC<sup>[258]</sup> and non-HPV related oropharyngeal SCC<sup>[259]</sup>, however few of these are validated<sup>[239]</sup>.

Research on biomarkers in HNSCC is a rapidly expanding field, with new potential markers that may provide valid therapeutic targets<sup>[260]</sup>, however it is difficult to demonstrate clinical utility without well designed biomarkers or panels undergoing rigorous assessment in clinical trials. Hence many questions remain, with HPV infection as yet not formally validated as a predictive biomarker for any specific treatment modality or agent<sup>[256]</sup>. More practical diagnostics could be achieved through serum<sup>[137,239]</sup> or radiological<sup>[256]</sup> biomarkers, however clinical utility of these remains to be proven. There is no standardisation of detection and when p16 expression is used as a marker for HPV infection, approximately 10% of cases may be false positives<sup>[167]</sup>, such that a combination of p16 overexpression with HPV DNA positivity may currently



represent the most practical investigation for biologically relevant HPV infection<sup>[200]</sup> and this has been shown to be the most relevant group in terms of prognosis<sup>[261]</sup>. The relevance of infection in head and neck cancer outside the oropharynx is unestablished and identification of robust fingerprints of HPV carcinogenesis will help to improve the estimate of HPV-related non-oropharyngeal HNSCC.

## CLINICAL IMPLICATIONS

HNSCC has a huge impact upon quality of life and longevity. Improvements in clinical outcome have been forthcoming through advancements in surgical technique, radiation oncology and emerging chemotherapeutic and biologic agents, however, despite a multidisciplinary team approach, treatments remain complex with an associated high morbidity and only two new treatments (EGFR antibodies and robotic surgery) have been approved in the past 30 years<sup>[262]</sup>.

HPV-related oropharyngeal SCC, distinct from other HNSCC<sup>[39,263]</sup>, generally presents with a more advanced clinical stage, with a higher nodal category<sup>[248,264]</sup>, despite lower tumour extent<sup>[133,264]</sup> and have different tendencies for extracapsular spread and perineural invasion<sup>[265]</sup>. These HPV-related tumours may even be clinically occult, but often present with early lymph node metastases<sup>[14,266]</sup>, which can be confused with branchial cleft cysts<sup>[267]</sup>. However, tonsil SCCs are long known to present with early lymph node metastases<sup>[268]</sup> and it may be that the characteristics of the affected site itself facilitate early spread or else potentially the depth of invasion<sup>[266]</sup>.

As stated above, these patients tend to be younger and are less likely to have significant exposure to tobacco and alcohol. Despite more advanced presentation, improved survival, consistently higher than 30%<sup>[269]</sup>, is evident in HPV-related oropharyngeal SCC<sup>[66,266,270,271]</sup>, irrespective of treatment modality<sup>[133,220,272-276]</sup>. It has been suggested, therefore, that the current classification system for HNSCCs be altered to reflect the different status of HPV-related HNSCCs<sup>[273]</sup>.

Detection of biologically relevant HPV infection is best accomplished using HPV E6 and E7 mRNA, however p16 in combination with HPV DNA correlates well and can be a practical alternative<sup>[277]</sup>. Studies have also shown an improved response to therapy from HPV-related HNSCCs<sup>[116,133,278-280]</sup>. As a result of this, it is possible that de-escalation of therapy would be appropriate for these tumours to improve associated morbidity and quality of life. Considering this, there are currently a number ongoing trials. A summary of some of these trials is shown in Table 1.

There have been conflicting reports on the benefit of cetuximab in HPV-related oropharyngeal SCC. While subset analysis in one study suggests improved survival for oropharyngeal SCCs in the cetuximab group (although not necessarily HPV-related)<sup>[281]</sup>, others including the RTOG 0522 and SPECRUM trials disagree<sup>[269,282]</sup>. Preclinical investigation on treatment effects are limited

by the sparse number of HPV-related HNSCC cell lines available.

While organ-preservation trials have led to primary chemoradiotherapy superseding surgical management in HNSCC, there has been renewed interest in transoral techniques for oropharyngeal SCC, particularly with the introduction of robotic surgery. Equivalent early oncologic outcomes to chemoradiotherapy and improved functional outcomes are promising<sup>[283]</sup>. Some trials involving transoral surgery are shown in Table 1.

Therapeutic vaccines are novel strategies aimed at improving the T-cell mediated immune response to HPV-related SCCs. Recent phase I and II clinical trials, some in combination with chemotherapy to boost effectiveness, are investigating these<sup>[269,284]</sup>.

There is currently no single standardized treatment for oropharyngeal SCCs, but before recommended management strategies are altered, results from randomized controlled trials are needed to assess the efficacy of the different treatment modalities available for both HPV-positive and HPV-negative oropharyngeal SCC<sup>[285]</sup>, although recruitment of sufficient numbers remains difficult<sup>[265]</sup>.

Induction of HPV-specific immune responses by prophylactic vaccination with recombinant HPV virus-like particles is likely the key to successful prevention of persistent HPV infection and the subsequent consequences. As such, bivalent and quadrivalent vaccines are now widely available and have shown efficacy in prevention of anal, cervical, vaginal, and vulvar pre-cancers in unexposed individuals<sup>[94,286,287]</sup>. Unfortunately, present vaccines are only proven to be effective if given before genotype-specific infection is established<sup>[288]</sup>, duration of protection remains unclear and cost is high. Given the high specificity of oropharyngeal cases linked to HPV-16, it is unlikely that other genotypes would replace HPV-16, particularly in view of evidence for induction of cross-genotype immunity with genotype-specific immunisation<sup>[289]</sup>.

In relation to the oropharynx, animal model investigation has revealed reduction in development of HPV-related oral lesions in immunised cases<sup>[290]</sup>. Recently, an IARC-led study established that a bivalent vaccine used for cervical cancer prevention also reduced oral infections with HPV 16 and 18 by 93.3%<sup>[291]</sup>. While oral HPV infection is a risk factor for development of HPV-related oropharyngeal SCC, pathogenesis is unclear and the lack of an obvious HPV-related precancerous stage does not facilitate screening and makes evaluation of vaccine effectiveness difficult. Accurate estimates of HPV-related oropharyngeal SCC will help determine the potential role of prophylactic vaccination. It is likely that the effects of vaccination on oropharyngeal SCC will only be revealed over time through longitudinal studies on incidence before and after vaccine introduction.

Treatment of HPV-related oropharyngeal SCC is currently varied geographically depending on tumour stage, patient status including age and co-morbidities, facilities available and HPV or p16 status. There remains uncertainty regarding vaccination, cetuximab and de-escalation

**Table 1 Ongoing clinical trials pertaining to treatment of human papillomavirus-related oropharyngeal squamous cell carcinoma**

Trial	Phase	Inclusion	Arm 1	Arm 2	Outcomes
RTOG 1016	III	p16 positive locally advanced oropharyngeal SCC	Radiation and concurrent chemotherapy	Radiation and concurrent cetuximab	Survival, toxicity, locoregional recurrence and quality of life
ECOG E1308	II	Stage III-IVa HPV positive oropharyngeal SCC	Complete response to induction chemotherapy and reduced dose radiation with concurrent cetuximab	Incomplete response to induction chemotherapy and standard dose radiation with concurrent cetuximab	Survival, toxicity, response, quality of life and biomarker correlation
De-ESCALaTe HPV	III	Stage III-IVa HPV positive oropharyngeal SCC	Cetuximab and concurrent radiotherapy	standard concurrent cisplatin and chemoradiotherapy	Morbidity, quality of life, cost, survival and recurrence
QUARTERBACK	III	Locally advanced HPV-16 positive oropharyngeal, unknown primary or nasopharyngeal SCC showing complete or partial response to induction therapy	Reduced dose radiation with cetuximab and chemotherapy	Standard dose radiation with chemotherapy	Survival, locoregional control, toxicity and biomarker correlation.
LCCC 1120	II	HPV positive and/or p16 positive low-risk oropharyngeal SCC	Decreased dose of radiation and chemotherapy	Standard radiation and chemotherapy	Pathological response rate, locoregional control, survival and quality of life
NCT01221753	II	Locally advanced HPV positive oropharyngeal SCC	Docetaxel/cisplatin/5-fluorouracil (TPF) induction chemotherapy followed by concurrent chemoradiation using a modified radiation dose	N/A	Locoregional control, survival and toxicity
SIRS	II	Early to mid-stage HPV positive oropharyngeal SCC who receive transoral robotic surgery plus a neck dissection, where clinically indicated	Observation only	Low dose postoperative radiation only Arm 3: Chemoradiation	Rates of locoregional control, overall survival and use of salvage chemoradiation in the observation group
TROG 12.01	III	HPV positive oropharyngeal SCC	Radiation and cetuximab	Radiation and cisplatin	Symptoms severity, swallowing, quality of life, toxicity, survival, locoregional recurrence
ADEPT	III	p16 positive oropharyngeal SCC that has undergone transoral resection with negative margins	Postoperative radiation alone	Postoperative radiation with cisplatin	Survival, locoregional control, toxicity and quality of life
NCT01088802	I / II	HPV positive T1-3 oropharyngeal SCC	De-escalated radiation from 70 Gy to 63 Gy with concurrent chemotherapy	De-escalated radiation from 58.1 Gy to 50.75 Gy with concurrent chemotherapy	Toxicity, quality of life and adverse events
ECOG E3311	II	Stage III-IVa HPV positive oropharyngeal SCC after transoral surgery and neck dissection with negative margins, no extracapsular spread and less than 4 lymph nodes involved	Transoral surgery with standard radiation	Transoral surgery with low-dose radiation	Survival, surgical complications, toxicity and swallowing

SCC: Squamous cell carcinoma; HPV: Human papillomavirus.

of therapy, which will be made clearer through current prospective trials, leading to better delineation of therapy for HNSCC subsets. Accurate assessment for biologically relevant HPV will be critical to improvement in treatment approaches.

## CONCLUSION

HPV has been established beyond doubt as a causative agent in oropharyngeal SCC and biologically active HPV can act as a prognosticator with better overall survival than HPV-negative HNSCCs. A distinct group of younger patients with limited tobacco and alcohol exposure have emerged as characteristic of this HPV-related subset

of HNSCC. However, the exact molecular mechanisms of carcinogenesis are not completely described and further studies are needed to assist development of optimal prevention and treatment modalities.

Despite the large pool of research on HPV in HNSCC, great variation exists in detection techniques. Detection of biologically relevant HPV infection will be important for clinical trial design. Also, biomarker discovery will be important not only to identify specific SCC subsets, including those that are HPV-related, to allow for individualised treatment strategies aimed at decreasing morbidity, but also to clarify the role of HPV in non-oropharyngeal sites.

With stored tissue available from the SEER database

in only 271 patients<sup>[265]</sup>, there needs to be greater cooperation between institutions to improve research into understanding this disease. Nevertheless, it is likely that the key approach in future will be prevention and so further studies in prophylactic vaccination, specifically in relation to oropharyngeal SCC, are needed.

## REFERENCES

- 1 Ferlay J, Shin HR, Bray F, Forman D, Mathers C, Parkin DM. Estimates of worldwide burden of cancer in 2008: GLOBOCAN 2008. *Int J Cancer* 2010; **127**: 2893-2917 [PMID: 21351269 DOI: 10.1002/ijc.25516]
- 2 Martinez I, Wang J, Hobson KE, Ferris RL, Khan SA. Identification of differentially expressed genes in HPV-positive and HPV-negative oropharyngeal squamous cell carcinomas. *Eur J Cancer* 2007; **43**: 415-432 [PMID: 17079134 DOI: 10.1016/j.ejca.2006.09.001]
- 3 O'Regan EM, Toner ME, Smyth PC, Finn SP, Timon C, Cahill S, Flavin R, O'Leary JJ, Sheils O. Distinct array comparative genomic hybridization profiles in oral squamous cell carcinoma occurring in young patients. *Head Neck* 2006; **28**: 330-338 [PMID: 16470878 DOI: 10.1002/hed.20354]
- 4 zur Hausen H. Human papillomaviruses and their possible role in squamous cell carcinomas. *Curr Top Microbiol Immunol* 1977; **78**: 1-30 [PMID: 202434]
- 5 IARC Working Group on the Evaluation of Carcinogenic Risks to Humans. Human papillomaviruses. *IARC Monogr Eval Carcinog Risks Hum* 1995; **64**: 1-378 [PMID: 16755705]
- 6 Walboomers JM, Jacobs MV, Manos MM, Bosch FX, Kummer JA, Shah KV, Snijders PJ, Peto J, Meijer CJ, Muñoz N. Human papillomavirus is a necessary cause of invasive cervical cancer worldwide. *J Pathol* 1999; **189**: 12-19 [PMID: 10451482 DOI: 10.1002/(SICI)1096-9896(199909)189]
- 7 Backes DM, Kurman RJ, Pimenta JM, Smith JS. Systematic review of human papillomavirus prevalence in invasive penile cancer. *Cancer Causes Control* 2009; **20**: 449-457 [PMID: 19082746 DOI: 10.1007/s10552-008-9276-9]
- 8 De Vuyst H, Clifford GM, Nascimento MC, Madeleine MM, Franceschi S. Prevalence and type distribution of human papillomavirus in carcinoma and intraepithelial neoplasia of the vulva, vagina and anus: a meta-analysis. *Int J Cancer* 2009; **124**: 1626-1636 [PMID: 19115209 DOI: 10.1002/ijc.24116]
- 9 Aldabagh B, Angeles JG, Cardones AR, Arron ST. Cutaneous squamous cell carcinoma and human papillomavirus: is there an association? *Dermatol Surg* 2013; **39**: 1-23 [PMID: 22928516 DOI: 10.1111/j.1524-4725.2012.02558.x]
- 10 Parkin DM. The global health burden of infection-associated cancers in the year 2002. *Int J Cancer* 2006; **118**: 3030-3044 [PMID: 16404738 DOI: 10.1002/ijc.21731]
- 11 Bosch FX, Broker TR, Forman D, Moscicki AB, Gillison ML, Doorbar J, Stern PL, Stanley M, Arbyn M, Poljak M, Cuzick J, Castle PE, Schiller JT, Markowitz LE, Fisher WA, Canfell K, Denny LA, Franco EL, Steben M, Kane MA, Schiffman M, Meijer CJ, Sankaranarayanan R, Castellsagué X, Kim JJ, Brotons M, Alemany L, Albero G, Diaz M, de Sanjosé S. Comprehensive control of human papillomavirus infections and related diseases. *Vaccine* 2013; **31** Suppl 7: H1-31 [PMID: 24332295 DOI: 10.1016/j.vaccine.2013.10.003]
- 12 Syrjänen K, Syrjänen S, Lamberg M, Pyrhönen S, Nuutinen J. Morphological and immunohistochemical evidence suggesting human papillomavirus (HPV) involvement in oral squamous cell carcinogenesis. *Int J Oral Surg* 1983; **12**: 418-424 [PMID: 6325356]
- 13 Löning T, Ikenberg H, Becker J, Gissmann L, Hoepfer I, zur Hausen H. Analysis of oral papillomas, leukoplakias, and invasive carcinomas for human papillomavirus type related DNA. *J Invest Dermatol* 1985; **84**: 417-420 [PMID: 2987361]
- 14 Paz IB, Cook N, Odom-Maryon T, Xie Y, Wilczynski SP. Human papillomavirus (HPV) in head and neck cancer. An association of HPV 16 with squamous cell carcinoma of Waldeyer's tonsillar ring. *Cancer* 1997; **79**: 595-604 [PMID: 9028373]
- 15 Andl T, Kahn T, Pfuhl A, Nicola T, Erber R, Conradt C, Klein W, Helbig M, Dietz A, Weidauer H, Bosch FX. Etiological involvement of oncogenic human papillomavirus in tonsillar squamous cell carcinomas lacking retinoblastoma cell cycle control. *Cancer Res* 1998; **58**: 5-13 [PMID: 9426048]
- 16 Gillison ML, Koch WM, Capone RB, Spafford M, Westra WH, Wu L, Zahurak ML, Daniel RW, Viglione M, Symer DE, Shah KV, Sidransky D. Evidence for a causal association between human papillomavirus and a subset of head and neck cancers. *J Natl Cancer Inst* 2000; **92**: 709-720 [PMID: 10793107]
- 17 El-Mofty SK. Human papillomavirus (HPV) related carcinomas of the upper aerodigestive tract. *Head Neck Pathol* 2007; **1**: 181-185 [PMID: 20614273 DOI: 10.1007/s12105-007-0021-6]
- 18 Westra WH. The changing face of head and neck cancer in the 21st century: the impact of HPV on the epidemiology and pathology of oral cancer. *Head Neck Pathol* 2009; **3**: 78-81 [PMID: 20596995 DOI: 10.1007/s12105-009-0100-y]
- 19 Vidal L, Gillison ML. Human papillomavirus in HNSCC: recognition of a distinct disease type. *Hematol Oncol Clin North Am* 2008; **22**: 1125-1142, vii [PMID: 19010263 DOI: 10.1016/j.hoc.2008.08.006]
- 20 Cohan DM, Popat S, Kaplan SE, Rigual N, Loree T, Hicks WL. Oropharyngeal cancer: current understanding and management. *Curr Opin Otolaryngol Head Neck Surg* 2009; **17**: 88-94 [PMID: 19373958]
- 21 Slebos RJ, Yi Y, Ely K, Carter J, Evjen A, Zhang X, Shyr Y, Murphy BM, Cmelak AJ, Burkey BB, Netterville JL, Levy S, Yarbrough WG, Chung CH. Gene expression differences associated with human papillomavirus status in head and neck squamous cell carcinoma. *Clin Cancer Res* 2006; **12**: 701-709 [PMID: 16467079 DOI: 10.1158/1078-0432.CCR-05-2017]
- 22 Pyeon D, Newton MA, Lambert PF, den Boon JA, Sengupta S, Marsit CJ, Woodworth CD, Connor JP, Haugen TH, Smith EM, Kelsey KT, Turek LP, Ahlquist P. Fundamental differences in cell cycle deregulation in human papillomavirus-positive and human papillomavirus-negative head/neck and cervical cancers. *Cancer Res* 2007; **67**: 4605-4619 [PMID: 17510386 DOI: 10.1158/0008-5472.CAN-06-3619]
- 23 Braakhuis BJ, Snijders PJ, Keune WJ, Meijer CJ, Ruijter-Schippers HJ, Leemans CR, Brakenhoff RH. Genetic patterns in head and neck cancers that contain or lack transcriptionally active human papillomavirus. *J Natl Cancer Inst* 2004; **96**: 998-1006 [PMID: 15240783]
- 24 Li G, Huang Z, Chen X, Wei Q. Role of human papillomavirus and cell cycle-related variants in squamous cell carcinoma of the oropharynx. *J Biomed Res* 2010; **24**: 339-346 [PMID: 23554649 DOI: 10.1016/S1674-8301(10)60047-4]
- 25 Begum S, Cao D, Gillison M, Zahurak M, Westra WH. Tissue distribution of human papillomavirus 16 DNA integration in patients with tonsillar carcinoma. *Clin Cancer Res* 2005; **11**: 5694-5699 [PMID: 16115905 DOI: 10.1158/1078-0432.CCR-05-0587]
- 26 Kreimer AR, Clifford GM, Snijders PJ, Castellsagué X, Meijer CJ, Pawlita M, Viscidi R, Herrero R, Franceschi S. HPV16 semiquantitative viral load and serologic biomarkers in oral and oropharyngeal squamous cell carcinomas. *Int J Cancer* 2005; **115**: 329-332 [PMID: 15688391 DOI: 10.1002/ijc.20872]
- 27 D'Souza G, Kreimer AR, Viscidi R, Pawlita M, Fakhry C, Koch WM, Westra WH, Gillison ML. Case-control study of human papillomavirus and oropharyngeal cancer. *N Engl J Med* 2007; **356**: 1944-1956 [PMID: 17494927 DOI: 10.1056/NEJMoa065497]
- 28 Begum S, Westra WH. Basaloid squamous cell carcinoma of the head and neck is a mixed variant that can be further



- resolved by HPV status. *Am J Surg Pathol* 2008; **32**: 1044-1050 [PMID: 18496144 DOI: 10.1097/PAS.0b013e31816380ec]
- 29 **Jo VY**, Mills SE, Stoler MH, Stelow EB. Papillary squamous cell carcinoma of the head and neck: frequent association with human papillomavirus infection and invasive carcinoma. *Am J Surg Pathol* 2009; **33**: 1720-1724 [PMID: 19745700 DOI: 10.1097/PAS.0b013e3181b6d8e6]
  - 30 **Carpenter DH**, El-Mofty SK, Lewis JS. Undifferentiated carcinoma of the oropharynx: a human papillomavirus-associated tumor with a favorable prognosis. *Mod Pathol* 2011; **24**: 1306-1312 [PMID: 21572403 DOI: 10.1038/modpathol.2011.87]
  - 31 **Singhi AD**, Stelow EB, Mills SE, Westra WH. Lymphoepithelial-like carcinoma of the oropharynx: a morphologic variant of HPV-related head and neck carcinoma. *Am J Surg Pathol* 2010; **34**: 800-805 [PMID: 20421782 DOI: 10.1097/PAS.0b013e3181d9ba21]
  - 32 **Bishop JA**, Westra WH. Human papillomavirus-related small cell carcinoma of the oropharynx. *Am J Surg Pathol* 2011; **35**: 1679-1684 [PMID: 21997688 DOI: 10.1097/PAS.0b013e3182299cde]
  - 33 **Kraft S**, Faquin WC, Krane JF. HPV-associated neuroendocrine carcinoma of the oropharynx: a rare new entity with potentially aggressive clinical behavior. *Am J Surg Pathol* 2012; **36**: 321-330 [PMID: 22301491 DOI: 10.1097/PAS.0b013e31823f2f17]
  - 34 **Masand RP**, El-Mofty SK, Ma XJ, Luo Y, Flanagan JJ, Lewis JS. Adenosquamous carcinoma of the head and neck: relationship to human papillomavirus and review of the literature. *Head Neck Pathol* 2011; **5**: 108-116 [PMID: 21305368 DOI: 10.1007/s12105-011-0245-3]
  - 35 **Combes JD**, Franceschi S. Role of human papillomavirus in non-oro-pharyngeal head and neck cancers. *Oral Oncol* 2014; **50**: 370-379 [PMID: 24331868 DOI: 10.1016/j.oraloncology.2013.11.004]
  - 36 **O'Duffy F**, O'Dwyer TP. The growing epidemic of HPV associated oropharyngeal malignancy. *Ir Med J* 2012; **105**: 101-102 [PMID: 22708219]
  - 37 **Näsman A**, Attner P, Hammarstedt L, Du J, Eriksson M, Giraud G, Ahrlund-Richter S, Marklund L, Romanitan M, Lindquist D, Ramqvist T, Lindholm J, Sparén P, Ye W, Dahlstrand H, Munck-Wikland E, Dalianis T. Incidence of human papillomavirus (HPV) positive tonsillar carcinoma in Stockholm, Sweden: an epidemic of viral-induced carcinoma? *Int J Cancer* 2009; **125**: 362-366 [PMID: 19330833 DOI: 10.1002/ijc.24339]
  - 38 **Sturgis EM**, Cinciripini PM. Trends in head and neck cancer incidence in relation to smoking prevalence: an emerging epidemic of human papillomavirus-associated cancers? *Cancer* 2007; **110**: 1429-1435 [PMID: 17724670 DOI: 10.1002/cncr.22963]
  - 39 **Murur S**, D'Souza G, Westra WH, Forastiere AA. HPV-associated head and neck cancer: a virus-related cancer epidemic. *Lancet Oncol* 2010; **11**: 781-789 [PMID: 20451455 DOI: 10.1016/S1470-2045(10)70017-6]
  - 40 **Panwar A**, Batra R, Lydiatt WM, Ganti AK. Human papilloma virus positive oropharyngeal squamous cell carcinoma: a growing epidemic. *Cancer Treat Rev* 2014; **40**: 215-219 [PMID: 24080155 DOI: 10.1016/j.ctrv.2013.09.006]
  - 41 **Chaturvedi AK**. Epidemiology and clinical aspects of HPV in head and neck cancers. *Head Neck Pathol* 2012; **6** Suppl 1: S16-S24 [PMID: 22782220 DOI: 10.1007/s12105-012-0377-0]
  - 42 **Isayeva T**, Li Y, Maswahu D, Brandwein-Gensler M. Human papillomavirus in non-oro-pharyngeal head and neck cancers: a systematic literature review. *Head Neck Pathol* 2012; **6** Suppl 1: S104-S120 [PMID: 22782230 DOI: 10.1007/s12105-012-0368-1]
  - 43 **Muñoz N**, Castellsagué X, de González AB, Gissmann L. Chapter 1: HPV in the etiology of human cancer. *Vaccine* 2006; **24** Suppl 3: S3/1-S310 [PMID: 16949995 DOI: 10.1016/j.vaccine.2006.05.115]
  - 44 **de Villiers EM**, Fauquet C, Broker TR, Bernard HU, zur Hausen H. Classification of papillomaviruses. *Virology* 2004; **324**: 17-27 [PMID: 15183049 DOI: 10.1016/j.virol.2004.03.033]
  - 45 **Conway MJ**, Meyers C. Replication and assembly of human papillomaviruses. *J Dent Res* 2009; **88**: 307-317 [PMID: 19407149 DOI: 10.1177/0022034509333446]
  - 46 **Qmichou Z**, Khyatti M, Berraho M, Ennaji MM, Benbacer L, Nejari C, Benjaafar N, Benider A, Attaleb M, El Mzibri M. Analysis of mutations in the E6 oncogene of human papillomavirus 16 in cervical cancer isolates from Moroccan women. *BMC Infect Dis* 2013; **13**: 378 [PMID: 23953248 DOI: 10.1186/1471-2334-13-378]
  - 47 **Pande S**, Jain N, Prusty BK, Bhambhani S, Gupta S, Sharma R, Batra S, Das BC. Human papillomavirus type 16 variant analysis of E6, E7, and L1 genes and long control region in biopsy samples from cervical cancer patients in north India. *J Clin Microbiol* 2008; **46**: 1060-1066 [PMID: 18199779 DOI: 10.1128/JCM.02202-07]
  - 48 **Xi LF**, Koutsky LA, Hildesheim A, Galloway DA, Wheeler CM, Winer RL, Ho J, Kiviat NB. Risk for high-grade cervical intraepithelial neoplasia associated with variants of human papillomavirus types 16 and 18. *Cancer Epidemiol Biomarkers Prev* 2007; **16**: 4-10 [PMID: 17220325 DOI: 10.1158/1055-9965.EPI-06-0670]
  - 49 **Tornesello ML**, Duraturo ML, Salatiello I, Buonaguro L, Losito S, Botti G, Stellato G, Greggi S, Piccoli R, Pilotti S, Stefanon B, De Palo G, Franceschi S, Buonaguro FM. Analysis of human papillomavirus type-16 variants in Italian women with cervical intraepithelial neoplasia and cervical cancer. *J Med Virol* 2004; **74**: 117-126 [PMID: 15258977 DOI: 10.1002/jmv.20154]
  - 50 **Pista A**, Oliveira A, Barateiro A, Costa H, Verdasca N, Paixão MT. Molecular variants of human papillomavirus type 16 and 18 and risk for cervical neoplasia in Portugal. *J Med Virol* 2007; **79**: 1889-1897 [PMID: 17935194 DOI: 10.1002/jmv.21002]
  - 51 **Cornet I**, Gheit T, Clifford GM, Combes JD, Dalstein V, Franceschi S, Tommasino M, Clavel C. Human papillomavirus type 16 E6 variants in France and risk of viral persistence. *Infect Agent Cancer* 2013; **8**: 4 [PMID: 23343041 DOI: 10.1186/1750-9378-8-4]
  - 52 **Gubanova E**, Brown B, Ivanov SV, Helleday T, Mills GB, Yarbrough WG, Issaeva N. Downregulation of SMG-1 in HPV-positive head and neck squamous cell carcinoma due to promoter hypermethylation correlates with improved survival. *Clin Cancer Res* 2012; **18**: 1257-1267 [PMID: 22247495 DOI: 10.1158/1078-0432.CCR-11-2058]
  - 53 **de Martel C**, Ferlay J, Franceschi S, Vignat J, Bray F, Forman D, Plummer M. Global burden of cancers attributable to infections in 2008: a review and synthetic analysis. *Lancet Oncol* 2012; **13**: 607-615 [PMID: 22575588 DOI: 10.1016/S1470-2045(12)70137-7]
  - 54 **Li N**, Franceschi S, Howell-Jones R, Snijders PJ, Clifford GM. Human papillomavirus type distribution in 30,848 invasive cervical cancers worldwide: Variation by geographical region, histological type and year of publication. *Int J Cancer* 2011; **128**: 927-935 [PMID: 20473886 DOI: 10.1002/ijc.25396]
  - 55 **Gillison ML**, Castellsagué X, Chaturvedi A, Goodman MT, Snijders P, Tommasino M, Arbyn M, Franceschi S. Eurogin Roadmap: comparative epidemiology of HPV infection and associated cancers of the head and neck and cervix. *Int J Cancer* 2014; **134**: 497-507 [PMID: 23568556 DOI: 10.1002/ijc.28201]
  - 56 **Mehanna H**, Beech T, Nicholson T, El-Hariry I, McConkey C, Paleri V, Roberts S. Prevalence of human papillomavirus in oropharyngeal and nonoropharyngeal head and neck cancer—systematic review and meta-analysis of trends by time and region. *Head Neck* 2013; **35**: 747-755 [PMID: 22267298 DOI: 10.1002/hed.22015]



- 57 **de Sanjose S**, Quint WG, Alemany L, Geraets DT, Klaus-termeier JE, Lloveras B, Tous S, Felix A, Bravo LE, Shin HR, Vallejos CS, de Ruiz PA, Lima MA, Guimera N, Clavero O, Alejo M, Llombart-Bosch A, Cheng-Yang C, Tatti SA, Kasamatsu E, Iljazovic E, Odida M, Prado R, Seoud M, Grce M, Usubutun A, Jain A, Suarez GA, Lombardi LE, Banjo A, Menéndez C, Domingo EJ, Velasco J, Nessa A, Chichareon SC, Qiao YL, Lerma E, Garland SM, Sasagawa T, Ferrera A, Hammouda D, Mariani L, Pelayo A, Steiner I, Oliva E, Meijer CJ, Al-Jassar WF, Cruz E, Wright TC, Puras A, Llave CL, Tzardi M, Agorastos T, Garcia-Barriola V, Clavel C, Ordi J, Andújar M, Castellsagué X, Sánchez GI, Nowakowski AM, Bornstein J, Muñoz N, Bosch FX. Human papillomavirus genotype attribution in invasive cervical cancer: a retrospective cross-sectional worldwide study. *Lancet Oncol* 2010; **11**: 1048-1056 [PMID: 20952254 DOI: 10.1016/S1470-2045(10)70230-8]
- 58 **St Guily JL**, Jacquard AC, Prétet JL, Haesebaert J, Beby-Defaux A, Clavel C, Agius G, Birembaut P, Okaïs C, Léocmach Y, Soubeyrand B, Pradat P, Riethmuller D, Mougín C, Denis F. Human papillomavirus genotype distribution in oropharynx and oral cavity cancer in France--The EDiTH VI study. *J Clin Virol* 2011; **51**: 100-104 [PMID: 21527208 DOI: 10.1016/j.jcv.2011.03.003]
- 59 **Chaturvedi AK**, Engels EA, Pfeiffer RM, Hernandez BY, Xiao W, Kim E, Jiang B, Goodman MT, Sibug-Saber M, Cozen W, Liu L, Lynch CF, Wentzensen N, Jordan RC, Altekruze S, Anderson WF, Rosenberg PS, Gillison ML. Human papillomavirus and rising oropharyngeal cancer incidence in the United States. *J Clin Oncol* 2011; **29**: 4294-4301 [PMID: 21969503 DOI: 10.1200/JCO.2011.36.4596]
- 60 **Kero K**, Rautava J, Syrjänen K, Grenman S, Syrjänen S. Oral mucosa as a reservoir of human papillomavirus: point prevalence, genotype distribution, and incident infections among males in a 7-year prospective study. *Eur Urol* 2012; **62**: 1063-1070 [PMID: 22771267 DOI: 10.1016/j.eururo.2012.06.045]
- 61 **St Guily JL**, Clavel C, Okaïs C, Prétet JL, Beby-Defaux A, Agius G, Birembaut P, Jacquard AC, Léocmach Y, Soubeyrand B, Riethmuller D, Denis F, Mougín C. Human papillomavirus genotype distribution in tonsil cancers. *Head Neck Oncol* 2011; **3**: 6 [PMID: 21299882 DOI: 10.1186/1758-3284-3-6]
- 62 **Gillison ML**, Broutian T, Pickard RK, Tong ZY, Xiao W, Kahle L, Graubard BI, Chaturvedi AK. Prevalence of oral HPV infection in the United States, 2009-2010. *JAMA* 2012; **307**: 693-703 [PMID: 22282321 DOI: 10.1001/jama.2012.101]
- 63 **Kreimer AR**, Bhatia RK, Messegue AL, González P, Herrera R, Giuliano AR. Oral human papillomavirus in healthy individuals: a systematic review of the literature. *Sex Transm Dis* 2010; **37**: 386-391 [PMID: 20081557 DOI: 10.1097/OLQ.0b013e3181c94a3b]
- 64 **Beachler DC**, Weber KM, Margolick JB, Strickler HD, Cranston RD, Burk RD, Wiley DJ, Minkoff H, Reddy S, Stammer EE, Gillison ML, D'Souza G. Risk factors for oral HPV infection among a high prevalence population of HIV-positive and at-risk HIV-negative adults. *Cancer Epidemiol Biomarkers Prev* 2012; **21**: 122-133 [PMID: 22045700 DOI: 10.1158/1055-9965.EPI-11-0734]
- 65 **Kreimer AR**, Clifford GM, Boyle P, Franceschi S. Human papillomavirus types in head and neck squamous cell carcinomas worldwide: a systematic review. *Cancer Epidemiol Biomarkers Prev* 2005; **14**: 467-475 [PMID: 15734974 DOI: 10.1158/1055-9965.EPI-04-0551]
- 66 **Chien CY**, Su CY, Fang FM, Huang HY, Chuang HC, Chen CM, Huang CC. Lower prevalence but favorable survival for human papillomavirus-related squamous cell carcinoma of tonsil in Taiwan. *Oral Oncol* 2008; **44**: 174-179 [PMID: 17418614 DOI: 10.1016/j.oraloncology.2007.01.018]
- 67 **Ribeiro KB**, Levi JE, Pawlita M, Koifman S, Matos E, Eluf-Neto J, Wunsch-Filho V, Curado MP, Shangina O, Zaridze D, Szeszenia-Dabrowska N, Lissowska J, Daudt A, Menezes A, Bencko V, Mates D, Fernandez L, Fabianova E, Gheit T, Tommasino M, Boffetta P, Brennan P, Waterboer T. Low human papillomavirus prevalence in head and neck cancer: results from two large case-control studies in high-incidence regions. *Int J Epidemiol* 2011; **40**: 489-502 [PMID: 21224273 DOI: 10.1093/ije/dyq249]
- 68 **Ernster JA**, Sciutto CG, O'Brien MM, Finch JL, Robinson LJ, Willson T, Mathews M. Rising incidence of oropharyngeal cancer and the role of oncogenic human papilloma virus. *Laryngoscope* 2007; **117**: 2115-2128 [PMID: 17891052 DOI: 10.1097/MLG.0b013e31813e5fbb]
- 69 **Auluck A**, Hislop G, Bajdik C, Poh C, Zhang L, Rosin M. Trends in oropharyngeal and oral cavity cancer incidence of human papillomavirus (HPV)-related and HPV-unrelated sites in a multicultural population: the British Columbia experience. *Cancer* 2010; **116**: 2635-2644 [PMID: 20336792 DOI: 10.1002/cncr.25087]
- 70 **Hocking JS**, Stein A, Conway EL, Regan D, Grulich A, Law M, Brotherton JM. Head and neck cancer in Australia between 1982 and 2005 show increasing incidence of potentially HPV-associated oropharyngeal cancers. *Br J Cancer* 2011; **104**: 886-891 [PMID: 21285981 DOI: 10.1038/sj.bjc.6606091]
- 71 **Lee YC**, Zugna D, Richiardi L, Merletti F, Marron M, Ahrens W, Pohlbeln H, Lagiou P, Trichopoulos D, Agudo A, Castellsagué X, Betka J, Holcatova I, Kjaerheim K, Macfarlane GJ, Macfarlane TV, Talamini R, Barzan L, Canova C, Simonato L, Conway DI, McKinney PA, Thomson P, Znaor A, Healy CM, McCartan BE, Boffetta P, Brennan P, Hashibe M. Smoking addiction and the risk of upper-aerodigestive-tract cancer in a multicenter case-control study. *Int J Cancer* 2013; **133**: 2688-2695 [PMID: 23719996 DOI: 10.1002/ijc.28288]
- 72 **Guha N**, Boffetta P, Wunsch Filho V, Eluf Neto J, Shangina O, Zaridze D, Curado MP, Koifman S, Matos E, Menezes A, Szeszenia-Dabrowska N, Fernandez L, Mates D, Daudt AW, Lissowska J, Dikshit R, Brennan P. Oral health and risk of squamous cell carcinoma of the head and neck and esophagus: results of two multicentric case-control studies. *Am J Epidemiol* 2007; **166**: 1159-1173 [PMID: 17761691 DOI: 10.1093/aje/kwm193]
- 73 **Talamini R**, Vaccarella S, Barbone F, Tavani A, La Vecchia C, Herrero R, Muñoz N, Franceschi S. Oral hygiene, dentition, sexual habits and risk of oral cancer. *Br J Cancer* 2000; **83**: 1238-1242 [PMID: 11027440 DOI: 10.1054/bjoc.2000.1398]
- 74 **Franceschi S**, Favero A, Conti E, Talamini R, Volpe R, Negri E, Barzan L, La Vecchia C. Food groups, oils and butter, and cancer of the oral cavity and pharynx. *Br J Cancer* 1999; **80**: 614-620 [PMID: 10408875 DOI: 10.1038/sj.bjc.6690400]
- 75 **Fioretti F**, Bosetti C, Tavani A, Franceschi S, La Vecchia C. Risk factors for oral and pharyngeal cancer in never smokers. *Oral Oncol* 1999; **35**: 375-378 [PMID: 10645401]
- 76 **Ahn J**, Segers S, Hayes RB. Periodontal disease, Porphyromonas gingivalis serum antibody levels and orodigestive cancer mortality. *Carcinogenesis* 2012; **33**: 1055-1058 [PMID: 22367402 DOI: 10.1093/carcin/bgs112]
- 77 **Meyer MS**, Joshipura K, Giovannucci E, Michaud DS. A review of the relationship between tooth loss, periodontal disease, and cancer. *Cancer Causes Control* 2008; **19**: 895-907 [PMID: 18478344 DOI: 10.1007/s10552-008-9163-4]
- 78 **Tezal M**, Sullivan MA, Hyland A, Marshall JR, Stoler D, Reid ME, Loree TR, Rigual NR, Merzianu M, Hauck L, Lillis C, Wactawski-Wende J, Scannapieco FA. Chronic periodontitis and the incidence of head and neck squamous cell carcinoma. *Cancer Epidemiol Biomarkers Prev* 2009; **18**: 2406-2412 [PMID: 19745222 DOI: 10.1158/1055-9965.EPI-09-0334]
- 79 **Kutler DL**, Auerbach AD, Satagopan J, Giampietro PF, Batish SD, Huvos AG, Goberdhan A, Shah JP, Singh B. High inci-

- dence of head and neck squamous cell carcinoma in patients with Fanconi anemia. *Arch Otolaryngol Head Neck Surg* 2003; **129**: 106-112 [PMID: 12525204]
- 80 **Kutler DI**, Wreesmann VB, Goberdhan A, Ben-Porat L, Sa-tagopan J, Ngai I, Huvo AG, Giampietro P, Levran O, Pu-jara K, Diotti R, Carlson D, Huryn LA, Auerbach AD, Singh B. Human papillomavirus DNA and p53 polymorphisms in squamous cell carcinomas from Fanconi anemia patients. *J Natl Cancer Inst* 2003; **95**: 1718-1721 [PMID: 14625263]
  - 81 **Toner M**, O'Regan EM. Head and neck squamous cell carcinoma in the young: a spectrum or a distinct group? Part 2. *Head Neck Pathol* 2009; **3**: 249-251 [PMID: 20596980 DOI: 10.1007/s12105-009-0137-y]
  - 82 **O'Regan EM**, Toner ME, Finn SP, Fan CY, Ring M, Hagmar B, Timon C, Smyth P, Cahill S, Flavin R, Sheils OM, O'Leary JJ. p16(INK4A) genetic and epigenetic profiles differ in relation to age and site in head and neck squamous cell carcinomas. *Hum Pathol* 2008; **39**: 452-458 [PMID: 18261630 DOI: 10.1016/j.humpath.2007.08.004]
  - 83 **Smith EM**, Ritchie JM, Summersgill KF, Klusmann JP, Lee JH, Wang D, Haugen TH, Turek LP. Age, sexual behavior and human papillomavirus infection in oral cavity and oropharyngeal cancers. *Int J Cancer* 2004; **108**: 766-772 [PMID: 14696105 DOI: 10.1002/ijc.11633]
  - 84 **El-Mofty SK**, Lu DW. Prevalence of human papillomavirus type 16 DNA in squamous cell carcinoma of the palate tonsil, and not the oral cavity, in young patients: a distinct clinicopathologic and molecular disease entity. *Am J Surg Pathol* 2003; **27**: 1463-1470 [PMID: 14576481]
  - 85 **Chaturvedi AK**, Anderson WF, Lortet-Tieulent J, Curado MP, Ferlay J, Franceschi S, Rosenberg PS, Bray F, Gillison ML. Worldwide trends in incidence rates for oral cavity and oropharyngeal cancers. *J Clin Oncol* 2013; **31**: 4550-4559 [PMID: 24248688 DOI: 10.1200/JCO.2013.50.3870]
  - 86 **Chaturvedi AK**, Engels EA, Anderson WF, Gillison ML. Incidence trends for human papillomavirus-related and -unrelated oral squamous cell carcinomas in the United States. *J Clin Oncol* 2008; **26**: 612-619 [PMID: 18235120 DOI: 10.1200/JCO.2007.14.1713]
  - 87 **Gillison ML**, D'Souza G, Westra W, Sugar E, Xiao W, Begum S, Viscidi R. Distinct risk factor profiles for human papillomavirus type 16-positive and human papillomavirus type 16-negative head and neck cancers. *J Natl Cancer Inst* 2008; **100**: 407-420 [PMID: 18334711 DOI: 10.1093/jnci/djn025]
  - 88 **Ritchie JM**, Smith EM, Summersgill KF, Hoffman HT, Wang D, Klusmann JP, Turek LP, Haugen TH. Human papillomavirus infection as a prognostic factor in carcinomas of the oral cavity and oropharynx. *Int J Cancer* 2003; **104**: 336-344 [PMID: 12569557 DOI: 10.1002/ijc.10960]
  - 89 **Smith EM**, Ritchie JM, Pawlita M, Rubenstein LM, Haugen TH, Turek LP, Hamsikova E. Human papillomavirus seropositivity and risks of head and neck cancer. *Int J Cancer* 2007; **120**: 825-832 [PMID: 17131312 DOI: 10.1002/ijc.22330]
  - 90 **Schwartz SM**, Daling JR, Doody DR, Wipf GC, Carter JJ, Madeleine MM, Mao EJ, Fitzgibbons ED, Huang S, Beckmann AM, McDougall JK, Galloway DA. Oral cancer risk in relation to sexual history and evidence of human papillomavirus infection. *J Natl Cancer Inst* 1998; **90**: 1626-1636 [PMID: 9811312]
  - 91 **Herrero R**, Castellsagué X, Pawlita M, Lissowska J, Kee F, Balaram P, Rajkumar T, Sridhar H, Rose B, Pintos J, Fernández L, Idris A, Sánchez MJ, Nieto A, Talamini R, Tavani A, Bosch FX, Reidel U, Snijders PJ, Meijer CJ, Viscidi R, Muñoz N, Franceschi S. Human papillomavirus and oral cancer: the International Agency for Research on Cancer multi-center study. *J Natl Cancer Inst* 2003; **95**: 1772-1783 [PMID: 14652239]
  - 92 **Martín-Hernán F**, Sánchez-Hernández JG, Cano J, Campo J, del Romero J. Oral cancer, HPV infection and evidence of sexual transmission. *Med Oral Patol Oral Cir Bucal* 2013; **18**: e439-e444 [PMID: 23524417]
  - 93 **Syrjanen S**, Termine N, Capra G, Paderni C, Panzarella V, Campisi G. Oral HPV infection: current strategies for prevention and therapy. *Curr Pharm Des* 2012; **18**: 5452-5469 [PMID: 22632393]
  - 94 **D'Souza G**, Dempsey A. The role of HPV in head and neck cancer and review of the HPV vaccine. *Prev Med* 2011; **53** Suppl 1: S5-S11 [PMID: 21962471 DOI: 10.1016/j.ypmed.2011.08.001]
  - 95 **D'Souza G**, Agrawal Y, Halpern J, Bodison S, Gillison ML. Oral sexual behaviors associated with prevalent oral human papillomavirus infection. *J Infect Dis* 2009; **199**: 1263-1269 [PMID: 19320589 DOI: 10.1086/597755]
  - 96 **Fakhry C**, D'souza G, Sugar E, Weber K, Goshu E, Minkoff H, Wright R, Seaberg E, Gillison M. Relationship between prevalent oral and cervical human papillomavirus infections in human immunodeficiency virus-positive and -negative women. *J Clin Microbiol* 2006; **44**: 4479-4485 [PMID: 17021055 DOI: 10.1128/JCM.01321-06]
  - 97 **Termine N**, Giovannelli L, Matranga D, Caleca MP, Bellavia C, Perino A, Campisi G. Oral human papillomavirus infection in women with cervical HPV infection: new data from an Italian cohort and a meta-analysis of the literature. *Oral Oncol* 2011; **47**: 244-250 [PMID: 21429788 DOI: 10.1016/j.oraloncology.2011.02.011]
  - 98 **Kreimer AR**, Alberg AJ, Daniel R, Gravitt PE, Viscidi R, Garrett ES, Shah KV, Gillison ML. Oral human papillomavirus infection in adults is associated with sexual behavior and HIV serostatus. *J Infect Dis* 2004; **189**: 686-698 [PMID: 14767823 DOI: 10.1086/381504]
  - 99 **Andrews E**, Shores C, Hayes DN, Couch M, Southerland J, Morris D, Seaman WT, Webster-Cyriaque J. Concurrent human papillomavirus-associated tonsillar carcinoma in 2 couples. *J Infect Dis* 2009; **200**: 882-887 [PMID: 19678755 DOI: 10.1086/605442]
  - 100 **Vogt SL**, Gravitt PE, Martinson NA, Hoffmann J, D'Souza G. Concordant Oral-Genital HPV Infection in South Africa Couples: Evidence for Transmission. *Front Oncol* 2013; **3**: 303 [PMID: 24377087 DOI: 10.3389/fonc.2013.00303]
  - 101 **Mbulawa ZZ**, Johnson LF, Marais DJ, Coetzee D, Williamson AL. Risk factors for oral human papillomavirus in heterosexual couples in an African setting. *J Infect* 2014; **68**: 185-189 [PMID: 24184808 DOI: 10.1016/j.jinf.2013.10.012]
  - 102 **Beder Ribeiro CM**, Ferrer I, Santos de Farias AB, Fonseca DD, Morais Silva IH, Monteiro Gueiros LA, Carvalho AT, Porter SR, Leao JC. Oral and genital HPV genotypic concordance between sexual partners. *Clin Oral Investig* 2014; **18**: 261-268 [PMID: 23483257 DOI: 10.1007/s00784-013-0959-6]
  - 103 **Pickard RK**, Xiao W, Broutian TR, He X, Gillison ML. The prevalence and incidence of oral human papillomavirus infection among young men and women, aged 18-30 years. *Sex Transm Dis* 2012; **39**: 559-566 [PMID: 22706220 DOI: 10.1097/OLQ.0b013e31824f1c65]
  - 104 **Rautava J**, Syrjänen S. Human papillomavirus infections in the oral mucosa. *J Am Dent Assoc* 2011; **142**: 905-914 [PMID: 21804057]
  - 105 **Rioux M**, Garland A, Webster D, Reardon E. HPV positive tonsillar cancer in two laser surgeons: case reports. *J Otolaryngol Head Neck Surg* 2013; **42**: 54 [PMID: 24246045 DOI: 10.1186/1916-0216-42-54]
  - 106 **Gillison ML**. Human papillomavirus-related diseases: oropharynx cancers and potential implications for adolescent HPV vaccination. *J Adolesc Health* 2008; **43**: S52-S60 [PMID: 18809146 DOI: 10.1016/j.jadohealth.2008.07.002]
  - 107 **Lingen MW**, Xiao W, Schmitt A, Jiang B, Pickard R, Kreinbrink P, Perez-Ordóñez B, Jordan RC, Gillison ML. Low etiologic fraction for high-risk human papillomavirus in oral cavity squamous cell carcinomas. *Oral Oncol* 2013; **49**: 1-8

- [PMID: 22841678 DOI: 10.1016/j.oraloncology.2012.07.002]
- 108 **D'Souza G**, Fakhry C, Sugar EA, Seaberg EC, Weber K, Minkoff HL, Anastos K, Palefsky JM, Gillison ML. Six-month natural history of oral versus cervical human papillomavirus infection. *Int J Cancer* 2007; **121**: 143-150 [PMID: 17354235 DOI: 10.1002/ijc.22667]
  - 109 **Stein AU**, Hariri S, Gillison ML, Broutian TR, Dunne EF, Tong ZY, Markowitz LE, Unger ER. Prevalence of Cervical and Oral Human Papillomavirus Infections Among US Women. *J Infect Dis* 2014; **209**: 1739-1743 [PMID: 24319284 DOI: 10.1093/infdis/jit799]
  - 110 **Kreimer AR**, Pierce Campbell CM, Lin HY, Fulp W, Papenfuss MR, Abrahamsen M, Hildesheim A, Villa LL, Salmerón JJ, Lazcano-Ponce E, Giuliano AR. Incidence and clearance of oral human papillomavirus infection in men: the HIM cohort study. *Lancet* 2013; **382**: 877-887 [PMID: 23827089 DOI: 10.1016/S0140-6736(13)60809-0]
  - 111 **Appleby P**, Beral V, Berrington de González A, Colin D, Franceschi S, Goodill A, Green J, Peto J, Plummer M, Sweetland S. Carcinoma of the cervix and tobacco smoking: collaborative reanalysis of individual data on 13,541 women with carcinoma of the cervix and 23,017 women without carcinoma of the cervix from 23 epidemiological studies. *Int J Cancer* 2006; **118**: 1481-1495 [PMID: 16206285 DOI: 10.1002/ijc.21493]
  - 112 **Lindell K**, Beer KT, Laissue J, Greiner RH, Aebbersold DM. Human papillomavirus positive squamous cell carcinoma of the oropharynx: a radiosensitive subgroup of head and neck carcinoma. *Cancer* 2001; **92**: 805-813 [PMID: 11550151]
  - 113 **Sinha P**, Logan HL, Mendenhall WM. Human papillomavirus, smoking, and head and neck cancer. *Am J Otolaryngol* 2012; **33**: 130-136 [PMID: 21546122 DOI: 10.1016/j.amjoto.2011.02.001]
  - 114 **Marks MA**, Chaturvedi AK, Kelsey K, Straif K, Berthiller J, Schwartz SM, Smith E, Wyss A, Brennan P, Olshan AF, Wei Q, Sturgis EM, Zhang ZF, Morgenstern H, Muscat J, Lazarus P, McClean M, Chen C, Vaughan TL, Wunsch-Filho V, Curado MP, Koifman S, Matos E, Menezes A, Daudt AW, Fernandez L, Posner M, Boffetta P, Lee YC, Hashibe M, D'Souza G. Association of marijuana smoking with oropharyngeal and oral tongue cancers: pooled analysis from the INHANCE consortium. *Cancer Epidemiol Biomarkers Prev* 2014; **23**: 160-171 [PMID: 24351902 DOI: 10.1158/1055-9965.EPI-13-0181]
  - 115 **American Lung Association - Epidemiology and Statistics Unit, Research and Program Services**. Trends in Tobacco Use. Washington, DC: American Lung Association, 2011
  - 116 **Colevas AD**. Population-based evaluation of incidence trends in oropharyngeal cancer focusing on socioeconomic status, sex, and race/ethnicity. *Head Neck* 2014; **36**: 34-42 [PMID: 23633438 DOI: 10.1002/hed.23253]
  - 117 **Warnakulasuriya S**. Global epidemiology of oral and oropharyngeal cancer. *Oral Oncol* 2009; **45**: 309-316 [PMID: 18804401 DOI: 10.1016/j.oraloncology.2008.06.002]
  - 118 **Shatalova EG**, Klein-Szanto AJ, Devarajan K, Cukierman E, Clapper ML. Estrogen and cytochrome P450 1B1 contribute to both early- and late-stage head and neck carcinogenesis. *Cancer Prev Res (Phila)* 2011; **4**: 107-115 [PMID: 21205741 DOI: 10.1158/1940-6207.CAPR-10-0133]
  - 119 **Markowitz LE**, Sternberg M, Dunne EF, McQuillan G, Unger ER. Seroprevalence of human papillomavirus types 6, 11, 16, and 18 in the United States: National Health and Nutrition Examination Survey 2003-2004. *J Infect Dis* 2009; **200**: 1059-1067 [PMID: 19719390 DOI: 10.1086/604729]
  - 120 **Safaeian M**, Porras C, Schiffman M, Rodriguez AC, Wacholder S, Gonzalez P, Quint W, van Doorn LJ, Sherman ME, Xhenseval V, Herrero R, Hildesheim A. Epidemiological study of anti-HPV16/18 seropositivity and subsequent risk of HPV16 and -18 infections. *J Natl Cancer Inst* 2010; **102**: 1653-1662 [PMID: 20944077 DOI: 10.1093/jnci/djq384]
  - 121 **Miller CS**, White DK. Human papillomavirus expression in oral mucosa, premalignant conditions, and squamous cell carcinoma: a retrospective review of the literature. *Oral Surg Oral Med Oral Pathol Oral Radiol Endod* 1996; **82**: 57-68 [PMID: 8843455]
  - 122 **Kreimer AR**, Villa A, Nyitray AG, Abrahamsen M, Papenfuss M, Smith D, Hildesheim A, Villa LL, Lazcano-Ponce E, Giuliano AR. The epidemiology of oral HPV infection among a multinational sample of healthy men. *Cancer Epidemiol Biomarkers Prev* 2011; **20**: 172-182 [PMID: 21148755 DOI: 10.1158/1055-9965.EPI-10-0682]
  - 123 **Engels EA**, Biggar RJ, Hall HI, Cross H, Crutchfield A, Finch JL, Grigg R, Hylton T, Pawlish KS, McNeel TS, Goedert JJ. Cancer risk in people infected with human immunodeficiency virus in the United States. *Int J Cancer* 2008; **123**: 187-194 [PMID: 18435450 DOI: 10.1002/ijc.23487]
  - 124 **Gillison ML**. Oropharyngeal cancer: a potential consequence of concomitant HPV and HIV infection. *Curr Opin Oncol* 2009; **21**: 439-444 [PMID: 19587593 DOI: 10.1097/CCO.0b013e32832f3e1b]
  - 125 **Beachler DC**, D'Souza G, Sugar EA, Xiao W, Gillison ML. Natural history of anal vs oral HPV infection in HIV-infected men and women. *J Infect Dis* 2013; **208**: 330-339 [PMID: 23596319 DOI: 10.1093/infdis/jit170]
  - 126 **García-Piñeres AJ**, Hildesheim A, Herrero R, Trivett M, Williams M, Atmetlla I, Ramírez M, Villegas M, Schiffman M, Rodríguez AC, Burk RD, Hildesheim M, Freer E, Bonilla J, Bratti C, Berzofsky JA, Pinto LA. Persistent human papillomavirus infection is associated with a generalized decrease in immune responsiveness in older women. *Cancer Res* 2006; **66**: 11070-11076 [PMID: 17108147 DOI: 10.1158/0008-5472.CAN-06-2034]
  - 127 **Keller MJ**, Burk RD, Xie X, Anastos K, Massad LS, Minkoff H, Xue X, D'Souza G, Watts DH, Levine AM, Castle PE, Colie C, Palefsky JM, Strickler HD. Risk of cervical precancer and cancer among HIV-infected women with normal cervical cytology and no evidence of oncogenic HPV infection. *JAMA* 2012; **308**: 362-369 [PMID: 22820789 DOI: 10.1001/jama.2012.5664]
  - 128 **Branca M**, Garbuglia AR, Benedetto A, Capiello T, Leoncini L, Migliore G, Agarossi A, Syrjänen K. Factors predicting the persistence of genital human papillomavirus infections and PAP smear abnormality in HIV-positive and HIV-negative women during prospective follow-up. *Int J STD AIDS* 2003; **14**: 417-425 [PMID: 12816671 DOI: 10.1258/095646203765371321]
  - 129 **Arnsperger C**, Shoenfeld Y, Amital H. Effects of tobacco smoke on immunity, inflammation and autoimmunity. *J Autoimmun* 2010; **34**: J258-J265 [PMID: 20042314 DOI: 10.1016/j.jaut.2009.12.003]
  - 130 **Simen-Kapeu A**, Kataja V, Yliskoski M, Syrjänen K, Dillner J, Koskela P, Paavonen J, Lehtinen M. Smoking impairs human papillomavirus (HPV) type 16 and 18 capsids antibody response following natural HPV infection. *Scand J Infect Dis* 2008; **40**: 745-751 [PMID: 19086247 DOI: 10.1080/00365540801995360]
  - 131 **O'Hanlon S**, Forster DP, Lowry RJ. Oral cancer in the North-East of England: incidence, mortality trends and the link with material deprivation. *Community Dent Oral Epidemiol* 1997; **25**: 371-376 [PMID: 9355775]
  - 132 **Boscolo-Rizzo P**, Del Mistro A, Bussu F, Lupato V, Baboci L, Almadori G, DA Mosto MC, Paludetti G. New insights into human papillomavirus-associated head and neck squamous cell carcinoma. *Acta Otorhinolaryngol Ital* 2013; **33**: 77-87 [PMID: 23853396]
  - 133 **Fakhry C**, Westra WH, Li S, Cmelak A, Ridge JA, Pinto H, Forastiere A, Gillison ML. Improved survival of patients with human papillomavirus-positive head and neck squamous cell carcinoma in a prospective clinical trial. *J Natl Cancer Inst* 2008; **100**: 261-269 [PMID: 18270337 DOI: 10.1093/jnci/djn011]



- 134 **Jiron J**, Sethi S, Ali-Fehmi R, Franceschi S, Struijk L, van Doorn LJ, Quint W, Kato I. Racial disparities in Human Papillomavirus (HPV) associated head and neck cancer. *Am J Otolaryngol* 2014; **35**: 147-153 [PMID: 24209992 DOI: 10.1016/j.amjoto.2013.09.004]
- 135 **Settle K**, Posner MR, Schumaker LM, Tan M, Suntharalingam M, Goloubeva O, Strome SE, Haddad RI, Patel SS, Campbell EV, Sarlis N, Lorch J, Cullen KJ. Racial survival disparity in head and neck cancer results from low prevalence of human papillomavirus infection in black oropharyngeal cancer patients. *Cancer Prev Res (Phila)* 2009; **2**: 776-781 [PMID: 19641042 DOI: 10.1158/1940-6207.CAPR-09-0149]
- 136 **Mork J**, Lie AK, Glatte E, Hallmans G, Jellum E, Koskela P, Møller B, Pukkala E, Schiller JT, Youngman L, Lehtinen M, Dillner J. Human papillomavirus infection as a risk factor for squamous-cell carcinoma of the head and neck. *N Engl J Med* 2001; **344**: 1125-1131 [PMID: 11297703 DOI: 10.1056/NEJM200104123441503]
- 137 **Kreimer AR**, Johansson M, Waterboer T, Kaaks R, Chang-Claude J, Drogen D, Tjønneland A, Overvad K, Quirós JR, González CA, Sánchez MJ, Larrañaga N, Navarro C, Barriarte A, Travis RC, Khaw KT, Wareham N, Trichopoulou A, Lagiou P, Trichopoulos D, Peeters PH, Panico S, Masala G, Grioni S, Tumino R, Vineis P, Bueno-de-Mesquita HB, Laurell G, Hallmans G, Manjer J, Ekström J, Skeie G, Lund E, Weiderpass E, Ferrari P, Byrnes G, Romieu I, Riboli E, Hildesheim A, Boeing H, Pawlita M, Brennan P. Evaluation of human papillomavirus antibodies and risk of subsequent head and neck cancer. *J Clin Oncol* 2013; **31**: 2708-2715 [PMID: 23775966 DOI: 10.1200/JCO.2012.47.2738]
- 138 **Toner M**, O'Regan EM. Head and neck squamous cell carcinoma in the young: a spectrum or a distinct group? Part 1. *Head Neck Pathol* 2009; **3**: 246-248 [PMID: 20596979 DOI: 10.1007/s12105-009-0135-0]
- 139 **Chung CH**, Parker JS, Karaca G, Wu J, Funkhouser WK, Moore D, Butterfoss D, Xiang D, Zanation A, Yin X, Shockley WW, Weissler MC, Dressler LG, Shores CG, Yarbrough WG, Perou CM. Molecular classification of head and neck squamous cell carcinomas using patterns of gene expression. *Cancer Cell* 2004; **5**: 489-500 [PMID: 15144956]
- 140 **Walter V**, Yin X, Wilkerson MD, Cabanski CR, Zhao N, Du Y, Ang MK, Hayward MC, Salazar AH, Hoadley KA, Fritchie K, Sailey CJ, Weissler MC, Shockley WW, Zanation AM, Hackman T, Thorne LB, Funkhouser WD, Muldrew KL, Olshan AF, Randell SH, Wright FA, Shores CG, Hayes DN. Molecular subtypes in head and neck cancer exhibit distinct patterns of chromosomal gain and loss of canonical cancer genes. *PLoS One* 2013; **8**: e56823 [PMID: 23451093 DOI: 10.1371/journal.pone.0056823]
- 141 **Agrawal N**, Frederick MJ, Pickering CR, Bettgowda C, Chang K, Li RJ, Fakhry C, Xie TX, Zhang J, Wang J, Zhang N, El-Naggar AK, Jasser SA, Weinstein JN, Treviño L, Drummond JA, Muzny DM, Wu Y, Wood LD, Hruban RH, Westra WH, Koch WM, Califano JA, Gibbs RA, Sidransky D, Vogelstein B, Velculescu VE, Papadopoulos N, Wheeler DA, Kinzler KW, Myers JN. Exome sequencing of head and neck squamous cell carcinoma reveals inactivating mutations in NOTCH1. *Science* 2011; **333**: 1154-1157 [PMID: 21798897 DOI: 10.1126/science.1206923]
- 142 **Stransky N**, Egloff AM, Tward AD, Kostic AD, Cibulskis K, Sivachenko A, Kryukov GV, Lawrence MS, Sougnez C, McKenna A, Shefler E, Ramos AH, Stojanov P, Carter SL, Voet D, Cortés ML, Auclair D, Berger MF, Saksena G, Guiducci C, Onofrio RC, Parkin M, Romkes M, Weissfeld JL, Seethala RR, Wang L, Rangel-Escareño C, Fernandez-Lopez JC, Hidalgo-Miranda A, Melendez-Zajgla J, Winckler W, Ardlie K, Gabriel SB, Meyerson M, Lander ES, Getz G, Golub TR, Garraway LA, Grandis JR. The mutational landscape of head and neck squamous cell carcinoma. *Science* 2011; **333**: 1157-1160 [PMID: 21798893 DOI: 10.1126/science.1208130]
- 143 **Zhang XC**, Xu C, Mitchell RM, Zhang B, Zhao D, Li Y, Huang X, Fan W, Wang H, Lerma LA, Upton MP, Hay A, Méndez E, Zhao LP. Tumor evolution and intratumor heterogeneity of an oropharyngeal squamous cell carcinoma revealed by whole-genome sequencing. *Neoplasia* 2013; **15**: 1371-1378 [PMID: 24403859]
- 144 **Lui VW**, Hedberg ML, Li H, Vangara BS, Pendleton K, Zeng Y, Lu Y, Zhang Q, Du Y, Gilbert BR, Freilino M, Sauerwein S, Peyser ND, Xiao D, Diergaarde B, Wang L, Chiosea S, Seethala R, Johnson JT, Kim S, Duvvuri U, Ferris RL, Romkes M, Nukui T, Kwok-Shing Ng P, Garraway LA, Hammerman PS, Mills GB, Grandis JR. Frequent mutation of the PI3K pathway in head and neck cancer defines predictive biomarkers. *Cancer Discov* 2013; **3**: 761-769 [PMID: 23619167 DOI: 10.1158/2159-8290.CD-13-0103]
- 145 **Rothenberg SM**, Ellisen LW. The molecular pathogenesis of head and neck squamous cell carcinoma. *J Clin Invest* 2012; **122**: 1951-1957 [PMID: 22833868]
- 146 **Chinn SB**, Darr OA, Owen JH, Bellile E, McHugh JB, Spector ME, Papagerakis SM, Chepeha DB, Bradford CR, Carey TE, Prince ME. Cancer stem cells: Mediators of tumorigenesis and metastasis in head and neck squamous cell carcinoma. *Head Neck* 2014 Jan 10; Epub ahead of print [PMID: 24415402 DOI: 10.1002/hed.23600]
- 147 **Chinn SB**, Darr OA, Peters RD, Prince ME. The role of head and neck squamous cell carcinoma cancer stem cells in tumorigenesis, metastasis, and treatment failure. *Front Endocrinol (Lausanne)* 2012; **3**: 90 [PMID: 22876238 DOI: 10.3389/fendo.2012.00090]
- 148 **Rastogi P**. Emergence of cancer stem cells in head and neck squamous cell carcinoma: A therapeutic insight with literature review. *Dent Res J (Isfahan)* 2012; **9**: 239-244 [PMID: 23087725]
- 149 **Bhaijee F**, Pepper DJ, Pitman KT, Bell D. Cancer stem cells in head and neck squamous cell carcinoma: a review of current knowledge and future applications. *Head Neck* 2012; **34**: 894-899 [PMID: 21850700 DOI: 10.1002/hed.21801]
- 150 **Iglesias-Bartolome R**, Martin D, Gutkind JS. Exploiting the head and neck cancer oncogene: widespread PI3K-mTOR pathway alterations and novel molecular targets. *Cancer Discov* 2013; **3**: 722-725 [PMID: 23847349 DOI: 10.1158/2159-8290.CD-13-0239]
- 151 **Urashima M**, Hama T, Suda T, Suzuki Y, Ikegami M, Sakanashi C, Akutsu T, Amagaya S, Horiuchi K, Imai Y, Mezawa H, Noya M, Nakashima A, Mafune A, Kato T, Kojima H. Distinct effects of alcohol consumption and smoking on genetic alterations in head and neck carcinoma. *PLoS One* 2013; **8**: e80828 [PMID: 24278325 DOI: 10.1371/journal.pone.0080828]
- 152 **SLAUGHTER DP**, SOUTHWICK HW, SMEJKAL W. Field cancerization in oral stratified squamous epithelium; clinical implications of multicentric origin. *Cancer* 1953; **6**: 963-968 [PMID: 13094644]
- 153 **Graveland AP**, Bremmer JF, de Maaker M, Brink A, Cobussen P, Zwart M, Braakhuis BJ, Bloemena E, van der Waal I, Leemans CR, Brakenhoff RH. Molecular screening of oral precancer. *Oral Oncol* 2013; **49**: 1129-1135 [PMID: 24120275 DOI: 10.1016/j.oraloncology.2013.09.005]
- 154 **Lucio M**, Andrea G, Bartolomeo GD, Fabio C, Dora S. Between-lesion discrepancies in terms of dysplasia, cell turnover and diagnosis in patients with multiple potentially malignant oral lesions. *Open Dent J* 2013; **7**: 169-174 [PMID: 24363787 DOI: 10.2174/1874210601307010169]
- 155 **Sudbø J**, Bryne M, Johannessen AC, Kildal W, Danielsen HE, Reith A. Comparison of histological grading and large-scale genomic status (DNA ploidy) as prognostic tools in oral dysplasia. *J Pathol* 2001; **194**: 303-310 [PMID: 11439362 DOI: 10.1002/1096-9896(200107)194]
- 156 **Sudbø J**, Kildal W, Johannessen AC, Koppang HS, Sudbø A, Danielsen HE, Risberg B, Reith A. Gross genomic aberrations



- in precancers: clinical implications of a long-term follow-up study in oral erythroplakias. *J Clin Oncol* 2002; **20**: 456-462 [PMID: 11786574]
- 157 **Rietbergen MM**, Braakhuis BJ, Moukhtari N, Bloemena E, Brink A, Sie D, Ylstra B, Baatenburg de Jong RJ, Snijders PJ, Brakenhoff RH, Leemans CR. No evidence for active human papillomavirus (HPV) in fields surrounding HPV-positive oropharyngeal tumors. *J Oral Pathol Med* 2014; **43**: 137-142 [PMID: 24118314 DOI: 10.1111/jop.12123]
  - 158 **Jain KS**, Sikora AG, Baxi SS, Morris LG. Synchronous cancers in patients with head and neck cancer: risks in the era of human papillomavirus-associated oropharyngeal cancer. *Cancer* 2013; **119**: 1832-1837 [PMID: 23423883 DOI: 10.1002/cncr.27988]
  - 159 **Smeets SJ**, Braakhuis BJ, Abbas S, Snijders PJ, Ylstra B, van de Wiel MA, Meijer GA, Leemans CR, Brakenhoff RH. Genome-wide DNA copy number alterations in head and neck squamous cell carcinomas with or without oncogene-expressing human papillomavirus. *Oncogene* 2006; **25**: 2558-2564 [PMID: 16314836 DOI: 10.1038/sj.onc.1209275]
  - 160 **Wilting SM**, Smeets SJ, Snijders PJ, van Wieringen WN, van de Wiel MA, Meijer GA, Ylstra B, Leemans CR, Meijer CJ, Brakenhoff RH, Braakhuis BJ, Steenbergen RD. Genomic profiling identifies common HPV-associated chromosomal alterations in squamous cell carcinomas of cervix and head and neck. *BMC Med Genomics* 2009; **2**: 32 [PMID: 19486517 DOI: 10.1186/1755-8794-2-32]
  - 161 **Perrone F**, Suardi S, Pastore E, Casieri P, Orsenigo M, Caramuta S, Dagrada G, Losa M, Licitra L, Bossi P, Staurengo S, Oggionni M, Locati L, Cantu G, Squadrelli M, Carbone A, Pierotti MA, Pilotti S. Molecular and cytogenetic subgroups of oropharyngeal squamous cell carcinoma. *Clin Cancer Res* 2006; **12**: 6643-6651 [PMID: 17121883 DOI: 10.1158/1078-0432.CCR-06-1759]
  - 162 **Strati K**, Lambert PF. Human papillomavirus association with head and neck cancers: understanding virus biology and using it in the development of cancer diagnostics. *Expert Opin Med Diagn* 2008; **2**: 11-20 [PMID: 20419065 DOI: 10.1517/17530059.2.1.11]
  - 163 **Doorbar J**. Molecular biology of human papillomavirus infection and cervical cancer. *Clin Sci (Lond)* 2006; **110**: 525-541 [PMID: 16597322 DOI: 10.1042/CS20050369]
  - 164 **Heffernan CB**, O'Neill JP, Timon C. Oncogenic impact of human papilloma virus in head and neck cancer. *J Laryngol Otol* 2010; **124**: 941-944 [PMID: 20519038 DOI: 10.1017/S0022215110001179]
  - 165 **Kim SH**, Koo BS, Kang S, Park K, Kim H, Lee KR, Lee MJ, Kim JM, Choi EC, Cho NH. HPV integration begins in the tonsillar crypt and leads to the alteration of p16, EGFR and c-myc during tumor formation. *Int J Cancer* 2007; **120**: 1418-1425 [PMID: 17205528 DOI: 10.1002/ijc.22464]
  - 166 **Thavaraj S**, Stokes A, Mazuno K, Henley-Smith R, Suh YE, Paleri V, Tavassoli M, Odell E, Robinson M. Patients with HPV-related tonsil squamous cell carcinoma rarely harbour oncogenic HPV infection at other pharyngeal sites. *Oral Oncol* 2014; **50**: 241-246 [PMID: 24434066 DOI: 10.1016/j.oraloncology.2013.12.012]
  - 167 **Rautava J**, Syrjänen S. Biology of human papillomavirus infections in head and neck carcinogenesis. *Head Neck Pathol* 2012; **6** Suppl 1: S3-S15 [PMID: 22782219 DOI: 10.1007/s12105-012-0367-2]
  - 168 **Fujimura Y**, Takeda M, Ikai H, Haruma K, Akisada T, Harada T, Sakai T, Ohuchi M. The role of M cells of human nasopharyngeal lymphoid tissue in influenza virus sampling. *Virchows Arch* 2004; **444**: 36-42 [PMID: 14551766 DOI: 10.1007/s00428-003-0898-8]
  - 169 **Moutsopoulos NM**, Vázquez N, Greenwell-Wild T, Ecevit I, Horn J, Orenstein J, Wahl SM. Regulation of the tonsil cytokine milieu favors HIV susceptibility. *J Leukoc Biol* 2006; **80**: 1145-1155 [PMID: 16943383 DOI: 10.1189/jlb.0306142]
  - 170 **Hafkamp HC**, Speel EJ, Haesevoets A, Bot FJ, Dinjens WN, Ramaekers FC, Hopman AH, Manni JJ. A subset of head and neck squamous cell carcinomas exhibits integration of HPV 16/18 DNA and overexpression of p16INK4A and p53 in the absence of mutations in p53 exons 5-8. *Int J Cancer* 2003; **107**: 394-400 [PMID: 14506739 DOI: 10.1002/ijc.11389]
  - 171 **Herfs M**, Yamamoto Y, Laury A, Wang X, Nucci MR, McLaughlin-Drubin ME, Mürner K, Feldman S, McKeon FD, Xian W, Crum CP. A discrete population of squamocolumnar junction cells implicated in the pathogenesis of cervical cancer. *Proc Natl Acad Sci USA* 2012; **109**: 10516-10521 [PMID: 22689991 DOI: 10.1073/pnas.1202684109]
  - 172 **Herfs M**, Vargas SO, Yamamoto Y, Howitt BE, Nucci MR, Hornick JL, McKeon FD, Xian W, Crum CP. A novel blueprint for 'top down' differentiation defines the cervical squamocolumnar junction during development, reproductive life, and neoplasia. *J Pathol* 2013; **229**: 460-468 [PMID: 23007879 DOI: 10.1002/path.4110]
  - 173 **Herfs M**, Parra-Herran C, Howitt BE, Laury AR, Nucci MR, Feldman S, Jimenez CA, McKeon FD, Xian W, Crum CP. Cervical squamocolumnar junction-specific markers define distinct, clinically relevant subsets of low-grade squamous intraepithelial lesions. *Am J Surg Pathol* 2013; **37**: 1311-1318 [PMID: 24076771 DOI: 10.1097/PAS.0b013e3182989ee2]
  - 174 **Brook I**. The clinical microbiology of Waldeyer's ring. *Otolaryngol Clin North Am* 1987; **20**: 259-272 [PMID: 3299209]
  - 175 **Wheeler CM**. Natural history of human papillomavirus infections, cytologic and histologic abnormalities, and cancer. *Obstet Gynecol Clin North Am* 2008; **35**: 519-536; vii [PMID: 19061814 DOI: 10.1016/j.ogc.2008.09.006]
  - 176 **Franco EL**, Villa LL, Sobrinho JP, Prado JM, Rousseau MC, Désy M, Rohan TE. Epidemiology of acquisition and clearance of cervical human papillomavirus infection in women from a high-risk area for cervical cancer. *J Infect Dis* 1999; **180**: 1415-1423 [PMID: 10515798 DOI: 10.1086/315086]
  - 177 **Lace MJ**, Anson JR, Klussmann JP, Wang DH, Smith EM, Haugen TH, Turek LP. Human papillomavirus type 16 (HPV-16) genomes integrated in head and neck cancers and in HPV-16-immortalized human keratinocyte clones express chimeric virus-cell mRNAs similar to those found in cervical cancers. *J Virol* 2011; **85**: 1645-1654 [PMID: 21123375 DOI: 10.1128/JVI.02093-10]
  - 178 **Park IS**, Chang X, Loyo M, Wu G, Chuang A, Kim MS, Chae YK, Lyford-Pike S, Westra WH, Saunders JR, Sidransky D, Pai SI. Characterization of the methylation patterns in human papillomavirus type 16 viral DNA in head and neck cancers. *Cancer Prev Res (Phila)* 2011; **4**: 207-217 [PMID: 21292634 DOI: 10.1158/1940-6207.CAPR-10-0147]
  - 179 **Woo SB**, Cashman EC, Lerman MA. Human papillomavirus-associated oral intraepithelial neoplasia. *Mod Pathol* 2013; **26**: 1288-1297 [PMID: 23599160 DOI: 10.1038/modpathol.2013.70]
  - 180 **Kreimer AR**, Chaturvedi AK. HPV-associated Oropharyngeal Cancers--Are They Preventable? *Cancer Prev Res (Phila)* 2011; **4**: 1346-1349 [PMID: 21893495 DOI: 10.1158/1940-6207.CAPR-11-0379]
  - 181 **Fakhry C**, Rosenthal BT, Clark DP, Gillison ML. Associations between oral HPV16 infection and cytopathology: evaluation of an oropharyngeal "pap-test equivalent" in high-risk populations. *Cancer Prev Res (Phila)* 2011; **4**: 1378-1384 [PMID: 21836021 DOI: 10.1158/1940-6207.CAPR-11-0284]
  - 182 **Rampias T**, Sasaki C, Weinberger P, Psyrris A. E6 and e7 gene silencing and transformed phenotype of human papillomavirus 16-positive oropharyngeal cancer cells. *J Natl Cancer Inst* 2009; **101**: 412-423 [PMID: 19276448 DOI: 10.1093/jnci/djp017]
  - 183 **Rampias T**, Sasaki C, Psyrris A. Molecular mechanisms of HPV induced carcinogenesis in head and neck. *Oral Oncol* 2014; **50**: 356-363 [PMID: 23953776 DOI: 10.1016/j.oraloncology.2013.07.011]

- 184 **Oh JE**, Kim JO, Shin JY, Zhang XH, Won HS, Chun SH, Jung CK, Park WS, Nam SW, Eun JW, Kang JH. Molecular genetic characterization of p53 mutated oropharyngeal squamous cell carcinoma cells transformed with human papillomavirus E6 and E7 oncogenes. *Int J Oncol* 2013; **43**: 383-393 [PMID: 23708675 DOI: 10.3892/ijo.2013.1953]
- 185 **Duensing S**, Munger K. Mechanisms of genomic instability in human cancer: insights from studies with human papillomavirus oncoproteins. *Int J Cancer* 2004; **109**: 157-162 [PMID: 14750163 DOI: 10.1002/ijc.11691]
- 186 **Gao G**, Johnson SH, Kasperbauer JL, Eckloff BW, Tombers NM, Vasmatazis G, Smith DI. Mate pair sequencing of oropharyngeal squamous cell carcinomas reveals that HPV integration occurs much less frequently than in cervical cancer. *J Clin Virol* 2014; **59**: 195-200 [PMID: 24440282 DOI: 10.1016/j.jcv.2013.12.006]
- 187 **Olthof NC**, Speel EJ, Kolligs J, Haesevoets A, Henfling M, Ramaekers FC, Preuss SF, Drebber U, Wieland U, Silling S, Lam WL, Vucic EA, Kremer B, Klussmann JP, Huebbers CU. Comprehensive analysis of HPV16 integration in OSCC reveals no significant impact of physical status on viral oncogene and virally disrupted human gene expression. *PLoS One* 2014; **9**: e88718 [PMID: 24586376 DOI: 10.1371/journal.pone.0088718]
- 188 **Pannone G**, Rodolico V, Santoro A, Lo Muzio L, Franco R, Botti G, Aquino G, Pedicillo MC, Cagiano S, Campisi G, Rubini C, Papagerakis S, De Rosa G, Tornesello ML, Buonaguro FM, Staibano S, Bufo P. Evaluation of a combined triple method to detect causative HPV in oral and oropharyngeal squamous cell carcinomas: p16 Immunohistochemistry, Consensus PCR HPV-DNA, and In Situ Hybridization. *Infect Agent Cancer* 2012; **7**: 4 [PMID: 22376902 DOI: 10.1186/1750-9378-7-4]
- 189 **Schmitt M**, Depuydt C, Benoy I, Bogers J, Antoine J, Arbyn M, Pawlita M. Multiple human papillomavirus infections with high viral loads are associated with cervical lesions but do not differentiate grades of cervical abnormalities. *J Clin Microbiol* 2013; **51**: 1458-1464 [PMID: 23447632 DOI: 10.1128/JCM.00087-13]
- 190 **Holzinger D**, Schmitt M, Dyckhoff G, Benner A, Pawlita M, Bosch FX. Viral RNA patterns and high viral load reliably define oropharynx carcinomas with active HPV16 involvement. *Cancer Res* 2012; **72**: 4993-5003 [PMID: 22991302 DOI: 10.1158/0008-5472.CAN-11-3934]
- 191 **Jung AC**, Briolat J, Millon R, de Reynies A, Rickman D, Thomas E, Abecassis J, Clavel C, Wasyluk B. Biological and clinical relevance of transcriptionally active human papillomavirus (HPV) infection in oropharynx squamous cell carcinoma. *Int J Cancer* 2010; **126**: 1882-1894 [PMID: 19795456 DOI: 10.1002/ijc.24911]
- 192 **Smeets SJ**, Hesselink AT, Speel EJ, Haesevoets A, Snijders PJ, Pawlita M, Meijer CJ, Braakhuis BJ, Leemans CR, Brakenhoff RH. A novel algorithm for reliable detection of human papillomavirus in paraffin embedded head and neck cancer specimen. *Int J Cancer* 2007; **121**: 2465-2472 [PMID: 17680565 DOI: 10.1002/ijc.22980]
- 193 **Thomas M**, Pim D, Banks L. The role of the E6-p53 interaction in the molecular pathogenesis of HPV. *Oncogene* 1999; **18**: 7690-7700 [PMID: 10618709 DOI: 10.1038/sj.onc.1202953]
- 194 **McMurray HR**, McCance DJ. Human papillomavirus type 16 E6 activates TERT gene transcription through induction of c-Myc and release of USF-mediated repression. *J Virol* 2003; **77**: 9852-9861 [PMID: 12941894]
- 195 **Mischo A**, Ohlenschlager O, Hortschansky P, Ramachandran R, Gorlach M. Structural insights into a wildtype domain of the oncoprotein E6 and its interaction with a PDZ domain. *PLoS One* 2013; **8**: e62584 [PMID: 23638119 DOI: 10.1371/journal.pone.0062584]
- 196 **Liu X**, Clements A, Zhao K, Marmorstein R. Structure of the human Papillomavirus E7 oncoprotein and its mechanism for inactivation of the retinoblastoma tumor suppressor. *J Biol Chem* 2006; **281**: 578-586 [PMID: 16249186 DOI: 10.1074/jbc.M508455200]
- 197 **Bose S**, Evans H, Lantzy L, Scharre K, Youssef E. p16(INK4A) is a surrogate biomarker for a subset of human papilloma virus-associated dysplasias of the uterine cervix as determined on the Pap smear. *Diagn Cytopathol* 2005; **32**: 21-24 [PMID: 15584047 DOI: 10.1002/dc.20175]
- 198 **Schlecht NF**, Brandwein-Gensler M, Nuovo GJ, Li M, Dunne A, Kawachi N, Smith RV, Burk RD, Prystowsky MB. A comparison of clinically utilized human papillomavirus detection methods in head and neck cancer. *Mod Pathol* 2011; **24**: 1295-1305 [PMID: 21572401 DOI: 10.1038/modpathol.2011.91]
- 199 **El-Naggar AK**, Westra WH. p16 expression as a surrogate marker for HPV-related oropharyngeal carcinoma: a guide for interpretative relevance and consistency. *Head Neck* 2012; **34**: 459-461 [PMID: 22180304 DOI: 10.1002/hed.21974]
- 200 **Wang H**, Sun R, Lin H, Hu WH. P16INK4A as a surrogate biomarker for human papillomavirus-associated oropharyngeal carcinoma: consideration of some aspects. *Cancer Sci* 2013; **104**: 1553-1559 [PMID: 24344719 DOI: 10.1111/cas.12287]
- 201 **Moody CA**, Laimins LA. Human papillomavirus oncoproteins: pathways to transformation. *Nat Rev Cancer* 2010; **10**: 550-560 [PMID: 20592731 DOI: 10.1038/nrc2886]
- 202 **Jabbar S**, Strati K, Shin MK, Pitot HC, Lambert PF. Human papillomavirus type 16 E6 and E7 oncoproteins act synergistically to cause head and neck cancer in mice. *Virology* 2010; **407**: 60-67 [PMID: 20797753 DOI: 10.1016/j.virol.2010.08.003]
- 203 **Schlecht NF**, Burk RD, Adrien L, Dunne A, Kawachi N, Sarta C, Chen Q, Brandwein-Gensler M, Prystowsky MB, Childs G, Smith RV, Belbin TJ. Gene expression profiles in HPV-infected head and neck cancer. *J Pathol* 2007; **213**: 283-293 [PMID: 17893858 DOI: 10.1002/path.2227]
- 204 **Jenkins G**, O'Byrne KJ, Panizza B, Richard DJ. Genome Stability Pathways in Head and Neck Cancers. *Int J Genomics* 2013; **2013**: 464720 [PMID: 24364026 DOI: 10.1155/2013/464720]
- 205 **Duensing S**, Lee LY, Duensing A, Basile J, Piboonniyom S, Gonzalez S, Crum CP, Munger K. The human papillomavirus type 16 E6 and E7 oncoproteins cooperate to induce mitotic defects and genomic instability by uncoupling centrosome duplication from the cell division cycle. *Proc Natl Acad Sci USA* 2000; **97**: 10002-10007 [PMID: 10944189 DOI: 10.1073/pnas.170093297]
- 206 **Patel D**, Incassati A, Wang N, McCance DJ. Human papillomavirus type 16 E6 and E7 cause polyploidy in human keratinocytes and up-regulation of G2-M-phase proteins. *Cancer Res* 2004; **64**: 1299-1306 [PMID: 14973072]
- 207 **Duensing S**, Munger K. The human papillomavirus type 16 E6 and E7 oncoproteins independently induce numerical and structural chromosome instability. *Cancer Res* 2002; **62**: 7075-7082 [PMID: 12460929]
- 208 **Akagi K**, Li J, Broutian TR, Padilla-Nash H, Xiao W, Jiang B, Rocco JW, Teknos TN, Kumar B, Wangsa D, He D, Ried T, Symer DE, Gillison ML. Genome-wide analysis of HPV integration in human cancers reveals recurrent, focal genomic instability. *Genome Res* 2014; **24**: 185-199 [PMID: 24201445 DOI: 10.1101/gr.164806.113]
- 209 **Strati K**, Pitot HC, Lambert PF. Identification of biomarkers that distinguish human papillomavirus (HPV)-positive versus HPV-negative head and neck cancers in a mouse model. *Proc Natl Acad Sci U S A* 2006; **103**: 14152-14157 [PMID: 16959885 DOI: 10.1073/pnas.0606698103]
- 210 **Sartor MA**, Dolinoy DC, Jones TR, Colacino JA, Prince ME, Carey TE, Rozek LS. Genome-wide methylation and expression differences in HPV(+) and HPV(-) squamous cell carcinoma cell lines are consistent with divergent mechanisms of carcinogenesis. *Epigenetics* 2011; **6**: 777-787 [PMID: 21613826]

- 211 **Lajer CB**, Garnæs E, Friis-Hansen L, Norrild B, Therkildsen MH, Glud M, Rossing M, Lajer H, Svane D, Skotte L, Specht L, Buchwald C, Nielsen FC. The role of miRNAs in human papilloma virus (HPV)-associated cancers: bridging between HPV-related head and neck cancer and cervical cancer. *Br J Cancer* 2012; **106**: 1526-1534 [PMID: 22472886 DOI: 10.1038/bjc.2012.109]
- 212 **Pickering CR**, Zhang J, Yoo SY, Bengtsson L, Moorthy S, Neskey DM, Zhao M, Ortega Alves MV, Chang K, Drummond J, Cortez E, Xie TX, Zhang D, Chung W, Issa JP, Zweidler-McKay PA, Wu X, El-Naggar AK, Weinstein JN, Wang J, Muzny DM, Gibbs RA, Wheeler DA, Myers JN, Frederick MJ. Integrative genomic characterization of oral squamous cell carcinoma identifies frequent somatic drivers. *Cancer Discov* 2013; **3**: 770-781 [PMID: 23619168 DOI: 10.1158/2159-8290.CD-12-0537]
- 213 **Hafkamp HC**, Manni JJ, Speel EJ. Role of human papillomavirus in the development of head and neck squamous cell carcinomas. *Acta Otolaryngol* 2004; **124**: 520-526 [PMID: 15224887]
- 214 **Liang C**, Marsit CJ, McClean MD, Nelson HH, Christensen BC, Haddad RI, Clark JR, Wein RO, Grillone GA, Houseman EA, Halec G, Waterboer T, Pawlita M, Krane JF, Kelsey KT. Biomarkers of HPV in head and neck squamous cell carcinoma. *Cancer Res* 2012; **72**: 5004-5013 [PMID: 22991304 DOI: 10.1158/0008-5472.CAN-11-3277]
- 215 **Hirshoren N**, Bulvik R, Neuman T, Rubinstein AM, Meirovitz A, Elkin M. Induction of heparanase by HPV E6 oncogene in head and neck squamous cell carcinoma. *J Cell Mol Med* 2014; **18**: 181-186 [PMID: 24286246 DOI: 10.1111/jcmm.12179]
- 216 **Rainsbury JW**, Ahmed W, Williams HK, Roberts S, Paleri V, Mehanna H. Prognostic biomarkers of survival in oropharyngeal squamous cell carcinoma: systematic review and meta-analysis. *Head Neck* 2013; **35**: 1048-1055 [PMID: 22997051 DOI: 10.1002/hed.22950]
- 217 **Ragin CC**, Taioli E. Survival of squamous cell carcinoma of the head and neck in relation to human papillomavirus infection: review and meta-analysis. *Int J Cancer* 2007; **121**: 1813-1820 [PMID: 17546592 DOI: 10.1002/ijc.22851]
- 218 **Duray A**, Descamps G, Decaestecker C, Rimmelinck M, Sirtaine N, Lechien J, Ernoux-Neufcoeur P, Bletard N, Somja J, Depuydt CE, Delvenne P, Saussez S. Human papillomavirus DNA strongly correlates with a poorer prognosis in oral cavity carcinoma. *Laryngoscope* 2012; **122**: 1558-1565 [PMID: 22532307 DOI: 10.1002/lary.23298]
- 219 **Ernoux-Neufcoeur P**, Arafa M, Decaestecker C, Duray A, Rimmelinck M, Leroy X, Herfs M, Somja J, Depuydt CE, Delvenne P, Saussez S. Combined analysis of HPV DNA, p16, p21 and p53 to predict prognosis in patients with stage IV hypopharyngeal carcinoma. *J Cancer Res Clin Oncol* 2011; **137**: 173-181 [PMID: 20376678 DOI: 10.1007/s00432-010-0871-2]
- 220 **Rischin D**, Young RJ, Fisher R, Fox SB, Le QT, Peters LJ, Solomon B, Choi J, O'Sullivan B, Kenny LM, McArthur GA. Prognostic significance of p16INK4A and human papillomavirus in patients with oropharyngeal cancer treated on TROG 02.02 phase III trial. *J Clin Oncol* 2010; **28**: 4142-4148 [PMID: 20697079 DOI: 10.1200/JCO.2010.29.2904]
- 221 **Klussmann JP**, Gültekin E, Weissenborn SJ, Wieland U, Dries V, Dienes HP, Eckel HE, Pfister HJ, Fuchs PG. Expression of p16 protein identifies a distinct entity of tonsillar carcinomas associated with human papillomavirus. *Am J Pathol* 2003; **162**: 747-753 [PMID: 12598309 DOI: 10.1016/S0002-9440(10)63871-0]
- 222 **Lewis JS**, Thorstad WL, Chernock RD, Haughey BH, Yip JH, Zhang Q, El-Mofty SK. p16 positive oropharyngeal squamous cell carcinoma: an entity with a favorable prognosis regardless of tumor HPV status. *Am J Surg Pathol* 2010; **34**: 1088-1096 [PMID: 20588174 DOI: 10.1097/PAS.0b013e3181e84652]
- 223 **Stephen JK**, Divine G, Chen KM, Chitale D, Havard S, Worsham MJ. Significance of p16 in Site-specific HPV Positive and HPV Negative Head and Neck Squamous Cell Carcinoma. *Cancer Clin Oncol* 2013; **2**: 51-61 [PMID: 23935769]
- 224 **Park K**, Cho KJ, Lee M, Yoon DH, Kim J, Kim SY, Nam SY, Choi SH, Roh JL, Han MW, Lee SW, Song SY, Back JH, Kim SB. p16 immunohistochemistry alone is a better prognosticator in tonsil cancer than human papillomavirus in situ hybridization with or without p16 immunohistochemistry. *Acta Otolaryngol* 2013; **133**: 297-304 [PMID: 23130632 DOI: 10.3109/00016489.2012.741327]
- 225 **Zhao N**, Ang MK, Yin XY, Patel MR, Fritchie K, Thorne L, Muldrew KL, Hayward MC, Sun W, Wilkerson MD, Chera BS, Hackman T, Zanation AM, Grilley-Olson JE, Couch ME, Shockley WW, Weissler MC, Shores CG, Funkhouser WK, Olshan AF, Hayes DN. Different cellular p16(INK4a) localisation may signal different survival outcomes in head and neck cancer. *Br J Cancer* 2012; **107**: 482-490 [PMID: 22735904 DOI: 10.1038/bjc.2012.264]
- 226 **Klingenberg B**, Hafkamp HC, Haesevoets A, Manni JJ, Slootweg PJ, Weissenborn SJ, Klussmann JP, Speel EJ. p16 INK4A overexpression is frequently detected in tumour-free tonsil tissue without association with HPV. *Histopathology* 2010; **56**: 957-967 [PMID: 20636796 DOI: 10.1111/j.1365-2559.2010.03576.x]
- 227 **Rayess H**, Wang MB, Srivatsan ES. Cellular senescence and tumor suppressor gene p16. *Int J Cancer* 2012; **130**: 1715-1725 [PMID: 22025288 DOI: 10.1002/ijc.27316]
- 228 **Hoffmann M**, Tribius S, Quabius ES, Henry H, Pfannenschmidt S, Burkhardt C, Görögh T, Halec G, Hoffmann AS, Kahn T, Röcken C, Haag J, Waterboer T, Schmitt M. HPV DNA, E6\*I-mRNA expression and p16INK4A immunohistochemistry in head and neck cancer - how valid is p16INK4A as surrogate marker? *Cancer Lett* 2012; **323**: 88-96 [PMID: 22484467 DOI: 10.1016/j.canlet.2012.03.033]
- 229 **Heath S**, Willis V, Allan K, Purdie K, Harwood C, Shields P, Simcock R, Williams T, Gilbert DC. Clinically significant human papilloma virus in squamous cell carcinoma of the head and neck in UK practice. *Clin Oncol (R Coll Radiol)* 2012; **24**: e18-e23 [PMID: 21752613 DOI: 10.1016/j.clon.2011.05.007]
- 230 **Hong A**, Jones D, Chatfield M, Lee CS, Zhang M, Clark J, Elliott M, Harnett G, Milross C, Rose B. HPV status of oropharyngeal cancer by combination HPV DNA/p16 testing: biological relevance of discordant results. *Ann Surg Oncol* 2013; **20** Suppl 3: S450-S458 [PMID: 23208131 DOI: 10.1245/s10434-012-2778-4]
- 231 **Bishop JA**, Ma XJ, Wang H, Luo Y, Illei PB, Begum S, Taube JM, Koch WM, Westra WH. Detection of transcriptionally active high-risk HPV in patients with head and neck squamous cell carcinoma as visualized by a novel E6/E7 mRNA in situ hybridization method. *Am J Surg Pathol* 2012; **36**: 1874-1882 [PMID: 23060353 DOI: 10.1097/PAS.0b013e318265fb2b]
- 232 **Gao G**, Chernock RD, Gay HA, Thorstad WL, Zhang TR, Wang H, Ma XJ, Luo Y, Lewis JS, Wang X. A novel RT-PCR method for quantification of human papillomavirus transcripts in archived tissues and its application in oropharyngeal cancer prognosis. *Int J Cancer* 2013; **132**: 882-890 [PMID: 22821242 DOI: 10.1002/ijc.27739]
- 233 **Schache AG**, Liloglou T, Risk JM, Jones TM, Ma XJ, Wang H, Bui S, Luo Y, Sloan P, Shaw RJ, Robinson M. Validation of a novel diagnostic standard in HPV-positive oropharyngeal squamous cell carcinoma. *Br J Cancer* 2013; **108**: 1332-1339 [PMID: 23412100 DOI: 10.1038/bjc.2013.63]
- 234 **Westra WH**. Detection of human papillomavirus in clinical samples. *Otolaryngol Clin North Am* 2012; **45**: 765-777 [PMID: 22793851 DOI: 10.1016/j.otc.2012.04.001]
- 235 **Rampias T**, Pectasides E, Prasad M, Sasaki C, Gouveris P, Dimou A, Kountourakis P, Perisanidis C, Burtneß B,



- Zaramboukas T, Rimm D, Fountzilias G, Psyrri A. Molecular profile of head and neck squamous cell carcinomas bearing p16 high phenotype. *Ann Oncol* 2013; **24**: 2124-2131 [PMID: 23406730 DOI: 10.1093/annonc/mdt013]
- 236 **Lothaire P**, de Azambuja E, Dequanter D, Lalami Y, Sotiriou C, Andry G, Castro G, Awada A. Molecular markers of head and neck squamous cell carcinoma: promising signs in need of prospective evaluation. *Head Neck* 2006; **28**: 256-269 [PMID: 16284973 DOI: 10.1002/hed.20326]
- 237 **Chen YJ**, Lee LY, Chao YK, Chang JT, Lu YC, Li HF, Chiu CC, Li YC, Li YL, Chiou JF, Cheng AJ. DSG3 facilitates cancer cell growth and invasion through the DSG3-plakoglobin-TCF/LEF-Myc/cyclin D1/MMP signaling pathway. *PLoS One* 2013; **8**: e64088 [PMID: 23737966 DOI: 10.1371/journal.pone.0064088]
- 238 **Chen YJ**, Chang JT, Lee L, Wang HM, Liao CT, Chiu CC, Chen PJ, Cheng AJ. DSG3 is overexpressed in head neck cancer and is a potential molecular target for inhibition of oncogenesis. *Oncogene* 2007; **26**: 467-476 [PMID: 16878157 DOI: 10.1038/sj.onc.1209802]
- 239 **Langer CJ**. Exploring biomarkers in head and neck cancer. *Cancer* 2012; **118**: 3882-3892 [PMID: 22281752 DOI: 10.1002/cncr.26718]
- 240 **Poeta ML**, Manola J, Goldwasser MA, Forastiere A, Benoit N, Califano JA, Ridge JA, Goodwin J, Kenady D, Saunders J, Westra W, Sidransky D, Koch WM. TP53 mutations and survival in squamous-cell carcinoma of the head and neck. *N Engl J Med* 2007; **357**: 2552-2561 [PMID: 18094376 DOI: 10.1056/NEJMoa073770]
- 241 **Jedlinski A**, Ansell A, Johansson AC, Roberg K. EGFR status and EGFR ligand expression influence the treatment response of head and neck cancer cell lines. *J Oral Pathol Med* 2013; **42**: 26-36 [PMID: 22643066 DOI: 10.1111/j.1600-0714.2012.01177.x]
- 242 **Johansson AC**, Ansell A, Jerhammar F, Lindh MB, Grénman R, Munck-Wikland E, Östman A, Roberg K. Cancer-associated fibroblasts induce matrix metalloproteinase-mediated cetuximab resistance in head and neck squamous cell carcinoma cells. *Mol Cancer Res* 2012; **10**: 1158-1168 [PMID: 22809838 DOI: 10.1158/1541-7786.MCR-12-0030]
- 243 **Ansell A**, Jerhammar F, Ceder R, Grafström R, Grénman R, Roberg K. Matrix metalloproteinase-7 and -13 expression associate to cisplatin resistance in head and neck cancer cell lines. *Oral Oncol* 2009; **45**: 866-871 [PMID: 19442568 DOI: 10.1016/j.oraloncology.2009.02.008]
- 244 **Farnebo L**, Tiefenböck K, Ansell A, Thunell LK, Garvin S, Roberg K. Strong expression of survivin is associated with positive response to radiotherapy and improved overall survival in head and neck squamous cell carcinoma patients. *Int J Cancer* 2013; **133**: 1994-2003 [PMID: 23564498 DOI: 10.1002/ijc.28200]
- 245 **Temam S**, Kawaguchi H, El-Naggar AK, Jelinek J, Tang H, Liu DD, Lang W, Issa JP, Lee JJ, Mao L. Epidermal growth factor receptor copy number alterations correlate with poor clinical outcome in patients with head and neck squamous cancer. *J Clin Oncol* 2007; **25**: 2164-2170 [PMID: 17538160 DOI: 10.1200/JCO.2006.06.6605]
- 246 **Hama T**, Yuza Y, Saito Y, O-uchi J, Kondo S, Okabe M, Yamada H, Kato T, Moriyama H, Kurihara S, Urashima M. Prognostic significance of epidermal growth factor receptor phosphorylation and mutation in head and neck squamous cell carcinoma. *Oncologist* 2009; **14**: 900-908 [PMID: 19726454 DOI: 10.1634/theoncologist.2009-0058]
- 247 **Chung CH**, Ely K, McGavran L, Varella-Garcia M, Parker J, Parker N, Jarrett C, Carter J, Murphy BA, Netteville J, Burkey BB, Sinard R, Cmelak A, Levy S, Yarbrough WG, Slebos RJ, Hirsch FR. Increased epidermal growth factor receptor gene copy number is associated with poor prognosis in head and neck squamous cell carcinomas. *J Clin Oncol* 2006; **24**: 4170-4176 [PMID: 16943533 DOI: 10.1200/JCO.2006.07.2587]
- 248 **Hafkamp HC**, Manni JJ, Haesevoets A, Voogd AC, Schepers M, Bot FJ, Hopman AH, Ramaekers FC, Speel EJ. Marked differences in survival rate between smokers and non-smokers with HPV 16-associated tonsillar carcinomas. *Int J Cancer* 2008; **122**: 2656-2664 [PMID: 18360824 DOI: 10.1002/ijc.23458]
- 249 **Bonner JA**, Harari PM, Giralt J, Azarnia N, Shin DM, Cohen RB, Jones CU, Sur R, Raben D, Jassem J, Ove R, Kies MS, Baselga J, Youssoufian H, Amellal N, Rowinsky EK, Ang KK. Radiotherapy plus cetuximab for squamous-cell carcinoma of the head and neck. *N Engl J Med* 2006; **354**: 567-578 [PMID: 16467544 DOI: 10.1056/NEJMoa053422]
- 250 **Lassen P**, Overgaard J, Eriksen JG. Expression of EGFR and HPV-associated p16 in oropharyngeal carcinoma: correlation and influence on prognosis after radiotherapy in the randomized DAHANCA 5 and 7 trials. *Radiother Oncol* 2013; **108**: 489-494 [PMID: 24060179 DOI: 10.1016/j.radonc.2013.08.036]
- 251 **Bozec A**, Peyrade F, Milano G. Molecular targeted therapies in the management of head and neck squamous cell carcinoma: recent developments and perspectives. *Anticancer Agents Med Chem* 2013; **13**: 389-402 [PMID: 23092267]
- 252 **Ukpo OC**, Thorstad WL, Lewis JS. B7-H1 expression model for immune evasion in human papillomavirus-related oropharyngeal squamous cell carcinoma. *Head Neck Pathol* 2013; **7**: 113-121 [PMID: 23179191 DOI: 10.1007/s12105-012-0406-z]
- 253 **Lyford-Pike S**, Peng S, Young GD, Taube JM, Westra WH, Akpeng B, Bruno TC, Richmon JD, Wang H, Bishop JA, Chen L, Drake CG, Topalian SL, Pardoll DM, Pai SI. Evidence for a role of the PD-1: PD-L1 pathway in immune resistance of HPV-associated head and neck squamous cell carcinoma. *Cancer Res* 2013; **73**: 1733-1741 [PMID: 23288508 DOI: 10.1158/0008-5472.CAN-12-2384]
- 254 **Kaskas NM**, Moore-Medlin T, McClure GB, Ekshyyan O, Vanchiere JA, Nathan CA. Serum biomarkers in head and neck squamous cell cancer. *JAMA Otolaryngol Head Neck Surg* 2014; **140**: 5-11 [PMID: 24232368 DOI: 10.1001/jamaoto.2013.5688]
- 255 **Badoual C**, Hans S, Merillon N, Van Ryswick C, Ravel P, Benhamouda N, Levionnois E, Nizard M, Si-Mohamed A, Besnier N, Gey A, Rotem-Yehudar R, Pere H, Tran T, Guerin CL, Chauvat A, Dransart E, Alanio C, Albert S, Barry B, Sandoval F, Quintin-Colonna F, Bruneval P, Fridman WH, Lemoine FM, Oudard S, Johannes L, Olive D, Brasnu D, Tartour E. PD-1-expressing tumor-infiltrating T cells are a favorable prognostic biomarker in HPV-associated head and neck cancer. *Cancer Res* 2013; **73**: 128-138 [PMID: 23135914 DOI: 10.1158/0008-5472.CAN-12-2606]
- 256 **Lucs AV**, Saltman B, Chung CH, Steinberg BM, Schwartz DL. Opportunities and challenges facing biomarker development for personalized head and neck cancer treatment. *Head Neck* 2013; **35**: 294-306 [PMID: 22287320 DOI: 10.1002/hed.21975]
- 257 **Nagadia R**, Pandit P, Coman WB, Cooper-White J, Punyadeera C. miRNAs in head and neck cancer revisited. *Cell Oncol (Dordr)* 2013; **36**: 1-7 [PMID: 23338821 DOI: 10.1007/s13402-012-0122-4]
- 258 **Song X**, Sturgis EM, Huang Z, Li X, Li C, Wei Q, Li G. Potentially functional variants of p14ARF are associated with HPV-positive oropharyngeal cancer patients and survival after definitive chemoradiotherapy. *Carcinogenesis* 2014; **35**: 62-68 [PMID: 24104554 DOI: 10.1093/carcin/bgt336]
- 259 **Wu Y**, Posner MR, Schumaker LM, Nikitakis N, Goloubeva O, Tan M, Lu C, Iqbal S, Lorch J, Sarlis NJ, Haddad RI, Cullen KJ. Novel biomarker panel predicts prognosis in human papillomavirus-negative oropharyngeal cancer: an analysis of the TAX 324 trial. *Cancer* 2012; **118**: 1811-1817 [PMID: 22009819 DOI: 10.1002/cncr.26485]
- 260 **Chiose SI**, Grandis JR, Lui VW, Diergaarde B, Maxwell JH, Ferris RL, Kim SW, Luvison A, Miller M, Nikiforova MN.



- PIK3CA, HRAS and PTEN in human papillomavirus positive oropharyngeal squamous cell carcinoma. *BMC Cancer* 2013; **13**: 602 [PMID: 24341335 DOI: 10.1186/1471-2407-13-602]
- 261 **Melkane AE**, Auperin A, Saulnier P, Lacroix L, Vielh P, Casiraghi O, Msakni I, Drusch F, Temam S. Human papillomavirus prevalence and prognostic implication in oropharyngeal squamous cell carcinomas. *Head Neck* 2014; **36**: 257-265 [PMID: 23728782 DOI: 10.1002/hed.23302]
- 262 **Prince A**, Aguirre-Ghizo J, Genden E, Posner M, Sikora A. Head and neck squamous cell carcinoma: new translational therapies. *Mt Sinai J Med* 2010; **77**: 684-699 [PMID: 21105129 DOI: 10.1002/msj.20216]
- 263 **Ang KK**, Sturgis EM. Human papillomavirus as a marker of the natural history and response to therapy of head and neck squamous cell carcinoma. *Semin Radiat Oncol* 2012; **22**: 128-142 [PMID: 22385920 DOI: 10.1016/j.semradonc.2011.12.004]
- 264 **Krane JF**. Role of cytology in the diagnosis and management of HPV-associated head and neck carcinoma. *Acta Cytol* 2013; **57**: 117-126 [PMID: 23406782 DOI: 10.1159/000346715]
- 265 **Mroz EA**, Forastiere AA, Rocco JW. Implications of the oropharyngeal cancer epidemic. *J Clin Oncol* 2011; **29**: 4222-4223 [PMID: 21969506 DOI: 10.1200/JCO.2011.37.8893]
- 266 **Joo YH**, Jung CK, Sun DI, Park JO, Cho KJ, Kim MS. High-risk human papillomavirus and cervical lymph node metastasis in patients with oropharyngeal cancer. *Head Neck* 2012; **34**: 10-14 [PMID: 21438064 DOI: 10.1002/hed.21697]
- 267 **McHugh JB**. Association of cystic neck metastases and human papillomavirus-positive oropharyngeal squamous cell carcinoma. *Arch Pathol Lab Med* 2009; **133**: 1798-1803 [PMID: 19886714 DOI: 10.1043/1543-2165-133.11.1798]
- 268 **Thompson LD**, Heffner DK. The clinical importance of cystic squamous cell carcinomas in the neck: a study of 136 cases. *Cancer* 1998; **82**: 944-956 [PMID: 9486586]
- 269 **Psyrris A**, Sasaki C, Vassilakopoulou M, Dimitriadis G, Rampias T. Future directions in research, treatment and prevention of HPV-related squamous cell carcinoma of the head and neck. *Head Neck Pathol* 2012; **6** Suppl 1: S121-S128 [PMID: 22782231 DOI: 10.1007/s12105-012-0362-7]
- 270 **Marur S**, Forastiere AA. Head and neck cancer: changing epidemiology, diagnosis, and treatment. *Mayo Clin Proc* 2008; **83**: 489-501 [PMID: 18380996 DOI: 10.4065/83.4.489]
- 271 **Fischer CA**, Kampmann M, Zlobec I, Green E, Tornillo L, Lugli A, Wolfensberger M, Terracciano LM. p16 expression in oropharyngeal cancer: its impact on staging and prognosis compared with the conventional clinical staging parameters. *Ann Oncol* 2010; **21**: 1961-1966 [PMID: 20423915 DOI: 10.1093/annonc/mdq210]
- 272 **Gillison ML**. HPV and prognosis for patients with oropharynx cancer. *Eur J Cancer* 2009; **45** Suppl 1: 383-385 [PMID: 19775640 DOI: 10.1016/S0959-8049(09)70058-9]
- 273 **Shaw R**, Robinson M. The increasing clinical relevance of human papillomavirus type 16 (HPV-16) infection in oropharyngeal cancer. *Br J Oral Maxillofac Surg* 2011; **49**: 423-429 [PMID: 20727631 DOI: 10.1016/j.bjoms.2010.06.023]
- 274 **Ang KK**, Harris J, Wheeler R, Weber R, Rosenthal DI, Nguyen-Tân PF, Westra WH, Chung CH, Jordan RC, Lu C, Kim H, Axelrod R, Silverman CC, Redmond KP, Gillison ML. Human papillomavirus and survival of patients with oropharyngeal cancer. *N Engl J Med* 2010; **363**: 24-35 [PMID: 20530316 DOI: 10.1056/NEJMoa0912217]
- 275 **Posner MR**, Lorch JH, Goloubeva O, Tan M, Schumaker LM, Sarlis NJ, Haddad RI, Cullen KJ. Survival and human papillomavirus in oropharynx cancer in TAX 324: a subset analysis from an international phase III trial. *Ann Oncol* 2011; **22**: 1071-1077 [PMID: 21317223 DOI: 10.1093/annonc/mdr006]
- 276 **Lassen P**, Eriksen JG, Krogdahl A, Therkildsen MH, Uthøi BP, Overgaard M, Specht L, Andersen E, Johansen J, Andersen LJ, Grau C, Overgaard J. The influence of HPV-associated p16-expression on accelerated fractionated radiotherapy in head and neck cancer: evaluation of the randomised DA-HANCA 6& amp; 7 trial. *Radiother Oncol* 2011; **100**: 49-55 [PMID: 21429609 DOI: 10.1016/j.radonc.2011.02.010]
- 277 **Klozar J**, Tachezy R. What are the implications of human papillomavirus status in oropharyngeal tumors for clinical practice? *Curr Opin Otolaryngol Head Neck Surg* 2014; **22**: 90-94 [PMID: 24492854 DOI: 10.1097/MOO.000000000000030]
- 278 **Vu HL**, Sikora AG, Fu S, Kao J. HPV-induced oropharyngeal cancer, immune response and response to therapy. *Cancer Lett* 2010; **288**: 149-155 [PMID: 19628331 DOI: 10.1016/j.canlet.2009.06.026]
- 279 **Kimple RJ**, Smith MA, Blitzer GC, Torres AD, Martin JA, Yang RZ, Peet CR, Lorenz LD, Nickel KP, Klingelutz AJ, Lambert PF, Harari PM. Enhanced radiation sensitivity in HPV-positive head and neck cancer. *Cancer Res* 2013; **73**: 4791-4800 [PMID: 23749640 DOI: 10.1158/0008-5472.CAN-13-0587]
- 280 **Rieckmann T**, Tribius S, Grob TJ, Meyer F, Busch CJ, Petersen C, Dikomey E, Kriegs M. HNSCC cell lines positive for HPV and p16 possess higher cellular radiosensitivity due to an impaired DSB repair capacity. *Radiother Oncol* 2013; **107**: 242-246 [PMID: 23602369 DOI: 10.1016/j.radonc.2013.03.013]
- 281 **Bonner JA**, Harari PM, Giral J, Cohen RB, Jones CU, Sur RK, Raben D, Baselga J, Spencer SA, Zhu J, Youssoufian H, Rowinsky EK, Ang KK. Radiotherapy plus cetuximab for locoregionally advanced head and neck cancer: 5-year survival data from a phase 3 randomised trial, and relation between cetuximab-induced rash and survival. *Lancet Oncol* 2010; **11**: 21-28 [PMID: 19897418 DOI: 10.1016/S1470-2045(09)70311-0]
- 282 **Koutcher L**, Sherman E, Fury M, Wolden S, Zhang Z, Mo Q, Stewart L, Schupak K, Gelblum D, Wong R, Kraus D, Shah J, Zelefsky M, Pfister D, Lee N. Concurrent cisplatin and radiation versus cetuximab and radiation for locally advanced head-and-neck cancer. *Int J Radiat Oncol Biol Phys* 2011; **81**: 915-922 [PMID: 20947269 DOI: 10.1016/j.ijrobp.2010.07.008]
- 283 **Genden EM**. The role for surgical management of HPV-related oropharyngeal carcinoma. *Head Neck Pathol* 2012; **6** Suppl 1: S98-103 [PMID: 22782229 DOI: 10.1007/s12105-012-0362-7]
- 284 **Lui VW**, Grandis JR. Primary chemotherapy and radiation as a treatment strategy for HPV-positive oropharyngeal cancer. *Head Neck Pathol* 2012; **6** Suppl 1: S91-S97 [PMID: 22782228 DOI: 10.1007/s12105-012-0364-5]
- 285 **Mehanna H**, Olaleye O, Licitra L. Oropharyngeal cancer is it time to change management according to human papilloma virus status? *Curr Opin Otolaryngol Head Neck Surg* 2012; **20**: 120-124 [PMID: 22327790 DOI: 10.1097/MOO.0b013e3283509735]
- 286 **Garland SM**, Smith JS. Human papillomavirus vaccines: current status and future prospects. *Drugs* 2010; **70**: 1079-1098 [PMID: 20518577 DOI: 10.2165/1089580-000000000-00000]
- 287 **Lu B**, Kumar A, Castellsagué X, Giuliano AR. Efficacy and safety of prophylactic vaccines against cervical HPV infection and diseases among women: a systematic review & meta-analysis. *BMC Infect Dis* 2011; **11**: 13 [PMID: 21226933 DOI: 10.1186/1471-2334-11-13]
- 288 **Bhat P**, Mattarollo SR, Gosmann C, Frazer IH, Leggatt GR. Regulation of immune responses to HPV infection and during HPV-directed immunotherapy. *Immunol Rev* 2011; **239**: 85-98 [PMID: 21198666 DOI: 10.1111/j.1600-065X.2010.00966.x]
- 289 **Safaeian M**, Kemp TJ, Pan DY, Porras C, Rodriguez AC, Schiffman M, Cortes B, Katki H, Wacholder S, Schiller JT, Gonzalez P, Penrose K, Lowy DR, Quint W, van Doorn LJ, Herrero R, Hildesheim A, Pinto LA. Cross-protective vaccine efficacy of the bivalent HPV vaccine against HPV31 is associated with humoral immune responses: results from the Costa Rica Vaccine Trial. *Hum Vaccin Immunother* 2013; **9**: 1399-1406 [PMID: 23571174 DOI: 10.4161/hv.24340]
- 290 **Maeda H**, Kubo K, Sugita Y, Miyamoto Y, Komatsu S, Takeuchi S, Umehayashi T, Morikawa S, Kawanishi K, Ka-

meiyama Y. DNA vaccine against hamster oral papilloma-virus-associated oral cancer. *J Int Med Res* 2005; **33**: 647-653 [PMID: 16372582]

- 291 **Herrero R**, Quint W, Hildesheim A, Gonzalez P, Struijk L, Katki HA, Porras C, Schiffman M, Rodriguez AC, Solomon D,

Jimenez S, Schiller JT, Lowy DR, van Doorn LJ, Wacholder S, Kreimer AR. Reduced prevalence of oral human papilloma-virus (HPV) 4 years after bivalent HPV vaccination in a randomized clinical trial in Costa Rica. *PLoS One* 2013; **8**: e68329 [PMID: 23873171 DOI: 10.1371/journal.pone.0068329]

**P- Reviewers:** Chen GS, Mandic R, Tian YP, Yeudall WA  
**S- Editor:** Wen LL **L- Editor:** A **E- Editor:** Wu HL



## Therapeutic strategies for targeting the ovarian tumor stroma

Song Yi Ko, Honami Naora

Song Yi Ko, Honami Naora, Department of Molecular and Cellular Oncology, University of Texas MD Anderson Cancer Center, Houston, TX 77030, United States

Author contributions: Ko SY and Naora H contributed equally to this work, generated the figure and wrote the manuscript.

Supported by Cancer and Prevention Research Institute of Texas grant, NO. RP120390 (HN); and United States National Institutes of Health grant, NO. CA141078 (HN)

Correspondence to: Honami Naora, PhD, Department of Molecular and Cellular Oncology, University of Texas MD Anderson Cancer Center, 1515 Holcombe Boulevard, Unit 108, Houston, TX 77030, United States. [hnaora@mdanderson.org](mailto:hnaora@mdanderson.org)

Telephone: +1-713-5634222 Fax: +1-713-7943270

Received: December 20, 2013 Revised: March 23, 2014

Accepted: May 13, 2014

Published online: June 16, 2014

### Abstract

Epithelial ovarian cancer is the most lethal type of gynecologic malignancy. Sixty percent of women who are diagnosed with ovarian cancer present with advanced-stage disease that involves the peritoneal cavity and these patients have a 5-year survival rate of less than 30%. For more than two decades, tumor-debulking surgery followed by platinum-taxane combination chemotherapy has remained the conventional first-line treatment of ovarian cancer. Although the initial response rate is 70%-80%, most patients with advanced-stage ovarian cancer eventually relapse and succumb to recurrent chemoresistant disease. A number of molecular aberrations that drive tumor progression have been identified in ovarian cancer cells and intensive efforts have focused on developing therapeutic agents that target these aberrations. However, increasing evidence indicates that reciprocal interactions between tumor cells and various types of stromal cells also play important roles in driving ovarian tumor progression and that these stromal cells represent attractive therapeutic targets. Unlike tumor cells, stromal cells within the tumor microenvironment are in general genetically

stable and are therefore less likely to become resistant to therapy. This concise review discusses the biological significance of the cross-talk between ovarian cancer cells and three major types of stromal cells (endothelial cells, fibroblasts, macrophages) and the development of new-generation therapies that target the ovarian tumor microenvironment.

© 2014 Baishideng Publishing Group Inc. All rights reserved.

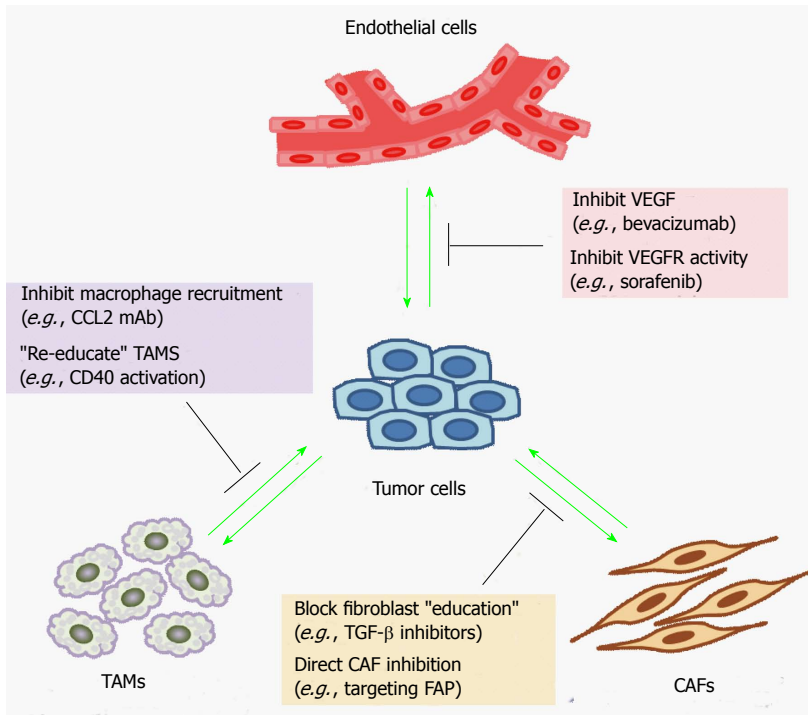
**Key words:** Ovarian cancer; Tumor stroma; Endothelial cells; Fibroblasts; Macrophages; Targeted therapy

**Core tip:** Despite advances in clinical management, advanced-stage ovarian cancer is still rarely cured by conventional chemotherapy. Substantial efforts have been directed to developing new therapies that target ovarian cancer cells. However, recent studies have revealed important roles of a variety of stromal cells in driving the aggressive behavior of ovarian cancer. Here, we discuss: (1) the significance of three major types of stromal cells in the progression of ovarian cancer; (2) how receptor/ligand-mediated interactions between ovarian cancer cells and stromal cells serve as focal points for therapeutic intervention; and (3) key examples of new-generation agents that target stromal cells.

Ko SY, Naora H. Therapeutic strategies for targeting the ovarian tumor stroma. *World J Clin Cases* 2014; 2(6): 194-200 Available from: URL: <http://www.wjgnet.com/2307-8960/full/v2/i6/194.htm> DOI: <http://dx.doi.org/10.12998/wjcc.v2.i6.194>

### INTRODUCTION

Epithelial ovarian cancer is the fifth leading cause of cancer death in women and the most lethal form of gynecologic malignancy<sup>[1]</sup>. The high morbidity and mortality caused by ovarian cancer primarily stems from late diagnosis. Sixty percent of women who are diagnosed with



**Figure 1** Therapeutic strategies to target the tumor microenvironment. Shown are examples of different strategies and agents that inhibit the regulation of a specific type of stromal cell or its functional properties. Several of these agents are in clinical use, whereas others are at different stages of clinical development. VEGF: Vascular endothelial growth factors; TAMs: Tumor-associated macrophages; CAFs: Cancer-associated fibroblasts; TGF- $\beta$ : Transforming growth factor- $\beta$ ; FAP: Fibroblast activation protein; CCL2: chemokine (C-C motif) ligand 2; VEGFR: Vascular endothelial growth factor receptor.

ovarian cancer present with extensive peritoneal carcinomatosis and these patients have a 5-year survival rate of less than 30%<sup>[1]</sup>. For more than 20 years, tumor-debulking surgery followed by platinum-taxane combination chemotherapy has remained the standard first-line treatment<sup>[2]</sup>. Although the initial response rate is 70%-80%, most patients with advanced-stage ovarian cancer relapse within 18 mo and eventually die from the disease<sup>[2]</sup>. Substantial efforts have been directed to developing new-generation agents that target functionally relevant molecular aberrations in ovarian cancer cells<sup>[5]</sup>. Inhibitors of poly (ADP-ribose) polymerase, a DNA repair enzyme, have been undergoing clinical trials in patients with BRCA-deficient ovarian cancer and have attracted considerable attention<sup>[4]</sup>. In addition to agents that target pathways in ovarian cancer cells, agents that target the tumor vasculature have been the focus of intensive clinical investigation<sup>[5,6]</sup>. Increasing evidence indicates that ovarian tumor progression is driven not only by dynamic interplay between tumor cells and endothelial cells but also by other types of stromal cells that are "educated" by tumors to acquire properties that are permissive for tumor growth. In this article, we provide an overview of the cross-talk between ovarian cancer cells, endothelial cells and two other key constituents of the tumor microenvironment, specifically, fibroblasts and macrophages, and discuss examples of clinically used and emerging experimental agents that target these stromal cells.

## ENDOTHELIAL CELLS

Of the cell types that comprise the ovarian tumor microenvironment, the endothelial cell has been the most extensively studied in terms of its clinical significance. A number of independent studies have identified that

increased tumor angiogenesis as manifested by high microvessel density is predictive of poor outcomes in ovarian cancer patients<sup>[7-9]</sup>. Angiogenesis is a dynamic process that involves the recruitment of endothelial progenitors, growth and maturation of endothelial cells and vessel formation, and is orchestrated by a repertoire of pro-angiogenic and anti-angiogenic factors<sup>[10,11]</sup>. Key pro-angiogenic factors include the vascular endothelial growth factors (VEGF), platelet-derived growth factor (PDGF), fibroblast growth factor-2 (FGF-2), angiopoietin, interleukin (IL)-6 and IL-8. Of these factors, VEGF-A has emerged as the predominant pro-angiogenic factor that is highly expressed in ovarian cancers<sup>[5,6]</sup>. VEGF-A has also been identified to be the causative factor of ascites formation by inducing vascular permeability<sup>[12]</sup>.

Intensive clinical efforts have focused on evaluating agents that inhibit VEGF signaling. These agents fall into two categories: (1) those that inhibit the ligand; and (2) those that inhibit tyrosine kinase activity of the VEGF receptors (VEGFR) (Figure 1). Of the former group, bevacizumab has been the most extensively evaluated agent in ovarian cancer. Bevacizumab is a humanized monoclonal antibody (mAb) that neutralizes all forms of VEGF and was originally Food and Drug Administration-approved in 2004 for treatment of metastatic colorectal cancer. Bevacizumab has been evaluated as a single agent in the treatment of patients with recurrent ovarian cancer in two pivotal phase II trials. In one of these studies (AVF 2949g), the response rate was 15.9% and median overall survival (OS) was 10.7 mo<sup>[13]</sup>. This study was terminated early due to a high rate of gastrointestinal perforations (5 of 44 patients, 11.4%). In the other study [Gynecologic Oncology Group (GOG) 170D], the response rate was 21.0%, median OS was 16.9 mo, and no bowel perforations were observed<sup>[14]</sup>. One possible explanation for



the differences in results of these trials is that the GOG study was limited to patients who had received no more than two prior lines of therapy, whereas 21 of the 44 patients in the AVF 2949g study (including the five patients who developed bowel perforations) had received three prior regimens. Bevacizumab has also been evaluated in combination with carboplatin and paclitaxel. In the first-line setting, two phase III trials (GOG 218 and ICON7) reported that progression-free survival (PFS) was increased (by 3.8 and 1.7 mo, respectively) with the combination of bevacizumab and standard chemotherapy followed by bevacizumab maintenance, as compared to standard chemotherapy alone<sup>[15,16]</sup>. In the recurrent setting, two other phase III studies have found that PFS was increased by approximately 3.6 mo when bevacizumab was combined with standard chemotherapy<sup>[17,18]</sup>. Another ligand-inhibitory agent is aflibercept, a fusion protein that acts as a soluble VEGFR decoy. In a phase II study of aflibercept in patients with recurrent ovarian cancer, the rate of gastrointestinal perforations was found to be low (1.4%) but the primary endpoint of a response rate of greater than 5% was not achieved<sup>[19]</sup>.

Tyrosine kinase inhibitors (TKIs) represent another important class of anti-angiogenic agents. Sorafenib is an oral multi-kinase inhibitor that targets several receptor tyrosine kinases including VEGFR-2, VEGFR-3, platelet-derived growth factor receptor- $\beta$  (PDGFR- $\beta$ ) and c-kit, and also the RAF family of serine/threonine kinases<sup>[20]</sup>. In a phase II trial of sorafenib monotherapy in patients with recurrent ovarian cancer, two of the 59 evaluable patients had partial responses whereas 20 had stable disease and 30 had progressive disease<sup>[21]</sup>. Another phase II study found that sorafenib did not improve efficacy of first-line carboplatin/paclitaxel treatment and resulted in additional toxicity<sup>[22]</sup>. Several TKIs that inhibit all three VEGFRs and both PDGFRs have been developed such as sunitinib, cediranib and pazopanib. Sunitinib has been found to have only modest activity as a single agent in patients with recurrent ovarian cancer<sup>[23,24]</sup>. Clinical trials are ongoing to evaluate cediranib<sup>[25]</sup> for treatment of recurrent ovarian cancer and pazopanib<sup>[26]</sup> as maintenance therapy for patients in remission following first-line platinum-taxane chemotherapy.

## CANCER-ASSOCIATED FIBROBLASTS

Cancer-associated fibroblasts (CAFs) constitute the cellular fibrotic component of the tumor stroma that is commonly described as “reactive” or desmoplastic stroma. CAFs are often distinguished from normal quiescent fibroblasts by their expression of markers of myofibroblasts and activated fibroblasts such as  $\alpha$ -smooth muscle actin ( $\alpha$ SMA) and fibroblast activation protein (FAP)<sup>[27,28]</sup>. CAFs derive from multiple cell types. Two important sources are mesenchymal stem cells (MSCs) and tissue-resident fibroblasts. MSCs are abundant in white adipose tissues such as the omentum<sup>[29]</sup>, the most commonly involved site in ovarian cancer. It has been demonstrated that ovarian cancer cell-derived factors,

such as transforming growth factor- $\beta$  (TGF- $\beta$ ) and lysophosphatidic acid, induce normal omental fibroblasts and adipose MSCs to acquire features of CAFs<sup>[30,31]</sup>. Studies of other types of tumors have shown that CAFs can also derive from bone marrow MSCs that are recruited to tumors<sup>[32,33]</sup>. There is evidence in breast cancer that some CAFs derive from tumor cells that have undergone epithelial-to-mesenchymal transition<sup>[34]</sup>. However, a study of ovarian cancer xenograft models found that stromal  $\alpha$ SMA<sup>+</sup> cells did not derive from tumor cells, suggesting that ovarian cancer cells are not a major source of CAFs<sup>[31]</sup>.

Substantial evidence indicates that CAFs contribute to poor survival of cancer patients by promoting tumor cell proliferation, angiogenesis and metastasis<sup>[27,28]</sup>. In a study of gene expression profiles of clinical specimens of ovarian cancer, Tothill *et al.*<sup>[35]</sup> identified that the subset of cases with the poorest outcomes was characterized by a desmoplastic gene signature. As compared to normal omental fibroblasts, CAFs more highly express IL-6, chemokine (C-X-C motif) ligand 12 (CXCL12) and VEGF-A, and are more effective in stimulating growth of ovarian cancer cells and endothelial cells<sup>[31]</sup>. The abundance of CAFs in ovarian cancers has been found to correlate with microvessel density<sup>[36]</sup>. CAFs also highly express TGF- $\beta$ , matrix metalloproteinases (MMPs) and numerous extracellular matrix proteins<sup>[27,28]</sup>, and stimulate invasiveness of ovarian cancer cells<sup>[36]</sup>. Furthermore, McLean and colleagues identified that propagating ovarian cancer cells with MSCs derived from ovarian cancer specimens increased the number of cancer stem cells<sup>[37]</sup>. These findings suggest that another mechanism by which CAFs drive tumorigenesis is by expanding the sub-population of tumor-initiating cells.

Given the profound negative impact of CAFs on outcomes, there have been intensive efforts to develop strategies to target this cell population (Figure 1). Several approaches to inhibit CAFs have been directed to targeting FAP. A humanized mAb to FAP has been found to be well-tolerated, but failed to show efficacy in a clinical trial of patients with metastatic colorectal cancer<sup>[38]</sup>. In a preclinical study, a DNA vaccine against FAP inhibited tumor growth and increased survival in a mouse colon cancer model<sup>[39]</sup>. A study by Brennen and colleagues exploited both the expression of FAP on CAFs and its proteolytic activity. These authors generated a prodrug that consisted of a FAP-specific peptide coupled to a thapsigargin analog as the cytotoxic moiety, and demonstrated that the compound induced stromal cell death and inhibited growth of breast and prostate tumor xenografts<sup>[40]</sup>. Another potential approach to inhibit CAFs is to prevent normal MSCs and fibroblasts from transitioning into CAFs by blocking TGF- $\beta$  signaling. A number of agents that inhibit TGF- $\beta$  signaling have been developed including TGF- $\beta$ -ligand traps, TGF- $\beta$  antisense oligonucleotides and small molecule inhibitors of the TGF- $\beta$  type I receptor kinase, and several of these agents have been evaluated in clinical trials<sup>[41,42]</sup>. The utility of TGF- $\beta$  inhibitors has been little-explored in ovarian cancer. In one

study, treatment of mice with the TGF- $\beta$  type I receptor inhibitor A83-01 reduced the fibrotic component of ovarian tumor xenografts but did not increase survival times<sup>[43]</sup>. Unlike TGF- $\beta$ , PDGF does not induce myofibroblastic differentiation but instead stimulates fibroblasts to produce mitogenic factors for tumor cells and pro-angiogenic factors. Blockade of PDGFR signaling in a mouse model of cervical cancer has been found to inhibit tumor growth and angiogenesis in part by inhibiting FGF-2 production by CAFs<sup>[44]</sup>. As discussed earlier, several TKIs that block VEGFR signaling also inhibit the PDGFRs. The impact of these TKIs on the desmoplastic stroma warrants further study as the PDGFRs are often highly expressed in CAFs.

## TUMOR-ASSOCIATED MACROPHAGES

Macrophages are normally present in the peritoneal cavity of healthy women and are abundant in ascites of ovarian cancer patients<sup>[45]</sup>. Tumor-associated macrophages (TAMs) are the major immune component of the tumor stroma<sup>[46,47]</sup>. Macrophages exhibit polarized phenotypes in response to different microenvironmental cues. Macrophages that are stimulated with microbial agents and interferon- $\gamma$  exhibit an immunostimulatory M1 phenotype. In contrast, TAMs exhibit an immunosuppressive M2 macrophage phenotype<sup>[46,47]</sup>. Polarization of macrophages towards an M2 phenotype is induced by stimulation with various cytokines such as IL-6, IL-10 and leukemia inhibitory factor (LIF) that are present at elevated levels in ascites of ovarian cancer patients<sup>[48,49]</sup>. Chemokine (C-C motif) ligand 2 (CCL2) and TGF- $\beta$ 2 are also expressed in ovarian cancer cells and in CAFs, and these ligands have been recently shown to induce normal peritoneal macrophages to acquire an M2 phenotype<sup>[50]</sup>. CCL2 is also a key chemotactic factor that is responsible for macrophage infiltration into tumors<sup>[47]</sup>.

TAMs are strongly associated with poor outcomes in cancer patients<sup>[46]</sup>. A principal mechanism by which TAMs promote tumor progression is by suppressing adaptive immunity. The M2 macrophage phenotype is characterized by high expression of immunosuppressive cytokines and chemokines such as CCL17, CCL18, CCL22, IL-10 and TGF- $\beta$ 1<sup>[47]</sup>. IL-10 and TGF- $\beta$ 1 inhibit T cell proliferation and dendritic cell maturation<sup>[47]</sup>. CCL18 induces naïve T cell anergy and has been identified to be the most abundant chemokine present in ovarian cancer patient ascites<sup>[51]</sup>. CCL17 and CCL22 promote recruitment of T regulatory cells (Treg) cells<sup>[52,53]</sup>. Treg cells suppress activity of effector T cells and have been found to promote ovarian tumor growth and to be predictive of poor survival in ovarian cancer patients<sup>[52]</sup>. In addition to expressing factors that suppress adaptive immunity, TAMs express MMPs, VEGF-A and other growth factors that stimulate metastasis and angiogenesis<sup>[46,47]</sup>. Depletion of peritoneal macrophages has been found to inhibit ascites and peritoneal spread of ovarian cancer in xenograft models<sup>[54]</sup>.

The recruitment of macrophages and their polariza-

tion towards a tumor-promoting M2 phenotype represent two candidate focal points for therapeutic intervention (Figure 1). Several approaches have been identified that “re-educate” TAMs towards a more tumoricidal M1 phenotype. Inhibition of the colony stimulating factor-1 receptor has been found to inhibit M2 macrophage polarization and to block glioma progression in animal models<sup>[55]</sup>. Inhibition of nuclear factor  $\kappa$ B signaling in TAMs also induced an M2-to-M1 switch, increased tumoricidal activity of macrophages and led to regression of ovarian tumor xenografts<sup>[56]</sup>. Activation of CD40, a member of the tumor necrosis factor receptor superfamily, induced tumoricidal activity of macrophages in mouse models of pancreatic adenocarcinoma<sup>[57]</sup>. The combination of agonistic CD40 mAb and gemcitabine chemotherapy has been found to be well-tolerated and to have anti-tumor activity in a phase I study of patients with advanced pancreatic adenocarcinoma<sup>[58]</sup>. Zoledronic acid is clinically used to prevent bone fractures and also impairs M2 polarization of macrophages<sup>[59]</sup>. CCL2 is an attractive target because of its ability to stimulate monocyte chemotaxis as well as M2 polarization. Neutralization of CCL2 induced regression of prostate cancer xenografts<sup>[60]</sup>. A mAb to CCL2 has recently undergone clinical evaluation<sup>[61]</sup>. Bindarit, an anti-inflammatory compound that inhibits CCL2 synthesis, has been found to inhibit growth of breast and prostate tumor xenografts<sup>[62]</sup>. Trabectedin is an alkaloid that binds the minor groove of DNA and disrupts the cell cycle<sup>[63]</sup>. In a phase III study of patients with recurrent ovarian cancer, the combination of Trabectedin and pegylated liposomal doxorubicin (PLD) was found to increase PFS by 1.5 mo as compared to PLD alone<sup>[64]</sup>. Trabectedin also inhibits production of CCL2 and IL-6 and inhibits the differentiation of monocytes into macrophages<sup>[65]</sup>. Germano *et al*<sup>[66]</sup> recently demonstrated the selective toxicity of Trabectedin for macrophages in xenograft models of ovarian cancer and several other solid tumors. In another recent study, Cieslewicz *et al*<sup>[67]</sup> identified a peptide (M2pep) that selectively binds to M2 macrophages. Administration of a fusion peptide comprising M2pep and a proapoptotic moiety improved survival rates of xenograft-bearing mice<sup>[67]</sup>, raising the possibility that the M2pep peptide could be used as a vehicle for delivering cytotoxic agents to TAMs.

## CONCLUSION

Over the past decade, a wealth of insight has been gained into the biology of ovarian cancer, the fertile nature of the peritoneal cavity for carcinomatosis, and the complex networks of receptor/ligand-mediated interactions between tumor cells and stromal cells. Several of the key receptors and ligands serve as molecular targets against which new-generation therapeutic agents have been developed and evaluated. Although several studies have yielded promising results, the efficacy of most stromal-targeting drugs as single agents seems limited. Several challenges remain such as identifying the most effective combinations of these drugs with conventional chemo-

therapy or with other targeted therapies, minimizing toxicity, and determining the appropriate clinical setting for their use.

## ACKNOWLEDGMENTS

The authors apologize for the inability to cite all contributing primary literature due to space constraints.

## REFERENCES

- 1 Siegel R, Naishadham D, Jemal A. Cancer statistics, 2013. *CA Cancer J Clin* 2013; **63**: 11-30 [PMID: 23335087 DOI: 10.3322/caac.21166]
- 2 Agarwal R, Kaye SB. Ovarian cancer: strategies for overcoming resistance to chemotherapy. *Nat Rev Cancer* 2003; **3**: 502-516 [PMID: 12835670 DOI: 10.1038/nrc1123]
- 3 Yap TA, Carden CP, Kaye SB. Beyond chemotherapy: targeted therapies in ovarian cancer. *Nat Rev Cancer* 2009; **9**: 167-181 [PMID: 19238149 DOI: 10.1038/nrc2583]
- 4 Garber K. PARP inhibitors bounce back. *Nat Rev Drug Discov* 2013; **12**: 725-727 [PMID: 24080684 DOI: 10.1038/nrd4147]
- 5 Spannuth WA, Sood AK, Coleman RL. Angiogenesis as a strategic target for ovarian cancer therapy. *Nat Clin Pract Oncol* 2008; **5**: 194-204 [PMID: 18268546 DOI: 10.1038/ncponc1051]
- 6 Burger RA. Overview of anti-angiogenic agents in development for ovarian cancer. *Gynecol Oncol* 2011; **121**: 230-238 [PMID: 21215996 DOI: 10.1016/j.ygyno.2010.11.035]
- 7 Hollingsworth HC, Kohn EC, Steinberg SM, Rothenberg ML, Merino MJ. Tumor angiogenesis in advanced stage ovarian carcinoma. *Am J Pathol* 1995; **147**: 33-41 [PMID: 7541612]
- 8 Alvarez AA, Krigman HR, Whitaker RS, Dodge RK, Rodriguez GC. The prognostic significance of angiogenesis in epithelial ovarian carcinoma. *Clin Cancer Res* 1999; **5**: 587-591 [PMID: 10100710]
- 9 Stone PJ, Goodheart MJ, Rose SL, Smith BJ, DeYoung BR, Buller RE. The influence of microvessel density on ovarian carcinogenesis. *Gynecol Oncol* 2003; **90**: 566-571 [PMID: 13678725]
- 10 Ferrara N. VEGF and the quest for tumour angiogenesis factors. *Nat Rev Cancer* 2002; **2**: 795-803 [PMID: 12360282 DOI: 10.1038/nrc909]
- 11 Hicklin DJ, Ellis LM. Role of the vascular endothelial growth factor pathway in tumor growth and angiogenesis. *J Clin Oncol* 2005; **23**: 1011-1027 [PMID: 15585754 DOI: 10.1200/JCO.2005.06.081]
- 12 Byrne AT, Ross L, Holash J, Nakanishi M, Hu L, Hofmann JI, Yancopoulos GD, Jaffe RB. Vascular endothelial growth factor-trap decreases tumor burden, inhibits ascites, and causes dramatic vascular remodeling in an ovarian cancer model. *Clin Cancer Res* 2003; **9**: 5721-5728 [PMID: 14654557]
- 13 Cannistra SA, Matulonis UA, Penson RT, Hambleton J, Dupont J, Mackey H, Douglas J, Burger RA, Armstrong D, Wenham R, McGuire W. Phase II study of bevacizumab in patients with platinum-resistant ovarian cancer or peritoneal serous cancer. *J Clin Oncol* 2007; **25**: 5180-5186 [PMID: 18024865 DOI: 10.1200/JCO.2007.12.0782]
- 14 Burger RA, Sill MW, Monk BJ, Greer BE, Sorosky JI. Phase II trial of bevacizumab in persistent or recurrent epithelial ovarian cancer or primary peritoneal cancer: a Gynecologic Oncology Group Study. *J Clin Oncol* 2007; **25**: 5165-5171 [PMID: 18024863 DOI: 10.1200/JCO.2007.11.5345]
- 15 Burger RA, Brady MF, Bookman MA, Fleming GF, Monk BJ, Huang H, Mannel RS, Homesley HD, Fowler J, Greer BE, Boente M, Birrer MJ, Liang SX. Incorporation of bevacizumab in the primary treatment of ovarian cancer. *N Engl J Med* 2011; **365**: 2473-2483 [PMID: 22204724 DOI: 10.1056/NEJMoa1104390]
- 16 Perren TJ, Swart AM, Pfisterer J, Ledermann JA, Pujade-Lauraine E, Kristensen G, Carey MS, Beale P, Cervantes A, Kurzeder C, du Bois A, Sehouli J, Kimmig R, Stähle A, Collinson F, Essapen S, Gourley C, Lortholary A, Selle F, Mirza MR, Leminen A, Plante M, Stark D, Qian W, Parmar MK, Oza AM. A phase 3 trial of bevacizumab in ovarian cancer. *N Engl J Med* 2011; **365**: 2484-2496 [PMID: 22204725 DOI: 10.1056/NEJMoa1103799]
- 17 Pujade-Lauraine E, Hilpert F, Weber B, Reuss A, Poveda A, Kristensen G, Sorio R, Vergote IB, Witteveen P, Bamias A, Pereira D, Wimberger P, Oaknin A, Mirza MR, Follana P, Bollag DT, Ray-Coquard I, AURELIA Investigators. AURELIA: A randomized phase III trial evaluating bevacizumab (BEV) plus chemotherapy (CT) for platinum (PT)-resistant recurrent ovarian cancer (OC). *J Clin Oncol* 2012; **30** (suppl; abstr: LBA5002)
- 18 Aghajanian C, Blank SV, Goff BA, Judson PL, Teneriello MG, Husain A, Sovak MA, Yi J, Nycum LR. OCEANS: a randomized, double-blind, placebo-controlled phase III trial of chemotherapy with or without bevacizumab in patients with platinum-sensitive recurrent epithelial ovarian, primary peritoneal, or fallopian tube cancer. *J Clin Oncol* 2012; **30**: 2039-2045 [PMID: 22529265 DOI: 10.1200/JCO.2012.42.0505]
- 19 Tew WP, Colombo N, Ray-Coquard I, Del Campo JM, Oza A, Pereira D, Mammoliti S, Matei D, Scambia G, Tonkin K, Shun Z, Sternas L, Spriggs DR. Intravenous aflibercept in patients with platinum-resistant, advanced ovarian cancer: results of a randomized, double-blind, phase 2, parallel-arm study. *Cancer* 2014; **120**: 335-343 [PMID: 24127346 DOI: 10.1002/cncr.28406]
- 20 Wilhelm SM, Carter C, Tang L, Wilkie D, McNabola A, Rong H, Chen C, Zhang X, Vincent P, McHugh M, Cao Y, Shujath J, Gawlak S, Eveleigh D, Rowley B, Liu L, Adnane L, Lynch M, Auclair D, Taylor I, Gedrich R, Voznesensky A, Riedl B, Post LE, Bollag G, Trail PA. BAY 43-9006 exhibits broad spectrum oral antitumor activity and targets the RAF/MEK/ERK pathway and receptor tyrosine kinases involved in tumor progression and angiogenesis. *Cancer Res* 2004; **64**: 7099-7109 [PMID: 15466206 DOI: 10.1158/0008-5472.CAN-04-1443]
- 21 Matei D, Sill MW, Lankes HA, DeGeest K, Bristow RE, Mutch D, Yamada SD, Cohn D, Calvert V, Farley J, Petricoin EF, Birrer MJ. Activity of sorafenib in recurrent ovarian cancer and primary peritoneal carcinomatosis: a gynecologic oncology group trial. *J Clin Oncol* 2011; **29**: 69-75 [PMID: 21098323 DOI: 10.1200/JCO.2009.26.7856]
- 22 Thompson DS, Dudley BS, Bismayer JA, Gian VG, Merritt WM, Whorf RC, Burris HA, Hainsworth JD. Paclitaxel/carboplatin with or without sorafenib in the first-line treatment of patients with stage III/IV epithelial ovarian cancer: A randomized phase II study of the Sarah Cannon Research Institute. *J Clin Oncol* 2013; **31**: 5513
- 23 Biagi JJ, Oza AM, Chachal HI, Grimshaw R, Ellard SL, Lee U, Hirte H, Sederias J, Ivy SP, Eisenhauer EA. A phase II study of sunitinib in patients with recurrent epithelial ovarian and primary peritoneal carcinoma: an NCIC Clinical Trials Group Study. *Ann Oncol* 2011; **22**: 335-340 [PMID: 20705911 DOI: 10.1093/annonc/mdq357]
- 24 Campos SM, Penson RT, Matulonis U, Horowitz NS, Whalen C, Pereira L, Tyburski K, Roche M, Szymonifka J, Berlin S. A phase II trial of Sunitinib malate in recurrent and refractory ovarian, fallopian tube and peritoneal carcinoma. *Gynecol Oncol* 2013; **128**: 215-220 [PMID: 22885865 DOI: 10.1016/j.ygyno.2012.07.126]
- 25 Ledermann JA, Perren TJ, Raja FA, Embleton A, Rustin GJS, Jayson G, Kaye SB, Swart AM, Vaughan M, Hirte H. Randomised double-blind phase III trial of cediranib (AZD 2171) in relapsed platinum sensitive ovarian cancer: Results of the



- ICON6 trial. *The European Cancer Congress 2013*; Abstract
- 26 **Du Bois A**, Floquet A, Kim JW, Rau J, Del Campo JM, Friedlander M, Pignata S, Fujiwara K, Vergote I, Colombo N, Mirza MR, Monk BJ, Wimberger P, Ray-Coquard I, Zang R, Diaz-Padilla I, Baumann KH, Kim JH, Harter P, on behalf of an Intergroup consortium. Randomized, double-blind, phase III trial of pazopanib versus placebo in women who have not progressed after first-line chemotherapy for advanced epithelial ovarian, fallopian tube, or primary peritoneal cancer (AEOC): Results of an international intergroup trial (AGO-OVAR16). *J Clin Oncol* 2013; **31**: LBA5503
  - 27 **Kalluri R**, Zeisberg M. Fibroblasts in cancer. *Nat Rev Cancer* 2006; **6**: 392-401 [PMID: 16572188 DOI: 10.1038/nrc1877]
  - 28 **Marsh T**, Pietras K, McAllister SS. Fibroblasts as architects of cancer pathogenesis. *Biochim Biophys Acta* 2013; **1832**: 1070-1078 [PMID: 23123598 DOI: 10.1016/j.bbdis.2012.10.013]
  - 29 **Zuk PA**, Zhu M, Ashjian P, De Ugarte DA, Huang JL, Mizuno H, Alfonso ZC, Fraser JK, Benhaim P, Hedrick MH. Human adipose tissue is a source of multipotent stem cells. *Mol Biol Cell* 2002; **13**: 4279-4295 [PMID: 12475952 DOI: 10.1091/mbc.E02-02-0105]
  - 30 **Jeon ES**, Moon HJ, Lee MJ, Song HY, Kim YM, Cho M, Suh DS, Yoon MS, Chang CL, Jung JS, Kim JH. Cancer-derived lysophosphatidic acid stimulates differentiation of human mesenchymal stem cells to myofibroblast-like cells. *Stem Cells* 2008; **26**: 789-797 [PMID: 18065393 DOI: 10.1634/stemcells.2007-0742]
  - 31 **Ko SY**, Barengo N, Ladanyi A, Lee JS, Marini F, Lengyel E, Naora H. HOXA9 promotes ovarian cancer growth by stimulating cancer-associated fibroblasts. *J Clin Invest* 2012; **122**: 3603-3617 [PMID: 22945634 DOI: 10.1172/JCI62229]
  - 32 **Direkze NC**, Hodivala-Dilke K, Jeffery R, Hunt T, Poulson R, Oukrif D, Alison MR, Wright NA. Bone marrow contribution to tumor-associated myofibroblasts and fibroblasts. *Cancer Res* 2004; **64**: 8492-8495 [PMID: 15574751 DOI: 10.1158/0008-5472.CAN-04-1708]
  - 33 **Quante M**, Tu SP, Tomita H, Gonda T, Wang SS, Takashi S, Baik GH, Shibata W, Diprete B, Betz KS, Friedman R, Varro A, Tycko B, Wang TC. Bone marrow-derived myofibroblasts contribute to the mesenchymal stem cell niche and promote tumor growth. *Cancer Cell* 2011; **19**: 257-272 [PMID: 21316604 DOI: 10.1016/j.ccr.2011.01.020]
  - 34 **Petersen OW**, Nielsen HL, Gudjonsson T, Villadsen R, Rank F, Niebuhr E, Bissell MJ, Rønnov-Jessen L. Epithelial to mesenchymal transition in human breast cancer can provide a nonmalignant stroma. *Am J Pathol* 2003; **162**: 391-402 [PMID: 12547698 DOI: 10.1016/S0002-9440(10)63834-5]
  - 35 **Tothill RW**, Tinker AV, George J, Brown R, Fox SB, Lade S, Johnson DS, Trivett MK, Etemadmoghadam D, Locandro B, Traficante N, Fereday S, Hung JA, Chiew YE, Haviv I, Australian Ovarian Cancer Study Group, Gertig D, DeFazio A, Bowtell DD. Novel molecular subtypes of serous and endometrioid ovarian cancer linked to clinical outcome. *Clin Cancer Res* 2008; **14**: 5198-5208 [PMID: 18698038 DOI: 10.1158/1078-0432.CCR-08-0196]
  - 36 **Zhang Y**, Tang H, Cai J, Zhang T, Guo J, Feng D, Wang Z. Ovarian cancer-associated fibroblasts contribute to epithelial ovarian carcinoma metastasis by promoting angiogenesis, lymphangiogenesis and tumor cell invasion. *Cancer Lett* 2011; **303**: 47-55 [PMID: 21310528 DOI: 10.1016/j.canlet.2011.01.011]
  - 37 **McLean K**, Gong Y, Choi Y, Deng N, Yang K, Bai S, Cabrera L, Keller E, McCauley L, Cho KR, Buckanovich RJ. Human ovarian carcinoma-associated mesenchymal stem cells regulate cancer stem cells and tumorigenesis via altered BMP production. *J Clin Invest* 2011; **121**: 3206-3219 [PMID: 21737876 DOI: 10.1172/JCI45273]
  - 38 **Hofheinz RD**, al-Batran SE, Hartmann F, Hartung G, Jäger D, Renner C, Tanswell P, Kunz U, Amelsberg A, Kuthan H, Stelhle G. Stromal antigen targeting by a humanised monoclonal antibody: an early phase II trial of sibroutuzumab in patients with metastatic colorectal cancer. *Onkologie* 2003; **26**: 44-48 [PMID: 12624517 DOI: 10.1159/000069863]
  - 39 **Wen Y**, Wang CT, Ma TT, Li ZY, Zhou LN, Mu B, Leng F, Shi HS, Li YO, Wei YQ. Immunotherapy targeting fibroblast activation protein inhibits tumor growth and increases survival in a murine colon cancer model. *Cancer Sci* 2010; **101**: 2325-2332 [PMID: 20804499 DOI: 10.1111/j.1349-7006.2010.01695.x]
  - 40 **Brennen WN**, Rosen DM, Wang H, Isaacs JT, Denmeade SR. Targeting carcinoma-associated fibroblasts within the tumor stroma with a fibroblast activation protein-activated pro-drug. *J Natl Cancer Inst* 2012; **104**: 1320-1334 [PMID: 22911669 DOI: 10.1093/jnci/djs336]
  - 41 **Bonafoux D**, Lee WC. Strategies for TGF-beta modulation: a review of recent patents. *Expert Opin Ther Pat* 2009; **19**: 1759-1769 [PMID: 19939191 DOI: 10.1517/13543770903397400]
  - 42 **Connolly EC**, Freimuth J, Akhurst RJ. Complexities of TGF- $\beta$  targeted cancer therapy. *Int J Biol Sci* 2012; **8**: 964-978 [PMID: 22811618 DOI: 10.7150/ijbs.4564]
  - 43 **Cai J**, Tang H, Xu L, Wang X, Yang C, Ruan S, Guo J, Hu S, Wang Z. Fibroblasts in omentum activated by tumor cells promote ovarian cancer growth, adhesion and invasiveness. *Carcinogenesis* 2012; **33**: 20-29 [PMID: 22021907 DOI: 10.1093/carcin/bgr230]
  - 44 **Pietras K**, Pahler J, Bergers G, Hanahan D. Functions of paracrine PDGF signaling in the proangiogenic tumor stroma revealed by pharmacological targeting. *PLoS Med* 2008; **5**: e19 [PMID: 18232728 DOI: 10.1371/journal.pmed.0050019]
  - 45 **Haskill S**, Becker S, Fowler W, Walton L. Mononuclear-cell infiltration in ovarian cancer. I. Inflammatory-cell infiltrates from tumour and ascites material. *Br J Cancer* 1982; **45**: 728-736 [PMID: 6979349]
  - 46 **Pollard JW**. Tumour-educated macrophages promote tumour progression and metastasis. *Nat Rev Cancer* 2004; **4**: 71-78 [PMID: 14708027 DOI: 10.1038/nrc1256]
  - 47 **Sica A**, Schioppa T, Mantovani A, Allavena P. Tumour-associated macrophages are a distinct M2 polarised population promoting tumour progression: potential targets of anti-cancer therapy. *Eur J Cancer* 2006; **42**: 717-727 [PMID: 16520032 DOI: 10.1016/j.ejca.2006.01.003]
  - 48 **Duluc D**, Delneste Y, Tan F, Moles MP, Grimaud L, Lenoir J, Preisser L, Anegón I, Catala L, Ifrah N, Descamps P, Gamezin E, Gascan H, Hebbbar M, Jeannin P. Tumor-associated leukemia inhibitory factor and IL-6 skew monocyte differentiation into tumor-associated macrophage-like cells. *Blood* 2007; **110**: 4319-4330 [PMID: 17848619 DOI: 10.1182/blood-2007-02-072587]
  - 49 **Matte I**, Lane D, Laplante C, Rancourt C, Piché A. Profiling of cytokines in human epithelial ovarian cancer ascites. *Am J Cancer Res* 2012; **2**: 566-580 [PMID: 22957308]
  - 50 **Ko SY**, Ladanyi A, Lengyel E, Naora H. Expression of the homeobox gene HOXA9 in ovarian cancer induces peritoneal macrophages to acquire an M2 tumor-promoting phenotype. *Am J Pathol* 2014; **184**: 271-281 [PMID: 24332016 DOI: 10.1016/j.ajpath.2013.09.017]
  - 51 **Schutysse E**, Struyf S, Proost P, Opdenakker G, Laureys G, Verhasselt B, Peperstraete L, Van de Putte I, Sacconi A, Allavena P, Mantovani A, Van Damme J. Identification of biologically active chemokine isoforms from ascitic fluid and elevated levels of CCL18/pulmonary and activation-regulated chemokine in ovarian carcinoma. *J Biol Chem* 2002; **277**: 24584-24593 [PMID: 11978786 DOI: 10.1074/jbc.M112275200]
  - 52 **Curiel TJ**, Coukos G, Zou L, Alvarez X, Cheng P, Mottram P, Evdemon-Hogan M, Conejo-Garcia JR, Zhang L, Burow M, Zhu Y, Wei S, Kryczek I, Daniel B, Gordon A, Myers L, Lackner A, Disis ML, Knutson KL, Chen L, Zou W. Specific recruitment of regulatory T cells in ovarian carcinoma fosters immune privilege and predicts reduced survival. *Nat Med*



- 2004; **10**: 942-949 [PMID: 15322536 DOI: 10.1038/nm1093]
- 53 **Mizukami Y**, Kono K, Kawaguchi Y, Akaike H, Kamimura K, Sugai H, Fujii H. CCL17 and CCL22 chemokines within tumor microenvironment are related to accumulation of Foxp3+ regulatory T cells in gastric cancer. *Int J Cancer* 2008; **122**: 2286-2293 [PMID: 18224687 DOI: 10.1002/ijc.23392]
  - 54 **Robinson-Smith TM**, Isaacsohn I, Mercer CA, Zhou M, Van Rooijen N, Hussein Zadeh N, McFarland-Mancini MM, Drew AF. Macrophages mediate inflammation-enhanced metastasis of ovarian tumors in mice. *Cancer Res* 2007; **67**: 5708-5716 [PMID: 17575137 DOI: 10.1158/0008-5472.CAN-06-4375]
  - 55 **Pyonteck SM**, Akkari L, Schuhmacher AJ, Bowman RL, Sevensenich L, Quail DF, Olson OC, Quick ML, Huse JT, Teijeiro V, Setty M, Leslie CS, Oei Y, Pedraza A, Zhang J, Brennan CW, Sutton JC, Holland EC, Daniel D, Joyce JA. CSF-1R inhibition alters macrophage polarization and blocks glioma progression. *Nat Med* 2013; **19**: 1264-1272 [PMID: 24056773 DOI: 10.1038/nm.3337]
  - 56 **Hagemann T**, Lawrence T, McNeish I, Charles KA, Kulbe H, Thompson RG, Robinson SC, Balkwill FR. "Re-educating" tumor-associated macrophages by targeting NF-kappaB. *J Exp Med* 2008; **205**: 1261-1268 [PMID: 18490490 DOI: 10.1084/jem.20080108]
  - 57 **Beatty GL**, Chiorean EG, Fishman MP, Saboury B, Teitelbaum UR, Sun W, Huhn RD, Song W, Li D, Sharp LL, Torigian DA, O'Dwyer PJ, Vonderheide RH. CD40 agonists alter tumor stroma and show efficacy against pancreatic carcinoma in mice and humans. *Science* 2011; **331**: 1612-1616 [PMID: 21436454 DOI: 10.1126/science.1198443]
  - 58 **Beatty GL**, Torigian DA, Chiorean EG, Saboury B, Brothers A, Alavi A, Troxel AB, Sun W, Teitelbaum UR, Vonderheide RH, O'Dwyer PJ. A phase I study of an agonist CD40 monoclonal antibody (CP-870,893) in combination with gemcitabine in patients with advanced pancreatic ductal adenocarcinoma. *Clin Cancer Res* 2013; **19**: 6286-6295 [PMID: 23983255 DOI: 10.1158/1078-0432.CCR-13-1320]
  - 59 **Tsagozis P**, Eriksson F, Pisa P. Zoledronic acid modulates antitumoral responses of prostate cancer-tumor associated macrophages. *Cancer Immunol Immunother* 2008; **57**: 1451-1459 [PMID: 18297280 DOI: 10.1007/s00262-008-0482-9]
  - 60 **Loberg RD**, Ying C, Craig M, Day LL, Sargent E, Neeley C, Wojno K, Snyder LA, Yan L, Pienta KJ. Targeting CCL2 with systemic delivery of neutralizing antibodies induces prostate cancer tumor regression in vivo. *Cancer Res* 2007; **67**: 9417-9424 [PMID: 17909051 DOI: 10.1158/0008-5472.CAN-07-1286]
  - 61 **Pienta KJ**, Machiels JP, Schrijvers D, Alekseev B, Shkolnik M, Crabb SJ, Li S, Seetharam S, Puchalski TA, Takimoto C, Elsayed Y, Dawkins F, de Bono JS. Phase 2 study of carlumab (CNTO 888), a human monoclonal antibody against CC-chemokine ligand 2 (CCL2), in metastatic castration-resistant prostate cancer. *Invest New Drugs* 2013; **31**: 760-768 [PMID: 22907596 DOI: 10.1007/s10637-012-9869-8]
  - 62 **Zollo M**, Di Dato V, Spano D, De Martino D, Liguori L, Marino N, Vastolo V, Navas L, Garrone B, Mangano G, Biondi G, Guglielmotti A. Targeting monocyte chemotactic protein-1 synthesis with bindarit induces tumor regression in prostate and breast cancer animal models. *Clin Exp Metastasis* 2012; **29**: 585-601 [PMID: 22484917 DOI: 10.1007/s10585-012-9473-5]
  - 63 **D'Incalci M**, Galmarini CM. A review of trabectedin (ET-743): a unique mechanism of action. *Mol Cancer Ther* 2010; **9**: 2157-2163 [PMID: 20647340 DOI: 10.1158/1535-7163.MCT-10-0263]
  - 64 **Monk BJ**, Herzog TJ, Kaye SB, Krasner CN, Vermorken JB, Muggia FM, Pujade-Lauraine E, Lisyanskaya AS, Makhson AN, Rolski J, Gorbounova VA, Ghatage P, Bidzinski M, Shen K, Ngan HY, Vergote IB, Nam JH, Park YC, Lebedinsky CA, Poveda AM. Trabectedin plus pegylated liposomal Doxorubicin in recurrent ovarian cancer. *J Clin Oncol* 2010; **28**: 3107-3114 [PMID: 20516432 DOI: 10.1200/JCO.2009.25.4037]
  - 65 **Allavena P**, Signorelli M, Chieppa M, Erba E, Bianchi G, Marchesi F, Olimpio CO, Bonardi C, Garbi A, Lissoni A, de Braud F, Jimeno J, D'Incalci M. Anti-inflammatory properties of the novel antitumor agent yondelis (trabectedin): inhibition of macrophage differentiation and cytokine production. *Cancer Res* 2005; **65**: 2964-2971 [PMID: 15805300 DOI: 10.1158/0008-5472.CAN-04-4037]
  - 66 **Germano G**, Frapolli R, Belgiovine C, Anselmo A, Pesce S, Liguori M, Erba E, Ubaldi S, Zucchetti M, Pasqualini F, Nebuloni M, van Rooijen N, Mortarini R, Beltrame L, Marchini S, Fuso Nerini I, Sanfilippo R, Casali PG, Pilotti S, Galmarini CM, Anichini A, Mantovani A, D'Incalci M, Allavena P. Role of macrophage targeting in the antitumor activity of trabectedin. *Cancer Cell* 2013; **23**: 249-262 [PMID: 23410977 DOI: 10.1016/j.ccr.2013.01.008]
  - 67 **Cieslewicz M**, Tang J, Yu JL, Cao H, Zavaljevski M, Motoyama K, Lieber A, Raines EW, Pun SH. Targeted delivery of proapoptotic peptides to tumor-associated macrophages improves survival. *Proc Natl Acad Sci U S A* 2013; **110**: 15919-15924 [PMID: 24046373 DOI: 10.1073/pnas.1312197110]

**P- Reviewers:** Cavallaro U, Sherbini MAHE **S- Editor:** Ji FF  
**L- Editor:** A **E- Editor:** Wu HL



## Concurrent stenoses: A common etiology of stroke in Asians

Bik Ling Man, Yat Pang Fu

Bik Ling Man, Yat Pang Fu, Division of Neurology, Department of Medicine and Geriatrics, Tuen Mun Hospital, Hong Kong, China

Author contributions: Man BL and Fu YP both contributed to this paper.

Correspondence to: Bik Ling Man, MD, Division of Neurology, Department of Medicine and Geriatrics, Tuen Mun Hospital, 23 Tsing Chung Koon Road, Hong Kong, China. [manbikling@gmail.com](mailto:manbikling@gmail.com)

Telephone: +852-856-24685111 Fax: +852-856-24569111

Received: October 30, 2013 Revised: February 24, 2014

Accepted: March 11, 2014

Published online: June 16, 2014

prognosis of these patients is poor and they are at high risk of further vascular events or death. The purpose of this review is to examine the epidemiology, risk factors, stroke mechanism and genetics of concurrent stenoses and to discuss strategies for treatment.

Man BL, Fu YP. Concurrent stenoses: A common etiology of stroke in Asians. *World J Clin Cases* 2014; 2(6): 201-205 Available from: URL: <http://www.wjgnet.com/2307-8960/full/v2/i6/201.htm> DOI: <http://dx.doi.org/10.12998/wjcc.v2.i6.201>

### Abstract

Atherosclerosis of cerebral vessels is a common cause of stroke. Racial differences in the distribution of cerebrovascular occlusive disease are well documented. Extracranial stenosis is more common in Caucasians, while intracranial stenosis is more common in Asians, Hispanics and African-Americans. Concurrent atherosclerosis of extracranial and intracranial vessels is common in Asians. The incidence of concurrent stenoses ranges from 10% to 48% in patients with symptomatic cerebrovascular disease. The long-term prognosis of these patients is poor and they are at high risk of further vascular events or death. The purpose of this review is to examine the epidemiology, risk factors, stroke mechanism and genetics of concurrent stenoses and to discuss strategies for treatment.

© 2014 Baishideng Publishing Group Inc. All rights reserved.

**Key words:** Atherosclerosis; Concurrent stenosis; Stroke; Asians

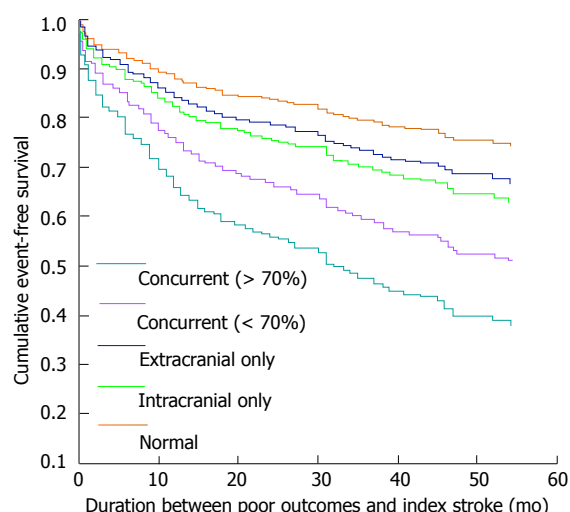
**Core tip:** Concurrent stenoses of extracranial and intracranial vessels are common in Asians, with an incidence that ranges from 10% to 48% in patients with symptomatic cerebrovascular disease. The long-term

### INTRODUCTION

Cerebrovascular occlusive disease due to atherosclerosis is a common cause of stroke worldwide. However, there are marked racial differences in the distribution of vascular stenosis. Extracranial stenosis is the most common large vessel cause in Caucasians, while intracranial stenosis is more prevalent in Asians, Hispanics and African-Americans<sup>[1-4]</sup>. Moreover, recent studies suggested that concurrent stenoses of extracranial and intracranial vessels are common in Asians. The purpose of this review is to examine the epidemiology, risk factors, stroke mechanism and genetics of concurrent stenoses and to discuss strategies for investigations and treatment.

### EPIDEMIOLOGY

The incidence of concurrent stenoses ranges from 10% to 48% in patients with symptomatic cerebrovascular disease<sup>[2,5-8]</sup>. Wong *et al*<sup>[9]</sup> found that 21% of stroke patients had concurrent stenoses in Hong Kong. Yang *et al*<sup>[10]</sup> report 33% of stroke patients had concurrent stenoses in China. Liu *et al*<sup>[8]</sup> found that 18% of stroke patients in Taiwan had significant concurrent stenoses. Lee *et al*<sup>[6]</sup> reported that 48% of patients with more than 30% extracranial carotid stenosis had concurrent intracranial stenoses in South Korea.



**Figure 1** Cumulative event-free survival in patients with different intracranial and extracranial lesions. Concurrent (< 70%): Concurrent lesions with < 70% extracranial stenosis; Concurrent (> 70%): Concurrent lesions with > 70% extracranial stenosis; Extracranial only: Extracranial stenosis only; Intracranial only: Intracranial stenosis only; Normal: Normal craniocervical vasculature.

## NATURAL HISTORY OF CONCURRENT STENOSES

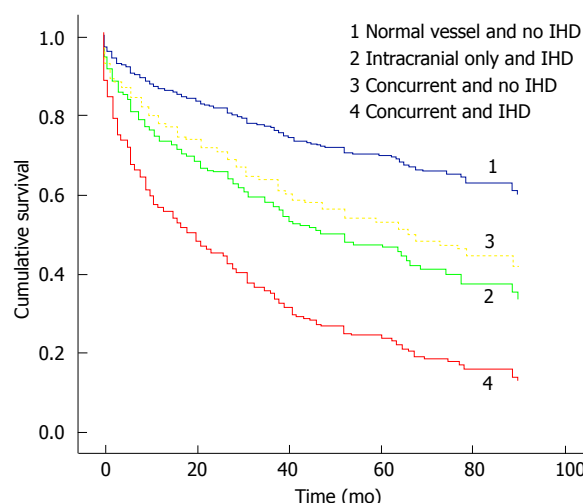
The long-term prognosis of ischemic stroke patients with concurrent atherosclerosis of intracranial and extracranial vessels is poor and they are at high risk of further vascular events or death. Our previous studies showed the 5-year cumulative rates of mortality, re-stroke and poor outcomes were 31%, 41% and 51%, respectively (Figure 1)<sup>[11]</sup>. Furthermore, ischemic stroke patients with concurrent stenoses and ischemic heart disease have an even worse prognosis. The 5-year cumulative rates of mortality, recurrent vascular events and combined poor outcomes were 40%, 50% and 83%, respectively (Figure 2)<sup>[12]</sup>. On the other hand, patients with concurrent stenoses and small vessel disease have poorer cognitive and functional outcomes<sup>[13]</sup>. This may be related to the burden of atherosclerosis and synergistic effect of multiple vascular lesions.

## RISK FACTORS ASSOCIATED WITH CONCURRENT STENOSES

Our previous studies showed that hypertension<sup>[14]</sup>, diabetes mellitus<sup>[15]</sup>, hyperlipidemia<sup>[15]</sup>, recurrent stroke and poor pre-stroke modified Rankin scale<sup>[16]</sup> are associated with concurrent stenoses.

## ETIOLOGIES

The major cause of concurrent stenoses is atherosclerosis of the cerebrovascular circulation which typically affects large or medium sized arteries. These vessels range from 200-850  $\mu\text{m}$  in diameter and are characterized by the accumulation of subintimal foam cells<sup>[16]</sup>. In the carotid



**Figure 2** Cumulative event-free survival of combined poor outcomes of different groups of patients. Normal vessel: Normal craniocervical vasculature; Intracranial only: Intracranial stenosis only; Concurrent: Concurrent stenoses.

artery, high risk plaques tend to be severely stenotic<sup>[17]</sup>. However, severe stenosis of the carotid artery is rare in Asian patients with concurrent stenosis<sup>[11]</sup>. Compared with extracranial vessels, the adventitia and the media of the intracranial arteries are thinner and their internal elastic lamina are fenestrated differently and thicker<sup>[18]</sup>. Luminal stenosis, lipid area, presence of neovasculature and inflammatory cells are all associated with ischemic stroke in the middle cerebral artery (MCA) territory<sup>[19]</sup>.

## STROKE MECHANISMS

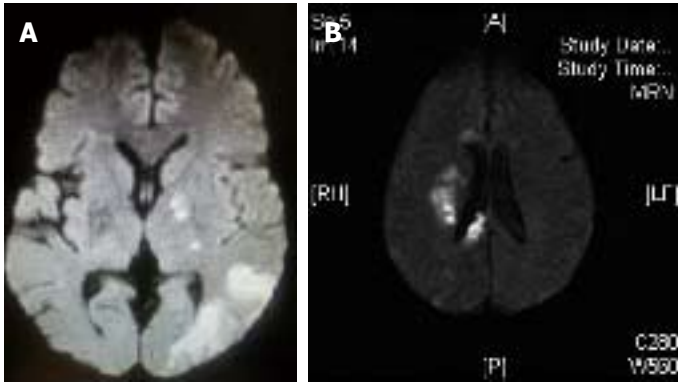
Patients with concurrent stenoses have more symptomatic stenoses, more concomitant perforating artery infarcts, pial infarcts, border zone infarcts and more multiple embolic infarcts in the territory of the leptomeningeal branches of MCA (Figure 3)<sup>[14]</sup>. The topographic patterns suggest that the combination of hemodynamic compromise attributable to concurrent stenoses and artery-to-artery embolization is a common stroke mechanism in these patients<sup>[14]</sup>.

## GENETICS

Genetic factors may play a role in the development of concurrent stenoses on top of the other well established vascular risk factors. Our study showed that genetic polymorphisms of the pathways affecting lipid metabolism and homocysteine are associated with concurrent stenosis<sup>[15]</sup>.

## TREATMENT OF CONCURRENT STENOSES

Patients with concurrent stenoses are at high risk of further vascular events or death. The optimal treatment for these groups of patients is still unknown. The American Heart Association/American Stroke Association recom-



**Figure 3** Magnetic resonance imaging diffusion-weighted images of different lesion patterns. A: Concomitant perforating artery infarct and pial infarcts; B: Border zone infarcts.

mend aspirin monotherapy, aspirin/extended-release dipyridamole combination and clopidogrel monotherapy as the acceptable options for all non-cardioembolic ischemic stroke patients<sup>[20]</sup>. A South Korean study<sup>[21]</sup> showed that the progression of intracranial stenosis was significantly less in patients taking cilostazol (a phosphodiesterase inhibitor).

However, medical treatment for patients with concurrent stenoses is often unsatisfactory<sup>[11,12]</sup> and surgical treatment may be indicated in these patients. Although severe carotid stenosis is rare in Asians, patients with severe carotid stenosis are recommended to have a carotid endarterectomy<sup>[17,22]</sup>. Carotid stenting is not recommended due to high perioperative risks and death associated with this procedure<sup>[23,24]</sup>.

The Carotid Occlusion Surgery Study trial, which investigated the relationship between cerebral hemodynamics and cognitive function in stroke patients undergoing treatment for unilateral carotid artery occlusion with extracranial-intracranial arterial bypass (EC-IC bypass), was stopped prematurely in 2011 because of slow recruitment and a very low incidence of ipsilateral symptomatic ischemic events in patients assigned to the medical arm<sup>[25]</sup>.

The increasing enthusiasm for intracranial stenting for significant intracranial stenosis was dampened by the significant periprocedural neurological complication rate, estimated at 5.3% to 28%<sup>[26-30]</sup>. The stenting *vs* aggressive medical management for prevention recurrent stroke in intracranial stenosis (SAMMPRIS) trial<sup>[31]</sup> has been halted due to the high perioperative risks of stroke and death in the treatment arm. However, the risks may be lower at centers with high volume and more experience in these stenting procedures. Jiang *et al*<sup>[32]</sup> reported on 100 consecutive patients from a single center with a 99% success rate of stent placement and 5% risk of 30 d perioperative stroke and death. Overall, the current evidence does not support the routine use of intracranial stenting in patients with intracranial stenosis.

## TRIALS IN PROGRESS

There are two ongoing randomized treatment trials using cilostazol in patients with intracranial stenosis. The first is the Trial of Cilostazol in Symptomatic Intracranial Arterial Stenosis II in Asia, which is a double-blind,

randomized trial comparing aspirin (75-150 mg per day) in combination with cilostazol (100 mg twice a day) with a combination of clopidogrel (75 mg per day) in patients with significant MCA or basilar artery stenosis<sup>[33]</sup>. The second is the open-label trial of Cilostazol-Aspirin Therapy Against Recurrent Stroke With Intracranial Artery Stenosis in Japan, comparing open-label aspirin and cilostazol with aspirin alone in patients with symptomatic 50%-99% stenosis of the supraclinoid internal carotid artery, MCA or basilar artery<sup>[34]</sup>. These trials may provide important information to optimize medical treatment in patients with intracranial stenosis.

Concerning the surgical treatment for intracranial stenosis, the Japanese EC-IC Bypass Trial (JET study) is in progress to determine the ability of STA-MCA bypass to prevent stroke caused specifically by intracranial stenosis, based on evaluations of hemodynamic ischemia<sup>[35,36]</sup>. The interim analyses of the JET study suggest that in patients with symptomatic intracranial stenosis and evidence of hemodynamic ischemia, surgical intervention with EC-IC bypass is superior to medical management in terms of stroke prevention. The final results of the trial are pending<sup>[36]</sup>.

The Early Stent-assisted Angioplasty in Symptomatic Intracranial Stenosis (ESASIS) trial<sup>[37]</sup> aims to study the benefit of stenting in reducing the risk of ipsilateral stroke, similar to the SAMMPRIS trial. The Data Safety Monitoring Board of the ESASIS study reviewed the 30 d safety data (combined stroke and death) of 77 randomized patients and found that the safety data of the stenting arm is reassuring when compared with that of the medical arm and is better than the high event rate of 14% being reported in the stenting arm of the SAMMPRIS study. The ESASIS trial is therefore recommended to continue recruitment but with close monitoring of safety.

## CONCLUSION

Concurrent intracranial and extracranial stenoses are common in Asians. The patients have a high risk of death and recurrent vascular events. The risk factors include hypertension, diabetes mellitus, hyperlipidemia, previous history of stroke and poor pre-stroke modified Rankin scale. The combination of hemodynamic compromise



attributable to concurrent stenoses and artery-to-artery embolization is a common stroke mechanism in these patients. Optimal treatment for patients with concurrent stenoses is still unknown and more studies are needed on possible interventions which can improve the prognosis of these patients.

## REFERENCES

- 1 **Caplan LR**, Gorelick PB, Hier DB. Race, sex and occlusive cerebrovascular disease: a review. *Stroke* 1986; **17**: 648-655 [PMID: 3526645 DOI: 10.1161/01.STR.17.4.648]
- 2 **Feldmann E**, Daneault N, Kwan E, Ho KJ, Pessin MS, Langenberg P, Caplan LR. Chinese-white differences in the distribution of occlusive cerebrovascular disease. *Neurology* 1990; **40**: 1541-1545 [PMID: 2215945]
- 3 **Wityk RJ**, Lehman D, Klag M, Coresh J, Ahn H, Litt B. Race and sex differences in the distribution of cerebral atherosclerosis. *Stroke* 1996; **27**: 1974-1980 [PMID: 8898801]
- 4 **Sacco RL**, Kargman DE, Zamanillo MC. Race-ethnic differences in stroke risk factors among hospitalized patients with cerebral infarction: the Northern Manhattan Stroke Study. *Neurology* 1995; **45**: 659-663 [PMID: 7723951 DOI: 10.1212/WNL.45.4.659]
- 5 **Wong KS**, Li H, Chan YL, Ahuja A, Lam WW, Wong A, Kay R. Use of transcranial Doppler ultrasound to predict outcome in patients with intracranial large-artery occlusive disease. *Stroke* 2000; **31**: 2641-2647 [PMID: 11062288]
- 6 **Lee SJ**, Cho SJ, Moon HS, Shon YM, Lee KH, Kim DI, Lee BB, Byun HS, Han SH, Chung CS. Combined extracranial and intracranial atherosclerosis in Korean patients. *Arch Neurol* 2003; **60**: 1561-1564 [PMID: 14623728]
- 7 **Suwanwela NC**, Chutinetr A. Risk factors for atherosclerosis of cervicocerebral arteries: intracranial versus extracranial. *Neuroepidemiology* 2003; **22**: 37-40 [PMID: 12566952]
- 8 **Liu HM**, Tu YK, Yip PK, Su CT. Evaluation of intracranial and extracranial carotid steno-occlusive diseases in Taiwan Chinese patients with MR angiography: preliminary experience. *Stroke* 1996; **27**: 650-653 [PMID: 8614924 DOI: 10.1161/01.STR.27.4.650]
- 9 **Wong KS**, Li H. Long-term mortality and recurrent stroke risk among Chinese stroke patients with predominant intracranial atherosclerosis. *Stroke* 2003; **34**: 2361-2366 [PMID: 12947158]
- 10 **Yang F**, Liu L, Li M, Li M, Yin Q, Guo R, Li Y, Chen G, Zhang R, Liu X. Pattern of cerebrovascular atherosclerotic stenosis in older Chinese patients with stroke. *J Clin Neurosci* 2013; **20**: 979-983 [PMID: 23685106 DOI: 10.1016/j.jocn.2012.09.017]
- 11 **Man BL**, Fu YP, Chan YY, Lam W, Hui CF, Leung WH, Wong KS. Use of magnetic resonance angiography to predict long-term outcomes of ischemic stroke patients with concurrent stenoses in Hong Kong. *Cerebrovasc Dis* 2009; **28**: 112-118 [PMID: 19506369]
- 12 **Man BL**, Fu YP, Chan YY, Lam W, Hui CF, Leung WH, Mok V, Wong KS. Long-term outcomes of ischemic stroke patients with concurrent intracranial and extracranial stenoses and ischemic heart disease. *Cerebrovasc Dis* 2010; **29**: 236-241 [PMID: 20029196]
- 13 **Man BL**, Fu YP, Wong A, Chan YY, Lam W, Hui AC, Leung WH, Mok V, Wong KS. Cognitive and functional impairments in ischemic stroke patients with concurrent small vessel and large artery disease. *Clin Neurol Neurosurg* 2011; **113**: 612-616 [PMID: 21530070 DOI: 10.1016/j.clineuro.2011.04.001]
- 14 **Man BL**, Fu YP, Chan YY, Lam W, Hui AC, Leung WH, Mok V, Wong KS. Lesion patterns and stroke mechanisms in concurrent atherosclerosis of intracranial and extracranial vessels. *Stroke* 2009; **40**: 3211-3215 [PMID: 19644065]
- 15 **Man BL**, Baum L, Fu YP, Chan YY, Lam W, Hui CF, Leung WH, Wong KS. Genetic polymorphisms of Chinese patients with ischemic stroke and concurrent stenoses of extracranial and intracranial vessels. *J Clin Neurosci* 2010; **17**: 1244-1247 [PMID: 20615707]
- 16 **Ono Y**, Ohta Y. Abnormality of blood coagulation. *Nihon Rinsho* 2000; **58**: 1626-1631 [PMID: 10944924]
- 17 Randomised trial of endarterectomy for recently symptomatic carotid stenosis: final results of the MRC European Carotid Surgery Trial (ECST). *Lancet* 1998; **351**: 1379-1387 [PMID: 9593407 DOI: 10.1016/S0140-6736(97)09292-1]
- 18 **Mohr JP**, Lazar RM, Marshall RS, Gautier JC, Hier DB. Middle cerebral artery disease. *Stroke: Pathophysiology, Diagnosis and Management*. 3 ed. Philadelphia, Churchill Livingstone: 1998: 427-479
- 19 **Chen XY**, Wong KS, Lam WW, Zhao HL, Ng HK. Middle cerebral artery atherosclerosis: histological comparison between plaques associated with and not associated with infarct in a postmortem study. *Cerebrovasc Dis* 2008; **25**: 74-80 [PMID: 18033961]
- 20 **Adams RJ**, Albers G, Alberts MJ, Benavente O, Furie K, Goldstein LB, Gorelick P, Halperin J, Harbaugh R, Johnston SC, Katzan I, Kelly-Hayes M, Kenton EJ, Marks M, Sacco RL, Schwamm LH. Update to the AHA/ASA recommendations for the prevention of stroke in patients with stroke and transient ischemic attack. *Stroke* 2008; **39**: 1647-1652 [PMID: 18322260 DOI: 10.1161/STROKEAHA.107.189063]
- 21 **Kwon SU**, Cho YJ, Koo JS, Bae HJ, Lee YS, Hong KS, Lee JH, Kim JS. Cilostazol prevents the progression of the symptomatic intracranial arterial stenosis: the multicenter double-blind placebo-controlled trial of cilostazol in symptomatic intracranial arterial stenosis. *Stroke* 2005; **36**: 782-786 [PMID: 15746463 DOI: 10.1161/01.STR.0000157667.06542.b7]
- 22 **North American Symptomatic Carotid Endarterectomy Trial Collaborators**. Beneficial effect of carotid endarterectomy in symptomatic patients with high-grade carotid stenosis. *N Engl J Med* 1991; **325**: 445-453 [PMID: 1852179 DOI: 10.1056/NEJM199108153250701]
- 23 **EVA-3S Investigators**. Endarterectomy vs. Angioplasty in Patients with Symptomatic Severe Carotid Stenosis (EVA-3S) Trial. *Cerebrovasc Dis* 2004; **18**: 62-65 [PMID: 15285076]
- 24 **Mantese VA**, Timaran CH, Chiu D, Begg RJ, Brott TG. The Carotid Revascularization Endarterectomy versus Stenting Trial (CREST): stenting versus carotid endarterectomy for carotid disease. *Stroke* 2010; **41**: S31-S34 [PMID: 20876500]
- 25 **Lanzino G**, D'Urso PI, Tymianski M. Advances in vascular neurosurgery 2010. *Stroke* 2011; **42**: 288-290 [PMID: 21233465]
- 26 **Gupta R**, Schumacher HC, Mangla S, Meyers PM, Duong H, Khandji AG, Marshall RS, Mohr JP, Pile-Spellman J. Urgent endovascular revascularization for symptomatic intracranial atherosclerotic stenosis. *Neurology* 2003; **61**: 1729-1735 [PMID: 14694038]
- 27 **Connors JJ**, Wojak JC. Percutaneous transluminal angioplasty for intracranial atherosclerotic lesions: evolution of technique and short-term results. *J Neurosurg* 1999; **91**: 415-423 [PMID: 10470816]
- 28 **Gomez C**, Misra VK, Campbell MS, Kadimi S, Soto RD, Orr SC. Elective stenting of intracranial stenosis is a safe and durable procedure. *Stroke* 2003; **34**: 307
- 29 **SSYL VIA Study Investigators**. Stenting of Symptomatic Atherosclerotic Lesions in the Vertebral or Intracranial Arteries (SSYL VIA): study results. *Stroke* 2004; **35**: 1388-1392 [PMID: 15105508 DOI: 10.1161/01.STR.0000128708.86762.d6]
- 30 **Chaturvedi S**, Fessler R. Angioplasty and stenting for stroke prevention: good questions that need answers. *Neurology* 2002; **59**: 664-668 [PMID: 12229910 DOI: 10.1212/WNL.59.5.664]
- 31 Available from: URL: <http://Clinicaltrial.gov> (NCT 00576693). 2011
- 32 **Jiang WJ**, Yu W, Du B, Gao F, Cui LY. Outcome of patients

- with  $\geq 70\%$  symptomatic intracranial stenosis after Wingspan stenting. *Stroke* 2011; **42**: 1971-1975 [PMID: 21636814 DOI: 10.1161/STROKEAHA.110.595926]
- 33 **Anonymous**. Trial of Cilostazol in Symptomatic intracranial Arterial Stenosis II (TOSS-2) (NCT001130039). Available from: URL: <http://www.clinicaltrials.gov> 2010
  - 34 **Anonymous**. Cilostazol-aspirin therapy against recurrent stroke with intracranial artery stenosis (NCT00333164). Available from: URL: <http://www.clinicaltrials.gov> 2010
  - 35 **Mizumura S**, Nakagawara J, Takahashi M, Kumita S, Cho K, Nakajo H, Toba M, Kumazaki T. Three-dimensional display in staging hemodynamic brain ischemia for JET study: objective evaluation using SEE analysis and 3D-SSP display. *Ann Nucl Med* 2004; **18**: 13-21 [PMID: 15072179]
  - 36 **Ogasawara K**, Ogawa A. [JET study (Japanese EC-IC Bypass Trial)]. *Nihon Rinsho* 2006; **64** Suppl 7: 524-527 [PMID: 17461199]
  - 37 **Leung TW**, Yu SC, Wong KS. Have medical therapy and stenting been fairly compared? A repercussion upon termination of recruitment in the SAMMPRIS trial. *Int J Stroke* 2011; **6**: 312-314 [PMID: 21745340 DOI: 10.1111/j.1747-4949.2011.00634.x]

**P- Reviewers:** Juttler E, Kobayashi T    **S- Editor:** Song XX  
**L- Editor:** Roemmele A    **E- Editor:** Wu HL



## Case of early right ventricular pacing lead perforation and review of the literature

Gary Nash, John Mark Williams, Rajasekhar Nekkanti, Assad Movahed

Gary Nash, John Mark Williams, Rajasekhar Nekkanti, Assad Movahed, Department of Cardiovascular Sciences, East Carolina University, Brody School of Medicine, East Carolina Heart Institute, Greenville, NC 27858, United States

Author contributions: Nash G, Williams JM, Nekkanti R and Movahed A contributed to the manuscript writing and revision. Supported by "East Carolina Heart Institute"

Correspondence to: Assad Movahed, MD, Department of Cardiovascular Sciences, East Carolina University, Brody School of Medicine, East Carolina Heart Institute, 115 Heart Drive, Mail Stop 651, Greenville, NC 27834, United States. [movaheda@ecu.edu](mailto:movaheda@ecu.edu)

Telephone: +1-252-7444400 Fax: +1-252-7447724

Received: November 19, 2013 Revised: March 6, 2014

Accepted: May 8, 2014

Published online: June 16, 2014

URL: <http://www.wjgnet.com/2307-8960/full/v2/i6/206.htm>

DOI: <http://dx.doi.org/10.12998/wjcc.v2.i6.206>

### INTRODUCTION

Cardiac perforation is a known complication of lead implantation and should be considered in cases of post operative lead malfunction. We present a case of early lead perforation diagnosed by chest computed tomography (CT).

### CASE REPORT

A 77-year-old Caucasian female with a past medical history of hypertension, hyperlipidemia and stage 3 chronic kidney disease was brought to the emergency department from home, after her family noticed her "passing out" while seated in a chair. She was noted to regain consciousness within a few seconds. On initial evaluation, her temperature was 36.6 degrees Celsius, blood pressure was 116/61 mmHg, pulse was 43 bpm and regular, respiratory rate was 12 breaths per minute, oxygen saturation on room air was 99%, physical exam was otherwise unremarkable. A sinus node rate of 88 bpm with 2:1 atrioventricular block (ventricular rate of 44 bpm), right bundle branch block and left anterior fascicular block was noted on a 12 lead electrocardiogram (ECG). Exercise myocardial scintigraphy performed one month prior to admission was normal. She was not taking any medications that could cause iatrogenic bradycardia. Ten seconds of ventricular asystole was noted on inpatient telemetry monitoring prompting insertion of a temporary transvenous pacemaker. Six hours later, a dual chamber permanent pacemaker was implanted in the cardiac electrophysiology lab with good post operative sensing and pacing thresholds in the atrium and ventricle. Twelve hours later she complained of left upper quadrant abdominal pain. Inpatient telemetry demonstrated 2:1 atrioventricular block with loss of ventricular capture at high

### Abstract

We report a case of a 77-year-old patient with complete atrioventricular block. She underwent permanent pacemaker implantation complicated by right ventricular lead perforation. This was suspected on transthoracic echocardiogram and confirmed by chest computed tomography. The lead was repositioned in the cardiac electrophysiology lab followed by an uneventful course thereafter.

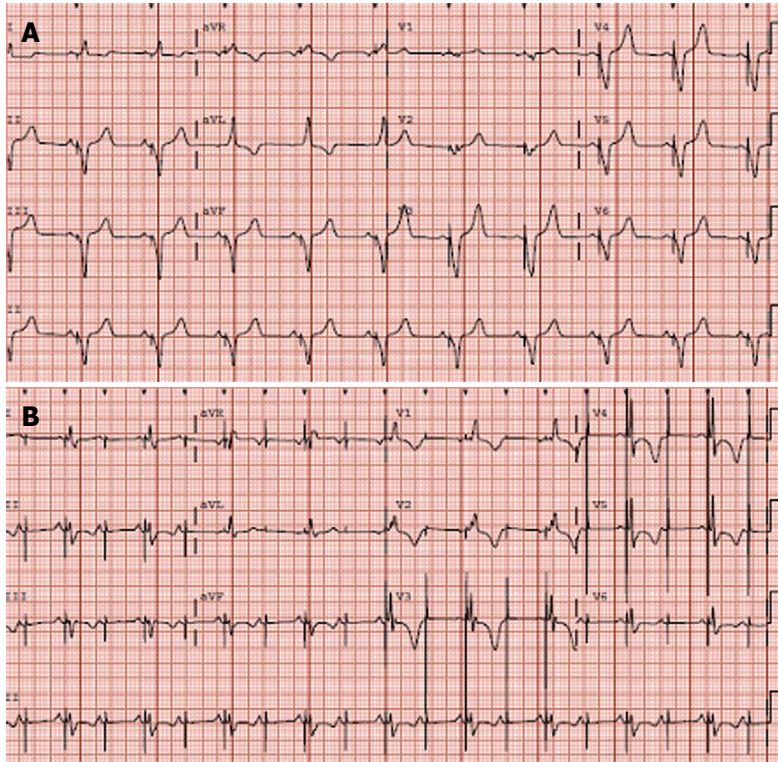
© 2014 Baishideng Publishing Group Inc. All rights reserved.

**Key words:** Pacemaker; Lead; Perforation

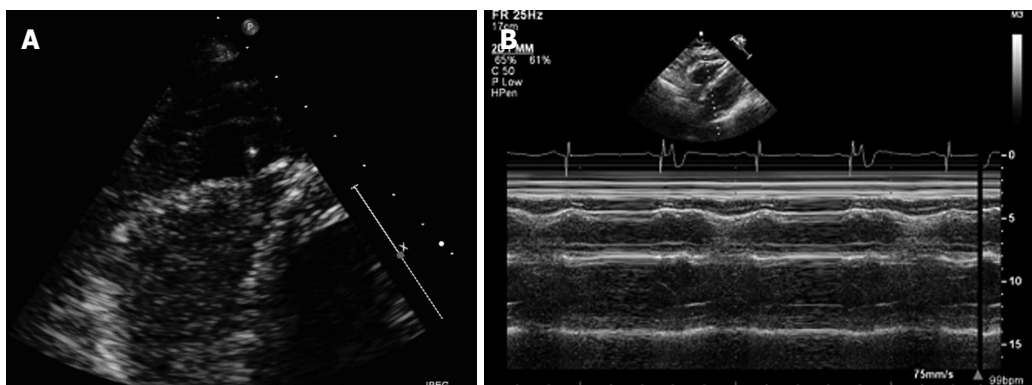
**Core tip:** Cardiac perforation should be considered in cases of pacing lead malfunction. Chest computed tomography is helpful in diagnosing lead perforation and can be done without contrast and using a small field of view to diminish the effective radiation dose.

Nash G, Williams JM, Nekkanti R, Movahed A. Case of early right ventricular pacing lead perforation and review of the literature. *World J Clin Cases* 2014; 2(6): 206-208 Available from:

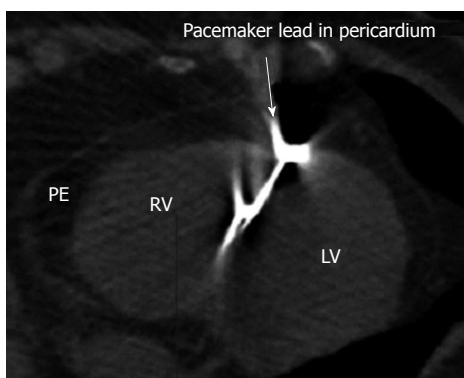




**Figure 1 Electrocardiogram.** Electrocardiogram on the top panel taken immediately after permanent pacemaker implantation demonstrates atrial sensing with ventricular pacing (A); The electrocardiogram on the bottom panel demonstrates failure to capture in the right ventricle with underlying 2:1 atrioventricular Block (B). The pacing configuration was bipolar with high outputs. Notice the prominent pacing spikes.



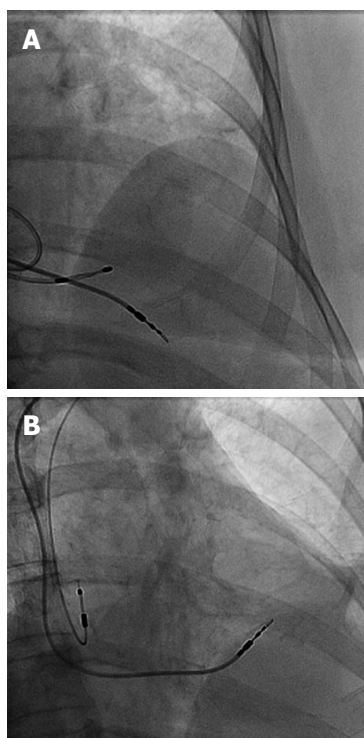
**Figure 2 Transthoracic echocardiogram.** A: Image is an apical 4 chamber view of a transthoracic echocardiogram showing a moderate sized localized pericardial effusion with an echo bright structure within the effusion suspicious for lead perforation; B: Image is taken in M-mode and demonstrates right ventricular diastolic collapse suggestive of increased pericardial pressures.



**Figure 3 This is an axial view of a non contrast chest computed tomography confirming diagnosis of right ventricular lead perforation.** The arrow points to the perforated lead. There is a pericardial effusion (PE). The right ventricle (RV) and left ventricle (LV) are also demonstrated.

pacing output (Figure 1). Chest X-ray did not show any shift in lead positions. A temporary transvenous pacemaker was reinserted. Ventricular lead perforation was suspected. A transthoracic echocardiogram demonstrated an echo bright structure protruding into the pericardial space. However, the images were suboptimal in quality and therefore technically limited to confirm lead perforation. A localized moderate sized pericardial effusion with right ventricular diastolic collapse best seen on M-mode imaging (Figure 2) was also noted. She demonstrated no clinical signs of cardiac tamponade. Non contrast chest CT confirmed lead perforation (Figure 3) with the tip of the right ventricular lead in the pericardial space. The lead was repositioned in the cardiac electrophysiology lab under fluoroscopic and echocardiographic guidance (Figure 4). Follow up echocardiogram revealed no change





**Figure 4 Image.** Top image shows the right ventricular permanent pacemaker lead protruding well past the heart border. A temporary transvenous pacemaker lead can also be seen within the right ventricle (A); The bottom image shows the repositioned right ventricular lead higher up on the interventricular septum and absence of the temporary transvenous pacemaker lead. The right atrial lead can also be seen in this image (B).

in the size of the effusion. There was also resolution of right ventricular diastolic collapse. Device interrogation demonstrated stable pacing and sensing thresholds in the right ventricle. The leads remained in stable position on chest X-ray. On follow up 1 wk later the patient was doing well with complete resolution of the pericardial effusion on echocardiogram.

## DISCUSSION

Complications associated with permanent pacemaker implantation include pneumothorax, myocardial perforation, lead dislodgement or fracture, infection, hematoma, erosion and vein thrombosis<sup>[1]</sup>. The rates of cardiac perforation range from 0.1% to 0.8% for pacemaker leads<sup>[2]</sup>. One should be alerted to the possibility of cardiac perforation by a pacemaker lead if pacing or sensing malfunction is noted. Most cases of lead perforation happen during or shortly after implant, but cases of late perforation as long as 4.8 years after implant have been reported<sup>[3]</sup>. Chest X-ray has traditionally been used to evaluate lead positioning in cases of suspected pacemaker lead perforation. Echocardiogram can be used to provide additional information such as extent of pericardial effusion. Another option is a non-contrast chest CT utilizing a small

field of view to reduce the effective radiation dose. In a small case series Henrikson *et al*<sup>[4]</sup> demonstrated that 64 slice Chest CT was able to make the diagnosis of cardiac perforation by a device lead in all suspected cases. Risk factors for lead perforation include patient characteristics such as female sex, age, small body habitus, thin heart walls; concomitant therapies such as steroids or anticoagulants; implant techniques; and the design characteristics of the lead<sup>[2]</sup>. Cardiac perforation by a lead can be corrected by repositioning it under fluoroscopic guidance in the cardiac electrophysiology lab, however surgery may be necessary.

## COMMENTS

### Case characteristics

This is a 77-year-old Caucasian female with a past medical history of hypertension, hyperlipidemia and stage 3 chronic kidney disease who presented with an episode of syncope.

### Clinical diagnosis

She had an episode of ventricular asystole while in the hospital and underwent permanent pacemaker implantation complicated by lead perforation.

### Differential diagnosis

Ischemic, infectious, iatrogenic and endocrine causes of atrioventricular block were ruled out.

### Laboratory diagnosis

The patient had normal electrolytes, thyroid stimulating hormone level and was not on any atrioventricular nodal blocking agents.

### Imaging diagnosis

A non-contrast chest computed tomography confirmed pacemaker lead perforation.

### Pathological diagnosis

There were no relevant pathological findings in this case.

### Treatment

The patient underwent permanent pacemaker implantation with subsequent lead revision after being diagnosed with cardiac perforation.

### Related reports

There are other case reports using various imaging modalities to diagnose cardiac perforation by a pacemaker lead.

### Experiences and lessons

Cardiac perforation by a pacemaker lead should be considered in cases of device malfunction regardless of the age of the device.

### Peer review

A well done case report. It finds no ancillary comments that would aid the readership, continued success with this excellent writing.

## REFERENCES

- 1 **Phibbs B**, Marriott HJ. Complications of permanent transvenous pacing. *N Engl J Med* 1985; **312**: 1428-1432 [PMID: 3887169 DOI: 10.1056/NEJM198505303122205]
- 2 **Carlson MD**, Freedman RA, Levine PA. Lead perforation: incidence in registries. *Pacing Clin Electrophysiol* 2008; **31**: 13-15 [PMID: 18181903 DOI: 10.1111/j.1540-8159.2007.00943.x]
- 3 **Alla VM**, Reddy YM, Abide W, Hee T, Hunter C. Delayed lead perforation: can we ever let the guard down? *Cardiol Res Pract* 2010; **2010**: [PMID: 20811487 DOI: 10.4061/2010/741751]
- 4 **Henrikson CA**, Leng CT, Yuh DD, Brinker JA. Computed tomography to assess possible cardiac lead perforation. *Pacing Clin Electrophysiol* 2006; **29**: 509-511 [PMID: 16689847 DOI: 10.1111/j.1540-8159.2006.00385.x]

P- Reviewers: Marinkovic SP, Sijens PE S- Editor: Qi Y  
L- Editor: A E- Editor: Wu HL



## Perforated jejunal ulcer associated with gastric mucosa in a jejunal diverticulum

John Bunni, Helen L Barrett, Tim A Cook

John Bunni, Tim A Cook, Department of Surgery, Gloucestershire Royal Hospital, Gloucester GL1 3NN, United Kingdom  
 Helen L Barrett, Department of Pathology, Gloucestershire Royal Hospital, Gloucester GL1 3NN, United Kingdom  
 Author contributions: Bunni J and Cook TA operated on the patient; Barrett HL assessed the pathology; Bunni J conceived and wrote the manuscript; all authors approved it.  
 Correspondence to: John Bunni, MB, ChB (Hons), MRCS, Registrar in General Surgery, Department of Surgery, Gloucestershire Royal Hospital, Great Western Rd, Gloucester GL1 3NN, United Kingdom. [johnbunni@hotmail.com](mailto:johnbunni@hotmail.com)  
 Telephone: +44-84-54222222 Fax: +44-84-54225612  
 Received: December 14, 2013 Revised: January 27, 2014  
 Accepted: May 8, 2014  
 Published online: June 16, 2014

### Abstract

Jejunal diverticula are rare and subsequent complications even more so. The usual small bowel diverticulum encountered by general surgeons is a Meckel's. These are embryological remnants of the vitello-intestinal duct and are on the anti-mesenteric surface of the terminal ileum. They may contain heterotopic gastric or pancreatic mucosa. Herein we explore the case of a young girl who presented with features of peritonitis secondary to a complication from a jejunal diverticulum. The case, pathology, complications and treatment of jejunal diverticulosis and heterotopic gastric mucosa in the jejunum are explored.

© 2014 Baishideng Publishing Group Inc. All rights reserved.

**Key words:** Jejunum; Perforation; Heterotopic gastric mucosa; Meckel's gastrointestinal diverticulum

**Core tip:** Herein we describe a rare but important cause of peritonitis in children. We feel it will be of interest to surgeons and pathologists alike and is an important reminder of the basic anatomy and pathology of surgical disease.

Bunni J, Barrett HL, Cook TA. Perforated jejunal ulcer associated with gastric mucosa in a jejunal diverticulum. *World J Clin Cases* 2014; 2(6): 209-210 Available from: URL: <http://www.wjgnet.com/2307-8960/full/v2/i6/209.htm> DOI: <http://dx.doi.org/10.12998/wjcc.v2.i6.209>

### INTRODUCTION

Jejunal diverticula are rare and subsequent complications even more so<sup>[1]</sup>. The usual small bowel diverticulum encountered by general surgeons is a Meckel's. These are embryological remnants of the vitello-intestinal duct and are on the anti-mesenteric surface of the terminal ileum. They may contain heterotopic gastric or pancreatic mucosa.

Complications of true jejunal diverticula are rare particularly in young children. Herein we explore the case of a young girl who presented with features of peritonitis secondary to a complication from a jejunal diverticulum. Following surgery she made an excellent recovery. We explore the case, pathology, complications and treatment of jejunal diverticulosis and heterotopic gastric mucosa in the jejunum.

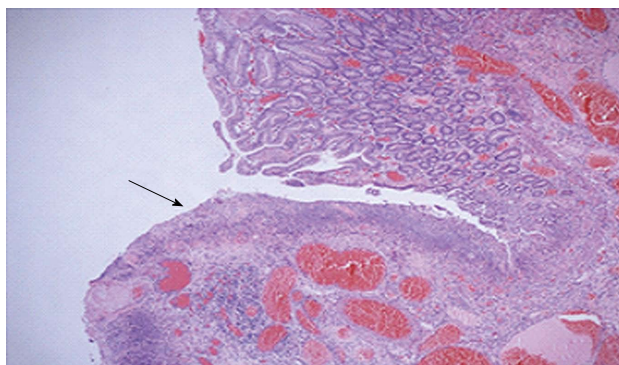
### CASE REPORT

A previously fit and well 5 years old girl presented to the pediatricians with a two day history of worsening abdominal pain, anorexia and vomiting.

Clinical findings were of pyrexia and generalised peritonitis. Bloods tests showed a lymphocytosis of  $29.2 \times 10^9/L$ .

A working differential diagnosis was of acute perforated appendicitis or perforated Meckel's diverticulum and she was taken immediately to the operating theatre.

A 1 cm proximal jejunal perforation was identified on the antimesenteric border, directly opposite a mesenteric diverticulum, with a normal appendix. Small bowel re-



**Figure 1** Ulcerated small bowel mucosa (arrow) adjacent to area of perforation.

section was performed with peritoneal toilet. She made a steady recovery and was discharged home on day four post-operatively.

## DISCUSSION

Histology of the small bowel showed features of a true diverticulum with gastric mucosa lining the diverticulum. *Helicobacter*-like organisms were not identified. The adjacent small bowel showed transmural inflammation and degeneration of the wall at the site of perforation with an adjacent serosal exudate (Figure 1). There was no evidence of malignancy. Sections of the appendix showed a mild serosal exudate but no evidence of mucosal acute inflammation.

Jejunal diverticula, like all diverticula can be true, involving all three layers of the bowel wall or false - a herniation of mucosa and submucosa through the muscularis propria. True diverticula are usually congenital and false are acquired. The latter are more common and are pulsion diverticula which arise at the weak point on the jejunal mesenteric surface (the point where the mural vessels penetrate the bowel wall). They are more common in middle aged males.

Rarer are the true diverticula which are congenital in nature. These can be on either the mesenteric or antimesenteric surface. The mesenteric diverticula are thought to be primarily related to the neurenteric remnants and duplications, and can be lined by gastric; intestinal or respiratory type epithelium or contain heterotopic pancreatic tissue.

Complications from jejunal diverticula are varied. Though the majority are silent, they can present with chronic abdominal pain, malabsorption, acute gastrointestinal haemorrhage, occult bleeding, diverticulitis, perforation, bacterial overgrowth or small bowel obstruction due to jejunal volvulus. Complications warranting surgical intervention occur in 8% to 30% of patients<sup>[2]</sup>.

In the elective setting, if suspicious of jejunal diverticulosis there are different investigations that can be performed. These include small bowel follow through,

small bowel enteroclysis, capsule endoscopy, computed tomography scanning as well as in the case of bleeding, radionuclide scans and mesenteric angiography.

Jejunal heterotopic gastric mucosa is a very rare entity, and literature review revealed the usual presenting age to be 14 years<sup>[3]</sup>. A common presentation is that of intermittent intussusception secondary to a small bowel (usually) polypoidal mass. This mass is predominantly located only a few centimetres distal to ligament of Treitz.

Management of jejunal diverticula depends on whether or not patients experience symptoms. Asymptomatic jejunal diverticula found incidentally rarely warrant treatment. In symptomatic cases small bowel resection and end-to-end anastomosis is advised.

Jejunal diverticula are rare and their complications even more so. There are subtle pathological differences and once responsible for complications the authors advise small bowel resection and end-to-end anastomosis so as to achieve a pathological diagnosis; cure the problem and ensure no remaining potential heterotopic mucosa of other organs remains.

## COMMENTS

### Case characteristics

This young patient presented with an acute abdomen and shock.

### Clinical diagnosis

Diagnose with peritonitis. Lab tests showed a lymphocytosis.

### Differential diagnosis

Acute appendicitis or perforated Meckel's diverticulum.

### Laboratory diagnosis

She was taken to the operating room whereby a small bowel perforation was identified and resected.

### Pathological diagnosis

Histopathological analysis revealed this to be a perforation secondary to heterotopic gastric mucosa.

### Treatment

Small bowel resection was performed with peritoneal toilet and making a steady recovery.

### Experiences and lessons

To rapidly identify the sick patient and not waste time on investigations that will not alter management. Awareness of the diversity of small bowel pathology.

### Peer review

This is a short case report showing a pediatric patient with perforating jejunal diverticulum. The case is rare and may be worth publication.

## REFERENCES

- 1 Zager JS, Garbus JE, Shaw JP, Cohen MG, Garber SM. Jejunal diverticulosis: a rare entity with multiple presentations, a series of cases. *Dig Surg* 2000; **17**: 643-645 [PMID: 11155015 DOI: 10.1159/000051978]
- 2 Wilcox RD, Shatney CH. Surgical significance of acquired ileal diverticulosis. *Am Surg* 1990; **56**: 222-225 [PMID: 2114067]
- 3 Boybeyi O, Karnak I, Güçer S, Orhan D, Senocak ME. Common characteristics of jejunal heterotopic gastric tissue in children: a case report with review of the literature. *J Pediatr Surg* 2008; **43**: e19-e22 [PMID: 18639669 DOI: 10.1016/j.jpedsurg.2008.02.072]

P- Reviewers: Kim BW, Kato J S- Editor: Ma YJ  
L- Editor: A E- Editor: Wu HL





## Abnormal electrocardiogram in a patient with amyotrophic lateral sclerosis mimicking myocardial ischaemia

Juana Martínez, César Ramón, César Morís, Julio Pascual, Germán Morís

Juana Martínez, César Ramón, Julio Pascual, Germán Morís, Neurology Department, Hospital Universitario Central Asturias, 33006 Oviedo, Spain

César Morís, Cardiology Department, Hospital Universitario Central Asturias, 33006 Oviedo, Spain

**Author contributions:** Martínez J and Morís G contributed to conception and design case history, data, medical care of the patient, drafting case history and revising article for intellectual content; Ramón C and Pascual J contributed to conception and design case history, revising article for intellectual content; Morís C contributed to collection of cardiological data, revision of the manuscript for intellectual content; all authors contributed to final approval of the version to be published.

**Correspondence to:** Germán Morís, MD, Neurology Department, Hospital Universitario Central Asturias, HUCA. C/Celestino Villamil s/n, 33006 Oviedo, Spain. [gmoris@gmail.com](mailto:gmoris@gmail.com)  
Telephone: +34-98-5108000 Fax: +34-98-5109479

Received: January 5, 2014 Revised: March 26, 2014

Accepted: May 8, 2014

Published online: June 16, 2014

This Case Report may support the impairment of cardiac autonomic control in patients with ALS.

© 2014 Baishideng Publishing Group Inc. All rights reserved.

**Key words:** Amyotrophic lateral sclerosis; Autonomic nervous system diseases; Electrocardiography; Myocardial ischemia; Cardiac catheterization

**Core tip:** A few cases showing electrocardiogram (ECG) abnormalities in amyotrophic lateral sclerosis (ALS) patients have been previously reported suggesting an autonomic disturbance in ALS. We present an ALS patient with abnormal ECG mimicking myocardial ischaemia, in whom both coronary disease and cardiac anatomic damage were ruled out supporting the autonomic nervous system involvement in this mainly motor neuron disease.

### Abstract

Amyotrophic lateral sclerosis (ALS) is a progressive neurodegenerative disorder that almost exclusively involves motor neurons although autonomic dysfunction has also been reported. We present an 84-year-old female with no documented history of heart disease, who was admitted with negative T waves in the electrocardiogram precordial leads mimicking myocardial ischaemia. No other abnormalities were shown in the rest of the cardiological evaluation, suggesting autonomic nervous system dysfunction. A neurophysiological study demonstrated acute and chronic denervation in multiple muscles with normal nerve conduction studies, confirming ALS diagnosis. Previous studies have shown that subclinical sympathetic hyperfunction and parasympathetic hypofunction might result in cardiovascular dysfunction in ALS patients. It is important to detect disturbances of autonomic cardiac control because this dysfunction may influence survival and quality of life, leading to a decrease in life expectancy in ALS patients.

Martínez J, Ramón C, Morís C, Pascual J, Morís G. Abnormal electrocardiogram in a patient with amyotrophic lateral sclerosis mimicking myocardial ischaemia. *World J Clin Cases* 2014; 2(6): 211-214 Available from: URL: <http://www.wjgnet.com/2307-8960/full/v2/i6/211.htm> DOI: <http://dx.doi.org/10.12998/wjcc.v2.i6.211>

### INTRODUCTION

Amyotrophic lateral sclerosis (ALS) is an idiopathic, fatal neurodegenerative disease caused by degeneration of the first and second motoneurons. Recent advances indicate heterogeneity in phenotype, pathological substrate and genetic predisposition, suggesting that ALS should be considered a syndrome rather than a single disease entity. Therefore, the clinical presentation and progression of ALS may vary considerably. Cognitive and behavioural impairment is a frequent feature of ALS but other non-motor clinical features, such as autonomic nervous system (ANS) dysfunction, are underreported<sup>[1,2]</sup>. The



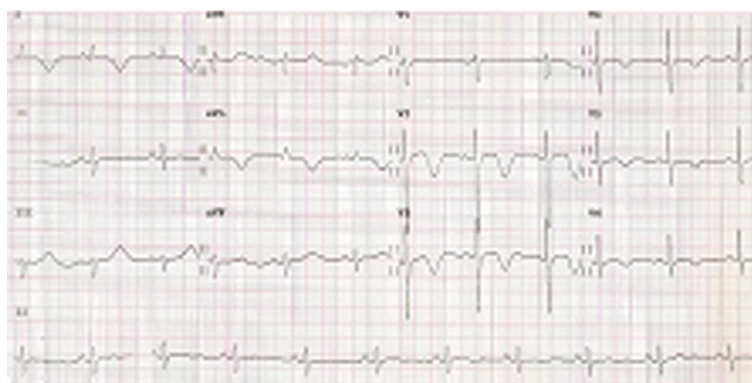

Figure 1 Resting 12-lead electrocardiogram showing negative T waves in precordial leads I, aVL, V2-V6.

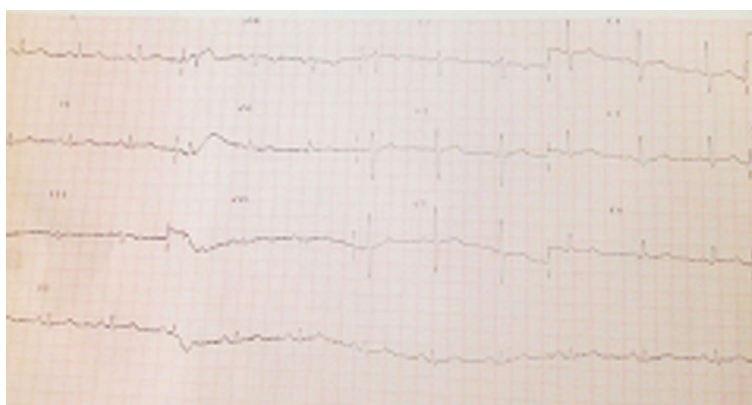


Figure 2 Normal 12-lead electrocardiogram performed in 2002.

affection of the ANS in ALS, as part of a complex degenerative process, has an increasing evidence and it is postulated that ALS patients develop dysautonomic dysfunction that may involve the heart<sup>[3]</sup>.

Herein, we report an ALS patient with both negative T waves on the electrocardiogram (ECG) and no data of underlying coronary disease, supporting ANS dysfunction in ALS.

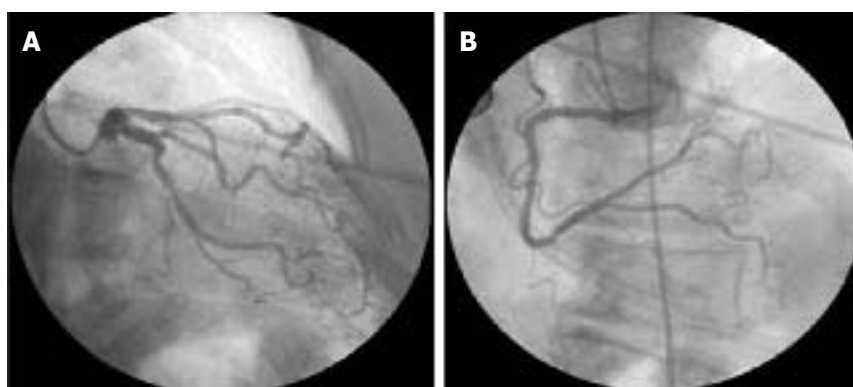
## CASE REPORT

An 84-year-old female with no history of heart disease was referred to our hospital because of chest pain, dyspnoea and abnormal ECG showing negative T waves in precordial leads V2-V6 and I, aVL (Figure 1). Initially, the patient had been admitted to a different hospital due to chest pain and progressive dyspnoea. While performing an electromyogram, an episode of shortness of breath, rales on auscultation and desaturation was documented. A chest radiograph was performed suggesting cardiac failure and an ECG showed anterior and lateral subepicardial ischaemia. Diagnostic of acute coronary syndrome was done and the patient was transferred to our Hospital.

The patient had a diagnosis of hypertension made several years before, being under enalapril treatment since then. No other treatments had ever been prescribed. There was no history of myocardial infarction, myocarditis, cardiomyopathy, pericarditis, hyper- or hypothyroidism or calcium metabolism disturbances. An ECG performed 10 years ago showed no abnormalities (Figure 2);

no other ECGs were performed before this episode. The patient was feeling well until six months ago, when she started experiencing painless and progressive weakness in her left hand. During the following weeks, weakness progressed to proximal and distal muscles in both upper limbs.

Neurological examination showed a normal mental status. Her speech was dysarthric, no facial paresis was noted but mild lingual weakness was observed. The visual fields were intact and ocular movements were full and smooth. Asymmetric muscle weakness and atrophy, involving the upper extremities, were present with severe atrophy of the left hand muscles. Mild proximal paresis was observed in both lower limbs. Fasciculations were noted in the tongue, upper, and lower extremities. Deep-tendon reflexes were brisk and there were bilateral ankle clonus. There was jaw hyperreflexia. Plantar responses were extensor. There were no sensory deficits. Bowel and bladder function remained normal. Complete blood cell count was normal, as were electrolyte, Troponin T, creatine kinase, creatinine, fasting plasma glucose and haemoglobin A1c concentrations. Liver function and thyroid function studies yielded normal results. A brain CT scan depicted no abnormalities and a cervical MRI showed no abnormal findings at the spinal cord or the nerve roots. A neurophysiological study demonstrated acute and ongoing chronic partial denervation in multiple muscles of bulbar region and both upper and lower extremities with normal nerve conduction studies. The diagnosis of definitive ALS was made according to the Awaji-Shima criteria<sup>[4]</sup>. Echocardiography showed 16 mm left ventricular



**Figure 3** Coronary angiogram showed normal coronary arteries. A: left coronary arteries; B: right coronary artery.

symmetrical hypertrophy with normal wall motion and a coronary angiography showed no significant anomalies (Figure 3). The patient suffered a progressive respiratory failure and she died four days after hospital admission.

## DISCUSSION

There is well known that various central nervous system disorders can cause ECG abnormalities that mimic coronary syndromes including S-T elevation, T wave inversion and Q-T prolongation. These findings have been well described in relation with subarachnoid or subdural haematomas. Central or peripheral autonomic dysfunction has been also described in patient with Parkinson's disease, multiple system atrophy or Guillain-Barré syndrome which increases the risk for arrhythmias, therefore, ECG monitoring is essential<sup>[6]</sup>.

The impact of ALS on the cardiovascular system is well known. Several studies have shown that subclinical sympathetic hyperfunction and parasympathetic hypo-function might result in cardiovascular dysfunction in ALS patients<sup>[3,6-10]</sup>. There are very few reports describing the ECG characteristics in relation with this pathology. ECG alterations in ALS have been presented as a pseudo-ischaemic pattern, however a pseudo-myocardial infarction pattern has also been described<sup>[11-13]</sup>. Moreover, an elevated Troponin T levels in a patient with ALS without underlying ischaemic cardiopathy has been reported as a consequence of hypoxic respiratory failure or as immune-mediated myocardial injury secondary to ALS<sup>[14]</sup>.

In ALS, involvement of sympathetic neurons has been associated with neuron degeneration in the intermediolateral nucleus of the upper thoracic spinal cord, causing subclinical findings such as reduction in nocturnal blood pressure and loss of correlation between blood pressure and heart rate. In a study analyzing changes in the corrected QT interval (QTc) and QTc dispersion, ECG showed that both the average QTc and QTc dispersion was significantly higher in patients with ALS supporting sympathetic disturbances in this motoneuron disease<sup>[6]</sup>. Furthermore, Pavlovic *et al*<sup>[3]</sup>, studied the cardiovascular autonomic control in 55 patients with ALS and compared it with 30 healthy controls. They found that patients with ALS have a significantly higher degree of both sympathetic and parasympathetic dysfunction with relative sympathetic predominance compared with

controls. Disturbances of autonomic cardiac control in ALS patients may influence survival and quality of life predisposing to hypertensive crisis, sudden cardiac death, and cardiovascular collapse, all leading to a decrease in life expectancy<sup>[3,10,15]</sup>. In addition, recent studies have established the contribution of neuronal ion channel dysfunction to the pathophysiology of ALS, mainly Na<sup>+</sup> and K<sup>+</sup> channels; moreover, the modulation of ion channel function has been proposed as the mechanism by which riluzole exerts the neuroprotective effects in ALS<sup>[16-18]</sup>. Based on ion channels dysfunction implicated in heart disease, it could also be argued that ECG changes in ALS patients may be related with ion channel dysfunction<sup>[19]</sup>.

We present an ALS patient with an ECG showing negative T waves in precordial leads mimicking myocardial ischaemia. Complementary tests ruled out systemic and cardiologic causes that might have been associated with these ECG disturbances; therefore, an association between the pseudo-ischaemic ECG and ALS was suspected. The underlying mechanism of these abnormalities in the ECG must be addressed although ANS dysfunction has been proposed. Unfortunately, neither a baseline ECG nor a follow-up ECG after the acute episode were performed and the only previous ECG was done 10 years before. However, we cannot completely rule out that other underlying processes not covered by our investigations were the cause. In conclusion, it is important to detect disturbances of autonomic cardiac dysfunction in ALS patients to avoid sudden death or other conditions leading to a decrease in life expectancy.

## COMMENTS

### Case characteristics

An 84-year-old female with a diagnosis of amyotrophic lateral sclerosis (ALS) presented with negative T waves in the electrocardiogram (ECG) mimicking myocardial ischaemia.

### Clinical diagnosis

The patient exhibited classical clinical features of ALS and an ECG showed negative T waves in precordial leads I, aVL and V2-V6.

### Differential diagnosis

Differential diagnosis included myocardial infarction or ischaemia, myocarditis, cardiomyopathy, pericarditis, hyper- or hypothyroidism or calcium metabolism disturbances.

### Laboratory diagnosis

A neurophysiological study demonstrated acute and ongoing chronic partial denervation in multiple muscles of bulbar region and both upper and lower ex-

tremities with normal nerve conduction studies.

### Imaging diagnosis

The cardiologic studies including echocardiogram and coronary angiography were normal.

### Treatment

The patient did not receive any treatment and she died in a few days.

### Related reports

A literature search revealed only a few cases of abnormal ECG in patients with ALS mimicking myocardial ischaemia or infarct.

### Term explanation

The Awaji-Shima criteria in the diagnosis of ALS were proposed in 2008 to enable earlier diagnosis of ALS to obviate diagnostic delay and to promote earlier entry into clinical trials.

### Experiences and lessons

The affection of the autonomic nervous system in ALS has increasing evidence and it is postulated that ALS patients develop dysautonomic dysfunction that may involve the heart

### Peer review

This is a well-written, interesting case report with good images.

## REFERENCES

- 1 **Hardiman O**, van den Berg LH, Kiernan MC. Clinical diagnosis and management of amyotrophic lateral sclerosis. *Nat Rev Neurol* 2011; **7**: 639-649 [PMID: 21989247 DOI: 10.1038/nrneurol.2011.153]
- 2 **Kiernan MC**, Vucic S, Cheah BC, Turner MR, Eisen A, Hardiman O, Burrell JR, Zoing MC. Amyotrophic lateral sclerosis. *Lancet* 2011; **377**: 942-955 [PMID: 21296405 DOI: 10.1016/s0140-6736(10)61156-7]
- 3 **Pavlovic S**, Stevic Z, Milovanovic B, Milicic B, Rakocevic-Stojanovic V, Lavrnjic D, Apostolski S. Impairment of cardiac autonomic control in patients with amyotrophic lateral sclerosis. *Amyotroph Lateral Scler* 2010; **11**: 272-276 [PMID: 20001491 DOI: 10.3109/17482960903390855]
- 4 **Costa J**, Swash M, de Carvalho M. Awaji criteria for the diagnosis of amyotrophic lateral sclerosis: a systematic review. *Arch Neurol* 2012; **69**: 1410-1416 [PMID: 22892641 DOI: 10.1001/archneurol.2012.254]
- 5 **Marsh E**, O'Callaghan P, Smith P. The humble electrocardiogram. *Pract Neurol* 2008; **8**: 46-59 [PMID: 18230709 DOI: 10.1136/jnnp.2007.140988]
- 6 **Asai H**, Hirano M, Udaka F, Shimada K, Oda M, Kubori T, Nishinaka K, Tsujimura T, Izumi Y, Konishi N, Matsumoto S, Kameyama M, Ueno S. Sympathetic disturbances increase risk of sudden cardiac arrest in sporadic ALS. *J Neurol Sci* 2007; **254**: 78-83 [PMID: 17303172 DOI: 10.1016/j.jns.2007.01.007]
- 7 **Chida K**, Sakamaki S, Takasu T. Alteration in autonomic function and cardiovascular regulation in amyotrophic lateral sclerosis. *J Neurol* 1989; **236**: 127-130 [PMID: 2709061]
- 8 **Kandinov B**, Korczyn AD, Rabinowitz R, Nefussy B, Drory VE. Autonomic impairment in a transgenic mouse model of amyotrophic lateral sclerosis. *Auton Neurosci* 2011; **159**: 84-89 [PMID: 20869331 DOI: 10.1016/j.autneu.2010.09.002]
- 9 **Baltadzhieva R**, Gurevich T, Korczyn AD. Autonomic impairment in amyotrophic lateral sclerosis. *Curr Opin Neurol* 2005; **18**: 487-493 [PMID: 16155429]
- 10 **Shimizu T**, Hayashi H, Kato S, Hayashi M, Tanabe H, Oda M. Circulatory collapse and sudden death in respirator-dependent amyotrophic lateral sclerosis. *J Neurol Sci* 1994; **124**: 45-55 [PMID: 7931421]
- 11 **Li AH**, Hsu KL, Liao CS, Tseng YZ, Lee YT. Amyotrophic lateral sclerosis with a 'pseudo-infarction' pattern on the electrocardiograph. A case report. *Cardiology* 2000; **93**: 133-136 [PMID: 10894921]
- 12 **Rodriguez-Castro CE**, Elfar A, Gonzalez-Ibarra FP, Siddiqui T, Abbas A. Amyotrophic lateral sclerosis and pseudo-infarct pattern on the electrocardiogram. *Am J Med* 2013; **126**: e3-e5 [PMID: 23684065 DOI: 10.1016/j.amjmed.2013.01.023]
- 13 **Zhang J**, Yang SW, Wang Z, Wei GR, Zhou YJ. Pseudo-ischaemic ECG in a patient with amyotrophic lateral sclerosis surviving for a decade. *BMJ Case Rep* 2012; **2012**: [PMID: 22665549 DOI: 10.1136/bcr.01.2012.5543]
- 14 **Von Lueder TG**, Melsom MN, Atar D, Agewall S. Amyotrophic lateral sclerosis (ALS), a novel rare cause of elevated plasma troponin T levels. *Clin Lab* 2011; **57**: 615-618 [PMID: 21888026]
- 15 **Gil J**, Funalot B, Verschueren A, Danel-Brunaud V, Camu W, Vandenberghe N, Desnuelle C, Guy N, Camdessanche JP, Cintas P, Carluer L, Pittion S, Nicolas G, Corcia P, Fleury MC, Maugras C, Besson G, Le Masson G, Couratier P. Causes of death amongst French patients with amyotrophic lateral sclerosis: a prospective study. *Eur J Neurol* 2008; **15**: 1245-1251 [PMID: 18973614 DOI: 10.1111/j.1468-1331.2008.02307.x]
- 16 **Kanai K**, Kuwabara S, Misawa S, Tamura N, Ogawara K, Nakata M, Sawai S, Hattori T, Bostock H. Altered axonal excitability properties in amyotrophic lateral sclerosis: impaired potassium channel function related to disease stage. *Brain* 2006; **129**: 953-962 [PMID: 16467388 DOI: 10.1093/brain/awl024]
- 17 **Krishnan AV**, Lin CS, Park SB, Kiernan MC. Axonal ion channels from bench to bedside: a translational neuroscience perspective. *Prog Neurobiol* 2009; **89**: 288-313 [PMID: 19699774 DOI: 10.1016/j.pneurobio.2009.08.002]
- 18 **Vucic S**, Lin CS, Cheah BC, Murray J, Menon P, Krishnan AV, Kiernan MC. Riluzole exerts central and peripheral modulating effects in amyotrophic lateral sclerosis. *Brain* 2013; **136**: 1361-1370 [PMID: 23616585 DOI: 10.1093/brain/awt085]
- 19 **Chockalingam P**, Wilde A. The multifaceted cardiac sodium channel and its clinical implications. *Heart* 2012; **98**: 1318-1324 [PMID: 22875823 DOI: 10.1136/heartjnl-2012-301784]

**P- Reviewers:** Chu D, Hirose H, Riva N, Schoenhagen P, Trohman RG **S- Editor:** Song XX **L- Editor:** A **E- Editor:** Wu HL



## Pyonephrosis as a sign of sarcomatoid carcinoma of the renal pelvis

Sergio Fernández-Pello, Victoria Venta, Iván González, Rodrigo Gil, Carmen Luz Menéndez

Sergio Fernández-Pello, Iván González, Rodrigo Gil, Department of Urology, Cabueñes Hospital, 33394 Gijón, Spain  
Victoria Venta, Carmen Luz Menéndez, Department of Pathology, Cabueñes Hospital, 33394 Gijón, Spain  
Author contributions: All the authors equally contributed to this paper.

Correspondence to: Sergio Fernández-Pello, MD, Department of Urology, Cabueñes Hospital, Calle de los prados 395, 33394 Gijón, Spain. [spello84@hotmail.com](mailto:spello84@hotmail.com)

Telephone: +43-512-50423401 Fax: +43-512-50424052

Received: December 13, 2013 Revised: January 6, 2014

Accepted: May 8, 2014

Published online: June 16, 2014

### Abstract

We report the case of an urgent nephrectomy because of a pyonephrosis and sepsis due to an unsuspected sarcomatoid transitional cell carcinoma, an infrequent subtype with a bad oncological prognosis. We present a 58-year-old man assessed by internal medicine for a general syndrome and weakness many months previously. A pyonephrotic kidney was observed at abdominal computed tomography in the context of septic shock, without suspecting the underlying cause. The pathology report described a sarcomatoid transitional cell carcinoma. Sarcomatoid transitional cell carcinoma is an invasive and infrequent subtype of urothelial tumors. The symptoms are often the same as other renal masses; however, in this case, sepsis and pyonephrosis were the rare initial symptoms.

© 2014 Baishideng Publishing Group Inc. All rights reserved.

**Key words:** Urothelial carcinoma; Renal pelvis; Sarcomatoid

**Core tip:** Sarcomatoid transitional cell carcinoma is an invasive and rare subtype of urothelial tumors. The symptoms are often the same as other renal masses; however, in this case, sepsis and pyonephrosis were

the rare initial symptoms.

Fernández-Pello S, Venta V, González I, Gil R, Menéndez CL. Pyonephrosis as a sign of sarcomatoid carcinoma of the renal pelvis. *World J Clin Cases* 2014; 2(6): 215-218 Available from: URL: <http://www.wjgnet.com/2307-8960/full/v2/i6/215.htm>  
DOI: <http://dx.doi.org/10.12998/wjcc.v2.i6.215>

### INTRODUCTION

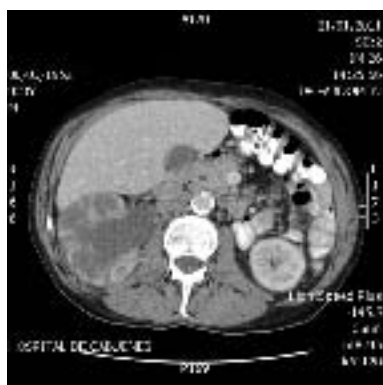
Primary tumors of the renal pelvis account for approximately 7% of all renal tumors<sup>[1]</sup>; most of them are urothelial carcinoma. Urothelium can display a wide range of metaplastic changes and neoplasms arising from this epithelium can show several types of differentiation, especially in high-grade neoplasms. Unlike bladder urothelial carcinomas, the majority of primary urothelial carcinomas of the renal pelvis present with a high histological grade and show a tendency to display unusual morphological features with a metaplastic phenomena and aggressive behavior. Due to their location inside the kidney, a delay in diagnosis may happen with advanced stages, metastatic disease or massive infiltration of the kidney<sup>[2,3]</sup>. The sarcomatoid subtype is a kind of high grade urothelial carcinoma, a histological variant defined by a biphasic differentiation, epithelial and mesenchymal. Few cases have been reported in the literature since 1961 when Fauci and colleagues reported the first case<sup>[4]</sup>.

### CASE REPORT

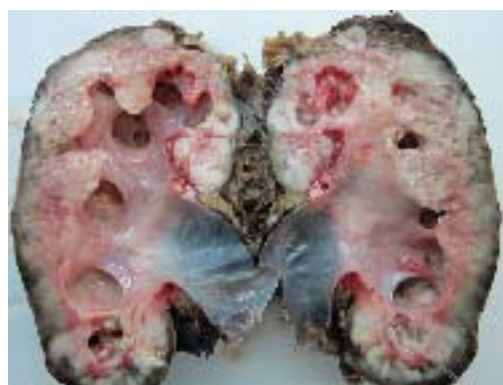We present a 58-year-old man assessed for a general syndrome and isolated episode of hematuria a few months previously.

His medical history included being a heavy smoker and alcohol consumer, deep venous thrombosis and alcoholic chronic pancreatitis with partial pancreatectomy 10 years previously.





**Figure 1** Contrast enhanced abdominal computed tomography shows a dilated and unstructured right kidney. No mass effect images.



**Figure 2** Macroscopic sagittal cut of the right kidney after nephrectomy, necrotic areas spread outside kidney and parenchyma is replaced by fibrotic tissue.

From the urological point of view, an isolated episode of gross hematuria was described and was concomitant with a high dosage of oral anticoagulants. At this time, ultrasound and cystoscopy were within the normal limits.

In hospital, he was afebrile with low levels of blood pressure. His blood analysis showed anemia (hemoglobin 8.6 g/dL), discrete leukocytosis and serum creatinine within normal limits.

An abdominal computed tomography (CT) was requested which described a bizarre right kidney with intraparenchymatous levels of liquid with the renal pelvis and right ureter dilated up to the entrance of the bladder (Figure 1).

Initially, endovenous third generation cephalosporin treatment was administered and a ureteral stent was placed. After 12 h of observation, the clinical course worsened, with severe hypotension and elevated blood analysis parameters of lactic acid, C protein and procalcitonin. In this critical situation of septic shock, an emergency right nephrectomy was performed with an eleventh rib incision. The intraoperative description was of a dilated right kidney with plentiful purulent liquid linked with a pyonephrosis with no apparent cause. The patient had a normal postoperative course and was discharged on the seventh day.

The surgery specimen weighed 500 g and the volume was 15 cm × 9 cm × 7 cm, with thick parenchyma with pyelocalyceal dilation with purulent content at the sagittal section. Necrotic areas spread outside the renal tissue, the perinephric fatty tissue (Figure 2).

The pathology report described a sarcomatoid urothelial carcinoma with invasion into the parenchyma, renal sinus, perinephric fatty, lymphovascular and neural tissue. Carcinoma *in situ* was also associated with the upper calyceal system according to the American joint committee of cancer (AJCC), seventh edition, pT4NX. Immunohistochemistry studies revealed positivity to CK7, CD10 and vimentin. Moreover, the report described intense proliferative activity Ki67, 80% (Figure 3).

Chemotherapy was rejected due to the clinical situation of the patient and the patient refused a new surgical intervention in order to eliminate the ureteral remnant. The patient was followed up periodically and 18 mo after

nephrectomy he was asymptomatic with no signs of relapse on imaging techniques.

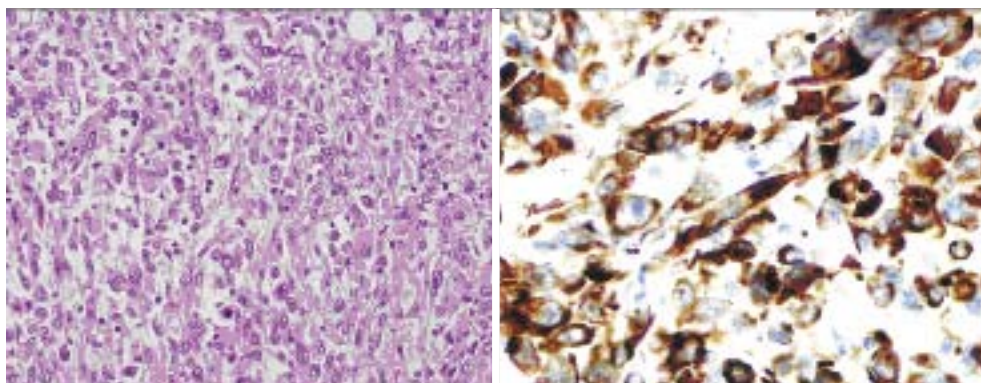
## DISCUSSION

Transitional cell carcinoma of the renal pelvis and ureter are relatively rare and are less than 1% of all genitourinary cancers, likewise 5% and 7% of urinary tract tumors<sup>[5]</sup>. Tumors arising from the renal pelvis are morphologically similar to those from the bladder. Their incidence varies from 0.7 to 1.1 per 100000 with a male to female ratio of 1.7 to 1, but with an increasing trend in women. They more frequently appear in the elderly (mean age 70 years). Over 90% of tumors arising from the renal pelvis and ureter are urothelial carcinomas. Hematuria and back pain are the most common signs and symptoms<sup>[6]</sup>. Hematuria, either gross or microscopic, is present in 75%-90% of cases. Back pain occurs in 20%-40% of cases, usually secondary to obstruction by the tumor that can mimic a ureteral calculus. Urinary symptoms, such as dysuria, urinary frequency, nocturia or urinary retention, can be found in up to 25%-50% of patients. The physical examination is usually normal, with the exception of a lumbar palpable mass in less than 10% of patients<sup>[5]</sup>.

Sarcomatoid transitional cell carcinoma (sarcomatoid carcinoma) of the renal pelvis should not be confused with sarcomatoid renal cell carcinoma, an undifferentiated high grade epithelial tumor whose origin is at the parenchyma. Another tumor with a bad prognosis is the collecting duct carcinoma (Bellini duct carcinoma) which is centered in the medulla, develops a tubulopapillary architecture and is surrounded by a desmoplastic reaction<sup>[7]</sup>. Radiologically, some researchers reported that sarcomatoid carcinomas and renal cell carcinomas are indistinguishable from each other.

The term “transitional cell carcinoma with sarcomatoid differentiation” should be used in solid tumors with biphasic epithelial and mesenchymal differentiation (with the presence or absence of heterologous components).

Another neoplasm considered at the differential diagnosis is carcinosarcoma. Carcinosarcomas and sarcoma-



**Figure 3** On the left side the sample (x 20) shows the invasive sarcomatoid pattern and on the right side the immunochemistry (x 40) positivity for CK7.

moid carcinomas are difficult to distinguish in hematoxylin-eosin samples. Carcinosarcomas are composed of two components, epithelial and sarcomatous, and sarcomatoid carcinomas are malignant epithelial tumors which show sarcomatoid changes<sup>[8]</sup>. There is too much confusion and disagreement in the literature regarding the nomenclature and histogenesis of these tumors. In some series, both terms, carcinosarcoma and sarcomatoid carcinoma, are included under the term “sarcomatoid carcinoma” and in others they are listed as two different entities<sup>[3,4,9,10]</sup>.

In addition, the differential diagnosis should also include locally aggressive and benign conditions, such as postoperative spindle cell nodes and pseudotumors as inflammatory myofibroblastic tumors.

Histologically, sarcomatoid areas may be combined with foci of transitional cell carcinoma, squamous cell carcinoma, adenocarcinoma or small cell carcinoma. Heterologous differentiation may be present but has no prognostic significance. All sarcomatoid carcinomas are high-grade and have a poor prognosis. These tumors show no difference in survival when compared stage by stage with conventional urothelial carcinoma. In the absence of invasive urothelial carcinoma or obvious epithelial differentiation, a prior history of urothelial carcinoma, the coexistence of urothelial carcinoma *in situ*, or immunoreactivity for cytokeratin or epithelial membrane antigen (EMA) in the sarcomatous areas are useful for the diagnosis of sarcomatoid carcinoma. The immunohistochemistry is the key to the diagnosis.

The immunoreactivity for keratins and EMA are specific for epithelial cells and the presence of epithelial markers in mesenchymal areas and/or the presence in sarcomatoid elements of ultrastructural features of epithelial differentiation (desmosomes or tonofilaments) suggest the diagnoses of sarcomatoid carcinoma. Likewise, the mesenchymal elements in carcinosarcomas do not stain with epithelial markers and have no desmosomes or tonofilaments<sup>[3]</sup>.

The gold standard treatment for urothelial carcinoma is surgery, in this case nephroureterectomy, but a nephrectomy was only performed because the presence of an aggressive tumour was unsuspected. Neoadjuvant chemotherapy was not an option for this patient. On the one hand, it was an emergency operation and on the

other hand, contrary to what has been demonstrated for bladder cancer, there have been no reported effects of neoadjuvant therapy for upper urinary tract cancer<sup>[11]</sup>.

Adjuvant chemotherapy can somehow achieve a recurrence free rate of up to 50% but clearly has no impact on survival and no data are currently available to provide any recommendations<sup>[12]</sup>. At our institution, chemotherapy is only considered as palliative in cases of metastatic evolution or with the presence of symptoms.

Adjuvant radiotherapy may improve local control of the disease and can be combined with a cisplatin regimen<sup>[13]</sup> but they are no longer considered at our center as a standard care for this kind of tumors.

This pT4Nx tumor is included in the IV stage according to AJCC classification (remember IV stage includes all pT4 with N+ or N0 and M+ or M0), the fact of pT4 being directly included in IV prognostic stage in spite of no pathological node report and no signs of metastatic disease. The observed overall survival with this classification with data taken from National Cancer Data Base for the year 2000 to 2002 is: 43.3% in 1 year, 24% in 2 years, 16.4% in 3 years, 12.4% in 4 years and 10.2% in 5 years.

An interesting paper describes the local relapse rate during a mean follow-up of 58 mo in 14% of the patients, with the overall mortality of 14% and the mean survival of 109 mo. Stage T3 and T4 were significantly linked with survival<sup>[14]</sup>.

We report the case of a 58-year-old man with the radiological finding of pyonephrosis and an emergency nephrectomy being performed with the worsening of the clinical condition. The pathology examination suggested a renal pelvis urothelial neoplasm with sarcomatoid differentiation. This neoplasm widely spread through perirenal fatty tissue and lymphatic vascular tissue.

Sarcomatoid subtype is a rare presentation of urothelial carcinoma and is linked with a bad prognosis. In the same sample, zones of epithelial carcinoma, adenocarcinoma and small cell carcinoma are usually described.

## COMMENTS

### Case characteristics

A 58-year-old man assessed for a general syndrome and isolated episode of hematuria.

### Clinical diagnosis

The radiological finding of pyonephrosis and worsening of the clinical condition, with an emergency nephrectomy being performed.

### Differential diagnosis

Ultrasound, cystoscopy, computed tomography (CT).

### Laboratory diagnosis

Blood analysis showed anemia (hemoglobin 8.6 g/dL). The surgery specimen weighed 500 g and volume was 15 cm × 9 cm × 7 cm, with thick parenchyma with pyelocalyceal dilation with purulent content at the sagittal section.

### Imaging diagnosis

An abdominal CT was requested and described a bizarre right kidney with intra-parenchymatous levels of liquid, with the renal pelvis and right ureter dilated up to the entrance of the bladder.

### Pathological diagnosis

The pathology report described a sarcomatoid urothelial carcinoma with invasion into the parenchyma, renal sinus, perinephric fatty, lymphovascular and neural tissue.

### Treatment

The clinical evolution with an emergency nephrectomy.

### Experiences and lessons

Sarcomatoid subtype is a rare presentation of urothelial carcinoma and is linked with a bad prognosis. In the same sample, zones of epithelial carcinoma, adenocarcinoma and small cell carcinoma are usually described.

### Peer review

The authors describe a case of pyonephrosis as a sign of sarcomatoid carcinoma of the renal pelvis. This is an interesting paper.

## REFERENCES

- 1 **Droller MJ**. Transitional Cell Carcinoma: upper tracts and bladder. In: Walsh PC, Gittes RF, Perlmutter AD, Stamey TA (eds). *Campbells Urology*. WB Saunders: Philadelphia, 1986: 1343-1440
- 2 **Perez-Montiel D**, Wakely PE, Hes O, Michal M, Suster S. High-grade urothelial carcinoma of the renal pelvis: clinicopathologic study of 108 cases with emphasis on unusual morphologic variants. *Mod Pathol* 2006; **19**: 494-503 [PMID: 16474378 DOI: 10.1038/modpathol.3800559]
- 3 **Lopez-Beltran A**, Pacelli A, Rothenberg HJ, Wollan PC, Zincke H, Blute ML, Bostwick DG. Carcinosarcoma and sarcomatoid carcinoma of the bladder: clinicopathological study of 41 cases. *J Urol* 1998; **159**: 1497-1503 [PMID: 9554341 DOI: 10.1097/00005392-199805000-00023]
- 4 **Lopez-Beltran A**, Escudero AL, Cavazzana AO, Spagnoli LG, Vicioso-Recio L. Sarcomatoid transitional cell carcinoma of the renal pelvis. A report of five cases with clinical, pathological, immunohistochemical and DNA ploidy analysis. *Pathol Res Pract* 1996; **192**: 1218-1224 [PMID: 9182292 DOI: 10.1016/S0344-0338(96)80154-3]
- 5 **Ozsahin M**, Ugurluer G, Zouhair A. Management of transitional-cell carcinoma of the renal pelvis and ureter. *Swiss Med Wkly* 2009; **139**: 353-356 [PMID: 19562529]
- 6 **Lopez-Beltran A**, Montironi R, Vidal-Jimenez A, Cheng L. Pathology of tumors of the renal pelvis and ureter, and the urethra. In: Mikuz G (ed). *Clinical Pathology of Urologic Tumors*. London: Informa Healthcare, 2007: 235-242 [DOI: 10.3109/9780203089835-38]
- 7 **Skinnider BF**, Folpe AL, Hennigar RA, Lim SD, Cohen C, Tamboli P, Young A, de Peralta-Venturina M, Amin MB. Distribution of cytokeratins and vimentin in adult renal neoplasms and normal renal tissue: potential utility of a cytokeratin antibody panel in the differential diagnosis of renal tumors. *Am J Surg Pathol* 2005; **29**: 747-754 [PMID: 15897741 DOI: 10.1097/01.pas.0000163362.78475.63]
- 8 **Yilmaz E**, Birlik B, Arican Z, Guney S. Carcinosarcoma of the renal pelvis and urinary bladder: a case report. *Korean J Radiol* 2003; **4**: 255-259 [PMID: 14726644 DOI: 10.3348/kjr.2003.4.4.255]
- 9 **Lopez-Beltran A**, Sauter G, Gasser T, Hartmann A. Urothelial tumors: infiltrating urothelial carcinoma. In: Eble JN, Sauter G, Epstein JI, Sesterhenn I (eds). *World Health Organization Classification of Tumors: Pathology and Genetics of Tumors of the Urinary System and Male Genital Organs*. Lyon: IARC Press, 2004
- 10 **Lopez-Beltran A**, Cheng L. Histologic variants of urothelial carcinoma: differential diagnosis and clinical implications. *Hum Pathol* 2006; **37**: 1371-1388 [PMID: 16949919 DOI: 10.1016/j.humpath.2006.05.009]
- 11 **Matin SF**, Margulis V, Kamat A, Wood CG, Grossman HB, Brown GA, Dinney CP, Millikan R, Siefker-Radtke AO. Incidence of downstaging and complete remission after neoadjuvant chemotherapy for high-risk upper tract transitional cell carcinoma. *Cancer* 2010; **116**: 3127-3134 [PMID: 20564621 DOI: 10.1002/cncr.25050]
- 12 **Vassilakopoulou M**, de la Motte Rouge T, Colin P, Ouzzane A, Khayat D, Dimopoulos MA, Papadimitriou CA, Bamias A, Pignot G, Nouhaud FX, Hurel S, Guy L, Bigot P, Roumiguié M, Rouprêt M. Outcomes after adjuvant chemotherapy in the treatment of high-risk urothelial carcinoma of the upper urinary tract (UUT-UC): results from a large multicenter collaborative study. *Cancer* 2011; **117**: 5500-5508 [PMID: 21638278 DOI: 10.1002/cncr.26172]
- 13 **Hall MC**, Womack JS, Roehrborn CG, Carmody T, Sagarowsky AI. Advanced transitional cell carcinoma of the upper urinary tract: patterns of failure, survival and impact of postoperative adjuvant radiotherapy. *J Urol* 1998; **160**: 703-706 [PMID: 9720526]
- 14 **Papatsoris AG**, Chrisofos M, Skolarikos A, Varkarakis I, Lekas A, Dellis A, Koritsiadis S, Deliveliotis C. Upper urinary tract transitional cell carcinoma. A 10-year experience. *Tumori* 2008; **94**: 75-78 [PMID: 18468339]

**P- Reviewers:** Ansari MS, Di Lorenzo G, Maurer T, Papatsoris AG

**S- Editor:** Ma YJ **L- Editor:** Roemmele A

**E- Editor:** Wu HL





## Two-level reconstruction of isolated fracture of the lesser tuberosity of the humerus

Vasileios S Nikolaou, Dimitrios Chytas, Evangelos Tyrpenou, George C Babis

Vasileios S Nikolaou, Dimitrios Chytas, Evangelos Tyrpenou, George C Babis, 2<sup>nd</sup> Orthopaedic Department, Athens University, 15124 Athens, Greece

Author contributions: Nikolaou VS performed the surgery and wrote the manuscript; Chytas D and Tyrpenou E did the literature search and prepared the first draft; Babis GC did the final checking and proof editing of the manuscript.

Correspondence to: Vasileios S Nikolaou, MD, PhD, Orthopaedic Surgeon, Lecturer in Orthopaedics, 2<sup>nd</sup> Orthopaedic Department, Athens University, 21 Dimitriou Ralli Str, Maroussi, 15124 Athens, Greece. [vassilios.nikolaou@gmail.com](mailto:vassilios.nikolaou@gmail.com)

Telephone: +30-6932-543400 Fax: +30-210-8022142

Received: December 29, 2013 Revised: April 17, 2014

Accepted: May 14, 2014

Published online: June 16, 2014

the humerus in adults are extremely rare. Only a few cases have been reported so far in the literature. The optimal treatment method of these fractures is still a matter of debate. Herein, we present a case of a 39-year-old man with an isolated lesser tuberosity fracture who was treated surgically in our institution. Due to fracture comminution, a two-level reconstruction technique with headless screws and buttress plate was applied. As far as we know, this method of fixation of this type of fracture has not been previously described in the literature.

Nikolaou VS, Chytas D, Tyrpenou E, Babis GC. Two-level reconstruction of isolated fracture of the lesser tuberosity of the humerus. *World J Clin Cases* 2014; 2(6): 219-223 Available from: URL: <http://www.wjgnet.com/2307-8960/full/v2/i6/219.htm> DOI: <http://dx.doi.org/10.12998/wjcc.v2.i6.219>

### Abstract

Fractures of the lesser tuberosity of the humerus are typically met in combination with other injuries of the shoulder. Case reports of isolated lesser tuberosity fractures are particularly rare and, consequently, therapeutic protocols have not yet been completely clarified. Conservative as well as surgical treatment has been recommended, while several operative techniques have been applied. We present a case of a 39-year-old man with an isolated lesser tuberosity fracture who was treated surgically in our institution. Due to fracture comminution, a two-level reconstruction technique with headless screws and buttress plate was applied. As far as we know, this method of fixation of this type of fracture has not been previously described in the literature. The patient tolerated the procedure well and excellent results were obtained at the latest follow-up.

© 2014 Baishideng Publishing Group Inc. All rights reserved.

**Key words:** Shoulder; Humerus; Lesser tuberosity; Fixation; Technique; Two-level reconstruction

**Core tip:** Isolated fractures of the lesser tuberosity of

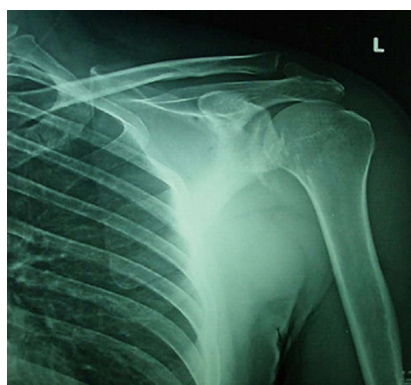### INTRODUCTION

Five percent of all humeral fractures involve the proximal end alone<sup>[1,2]</sup>. Out of this, only 2% account for isolated lesser tuberosity fractures, making the incidence extremely rare. More often, they are seen as an isolated injury or with a combined posterior dislocation of the shoulder<sup>[3]</sup>. Moreover, these fractures may be difficult to identify because of the osseous overlapping in the standard x-ray examination or they are misdiagnosed as intra-articular loose bodies or calcifications of the rotator cuff<sup>[4]</sup>.

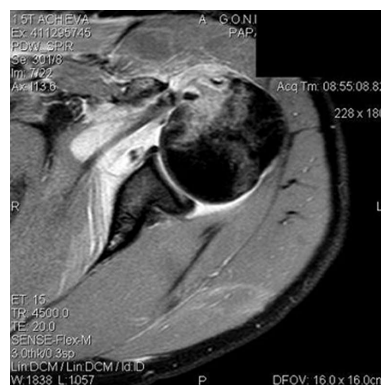The injury typically requires traumatic abduction and external rotation of the upper arm in relation to the shoulder. The forceful contraction of the subscapularis muscle leads to the avulsion fracture of the lesser tuberosity.

Epidemiologically, little is known but it has been described as an injury that involves male patients between the 2<sup>nd</sup> and 5<sup>th</sup> decades of life and youngsters with an open humeral physis. If not treated or missed, these injuries may lead to subscapularis weakness and/or impingement.

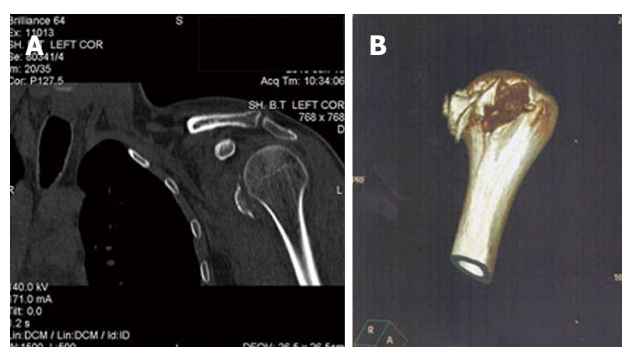




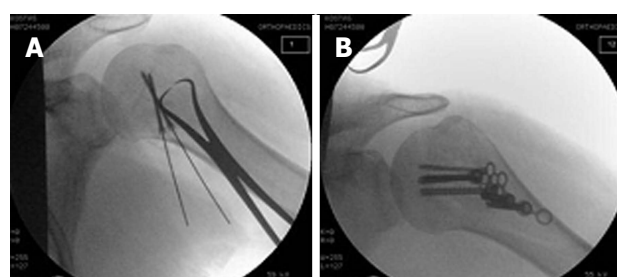
**Figure 1** Anteroposterior radiograph of left shoulder showing a crescent-shaped fragment near the inferior part of the glenoid rim.



**Figure 3** Magnetic resonance imaging exam of the left shoulder excluded intra-articular extension of the fracture or other tendon ruptures.



**Figure 2** Further examination with computed tomography scan (A) and 3D computed tomography reconstruction (B) confirmed the diagnosis and revealed the comminution of the lesser tuberosity avulsion fracture.



**Figure 4** Intra-operative fluoroscopic images. Initially, the bigger fragments of the lesser tuberosity were reduced using reduction forceps and fixed using cannulated headless Hebert screws (A). The smaller fragments were then reduced and stabilized under a low profile, bendable neutralization buttress plate (B).

ment of the malunited part<sup>[5,6]</sup>.

Generally, open reduction and internal fixation is the treatment of choice in otherwise medically fit patients but some authors suggest conservative treatment for minimally displaced fractures and report clinically successful results<sup>[7,8]</sup>.

Operative procedures can be challenging in cases of comminuted fractures of the lesser tuberosity. We present a case of a comminuted isolated avulsion fracture of the lesser tuberosity of the humerus in a young male patient. A two-level reconstruction technique is described.

## CASE REPORT

A 39-year-old male presented to our emergency department with a history of a fall from a height of about 2 m on to his outstretched left arm. On clinical examination, there was tenderness on palpation on the frontal aspect of the proximal humerus and restriction of movements of the joint, energetically and passively. No neurovascular damage was noted.

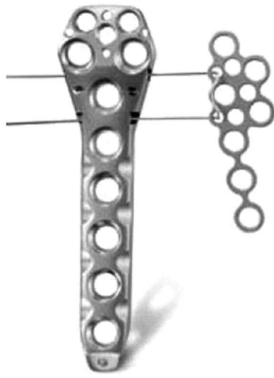
Standard anteroposterior radiograph revealed a crescent-shaped fragment near the inferior part of the glenoid rim. At that point, lateral X-ray was not possible due to patient's pain (Figure 1).

The patient was admitted to our orthopedic department and a computed tomography (CT) scan was per-

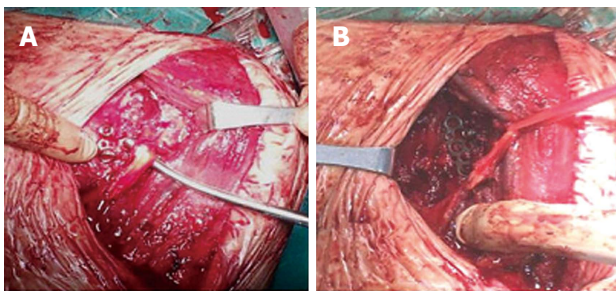
formed to describe the damage in greater detail (Figure 2). A magnetic resonance imaging (MRI) scan was also performed to exclude possible intra-articular damage and/or tendon pathology (Figure 3).

The isolated comminuted avulsion fracture of the lesser tuberosity was confirmed, with no other intra-articular pathology of the shoulder joint. It was decided to operate and the patient was transferred to the operating room 48 h after the injury.

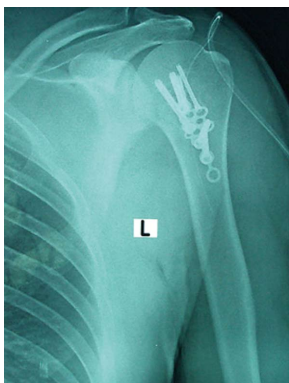
Under general anesthesia and with the patient supine in the so-called beach chair position, with the image intensifier placed on the opposite side of the operating table, a standard deltopectoral approach was used. Fragments of the avulsed lesser tuberosity with the subscapularis tendon were identified. The fracture did not extend to the articular surface or the bicipital groove. Initially, the larger fragment of the avulsed lesser tuberosity was reduced using reduction forceps. Two cannulated Herbert screws were used to stabilize the fragment (Figure 4). The smaller fragments were then reduced and stabilized using a low profile, bendable neutralization buttress plate (T-plate, NCB proximal humerus, Zimmer Company, Winterthur, Switzerland) (Figure 5). The long head of the biceps tendon was identified and found to be stable (Figure 6). Excellent fracture reduction was confirmed with intraoperative fluoroscopy (Figure 4). A drain was positioned and the wound was closed in the usual fashion. Figure 7 shows the immediate post-operative X-ray.



**Figure 5** The 7-holes T-minus plate (right) that was used as a buttress plate is part of the Non-Contact Bridging proximal humerus, polyaxial locking plate system (Zimmer Company, Winterthur, Switzerland).



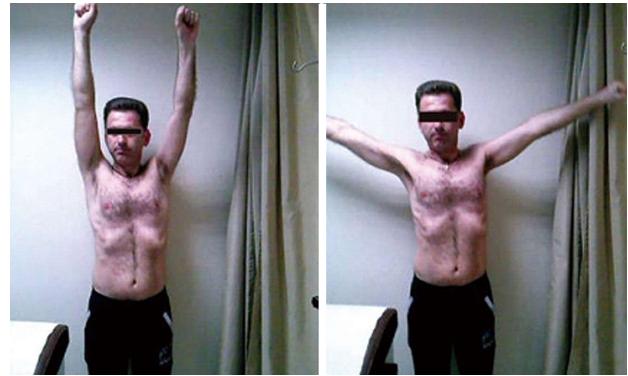**Figure 6** Intraoperative photos. A: The headless Herbert screw is inserted and the larger fragments have been stabilized; B: The T-minus plate has been positioned acting as a buttress plate. The biceps tendon was found to be stable and was protected during the procedure.



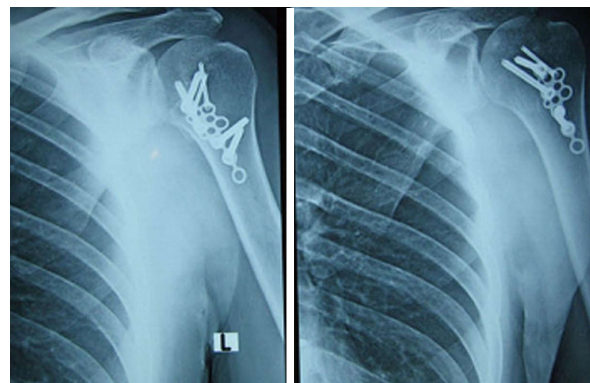
**Figure 7** Immediate post-op X-ray of the left shoulder, showing excellent fracture reduction.

The arm was placed in a sling in a neutral position and the elbow flexed 90 degrees. The patient was released from the hospital 2 d post-operatively. Immediately after stitches removal, the patient initiated his rehabilitation program, with passive assisted exercises to regain full range of motion. Six weeks post-operatively, active exercises were implicated.

On follow-up, the patient had achieved painless full range of motion and regained his normal activities. X-ray examination at the latest follow-up, 18 mo after surgery, revealed full union of the fracture and no hardware fail-



**Figure 8** At the latest follow-up, the patient demonstrated pain-free, full range of movement of the left shoulder.



**Figure 9** Eighteen months after surgery, X-ray examination of the left shoulder shows full union of fracture without hardware movement or failure.

ure (Figures 8 and 9).

## DISCUSSION

Approximately 2% of proximal humeral fractures are isolated fractures of the lesser tuberosity<sup>[9]</sup>. This demonstrates how rarely those injuries are met. Until now, the lack of an extensive published case series does not allow the determination of a standard therapeutic protocol for this type of fracture. The small sized lesser tuberosity, which is adequately protected in the medial aspect of the proximal humerus, is not frequently fractured and, when this happens, sudden contraction of the subscapularis muscle, which is attached to the tuberosity and prevents the abduction and external rotation of the shoulder, is the most common mechanism of injury<sup>[6]</sup>. The clinical presentation of the patient, characterized by pain particularly in the frontal aspect of the shoulder and restricted motion, is not typical and requires proper radiographic control, which generally includes at least two views of the shoulder. Although in our case the fracture can be noted in the anteroposterior view of the shoulder, often the diagnosis is missed or delayed due to the lack of a complete imaging. An axillary view especially generally demonstrates lesser tuberosity fractures most clearly and possibly displaced fragments<sup>[10]</sup>. However, on plain radiographs, these fractures may be misdiagnosed as calcific tendonitis

of the rotator cuff or osseous Bankart lesions<sup>[8]</sup>.

Thus, the usefulness of a CT scan in the diagnosis and treatment of this type of fracture, including the surgical technique for its fixation, is particularly important<sup>[2]</sup>. More specifically, a CT scan is a valuable tool in the hands of the surgeon for the estimation of specific characteristics of the fracture, such as displacement, comminution and possible involvement of the articular surface<sup>[2]</sup>. Further investigation with MRI can also help in determining possible severe soft tissue damage, including rotator cuff tendon injury, or severe trauma of the articular surface.

Once the diagnosis is made, several therapeutic options have been proposed. Conservative treatment, although not frequently indicated, has its own remarkable position in the therapeutic “arsenal”, particularly in minimally displaced fractures<sup>[10]</sup> and in children<sup>[11,12]</sup>. However, controversy exists about the displacement of fracture as an indication of surgery; some authors recommend open reduction and internal fixation of even minimally displaced fractures in order to avoid late displacement and involvement of the bicipital groove<sup>[7]</sup>. Generally, operative treatment is recommended in cases of displacement more than 5 mm, angulation more than 45 degrees, persistent pain, blockage to motion and significant clinical weakness<sup>[5]</sup>.

Regardless of the size or displacement of the fractured fragments, a review of the literature demonstrates that open reduction and internal fixation is the gold standard of the management of isolated lesser tuberosity fractures. Apart from open reduction and internal fixation, other methods of surgical treatment do exist and have generally given satisfactory results; surgical excision of the fractured fragment<sup>[13-15]</sup> and arthroscopically assisted reduction<sup>[16]</sup> have been proposed by several authors and have been proven efficient.

The common technique of open reduction and internal fixation of isolated lesser tuberosity fractures described in the literature includes the use of screws, cerclage wire<sup>[6]</sup> and, particularly in skeletally immature patients, the use of heavy sutures and suture anchors<sup>[5]</sup>.

In conclusion, as far as we know, a two-level reconstruction of this type of fracture with headless screws and a buttress plate has not been previously described. The fact that led us to this surgical option was the comminution of the fracture and subsequent inability of adequate fixation with screws only. The larger fragments of the fracture were successfully fixed with headless Herbert screws. The smaller fragments were buttressed using a low profile, multi-hole plate. This plate also provided a more secure fixation of the larger fragments. As was proven, the clinical outcome was satisfactory and comparable with other cases in which different surgical methods were applied.

## COMMENTS

### Case characteristics

Isolated fracture of the lesser tuberosity of the humerus in a young adult male.

### Clinical diagnosis

There was tenderness on palpation on the frontal aspect of the proximal humerus and restriction of movements of the joint, energetically and passively. No neurovascular damage was noted.

### Differential diagnosis

Shoulder fracture dislocation, rotator cuff pathology and/or osseous Bankart lesion were considered in the differential diagnosis based on patient's symptoms. X-ray examination, computed tomography (CT) scan with 3D reconstruction and magnetic resonance imaging (MRI) of the injured shoulder were carried out.

### Imaging diagnosis

Standard anteroposterior radiograph revealed a crescent-shaped fragment near the inferior part of the glenoid rim. Further examination with CT scan and 3D CT reconstruction confirmed the diagnosis and revealed the comminution of the lesser tuberosity avulsion fracture. MRI exam of the left shoulder excluded intra-articular extension of the fracture or other tendon ruptures.

### Treatment

Due to fracture comminution, a two-level reconstruction technique with headless screws and buttress plate was applied.

### Experiences and lessons

Isolated fractures of the lesser tuberosity of the humerus are extremely rare in adults. Open reduction and internal fixation is usually the treatment of choice. In the setting of severe fragment comminution, adequate stabilization of the fractured lesser tuberosity can be challenging. Using the proposed operative technique, with two-level reconstruction of the lesser tuberosity, resulted in excellent fracture healing and the clinical outcome was satisfactory and comparable with other cases in which different surgical methods were applied.

### Peer review

This is a well written case report describing a new surgical approach. It will be of general interest to orthopedic surgeons.

## REFERENCES

- 1 **Palvanen M**, Kannus P, Niemi S, Parkkari J. Update in the epidemiology of proximal humeral fractures. *Clin Orthop Relat Res* 2006; **442**: 87-92 [PMID: 16394745]
- 2 **Kristiansen B**, Barfod G, Bredesen J, Erin-Madsen J, Grum B, Horsnaes MW, Aalberg JR. Epidemiology of proximal humeral fractures. *Acta Orthop Scand* 1987; **58**: 75-77 [PMID: 3577743]
- 3 **Robinson CM**, Teoh KH, Baker A, Bell L. Fractures of the lesser tuberosity of the humerus. *J Bone Joint Surg Am* 2009; **91**: 512-520 [PMID: 19255210 DOI: 10.2106/JBJS.H.00409]
- 4 **Chun JM**, Groh GI, Rockwood CA. Two-part fractures of the proximal humerus. *J Shoulder Elbow Surg* 1994; **3**: 273-287 [PMID: 22959788 DOI: 10.1016/S1058-2746(09)80071-2]
- 5 **Levine B**, Pereira D, Rosen J. Avulsion fractures of the lesser tuberosity of the humerus in adolescents: review of the literature and case report. *J Orthop Trauma* 2005; **19**: 349-352 [PMID: 15891546]
- 6 **Ogawa K**, Takahashi M. Long-term outcome of isolated lesser tuberosity fractures of the humerus. *J Trauma* 1997; **42**: 955-959 [PMID: 9191680]
- 7 **Sugalski MT**, Hyman JE, Ahmad CS. Avulsion fracture of the lesser tuberosity in an adolescent baseball pitcher: a case report. *Am J Sports Med* 2004; **32**: 793-796 [PMID: 15090399 DOI: 10.1177/0095399703258620]
- 8 **van Laarhoven HA**, te Slaa RL, van Laarhoven EW. Isolated avulsion fracture of the lesser tuberosity of the humerus. *J Trauma* 1995; **39**: 997-999 [PMID: 7474023]
- 9 **Gruson KI**, Ruchelsman DE, Tejwani NC. Isolated tuberosity fractures of the proximal humeral: current concepts. *Injury* 2008; **39**: 284-298 [PMID: 18243203 DOI: 10.1016/j.injury.2007.09.022]
- 10 **Tosun B**, Kesemenli CC. Isolated avulsion fracture of lesser tuberosity of the humerus: Review of the literature and report of two cases. *Int J Shoulder Surg* 2011; **5**: 50-53 [PMID: 21897585 DOI: 10.4103/0973-6042.83198]
- 11 **Ross GJ**, Love MB. Isolated avulsion fracture of the lesser



- tuberosity of the humerus: report of two cases. *Radiology* 1989; **172**: 833-834 [PMID: 2772197 DOI: 10.1148/radiology.172.3.2772197]
- 12 **Shibuya S**, Ogawa K. Isolated avulsion fracture of the lesser tuberosity of the humerus. A case report. *Clin Orthop Relat Res* 1986; **(211)**: 215-218 [PMID: 3769259]
  - 13 **Kunkel SS**, Monesmith EA. Isolated avulsion fracture of the lesser tuberosity of the humerus: A case report. *J Shoulder Elbow Surg* 1993; **2**: 43-46 [PMID: 22959297 DOI: 10.1016/S1058-2746(09)80137-7]
  - 14 **Berbig R**, Keller H, Metzger U. Isolated fracture of the lesser tuberosity of the humerus: case reports and review of the literature. *Z Unfallchir Versicherungsmed* 1994; **87**: 159-168 [PMID: 7986638]
  - 15 **LaBriola JH**, Mohaghegh HA. Isolated avulsion fracture of the lesser tuberosity of the humerus. A case report and review of the literature. *J Bone Joint Surg Am* 1975; **57**: 1011 [PMID: 1184633]
  - 16 **Scheibel M**, Martinek V, Imhoff AB. Arthroscopic reconstruction of an isolated avulsion fracture of the lesser tuberosity. *Arthroscopy* 2005; **21**: 487-494 [PMID: 15800530 DOI: 10.1016/j.arthro.2004.11.012]

**P- Reviewers:** Naugler C, Serhan H, Solomon LB

**S- Editor:** Song XX **L- Editor:** Roemmele A **E- Editor:** Wu HL





## Simultaneous bilateral robotic partial nephrectomy: Case report and critical evaluation of the technique

Claudio Giberti, Fabrizio Gallo, Maurizio Schenone, Pierluigi Cortese

Claudio Giberti, Fabrizio Gallo, Maurizio Schenone, Pierluigi Cortese, Department of Urology, San Paolo Hospital, 17100 Savona, Italy

**Author contributions:** Giberti C, Gallo F and Schenone M planned and performed the surgical procedure; Cortese P provided the figures; Gallo F wrote the manuscript; all the authors were involved in editing the manuscript and had read, revised and approved the final draft.

**Correspondence to:** Fabrizio Gallo MD, Department of Urology, San Paolo Hospital, Via Genova, 30, 17100 Savona, Italy. [fabrizio.gallo@fastwebmail.it](mailto:fabrizio.gallo@fastwebmail.it)

Telephone: +39-34-79043036 Fax: +39-19-8404447

Received: December 31, 2013 Revised: February 14, 2014

Accepted: April 17, 2014

Published online: June 16, 2014

### Abstract

We report our first simultaneous bilateral robot assisted partial nephrectomy (RAPN) in order to show and critically discuss the feasibility of this procedure. **Materials and methods** A 69-year-old male patient visited our department due to incidental finding of bilateral mesorenal small masses (2.5 cm on the right and 3.5 cm on the left) suspicious for malignancy. We started from the right side with patient in flank position. Port placement: 12-mm periumbilical camera port, two 8-mm robotic ports in wide "V" configuration, additional 12 mm assistant port on the midline between the umbilicus and symphysis pubis. A right unclamping RAPN with sliding clip renorrhaphy was performed. The trocars were removed and the robot undocked. Without interrupting the anesthesiological procedures, the patient was reported in supine position and, after 180 degrees rotation of the surgical bed, was newly placed in contralateral flank position. Using both the previous periumbilical and midline ports, two other 8-mm robotic trocars were placed. The robot was then redocked and RAPN was also performed on the left side using the same previously reported technique. **Results** Total time: 285 min. Estimated blood losses: 150 cc. Postoperative

period: uneventful. Pathological examination: bilateral renal cell carcinoma, negative surgical margins. **Conclusions** Our experience was encouraging and confirmed the feasibility and safety of this procedure. The planning of our technique was time and cost effective with cosmetic benefit for the patient. However, we think that an appropriate selection of the patients and a skill in robotic renal surgery are advisable before approaching this type of surgery.

© 2014 Baishideng Publishing Group Co., Limited. All rights reserved.

**Key words:** Robotics; Nephrectomy; Renal cell carcinoma; Remote operation robotics

**Core tip:** Very few papers have been reported concerning simultaneous bilateral robot assisted partial nephrectomy. We think that our technique was noteworthy for some important aspects: the number of the ports was minimized, the disposition of the operator room allows the quick rotation of the patient's bed and the redocking of the robot, the operative time was acceptable, the unclamping technique decreased the risk of renal insufficiency, the cost for two nephrectomies was decreased. In conclusion, our technique was safe, feasible, time and cost effective with a cosmetic benefit for the patient.

Giberti C, Gallo F, Schenone M, Cortese P. Simultaneous bilateral robotic partial nephrectomy: Case report and critical evaluation of the technique. *World J Clin Cases* 2014; 2(6): 224-227 Available from: URL: <http://www.wjgnet.com/2307-8960/full/v2/i6/224.htm> DOI: <http://dx.doi.org/10.12998/wjcc.v2.i6.224>

### INTRODUCTION

In the last few years, robot-assisted partial nephrectomy (RAPN) has become a promising procedure able to

bridge the technical difficulties of laparoscopic partial nephrectomy (LPN), permitting a broader diffusion of laparoscopic treatment of renal masses<sup>[1-3]</sup>.

In fact, the 3D vision, the optical magnification and the robotic instruments allow surgeons to realize very precise tumor resection and to simplify the reconstructive steps of the procedure, minimizing the potential risks due to the ischemia time.

More recently, the expanded role of robot-assisted surgery has also included the simultaneous treatment of bilateral renal tumors<sup>[4,5]</sup>.

This type of procedure, which is certainly fascinating, still needs to be well defined regarding the indications and the technique. We report our first case of simultaneous bilateral robotic partial nephrectomy in order to show the feasibility of our technique and critically discuss both the advantages and the disadvantages of this procedure.

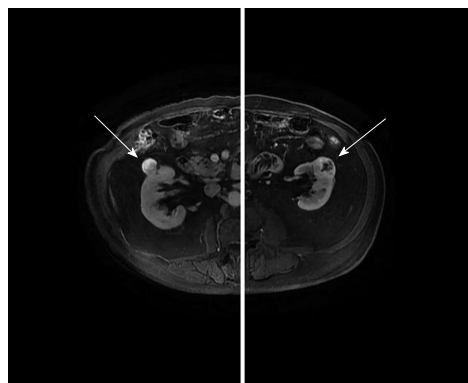
## CASE REPORT

### Patient

A 69-year-old male patient visited our department due to the incidental finding of bilateral small renal masses. Magnetic resonance scans showed a 2.5 cm mass in the middle portion of the right kidney and a 3.5 cm mass in the middle portion of the left kidney with no involvement of the collecting systems. The two masses were suspicious for malignancy (Figure 1). The differential diagnosis was made with benign tumors and complicated cysts. There was no past surgical history. General physical examination and the preoperative exams were normal. The body mass index (BMI) was 23.51.

### Surgical technique

The operating theatre was set up as shown in Figure 2. The procedure was performed using a three-arm Da Vinci Robot, standard version, starting from the right side. The patient was secured in a flank position with the table slightly bent. Regarding the port placement, a 12-mm periumbilical port was placed for the camera. Two 8-mm robotic instrument ports were placed approximately 8 cm from the camera in a wide “V” configuration centered on the renal tumor. An additional 12 mm assistant trocar was placed on the midline between the umbilicus and symphysis pubis (Figure 3). A 30° angle lens was used. The robotic instruments included bipolar fenestrated forceps, monopolar cautery scissors, and two needle drivers. The peritoneum was incised sharply along the line of Toldt and the bowel was mobilized medially exposing the Gerota’s fascia. The renal artery and vein were isolated and vessel loops were placed around them. The Gerota’s fascia was dissected off the surface of the kidney and the kidney was extensively mobilized until easy access to the tumor was achieved from all sides. The RAPN was then performed without hilar clamping. The renal specimen was retrieved using an endobag. The inner defect was closed with a running outside-in Monocryl 4-0 suture preloaded with a Hem-o-lok clip, taking care to include retracted vessels or calyces into the suture. The borders



**Figure 1** Magnetic resonance scans. The right and left small renal masses are indicated.

of the defect were closed with another running outside to inside Monocryl 2-0 suture including a haemostatic agent and secured with Hem-o-lok clips at each bite. Through the sliding clip technique, the right tension was brought on these sutures<sup>[6]</sup>.

The Gerota’s fascia and the peritoneum were closed. A wound drain was introduced through the inferior 8-mm port. All the trocars were removed and the robot was undocked.

Without interrupting the anesthesia, the patient was repositioned in the supine position and, after a 180 degree rotation of the surgical bed, he was placed in the contralateral flank position. Using both the previous periumbilical and midline ports for the camera and the additional 12-mm assistant trocar, respectively, the other 8-mm robotic trocars were placed in a wide “V” configuration centered on the left renal tumor (Figure 3). The robot was then redocked without changing any disposition of the instruments, the furniture or the staff inside the operating theatre.

A second RAPN without hilar clamping was also performed on the left side following the previously reported technique. Intraoperative ultrasonography was used on this side in order to score the margins of the lesion.

The total operation time was 285 min and total console time was 240 min. The estimated blood loss was 150 cc. The postoperative period was uneventful. The patient was mobilized on day 2. The urethral catheter was removed on day 2. The right and left drains were removed on days 2 and 3, respectively. The patient was discharged on day 4. The pathological examination reported bilateral renal cell carcinoma, Fuhrman grade 1, with negative surgical margins. Six months after surgery, computed tomography scan did not show tumor local recurrences.

## DISCUSSION

The robotic approach for conservative renal surgery is becoming increasingly common due to the reported encouraging outcomes in terms of safety, feasibility and efficacy of this procedure<sup>[1-3,7]</sup>. Very few papers have been reported in literature concerning simultaneous bilateral RAPNs probably due to the low incidence of bilateral re-

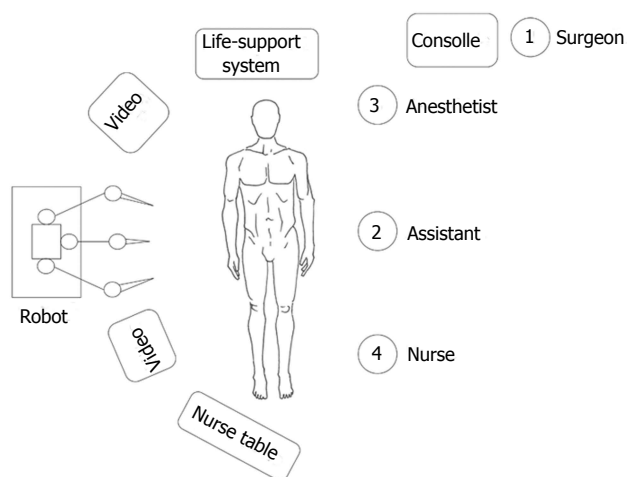


Figure 2 Disposition of the operating theatre.

nal tumors but also due to the difficulties of this type of surgery<sup>[4-5]</sup>. The potential benefits of simultaneous bilateral surgery could be related to the advantages of a unique surgical procedure with single anesthesia, shorter overall hospitalization, faster overall recovery and lower costs than two separate procedures. Furthermore, a cosmetic benefit due to the reuse of some ports for both sides could be considered. However, these advantages could be balanced by the risks of longer total anesthesia time, higher blood loss and postoperative renal insufficiency. In this setting, the procedure should be planned appropriately in order to maximize the benefits and minimize the risks. We think that our technique was noteworthy for some aspects.

The positioning of the ports was planned accurately in order to minimize the number of the abdominal incisions. In particular, the camera and the assistant ports were positioned on the xifopubic line and used for both sides. In the end, the bilateral RAPN was performed using only six ports.

The disposition of the operating theatre was studied in order to allow the rotation of the patient's bed without changing the positions of the robot, the instruments and the operators. This detail allowed us to undock and redock the robot very quickly between the two nephrectomies, avoiding the waste of precious minutes.

Overall, the entire operation lasted less than 5 h including anesthesiological procedures, patient positioning and trocar placement. We think that this is an acceptable anesthesia time for a bilateral procedure as confirmed by the regular observations made in the postoperative period.

The surgical technique with no arterial clamping decreased the risk of postoperative renal insufficiency which can be more frequent after a bilateral procedure, especially when bilateral clamping is performed, as already reported in literature<sup>[4]</sup>.

This procedure was really cost effective. In fact, the two nephrectomies were performed without shutting the robot down and using the same surgical instruments. These aspects helped strongly to decrease the costs of a robotic operation.

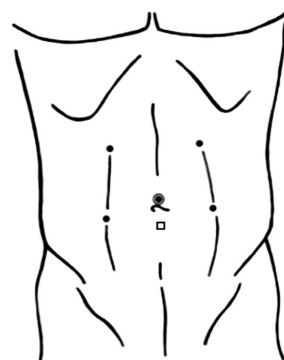


Figure 3 Port placements. Four 8-mm robotic ports (black circles), one 12-mm periumbilical camera port (double circle) and one 12-mm midline port (square).

Some limitations of our technique should be mentioned. In fact, an appropriate selection of the patients (mainly regarding the size, the location of the tumors or the preexisting condition of chronic renal insufficiency) and a very good skill in renal robotic surgery are really advisable before approaching this type of surgery.

In conclusion, our experience was encouraging and confirmed the feasibility and the safety of this procedure. Furthermore, the planning of our technique was time and cost effective with a cosmetic benefit for the patient. However, we think that an appropriate selection of the patients and skill in robotic renal surgery are really advisable before approaching this type of surgery.

## ACKNOWLEDGMENTS

We thank Dr. Jennifer McDermott for the language revision.

## COMMENTS

### Case characteristics

A 69-year-old male patient visited our department due to the incidental finding of bilateral small renal masses.

### Clinical diagnosis

The general physical examination was normal, the renal masses were not palpable. The body mass index was 23.51.

### Differential diagnosis

Benign tumors, complicated cysts.

### Laboratory diagnosis

The preoperative exams were normal.

### Imaging diagnosis

Magnetic resonance scans showed a 2.5 cm mass in the middle portion of the right kidney and a 3.5 cm mass in the middle portion of the left kidney with no involvement of the collecting systems.

### Pathological diagnosis

The pathological examination reported bilateral renal cell carcinoma, Fuhrman grade 1, with negative surgical margins.

### Treatment

A simultaneous bilateral robotic partial nephrectomy was performed.

### Related reports

The surgical treatment of small renal masses is well known using different approaches (mainly open surgery, laparoscopy and cryotherapy). However, very few papers have been reported in literature concerning simultaneous bilateral

robot assisted partial nephrectomy probably due to the low incidence of bilateral renal tumors but also due to the difficulties of this type of surgery.

### Experiences and lessons

This case report showed the feasibility, the safety, the time and cost effectiveness of this procedure with a cosmetic benefit for the patient.

### Peer review

This is a well written and interesting case.

## REFERENCES

- 1 **Leslie S**, Goh AC, Gill IS. Partial nephrectomy--contemporary indications, techniques and outcomes. *Nat Rev Urol* 2013; **10**: 275-283 [PMID: 23588406 DOI: 10.1038/nrurol.2013.69]
- 2 **Mottrie A**, Borghesi M, Ficarra V. Is traditional laparoscopy the real competitor of robot-assisted partial nephrectomy? *Eur Urol* 2012; **62**: 1034-1036; discussion 1038-1039 [PMID: 22854247 DOI: 10.1016/j.eururo.2012.07.039]
- 3 **Aboumarzouk OM**, Stein RJ, Eyraud R, Haber GP, Chlosta PL, Somani BK, Kaouk JH. Robotic versus laparoscopic partial nephrectomy: a systematic review and meta-analysis. *Eur Urol* 2012; **62**: 1023-1033 [PMID: 22771266 DOI: 10.1016/j.eururo.2012.06.038]
- 4 **Jung JH**, Arkoncel FR, Lee JW, Oh CK, Yusoff NA, Kim KJ, Rha KH. Initial clinical experience of simultaneous robot-assisted bilateral partial nephrectomy and radical prostatectomy. *Yonsei Med J* 2012; **53**: 236-239 [PMID: 22187260 DOI: 10.3349/ymj.2012.53.1.236]
- 5 **Seo IY**, Rim JS. Bilateral robotic single-site partial nephrectomy. *J Laparoendosc Adv Surg Tech A* 2011; **21**: 435-438 [PMID: 21561330 DOI: 10.1089/lap.2011.0052]
- 6 **Benway BM**, Wang AJ, Cabello JM, Bhayani SB. Robotic partial nephrectomy with sliding-clip renorrhaphy: technique and outcomes. *Eur Urol* 2009; **55**: 592-599 [PMID: 19144457 DOI: 10.1016/j.eururo.2008.12.028]
- 7 **Haber GP**, White WM, Crouzet S, White MA, Forest S, Autorino R, Kaouk JH. Robotic versus laparoscopic partial nephrectomy: single-surgeon matched cohort study of 150 patients. *Urology* 2010; **76**: 754-758 [PMID: 20646744 DOI: 10.1016/j.urology.2010.03.058]

**P- Reviewers:** Gbolade BA, Sanju G **S- Editor:** Qi Y

**L- Editor:** A **E- Editor:** Wu HL





## Cabazitaxel in castration resistant prostate cancer with brain metastases: 3 case reports

Sabino De Placido, Pasquale Rescigno, Piera Federico, Carlo Buonerba, Davide Bosso, Livio Puglia, Michela Izzo, Tania Policastro, Giuseppe Di Lorenzo

Pasquale Rescigno, Piera Federico, Carlo Buonerba, Davide Bosso, Livio Puglia, Michela Izzo, Tania Policastro, Sabino De Placido, Giuseppe Di Lorenzo, Genitourinary Cancer Section, Medical Oncology, Department of Clinical Medicine, Federico II University, Napoli 80140, Italy

**Author contributions:** De Placido S and Rescigno P contributed to the drafting of the manuscript; Federico P, Buonerba C, Bosso D, Puglia L, Izzo M and Policastro T contributed to the acquisition of the data; De Placido S and Di Lorenzo G contributed to the critical revision of the manuscript.

**Correspondence to:** Giuseppe Di Lorenzo, MD, PhD, Genitourinary Cancer Section, Medical Oncology, Department of Clinical Medicine, Federico II University, Corso Umberto I, Napoli 80140, Italy. [giuseppeditorenzoncol@hotmail.com](mailto:giuseppeditorenzoncol@hotmail.com)

Telephone: +39-081-7463660 Fax: +39-081-2203147

Received: January 5, 2014 Revised: March 31, 2014

Accepted: May 8, 2014

Published online: June 16, 2014

the incidence of brain metastases (BMs) has increased in patients with metastatic castration resistant prostatic cancer (mCRPC). Despite the large number of treatments now available, the prognosis of patients with BMs is still poor. First, we demonstrate the efficacy of cabazitaxel on brain metastases in three CRPC patients and then show its profile of tolerability in combination with whole brain radiotherapy.

De Placido S, Rescigno P, Federico P, Buonerba C, Bosso D, Puglia L, Izzo M, Policastro T, Di Lorenzo G. Cabazitaxel in castration resistant prostate cancer with brain metastases: 3 case reports. *World J Clin Cases* 2014; 2(6): 228-231 Available from: URL: <http://www.wjgnet.com/2307-8960/full/v2/i6/228.htm> DOI: <http://dx.doi.org/10.12998/wjcc.v2.i6.228>

### Abstract

Prostate cancer is the most common non-cutaneous malignancy for men. The skeleton is the most common metastatic site but, following an improvement in survival, metastases in uncommon sites are being found more frequently in clinical practice, especially brain metastases. Despite the new drugs now available for metastatic castration resistant prostate cancer, no clinical evidence exists about their effectiveness on brain metastases. We describe the clinical history of 3 patients treated with cabazitaxel plus whole brain radiotherapy. These case reports demonstrate that cabazitaxel is highly active and well tolerated in brain metastases.

© 2014 Baishideng Publishing Group Inc. All rights reserved.

**Key words:** Cabazitaxel; Brain metastases; Prostate cancer

**Core tip:** Due to the improvement in terms of survival,

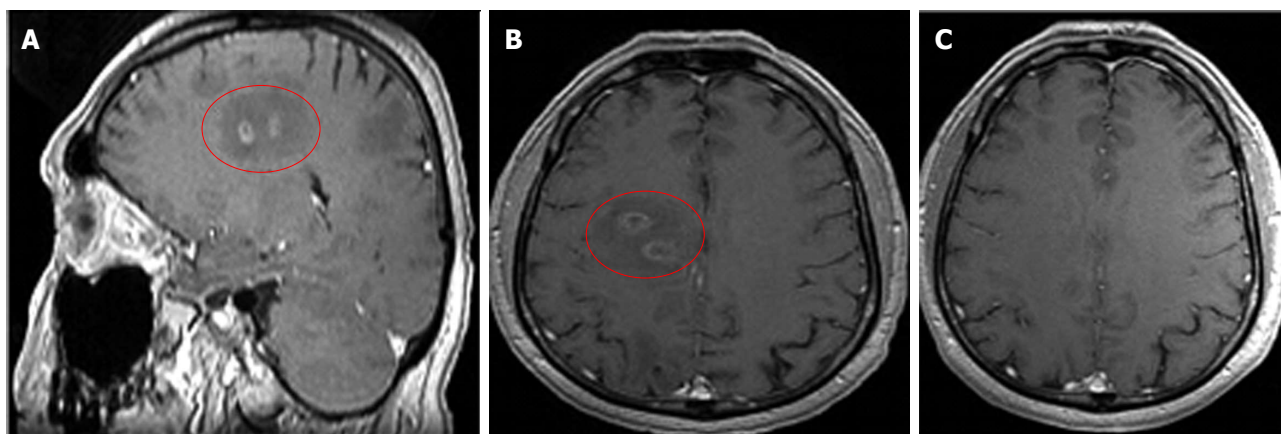
### INTRODUCTION

Prostate cancer (PC) is the most common non-cutaneous malignancy for men, with an estimated number of new cases of 241740 in 2013 in the United States<sup>[1]</sup>. Nevertheless, PC is not the leading cause of death in the male population due to its ability to rarely metastasize to organs other than bones<sup>[2]</sup>.

Although the skeleton remains the most common metastatic site, the availability of new active drugs for metastatic castration resistant prostatic cancer (mCRPC) has changed the natural history of this disease, leading to a considerable improvement in survival so that metastases in previously considered uncommon sites are now found more frequently<sup>[3]</sup>.

Brain is the site of metastases in almost 12% of cases with a poor prognosis at their appearance<sup>[4]</sup>.

Despite an increased incidence of BMs, the impact of new drugs for mCRPC on this metastatic site remains poorly understood. First of all, patients with BMs are not routinely enrolled in phase III clinical trials and there are



**Figure 1** Show a complete response in the brain lesions before and after 6 cycles of cabazitaxel. A, B: Brain metastases before cabazitaxel; C: Complete response after 6 cycles of cabazitaxel.

no prospective and ad-hoc studies in this particular setting. Actually, there is only preclinical data showing that cabazitaxel is able to pass the brain-blood barrier (BBB)<sup>[5]</sup> but no evidence about its efficacy in humans.

Otherwise, there is also little data concerning the role of radiation therapy on the treatment of BMs from PC which seems to have only a palliative intent<sup>[6]</sup>. Here, we describe three case reports of brain metastases in CRPC patients who were treated with cabazitaxel plus whole brain radiotherapy.

## CASE REPORT

The patients were 70, 70 and 72 years old. All patients presented at diagnosis with a high risk disease (Table 1). Patients 1 and 2 did not receive primary treatment because bone metastases and lymph node metastases were detected with bone and computed tomography scans. These 2 patients began hormonal therapy with luteinizing hormone releasing hormone analogue (aLHRH) first and then with complete androgen blockage (CAB), adding bicalutamide 50 mg.

Patient 3 underwent prostatectomy and radiotherapy for locally advanced disease. The disease progressed after 5 mo due to the appearance of bone metastases and aLHRH was started. All patients had a long androgen deprivation therapy (ADT) history (36-50 mo). Docetaxel was first line chemotherapy with a progression free survival (PFS) of 7, 7 and 11 mo respectively (Table 1). Patient 3 was treated with abiraterone as second line treatment and progressed after 6 mo.

The patients presented with multiple BMs (in number, 2, 3 and 3 respectively) confirmed with a magnetic resonance imaging (MRI) before starting cabazitaxel and the liver and lung were the other metastatic sites (Table 1). A total of 30 cycles of cabazitaxel were administered at standard dose without reductions (Table 1). Contemporaneous whole brain radiotherapy was performed at the dose of 30 Gy.

Patient 3 obtained a complete response on brain and

liver metastases with a PSA reduction of 90% after 6 cycles (Figure 1), while two partial responses in brain (the lesions were halved) and lung were observed, with a PSA decrease of 40% after 6 cycles for patient 1 and 2.

No grade 3-4 toxicities were experienced; all patients received pegylated granulocyte colony stimulating factor (PEG-G-CSF) to prevent febrile neutropenia. The most important non-hematological toxicities were grade 2 nausea and asthenia.

The PFS of patients 1 and 2 was 7 and 13 mo while patient 3 is still progression-free. Patients 1 and 2 received further therapy after cabazitaxel (abiraterone and platinum regimen) and died after 3 mo.

## DISCUSSION

BM appearance is a rare and terminal event in the natural history of PC due to greater aggressiveness and poor response to common therapies. BMs are often essentially single, supratentorial and occur with nonfocal neurological symptoms related to intracranial hypertension. A retrospective study of 103 patients with BMs showed that radiotherapy alone is an effective treatment with a median survival of 3.5 mo<sup>[7]</sup>.

Further improvement in survival was noted in five patients who underwent stereotactic radiosurgery (SRS). Although no complete responses were obtained, symptoms improved<sup>[8]</sup>.

BMs are more frequent in the CRPC setting than in the past due to the availability of new drugs and longer survival of metastatic patients. In the docetaxel era, the prognosis of patients with BMs was still poor and median survival was only 8 weeks after BM diagnosis, demonstrating the clinical ineffectiveness of docetaxel<sup>[3]</sup>.

Among the new approved drugs for mCRPC, such as cabazitaxel, abiraterone, enzalutamide and sipuleucel-T, only cabazitaxel has been shown to be able to pass the BBB. Cisternino and colleagues observed a non-linear accumulation of cabazitaxel in the brains of rats, occurring by saturation of the P-glycoprotein in the BBB<sup>[5]</sup>.

**Table 1 Patient characteristics**

	Patient 1	Patient 2	Patient 3
Age (yr)	70	70	72
Comorbidities	Hypertension	Hypertension	Diabetes
Primary treatment	Hormonal therapy	Hormonal therapy	Surgery and radiation therapy
Gleason score	8 (4 + 4)	8 (4 + 4)	8 (5 + 3)
PSA at baseline <sup>1</sup> (ng/mL)	158	82	17
ADT time (mo)	38	36	50
Docetaxel cycles	12	8	8
PSA pre-cabazitaxel (ng/mL)	95	292	140
Sites of metastases	Bone, lung, brain	Bone, lung, brain	Bone, liver, brain
Cabazitaxel cycles	12	8	10
Best response	PR on brain and lung	PR on brain and lung	CR on liver and brain
Toxicities	Anemia grade 1, asthenia grade 2	Nausea grade 2; neutropenia grade 2	Asthenia grade 2

<sup>1</sup>Before primary treatment. ADT: androgen deprivation therapy; PR: Partial response; CR: Complete response.

These 3 case reports describe the role of cabazitaxel in patients with BMs for the first time and the results are encouraging for 3 reasons.

Firstly, it shows the definite efficacy of cabazitaxel in BMs with an amazing PFS compared with the Tropic trial PFS<sup>[9]</sup>. Secondly, the association of whole brain radiotherapy and chemotherapy with cabazitaxel gives better results in terms of radiological response and survival than the data presented above.

Thirdly, the combination does not seem to be particularly toxic, especially in terms of hematological toxicities. We administered preventive PEG-G-CSF and, as previously shown in an Italian study, it reduced the grade 3 and 4 neutropenia reported with cabazitaxel<sup>[10]</sup>. Of note, all three patients had a gleason 8 at diagnosis, which is consistent with our previously reported findings suggesting improved PFS in patients with high gleason score receiving cabazitaxel<sup>[11]</sup>.

Our case reports demonstrate that cabazitaxel improved PFS and overall survival in our patients with BMs and is well tolerated in combination with we decided to report these cases in a full paper without presenting them as a meeting abstract, considering that only 50% of abstracts are subsequently published as full papers<sup>[12]</sup>. The lack of ad-hoc studies and the exclusion of men with brain metastases from phase III trials make our data the first evidence in this field. Prospective trials are needed to confirm our preliminary results.

## COMMENTS

### Case characteristics

All patients presented at diagnosis with a high risk disease.

### Treatment

The authors demonstrate the efficacy of cabazitaxel on brain metastases in three castration resistant prostatic cancer patients and show its profile of tolerability in combination with whole brain radiotherapy.

### Experiences and lessons

These case reports demonstrate that cabazitaxel is highly active and well tolerated in brain metastases.

### Peer review

Nice, well written paper with interesting data potentially useful in the clinical setting.

## REFERENCES

- 1 Siegel R, Naishadham D, Jemal A. Cancer statistics, 2013. *CA Cancer J Clin* 2013; **63**: 11-30 [PMID: 23335087 DOI: 10.3322/caac.21166]
- 2 Scosyrev E, Messing EM, Mohile S, Golijanin D, Wu G. Prostate cancer in the elderly: frequency of advanced disease at presentation and disease-specific mortality. *Cancer* 2012; **118**: 3062-3070 [PMID: 22006014 DOI: 10.1002/cncr.26392]
- 3 Caffo O, Vecchia A, Fellin G, Mussari S, Russo L, Tomio L, Galligioni E. Frequency of brain metastases from prostate cancer: an 18-year single-institution experience. *J Neurooncol* 2013; **111**: 163-167 [PMID: 23096134 DOI: 10.1007/s11060-012-0994-1]
- 4 Gandaglia G, Abdollah F, Schiffmann J, Trudeau V, Shariat SF, Kim SP, Perrotte P, Montorsi F, Briganti A, Trinh QD, Karakiewicz PI, Sun M. Distribution of metastatic sites in patients with prostate cancer: A population-based analysis. *Prostate* 2014; **74**: 210-216 [PMID: 24132735 DOI: 10.1002/pros.22742]
- 5 Cisternino S, Bourasset F, Archimbaud Y, Sémiond D, Sanderink G, Scherrmann JM. Nonlinear accumulation in the brain of the new taxoid TXD258 following saturation of P-glycoprotein at the blood-brain barrier in mice and rats. *Br J Pharmacol* 2003; **138**: 1367-1375 [PMID: 12711638 DOI: 10.1038/sj.bjp.0705150]
- 6 Expósito J, Jaén J, Alonso E, Tovar I. Use of palliative radiotherapy in brain and bone metastases (VARA II study). *Radiat Oncol* 2012; **7**: 131 [PMID: 22863023 DOI: 10.1186/1748-717X-7-131]
- 7 Tremont-Lukats IW, Bobustuc G, Lagos GK, Lolas K, Kyritsis AP, Puduvalli VK. Brain metastasis from prostate carcinoma: The M. D. Anderson Cancer Center experience. *Cancer* 2003; **98**: 363-368 [PMID: 12872358 DOI: 10.1002/cncr.11522]
- 8 Kim SH, Chao ST, Toms SA, Vogelbaum MA, Barnett GH, Suh JH, Weil RJ. Stereotactic radiosurgical treatment of parenchymal brain metastases from prostate adenocarcinoma. *Surg Neurol* 2008; **69**: 641-646; discussion 646 [PMID: 18262258 DOI: 10.1016/j.surneu.2007.05.035]
- 9 de Bono JS, Oudard S, Ozguroglu M, Hansen S, Machiels JP, Kocak I, Gravis G, Bodrogi I, Mackenzie MJ, Shen L, Roessner M, Gupta S, Sartor AO. Prednisone plus cabazitaxel or mitoxantrone for metastatic castration-resistant prostate cancer progressing after docetaxel treatment: a randomised open-label trial. *Lancet* 2010; **376**: 1147-1154 [PMID: 20888992 DOI: 10.1016/S0140-6736(10)61389-X]
- 10 Di Lorenzo G, D'Aniello C, Buonerba C, Federico P, Rescigno P, Puglia L, Ferro M, Bosso D, Cavaliere C, Palmieri G, Sonpavde G, De Placido S. Peg-filgrastim and cabazitaxel in prostate cancer patients. *Anticancer Drugs* 2013; **24**: 84-89 [PMID: 23044721 DOI: 10.1097/CAD.0b013e32835a56bc]
- 11 Buonerba C1, Pond GR, Sonpavde G, Federico P, Rescigno P, Puglia L, Bosso D, Virtuoso A, Policastro T, Izzo M, Vaccaro L, Ferro M, Aieta M, Perdonà S, Palmieri G, De Placido S, Di Lorenzo G. Potential value of Gleason score in predicting the benefit of cabazitaxel in metastatic castration-resistant pros-

tate cancer. *Future Oncol* 2013 Jun; **9**: 889-897 [DOI: 10.2217/fon.13.39]

- 12 **Autorino R**, Quarto G, Di Lorenzo G, De Sio M, Damiano

R.Are abstracts presented at the EAU meeting followed by publication in peer-reviewed journals? A critical analysis. *Eur Urol* 2007 Mar; **51**: 833-840

**P- Reviewers:** Creta M, Figg WD, Georgoulas V, Rubello D  
**S- Editor:** Song XX **L- Editor:** Roemmele A **E- Editor:** Wu HL





## Gastrointestinal perforation due to incarcerated Meckel's diverticulum in right femoral canal

Yusuf Yagmur, Sami Akbulut, Mehmet Ali Can

Yusuf Yagmur, Sami Akbulut, Mehmet Ali Can, Department of Surgery, Diyarbakir Education and Research Hospital, 21400 Diyarbakir, Turkey

Author contributions: Yagmur Y and Akbulut S designed the report; Akbulut S and Can MA performed surgical operation; Akbulut S and Yagmur Y organized the report and wrote paper.

Correspondence to: Sami Akbulut, MD, FICS, FACS, Department of Surgery, Diyarbakir Education and Research Hospital, 21400 Diyarbakir, Turkey. [akbulutsami@gmail.com](mailto:akbulutsami@gmail.com)

Telephone: +90-412-2580075 Fax: +90-412-2580070

Received: December 26, 2013 Revised: February 11, 2014

Accepted: April 9, 2014

Published online: June 16, 2014

### Abstract

Meckel's diverticulum is a very common congenital anomaly of the gastrointestinal tract but many cases remain asymptomatic and are diagnosed incidentally during laparoscopic or other surgical procedures. Cases of femoral hernia involving Meckel's diverticulum are rare, with less than 50 cases reported in the literature since Littre published the first description of this coincident condition over 300 years ago. While all true "Littre's hernias" contain a Meckel's diverticulum, the involved anatomical sites are various, the most common being the inner groin (inguinal), the outer groin (femoral), and the belly button (umbilical). Complications of Littre's hernias include incarceration, strangulation, necrosis, and perforation. Herein, we describe a case of Littre's hernia that involved an incarcerated Meckel's diverticulum in a femoral hernia that was diagnosed upon investigation of symptomatology manifesting from perforation and was successfully managed by surgical resection with stapler devices.

© 2014 Baishideng Publishing Group Inc. All rights reserved.

**Key words:** Meckel's diverticulum; Incarceration; Littre Hernia; Gastrointestinal perforation

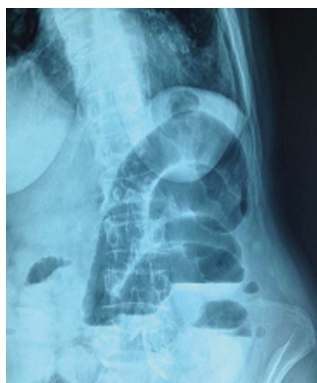**Core tip:** Meckel's diverticulum is most commonly di-

agnosed congenital anomaly of the gastrointestinal tract. Any hernia containing a Meckel's diverticulum is designated as a Littre's hernia. Although rare in overall incidence, the most common complications of Littre's hernias are perforation, bowel obstruction secondary to strangulation, and incarceration within the hernial sac. In this case study, we present and share the diagnosis and successfully management of a case of incarcerated Meckel's diverticulum in a femoral hernia (Littre's hernia) with perforation.

Yagmur Y, Akbulut S, Can MA. Gastrointestinal perforation due to incarcerated Meckel's diverticulum in right femoral canal. *World J Clin Cases* 2014; 2(6): 232-234 Available from: URL: <http://www.wjgnet.com/2307-8960/full/v2/i6/232.htm> DOI: <http://dx.doi.org/10.12998/wjcc.v2.i6.232>

### INTRODUCTION

The most commonly diagnosed congenital abnormality of the small intestine, Meckel's diverticulum, occurs when a portion of the vitelline duct fails to properly regress into the antimesenteric border of the terminal ileum at the end of the seventh week of gestation. As such, a Meckel's diverticulum contains all layers of the intestinal wall and is classified as a true diverticulum<sup>[1-6]</sup>. Estimates of the incidence of this condition have ranged from 0.3% to 3%, but its frequent asymptomatic nature may belie its true rates among the general population. Meckel's diverticula can be diagnosed as incident findings in laparoscopic or laparotomic examinations for unexplained symptoms or other conditions that have manifested clinical symptoms. Any hernia containing a Meckel's diverticulum is designated as a Littre's hernia. The most common sites of these coincident anatomical abnormalities are the inner groin (inguinal hernia, approximately 50%), the outer groin (femoral hernia, approximately 20%), and the belly button (umbilical hernia, approximately 20%).

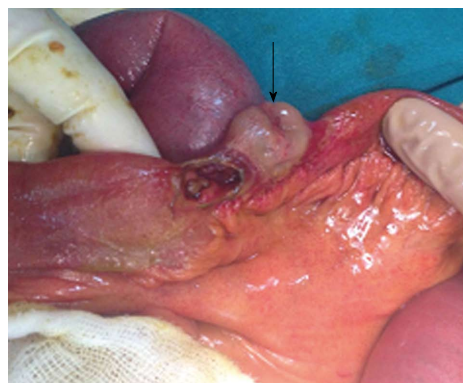

**Figure 1** Air-fluid levels detected by abdominal radiography. The findings were compatible with intestinal obstruction.

Although rare in overall incidence, the most common complications of Littre's hernias are perforation, bowel obstruction secondary to strangulation, and incarceration within the hernial sac<sup>[1]</sup>. Herein, we report the diagnosis and successful management of a case of incarcerated Meckel's diverticulum in a femoral hernia (Littre's hernia) with ileal perforation.

## CASE REPORT

A 73-year-old female presented to our Emergency Department with severe abdominal pain, nausea, and vomiting; the symptoms had begun one week previous, but had increased in severity over the last two days. The patient also reported the last instances of flatulence and defecation being three days previous. Results of standard laboratory blood tests were normal, hemoglobin: 13.2 g/dL (normal range, NR: 12.5-16.0), blood urea nitrogen: 22 mg/dL (NR: 10-50 mg/dL), and creatinine: 0.5 mg/dL (NR: 0.4-1.2 mg/dL), with the exception of a high white blood cell count [16000/ $\mu$ L (NR: 4100-11200/ $\mu$ L)] and neutrophil ratio [89% (NR: 50%-78%)]. In physical examination, auscultation revealed obstructive and hyperactive bowel sounds and palpation revealed serious tenderness with rebound pain that was particularly robust in the right lower quadrant. Abdominal radiographic examination showed air-fluid levels (Figure 1). Nasogastric decompression was performed in the Emergency Department. The collected clinical symptoms and findings from biochemical analysis and radiological examination suggested acute mechanical small bowel obstruction possibly related to internal herniation or perforation. The patient was prepared for exploration. Laparotomy with a midline incision revealed a Meckel's diverticulum with an ileal segment incarcerated in the right femoral canal and which had perforated the antimesenteric border of the ileum (Figure 2). The abnormality was managed by first removing the diverticulum through the femoral canal, suturing the femoral canal closed, resecting the partial ileal segment that included the perforated ileal segment and Meckel's diverticulum (15 cm in length), and creating a side-to-side anastomosis with stapler devices (Endo-GIA Stapling System; Covidian, Dublin, Ireland). Post-



**Figure 2** Perforation area proximal to the Meckel's diverticulum. The Meckel's diverticulum is indicated by a black arrow.

operative recovery was uncomplicated and the patient was discharged to home. Pathological analysis of the resected tissues showed no signs of gastric or pancreatic metaplasia.

## DISCUSSION

In the first five weeks of normal gestational development, the Meckel's diverticulum is the intestinal portion of the omphaloenteric duct through which the midgut communicates with the umbilical vesicle. Located at the antimesenteric border of the ileum, about 30 to 90 cm from the ileocecal valve, it can measure between 3 and 6 cm in length and is usually approximately 2 cm in diameter<sup>[2]</sup>. Failure of the tissue to regress by gestational week 7 is not fatal, and the congenital abnormality may remain asymptomatic (and undetected) throughout life. The lifetime complication rate estimated to be approximately 4%, with a higher incidence in males<sup>[4]</sup>, and the most common complications are bleeding, inflammation, and obstruction<sup>[5]</sup>.

Cases of femoral hernia involving Meckel's diverticulum are rare, with less than 50 cases reported in the literature since Littre published the first description of this coincident condition over 300 years ago<sup>[2]</sup>. A true Littre's hernia contains a Meckel's diverticulum alone, but cases of mixed Littre's hernia containing ileum or other abdominal viscera have been reported<sup>[3]</sup>. Perforation of the Meckel's diverticulum may occur due to peptic ulceration or compromised circulation and luminal patency at the narrow neck of the hernia<sup>[3]</sup>.

Preoperative diagnosis of a strangulated Littre's hernia is unlikely, as the presenting signs and symptoms are subtler and evolve more slowly than those of strangulated small intestine. Fever, pain, and signs of intestinal obstruction occur late or not at all. Moreover, there may be no specific sign of bowel involvement, other than local inflammation surrounding the hernia until an enterocutaneous fistula develops<sup>[5]</sup>. The *septuagenarian* case described herein presented with signs of obstruction (*i.e.*, serious abdominal tenderness, rebound pain, and air-fluid levels).

In Littre's hernia, obstruction can occur if the base of the diverticulum is broad enough to cause narrowing of the intestinal lumen. Presenting symptoms are tender

mass proximal to a hernial orifice with nausea, vomiting, abdominal pain, local groin pain and swelling. Pyrexia is normally associated with strangulation<sup>[5]</sup>. Repair of the Littre's hernia consists of local diverticulum resection and herniorrhaphy. In cases of perforation, care must be taken to not contaminate the hernia field<sup>[2]</sup>, and resection of the diverticulum ileal loop with end-to-end or side-to-side anastomosis is the recommended treatment.

## COMMENTS

### Case characteristics

A 73-year-old female presented to our Emergency Department with severe abdominal pain, nausea, and vomiting; the symptoms had begun one week previous, but had increased in severity over the last two days.

### Clinical diagnosis

Auscultation revealed obstructive and hyperactive bowel sounds and palpation revealed serious tenderness with rebound pain that was particularly robust in the right lower quadrant.

### Imaging diagnosis

Abdominal radiographic examination showed air-fluid levels. Laparotomy with a midline incision revealed a Meckel's diverticulum with an ileal segment incarcerated in the right femoral canal and which had perforated the antimesenteric border of the ileum

### Pathological diagnosis

Pathological analysis of the resected tissues showed no signs of gastric or pancreatic metaplasia.

### Treatment

Care must be taken to not contaminate the hernia field, and resection of the diverticulum ileal loop with end-to-end or side-to-side anastomosis is the recommended treatment.

### Peer review

The authors described the case of gastrointestinal perforation due to incarcerated Meckel's diverticulum in right femoral canal. The authors also demonstrated the figure of air-fluid levels detected by abdominal radiography.

## REFERENCES

- 1 **Perlman JA**, Hoover HC, Safer PK. Femoral hernia with strangulated Meckel's diverticulum (Littre's hernia). *Am J Surg* 1980; **139**: 286-289 [PMID: 6986804 DOI: 10.1016/0002-9610(80)90275-5]
- 2 **Skandalakis PN**, Zoras O, Skandalakis JE, Mirilas P. Littre hernia: surgical anatomy, embryology, and technique of repair. *Am Surg* 2006; **72**: 238-243 [PMID: 16553126]
- 3 **Jacob TJ**, Gaikwad P, Tirkey AJ, Rajinikanth J, Raj JP, Muthusami JC. Perforated obturator Littre hernia. *Can J Surg* 2009; **52**: E77-E78 [PMID: 19503657]
- 4 **Dumper J**, Mackenzie S, Mitchell P, Sutherland F, Quan ML, Mew D. Complications of Meckel's diverticula in adults. *Can J Surg* 2006; **49**: 353-357 [PMID: 17152574]
- 5 **Mirza MS**. Incarcerated Littre's femoral hernia: case report and review of the literature. *J Ayub Med Coll Abbottabad* 2007; **19**: 60-61 [PMID: 18183723]
- 6 **Emre A**, Akbulut S, Yilmaz M, Kanlioz M, Aydin BE. Double Meckel's diverticulum presenting as acute appendicitis: a case report and literature review. *J Emerg Med* 2013; **44**: e321-e324 [PMID: 23340118 DOI: 10.1016/j.jemermed.2012.11.001]

**P- Reviewers:** Contini S, Lin JK, Masaki T, Pellicano R, Sadik R

**S- Editor:** Gou SX **L- Editor:** A **E- Editor:** Wu HL



## Facial nerve palsy, headache, peripheral neuropathy and Kaposi's sarcoma in an elderly man

Dimitrios Daoussis, Elisabeth Chroni, Athanassios C Tsamandas, Andrew P Andonopoulos

Dimitrios Daoussis, Andrew P Andonopoulos, Division of Rheumatology, Department of Internal Medicine, University of Patras School of Medicine, 26504 Patras, Greece

Elisabeth Chroni, Department of Neurology, University of Patras School of Medicine, 26504 Patras, Greece

Athanassios C Tsamandas, Department of Pathology, University of Patras School of Medicine, 26504 Patras, Greece

**Author contributions:** Daoussis D and Andonopoulos AP conceived the idea of the study, performed the clinical assessments and drafted the manuscript; Chroni E performed the nerve conduction studies and assisted in manuscript drafting; Tsamandas AC performed all histological assessments and assisted in manuscript drafting.

**Correspondence to:** Dimitrios Daoussis, MD, Assistant Professor of Internal Medicine/Rheumatology, Division of Rheumatology, Department of Internal Medicine, University of Patras School of Medicine, Rion, 26504 Patras, Greece. [jimdaoussis@hotmail.com](mailto:jimdaoussis@hotmail.com)

Telephone: +30-2613-603693 Fax: +30-2610-993982

Received: February 12, 2014 Revised: March 26, 2014

Accepted: April 17, 2014

Published online: June 16, 2014

### Abstract

We present a case of an elderly man, who initially presented with right facial nerve palsy, ipsilateral headache, elevated erythrocyte sedimentation rate (ESR) and no fever. A presumptive diagnosis of giant cell arteritis was made and the patient was treated with high-dose steroids. A temporal artery biopsy was negative. Several months later, while on 16 mg of methylprednisolone daily, he presented with severe sensorimotor peripheral symmetric neuropathy, muscle wasting and inability to walk, uncontrolled blood sugar and psychosis. A work-up for malignancy was initiated with the suspicion of a paraneoplastic process. At the same time a biopsy of the macular skin lesions that had appeared on the skin of the left elbow and right knee almost simultaneously was inconclusive, whereas a repeat biopsy from the same area of the lesions that had become nodular, a month later, was indicative of Kaposi's

sarcoma. Finally, a third biopsy of a similar lesion, after spreading of the skin process, confirmed the diagnosis of Kaposi's sarcoma. He was treated with interferon  $\alpha$  and later was seen in very satisfactory condition, with no clinical evidence of neuropathy, normal muscle strength, no headache, normal electrophysiologic nerve studies, involution of Kaposi's lesions and a normal ESR.

© 2014 Baishideng Publishing Group Inc. All rights reserved.

**Key words:** Facial nerve palsy; Peripheral neuropathy; Vasculitis; Paraneoplastic syndrome; Kaposi's sarcoma

**Core tip:** We present a case of an elderly man, who initially presented with right facial nerve palsy, ipsilateral headache, elevated erythrocyte sedimentation rate and no fever. A presumptive diagnosis of giant cell arteritis was made and the patient was started on high-dose steroids. Several months later, he presented with severe sensorimotor peripheral symmetric neuropathy. A biopsy of the macular skin lesions that had appeared almost simultaneously, was suggestive of Kaposi's sarcoma. Although peripheral and cranial nerve involvement has not been reported in Kaposi's sarcoma, we postulate that the patient's condition could be attributed to that, within the context of a paraneoplastic process.

Daoussis D, Chroni E, Tsamandas AC, Andonopoulos AP. Facial nerve palsy, headache, peripheral neuropathy and Kaposi's sarcoma in an elderly man. *World J Clin Cases* 2014; 2(6): 235-239 Available from: URL: <http://www.wjgnet.com/2307-8960/full/v2/i6/235.htm> DOI: <http://dx.doi.org/10.12998/wjcc.v2.i6.235>

### INTRODUCTION

We present herein an interesting case of an elderly patient with right facial nerve palsy, ipsilateral headache, elevated erythrocyte sedimentation rate (ESR), sensorimotor neu-



ropathy and Kaposi's sarcoma.

## CASE REPORT

### History report

**Dimitrios Daoussis, MD:** The patient was a 72-year-old white man, who was initially admitted on September 16, 2009 to the department of neurology, with chief complaint of severe persistent right sided headache. Twenty days prior to admission, he experienced acutely right facial nerve palsy of peripheral type. Ten days later he developed severe right temporal headache, and was started on prednisolone 25 mg/d by oral administration (*po*) advised by a neurologist. He had noticed gradual impairment of hearing acuity since four months ago. Glaucoma had been present for the last three years, and right eye blindness for ten years, due to an accident. There was no fever, and except for right peripheral facial nerve palsy, physical examination was unremarkable. Laboratory examination revealed a hematocrit of 35.1% with mean corpuscular volume 93.4, a white blood cell (WBC) count of 12700/ $\mu$ L, a platelet count of 372 000/ $\mu$ L and a markedly elevated ESR of 105 mm/h. All biochemical parameters and his serologic profile, including rheumatoid factor, antinuclear antibodies, complement (C3 and C4) and antineutrophil cytoplasmic antibodies (ANCA) were within the normal range. Computed tomography (CT) and magnetic resonance imaging (MRI) brain scans were normal. Otolaryngologic evaluation suggested bilateral adhesive otitis, whereas ophthalmologic examination confirmed the presence of glaucoma and the right side blindness. The patient was started on methylprednisolone 48 mg/d *po*, with the presumptive diagnosis of giant cell arteritis (GCA). He was discharged on this regimen on September 24, 2009, pending the result of a right temporal artery biopsy, performed on the day of discharge.

He was first seen at the rheumatology outpatient clinic three months later, on December 20, 2009, again complaining of right temporal headache, despite of having been taking methylprednisolone 40 mg/d. The report of the temporal artery biopsy was negative for GCA and steroid tapering was started.

On February 23, 2010, he reported deterioration of his headaches, whereas his ESR was 58 mm/h. Methylprednisolone dose was increased back to 32 mg/d, and on March 22, 2010, his ESR had dropped to 6 mm/h and headaches had improved. Gradual tapering of steroids was again undertaken and an appointment after two months was given.

The patient was admitted to the department of medicine on June 26, 2010 with fatigue, profound muscle weakness, inability to walk and psychosis. While on methylprednisolone 16 mg/d, his admission glucose was 665 mg/dL, whereas it had been always normal before. He was afebrile without headache. He was profoundly wasted, with severe proximal muscle weakness and decreased deep tendon reflexes. The right facial nerve palsy had improved. Two bluish-red macules, about 1.5 cm in diameter, were noticed over the skin of the right knee and

left elbow, respectively. Laboratory tests revealed a hematocrit of 29.8%, mild leukocytosis, normal platelet count, an ESR of 28 mm/h, potassium of 3.73 mg%, sodium of 136 mg%, calcium of 8.64 mg%, magnesium of 1.5 mg%, creatinine of 0.6 mg%, total serum protein of 5 g% with albumin 2 g%, and normal creatine phosphokinase, transaminases, alkaline phosphatase and normal urinalysis. Serologic profile for rheumatic diseases and A, B and C hepatitis was unrevealing. Serum angiotensin converting enzyme (SACE) level was normal. A chest X-ray was also normal. An electrophysiologic evaluation was compatible with mixed sensorimotor neuropathy, worse on the lower extremities, but no myositis was found, except for changes due to chronic steroid administration. Cerebrospinal fluid examination was normal. Proximal muscle biopsy did not disclose myositis, vasculitis or granuloma. A purified protein derivative skin test was negative. Thyroid function was also normal.

With the suspicion of an underlying occult malignancy, an extensive work-up towards that direction was initiated; gastroscopy, barium enema, brain, thoracic and abdominal CT scans, thyroid ultrasound and cancer indices including alpha fetoprotein, carcinoembryonic antigen (CEA), CA 19-9, prostatic specific antigen, beta horionic gonadotrophin were all normal. A biopsy of the left elbow skin lesion displayed atypical changes (see pathological description below).

With the patient's condition deteriorating, both clinically and in laboratory test results (Ht = 20.3%, ESR = 70 mm/h), with uncontrolled blood sugar levels, and cushingoid features, including psychosis and severe muscle wasting, in an attempt to spare steroids, we treated the patient with methotrexate 7.5 mg/wk. His condition improved and on July 24, 2000, one month after his admission, he was discharged on the above methotrexate dose, methylprednisolone 16 mg/d and insulin, to be followed closely.

On the August 23 appointment, the patient's general condition was relatively satisfactory, with significant improvement of his muscle strength, and a hematocrit of 36.6% and ESR 15 mm/h. However, the previously noted macules on the skin of the left elbow and right knee had become nodular and a biopsy of the lesion of the elbow was taken. This biopsy was indicative of Kaposi's sarcoma, although not typical. One month later, on September 27, the patient returned with similar bluish-red nodules all over his body, typical of Kaposi's sarcoma, and a third biopsy confirmed the diagnosis. The methotrexate was discontinued and the patient was admitted on October 5, 2000 to the dermatology service and started on interferon  $\alpha$  (IFN $\alpha$ -2 $\alpha$ ) treatment. At that time, his hematocrit was 35% and ESR 25 mm/h, whereas serology for HIV was negative. An electrophysiologic nerve study showed definite improvement of the neuropathy. He was discharged on November 18, 2000, on IFN $\alpha$  and methylprednisolone 16 mg/d.

On January 9, 2011 at his outpatient visit, he was found in very good condition, with normal muscle strength and gait, very mild right temporal headache, no

**Table 1** Findings of nerve conduction serial studies in this patient

Nerve	Parameter	1 <sup>st</sup> study	2 <sup>nd</sup> study	3 <sup>rd</sup> study	Normal limits
Motor conduction					
Median	CV (ms)	46	60	60	≥ 50
	CMAP (mV)	4	6	6	≥ 5
	Min F-wave (ms)	32	28	27	≤ 30
Peroneal	CV (ms)	35	40	43	≥ 41
	CMAP (mV)	0.4	1	2	≥ 2
	Min F-wave (ms)	-	-	54	≤ 52
Sensory conduction					
Sural	CV (ms)	-	-	32	≥ 40
	SAP (μV)	-	-	4	≥ 8

CV: Conduction velocity; CMAP: Compound muscle action potential; SAP: Sensory action potential.

psychotic features, with normal deep tendon reflexes, and with only pale-brownish skin macules, remnants of involuted previous nodular lesions. A third electrophysiologic study showed further improvement of the neuropathy, and the patient was put to regular follow-up.

### Electrophysiologic nerve studies

**Elisabeth Chroni, MD, PhD:** The findings were consistent with distal sensorimotor neuropathy of mixed-axonal and demyelinating-type. On follow-up studies 5 and 7 mo later, a gradual improvement was observed.

Electromyography of facial muscles showed denervation potentials (fibrillations and positive waves) at rest and poor recruitment of motor units indicating axonal damage of facial nerve. All the above are depicted in Table 1.

### Pathological description

**Athanassios C Tsamandas, MD:** The first biopsy revealed areas with proliferation of fibroblasts and capillaries, in the dermis (Figure 1A-D). The vessels of medium size displayed fibrosis of the wall, luminal narrowing and elastic lamina disruption without any fibrin deposition. The second biopsy (Figure 1E-G) was consistent with early changes of Kaposi's sarcoma (macular-patch stage). The third biopsy (Figure 1H-M) showed a well-defined nodule composed of vascular spaces and spindle cells that replaced the dermal collagen. Spindle cells and endothelial cells lining the vascular clefts were CD34 (+). A diagnosis of Kaposi's sarcoma was made.

Retrospectively, the slides were reviewed and the features in the first biopsy were suggestive of a very early Kaposi's sarcoma lesion.

## DISCUSSION

**Andrew P Andonopoulos, MD, FACP:** It would be simplistic to guess that our patient had a Bell's palsy, independent of the neuropathy he later developed, and the malignancy which appeared almost concomitantly with the latter. The facial nerve palsy and the headache, along with the impressively elevated ESR, speak against

the possibility of idiopathic Bell's palsy. Furthermore, the patient had no hypertension or diabetes. The psychotic episode that our patient suffered was probably associated with the iatrogenic Cushing.

Similarly, the whole picture and its evolution are against the possibility of a metabolic or toxic cause of the neurologic syndrome in our patient. Instead, it would be very suggestive of a vasculitic process, if not related to a paraneoplastic syndrome, due to the malignancy, which appeared almost simultaneously with the peripheral neuropathy.

At a first glance, there was a very strong diagnostic possibility of GCA at the time of the initial presentation of this elderly gentleman, with temporal headache and an impressively elevated ESR. The negative biopsy, despite the fact that the specimen was meticulously examined and even recut later, does not rule out this possibility, because the procedure is not 100% sensitive<sup>[1]</sup>. However, one could argue that the response of the headache to the treatment was not the one typically expected in GCA, as it was mentioned. The apparent response of the ESR to steroid administration, does not necessarily mean that the elevated ESR was secondary to GCA, because similar responses may be encountered in several vasculitic or even other different processes. Furthermore, the development of neuropathy secondary to GCA, on steroid treatment, would be unusual. Peripheral neuropathy has been described in GCA as a rather rare manifestation, coincident with clinically active disease. In a study by Caselli *et al*<sup>[2]</sup> out of 166 consecutive patients with GCA, 23 had clinical evidence of peripheral neuropathic disease, of whom 11 had a generalized peripheral neuropathy, nine had mononeuritis multiplex and three had a mononeuropathy. Only a few reports of facial nerve palsy in the context of GCA appear in the literature<sup>[3-7]</sup>.

Wegener's granulomatosis is, among the vasculitides, the one that can involve most commonly cranial nerves, besides causing peripheral neuropathy<sup>[8]</sup>. Our patient had no features of Wegener's granulomatosis, without upper airway, lung or kidney involvement, and negative ANCA.

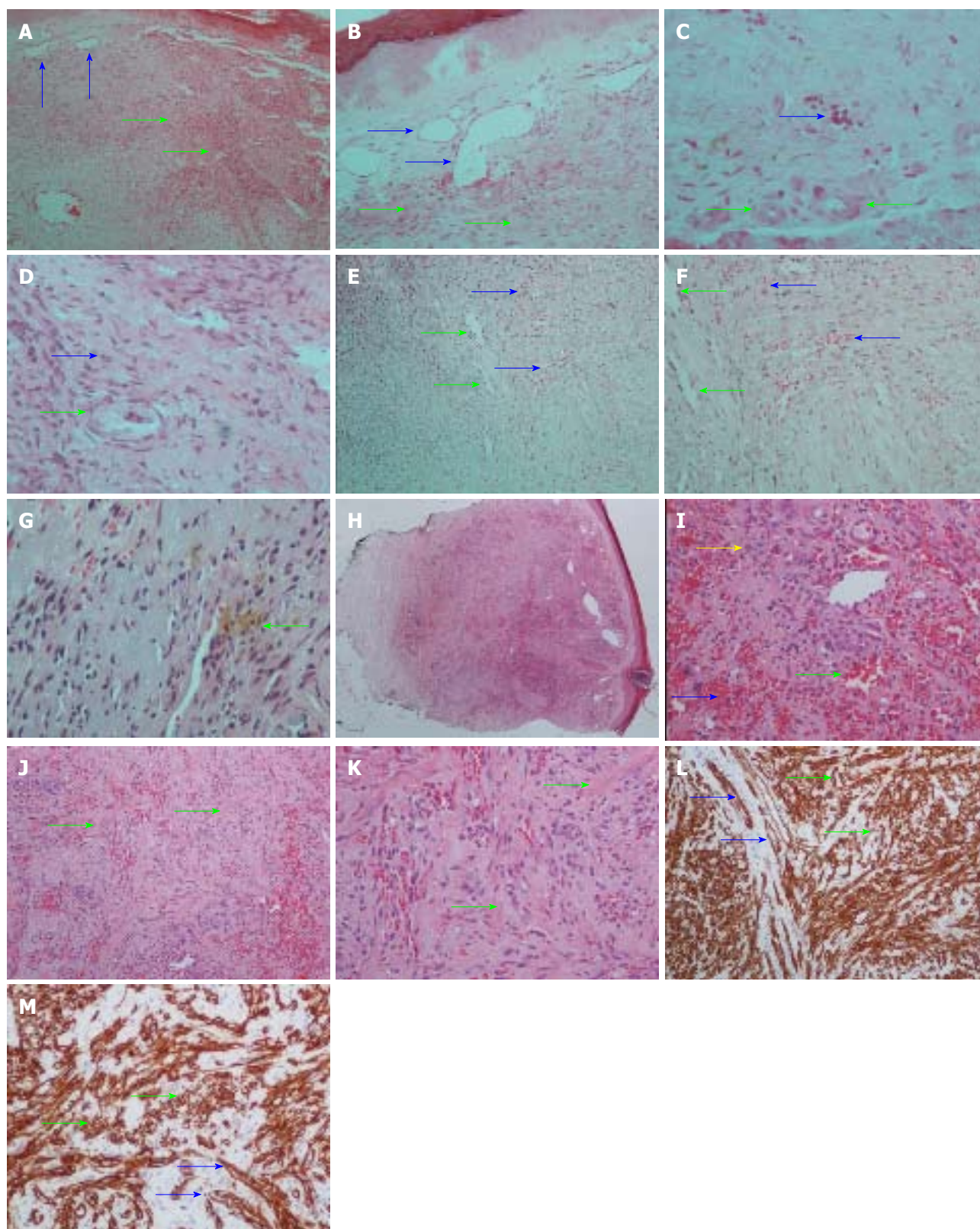
Polyarteritis nodosa would be another remote possibility, but the absence of fever, hypertension and kidney involvement, along with the negative, for vasculitis, muscle biopsy argue against this possibility<sup>[9]</sup>. Churg-Strauss syndrome could not account for our patient's picture, because the hallmarks of this entity were absent<sup>[10]</sup>.

Isolated granulomatous vasculitis of the central nervous system could have been another possibility. The advanced age of our patient, the impressively high ESR, and especially the normal brain MRI and cerebrospinal fluid argue strongly against this diagnosis<sup>[11]</sup>. Finally, our patient had no evidence of sarcoidosis, with normal chest X-ray, normal SACE and negative for non-caseating granuloma muscle biopsy.

Keeping all the above considerations in mind, one then should try to correlate the patient's manifestations with the malignant disease which he was found to have.

Axonal peripheral neuropathy, such as this patient had, can be a feature of a paraneoplastic syndrome,





**Figure 1 Microphotographs.** A, B: The first skin biopsy showing proliferation of fibroblasts (green arrows) and capillaries (blue arrows) in the dermis (H and E, A,  $\times 100$ ; B,  $\times 200$ ); C: The same biopsy showing narrowing of the lumen of medium size vessels (green arrow) and blood cell extravasation (blue arrow) (H and E,  $\times 200$ ); D: The same biopsy showing lumen narrowing of a medium size vessel (green arrows) and fibroblast proliferation (blue arrow) (H and E,  $\times 400$ ); E, F: The second skin biopsy showing dilated and irregular vessels (green arrows) and blood extravasation (blue arrows). (H and E, E,  $\times 100$ ; F,  $\times 200$ ); G: The same biopsy showing the presence of siderophages (green arrow) (H and E,  $\times 400$ ); H: The third skin biopsy showing a well-defined nodule composed of vascular spaces and spindle cells that has replaced the dermal collagen (H and E,  $\times 20$ ); I: At a higher magnification, there are blood-filled vessels (green arrow), spindle cells (yellow arrow) and blood cell extravasation (blue arrow) (H and E,  $\times 200$ ); J, K: The same biopsy showing compartmentalization of the nodule by bands of fibrocollagen tissue (green arrows); L, M: The same biopsy showing that spindle cells (green arrows) and endothelial vascular cells (blue arrows) expressed CD34. Streptavidin-biotin peroxidase (L,  $\times 100$ ; M,  $\times 200$ ).

shared by several malignancies, mainly of the lung, but of other organs as well. A meticulous search of the literature did not result in the finding of any report of Kaposi's sarcoma associated with a paraneoplastic picture from the nervous system, nor with any related to direct peripheral nerve invasion by this particular malignancy. However, this possibility cannot be excluded in our patient, and in view of our inability to find another cause responsible for his symptoms, if we wanted to put everything under one basic pathogenetic process, it would be very tempting to attribute the whole picture to the underlying malignancy.

On the other hand, it would be very difficult to accept that Kaposi's sarcoma in our patient developed iatrogenically, following immunosuppression. Kaposi's sarcoma may be caused by iatrogenic immunosuppression, but this has been mainly reported in transplant patients, receiving heavy immunosuppressive treatment with cyclosporin A and steroids with azathioprine. In addition, our patient must have Kaposi's lesions, although not diagnosed, as it could be documented from the presentation, before methotrexate was started.

In conclusion, although peripheral and cranial nerve involvement has not been reported in Kaposi's sarcoma, we postulate that the patient's condition could be attributed to this within the context of a paraneoplastic process.

## COMMENTS

### Case characteristics

A 72-year-old man with ipsilateral headache, skin lesions and neuropathy.

### Clinical diagnosis

Facial nerve palsy and peripheral neuropathy.

### Differential diagnosis

Giant cell arteritis (GCA) or other systemic vasculitis vs paraneoplastic manifestations in the context of Kaposi's sarcoma.

### Laboratory diagnosis

Raised inflammatory markers and anemia.

### Imaging diagnosis

Negative computed tomography (CT) scan of thorax-abdomen, negative brain CT and magnetic resonance imaging.

### Pathological diagnosis

Biopsies of skin lesions diagnostic of Kaposi's sarcoma.

### Treatment

Initial treatment with high-dose steroids with the diagnosis of GCA. Following diagnosis of Kaposi's sarcoma, the patient was successfully treated with interferon.

### Experiences and lessons

A paraneoplastic process may present with atypical manifestations.

### Peer review

Although peripheral and cranial nerve involvement has not been reported in Kaposi's sarcoma, authors postulate that the patient's picture could be attributed to this within the context of a paraneoplastic process. This is a very interesting case.

## REFERENCES

- 1 **Niederkoehr RD**, Levin LA. A Bayesian analysis of the true sensitivity of a temporal artery biopsy. *Invest Ophthalmol Vis Sci* 2007; **48**: 675-680 [PMID: 17251465 DOI: 10.1167/iov.06-1106]
- 2 **Caselli RJ**, Daube JR, Hunder GG, Whisnant JP. Peripheral neuropathic syndromes in giant cell (temporal) arteritis. *Neurology* 1988; **38**: 685-689 [PMID: 2834668 DOI: 10.1212/WNL.38.5.685]
- 3 **Zamarbide ID**, Maxit MJ. Fisher's one and half syndrome with facial palsy as clinical presentation of giant cell temporal arteritis. *Medicina (B Aires)* 2000; **60**: 245-248 [PMID: 10962818]
- 4 **Eggenberger E**. Eight-and-a-half syndrome: one-and-a-half syndrome plus cranial nerve VII palsy. *J Neuroophthalmol* 1998; **18**: 114-116 [PMID: 9621267 DOI: 10.1097/00041327-199806000-00008]
- 5 **Taillan B**, Fuzibet JG, Vinti H, Castela J, Gratecos N, Dujardin P, Pesce A. Peripheral facial paralysis disclosing Horton's disease. *Rev Rhum Mal Osteoartic* 1989; **56**: 342 [PMID: 2711115]
- 6 **Bakchine S**, Côte D, Massiou H, Derouesné C. A case of peripheral facial paralysis in Horton's disease. *Presse Med* 1985; **14**: 2062 [PMID: 2934700]
- 7 **Roomet A**, Allen JS. Temporal arteritis heralded by facial nerve palsy. *JAMA* 1974; **228**: 870-871 [PMID: 4406305 DOI: 10.1001/jama.228.7.870]
- 8 **Asakura K**, Muto T. Neurological involvement in Wegener's granulomatosis. *Brain Nerve* 2013; **65**: 1311-1317 [PMID: 24200609]
- 9 **Colmegna I**, Maldonado-Cocco JA. Polyarteritis nodosa revisited. *Curr Rheumatol Rep* 2005; **7**: 288-296 [PMID: 16045832 DOI: 10.1007/s11926-005-0039-2]
- 10 **Vaglio A**, Buzio C, Zwerina J. Eosinophilic granulomatosis with polyangiitis (Churg-Strauss): state of the art. *Allergy* 2013; **68**: 261-273 [PMID: 23330816 DOI: 10.1111/all.12088]
- 11 **Hammad TA**, Hajj-Ali RA. Primary angiitis of the central nervous system and reversible cerebral vasoconstriction syndrome. *Curr Atheroscler Rep* 2013; **15**: 346 [PMID: 23793732 DOI: 10.1007/s11883-013-0346-4]

**P- Reviewers:** Campbell JH, Juan DS **S- Editor:** Wen LL  
**L- Editor:** Ma JY **E- Editor:** Wu HL





# World Journal of *Clinical Cases*

*World J Clin Cases* 2014 July 16; 2(7): 240-315





## Contents

Monthly Volume 2 Number 7 July 16, 2014

<b>REVIEW</b>	240	Infectious burden and atherosclerosis: A clinical issue <i>Sessa R, Di Pietro M, Filardo S, Turriziani O</i>
<b>MINIREVIEWS</b>	250	Is there a role for fish oil in inflammatory bowel disease? <i>Farrukh A, Mayberry JF</i>
	253	Critical review of topical management of oral hairy leukoplakia <i>Brasileiro CB, Abreu MHNG, Mesquita RA</i>
<b>EVIDENCE-BASED MEDICINE</b>	257	Association between resting energy expenditure, psychopathology and HPA-axis in eating disorders <i>Castellini G, Castellani W, Lelli L, Lo Sauro C, Dini C, Lazzeretti L, Bencini L, Mannucci E, Ricca V</i>
<b>OBSERVATIONAL STUDY</b>	265	Role of ethnicity in social anxiety disorder: A cross-sectional survey among health science students <i>De Jager P, Suliman S, Seedat S</i>
	272	Cut-off of body mass index and waist circumference to predict hypertension in Indian adults <i>Midha T, Krishna V, Nath B, Kumari R, Rao YK, Pandey U, Kaur S</i>
<b>CASE REPORT</b>	279	Perirenal extra-adrenal myelolipoma <i>Hajiran A, Morley C, Jansen R, Kandzari S, Bacaj P, Zaslau S, Cardinal J</i>
	284	Verrucous carcinoma of the esophagus: A case report and literature review <i>Ramani C, Shah N, Nathan RS</i>
	289	360° fusion for realignment of high grade cervical kyphosis by one step surgery: Case report <i>Landi A, Marotta N, Mancarella C, Dugoni DE, Tarantino R, Delfini R</i>
	293	Focal epithelial hyperplasia in a human immuno-deficiency virus patient treated with laser surgery <i>Galanakis A, Palaia G, Tenore G, Del Vecchio A, Romeo U</i>



- 297** Optimal management of a patient with recurrent nasopharyngeal carcinoma  
*Perri F, Dell'Oca I, Muto P, Schiavone C, Aversa C, Fulciniti F, Solla R, Della Vittoria Scarpati G, Buonerba C, Di Lorenzo G, Caponigro F*
- 301** Disseminated infection due to *Mycobacterium bovis* after intravesical BCG instillation  
*Marquez-Batalla S, Fraile-Villarejo E, Belhassen-García M, Gutierrez-Zubiaurre N, Cordero-Sánchez M*
- 304** One-stage revision in two cases of *Salmonella* prosthetic hip infection  
*Jeroense KTV, Kuiper JWP, Colen S, Schade RP, Saouti R*
- 309** Passage of nasogastric tube through tracheo-esophageal fistula into stomach: A rare event  
*Kamble RS, Gupta R, Gupta A, Kothari P, Dikshit KV, Kesan K, Mudkhedkar K*
- 311** Diagnostic pitfall of sebaceous gland metaplasia of the esophagus  
*Chiu KW, Wu CK, Lu LS, Eng HL, Chiou SS*

**APPENDIX** I-V Instructions to authors**ABOUT COVER**

Editorial Board Member of *World Journal of Clinical Cases*, Sachin Chakradhar Sarode, Associate Professor, Department of Oral Pathology and Microbiology, Dr .D. Y. Patil Dental College and Hospital, Dr. D. Y. Patil Vidyapeeth, Sant Tukaram nagar, Pimpri, Pune 411018, India

**AIM AND SCOPE**

*World Journal of Clinical Cases* (*World J Clin Cases*, *WJCC*, online ISSN 2307-8960, DOI: 10.12998) is a peer-reviewed open access academic journal that aims to guide clinical practice and improve diagnostic and therapeutic skills of clinicians.

The primary task of *WJCC* is to rapidly publish high-quality Autobiography, Case Report, Clinical Case Conference (Clinicopathological Conference), Clinical Management, Diagnostic Advances, Editorial, Field of Vision, Frontier, Medical Ethics, Original Articles, Clinical Practice, Meta-Analysis, Minireviews, Review, Therapeutics Advances, and Topic Highlight, in the fields of allergy, anesthesiology, cardiac medicine, clinical genetics, clinical neurology, critical care, dentistry, dermatology, emergency medicine, endocrinology, family medicine, gastroenterology and hepatology, geriatrics and gerontology, hematology, immunology, infectious diseases, internal medicine, obstetrics and gynecology, oncology, ophthalmology, orthopedics, otolaryngology, pathology, pediatrics, peripheral vascular disease, psychiatry, radiology, rehabilitation, respiratory medicine, rheumatology, surgery, toxicology, transplantation, and urology and nephrology.

**INDEXING/ABSTRACTING**

*World Journal of Clinical Cases* is now indexed in PubMed Central, PubMed, Digital Object Identifier.

**FLYLEAF**

## I-V Editorial Board

**EDITORS FOR THIS ISSUE**

Responsible Assistant Editor: *Xiang Li*  
Responsible Electronic Editor: *Huan-Liang Wu*  
Proofing Editor-in-Chief: *Lian-Sheng Ma*

Responsible Science Editor: *Fang-Fang Ji*  
Proofing Editorial Office Director: *Xin-Xia Song*

**NAME OF JOURNAL**  
*World Journal of Clinical Cases*

**ISSN**  
ISSN 2307-8960 (online)

**LAUNCH DATE**  
April 16, 2013

**FREQUENCY**  
Monthly

**EDITORS-IN-CHIEF**  
**Giuseppe Di Lorenzo, MD, PhD, Professor**, Genitourinary Cancer Section and Rare-Cancer Center, University Federico II of Napoli, Via Sergio Pansini, 5 Ed. 1, 80131, Naples, Italy

**Jan Jacques Michiels, MD, PhD, Professor**, Primary Care, Medical Diagnostic Center Rijnmond Rotterdam, Bloodcoagulation, Internal and Vascular Medicine, Erasmus University Medical Center, Rotterdam, Goodheart Institute and Foundation, Erasmus Tower, Veenmos 13, 3069 AT, Erasmus City, Rotterdam, The Netherlands

**Sandro Vento, MD**, Department of Internal Medicine, University of Botswana, Private Bag 00713, Gaborone,

Botswana

**Shuhei Yoshida, MD, PhD**, Division of Gastroenterology, Beth Israel Deaconess Medical Center, Dana 509, Harvard Medical School, 330 Brookline Ave, Boston, MA 02215, United States

**EDITORIAL OFFICE**  
Jin-Lei Wang, Director  
Xiu-Xia Song, Vice Director  
*World Journal of Clinical Cases*  
Room 903, Building D, Ocean International Center, No. 62 Dongsihuan Zhonglu, Chaoyang District, Beijing 100025, China  
Telephone: +86-10-85381891  
Fax: +86-10-85381893  
E-mail: [editorialoffice@wjnet.com](mailto:editorialoffice@wjnet.com)  
Help Desk: <http://www.wjnet.com/esp/helpdesk.aspx>  
<http://www.wjnet.com>

**PUBLISHER**  
Baishideng Publishing Group Inc  
8226 Regency Drive,  
Pleasanton, CA 94588, USA  
Telephone: +1-925-223-8242  
Fax: +1-925-223-8243  
E-mail: [bpgoffice@wjnet.com](mailto:bpgoffice@wjnet.com)  
Help Desk: <http://www.wjnet.com/esp/helpdesk.aspx>

<http://www.wjnet.com>

**PUBLICATION DATE**  
July 16, 2014

**COPYRIGHT**  
© 2014 Baishideng Publishing Group Inc. Articles published by this Open Access journal are distributed under the terms of the Creative Commons Attribution Non-commercial License, which permits use, distribution, and reproduction in any medium, provided the original work is properly cited, the use is non commercial and is otherwise in compliance with the license.

**SPECIAL STATEMENT**  
All articles published in journals owned by the Baishideng Publishing Group (BPG) represent the views and opinions of their authors, and not the views, opinions or policies of the BPG, except where otherwise explicitly indicated.

**INSTRUCTIONS TO AUTHORS**  
Full instructions are available online at [http://www.wjnet.com/2307-8960/g\\_info\\_20100722180909.htm](http://www.wjnet.com/2307-8960/g_info_20100722180909.htm)

**ONLINE SUBMISSION**  
<http://www.wjnet.com/esp/>



## Infectious burden and atherosclerosis: A clinical issue

Rosa Sessa, Marisa Di Pietro, Simone Filardo, Ombretta Turriziani

Rosa Sessa, Marisa Di Pietro, Simone Filardo, Department of Public Health and Infectious Diseases, "Sapienza" University, 00185 Rome, Italy

Ombretta Turriziani, Department of Molecular Medicine, "Sapienza" University, 00185 Rome, Italy

Author contributions: Sessa R, Di Pietro M, Filardo S and Turriziani O contributed to this paper; all authors read and approved the final version of the manuscript before submission.

Supported by Grants to R. Sessa from Center for Social Disease Research, "Sapienza" University, Rome

Correspondence to: Rosa Sessa, PhD, Department of Public Health and Infectious Diseases, "Sapienza" University, P.le Aldo Moro 5, 00185 Rome, Italy. [rosa.sessa@uniroma1.it](mailto:rosa.sessa@uniroma1.it)

Telephone: +39-064-9914102 Fax: +39-064-9914634

Received: December 27, 2013 Revised: May 16, 2014

Accepted: June 10, 2014

Published online: July 16, 2014

### Abstract

Atherosclerotic cardiovascular diseases, chronic inflammatory diseases of multifactorial etiology, are the leading cause of death worldwide. In the last decade, more infectious agents, labeled as "infectious burden", rather than any single pathogen, have been showed to contribute to the development of atherosclerosis through different mechanisms. Some microorganisms, such as *Chlamydia pneumoniae* (*C. pneumoniae*), human cytomegalovirus, *etc.* may act directly on the arterial wall contributing to endothelial dysfunction, foam cell formation, smooth muscle cell proliferation, platelet aggregation as well as cytokine, reactive oxygen specie, growth factor, and cellular adhesion molecule production. Others, such as *Helicobacter pylori* (*H. pylori*), influenza virus, *etc.* may induce a systemic inflammation which in turn may damage the vascular wall (*e.g.*, by cytokines and proteases). Moreover, another indirect mechanism by which some infectious agents (such as *H. pylori*, *C. pneumoniae*, periodontal pathogens, *etc.*) may play a role in the pathogenesis of atherosclerosis is molecular mimicry. Given the complexity of the mechanisms by which each microorganism may contribute to atherosclerosis, defining the interplay of more

infectious agents is far more difficult because the pro-atherogenic effect of each pathogen might be amplified. Clearly, continued research and a greater awareness will be helpful to improve our knowledge on the complex interaction between the infectious burden and atherosclerosis.

© 2014 Baishideng Publishing Group Inc. All rights reserved.

**Key words:** Infectious burden; Atherosclerosis; Bacteria; Virus; Pathogenetic mechanisms

**Core tip:** Several studies support the hypothesis that the infectious burden (IB) may be more involved in the pathogenesis of atherosclerosis than any single pathogen. However, because of the complexity of the interplay of more infectious agents in the host and the limitations of the methods available for the assessment of IB, the role of IB in the pathogenesis of atherosclerosis may have been underestimated.

Sessa R, Di Pietro M, Filardo S, Turriziani O. Infectious burden and atherosclerosis: A clinical issue. *World J Clin Cases* 2014; 2(7): 240-249 Available from: URL: <http://www.wjgnet.com/2307-8960/full/v2/i7/240.htm> DOI: <http://dx.doi.org/10.12998/wjcc.v2.i7.240>

### INTRODUCTION

Atherosclerosis, a chronic inflammatory disease of multifactorial etiology, may be considered as a multistage process, starting from the endothelial injury to the fibrous cap and thrombus formation in the advanced plaque. Key process in the development of atherosclerosis is low density lipoprotein (LDL) oxidation and accumulation in vascular cells, promoting foam cell formation as well as increased secretion of mediators of inflammation, such as interleukin (IL)-1, IL-6 and tumor necrosis factor (TNF)- $\alpha$ <sup>[1]</sup>. The inflammatory state, in turn, can induce oxidative stress by enhancing the production of reactive

oxygen species (ROS) in the vascular wall<sup>[1]</sup>, contributing to the progression and destabilization of atherosclerotic plaque and consequently to cardiovascular diseases (CVDs). It is well known that CVDs are the leading cause of death worldwide, accounting for approximately 17.3 million deaths per year<sup>[2]</sup>.

Current opinion is that increased incidence of CVDs is probably the result of a high prevalence of both traditional risk factors such as hypertension, dyslipidemia, etc. and nontraditional risk factors including inflammation, oxidative stress, and infectious agents<sup>[3]</sup>. In the last decade, infectious agents have acquired a growing importance, since they are able to induce inflammation and/or oxidative stress<sup>[4]</sup>.

More recently, several studies have provided evidence that more infectious agents, for example, *Chlamydia pneumoniae* (*C. pneumoniae*), *Helicobacter pylori* (*H. pylori*), human cytomegalovirus (HCMV), Herpes simplex virus (HSV), labeled as “infectious burden” (IB), rather than any single pathogen, may be involved in the development of atherosclerosis and the subsequent cardiovascular events.

## EVIDENCE LINKING INFECTIOUS BURDEN WITH ATHEROSCLEROSIS

Zhu *et al.*<sup>[5]</sup> were the first to show the association between increasing risk of coronary artery disease (CAD) and increasing number of infectious agents including *C. pneumoniae*, *H. pylori*, HCMV, HSV-1 and 2, and hepatitis A virus (HAV). Indeed, the prevalence of CAD was 48%, 69% and 85% in individuals with seropositivity to  $\leq 2$  pathogens, to 3 or 4 pathogens and to 5 pathogens respectively. Since then, several serological studies found a prospective relation between increasing number of infectious agents (HSV-1 and 2, HCMV, Epstein Barr virus, EBV, *Haemophilus influenzae*, *C. pneumoniae*, *Mycoplasma pneumoniae*, and *H. pylori*) and CVD outcomes<sup>[6-8]</sup>. At the same time, serological assessments demonstrated the association between increasing number of infectious agents (*C. pneumoniae*, *H. pylori*, *M. pneumoniae*, *H. influenzae*, HCMV, EBV, HSV-1 and 2) and progression of atherosclerosis<sup>[9,10]</sup>. Again, cross-sectional and case-control studies confirmed the relationship between the seropositivity to *C. pneumoniae*, *H. pylori*, HAV, HCMV, HSV-1 and 2, and atherosclerosis<sup>[11,12]</sup>.

The evidence for a direct contribution of IB in the pathogenesis of atherosclerosis is based on the simultaneous detection of two pathogens in the atherosclerotic plaque (*C. pneumoniae* and *H. pylori* or *M. pneumoniae* and *C. pneumoniae* or *C. pneumoniae* and HCMV)<sup>[13-15]</sup>. Better yet is the evidence for a synergistic effect of *C. pneumoniae* and *H. pylori*, *M. pneumoniae* and *C. pneumoniae*, HCMV and *C. pneumoniae* in initiating or aggravating atherosclerosis in several animal models<sup>[16-18]</sup>. Similarly, there are some data showing the synergistic effect of the co-infection with *C. pneumoniae* and HCMV on the expression of atherogenic factors including IL-6, IL-8 and basic fibroblast growth factor in vascular smooth muscle cells (VSMCs) involved

in advanced plaque formation<sup>[19]</sup>. Also seropositivity for both *C. pneumoniae* and HCMV infections was found to be associated with premature myocardial infarction even after adjustment for coronary risk factors and socioeconomic status<sup>[20]</sup>.

Interestingly, the significant association between the increasing number of infectious agents together with elevated IL-6, C-reactive protein (CRP), and fibrinogen levels, and CAD prevalence, supports the hypothesis that inflammation may be one pathway by which more infectious agents and CVDs are linked<sup>[5,8,12]</sup>.

The involvement of IB in the pathogenesis of atherosclerosis is expected since numerous infectious agents have been shown to play a role in the development and progression of atherosclerosis<sup>[4]</sup>.

*C. pneumoniae*, an obligate intracellular bacterium, is responsible for respiratory infections such as sinusitis, pharyngitis and pneumonia. Exposure to *C. pneumoniae* is extremely common and epidemiological studies indicate that anti-*C. pneumoniae* antibody prevalence is 50% by the age of 20 and increases with increasing age<sup>[21]</sup>. *C. pneumoniae* is characterized by the ability to systematically disseminate from the lungs through peripheral blood mononuclear cells and to localize in several extrapulmonary tissues<sup>[22-25]</sup>. In recent years, it has been demonstrated that *C. pneumoniae*, in response to several stress conditions (iron or essential amino acid starvation, interferon (IFN)- $\gamma$  or antibiotic treatment), can generate a persistent form during its developmental cycle<sup>[26-29]</sup>. Chlamydial persistent form may endure for a long time inside host cells since it is more suited to evade the host immune response and is more difficult to eradicate with antibiotics, leading to a chronic inflammatory state<sup>[26]</sup>.

Cumulative evidence on the involvement of *C. pneumoniae* and atherosclerosis has been provided by seroepidemiological studies<sup>[30-32]</sup>, *C. pneumoniae* DNA detection in the atherosclerotic plaque<sup>[31-33]</sup>, the isolation of viable bacteria from the atheroma<sup>[4,32]</sup> and *in vivo* studies, demonstrating that *C. pneumoniae* infection may accelerate the progression of atherosclerotic lesion in animal models<sup>[4,31,34]</sup>. Lastly, *in vitro* studies have evidenced that *C. pneumoniae* is able to multiply within vascular cells, such as macrophages, endothelial cells, SMCs and platelets, and to induce chronic inflammation through the elicitation of inflammatory cytokines (*e.g.*, IL-6, IL-1 $\beta$  and TNF- $\alpha$ )<sup>[31,32,35]</sup>. Furthermore, once inside the vascular tissue, *C. pneumoniae* has been shown to induce the production of ROS leading to oxidative stress, which contributes to LDL oxidation and accumulation within vascular cells and to foam cell formation<sup>[36]</sup>.

Periodontal pathogens, such as *Porphyromonas gingivalis* (*P. gingivalis*), *Aggregatibacter actinomycetemcomitans* (*A. actinomycetemcomitans*), *Tannerella forsythia* (*T. forsythia*), *Prevotella intermedia*, *Fusobacterium nucleatum* (*F. nucleatum*), *Treponema denticola*, *Campylobacter rectus*, *Streptococcus sanguis*, and *Streptococcus mutans*, are responsible of a complex group of chronic oral inflammatory diseases like periodontitis or gingivitis. Over the last years, different lines of evidence have supported the role of periodontal bacteria in cardio-

vascular diseases. First of all, it has been demonstrated that oral bacteria can disseminate in the blood stream causing bacteremia<sup>[37]</sup> and localize in vascular wall. Indeed, DNA, RNA and antigens of a variety of oral bacterial species (*e.g.*, *P. gingivalis*, *A. actinomycetemcomitans*, *T. forsythia* and *F. nucleatum*) have been detected in atherosclerotic plaques<sup>[4]</sup>. More importantly, evidence of live *P. gingivalis* and *A. actinomycetemcomitans* in the atheroma<sup>[38]</sup>, supports the direct involvement of these pathogens in the pathogenesis of atherosclerosis. Moreover, *in vivo* studies have shown the ability of *P. gingivalis* to accelerate atherosclerosis in murine models<sup>[4,39]</sup> and to induce aortic and coronary lesions in both normocholesterolemic and hypercholesterolemic pigs<sup>[40]</sup>. *In vitro* studies have demonstrated that periodontal pathogens are able to infect endothelial cells, SMCs and macrophages, eliciting the production of proinflammatory cytokines and chemokines (*e.g.*, IL-6 and monocyte chemoattractant protein (MCP)-1) and the formation of foam cells, hence contributing to atherosclerosis<sup>[41,42]</sup>.

*H. pylori*, a common cause of chronic gastritis as well as a risk factor for gastric cancer, is widespread in the general population. In the last decade, it has been considered as a possible risk factor for atherosclerosis, since *H. pylori* DNA has been found in the atherosclerotic plaque<sup>[4,14]</sup>. Several seroepidemiological studies have confirmed a relationship between *H. pylori* and atherosclerosis although others have failed to demonstrate such an association<sup>[43-46]</sup>. Controversial are data showing the ability of *H. pylori* to accelerate the atherosclerotic lesion development in mouse models<sup>[4]</sup>. However, *H. pylori* may also contribute to the systemic inflammation underlying atherosclerosis through the elicitation of acute-phase reactants (*e.g.*, CRP) and inflammatory cytokines (*e.g.*, IL-6)<sup>[47]</sup>.

Other bacteria, such as *M. pneumoniae*, have been proposed as possible pathogens in atherosclerosis with controversial results. Several seroepidemiological studies have found the association between CVDs and *M. pneumoniae*<sup>[48,49]</sup>. Furthermore, an *in vivo* study has demonstrated that *M. pneumoniae* infection aggravated atherosclerosis in hypercholesterolemic mice<sup>[18]</sup>. However, pathological studies have not supported the association between this microorganism and atherosclerosis, since *M. pneumoniae* DNA has been detected in atherosclerotic tissues as well as in healthy vessels<sup>[4]</sup>.

Lifelong persistent infection with HCMV has been also associated with atherosclerosis. HCMV was first detected in human atheromatous tissue by Benditt *et al*<sup>[50]</sup> in 1983. Experimental data have shown the ability of HCMV to infect the human vascular wall, resulting in altered function of the endothelium<sup>[51]</sup>. Furthermore, both antigen and nucleic acid sequence of HCMV have been detected in SMCs from carotid artery plaques<sup>[52-54]</sup>.

In addition, HCMV DNA has been more often detected in arterial samples from patients with atherosclerosis than in control subjects<sup>[55]</sup>. Similarly, higher prevalence as well as higher titer of HCMV antibody have been observed in patients undergoing vascular surgery for

atherosclerosis than in control subjects<sup>[56]</sup>. In addition, a meta-analysis study has reported a significant increased coronary heart disease risk for patients infected with HCMV<sup>[57]</sup>.

Recently it has been suggested that HSV-2, but not HSV-1, was associated with premature CVD<sup>[58]</sup>. Consistent with a potential relationship between HSV-2 and CVD, Raza-Ahmad *et al*<sup>[59]</sup> previously examined coronary artery specimens of patients undergoing coronary artery bypass grafting and found 45% of them positive for HSV-2 and only 1% positive for HSV-1. Likewise, a large cross sectional study linked HSV-2 to hypertension, but it did not find any association with HSV-1. The reasons of the association with HSV-2 and not with HSV-1 are unclear.

There is also evidence supporting the role of influenza as a trigger for cardiovascular events<sup>[60]</sup>. However, data are debated. Some authors think that influenza (A and B) seropositivity is not a predictor of risk for CAD. Others propose that influenza virus might play a role in atherogenesis or atherothrombosis and that influenza vaccination might reduce the risk of recurrent myocardial infarction<sup>[60,61]</sup>. Recently, a correlation between influenza B virus infection and acute myocardial infarction has been reported<sup>[62]</sup>.

Although there have been positive associations of antibody titers or viral antigens of the hepatitis viruses with CVD<sup>[63-65]</sup>, many recent studies have reported no association. Zhu *et al*<sup>[63]</sup> has suggested a causal role for HAV infection in atherogenesis, on the basis of a significantly higher prevalence of CAD among subjects living in the Washington, DC, area who had serum IgG antibodies to HAV. The same research group has reported a high relative hazard for myocardial infarction or death among individuals positive for IgG antibodies to HAV. However, some authors believe that epidemiological evidence argues against a significant role for HAV infection in atherogenesis, since in countries where HAV infection is far less frequent, such as northern European countries and Australia, the incidence of cardiovascular diseases is remarkably higher than that detected in countries showing an high HAV infection prevalence<sup>[66]</sup>.

Several studies have also investigated the association of atherosclerosis with hepatitis C virus (HCV) infection, with conflicting results. Some studies have reported that the presence of antibody against HCV was associated with an increased risk of carotid artery plaque in the general population<sup>[65]</sup>. In addition, positive-strand HCV RNA has been detected in carotid plaque tissues from anti-HCV antibody-positive patients but it was not detected in anti-HCV antibody-negative patients<sup>[67,68]</sup>. Furthermore, multivariate logistic regression analysis has showed that HCV core protein positivity was an independent predictor of carotid plaque, supporting the possible link between persistent HCV infection and carotid atherosclerosis in subjects without severe liver dysfunction<sup>[69]</sup>. Patients with chronic HCV infection are known to develop not only hepatitis, but also various metabolic disorders<sup>[70,71]</sup>. Indeed, HCV affects both glucose and



lipid metabolism. Recent population-based studies have demonstrated hypolipidemia in subjects with chronic HCV infection<sup>[72,73]</sup>. Although altered lipid metabolism is linked to atherosclerosis, the effect of HCV on atherosclerosis remains controversial<sup>[73-75]</sup>. A systematic review published by Roed *et al.*<sup>[76]</sup> has suggested an increased risk of CAD in HCV infected individuals. Recently, a study has revealed that chronic HCV infection was associated with increased insulin resistance and with mild atherosclerosis, thus underlining the complexity of this association<sup>[77]</sup>.

A growing body of literature reports that human immunodeficiency virus (HIV) infected patients suffer from an elevated risk for both subclinical atherosclerotic disease and CVD events than uninfected individuals<sup>[78-81]</sup>. However, the results of a meta-analysis as well as a number of independent studies have questioned this association<sup>[82,83]</sup>. Furthermore, antiretroviral therapy (ART) has been shown to have independent effects on lesion development in several experimental studies, and some compounds, such as protease inhibitors, are associated with lipodystrophy, central adiposity, hyperlipidaemia, and endothelial dysfunction, all recognized risk factors for CVD<sup>[84-86]</sup>. However, the risk of CVD associated with HIV infection is not fully accounted for by the effects of antiretrovirals in these studies. Indeed, other papers have suggested that direct HIV infection of endothelial cells could contribute to atherosclerosis by causing endothelial dysfunction<sup>[87]</sup>. Furthermore, Hsue *et al.*<sup>[88]</sup> have shown that increased atherosclerosis can occur in the absence of ART in HIV-infected patients. Recently, Desvarieux *et al.*<sup>[89]</sup> have further emphasized the role of HIV in atherosclerosis, reporting the preponderant association of HIV infection (rather than ART) with increased atherosclerosis in never smokers, thus also determining the validity of the relationship independent of this important confounder.

## POSSIBLE MECHANISMS UNDERLYING INFECTIOUS BURDEN RELATED TO ATHEROSCLEROSIS

A substantial body of evidence supports the hypothesis that more infectious agents rather than a single pathogen may contribute to atherosclerosis through different mechanisms (Figure 1). Some microorganisms, such as *A. actinomycetemcomitans*, may act directly on the arterial wall contributing to endothelial dysfunction, foam cell formation, SMC proliferation, platelet aggregation and cytokine production<sup>[4,41]</sup>. Otherwise, microorganisms, such as *H. pylori*, may induce a systemic inflammation which in turn may damage the vascular wall (*e.g.*, by cytokines and proteases). Indeed, many observational studies have reported the association of the seropositivity to *H. pylori* with a sensitive marker of systemic inflammation and even predictor of acute cardiovascular events such as CRP<sup>[90,91]</sup>.

Furthermore, there are also infectious agents, such as *C. pneumoniae* and *P. gingivalis*, that may contribute to atherosclerosis by both direct and indirect mechanisms. As a direct effect, these microorganisms have been

shown to infect macrophages, SMCs and endothelial cells inducing the production of ROS, cytokines (IL-6, IL-1 $\beta$  and TNF- $\alpha$ , *etc.*), growth factors (basic fibroblast growth factor, bFGF, tumor growth factor (TGF)- $\beta$ , *etc.*) and cellular adhesion molecules (vascular cell adhesion molecule-1, VCAM-1, intercellular adhesion molecule-1, ICAM-1, endothelial-leukocyte adhesion molecule-1, ELAM-1, *etc.*), all responsible for the typical pathological changes of the atherosclerotic plaque<sup>[36,41,42]</sup>. On the other hand, *C. pneumoniae* and *P. gingivalis* can contribute to atherosclerosis indirectly by inducing systemic inflammation<sup>[92,93]</sup>. Indeed, circulating cytokines (IL-6) and acute phase proteins (serum amyloid A), produced in response to systemic infection of animal models with *C. pneumoniae* or *P. gingivalis*, have been associated with the progression and destabilization of atherosclerotic lesions<sup>[94,95]</sup>. Also, in human, increases in circulating CRP levels and *P. gingivalis* or *C. pneumoniae* antibody levels have been associated with an increased risk of CAD<sup>[4,96]</sup>.

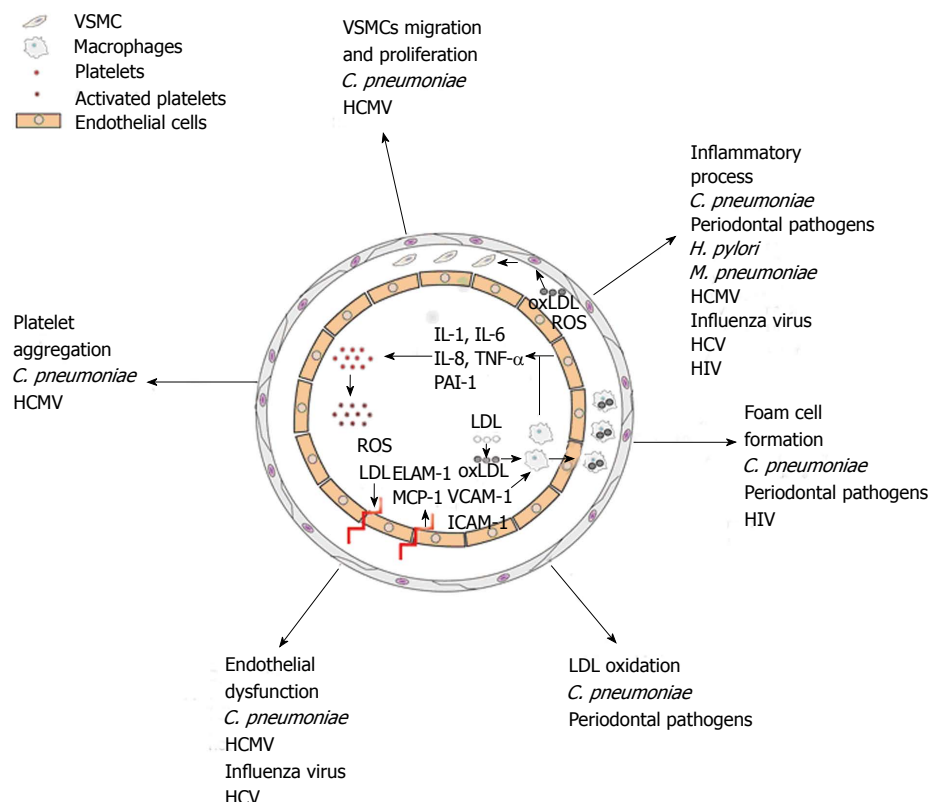
Another indirect mechanism by which infectious agents play a role in the pathogenesis of atherosclerosis is molecular mimicry. There is evidence that the humoral immune response against the heat shock proteins (HSPs) found in *C. pneumoniae*, *H. pylori* and *P. gingivalis*, may cross-react with human HSPs in vascular cells, initiating an autoimmune process, responsible for vascular endothelial injury<sup>[97-99]</sup>. In fact, antibody levels against HSPs have been associated with early and advanced atherosclerosis<sup>[100]</sup>. In addition, *in vivo* studies have also confirmed that the T-cell immune response against HSP, derived from *H. pylori*, *C. pneumoniae* and *P. gingivalis*, could promote atherogenesis<sup>[101-103]</sup>.

As far as concern viral agents, data supporting a direct effect of these agents on the pathogenesis of atherosclerosis are usually weak; infections with viruses are more likely to have an indirect effect on the initiation and progression of atherosclerosis.

Relative to HCMV, it has been observed that SMCs isolated from atherosclerotic coronary lesions, harbor HCMV DNA sequences and express immediate early proteins, such as IE84, one of the immediate early proteins of the virus that binds and inhibits p53<sup>[104]</sup>. Inhibition of p53 by the virus is held responsible for the enhanced proliferation of SMCs and impaired apoptosis, either of which may contribute to restenosis<sup>[104]</sup>. Furthermore, persistent infection of HCMV in endothelial cells leads to dysfunction of these cells and activates proinflammatory signaling pathways, which promote enhanced proliferation and migration of monocytes and SMCs into *intima* of the vascular wall as well as lipid accumulation and expansion of the atherosclerotic lesion<sup>[105,106]</sup>.

The precise mechanism by which influenza virus infection contributes to atherosclerosis is unclear, however inflammation and coagulopathy seem to be key factors. Specifically, the potential mechanisms may include: (1) antigenic cross-reactivity; (2) an increase in pro-inflammatory and prothrombotic cytokines, such as IL-2, IL-6, IL-10 and IL-18; (3) pronounced expression of inflammatory cytokines by infected monocytes and reduced





**Figure 1 Schematic representation of transversal artery section.** Possible etiopathogenetic mechanisms of the infectious agents in atherosclerotic plaque development. *C. pneumoniae*: *Chlamydia pneumoniae*; HCMV: Human cytomegalovirus; *H. pylori*: *Helicobacter pylori*; *M. pneumoniae*: *Mycoplasma pneumoniae*; HCV: Hepatitis C virus; HIV: Human immunodeficiency virus; SMC: Smooth muscle cell; ROS: Reactive oxygen species; LDL: Low-density lipoprotein; Ox-LDL: Oxidized low-density lipoprotein; IL: Interleukin; TNF- $\alpha$ : Tumor necrosis factor; PAI: Plasminogen activator inhibitor-1; ELAM-1: Endothelial-leukocyte adhesion molecule-1; VCAM-1: Vascular cell adhesion molecule-1; ICAM-1: Intercellular adhesion molecule-1; MCP-1: Monocyte chemoattractant protein-1.

clotting time; (4) increased trafficking of macrophages into the arterial wall; and (5) induction of procoagulant activity in infected endothelial cells, reduced clotting time, and increased expression of tissue factor<sup>[60,62]</sup>. Repeated influenza virus infection may injure vascular endothelial cells and initiate the inflammatory response that is required to accelerate and enhance the development of atherosclerosis.

It has been suggested that influenza virus may trigger the destabilization of already present vulnerable plaques. Naghavi *et al*<sup>[107]</sup> have showed that inoculation of influenza virus A in atherosclerotic apolipoprotein E-deficient mice led to a marked increase in inflammation and thrombosis in plaques but not in normal area. Influenza virus infection may cause the production of IL-2, IL-6, IL-10, IL-18, IFN- $\gamma$  and TNF- $\alpha$ , which induces endothelial cells to release endothelin (ET)-1, sICAM-1 and sVCAM-1. These inflammatory cytokines may trigger the destabilization of existing vulnerable plaques and lead to an acute myocardial infarction without being involved in the development or progression of atherosclerosis<sup>[108]</sup>.

As stated before, the role of HCV in atherosclerosis is widely debated. A role of chronic inflammation in atherogenesis has been suggested<sup>[109]</sup> because chronic HCV infection has been associated with vasculitis and mixed cryoglobulinemia, which may cause vascular injury as well as cerebrovascular damage<sup>[110]</sup>. Concentrations of sICAM-1 have been reported to be higher in HCV patients than in control subjects<sup>[111]</sup>, and Cacoub *et al*<sup>[112]</sup> have reported a possible association of anti-endothelial cell auto-antibodies, commonly observed in HCV patients but not in other viral diseases, with vasculitis. However, a recent

paper has demonstrated a favorable effect of HCV on atherosclerosis<sup>[77]</sup> probably due to the alteration in lipid parameters of the subjects with chronic HCV infection caused by the progression of liver disease and partly by a metabolic process associated with HCV replication.

Several papers have reported that atherosclerosis is consistently higher among the HIV positive patients, with or without treatment. Recently Shrestha *et al*<sup>[113]</sup> have postulated three key sequential biological processes that lead to accelerate progression of atherosclerosis: (1) inflammation leads to the recruitment of monocytes; (2) monocytes migrate to the endothelium and differentiate to macrophages and foam cells; and (3) apoptosis of foam cells leads to plaque development through calcium-dependent endoplasmic reticulum stress. The HIV itself, or together with treatment, affects this progression by increasing inflammation, promoting the transformation of monocytes, and increasing apoptosis through ER stress and an imbalance of calcium.

Given the complexity of the mechanisms by which each microorganism may play a role in the pathogenesis of atherosclerosis, defining the interplay of more infectious agents is far more difficult because the pro-atherogenic effect of each pathogen might be amplified.

## ASSESSMENT OF INFECTIOUS BURDEN RELATED TO ATHEROSCLEROSIS

The main unanswered question is the definition of IB. Several infectious agents, such as *C. pneumoniae*, *H. influenzae*, *H. pylori*, *M. pneumoniae*, HCMV, HSV, EBV and HAV, *etc.* have been proposed as constituting the IB related to

atherosclerosis, but, to date, there is no consensus both on the number and on which microorganisms should be considered.

The majority of the infectious agents involved in the IB are widespread, as evidenced from the high prevalence of antibodies in the general population; more than half of the world population is seropositive, for example, to *C. pneumoniae*, *H. pylori*, HCMV and HSV. Again, HSV, HCMV, *C. pneumoniae* and *H. pylori* infections could be acquired early in life, and persist over time. The situation is further complicated by the fact that the infectious agents involved in IB are responsible for persistent infection (*e.g.*, HIV and *C. pneumoniae*), repeated infection (*e.g.*, influenza virus), latent infection followed by life-long reactivation (*e.g.*, HSV and HCMV) or chronic infection (*e.g.*, HBV, HCV and, *H. pylori*).

Nowadays, the assessment of the IB related to atherosclerosis is based mainly on serological methods. The main limitations of serology are to define whether the antibody response reflects a past or chronic infection and to identify the differences in seropositivity between patients and general population, especially if seropositivity is common. In addition, serological diagnostic methods are not appropriate for the detection of novel or rare pathogens. Lastly, most serological assays are designed for diagnostic testing in clinical settings, and not for the assessment of the burden of infections acquired through life. Notably, most of the infectious agents involved in the IB, such as *C. pneumoniae*, *H. pylori*, HSV, and HCMV, can cause asymptomatic infections that are not routinely investigated. As a result, these undiagnosed infections, if left untreated, can contribute to the development of severe complications, including CVDs.

Other technical obstacles in the assessment of the IB related to atherosclerosis include difficulties in obtaining atherosclerotic plaques and in isolating and culturing certain infectious agents. Indeed, atherosclerotic plaques are obtained too late during the course of the disease to be of clinical use.

Another intriguing issue is the interaction of more infectious agents with host factors, such as age, gender, ethnicity, and other concomitant infections or clinical conditions that may impair the host immune system, thus potentially modifying the establishment, progression and outcome of the infection. Moreover, genome-wide association studies have now convincingly shown that the susceptibility to an infection as well as the diverse outcomes (for example the resolution of infection, the clinical deterioration to severe disease, or the progression from acute infection to persistent infection) can be, at least, partly explained by genetic variation<sup>[114]</sup>. In this regard, a recent study has showed that *IL-6* gene polymorphisms appear to influence the susceptibility to the atherogenic effect of more infectious agents including *C. pneumoniae*, CMV, *H. pylori* and HSV-1<sup>[115]</sup>.

## CONCLUSION

Based on the extent of the issues previously described,

the role of the IB in the pathogenesis of atherosclerosis may have been substantially underestimated, so that the true impact of IB is likely to be much greater than it is currently recognized.

Different approaches could be taken to address the problem; one possibility may be to conceive a well-designed protocol that includes the number and the type of infectious agents, the antibody response (IgG and/or IgA) as well as the monitoring of antibody titer, atherosclerotic biological markers and cytokines. The latter are particularly critical in chronic viral infections, such as HIV infection, in which two monocytes surface markers (CD11b and chemokine (C-X-C motif) receptor (CXCR)-1) have been proposed as predictors of CVD<sup>[116]</sup>.

Clearly, continued research and a better awareness of this problem will be helpful to improve our knowledge on the complex interaction between IB and atherosclerosis.

## REFERENCES

- 1 **Hulsmans M**, Holvoet P. The vicious circle between oxidative stress and inflammation in atherosclerosis. *J Cell Mol Med* 2010; **14**: 70-78 [PMID: 19968738 DOI: 10.1096/fj.11-181149]
- 2 **World Health Organization**. Global Atlas on Cardiovascular Disease Prevention and Control. Mendis S, Puska P, Norrving B (Editors). Available from: URL: [http://whqlibdoc.who.int/publications/2011/9789241564373\\_eng.pdf](http://whqlibdoc.who.int/publications/2011/9789241564373_eng.pdf)
- 3 **Balogopal PB**, de Ferranti SD, Cook S, Daniels SR, Gidding SS, Hayman LL, McCrindle BW, Mietus-Snyder ML, Steinberger J. Nontraditional risk factors and biomarkers for cardiovascular disease: mechanistic, research, and clinical considerations for youth: a scientific statement from the American Heart Association. *Circulation* 2011; **123**: 2749-2769 [PMID: 21555711 DOI: 10.1161/CIR.0b013e31821c7c64]
- 4 **Rosenfeld ME**, Campbell LA. Pathogens and atherosclerosis: update on the potential contribution of multiple infectious organisms to the pathogenesis of atherosclerosis. *Thromb Haemost* 2011; **106**: 858-867 [PMID: 22012133 DOI: 10.1160/TH11-06-0392]
- 5 **Zhu J**, Quyyumi AA, Norman JE, Csako G, Waclawiw MA, Shearer GM, Epstein SE. Effects of total pathogen burden on coronary artery disease risk and C-reactive protein levels. *Am J Cardiol* 2000; **85**: 140-146 [PMID: 10955367 DOI: 10.1016/S0002-9149(99)00653-0]
- 6 **Rupprecht HJ**, Blankenberg S, Bickel C, Rippin G, Hafner G, Prellwitz W, Schlumberger W, Meyer J. Impact of viral and bacterial infectious burden on long-term prognosis in patients with coronary artery disease. *Circulation* 2001; **104**: 25-31 [PMID: 11435333]
- 7 **Smieja M**, Gnarpe J, Lonn E, Gnarpe H, Olsson G, Yi Q, Dzavik V, McQueen M, Yusuf S. Multiple infections and subsequent cardiovascular events in the Heart Outcomes Prevention Evaluation (HOPE) Study. *Circulation* 2003; **107**: 251-257 [PMID: 12538424 DOI: 10.1161/01.CIR.0000044940.65226.1F]
- 8 **Mundkur LA**, Rao VS, Hebbagudi S, Shanker J, Shivanandan H, Nagaraj RK, Kakkar VV. Pathogen burden, cytomegalovirus infection and inflammatory markers in the risk of premature coronary artery disease in individuals of Indian origin. *Exp Clin Cardiol* 2012; **17**: 63-68 [PMID: 22826649]
- 9 **Espinola-Klein C**, Rupprecht HJ, Blankenberg S, Bickel C, Kopp H, Victor A, Hafner G, Prellwitz W, Schlumberger W, Meyer J. Impact of infectious burden on progression of carotid atherosclerosis. *Stroke* 2002; **33**: 2581-2586 [PMID: 12411646 DOI: 10.1161/01.STR.0000034789.82859.A4]
- 10 **Espinola-Klein C**, Rupprecht HJ, Blankenberg S, Bickel C, Kopp H, Rippin G, Victor A, Hafner G, Schlumberger W,

- Meyer J. Impact of infectious burden on extent and long-term prognosis of atherosclerosis. *Circulation* 2002; **105**: 15-21 [PMID: 11772870 DOI: 10.1161/hc0102.101362]
- 11 **Elkind MS**, Ramakrishnan P, Moon YP, Boden-Albala B, Liu KM, Spitalnik SL, Rundek T, Sacco RL, Paik MC. Infectious burden and risk of stroke: the northern Manhattan study. *Arch Neurol* 2010; **67**: 33-38 [PMID: 19901154 DOI: 10.1001/archneurol.2009.271]
  - 12 **Nazmi A**, Diez-Roux AV, Jenny NS, Tsai MY, Szklo M, Aiello AE. The influence of persistent pathogens on circulating levels of inflammatory markers: a cross-sectional analysis from the Multi-Ethnic Study of Atherosclerosis. *BMC Public Health* 2010; **10**: 706 [PMID: 21083905 DOI: 10.1186/1471-2458-10-706]
  - 13 **Higuchi Mde L**, Reis MM, Sambiasi NV, Palomino SA, Castelli JB, Gutierrez PS, Aiello VD, Ramires JA. Coinfection with *Mycoplasma pneumoniae* and *Chlamydia pneumoniae* in ruptured plaques associated with acute myocardial infarction. *Arq Bras Cardiol* 2003; **81**: 12-22, 1-11 [PMID: 12908069]
  - 14 **Kaplan M**, Yavuz SS, Cinar B, Koksai V, Kut MS, Yapici F, Gercekoglu H, Demirtas MM. Detection of *Chlamydia pneumoniae* and *Helicobacter pylori* in atherosclerotic plaques of carotid artery by polymerase chain reaction. *Int J Infect Dis* 2006; **10**: 116-123 [PMID: 16183317 DOI: 10.1016/j.ijid.2004.10.008]
  - 15 **Virok D**, Kis Z, Kari L, Barzo P, Sipka R, Burian K, Nelson DE, Jackel M, Kerenyi T, Bodosi M, Gönczöl E, Endresz V. *Chlamydia pneumoniae* and human cytomegalovirus in atherosclerotic carotid plaques--combined presence and possible interactions. *Acta Microbiol Immunol Hung* 2006; **53**: 35-50 [PMID: 16696549 DOI: 10.1556/AMicr.53.2006.1.3]
  - 16 **Burnett MS**, Gaydos CA, Madico GE, Glad SM, Paigen B, Quinn TC, Epstein SE. Atherosclerosis in apoE knockout mice infected with multiple pathogens. *J Infect Dis* 2001; **183**: 226-231 [PMID: 11120928 DOI: 10.1086/317938]
  - 17 **Liuba P**, Pesonen E, Paakkari I, Batra S, Andersen L, Forslid A, Ylä-Herttua S, Persson K, Wadström T, Wang X, Laurini R. Co-infection with *Chlamydia pneumoniae* and *Helicobacter pylori* results in vascular endothelial dysfunction and enhanced VCAM-1 expression in apoE-knockout mice. *J Vasc Res* 2003; **40**: 115-122 [PMID: 12808347 DOI: 10.1159/000070708]
  - 18 **Damy SB**, Higuchi ML, Timenetsky J, Reis MM, Palomino SP, Ikegami RN, Santos FP, Osaka JT, Figueiredo LP. *Mycoplasma pneumoniae* and/or *Chlamydia pneumoniae* inoculation causing different aggravations in cholesterol-induced atherosclerosis in apoE KO male mice. *BMC Microbiol* 2009; **9**: 194 [PMID: 19744321 DOI: 10.1186/1471-2180-9-194]
  - 19 **Prochnau D**, Straube E, Figulla HR, Rödel J. Supra-additive expression of interleukin-6, interleukin-8 and basic fibroblast growth factor in vascular smooth muscle cells following coinfection with *Chlamydia pneumoniae* and cytomegalovirus as a novel link between infection and atherosclerosis. *Can J Infect Dis Med Microbiol* 2012; **23**: e26-e30 [PMID: 23730316]
  - 20 **Gattone M**, Iacoviello L, Colombo M, Castelnovo AD, Soffiantino F, Gramoni A, Picco D, Benedetta M, Giannuzzi P. *Chlamydia pneumoniae* and cytomegalovirus seropositivity, inflammatory markers, and the risk of myocardial infarction at a young age. *Am Heart J* 2001; **142**: 633-640 [PMID: 11579353 DOI: 10.1067/mhj.2001.118118]
  - 21 **Grayston JT**. Background and current knowledge of *Chlamydia pneumoniae* and atherosclerosis. *J Infect Dis* 2000; **181** Suppl 3: S402-S410 [PMID: 10839724]
  - 22 **Sessa R**, Di Pietro M, Schiavoni G, Santino I, Cipriani P, Romano S, Penco M, del Piano M. Prevalence of *Chlamydia pneumoniae* in peripheral blood mononuclear cells in Italian patients with acute ischaemic heart disease. *Atherosclerosis* 2001; **159**: 521-525 [PMID: 11730834 DOI: 10.1016/S0021-9150(01)00537-8]
  - 23 **Wang SS**, Tondella ML, Bajpai A, Mathew AG, Mehranpour P, Li W, Kacharava AG, Fields BS, Austin H, Zafari AM. Circulating *Chlamydia pneumoniae* DNA and advanced coronary artery disease. *Int J Cardiol* 2007; **118**: 215-219 [PMID: 17023075 DOI: 10.1016/j.ijcard.2006.07.013]
  - 24 **Di Pietro M**, Schiavoni G, Sessa V, Pallotta F, Costanzo G, Sessa R. *Chlamydia pneumoniae* and osteoporosis-associated bone loss: a new risk factor? *Osteoporos Int* 2013; **24**: 1677-1682 [PMID: 23160916 DOI: 10.1007/s00198-012-2217-1]
  - 25 **Di Pietro M**, Filardo S, Cazzavillan S, Segala C, Bevilacqua P, Bonoldi E, D'Amore ES, Rassu M, Sessa R. Could past *Chlamydia* vascular infection promote the dissemination of *Chlamydia pneumoniae* to the brain? *J Biol Regul Homeost Agents* 2013; **27**: 155-164 [PMID: 23489695]
  - 26 **Schoborg RV**. *Chlamydia* persistence -- a tool to dissect *chlamydia*-host interactions. *Microbes Infect* 2011; **13**: 649-662 [PMID: 21458583 DOI: 10.1016/j.micinf.2011.03.004]
  - 27 **Di Pietro M**, Tramonti A, De Santis F, De Biase D, Schiavoni G, Filardo S, Zagaglia C, Sessa R. Analysis of gene expression in penicillin G induced persistence of *Chlamydia pneumoniae*. *J Biol Regul Homeost Agents* 2012; **26**: 277-284 [PMID: 22824742]
  - 28 **Di Pietro M**, De Santis F, De Biase D, Sessa R. The elusive but pathogenic peptidoglycan of *Chlamydiae*. *Eur J Inflamm* 2013; **11**: 257-260
  - 29 **Di Pietro M**, Filardo S, De Santis F, Sessa R. New insights into *Chlamydiae* persistence: an energy metabolism strategy? *Int J Immunopathol Pharmacol* 2013; **26**: 525-528 [PMID: 23755769]
  - 30 **Sessa R**, Di Pietro M, Santino I, del Piano M, Varveri A, Dagianti A, Penco M. *Chlamydia pneumoniae* infection and atherosclerotic coronary disease. *Am Heart J* 1999; **137**: 1116-1119 [PMID: 10347340]
  - 31 **Sessa R**, Nicoletti M, Di Pietro M, Schiavoni G, Santino I, Zagaglia C, Del Piano M, Cipriani P. *Chlamydia pneumoniae* and atherosclerosis: current state and future perspectives. *Int J Immunopathol Pharmacol* 2009; **22**: 9-14 [PMID: 19309547]
  - 32 **Joshi R**, Khandelwal B, Joshi D, Gupta OP. *Chlamydia pneumoniae* infection and cardiovascular disease. *N Am J Med Sci* 2013; **5**: 169-181 [PMID: 23626952 DOI: 10.4103/1947-2714.109178]
  - 33 **Sessa R**, Di Pietro M, Schiavoni G, Santino I, Benedetti-Valentini F, Perna R, Romano S, del Piano M. *Chlamydia pneumoniae* DNA in patients with symptomatic carotid atherosclerotic disease. *J Vasc Surg* 2003; **37**: 1027-1031 [PMID: 12756349 DOI: 10.1067/mva.2003.200]
  - 34 **Chen S**, Shimada K, Zhang W, Huang G, Crother TR, Arditi M. IL-17A is proatherogenic in high-fat diet-induced and *Chlamydia pneumoniae* infection-accelerated atherosclerosis in mice. *J Immunol* 2010; **185**: 5619-5627 [PMID: 20935201 DOI: 10.4049/jimmunol.1001879]
  - 35 **Di Pietro M**, Schiavoni G, Del Piano M, Shaik Y, Boscolo P, Caraffa A, Teté S, Conti F, Sessa R. *Chlamydia pneumoniae* and atherosclerosis: the role of mast cells. *J Biol Regul Homeost Agents* 2009; **23**: 65-69 [PMID: 19589286]
  - 36 **Di Pietro M**, Filardo S, De Santis F, Sessa R. *Chlamydia pneumoniae* infection in atherosclerotic lesion development through oxidative stress: a brief overview. *Int J Mol Sci* 2013; **14**: 15105-15120 [PMID: 23877837 DOI: 10.3390/ijms140715105]
  - 37 **Castillo DM**, Sánchez-Beltrán MC, Castellanos JE, Sanz I, Mayorga-Fayad I, Sanz M, Lafaurie GI. Detection of specific periodontal microorganisms from bacteraemia samples after periodontal therapy using molecular-based diagnostics. *J Clin Periodontol* 2011; **38**: 418-427 [PMID: 21392048 DOI: 10.1111/j.1600-051X.2011.01717.x]
  - 38 **Kozarov EV**, Dorn BR, Shelburne CE, Dunn WA, Prohulske-Fox A. Human atherosclerotic plaque contains viable invasive *Actinobacillus actinomycetemcomitans* and *Porphyromonas gingivalis*. *Arterioscler Thromb Vasc Biol* 2005; **25**: e17-e18 [PMID: 15662025]



- 39 **Hayashi C**, Viereck J, Hua N, Phinikaridou A, Madrigal AG, Gibson FC, Hamilton JA, Genco CA. Porphyromonas gingivalis accelerates inflammatory atherosclerosis in the innominate artery of ApoE deficient mice. *Atherosclerosis* 2011; **215**: 52-59 [PMID: 21251656 DOI: 10.1016/j.atherosclerosis.2010]
- 40 **Brodala N**, Merricks EP, Bellinger DA, Damrongsri D, Ofenbacher S, Beck J, Madianos P, Sotres D, Chang YL, Koch G, Nichols TC. Porphyromonas gingivalis bacteremia induces coronary and aortic atherosclerosis in normocholesterolemic and hypercholesterolemic pigs. *Arterioscler Thromb Vasc Biol* 2005; **25**: 1446-1451 [PMID: 15845905 DOI: 10.1161/01.ATV.0000167525.69400.9c]
- 41 **Rodrigues PH**, Reyes L, Chadda AS, Bélanger M, Wallet SM, Akin D, Dunn W, Progulske-Fox A. Porphyromonas gingivalis strain specific interactions with human coronary artery endothelial cells: a comparative study. *PLoS One* 2012; **7**: e52606 [PMID: 23300720 DOI: 10.1371/journal.pone.0052606]
- 42 **Shaik-Dasthagirisahab YB**, Huang N, Baer MT, Gibson FC. Role of MyD88-dependent and MyD88-independent signaling in Porphyromonas gingivalis-elicited macrophage foam cell formation. *Mol Oral Microbiol* 2013; **28**: 28-39 [PMID: 23194377 DOI: 10.1111/omi.12003]
- 43 **Christodoulou DK**, Milonis HJ, Pappa P, Katsanos KH, Sigounas D, Florentin M, Elisaf M, Tsianos EV. Association of Helicobacter pylori infection with cardiovascular disease-is it just a myth? *Eur J Intern Med* 2011; **22**: 191-194 [PMID: 21402252 DOI: 10.1016/j.ejim.2010.11.010]
- 44 **Park MJ**, Choi SH, Kim D, Kang SJ, Chung SJ, Choi SY, Yoon DH, Lim SH, Kim YS, Yim JY, Kim JS, Jung HC. Association between Helicobacter pylori Seropositivity and the Coronary Artery Calcium Score in a Screening Population. *Gut Liver* 2011; **5**: 321-327 [PMID: 21927661 DOI: 10.5009/gnl.2011.5.3.321]
- 45 **Schöttker B**, Adamu MA, Weck MN, Müller H, Brenner H. Helicobacter pylori infection, chronic atrophic gastritis and major cardiovascular events: a population-based cohort study. *Atherosclerosis* 2012; **220**: 569-574 [PMID: 22189198 DOI: 10.1016/j.atherosclerosis.2011.11.029]
- 46 **Chen Y**, Segers S, Blaser MJ. Association between Helicobacter pylori and mortality in the NHANES III study. *Gut* 2013; **62**: 1262-1269 [PMID: 23303440 DOI: 10.1136/gutjnl-2012-303018]
- 47 **Rogha M**, Nikvarz M, Pourmoghaddas Z, Shirneshan K, Dadkhah D, Pourmoghaddas M. Is helicobacter pylori infection a risk factor for coronary heart disease? *ARYA Atheroscler* 2012; **8**: 5-8 [PMID: 23056092]
- 48 **Reunanen A**, Roivainen M, Kleemola M. Increased titer of antibodies to Mycoplasma pneumoniae may be associated with coronary heart disease. *Atherosclerosis* 2005; **180**: 209-210 [PMID: 15823295 DOI: 10.1046/j.1365-2796.2002.01052.x]
- 49 **Daxböck F**, Assadian A, Watkins-Riedel T, Assadian O. Persistently elevated IgA antibodies to Mycoplasma pneumoniae in patients with internal carotid artery stenosis. *GMS Krankenhhyg Interdiszip* 2011; **6**: Doc04 [PMID: 22242085 DOI: 10.3205/dgkh000161]
- 50 **Benditt EP**, Barrett T, McDougall JK. Viruses in the etiology of atherosclerosis. *Proc Natl Acad Sci USA* 1983; **80**: 6386-6389 [PMID: 6312457]
- 51 **Van Dam-Mieras MC**, Bruggeman CA, Muller AD, Debie WH, Zwaal RF. Induction of endothelial cell procoagulant activity by cytomegalovirus infection. *Thromb Res* 1987; **47**: 69-75 [PMID: 2821649]
- 52 **Melnick JL**, Petrie BL, Dreesman GR, Burek J, McCollum CH, DeBakey ME. Cytomegalovirus antigen within human arterial smooth muscle cells. *Lancet* 1983; **2**: 644-647 [PMID: 6136795 DOI: 10.1016/S0140-6736(83)92529-1]
- 53 **Yi L**, Wang DX, Feng ZJ. Detection of human cytomegalovirus in atherosclerotic carotid arteries in humans. *J Formos Med Assoc* 2008; **107**: 774-781 [PMID: 18926944 DOI: 10.1016/S0929-6646(08)60190-4]
- 54 **Xenaki E**, Hassoulas J, Apostolakis S, Sourvinos G, Spanidos DA. Detection of cytomegalovirus in atherosclerotic plaques and nonatherosclerotic arteries. *Angiology* 2009; **60**: 504-508 [DOI: 10.1177/0003319708322390]
- 55 **Hendrix MG**, Salimans MM, van Boven CP, Bruggeman CA. High prevalence of latently present cytomegalovirus in arterial walls of patients suffering from grade III atherosclerosis. *Am J Pathol* 1990; **136**: 23-28 [PMID: 2153348]
- 56 **Adam E**, Melnick JL, Probstfield JL, Petrie BL, Burek J, Bailey KR, McCollum CH, DeBakey ME. High levels of cytomegalovirus antibody in patients requiring vascular surgery for atherosclerosis. *Lancet* 1987; **2**: 291-293 [PMID: 2886763 DOI: 10.1016/S0140-6736(87)90888-9]
- 57 **Ji YN**, An L, Zhan P, Chen XH. Cytomegalovirus infection and coronary heart disease risk: a meta-analysis. *Mol Biol Rep* 2012; **39**: 6537-6546 [PMID: 22311014 DOI: 10.1007/s11033-012-1482-6]
- 58 **Mendy A**, Vieira ER, Gasana J. Seropositivity to herpes simplex virus type 2, but not type 1 is associated with premature cardiovascular diseases: a population-based cross-sectional study. *Atherosclerosis* 2013; **231**: 18-21 [PMID: 24125404 DOI: 10.1016/j.atherosclerosis.2013.08.020]
- 59 **Raza-Ahmad A**, Klassen GA, Murphy DA, Sullivan JA, Kinley CE, Landymore RW, Wood JR. Evidence of type 2 herpes simplex infection in human coronary arteries at the time of coronary artery bypass surgery. *Can J Cardiol* 1995; **11**: 1025-1029 [PMID: 8542544]
- 60 **Madjid M**, Naghavi M, Litovsky S, Casscells SW. Influenza and cardiovascular disease: a new opportunity for prevention and the need for further studies. *Circulation* 2003; **108**: 2730-2736 [PMID: 14610013 DOI: 10.1161/01.CIR.0000102380.47012.92]
- 61 **Lavallée P**, Perchaud V, Gautier-Bertrand M, Grabli D, Amarenco P. Association between influenza vaccination and reduced risk of brain infarction. *Stroke* 2002; **33**: 513-518 [PMID: 11823662 DOI: 10.1161/hs0202.102328]
- 62 **Guan X**, Yang W, Sun X, Wang L, Ma B, Li H, Zhou J. Association of influenza virus infection and inflammatory cytokines with acute myocardial infarction. *Inflamm Res* 2012; **61**: 591-598 [PMID: 22373653 DOI: 10.1007/s00011-012-0449-3]
- 63 **Zhu J**, Quyyumi AA, Norman JE, Costello R, Csako G, Epstein SE. The possible role of hepatitis A virus in the pathogenesis of atherosclerosis. *J Infect Dis* 2000; **182**: 1583-1587 [PMID: 11069227 DOI: 10.1086/3171613]
- 64 **Alyan O**, Kacmaz F, Ozdemir O, Deveci B, Astan R, Celebi AS, Ilkay E. Hepatitis C infection is associated with increased coronary artery atherosclerosis defined by modified Reardon severity score system. *Circ J* 2008; **72**: 1960-1965 [PMID: 18957787 DOI: 10.1253/circj.CJ-08-0459]
- 65 **Ishizaka N**, Ishizaka Y, Takahashi E, Toda Ei E, Hashimoto H, Ohno M, Nagai R, Yamakado M. Increased prevalence of carotid atherosclerosis in hepatitis B virus carriers. *Circulation* 2002; **105**: 1028-1030 [PMID: 11877348]
- 66 **Cainelli F**, Concia E, Vento S. Hepatitis A virus infection and atherosclerosis. *J Infect Dis* 2001; **184**: 390-391 [PMID: 11443571]
- 67 **Boddi M**, Abbate R, Chellini B, Giusti B, Giannini C, Pratesi G, Rossi L, Pratesi C, Gensini GF, Paperetti L, Zignego AL. Hepatitis C virus RNA localization in human carotid plaques. *J Clin Virol* 2010; **47**: 72-75 [PMID: 19896417 DOI: 10.1016/j.jcv.2009.10.005]
- 68 **Boddi M**, Abbate R, Chellini B, Giusti B, Solazzo V, Soft F, Pratesi G, Pratesi C, Gensini G, Zignego AL. HCV infection facilitates asymptomatic carotid atherosclerosis: preliminary report of HCV RNA localization in human carotid plaques. *Dig Liver Dis* 2007; **39** Suppl 1: S55-S60 [PMID: 17936225 DOI: 10.1016/S1590-8658(07)80012-0]
- 69 **Ishizaka Y**, Ishizaka N, Takahashi E, Unuma T, Tooda E, Hashimoto H, Nagai R, Yamakado M. Association between hepatitis C virus core protein and carotid atherosclerosis.



- Circ J* 2003; **67**: 26-30 [PMID: 12520147 DOI: 10.1253/circ.67.26]
- 70 **Weinman SA**, Belalcazar LM. Hepatitis C: a metabolic liver disease. *Gastroenterology* 2004; **126**: 917-919 [PMID: 14988846 DOI: 10.1053/j.gastro.2003.01.001]
  - 71 **Kawaguchi T**, Izumi N, Charlton MR, Sata M. Branched-chain amino acids as pharmacological nutrients in chronic liver disease. *Hepatology* 2011; **54**: 1063-1070 [PMID: 21563202 DOI: 10.1002/hep.24412]
  - 72 **Miyazaki T**, Honda A, Ikegami T, Saitoh Y, Hirayama T, Hara T, Doy M, Matsuzaki Y. Hepatitis C virus infection causes hypolipidemia regardless of hepatic damage or nutritional state: An epidemiological survey of a large Japanese cohort. *Hepatol Res* 2011; **41**: 530-541 [PMID: 21501354 DOI: 10.1111/j.1872-034X.2011.00803.x]
  - 73 **Mostafa A**, Mohamed MK, Saeed M, Hasan A, Fontanet A, Godslan I, Coady E, Esmat G, El-Hoseiny M, Abdul-Hamid M, Hughes A, Chaturvedi N. Hepatitis C infection and clearance: impact on atherosclerosis and cardiometabolic risk factors. *Gut* 2010; **59**: 1135-1140 [PMID: 20584782 DOI: 10.1136/gut.2009.202317]
  - 74 **Ishizaka N**, Ishizaka Y, Takahashi E, Tooda Ei, Hashimoto H, Nagai R, Yamakado M. Association between hepatitis C virus seropositivity, carotid-artery plaque, and intima-media thickening. *Lancet* 2002; **359**: 133-135 [PMID: 11809259 DOI: 10.1016/S0140-6736(02)07339-7]
  - 75 **Yang KC**, Chen MF, Su TC, Jeng JS, Hwang BS, Lin LY, Liao CS, Lee YT. Hepatitis B virus seropositivity is not associated with increased risk of carotid atherosclerosis in Taiwanese. *Atherosclerosis* 2007; **195**: 392-397 [PMID: 17134707 DOI: 10.1016/j.atherosclerosis.2006.10.018]
  - 76 **Roed T**, Lebech AM, Kjaer A, Weis N. Hepatitis C virus infection and risk of coronary artery disease: a systematic review of the literature. *Clin Physiol Funct Imaging* 2012; **32**: 421-430 [PMID: 23031062 DOI: 10.1111/j.1475-097X.2012.01152.x]
  - 77 **Miyajima I**, Kawaguchi T, Fukami A, Nagao Y, Adachi H, Sasaki S, Imaizumi T, Sata M. Chronic HCV infection was associated with severe insulin resistance and mild atherosclerosis: a population-based study in an HCV hyperendemic area. *J Gastroenterol* 2013; **48**: 93-100 [PMID: 22678465 DOI: 10.1007/s00535-012-0610-3]
  - 78 **Hsue PY**, Lo JC, Franklin A, Bolger AF, Martin JN, Deeks SG, Waters DD. Progression of atherosclerosis as assessed by carotid intima-media thickness in patients with HIV infection. *Circulation* 2004; **109**: 1603-1608 [PMID: 15023877 DOI: 10.1161/01.CIR.0000124480.32233.8A]
  - 79 **Thiébaud R**, Aurillac-Lavignolle V, Bonnet F, Ibrahim N, Cipriano C, Neau D, Dupon M, Dabis F, Mercié P. Change in atherosclerosis progression in HIV-infected patients: ANRS Aquitaine Cohort, 1999-2004. *AIDS* 2005; **19**: 729-731 [PMID: 15821400]
  - 80 **Jerico C**, Knobel H, Calvo N, Sorli ML, Guelar A, Gimeno-Bayón JL, Saballs P, López-Colomé JL, Pedro-Botet J. Subclinical carotid atherosclerosis in HIV-infected patients: role of combination antiretroviral therapy. *Stroke* 2006; **37**: 812-817 [PMID: 16439699 DOI: 10.1161/01.STR.0000204037.26797.7f]
  - 81 **Lang S**, Mary-Krause M, Simon A, Partisani M, Gilquin J, Cotte L, Boccara F, Costagliola D. HIV replication and immune status are independent predictors of the risk of myocardial infarction in HIV-infected individuals. *Clin Infect Dis* 2012; **55**: 600-607 [PMID: 22610928 DOI: 10.1093/cid/cis489]
  - 82 **Currier JS**, Kendall MA, Zackin R, Henry WK, Alston-Smith B, Torriani FJ, Schouten J, Mickelberg K, Li Y, Hodis HN. Carotid artery intima-media thickness and HIV infection: traditional risk factors overshadow impact of protease inhibitor exposure. *AIDS* 2005; **19**: 927-933 [PMID: 15905673]
  - 83 **Hultén E**, Mitchell J, Scally J, Gibbs B, Villines TC. HIV positivity, protease inhibitor exposure and subclinical atherosclerosis: a systematic review and meta-analysis of observational studies. *Heart* 2009; **95**: 1826-1835 [PMID: 19632982 DOI: 10.1136/hrt.2009.177774]
  - 84 **Stein JH**, Klein MA, Bellehumeur JL, McBride PE, Wiebe DA, Otvos JD, Sosman JM. Use of human immunodeficiency virus-1 protease inhibitors is associated with atherogenic lipoprotein changes and endothelial dysfunction. *Circulation* 2001; **104**: 257-262 [PMID: 11457741]
  - 85 **Badiou S**, Merle De Boever C, Dupuy AM, Baillat V, Cristol JP, Reynes J. Decrease in LDL size in HIV-positive adults before and after lopinavir/ritonavir-containing regimen: an index of atherogenicity? *Atherosclerosis* 2003; **168**: 107-113 [PMID: 12732393 DOI: 10.1016/S0021-9150(03)00058-3]
  - 86 **Asztalos BF**, Schaefer EJ, Horvath KV, Cox CE, Skinner S, Gerrior J, Gorbach SL, Wanke C. Protease inhibitor-based HAART, HDL, and CHD-risk in HIV-infected patients. *Atherosclerosis* 2006; **184**: 72-77 [PMID: 15935358 DOI: 10.1016/j.atherosclerosis.2005.04.013]
  - 87 **Duffy P**, Wang X, Lin PH, Yao Q, Chen C. HIV Nef protein causes endothelial dysfunction in porcine pulmonary arteries and human pulmonary artery endothelial cells. *J Surg Res* 2009; **156**: 257-264 [PMID: 19540523 DOI: 10.1016/j.jss.2009.02.005]
  - 88 **Hsue PY**, Hunt PW, Schnell A, Kalapus SC, Hoh R, Ganz P, Martin JN, Deeks SG. Role of viral replication, antiretroviral therapy, and immunodeficiency in HIV-associated atherosclerosis. *AIDS* 2009; **23**: 1059-1067 [PMID: 19390417 DOI: 10.1097/QAD.0b013e32832b514b]
  - 89 **Desvarieux M**, Boccara F, Meynard JL, Bastard JP, Mallat Z, Charbit B, Demmer RT, Haddour N, Fellahi S, Tedgui A, Cohen A, Capeau J, Boyd A, Girard PM. Infection duration and inflammatory imbalance are associated with atherosclerotic risk in HIV-infected never-smokers independent of antiretroviral therapy. *AIDS* 2013; **27**: 2603-2614 [PMID: 24100713 DOI: 10.1097/QAD.0b013e3283634819]
  - 90 **Jackson L**, Britton J, Lewis SA, McKeever TM, Atherton J, Fullerton D, Fogarty AW. A population-based epidemiologic study of *Helicobacter pylori* infection and its association with systemic inflammation. *Helicobacter* 2009; **14**: 108-113 [PMID: 19751435 DOI: 10.1111/j.1523-5378.2009.00711.x]
  - 91 **Rogha M**, Dadkhah D, Pourmoghaddas Z, Shirneshan K, Nikvarz M, Pourmoghaddas M. Association of *Helicobacter pylori* infection with severity of coronary heart disease. *ARYA Atheroscler* 2012; **7**: 138-141 [PMID: 23205045]
  - 92 **Schiavoni G**, Di Pietro M, Ronco C, De Cal M, Cazzavillan S, Rattu M, Nicoletti M, Del Piano M, Sessa R. Chlamydia pneumoniae infection as a risk factor for accelerated atherosclerosis in hemodialysis patients. *J Biol Regul Homeost Agents* 2010; **24**: 367-375 [PMID: 20846485]
  - 93 **Pejic L**, Kesic LJ, Milasin J. C-reactive protein as a systemic marker of inflammation in periodontitis. *Eur J Clin Microbiol Infect Dis* 2011; **30**: 407-414 [PMID: 21057970 DOI: 10.1007/s10096-010-1101-1]
  - 94 **Campbell LA**, Yaraei K, Van Lenten B, Chait A, Blessing E, Kuo CC, Nosaka T, Ricks J, Rosenfeld ME. The acute phase reactant response to respiratory infection with *Chlamydia pneumoniae*: implications for the pathogenesis of atherosclerosis. *Microbes Infect* 2010; **12**: 598-606 [PMID: 20417302 DOI: 10.1016/j.micinf.2010.04.001]
  - 95 **Kebschull M**, Demmer RT, Papapanou PN. "Gum bug, leave my heart alone!"--epidemiologic and mechanistic evidence linking periodontal infections and atherosclerosis. *J Dent Res* 2010; **89**: 879-902 [PMID: 20639510 DOI: 10.1177/0022034510375281]
  - 96 **Roivainen M**, Viik-Kajander M, Palosuo T, Toivanen P, Leinonen M, Saikku P, Tenkanen L, Manninen V, Hovi T, Mänttari M. Infections, inflammation, and the risk of coronary heart disease. *Circulation* 2000; **101**: 252-257 [PMID: 10645920]
  - 97 **Okada T**, Ayada K, Usui S, Yokota K, Cui J, Kawahara Y, Inaba T, Hirohata S, Mizuno M, Yamamoto D, Kusachi S, Matsuura E, Oguma K. Antibodies against heat shock protein 60

- derived from *Helicobacter pylori*: diagnostic implications in cardiovascular disease. *J Autoimmun* 2007; **29**: 106-115 [PMID: 17606364 DOI: 10.1016/j.jaut.2007.05.004]
- 98 **Choi J**, Lee SY, Kim K, Choi BK. Identification of immunoreactive epitopes of the *Porphyromonas gingivalis* heat shock protein in periodontitis and atherosclerosis. *J Periodontol Res* 2011; **46**: 240-245 [PMID: 21241301 DOI: 10.1111/j.1600-0765.2010.01339.x]
  - 99 **Kreutmayer S**, Csordas A, Kern J, Maass V, Almanzar G, Offtendering M, Öllinger R, Maass M, Wick G. Chlamydia pneumoniae infection acts as an endothelial stressor with the potential to initiate the earliest heat shock protein 60-dependent inflammatory stage of atherosclerosis. *Cell Stress Chaperones* 2013; **18**: 259-268 [PMID: 23192457 DOI: 10.1007/s12192-012-0378-7]
  - 100 **Andrié RP**, Bauriedel G, Braun P, Höpp HW, Nickenig G, Skowasch D. Prevalence of intimal heat shock protein 60 homologues in unstable angina and correlation with anti-heat shock protein antibody titers. *Basic Res Cardiol* 2011; **106**: 657-665 [PMID: 21416407 DOI: 10.1007/s00395-011-0171-2]
  - 101 **Ausiello CM**, Palazzo R, Spensieri F, Fedele G, Lande R, Ciervo A, Fioroni G, Cassone A. 60-kDa heat shock protein of *Chlamydia pneumoniae* is a target of T-cell immune response. *J Biol Regul Homeost Agents* 2005; **19**: 136-140 [PMID: 16602628]
  - 102 **Ford P**, Gemmell E, Walker P, West M, Cullinan M, Seymour G. Characterization of heat shock protein-specific T cells in atherosclerosis. *Clin Diagn Lab Immunol* 2005; **12**: 259-267 [PMID: 15699420 DOI: 10.1128/CDLI.12.2.259-267.2005]
  - 103 **Ayada K**, Yokota K, Hirai K, Fujimoto K, Kobayashi K, Oga-wa H, Hatanaka K, Hirohata S, Yoshino T, Shoenfeld Y, Mat-suura E, Oguma K. Regulation of cellular immunity prevents *Helicobacter pylori*-induced atherosclerosis. *Lupus* 2009; **18**: 1154-1168 [PMID: 19880562 DOI: 10.1177/0961203309106600]
  - 104 **Speir E**, Modali R, Huang ES, Leon MB, Shawl F, Finkel T, Epstein SE. Potential role of human cytomegalovirus and p53 interaction in coronary restenosis. *Science* 1994; **265**: 391-394 [PMID: 8023160]
  - 105 **Dengler TJ**, Raftery MJ, Werle M, Zimmermann R, Schön-rich G. Cytomegalovirus infection of vascular cells induces expression of pro-inflammatory adhesion molecules by para-crine action of secreted interleukin-1beta. *Transplantation* 2000; **69**: 1160-1168 [PMID: 10762222]
  - 106 **Rahbar A**, Söderberg-Nauclér C. Human cytomegalovirus infection of endothelial cells triggers platelet adhesion and aggregation. *J Virol* 2005; **79**: 2211-2220 [PMID: 15681423 DOI: 10.1128/JVI.79.4.2211-2220.2005]
  - 107 **Naghavi M**, Wyde P, Litovsky S, Madjid M, Akhtar A, Na-guib S, Siadaty MS, Sanati S, Casscells W. Influenza infection exerts prominent inflammatory and thrombotic effects on the atherosclerotic plaques of apolipoprotein E-deficient mice. *Circulation* 2003; **107**: 762-768 [PMID: 12578882 DOI: 10.1161/01.CIR.0000048190.68071.2B]
  - 108 **Naghavi M**, Barlas Z, Siadaty S, Naguib S, Madjid M, Cass-cells W. Association of influenza vaccination and reduced risk of recurrent myocardial infarction. *Circulation* 2000; **102**: 3039-3045 [PMID: 11120692]
  - 109 **Blake GJ**, Ridker PM. Novel clinical markers of vascular wall inflammation. *Circ Res* 2001; **89**: 763-771 [PMID: 11679405]
  - 110 **Petty GW**, Duffy J, Houston J. Cerebral ischemia in patients with hepatitis C virus infection and mixed cryoglobulinemia. *Mayo Clin Proc* 1996; **71**: 671-678 [PMID: 8656709]
  - 111 **Capra F**, De Maria E, Lunardi C, Marchiori L, Mezzelani P, Beri R, Gabrielli GB. Serum level of soluble intercellular adhesion molecule 1 in patients with chronic liver disease related to hepatitis C virus: A prognostic marker for responses to interferon treatment. *J Infect Dis* 2000; **181**: 425-431 [PMID: 10669322 DOI: 10.1086/315265]
  - 112 **Cacoub P**, Ghillani P, Revelen R, Thibault V, Calvez V, Charlotte F, Musset L, Youinou P, Piette JC. Anti-endothelial cell auto-antibodies in hepatitis C virus mixed cryoglobulinemia. *J Hepatol* 1999; **31**: 598-603 [PMID: 10551381 DOI: 10.1016/S0168-8278(99)80337-7]
  - 113 **Shrestha S**, Irvin MR, Grunfeld C, Arnett DK. HIV, inflammation, and calcium in atherosclerosis. *Arterioscler Thromb Vasc Biol* 2014; **34**: 244-250 [PMID: 24265418 DOI: 10.1161/ATVBAHA.113.302191]
  - 114 **Khor CC**, Hibberd ML. Host-pathogen interactions revealed by human genome-wide surveys. *Trends Genet* 2012; **28**: 233-243 [PMID: 22445588 DOI: 10.1016/j.tig.2012.02.001]
  - 115 **Georges JL**, Rupprecht HJ, Blankenberg S, Poirier O, Bickel C, Hafner G, Nicaud V, Meyer J, Cambien F, Tiret L. Impact of pathogen burden in patients with coronary artery disease in relation to systemic inflammation and variation in genes encoding cytokines. *Am J Cardiol* 2003; **92**: 515-521 [PMID: 12943869 DOI: 10.1016/S0002-9149(03)00717-3]
  - 116 **Westhorpe CL**, Maisa A, Spelman T, Hoy JF, Dewar EM, Karapanagiotidis S, Hearps AC, Cheng WJ, Trevillyan J, Lewin SR, Sviridov D, Elliott JH, Jaworowski A, Dart AM, Crowe SM. Associations between surface markers on blood monocytes and carotid atherosclerosis in HIV-positive individuals. *Immunol Cell Biol* 2014; **92**: 133-138 [PMID: 24296810 DOI: 10.1038/icb.2013.84]

P- Reviewers: He JY, Stover CM S- Editor: Song XX

L- Editor: A E- Editor: Wu HL



## Is there a role for fish oil in inflammatory bowel disease?

Affifa Farrukh, John Francis Mayberry

Affifa Farrukh, John Francis Mayberry, Department of Digestive Diseases, University Hospitals of Leicester NHS Trust, Leicester General Hospital, Leicester LE5 4PW, United Kingdom

**Author contributions:** Both authors made substantial contributions to conception and design, acquisition of data, or analysis and interpretation of data; drafted the article and revised it critically for important intellectual content; and final approval of this version to be published.

**Correspondence to:** Dr. Affifa Farrukh, Department of Digestive Diseases, University Hospitals of Leicester NHS Trust, Leicester General Hospital, Gwendolen Road, Leicester LE5 4PW, United Kingdom. [anupvora@gmail.com](mailto:anupvora@gmail.com)

Telephone: +44-01-162584787 Fax: +44-01-162584787

Received: April 5, 2014 Revised: May 2, 2014

Accepted: June 10, 2014

Published online: July 16, 2014

### Abstract

A number of animal and human studies suggest omega 3-fatty acids are anti-inflammatory. As a result they may have a therapeutic role in inflammatory bowel disease (IBD). The aim of this review is to briefly assess the literature about the utility of poly-unsaturated fatty acids (PUFAs) in the management of IBD. Taken together, almost all studies suggest some beneficial effects of n-3 PUFAs in IBD but the mechanism remains controversial. In addition, clinical benefit seems to be largely confined to ulcerative colitis. However all studies have concluded that these compounds have no potential for a steroid/aminosalicylic acid sparing effect or to maintain remission. Now the question arises as to whether this treatment is of real value to IBD patients? Clearly they have some therapeutic potential but further work is needed.

© 2014 Baishideng Publishing Group Inc. All rights reserved.

**Key words:** Fish oil; Ulcerative colitis; Crohn's disease; Treatment; n-3 poly-unsaturated fatty acids

**Core tip:** Fish oil supplements are probably of benefit to

patients with ulcerative colitis. They have a much less certain role in Crohn's disease.

Farrukh A, Mayberry JF. Is there a role for fish oil in inflammatory bowel disease? *World J Clin Cases* 2014; 2(7): 250-252 Available from: URL: <http://www.wjgnet.com/2307-8960/full/v2/i7/250.htm> DOI: <http://dx.doi.org/10.12998/wjcc.v2.i7.250>

### INTRODUCTION

Both animal and clinical work suggest that omega 3-fatty acids are anti-inflammatory in their action and so have the potential to be of use in the treatment of inflammatory bowel disease (IBD). In particular, they appeal to patients who see them as both safe and natural. The purpose of this review is to survey the literature and assess the utility of poly-unsaturated fatty acids (PUFAs) in the management of IBD.

### THE UTILITY OF PUFAS IN THE MANAGEMENT OF IBD

The aetiology of IBD remains unclear but local mediators including arachidonic acid metabolites, cytokines and altered cell mediated immunity are likely to contribute to the disease. The rationale for the prescription of n-3 PUFA to promote a healthy gastrointestinal tract has been linked to their suggested anti-inflammatory properties. Different strategies have been adopted in various clinical trials to evaluate n-3 PUFA in patients with IBD. Inhibition of natural cytotoxicity, changes in interleukin 2 (IL-2) and arachidonic acid metabolites, *e.g.*, LTB<sub>4</sub> are the main chemotactic signals seen in the mucosa during a relapse. All are known to mediate the natural killer activity. A second hypothesis is based on the possible deficiency of essential fatty acids (EFAs) in IBD and its effect on cell membranes<sup>[1]</sup>. A further possibility is that fish oil ameliorates oxidative stress in IBD.

In a randomised crossover trial from four units which

involved 18 patients with ulcerative colitis (UC) fish oil supplements reduced LTB<sub>4</sub> levels in a rectal dialysate. Histology improved and patients' weight increased<sup>[2]</sup>.

Conversely, a small Canadian trial of 11 patients found that addition of fish oil was of clinical benefit in UC but did not reduce mucosal LTB<sub>4</sub><sup>[3]</sup>. However, over a six month period serum LTB<sub>4</sub> was insignificant while there was a simultaneous fall in NK cell cytotoxicity<sup>[4]</sup>.

An American study of 47 patients with long-standing bowel problems looked at the frequency of essential fatty acid deficiency. The majority had Crohn's disease. Compared to 56 control subjects, patients' metabolism was comparable to that seen in essential fatty acid deficiency (EFAD). Patients had: (1) 7% lower PUFA levels; (2) Lower concentrations of saturated and monounsaturated fatty acids.

The authors suggested patients with IBD should be assessed for EFAD and receive significant quantities of supplements with a high EFA content<sup>[5]</sup>. In contrast, a Japanese study found that EFAD rarely occurs in Crohn's disease<sup>[6]</sup>. A United Kingdom prospective study based on 26000 recruits living in Norfolk showed that total dietary n-3PUFAs, eicosapentaenoic acid and docosahexaenoic acid were associated with a reduced risk of ulcerative colitis<sup>[7]</sup>. This was not found in a small cross-sectional study of 51 patients with inflammatory bowel disease from Hungary<sup>[8]</sup>.

To gauge whether fish oil can reduce oxidative stress in ulcerative colitis a Brazilian crossover study of nine patients on conventional treatment with sulfasalazine also received omega-3 fatty acids or placebo for two months separated by two months. They were compared with nine healthy people. Disease activity was examined through a range of standard serological measures as well as endoscopy and histology. The results showed that fish oil can act as a free radical scavenger and so protect patients<sup>[9]</sup>. The influence of monounsaturated, n-3, and n-3 + n-6 polyunsaturated fatty acids on histology, mucosal defence, mucosal prostaglandin E<sub>2</sub> and LTB<sub>4</sub> in a rat model was investigated in Spain. It concluded that n-3 PUFAs can prevent inflammation but cause a decrease in the colon's defence system leading to oxidative injury<sup>[10]</sup>. Therefore, although it seems likely that these compounds have anti-inflammatory effects, the mechanism by which they achieve this needs further exploration.

There are some important considerations which should be borne in mind before promoting their use in the clinical care of patients with IBD: (1) Do they decrease disease activity? (2) Do they maintain remission? (3) Can they be used as an alternative to steroids or aminosalicylic acid (ASA) compounds?

There are studies which demonstrated a reduction in disease activity with these compounds, *e.g.*, a pilot study in United Kingdom evaluated their effectiveness both in terms of disease activity and histological scores when compared with pre-treatment measures<sup>[11,12]</sup>. In a German trial 5-ASA compounds were stopped in 64 patients who had ulcerative colitis and had been in remission for three months. They received a fish oil supplement and

their clinical course was followed for 24 mo with colonoscopies at the beginning and end of the study. Freedom from disease activity was only seen in two of the 24 mo and the overall relapse rate was similar for active treatment and placebo groups. It seems that n-3 PUFAs can temporarily retard but not prevent relapse in UC<sup>[12]</sup>. Another randomised blinded control study of 87 patients from United Kingdom found fish oil had some benefit. Corticosteroid requirements were reduced for those 53 patients who had active disease on trial entry. Fish oil induced faster remission, although this trend did not reach significance. In contrast there was no difference in relapse rates if patients were in remission. So, it appears fish oil supplementation has a modest benefit in active disease allowing use of smaller doses of corticosteroids. In contrast they seem to have no role in maintenance<sup>[13]</sup>. A randomised controlled multicentre trial of 204 patients with Crohn's disease in Germany confirmed that omega-3 fatty acids had no role in prolonging remission<sup>[14,15]</sup>. Confirmation of the limited benefit in ulcerative colitis and absence of effect in Crohn's disease was first suggested in 1989 in a study of 39 patients<sup>[16]</sup>. The multicentre EPIC study from North America and Europe which included 738 patients with Crohn's disease again confirmed that omega 3 free fatty acids had no role in maintenance<sup>[17]</sup>. Support for such an interpretation comes from 3 systematic reviews<sup>[18-20]</sup>. However, this might not be the case in children and young people. In a study of 38 patients addition of enteric coated omega-3 fatty acids to 5-ASA treatment appeared of benefit<sup>[21]</sup>. Support for their role in Crohn's disease also came from a rigorous trial in 78 patients<sup>[22]</sup>.

Ten patients with moderately active colitis were assessed in a study which used a randomized cross-over methodology. The treatments were either sulfasalazine or omega-3 fatty acids for 2 mo. Response was measured by endoscopic assessment, histological review and whole-body protein turnover. Treatment with omega-3 fatty acids alone led to a less objective improvement than conventional treatment. This shows that for active ulcerative colitis sulfasalazine is better than omega-3 fatty acids<sup>[23]</sup>.

## CONCLUSION

Taken together, almost all studies suggest some beneficial effects of n-3 PUFAs in IBD but the mechanism remains controversial. In addition, clinical benefit seem largely confined to UC. However all studies have concluded that these compounds have no potential for a Steroid/ASA sparing effect or to maintain remission. Now the question arises as to whether this treatment is of real value to IBD patients? Clearly they have some therapeutic potential but further work is needed with larger numbers and more highly powered trials.

## REFERENCES

- 1 Uchiyama K, Nakamura M, Odahara S, Koido S, Katahira K, Shiraishi H, Ohkusa T, Fujise K, Tajiri H. N-3 polyunsatu-



- rated fatty acid diet therapy for patients with inflammatory bowel disease. *Inflamm Bowel Dis* 2010; **16**: 1696-1707 [PMID: 20222122 DOI: 10.1002/ibd.21251]
- 2 **Stenson WE**, Cort D, Rodgers J, Burakoff R, DeSchryver-Kecskemeti K, Gramlich TL, Beeken W. Dietary supplementation with fish oil in ulcerative colitis. *Ann Intern Med* 1992; **116**: 609-614 [PMID: 1312317 DOI: 10.7326/0003-4819-116-8-609]
- 3 **Aslan A**, Triadafilopoulos G. Fish oil fatty acid supplementation in active ulcerative colitis: a double-blind, placebo-controlled, crossover study. *Am J Gastroenterol* 1992; **87**: 432-437 [PMID: 1553930]
- 4 **Almallah YZ**, El-Tahir A, Heys SD, Richardson S, Eremin O. Distal procto-colitis and n-3 polyunsaturated fatty acids: the mechanism(s) of natural cytotoxicity inhibition. *Eur J Clin Invest* 2000; **30**: 58-65 [PMID: 10620003 DOI: 10.1046/j.1365-2362.2000.00581.x]
- 5 **Siguel EN**, Lerman RH. Prevalence of essential fatty acid deficiency in patients with chronic gastrointestinal disorders. *Metabolism* 1996; **45**: 12-23 [PMID: 8544768 DOI: 10.1016/S0026-0495(96)90194-8]
- 6 **Kuroki F**, Iida M, Matsumoto T, Aoyagi K, Kanamoto K, Fujishima M. Serum n3 polyunsaturated fatty acids are depleted in Crohn's disease. *Dig Dis Sci* 1997; **42**: 1137-1141 [PMID: 9201073 DOI: 10.1023/A: 1018873217192]
- 7 **John S**, Luben R, Shrestha SS, Welch A, Khaw KT, Hart AR. Dietary n-3 polyunsaturated fatty acids and the aetiology of ulcerative colitis: a UK prospective cohort study. *Eur J Gastroenterol Hepatol* 2010; **22**: 602-606 [PMID: 20216220 DOI: 10.1097/MEG.0b013e3283352d05]
- 8 **Figler M**, Gasztonyi B, Cseh J, Horváth G, Kisbenedek AG, Bokor S, Decsi T. Association of n-3 and n-6 long-chain polyunsaturated fatty acids in plasma lipid classes with inflammatory bowel diseases. *Br J Nutr* 2007; **97**: 1154-1161 [PMID: 17381967 DOI: 10.1017/S0007114507682956]
- 9 **Barbosa DS**, Cecchini R, El Kadri MZ, Rodríguez MA, Burini RC, Dichi I. Decreased oxidative stress in patients with ulcerative colitis supplemented with fish oil omega-3 fatty acids. *Nutrition* 2003; **19**: 837-842 [PMID: 14559317 DOI: 10.1016/S0899-9007(03)00162-X]
- 10 **Nieto N**, Fernandez MI, Torres MI, Ríos A, Suarez MD, Gil A. Dietary monounsaturated n-3 and n-6 long-chain polyunsaturated fatty acids affect cellular antioxidant defense system in rats with experimental ulcerative colitis induced by trinitrobenzene sulfonic acid. *Dig Dis Sci* 1998; **43**: 2676-2687 [PMID: 9881500 DOI: 10.1023/A: 1026655311878]
- 11 **Almallah YZ**, Richardson S, O'Hanrahan T, Mowat NA, Brunt PW, Sinclair TS, Ewen S, Heys SD, Eremin O. Distal procto-colitis, natural cytotoxicity, and essential fatty acids. *Am J Gastroenterol* 1998; **93**: 804-809 [PMID: 9625132 DOI: 10.1111/j.1572-0241.1998.229\_a.x]
- 12 **Loeschke K**, Ueberschaer B, Pietsch A, Gruber E, Ewe K, Wiebecke B, Heldwein W, Lorenz R. n-3 fatty acids only delay early relapse of ulcerative colitis in remission. *Dig Dis Sci* 1996; **41**: 2087-2094 [PMID: 8888725 DOI: 10.1007/BF02093614]
- 13 **Hawthorne AB**, Daneshmend TK, Hawkey CJ, Belluzzi A, Everitt SJ, Holmes GK, Malkinson C, Shaheen MZ, Willars JE. Treatment of ulcerative colitis with fish oil supplementation: a prospective 12 month randomised controlled trial. *Gut* 1992; **33**: 922-928 [PMID: 1353742 DOI: 10.1136/gut.33.7.922]
- 14 **Frey M**. Behavioral correlates of health and illness in youths with chronic illness. *Appl Nurs Res* 1996; **9**: 167-176 [PMID: 8961573 DOI: 10.1016/S0897-1897(96)80029-2]
- 15 **Lorenz-Meyer H**, Bauer P, Nicolay C, Schulz B, Purrmann J, Fleig WE, Scheurlen C, Koop I, Pudel V, Carr L. Omega-3 fatty acids and low carbohydrate diet for maintenance of remission in Crohn's disease. A randomized controlled multicenter trial. Study Group Members (German Crohn's Disease Study Group). *Scand J Gastroenterol* 1996; **31**: 778-785 [PMID: 8858747 DOI: 10.3109/00365529609010352]
- 16 **Lorenz R**, Weber PC, Szimnau P, Heldwein W, Strasser T, Loeschke K. Supplementation with n-3 fatty acids from fish oil in chronic inflammatory bowel disease--a randomized, placebo-controlled, double-blind cross-over trial. *J Intern Med Suppl* 1989; **731**: 225-232 [PMID: 2650694]
- 17 **Feagan BG**, Sandborn WJ, Mittmann U, Bar-Meir S, D'Haens G, Bradette M, Cohen A, Dallaire C, Ponich TP, McDonald JW, Hébuterne X, Paré P, Klvana P, Niv Y, Ardizzone S, Alexeeva O, Rostom A, Kiudelis G, Spleiss J, Gilgen D, Vandervoort MK, Wong CJ, Zou GY, Donner A, Rutgeerts P. Omega-3 free fatty acids for the maintenance of remission in Crohn disease: the EPIC Randomized Controlled Trials. *JAMA* 2008; **299**: 1690-1697 [PMID: 18398081 DOI: 10.1001/jama.299.14.1690]
- 18 **Cabrè E**, Mañosa M, Gassull MA. Omega-3 fatty acids and inflammatory bowel diseases - a systematic review. *Br J Nutr* 2012; **107** Suppl 2: S240-S252 [PMID: 22591898 DOI: 10.1017/S0007114512001626]
- 19 **Marion-Letellier R**, Savoye G, Beck PL, Panaccione R, Ghosh S. Polyunsaturated fatty acids in inflammatory bowel diseases: a reappraisal of effects and therapeutic approaches. *Inflamm Bowel Dis* 2013; **19**: 650-661 [PMID: 23328774 DOI: 10.1097/MIB.0b013e3182810122]
- 20 **Turner D**, Zlotkin SH, Shah PS, Griffiths AM. Omega 3 fatty acids (fish oil) for maintenance of remission in Crohn's disease. *Cochrane Database Syst Rev* 2007; **18**: CD006320 [PMID: 17443620]
- 21 **Romano C**, Cucchiara S, Barabino A, Annese V, Sferlazzas C. Usefulness of omega-3 fatty acid supplementation in addition to mesalazine in maintaining remission in pediatric Crohn's disease: a double-blind, randomized, placebo-controlled study. *World J Gastroenterol* 2005; **11**: 7118-7121 [PMID: 16437657]
- 22 **Belluzzi A**, Brignola C, Campieri M, Pera A, Boschi S, Miglioli M. Effect of an enteric-coated fish-oil preparation on relapses in Crohn's disease. *N Engl J Med* 1996; **334**: 1557-1560 [PMID: 8628335]
- 23 **Dichi I**, Frenhane P, Dichi JB, Correa CR, Angeleli AY, Bicu-do MH, Rodrigues MA, Victória CR, Burini RC. Comparison of omega-3 fatty acids and sulfasalazine in ulcerative colitis. *Nutrition* 2000; **16**: 87-90 [PMID: 10696629]

**P- Reviewers:** Esmat S, Guslandi M, Matsumoto S, Naito Y

**S- Editor:** Ji FF **L- Editor:** A **E- Editor:** Wu HL



## Critical review of topical management of oral hairy leukoplakia

Cláudia B Brasileiro, Mauro Henrique NG Abreu, Ricardo A Mesquita

Cláudia B Brasileiro, Ricardo A Mesquita, Department of Oral Surgery and Pathology, School of Dentistry, Universidade Federal de Minas Gerais, Pampulha, 31270-901, Belo Horizonte/MG, Brazil

Mauro Henrique NG Abreu, Department of Community and Preventive Dentistry, School of Dentistry, Universidade Federal de Minas Gerais, Pampulha, 31270-901, Belo Horizonte/MG, Brazil  
Author contributions: Mesquita RA and Abreu MHNG were responsible for the concept and review of the manuscript; Brasileiro CB performed research and wrote the manuscript.

Correspondence to: Ricardo A Mesquita, PhD, Department of Oral Surgery and Pathology, School of Dentistry, Universidade Federal de Minas Gerais, sala 3202-D, Av. Antônio Carlos, 6627, Pampulha, 31270-901, Belo Horizonte/MG, Brazil. [ramesquita@ufmg.br](mailto:ramesquita@ufmg.br)

Telephone: +55-31-34092499 Fax: +55-31-34092430

Received: January 28, 2014 Revised: April 2, 2014

Accepted: May 16, 2014

Published online: July 16, 2014

### Abstract

Oral hairy leukoplakia (OHL) is a disease associated with Epstein-Barr virus and human immunodeficiency virus infections. OHL is usually an asymptomatic lesion, but in some cases treatment is recommended to reestablish the normal characteristics of the tongue, to eliminate pathogenic microorganisms, to improve patient comfort and for cosmetic reasons. Proposed treatments for this condition include surgery, systemic antiviral treatment and topical management. Topical treatment is an inexpensive and safe therapy that is easy to apply, noninvasive, free of systemic adverse effects and effective over a long period of time. The aim of this study was to present a review of the literature for topical therapy for OHL. Gentian violet, retinoids, podophyllin, acyclovir and podophyllin associated with topical antiviral drugs were used to treat OHL. Reports with this focus are limited, and since 2010, no new studies have been published that discuss the efficacy of topical treatments for OHL. Podophyllin with acyclovir

cream was found to be effective, causing regression of lesions with no recurrences. Additional searches are necessary to provide clinical evidence of topical management effectiveness.

© 2014 Baishideng Publishing Group Inc. All rights reserved.

**Key words:** Oral hairy leukoplakia; Human immunodeficiency virus infection; Topical treatment; Topical agents; Recurrence rate

**Core tip:** This literature review was performed to assess the evidence for topical treatments for oral hairy leukoplakia (OHL). Although highly active antiretroviral therapy has reduced oral lesions associated with human immunodeficiency virus, prevalence studies revealed that OHL is still observed in patients with HIV infections. Knowledge about appropriate management of this condition is relevant, specifically regarding topical treatments that are less invasive, low-cost, easy to apply and free of systemic adverse effects.

Brasileiro CB, Abreu MHNG, Mesquita RA. Critical review of topical management of oral hairy leukoplakia. *World J Clin Cases* 2014; 2(7): 253-256 Available from: URL: <http://www.wjgnet.com/2307-8960/full/v2/i7/253.htm> DOI: <http://dx.doi.org/10.12998/wjcc.v2.i7.253>

### INTRODUCTION

Oral hairy leukoplakia (OHL) was first described in 1984 by Greenspan *et al*<sup>[1]</sup> and is described as a white plaque generally on the lateral borders of the tongue in patients with human immunodeficiency virus (HIV) that later developed acquired immunodeficiency syndrome (AIDS). Later, other studies confirmed OHL as an early indicator of HIV infection and revealed that this disease may be related to the progression to AIDS. However, OHL

**Table 1 Topical agents used in the treatment of oral hairy leukoplakia and study types**

	Case reports	Case series	Randomized clinical trial
Gentian violet	Bhandarkar <i>et al</i> <sup>[3]</sup>		
Retinoids		Schöfer <i>et al</i> <sup>[11]</sup> Alessi <i>et al</i> <sup>[12]</sup>	
Podophyllin		Lozada-Nur <i>et al</i> <sup>[13]</sup> Sanchez <i>et al</i> <sup>[15]</sup> Gowdey <i>et al</i> <sup>[14]</sup> Ficarra <i>et al</i> <sup>[16]</sup>	
Acyclovir			Moura <i>et al</i> <sup>[2]</sup>
Combined topical therapy (Topical antiviral agents and podophyllin)			Moura <i>et al</i> <sup>[4]</sup>

is not exclusive to HIV infection and may be associated with other cases of immunosuppressed patients<sup>[1-3]</sup>. OHL appears clinically as an asymptomatic white lesion on the lateral border of the tongue, unilaterally or bilaterally, with imprecise boundaries, a flat, corrugated or hairy surface, that is not removed by scraping<sup>[4]</sup>. Some patients may present with symptoms including mild pain and alteration of taste<sup>[5]</sup>.

The pathogenesis of OHL is related to the infection of oral squamous epithelial cells with the Epstein-Barr virus (EBV)<sup>[3,4]</sup>. The absence of or high reduction of Langerhans cells in OHL has been demonstrated<sup>[6]</sup>. Langerhans cells are the antigen-presenting immune cells that are required for an immune system response to a viral infection. This deficiency of Langerhans cells may permit EBV to replicate<sup>[5-7]</sup>.

Topical therapy is the most highly recommended treatment for OHL because it has a low cost, is easy to use, has few side effects and is effective for a long period of time<sup>[4]</sup>. However, there are few studies that evaluate the effects of topical treatment in patients with OHL. This can be explained by the significant reduction in the prevalence of the oral lesions in HIV patients after the introduction of highly active antiretroviral therapy<sup>[4,8]</sup>. The purpose of this article is to present a review of topical therapies for OHL. The methodology was a search of the literature, from 1966 through December 2013, related to the topical treatment of OHL and listed on PubMed. The search was conducted in both English and Portuguese, and the keywords used were “oral hairy leukoplakia”, “oral hairy leukoplakia and topical management” and “oral hairy leukoplakia and topical treatment”. Additional studies were found in the reference lists of the selected articles. Randomized clinical trials, case reports and review articles were included in the current paper (Table 1).

## REVIEW

Usually, OHL does not require specific therapy, and when indicated, therapy is intended to restore the patient's comfort, eliminate the hairiness, reestablish the normal appearance of the tongue for aesthetic reasons and remove

niches for bacteria, viruses (EBV) and fungi to prevent the establishment of other oral diseases<sup>[2]</sup>. Proposed treatments include surgery, systemic antiviral therapy and topical management. A search of the literature found 16 articles related to topical treatments for OHL. All forms of topical management of OHL identified in published studies will be presented herein.

### Gentian violet

Gentian violet is a triphenylmethane dye that was synthesized by Charles Lauth, in 1861, under the name of “Violet de Paris”. Churchman, in 1912, demonstrated the bacteriostatic action of gentian violet against Gram-positive microorganisms *in vitro* and in animal models, as well as the antimycotic effects of this agent against multiple species of *Candida*<sup>[9]</sup>. Since then, several studies have evaluated the antibacterial and antifungal actions of gentian violet.

The antiviral properties of gentian violet were investigated based on evidence that EBV viral products induce the generation of reactive oxygen, and gentian violet is a potent inhibitor of reactive oxygen species<sup>[10]</sup>. Given that gentian violet is well-tolerated, approved for human use and is an inexpensive agent, Bhandarkar *et al*<sup>[3]</sup> performed a study using gentian violet (2%) as a topical treatment for OHL in one HIV-infected man. Gentian violet was applied topically to the lesion three times in a one-month period. Complete regression of OHL was observed at a one-month follow-up, and there was no recurrence of the OHL one year after treatment.

### Retinoids

Retin-A is a dekeratinizing agent responsible for the modulation of the presence of Langerhans cells in OHL. Local application of 0.1% vitamin A twice daily was performed in twelve cases of OHL and regression of the lesions was observed after 10 d<sup>[11]</sup>. Daily application of a tretinoin solution (Retin-A) for 15 to 20 d was performed in 22 patients, and 37 patients received no treatment. Lesion healing was observed in 69% of treated patients and spontaneous regression was detected in 10.8% of untreated patients<sup>[12]</sup>. Retin-A is a costly drug and causes a burning sensation after prolonged use<sup>[13,14]</sup>.

### Podophyllin

Podophyllin is a dry, alcoholic extract of rhizomes and roots of *Podophyllum peltatum*. It is a lipid-soluble substance that crosses cell membranes and interferes with cell replication; this substance is commonly used as a topical chemotherapy agent<sup>[14]</sup>. It is inexpensive, simple to apply, and effective over a long period of time. Although podophyllin has a very bitter and unpleasant taste, the palate returns to normal two hours after of application<sup>[2]</sup>.

The results of a 25% alcoholic solution of podophyllin as topical therapy for OHL are significant, especially in the first week after application. In a case series, nine patients were treated with podophyllin resin 25% sol in a benzoin compound tincture. The results showed complete regression of all lesions: five patients within one

week and four after a second application a week later. Those four patients had presented with more extensive lesions<sup>[13]</sup>. In another study, six men with OHL were treated with a once-daily application of podophyllin 25%, and healing of all lesions was verified in three to 5 d<sup>[15]</sup>. Gowdey *et al.*<sup>[14]</sup> assessed ten HIV-infected patients with OHL on the tongue and treated one side with a single application of topical podophyllin resin 25% solution. The other side was used as a control. The patients were evaluated at days two, seven, and thirty of the study. They described a slight change of taste, burning sensation and pain with a short duration. There was regression of lesions, especially on the second day after application.

The dose usually applied in topical therapy for OHL varied from 10 mg to 20 mg of podophyllin<sup>[2,14]</sup>. This dose has not been associated with adverse or systemic effects; these effects are observed after ingestion or when more than 100 mg of podophyllin is topically applied and not removed within 4 to 6 h<sup>[14]</sup>.

### Acyclovir

Acyclovir is a chemotherapeutic antiviral agent that is highly effective against herpes simplex virus types I and II, EBV, Varicella zoster virus, and cytomegalovirus<sup>[2]</sup>. The only previous study performed using acyclovir cream for topical treatment was performed by Ficarra *et al.*<sup>[16]</sup>. The authors observed OHL in 23 out of 120 HIV-positive patients (19%), and found a complete resolution of OHL in two patients and partial regression in one patient after topical application of acyclovir cream.

### Combined topical therapy

Topical antiviral drugs may be used in combination with podophyllin, increasing the efficiency of OHL treatment. After the dekeratinization of superficial epithelial cells by podophyllin, the topical antiviral drug acts on exposed and infected cells located below the surface<sup>[4]</sup>. A clinical trial study, performed randomly, proposed a combined topical therapy of 25% podophyllin and 5% acyclovir cream and compared the results with 25% podophyllin<sup>[2]</sup>. In both protocols, applications were performed weekly. All lesions treated with podophyllin and acyclovir showed total clinical regression, and in the podophyllin group, four lesions did not display total clinical resolution after 25 applications. Furthermore, in the 25% podophyllin group, smaller lesions showed clinical regression with fewer applications than larger lesions. In the 25% podophyllin and 5% acyclovir cream group, there was no significant difference in the number of applications.

Based on their previous study, a new topical treatment for OHL employing 25% podophyllin resin with 1% penciclovir cream was tested and the results were compared to 25% podophyllin resin and 25% podophyllin resin with 5% acyclovir cream applied topically<sup>[14]</sup>. Fourteen patients were treated in each protocol. The authors concluded that about half of the patients (55%) had clinical healing of OHL within 7-8 wk of each topical treatment, but the 25% podophyllin resin with 5% acyclovir cream resulted in a faster clinical healing rate of OHL after the

sixth week; moreover, no recurrent lesions were observed in this treatment group twelve months after clinical healing of OHL.

### Recurrence rate

Some studies evaluated the recurrence rate of OHL after topical treatment. Bhandarkar *et al.*<sup>[3]</sup> and Ficarra *et al.*<sup>[16]</sup> showed no recurrence of the lesion one year after 2% gentian violet treatment and six months after acyclovir cream topical therapy, respectively, in patients with total clinical regression. For topical retinoid, recurrence is observed a few days following discontinuation of treatment<sup>[11]</sup>. Sanchez *et al.*<sup>[15]</sup> observed a recurrence rate of 33.3% of OHL treated with 25% podophyllin. Two of the six cases evaluated presented with regression of the lesion four and nine months after treatment. Moura *et al.*<sup>[2]</sup> showed a recurrence of 11.2% twelve months post-therapy with 25% podophyllin. No recurrence was observed in the 25% podophyllin resin with 5% acyclovir cream group. These data suggest that synergism of podophyllin and acyclovir decreases recurrence of OHL after topical therapy.

Systemic antiviral drugs such as desciclovir, valacyclovir, acyclovir and ganciclovir have been used for OHL treatment with recurrence observed after discontinuation<sup>[17,18]</sup>. The possibility of the occurrence of side effects and drug resistance must be carefully evaluated so that the potential harm of treatment does not exceed the expected benefits<sup>[18]</sup>. Surgical excision as a treatment for OHL has been performed, and no recurrence was observed within three months. However, most patients presented with new foci of OHL after this time<sup>[19]</sup>. Considering this, and comparing it to systemic therapy and surgery, topical treatment is recommended because it does not produce systemic adverse effects, is less invasive and is effective over a long period of time<sup>[4]</sup>.

## CONCLUSION

A combined topical therapy of 25% podophyllin and 5% acyclovir cream is effective, demonstrating fast healing without recurrence. In this case, additional multicenter studies are necessary. As for other agents, gentian violet (2%) was also used successfully in the treatment of OHL, with no recurrences in a year, although only one previous study has evaluated the effectiveness of this therapy. Future double-blind and placebo-controlled trials are needed to provide clinical evidence for the efficacy of topical management of OHL.

## ACKNOWLEDGMENTS

The authors wish to thank National Council for Scientific and Technological Development (CNPq) and Office of the Dean of Research of Universidade Federal de Minas Gerais (PRPq, #01/2014).

## REFERENCES

- 1 Greenspan JS, Greenspan D. Oral hairy leukoplakia: diagno-



- sis and management. *Oral Surg Oral Med Oral Pathol* 1989; **67**: 396-403 [PMID: 2542857 DOI: 10.1016/0030-4220(89)90381-2]
- 2 **Moura MD**, Guimarães TR, Fonseca LM, de Almeida Pordeus I, Mesquita RA. A random clinical trial study to assess the efficiency of topical applications of podophyllin resin (25%) versus podophyllin resin (25%) together with acyclovir cream (5%) in the treatment of oral hairy leukoplakia. *Oral Surg Oral Med Oral Pathol Oral Radiol Endod* 2007; **103**: 64-71 [PMID: 17178496 DOI: 10.1016/j.tripleo.2006.02.016]
- 3 **Bhandarkar SS**, MacKelfresh J, Fried L, Arbiser JL. Targeted therapy of oral hairy leukoplakia with gentian violet. *J Am Acad Dermatol* 2008; **58**: 711-712 [PMID: 18342722 DOI: 10.1016/j.jaad.2007.11.017]
- 4 **Moura MD**, Haddad JP, Senna MI, Ferreira e Ferreira E, Mesquita RA. A new topical treatment protocol for oral hairy leukoplakia. *Oral Surg Oral Med Oral Pathol Oral Radiol Endod* 2010; **110**: 611-617 [PMID: 20813564 DOI: 10.1016/j.tripleo.2010.05.015]
- 5 **Walling DM**. Oral hairy leukoplakia: an Epstein-Barr virus-associated disease of patients with HIV. *Res Initiat Treat Action* 2000; **6**: 10-15 [PMID: 11708168]
- 6 **Daniels TE**, Greenspan D, Greenspan JS, Lennette E, Schiødt M, Petersen V, de Souza Y. Absence of Langerhans cells in oral hairy leukoplakia, an AIDS-associated lesion. *J Invest Dermatol* 1987; **89**: 178-182 [PMID: 3110300 DOI: 10.1111/1523-1747.ep12470556]
- 7 **Dongo M**, Gonçalves LS, Ferreira SM, Noce CW, Dias EP, Júnior AS. Gender differences in oral manifestations among HIV-infected Brazilian adults. *Int Dent J* 2013; **63**: 189-195 [PMID: 23879254 DOI: 10.1111/idj.12029]
- 8 **Patton LL**, Ramirez-Amador V, Anaya-Saavedra G, Nitayananta W, Carrozzo M, Ranganathan K. Urban legends series: oral manifestations of HIV infection. *Oral Dis* 2013; **19**: 533-550 [PMID: 23517181 DOI: 10.1111/odi.12103]
- 9 **Maley AM**, Arbiser JL. Gentian violet: a 19th century drug re-emerges in the 21<sup>st</sup> century. *Exp Dermatol* 2013; **22**: 775-780 [PMID: 24118276 DOI: 10.1111/exd.12257]
- 10 **Perry BN**, Govindarajan B, Bhandarkar SS, Knaus UG, Valo M, Sturk C, Carrillo CO, Sohn A, Cerimele F, Dumont D, Losken A, Williams J, Brown LF, Tan X, Ioffe E, Yancopoulos GD, Arbiser JL. Pharmacologic blockade of angiopoietin-2 is efficacious against model hemangiomas in mice. *J Invest Dermatol* 2006; **126**: 2316-2322 [PMID: 16741507 DOI: 10.1038/sj.jid.5700413]
- 11 **Schöfer H**, Ochsendorf FR, Helm EB, Milbradt R. Treatment of oral 'hairy' leukoplakia in AIDS patients with vitamin A acid (topically) or acyclovir (systemically). *Dermatologica* 1987; **174**: 150-151 [PMID: 3556707 DOI: 10.1159/000249008]
- 12 **Alessi E**, Berti E, Cusini M, Zerboni R, Cavicchini S, Tomasi D, Muratori S. Oral hairy leukoplakia. *J Am Acad Dermatol* 1990; **22**: 79-86 [PMID: 2153716 DOI: 10.1016/0190-9622(90)70012-7]
- 13 **Lozada-Nur F**, Costa C. Retrospective findings of the clinical benefits of podophyllum resin 25% sol on hairy leukoplakia. Clinical results in nine patients. *Oral Surg Oral Med Oral Pathol* 1992; **73**: 555-558 [PMID: 1518642 DOI: 10.1016/0030-4220(92)90097-A]
- 14 **Gowdey G**, Lee RK, Carpenter WM. Treatment of HIV-related hairy leukoplakia with podophyllum resin 25% solution. *Oral Surg Oral Med Oral Pathol Oral Radiol Endod* 1995; **79**: 64-67 [PMID: 7614164 DOI: 10.1016/S1079-2104(05)80076-9]
- 15 **Sanchez M**, Spielman T, Epstein W, Moy J. Treatment of oral hairy leukoplakia with podophyllin. *Arch Dermatol* 1992; **128**: 1659 [PMID: 1456770 DOI: 10.1001/archderm.128.12.1659]
- 16 **Ficarra G**, Barone R, Gaglioti D, Milo D, Riccardi R, Romagnoli P, Zorn M. Oral hairy leukoplakia among HIV-positive intravenous drug abusers: a clinicopathologic and ultrastructural study. *Oral Surg Oral Med Oral Pathol* 1988; **65**: 421-426 [PMID: 3283634 DOI: 10.1016/0030-4220(88)90356-8]
- 17 **Scully C**, McCarthy G. Management of oral health in persons with HIV infection. *Oral Surg Oral Med Oral Pathol* 1992; **73**: 215-225 [PMID: 1312692 DOI: 10.1016/0030-4220(92)90197-X]
- 18 **Baccaglini L**, Atkinson JC, Patton LL, Glick M, Ficarra G, Peterson DE. Management of oral lesions in HIV-positive patients. *Oral Surg Oral Med Oral Pathol Oral Radiol Endod* 2007; **103** Suppl: S50.e1-S50.23 [PMID: 17379155 DOI: 10.1016/j.tripleo.2006.11.002]
- 19 **Herbst JS**, Morgan J, Raab-Traub N, Resnick L. Comparison of the efficacy of surgery and acyclovir therapy in oral hairy leukoplakia. *J Am Acad Dermatol* 1989; **21**: 753-756 [PMID: 2808791 DOI: 10.1016/S0190-9622(89)70250-4]

P- Reviewers: Boffano P, Sarode SC S- Editor: Song XX

L- Editor: A E- Editor: Wu HL



## Association between resting energy expenditure, psychopathology and HPA-axis in eating disorders

Giovanni Castellini, Walter Castellani, Lorenzo Lelli, Carolina Lo Sauro, Carla Dini, Lisa Lazzeretti, Lorenza Bencini, Edoardo Mannucci, Valdo Ricca

Giovanni Castellini, Lorenzo Lelli, Lisa Lazzeretti, Lorenza Bencini, Valdo Ricca, Department of Neuroscience, Psychology, Drug Research and Child Health, University of Florence, 50134 Firenze, Italy

Walter Castellani, Department of Respiratory Physiopathology, Palagi Hospital, 50134 Firenze, Italy

Carolina Lo Sauro, Department of Health Science, University of Florence, 50134 Firenze, Italy

Carla Dini, Nutrition Service, University of Florence, 50134 Firenze, Italy

Edoardo Mannucci, Non Invasive Cardiology, Department of Heart and Vessels, University of Florence, 50134 Firenze, Italy

**Author contributions:** Castellini G, Lelli L and Ricca V contributed equally to this work; Castellini G, Lelli L, Lo Sauro C and Ricca V designed the research; Castellani W, Dini C, Lazzeretti L and Bencini L performed the research; Castellini G and Mannucci E analyzed the data; Castellini G, Lelli L and Ricca V wrote the paper.

**Correspondence to:** Valdo Ricca, MD, Psychiatric Unit, Department of Neuroscience, Psychology, Drug Research and Child Health, University of Florence, Largo Brambilla 3, 50134 Firenze, Italy. [valdo.ricca@unifi.it](mailto:valdo.ricca@unifi.it)

Telephone: +39-055-7947487 Fax: +39-055-7947487

Received: April 14, 2014 Revised: May 30, 2014

Accepted: June 18, 2014

Published online: July 16, 2014

### Abstract

**AIM:** To investigate the complex relationships between resting energy expenditure (REE), eating psychopathology, and Hypothalamus Pituitary Adrenal axis functioning in patients with eating disorders.

**METHODS:** The study was designed as a cross-sectional survey, and it was planned by the Clinic for Eating Disorders of the University of Florence (Italy). The protocol was approved by the Ethics Committee of the Institution. Twenty two anorexia nervosa and twenty one Bulimia Nervosa patients were assessed by means of a clinical interview and the structured clinical

interview for diagnostic and statistical manual of mental disorders, fourth edition. Eating attitudes and behaviour were specifically investigated by means of the eating disorder examination questionnaire (EDE-Q). Patients were also evaluated by means of the symptom checklist (SCL 90-R), REE was measured by means of indirect calorimetry, and blood cortisol morning levels were evaluated.

**RESULTS:** Both anorexia nervosa and bulimia nervosa patients showed a reduced REE as compared with predicted REE. Body mass index (BMI) was positively associated with resting energy expenditure in Bulimics, whereas a strong, negative association between BMI and REE was observed in Anorectics. The pattern of associations between variables supported a mediation model, where shape concern accounted for variations in REE and cortisol levels (mediator), and variations in the mediator significantly accounted for variations in REE. When these associations were taken into account together, the relationship between shape concern and REE was no longer significant, whereas the association between cortisol levels and REE retained its significance, showing strong evidence for a single, dominant mediator. Anorectics and Bulimics showed an opposite pattern of association between BMI and REE. In Anorectics only, a higher REE was associated with a more severe eating disorder specific psychopathology, and cortisol levels represent a possible mediating factor for this relationship.

**CONCLUSION:** The data supported a mediation model where cortisol levels mediated the relationship between eating psychopathology (concern about body shape) and REE.

© 2014 Baishideng Publishing Group Inc. All rights reserved.

**Key words:** Anorexia nervosa; Bulimia nervosa; Cortisol; Psychopathology; Resting energy expenditure

**Core tip:** We have investigated the relationship between resting energy expenditure (REE), eating psychopathology, and hypothalamus adrenal axis in EDs. Twenty two anorexia nervosa (AN) and 21 bulimia nervosa (BN) patients were assessed. Both AN and BN showed a reduced REE as compared with predicted REE. AN and BN showed an opposite pattern of association between REE and Body Mass Index (BMI) which was positively associated with REE in BN, whereas a strong, negative association between BMI and REE was observed in AN. In AN only, a higher REE was associated with a more severe eating disorder psychopathology, and higher cortisol levels. The data supported a mediation model where cortisol levels mediated the relationship between eating psychopathology and REE.

Castellini G, Castellani W, Lelli L, Lo Sauro C, Dini C, Lazzeretti L, Bencini L, Mannucci E, Ricca V. Association between resting energy expenditure, psychopathology and HPA-axis in eating disorders. *World J Clin Cases* 2014; 2(7): 257-264 Available from: URL: <http://www.wjgnet.com/2307-8960/full/v2/i7/257.htm> DOI: <http://dx.doi.org/10.12998/wjcc.v2.i7.257>

## INTRODUCTION

Chronic underfeeding and binge-purging behaviours can lead to alterations in metabolism and body composition. Several studies investigated energy metabolism in patients with anorexia nervosa (AN)<sup>[1-6]</sup>, and the observed reduction of resting energy expenditure (REE) has been associated to the smaller volume of metabolically active tissues and to an adaptation to underfeeding<sup>[6-8]</sup>. Measured REE is significantly lower than predicted REE in AN subjects<sup>[9]</sup>. As far as bulimic normal weight patients are concerned, most of the published studies found that the resting metabolic rate of these patients was significantly lower than that of controls<sup>[10,11]</sup>, whereas Detzer *et al*<sup>[12]</sup> did not find significant differences between patients with bulimia nervosa (BN) and controls.

REE is one component of the total energy expenditure. It includes basal metabolic rate, which refers to the minimum part of energy required to maintain the organisms' basic functions, and it is related to the amount of energy utilized when the body is at complete rest. It can be measured by means of indirect calorimetry, and it is often used in clinical settings. REE alterations found in eating disorders could be partly explained with the quantitative changes in cell mass<sup>[11,13]</sup>. Similarly, Vaisman *et al*<sup>[14]</sup> attributed the lowered resting metabolic rate to the reduction in lean body mass.

Alternatively, previous findings supported the relationship between stress induced cortisol levels and metabolic rate. In eating disorders, increased hypothalamus adrenal axis (HPA) arousal with abnormalities in its regulation is well proven<sup>[15,16]</sup>; HPA axis hyperactivity is well documented in AN and BN especially during the acute phase of the illness, even if the abnormalities showed by

the BN patients are milder<sup>[17]</sup>. The HPA axis alterations can influence other biological systems involved in eating behaviour, such as leptin, endogenous opioids, thyroid, reproductive, immune and sympathetic nervous systems and the abnormalities in these systems could be considered to be involved in the onset and the maintenance of eating disorders<sup>[17]</sup>. HPA axis abnormalities seem to be associated with an history of stressful life events and an excess of traumatic life events, such as sexual and physical abuse are reported in patients with eating disorders. As the relationship between life events and HPA axis is well known<sup>[17-19]</sup>, it is not unexpected that the HPA axis may also be functioning abnormally in eating disorders. Moreover cortisol is considered a catabolic hormone<sup>[20,21]</sup>, and it has been found that weight gain in AN was associated with normalization of plasmatic and urinary cortisol levels<sup>[22]</sup>, HPA functioning and the reduction of cortisol secretory burst<sup>[23]</sup>.

Finally, few studies considered the relationship between eating disorder psychopathology and REE in eating disorders patients, with conflicting results<sup>[13,23,24]</sup>.

The aims of the present study were as follows: (1) to evaluate the pattern of association between body mass index (BMI) and REE in AN and BN; (2) to investigate the possible mechanisms of REE alterations in AN and BN, analyzing the interaction between eating disorder psychopathology, HPA functioning and metabolic status.

## MATERIALS AND METHODS

### Sample and measures

The study was designed as a cross-sectional survey, and it was planned by the Clinic for Eating Disorders of the University of Florence (Italy). The protocol was approved by the Ethics Committee of the Institution. A written informed consent was obtained from each patient after the procedures of the study were fully explained. The study was performed on a series of 61 eating disorders patients attending the Clinic for Eating Disorders between January 2010 and July 2013, provided they met the following inclusion criteria: female, age between 18 and 60 years, diagnosis of AN restricting type and BN Binge/Purging type, assessed by means of the Structured Clinical Interview for Diagnostic and statistical manual of mental disorders, fourth edition (DSM-IV)<sup>[25,26]</sup>. Patients were included if they reported at least 1 year of a stable Eating Disorder diagnosis (at least 1 year with full diagnostic criteria for anorexia nervosa or bulimia nervosa according the DSM-IV criteria and without diagnostic crossover in the same year), at least 6 wk of a stable body weight, no intense physical exercise in the past six months (both assessed by means of a face-to face clinical interview). None of the patients were in a remission or recovery phase of disease. The exclusion criteria were as follows: comorbid schizophrenia or bipolar disorder, illiteracy, mental retardation, severe medical conditions, current use of psychoactive medications that can interfere with HPA Axis response (*i.e.*, antidepressants use could increase human hippocampal neurogenesis by activating

the glucocorticoid receptor<sup>[27]</sup>.

Six patients refused to participate in the study, and 12 patients were excluded because of the following reasons: bipolar disorder (2 patient), illiteracy (1 patient), mental retardation (1 patient), severe medical conditions (3 patients with heart failure, 1 with renal failure), pharmacological treatments (4 patients taking SSRI). The final sample was composed of 43 female subjects, 22 with AN Restricting Type, and 21 with BN Binge/Purging type. The Structured clinical interview for DSM-IV<sup>[26]</sup> axis was used to confirm psychiatric diagnoses.

### Psychological assessment

Psychopathological, behavioural and sociodemographic data were collected through a face-to-face interview on the first day of admission, by two expert psychiatrists (L.L., C.L.S.). The structured clinical interview for DSM IV<sup>[26]</sup> was applied to evaluate diagnoses according to DSM-IV. Anthropometric measurements were made using standard calibrated instruments. Height (m) was measured using a wall-mounted stadiometer, weight (kg) using electronic scales. BMI was calculated. Eating attitudes and behaviour were specifically investigated by means of the eating disorder examination questionnaire (EDE-Q)<sup>[28]</sup>. The self-reported EDE-Q consists of 38 items, assessing the core psychopathological features of eating disorders, and contains 4 subscales: dietary restraint, eating concern, weight concern, and shape concern. Finally, patients were evaluated by means of the symptom checklist (SCL 90-R)<sup>[29]</sup>, a psychometric instrument devoted to the identification of psychopathological distress.

### Blood samples

Blood samples were drawn in the morning (8 am), after an overnight fast, for the determination of cortisol levels (mcg/L), TSH, and thyroid hormones levels.

### Indirect calorimetry

REE was measured by means of indirect calorimetry using a canopy system (MMC Horizon, Sensor Medics, Anaheim, United States in a quiet environment, with the patients in the supine position for 20 min before measurement, because activities of daily living increase REE, but a short rest (20 min) before testing is sufficient for the effect to dissipate) and after a 12 h overnight fast. Measurement duration of 10 min with the first 5 min deleted and the remaining 5 min having a coefficient of variation < 10% gave accurate readings of REE<sup>[30]</sup>. Energy expenditure was derived from CO<sub>2</sub> production and O<sub>2</sub> consumption, with the appropriate Weir's formula, neglecting protein oxidation<sup>[31]</sup>. The inter-day coefficient of variation of such measurements (as determined in six patients on subsequent days) was always less than 3%, without any sequence effect. Basal energy expenditure can be measured a number of different ways, but perhaps the most convenient way is by indirect calorimetry. This method is based on the assumption that metabolism is a reflection of energy expenditure. Since the oxidation

of nutrients requires oxygen, by measuring oxygen consumption and carbon dioxide production, an estimate of energy production in kilocalories can be made. However, if indirect calorimetry is unavailable, the Harris-Benedict equations (multiple linear regression equations derived from a sample of normal individuals), based on height, weight, age, and sex, can be used clinically to estimate basal energy expenditure<sup>[8]</sup>. For females, the equation is: basal energy expenditure =  $655.1 + (9.56 \times \text{body weight in kg}) + (1.84 \times \text{height in cm}) - (4.67 \times \text{age in years})$ <sup>[32,33]</sup>. REE was measured prior to start psychological and pharmacological interventions.

### Statistical analysis

For between-group comparisons (AN *vs* BN),  $\chi^2$  and Independent-Samples *t* test were applied, while Paired Sample *t* test was adopted to compare REE with predicted REE within each group. Correlation analyses (Pearson's correlation), and subsequently linear regression analyses were performed in the whole sample, and within each group, to assess the associations between BMI, cortisol levels, eating specific and general psychopathology, and REE.

Subsequently, moderator and mediator effect analyses were performed. Whereas moderator variables specify when certain effects will hold, mediators consider how or why such effects occur (Baron and Kenny)<sup>[34]</sup>. The moderator function of third variables partitions a focal independent variable into subgroups, that establish its domains of maximal effectiveness in regard to a given dependent variable. Therefore, in order to evaluate whether the relationship between REE and BMI was different within Eating Disorders subgroups (first aim of the study), general linear model (GLM) was used to examine the moderating effect of diagnosis (AN *vs* BN) on the interaction between REE and BMI.

In order to evaluate the possible mechanisms that could explain the associations between REE and BMI (second aim of the study), mediators effect analyses were performed. The mediator function of a third variable represents the generative mechanism through which the focal independent variable is able to influence the dependent variable of interest.

## RESULTS

Table 1 reported demographic, clinical and psychopathological variables for AN and BN patients. No significant difference was detected between AN and BN, with the exception of BMI and FT3, which were higher in BN as compared with AN patients. No significant difference was found between AN and BN, in terms of REE while predicted REE was significant lower in AN. REE was lower than predicted REE, in both AN ( $t = 2.27$ ;  $P = 0.034$ ) and BN ( $t = 5.82$ ;  $P < 0.001$ ) groups. These comparisons retained their significance even when adjusting for FT3 hormones.

GLM analysis (Figure 1; part A) was adopted to evaluate whether the relationship between REE and BMI was different according to EDs subgroups (AN and BN).



**Table 1** General and clinical characteristics of the sample

	Anorexia Nervosa; n: 22	Bulimia Nervosa; n: 21	t
Age (yr)	31.73 ± 9.86	27.86 ± 7.12	1.46
Education (yr)	18.13 ± 3.78	18.66 ± 2.67	0.52
BMI (kg/m <sup>2</sup> )	15.43 ± 2.00	22.96 ± 1.49	-13.8 <sup>b</sup>
REE (kcal/d)	1088 ± 174	1092 ± 207	-0.06
Predicted REE (kcal/d) <sup>a</sup>	1196 ± 85	1421 ± 207	4.53 <sup>b</sup>
Cortisol levels (mcg/L)	513.65 ± 159.52	496.05 ± 133.22	0.37
TSH (mU/L)	2.14 ± 1.57	1.67 ± 0.70	1.22
FT3 (pmol/L)	3.82 ± 0.98	4.75 ± 0.81	-3.35 <sup>b</sup>
FT4 (pmol/L)	14.10 ± 3.43	14.14 ± 2.29	-0.03
SCL-90 GSI	1.59 ± 0.57	1.52 ± 0.70	0.31
EDE-Q total	3.24 ± 1.59	3.24 ± 1.16	0.08
EDE-Q restraint	3.26 ± 2.23	3.19 ± 1.33	0.11
EDE-Q eating concern	2.86 ± 1.65	2.96 ± 1.38	-0.19
EDE-Q weight concern	3.36 ± 1.54	3.10 ± 1.53	0.54
EDE-Q shape concern	3.48 ± 1.66	3.74 ± 1.09	-0.57
Binge eating episodes (month frequency)		9.7 ± 6.4	
Purging behaviours (month frequency)		8.4 ± 5.9	

<sup>a</sup>Calculated by means of Harris-Benedict equation. Data are expressed as mean ± SD deviation; for between groups comparisons: Independent-Sample *t* test; <sup>b</sup>*P* < 0.05; <sup>c</sup>*P* < 0.01. REE: Resting energy expenditure; BMI: Body mass index; SCL-90 GSI: Symptom checklist (SCL 90-R) global severity index; EDE-Q: Eating disorder examination questionnaire.

GLM (age adjusted) showed a significant effect of REE by diagnosis on BMI ( $\beta = 0.32$ ;  $P < 0.001$ ). The significant interaction was confirmed even when adjusting for body surface area. Therefore, when the interaction was broken down (Figure 1; part B), an opposite pattern of association was found in AN and BN: the increased BMI was associated with higher REE in the BN group (age adjusted  $\beta = 0.64$ ,  $P = 0.001$ ), while in AN patients the reduced BMI was associated with higher REE (age adjusted  $\beta = 0.63$ ,  $P = 0.003$ ).

To evaluate the possible underlying mechanisms for maintenance of REE in AN and BN, Person's correlations were performed, considering psychopathological variables, cortisol levels, BMI and REE, within AN and BN patients (Table 2). No significant association was found in BN patients between REE and binge eating or purging behaviours, TSH or thyroid hormones levels. Considering AN patients, a strong positive association was found between REE and EDE-Q shape concern. Moreover, in the same group, significant positive correlations between EDE-Q shape concern and cortisol levels were also observed, as well as between cortisol levels and REE. Conversely, in BN group these associations were lacking or less significant than in AN.

In order to explain the relationship between a more severe eating disorder psychopathology and a higher REE in AN, we hypothesized a possible mediating role of cortisol levels. According to Baron *et al.*<sup>[34]</sup>, we assumed a three variable system represented by a path diagram,

where the dependent variable was REE (Figure 2). It included a direct impact (Path c) of the independent variable (EDE-Q shape concern), the impact of the mediator (cortisol levels; Path b), and the impact of the independent variable on the mediator (Path a). To test for mediation, we regressed the mediator on the independent variable, the dependent variable on the independent variable, the independent variable on the dependent variable (direct impact), and the dependent variable on both the independent variable and on the mediator. Separate coefficients were estimated and reported. According to this model, the following conditions supported mediation hypothesis: (1) variations in levels of the independent variable (EDE-Q shape concern) significantly accounted for variations in the mediator (cortisol levels;  $\beta = 0.47$ ;  $P = 0.01$ ); (2) variations in the mediator significantly accounted for variations in the dependent variable (REE;  $\beta = 0.80$ ;  $P < 0.01$ ); (3) variations in the independent variable significantly accounted for variations in the dependent variable (REE;  $\beta = 0.63$ ;  $P < 0.01$ ); (4) finally, when Paths a and b were controlled, this previously significant relation between EDE-Q shape concern and REE was no longer significant ( $\beta = 0.12$ ;  $P = 0.53$ ), while the relation between cortisol levels and REE retained its significance ( $\beta = 0.75$ ;  $P = 0.002$ ), showing strong evidence for a single, dominant mediator.

In order to calculate the indirect effect of EDE-Q shape concern on REE *via* the mediator (cortisol levels) we performed the Sobel test<sup>[35]</sup>, which resulted to be significant ( $Z = 2.51$ ;  $P = 0.005$ ). The model described above was tested also for EDE-Q total and subscale scores (data not shown). The best fit for the data was represented by the model including EDE-Q shape concern scores.

## DISCUSSION

To the best of our knowledge, this is the first study which evaluated REE in AN and BN, considering eating disorder specific psychopathology and HPA functioning as possible factors involved in the metabolic alterations.

According to our main results: (1) AN and BN patients showed an opposite pattern of association between BMI and REE. In AN patients, a higher REE was negatively associated with BMI, whereas BN patients showed a positive association between these two variables; (2) in AN patients only, a higher REE was associated with a more severe eating disorder specific psychopathology, and cortisol levels represented a possible mediating factor for this relationship.

According to previous findings<sup>[2,9,11,13]</sup>, both AN and BN showed a reduced REE, which was significantly lower than the predicted REE. It has been suggested that dietary restraint places both AN and BN patients in a state of semi-starvation which is responsible for REE reduction, and it is partially compensated by binge eating behaviours in BN<sup>[7]</sup>. However, in the present study, AN patients did not show a reduced REE compared with BN, despite their lower BMI. In AN patients, we found

**Table 2** Pearson's correlations

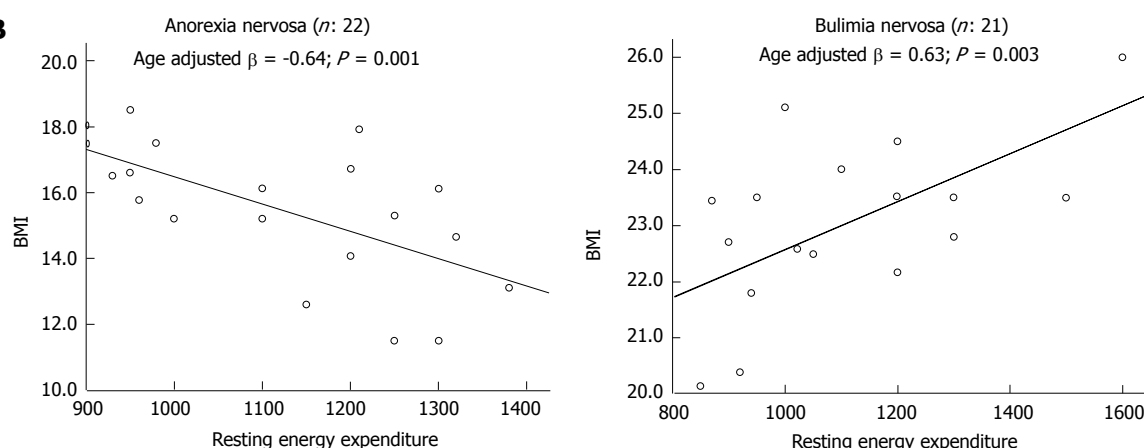
	BMI	REE	Cortisol levels	SCL-90 GSI	EDE-Q total	EDE-Q restraint	EDE-Q EC	EDE-Q WC	EDE-Q SC
Anorexia Nervosa patients; <i>n</i> : 22									
Age	-0.11	-0.07	-0.05	-0.58 <sup>a</sup>	-0.12	0.06	-0.13	-0.12	0.02
BMI		-0.63 <sup>b</sup>	-0.49 <sup>a</sup>	0.13	-0.32	-0.20	-0.42	-0.25	-0.46 <sup>a</sup>
REE			0.83 <sup>b</sup>	0.10	0.39	0.17	0.33	0.45	0.63 <sup>b</sup>
Cortisol levels				0.68	0.33	0.09	0.28	0.34	0.68 <sup>b</sup>
SCL-90 GSI					0.40	0.34	0.35	0.35	0.76 <sup>b</sup>
Bulimia Nervosa patients; <i>n</i> : 21									
Age	-0.16	0.14	-0.04	0.09	0.24	0.38	-0.12	0.42	0.13
BMI		0.59 <sup>b</sup>	0.77	-0.20	0.16	-0.21	0.45 <sup>a</sup>	0.15	0.2
REE			0.24	0.00	0.43	0.33	0.42	0.19	0.46 <sup>a</sup>
Cortisol levels				-0.10	-0.05	0.33	-0.12	0.12	0.23
SCL-90 GSI					0.37	0.28	0.40	-0.02	0.30

Data are Pearson's correlation coefficients: <sup>a</sup> $P < 0.05$ ; <sup>b</sup> $P < 0.01$ . REE: Resting energy expenditure; BMI: Body mass index; SCL-90 GSI: Symptom checklist (SCL 90-R) global severity index; EDE-Q: Eating disorder examination questionnaire; EC: Eating concern; WC: Weight concern; SC: Shape concern.

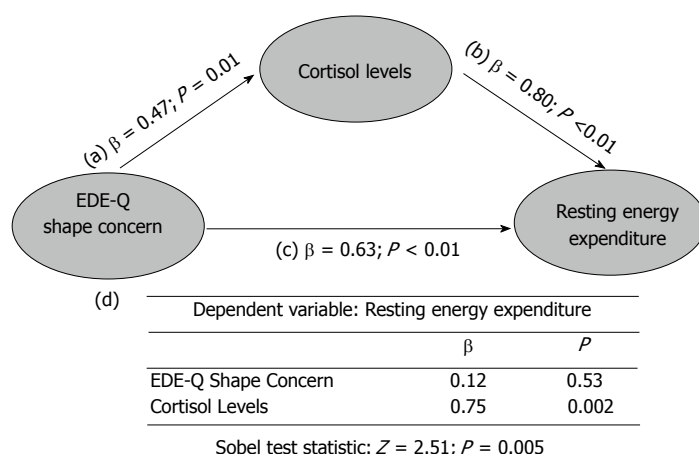
**A**

General linear model-dependent variable: Body mass index (all eating disorders patients included, *n*: 43)

	$\beta$	<i>t</i>	<i>P</i>
Age	-0.11	-2.16	0.04
Resting energy expenditure	0.20	3.29	0.002
Diagnosis (AN: 0; BN: 1)	-1.91	-20.54	< 0.001
Resting energy expenditure X Diagnosis interaction	-0.68	-6.83	< 0.001

**B**

**Figure 1** Moderators of the relationship between resting energy expenditure and body mass index. A: General linear model analysis (age adjusted) showed the effect of resting energy expenditure (REE) by diagnosis. Diagnosis was coded as dummy variables: 0 = Anorexia nervosa, 1 = Bulimia nervosa; B: The interaction showed in part A was broken down within diagnoses. Graphs reports results from linear regression analyses (age adjusted) of the opposite pattern of association between REE and body mass index (BMI) in anorexia nervosa and bulimia nervosa subjects.



**Figure 2** Mediator Model for the relationship between shape concern, cortisol levels and resting energy expenditure. The model included a direct impact (Path c) of the independent variable [eating disorder examination questionnaire (EDE-Q) shape concern] on the dependent variable (REE), the impact of the mediator (cortisol levels; Path b), and the impact of the independent variable on the mediator (Path a). The  $\beta$  values of separate regression analyses are reported in the graph. Table (d) section of the figure) reported the regression analysis of the combined effect of EDE-Q shape concern, and cortisol levels on REE. The bottom part of the graph reports the results of the Sobel test, in order to calculate the indirect effect of shape concern on REE via the mediator (cortisol levels).

that a higher REE was associated with a worse clinical condition, including lower BMI and higher eating disorder psychopathology.

It is generally assumed that AN patients maintain their low weight by severely restricting food intake, purging, and engaging in physical activity<sup>[36]</sup>. However, clinical observations consistently suggest that these patients gain weight with great difficulty, and they usually maintain their low body weight for a long time, as well. The physiological maintenance of their low body weight has been inferred from some clinical observations suggesting that AN patients apparently require high energy intake to gain weight<sup>[37]</sup>. This relative increase in energy expenditure could also account for the difficulties of AN subjects to gain weight when desired.

This pilot study provided evidences for possible explaining mechanisms of this phenomenon. We found that a severe underweight status in AN was associated with relative higher REE, and that these two conditions were both associated with an over concern about body shape, which represents the “core psychopathology” of AN.

In order to explain such a relationship, we hypothesized a mediating role of the HPA axis. According to mediation model by Baron *et al.*<sup>[34]</sup>, a given variable may be said to function as a mediator to the extent that it accounts for the relationship between the predictor and the criterion. In this study, the cortisol levels (mediator) explained how eating specific psychopathology accounted for REE variability in AN patients.

As a possible causal mechanisms, it has been supposed that increased plasma cortisol in AN is due to the higher corticotropin releasing hormone (CRH) production in the central nervous system. As already described, stress-which in this study was specifically related with eating psychopathology- may lead to the hypersecretion of CRH, which is known to be a potent anorexic agent<sup>[21]</sup>.

Furthermore, previous findings supported the relationship between stress induced cortisol levels and REE. It has been suggested that, when in excess, cortisol is an overall catabolic hormone, which decreases lean body mass and muscle mass and increase energy expenditure<sup>[20,21]</sup>. Moreover, it increases availability of all fuel substrates by mobilization of glucose<sup>[38]</sup>, free fatty acids<sup>[39]</sup>, and amino acids from endogenous stores<sup>[40]</sup>. Given the cross-sectional design of the study, we are not able to derive final conclusion on causal relationship psychopathology and REE. The present mediation model support a strong mediator role of cortisol, suggesting a possible underlying mechanism. However, it does not explain all the variance of the mentioned association, which could be caused by other metabolic factors related to underweight in AN patients.

Some limitations of this pilot study should be considered. First of all we do not analyze the body composition of the patients, one of the determinant of the REE. Then, the cross-sectional design of the study does not allow any firm conclusion about causal relationships. Tem-

perament and personality disorders information were not available. Finally the sample size is small, and it did not allow the generalization of the main findings. Moreover, it is possible that other psychopathological measures (*e.g.*, EDE-Q weight concern) could reach significant associations with larger samples. Therefore, our results should be considered as preliminary, and larger, prospective researches are warranted in order to confirm or not these findings. The results of the present study supported the hypothesis that Cortisol levels in AN, through changes in REE, could represent a biological substrate for the capacity to maintain low body weight, and for the inefficiency at gaining weight. Safe and effective re-feeding strategies in Eating Disorders should carefully consider the complex mechanisms which can determine the energy balance impairment observed in AN and BN patients.

## COMMENTS

### Background

Metabolic changes in eating disorders patients may partially explain the obstacles of weight regain interventions. One of the reasons can be the resting energy expenditure alteration which appears to be correlated with the disorder severity in terms of both weight loss and eating disorder psychopathology. Cortisol levels, a measure of response to stress appear to be a putative biological mechanism underlying the association between eating psychopathology and resting energy expenditure.

### Research frontiers

The present paper is in line with the recent advanced neurobiological and psychosomatic models based on the complex interaction between psychiatric conditions, stress response and subjective perception of symptoms.

### Innovations and breakthroughs

Resting energy expenditure abnormalities have already been described in Anorexia Nervosa patients, but generally they do not consider the role of psychopathology, as a marker of severity of the disorder. The present study is original and innovative, since it proposes a model which includes resting expenditure, cortisol levels as a marker of stress, as well as eating disorder specific psychopathology.

### Applications

The present study demonstrated that the severity of psychopathology represents not just an indicator of subjective perception of the eating disorder, but also of more compromised metabolic condition which could interfere with treatment process.

### Terminology

Resting Energy Expenditure: it is based on the assumption that metabolism is a reflection of energy expenditure. Since the oxidation of nutrients requires oxygen, by measuring oxygen consumption and carbon dioxide production, an estimate of energy production in kilocalories can be made. Shape concern: it includes all the concerns and behaviors associated with once own body. It is the core psychopathological feature of eating disorders.

### Peer review

This is, in summary, an interesting cross-sectional survey aimed to investigate the relationship between resting energy expenditure, eating psychopathology, and hypothalamus pituitary adrenal-axis functioning in twenty-two patients with eating disorders. The manuscript is interesting and well-written.

## REFERENCES

- 1 Melchior JC, Rigaud D, Rozen R, Malon D, Apfelbaum M. Energy expenditure economy induced by decrease in lean body mass in anorexia nervosa. *Eur J Clin Nutr* 1989; **43**: 793-799 [PMID: 2627927]
- 2 Platte P, Pirke KM, Trimborn P, Pietsch K, Krieg JC, Fichter MM. Resting metabolic rate and total energy expenditure in

- acute and weight recovered patients with anorexia nervosa and in healthy young women. *Int J Eat Disord* 1994; **16**: 45-52 [PMID: 7920580 DOI: 10.1002/1098-108X(199407)16:1<45::AID-EAT2260160104>3.0.CO;2-Z]
- 3 **Schebendach JE**, Golden NH, Jacobson MS, Hertz S, Shenker IR. The metabolic responses to starvation and refeeding in adolescents with anorexia nervosa. *Ann N Y Acad Sci* 1997; **817**: 110-119 [PMID: 9239182 DOI: 10.1111/j.1749-6632.1997.tb48200.x]
  - 4 **Polito A**, Fabbri A, Ferro-Luzzi A, Cuzzolaro M, Censi L, Ciarapica D, Fabbri E, Giannini D. Basal metabolic rate in anorexia nervosa: relation to body composition and leptin concentrations. *Am J Clin Nutr* 2000; **71**: 1495-1502 [PMID: 10837290]
  - 5 **Russell J**, Baur LA, Beumont PJ, Byrnes S, Gross G, Touyz S, Abraham S, Zipfel S. Altered energy metabolism in anorexia nervosa. *Psychoneuroendocrinology* 2001; **26**: 51-63 [PMID: 11070334 DOI: 10.1016/S0306-4530(00)00036-6]
  - 6 **Scalfi L**, Marra M, De Filippo E, Caso G, Pisanis F, Contaldo F. The prediction of basal metabolic rate in female patients with anorexia nervosa. *Int J Obes Relat Metab Disord* 2001; **25**: 359-364 [PMID: 11319633 DOI: 10.1038/sj.ijo.0801547]
  - 7 **de Zwaan M**, Aslam Z, Mitchell JE. Research on energy expenditure in individuals with eating disorders: a review. *Int J Eat Disord* 2002; **32**: 127-134 [DOI: 10.1002/eat.10074]
  - 8 **van Marken Lichtenbelt WD**, Heidendal GA, Westertep KR. Energy expenditure and physical activity in relation to bone mineral density in women with anorexia nervosa. *Eur J Clin Nutr* 1997; **51**: 826-830 [PMID: 9426357 DOI: 10.1038/sj.ejcn.1600492]
  - 9 **Kosmiski L**, Schmiede SJ, Mascolo M, Gaudiani J, Mehler PS. Chronic starvation secondary to anorexia nervosa is associated with an adaptive suppression of resting energy expenditure. *J Clin Endocrinol Metab* 2014; **99**: 908-914 [PMID: 24302748]
  - 10 **Devlin MJ**, Walsh BT, Kral JG, Heymsfield SB, Pi-Sunyer FX, Dantzig S. Metabolic abnormalities in bulimia nervosa. *Arch Gen Psychiatry* 1990; **47**: 144-148 [PMID: 2302026 DOI: 10.1001/archpsyc.1990.01810140044007]
  - 11 **Obazanek E**, Lesem MD, Goldstein DS, Jimerson DC. Reduced resting metabolic rate in patients with bulimia nervosa. *Arch Gen Psychiatry* 1991; **48**: 456-462 [PMID: 2021298 DOI: 10.1001/archpsyc.1991.01810290068013]
  - 12 **Detzer MJ**, Leitenberg H, Poehlman ET, Rosen JC, Silberg NT, Vara LS. Resting metabolic rate in women with bulimia nervosa: a cross-sectional and treatment study. *Am J Clin Nutr* 1994; **60**: 327-332 [PMID: 8074061]
  - 13 **Casper RC**, Schoeller DA, Kushner R, Hnilicka J, Gold ST. Total daily energy expenditure and activity level in anorexia nervosa. *Am J Clin Nutr* 1991; **53**: 1143-1150 [PMID: 1850575]
  - 14 **Vaisman N**, Rossi MF, Goldberg E, Dibden LJ, Wykes LJ, Pencharz PB. Energy expenditure and body composition in patients with anorexia nervosa. *J Pediatr* 1988; **113**: 919-924 [PMID: 3183853 DOI: 10.1016/S0022-3476(88)80032-5]
  - 15 **Brambilla F**, Ferrari E, Brunetta M, Peirone A, Draisci A, Sacerdote P, Panerai A. Immunoendocrine aspects of anorexia nervosa. *Psychiatry Res* 1996; **62**: 97-104 [PMID: 8739119 DOI: 10.1016/0165-1781(96)02992-7]
  - 16 **Monteleone P**, Luisi M, Colurcio B, Casarosa E, Monteleone P, Ioime R, Genazzani AR, Maj M. Plasma levels of neuroactive steroids are increased in untreated women with anorexia nervosa or bulimia nervosa. *Psychosom Med* 2001; **63**: 62-68 [PMID: 11211066 DOI: 10.1097/00006842-200101000-00008]
  - 17 **Lo Sauro C**, Ravaldi C, Cabras PL, Faravelli C, Ricca V. Stress, hypothalamic-pituitary-adrenal axis and eating disorders. *Neuropsychobiology* 2008; **57**: 95-115 [PMID: 18552511 DOI: 10.1159/000138912]
  - 18 **Tyrka AR**, Wier L, Price LH, Ross N, Anderson GM, Wilkinson CW, Carpenter LL. Childhood parental loss and adult hypothalamic-pituitary-adrenal function. *BIOL PSYCHIAT* 2008; **63**: 1247-1254 [DOI: 10.1016/j.biopsych.2008.01.011]
  - 19 **Van Voorhees E**, Scarpa A. The effects of child maltreatment on the hypothalamic-pituitary-adrenal axis. *Trauma Violence Abuse* 2004; **5**: 333-352 [PMID: 15361587 DOI: 10.1177/1524838004269486]
  - 20 **Tataranni PA**, Larson DE, Snitker S, Young JB, Flatt JP, Ravussin E. Effects of glucocorticoids on energy metabolism and food intake in humans. *Am J Physiol* 1996; **271**: E317-E325 [PMID: 8770026]
  - 21 **Christiansen JJ**, Djurhuus CB, Gravholt CH, Iversen P, Christiansen JS, Schmitz O, Weeke J, Jørgensen JO, Møller N. Effects of cortisol on carbohydrate, lipid, and protein metabolism: studies of acute cortisol withdrawal in adrenocortical failure. *J Clin Endocrinol Metab* 2007; **92**: 3553-3559 [PMID: 17609300 DOI: 10.1210/jc.2007-0445]
  - 22 **Misra M**, Miller KK, Almazan C, Ramaswamy K, Aggarwal A, Herzog DB, Neubauer G, Breu J, Klibanski A. Hormonal and body composition predictors of soluble leptin receptor, leptin, and free leptin index in adolescent girls with anorexia nervosa and controls and relation to insulin sensitivity. *J Clin Endocrinol Metab* 2004; **89**: 3486-3495 [PMID: 15240636 DOI: 10.1210/jc.2003-032251]
  - 23 **Rigaud D**, Verges B, Colas-Linhart N, Petiet A, Moukaddem M, Van Wymelbeke V, Brondel L. Hormonal and psychological factors linked to the increased thermic effect of food in malnourished fasting anorexia nervosa. *J Clin Endocrinol Metab* 2007; **92**: 1623-1629 [PMID: 17341571 DOI: 10.1210/jc.2006-1319]
  - 24 **Konrad KK**, Carels RA, Garner DM. Metabolic and psychological changes during refeeding in anorexia nervosa. *Eat Weight Disord* 2007; **12**: 20-26 [PMID: 17384526]
  - 25 **American Psychiatric Association**. Diagnostic and statistical manual of mental disorders (4th ed.) Washington, DC: American Psychiatric Association, 1994
  - 26 **First MB**, Spitzer RL, Gibbon M, Williams JBW. Structured Clinical Interview for DSM-IV Axis I Disorders-Patient Edition (SCID-I/P version 2.0). New York: Biometrics Research Department, New York State Psychiatric Institute, 1995
  - 27 **Anacker C**, Zunszain PA, Cattaneo A, Carvalho LA, Garabedian MJ, Thure S, Price J, Pariante CM. Antidepressants increase human hippocampal neurogenesis by activating the glucocorticoid receptor. *Mol Psychiatry* 2011; **1**-13 [DOI: 10.1038/mp.2011.26]
  - 28 **Fairburn CG**, Beglin SJ. Assessment of eating disorders: interview or self-report questionnaire? *Int J Eat Disord* 1994; **16**: 363-370 [PMID: 7866415]
  - 29 **Derogatis LR**, Lipman RS, Covi L. SCL-90: an outpatient psychiatric rating scale--preliminary report. *Psychopharmacol Bull* 1973; **9**: 13-28 [PMID: 4682398]
  - 30 **Compher C**, Frankenfield D, Keim N, Roth-Yousey L; Evidence Analysis Working Group. Best practice methods to apply to measurement of resting metabolic rate in adults: a systematic review. *J Am Diet Assoc* 2006; **106**: 881-903 [DOI: 10.1016/j.jada.2006.02.009]
  - 31 **Weir JB**. New methods for calculating metabolic rate with special reference to protein metabolism. *J Physiol* 1949; **109**: 1-9 [PMID: 15394301]
  - 32 **Harris JA**, Benedict FG. A biometric study of basal metabolism in man. Washington DC: Carnegie Institute, 1919
  - 33 **Salisbury JJ**, Levine AS, Crow SJ, Mitchell JE. Refeeding, metabolic rate, and weight gain in anorexia nervosa: a review. *Int J Eat Disord* 1995; **17**: 337-345 [PMID: 7620473 DOI: 10.1002/1098-108X(199505)17:4<337::AID-EAT2260170405>3.0.CO;2-Q]
  - 34 **Baron RM**, Kenny DA. The moderator-mediator variable distinction in social psychological research: conceptual, strategic, and statistical considerations. *J Pers Soc Psychol* 1986; **51**: 1173-1182 [PMID: 3806354 DOI: 10.1037/0022-3514.51.6.1173]
  - 35 **Sobel ME**. Asymptotic confidence intervals for indirect effects in structural equations models. In: Leinhardt S, ed.



Sociological methodology. San Francisco: Jossey-Bass, 1982: 290-312

- 36 **Obarzanek E**, Lesem MD, Jimerson DC. Resting metabolic rate of anorexia nervosa patients during weight gain. *Am J Clin Nutr* 1994; **60**: 666-675 [PMID: 7942571]
- 37 **Kaye WH**, Gwirtsman HE, Obarzanek E, George DT. Relative importance of calorie intake needed to gain weight and level of physical activity in anorexia nervosa. *Am J Clin Nutr* 1988; **47**: 989-994 [PMID: 3376913]
- 38 **Dinneen S**, Alzaid A, Miles J, Rizza R. Metabolic effects of the nocturnal rise in cortisol on carbohydrate metabolism in normal humans. *J Clin Invest* 1993; **92**: 2283-2290 [PMID: 8227343 DOI: 10.1172/JCI116832]
- 39 **Djurhuus CB**, Gravholt CH, Nielsen S, Mengel A, Christiansen JS, Schmitz OE, Møller N. Effects of cortisol on lipolysis and regional interstitial glycerol levels in humans. *Am J Physiol Endocrinol Metab* 2002; **283**: E172-E177 [PMID: 12067858]
- 40 **Berneis K**, Vosmeer S, Keller U. Effects of glucocorticoids and of growth hormone on serum leptin concentrations in man. *Eur J Endocrinol* 1996; **135**: 663-665 [PMID: 9025709 DOI: 10.1530/eje.0.1350663]

**P- Reviewers:** Akgül S, Inui A, Marchesini G, Serafini G

**S- Editor:** Ji FF **L- Editor:** A **E- Editor:** Wu HL



## Role of ethnicity in social anxiety disorder: A cross-sectional survey among health science students

Philip De Jager, Sharain Suliman, Soraya Seedat

Philip De Jager, Vrije Universiteit, Faculty of Health Sciences, 1055 VB Amsterdam, The Netherlands

Sharain Suliman, Soraya Seedat, Department of Psychiatry, Faculty of Medicine and Health Sciences, Stellenbosch University, Tygerberg 7505, South Africa

**Author contributions:** De Jager P conceptualized and conducted the study, wrote the protocol, analyzed and interpreted data and was the first author on the manuscript; Suliman S analyzed and interpreted the data and co-authored the manuscript; Seedat S conceptualised the study, supervised the protocol and study, analyzed and interpreted the data and co-authored and supervised the manuscript.

**Supported by** The South African Research Chairs Initiative of the Department of Science and Technology and the National Research Foundation

**Correspondence to:** Dr. Sharain Suliman, Department of Psychiatry, Faculty of Medicine and Health Sciences, Stellenbosch University, PO Box 19063, Tygerberg 7505, South Africa. [sharain@sun.ac.za](mailto:sharain@sun.ac.za)

Telephone: +27-21-9389161 Fax: +27-21-9335790

Received: April 14, 2014 Revised: May 26, 2014

Accepted: June 18, 2014

Published online: July 16, 2014

Disorders Identification Test and Drug Use Disorders Identification Test, and depression with the Centre for Epidemiological Studies Depression Scale.

**RESULTS:** Of 112 students who completed the E-SPIN questionnaire, 54.4% ( $n = 61$ ) met criteria for SAD, with significantly more females than males meeting criteria. Ethnicity had a significant effect on SAD symptomatology, but there was no effect of ethnicity on the rates of drug and alcohol abuse in students with and without SAD. Overall significantly more students with SAD met criteria for depression compared with students without the disorder.

**CONCLUSION:** Among university students, SAD is prevalent regardless of whether interactions are with individuals of the same or different ethnic group. However, ethnicity may be an important determinant of social anxiety for some ethnic groups. SAD was significantly associated with major depression but not significantly associated with drug or alcohol abuse.

© 2014 Baishideng Publishing Group Inc. All rights reserved.

### Abstract

**AIM:** To investigate the influence of ethnicity in social anxiety disorder (SAD), and the relationship with symptom severity, depression and substance use or abuse, in health sciences' students.

**METHODS:** This was a cross-sectional survey of 112 1<sup>st</sup>, 2<sup>nd</sup> and 3<sup>rd</sup> year students from the Faculty of Medicine and Health Sciences at Stellenbosch University, Cape Town, South Africa. The self-reported Social Anxiety Spectrum questionnaire was used to assess for SAD. The Social Phobia Inventory (SPIN) was adapted to a version called the E-SPIN (Ethnic-SPIN) in order to evaluate the effects of ethnicity. Two sub-questions per stem question were included to assess whether SAD symptoms in social interactions were ethnicity dependent. Substance use was assessed with the Alcohol Use

**Key words:** Social anxiety; Social phobia; Ethnicity; Students; South Africa

**Core tip:** We investigated the relationship between social anxiety disorder (SAD) and ethnicity, as well as its association with depression and alcohol and drug abuse, among South African students. High levels of social anxiety were present and were significantly associated with major depression but not with drug or alcohol abuse. Ethnicity was found to independently influence social anxiety symptomatology, suggesting that it is an important factor in student interactions in this context. These results contribute to the extant literature by demonstrating that different risk factors may be uniquely associated with SAD for different ethnic/racial groups, and require further exploration given South Africa's historical context.

De Jager P, Suliman S, Seedat S. Role of ethnicity in social anxiety disorder: A cross-sectional survey among health science students. *World J Clin Cases* 2014; 2(7): 265-271 Available from: URL: <http://www.wjgnet.com/2307-8960/full/v2/i7/265.htm> DOI: <http://dx.doi.org/10.12998/wjcc.v2.i7.265>

## INTRODUCTION

Social anxiety disorder (SAD), which is characterized by a persistent fear of social or performance situations (such as public speaking) where embarrassment might occur, is a common, psychiatric condition, with a lifetime prevalence ranging from 7% to 13% in the general population<sup>[1]</sup>. Age of onset is generally early; by age 11 in about 50% individuals and by age 20 in approximately 80% of individuals<sup>[2]</sup>. SAD is also highly comorbid with major depression, substance use disorders and other anxiety disorders, and the lifetime prevalence of any two of the aforementioned conditions ranges from 69% to 81%<sup>[3]</sup>. A nationally representative household survey conducted in South Africa between 2002 and 2004 found the most prevalent group of disorders to be anxiety disorders (15.8%). After agoraphobia without panic, SAD was the second most common anxiety disorder. In addition, high lifetime rates of substance abuse (13.5%) and major depression (9.8%) with an early age at onset were documented<sup>[2,4]</sup>.

Psychological treatments and medication have been shown to be effective in the treatment of SAD, with a combination of the two seeming to be most beneficial<sup>[5-7]</sup>. Despite this, the condition remains underdiagnosed and only a small proportion of those in need receive treatment<sup>[8]</sup>, possibly due to factors such as fear of stigmatization, inability to access care due to financial issues, and lack of awareness of the disorder by both patients and service providers.

The student population is diverse and provides many opportunities for social contact and support. Academic activities require social interaction and performance as part of students' learning and assessment, while interpersonal skills are key attributes of student academic success<sup>[9]</sup>. University or college students fall in the age range of increased risk for the onset of SAD. As well as struggling with fundamental issues related to identity and self-management, students are particularly vulnerable to experiences of social anxiety<sup>[10,11]</sup>. Fears of confirming negative stereotypes may also play a significant role in the symptoms of SAD. A related phenomenon is the occurrence of intergroup anxiety, where interracial relations or exchanges carry the potential for intense social anxiety<sup>[12]</sup>. Stephan *et al.*<sup>[13]</sup> term intergroup anxiety as an emotion that involves feelings of uneasiness and awkwardness in the presence of out-group members (people from different ethnic groups than oneself). Recent literature has shown that ethnicity and culture both have a big impact on how anxiety is experienced and how individuals deal with it. In a review by Hofmann *et al.*<sup>[14]</sup>, the authors con-

cluded that an individual's social concerns need to be examined in the context of cultural, racial, and ethnic background to adequately assess the degree and expression of social anxiety and SAD. South Africa is a multicultural and multi-ethnic society and, given the particular circumstances of the country's colonial and apartheid past, it is important to understand the role of ethnicity in social interactions.

This study investigated the influence of ethnicity on social interactions and SAD, and the association of SAD with symptom severity, depression and substance use in a student sample. We hypothesised higher rates of social anxiety and distress in interactions between different ethnic groups compared with same-ethnicity interactions. We further hypothesised that ethnicity would independently predict social anxiety symptomatology and that social anxiety and distress in different-ethnicity interactions would be positively correlated with depression, alcohol and drug abuse symptomatology.

## MATERIALS AND METHODS

We conducted a cross-sectional survey among health science students (medical and allied health science students) at the Stellenbosch University Faculty of Medicine and Health Sciences, Cape Town (South Africa). We sampled 1<sup>st</sup>, 2<sup>nd</sup> and 3<sup>rd</sup> year students. The faculty is representative of all the main ethnic groupings in the country (Black, Coloured, Indian, White). The study was approved by the Health Research Ethics Committee of Stellenbosch University and was conducted in accordance with The Declaration of Helsinki and Medical Research Ethical Guidelines on Human Research. After obtaining permission from the respective student departments, an invitation was sent out *via* email to all students inviting them to complete an online questionnaire on a secure online site, SurveyMonkey.com. Carlbring *et al.*<sup>[15]</sup> have demonstrated that anxiety measures completed *via* online questionnaires show similar psychometric properties when compared with questionnaires administered through conventional methods. Survey monkey is a secure service that stores all data in an encrypted, anonymous form. In total three email invitations were sent out. We also made use of other recruitment methods, such as handing out flyers to students after lectures and advertising the survey on the local student website and on television (LCD) screens at the faculty. Students were required to provide informed consent prior to completing the survey. The informed consent form was available online and in the e-mails sent to students, and provided study information (*i.e.*, aims), as well as contact details of investigators and the ethics committee.

We developed a socio-demographic data form that was used to elicit socio-economic status (SES) and socio-demographic profiles. The SES variable was based on questions pertaining to household access to basic needs, number of inhabitants and their educational level, as well as total income. A total score out of 44 was then calculated. Three SES categories were created by dividing the

SES scores into thirds: low: 6-19, medium 20-33, high 34-44. This indicator is similar to that currently used by Statistics South Africa and has been used by others in the South African context<sup>[16]</sup>.

The social phobia inventory (SPIN) is a brief 17-item self-report instrument for measuring SAD severity. A cut off score of 19 distinguishes those with SAD from those without<sup>[17,18]</sup>. The SPIN consists of questions that evaluate fear, avoidance and physiological discomfort. Each of the 17 items is rated on a scale from 0 to 4: not at all, a little bit, somewhat, very much, and extremely (higher scores correspond to greater distress). Scores range from 0-68. The SPIN has proved to be a useful and valid self-rated scale to assess fear, avoidance and physiological aspects of SAD. It validly measures severity of illness, is sensitive to reduction in symptoms over time, and discriminates between treatments<sup>[18]</sup>. The internal consistency (Cronbach's alpha) for individuals with SAD was 0.92 and for combined clinical and non-clinical samples the Cronbach's alpha has been shown to be 0.95<sup>[18]</sup>. For the current study, we adapted the SPIN to evaluate the effects of ethnicity. The E-SPIN or Ethnicity-SPIN includes two sub-questions for each stem question to determine whether respondents experience an exacerbation of SAD symptoms and greater distress when interacting with individuals from a different ethnic group compared to interactions with their own ethnic group.

The Social Anxiety Spectrum Self-Report (SHY-SR) questionnaire is a self-report inventory, used to measure the spectrum of social anxiety. It was derived from the Structured Clinical Interview for Social Anxiety Spectrum, the SCI-SHY, an interview which has previously been validated in psychiatric samples and in control groups in a large Italian multi-center study<sup>[19,20]</sup>. The version of the SHY-SR used in the current study was the "last month" questionnaire. This version includes an appendix on substances and three domains: (1) the interpersonal sensitivity domain, which assesses hypersensitivity to criticism, judgment and refusal, discomfort when the centre of attention, low self-confidence, feeling of inferiority, poor assertiveness, and interpersonal difficulties; (2) the behavioral inhibition and somatic symptoms (BI) domain which explores social behaviour and somatic symptoms associated with social anxiety; and (3) the specific phobias (SP) domain, which assesses situations that may trigger anticipatory anxiety and avoidance behaviours. The items of the SP domain are grouped into 14 subsections, ranging from talking on the phone to dating. These questions are dichotomous (yes/no) and refer to experiences that have occurred in the last month. The instrument is designed for administration in both adults and adolescents. A variety of cut-off scores have been determined using the receiver operating characteristic curve on data used to investigate the validity and reliability of the SCI-SHY. The diagnostic cut-off score of 68, which has a sensitivity and specificity of 84.8% and 85.6%, respectively, was used here<sup>[21]</sup>.

The Center for Epidemiological Studies Depression Scale (CES-D) is a short 20-item questionnaire<sup>[22]</sup>. Each

item is rated on a four-point scale during the last seven-day period. The scales range from "rarely or none of the time" to "most or all of the time". Scores range from 0 to 60, with higher scores indicating more symptoms of depression. CES-D scores of 16 to 26 are considered indicative of mild depression and scores of 27 or more indicative of severe depression<sup>[23]</sup>. The CES-D has been validated in a number of studies in community and primary care populations and has good test-retest reliability<sup>[20]</sup>. The scale has very good internal reliability, with a Cronbach's alpha value of 0.85 in the general population and 0.90 in a psychiatric population<sup>[22]</sup>.

Alcohol Use Disorders Identification Test (AUDIT) detects hazardous and harmful alcohol use<sup>[24]</sup>. The AUDIT contains 10 items referring to alcohol consumption and alcohol-related problems in the past 12-mo period with a cut off score of 8. Responses to each question are scored from 0 to 4, giving a maximum possible score of 40. The AUDIT was designed to measure three domains; consumption (3 items), dependence (3 items) and alcohol-related consequences (4 items). In its original psychometric evaluation, 92% of those diagnosed with alcohol abuse had a score of 8 or more, while 94% of those with non-hazardous consumption had a score of less than 8<sup>[24]</sup>. In a study that assessed the psychometric performance of three alcohol use disorder tools including the AUDIT, the AUDIT had a Cronbach alpha of 0.75<sup>[25]</sup>.

The Drug Use Disorders Identification (DUDIT) (Berman *et al*<sup>[26]</sup>, 2005) is a self-report screening instrument that focuses on current drug-related problems. The eleven items of the DUDIT were chosen to yield information on the level of drug intake and fulfillment of selected criteria for substance abuse/harmful use and dependence according to the International Classification of Diseases, 10<sup>th</sup> edition (ICD-10) and Diagnostic and Statistical Manual of Mental Disorders, 4<sup>th</sup> edition (DSM-IV) diagnostic systems. Responses to each question are scored from 0 to 4 with a maximum score of 44. In the general population, the DUDIT can screen for drug-related problems at a cut-off score of 6 (for men) and 2 (for women). The DUDIT predicts drug dependence with a sensitivity of 90% for both DSM-IV and ICD-10 with a respective specificity of 78% and 88%, and has an internal reliability of 0.80.

### Statistical analysis

Only completed questionnaires were included in the data analysis. Demographic variables were compared between those with SAD and those without SAD on the E-SPIN using cross-tabulations with  $\chi^2$  statistics. The SHY-SR means and standard deviations of the sample were reported using the subscale cut-off scores of the instrument. Owing to missing data, 7 items were omitted from the SH-SR questionnaire. Domain scores were transformed to a 0-100 scale which facilitated comparison of domain scores with other studies. ANOVAs (analysis of variance tests) were conducted to determine differences between groups. Furthermore, we also compared AUDIT, DUDIT and CES-D cut off scores between



**Table 1 Means and standard deviations of the Ethnicity-Social Phobia Inventory (with questions of same and different ethnicity interactions), Social Anxiety Spectrum Self-Report (with subscale groups high, middle and low), Drug Use Disorders Identification Test, Alcohol Use Disorders Identification Test and Center for Epidemiological Studies Depression Scale scores of respondents**

	Mean	SD
E-SPIN	22.03	12.23
Interaction same ethnicity	20.36	11.31
Interaction different ethnicity	22.23	12.84
DUDIT	1.02	2.36
AUDIT	3.31	4.42
CES-D	17.12	12.89
SHY-SR cut-off	51.77	32.12
High > 67	87.79	22.15
Middle 59-67	66.00	1.73
Low < 59	31.48	15.01
SHY-SR sub-scale raw scores		
IPS	14.00	6.49
BI	5.58	4.12
SP	31.51	22.96
Transformed SHY-SR sub-scale scores (1-100 scale)		
IPS	48.3	22.4
BI	34.9	25.8
SP	31.6	23.4

N's vary from 89 to 112 due to missing data. The diagnostic cut-off score for the SHY-SR is 68, the cut-off score of 59 identifies subjects who score high on the social anxiety spectrum but do not meet the diagnostic criteria for the social anxiety disorder (SAD). SHY-SR: Sub-scale domains includes; IPS: Interpersonal sensitivity; BI: Behavioral inhibition; SP: Specific phobia. E-SPIN: Ethnicity-Social Phobia Inventory; DUDIT: Drug Use Disorders Identification Test; AUDIT: Alcohol Use Disorders Identification test; CES-D: Center for Epidemiological Studies Depression Scale; SHY-SR: Social Anxiety Spectrum Self-Report.

students with SAD and those without SAD using  $\chi^2$  tests. Multiple regression analysis was conducted with E-SPIN scores as the dependent variable and ethnicity as the independent variable. Variables such as age, gender, SES were used as covariates in the model. We used a linear regression model to determine if ethnicity predicts E-SPIN scores (*i.e.*, whether ethnicity provides additional explanatory power to explain social anxiety symptom severity). We selected a 5% increase in overall R-squared as our effect size. All statistical analyses were performed using the SPSS 19.0 software package (SPSS Inc., Chicago, IL)<sup>[27]</sup>.

## RESULTS

Of the 958 students invited to participate, responses were received from 120 students (12.5%). Respondents had a mean age of 19.68 years (SD = 2.48) and comprised of 40 (33.3%) males and 80 (66.6%) females. Given that the gender distribution of students at the university is roughly 50/50 this shows that females were more likely to complete the survey. The ethnicity of respondents was similar to that in the general undergraduate student population for Black and Coloured students (16% each), but there were significantly more Indian/Asian respondents (15% *vs* under 3% in the student population), and fewer

White respondents (48% *vs* 65% in the student population).

The majority were studying for a Bachelor of Medicine and Surgery degree 101 (84.2%), with the remainder (15.8%) being Bachelor students in Dietetics, Physiotherapy, Occupational Therapy, and Speech Language and Hearing Therapy. Of this sample, 112 finished the E-SPIN questionnaire (same and different ethnicity interactions), 90 finished the SHY-SR and DUDIT, whereas the AUDIT and CES-D were completed by 89 students. The mean SES score was 33 (range: 19-44) with all ethnic groups falling into the "high" SES category. Despite this, the difference in SES between ethnic groups approached significance, with white and black participants endorsing a higher SES than Coloured and Indian participants, based on our scale [ $F(3,43) = 2.804$ ;  $P = 0.051$ ].

Table 1 differentiates students in the sample based on clinical cut-offs on the various measures of psychopathology, and presents the means and standard deviations of the original and transformed (0-100) scores of the SHY-SR. Of the 90 students who completed the SHY-SR, 28 (31.1%) scored above the diagnostic cut-off score of 68 and had a mean score of 51.77 (SD = 32.12). High scorers (5.6%) had a mean score of 87.79 (SD = 22.15) while low scorers (63.3%) students had a mean score of 31.48 (SD = 15.01). Ethnic groups did not differ significantly on total SHY-SR scores, but there was a significant difference in the SP domain  $F(3,86) = 2.867$ ,  $P = 0.041$ , with Coloured students scoring significantly higher than White students.

Table 2 shows the association of SAD with socio-demographic and psychopathology variables. 54.5% ( $n = 61$ ) of students met criteria for SAD, with significantly more females 63.2% ( $n = 48$ ), than males 36.1% ( $n = 13$ ). More students met criteria for SAD in the context of different ethnic interactions (59.8%,  $n = 67$ ) than in the context of same ethnicity interactions (53.6%,  $n = 60$ ). Gender differences were present with significantly more females than males meeting criteria for SAD, both in same ethnicity [60.5% females ( $n = 46$ ) *vs* 38.9% males ( $n = 14$ ) ( $\chi^2 = 4.598$ ,  $df = 1$ ,  $P < 0.05$ )], and different ethnicity [67.1 % females ( $n = 51$ ) *vs* 44.4% males ( $n = 16$ ) ( $\chi^2 = 5.222$ ,  $df = 3$ ,  $P < 0.05$ )] interactions. Further, there was an association between ethnic group and SAD in the context of same ethnic interactions; Black students experienced significantly more anxiety in interactions with others of ( $\chi^2 = 8.530$ ,  $df = 3$ ,  $P < 0.05$ ).

There was no effect of ethnicity on the rates of drug and alcohol abuse in students with and without SAD. Overall significantly more students with SAD met criteria for depression (73.8%) compared with students without the disorder (26.2%), ( $\chi^2 = 7.512$ ,  $df = 1$ ,  $P < 0.01$ ). This was true both for same ethnicity (73.8% *vs* 26.2%,  $\chi^2 = 10.041$ ,  $df = 1$ ,  $P < 0.01$ ) and different ethnicity (73.8% *vs* 26.2%,  $\chi^2 = 5.751$ ,  $df = 1$ ,  $P < 0.01$ ) interactions (Table 2).

We conducted a multiple linear regression with the E-SPIN total score as the independent variable, ethnicity as the dependent variable, and SES, age and gender as covariates. The adjusted  $R^2$  was 0.074. In subsequent

**Table 2 Social anxiety (Ethnicity-Social Phobia Inventory scores): Socio-demographic variables and associated psychopathology in students with and without social anxiety disorder**

Socio-demographic status:	E-SPIN (same ethnicity)			E-SPIN (different ethnicity)		
	No-SAD <i>n</i> (%)	SAD <i>n</i> (%)	$\chi^2$ ( <i>P</i> )	No-SAD <i>n</i> (%)	SAD <i>n</i> (%)	$\chi^2$ ( <i>P</i> )
Gender						
Male	22 (61.1)	14 (38.9)	4.60 <sup>a</sup>	20 (55.6)	16 (44.4)	5.22 <sup>a</sup>
Female	30 (39.5)	46 (60.5)		25 (32.9)	51 (67.1)	
Ethnicity						
Black	3 (17.6)	14 (82.4)	8.53 <sup>a</sup>	3 (17.6)	14 (82.4)	6.02 (0.11)
White	31 (56.4)	24 (43.6)		27 (49.1)	28 (50.9)	
Indian/Asian	8 (47.1)	9 (52.9)		7 (41.2)	10 (57.8)	
Colored	7 (36.8)	12 (63.2)		6 (31.6)	13 (68.4)	
SES						
Low	1 (50.0)	1 (50.0)	3.84 (0.15)	1 (50.0)	1 (50.0)	5.19 (0.08)
Medium	19 (36.5)	33 (63.5)		15 (28.8)	37 (71.2)	
High	32 (55.2)	26 (44.8)		29 (50.0)	29 (50.0)	
Clinical measures:						
DUDIT						
No drug related problems	31 (41.3)	44 (58.7)	1.76 (0.18)	30 (40.0)	45 (60.0)	0.23 (0.63)
Drug related problems	9 (60.0)	6 (40.0)		5 (33.3)	10 (66.7)	
AUDIT						
No alcohol related problems	32 (42.7)	43 (57.3)	0.26 (0.61)	29 (38.7)	46 (61.3)	0.09 (0.77)
Alcohol related problems	7 (50.0)	7 (50.0)		6 (42.9)	8 (57.1)	
CES-D						
No depression	28 (59.6)	19 (40.4)	10.04 <sup>b</sup>	24 (51.1)	23 (48.9)	5.75 <sup>a</sup>
Depression	11 (26.2)	31 (73.8)		11 (26.2)	31 (73.8)	

<sup>a</sup>*P* < 0.05, 60.5% females (*n* = 46) *vs* 38.9% males (*n* = 14); different ethnicity 67.1 % females (*n* = 51) *vs* 44.4% males; and anxiety in ethnic group and SAD in the context of same-ethnic interactions-Black students *vs* others of their own ethnicity; <sup>b</sup>*P* < 0.01, students with SAD met criteria for depression (73.8%) *vs* students without the disorder (26.2%); same ethnicity 73.8% *vs* 26.2%; and different ethnicity 73.8% *vs* 26.2%. SES Categories Low: 6-19; Medium: 20-33; High: 34-44; E-SPIN: Ethnicity-Social Phobia Inventory; DUDIT: Drug Use Disorders Identification Test; AUDIT: Alcohol Use Disorders Identification Test; CES-D: Center for Epidemiological Studies Depression Scale; SES: Social economic status; SHY-SR: Social Anxiety Spectrum Self-Report Scale.

multiple linear regression with ethnicity excluded, the adjusted *R*<sup>2</sup> was 0.068, (a decrease of 6%). We had selected a 5% change in overall *R*-squared as the effect size, thus ethnicity had sufficient explanatory power in predicting E-SPIN scores, when controlling for age, gender and SES.

## DISCUSSION

We investigated the relationship between SAD and ethnicity in a student sample, as well as its association with depression and alcohol and drug abuse. This is, to our knowledge, the first study of this nature among South African students. South Africa is a multicultural and multi-ethnic society and, given the country's colonial and apartheid past, it is important to understand the role of ethnicity in social interactions. University or college students fall in the age group of increased risk for the onset of SAD. As well as struggling with fundamental issues related to identity and self-management, students are particularly vulnerable to experiences of social anxiety<sup>[10,11]</sup>.

First, more than half of the sample (54.4%) met criteria for SAD. This rate increased to 60.8% in response to questions regarding interactions with different ethnic groups. Although these rates are significantly higher than in the general population, our sample, as a whole, does not appear to suffer more from SAD than other student samples, as former studies have tended to report higher rates using the SPIN in student populations<sup>[1,10,28]</sup>. Stewart *et al*<sup>[29]</sup> also

found a high prevalence of SAD in college students and suggested that normative developmental and contextual issues in the lives of college students may be contributory.

Second, SHY-SR sub-scale domain scores were relatively high, and higher than in an Italian study of 520 high school students (mean age of 18.4 years) in their last year of school<sup>[21]</sup>. Transition from high school to a tertiary setting with the additional academic and social adaptational pressures may partially explain the higher social anxiety symptomatology in the current study.

Third, SAD was more prevalent among females which is consistent with community samples internationally<sup>[3,30]</sup>. However, findings from student samples indicate that gender differences are not common. For instance, there was no significant main effect for gender in a study by Stewart *et al*<sup>[11]</sup>. Further, in a study that compared a clinical sample with a non-clinical undergraduate sample, although women in the clinical sample reported relatively higher fears of criticism/embarrassment and authority than a semi-colon men, suggesting that women with SAD may be more fearful of criticism/embarrassment and more fearful of authority than men, this was not shown in the non-clinical undergraduate sample<sup>[31]</sup>.

Fourth, we found that ethnicity independently influenced severity of social anxiety symptomatology, suggesting that it is an important factor in student interactions in the South African context. Previous research in the area of intercultural communication has suggested that

uncertainty as well as anxiety are important predictors of avoidance behaviour in intercultural encounters<sup>[32,33]</sup>. Given that the expressions of racial bias are no longer socially acceptable<sup>[9]</sup>, research on intergroup prejudice, in particular, indicates that the idea of appearing prejudiced in front of others may elicit strong social anxiety, which may emerge in interracial interactions, as well as in same-race interactions in which an individual fears social sanctions from in-group members for expressing prejudice toward an out-group<sup>[34]</sup>.

Of interest was that Black students appear to fear social disapproval from others of their own ethnicity more than from those of other ethnicities. A possible explanation for this may be that this group of students experienced greater stereotype confirmation concern, a construct described as “a chronic experience of uncertainty and apprehension about appearing to confirm as self-characteristic, a stereotype about ones’ group”<sup>[35]</sup>, among their own ethnic group. Furthermore, Coloured students were found to experience significantly more anxiety in situations that triggered anticipatory anxiety and avoidance behaviours, such as talking on the phone (the SHY-SR specific phobias domain). These results, on the contribution of ethnicity in SAD, are not strongly significant but require further exploration given the historical context, and contribute to the extant literature by demonstrating that different risk factors may be uniquely associated with SAD for different ethnic/racial groups.

SAD was significantly associated with major depression but not significantly associated with drug or alcohol abuse. These findings are consistent with a study on the prevalence of SAD and comorbidities among Nigerian undergraduates, which found that both lifetime and 12 mo depression were significantly associated with lifetime and 12 mo SAD but that there was no significant relationship between SAD and alcohol abuse<sup>[36]</sup>. This suggests that in the student population depression is more likely to be co-morbid with SAD than substance abuse. These findings are further supported by a study of 228 American college students which found that alcohol problems were more directly related to peer influence and social networks than to social anxiety<sup>[37]</sup>. High rates of co-morbidity with depression among university students contribute to further disability (*e.g.*, academic achievement) and quality of life impairments.

Results of this study must be considered preliminary given the small sample size and the fact that self-report measures were used. Participant bias is also an important consideration, as this was a convenience sample and only 112 of a total of 958 first, second and third year students who were invited actually participated. It is therefore plausible that the sample is skewed toward students who were more symptomatic and who chose to participate. This survey could be extended to include health science students at other universities, especially those institutions characterised by greater ethnic diversity. Furthermore, it would be advantageous to explore ways to increase student participation while keeping anonymity intact. It would also be useful to conduct a comparative analysis of

first, second and third year students to elucidate whether SAD prevalence and symptom severity intensifies or is alleviated through the undergraduate student years, particularly with regards to in- and out-group interactions.

## COMMENTS

### Background

Social anxiety disorder (SAD) is a common psychiatric condition that is often comorbid with major depression, substance use disorders and other anxiety disorders. University students fall in the age range of increased risk for the onset of SAD. Recent literature has shown that ethnicity and culture both impact on the experience of anxiety and how individuals deal with it, and indicate that an individual's social concerns need to be examined in the context of cultural, racial, and ethnic background to adequately assess the degree and expression of social anxiety and SAD.

### Research frontiers

South Africa is a multicultural and multi-ethnic society and, given the particular circumstances of the country's colonial and apartheid past, it is important to understand the role of ethnicity in social interactions.

### Innovations and breakthroughs

Although the results on the contribution of ethnicity in SAD are not strongly significant, they do require further exploration given the historical context. This study contributes to the extant literature demonstrating that different risk factors may be uniquely associated with SAD for different ethnic/racial groups.

### Applications

This study indicates that ethnicity has the potential to independently influence severity of social anxiety symptomatology, suggesting that it is an important factor in student interactions, particularly in the South African context, and as such should be considered when assessing for SAD.

### Terminology

SAD or social anxiety disorder is a fairly prevalent anxiety disorder that causes extreme discomfort or fear regarding being judged or evaluated by others in social interactions.

### Peer review

The manuscript aims to investigate the role of ethnic factors in SAD among South African medical students. The topic is interesting and of high scientific and social significance.

## REFERENCES

- 1 **Furmark T.** Social phobia: overview of community surveys. *Acta Psychiatr Scand* 2002; **105**: 84-93 [PMID: 11939957 DOI: 10.1034/j.1600-0447.2002.1r103.x]
- 2 **Stein DJ, Seedat S, Herman A, Moomal H, Heeringa SG, Kessler RC, Williams DR.** Lifetime prevalence of psychiatric disorders in South Africa. *Br J Psychiatry* 2008; **192**: 112-117 [PMID: 18245026 DOI: 10.1192/bjp.bp.106.029280]
- 3 **Fehm L, Wittchen HU.** Comorbidity in Social Anxiety Disorder. In: Bandelow B, Stein DJ, eds. *Social Anxiety Disorder*. New York, NY: Marcel Dekker. 2004: 49-63
- 4 **Herman AA, Stein DJ, Seedat S, Heeringa SG, Moomal H, Williams DR.** The South African Stress and Health (SASH) study: 12-month and lifetime prevalence of common mental disorders. *S Afr Med J* 2009; **99**: 339-344 [PMID: 19588796]
- 5 **Acarturk C, Cuijpers P, van Straten A, de Graaf R.** Psychological treatment of social anxiety disorder: a meta-analysis. *Psychol Med* 2009; **39**: 241-254 [PMID: 18507874 DOI: 10.1017/S0033291708003590]
- 6 **Powers Mark B, Sigmarsson Snorri R, Emmelkamp Paul MG** (2008). A meta-analytic review of psychological treatments for social anxiety disorder. *INT J COGN THER* 2008; **1**: 94-113 [DOI: 10.1521/ijct.2008.1.2.94]
- 7 **Roy-Byrne Peter P, Cowley Deborah S** (2007). Pharmacological treatments for panic disorder, generalized anxiety disorder, specific phobia, and social anxiety disorder. In: *A guide to treatments that work* (3rd ed.). Nathan, Peter E.



- (Ed.); Gorman, Jack M. (Ed.); New York, NY, US: Oxford University Press, 2007: 395-430
- 8 **Wang PS**, Berglund P, Olfson M, Pincus HA, Wells KB, Kessler RC. Failure and delay in initial treatment contact after first onset of mental disorders in the National Comorbidity Survey Replication. *Arch Gen Psychiatry* 2005; **62**: 603-613 [PMID: 15939838 DOI: 10.1001/archpsyc.62.6.603]
  - 9 **Topham P**. Feeling stupid: A survey of university students' experience of social anxiety in learning situations (Project Report). Bristol UK: University of The West of England Bristol, 2009: 2-75
  - 10 **Stewart D**, Johnson E, Walker J and Degen G. Prevalence of social phobia and its relationship with psychopathology and egocentrism in a university setting. Quebec City: The Canadian Psychological Association Annual Conference, 2001
  - 11 **Stewart D**, Walker J, Porpiglia C. Social anxiety on campus: Prevalence in clinical and non-clinical university student samples (2005, May). The Anxiety Disorders Association of Canada Annual Conference, Toronto: ON, 2005
  - 12 **Schlenker BR**, Leary MR. Social anxiety and self-presentation: a conceptualization and model. *Psychol Bull* 1982; **92**: 641-669 [PMID: 7156261 DOI: 10.1037/0033-2909.92.3.641]
  - 13 **Stephan WG**, Stephan CW. Intergroup anxiety. *J Soc Issues* 1985; **55**: 729-743 [DOI: 10.1111/0022-4537.00144]
  - 14 **Hofmann SG**, Anu Asnaani MA, Hinton DE. Cultural aspects in social anxiety and social anxiety disorder. *Depress Anxiety* 2010; **27**: 1117-1127 [PMID: 21132847 DOI: 10.1002/da.20759]
  - 15 **Carlbring P**, Brunt S, Bohman S, Austin D, Richards J, Öst LG, Andersson G. Internet vs. paper and pencil administration of questionnaires commonly used in panic/agoraphobia research. *Computers in Human Behaviour* 2007; **23**: 1421-1434 [DOI: 10.1016/j.chb.2005.05.002]
  - 16 **Myburgh NG**, Solanki GC, Smith MJ, Lalloo R. Patient satisfaction with health care providers in South Africa: the influences of race and socioeconomic status. *Int J Qual Health Care* 2005; **17**: 473-477 [PMID: 15985504 DOI: 10.1093/intqhc/mzi062]
  - 17 **Connor KM**, Davidson JR, Churchill LE, Sherwood A, Foa E, Weisler RH. Psychometric properties of the Social Phobia Inventory (SPIN). New self-rating scale. *Br J Psychiatry* 2000; **176**: 379-386 [PMID: 10827888 DOI: 10.1192/bjp.176.4.379]
  - 18 **Antony MM**, Coons MJ, McCabe RE, Ashbaugh A, Swinson RP. Psychometric properties of the social phobia inventory: further evaluation. *Behav Res Ther* 2006; **44**: 1177-1185 [PMID: 16257387 DOI: 10.1016/j.jbrat.2005.08.013]
  - 19 **Dell'Osso L**, Rucci P, Cassano GB, Maser JD, Endicott J, Shear MK, Sarno N, Sacttoni M, Grochocinski VJ, Frank E. Measuring social anxiety and obsessive-compulsive spectra: comparison of interviews and self-report instruments. *Compr Psychiatry* 2002; **43**: 81-87 [PMID: 11893984 DOI: 10.1053/comp.2002.30795]
  - 20 **Dell'Osso L**, Cassano GB, Sarno N Millanfranchi A, Pfanner C, Gemignani A, Maser JDM, Shear K, Grochocinski VJ, Rucci P, Frank E. Validity and reliability of the Structured Clinical Interview for Obsessive-compulsive Spectrum (SCI-OBS) and of the Structured Clinical Interview for Social Phobia Spectrum (SCI-SHY). *Intern J Methods Psychiat Res* 2000; **9**: 11-24 [DOI: 10.1002/mpr.76]
  - 21 **Dell'Osso L**, Sacttoni M, Papasogli A, Rucci P, Ciapparelli A, Di Poggio AB, Ducci F, Hardoy C, Cassano GB. Social anxiety spectrum: gender differences in Italian high school students. *J Nerv Ment Dis* 2002; **190**: 225-232 [PMID: 11960083 DOI: 10.1097/00005053-200204000-00003]
  - 22 **Radloff LS**. The CES-D Scale: A self-report depression scale for research in the general population. *Appl Psychol Meas* 1977; **1**: 385-401 [DOI: 10.1177/014662167700100306]
  - 23 **Zich JM**, Attkisson CC, Greenfield TK. Screening for depression in primary care clinics: the CES-D and the BDI. *Int J Psychiatry Med* 1990; **20**: 259-277 [PMID: 2265888 DOI: 10.2190/LYKR-7VHP-YJEM-MKM2]
  - 24 **Saunders JB**, Aasland OG, Babor TF, de la Fuente JR, Grant M. Development of the Alcohol Use Disorders Identification Test (AUDIT): WHO Collaborative Project on Early Detection of Persons with Harmful Alcohol Consumption--II. *Addiction* 1993; **88**: 791-804 [PMID: 8329970 DOI: 10.1111/j.1360-0443.1993.tb02093.x]
  - 25 **Rumpf HJ**, Hapke U, Meyer C, John U. Screening for alcohol use disorders and at-risk drinking in the general population: psychometric performance of three questionnaires. *Alcohol Alcohol* 2002; **37**: 261-268 [PMID: 12003915 DOI: 10.1093/alcalc/37.3.261]
  - 26 **Berman AH**, Bergman H, Palmstierna T, Schlyter F. Evaluation of the Drug Use Disorders Identification Test (DUDIT) in criminal justice and detoxification settings and in a Swedish population sample. *Eur Addict Res* 2005; **11**: 22-31 [PMID: 15608468 DOI: 10.1159/000081413]
  - 27 SPSS Inc. Chicago, IL SPSS Statistics for Windows Version 19.0 2010. Available from: URL: <http://www-01.ibm.com/software/analytics/spss/>
  - 28 **Radomsky AS**, Ashbaugh AR, Saxe ML, Ouimet AJ, Golden ER, Lavoie SL, O'Connor, KP. Psychometric properties of the French and English versions of the Social Phobia Inventory. *Can J Behav Sci* 2006; **38**: 354-360 [DOI: 10.1037/cjbs2006021]
  - 29 **Stewart DW**, Mandrusiak M. Social Phobia in College Students. *J college stud psychother* 2007; **22**: 65-76 [DOI: 10.1300/J035v22n02\_06]
  - 30 **Grant BF**, Hasin DS, Blanco C, Stinson FS, Chou SP, Goldstein RB, Dawson DA, Smith S, Saha TD, Huang B. The epidemiology of social anxiety disorder in the United States: results from the National Epidemiologic Survey on Alcohol and Related Conditions. *J Clin Psychiatry* 2005; **66**: 1351-1361 [PMID: 16420070 DOI: 10.4088/JCP.v66n1102]
  - 31 **Carleton RN**, Collimore KC, Asmundson GJ, McCabe RE, Rowa K, Antony MM. SPINning factors: factor analytic evaluation of the Social Phobia Inventory in clinical and nonclinical undergraduate samples. *J Anxiety Disord* 2010; **24**: 94-101 [PMID: 19818582 DOI: 10.1016/j.janxdis.2009.09.003]
  - 32 **Duronto PM**, Nishida T and Nakayama S. Uncertainty, anxiety, and avoidance in communication with strangers. *Int J Intercult Relat* 2005; **29**: 549-560 [DOI: 10.1016/j.jintrel.2005.08.003]
  - 33 **Hubbert KN**, Gudykunst WB, Guerrero SL. Intergroup communication over time. *Int J Intercult Relat* 1999; **23**: 13-46 [DOI: 10.1016/S0147-1767(98)00024-8]
  - 34 **Ofan RH**, Rubin N, Amodio DM. Situation-based social anxiety enhances the neural processing of faces: evidence from an intergroup context. *SCAN* 2013: 1-7
  - 35 **Contrada RJ**, Ashmore RD, Gary ML, Coups E, Egeth JD, Sewell A, Ewell K, Goyal TM, Chasse V. Measures of Ethnicity-Related Stress: Psychometric properties, ethnic group differences, and associations with well-being. *J Appl Soc Psychol* 2001; **31**: 1775-1820 [DOI: 10.1111/j.1559-1816.2001.tb00205.x]
  - 36 **Bella TT**, Omigbodun OO. Social phobia in Nigerian university students: prevalence, correlates and co-morbidity. *Soc Psychiatry Psychiatr Epidemiol* 2009; **44**: 458-463 [PMID: 18979054 DOI: 10.1007/s00127-008-0457-3]
  - 37 **Ham LS**, Hope DA. Incorporating social anxiety into a model of college problem drinking: replication and extension. *Psychol Addict Behav* 2006; **20**: 348-355 [PMID: 16938075 DOI: 10.1037/0893-164X.20.3.348]

P- Reviewers: Dremencov E, Kravos M S- Editor: Ji FF

L- Editor: A E- Editor: Wu HL





## Cut-off of body mass index and waist circumference to predict hypertension in Indian adults

Tanu Midha, Vinay Krishna, Bhola Nath, Ranjeeta Kumari, Yashwant Kumar Rao, Umeshwar Pandey, Samarjeet Kaur

Tanu Midha, Department of Community Medicine, Government Medical College, Kannauj, Uttar Pradesh 209732, India

Vinay Krishna, Department of Cardiovascular and Thoracic Surgery, LPS Institute of Cardiology, Kanpur, Uttar Pradesh 208002, India

Bhola Nath, Department of Community Medicine, VCSGMS and RI, Srinagar, Garhwal, Uttarakhand 246174, India

Ranjeeta Kumari, Department of Community and Family Medicine, AIIMS, Rishikesh 249201, India

Yashwant Kumar Rao, Department of Pediatrics, GSVM Medical College, Kanpur, Uttar Pradesh 208002, India

Umeshwar Pandey, Department of Cardiology, LPS Institute of Cardiology, Kanpur, Uttar Pradesh 208002, India

Samarjeet Kaur, Department of Community Medicine, GSVM Medical College, Kanpur, Uttar Pradesh 208002, India

**Author contributions:** Midha T, Krishna V, Nath B and Kumari R contributed to conception and design of the study, acquisition of data, or analysis and interpretation of data, drafting the article and final approval of the version to be published; Rao YK, Pandey U and Kaur S helped in conception and design of the study, interpretation of data, revising the article and final approval of the version to be published.

**Correspondence to:** Tanu Midha, Assistant Professor, Department of Community Medicine, Government Medical College, National Highway 91A, Kannauj, Uttar Pradesh 209732, India. [tanumidha2001@gmail.com](mailto:tanumidha2001@gmail.com)

Telephone: +91-933-5828435 Fax: +91-512-2535483

Received: January 9, 2014 Revised: February 25, 2014

Accepted: June 10, 2014

Published online: July 16, 2014

naire was used to elicit the required information from the study participants and the diagnostic criteria for hypertension were taken according to the Seventh Joint National Committee Report on Hypertension (JNC-7). Receiver operating characteristic (ROC) analysis was used to estimate the cut-off values of BMI and waist circumference to predict hypertension.

**RESULTS:** The ROC analysis revealed that BMI is a good predictor of hypertension for both men (area under the ROC curve 0.714) and women (area under the ROC curve 0.821). The cut-off values of BMI for predicting hypertension were identified as  $\geq 24.5$  kg/m<sup>2</sup> in men and  $\geq 24.9$  kg/m<sup>2</sup> in women. Similarly, the ROC analysis for waist circumference showed that it is a good predictor of hypertension both for men (area under the ROC curve 0.784) and women (area under the ROC curve 0.815). The cut-offs for waist circumference for predicting hypertension were estimated as  $\geq 83$  cm for men and  $\geq 78$  cm for women. Adults with high BMI or high waist circumference had a higher prevalence of hypertension, respectively.

**CONCLUSION:** Simple anthropometric measurements such as BMI and waist circumference can be used for screening people at increased risk of hypertension in order to refer them for more careful and early diagnostic evaluation. Policies and programs are required for primary and secondary prevention of hypertension.

© 2014 Baishideng Publishing Group Inc. All rights reserved.

### Abstract

**AIM:** To determine the cut-off values of body mass index (BMI) and waist circumference to predict hypertension in adults in north India.

**METHODS:** A community based cross-sectional study was conducted in 801 subjects in Kanpur, aged 20 years and above, using multistage stratified random sampling technique. A pre-tested structured question-

**Key words:** Anthropometric indices; Body mass index; Waist circumference; Obesity; Hypertension; Adults

**Core tip:** The Receiver operating characteristic analysis for body mass index (BMI) and waist circumference, respectively, showed good discriminatory power for hypertension in both men and women. The cut-off for BMI was identified as  $\geq 24.5$  kg/m<sup>2</sup> in men and  $\geq 24.9$

kg/m<sup>2</sup> in women. The cut-off for waist circumference for screening of hypertension was estimated as  $\geq 83$  cm in men and  $\geq 78$  cm in women. BMI and waist circumference, being simple tools in identifying hypertension, can be used for primordial and primary prevention and can thereby bring about a substantial reduction in cardiovascular morbidity and mortality which occurs as a consequence of hypertension.

Midha T, Krishna V, Nath B, Kumari R, Rao YK, Pandey U, Kaur S. Cut-off of body mass index and waist circumference to predict hypertension in Indian adults. *World J Clin Cases* 2014; 2(7): 272-278 Available from: URL: <http://www.wjg-net.com/2307-8960/full/v2/i7/272.htm> DOI: <http://dx.doi.org/10.12998/wjcc.v2.i7.272>

## INTRODUCTION

According to World Health Organization (WHO), cardiovascular diseases (CVDs) are the number one cause of death globally: more people die annually from CVDs than from any other cause<sup>[1]</sup>. An estimated 17.3 million people died from CVDs in 2008, representing 30% of all global deaths. The prevalence of hypertension in adults aged 25 years and above, worldwide, was around 40% in 2008<sup>[1]</sup>. Globally, raised blood pressure is estimated to cause 7.5 million deaths, about 12.8% of the total mortality. This, accounts for 57 million disability adjusted life years (DALYS) or 3.7% of total DALYS<sup>[1]</sup>. WHO has estimated that hypertension is directly responsible for about 62% of CVDs and 49% of ischemic heart disease (IHD) worldwide<sup>[2]</sup>.

A meta-analysis of prevalence studies on hypertension in India, from January 2000 to June 2012, revealed a high prevalence of hypertension in the urban (40.8%) as well as rural population (17.9%)<sup>[3]</sup>. India accounts for 17% of the world's population, second largest in the world, thereby contributing largely to the statistics of any disease in the world<sup>[4]</sup>.

Hypertension is a controllable disease and it has been reported that targeted reductions in blood pressure in hypertensives as well as modest population-wide blood pressure reductions are expected to produce large reductions in the burden of cardiovascular disease<sup>[5]</sup>. Miall suggested that genetic influences contribute not more than a third to the variance in blood pressure levels<sup>[6]</sup>. If the remaining two-thirds are environmental in origin, then an understanding of these environmental factors and appropriate preventive measures could help to bring down the burden of hypertension in the world. According to the Seventh Report of the Joint National Committee (JNC-7) on prevention, detection, evaluation, and treatment of high blood pressure, modification of risk factors plays an important role in the prevention and control of high blood pressure<sup>[7]</sup>.

Recent studies show that for every known person with hypertension there are two persons with either undi-

agnosed hypertension or prehypertension<sup>[8]</sup>. Screening the population for hypertension can go a long way in identifying individuals with undiagnosed hypertension and prevent a significant proportion of cardiovascular morbidity and mortality due to inapparent hypertension.

Being overweight in adulthood is well known to increase the risk of CVD especially hypertension<sup>[9]</sup>. It has also been seen that having a body mass index (BMI) outside the normal range significantly worsens risk parameters for CVD in school aged children<sup>[10]</sup>. Recognizing obesity using BMI and waist circumference as a marker, and thereby screening for cardiovascular risk can be a simple and inexpensive method of combating CVDs at the primary health care level. Given the magnitude of the problem of hypertension in India and its grave cardiovascular consequences, accurate estimates of cut-offs of BMI and waist circumference in predicting hypertension in the Indian population are necessary to plan effective control measures.

## MATERIALS AND METHODS

### Study population

The study population consisted of the total population of Kanpur district aged more than 20 years.

### Study design and sample size

This was a population based cross-sectional study. The sample size required ( $N = 372$ ) was calculated taking a prevalence of obesity of 6.2%, as reported in the "Five City study" from Moradabad, with a precision of 2.5% and a confidence level of 95%<sup>[11]</sup>. The formula used was,  $n = Z_{(1-\alpha/2)}^2 pq/d^2$  (where  $Z_{(1-\alpha/2)}$  was taken at 95% confidence;  $p$  = prevalence of obesity,  $q = 100-p$ ;  $d$  = absolute precision). For this study,  $p = 6.2\%$ ;  $q = 93.8\%$ ;  $d = 2.5\%$ . Adding a 10% for incomplete answers, the total number came out to be 409. Since it was a multistage stratified random sampling, a design effect of 2 was included to minimize any error due to inherent variation in the population. The calculated sample size was multiplied by 2 to obtain the sample size of 818. The data was analyzed for 801 subjects only who had provided complete answers.

### Sampling technique

Urban Kanpur has 110 wards and a total population of 2797511 according to 2001 census, and rural Kanpur has 10 blocks and a population of 1370488 which implies a ratio of 2:1 respectively<sup>[12]</sup>. Therefore, applying Probability Proportional to Size (PPS), out of 818 subjects, two-thirds (545) were selected from the urban population and one-third (273) were selected from the rural population. Multistage stratified random sampling technique was used to select representative subjects of Kanpur district. At the first stage, 8 wards were randomly selected to study the urban population<sup>[13]</sup>. Similarly, to study the rural population, 4 blocks were randomly selected<sup>[14]</sup>. At the second stage, 1 urban locality from each ward was randomly selected. Similarly, 1 village from each block was randomly selected. A total of 68 subjects from each

**Table 1** Characteristics of the study population

Parameters	Men (n = 356)	Women (n = 445)	Total (n = 801)
Age (yr)	36.4 ± 13.8	34.8 ± 11.6	35.5 ± 12.6
Weight (kg)	58.6 ± 11.5	51.7 ± 11.7	54.8 ± 12.1
Height (cm)	165.3 ± 7.1	151.7 ± 5.9	157.7 ± 9.3
BMI (kg/m <sup>2</sup> )	21.4 ± 3.9	22.4 ± 4.6	21.9 ± 4.3
Waist circumference (cm)	78.9 ± 11.0	74.4 ± 11.1	76.5 ± 11.3
SBP (mmHg)	127 ± 16	122 ± 18	124 ± 17
DBP (mmHg)	82 ± 9	78 ± 10	80 ± 9

Values are written as mean ± SD. SBP: Systolic blood pressure; DBP: Diastolic blood pressure; BMI: Body mass index.

urban locality/village were interviewed to complete the required sample size.

### Selection of subjects

The households in every urban area/village were selected for the study by systematic sampling. Depending upon the population of the particular urban locality/village, a random number was chosen and every  $n^{\text{th}}$  household was selected for the study. This process was continued till the required sample size was completed. In every household, only one member, aged more than 20 years was randomly selected. Out of the 545 respondents interviewed in the urban area, 10 were excluded owing to incomplete answers, whereas of the 273 respondents interviewed in the rural area 7 were excluded. Therefore, the final analysis included the responses from a total of 801 study subjects. Data collection was done from December 2006 to February 2007.

### Data collection

A pre-tested structured questionnaire was used to elicit the required information from the study participants. A standard mercury sphygmomanometer was used for recording blood pressure. Before the measurement was taken, the patient was seated comfortably for at least 5 min. Care was taken that the arm muscles were relaxed and the arm was supported at heart level. The cuff was applied to the right upper arm and was inflated until the manometer reading was 30 mm Hg above the level at which the radial pulse disappears, and then slowly deflated at a rate of approximately 2 mmHg/s. During this time, the Korotkoff sounds were monitored using a stethoscope placed over the brachial artery. The first (appearance) and the fifth (disappearance) Korotkoff sounds were recorded as the systolic and diastolic blood pressure, respectively. Blood pressures were measured twice and their mean was recorded. According to JNC-7<sup>[15]</sup>, normal blood pressure was defined as a systolic blood pressure (SBP) < 120 mmHg and a diastolic blood pressure (DBP) < 80 mmHg; pre-hypertension as SBP 120-139 mmHg and/or DBP 80-89 mmHg; Stage I hypertension as SBP 140-159 mmHg and/or DBP 90-99 mmHg and stage II hypertension as ≥ 160 mmHg and/or DBP ≥ 100 mmHg. In the present study, subjects in stage I and Stage II were considered as hypertensive. Waist circumference was

measured to the nearest 0.1 cm using a non-extensible tape. Measurement was made at the level of the umbilicus, with the subject in the erect position, breathing silently.

### Statistical analysis

Data was compiled in Microsoft Excel and analysed using MedCalc12.7.5 software. Receiver operating characteristic (ROC) analysis was used to compare the predictive validity, and to determine the optimal cut-off values of anthropometric indices. Area under the curve was also measured to determine the diagnostic power of the test, and to describe the probability that the anthropometric indices would correctly identify subjects with hypertension. Optimal cut-off values were measured by calculating the sensitivity and specificity of the anthropometric measurements at various cut-off points. Youden index was calculated to find out the associated criterion with maximum sensitivity and specificity for predicting hypertension.

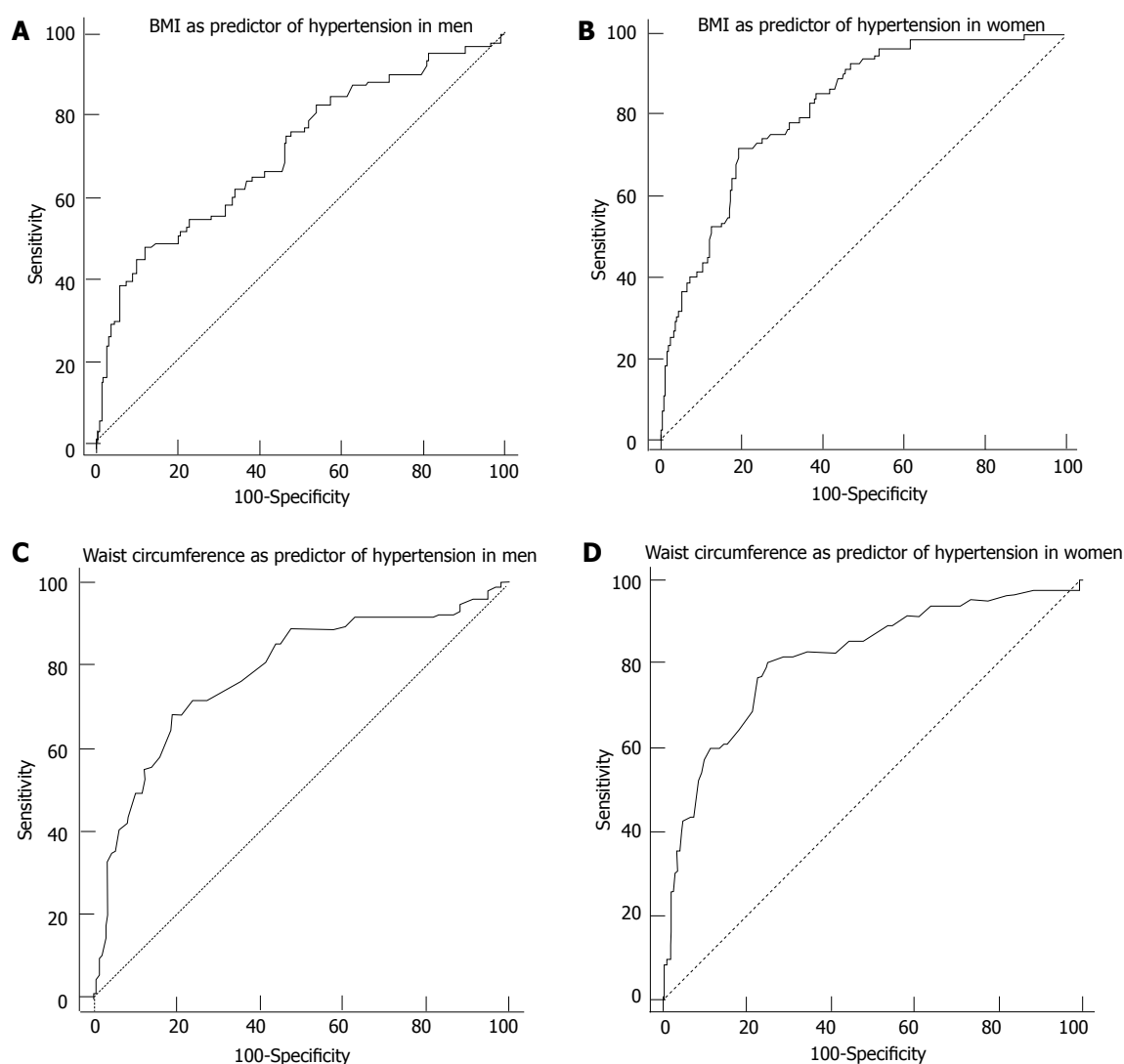
## RESULTS

In the present study, the mean age of the study subjects was 35.5 ± 12.6 years, while that of men and women respectively was 36.4 ± 13.8 years and 34.8 ± 11.6 years (Table 1). Average BMI of the study population was 21.9 ± 4.3 kg/m<sup>2</sup>. The mean waist circumference of men was 78.9 ± 11.0 cm and that of women was 74.4 ± 11.1 cm. Average systolic and diastolic blood pressure of the study population was 124 ± 17 mmHg and 80 ± 9 mmHg respectively. The mean systolic blood pressure among men was 127 ± 16 mmHg and that among women was 122 ± 18 mmHg. The mean diastolic blood pressure among men and women was 82 ± 9 mmHg and 78 ± 10 mmHg respectively.

The ROC analysis for BMI showed good discriminatory power for hypertension for both men and women. Area under the ROC curve was 0.714 for men and 0.821 for women respectively (Figure 1 A and B). The cut-off for BMI with better properties for screening of hypertension was identified as ≥ 24.5 kg/m<sup>2</sup> in men and ≥ 24.9 kg/m<sup>2</sup> in women (Table 2). The sensitivity and specificity of cut-off for BMI in men was 48.1% and 87.2% respectively, and that for women was 71.9% and 80.7% respectively.

Similarly, the ROC analysis for waist circumference revealed that it is a predictor of hypertension for both men and women. Area under the ROC curve was 0.784 for men and 0.815 for women respectively (Figure 1C and D). The cut-offs for waist circumference for screening of hypertension was estimated as ≥ 83 cm for men and ≥ 78 cm for women (Table 2). The sensitivity and specificity of cut-off of waist circumference in men was 67.9% and 80.4% respectively while that for women was 81.7% and 71.3% respectively. Adults with high BMI or high waist circumference had a higher prevalence of hypertension, respectively.

ROC analysis was also done after combining the pre-hypertensive and hypertensive subjects as non-normoten-



**Figure 1** Criterion values and coordinates of the receiver operating characteristic curve. A: Receiver operating characteristic (ROC) analysis for body mass index (BMI) as a predictor of hypertension among men revealed area under the curve = 0.714. The optimal cut-off for maximum sensitivity and specificity was 24.5; B: ROC analysis for BMI as a predictor of hypertension among women revealed area under the curve = 0.821. The optimal cut-off for maximum sensitivity and specificity was 24.9; C: ROC analysis for waist circumference as a predictor of hypertension among men revealed area under the curve = 0.784. The optimal cut-off for maximum sensitivity and specificity was 83; D: ROC analysis for waist circumference as a predictor of hypertension among women revealed area under the curve = 0.815. The optimal cut-off for maximum sensitivity and specificity was 78.

sive and the remaining normal subjects as normotensive. It was observed that BMI was not a good predictor of non-normotensive status both in men and women. Area under the curve was 0.452 for BMI among men and 0.540 among women respectively. Similarly it was found that waist circumference did have good discriminatory power for non-normotensive status both in men and women. Area under the curve was 0.429 among men and 0.552 among women respectively. These results were not statistically significant.

Therefore, BMI and waist circumference can be considered good predictors of hypertension but not of pre-hypertension.

## DISCUSSION

In the present study, cut-off for BMI for predicting hypertension was identified as  $\geq 24.5$  kg/m<sup>2</sup> in men and

$\geq 24.9$  kg/m<sup>2</sup> in women. In a study from Malaysia, the mean age of the study subjects was  $44 \pm 14$  years and the cut-off for BMI as predictor of hypertension was 25.5 kg/m<sup>2</sup> in men and 24.9 kg/m<sup>2</sup> in women, which was very similar to our study. Areas under the curves of BMI as a predictor of hypertension were 0.59 and 0.61 in men and women, respectively<sup>[16]</sup>. Area under the curves of 0.6-0.7 are considered to be poor while 0.7-0.8 are considered fair, as seen in our study. Increased CVD risks related to obesity at lower BMIs have been found in Asians<sup>[17,18]</sup>. In addition, Asians are also predisposed to visceral or abdominal obesity<sup>[19]</sup>. Therefore, WHO recently proposed lower BMI values to define overweight and obesity in people of the Asia-Pacific region<sup>[20]</sup>. According to the World Heart Federation, if a person's BMI is more than 30, he/she is obese and at serious risk of cardiovascular disease, whereas in our study, optimal cut-off for BMI for predicting hypertension was identified as  $\geq 24.5$  kg/m<sup>2</sup> in



**Table 2 Receiver operating characteristic analysis for body mass index and waist circumference as predictor of hypertension in men and women**

Indicators	BMI in men	BMI in women	WC in men	WC in women
Area under the ROC curve	0.714	0.821	0.784	0.815
Standard error	0.0312	0.0237	0.0286	0.0284
95% CI	0.664 to 0.760	0.783 to 0.856	0.737 to 0.826	0.776 to 0.850
z statistic	6.857	13.572	9.922	11.117
Significance level	< 0.0001	< 0.0001	< 0.0001	< 0.0001
P (Area = 0.5)				
Youden index J	0.3611	0.5294	0.4912	0.5542
Associated criterion	> 24.5	> 24.9	> 83	> 78

BMI: Body mass index; ROC: Receiver operating characteristic.

men and  $\geq 24.9$  kg/m<sup>2</sup> in women<sup>[21]</sup>.

However, some studies have also revealed that BMI follows a J-shaped curve to predict all case mortality. BMI is a strong predictor of overall mortality both above and below the apparent optimum of about 22.5-25 kg/m<sup>2</sup><sup>[22]</sup>. The progressive excess mortality above this range is mainly due to vascular diseases and is probably causal at large. At 30-35 kg/m<sup>2</sup>, median survival is reduced by 2-4 years; at 40-45 kg/m<sup>2</sup>, it is reduced by 8-10 years (which is comparable with the effects of smoking). The definite excess mortality below 22.5 kg/m<sup>2</sup> is mainly due to smoking-related diseases, and is not fully explained.

In the present study, the optimal cut-offs of waist circumference for screening of hypertension was estimated as  $\geq 83$  cm for men and  $\geq 78$  cm for women. The waist circumference cut-offs for risk of hypertension obtained in this study are comparable to those reported by Snehalatha *et al.*<sup>[23]</sup> for South Indians, which was reported as 85 cm for men and 80 cm for women wherein the mean age of the study population was  $40.4 \pm 14.2$  years. These were also similar to the cut-offs observed by Rao *et al.*<sup>[24]</sup> in Maharashtra as 86 cm in the male population averaging  $42.9 \pm 7.9$  years and 79 cm in the female population averaging  $42.2 \pm 7.8$  years<sup>[23,24]</sup>. The cut-offs in the present study were slightly lower for men when compared to those reported by Misra *et al.*<sup>[25]</sup> for North Indians (90 cm for men averaging  $40.5 \pm 14.7$  years) and slightly higher for women (80 cm for women having mean age of  $38.8 \pm 14.8$  years). In other Asian populations, cut-offs reported by Wildman *et al.*<sup>[26]</sup> for Chinese adults (86 cm for both sexes) and those observed by Lin *et al.*<sup>[27]</sup> for adults from Taiwan as 80.5 cm for men and 71.5 cm for women with mean age  $37.3 \pm 10.9$  years in men and  $37.0 \pm 11.1$  years in women, were on the lower side. Ethnicity plays an important role in determining the predictive power of waist circumference for hypertension. Also, nutrition habits vary among different populations which may be the reason for the difference in waist circumference cut-offs.

According to the World Heart Federation, if the waist circumference is more than 102 cm among men,

the person is at serious risk of CVDs, but for Asian men the cut-off has been set at 90 cm<sup>[21]</sup>. Similarly for women the high risk cut-off is 88 cm whereas in Asian women, it is 80 cm. In our study, the optimal cut-offs for waist circumference for predicting hypertension were  $\geq 83$  cm for men and  $\geq 78$  cm for women, which approximate the Asian cut-offs. In Asians, more than in the Western population, there is a strong association between blood pressure and stroke. It has been estimated that reduction of 3 mmHg in DBP would reduce the number of strokes in Asia by one third. Identification of indicators predicting risk of hypertension therefore has an important implication towards prevention of morbidity and mortality due to CVDs<sup>[28]</sup>.

A major limitation of the study was that the classification of hypertension was based on a single measurement of blood pressure. Secondly, the number of female study subjects was greater than males which might act as a source of bias in studying the difference in the cut-offs for predicting hypertension in men and women, respectively. Although this is not a meta-analysis, it is a useful study with practical application for the prevention and control of hypertension.

The present study reveals that BMI and waist circumference are simple tools in identifying hypertension. Although it is not easy to determine how low the cut-off should be, the findings in this study provide sufficient evidence that BMI and waist circumference can be used as a screening tool for hypertension. Since high blood pressure itself is the entry point to other non-communicable diseases, this emphasizes the need for further research to identify cut-offs of simple anthropometric measurements, which can be calculated by people themselves, for screening of hypertension. Given the risk of CVD associated with high blood pressure, hypertension screening and health education programs regarding weight reduction may be considered as a cost-effective public health approach in dealing with the morbidity attributed to CVDs. This study is only a prelude to the upcoming research in the field of non-communicable diseases especially in the Asian population which is more vulnerable to adverse effects of obesity.

## COMMENTS

### Background

Cardiovascular diseases (CVDs) are the most common cause of mortality in the world; around 30% of all global deaths in 2008 were attributed CVDs. High blood pressure is the entry point to CVDs and other non-communicable diseases. The magnitude of hypertension in adults aged 25 and over was around 40% in the world in 2008. A meta-analysis in 2013 estimated the prevalence of hypertension as 40.8% in the urban and 17.9% in the rural Indian population. Body mass index (BMI) and waist circumference are simple tools in predicting hypertension, which can be calculated by the people themselves. The findings in this study provide cut-off levels of BMI and waist circumference for screening of hypertension in the Indian population. Given the risk of CVDs associated with high blood pressure, hypertension screening and health education programs regarding weight reduction may be considered as a cost-effective public health approach in dealing with the morbidity attributed to CVDs. Therefore, a precise estimate of the cut-offs of BMI and waist circumference specific to the indigenous population of the country is required to assess the magnitude of

the problem that has to be addressed and to design programs and policies for prevention and control.

### Research frontiers

In India, very few studies are available on the cut-offs of BMI and waist circumference for predicting hypertension. Given the variation in anthropometry due to ethnic differences and discrepancies in the nutritional status of different populations, an estimate of the cut-offs for screening of hypertension in the Indian population is required which can help in the development of preventive strategies.

### Innovations and breakthroughs

BMI and waist circumference have good discriminatory power for predicting hypertension in the Indian population and this knowledge will help in shaping primordial and primary level preventive programs for the country.

### Applications

Very few studies on cut-off levels of BMI and waist circumference for screening of hypertension are available in India; therefore, the main application of this study is to provide cut-offs levels for our indigenous population to help develop a strategy for control and prevention of hypertension appropriate for the country.

### Terminology

The ROC curve is a fundamental tool for diagnostic test evaluation using a graphical plot. In a ROC curve the true positive rate (Sensitivity) is plotted as a function of the false positive rate (100-Specificity) for different cut-off points of a parameter. Each point on the ROC curve represents a sensitivity/specificity pair corresponding to a particular decision threshold. The ROC curve estimates and reports all of the combinations of sensitivity and specificity that a diagnostic test is able to provide. The area under the ROC curve (AUC) is a measure of how well a parameter can distinguish between two diagnostic groups (diseased/normal). Accuracy of a diagnostic test is measured by the area under the ROC curve. An area of 1 represents a perfect test; an area of 0.5 represents a worthless test. The associated criterion value corresponding with the Youden index J is the optimal criterion value when disease prevalence is 50% and equal weight is given to sensitivity and specificity.

### Peer review

The study titled "Optimal Cut-off values of BMI and waist circumference to predict hypertension in adults: A cross-sectional study in a north Indian population" has been well thought out. It may be an incremental contribution of the manuscript to the field. Design of the manuscript is also good. It is well-marked that this paper would have a few literature errors formally.

## REFERENCES

- 1 **World Health Organization.** Global Health Repository. Available from: URL: [http://www.who.int/gho/ncd/risk\\_factors/blood\\_pressure\\_prevalence\\_text/en/index.html](http://www.who.int/gho/ncd/risk_factors/blood_pressure_prevalence_text/en/index.html)
- 2 **World Health Report.** Reducing Risks, Promoting Healthy Life. 2002; Chapter 4; p-12. Available from: URL: [http://www.who.int/whr/2002/en/whr02\\_ch4.pdf](http://www.who.int/whr/2002/en/whr02_ch4.pdf).
- 3 **Midha T, Nath B, Kumari R, Rao YK, Pandey U.** Prevalence of hypertension in India: A meta-analysis. *World J Meta-Anal* 2013; **1**: 83-89 [DOI: 10.13105/wjma.v1.i2.83]
- 4 **World Development Report 2006.** Equity and Development. Washington D.C: A co-publication of the World Bank and Oxford University Press, 2006
- 5 **Rodgers A, Lawes C, MacMahon S.** Reducing the global burden of blood pressure-related cardiovascular disease. *J Hypertens Suppl* 2000; **18**: S3-S6 [PMID: 10939783]
- 6 **Miall WE.** Heredity and hypertension. *Practitioner* 1971; **207**: 20-27 [PMID: 5557040]
- 7 **Chobanian AV, Bakris GL, Black HR, Cushman WC, Green LA, Izzo JL, Jones DW, Materson BJ, Oparil S, Wright JT, Roccella EJ.** The Seventh Report of the Joint National Committee on Prevention, Detection, Evaluation, and Treatment of High Blood Pressure: the JNC 7 report. *JAMA* 2003; **289**: 2560-2572 [PMID: 12748199 DOI: 10.1001/jama.289.19.2560]
- 8 **Joshi SR, Saboo B, Vadivale M, Dani SI, Mithal A, Kaul U, Badgandi M, Iyengar SS, Viswanathan V, Sivakadaksham N, Chattopadhyaya PS, Biswas AD, Jindal S, Khan IA, Sethi BK, Rao VD, Dalal JJ.** Prevalence of diagnosed and undiagnosed diabetes and hypertension in India--results from the Screening India's Twin Epidemic (SITE) study. *Diabetes Technol Ther* 2012; **14**: 8-15 [PMID: 22050271 DOI: 10.1089/dia.2011.0243]
- 9 **McPherson K, Marsh T, Brown M.** Tackling obesities: future choices-modelling future trends in obesity and the impact on health: report for Foresight (Government Office for Science, 2007). Available from: URL: [http://www.gov.uk/government/uploads/system/uploads/attachment\\_data/file/287937/07-1184x-tackling-obesities-future-choices-report.pdf](http://www.gov.uk/government/uploads/system/uploads/attachment_data/file/287937/07-1184x-tackling-obesities-future-choices-report.pdf)(last accessed 3-7-14)
- 10 **Friedemann C, Heneghan C, Mahtani K, Thompson M, Perera R, Ward AM.** Cardiovascular disease risk in healthy children and its association with body mass index: systematic review and meta-analysis. *BMJ* 2012; **345**: e4759 [PMID: 23015032 DOI: 10.1136/bmj.e4759]
- 11 **Singh RB, Pella D, Mechirova V, Kartikey K, Demeester F, Tomar RS, Beegom R, Mehta AS, Gupta SB, De Amit K, Neki NS, Haque M, Nayse J, Singh S, Thakur AS, Rastogi SS, Singh K, Krishna A.** Prevalence of obesity, physical inactivity and undernutrition, a triple burden of diseases during transition in a developing economy. The Five City Study Group. *Acta Cardiol* 2007; **62**: 119-127 [PMID: 17536599 DOI: 10.2143/AC.62.2.2020231]
- 12 **Government of India.** Census of India 2001, Population Totals, Paper - 1; 2001. Available from: URL: <http://www.censusindia.gov.in/pca/SearchDetails.aspx?Id=163690> (last accessed 3-7-14)
- 13 **Ward-wise List of Slum/Nonslum Areas.** Nagar Nigam: Kanpur District, 2002: 3
- 14 **Blockwise List of Villages.** Kanpur District: Office of Chief Development Office, 2002: 10
- 15 **Chobanian AV, Bakris GL, Black HR, Cushman WC, Green LA, Izzo JL, Jones DW, Materson BJ, Oparil S, Wright JT, Roccella EJ.** Seventh report of the Joint National Committee on Prevention, Detection, Evaluation, and Treatment of High Blood Pressure. *Hypertension* 2003; **42**: 1206-1252 [PMID: 14656957 DOI: 10.1161/01.HYP.0000107251.49515.c2]
- 16 **Zaher ZM, Zambari R, Pheng CS, Muruga V, Ng B, Appannah G, Onn LT.** Optimal cut-off levels to define obesity: body mass index and waist circumference, and their relationship to cardiovascular disease, dyslipidaemia, hypertension and diabetes in Malaysia. *Asia Pac J Clin Nutr* 2009; **18**: 209-216 [PMID: 19713180]
- 17 **Deurenberg-Yap M, Yian TB, Kai CS, Deurenberg P, VAN Staveren WA.** Manifestation of cardiovascular risk factors at low levels of body mass index and waist-to-hip ratio in Singaporean Chinese. *Asia Pac J Clin Nutr* 1999; **8**: 177-183 [PMID: 24394159 DOI: 10.1046/j.1440-6047.1999.00091.x]
- 18 **Hsieh SD, Yoshinaga H, Muto T, Sakurai Y, Kosaka K.** Health risks among Japanese men with moderate body mass index. *Int J Obes Relat Metab Disord* 2000; **24**: 358-362 [PMID: 10757631 DOI: 10.1038/sj.ijo.0801157]
- 19 **Wang J, Russell-Aulet M, Mazariegos M, Burastero S, Thornton J, Lichtman S, Heymsfield SB, Pierson Jr NP.** Body fat by dual photon absorptiometry (DPA): comparisons with traditional methods in Asians, Blacks and Caucasians. *Am J Hum Biol* 1992; **4**: 501-510 [DOI: 10.1002/ajhb.1310040409]
- 20 **World Health Organization.** The Asia-Pacific perspective: redefining obesity and its treatment (WHO: Geneva, 2000). Available from: URL: [http://www.wpro.who.int/nutrition/documents/Redefining\\_obesity/en/](http://www.wpro.who.int/nutrition/documents/Redefining_obesity/en/) (last accessed 3-7-14)
- 21 **World heart federation.** Available from: URL: <http://www.world-heart-federation.org/cardiovascular-health/cardiovascular-disease-risk-factors/obesity/>
- 22 **Whitlock G, Lewington S, Sherliker P, Clarke R, Emberson J, Halsey J, Qizilbash N, Collins R, Peto R.** Body-mass index and cause-specific mortality in 900 000 adults: collaborative analyses of 57 prospective studies. *Lancet* 2009; **373**: 1083-1096 [PMID: 19299006 DOI: 10.1016/S0140-6736(09)60318-4]
- 23 **Snehalatha C, Viswanathan V, Ramachandran A.** Cutoff

- values for normal anthropometric variables in asian Indian adults. *Diabetes Care* 2003; **26**: 1380-1384 [PMID: 12716792 DOI: 10.2337/diacare.26.5.1380]
- 24 **Rao S**, Waingankar PP. Performance of waist circumference relative to BMI in predicting risk of obesity and hypertension among affluent Indian adults. *Health* 2013; **5**: 16-22 [DOI: 10.4236/health.2013.58A3003]
  - 25 **Misra A**, Vikram NK, Gupta R, Pandey RM, Wasir JS, Gupta VP. Waist circumference cutoff points and action levels for Asian Indians for identification of abdominal obesity. *Int J Obes (Lond)* 2006; **30**: 106-111 [PMID: 16189502 DOI: 10.1038/sj.ijo.0803111]
  - 26 **Wildman RP**, Gu D, Reynolds K, Duan X, He J. Appropriate body mass index and waist circumference cutoffs for categorization of overweight and central adiposity among Chinese adults. *Am J Clin Nutr* 2004; **80**: 1129-1136 [PMID: 15531658]
  - 27 **Lin WY**, Lee LT, Chen CY, Lo H, Hsia HH, Liu IL, Lin RS, Shau WY, Huang KC. Optimal cut-off values for obesity: using simple anthropometric indices to predict cardiovascular risk factors in Taiwan. *Int J Obes Relat Metab Disord* 2002; **26**: 1232-1238 [PMID: 12187401 DOI: 10.1038/sj.ijo.0802040]
  - 28 **Cheung YB**, Low L, Osmond C, Barker D, Karlberg J. Fetal growth and early postnatal growth are related to blood pressure in adults. *Hypertension* 2000; **36**: 795-800 [PMID: 11082145 DOI: 10.1161/01.HYP.36.5.795]

**P- Reviewers:** Puddu PE, Talas ZS, Undela K, Xu XH  
**S- Editor:** Wen LL **L- Editor:** A **E- Editor:** Wu HL



## Perirenal extra-adrenal myelolipoma

Ali Hajiran, Chad Morley, Robert Jansen, Stanley Kandzari, Patrick Bacaj, Stanley Zaslau, Jon Cardinal

Ali Hajiran, Chad Morley, Robert Jansen, Stanley Kandzari, Patrick Bacaj, Stanley Zaslau, Jon Cardinal, Division of Urology, West Virginia University, Morgantown, WV 26505, United States

Patrick Bacaj, Department of Pathology, West Virginia University, Morgantown, WV 26505, United States

Jon Cardinal, Division of Surgical Oncology, West Virginia University, Morgantown, WV 26505, United States

Author contributions: Hajiran A, Morley C, Jansen R and Kandzari S wrote the paper; Cardinal J participated in the presented surgical case; Bacaj P provided the histological diagnosis and commentary; Jansen R, Kandzari S, Zaslau S and Cardinal J edited the final paper and provided additional commentary.

Correspondence to: Stanley Zaslau, MD, MBA, FACS, Professor and Chief, Division of Urology, West Virginia University, PO Box 9238, Morgantown, WV 26506.

United States. szaslau@hsc.wvu.edu

Telephone: +1-304-2932706 Fax: +1-304-2932807  
Received: December 11, 2013 Revised: April 22, 2014

Accepted: May 28, 2014

Published online: July 16, 2014

**Core tip:** We report a case of a patient with an incidentally discovered perirenal mass that was initially concerning for a retroperitoneal liposarcoma. Following surgical resection and pathological analysis, the lesion was found to be an extra-adrenal myelolipoma. This case report and review of the literature demonstrates the importance of the proper work-up and management of perirenal lipoma variants while addressing the issues of tissue biopsy, surgical intervention, and pre- and post-operative surveillance.

Hajiran A, Morley C, Jansen R, Kandzari S, Bacaj P, Zaslau S, Cardinal J. Perirenal extra-adrenal myelolipoma. *World J Clin Cases* 2014; 2(7): 279-283 Available from: URL: <http://www.wjgnet.com/2307-8960/full/v2/i7/279.htm> DOI: <http://dx.doi.org/10.12998/wjcc.v2.i7.279>

### Abstract

Myelolipomas are rare tumors consisting of both adipose and hematopoietic tissue and are typically found within the adrenal gland. Extra-adrenal involvement is rare, especially those tumors involving the perirenal space and collecting system. We report a case of a patient with an incidentally discovered perirenal mass that was initially concerning for a retroperitoneal liposarcoma. Following surgical resection and pathological analysis, the lesion was found to be an extra-adrenal myelolipoma. This case report and review of the literature demonstrates the importance of the proper work-up and management of perirenal lipoma variants while addressing the issues of tissue biopsy, surgical intervention, and pre- and post-operative surveillance.

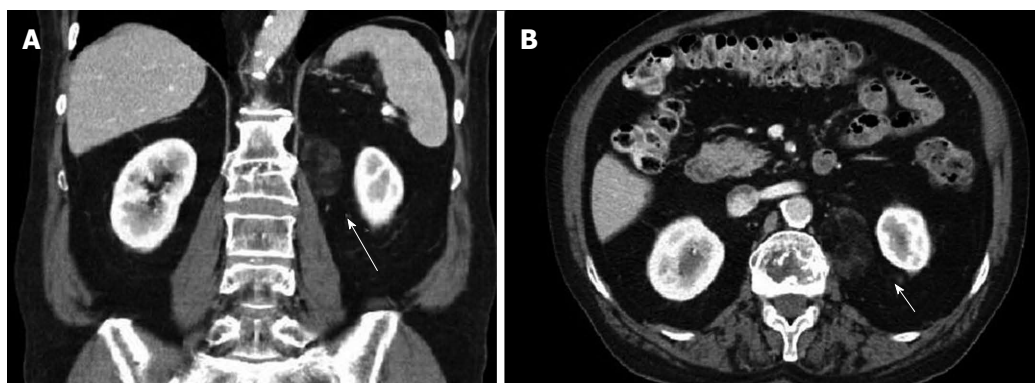
© 2014 Baishideng Publishing Group Inc. All rights reserved.

**Key words:** Myelolipoma; Lipoma; Perirenal mass; Nephrectomy; Oncology

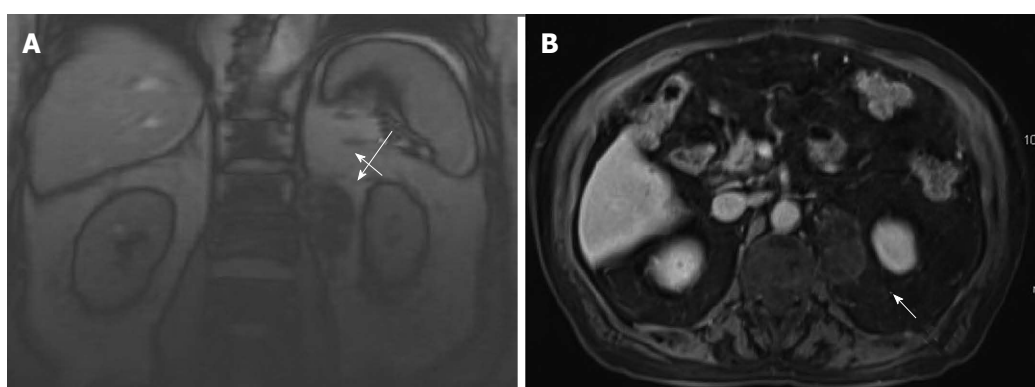
### INTRODUCTION

Myelolipomas are mesenchymal tumors which consist of a mixture of mature adipose tissue with hematopoietic cells. This intriguing tumor most commonly occurs within the adrenal gland; however, it has been occasionally found within the pelvis, thorax, retroperitoneal space, and various other sites throughout the body<sup>[1-7]</sup>. There have been less than 60 reported cases of extra-adrenal myelolipomas to this date, with the majority of the literature describing neoplasms found within the pre-sacral space<sup>[2,8-10]</sup>. Perirenal extra-adrenal myelolipomas are especially rare, with only 9 cases previously reported<sup>[11]</sup>. We present a case of a patient with an incidentally discovered perirenal mass which, after having shown interval growth on longitudinal surveillance imaging studies, was surgically resected along with a left nephrectomy for presumed retroperitoneal liposarcoma. On final pathological analysis the lesion was found to be an extra-adrenal myelolipoma.





**Figure 1 Initial computed tomography scan.** Shows incidentally found non-enhancing heterogeneous mass measuring approximately 3.8 cm × 2.3 cm in longitudinal (A) and anterior-posterior dimensions (B), just inferior to the left renal vein (long arrow) and medial to the left kidney (arrow).



**Figure 2 Surveillance magnetic resonance imaging.** Imaging obtained 17 mo after the initial diagnostic computed tomography scan shows that the mass, located just inferior to the left renal vein (long arrow) and medial to the left kidney (arrow), increased in size to 5.0 cm × 3.4 cm in longitudinal (A) and anterior-posterior dimensions (B).

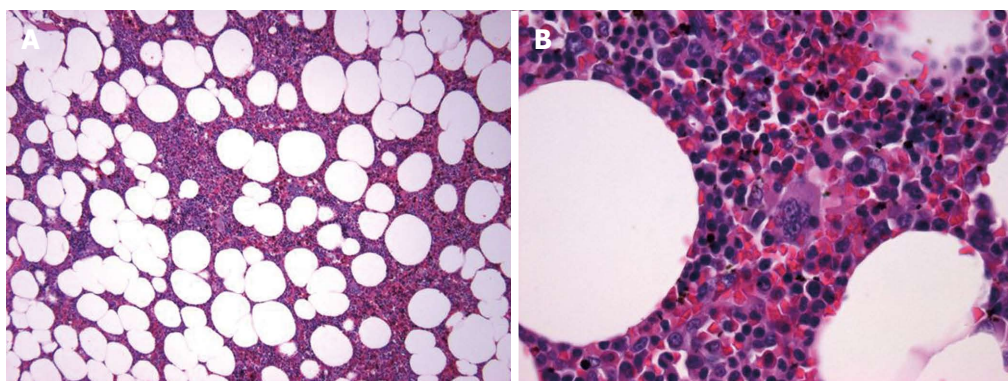
## CASE REPORT

A 78-year-old gentleman presented to the surgical oncology clinic to be evaluated for a left-sided retroperitoneal mass that was incidentally discovered on a computed tomography (CT) scan for a suspected case of acute pancreatitis. His prior medical history included hypertension, hyperlipidemia, acalculous cholecystitis, atrial fibrillation, and coronary artery disease. Initial radiographic findings revealed a non-enhancing heterogeneous mass measuring approximately 3.8 cm × 2.3 cm in longitudinal and anterior-posterior (AP) dimensions, just inferior to the left renal vein and medial to the left kidney (Figure 1). As the lesion appeared to contain mostly adipose with a small amount of soft tissue density, a well differentiated liposarcoma was suspected. The patient was initially offered surgical resection of the lesion, which he refused. Given the small size of the mass and patient's age and health status, the decision was made to closely monitor the lesion with routine cross-sectional surveillance imaging and regular follow-up at 4 to 6 mo.

Throughout the surveillance period, the patient did not complain of any new symptoms. Physical examination repeatedly revealed a soft, non-tender abdomen with no palpable masses or hernias. Repeat cross-sectional

imaging studies, however, did reveal a slowly enlarging left-sided heterogeneous perirenal mass. A magnetic resonance imaging (MRI) obtained 17 mo after initial diagnosis showed that the mass had increased in size to 5.0 cm × 3.4 cm (Figure 2). Four months prior the tumor had remained unchanged. The concern for a progressing malignant lesion prompted the decision to proceed with surgical intervention. Due to its proximity to the renal vessels, as well as the fact that the preoperative diagnosis was liposarcoma, the mass was excised en bloc with the left kidney in an attempt to gain wide surgical margins. The patient tolerated the procedure well and his post-operative course was uneventful. He was discharged home in stable condition on the ninth day following the procedure.

Gross pathology revealed an encapsulated, well-defined, focally hemorrhagic mass measuring 7.2 cm × 4.1 cm × 3.3 cm in size. The tumor did not extend into the renal capsule or adrenal gland. Histology revealed that the mass was composed of mostly mature adipocytes mixed with islands of hematopoietic cells. Trilineage hematopoiesis was present, including nucleated red blood cells and megakaryocytes (Figure 3). Tumor resection margins were free. The above mentioned morphological features were consistent with the diagnosis of “perirenal (extra-



**Figure 3** Hematoxylin and eosin stain at 10 × (A) and 60 × (B) magnification. Shows mature adipose cells with hematopoietic cells including erythroid precursors, granulocytic precursors, and megakaryocytes.

adrenal) myelolipoma”.

## DISCUSSION

Myelolipoma is a unique mesenchymal tumor that is composed of a mixture of adipose and hematopoietic cells. The first case of an adrenal lesion containing both fat and myeloid elements was described by Gierke<sup>[12]</sup> in 1905. The reported incidence of myelolipoma on autopsy ranges from 0.08% to 0.4%<sup>[13]</sup>. This type of tumor is most commonly localized to the adrenal gland; however, there are rare but well-documented cases of extra-adrenal involvement<sup>[1]</sup>. To our knowledge, less than 60 cases of extra-adrenal myelolipomas have been reported<sup>[2,8-10]</sup>, most of them involving the pre-sacral space. Tumors involving the mediastinum, lung, spleen, mandible, and nasal cavity have also been described<sup>[2-7]</sup>. Perirenal extra-adrenal myelolipomas are especially rare, with only 9 cases described so far<sup>[11]</sup>.

A review of the literature shows that extra-adrenal myelolipomas exhibit a slight female predominance and are typically discovered between the ages of 50 to 70 years old<sup>[4,7,11]</sup>. Most tumors are unilateral and have been found to range from 2 to 26 cm in size at the time of diagnosis<sup>[14,15]</sup>. The etiology of extra-adrenal myelolipomas is still to be established. Several theories exist regarding their embryologic origin and pathogenesis. Amin *et al*<sup>[16]</sup> suggest that there may be a relationship between the reactivation of primitive peritoneal foci of extramedullary hematopoiesis under pathological stresses (*i.e.*, severe anemia, sepsis, myeloproliferative disease) and the origin and progression of extra-adrenal myelolipomas. Another theory postulates that myelolipomas originate from metaplasia of previously uncommitted adrenal cortical mesenchymal cells or hematopoietic stem cells that normally migrate to the adrenal gland during intrauterine development<sup>[16]</sup>.

The widespread application of modern imaging techniques has led to a dramatic increase in the detection of extra-adrenal myelolipomas. The majority of patients are asymptomatic at the time of diagnosis, and lesions are discovered incidentally on imaging for alternative medical problems. Typically, physical examination and routine

blood tests fail to yield any conclusive diagnostic findings. Depending on the size and location of the lesion, some patients may present with vague flank or abdominal pain due to hemorrhage, mechanical compression, or tumor infarction<sup>[17]</sup>. CT and MRI have been used to diagnose extra-adrenal myelolipomas. When a myelolipoma is contained within the adrenal gland, the diagnosis is straightforward because it is the only known entity composed of adipose tissue occurring in this location<sup>[18]</sup>. A fatty mass within the retroperitoneal space represents a diagnostic challenge because the differential diagnosis includes an angiomyolipoma, a retroperitoneal teratoma, or a well-differentiated liposarcoma. A study that reviewed the MRI results of 126 consecutively imaged grossly fatty masses found that the sensitivity of MRI in diagnosing well-differentiated liposarcomas is 100%; however, its specificity is merely 83% due to the inability to differentiate between liposarcomas and other lipoma variants<sup>[19]</sup>.

Fine needle biopsy under ultrasound or CT guidance may be useful for the diagnosis of extra-adrenal myelolipoma. Well-differentiated liposarcoma differs from myelolipoma in that the former contains atypical stromal cells, variable-sized adipocytes, some of them with nuclear atypia, and lipoblast which, however, are not diagnostic, being absent in some cases. By contrast, extra-adrenal myelolipomas are composed of mature adipocytes with scattered hematopoietic cells, including megakaryocytes<sup>[20]</sup>. Although these histological differences between the two tumors, in many cases the final diagnosis is difficult, if not impossible, based on tissue biopsy<sup>[11]</sup>. Furthermore, the risks of hemorrhage, rupture, or infection that are associated with biopsy must factor into a clinician's decision to proceed with this invasive diagnostic procedure<sup>[11]</sup>. In our patient, tissue biopsy was deferred due to the patient's preference to forego the procedure.

There is currently no standard treatment for patients with this disease. Daneshmand *et al*<sup>[21]</sup> suggest that small asymptomatic tumors (< 4 cm) should be monitored with routine cross-sectional surveillance imaging, while large symptomatic tumors (> 7 cm) should be surgically removed. Extra-adrenal myelolipomas have been removed using a thoracoabdominal incision, but recently a laparoscopic approach has proven to be just as effective<sup>[10]</sup>.

**Table 1** Review of reported cases of perirenal extra-adrenal myelolipomas

Age at time of diagnosis (yr)	Sex	Presentation	Diagnostic imaging	Biopsy	Gross pathology	Treatment	Ref.
45	Male	Asymptomatic	CT (5 cm × 5 cm)	No	6.0 cm × 3.5 cm × 2.5 cm	Partial nephrectomy	Wagner <i>et al</i> <sup>[23]</sup> , 1997
45	Female	Flank pain Dysuria Frequency Urgency	CT (10 cm × 7 cm)	Yes	9.0 cm × 6.4 cm × 5.5 cm	Laparoscopic mass resection	Beiko <i>et al</i> <sup>[10]</sup> , 2010
60	Male	Abdominal pain	CT (4.2 cm × 3.7 cm)	No	Not reported	Radical nephrectomy	Pascual García <i>et al</i> <sup>[24]</sup> , 2007
63	Male	Asymptomatic	CT (6.5 cm × 5.5 cm)	No	Not reported	Open mass resection	Dan <i>et al</i> <sup>[15]</sup> , 2012
65	Male	Flank pain, Weight loss Hematuria	CT (5.5 cm × 4.5 cm)	No	7.0 cm × 5.0 cm × 1.5 cm	Radical nephrectomy	Talwalkar <i>et al</i> <sup>[9]</sup> , 2006
66	Female	Abdominal distention	CT (20 cm × 20 cm)	No	20 cm × 15 cm × 15 cm	Open mass resection	Brietta <i>et al</i> <sup>[25]</sup> , 1994
67	Male	Asymptomatic	CT (7 cm × 5 cm)	No	Not reported	Radical nephrectomy	Sneiders <i>et al</i> <sup>[26]</sup> , 1993
70	Male	Flank pain Fever	Ultrasound (12 cm × 8.5 cm)	No	17.0 cm × 10.0 cm × 5.0 cm	Open mass resection	Kilinc <sup>[27]</sup> , 2007
77	Male	Abdominal distension Hypertension	CT (Bilateral fat-containing masses)	Yes	Not reported	Follow-up CT 3 mo showed no change	Temizoz <i>et al</i> <sup>[20]</sup> , 2010

CT: Computed tomography.

Early detection and proper management of myelolipomas is important due to the potential for tumor growth and hemorrhage. A study of 86 myelolipomas found that hemorrhage is more common in larger lesions with a diameter measuring greater than 10 cm<sup>[22]</sup>.

A review of 9 reported cases perirenal extra-adrenal myelolipomas, shows that the average age at diagnosis is 62 years of age (Table 1). Perirenal lesions exhibited a male-to-female ratio of 7:2. At the time of diagnosis, patients were either asymptomatic or complained of various symptoms including flank pain, dysuria, frequency, urgency, weight loss, hematuria, or abdominal distention. CT and ultrasound were the imaging modalities used to characterize the masses. Biopsy was used in only 2 of the 9 cases prior to surgical intervention. The average size on imaging is 8.7 cm × 7.4 cm, while the size of the resected masses on gross pathological evaluation is 11.8 cm × 8.0 cm × 5.9 cm. Treatment included open and laparoscopic mass excision with or without nephrectomy or partial nephrectomy depending on concern for adequate surgical margins. Upon reviewing the literature, we felt it was reasonable to monitor the lesion with routine surveillance imaging until the tumor increased in size and to perform a mass resection with a nephrectomy to ensure adequate surgical margins.

Since an extra-adrenal myelolipoma is such a rare entity, a retroperitoneal mass that has imaging characteristics of a well-differentiated liposarcoma should ultimately end up being approached and treated as such. However, this report demonstrates that extra-adrenal myelolipoma should be considered as part of the list of differential diagnoses. In cases in which surgical extirpation of an extra-adrenal myelolipoma is performed, there are no clear

recommendations for post-operative surveillance. Our review did not reveal a case of local recurrence of a retroperitoneal myelolipoma, however, routine radiographic surveillance would certainly be helpful to detect potential locally recurrent disease.

In summary, perirenal extra-adrenal myelolipoma is extremely rare. This neoplasm is typically discovered incidentally on cross-sectional imaging and commonly thought to be a liposarcoma. It can be managed conservatively or surgically depending on the patient's symptoms or level of concern for a malignant lesion. Early detection and proper management of myelolipomas are important due to the potential for tumor growth and hemorrhage.

## COMMENTS

### Case characteristics

This case features a left-sided retroperitoneal mass that was incidentally discovered on a computed tomography (CT) scan for a suspected case of acute pancreatitis.

### Clinical diagnosis

Imaging revealed a non-enhancing heterogeneous mass measuring approximately 3.8 cm × 2.3 cm in longitudinal and anterior-posterior dimensions, just inferior to the left renal vein and medial to the left kidney, and histological evaluation revealed that the mass was composed of mostly mature adipocytes mixed with islands of hematopoietic cells.

### Differential diagnosis

Differential diagnosis was most concerning for liposarcoma, lipoma, malignant fibrous histiocytoma, or a fibrosarcoma.

### Laboratory diagnosis

Laboratory findings were non-contributory to arriving at the final diagnosis.

### Imaging diagnosis

CT and MRI were used to initially detect and follow the progression of the mass.

### Pathological diagnosis

Hematoxylin and eosin (H and E) stain at 10 x and 60 x magnification revealed



mature adipose cells with hematopoietic cells including erythroid precursors, granulocytic precursors, and megakaryocytes.

### Treatment

The mass was excised en bloc with the left kidney in an attempt to gain wide surgical margins.

### Related reports

The list of references to this article contains several related reports to aid readers to further understand this topic.

### Term explanation

*Myelolipoma* is a unique mesenchymal tumor that is composed of a mixture of adipose and hematopoietic cells.

### Experiences and lessons

Perirenal extra-adrenal myelolipomas are neoplasms that are typically discovered incidentally on cross-sectional imaging, they can be managed conservatively or surgically depending on the patient's symptoms or level of concern for a malignant lesion, and early detection and proper management of myelolipomas are critical due to the potential for tumor growth and hemorrhage.

### Peer review

This study describes a lesion which is not a unique phenomenon. Nevertheless, it is well written with a good review of the literature.

## REFERENCES

- 1 Meaglia JP, Schmidt JD. Natural history of an adrenal myelolipoma. *J Urol* 1992; **147**: 1089-1090 [PMID: 1552592]
- 2 Baker KS, Lee D, Huang M, Gould ES. Presacral myelolipoma: a case report and review of imaging findings. *J Radiol Case Rep* 2012; **6**: 1-9 [PMID: 23378876]
- 3 Geng C, Liu N, Yang G, Qi M, Chen W. Primary mediastinal myelolipoma: A case report and review of the literature. *Oncol Lett* 2013; **5**: 862-864 [PMID: 23426140]
- 4 Huang WT, Zhao SJ, Lin DM. Pulmonary-bronchus myelolipoma and review on extra-adrenal myelolipomas in Chinese literature. *Chin Med J (Engl)* 2012; **125**: 3188-3190 [PMID: 22932206]
- 5 Cina SJ, Gordon BM, Curry NS. Ectopic adrenal myelolipoma presenting as a splenic mass. *Arch Pathol Lab Med* 1995; **119**: 561-563 [PMID: 7605177]
- 6 Chiarini L, Bertoldi C, Criscuolo M, Ferronato G. [Myelolipomatosis. A report of a case located in the mandible]. *Minerva Stomatol* 1992; **41**: 165-172 [PMID: 1461236]
- 7 George SA, Manipadam MT, Thomas R. Primary myelolipoma presenting as a nasal cavity polyp: a case report and review of the literature. *J Med Case Rep* 2012; **6**: 127 [PMID: 22584001 DOI: 10.1186/1752-1947-6-127]
- 8 Bandurski R, Zareba K, Kędra B. Rare case of multifocal (adrenal and extra - adrenal ) myelolipoma. *Pol Przegl Chir* 2013; **85**: 348-350 [PMID: 23828417]
- 9 Talwalkar SS, Shaheen SP. Extra-adrenal myelolipoma in the renal hilum: a case report and review of the literature. *Arch Pathol Lab Med* 2006; **130**: 1049-1052 [PMID: 16831034]
- 10 Beiko D, Roldan H, Sengupta SK, George RL. Laparoscopic excision of a large extra-adrenal perirenal myelolipoma. *Can Urol Assoc J* 2010; **4**: E39-E41 [PMID: 20368880]
- 11 Ghaouti M, Znati K, Jahid A, Zouaia F, Bernoussi Z, Mahassini N. Renal myelolipoma: a rare extra-adrenal tumor in a rare site: a case report and review of the literature. *J Med Case Rep* 2013; **7**: 92 [PMID: 23556993]
- 12 Gierke E. Unusual myeloid tissue in the adrenal gland. *Beitr Pathol Anat* 1905; **3**: 11-25
- 13 Doddi S, Singhal T, Leake T, Sinha P. Management of an incidentally found large adrenal myelolipoma: a case report. *Cases J* 2009; **2**: 8414 [PMID: 19918428 DOI: 10.4076/1757-1626-2-8414]
- 14 Kammen BF, Elder DE, Fraker DL, Siegelman ES. Extraadrenal myelolipoma: MR imaging findings. *AJR Am J Roentgenol* 1998; **171**: 721-723 [PMID: 9725304 DOI: 10.2214/ajr.171.3.9725304]
- 15 Dan D, Bahadursingh S, Hariharan S, Ramjit C, Naraynsingh V, Maharaj R. Extra-adrenal perirenal myelolipoma. A case report and review of literature. *G Chir* 2012; **33**: 62-65 [PMID: 22525547]
- 16 Amin MB, Tickoo SK, Schultz D. Myelolipoma of the renal sinus. An unusual site for a rare extra- adrenal lesion. *Arch Pathol Lab Med* 1999; **123**: 631-634 [PMID: 10388922]
- 17 Olobatuyi FA, MacLennan GT. Myelolipoma. *J Urol* 2006; **176**: 1188 [PMID: 16890722 DOI: 10.1016/j.juro.2006.06.095]
- 18 Butori N, Guy F, Collin F, Benet C, Causeret S, Isambert N. Retroperitoneal extra-adrenal myelolipoma: appearance in CT and MRI. *Diagn Interv Imaging* 2012; **93**: e204-e207 [PMID: 22421286]
- 19 Gaskin CM, Helms CA. Lipomas, lipoma variants, and well-differentiated liposarcomas (atypical lipomas): results of MRI evaluations of 126 consecutive fatty masses. *AJR Am J Roentgenol* 2004; **182**: 733-739 [PMID: 14975977 DOI: 10.2214/ajr.182.3.1820733]
- 20 Temizoz O, Gencellac H, Demir MK, Unlu E, Ozdemir H. Bilateral extra-adrenal perirenal myelolipomas: CT features. *Br J Radiol* 2010; **83**: e198-e199 [PMID: 20846975 DOI: 10.1259/bjr/28801968]
- 21 Daneshmand S, Quek ML. Adrenal myelolipoma: diagnosis and management. *Urol J* 2006; **3**: 71-74 [PMID: 17590837]
- 22 Kenney PJ, Wagner BJ, Rao P, Heffess CS. Myelolipoma: CT and pathologic features. *Radiology* 1998; **208**: 87-95 [PMID: 9646797]
- 23 Wagner JR, Kleiner DE, Walther MM, Linehan WM. Perirenal myelolipoma. *Urology* 1997; **49**: 128-130 [PMID: 9000202 DOI: 10.1016/S0090-4295(97)00368-3]
- 24 Pascual García X, Bujons Tur A, Rodríguez Faba O, Gómez Ruiz JJ, Palou Redorta J, Villavicencio Mavrich H. Extraadrenal perirenal myelolipoma: report of a case and review of the literature. *Actas Urol Esp* 2007; **31**: 932-934 [PMID: 18020221 DOI: 10.1016/S0210-4806(07)73751-8]
- 25 Brietta LK, Watkins D. Giant extra-adrenal myelolipoma. *Arch Pathol Lab Med* 1994; **118**: 188-190 [PMID: 8311663]
- 26 Sneiders A, Zhang G, Gordon BE. Extra-adrenal perirenal myelolipoma. *J Urol* 1993; **150**: 1496-1497 [PMID: 8411435]
- 27 Kilinc N. Extra-adrenal myelolipoma: A case report and review of the literature. *Pak J Med Sci* 2007; **23**: 779-781

P- Reviewers: Fernandez-Pello S, Magro G, Tsamis D  
S- Editor: Ma YJ L- Editor: A E- Editor: Wu HL





## Verrucous carcinoma of the esophagus: A case report and literature review

Chintan Ramani, Neil Shah, Ramasamy Swami Nathan

Chintan Ramani, Neil Shah, Ramasamy Swami Nathan, Department of internal medicine, Hackensack UMC mountainside, Montclair, NJ 07042, United States

Author contributions: Nathan RS performed the endoscopy and diagnosed the case; Ramani C with Shah N and Nathan RS did the literature search and Ramani C wrote a report.

Correspondence to: Ramasamy Swami Nathan, MD, Academic Chief Gastroenterology, Department of internal medicine, Hackensack UMC mountainside, 1 Bay Ave, Montclair, NJ 07042, United States. [chintan.ramani@mountainsidehosp.com](mailto:chintan.ramani@mountainsidehosp.com)

Telephone: +1-973-2398372 Fax: +1-973-2398403

Received: October 28, 2013 Revised: March 23, 2014

Accepted: May 19, 2014

Published online: July 16, 2014

### Abstract

Verrucous carcinoma of the esophagus is a variant of a squamous cell cancer. Our case is a 78-year-old male patient comes in with the dysphagia and weight loss, and on endoscopy (EGD) he is found to have an irregular intraluminal mass at the distal esophagus. With the deep EGD assisted biopsy, diagnosis of the verrucous carcinoma is made. Due to multiple co morbidities and possible infiltration to the pericardium, patient is taken for the esophageal stent placement and is being referred for the chemo-radiation treatment. The diagnosis can be very difficult to make with the superficial biopsies due to very non specific histological changes and requires very high clinical suspicion and deep mucosal biopsies are required for accurate diagnosis of the tumor. Chronic and local disease process is the main risk factor for the development of the verrucous carcinoma of the esophagus. Surgery is the treatment of the choice for the early stage tumor and advanced cases are treated with the palliation and possibly chemo-radiation. The prognosis is usually guarded and needs long term follow up.

**Key words:** Verrucous carcinoma; Hyperkeratosis; Esophageal stent placement; Esophageal carcinoma; Endoscopic Ultrasound

**Core tip:** A verrucous carcinoma is a slow growing, well differentiated, rare form of squamous carcinoma variant. It is associated with chronic, local disease process and it invades locally. On endoscopy (EGD), it appears as an exophytic irregular warty projecting mass, and it is very difficult to diagnose by superficial biopsy due to non specific superficial histological findings. So it requires high index of suspicion and deep biopsy with EGD or endoscopic ultrasonography (EUS). It projects as hypoechoic mucosal thickening on EUS. Early stages of cancers are treated surgically. Advanced cases can be referred for esophageal stent placement for palliation and chemo radiation. It has high morbidity and mortality and requires long term follow up for accurate numbers regarding to the treatment and the follow up.

Ramani C, Shah N, Nathan RS. Verrucous carcinoma of the esophagus: A case report and literature review. *World J Clin Cases* 2014; 2(7): 284-288 Available from: URL: <http://www.wjgnet.com/2307-8960/full/v2/i7/284.htm> DOI: <http://dx.doi.org/10.12998/wjcc.v2.i7.284>

### INTRODUCTION

Verrucous carcinoma of the esophagus is a rare form of carcinoma of squamous cell origin<sup>[1-9]</sup>. Majority of the cases are associated with the smoking, reflux esophagitis, alcohol use, human papilloma virus (HPV), achalasia and few other chronic inflammatory conditions<sup>[1-9]</sup>. An incidence rate of such cancer has been shown to be higher in males than females with a ratio of 2:1 and seen in the group from 35 to 80 years<sup>[1-3,6]</sup>. Superficial biopsies of the lesion often show merely chronic inflammation with no

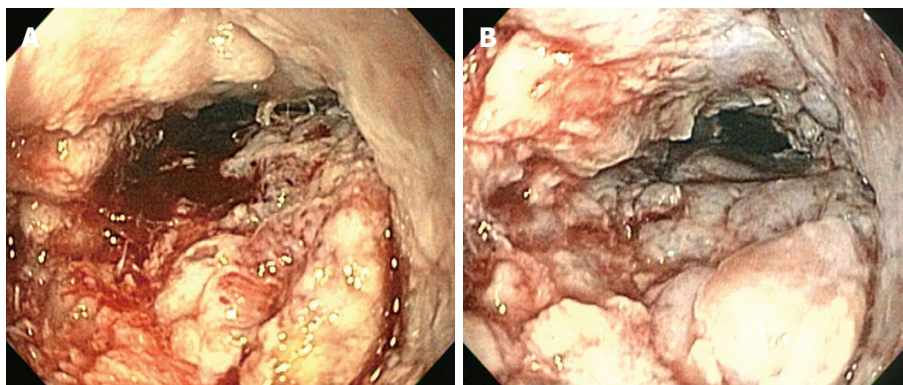


Figure 1 Upper endoscopy showing an irregular velvety appearing intraluminal mass in the esophagus (A and B).

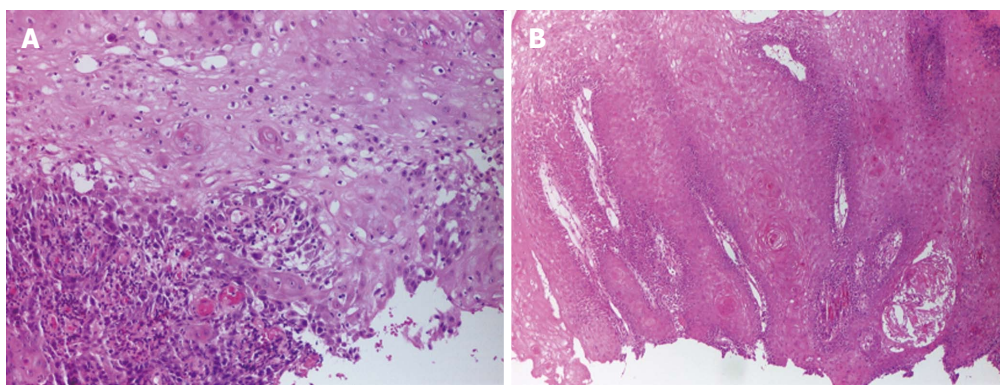


Figure 2 Superficial biopsy of the lesion showing Mild cytological atypia and chronic inflammation and reactive appearing basal layer of sq cell epithelium (A); deep biopsy of the lesion with a jumbo forceps showing Florid proliferation of sq epithelium with verrucous pattern (B).

high grade dysplasia, which makes it difficult to diagnose.

So far, less than 30 cases of such carcinomas are reported in the English literature. We are presenting a case of the verrucous carcinoma of the esophagus with no documented risk factors associated with the carcinoma and a diagnosis is made by deep biopsies of the lesions.

## CASE REPORT

We have recently seen a 78-year-old African American man, presenting with dysphagia, weight loss of 15 Lbs over 4-5 wk and right lower quadrant dull, and non radiating abdominal pain. His past medical history included coronary artery disease status post angioplasty with stent placement, hypertension, dyslipidemia, and diabetes mellitus with complications including diabetic retinopathy and nephropathy. He was non-smoker and non-drinker and denied any history of GERD. And symptoms were gradual in onset over last couple of months. His physical exam showed no abnormality. On lab evaluation, His BUN and serum creatinine were 42 and 2.4 respectively, normal liver function tests; Hemoglobin was 12.4 g/dL with MCV 84.4 fl. All other labs were within normal limits. ultrasonography of the abdomen and computed tomography (CT) scan of the abdomen and pelvis were unremarkable for any hepatobiliary, pancreatic or intestinal pathology. He underwent barium esophagogram, and was

found to have a long, irregular stricture involving the mid and distal esophagus with an apparent intraluminal mass at its proximal end. The endoscopic examination showed a luminal warty appearing mass occupying distal 8 cm of the esophagus (Figure 1). Endoscopic ultrasonography (EUS) examination was performed which showed solid tumor measuring approx 5 cm in greatest dimension, possibly infiltrating into the pericardium (Figure 2). It also showed hypoechoic concentric wall thickening that appeared to be either an inflammatory process or lymphoma.

Initial biopsies were remarkable for squamous epithelial cells with parakeratosis and marked acute and chronic inflammation, ulceration and focal squamous cell with atypia. The repeat endoscopic examination and extensive biopsies with jumbo forceps revealed the diagnosis of verrucous carcinoma of the esophagus. In situ hybridization for both high and low risk HPV was negative.

A CT scan of the chest showed some mediastinal lymph nodes. Bone scan showed no any bone metastasis. In view of the dysphagia, patient underwent endoscopy (EGD) and placement of an esophageal Wallflex stent (Boston scientific partially covered 23 mm wide and 125 mm long).

Due to extensive medical history and fairly advanced stage, surgery was contraindicated and the patient was referred for chemotherapy and radiation.

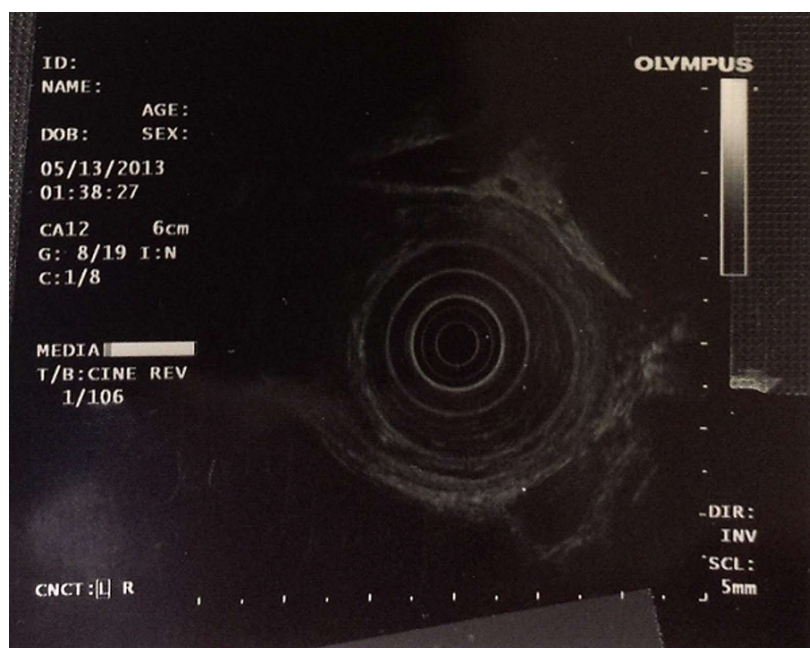


Figure 3 Tumor infiltrating pericardium.

## DISCUSSION

Verrucous carcinomas are a variant of squamous carcinoma. They are slow growing and seen in the oropharynx, larynx, glans penis, scrotum, vulva, vagina, cervix, endometrium, urinary bladder, anorectal region and the sole of the feet<sup>[2-4]</sup>. The Verrucous carcinomas are believed to be associated with the chronic mucosal irritation or inflammation or a long-term disease process<sup>[2,4]</sup>.

Amongst all different sites for verrucous carcinoma, it is rarely seen in the esophagus<sup>[1-9]</sup>. First ever case of such cancer in esophagus was reported by Minelly in 1967<sup>[2,3,4,7]</sup> and thereafter so far less than 30 cases are reported in the English literature<sup>[8]</sup>.

The etiological factors are not clearly delineated in the literature but it seems to be associated with the chronic inflammatory conditions or long term local disease process<sup>[1-9]</sup>. Risk factors may include smoking; alcohol abuse; hiatal hernia; achalasia; esophagitis; caustic injury from lye, battery or kerosene ingestion; esophageal diverticulum or nutcracker esophagus. In the recent years, few reported cases have shown the association with the HPV virus, although the clear association is very unclear<sup>[5,6,8,9]</sup>. Our case was not clearly associated with the any of these documented risk factors. Devlin *et al*<sup>[3]</sup> mentions that the acid inhibition decreases the tumor length and also changes the appearance from polypoid to sessile and warty. This hypothesizes that the long term acid damage could be a contributory for the development of the verrucous carcinoma.

The incidence rate is higher in male as compared to female with a ratio of approx 2:1<sup>[1-3]</sup>. An age distribution of this type of carcinoma ranges from 36 to 79 with a mean age of 61<sup>[1-3]</sup>. Most common presenting

sign and symptoms in the verrucous carcinoma of the esophagus are dysphagia and weight loss, seen in our case as well<sup>[1-3,5,6]</sup>. Other symptoms would be hematemesis, coughing and odynophagia<sup>[2,6]</sup>. Endoscopic appearance of such lesions includes, shaggy, white, exophytic, wart-like, velvety, papillary, spiked, cauliflower like mass<sup>[1-3,7-9]</sup>. The tumor is located mostly in the lower esophagus (70%) with no clear reason but it can involve the upper (23%) or the mid part of the esophagus (7%) as well<sup>[2-9]</sup>.

A diagnosis is usually made by either endoscopy guided deep mucosal biopsy or EUS guided tunnel biopsy or post surgery specimen evaluation. Verrucous carcinoma of the esophagus usually evolves in the sequential fashion from acanthosis, hyperkeratosis, parakeratosis, leukoplakia, verrucous lesions, and papillary hyperplasia to verrucous carcinoma<sup>[2]</sup>. Superficial biopsies of such lesions show only non specific acanthosis, parakeratosis, or hyperkeratosis, with associated acute or chronic inflammation<sup>[2,3,6,8]</sup>, which makes these types of carcinomas are difficult to diagnose and requires high index of suspicion and repeat endoscopic deep biopsies as in our case (Figure 3). Endoscopic biopsies have revealed 46% cases of the verrucous carcinoma, remaining of them have been diagnosed either after surgery or with the use of EUS<sup>[2-9]</sup>. EUS is highly accurate imaging modalities for the diagnosis and staging as well as follow up of esophageal tumors. It also estimates the depth of invasion as well as any lymphadenopathy which is helpful in staging. EUS guided tunnel biopsy of such lesions can be useful as seen in few case reports<sup>[2-4,8]</sup>. A Verrucous carcinoma of the esophagus commonly projects as a diffuse hypoechoic mucosal thickening with varying degree of depth with varying degree of lymphadenopathy in EUS exam<sup>[2-4,7,8]</sup>. It invades as a column of neoplastic



cells in a pushing manner instead of invasion in discrete cells<sup>[3]</sup>, with the 80% invades through and beyond superficial epithelium, 8% limited to the superficial epithelium only and 12% unclear<sup>[2-9]</sup>. More than 50% cases are found have inflammatory infiltrates surrounding the tumor<sup>[3,6]</sup>, and the lymphnode biopsy mostly shows hyperplastic nodes secondary to local inflammation which can prove that the chronic inflammation predisposes to the verrucous carcinoma of the esophagus<sup>[2,7]</sup>. Overall, histologically, it is similar to benign squamous papilloma and the tumor infiltration beyond the superficial mucosa fairly differentiates it from the benign squamous cell papilloma<sup>[2]</sup>.

Despite of its slow growth and high degree of differentiation, it has very poor prognosis. As per literature, there is a delay between the onset of the symptoms and the diagnosis. And at the time of the diagnosis, majority of the cases are locally advanced<sup>[1-9]</sup>. Morbidity and mortality associated with such tumors are mainly due to local invasion or due to surgical complications. There is no any reported case of distant metastasis in the literature. It can spread locally to the lungs, bronchi, pleura and can form fistulas<sup>[1,2,8]</sup>. Our case is the first reported instance of pericardial invasion confirmed with EUS study. With regards to therapy, early stages of the cancer can be treated surgically with esophageal resection or polypectomy/mucosal resection<sup>[1-9]</sup>. More advanced cases, or non surgical candidates can be treated with esophageal stent placement, as done in our case. Due to rarity of such tumors, no clear data are available for any effective chemo- radiation therapy. However, most recent post operative follow up case series have shown better prognosis with cancer free survival ranges from 9 mo to 3 years<sup>[2,3]</sup>. We need a long term follow up with such patients and that can improve the outcome.

A verrucous carcinoma is a slow growing, well differentiated, rare form of squamous carcinoma variant. It is associated with chronic, local disease process and it invades locally. On EGD, it appears as an exophytic irregular warty projecting mass, and it is very difficult to diagnose by superficial biopsy due to non specific superficial histological findings. So it requires high index of suspicion and deep biopsy with EGD or EUS. It projects as hypoechoic mucosal thickening on EUS. Early stages of cancers are treated surgically. Advanced cases can be referred for esophageal stent placement for palliation and chemo radiation. It has high morbidity and mortality and requires long term follow up for accurate numbers regarding to the treatment and the follow up.

## COMMENTS

### Case characteristics

A 78-year-old African American man presented with dysphagia, weight loss of 15 Lbs over 4-5 wk and right lower quadrant dull, and non radiating abdominal pain.

### Clinical Diagnosis

Physical examination was unremarkable.

### Differential diagnosis

Benign squamous papilloma, adenocarcinoma of the esophagus

### Laboratory diagnosis

BUN and serum creatinine were 42 and 2.4 respectively, normal liver function tests; Hemoglobin was 12.4 with MCV 84.4.

### Imaging diagnosis

A barium esophagogram showed a long, irregular stricture involving the mid and distal esophagus with an apparent intraluminal mass at its proximal end. A computed tomography scan of the chest showed some mediastinal lymph nodes. Bone scan showed no any bone metastasis.

### Pathological diagnosis

The endoscopic examination and extensive biopsies with jumbo forceps revealed the diagnosis of verrucous carcinoma of the esophagus. In situ hybridization for both high and low risk HPV was negative.

### Treatment

Due to extensive medical history and fairly advanced stage, surgery was contraindicated and the patient Patient underwent EGD and placement of an esophageal Wallflex stent and was referred to chemotherapy and radiation.

### Related reports

The etiological factors are not clearly delineated in the literature. It has high morbidity and mortality and requires long term follow up for accurate numbers regarding to the treatment and the follow up.

### Experiences and lessons

This report presents a case of rare variant of squamous cell cancer of esophagus, and difficulties associated with the diagnosis and treatment. It is very beneficial for the patients, if it is diagnosed in the early stages. But nonspecific superficial biopsies make it difficult to diagnose and it requires high index of suspicion even without any associated risk factors.

### Peer review

It is indeed a rare form of squamous cell carcinoma. Due to the same reasons, there are not enough studies available in terms of management that can be applied to general population.

## REFERENCES

- 1 **Malik AB**, Bidani JA, Rich HG, McCully KS. Long-term survival in a patient with verrucous carcinoma of the esophagus. *Am J Gastroenterol* 1996; **91**: 1031-1033 [PMID: 8633546]
- 2 **Osborn NK**, Keate RF, Trastek VF, Nguyen CC. Verrucous carcinoma of the esophagus: clinicopathologic features and treatment of a rare entity. *Dig Dis Sci* 2003; **48**: 465-474 [PMID: 12757157]
- 3 **Devlin S**, Falck V, Urbanski SJ, Mitchell P, Romagnuolo J. Verrucous carcinoma of the esophagus eluding multiple sets of endoscopic biopsies and endoscopic ultrasound: a case report and review of the literature. *Can J Gastroenterol* 2004; **18**: 459-462 [PMID: 15229749]
- 4 **Na S**, Choi KD, Yoo C, Chang Y, Song HJ, Lee GH, Jung HY, Cho KJ, Kim JH. Verrucous carcinoma of the esophagus. *Gastrointest Endosc* 2009; **70**: 803-806 [PMID: 19555942 DOI: 10.1016/j.gie.2009.01.048]
- 5 **Tonna J**, Palefsky JM, Rabban J, Campos GM, Theodore P, Ladabaum U. Esophageal verrucous carcinoma arising from hyperkeratotic plaques associated with human papilloma virus type 51. *Dis Esophagus* 2010; **23**: E17-E20 [PMID: 20626449]
- 6 **Macias-Garcia F**, Martinez-Lesquereux L, Fernandez B, Parada P, Larino-Noia J, Sobrino-Faya M, Iglesias-Canle J, Iglesias-Garcia J, Forteza J, Dominguez-Munoz JE. Verrucous carcinoma of the esophagus: a complex diagnosis. *Endoscopy* 2010; **42** Suppl 2: E137-E138 [PMID: 20405383 DOI: 10.1055/s-0029-1244051]
- 7 **Chu Q**, Jaganmohan S, Kelly B, Holey J. Verrucous carcinoma of the esophagus: a rare variant of squamous cell carcinoma for which a preoperative diagnosis can be a difficult one to make. *J La State Med Soc* 2011; **163**: 251-253 [PMID: 22272545]
- 8 **Feinstein AR**. The unit fragility index: an additional ap-



praisal of "statistical significance" for a contrast of two proportions. *J Clin Epidemiol* 1990; **43**: 201-209 [PMID: 2303850 DOI: 10.4321/S1130-01082012000800013]

- 9 **Liberale G**, De Simone P, Snoeck R, Féron P, Gelin M, El Nakadi I. Verrucous carcinoma of the esophagus. A case report. *Minerva Chir* 2005; **60**: 61-65 [PMID: 15902055]

**P- Reviewers:** Eslick GD, Gimeno-Garcia AZ, Natsugoe S  
**S- Editor:** Qi Y **L- Editor:** A **E- Editor:** Wu HL



## 360° fusion for realignment of high grade cervical kyphosis by one step surgery: Case report

Alessandro Landi, Nicola Marotta, Cristina Mancarella, Demo Eugenio Dugoni, Roberto Tarantino, Roberto Delfini

Alessandro Landi, Nicola Marotta, Cristina Mancarella, Demo Eugenio Dugoni, Roberto Tarantino, Roberto Delfini, Department of Neurology and Psychiatry, Division of Neurosurgery, University of Rome, Sapienza, 00100 Rome, Italy  
Author contributions: All authors contributed to this work.

Correspondence to: Alessandro Landi, MD, PhD, Department of Neurology and Psychiatry, Division of Neurosurgery, University of Rome, Sapienza, Viale del Policlinico 155, 00100 Rome, Italy. [dott.alessandro.landi@gmail.com](mailto:dott.alessandro.landi@gmail.com)

Telephone: +39-06-49979105 Fax: +39-06-49979113

Received: November 26, 2013 Revised: April 17, 2014

Accepted: May 16, 2014

Published online: July 16, 2014

Delfini R. 360° fusion for realignment of high grade cervical kyphosis by one step surgery: Case report. *World J Clin Cases* 2014; 2(7): 289-292 Available from: URL: <http://www.wjgnet.com/2307-8960/full/v2/i7/289.htm> DOI: <http://dx.doi.org/10.12998/wjcc.v2.i7.289>

### INTRODUCTION

The treatment option for correcting a cervical kyphotic deformity is currently controversial. Lots of studies examined the one-stage combined anterior-posterior treatment, although the rate of fusion and the long term follow up controls are rarely mentioned in the literature<sup>[1-7]</sup>. We present the case of a 67-year-old woman affected by a severe cervical kyphosis. We performed a one-step combined anterior/posterior approach to correct the deformity, getting a good reduction of kyphosis and good stability in a long term follow up. We enclosed that the evidence of motility by dynamic X-rays permits a good anterior decompression and reduction only by discectomy, fusion and plating, without need of multiple corpectomy. Treatment must be completed with posterior fixation and fusion. These strategies could be performed in one step, and shows a good reduction and optimal stability in a long term follow-up. Immobilizing with hard collar and neurophysiological monitoring remains fundamental for the safe and efficacy of this treatment.

### CASE REPORT

A 67-year-old woman affected by a severe cervical kyphotic deformity, came to our attention complaining 4 months of bilateral cervicobrachialgia. She didn't have any significant medical diseases; she denied to have ever suffered of ankylosing spondylitis, osteogenesis imperfecta, rheumatoid arthritis or Larsen syndrome.

Neurological examination showed moderate upper limbs weakness, confirmed by signs of radicular suffering

### Abstract

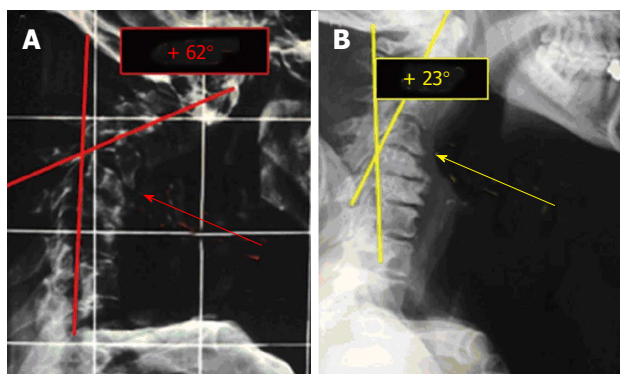
Surgical treatment for cervical kyphotic deformity is still controversial. Circumferential approach has been well described in the literature but long terms outcomes are not well reported. Important to decide the correct treatment option is the preoperative radiological exams to value the type of deformity (flexible or fixed). We report the case of a 67-year-old woman affected by a severe cervical kyphotic deformity who underwent combined anterior/posterior surgical approach, getting a good reduction of the deformity and an optimal stability in a long term follow up.

© 2014 Baishideng Publishing Group Inc. All rights reserved.

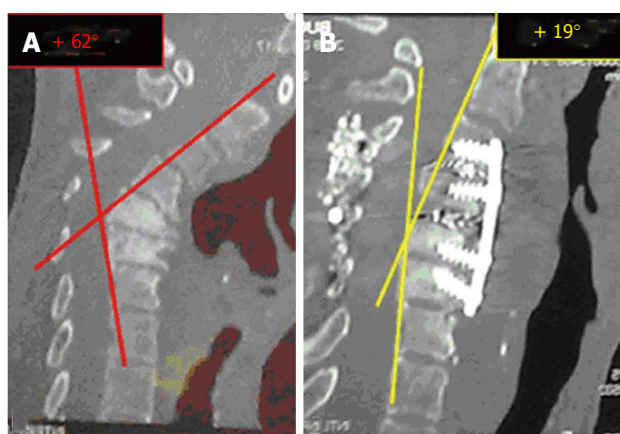
**Key words:** Cervical deformity; High grade kyphosis; Circumferential fusion; Surgical technique; Degenerative cervical spine

**Core tip:** The choice of the treatment for cervical kyphotic deformity takes into account preoperative radiological exams which allow the classification of the deformity in flexible or fixed.

Landi A, Marotta N, Mancarella C, Dugoni DE, Tarantino R,



**Figure 1 X-ray pictures.** A: Standard X-ray demonstrating a severe cervical kyphosis (preop. Angle of Jackson + 62°); B: A cervical spine X-ray on the bed with a pillow under the shoulders showing a good reduction of kyphosis (+ 23° according to Jackson) due to the motor unit C4-C5 mobility.

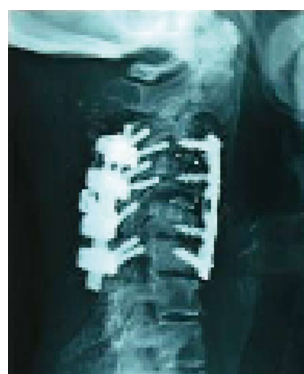

**Figure 2 The preoperative computed tomography.** A: Scan control (preop. Angle of Jackson + 62°); B: Showing a good reduction of kyphosis (postop angle of Jackson + 19°).

on the ElectroMioGraphy (EMG). The patient performed standard and flexion/extension cervical spine X-ray demonstrating a severe cervical kyphosis [preop. Ishihara index 64.18% and (8) preop. Angle of Jackson +62°] apparently fixed on the dynamic X-ray. Performed, then, cervical spine computed tomography (CT) and Magnetic Resonance Imaging showing important myeloradicular compression at C5-C6 and C4-C5.

The immediate preoperative exam that the patient had to perform was a cervical spine X-ray on the bed with a pillow under the shoulders in prevision to apply a traction system. This exam showed a good reduction of kyphosis (+23° according to Jackson) due to the motor unit C4-C5 mobility (Figure 1). It was therefore decided not to apply traction and to proceed with combined anterior/posterior surgical approach using neurophysiological monitoring SomatoSensory evoked potentials (SSEP), EMG and motor evoked potentials (MEP).

The first surgical step was the anterior approach, with hyperextension of the neck of the patient. The reduction status of the kyphosis was assessed under fluoroscopic visualization; patient underwent left anterior presternocleidomastoid-precavotid approach, anterior



**Figure 3 A postoperative X-ray control after 6 mo showing a good anterior and posterolateral arthrodesis.**

decompression through microdiscectomy C3-C4 and C4-C5, followed by interbody fusion using a carbon fiber cage in lordosis and anterior plate fixed on C3-C4-C5-C6. The second step was represented by the posterior approach, so the patient was placed in prone position. A C3/C6 posterior stabilization according to magerl was performed followed by posterolateral fusion at all levels. At the end of the procedure a Philadelphia brace was applied. The postoperative CT and X-ray control (Figure 2) and after 3 and 6 mo showed a good reduction of kyphosis (postop. Ishihara index 32.38 % and postop angle of Jackson + 19° with reduction of kyphosis of 31.8% according to Ishihara and 43° according to Jackson), and a good anterior and posterolateral arthrodesis (Figure 3). The patient presented a complete regression of the upper limbs deficit and of the cervicobrachialgia. Six months later the patient is symptoms free.

## DISCUSSION

Cervical kyphosis can be classified into two different groups: type 1 (flexible cervical kyphosis) and type 2 (fixed cervical kyphosis). The treatment for flexible cervical kyphosis (type 1) posturally reducible is usually a posterior stabilization with fusion to guarantee the stability of the cervical spine<sup>[6,7]</sup>. Alternatively, some authors have reported the use of anterior only surgery for flexible cervical kyphosis as discectomy and corpectomy. This approach is useful for anterior column load sharing however it is not required for deformity correction. Fixed cervical kyphosis characterized by postural rigidity needs circumferential approach<sup>[8-10]</sup>. The circumferential approach for the correction of cervical kyphotic deformity is well described in the literature although the long term controls are not always diriment on the real fusion of the correction<sup>[11,12]</sup>. The debate is not whether or not to perform circumferential correction, but if it is more useful to perform a multiple anterior discectomy or multiple corpectomy. In the literature it is described as the execution of multiple discectomies has a greater potential for correction of kyphosis in relation to: (1) a greater kyphosis correction due to the possibility of including more lordotic cages at multiple levels, so to restore a greater

degree of lordosis; and (2) a greater possibility of fusion because of a larger cage-bone interface compared with the use of a Harms mesh or an expansion cage.

In cases of multilevel cervical stenosis, the choice of surgical technique (discectomy *vs* corpectomy) mainly depends on the location of the stenosis. In the case of a kyphotic deformity however, the choice depends on the mobility or less of the bodies involved in the deformity<sup>[10-16]</sup>. It is also important to note that such deformities occur slowly over the time and are frequently the product of a degenerative process that affects the patient for many years: this include a wrong postural attitude that causes a compensatory hypertrophy of the supporting muscles of the neck, which may hide a metameric mobility of kyphosis. In our case, in fact, the dynamic exam in the upright position showed that the kyphosis appeared fixed and cannot be reduced<sup>[10]</sup>.

The X-ray performed in the bed with a pillow under the shoulder, allowed us to appreciate how such kyphosis was actually not fixed on two vertebrae. This made us choose a multiple discectomy and not corpectomy with consequent greater angular correction of kyphosis. Another important aspect in the evaluation of the motor unit motility is the reactive ankylosis of the articular processes. In the severe kyphosis the fusion occurs both at the level of the disc and of the articular masses, thus preventing a good correction of kyphosis after performing the anterior approach. When the articular masses are ankylosed it is necessary a 3-step surgery. The first step is represented by a posterior approach to release the ankylosed articular masses in order to allow the reduction of kyphosis. The second step is the anterior approach with discectomy, and the third step is represented by the posterior approach again to fix and to make arthrodesis<sup>[17-20]</sup>.

To this end, it is crucial to recognize accurately the real motility of the vertebral body, and to do that it is important to perform a dynamic exam without load, to eliminate the reactive contracture of the muscles supporting the neck. Useful for this purpose is to perform radiographic examinations in supine position with supports placed at the base of the neck which put the cervical spine in hyperextension eliminating the analgesic muscle contracture. Another aspect to highlight is the use of intraoperative neurophysiological monitoring, in particular SEPP and MEP; these allow a direct observation of the function of the spinal cord during the entire procedure. The neurophysiological monitoring is important especially during the correction of the spinal deformities because, as these constituted and organized by time, may have led to spinal cord adaptations that may break with the correction maneuvers, resulting in severe neurological deficits. Their use avoid for such eventuality.

In a conclusion, we enclosed that the evidence of motility by dynamic X-rays permits a good anterior decompression and reduction only by discectomy, fusion and plating, without need of multiple corpectomy. Treatment have to be completed with posterior fixation and fusion. These strategies could be performed in one step,

and shows a good reduction and optimal stability in a long term follow-up. Immobilizing with hard collar and neurophysiological monitoring remains fundamental for the safe and efficacy of these treatment.

## COMMENTS

### Case characteristics

The patient complained a 4-mo history of bilateral cervicobrachialgia.

### Clinical diagnosis

At the neurological examination the patient presented moderate upper limb weakness and severe cervical kyphotic deformity.

### Differential diagnosis

Through radiological exams we put cervical kyphotic deformity due to degenerative process in differential diagnosis with neoplastic and infective pathologies.

### Imaging diagnosis

The patient underwent computed tomography scan, magnetic resonance imaging and dynamic X-ray. The most important preoperative exam was X-ray performed in supine position with a pillow under the shoulder.

### Pathological diagnosis

The patient suffered severe cervical kyphotic deformity.

### Treatment

The authors performed combined anterior/posterior surgical approach using neurophysiological monitoring SomatoSensory Evoked Potentials, ElectroMioGrapy and Motor Evoked Potentials.

### Related reports

The choice of surgical treatment depends on the mobility or less of the bodies involved in the deformity.

### Term explanation

Cervical kyphosis is a progressive deformity; circumferential approach means one step combined anterior/posterior approach.

### Experiences and lessons

It is important to recognize the real motility of the vertebral body, and to do that it is necessary to perform a dynamic exam without load, to eliminate the reactive contracture of the muscles supporting the neck.

### Peer review

The author introduces an efficient surgical treatment for severe cervical spine deformity, and to improve the quality of life.

## REFERENCES

- 1 **Abumi K**, Shono Y, Taneichi H, Ito M, Kaneda K. Correction of cervical kyphosis using pedicle screw fixation systems. *Spine* (Phila Pa 1976) 1999; **24**: 2389-2396 [PMID: 10586466]
- 2 **Kanter AS**, Wang MY, Mummaneni PV. A treatment algorithm for the management of cervical spine fractures and deformity in patients with ankylosing spondylitis. *Neurosurg Focus* 2008; **24**: E11 [PMID: 18290737]
- 3 **Ferch RD**, Shad A, Cadoux-Hudson TA, Teddy PJ. Anterior correction of cervical kyphotic deformity: effects on myelopathy, neck pain, and sagittal alignment. *J Neurosurg* 2004; **100**: 13-19 [PMID: 14748568]
- 4 **Zdeblick TA**, Bohlman HH. Cervical kyphosis and myelopathy. Treatment by anterior corpectomy and strut-grafting. *J Bone Joint Surg Am* 1989; **71**: 170-182 [PMID: 2645290]
- 5 **Lin D**, Zhai W, Lian K, Kang L, Ding Z. Anterior versus posterior approach for four-level cervical spondylotic myelopathy. *Orthopedics* 2013; **36**: e1431-e1436 [PMID: 24200449]
- 6 **Spivak J**, Giordano CP. Cervical kyphosis. In: Bridwell KH, DeWald RL, eds. *The Textbook of Spinal Surgery*. 2nd ed. Philadelphia: Lippincott-Raven, 1997: 1027-1038
- 7 **Ganju A**, Ondra SL, Shaffrey CI. Cervical kyphosis. *Tech Orthop* 2003; **17**: 345-354 [DOI: 10.1097/00013611-200209000-00010]
- 8 **Herman JM**, Sonntag VK. Cervical corpectomy and plate fixation for postlaminectomy kyphosis. *J Neurosurg* 1994; **80**: 963-970 [PMID: 8189276]



- 9 Steinmetz MP, Kager CD, Benzel EC. Ventral correction of postsurgical cervical kyphosis. *J Neurosurg (Spine 2)* 2002; **97**: 1-7
- 10 Batzdorf U, Batzdorff A. Analysis of cervical spine curvature in patients with cervical spondylosis. *Neurosurgery* 1988; **22**: 827-836 [PMID: 3380271]
- 11 McAfee PC, Bohlman HH, Ducker TB, Zeidman SM, Goldstein JA. One-stage anterior cervical decompression and posterior stabilization. A study of one hundred patients with a minimum of two years of follow-up. *J Bone Joint Surg Am* 1995; **77**: 1791-1800 [PMID: 8550645]
- 12 Mummaneni PV, Dhall SS, Rodts GE, Haid RW. Circumferential fusion for cervical kyphotic deformity. *J Neurosurg Spine* 2008; **9**: 515-521 [PMID: 19035741]
- 13 Takeshita K, Murakami M, Kobayashi A, Nakamura C. Relationship between cervical curvature index (Ishihara) and cervical spine angle (C2--7). *J Orthop Sci* 2001; **6**: 223-226 [PMID: 11484114]
- 14 Chang SW, Kakarla UK, Maughan PH, DeSanto J, Fox D, Theodore N, Dickman CA, Papadopoulos S, Sonntag VK. Four-level anterior cervical discectomy and fusion with plate fixation: radiographic and clinical results. *Neurosurgery* 2010; **66**: 639-646; discussion 646-647 [PMID: 20305488]
- 15 Chibbaro S, Benvenuti L, Carnesecchi S, Marsella M, Pulerà F, Serino D, Gagliardi R. Anterior cervical corpectomy for cervical spondylotic myelopathy: experience and surgical results in a series of 70 consecutive patients. *J Clin Neurosci* 2006; **13**: 233-238 [PMID: 16503487]
- 16 Hussain M, Nassr A, Natarajan RN, An HS, Andersson GB. Corpectomy versus discectomy for the treatment of multilevel cervical spine pathology: a finite element model analysis. *Spine J* 2012; **12**: 401-408 [PMID: 22572585]
- 17 Kawakami M, Tamaki T, Iwasaki H, Yoshida M, Ando M, Yamada H. A comparative study of surgical approaches for cervical compressive myelopathy. *Clin Orthop Relat Res* 2000; **(381)**: 129-136 [PMID: 11127649]
- 18 Konya D, Ozgen S, Gercek A, Pamir MN. Outcomes for combined anterior and posterior surgical approaches for patients with multilevel cervical spondylotic myelopathy. *J Clin Neurosci* 2009; **16**: 404-409 [PMID: 19153044]
- 19 Lin Q, Zhou X, Wang X, Cao P, Tsai N, Yuan W. A comparison of anterior cervical discectomy and corpectomy in patients with multilevel cervical spondylotic myelopathy. *Eur Spine J* 2012; **21**: 474-481 [PMID: 21826497]
- 20 Jiang SD, Jiang LS, Dai LY. Anterior cervical discectomy and fusion versus anterior cervical corpectomy and fusion for multilevel cervical spondylosis: a systematic review. *Arch Orthop Trauma Surg* 2012; **132**: 155-161 [PMID: 21968573]

P- Reviewers: Tong C, Zhan RY S- Editor: Wen LL  
L- Editor: A E- Editor: Wu HL



## Focal epithelial hyperplasia in a human immuno-deficiency virus patient treated with laser surgery

Alexandros Galanakis, Gaspare Palaia, Gianluca Tenore, Alessandro Del Vecchio, Umberto Romeo

Alexandros Galanakis, Gaspare Palaia, Gianluca Tenore, Alessandro Del Vecchio, Umberto Romeo, Department of Oral and Maxillofacial Science, Sapienza University of Rome, 00161 Rome, Italy

Author contributions: Galanakis A, Tenore G, Del Vecchio A and Romeo U were the attending doctors for the patients; Palaia G and Romeo U designed the report; Galanakis A and Romeo U performed the surgeries; Palaia G organized the report; and Galanakis A wrote the paper.

Correspondence to: Alexandros Galanakis, DDS, PhD, Department of Oral and Maxillofacial Sciences, Sapienza University of Rome, Via Caserta 6, 00161 Rome, Italy. [agalanakis@hotmail.it](mailto:agalanakis@hotmail.it)

Telephone: +39-320-0713294 Fax: +39-064-9976630

Received: December 24, 2013 Revised: April 21, 2014

Accepted: May 15, 2014

Published online: July 16, 2014

virus positive and was a smoker with numerous, asymptomatic oral papules clinically and histologically corresponding to FEH. The labial and buccal mucosa were especially affected by lesions. Surgical treatment was performed using a 532-nm potassium titanyl phosphate laser (SmartLite, Deka, Florence, Italy) in continuous mode with a 300  $\mu$ m fiber and power of 1.4 W (power density 1980.22 W/cm<sup>2</sup>). After anesthesia without vasoconstrictors, the lesions were tractioned with sutures or an Allis clamp and then completely excised. The lesions were preserved in 10% formalin for histological examination, which confirmed the clinical diagnosis of FEH. In this case, the laser allowed excellent control of bleeding, without postoperative sutures, and optimal wound healing.

© 2014 Baishideng Publishing Group Inc. All rights reserved.

**Key words:** Lasers; Focal epithelial hyperplasia; Mouth; Human immunodeficiency virus; Oral pathology

### Abstract

Focal epithelial hyperplasia (FEH), or Heck's disease, is a rare disease of the oral mucosa; it is mostly found in children or young adults who are immunosuppressed and who live in regions with low socioeconomic status. It is characterized by asymptomatic papules on the oral mucosa, gingiva, tongue, and lips. Healing can be spontaneous, and treatment is indicated if there are aesthetic or functional complications. Human papillomavirus, especially genotypes 13 and 32, has been associated with FEH and is detected in the majority of lesions. Histopathologically, FEH is characterized by parakeratosis, epithelial hyperplasia, focal acanthosis, and fusion and horizontal outgrowth of epithelial ridges. A 37-year-old male patient was referred to the Department of Oral and Maxillofacial Sciences at the Sapienza University of Rome, complaining of numerous exophytic lesions in his mouth. He stated that the lesions were not painful but he had experienced occasional bleeding after incidental masticatory trauma. He had received no previous treatment for the oral lesions. His medical history revealed that he was human immuno-deficiency

**Core tip:** Focal epithelial hyperplasia (FEH), or Heck's disease, is a rare disease of the oral mucosa, characterized by asymptomatic papules in the oral cavity. Human papillomaviruses have been associated with FEH and have been detected in the majority of lesions. Histopathologically, FEH is characterized by parakeratosis, epithelial hyperplasia, and acanthosis. Here, the case of a 37-year-old male patient, human immuno-deficiency virus-positive, smoker, with numerous asymptomatic oral papules clinically and histologically corresponding to FEH is described. Surgical treatment was performed using a 532-nm potassium-titanyl-phosphate laser. In this case, the laser allowed excellent control of bleeding without postoperative sutures and optimal wound healing.

Galanakis A, Palaia G, Tenore G, Del Vecchio A, Romeo U. Focal epithelial hyperplasia in a human immuno-deficiency virus patient treated with laser surgery. *World J Clin Cases*

## INTRODUCTION

Focal epithelial hyperplasia (FEH), or Heck's disease, is an uncommon, benign disease of the oral mucosa; it is mostly found in children and young adults. It has also been described in some Native American communities in North and South America, as well as in Eskimos of Greenland<sup>[1,2]</sup>. FEH is characterized by numerous nodules or papules, usually painless, with sizes that vary from 1 mm to 1 cm, that are mainly found on the lips, buccal mucosa, tongue and palate<sup>[3]</sup>. Human papilloma-virus (HPV) has been detected in the lesions with both electron microscopy and DNA testing<sup>[4,5]</sup>. The most frequently involved viruses are HPV 13 and HPV 32<sup>[5]</sup>. The case of a young HIV-positive adult affected by FEH is reported below.

## CASE REPORT

An African male patient, 37-year-old, was referred to the Department of Oral and Maxillofacial Sciences at the Sapienza University of Rome, complaining about numerous exophytic lesions in his mouth. He stated that the lesions were not painful but that he had experienced occasional bleeding after incidental masticatory trauma. He had not received previous treatment for the oral lesions. His medical history revealed that he was human immunodeficiency virus (HIV)-positive. The diagnosis of HIV was made 2 years previously. He was, at the time of the visit, in treatment with lopinavir and ritonavir (Kaletra, Abbott Italy, Campoverde di Aprilia, Italy), emtricitabine and tenofovir (Truvada, Gilead, Foster City, CA, United States), and in prophylaxis with sulfamethoxazole and trimetoprim (Bactrim, Roche, Milan, Italy). He also smoked 10 cigarettes per day, but he did not make use of alcoholic drinks.

According to the classification of the Centers for Disease Control, he was classified as stage A3.

Extraoral examination did not reveal any signs of other diseases. Intraoral examination showed the presence of 17 sessile, soft, normochromic lesions in the oral cavity. The lesions were localized on the lower lip and the buccal mucosa, on both sides (Figure 1). After the examination, a diagnostic hypothesis of FEH was assumed. Excisional biopsy was performed on one of the lesions to confirm the diagnostic hypothesis. The biopsy was performed using a potassium-titanyl-phosphate (KTP) laser with a wavelength of 532 nm (SmartLite, Deka, Florence, Italy) in continuous mode with a 300  $\mu$ m fiber, power 1.4 W (power density 1980.22 W/cm<sup>2</sup>). After anesthesia without vasoconstrictors (Mepivacaina Pierrel 30 mg/mL, Pierrel, Milan, Italy) the lesions were tractioned with sutures or an Allis clamp and then completely excised (Figure 2).

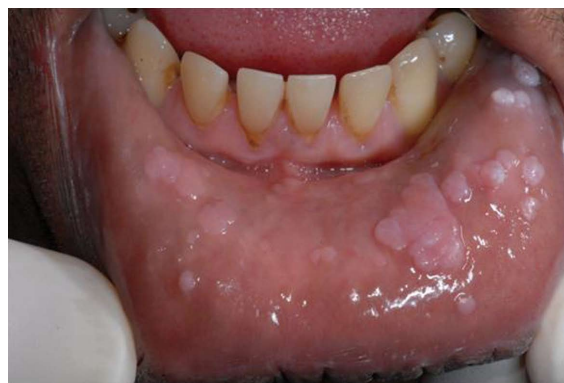

Figure 1 Clinical aspect of the focal epithelial hyperplasia lesions on the lower lip mucosa.

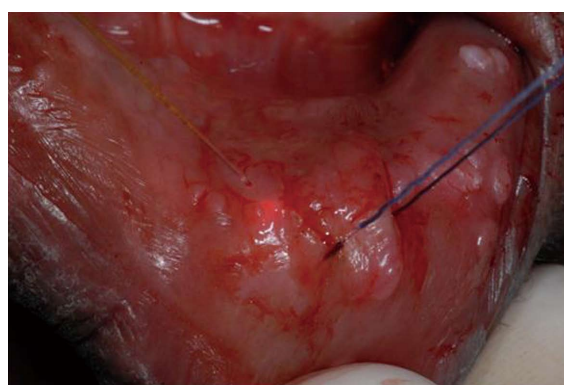


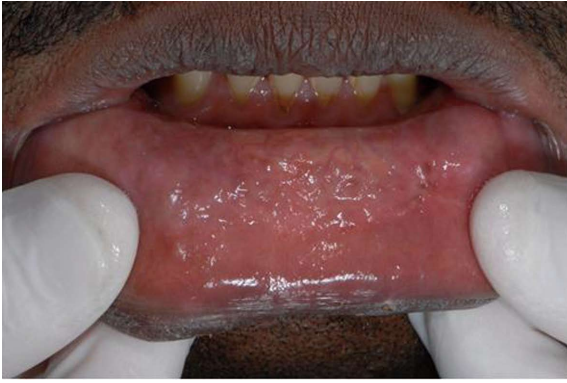Figure 2 Laser excisional biopsy of one of the lesions on the lower lip.

The specimens were preserved in 10% buffered formalin for histological examination, which confirmed the clinical diagnosis of FEH.

In this case, the laser allowed excellent control of bleeding, without postoperative sutures, and optimal wound healing. After the first excisional biopsy, all of the lesions were surgically removed, in several steps, using the same operative approach. The patient was monitored with follow-up visits for one year, during which no recurrence of the pathology was observed (Figure 3), and he was asked to return if any lesions reappeared in the future.

## DISCUSSION

FEH is a rare condition in Italy and Europe. Here, we describe the case of an immunosuppressed African man with FEH. This pathology has been extensively described among native South and North American populations<sup>[1,6-8]</sup>. It seems that there could be a genetic predilection for FEH, as cases seem to be limited to specific ethnic groups in certain geographic regions<sup>[1,6]</sup>. Ledesma-Montes *et al*<sup>[7]</sup> suggested a series of factors that could contribute to the development of FEH: poverty, genetic predisposition (ethnic factors), and a deficient hygienic lifestyle. FEH lesions are most frequently localized on the buccal mucosa, lip, tongue, and commissures; the retromolar area, palate, and mouth floor are rarer local-



**Figure 3** Clinical aspect of the healing after excision of the lesions on the lower lip, 1 yr after treatment.

izations<sup>[7]</sup>. FEH must be included in differential diagnosis with several pathological conditions that can be observed in the oral cavity<sup>[8]</sup>, namely, condylomata acuminata, verrucous carcinoma, inflammatory fibrous hyperplasia, inflammatory papillary hyperplasia, and verruciform xanthoma<sup>[3]</sup>. Condyloma may appear similarly because it is caused by the same virus, but FEH lesions are more numerous and flatter, with typical localizations (buccal mucosa, lip and tongue)<sup>[9]</sup>. Verrucous carcinoma is a malign neoplasm that usually occurs in a different age group, usually in the sixth decade of life, with epidemiological characteristics that are similar to other oral carcinomas<sup>[10]</sup>.

The last three pathologies are reactive lesions that usually occur with an irritating stimulus<sup>[9]</sup>. The diagnosis of FEH can be performed on the basis of clinical observation and can be confirmed by histological examination<sup>[11-13]</sup>.

The histological features of this disease are parakeratosis, acanthosis, elongation of rete ridges, some of which may be anastomosed (the so-called “bronze age battle-axe” appearance<sup>[14]</sup>, and usually koilocytes, as well as other cellular modifications that can indicate viral infection<sup>[5,14]</sup>. Cells with nuclear degeneration, called mitosoid cells, can also appear<sup>[15]</sup>. FEH can be associated with HIV infection, although the relationship between these conditions has not yet been completely clarified<sup>[12]</sup>. Suppression of the immune system leaves the patient vulnerable to opportunistic infections, including HPV infections<sup>[12]</sup>.

There is no agreement in the literature on the potential malignant transformation of FEH lesions in immunocompromised patients. Moerman *et al*<sup>[12]</sup> stated that FEH lesions may have a high risk of malignant transformation in immunocompromised patients. Durso *et al*<sup>[13]</sup> tended to consider FEH a benign condition and stated that to date, no research has demonstrated the potential for malignant transformation of FEH lesions with HPV 13 and 32 subtypes. Only one case of malignant transformation of FEH caused by HPV type 24 has been reported<sup>[16]</sup>. Further studies are required to clarify this point.

Several therapeutic approaches have been proposed throughout the years. Some authors advise against re-

moving the lesions because spontaneous regression can be observed<sup>[17]</sup>, especially in children. Steinhoff *et al*<sup>[18]</sup> successfully treated FEH with topical applications of interferon beta. Other described methods include scalpel surgery, electrocoagulation, electrodesiccation, cryosurgery, and laser surgery<sup>[19,20]</sup>. In this case, laser surgery allowed excellent control of bleeding, without postoperative sutures, and optimal wound healing. Moreover, histological analysis is always possible with laser surgery when the proper parameters and correct surgical technique are used<sup>[21]</sup>.

## COMMENTS

### Case characteristics

A 37-year-old male with a history of human immuno-deficiency virus (HIV) infection presented with numerous asymptomatic lesions in the oral cavity.

### Clinical diagnosis

Seventeen sessile, soft, normochromic lesions on the lower lip and the buccal mucosa, on both sides.

### Differential diagnosis

Condylomata acuminata, verrucous carcinoma, inflammatory fibrous hyperplasia, inflammatory papillary hyperplasia, verruciform xanthoma.

### Laboratory diagnosis

Cluster of differentiation 4 receptors (CD4) 129/μL; HIV RNA < 37 copies/mL; metabolic panel and coagulation within normal limits.

### Pathological diagnosis

Histological examination revealed parakeratosis, acanthosis, presence of koilocytes and mitosoid cells.

### Treatment

Excisional biopsy with a 532-nm potassium titanyl phosphate (KTP) laser.

### Related reports

Focal epithelial hyperplasia (FEH) can be associated with HIV infection, although the relationship between these two conditions has not yet been completely clarified; most likely, suppression of the immune system leaves the patient vulnerable to opportunistic infections, including HPV infections.

### Term explanation

KTP lasers are powerful tools for oral surgery and oral pathology, as are other types of lasers.

### Experiences and lessons

Oral lesions can be a manifestation of more complex systemic diseases; advanced surgical techniques can be useful tools in the management of multiple oral viral lesions.

### Peer review

This paper is worthy of publication as an interesting case report of uncommon oral mucosa disease in HIV infected patient. Particularly, an information of efficiency of KTP laser surgery in treatment of Heck's disease will be useful for clinicians.

## REFERENCES

- 1 Archard HO, Heck JW, Stanley HR. Focal epithelial hyperplasia: an unusual oral mucosal lesion found in Indian children. *oral surg oral med oral pathol* 1965; **20**: 201-212 [PMID: 14322615 DOI: 10.1016/0030-4220(65)90192-1]
- 2 Clausen FP, Mogeltoft M, Roed-Petersen B, Pindborg JJ. Focal epithelial hyperplasia of the oral mucosa in a south-west Greenlandic population. *Scand J Dent Res* 1970; **78**: 287-294 [PMID: 5273696]
- 3 Terezhalmay GT, Riley CK, Moore WS. Focal epithelial hyperplasia (Heck's disease). *Quintessence Int* 2001; **32**: 664-665 [PMID: 11526896]
- 4 Hanks CT, Fishman SL, Guzman MN. Focal epithelial hyperplasia. A light and electron microscopic study. *Oral Surg*



- Oral Med Oral Pathol* 1972; **33**: 934-943 [PMID: 4503460 DOI: 10.1016/0030-4220(72)90185-5]
- 5 **Falaki F**, Amir Chaghmaghi M, Pakfetrat A, Delavarian Z, Mozaffari PM, Pazooki N. Detection of human papilloma virus DNA in seven cases of focal epithelial hyperplasia in Iran. *J Oral Pathol Med* 2009; **38**: 773-776 [PMID: 19453844 DOI: 10.1111/j.1600-0714.2009.00784.x]
- 6 **Witkop CJ**, Niswander JD. Focal epithelial hyperplasia in central and south american indians and ladinos. *Oral Surg Oral Med Oral Pathol* 1965; **20**: 213-217 [PMID: 14319596 DOI: 10.1016/0030-4220(65)90193-3]
- 7 **Ledesma-Montes C**, Garcés-Ortíz M, Hernández-Guerrero JC. Clinicopathological and immunocytochemical study of multifocal epithelial hyperplasia. *J Oral Maxillofac Surg* 2007; **65**: 2211-2217 [PMID: 17954316 DOI: 10.1016/j.joms.2006.11.035]
- 8 **Cubie HA**. Diseases associated with human papillomavirus infection. *Virology* 2013; **445**: 21-34 [PMID: 23932731 DOI: 10.1016/j.virol.2013.06.007]
- 9 **Borborema-Santos CM**, Castro MM, Santos PJ, Talhari S, Astolfi-Filho S. Oral focal epithelial hyperplasia: report of five cases. *Braz Dent J* 2006; **17**: 79-82 [PMID: 16721472 DOI: 10.1590/S0103-64402006000100018]
- 10 **Zhu LK**, Ding YW, Liu W, Zhou YM, Shi LJ, Zhou ZT. A clinicopathological study on verrucous hyperplasia and verrucous carcinoma of the oral mucosa. *J Oral Pathol Med* 2012; **41**: 131-135 [PMID: 21913992 DOI: 10.1111/j.1600-0714.2011.01078.x]
- 11 **Bassioukas K**, Danielides V, Georgiou I, Photos E, Zagorianakou P, Skevas A. Oral focal epithelial hyperplasia. *Eur J Dermatol* 2000; **10**: 395-397 [PMID: 10882951]
- 12 **Moerman M**, Danielides VG, Nousia CS, Van Wanzeele F, Forsyth R, Vermeersch H. Recurrent focal epithelial hyperplasia due to HPV13 in an HIV-positive patient. *Dermatology* 2001; **203**: 339-341 [PMID: 11752826 DOI: 10.1159/000051786]
- 13 **Durso BC**, Pinto JM, Jorge J, de Almeida OP. Extensive focal epithelial hyperplasia: case report. *J Can Dent Assoc* 2005; **71**: 769-771 [PMID: 16324231]
- 14 **Marvan E**, Firth N. Focal epithelial hyperplasia in an HIV positive man. An illustrated case and review of the literature. *Aust Dent J* 1998; **43**: 305-310 [PMID: 9848979 DOI: 10.1111/j.1834-7819.1998.tb00178.x]
- 15 **Segura-Saint-Gerons R**, Toro-Rojas M, Ceballos-Salobreña A, Aparicio-Soria JL, Fuentes-Vaamonde H. Focal epithelial hyperplasia. A rare disease in our area. *Med Oral Patol Oral Cir Bucal* 2005; **10**: 128-131 [PMID: 15735545]
- 16 **Niebrügge B**, Villiers E, Gerlach K, Franke I, Gollnick H. Demonstration of HPV 24 in long-standing Heck's disease with malignant transformation. *Eur J Dermatol* 1999; **9**: 477-479 [PMID: 10491507]
- 17 **Pfister H**, Hettich I, Runne U, Gissmann L, Chliff GN. Characterization of human papillomavirus type 13 from focal epithelial hyperplasia Heck lesions. *J Virol* 1983; **47**: 363-366 [PMID: 6312071]
- 18 **Steinhoff M**, Metze D, Stockfleth E, Luger TA. Successful topical treatment of focal epithelial hyperplasia (Heck's disease) with interferon-beta. *Br J Dermatol* 2001; **144**: 1067-1069 [PMID: 11359400 DOI: 10.1046/j.1365-2133.2001.04201.x]
- 19 **Akyol A**, Anadolu R, Anadolu Y, Ekmekci P, Gürgey E, Akay N. Multifocal papillomavirus epithelial hyperplasia: successful treatment with CO2 laser therapy combined with interferon alpha-2b. *Int J Dermatol* 2003; **42**: 733-735 [PMID: 12956692 DOI: 10.1046/j.1365-4362.2003.01777.x]
- 20 **Said AK**, Leao JC, Fedele S, Porter SR. Focal epithelial hyperplasia - an update. *J Oral Pathol Med* 2013; **42**: 435-442 [PMID: 23061874 DOI: 10.1111/jop.12009]
- 21 **Romeo U**, Palaia G, Del Vecchio A, Tenore G, Gambarini G, Gutknecht N, De Luca M. Effects of KTP laser on oral soft tissues. An in vitro study. *Lasers Med Sci* 2010; **25**: 539-543 [PMID: 20162316 DOI: 10.1007/s10103-010-0756-2]

**P- Reviewers:** Bugaj AM, Kaliyadan F **S- Editor:** Ji FF

**L- Editor:** A **E- Editor:** Wu HL



## Optimal management of a patient with recurrent nasopharyngeal carcinoma

Francesco Perri, Italo Dell'Oca, Paolo Muto, Concetta Schiavone, Corrado Aversa, Franco Fulciniti, Raffaele Solla, Giuseppina Della Vittoria Scarpati, Carlo Buonerba, Giuseppe Di Lorenzo, Francesco Caponigro

Francesco Perri, Francesco Caponigro, Head and Neck Medical Oncology Unit, National Tumor Institute of Naples, 80131 Naples, Italy

Italo Dell'Oca, Radiotherapy Unit, S. Raffaele Hospital of Milan, 20100 Milan, Italy

Paolo Muto, Concetta Schiavone, Radiotherapy Unit, National tumor Institute of Naples, 80131 Naples, Italy

Corrado Aversa, Otolaryngology Unit, National Tumor Institute of Naples, 80131 Naples, Italy

Franco Fulciniti, Pathology Unit, National Tumor Institute of Naples, 80131 Naples, Italy

Raffaele Solla, Institute of Biostructures and Bioimage, National Council of Research (CNR) of Naples, 80131 Naples, Italy

Giuseppina Della Vittoria Scarpati, Oncology and Molecular Biology Research Unit, University of Salerno, 84090 Salerno, Italy

Carlo Buonerba, Giuseppe Di Lorenzo, Medical Oncology, University Federico II of Naples, 80131 Naples, Italy

Author contributions: All authors contributed to this paper.

Correspondence to: Francesco Perri, MD, Head and Neck Medical Oncology Unit, National Tumor Institute of Naples, Via Mariano Semmola, 80131 Naples, Italy. [francesco.perri80@alice.it](mailto:francesco.perri80@alice.it)

Telephone: +39-815-903362 Fax: +39-815-903822

Received: January 15, 2014 Revised: April 24, 2014

Accepted: May 16, 2014

Published online: July 16, 2014

© 2014 Baishideng Publishing Group Inc. All rights reserved.

**Key words:** Cetuximab; Nasopharyngeal carcinoma; Re-irradiation; Surgery of metastases; Undifferentiated

**Core tip:** Recurrent nasopharyngeal carcinoma requires multi-modality therapy based on radiotherapy, surgery and chemotherapy, with a careful evaluation of expected toxicity and patient's quality of life.

Perri F, Dell'Oca I, Muto P, Schiavone C, Aversa C, Fulciniti F, Solla R, Della Vittoria Scarpati G, Buonerba C, Di Lorenzo G, Caponigro F. Optimal management of a patient with recurrent nasopharyngeal carcinoma. *World J Clin Cases* 2014; 2(7): 297-300 Available from: URL: <http://www.wjgnet.com/2307-8960/full/v2/i7/297.htm> DOI: <http://dx.doi.org/10.12998/wjcc.v2.i7.297>

### INTRODUCTION

Nasopharyngeal carcinoma (NPC) accounts for less than 1% of all malignancies and is rare in western countries<sup>[1]</sup>. NPC is usually poorly differentiated and is diagnosed in young patients. The prognosis of loco-regional disease is satisfactory, with a 5-year overall survival exceeding 80%. Radiation alone is employed for stage I - II disease, while for locally advanced NPC the combination of chemotherapy and radiotherapy is the standard approach<sup>[1]</sup>. The advent of new radiotherapy techniques, like intensity modulated radiotherapy (IMRT), has further improved prognosis of newly diagnosed NPC patients and contributed to allow re-irradiation of recurrent disease. On the other hand, management of recurrent/metastatic disease remains challenging for medical and radiation oncologists. In addition to cisplatin-based chemotherapy, which is the standard systemic treatment for NPC<sup>[2]</sup>, cetuximab may be in patients with NPC and squamous histology according to guidelines. Importantly, in undifferentiated

### Abstract

Nasopharyngeal carcinoma is rare in western countries, accounting for less than 1% of all malignancies. Despite prognosis is satisfactory for newly diagnosed, non-metastatic disease, management of recurrent disease is challenging, with a survival expectancy of approximately 6 mo with the use of chemotherapy as the sole salvage treatment. We report a case of recurrent nasopharyngeal carcinoma treated with a combination of chemotherapy, radiotherapy and surgery in the context of a multidisciplinary approach. A durable complete response was achieved.

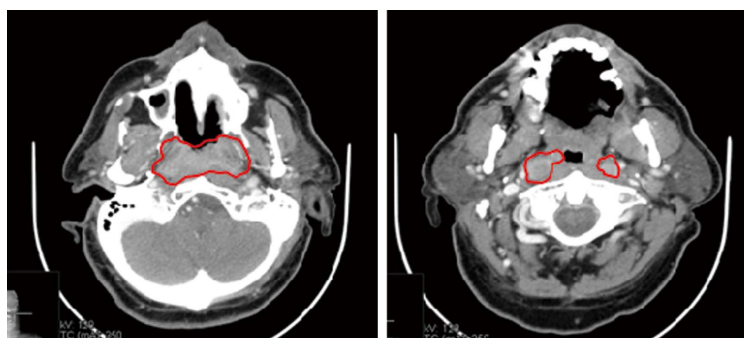


Figure 1 A large lesion arising from the posterior wall of the nasopharynx and bilateral lymphnode metastasis were detected in the parapharyngeal space (October 2009).

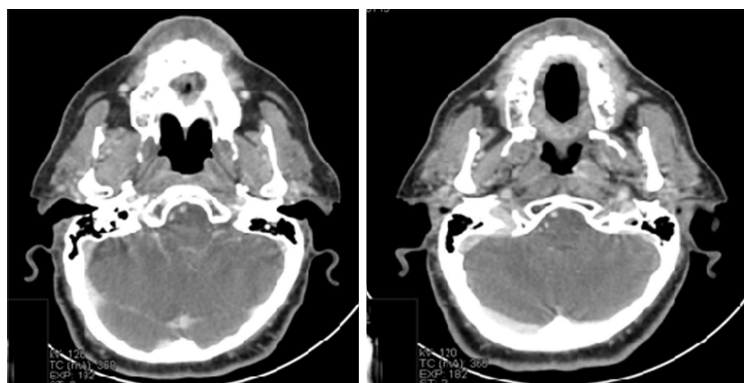


Figure 2 After neoadjuvant TPF followed by cetuximab-radiotherapy, a complete response was obtained (March 2010).

NPC, epithelial growth factor receptor is often overexpressed and k-RAS is never mutated, so cetuximab may provide benefit also in these patients<sup>[5]</sup>. We here report how multidisciplinary management coupled with recent advances in the field allowed us to obtain a durable complete response in a patient with relapsing undifferentiated nasopharyngeal carcinoma.

## CASE REPORT

In September 2009, a 59-year-old male patient was referred to our office for undifferentiated nasopharyngeal carcinoma. Histological diagnosis was made on fiberoptic-guided biopsy. A computed tomography (CT) scan showed a large lesion arising from the posterior wall of the nasopharynx and extending into the paranasal sinuses. The lesion infiltrated the clivus and the oropharynx, and bilateral laterocervical lymphnode metastases were detected. Magnetic resonance imaging (MRI) confirmed CT findings (clinical stage, T4N3M0, IVa AJCC).

A therapeutic strategy based on 3 cycles of neoadjuvant docetaxel, cisplatin and 5-fluorouracil followed by radiotherapy was pursued after written informed consent was obtained. Docetaxel and cisplatin were given at doses of 75 mg/m<sup>2</sup> on day one and 5-Fluorouracil was administered at 750 mg/m<sup>2</sup> daily *via* continuous infusion for four consecutive days every three weeks. In November 2009, CT scan (Figure 1) showed partial response according to RECIST criteria 1.1 (reduction greater than 50% in the sum of the longest diameters of target lesions). From December 2009 until February 2010, a combined cetuximab-RT treatment was delivered. Cetuximab was given at standard doses. A total dose of 70 Gy (2 Gy dose frac-

tions) on clinical target volume was delivered *via* 3D conformational radiotherapy. Toxicity mainly consisted of grade 2 cutaneous rash and grade 2 xerostomia, and did not lead to treatment interruption. Forty-five days after completion of chemo-radiotherapy, a complete response was shown on CT scan (Figure 2) and on PET scan after 60 d.

The patient remained free of disease recurrence until May 2012, when CT scan showed loco-regional recurrence involving the nasopharynx, the left orbital cavity and intraparotid lymph nodes on the left side of the head. Patient presented with visual disturbances and moderate pain. PET scan and cytology confirmed the nature and extension of the recurrence. After multidisciplinary consultation involving the medical oncologist, the radiation oncologist, the pathologist and the surgeon, we decided to use a combined strategy based on an neoadjuvant chemotherapy, followed by re-irradiation and a surgical evaluation of residual disease.

Given the prolonged time to relapse, we deemed the disease to have preserved its sensitivity to taxanes and platinum compounds, so we delivered carboplatin (CB-DCA) AUC 5 (area under curve) on day one every 3 wk, paclitaxel at the dose of 175 mg/m<sup>2</sup> on day one every three weeks and standard doses of weekly cetuximab. Radiological and symptomatic improvement was obtained after three cycles. A CT scan showed disappearance of the nasopharyngeal lesion, shrinkage of the lymphnode mass but no change of the orbital lesion. Toxicity was low, with grade 1 skin rash the most relevant side effect. Re-irradiation was performed from the end of August to the beginning of October 2012 *via* helical IMRT, 18 FDG PET/CT based planning. A total dose of 66 Gy, deliv-

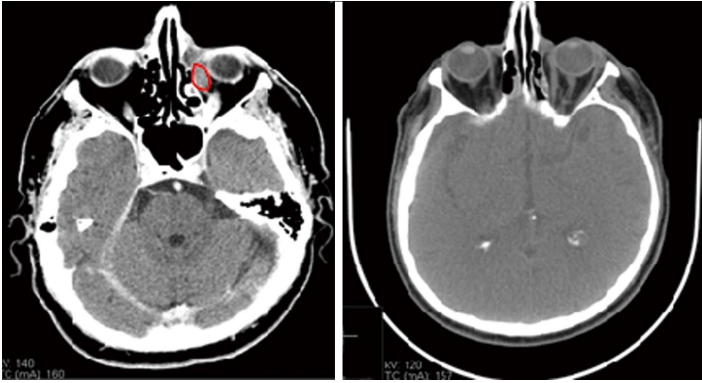


Figure 3 Computed tomography scan showed an intraorbital lesion (May 2012).

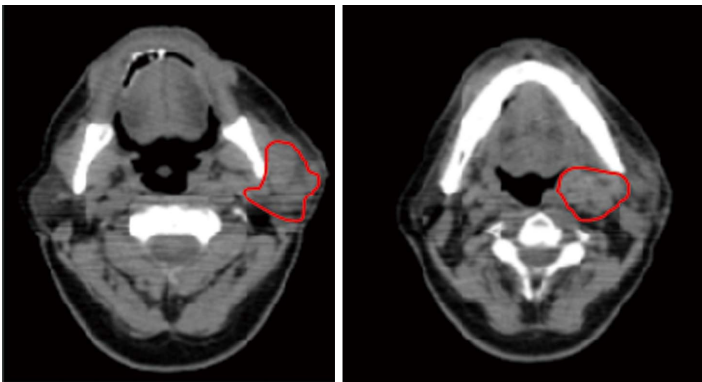


Figure 4 Computed tomography scan showed that the only site of persistent disease was the lymph node mass in the neck (December 2012).

ered in 30 daily fractions of 2.2 Gy, were administered to the site of disease, with the exclusion of the lymph node mass in the neck, with disappearance (Figure 3) of both the orbital lesion and the nasopharynx. After subsequent chemotherapy (three cycles of CBDCA-Pac and cetuximab) CT scan showed that the only site of persistent disease was the lymph node mass in the neck (Figure 4). Patient was scheduled for surgical removal of parathyroid and laterocervical II, III and IV neck levels. In June 2013, CT scan showed no sign of residual disease. As of January 2014, the patient is free of disease. He complains of grade 2 chronic xerostomia due to radiotherapy, and a facial nerve paralysis due to the surgical intervention.

## DISCUSSION

Locally advanced nasopharyngeal carcinoma can be successfully managed by combination platinum-based chemotherapy and radiotherapy<sup>[4]</sup>. Neo-adjuvant chemotherapy is also a valuable option and is especially indicated in patients with large lesions and locally advanced disease, in order to decrease the gross tumor volume<sup>[5]</sup>. Combination of taxanes and platinum compounds is highly active, not only in nasopharyngeal carcinomas but also in other clinical situations, such as head-neck carcinomas of unknown primary<sup>[6]</sup>.

On the other hand, current management of recurrent/metastatic disease is far from yielding satisfactory results, and the prognosis is grim. In addition to cisplatin-based chemotherapy, cetuximab may also be employed in patients with NPC, as shown in some preliminary experiences<sup>[7]</sup>. Our case appears of great interest not only

because cetuximab appeared to improve the outcome at first presentation, but it appeared to have preserved its effectiveness at disease relapse. Cetuximab was well tolerated both at initial presentation and at recurrence. Randomized controlled trials are required to assess efficacy of cetuximab in nasopharyngeal carcinoma before it can be recommended in this setting.

Our case also highlights the importance of a multidisciplinary approach in all patients and especially in those with recurrent disease. The multidisciplinary approach is able to balance toxicity and efficacy associated to combined use of diversified treatments. In recurrent patients, the use of chemotherapy as the sole salvage treatment is associated to a 6-mo prognosis<sup>[8-10]</sup>. With a multidisciplinary approach, we obtained a complete response, and our patient is free of disease recurrence after more than 6 mo and has an acceptable quality of life. Doctor-doctor and patient-doctor communication was of utmost importance for the management of this case, which should set an example of optimal integrated strategy of recurrent nasopharyngeal carcinoma.

## COMMENTS

### Case characteristics

Patient presented with recurrent nasopharyngeal carcinoma treated with chemotherapy, biological therapy, radiation therapy and surgery.

### Clinical diagnosis

Patient was affected by a locally advanced nasopharyngeal tumor, which was shown to be undifferentiated carcinoma on biopsy

### Differential diagnosis

Differential diagnosis included lymphoma and squamous carcinoma.



### Laboratory diagnosis

Patient had normal liver, bone marrow and kidney function at diagnosis and throughout treatment.

### Imaging diagnosis

Patient had locally advanced disease at diagnosis, with a large lesion arising from the posterior wall of the nasopharynx and infiltrating the clivus and bilateral laterocervical lymphnode metastases.

### Pathological diagnosis

Patient was affected by undifferentiated nasopharyngeal carcinoma.

### Treatment

After patient underwent treatment with docetaxel, cisplatin and 5-Fluorouracil and combined cetuximab-radiotherapy, he was treated with carboplatin, paclitaxel and cetuximab, followed by re-irradiation and surgery.

### Term explanation

Clinical target volume.

### Experiences and lessons

Irradiation with cetuximab is advantageous when chemotherapy cannot be delivered.

### Peer review

This paper is a useful clinical case in head and neck diseases.

## REFERENCES

- 1 **Caponigro F**, Longo F, Ionna F, Perri F. Treatment approaches to nasopharyngeal carcinoma: a review. *Anticancer Drugs* 2010; **21**: 471-477 [PMID: 20124988 DOI: 10.1097/CAD.0b013e328337160e]
- 2 **Boussen H**, Cvitkovic E, Wendling JL, Azli N, Bachouchi M, Mahjoubi R, Kalifa C, Wibault P, Schwaab G, Armand JP. Chemotherapy of metastatic and/or recurrent undifferentiated nasopharyngeal carcinoma with cisplatin, bleomycin, and fluorouracil. *J Clin Oncol* 1991; **9**: 1675-1681 [PMID: 1714951]
- 3 **Chan AT**, Hsu MM, Goh BC, Hui EP, Liu TW, Millward MJ, Hong RL, Whang-Peng J, Ma BB, To KF, Mueser M, Amellal N, Lin X, Chang AY. Multicenter, phase II study of cetuximab in combination with carboplatin in patients with recurrent or metastatic nasopharyngeal carcinoma. *J Clin Oncol* 2005; **23**: 3568-3576 [PMID: 15809453 DOI: 10.1200/JCO.2005.02.147]
- 4 **Ma J**, Mai HQ, Hong MH, Min HQ, Mao ZD, Cui NJ, Lu TX, Mo HY. Results of a prospective randomized trial comparing neoadjuvant chemotherapy plus radiotherapy with radiotherapy alone in patients with locoregionally advanced nasopharyngeal carcinoma. *J Clin Oncol* 2001; **19**: 1350-1357 [PMID: 11230478]
- 5 **Perri F**, Bosso D, Buonerba C, Lorenzo GD, Scarpato GD. Locally advanced nasopharyngeal carcinoma: Current and emerging treatment strategies. *World J Clin Oncol* 2011; **2**: 377-383 [PMID: 22171280 DOI: 10.5306/wjco.v2.i12.377]
- 6 **Perri F**, Ionna F, Muto P, Buonerba C, Della Vittoria Scarpato G, Bosso D, Fulciniti F, Daponte A, Argenone A, Sandomenico F, DI Lorenzo G, Caponigro F. Induction docetaxel-cisplatin followed by extended-field radiotherapy in patients with cervical metastases from unknown primary carcinoma. *Anticancer Res* 2013; **33**: 1135-1139 [PMID: 23482792]
- 7 **Smee RI**, Meagher NS, Broadley K, Ho T, Williams JR, Bridger GP. Recurrent nasopharyngeal carcinoma: current management approaches. *Am J Clin Oncol* 2010; **33**: 469-473 [PMID: 19935385 DOI: 10.1097/COC.0b013e3181b4b037]
- 8 **Roeder F**, Zwicker F, Saleh-Ebrahimi L, Timke C, Thieke C, Bischof M, Debus J, Huber PE. Intensity modulated or fractionated stereotactic reirradiation in patients with recurrent nasopharyngeal cancer. *Radiat Oncol* 2011; **6**: 22 [PMID: 21356126 DOI: 10.1186/1748-717X-6-22]
- 9 **Teo PM**, Kwan WH, Chan AT, Lee WY, King WW, Mok CO. How successful is high-dose (> 60 Gy) reirradiation using mainly external beams in salvaging local failures of nasopharyngeal carcinoma? *Int J Radiat Oncol Biol Phys* 1998; **40**: 897-913 [PMID: 9531376 DOI: 10.1016/S0360-3016(97)00854-7]
- 10 **Perri F**, Muto P, Aversa C, Daponte A, Della Vittoria G, Pepe S, Caponigro F. Integrated therapeutic approaches in head and neck cancer: the importance of multidisciplinary team management. *Anticancer Agents Med Chem* 2013; **13**: 834-843 [PMID: 23194421 DOI: 10.2174/18715206113139990110]

P- Reviewers: Ao R, Li YZ S- Editor: Song XX

L- Editor: A E- Editor: Wu HL



## Disseminated infection due to *Mycobacterium bovis* after intravesical BCG instillation

Sara Marquez-Batalla, Esther Fraile-Villarejo, Moncef Belhassen-García, Nieves Gutierrez-Zubiaurre, Miguel Cordero-Sánchez

Sara Marquez-Batalla, Esther Fraile-Villarejo, Servicio de Medicina Interna (CAUSA), IBSAL, Universidad de Salamanca, 37007 Salamanca, Spain

Moncef Belhassen-García, Miguel Cordero-Sánchez, Servicio de Medicina Interna, Sección de Enfermedades Infecciosas, Complejo Asistencial Universitario de Salamanca (CAUSA), Instituto de Investigación Biomedica de Salamanca (IBSAL), Universidad de Salamanca, 37007 Salamanca, Spain

Nieves Gutierrez-Zubiaurre, Servicio de Microbiología, (CAUSA), CIETUS, IBSAL, 37007 Salamanca, Spain

**Author contributions:** Marquez-Batalla S and Fraile-Villarejo E collected the patients clinical data; Gutierrez-Zubiaurre N performed the microbiological analyses; Marquez-Batalla S, Cordero-Sánchez M and Belhassen-García M designed the report and wrote the paper.

**Correspondence to:** Moncef Belhassen-García, MD, PhD, Servicio de Medicina Interna, Sección de Enfermedades Infecciosas, Complejo Asistencial Universitario de Salamanca (CAUSA), Instituto de Investigación Biomedica de Salamanca (IBSAL), Universidad de Salamanca, Paseo San Vicente 58-182, 37007 Salamanca, Spain. [mbelhassen@hotmail.com](mailto:mbelhassen@hotmail.com)  
Telephone: +34-923-291306 Fax: +34-923-291131

Received: February 22, 2014 Revised: April 19, 2014

Accepted: April 25, 2014

Published online: July 16, 2014

**Key words:** Tuberculosis; *Mycobacterium bovis*; Bladder cancer; Bacillus Calmette-Guerin

**Core tip:** Intravesical instillation of bacillus Calmette-Guerin (BCG) is a therapeutic option in bladder cancer. Multi-system effects are a rare complication of this procedure, and certain aspects concerning its diagnosis and treatment are unclear. We report the case of a patient who developed effects on multiple organs after intravesical BCG instillations, and we review current knowledge concerning the diagnosis and management of BCG infection.

Marquez-Batalla S, Fraile-Villarejo E, Belhassen-García M, Gutierrez-Zubiaurre N, Cordero-Sánchez M. Disseminated infection due to *Mycobacterium bovis* after intravesical BCG instillation. *World J Clin Cases* 2014; 2(7): 301-303 Available from: URL: <http://www.wjgnet.com/2307-8960/full/v2/i7/301.htm> DOI: <http://dx.doi.org/10.12998/wjcc.v2.i7.301>

### Abstract

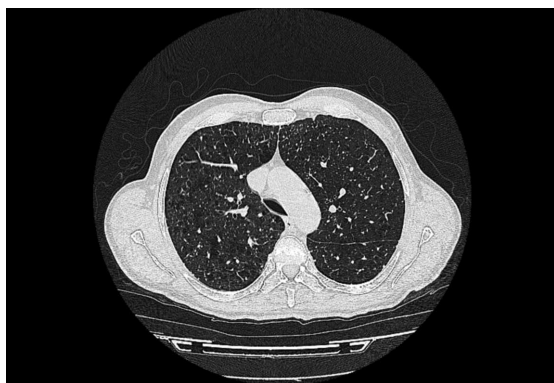Intravesical bacillus Calmette-Guerin (BCG) instillation has been adopted for the treatment of patients with superficial bladder cancer. Severe adverse events due to local instillation of BCG are uncommon, with an overall rate of serious complications of less than 5%. We report the case of an immunocompetent adult patient with multi-system effects, namely pneumonitis, granulomatous hepatitis and meningitis, who responded well to standard treatment for *Mycobacterium bovis*. This case highlights the importance of a thorough assessment of this type of patient.

### INTRODUCTION

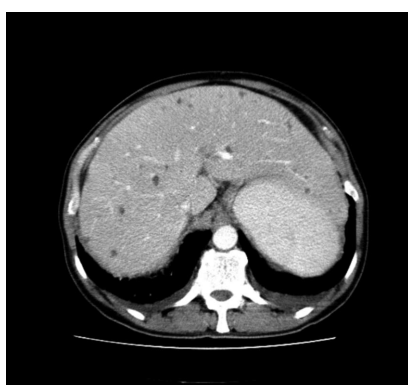Intravesical administration of bacillus Calmette-Guerin (BCG) is an essential tool in the treatment of superficial bladder carcinoma *in situ*<sup>[1]</sup>. This approach is generally well tolerated, although it occasionally leads to severe local and/or systemic complications<sup>[2]</sup>. The most serious complications of intravesical BCG instillation are related to disseminated infection. When disseminated BCG infection occurs, antituberculous therapy with or without glucocorticoids should be administered. We report a case of disseminated infection due to intravesical BCG instillations, resulting in pneumonitis, granulomatous hepatitis and meningitis.

### CASE REPORT

We present the case of a 64-year-old male patient with a

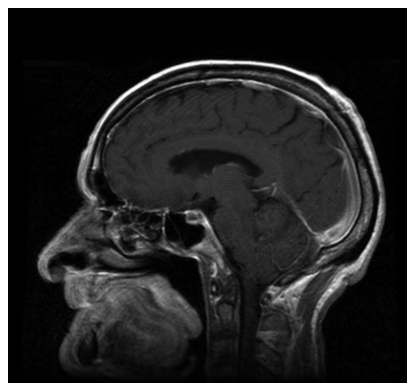

**Figure 1** A thoracic computed tomography scan revealed a pulmonary micronodular pattern.



**Figure 2** An abdominal computed tomography scan revealed hepatic granulomas and hepatosplenomegaly.

history of urothelial vesical neoplasm, benign prostatic hyperplasia and chronic obstructive pulmonary disease. He was being treated with tamsulosin, tiotropium bromide and salbutamol. Six months before, he had received six weekly doses of intravesical BCG instillation as an induction treatment, and one month before, he had started maintenance therapy with three doses per week. At the time of presentation, he reported weakness, weight loss and a slight fever with three weeks of evolution. Physical examination revealed hepatosplenomegaly. An analysis showed hepatic cholestasis (alkaline phosphatase 358 U/L, gamma-glutamyl transpeptidase 306 U/L), lactate dehydrogenase (LDH) 547 U/L and C-reactive protein 1.27 mg/dL. A complete blood count and urine sediment were normal. A thoracic X-ray showed multiple micronodular opacities. A thoraco-abdominal CT scan revealed a pulmonary micronodular pattern, hepatic granulomas and hepatosplenomegaly (Figures 1 and 2). Blood and urine cultures for bacteria were negative, as was a serological analysis (for HIV, HBV, HCV and *Treponema pallidum*). The urinalysis was positive for the species *Mycobacterium tuberculosis*, and *Mycobacterium bovis* (*M. bovis*) BCG grew with resistance to cycloserine and pyrazinamide. A genetic study detected the pnc A C169G (H57D) mutation, and we identified the species as *M. bovis*. The patient started treatment with isoniazid, rifampicin and etham-



**Figure 3** Magnetic resonance imaging showed thickening and linear meningeal enhancement.

butol. After one week of treatment, the patient showed dizziness and instability while standing still and walking. The cerebrospinal fluid (CSF) showed red blood cells 4500/ $\mu$ L, leukocytes 16  $\mu$ L (polymorphonuclear 25%, mononuclear 75%), proteins 82 mg/mL, glucose 67 mg/mL (capillary glycemia 144 mg/dL), LDH: 35 IU/L and adenosine deaminase 5.6 U/L (0-5). Magnetic resonance imaging of the brain (Figure 3) showed thickening and linear meningeal enhancement. Microbiological analysis of the CSF was negative. Given the meningeal involvement, anti-tuberculosis treatment was administered for one year, with good clinical and radiological responses.

## DISCUSSION

The adverse effects of intravesical BCG instillations can appear early or several years after the treatment. Although there are certain common local effects, such as cystitis (91%)<sup>[3]</sup> (this condition can be difficult to differentiate from other urinary tract infections), systemic complications are rare. The frequency of appearance ranges from 2.9% in cases with fever to 0.3% in cases with skin exanthema<sup>[4]</sup>. The most severe symptoms are pneumonitis, hepatitis, sepsis and pancytopenia. No differences in the incidence of complications were observed when comparing different BCG preparations or doses<sup>[5]</sup>. The spreading mechanism is not exhaustively known. Certain authors think that hematogenous spread occurs from the bladder<sup>[3]</sup>, whereas others believe that the spread is due to a type IV hypersensitivity-related mechanism<sup>[6]</sup>. The response to glucocorticoids administered along with antituberculous drugs has also supported the notion of a hypersensitivity response. There are no established effective measures to prevent a disseminated infection with BCG<sup>[7]</sup>, although the risk increases when instillations are temporally close to surgery or to traumatic catheterization<sup>[8]</sup>. The genetic study of the urine sample of our patient allowed us to identify *M. bovis* and to confirm its classic resistance profile. Given the meningeal involvement in the patient in our case, the treatment was extended for one year, with combination with corticoids in the first weeks.

In conclusion, intravesical BCG instillation can induce disseminated infection. Molecular techniques can help in early diagnosis because a delay in management can be lethal. In our patient, standard triple therapy with steroids led to complete recovery.

## COMMENTS

### Case characteristics

A 64-year-old male patient with an urothelial-vesical neoplasm treated by intravesical bacillus Calmette-Guérin (BCG) instillations.

### Clinical diagnosis

Hepatosplenomegaly and later dizziness and instability.

### Differential diagnosis

Neoplasm and central nervous system infection.

### Laboratory diagnosis

Alkaline phosphatase 358 U/L, gamma-glutamyl transpeptidase 306 U/L, lactate dehydrogenase 547 U/L and C-reactive protein 1.27 mg/dL. A complete blood count and urine sediment were normal.

### Imaging diagnosis

A thoracic X-ray showed multiple micronodular opacities. A thoraco-abdominal computed tomography scan revealed a pulmonary micronodular pattern, hepatic granulomas and hepatosplenomegaly. Magnetic resonance imaging of the brain showed thickening and linear meningeal enhancement.

### Pathological diagnosis

A urinalysis was positive for *Mycobacterium bovis*.

### Treatment

Anti-tuberculosis treatment was administered for one year.

### Related reports

Severe adverse events due to local instillation of BCG are uncommon, and disseminated BCG infection can simulate several diseases.

### Term explanation

BGG is a low-virulence mycobacterium that originates from successive cultures of *Mycobacterium bovis*. Pnc A is a gene encoding the mycobacterial enzyme pyrazinamidase.

### Experiences and lessons

BCG can induce disseminated disease with multi-system failure.

### Peer review

This paper reports the case of serious complications in a variety of organs after intravesical BCG instillation. The manuscript is basically well written.

## REFERENCES

- 1 **Malmström PU**, Sylvester RJ, Crawford DE, Friedrich M, Krege S, Rintala E, Solsona E, Di Stasi SM, Witjes JA. An individual patient data meta-analysis of the long-term outcome of randomised studies comparing intravesical mitomycin C versus bacillus Calmette-Guérin for non-muscle-invasive bladder cancer. *Eur Urol* 2009; **56**: 247-256 [PMID: 19409692 DOI: 10.1016/j.eururo.2009.04.038]
- 2 **McParland C**, Cotton DJ, Gowda KS, Hoepfner VH, Martin WT, Weckworth PF. Miliary Mycobacterium bovis induced by intravesical bacille Calmette-Guérin immunotherapy. *Am Rev Respir Dis* 1992; **146**: 1330-1333 [PMID: 1443892 DOI: 10.1164/ajrccm/146.5\_Pt\_1.1330]
- 3 **Gonzalez OY**, Musher DM, Brar I, Furgeson S, Boktour MR, Septimus EJ, Hamill RJ, Graviss EA. Spectrum of bacille Calmette-Guérin (BCG) infection after intravesical BCG immunotherapy. *Clin Infect Dis* 2003; **36**: 140-148 [PMID: 12522745 DOI: 10.1086/344908]
- 4 **Miranda S**, Verdet M, Héron F, Vittecoq O, Levesque H, Marie I. [Acute reactive arthritis after intravesical instillation of bacillus Calmette-Guérin. Two case reports and literature review]. *Rev Med Interne* 2010; **31**: 558-561 [PMID: 20494494 DOI: 10.1016/j.revmed.2010.01.010]
- 5 **Lamm DL**. Efficacy and safety of bacille Calmette-Guérin immunotherapy in superficial bladder cancer. *Clin Infect Dis* 2000; **31** Suppl 3: S86-S90 [PMID: 11010830 DOI: 10.1086/314064]
- 6 **Elkabani M**, Greene JN, Vincent AL, VanHook S, Sandin RL. Disseminated Mycobacterium bovis after intravesicular bacillus calmette-Guérin treatments for bladder cancer. *Cancer Control* 2000; **7**: 476-481 [PMID: 11000618]
- 7 **Damiano R**, De Sio M, Quarto G, Di Lorenzo G, Perdonà S, Palumbo IM, Azzarito G, Giugliano F, Autorino R. Short-term administration of prulifloxacin in patients with non-muscle-invasive bladder cancer: an effective option for the prevention of bacillus Calmette-Guérin-induced toxicity? *BJU Int* 2009; **104**: 633-639 [PMID: 19298412 DOI: 10.1111/j.1464-410X.2009.08469.x]
- 8 **Nadasy KA**, Patel RS, Emmett M, Murillo RA, Tribble MA, Black RD, Sutker WL. Four cases of disseminated Mycobacterium bovis infection following intravesical BCG instillation for treatment of bladder carcinoma. *South Med J* 2008; **101**: 91-95 [PMID: 18176300 DOI: 10.1097/SMJ.0b013e31815d4047]

P- Reviewers: Hsu WH, Nagata T S- Editor: Song XX  
L- Editor: A E- Editor: Wu HL





## One-stage revision in two cases of *Salmonella* prosthetic hip infection

Kimberly TV Jeroense, Jesse WP Kuiper, Sascha Colen, Rogier P Schade, Rachid Saouti

Kimberly TV Jeroense, Rachid Saouti, Department of Orthopaedic Surgery, VU University Medical Centre, Amsterdam 1081 HV, Noord-Holland, The Netherlands

Jesse WP Kuiper, Centre for Orthopaedic Research Alkmaar, Medical Centre Alkmaar, Alkmaar 1815 JD, Noord-Holland, The Netherlands

Sascha Colen, Department of Orthopedic Surgery and Traumatology, Sint Bonifatius Hospital, Lingen, 49808, Ems, Germany

Rogier P Schade, Department of Medical Microbiology and Infection Control, VU University Medical Centre, Amsterdam 1081 HV, Noord-Holland, The Netherlands

Author contributions: Jeroense KTV, Kuiper JWP, Colen S, Schade RP and Saouti R designed the report; Kuiper JWP, Jeroense KTV and Saouti R collected the patient's clinical data; Jeroense KTV and Kuiper JWP wrote the paper; all authors revised the manuscript.

Correspondence to: Jesse WP Kuiper, Orthopaedic Surgery Resident, Centre for Orthopaedic Research Alkmaar, Medical Centre Alkmaar, Wilhelminalaan 12, Alkmaar 1815 JD, The Netherlands. [jwp.kuiper@gmail.com](mailto:jwp.kuiper@gmail.com)

Telephone: +31-72-5484342 Fax: +31-72-5482168

Received: December 28, 2013 Revised: April 17, 2014

Accepted: May 28, 2014

Published online: July 16, 2014

as well. According to the latest guidelines, one-stage revision has comparable success rates and less morbidity compared to two-stage treatment, when selecting the right patients. In our opinion, PJI caused by *Salmonella* should be treated just as PJI caused by other bacteria, with consideration of the selection criteria as mentioned in several treatment guidelines. As illustrated by these two cases, one-stage revision can be successful in both early and late *Salmonella* PJI of the hip.

© 2014 Baishideng Publishing Group Inc. All rights reserved.

**Key words:** *Salmonella*; Prosthetic joint infection; One-stage revision; Two-stage revision; Treatment

**Core tip:** Prosthetic joint infection (PJI) of the hip by *Salmonella* species is rare. There is an ongoing debate whether treatment of prosthetic joint infection should consist of a one- or two-stage approach and also whether or not PJI caused by *Salmonella* should be treated similarly to PJI caused by other bacteria. We report two cases of *Salmonella* PJI, one early and one late infection, successfully treated by one-stage revision.

### Abstract

We describe two cases of prosthetic joint infection (PJI) of the hip due to *Salmonella*. The first patient presented with an early infection 5 d after being discharged following a total hip replacement and the second patient presented at the emergency ward with a late infection, thirteen years following a total hip replacement. Both cases occurred within one month of each other at our institution and both were successfully treated with a one-stage revision. PJI caused by *Salmonella* species is very rare: so far only 20 *Salmonella* PJIs of the hip have been described. Therefore, full consensus on the best treatment approach has not yet been reached. An aggressive two-stage approach is advised because of the virulence of *Salmonella*, although a limited number of successful one-stage approaches have been described

Jeroense KTV, Kuiper JWP, Colen S, Schade RP, Saouti R. One-stage revision in two cases of *Salmonella* prosthetic hip infection. *World J Clin Cases* 2014; 2(7): 304-308 Available from: URL: <http://www.wjgnet.com/2307-8960/full/v2/i7/304.htm> DOI: <http://dx.doi.org/10.12998/wjcc.v2.i7.304>

### INTRODUCTION

*Salmonella* infections are usually associated with food consumption, specifically raw egg and related products, which account for at least one third of all outbreaks in the United States<sup>[1]</sup>. In the Netherlands, a Salmonellosis incidence of around 300/100000 is seen, mostly manifesting as gastroenteritis<sup>[2]</sup>. Although a general decline in human Salmonellosis has occurred in the last two

decades<sup>[1,2]</sup>, because of demographic changes, the excess mortality due to *Salmonella* infections was predicted to double in the next 50 years<sup>[3]</sup>.

The same demographic changes, i.e. the relatively and absolutely growing elderly population, will account for an increase in the number of total hip arthroplasties (THAs), and subsequently prosthetic joint infections (PJIs) of these hips<sup>[4]</sup>. PJI occurs in around 1%-2% of all THAs<sup>[5]</sup>, and is one of the most severe and costly complications, usually requiring additional surgery, a prolonged hospital stay and administration of antibiotic agents, and (temporary) decreased function and quality of life<sup>[6,7]</sup>.

PJI caused by *Salmonella* is nevertheless rare: only 28 patients (30 joints) have been described in the literature, of which 20 were prosthetic hip infections<sup>[8]</sup>. In the case of *Salmonella typhi*, the most common serotype, the prevalence of involvement of the bones or joints is only 1% or even less<sup>[9]</sup>. A higher frequency of *Salmonella* infections is seen in patients with sickle cell disease, systemic lupus erythematosus (SLE) and other immunocompromised states<sup>[5,10]</sup>, and in children aged under five<sup>[3,11,12]</sup>. Most cases of *Salmonella* joint infections are caused by hematogenous spread<sup>[5,13]</sup>.

An aggressive approach with two-stage revision is advised in cases of *Salmonella* PJI, because of the bacterial virulence<sup>[8]</sup>.

We describe two cases of *Salmonella* prosthetic hip infection, both occurring within one month of each other, treated with one-stage revision.

## CASE REPORT

### Case 1

A 68-year-old female patient visited our outpatient clinic for severe osteoarthritis of the right hip. Her medical history further included clubfoot correction in her early youth, pneumonectomy for carcinoid tumor, hypophysectomy after pituitary adenoma, hypertension, renal failure grade 3, heart failure grade 3, atrial flutter and a stroke. She was using anticoagulants (acenocoumarol) and steroids (hydrocortisone) among other medication. She also mentioned an allergy for cephalosporins. In accord with the patient THA was planned.

Four days prior to surgery, her anticoagulants were replaced by therapeutic low molecular weight heparins (LMWH, nadroparin 5700 IE two times daily). Peri-operatively, prophylactic clindamycin was administered. A non-cemented Trident cup with polyethylene insert (Trident system, Stryker Orthopaedics, Mahwah, New Jersey, United States) and a cemented Exeter stem (Exeter Total Hip system, Stryker Orthopaedics, Mahwah, New Jersey, United States) using Simplex P bone cement with Tobramycin (1 g tobramycin, Stryker Orthopaedics, Mahwah, New Jersey, United States) were implanted.

After an uncomplicated rehabilitation course of 5 d the patient was discharged. However, she was readmitted at her local hospital just 2 d later, with anemia (hemoglobin of 4.1 mmol/L, reference value 7.5-10.0 mmol/L). She was given 2 units of packed red blood cells (PRBC)

and was transferred to our center.

Due to a sudden onset of right flank pain and elevated liver enzymes, an abdominal computed tomography was performed, which revealed a retroperitoneal hematoma, possibly with ongoing bleeding. Administration of nadroparin was discontinued, the patient received another 4 units of PRBC and after fluid resuscitation her hemodynamic status remained stable.

Gram staining of joint aspirate and superficial wound cultures revealed gram negative rods, while blood parameters showed a C-reactive protein (CRP of 334 mg/L (reference value < 8 mg/L). DAIR (debridement, antibiotics, irrigation and retention) was performed soon after. Intra-operatively 5 cultures were gathered, the insert and prosthetic head were exchanged, and 3 resorbable gentamicin sponges (130 mg gentamicin per sponge; Garacol, EUSA Pharma, Oxford, United Kingdom) were left in the surgical area. Afterwards, intravenous ciprofloxacin was started at 400 mg 3 times daily combined with intravenous vancomycin 1000 mg once daily.

After one week the cultures taken intra-operatively yielded Group E *Salmonella* species. At that moment the vancomycin was stopped while intravenous ciprofloxacin was continued for another week. This was followed by 4 wk of 750 mg ciprofloxacin orally twice a day. Then, due to her existing renal failure, the dosage of ciprofloxacin was lowered to 500 mg twice a day for one week and 500mg once a day for yet another week.

Due to sanguinous wound drainage, the dosage of nadroparin was changed to the prophylactic dosage (0.3 mL = 2850 IE, once a day). Because of the continuing wound drainage and increasing CRP from 119 to 147 mg/L, it was decided to proceed with a one-stage revision, nearly two months after the initial arthroplasty.

Intra-operatively, all components and cement were removed and the wound was thoroughly debrided and irrigated. Subsequently the medullary canal was reamed and an uncemented Restoration Modular stem (Restoration Modular System, Stryker Orthopaedics, Mahwah, New Jersey, United States) and Trident cup were inserted. Antibiotic treatment was continued with ciprofloxacin, according to the antibiogram from the cultures taken previously.

A subsequent debridement, antibiotics and implant retention (DAIR) procedure was performed because of persistent leakage, which appeared to be due to a fracture of the proximal femur around the stable stem. After wiring of this fracture and after exchanging the insert and prosthetic head of THA again, the patient recovered quickly and wound leakage ceased.

The 5 cultures taken during the one-stage revision, as well as the 2 cultures from the second DAIR procedure, all taken during antibiotic treatment, turned out negative. After the second DAIR procedure oral ciprofloxacin dose was administered at 750 mg 2 times daily again. After 5 wk this was lowered back to 500 mg once a day (because of the renal failure).

At the first follow up, two months since the one-stage revision, the patient was walking with a walker. The wound still showed a little redness, but CRP had declined

to 26 mg/L and erythrocyte sedimentation rate (ESR) was 43 mm/h (reference value < 20 mm/h).

At 5 mo follow-up, antibiotic treatment was stopped, the wound showed no signs of infection and ESR had normalized.

## Case 2

A 59-year-old man presented at the emergency department with pain in the right groin since four days, along with a progressive fever and nausea. At the age 16 he underwent screw osteosynthesis, because of epiphysiolysis capitis femoris, which was followed by THA in 1999 at the age of 46. No other comorbidities were present.

On physical examination of the hip the patient showed a painless function of 100 degrees flexion, 0 degrees extension, 20 degrees endorotation, and 30 degrees exorotation. Pressure in the groin was painful, however. The psoas sign was negative.

Additional blood tests showed a C-reactive protein of 193 mg/L and ESR 23 mm/h. On X-ray the prosthetic head appeared not to be centered (sign of polyethylene wear), though there were no signs of loosening of the prosthesis. Ultrasound of the groin revealed a 5.5 cm × 7.5 cm abscess. Aspiration produced some drops of pus, along with serosanguinous synovial fluid. After culturing the aspirated fluid revealed *Salmonella enteritidis*.

Antibiotic treatment was postponed until after intra-operative cultures could be taken, as the patient was not septic.

Six days after admission the patient underwent a one-stage revision. The decision to proceed with a one-stage revision rather than performing a DAIR procedure, was made intra-operatively, when osteolytic lesions were found around the femoral stem. A Trident cup and Omnifit stem (Omnifit system, Stryker Orthopaedics, Mahwah, New Jersey, United States) were inserted. Ciprofloxacin was started at 400 mg intravenously three times daily.

After the operation, CRP declined to 49 mg/L (from 245 mg/L at the day of operation) and the incision showed no redness or wound drainage. All 5 cultures obtained intra-operatively showed *Salmonella enteritidis*. The patient was discharged with a regimen of oral ciprofloxacin (750 mg twice a day) after having received ciprofloxacin intravenously for 8 d.

At follow up, two weeks after discontinuing the antibiotic treatment (3 mo regime in total) and a total of 3 mo after discharge, the patient had no infectious signs or symptoms. Blood results showed a CRP of 5 mg/L, and an ESR of 9 mm/h. At 6 mo follow up the clinical and radiological findings were normal.

## DISCUSSION

PJIs are a severe complication seen in 1%-2% of cases after arthroplasty, causing additional costs and morbidity, including serious impairment in quality of life for the patient<sup>[7]</sup>. PJI due to *Salmonella* is especially uncommon.

Although most patients having a *Salmonella* infection are suffering from gastro-intestinal complaints, in the

presented cases no overt gastro-intestinal symptoms were present (one patient presented only with mild nausea), indicating that PJI by *Salmonella* can occur without general gastro-intestinal complaints as has been previously stated<sup>[12]</sup>.

Even though our cases presented within the same month, the course of infection was different. In the first case, symptoms occurred only 2 wk after initial THA, classifying this as an early infection<sup>[14,15]</sup> suggesting intra-operative contamination, although *Salmonella* usually spreads *via* the hematogenous route<sup>[16]</sup>. Another possibility is a carrier state of *Salmonella* species, however, we did not take fecal cultures to rule this out. Hematogenous spread in the early postoperative phase, although unlikely, is of course also possible.

The second PJI would be classified as a late infection<sup>[14,15]</sup> occurring 13 years after initial surgery.

When comparing this with other case-reports, there seems to be no outspoken trend in time since THA before infection: out of the 20 cases of *Salmonella* PJI in THA, 9 were late (> 24 mo)<sup>[11,14,17-22]</sup>, 5 were delayed (3-24 mo)<sup>[23-26]</sup> and 5 were early infections (< 3 mo)<sup>[10,15,17,27]</sup>. In one case time until infection was not specified<sup>[28]</sup>.

In bone infections the most encountered serotypes of *Salmonella* are *S. typhimurium* (group D) and *S. enteritidis* (group B)<sup>[15]</sup>. In the first case PJI was caused by group E *Salmonella*, which has not been reported before. The other patient's culture turned out to be the more common *Salmonella enteritidis*, reported previously in 5 PJIs of the hip<sup>[8,11,20,23,28]</sup> and in 6 PJIs of the knee<sup>[8,10,23,29-31]</sup>.

For both our patients, the original treatment plan was to perform a DAIR procedure. In the first patient however, DAIR treatment failed, and a one-stage revision was performed.

During surgery in the second patient we proceeded with a one-stage revision rather than a DAIR procedure because of the encountered osteolysis. Because of good previous experiences by the surgeon, we opted for a one-stage revision rather than a two-stage revision. Only one case treated with a one-stage revision has been described before. In that case it was performed instead of the preferred two-stage procedure, because of the patient's comorbidity<sup>[11]</sup>.

In 2004, Zimmerli *et al*<sup>[15]</sup> already set ground rules for choosing between retention or resection of the prosthesis. This choice is based on duration of symptoms, (absence of) prosthetic loosening, tissue status and bacterial susceptibility.

In a recent systematic review by Leonard *et al*<sup>[32]</sup>, functional outcome and reinfection rates were compared between one- and two-stage revision for PJI of the hip. There seems to be a trend toward better functional outcome in single-stage surgery, whereas reinfection rates turn out to be comparable between the two approaches. Besides this, a two-stage revision is associated with a significantly higher morbidity and mortality, and tissue changes associated with a period without a hip implant can lead to important functional deficits after reimplantation<sup>[32]</sup>.



Furthermore, if the selection criteria, mentioned by Zimmerli *et al.*<sup>[15]</sup> and by multiple other articles as summarized in the infectious diseases society of America (IDSA) guidelines<sup>[14]</sup>, are strictly followed, retention and debridement and one-stage revision have high success rates, with less morbidity, in selected patients.

Nevertheless, despite commonly accepted directives and reported good results of one-stage revision in general PJI, both Tóth *et al.*<sup>[11]</sup> and De la Torre *et al.*<sup>[8]</sup> advocate a two-stage approach in patients with a *Salmonella* PJI.

De la Torre *et al.*<sup>[8]</sup> propagate the aggressive treatment approach, because the virulence of *Salmonella* infections, difficulty in re-revision, and results of debridement procedures (based on a meta-analysis of studies published between 1977 and 1999)<sup>[8,33]</sup>. The virulence of *Salmonella* infections will generally cause a quick onset of symptoms. This means patients will present with symptoms quickly, and treatment can be started early (surgically and medically). If the bacterium has good susceptibility, a high cure rate can be expected, just like the guidelines propagate (Osmon 2013)<sup>[14]</sup>.

In a recent study by Papavasileiou *et al.*<sup>[34]</sup>, the antimicrobial resistance of *Salmonella enteritidis* was compared between the planktonic form and the biofilm form in multiple antibiotics<sup>[34]</sup>. It appeared that the best results were obtained with ciprofloxacin and moxifloxacin<sup>[34]</sup>. None of the previously described case-reports in which ciprofloxacin was used reported recurrence of PJI<sup>[11,23,29,30,35]</sup>. This includes the one case treated with a one-stage revision<sup>[11]</sup>.

So far neither of our patients, both treated with a one-stage approach and ciprofloxacin, show signs of reinfection. However, the first patient had undergone a DAIR procedure prior to, and after the one-stage approach, which might have influenced the outcome in a positive way: the IDSA guidelines describe that the thoroughness of debridement positively affects the success rate of a single stage surgery<sup>[14]</sup>, and in our opinion, this might be true for multiple debridements as well.

In conclusion, good results can be achieved with one-stage revision, taking into consideration the guidelines for selecting the right patients<sup>[14,15]</sup>, in combination with the use of appropriate antibiotics with a good activity against the causative micro-organism. One-stage revision is, in selected cases, a better alternative than the two-stage approach, causing less morbidity, less mortality and a much smaller burden of disease for the patient. In our opinion, *Salmonella* PJI could and should be treated as other bacterial PJIs, depending on the factors mentioned in the guidelines, and therefore one-stage revision could also be performed more often in these particular cases.

## COMMENTS

### Case characteristics

Case 1: A 68-year-old female with a history of severe osteoarthritis of the right hip was readmitted with anemia 5 d after right total hip arthroplasty; Case 2: A 59-year-old male with a history of total hip arthroplasty presented at the emergency department with pain in the right groin.

### Clinical diagnosis

Case 1: Anemia and sudden onset of right flank pain shortly after right total hip arthroplasty; Case 2: Mildly declined function of the hip, painful pressure in the groin, along with fever and nausea.

### Differential diagnosis

Case 1: Post-operative bleeding, periprosthetic joint infection, loosening of the prosthesis, periprosthetic fissure or fracture, total hip arthroplasty (THA) dislocation, intraabdominal pathology; Case 2: Periprosthetic joint infection, loosening of the prosthesis, THA dislocation, heterotopic ossification, hernia inguinalis

### Laboratory diagnosis

Case 1: Hemoglobin 4.1 mmol/L; C-reactive protein (CRP) 334 mg/L; elevated liver enzymes; Case 2: CRP 193 mg/L; erythrocyte sedimentation rate 23 mm/h.

### Imaging diagnosis

Case 1: Computed tomography revealed a retroperitoneal hematoma; Case 2: On X-ray the prosthetic head appeared not to be centered, without signs of loosening of the prosthesis, while an ultrasound of the groin revealed a 5.5 cm × 7.5 cm abscess.

### Pathological diagnosis

Case 1: Intraoperatively taken cultures yielded group E *Salmonella* species; Case 2: Joint aspiration fluid revealed *Salmonella enteritidis*.

### Treatment

Case 1: After one failed debridement, antibiotics and implant retention-procedure, one-stage revision was performed followed by ciprofloxacin; Case 2: Because of encountered osteolysis the patient was treated with a one-stage revision, followed by ciprofloxacin.

### Related reports

There is an ongoing debate whether prosthetic joint infection of the hip is best treated by one- or two-stage revision surgery, but also whether *Salmonella* infections should be treated similarly to periprosthetic joint infections due to other bacteria.

### Experiences and lessons

This case report illustrates that one-stage revision of periprosthetic joint infections of the hip can be a successful treatment even when infection is due to *Salmonella* species.

### Peer review

This is a report of two case with a prosthetic joint infection cause by *Salmonella* treated with one-stage revision. The paper is very well presented with a clear message.

## REFERENCES

- 1 Braden CR. *Salmonella enterica* serotype Enteritidis and eggs: a national epidemic in the United States. *Clin Infect Dis* 2006; **43**: 512-517 [PMID: 16838242 DOI: 10.1086/505973]
- 2 RIVM (Netherlands National Institute for Public Health and the Environment), Available from: URL: <http://www.rivm.nl/Onderwerpen/S/Salmonellose>
- 3 Bouwknegt M, van Pelt W, Havelaar AH. Scoping the impact of changes in population age-structure on the future burden of foodborne disease in the Netherlands, 2020-2060. *Int J Environ Res Public Health* 2013; **10**: 2888-2896 [PMID: 23851976 DOI: 10.3390/ijerph10072888]
- 4 Kurtz S, Ong K, Lau E, Mowat F, Halpern M. Projections of primary and revision hip and knee arthroplasty in the United States from 2005 to 2030. *J Bone Joint Surg Am* 2007; **89**: 780-785 [PMID: 17403800 DOI: 10.2106/JBJS.F.00222]
- 5 Musante DB, Ogden WS. *Salmonella* infection in joint arthroplasty. *Orthopedics* 2004; **27**: 770-772 [PMID: 15315049]
- 6 Del Pozo JL, Patel R. Clinical practice. Infection associated with prosthetic joints. *N Engl J Med* 2009; **361**: 787-794 [PMID: 19692690 DOI: 10.1056/NEJMc0905029]
- 7 Cahill JL, Shadbolt B, Scarvell JM, Smith PN. Quality of life after infection in total joint replacement. *J Orthop Surg (Hong Kong)* 2008; **16**: 58-65 [PMID: 18453662]
- 8 De la Torre B, Tena D, Arias M, Romanillos O. Recurrent prosthetic joint infection due to *Salmonella enteritidis*: case report and literature review. *Eur J Orthop Surg Traumatol* 2012;



- 22 (Suppl 1): S89-S97 [DOI: 10.1007/s00590-012-0955-6]
- 9 **Huang DB**, DuPont HL. Problem pathogens: extra-intestinal complications of *Salmonella enterica* serotype Typhi infection. *Lancet Infect Dis* 2005; **5**: 341-348 [PMID: 15919620 DOI: 10.1016/S1473-3099(05)70138-9]
- 10 **Day LJ**, Qayyum QJ, Kauffman CA. *Salmonella* prosthetic joint septic arthritis. *Clin Microbiol Infect* 2002; **8**: 427-430 [PMID: 12199853]
- 11 **Tóth K**, Janositz G, Kovács G, Sisák K, Rudner E. Successful treatment of late *Salmonella* infections in total hip replacement - report of two cases. *BMC Infect Dis* 2010; **10**: 160 [PMID: 20529326 DOI: 10.1186/1471-2334-10-160]
- 12 **Oe K**, Wada T, Ohno H, Kushida T, Iida H. *Salmonella* septic arthritis following total knee arthroplasty for rheumatoid arthritis in a patient receiving etanercept. *J Orthop Sci* 2011; **16**: 258-262 [PMID: 21301900 DOI: 10.1007/s00776-011-0023-9]
- 13 **Cohen JL**, Bartlett JA, Corey GR. Extra-intestinal manifestations of *salmonella* infections. *Medicine* (Baltimore) 1987; **66**: 349-388 [PMID: 3306260 DOI: 10.1097/00005792-198709000-00003]
- 14 **Osmon DR**, Berbari EF, Berendt AR, Lew D, Zimmerli W, Steckelberg JM, Rao N, Hanssen A, Wilson WR. Executive summary: diagnosis and management of prosthetic joint infection: clinical practice guidelines by the Infectious Diseases Society of America. *Clin Infect Dis* 2013; **56**: 1-10 [PMID: 23230301 DOI: 10.1093/cid/cis966]
- 15 **Zimmerli W**, Trampuz A, Ochsner PE. Prosthetic-joint infections. *N Engl J Med* 2004; **351**: 1645-1654 [PMID: 15483283 DOI: 10.1056/NEJMra040181]
- 16 **Langenskiöld A**, Riska EB. Haematogenous *salmonella* infection around a metal hip endoprosthesis. *Acta Orthop Scand* 1967; **38**: 220-225 [PMID: 6033415 DOI: 10.3109/17453676708989635]
- 17 **Samra Y**, Shaked Y, Maier MK. Nontyphoid salmonellosis in patients with total hip replacement: report of four cases and review of the literature. *Rev Infect Dis* 1986; **8**: 978-983 [PMID: 3541130 DOI: 10.1093/clinids/8.6.978]
- 18 **Sherman JW**, Conte JE. Ceftriaxone treatment of multidrug-resistant *Salmonella* osteomyelitis. *Am J Med* 1987; **83**: 137-138 [PMID: 3605165 DOI: 10.1016/0002-9343(87)90508-0]
- 19 **Widmer AF**, Colombo VE, Gächter A, Thiel G, Zimmerli W. *Salmonella* infection in total hip replacement: tests to predict the outcome of antimicrobial therapy. *Scand J Infect Dis* 1990; **22**: 611-618 [PMID: 2259871 DOI: 10.3109/00365549009027105]
- 20 **Creisson A**, Martinot C, Fuzibet JG, Taillan B, Verdier JM, Dujardin P. *Salmonella enteritidis* infection at the site of an articular prosthesis. *Presse Med* 1991; **20**: 1290 [PMID: 1832770]
- 21 **Tattevin P**, Crémieux AC, Joly-Guillou ML, Carbon C. First case of *Salmonella hirschfeldii* (paratyphi C) infection of a prosthetic hip. *Clin Microbiol Infect* 1998; **4**: 228-230 [PMID: 11864333 DOI: 10.1111/j.1469-0691.1998.tb00676.x]
- 22 **Fu TS**, Ueng SW. Two-staged revision total hip arthroplasty due to *Salmonella* infection: case report. *Chang Gung Med J* 2001; **24**: 202-207 [PMID: 11355089]
- 23 **Arda B**, Sipahi OR, Yamazhan T, Emircan I, Aksu K, Ulusoy S. *Salmonella enteritidis* related prosthetic joint infection. *West Indian Med J* 2006; **55**: 454-455 [PMID: 17691246 DOI: 10.1590/S0043-31442006000600018]
- 24 **Ahlberg A**, Carlsson AS, Lindberg L. Hematogenous infection in total joint replacement. *Clin Orthop Relat Res* 1978; **69**: 69-75 [PMID: 743846]
- 25 **Ortiz-Neu C**, Marr JS, Cherubin CE, Neu HC. Bone and joint infections due to *Salmonella*. *J Infect Dis* 1978; **138**: 820-828 [PMID: 368264 DOI: 10.1093/infdis/138.6.820]
- 26 **Chong PY**, Sporer SM. Case report: *Salmonella* infection following total hip arthroplasty. *Iowa Orthop J* 2005; **25**: 42-43 [PMID: 16089070]
- 27 **Cheng N**, Mulier JC. *Salmonella* osteomyelitis in total hip replacement. A case report of hematogenous infection from gastro-intestinal tract. *Arch Orthop Trauma Surg* 1982; **99**: 281-283 [PMID: 7092526 DOI: 10.1007/BF00381408]
- 28 **Chen CM**, Lu TC, Lo WH, Chiu FY. *Salmonella* infection in total hip replacement--report of successful reimplantation and review of the literature. *Zhonghua Yixue Zazhi* (Taipei) 1999; **62**: 472-476 [PMID: 10418184]
- 29 **Kobayashi H**, Hall GS, Tuohy MJ, Knothe U, Procop GW, Bauer TW. Bilateral periprosthetic joint infection caused by *Salmonella enterica* serotype Enteritidis, and identification of *Salmonella* sp using molecular techniques. *Int J Infect Dis* 2009; **13**: e463-e466 [PMID: 19269872 DOI: 10.1016/j.ijid.2008.12.015]
- 30 **Madan S**, Abbas D, Jowett RL, Mounce K. *Salmonella enteritidis* infection in total knee replacement. *Rheumatology (Oxford)* 2001; **40**: 112-113 [PMID: 11157155 DOI: 10.1093/rheumatology/40.1.112]
- 31 **Miron D**, Zuker M, Lev-El A. [*Salmonella* prosthetic knee septic arthritis successful retention of the prosthesis with prolonged suppressive therapy]. *Harefuah* 2006; **145**: 261-23, 319 [PMID: 16642625]
- 32 **Leonard HA**, Liddle AD, Burke O, Murray DW, Pandit H. Single- or two-stage revision for infected total hip arthroplasty? A systematic review of the literature. *Clin Orthop Relat Res* 2014; **472**: 1036-1042 [PMID: 24057192 DOI: 10.1007/s11999-013-3294-y]
- 33 **Silva M**, Tharani R, Schmalzried TP. Results of direct exchange or debridement of the infected total knee arthroplasty. *Clin Orthop Relat Res* 2002; **(404)**: 125-131 [PMID: 12439250]
- 34 **Papavasileiou K**, Papavasileiou E, Tseleni-Kotsovoli A, Bersimis S, Nicolaou C, Ioannidis A, Chatzipanagiotou S. Comparative antimicrobial susceptibility of biofilm versus planktonic forms of *Salmonella enterica* strains isolated from children with gastroenteritis. *Eur J Clin Microbiol Infect Dis* 2010; **29**: 1401-1405 [PMID: 20640867 DOI: 10.1007/s10096-010-1015-y]
- 35 **Carlile GS**, Elvy J, Toms AD. *Salmonella* infection of a total knee replacement. *Knee* 2010; **17**: 356-358 [PMID: 19897369 DOI: 10.1016/j.knee.2009.10.003]

P- Reviewer: Drosos GI S- Editor: Song XX L- Editor: A  
E- Editor: Wu HL



## Passage of nasogastric tube through tracheo-esophageal fistula into stomach: A rare event

Ravikiran Shankar Kamble, Rahul Kumar Gupta, Abhaya Gupta, Paras Kothari, K Vishesh Dikshit, Krishnakumar Kesan, Kedar Mudkhedkar

Ravikiran Shankar Kamble, Rahul Kumar Gupta, Abhaya Gupta, Paras Kothari, K Vishesh Dikshit, Krishnakumar Kesan, Kedar Mudkhedkar, Department of Pediatric Surgery, Lokamany Tilak Municipal Medical College and Government Hospital, Maharashtra 400022, India

Author contributions: Kamble RS, Gupta R and Gupta A evaluated the patient and performed the surgery and compiled the manuscript; Kothari P guided for surgery and follow up; Dikshit KV and Mudkhedkar K collected data; Kesan K edited the manuscript.

Correspondence to: Dr. Ravikiran Shankar Kamble, Department of Pediatric Surgery, Lokamany Tilak Municipal Medical College and Government Hospital, Sion, Mumbai, Maharashtra 400022, India. [drkambleravi80@gmail.com](mailto:drkambleravi80@gmail.com)

Telephone: +91-22-24042190

Received: February 16, 2014 Revised: May 14, 2014

Accepted: May 28, 2014

Published online: July 16, 2014

### Abstract

Esophageal atresia with tracheo-oesophageal fistula (TEF) occurs in 1 in 3500 live births. Anorectal malformation is found to be associated with 14% of TEF. Esophageal atresia with TEF is a congenital anomaly which classically presents as excessive frothing from the mouth and respiratory distress. Rarely gastric position of the feeding tube in a case of TEF can be obtained delaying the diagnosis of TEF. We had an uncommon situation where a nasogastric tube reached the stomach through the trachea and tracheo-esophageal fistula, leading to misdiagnosis in a case of esophageal atresia with tracheoesophageal fistula. By using a stiff rubber catheter instead of a soft feeding tube for the diagnosis of esophageal atresia and TEF, such situation can be avoided.

© 2014 Baishideng Publishing Group Inc. All rights reserved.

**Key words:** Esophageal atresia; Tracheoesophageal

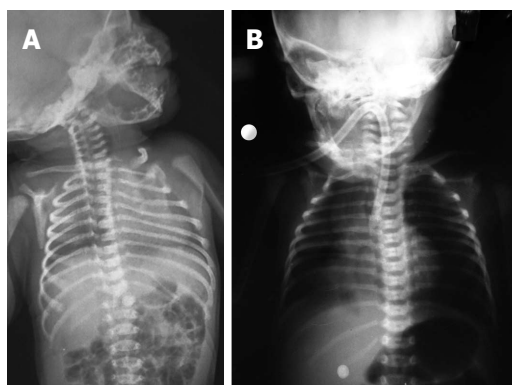
fistula; Nasogastric tube; Red rubber catheter; Misdiagnosis

**Core tip:** Esophageal atresia with tracheoesophageal fistula is congenital anomaly which presents as excessive frothing from mouth and respiratory distress. It can be suspected when a nasogastric tube difficult to insert into stomach or radiographically presence coiled nasogastric tube in pharynx. We had an uncommon situation where a nasogastric tube reached the stomach through the trachea and tracheo-esophageal fistula, leading to misdiagnosis in a case of esophageal atresia with tracheoesophageal fistula. Similar clinical situations can be avoided by using a stiff rubber catheter instead of a soft feeding tube for the diagnosis of esophageal atresia and tracheo-oesophageal fistula.

Kamble RS, Gupta R, Gupta A, Kothari P, Dikshit KV, Kesan K, Mudkhedkar K. Passage of nasogastric tube through tracheo-esophageal fistula into stomach: A rare event. *World J Clin Cases* 2014; 2(7): 309-310 Available from: URL: <http://www.wjgnet.com/2307-8960/full/v2/i7/309.htm> DOI: <http://dx.doi.org/10.12998/wjcc.v2.i7.309>

### INTRODUCTION

Esophageal atresia with tracheoesophageal fistula (TEF) is a congenital anomaly which classically presents as excessive frothing from the mouth and respiratory distress. It is diagnosed by inability to pass a catheter into the stomach which usually gets stuck at 10 to 12 cm from the mouth. We had an uncommon situation where a nasogastric tube reached the stomach through the trachea and tracheo-esophageal fistula, leading to misdiagnosis in a case of esophageal atresia with tracheoesophageal fistula.



**Figure 1 Radiograph.** A: Showing tip of nasogastric tube in stomach; B: Showing red rubber catheter in upper esophageal pouch.

## CASE REPORT

A one day old, full term, male child (2.7 kg) was referred from a peripheral Hospital as a case of imperforate anus with cleft lip and palate. At the peripheral hospital a 7 Fr nasogastric tube was inserted which had bilious aspirate. A chest X-ray showed the nasogastric tube in the stomach (Figure 1A). The baby had excessive oral secretions and bilateral chest crepitations along with cleft lip and palate. Prone crosstable X-ray was suggestive of high anorectal malformation. The patient was taken for diverting colostomy.

During intubation the anesthetist noticed that the nasogastric tube was passing through the trachea. Findings were reconfirmed by laryngoscopy and laryngotracheo-esophageal cleft was ruled out. We tried to pass a number 10 stiff red rubber catheter through esophagus but were unable to pass beyond 10 cm. A diagnosis of esophageal atresia (EA) with tracheoesophageal fistula (TEF) was suspected and X-ray chest was repeated with the red rubber catheter *in situ* which confirmed the diagnosis (Figure 1B). Right posterolateral thoracotomy was done. The patient had tracheoesophageal fistula type III with a Wide fistula, short upper pouch and a long gap. The fistula was ligated and a Left sided cervical oesophagostomy with feeding gastrostomy was done. Transverse colostomy was done for imperforate anus.

The baby was shifted on ventilator and was successfully weaned off at post operative day 5. The baby is now 4 mo old and is doing well on follow up. He is awaiting definitive management for anorectal malformation, esophageal replacement, cleft lip and cleft palate repair.

## DISCUSSION

Esophageal atresia with TEF occurs in 1 in 3500 live births<sup>[1]</sup>. Anorectal malformation is found to be associated with 14% of TEF<sup>[1]</sup>. TEF classically presents as excessive frothing from the mouth and regurgitation, choking and coughing after feed. There is a routine prac-

tice of passing a 5Fr or 6Fr infant feeding tube through the nose in patients of imperforate anus to decompress the obstructed intestinal tract and also to rule out associated esophageal atresia. If the radiograph shows a coiled catheter in the upper esophageal pouch one can suspect esophageal atresia.

Rarely gastric position of the feeding tube in a case of TEF can be obtained delaying the diagnosis of TEF<sup>[2,3]</sup>. In this case we did not suspect an esophageal atresia as the patient came with the IFT in the stomach with bilious aspirate and this had been confirmed radio graphically. The feeding tube could reach the stomach from the upper pouch then into the tracheal route and then through the TEF. A peculiar pathological anatomy and a weak cough reflex made this occurrence possible. Only three such cases have been reported so far in literature<sup>[2,3]</sup>. If an esophageal atresia is suspected on clinical grounds the ideal test would be to pass a stiff red rubber catheter through the mouth and note the resistance. Radiographs should be taken with a red rubber catheter *in situ* which will show the position of the catheter tip. Barium esophagography is not usually advised due to the risk of aspiration pneumonitis. Instead a small amount of air can be used as contrast<sup>[1]</sup>.

In a conclusion, all neonates with excessive frothing and respiratory distress should be evaluated for TEF. Similar clinical situations can be avoided by using a stiff rubber catheter instead of a soft feeding tube for the diagnosis of EA and TEF.

## COMMENTS

### Case characteristics

Authors' came across a uncommon situation, a neonate referred from peripheral hospital with nasogastric tube passed through tracheo-esophageal fistula into the stomach.

### Clinical diagnosis

The baby had excessive oral secretions and bilateral chest crepitations along with cleft lip and palate.

### Differential diagnosis

Prone crosstable X-ray was suggestive of high anorectal malformation.

### Peer review

The case report is interesting and well written, the field of the report is focused on pediatric.

## REFERENCES

- 1 **Carroll MH**, Arnold GC. Congenital anomalies of Esophagus. In: Arnold GC, Editor. *Pediatric Surgery*, 7th Edition. Philadelphia: Elsevier Saunders, 2012: 893-918
- 2 **Hombalkar NN**, Dhanawade S, Hombalkar P, Vaze D. Esophageal atresia with tracheo-esophageal fistula: Accidental transtracheal gastric intubation. *J Indian Assoc Pediatr Surg* 2009; **14**: 224-225 [PMID: 20419027 DOI: 10.4103/0971-9261.59608]
- 3 **Rani RS**, Shenoi A, Nagesh NK, Ramachandra C. Inadvertent passage of infant feeding tube into the stomach through a tracheo-esophageal fistula. *Indian Pediatr* 2000; **37**: 96-97 [PMID: 10745397]

P- Reviewer: Lisotti A S- Editor: Wen LL L- Editor: A  
E- Editor: Wu HL



## Diagnostic pitfall of sebaceous gland metaplasia of the esophagus

King-Wah Chiu, Cheng-Kun Wu, Long-Sheng Lu, Hock-Liew Eng, Shue-Shian Chiou

King-Wah Chiu, Cheng-Kun Wu, Long-Sheng Lu, Shue-Shian Chiou, Department of Internal Medicine, Division of Gastroenterology and Hepatology, Kaohsiung Chang Gung Memorial Hospital, and Chang Gung University, College of Medicine, Kaohsiung 83305, Taiwan

Hock-Liew Eng, Department of Pathology, Kaohsiung Chang Gung Memorial Hospital, and Chang Gung University, College of Medicine, Kaohsiung 83305, Taiwan

Author contributions: Chiu KW designed the report; Chiou SS was attending doctors for the patients; Eng HL performed pathological examinations; Wu CK and Lu LS were performed image diagnosis; Chiu KW and Chiou SS organized the report; and Chiu KW wrote paper.

Correspondence to: King-Wah Chiu, MD, Department of Internal Medicine, Division of Gastroenterology and Hepatology, Kaohsiung Chang Gung Memorial Hospital, Chang Gung University, College of Medicine, 123, Ta-Pei Road, Niao-Sung District, Kaohsiung 83305, Taiwan. [kwchiu@adm.cgmh.org.tw](mailto:kwchiu@adm.cgmh.org.tw)  
Telephone: +886-7-73171238190 Fax: +886-7-7336856

Received: October 12, 2013

Revised: March 6, 2014

Accepted: May 16, 2014

Published online: July 16, 2014

### Abstract

We investigated the sebaceous gland metaplasia (SGM) of the esophagus and clarified the evidence of misdiagnosis and its diagnosis pitfall. Cases of pathologically proven SGM were enrolled in the clinical analysis and reviewed description of endoscope. In the current study, we demonstrated that SGM is very rare esophageal condition with an incidence around 0.00465% and an occurrence rate of 0.41 per year. There were 57.1% of senior endoscopists identified 8 episodes of SGM. In contrast, 7.7% of junior endoscopists identified SGM in only 2 episodes. Moreover, we investigated the difference in endoscopic biopsy attempt rate between the senior and junior endoscopist ( $P = 0.0001$ ). The senior endoscopists had more motivation to look for SGM than did junior endoscopists ( $P = 0.01$ ). We concluded that SGM of the esophagus is rare condition that is easily and not recognized in endoscopy studies omitting

pathological review.

© 2014 Baishideng Publishing Group Inc. All rights reserved.

**Key words:** Esophagus; Sebaceous gland; Metaplasia; Endoscopy; Endoscopist

**Core tip:** Cases of pathologically proven sebaceous gland metaplasia (SGM) of the esophagus were enrolled in the clinical analysis and reviewed the description of endoscope. It is very rare esophageal condition with an incidence around 0.00465% and an occurrence rate of 0.41 per year. There are 57.1% of senior endoscopists identified 8 episodes of SGM and 7.7% of junior endoscopists identified SGM in only 2 episodes. The senior endoscopist had more motivation to look for SGM than did junior endoscopists. We concluded SGM of the esophagus is rare condition that is easily and not recognized in endoscopy studies omitting pathological review.

Chiu KW, Wu CK, Lu LS, Eng HL, Chiou SS. Diagnostic pitfall of sebaceous gland metaplasia of the esophagus. *World J Clin Cases* 2014; 2(7): 311-315 Available from: URL: <http://www.wjgnet.com/2307-8960/full/v2/i7/311.htm> DOI: <http://dx.doi.org/10.12998/wjcc.v2.i7.311>

### INTRODUCTION

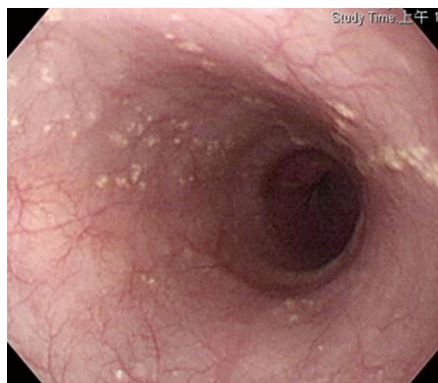
Sebaceous gland metaplasia (SGM) tends to be found incidentally during autopsy or esophageal resection<sup>[1,2]</sup>. From the point of differential diagnosis of esophageal lesions, SGM becomes of scientific interest during endoscopic studies. Endoscopists should take the first look at unusual lesions<sup>[3]</sup>. Although several reports have attempted to determine whether SGM is the result of a metaplastic process or a congenital anomaly, histological examination of endoscopic biopsies is traditionally used to make a pathological diagnosis in clinical practice<sup>[2]</sup>. Biopsied tis-



**Table 1** The clinical profile, pre-biopsy diagnosis, biopsy diagnosis, and pathological review of the 6 cases of sebaceous gland metaplasia

Case	Sex	Age	1 <sup>st</sup> visit	Source	Symptom	1 <sup>st</sup> ESP	1 <sup>st</sup> End. Dx	Biopsy	Review	2 <sup>nd</sup> ESP	2 <sup>nd</sup> End. Dx	Biopsy	Review
1	M	46	1998	Outpatient	Peptic	Senior 1	Xanthoma	SGM	+				
2	M	71	1999	Health screen	Denied	Senior 1	SGM	SGM	+				
3	M	60	2002	Outpatient	Peptic	Senior 1	SGM	SGM	+	Senior 2	Xanthoma	-	-
4	M	65	2002	Health screen	Denied	Senior 2	Papilloma	SGM	-	Senior 4	Papilloma	-	-
5	F	49	2008	Health screen	Denied	Junior 2	Candidiasis	SGM	-	Junior 1	Negative	-	-
6	F	55	2012	Health screen	Denied	Senior 3	Candidiasis	-	-	Senior 3	Xanthoma	SGM	+

ESP: Endoscopist; End. Dx: Endoscopic diagnosis; Review: Pathological review; SGM: Sebaceous gland metaplasia.



**Figure 1** Sebaceous gland metaplasia in the esophagus. Numerous tiny round yellowish lesions clustering distribution at the submucosa of the middle and lower esophagus.

sues can be taken for histological and marker studies of SGM<sup>[4,5]</sup>. Due to the benign nature of SGM-containing endoscopic readings<sup>[6]</sup>, the diagnosis is commonly missed when tissue biopsies are not reviewed. Therefore, the aim of this study was to clarify the incidence of SGM and identify the hallmarks of SGM in endoscopic review.

## CASE REPORT

### Method

From January 1, 1998 to June 30, 2012, a total of 215046 patients underwent endoscopic procedures with 35302 tissue biopsies taken by 33 endoscopists in the endoscopy unit of Kaohsiung Chang Memorial Hospital. The endoscopic procedures included 864 esophagoscopies and 214182 gastroscopies (include 650 nasoendoscopies). Cases of endoscopic ultrasound of the upper gastrointestinal tract, endoscopic retrograde cholangiopancreatography, and double-balloon enteroscopy *via* an oral route were excluded from this study. The cases of pathologically proven SGM were enrolled in the clinical analysis and the endoscopic characteristics were reviewed.

By definition, an endoscopist with more than 20 years of experience was defined as a senior endoscopist, while an endoscopist with less than 20 years of experience was defined as a junior endoscopist. Accordingly, 7 senior and 26 junior endoscopists were identified. The senior endoscopists performed 110022 (51.2%) endoscopic studies and 16012 (14.5%) endoscopic biopsies, and the junior

endoscopists performed 105046 (48.8%) endoscopic studies and 19290 (18.4%) endoscopic biopsies. Histological examinations of the endoscopic biopsies were performed by an experienced pathologist.

Statistical analyses were performed using SPSS software (version 12.0; SPSS, Chicago, IL, United States). Comparisons of the endoscopic biopsy parameters and SGM frequency between the senior and junior endoscopists were performed using the  $\chi^2$  test and Fisher's exact test. *P* values less than 0.05 were considered statistically significant.

### Results

Among the 215046 endoscopic studies performed during the study period, there were 6 cases of pathologically documented SGM in 10 endoscopic studies (Table 1). The incidence and occurrence rates were 0.00465% was 0.41 per year, respectively. The male to female ratio was 3:1, and the mean age was 57.6 years (range 46-71 years). Four of the 6 cases with SGM came from a health screening center, and the other 2 came from outpatient clinics. All of the cases had numerous tiny yellowish lesions with histopathological examination identified heterotopic sebaceous gland located in the middle-lower esophagus (Figure 1).

The primary endoscopic impression was xanthoma (by senior 1, 2 and 3) in 3 cases, candidiasis (by junior 2 and senior 3) in 2 cases, papilloma (by senior 2 and senior 4) in 2 cases, and a negative description (by junior 1) in 1 case (Table 1). No cases of SGM were recognized by the senior endoscopists 1, 2, 3 and 4 or junior endoscopists 1 and 2 in the primary endoscopic study, and no cases (0/3) of SGM were recognized by senior endoscopists 2 or 4 or junior endoscopist 1 in the secondary endoscopic impression without tissue pathology review (Table 1). The rate improved after pathological review, there was a 100% (2/2) positive diagnosis experienced in the case 2 and case 3 in the primary endoscopic impression by senior 1, and only 3.03% (1/33) of our endoscopists did it.

Among the 6 pathologically confirmed cases of SGM, 5 were diagnosed in the first endoscopic study by tissue biopsy, while the sixth case was diagnosed in the second endoscopic study by tissue biopsy (Table 1). Among the 7 senior endoscopists who performed 110022 (51.2%) endoscopies, 16012 (14.5%) endoscopic biopsies were performed, an average of 2287 biopsies per senior en-

**Table 2** Rates of identification of sebaceous gland metaplasia by the senior and junior endoscopists

ESP (n)	End. study	End. biopsy (%)	End. biopsy/ESP	No. of ESP identifying SGM (%)	Identification episodes
Senior (7)	110022	16012 (14.5) <sup>1</sup>	2287.4	4 (57.1) <sup>2</sup>	8 <sup>3</sup>
Junior (26)	105024	19290 (18.4) <sup>1</sup>	741.9	2 (7.7) <sup>2</sup>	2 <sup>4</sup>
Total (33)	215046	35302 (16.4)	1069.8	6 (18.2)	10

<sup>1</sup>P = 0.0001 using the  $\chi^2$  test; <sup>2</sup>P = 0.01 using Fisher's exact test; <sup>3</sup>senior 1 in 3, senior 2 in 2, senior 3 in 2, and senior 4 in 1 meet; <sup>4</sup>junior 1 in 1 and junior 2 in 1 case of identified SG. SGM: Sebaceous gland metaplasia; ESP: Endoscopist; End: Endoscopic.

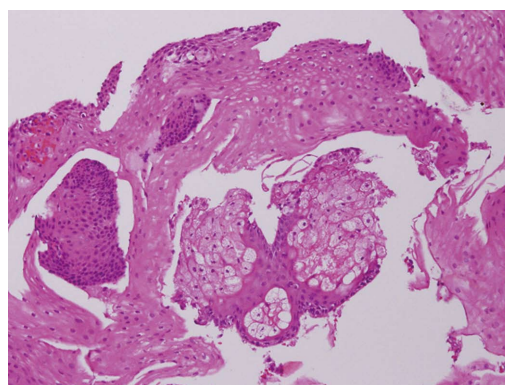
doscopist and 4 (57.1%) cases diagnosed of SGM in 8 episodes by senior 1 of 3 times, senior 2 of 2 times, senior 3 of 2 times, and senior 4 in 1 time. In contrast, of the 105024 (48.8%) endoscopies performed by 26 junior endoscopists, 19290 (18.4%) endoscopic biopsies were performed, an average of 741.9 biopsies per junior endoscopists, and identified-2 (7.7%) cases SGM in only 2 episodes by junior 1 and junior 2 respectively. Significantly fewer endoscopic biopsies were performed by the senior endoscopists than by the junior endoscopists ( $P = 0.0001$ ), and significantly more cases of HSGM were identified by senior endoscopists than by junior endoscopists ( $P = 0.01$ ) (Table 2).

Endoscopic biopsy showed multiple light yellow plaques 2-5 mm in diameter with clustering distribution that embedded the surface of the esophagus (Figure 1). In 100% (6/6) of cases, sebaceous glands were located at the lower to middle esophagus. Pathological analysis revealed stratified squamous epithelium with lobules of sebaceous glands abutting the lower epithelium. No associated polymorphic nuclear or cellular infiltration was noted (Figure 2).

## DISCUSSION

The present study demonstrated that SGM is a very rare esophageal condition with an incidence around 0.00465% and an occurrence rate of 0.41 per year. There was no doubt of the pathological diagnosis of SGM<sup>[7,8]</sup>, but endoscopic biopsy should make an important impact on the incidence of SGM. In the real world, endoscopic biopsy is performed by endoscopists for 2 possible reasons: a suspected malignant lesion, or a lesion that is difficult to identify under endoscopic study. Such lesions look benign, especially in narrow band imaging<sup>[9,10]</sup>, we believed that endoscopists does not perform biopsy, if they macroscopically diagnosed the lesion for benign. It may be a reason for the incidence of SGM is likely underestimated.

In the current study, senior endoscopist 1 encountered SGM 3 times (cases 1, 2 and 3) in 1998, 1999 and 2002. After the endoscopic biopsy and pathological review in the first case, a 100% (2/2) endoscopic diagnosis rate of senior endoscopist 1 was noted in cases 2 and 3. In contrast, senior endoscopist 2 missed an endoscopic diagnosis in a xanthoma due to a lack of pathological re-

**Figure 2** Esophageal squamous epithelial with sebaceous glands (HE stained  $\times 400$ ).

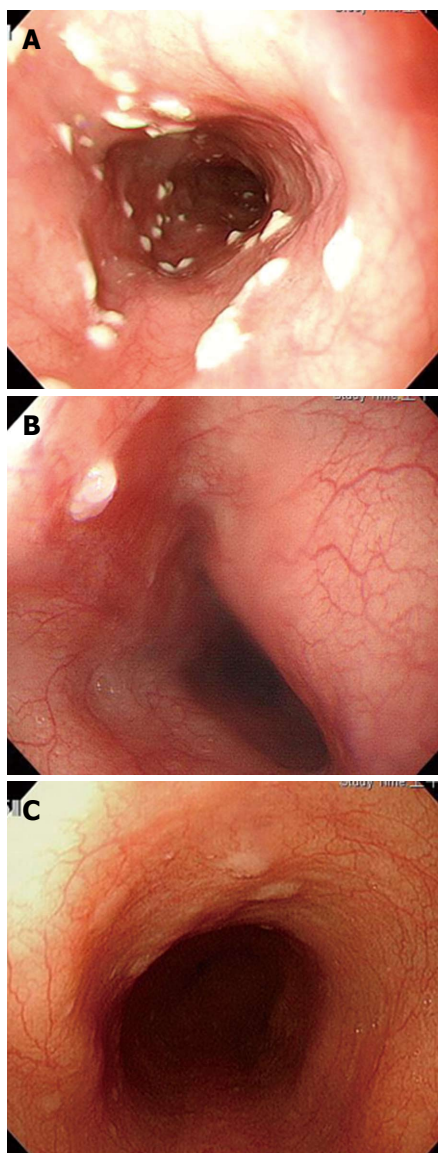
view despite the first case being proven. Senior endoscopist 2 also missed an endoscopic diagnosis in a papilloma that was biopsied but not pathologically reviewed.

In the meantime, senior endoscopist 4 also missed an endoscopic diagnosis in a papilloma in case 4 due to lack of pathological review. In SGM cases 5 and 6, the primary endoscopic diagnosis of candida esophagitis was made by junior endoscopist 2 and senior endoscopist 3. Junior endoscopist 2 had performed an endoscopic biopsy in case 5, but senior endoscopist 3 did not in case 6.

Due to the lack of a pathological review, junior endoscopist 1 made a negative endoscopic diagnosis in case 5 during a scheduled health screen. In contrast, senior endoscopist 2 also missed the endoscopic diagnosis in SGM case 6 due to the lack of a response to candida infection treatment in the follow-up clinic. Because endoscopic biopsy and pathological review were both performed, 6 cases of SGM were documented in our series.

Our series showed that 66.7% of the cases of SGM came from health screening centers, and for these cases the pathology reports were not returned to the ordering endoscopist. In addition, the interpreting doctor at the health screening center was not the original endoscopist, and the patients did not return to the outpatient clinic due to there being no evidence of malignancy. To overcome the diagnostic underestimation demonstrated here, endoscopists need to actively follow up each pathological report after an endoscopic biopsy, or a computer management system should send the final pathological report to the original endoscopist on a weekly basis. Therefore, the accurate diagnosis of SGM requires both endoscopic biopsy and pathological review<sup>[11]</sup>.

Studies have reported that candida infection (Figure 3A) is the most common endoscopic diagnosis to appear as SGM<sup>[7,8]</sup>. In the present study (Table 1), 10 episodes of SGM were found at a rate of 3 in xanthomas, 2 in candida infections, and 2 in papillomas (Figure 3B). The same situation was the first impression as candida infection of the esophagus but no medication response to it in our case 6<sup>[12]</sup>. SGM case 6 was determined by a subsequent pathological review. For most endoscopists, the first impression would be glycogenic acanthosis (Figure 3C), potentially with minor atypical features. All of the



**Figure 3 Photograph.** A: Candida infection of the esophagus. Multiple small brightly whitish elevated patches at the upper and middle esophagus; B: Papilloma of the esophagus. A single round whitish elevated nodule at the middle esophagus; C: Glycogenic acanthosis of the esophagus. Some small round lucent to lightly whitish nodules at the upper and middle esophagus.

above situations belong to the benign nature of the etiology of SGM, and the symptoms of SGM are not alarming enough to warrant an endoscopic biopsy. Therefore, missing endoscopic diagnosis occurs easily in situations in which both endoscopic biopsy and pathological review are not both performed.

An interesting finding in the current study was the difference in endoscopic biopsy attempts between the senior and junior endoscopists. More cases were examined by the senior endoscopists than by the junior endoscopists (51.2% *vs* 48.8%), in contrast to the endoscopic biopsy rate (14.5% *vs* 18.4%). The large difference in the number of biopsies taken by senior (21.2%) *vs* junior endoscopists (78.8%) might give a false impression in statistical analysis. Senior endoscopists had a 3-fold higher number of endoscopic biopsies compared to the junior

endoscopists (2287.4 *vs* 741.9 endoscopic biopsies per endoscopist). Senior endoscopists had more motivation to look for SGM than the junior endoscopists. Anyway, SGM is a very rare endoscopically indistinct benign finding in the esophagus. The histogenesis of ectopic sebaceous glands in the esophagus is unknown; whilst it could be a congenital abnormality, a majority of authors defined it like an acquired metaplastic process. No malignant transformation has yet been reported. From the pathologists' point of view an inflammatory or neoplastic process has to be excluded as the cause of the non-distinctive endoscopic findings<sup>[8,13]</sup>. In our recent study found that senior endoscopists are more interested than junior endoscopist, in look for the esophagus SGM cells as well as the attempt for endoscopic biopsy<sup>[14]</sup>.

In conclusion, asymptomatic esophageal SGM is a rare condition that occurs in old age (> 50 years) and is male dominant. A differential diagnosis of a benign non-inflammatory nature should be kept in mind in daily practice with endoscopic biopsies and pathological review but may be never seen clinically.

## COMMENTS

### Case characteristics

Sebaceous gland metaplasia of esophagus tends to be found incidentally because of the usually no symptoms.

### Clinical diagnosis

It is hard to make a clinical diagnosis due to the silent disease.

### Differential diagnosis

Endoscopic biopsy with pathological review is very important for the differential diagnosis from the other esophageal pathologies.

### Laboratory diagnosis

Histological examination with HE stained showed characteristic sebaceous differentiation.

### Imaging diagnosis

Endoscopy demonstrated numerous tiny rounded, elevated, white-yellowish lesions distributed at the middle and lower esophagus.

### Pathological diagnosis

Histopathological examination identified numerous sebaceous glands were located in the lamina propria, revealed lobules of cells that showed characteristic sebaceous differentiation.

### Treatment

Because there were no esophageal symptoms or/and eating problems, the patient did not require endoscopic surgery or other treatment.

### Term explanation

A sebaceous cell of presumed ectodermal origin, in the esophageal mucosa, which is of endodermal origin, is of scientific interest. Different theories may explain the existence of this peculiarity by sebaceous gland metaplasia is the most plausible.

### Experiences and lessons

Sebaceous gland metaplasia tends to be found incidentally during autopsy or esophageal resection.

### Peer review

This is a well designed and well written case report which may be interesting for gastroenterologists and other clinicians.

## REFERENCES

- 1 Zak FG, Lawson W. Sebaceous glands in the esophagus. First case observed grossly. *Arch Dermatol* 1976; **112**: 1153-1154 [PMID: 952538 DOI: 10.1001/archderm.1976.01630320059018]
- 2 Nakanishi Y, Ochiai A, Shimoda T, Yamaguchi H, Tachi-



- mori Y, Kato H, Watanabe H, Hirohashi S. Heterotopic sebaceous glands in the esophagus: histopathological and immunohistochemical study of a resected esophagus. *Pathol Int* 1999; **49**: 364-368 [PMID: 10365859 DOI: 10.1046/j.1440-1827.1999.00874.x]
- 3 **Bambirra EA**, de Souza Andrade J, Hooper de Souza LA, Savi A, Ferreira Lima G, Affonso de Oliveira C. Sebaceous glands in the esophagus. *Gastrointest Endosc* 1983; **29**: 251-252 [PMID: 6618133 DOI: 10.1016/S0016-5107(83)72605-2]
- 4 **Nakada T**, Inoue F, Iwasaki M, Nagayama K, Tanaka T. Ectopic sebaceous glands in the esophagus. *Am J Gastroenterol* 1995; **90**: 501-503 [PMID: 7532913]
- 5 **van Esch E**, Brennan S. Sebaceous gland metaplasia in the oesophagus of a cynomolgus monkey (*Macaca fascicularis*). *J Comp Pathol* 2012; **147**: 248-252 [PMID: 22305858 DOI: 10.1016/j.jcpa.2011.11.201]
- 6 **Grube-Pagola P**, Vicuña-González RM, Rivera-Salgado I, Alderete-Vázquez G, Remes-Troche JM, Valencia-Romero AM. [Ectopic sebaceous glands in the esophagus. Report of three cases]. *Gastroenterol Hepatol* 2011; **34**: 75-78 [PMID: 21339017 DOI: 10.1016/j.gastrohep.2010.10.016]
- 7 **Thalheimer U**, Wright JL, Maxwell P, Firth J, Millar A. Sebaceous glands in the esophagus. *Endoscopy* 2008; **40** Suppl 2: E57 [PMID: 18633905 DOI: 10.1055/s-2007-967059]
- 8 **Marín-Serrano E**, Jaquotot-Herranz M, Casanova-Martínez L, Tur-González R, Segura-Cabral JM. Ectopic sebaceous glands in the esophagus. *Rev Esp Enferm Dig* 2010; **102**: 141-142 [PMID: 20361850 DOI: 10.4321/S1130-01082010000200009]
- 9 **Ide E**, Maluf-Filho F, Chaves DM, Matuguma SE, Sakai P. Narrow-band imaging without magnification for detecting early esophageal squamous cell carcinoma. *World J Gastroenterol* 2011; **17**: 4408-4413 [PMID: 22110267 DOI: 10.3748/wjg.v17.i39.4408]
- 10 **Kawai T**, Takagi Y, Yamamoto K, Hayama Y, Fukuzawa M, Yagi K, Fukuzawa M, Kataoka M, Kawakami K, Itoi T, Moriyasu F, Matsubayashi J, Nagao T. Narrow-band imaging on screening of esophageal lesions using an ultrathin transnasal endoscopy. *J Gastroenterol Hepatol* 2012; **27** Suppl 3: 34-39 [PMID: 22486869 DOI: 10.1111/j.1440-1746.2012.07068.x]
- 11 **Fukuchi M**, Tsukagoshi R, Sakurai S, Kiriya S, Horiuchi K, Yuasa K, Suzuki M, Yamauchi H, Tabe Y, Fukasawa T, Naitoh H, Kuwano H. Ectopic Sebaceous Glands in the Esophagus: Endoscopic Findings over Three Years. *Case Rep Gastroenterol* 2012; **6**: 217-222 [PMID: 22701398 DOI: 10.1159/000338651]
- 12 **Hoshika K**, Inoue S, Mizuno M, Iida M, Shimizu M. Endoscopic detection of ectopic multiple minute sebaceous glands in the esophagus. Report of a case and review of the literature. *Dig Dis Sci* 1995; **40**: 287-290 [PMID: 7851191 DOI: 10.1007/BF02065411]
- 13 **Suttorp AC**, Heike M, Fährndrich M, Reis H, Lorenzen J. Talgdrüsenheterotopie im Ösophagus. *Der Pathologe* 2013; **34**: 162-164 [PMID: 23111754 DOI: 10.1007/s00292-012-1714-5]
- 14 **Chiu KW**, Chiu SS. Endoscopic biopsy as a quality assurance for the endoscopic service. *Plos one* 2013; **11**: e78557 [PMID: 24265698 DOI: 10.1371/journal.pone.0078557]

**P- Reviewers:** Alsolaiman M, Bugaj AM, Huerta-Franco MR

**S- Editor:** Wen LL **L- Editor:** A **E- Editor:** Wu HL





# World Journal of *Clinical Cases*

*World J Clin Cases* 2014 August 16; 2(8): 316-401





## Contents

Monthly Volume 2 Number 8 August 16, 2014

- |                             |     |  |
|-----------------------------|-----|--|
| <b>REVIEW</b>               | 316 | Progress in sensorimotor rehabilitative physical therapy programs for stroke patients<br><i>Chen JC, Shaw FZ</i>   |
| <b>MINIREVIEWS</b>          | 327 | Dissociative symptoms and dissociative disorders comorbidity in obsessive compulsive disorder: Symptom screening, diagnostic tools and reflections on treatment<br><i>Belli H</i>      |
|                             | 332 | Metabolic syndrome and childhood trauma: Also comorbidity and complication in mood disorder<br><i>Kesebir S</i>  |
|                             | 338 | Pseudocyesis, delusional pregnancy, and psychosis: The birth of a delusion<br><i>Seeman MV</i>   |
| <b>RETROSPECTIVE STUDY</b>  | 345 | Tree stand falls: A persistent cause of neurological injury in hunting<br><i>Pierre CA, Plog BA, Srinivasan V, Srinivasan K, Petraglia AL, Huang JH</i>                                |
|                             | 351 | Intracerebroventricular opiate infusion for refractory head and facial pain<br><i>Lee DJ, Gurkoff GG, Goodarzi A, Muizelaar JP, Boggan JE, Shahlaie S</i>                              |
| <b>CLINICAL TRIAL STUDY</b> | 357 | Distal biceps tendon rupture reconstruction using muscle-splitting double-incision approach<br><i>Tarallo L, Mugnai R, Zambianchi F, Adani R, Catani F</i>                             |
| <b>OBSERVATIONAL STUDY</b>  | 362 | Dabigatran etixilate and traumatic brain injury: Evolving anticoagulants require evolving care plans<br><i>Pakraftar S, Atencio D, English J, Corcos A, Altschuler EM, Stahlfeld K</i> |
| <b>CASE REPORT</b>          | 367 | Desmoplastic small round cell tumor with atypical immunohistochemical profile and rhabdoid-like differentiation<br><i>Liang L, Tatevian N, Bhattacharjee M, Tsao K, Hicks J</i>        |
|                             | 373 | Resolution of hemolysis from pump thrombus during left ventricular assist device exchange<br><i>Unai S, Hirose H, Entwistle JWC, Samuels LE</i>  |



- 377    Transthoracic echo: A sensitive tool for detecting cardiac extension of renal cell carcinoma?  
*Bejarano M, Cameron YL, Koutlas TC, Movahed A*
- 380    Prucalopride-associated acute tubular necrosis  
*Sivabalasundaram V, Habal F, Cherney D*
- 385    Actinic prurigo of the lip: Two case reports  
*Miranda AMO, Ferrari TM, Werneck JT, Silva Junior A, Cunha KS, Dias EP*
- 391    Appendicitis in double cecal appendix: Case report  
*Alves JR, Maranhão IGO, Oliveira PVV*
- 395    Rare large homozygous *CFTR* gene deletion in an Iranian patient with cystic fibrosis  
*Farjadian S, Moghtaderi M, Zuntini R, Ferrari S*
- 398    Gastric conduit perforation  
*Patil N, Kaushal A, Jain A, Saluja SS, Mishra PK*

**APPENDIX** I-V Instructions to authors**ABOUT COVER**

Editorial Board Member of *World Journal of Clinical Cases*, Karl-Anton Kreuzer, MD, Medizinische Klinik m.S. Hämatologie und Onkologie, Campus Virchow-Klinikum, Universitätsklinikum Charité, Humboldt-Universität zu Berlin, Augustenburger Platz 1, 13353 Berlin, Germany

**AIM AND SCOPE**

*World Journal of Clinical Cases* (*World J Clin Cases*, *WJCC*, online ISSN 2307-8960, DOI: 10.12998) is a peer-reviewed open access academic journal that aims to guide clinical practice and improve diagnostic and therapeutic skills of clinicians.

The primary task of *WJCC* is to rapidly publish high-quality Autobiography, Case Report, Clinical Case Conference (Clinicopathological Conference), Clinical Management, Diagnostic Advances, Editorial, Field of Vision, Frontier, Medical Ethics, Original Articles, Clinical Practice, Meta-Analysis, Minireviews, Review, Therapeutics Advances, and Topic Highlight, in the fields of allergy, anesthesiology, cardiac medicine, clinical genetics, clinical neurology, critical care, dentistry, dermatology, emergency medicine, endocrinology, family medicine, gastroenterology and hepatology, geriatrics and gerontology, hematology, immunology, infectious diseases, internal medicine, obstetrics and gynecology, oncology, ophthalmology, orthopedics, otolaryngology, pathology, pediatrics, peripheral vascular disease, psychiatry, radiology, rehabilitation, respiratory medicine, rheumatology, surgery, toxicology, transplantation, and urology and nephrology.

**INDEXING/ABSTRACTING**

*World Journal of Clinical Cases* is now indexed in PubMed Central, PubMed, Digital Object Identifier.

**FLYLEAF**

## I-V Editorial Board

**EDITORS FOR THIS ISSUE**

Responsible Assistant Editor: *Xiang Li*  
Responsible Electronic Editor: *Ya-Jing Lu*  
Proofing Editor-in-Chief: *Lian-Sheng Ma*

Responsible Science Editor: *Ling-Ling Wen*  
Proofing Editorial Office Director: *Xin-Xia Song*

**NAME OF JOURNAL**  
*World Journal of Clinical Cases*

**ISSN**  
ISSN 2307-8960 (online)

**LAUNCH DATE**  
April 16, 2013

**FREQUENCY**  
Monthly

**EDITORS-IN-CHIEF**  
**Giuseppe Di Lorenzo, MD, PhD, Professor**, Genitourinary Cancer Section and Rare-Cancer Center, University Federico II of Napoli, Via Sergio Pansini, 5 Ed. 1, 80131, Naples, Italy

**Jan Jacques Michiels, MD, PhD, Professor**, Primary Care, Medical Diagnostic Center Rijnmond Rotterdam, Bloodcoagulation, Internal and Vascular Medicine, Erasmus University Medical Center, Rotterdam, Goodheart Institute and Foundation, Erasmus Tower, Veenmos 13, 3069 AT, Erasmus City, Rotterdam, The Netherlands

**Sandro Vento, MD**, Department of Internal Medicine, University of Botswana, Private Bag 00713, Gaborone,

Botswana

**Shuhei Yoshida, MD, PhD**, Division of Gastroenterology, Beth Israel Deaconess Medical Center, Dana 509, Harvard Medical School, 330 Brookline Ave, Boston, MA 02215, United States

**EDITORIAL OFFICE**  
Jin-Lei Wang, Director  
Xiu-Xia Song, Vice Director  
*World Journal of Clinical Cases*  
Room 903, Building D, Ocean International Center, No. 62 Dongsihuan Zhonglu, Chaoyang District, Beijing 100025, China  
Telephone: +86-10-85381891  
Fax: +86-10-85381893  
E-mail: [editorialoffice@wjnet.com](mailto:editorialoffice@wjnet.com)  
Help Desk: <http://www.wjnet.com/esp/helpdesk.aspx>  
<http://www.wjnet.com>

**PUBLISHER**  
Baishideng Publishing Group Inc  
8226 Regency Drive,  
Pleasanton, CA 94588, USA  
Telephone: +1-925-223-8242  
Fax: +1-925-223-8243  
E-mail: [bpgoffice@wjnet.com](mailto:bpgoffice@wjnet.com)  
Help Desk: <http://www.wjnet.com/esp/helpdesk.aspx>

<http://www.wjnet.com>

**PUBLICATION DATE**  
August 16, 2014

**COPYRIGHT**  
© 2014 Baishideng Publishing Group Inc. Articles published by this Open Access journal are distributed under the terms of the Creative Commons Attribution Non-commercial License, which permits use, distribution, and reproduction in any medium, provided the original work is properly cited, the use is non commercial and is otherwise in compliance with the license.

**SPECIAL STATEMENT**  
All articles published in journals owned by the Baishideng Publishing Group (BPG) represent the views and opinions of their authors, and not the views, opinions or policies of the BPG, except where otherwise explicitly indicated.

**INSTRUCTIONS TO AUTHORS**  
Full instructions are available online at [http://www.wjnet.com/2307-8960/g\\_info\\_20100722180909.htm](http://www.wjnet.com/2307-8960/g_info_20100722180909.htm)

**ONLINE SUBMISSION**  
<http://www.wjnet.com/esp/>



## Progress in sensorimotor rehabilitative physical therapy programs for stroke patients

Jia-Ching Chen, Fu-Zen Shaw

Jia-Ching Chen, Department of Rehabilitation, Tzu Chi Buddhist General Hospital, Hualien 970, Taiwan

Jia-Ching Chen, Department of Physical Therapy, Tzu Chi University, Hualien 970, Taiwan

Fu-Zen Shaw, Department of Psychology, National Cheng Kung University, Tainan 701, Taiwan

Author contributions: Chen JC and Shaw FZ contributed to this paper.

Supported by The National Science Council of Taiwan, No. NSC100-2410-H-006-025-MY3

Correspondence to: Fu-Zen Shaw, PhD, Department of Psychology, National Cheng Kung University, No. 1 University Road, Tainan 701, Taiwan. [fzshaw@yahoo.com.tw](mailto:fzshaw@yahoo.com.tw)

Telephone: +886-6-2004555 Fax: +886-6-2752029

Received: January 2, 2014 Revised: May 15, 2014

Accepted: July 12, 2014

Published online: August 16, 2014

© 2014 Baishideng Publishing Group Inc. All rights reserved.

**Key words:** Stroke; Rehabilitation; Sensory stimulation; Thermal stimulation

**Core tip:** Rehabilitation strategies, including conventional interventions with an empirical basis and advanced interventions based on scientific evidence, are reviewed. The concept of a training package that is related to the severity of impairment and the phase of recovery from stroke is proposed to maximize the recovery of motor function after a stroke. The training package for therapists provides valuable suggestions for selecting from the available and suitable advanced rehabilitation methods as well as from the conventional rehabilitation methods.

### Abstract

Impaired motor and functional activity following stroke often has negative impacts on the patient, the family and society. The available rehabilitation programs for stroke patients are reviewed. Conventional rehabilitation strategies (Bobath, Brunnstrom, proprioception neuromuscular facilitation, motor relearning and function-based principles) are the mainstream tactics in clinical practices. Numerous advanced strategies for sensory-motor functional enhancement, including electrical stimulation, electromyographic biofeedback, constraint-induced movement therapy, robotics-aided systems, virtual reality, intermittent compression, partial body weight supported treadmill training and thermal stimulation, are being developed and incorporated into conventional rehabilitation programs. The concept of combining valuable rehabilitative procedures into "a training package", based on the patient's functional status during different recovery phases after stroke is proposed. Integrated sensorimotor rehabilitation programs with appropriate temporal arrangements might provide great functional benefits for stroke patients.

Chen JC, Shaw FZ. Progress in sensorimotor rehabilitative physical therapy programs for stroke patients. *World J Clin Cases* 2014; 2(8): 316-326 Available from: URL: <http://www.wjgnet.com/2307-8960/full/v2/i8/316.htm> DOI: <http://dx.doi.org/10.12998/wjcc.v2.i8.316>

### INTRODUCTION

Following stroke, more than half of the patients have moderate to severe deficits at admission, and their functional activities are often confined to the bedside or wheelchair<sup>[1,2]</sup>. The most commonly occurring deficits are hemiparesis, resulting in an immediate impairment to upper limb function<sup>[2-4]</sup>, or the ability to stand, balance and walk<sup>[2,3,5]</sup>. These deficits not only limit the person's activities in the family and participation in society but pose a heavy physical burden on their relatives or caregivers<sup>[6]</sup>. Stroke patients recover their walking function to a certain degree after discharge from hospital. However, 50% or more of stroke patients are still frustrated by mild or severe deficits of their upper limb functions 6 mo post-

stroke<sup>[2-5]</sup>. Thus, facilitating the restoration of upper limb motor function and maximizing walking ability as early as possible after a stroke are generally priorities for stroke patients, their families and clinicians.

In the clinic, numerous rehabilitative approaches have been shown to promote functional motor recovery after stroke<sup>[7-14]</sup>. In general, repetitive sensory stimulation and mass motor or task practice facilitate neuroplasticity and brain reorganization in stroke patients, resulting in enhanced motor and functional recovery after stroke<sup>[13-17]</sup>. In this scenario, physical therapy that emphasizes sensory stimulation has gained increased prominence among modern rehabilitation strategies<sup>[13-16]</sup>. However, there has been no systematic review of sensorimotor rehabilitation programs according to the patient's status during different stroke rehabilitation phases (the acute, subacute and chronic phases). Due to the dynamic and complex process of stroke recovery (the patient's status and recovery phase)<sup>[10,11]</sup> and the methodological heterogeneity in various studies<sup>[7-10]</sup>, it is difficult to draw a conclusion as to which programs are superior to others or which ones could be adopted for the entire rehabilitation process. In this article, we attempt to summarize all of the possible programs and introduce a schematic program that combines valuable treatments<sup>[9,11]</sup> into "a training package" to maximize the functional outcomes of stroke patients.

## CATEGORIZATION OF STROKE REHABILITATION PROGRAMS

Regarding physical therapy for stroke patients, the rehabilitative programs can be categorized into two main groups according to the theoretical backgrounds of the clinical trials<sup>[7-14]</sup>: conventional and advanced rehabilitation programs.

Conventional rehabilitation programs address the effectiveness of treatment approaches based on neurophysiological, motor control and learning, or strengthening and functional principles. These programs are often called traditional physiotherapeutic "schools"<sup>[7-9,13,14]</sup>. The present study considered conventional rehabilitation programs to be the regular or standard therapies applied in clinical stroke rehabilitation. Conventional rehabilitation strategies are mostly based on clinical experiences and observations<sup>[18-24]</sup>. They were developed early and are usually applied for routine rehabilitation in the clinic.

Advanced rehabilitation programs emphasize the effectiveness of specific interventions based on neuroscientific evidence<sup>[7-14]</sup>. Because stroke patients must receive a reasonable level of rehabilitation in the hospital, conventional rehabilitation strategies are generally employed in the clinic. There is concern over incorporating advanced rehabilitation strategies with conventional rehabilitation strategies in the hospital due to ethical issues. In particular, in the case of acute and subacute stroke patients, the assessment for advanced rehabilitation yields two groups: a conventional + advanced rehabilitation group *vs* a conventional rehabilitation group. Only a few

studies in chronic stroke patients have directly compared the advanced treatment with "dose-matched" conventional rehabilitation.

## CONVENTIONAL REHABILITATION STRATEGIES

The conventional rehabilitation strategies for stroke include the Bobath (also called Neurodevelopmental Treatment)<sup>[14,18,19]</sup>, Brunnstrom<sup>[20]</sup>, proprioceptive neuromuscular facilitation (PNF)<sup>[21]</sup>, motor relearning<sup>[22]</sup> and the functional or strengthening<sup>[7-9,13,14,23,24]</sup> approaches. Although these approaches are mostly based on empirical results rather than scientific evidence, they or their concepts are commonly adopted in clinical settings in the standard or routine rehabilitation programs for stroke patients to regain their motor functions<sup>[7-9,11-14]</sup>.

In recent decades, several studies have shown the positive effects of these interventions on the recovery of motor functions after strokes<sup>[23-33]</sup>. Among these approaches, the Bobath treatment is widely used in Western countries<sup>[30-33]</sup>. Abnormal muscle tone and movement patterns, which generally lead to impaired postural control, are deemed the two major problems experienced by people with hemiplegia. Therefore, a major goal of the Bobath treatment<sup>[18,19]</sup> is to normalize the movement pattern and postural control (or tone) by handling the major joints of each body part of the patient, such as the neck, shoulder, hand, hip, knee and ankle. Recently, the Bobath treatment was re-defined as a problem-solving approach for the assessment and treatment of individuals with deficits in function, movement, and postural control caused by a central nervous system lesion. The goals in a given task are successfully met by identifying and analyzing problems in the movement components and the underlying impairments during functional activities and participation<sup>[19]</sup>. Incorporating appropriate inputs (visual, verbal, or tactile) also plays a vital role in Bobath training because the afferent inputs affect the motor performance<sup>[19]</sup>. The Bobath treatment should improve the efficiency of movement and generally facilitate the activities of everyday life.

The Brunnstrom approach<sup>[20]</sup> considers six hierarchical movement developmental stages, from flaccidity to normal movement-pattern control. The Brunnstrom treatment involves a reflex or limb synergistic movement, initially with cutaneous stimulation. Later, the appropriate inhibition of the synergy pattern and facilitation of the anti-synergy pattern are required to attain normal movement control and functional performance. Visual and somatic modalities are considered in the motor training using the Brunnstrom approach, which facilitates volitional movement and motor recovery for patients with moderate to severe strokes.

The PNF approach stresses stimulating proprioceptors in the muscles/joints of the affected limbs following stroke. The PNF procedures are often accompanied by verbal/visual and tactile feedback to facilitate muscle

**Table 1** Summary of conventional rehabilitation therapies with an emphasis on sensory inputs and outcomes

Treatment	Sensory inputs	Rationale	Sensory outcome	Result <sup>1</sup>
Bobath	Visual, verbal and tactile	Neurophysiology concept (emphasis on selective movement and postural control by key points of the body, with problem-solving training)	None	UL (-), LL (-)
Brunnstrom	Visual and cutaneous	Neurophysiology (an ordered, predictable, stepwise progression from initial flaccidity to stereotypical synergy and then to normal patterns of voluntary movements)	None	NA
PNF	Visual, tactile, verbal and proprioceptive	Neurophysiology concept (through the stimulation or relaxation of muscle groups combined with various sensory inputs in response to specific movement patterns to promote functional movement)	None	NA
Motor relearning	Visual, tactile and auditory	Neuropsychology (Active practice of context-specific motor task with well-designed motor and sensory components )	None	NA [UL (-) and LL (-) motor control with 3 RCTs]

<sup>1</sup>Obtained from meta-analyses or systematic reviews. PNF: Proprioceptive neuromuscular facilitation; -: Not better than the control group; LL: Lower limb; UL: Upper limb; NA: Not available; RCT: Randomized clinical trial.

contraction and motor control in terms of many techniques, such as joint approximation, traction, irradiation or overflow. Therapists rebuild the movement and function of the limbs rendered paretic due to strokes by guiding a specific movement pattern (diagonal or spiral direction) for concomitant muscle contractions with reversal, stabilization, repetition or combination techniques. The motor control or movement pattern facilitated by the therapist follows a sequence of static/dynamic and assistive-active-resistant progressions for regaining motor control and enhancing the muscle strength of the paretic limbs of stroke patients. Verbal and vision inputs are also basic facilitative procedures used in this approach<sup>[21]</sup>. The facilitated progression due to the PNF procedures follows a hierarchical process from mobility to stability, then controlled mobility to skillful movement.

The motor relearning technique<sup>[22]</sup> emphasizes the active practice of context-specific motor tasks in a structured environment with appropriate feedback, manual guiding or verbal commands. Through this well-designed learning program, stroke patients progressively learn to perform the task-oriented functional activities well. In general, the motor relearning technique consists of the following four steps: (1) analysis of the task; (2) practicing the missing components of the task; (3) practicing the entire task; and (4) transferring the training to perform the task. This technique requires the patient to first understand the kinematics and kinetics of normal movement and then the patients can use the kinetic knowledge to practice various dynamic characteristics of the movements necessary to complete a task. The motor relearning technique recruits a single or several inputs (visual, verbal, or auditory) within a training program.

The functional and strengthening approaches, which are based on theories regarding motor control and learning, consist of bed mobility, sitting, transfers, sit-to-stand and gait<sup>[7-9,13]</sup>. Clinically, the therapists target the impairments in the neuromuscular or musculoskeletal system following stroke and provide practice or an experience leading to changes in the capability of producing skilled action. To reduce impairments and facilitate functioning,

the therapists encourage the patients to practice purposeful or functional movement and postural adjustment by selective allocation of muscle tension across joint segments<sup>[7-9,13]</sup>.

The aforementioned rehabilitation strategies are often used in a clinical setting for stroke patients, but the scientific evidence regarding these conventional rehabilitation methods remains limited. The functional outcomes of the Bobath and motor relearning approaches<sup>[25-27]</sup> were not significantly different throughout a 4-year follow-up<sup>[27]</sup>, but the motor relearning treatment is seemingly preferred for shortening the length of hospitalization of stroke patients during the acute phase. No significant difference was found in the functional outcomes of stroke patients given the Bobath, PNF, Brunnstrom and/or strengthening treatments<sup>[24,28,29]</sup>. Although the Bobath technique is more popular in Western countries<sup>[30,31]</sup>, recent reviews indicated that the Bobath technique is not superior to the other approaches in general, including the outcomes regarding the sensorimotor control of upper and lower limbs, dexterity, mobility, the activities of daily living or the health-related quality of life<sup>[31-33]</sup>. Interestingly, a mixture of treatments combining different approaches may be more beneficial than receiving no treatment or a placebo control for lower limb functionality and postural control after strokes<sup>[8]</sup>.

Table 1 summarizes the characteristics of the sensory inputs and outcomes, theoretical basis, and the results of the four conventional rehabilitative strategies. Due to the methodological heterogeneity in previous studies and the lack of well-designed larger investigations, the ideal and favorable training strategies among these conventional treatments for stroke rehabilitation are yet to be determined<sup>[19-23]</sup>.

## ADVANCED REHABILITATION STRATEGIES

Numerous advanced and novel rehabilitation treatments have been developed for patients in the acute, subacute or chronic phase of stroke, to facilitate and maximize their functional recovery<sup>[7-14]</sup>. Most of these techniques are

based on neuroscientific evidence rather than pragmatism. For instance, neuroplasticity and brain reorganization in patients with good functional recovery from strokes have been demonstrated using functional brain imaging or other advanced neuro-technologies<sup>[8-11,15,16]</sup>. Compared to conventional rehabilitation treatments, more high-quality clinical trials concerning the advanced rehabilitation strategies have been reported in recent decades. In this study, several advanced rehabilitation techniques and their enhanced results compared with those of conventional rehabilitation treatment are summarized below.

## ELECTRICAL STIMULATION

Electrical stimulation (ES) is a technique that was developed early and is widely applied to stroke rehabilitation as an adjunctive treatment<sup>[7-10,17,34-44]</sup>. Many aspects of ES, including transcutaneous electrical nerve stimulation (TENS)<sup>[34-38]</sup>, functional electrical stimulation (FES) or neuromuscular electrical stimulation (NMES)<sup>[14-17,34,37-40,44]</sup>, and electromyographic (EMG) biofeedback<sup>[41-43]</sup>, have been used for different clinical purposes. TENS is generally applied for sensory stimulation (sensory threshold) or for selective muscle contraction (motor threshold) based on the patient's status<sup>[35-38]</sup>. In contrast, the intensities of the other three modalities are largely above the motor threshold<sup>[34,37-44]</sup>. ES primarily stimulates cutaneous receptors and proprioceptors and/or activates muscle contractions and joint movements, which can increase the cortical excitability of the somatosensory and/or motor areas. Long-lasting cortical plasticity occurs, accompanied by motor recovery, in stroke patients treated by ES<sup>[13-17,36]</sup>. ES is popularly used as an adjunct in clinical rehabilitations and has a positive effect on the range of motion, motor control, and muscle strength of the affected limbs and the gait speed of stroke patients<sup>[13-16,34-43]</sup>. The ES intensity with sensory threshold shows effects on motor outcomes<sup>[16,37]</sup>. In particular, ES combined with active training significantly improved the performance of both sensory and motor functions<sup>[34,36]</sup>. In addition, ES may also be beneficial in preventing secondary complications of stroke<sup>[39]</sup>, such as shoulder pain, subluxation, spasticity and upper limb contracture.

The EMG biofeedback technique, another type of ES involving minimally active muscle contraction at the targeted joint, is also beneficial for the control of motor function or the muscle strength of the upper limb following stroke<sup>[41-43]</sup>. However, the EMG-triggered feedback causes little improvement in upper limb functionality<sup>[43]</sup>. The effect of the NMES with three periods of stimulation on the upper extremities of 66 stroke survivors with severe motor deficits was investigated<sup>[44]</sup>. However, the optimal effective parameters of ES are inconclusive<sup>[36,37]</sup>. The ES treatments used in all of the previous studies have been added to conventional rehabilitation programs to enhance motor-function recovery after a stroke<sup>[34-38,40-44]</sup>.

## ROBOTIC-AIDED SYSTEMS

The most advantageous feature of robotic-aided system is that it reduces the physical effort of handling patients

using computer-assisted devices. Because the system can automatically set the duration and intensity of the paretic limb movement using either passive or active assistance, robotic-aided therapy allows patients to train independently with no therapist or with a supervising therapist<sup>[45,46]</sup>. The device may provide different optimized movement patterns to help moderate to severe stroke patients regain their motor functions. However, a robotic-aided system requires that the distal part of the limb (hand or foot) be fixed on the handle bar or footplate of the device during training.

At least five types of robotic-aided systems have been developed for upper limb rehabilitation after a stroke, including the MIT-MANUS, the InMotion shoulder-elbow robot, the ARM Guide, the mirror-image motion enabler, and the bi-manu-track<sup>[45-50]</sup>. Generally, the exercise protocols of a robotic therapy system for upper limb rehabilitation after a stroke focus on shoulder and elbow movement patterns and fixing the hand (or fingers) in the robotic handle bar<sup>[44-48]</sup>. The system guides a patient's paretic hand on a support board in front of the patient and tracks the movement of the robotic handle to the target on the computer screen to attain a goal-directed movement through simultaneous visual, auditory, and proprioceptive feedback. Robotic-aided therapy has demonstrated advantages for motor recovery but did not affect the daily functions of stroke patients<sup>[46]</sup>. However, when directly compared with matched intensive conventional rehabilitative techniques, the robot-assisted therapy showed no additional benefit for moderate to severe arm impairment in subacute stroke patients<sup>[47]</sup>.

The Lokomat and Gait Trainer were recently developed as robotic-gait machines for lower limb rehabilitation following stroke and are intended to relieve the strenuous efforts of the therapists<sup>[51-53]</sup>. Although their effects were not significantly different compared with those of a similar dosage of treadmill training<sup>[51]</sup> or conventional therapy<sup>[52]</sup>, using the robotic-gait machine is a feasible treatment for lower limb and gait rehabilitation<sup>[51-53]</sup>. Robotic-gait therapy combined with conventional therapy is more effective for gait performance than conventional therapy alone in patients with subacute stroke who have greater motor impairment<sup>[53]</sup>. A similar phenomenon regarding better improvement has been reported for using robotic-gait therapy combined with FES treatment<sup>[54]</sup>.

The use of a robotic-aided system for stroke rehabilitation is rapidly growing. Recently, robotic-aided therapy combined with individual arm therapy (IAT) using a motor relearning approach was as effective as double sessions of IAT in terms of the restoration of upper limb motor functions<sup>[47]</sup>. Robot-assisted therapy during the training phase is more convenient than conventional rehabilitation therapy. However, the cost of the devices is still prohibitive for the average clinic<sup>[52]</sup>.

## PARTIAL BODY WEIGHT SUPPORTED TREADMILL TRAINING

Partial body weight supported treadmill training (PBWSTT)



involves using a treadmill with body-weight support provided by a harness that is connected to an overhead support system, with coincidental proprioceptive stimulation and visual inflow during stepping. PBWSTT is a method used to treat walking impairments post-stroke. PBWSTT has been used for more than 20 years and is beneficial for the walking function of stroke patients<sup>[55-60]</sup>. Initially, the stroke subjects in most of the previous PBWSTT studies were independent or partially independent walkers and many of the studies were conducted using chronic stroke patients<sup>[55-57]</sup>. These studies reported a good outcome after the application of the PBWSTT. In contrast, the outcomes of early severe stroke patients or even patients after a 6-mo follow-up compared with those given conventional rehabilitation training are controversial<sup>[57,58]</sup>. In a large long-term follow-up study, the effects of PBWSTT were not superior to progressive exercise at home that was managed by a physical therapist<sup>[59]</sup>. The use of PBWSTT for walking rehabilitation of stroke patients slightly improved the walking velocity and walking endurance but not significantly compared with the effects of conventional rehabilitation<sup>[60]</sup>. Moreover, two (or even three) therapists and a strenuous effort are generally required during PBWSTT therapy. Thus, these factors could limit clinical therapists from initiating walking training on the treadmill to moderate to severe stroke patients in the acute phase.

## VIRTUAL REALITY

Computerized virtual reality (VR), a type of human-computer interface technology, allows patients to interact with a multisensory simulated environment and to receive “real-time” feedback on their performance<sup>[61,62]</sup>. Visual and auditory feedback is crucial for instantaneous reactions to stimulation from the environment or the exercises. The feedback training incorporated with conventional rehabilitation treatment led to significant improvement of the upper arm functions of stroke patients<sup>[61,62]</sup>.

VR applications can range from nonimmersive to fully immersive. Recently, a variety of nonimmersive video game systems developed by the entertainment industry have become available for home use. The home-based VR system is inexpensive and more accessible to clinicians and individuals. Among patients with acute strokes who were receiving conventional rehabilitation, the group receiving VR therapy using Wii games demonstrated better recovery of motor function than the recreational group<sup>[63]</sup>. Furthermore, VR therapy in conjunction with PBWSTT treatment is feasible and effective in improving patients’ walking and balancing abilities post-stroke<sup>[64]</sup>.

Although VR can enhance patients’ motivation and compliance regarding rehabilitation and reduce their perception of exertion during activities, it is unable to replace actual sensory experiences, such as manipulating objects during normal daily activities. Sometimes, the VR system may cause symptoms of motion sickness, such as nausea, disorientation, dizziness, and headache, in a few patients during training<sup>[61]</sup>. A recent review<sup>[62]</sup> summarized

the results of five randomized clinical trials (RCTs) and seven observational studies, concluding that large multicenter, well-designed randomized trials of VR therapy are required. However, the subjects enrolled in most VR studies have a moderate to mild status, which limits the apparatus to a selected group of stroke patients. The cost and complexity of VR devices and the supporting software may not be acceptable for all clinical centers.

## INTERMITTENT COMPRESSION

The intermittent compression technique is a neurophysiological treatment. This treatment involves the stimulation of cutaneous and proprioceptive receptors by repeated movements. Previous randomized control trials have shown its beneficial effects on the sensory and motor functions of stroke patients in the acute<sup>[65]</sup> or chronic<sup>[66]</sup> phase. A significant enhancement was observed in subjects even at the 5-year follow-up<sup>[67]</sup>. However, heretofore, no further investigations have been conducted.

## CONSTRAINT-INDUCED MOVEMENT THERAPY

Constraint-induced movement therapy (CIMT) is a revolutionary rehabilitation technique based on the “learned non-use” theory<sup>[68-73]</sup>. The concept of CIMT involves constraining the movements of the non-affected arm with a sling or mitten and forcing the paretic hand to practice using a task-orientated approach for most of the waking hours. Highly intensive and mass-repetitive practice using the affected arm is the major requirement for at least 2 wk of training. Two mechanisms underlying CIMT were proposed<sup>[71,73]</sup>: the “learned non-use” of the affected limb, which is often behaviorally reinforced, is reversed and the contralateral cortical area responsible for the movement of the affected limb is expanded due to repetitive forced use<sup>[69]</sup>. Although CIMT therapy has been proven to have a significant effect on the upper limb mobility following strokes<sup>[68-73]</sup>, a minimal voluntary movement (wrist extension of at least 20 degrees and finger flexion of 10 degrees) at the beginning of treatment and during long-duration daily treatment is required for the application of this therapy. Thus, it is uncertain whether the CIMT approach is appropriate for patients with flaccidity or little volitional movement of their upper limbs during either the early or chronic phase of stroke and those with insufficient tolerance of the method. In the case of mild motor function in chronic stroke patients<sup>[71,73]</sup>, CIMT therapy could act as a routine rehabilitation technique.

## THERMAL STIMULATION

Thermal stimulation (TS) was first developed using alternative hot and cold stimulation. TS combined with conventional rehabilitation methods has been demonstrated to facilitate upper-limb motor function in acute stroke patients<sup>[74]</sup>. TS causes greater activation of the brain areas

**Table 2** Comparison of the characteristics of sensory stimulation modalities and the rationales for recent advanced rehabilitation strategies and their outcomes

Treatment	Sensory modality	Rationale	Sensory outcome	Result <sup>1</sup>
Electrical stimulation	Proprioceptive and tactile	Neurophysiology/neuropsychology	Yes (+)	UL (+) for motor control, LL (+) for gait ability
Robotic therapy	Visual, auditory and proprioceptive	Neurophysiology/neuropsychology	None	UL (+) for motor control
Virtual reality	Visual and auditory	Neuropsychology	None	NA [UL (+/-) motor control with RCTs]
Intermittent compression	Tactile and proprioceptive	Neurophysiology	Yes (+)	NA [UL (+) motor control with RCTs]
CIMT	Visual and verbal	Neuropsychology	None	UL (+)
PBWSTT	Visual and proprioceptive	Neurophysiology/neuropsychology	None	LL (+) motor and gait function
Thermal stimulation	Hot and cold agent	Neurophysiology/neuropsychology	Yes (+)	NA [UL/LE (+) motor control with 5 RCTs]

<sup>1</sup>Obtained from meta-analyses or systematic reviews. CIMT: Constraint-induced movement therapy; PBWSTT: Partial body weight-supported treadmill training; +: Positive effect; -: No better than the control group; LL: Lower limb; UL: Upper limb; NA: Not available; RCT: Randomized clinical trial.

involved in tactile or mechanical stimulation, as shown in functional brain imaging studies of healthy subjects<sup>[75,76]</sup>. In RCTs, TS significantly improved several aspects of the upper- and lower-limb outcomes of acute and subacute stroke patients<sup>[74,77-80]</sup> when combined with standard rehabilitation therapy. Comparable enhancement was also observed and maintained in the lower-limb outcomes at the 3-mo follow-up but disappeared at the 6-mo follow-up<sup>[79]</sup>. The use of TS in rehabilitation not only provides sensory stimulation but also deploys the forced-use strategy to provoke volitional/reflexive motor activity. Neural plasticity may be a reason for the effect of TS in stroke patients. TS can be a low-cost, practicable intervention using home-made materials, such as a water pack. Thus, TS can easily be established as a generally popular home-care therapy. Table 2 summarizes the characteristics of the stimulation modalities used in recent rehabilitation programs.

## A “TRAINING PACKAGE” CONCEPT FOR REAHABILITATION

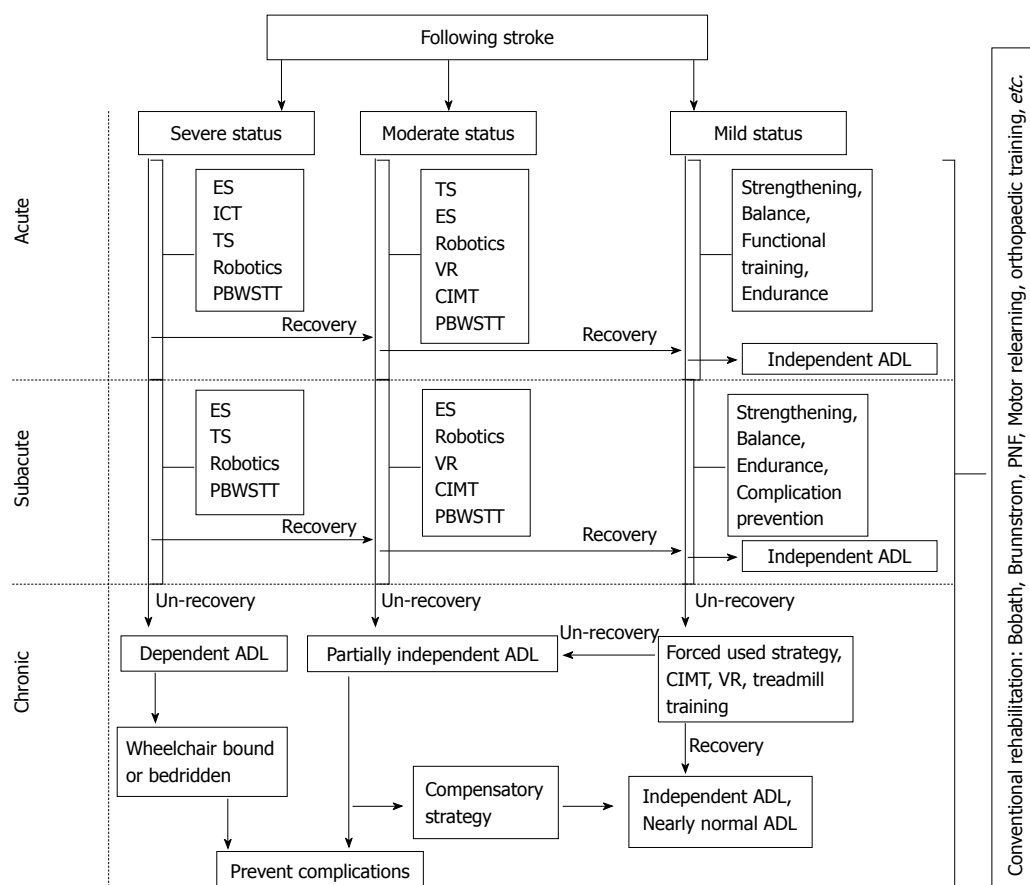
Both conventional rehabilitation strategies and the recently developed advanced treatments mostly emphasized the motor functional outcomes and viewed various types of sensory stimulation (inputs) or feedback as crucial components in stroke rehabilitation<sup>[7,13-17,34-38,41-43,46,63,74]</sup>. A large number of robust large-scale studies of evidence-based treatments for stroke rehabilitation have been published in recent decades<sup>[7-11]</sup>. These studies provide evidence that advanced rehabilitation methods significantly enhance functional outcomes during particular phases of recovery from stroke. In addition to the significance of the advanced rehabilitation therapies, knowing the ideal and most powerful training strategies for recovery during the acute, subacute to chronic phases is very helpful to stroke patients and therapists. Before we describe the concept of an ideal training program (a training package), several perspectives need to be considered.

First, no clear evidence indicates that the recently developed rehabilitation therapy can replace any of the treatments based on physiotherapeutic “schools” that are

generally viewed as the standard rehabilitation treatments for stroke. In general, most of the specific rehabilitation strategies have been adopted or added as supplementary methods by therapists to reinforce functional recovery after stroke. The significance of the advanced therapies, such as ES<sup>[37,38,42]</sup>, robotic therapy<sup>[46]</sup>, virtual reality therapy<sup>[62]</sup>, PBWSTT<sup>[59,60]</sup>, and CIMT<sup>[71,73]</sup>, has been derived through meta-analysis of stroke patients in a particular phase. However, no large longitudinal study that integrated these advanced therapies to treat stroke patients throughout the entire rehabilitation process has been conducted.

Second, previous studies focused mostly on comparing the effect of specific treatments within a particular period following stroke, either in the acute/subacute or chronic phase. However, the progress of stroke recovery is dynamic and individualized, dependent on the nature of the injury, the patient's characteristics and other intrinsic or extrinsic factors<sup>[10,11]</sup>. Faced with the dynamic alteration of motor function, there is no evidence to support that any single intervention plays an important role in achieving the maximum benefit throughout an entire rehabilitation process, from acute to subacute to chronic status. Due to the diversity of the advanced treatments and the heterogeneous methodologies applied, previous meta-analyses or systematic review articles generally focused on the effect of a single specific treatment<sup>[9,14,36-38,42,46,60,62,71,73]</sup>. Thus, it is difficult to compare their performance in a time-related progression.

Third, very few studies have systematically evaluated the optimal intensity and/or duration of a specific intervention. Thus, it is unclear what the threshold of an effective “dose” of an intervention might be or how long an effective intervention should be applied. As a result, the intervention may cease before rehabilitation reaches a peak. Lastly, therapy in clinical practice is often provided for only a few weeks, generally 4 to 8 wk<sup>[9,14,31,36-38,42,46,60,62,73]</sup>. A therapy may fail to provide comprehensive progression in the intensity and task complexity because the optimal frequency and duration of treatment sessions are undetermined. Moreover, therapists often use the treatments either single or combined with other treatments in clinical practice according



**Figure 1** Schematic flowchart for selecting from the available rehabilitation strategies for stroke patients with impairments of various severity levels during different stroke phases. Functional recovery from a severe to moderate and mild condition after stroke is indicated by arrows with indications of the progression of recovery and unrecovery. Appropriate advanced rehabilitation technique(s) combined with conventional rehabilitation are selected to maximize the patient's functional recovery according to his/her initial motor function (mild, moderate or severe) in the clinic. ADLs: Activities of daily living; CIMT: Constraint induced movement therapy; ES: Electrical stimulation; PBWSTT: Partial body weight supported treadmill training; PNF: Proprioceptive neuromuscular facilitation; TS: Thermal stimulation.

to the patient's status and progress during the recovery phase. Therefore, customizing the available interventions during different recovery phases after stroke to meet the needs of the patient's current status to optimize the outcomes will be a major challenge for therapists.

A single or two rehabilitation approaches can be easily used in the clinic and home, and these strategies must be based on the individual's progression throughout the rehabilitation period. Combining valuable treatments is believed to be a good tactic for facilitating the restoration of functional mobility. It is generally believed that treatments could be given in a parallel or sequential way depending on the patient's recovery process and her/his functional status. Figure 1 shows a schematic diagram of the available techniques that are suggested for patients with different functional status during the three stroke phases. Based on the available evidence described above, the appropriate advanced intervention combined with a conventional rehabilitation treatment has been summarized for stroke patients with impairments of different severities. Functional progression is indicated by arrows in terms of the outcome, *i.e.*, recovery or unrecovery. The therapist can easily select the appropriate strategies to maximize the functional outcome of stroke patients.

For instance, if a patient shows little or no voluntary movement of the paretic limb (severe status) during the early poststroke stage, rehabilitation through task-oriented training is often difficult to apply<sup>[50-57]</sup>. Most of newly developed therapies, which require a minimal motor ability, cannot be utilized during the early phase of recovery of stroke patients<sup>[40,49-50,53-58]</sup>. ES<sup>[35-37]</sup>, TS<sup>[74,78-79]</sup> and robotics-aided treatments<sup>[44,46,48]</sup> provide significant improvement in several aspects of motor or functional activities, particularly for those in the initial phase of recovery from moderate to severe strokes who show little or no voluntary movement. Thus, these techniques could be chosen to treat or activate motor activity in the paretic limbs. Until the patient's condition has progressed to a moderate or mild status, alternative interventions, such as VR, CIMT or PBWSTT, which combine strengthening and functional training strategies, can improve the outcome. From a practical perspective, the training package schematic shown in Figure 1 provides selective strategies for the initial phase of recovery to the subsequent recovery process for stroke patients with a different severity status. Although the various interventions are categorized according to the severity status, an optimal rehabilitation program (the ideal training package) can be individualized

and needs to be further investigated.

An appropriate protocol for a selected group of patients plays an important role in terms of cost-effectiveness, limiting the period of hospitalization and minimizing the labor of the therapist during the early phase of stroke recovery. For example, in terms of a “training package”, when therapists need to decide the clinical plan for the upper limb rehabilitation of acute stroke patients with a moderate to severe status during the initial stage, the TS technique would be the choice that facilitates active movement cost-effectively as early as possible. When a certain degree of voluntary movement is elicited in the stroke patient, the therapist can apply other suitable techniques, such as CIMT or forced use with a task-oriented approach. Ideally, a protocol combining several rehabilitation strategies at the right time, as “a training package”, could maximize the patient’s progress during recovery. Although we propose a reasonable strategy for planning a rehabilitation roadmap based on the available evidence for a particular status of stroke, the ideal training package for the progression of a stroke patient remains to be determined.

## CONCLUSION

Rehabilitation is a long process for a stroke patient. How to choose the appropriate route(s) in a complex roadmap for stroke patients whose status differs during the phases of their recovery is always a great challenge to the clinician, patient and family. Conventional rehabilitation therapies (including the Bobath, PNF, motor relearning and Brunnstrom techniques, either singly or combined) are the regular or routine treatments applied in stroke rehabilitation units. Several advanced rehabilitation strategies with a strong evidence basis have been developed and are summarized here. According to the patient’s mobility status and recovery phase, the appropriate advanced rehabilitation therapy combined with conventional rehabilitation treatment comprise a training package. This training package may provide suggestion for therapists to maximize the improvement of stroke patients in the right timeframe. To further validate the usefulness of the training package approach, longitudinal or serial studies of the outcomes of selected and combined therapies are important.

## REFERENCES

- 1 Wade DT, Hewer RL. Functional abilities after stroke: measurement, natural history and prognosis. *J Neurol Neurosurg Psychiatry* 1987; **50**: 177-182 [PMID: 3572432]
- 2 Jørgensen HS, Nakayama H, Raaschou HO, Vive-Larsen J, Støier M, Olsen TS. Outcome and time course of recovery in stroke. Part II: Time course of recovery. The Copenhagen Stroke Study. *Arch Phys Med Rehabil* 1995; **76**: 406-412 [PMID: 7741609 DOI: 10.1016/S0003-9993(95)80568-0]
- 3 Wade DT, Skilbeck CE, Hewer RL. Predicting Barthel ADL score at 6 months after an acute stroke. *Arch Phys Med Rehabil* 1983; **64**: 24-28 [PMID: 6849630]
- 4 Nakayama H, Jørgensen HS, Raaschou HO, Olsen TS. Recovery of upper extremity function in stroke patients: the Copenhagen Stroke Study. *Arch Phys Med Rehabil* 1994; **75**: 394-398 [PMID: 8172497 DOI: 10.1016/0003-9993(94)90161-9]
- 5 Jørgensen HS, Nakayama H, Raaschou HO, Olsen TS. Recovery of walking function in stroke patients: the Copenhagen Stroke Study. *Arch Phys Med Rehabil* 1995; **76**: 27-32 [PMID: 7811170 DOI: 10.1016/S0003-9993(95)80038-7]
- 6 Bugge C, Alexander H, Hagen S. Stroke patients’ informal caregivers. Patient, caregiver, and service factors that affect caregiver strain. *Stroke* 1999; **30**: 1517-1523 [PMID: 10436093 DOI: 10.1161/01.STR.30.8.1517]
- 7 Van Peppen RP, Kwakkel G, Wood-Dauphinee S, Hendriks HJ, Van der Wees PJ, Dekker J. The impact of physical therapy on functional outcomes after stroke: what’s the evidence? *Clin Rehabil* 2004; **18**: 833-862 [PMID: 15609840 DOI: 10.1191/0269215504cr843oa]
- 8 Pollock A, Baer G, Langhorne P, Pomeroy V. Physiotherapy treatment approaches for the recovery of postural control and lower limb function following stroke: a systematic review. *Clin Rehabil* 2007; **21**: 395-410 [PMID: 17613560 DOI: 10.1177/0269215507073438]
- 9 Veerbeek JM, van Wegen E, van Peppen R, van der Wees PJ, Hendriks E, Rietberg M, Kwakkel G. What is the evidence for physical therapy poststroke? A systematic review and meta-analysis. *PLoS One* 2014; **9**: e87987 [PMID: 24505342 DOI: 10.1371/journal.pone.0087987]
- 10 Zorowitz R, Brainin M. Advances in brain recovery and rehabilitation 2010. *Stroke* 2011; **42**: 294-297 [PMID: 21233467 DOI: 10.1161/strokeaha.110.605063]
- 11 Dobkin BH. Strategies for stroke rehabilitation. *Lancet Neurol* 2004; **3**: 528-536 [PMID: 15324721 DOI: 10.1016/S1474-4422(04)00851-8]
- 12 Dobkin BH, Dorsch A. New evidence for therapies in stroke rehabilitation. *Curr Atheroscler Rep* 2013; **15**: 331 [PMID: 23591673 DOI: 10.1007/s11883-013-0331-y]
- 13 Jette DU, Latham NK, Smout RJ, Gassaway J, Slavin MD, Horn SD. Physical therapy interventions for patients with stroke in inpatient rehabilitation facilities. *Phys Ther* 2005; **85**: 238-248 [PMID: 15733048]
- 14 Woldag H, Hummelsheim H. Evidence-based physiotherapeutic concepts for improving arm and hand function in stroke patients: a review. *J Neurol* 2002; **249**: 518-528 [PMID: 12021939 DOI: 10.1007/s00415-003-0982-7]
- 15 Sawaki L, Wu CW, Kaelin-Lang A, Cohen LG. Effects of somatosensory stimulation on use-dependent plasticity in chronic stroke. *Stroke* 2006; **37**: 246-247 [PMID: 16322491 DOI: 10.1161/01.STR.0000195130.16843.ac]
- 16 Schaechter JD, van Oers CA, Groisser BN, Salles SS, Vangel MG, Moore CI, Dijkhuizen RM. Increase in sensorimotor cortex response to somatosensory stimulation over subacute poststroke period correlates with motor recovery in hemiparetic patients. *Neurorehabil Neural Repair* 2012; **26**: 325-334 [PMID: 21952198 DOI: 10.1177/1545968311421613]
- 17 Celnik P, Hummel F, Harris-Love M, Wolk R, Cohen LG. Somatosensory stimulation enhances the effects of training functional hand tasks in patients with chronic stroke. *Arch Phys Med Rehabil* 2007; **88**: 1369-1376 [PMID: 17964875 DOI: 10.1016/j.apmr.2007.08.001]
- 18 Bobath B. Adult hemiplegia: evaluation and treatment. 2th ed. London: Heinemann Medical Books, 1990
- 19 International Bobath Instructors Training Association (IBITA). Theoretical assumptions of clinical practice. IBITA annual general meeting, Sept 2006. Available from: URL: <http://www.ibita.org>
- 20 Sawner K, Lavigne J. Brunnstrom’s movement therapy in hemiplegia: a neurophysiological approach. 2th ed. Philadelphia, Pa: Lippincott, 1992
- 21 Knott M, Voss DE. Proprioceptive neuromuscular facilitation. 2th ed. New York: Harper and Row, 1968



- 22 Carr J, Shepherd R. A motor relearning programme for stroke. 2th ed. Oxford: Butterworth-Heinemann, 1987
- 23 Ada L, Dorsch S, Canning CG. Strengthening interventions increase strength and improve activity after stroke: a systematic review. *Aust J Physiother* 2006; **52**: 241-248 [PMID: 17132118]
- 24 Basmajian JV, Gowland CA, Finlayson MA, Hall AL, Swanson LR, Stratford PW, Trotter JE, Brandstater ME. Stroke treatment: comparison of integrated behavioral-physical therapy vs traditional physical therapy programs. *Arch Phys Med Rehabil* 1987; **68**: 267-272 [PMID: 3579530]
- 25 Langhammer B, Stanghelle JK. Bobath or motor relearning programme? A comparison of two different approaches of physiotherapy in stroke rehabilitation: a randomized controlled study. *Clin Rehabil* 2000; **14**: 361-369 [PMID: 10945420 DOI: 10.1191/0269215500cr338oa]
- 26 van Vliet PM, Lincoln NB, Foxall A. Comparison of Bobath based and movement science based treatment for stroke: a randomised controlled trial. *J Neurol Neurosurg Psychiatry* 2005; **76**: 503-508 [PMID: 15774435 DOI: 10.1136/jnnp.2004.040436]
- 27 Langhammer B, Stanghelle JK. Bobath or motor relearning programme? A follow-up one and four years post stroke. *Clin Rehabil* 2003; **17**: 731-734 [PMID: 14606738 DOI: 10.1191/0269215503cr670oa]
- 28 Dickstein R, Hocherman S, Pillar T, Shaham R. Stroke rehabilitation. Three exercise therapy approaches. *Phys Ther* 1986; **66**: 1233-1238 [PMID: 3737695]
- 29 Wagenaar RC, Meijer OG, van Wieringen PC, Kuik DJ, Hazenberg GJ, Lindeboom J, Wichers F, Rijswijk H. The functional recovery of stroke: a comparison between neurodevelopmental treatment and the Brunnstrom method. *Scand J Rehabil Med* 1990; **22**: 1-8 [PMID: 2326602]
- 30 Lennon S, Baxter D, Ashburn A. Physiotherapy based on the Bobath concept in stroke rehabilitation: a survey within the UK. *Disabil Rehabil* 2001; **23**: 254-262 [PMID: 11336098]
- 31 Paci M. Physiotherapy based on the Bobath concept for adults with post-stroke hemiplegia: a review of effectiveness studies. *J Rehabil Med* 2003; **35**: 2-7 [PMID: 12610841 DOI: 10.1080/16501970306106]
- 32 Luke C, Dodd KJ, Brock K. Outcomes of the Bobath concept on upper limb recovery following stroke. *Clin Rehabil* 2004; **18**: 888-898 [PMID: 15609844 DOI: 10.1191/0269215504cr793oa]
- 33 Kollen BJ, Lennon S, Lyons B, Wheatley-Smith L, Scheper M, Buurke JH, Halfens J, Geurts AC, Kwakkel G. The effectiveness of the Bobath concept in stroke rehabilitation: what is the evidence? *Stroke* 2009; **40**: e89-e97 [PMID: 19182079 DOI: 10.1161/strokeaha.108.533828]
- 34 Chae J, Bethoux F, Bohine T, Dobos L, Davis T, Friedl A. Neuromuscular stimulation for upper extremity motor and functional recovery in acute hemiplegia. *Stroke* 1998; **29**: 975-979 [PMID: 9596245 DOI: 10.1161/01.STR.29.5.975]
- 35 Tyson SF, Sadeghi-Demneh E, Nester CJ. The effects of transcutaneous electrical nerve stimulation on strength, proprioception, balance and mobility in people with stroke: a randomized controlled cross-over trial. *Clin Rehabil* 2013; **27**: 785-791 [PMID: 23503739 DOI: 10.1177/0269215513478227]
- 36 Laufer Y, Elboim-Gabyzon M. Does sensory transcutaneous electrical stimulation enhance motor recovery following a stroke? A systematic review. *Neurorehabil Neural Repair* 2011; **25**: 799-809 [PMID: 21746874 DOI: 10.1177/1545968310397205]
- 37 de Kroon JR, Ijzerman MJ, Chae J, Lankhorst GJ, Zilvold G. Relation between stimulation characteristics and clinical outcome in studies using electrical stimulation to improve motor control of the upper extremity in stroke. *J Rehabil Med* 2005; **37**: 65-74 [PMID: 15788340 DOI: 10.1080/16501970410024190]
- 38 Robbins SM, Houghton PE, Woodbury MG, Brown JL. The therapeutic effect of functional and transcutaneous electric stimulation on improving gait speed in stroke patients: a meta-analysis. *Arch Phys Med Rehabil* 2006; **87**: 853-859 [PMID: 16731222 DOI: 10.1016/j.apmr.2006.02.026]
- 39 Chantaine A, Baribeault A, Uebelhart D, Gremion G. Shoulder pain and dysfunction in hemiplegia: effects of functional electrical stimulation. *Arch Phys Med Rehabil* 1999; **80**: 328-331 [PMID: 10084443 DOI: 10.1016/S0003-9993(99)90146-6]
- 40 Yan T, Hui-Chan CW, Li LS. Functional electrical stimulation improves motor recovery of the lower extremity and walking ability of subjects with first acute stroke: a randomized placebo-controlled trial. *Stroke* 2005; **36**: 80-85 [PMID: 15569875 DOI: 10.1161/01.STR.0000149623.24906.63]
- 41 Inglis J, Donald MW, Monga TN, Sproule M, Young MJ. Electromyographic biofeedback and physical therapy of the hemiplegic upper limb. *Arch Phys Med Rehabil* 1984; **65**: 755-759 [PMID: 6391417]
- 42 Bolton DA, Cauraugh JH, Hausenblas HA. Electromyogram-triggered neuromuscular stimulation and stroke motor recovery of arm/hand functions: a meta-analysis. *J Neurol Sci* 2004; **223**: 121-127 [PMID: 15337612 DOI: 10.1016/j.jns.2004.05.005]
- 43 Hemmen B, Seelen HA. Effects of movement imagery and electromyography-triggered feedback on arm hand function in stroke patients in the subacute phase. *Clin Rehabil* 2007; **21**: 587-594 [PMID: 17702700 DOI: 10.1177/0269215507075502]
- 44 Hsu SS, Hu MH, Wang YH, Yip PK, Chiu JW, Hsieh CL. Dose-response relation between neuromuscular electrical stimulation and upper-extremity function in patients with stroke. *Stroke* 2010; **41**: 821-824 [PMID: 20203321 DOI: 10.1161/STROKEAHA.109.574160]
- 45 Volpe BT, Krebs HI, Hogan N, Edelstein OTR L, Diels C, Aisen M. A novel approach to stroke rehabilitation: robot-aided sensorimotor stimulation. *Neurology* 2000; **54**: 1938-1944 [PMID: 10822433 DOI: 10.1212/WNL.54.10.1938]
- 46 Kwakkel G, Kollen BJ, Krebs HI. Effects of robot-assisted therapy on upper limb recovery after stroke: a systematic review. *Neurorehabil Neural Repair* 2008; **22**: 111-121 [PMID: 17876068 DOI: 10.1177/1545968307305457]
- 47 Hesse S, Heß A, Werner C C, Kabbert N, Buschfort R. Effect on arm function and cost of robot-assisted group therapy in subacute patients with stroke and a moderately to severely affected arm: a randomized controlled trial. *Clin Rehabil* 2014; **28**: 637-647 [PMID: 24452706 DOI: 10.1177/0269215513516967]
- 48 Chang JJ, Tung WL, Wu WL, Huang MH, Su FC. Effects of robot-aided bilateral force-induced isokinetic arm training combined with conventional rehabilitation on arm motor function in patients with chronic stroke. *Arch Phys Med Rehabil* 2007; **88**: 1332-1338 [PMID: 17908578 DOI: 10.1016/j.apmr.2007.07.016]
- 49 Masiero S, Celia A, Rosati G, Armani M. Robotic-assisted rehabilitation of the upper limb after acute stroke. *Arch Phys Med Rehabil* 2007; **88**: 142-149 [PMID: 17270510 DOI: 10.1016/j.apmr.2006.10.032]
- 50 Lo AC, Guarino PD, Richards LG, Haselkorn JK, Wittenberg GF, Federman DG, Ringer RJ, Wagner TH, Krebs HI, Volpe BT, Bever CT, Bravata DM, Duncan PW, Corn BH, Maffucci AD, Nadeau SE, Conroy SS, Powell JM, Huang GD, Peduzzi P. Robot-assisted therapy for long-term upper-limb impairment after stroke. *N Engl J Med* 2010; **362**: 1772-1783 [PMID: 20400552 DOI: 10.1056/NEJMoa0911341]
- 51 Werner C, Von Frankenberg S, Treig T, Konrad M, Hesse S. Treadmill training with partial body weight support and an electromechanical gait trainer for restoration of gait in subacute stroke patients: a randomized crossover study. *Stroke* 2002; **33**: 2895-2901 [PMID: 12468788 DOI: 10.1161/01.STR.0000035734.61539.F6]
- 52 Husemann B, Müller F, Krewer C, Heller S, Koenig E. Ef-

- fects of locomotion training with assistance of a robot-driven gait orthosis in hemiparetic patients after stroke: a randomized controlled pilot study. *Stroke* 2007; **38**: 349-354 [PMID: 17204680]
- 53 **Morone G**, Bragoni M, Iosa M, De Angelis D, Venturiero V, Coiro P, Pratesi L, Paolucci S. Who may benefit from robotic-assisted gait training? A randomized clinical trial in patients with subacute stroke. *Neurorehabil Neural Repair* 2011; **25**: 636-644 [PMID: 21444654 DOI: 10.1177/1545968311401034]
  - 54 **Ng ME**, Tong RK, Li LS. A pilot study of randomized clinical controlled trial of gait training in subacute stroke patients with partial body-weight support electromechanical gait trainer and functional electrical stimulation: six-month follow-up. *Stroke* 2008; **39**: 154-160 [PMID: 18006861 DOI: 10.1161/strokeaha.107.495705]
  - 55 **Visintin M**, Barbeau H, Korner-Bitensky N, Mayo NE. A new approach to retrain gait in stroke patients through body weight support and treadmill stimulation. *Stroke* 1998; **29**: 1122-1128 [PMID: 9626282 DOI: 10.1161/01.STR.29.6.1122]
  - 56 **Kosak MC**, Reding MJ. Comparison of partial body weight-supported treadmill gait training versus aggressive bracing assisted walking post stroke. *Neurorehabil Neural Repair* 2000; **14**: 13-19 [PMID: 11228945 DOI: 10.1177/154596830001400102]
  - 57 **Nilsson L**, Carlsson J, Danielsson A, Fugl-Meyer A, Hellström K, Kristensen L, Sjölund B, Sunnerhagen KS, Grimby G. Walking training of patients with hemiparesis at an early stage after stroke: a comparison of walking training on a treadmill with body weight support and walking training on the ground. *Clin Rehabil* 2001; **15**: 515-527 [PMID: 11594641 DOI: 10.1191/026921501680425234]
  - 58 **Franceschini M**, Carda S, Agosti M, Antenucci R, Malgrati D, Cisari C. Walking after stroke: what does treadmill training with body weight support add to overground gait training in patients early after stroke?: a single-blind, randomized, controlled trial. *Stroke* 2009; **40**: 3079-3085 [PMID: 19556526 DOI: 10.1161/strokeaha.109.555540]
  - 59 **Duncan PW**, Sullivan KJ, Behrman AL, Azen SP, Wu SS, Nadeau SE, Dobkin BH, Rose DK, Tilson JK, Cen S, Hayden SK. Body-weight-supported treadmill rehabilitation after stroke. *N Engl J Med* 2011; **364**: 2026-2036 [PMID: 21612471 DOI: 10.1056/NEJMoa1010790]
  - 60 **Mehrholtz J**, Pohl M, Elsner B. Treadmill training and body weight support for walking after stroke. *Cochrane Database Syst Rev* 2014; **1**: CD002840 [PMID: 24458944 DOI: 10.1002/14651858]
  - 61 **Lewis CH**, Griffin MJ. Human factors consideration in clinical applications of virtual reality. *Stud Health Technol Inform* 1997; **44**: 35-56 [PMID: 10175342]
  - 62 **Saposnik G**, Levin M. Virtual reality in stroke rehabilitation: a meta-analysis and implications for clinicians. *Stroke* 2011; **42**: 1380-1386 [PMID: 21474804 DOI: 10.1161/strokeaha.110.605451]
  - 63 **Saposnik G**, Teasell R, Mamdani M, Hall J, McIlroy W, Cheung D, Thorpe KE, Cohen LG, Bayley M. Effectiveness of virtual reality using Wii gaming technology in stroke rehabilitation: a pilot randomized clinical trial and proof of principle. *Stroke* 2010; **41**: 1477-1484 [PMID: 20508185 DOI: 10.1161/strokeaha.110.584979]
  - 64 **Walker ML**, Ringelb SI, Maihafer GC, Walker R, Crouch JR, Van Lunen B, Morrison S. Virtual reality-enhanced partial body weight-supported treadmill training poststroke: feasibility and effectiveness in 6 subjects. *Arch Phys Med Rehabil* 2010; **91**: 115-122 [PMID: 20103405 DOI: 10.1016/j.apmr.2009.09.009]
  - 65 **Feys HM**, De Weerd WJ, Selz BE, Cox Steck GA, Spichiger R, Vereeck LE, Putman KD, Van Hoydonck GA. Effect of a therapeutic intervention for the hemiplegic upper limb in the acute phase after stroke: a single-blind, randomized, controlled multicenter trial. *Stroke* 1998; **29**: 785-792 [PMID: 9550512 DOI: 10.1161/01.STR.29.4.785]
  - 66 **Cambier DC**, De Corte E, Danneels LA, Witvrouw EE. Treating sensory impairments in the post-stroke upper limb with intermittent pneumatic compression. Results of a preliminary trial. *Clin Rehabil* 2003; **17**: 14-20 [PMID: 12617375 DOI: 10.1191/0269215503cr580oa]
  - 67 **Feys H**, De Weerd W, Verbeke G, Steck GC, Capiou C, Kiekens C, Dejaeger E, Van Hoydonck G, Vermeersch G, Cras P. Early and repetitive stimulation of the arm can substantially improve the long-term outcome after stroke: a 5-year follow-up study of a randomized trial. *Stroke* 2004; **35**: 924-929 [PMID: 15001789 DOI: 10.1161/01.STR.0000121645.44752.f7]
  - 68 **Taub E**, Uswatte G, Pidikiti R. Constraint-Induced Movement Therapy: a new family of techniques with broad application to physical rehabilitation--a clinical review. *J Rehabil Res Dev* 1999; **36**: 237-251 [PMID: 10659807]
  - 69 **Taub E**, Uswatte G, Elbert T. New treatments in neurorehabilitation founded on basic research. *Nat Rev Neurosci* 2002; **3**: 228-236 [PMID: 11994754]
  - 70 **Dromerick AW**, Edwards DF, Hahn M. Does the application of constraint-induced movement therapy during acute rehabilitation reduce arm impairment after ischemic stroke? *Stroke* 2000; **31**: 2984-2988 [PMID: 11108760 DOI: 10.1161/01.STR.31.12.2984]
  - 71 **Hakkennes S**, Keating JL. Constraint-induced movement therapy following stroke: a systematic review of randomised controlled trials. *Aust J Physiother* 2005; **51**: 221-231 [PMID: 16321129]
  - 72 **Boake C**, Noser EA, Ro T, Baraniuk S, Gaber M, Johnson R, Salmeron ET, Tran TM, Lai JM, Taub E, Moye LA, Grotta JC, Levin HS. Constraint-induced movement therapy during early stroke rehabilitation. *Neurorehabil Neural Repair* 2007; **21**: 14-24 [PMID: 17172550 DOI: 10.1177/1545968306291858]
  - 73 **McIntyre A**, Viana R, Janzen S, Mehta S, Pereira S, Teasell R. Systematic review and meta-analysis of constraint-induced movement therapy in the hemiparetic upper extremity more than six months post stroke. *Top Stroke Rehabil* 2012; **19**: 499-513 [PMID: 23192715 DOI: 10.1310/tsr1906-499]
  - 74 **Chen JC**, Liang CC, Shaw FZ. Facilitation of sensory and motor recovery by thermal intervention for the hemiplegic upper limb in acute stroke patients: a single-blind randomized clinical trial. *Stroke* 2005; **36**: 2665-2669 [PMID: 16269638 DOI: 10.1161/01.STR.0000189992.06654.ab]
  - 75 **Gelnar PA**, Krauss BR, Sheehe PR, Szeverenyi NM, Apkarian AV. A comparative fMRI study of cortical representations for thermal painful, vibrotactile, and motor performance tasks. *Neuroimage* 1999; **10**: 460-482 [PMID: 10493903 DOI: 10.1006/nimg.1999.0482]
  - 76 **Davis KD**, Kwan CL, Crawley AP, Mikulis DJ. Functional MRI study of thalamic and cortical activations evoked by cutaneous heat, cold, and tactile stimuli. *J Neurophysiol* 1998; **80**: 1533-1546 [PMID: 9744957]
  - 77 **Wu HC**, Lin YC, Hsu MJ, Liu SM, Hsieh CL, Lin JH. Effect of thermal stimulation on upper extremity motor recovery 3 months after stroke. *Stroke* 2010; **41**: 2378-2380 [PMID: 20798364 DOI: 10.1161/strokeaha.110.593673]
  - 78 **Chen JC**, Lin CH, Wei YC, Hsiao J, Liang CC. Facilitation of motor and balance recovery by thermal intervention for the paretic lower limb of acute stroke: a single-blind randomized clinical trial. *Clin Rehabil* 2011; **25**: 823-832 [PMID: 21504953 DOI: 10.1177/0269215511399591]
  - 79 **Liang CC**, Hsieh TC, Lin CH, Wei YC, Hsiao J, Chen JC. Effectiveness of thermal stimulation for the moderately to severely paretic leg after stroke: serial changes at one-year follow-up. *Arch Phys Med Rehabil* 2012; **93**: 1903-1910 [PMID:

22766450 DOI: 10.1016/j.apmr.2012.06.016]

- 80 **Hsu HW**, Lee CL, Hsu MJ, Wu HC, Lin R, Hsieh CL, Lin JH.  
Effects of noxious versus innocuous thermal stimulation on

lower extremity motor recovery 3 months after stroke. *Arch  
Phys Med Rehabil* 2013; **94**: 633-641 [PMID: 23178539 DOI:  
10.1016/j.apmr.2012.11.021]

**P- Reviewer:** Cui L, Lai SL **S- Editor:** Song XX  
**L- Editor:** Wang TQ **E- Editor:** Lu YJ



# Dissociative symptoms and dissociative disorders comorbidity in obsessive compulsive disorder: Symptom screening, diagnostic tools and reflections on treatment

Hasan Belli

Hasan Belli, Department of Psychiatry, Bagcilar Education and Research Hospital, Bagcilar, Istanbul 34400, Turkey

Author contributions: Belli H contributed to this paper.

Correspondence to: Hasan Belli, MD, Associate Professor, Department of Psychiatry, Bagcilar Education and Research Hospital, Merkez Mahallesi, Bagcilar, Istanbul 34400, Turkey. [hasan.belli@hotmail.com](mailto:hasan.belli@hotmail.com)

Telephone: +90-212-4404002 Fax: +90-212-4404000

Received: March 15, 2014 Revised: May 13, 2014

Accepted: June 18, 2014

Published online: August 16, 2014

## Abstract

Borderline personality disorder, conversion disorder and obsessive compulsive disorder frequently have dissociative symptoms. The literature has demonstrated that the level of dissociation might be correlated with the severity of obsessive compulsive disorder (OCD) and that those not responding to treatment had high dissociative symptoms. The structured clinical interview for DSM-IV dissociative disorders, dissociation questionnaire, somatoform dissociation questionnaire and dissociative experiences scale can be used for screening dissociative symptoms and detecting dissociative disorders in patients with OCD. However, a history of neglect and abuse during childhood is linked to a risk factor in the pathogenesis of dissociative psychopathology in adults. The childhood trauma questionnaire-53 and childhood trauma questionnaire-40 can be used for this purpose. Clinicians should not fail to notice the hidden dissociative symptoms and childhood traumatic experiences in OCD cases with severe symptoms that are resistant to treatment. Symptom screening and diagnostic tools used for this purpose should be known. Knowing how to treat these pathologies in patients who are diagnosed with OCD can be crucial.

**Key words:** Dissociation; Obsessive compulsive disorder; Screening and diagnostic tools

**Core tip:** The literature has demonstrated that the level of dissociation might be correlated with the severity of obsessive compulsive disorder (OCD) and that those not responding to treatment had high dissociative symptoms. The structured clinical interview for DSM-IV dissociative disorders, dissociation questionnaire, somatoform dissociation questionnaire and dissociative experiences scale can be used for screening dissociative symptoms and detecting dissociative disorders in patients with OCD. However, a history of neglect and abuse during childhood is linked to a risk factor in the pathogenesis of dissociative psychopathology in adults. The childhood trauma questionnaire-53 and childhood trauma questionnaire-40 can be used for this purpose.

Belli H. Dissociative symptoms and dissociative disorders comorbidity in obsessive compulsive disorder: Symptom screening, diagnostic tools and reflections on treatment. *World J Clin Cases* 2014; 2(8): 327-331 Available from: URL: <http://www.wjgnet.com/2307-8960/full/v2/i8/327.htm> DOI: <http://dx.doi.org/10.12998/wjcc.v2.i8.327>

## INTRODUCTION

The term dissociation was used by James in 1890 from the translation of the French term *désagrégation* after it was described by Pierre Janet in 1889. Pierre Janet described dissociation as the deterioration in the unification of experiences at the mental level. These experiences consisted of perception, memory, cognition and emotions. Normally, these experiences all together constituted wholeness in the stream of mind<sup>[1,2]</sup>. Patients perceive dissociation as dispersion in the wholeness of sense of self. This



dispersion emerges as the deterioration in the unity of chronological, biographic and perceptive identity<sup>[2,3]</sup>.

Dissociative disorders were first described as categorical independent nosographical cases in the Diagnostic and Statistical Manual of Mental Disorders (DSM-III) which was published in 1980. Before that, they were among the phenomena associated with dissociative symptomatology hysteria<sup>[1,2]</sup>.

According to DSM-IV-TR, dissociation is described as the deterioration in the integrative functions of consciousness, like the perception of memory, identity and environment. On the other hand, in the etiology of dissociation, traumatic experiences, especially like childhood abuse, take an important place<sup>[4,5]</sup>. Dissociation functions as the autohypnotic defense mechanism that provides the psychological wholeness of the individual against these traumas<sup>[6]</sup>. Dissociative disorders contain a group of clinical syndromes associated with the deterioration of one or more of these features described. Dissociation may have a sudden or gradual, temporary or chronic stream. Among the dissociative disorders, the type that has the most chronic and complex features and that contains all the other dissociative phenomena is the dissociative identity disorder. Other dissociative disorders are depersonalization disorder, dissociative amnesia and dissociative fugue disorder. On the other hand, the category that does not meet the specific diagnostic criteria is described as the dissociative disorder that cannot be named otherwise. According to some writers, in cases when the prevalence of dissociative disorders is used as a base for the DSM-IV diagnosis criteria in clinical practice, it cannot be estimated. These disorders may go unnoticed in clinical practice and it is thought that they are more widespread than estimated. Besides, there is no research based on large populations<sup>[2,3]</sup>. However, according to recent research, the frequency is estimated to be 5.6% to 10% in the general population<sup>[1]</sup>. Despite the fact that they are a separate diagnostic category on their own, dissociative symptoms can be observed together with almost all the psychiatric disorders. They can affect the clinical stream of the psychiatric disorders that they are found with<sup>[7]</sup>. Dissociative symptoms are frequently found with borderline personality disorder<sup>[8,9]</sup>, conversion disorder<sup>[10]</sup> and obsessive compulsive disorder<sup>[11]</sup>.

Obsessive compulsive disorder (OCD) is a disorder frequently encountered and its lifelong prevalence is between 1% and 3%<sup>[4]</sup>. OCD is an illness that generally has a chronic stream. This disorder is characterized by obsessions or compulsions, takes very much of the person's time and causes intense stress or affects the individual's personal life<sup>[12]</sup>.

## DISSOCIATIVE PROCESSES AMONG PATIENTS WITH OBSESSIVE COMPULSIVE DISORDER

OCD is phenotypically very heterogeneous. This disease

has several manifestations, with various dimensions regarding symptoms. In this study, 50 patients who had been diagnosed with OCD were investigated in terms of dissociative symptoms and the relationship of these with symptom dimensions of OCD. In general, dissociative scores were correlated with the level of severity of OCD. However, the controlling dimension was the parameter that was most closely correlated with dissociation. Amnesic dissociative symptoms were found to be correlated with controlling compulsive scores<sup>[11]</sup>.

Rufer *et al*<sup>[13]</sup> evaluated 52 patients with the diagnosis of OCD. In this study, Cognitive Behavioral Therapy (CBT) was administered to patients for 9.5 wk on average and patients received exposure therapy. In this study group, a high level of dissociative symptoms was detected in patients who ceased treatment because of non compliance. In 43 patients who continued the treatment, however, those with severe OCD symptoms and not responding to the treatment had high dissociative symptoms. In this study, it was reported that high dissociative symptoms can be an indicator for poor response to CBT.

In a study where Belli *et al*<sup>[14]</sup> included 78 OCD cases, a significant relationship between severity of obsessive compulsive symptoms and dissociative symptom levels was detected. Dissociative disorder dual diagnoses were also investigated using SCID-D. The rate of having at least one dissociative disorder in study group was 14%. In this study, the most common dissociative disorder was depersonalization disorder, followed by dissociative amnesia and dissociative identity disorder. These diagnoses indicated that complicated dissociative disorders accompanied OCD considerably. In another study, Belli *et al*<sup>[15]</sup> found high levels of dissociative symptoms and a significant correlation between these symptoms and obsessive compulsive symptoms was noted. However, no significant relationship between dissociative symptoms and childhood traumatic experiences was detected.

Semiz *et al*<sup>[16]</sup> divided the patients into two groups in a study which included 120 OCD patients. Fifty-eight of these patients constituted the treatment-resistant group, whereas the treatment-responding group included 62 patients. The groups were compared to each other. The treatment-resistant group had a higher level of disease severity, dissociative symptoms and childhood traumas. The results of this study suggested that dissociative symptoms and childhood traumatic experiences can precede poor response to treatment.

In another study, Selvi *et al*<sup>[17]</sup> investigated 95 OCD patients from a different aspect. In this study, the relationship between possible dissociation, childhood trauma and cognitive processes in patients with OCD was investigated. It was found that dissociative symptomatology was strongly related to pathological processes that constituted OCD symptoms.

One of the most important methods for the treatment of OCD is Cognitive Behavioral Therapy (CBT). Pathological cognitive processes are looked for in the

formulation of treatment in OCD. However, no adequate response to CBT was reported in 30%-60% of cases. This also requires consideration of multifactorial intrapsychic structures that constitute OCD. The hypnotherapeutic approach that focuses on dissociative phenomena is one of the most important of these factors. Hypnotherapeutic approaches can also be used in the treatment of OCD<sup>[18]</sup>. It was reported that dissociative symptomatology can be a very important factor in not responding to treatment. This condition can involve not only treatment resistance to CBT, but also cases who do not adequately respond to medication<sup>[19]</sup>. However, the relationship between dissociative symptomatology with childhood traumatic experiences was well established. Hypnotherapeutic approaches can also be used in repairing the traumatic memory<sup>[20]</sup>. It is apparent that systematic studies are needed to measure the efficiency of hypnotherapeutic approaches in treatment resistant cases in regards to relevant dissociative pathology. Ego state therapy, a systematic approach in which hypnotic phenomena are used<sup>[21]</sup>, can be beneficial in the treatment of complex conditions, such as the dissociative amnesia or dissociative identity disorder that accompany OCD.

## ASSESSMENT OF DISSOCIATION SYMPTOMS AND CHILDHOOD TRAUMATIC EXPERIENCES IN PATIENTS USING THE TOOLS AND SCALES

### *The structured clinical interview for DSM-IV dissociative disorders*

SCID-D is a semi-structured interview tool developed by Steinberg. It is used to explore and determine the dissociative disorders according to DSM-IV. By using this interview tool, dissociative identity disorder, depersonalization disorder, dissociative amnesia, dissociative fugue and the dissociative disorder diagnoses that cannot be named otherwise can be established. Because of the fact that the dissociative identity disorder diagnosis can meet the symptoms of all the other diagnosis categories, it is generally established on its own. If this diagnosis is established, then generally no other diagnoses are established<sup>[22]</sup>.

### *Dissociation questionnaire*

This scale was developed by Svedin *et al*<sup>[23]</sup>. By using this scale, dissociative experiences are explored and the severity of these symptoms is evaluated. This scale can be used to explore the traumatic experiences of psychiatry patients and consists of 63 questions. Individuals mark the choices appropriate to them. Every heading is evaluated by a point between 1 and 5 and the average score is obtained by dividing the total points by 63<sup>[23]</sup>.

### *The somatoform dissociation questionnaire*

This scale is a self-rating instrument that consists of 20 articles that patients themselves fill out, used in the

exploration of somatoform symptoms of patients who have had traumatic experiences. Every heading is evaluated by a point between 1 and 5 and the average score is obtained by dividing the total points by 20. This scale was developed by Nijenhuis *et al*<sup>[24]</sup>.

### *The dissociative experiences scale*

This scale is a psychological self-rating instrument that evaluates dissociative symptoms. The scale contains 28 questions, a general score and four sub scales. Every heading is evaluated by a point between 0 and 100 and the average score is obtained by dividing the total points by 28<sup>[25]</sup>.

A history of neglect and abuse during childhood is linked to a risk factor in the pathogenesis of dissociative psychopathology in adults<sup>[5,26-29]</sup>. Dissociation is also linked to traumatic life events, especially childhood traumas<sup>[30]</sup>. Therefore, childhood traumas must be investigated when dissociative symptoms are found in patients with an OCD diagnosis. This could be very important in planning treatment and the following scales can be used for this purpose.

### *Childhood trauma questionnaire (CTQ-53)*

This is a self-rating scale developed by Bernstein *et al*<sup>[31]</sup> consisting of 53 questions. With this scale, childhood emotional, physical and sexual abuse and childhood physical and emotional neglect situations are evaluated. Points between 1 and 5 are given for all types of possible childhood traumas and the total of the points are derived from the total points of every childhood trauma between 5 and 25. The measurement also contains the minimization/denial scale that has three headings and is potentially out of the rating<sup>[31]</sup>. The 3 items comprising the minimization/denial scale are dichotomized (never = 0, all other responses = 1) and summed; a total of one (1) or greater "suggests the possible underreporting of maltreatment" false negatives.

### *Childhood trauma questionnaire (CTQ-40)*

This scale was developed by Bernstein *et al*<sup>[31]</sup>. It consists of 40 questions and every question has five choices. It is a self-rating scale that explores childhood traumatic experiences before the age of 18. The answers are composed of five choices. These answers are: never (1); rarely (2); sometimes (3); often (4); and very often (5). High scores reveal that abuse in adolescence and childhood took place very often. The total points are between 40 and 200<sup>[31]</sup>.

## CONCLUSION

OCD is a disorder with high lifelong prevalence that can severely deteriorate the quality of life. Therefore, every aspect influencing the development and treatment of this disorder should be addressed seriously.

The individuals diagnosed with OCD can be evaluated in three categories in an etiological context. These dimensions can be classified as cognitive, biological and

emotional<sup>[32,33]</sup>. Some writers emphasize the importance of traumatic dissociative, existential and acquired developmental factors in the etiology of OCD of some patients in the emotional dimension. For many years, various treatments have been suggested for the treatment of OCD. It is frequently emphasized that cognitive behavioral therapy is one of the most effective treatment methods<sup>[34]</sup>. Some authors<sup>[20,35,36]</sup> indicated that the therapist should target the stress eugenic factors that are acquired in intrapsychic and developmental ways and that contain conflicts, existential traumas and dissociated pieces of personality in order for the OCD symptoms to be treated successfully. However, the relationship between dissociative symptomatology and childhood traumas has not been clearly defined. To a large extent, dissociation is especially related to childhood abuse<sup>[26,37]</sup>. Dissociation functions as the autohypnotic defense mechanism that provides the psychological wholeness of the individual against these traumas<sup>[4,5]</sup>. In addition to the cognitive behavioral model, different methods can also be used in the treatment of dissociative symptoms and chronic dissociative disorders. Some writers stated that ego state therapy and hypnotherapy can be effective on dissociative processes. In the ego state therapy, hypnotic phenomena are used as the basic technique. In this therapy method, it is thought that the self develops in a fragmented way and functions by becoming integrated. Childhood trauma and stresses can disrupt this integrity. During the therapy, these childhood experiences are concentrated on again in order to fix the disrupted integrity. It is apparent that systematic studies are needed to measure efficiency of hypnotherapeutic approaches in treatment resistant cases in regard to relevant dissociative pathology. Ego state therapy is a systematic approach in which hypnotic phenomena are used<sup>[20,21]</sup>.

Investigating the dissociative symptoms, complex dissociative disorders and childhood traumas is very important in patients who are diagnosed with OCD. Clinicians should not fail to notice the hidden dissociative symptoms and childhood traumatic experiences in OCD cases with severe symptoms and resistant to treatment. Symptom screening scales and diagnostic tools used for this purpose should be known. To know how to treat these pathologies in patients who are diagnosed with OCD, particularly in cases with resistance to treatment, can be crucial.

OCD is a disease with high lifelong prevalence that can severely deteriorate the quality of life. The literature has demonstrated that the level of dissociation might be correlated with the severity of OCD and that those not responding to treatment had high dissociative symptoms.

It is important to know the scales that explore the dissociative symptoms and childhood experiences for patients diagnosed with OCD. Apart from that, the tools that serve to diagnose complex and chronic dissociative disorders can also help. More research that investigates the relationship between OCD and dissociative processes are needed. These studies need to have a large sample size that comprises both genders. As these studies in-

crease, serious developments will take place in treatment plans.

## REFERENCES

- 1 Dell PF, O'Neil JA. Dissociation and the dissociative disorders: DSM-V and beyond. New York: Routledge, 2009
- 2 Macri F, Salviati M, Provenzano A, Melcore C, Terlizzi S, Campi S, Biondi M. Psychopathological severity index and dissociative symptomatology in a group of non-psychotic outpatients. *J Psychopathology* 2013; **19**: 105-108
- 3 Isaac M, Chand PK. Dissociative and conversion disorders: defining boundaries. *Curr Opin Psychiatry* 2006; **19**: 61-66 [PMID: 16612181 DOI: 10.1097/01.yco.0000194811.83720.69]
- 4 Zlotnick C, Shea MT, Pearlstein T, Simpson E, Costello E, Begin A. The relationship between dissociative symptoms, alexithymia, impulsivity, sexual abuse, and self-mutilation. *Compr Psychiatry* 1996; **37**: 12-16 [PMID: 8770520 DOI: 10.1016/S0010-440X(96)90044-9]
- 5 Zlotnick C, Shea MT, Zakriski A, Costello E, Begin A, Pearlstein T, Simpson E. Stressors and close relationships during childhood and dissociative experiences in survivors of sexual abuse among inpatient psychiatric women. *Compr Psychiatry* 1995; **36**: 207-212 [PMID: 7648844 DOI: 10.1016/010-440X(95)90083-8]
- 6 Cardena E. The domain of dissociation. In: Lynn SJ, Rhue JW, editors. Dissociation. Clinical and Theoretical Perspectives. New York: Guilford Press, 1994; 15-31
- 7 Sar V, Ross C. Dissociative disorders as a confounding factor in psychiatric research. *Psychiatr Clin North Am* 2006; **29**: 129-144, ix [PMID: 16530590 DOI: 10.1016/j.psc.2005.10.008]
- 8 Sar V, Kundakci T, E. Kiziltan E, Dogan O. The axis-I dissociative disorder comorbidity of borderline personality disorder among psychiatric outpatients. *J Trau Dissociat* 2003; **4**: 119-136 [DOI: 10.1300/J229v04n01\_08]
- 9 Sar V, Akyuz G, Kugu N, Ozturk E, Ertem-Vehid H. Axis I dissociative disorder comorbidity in borderline personality disorder and reports of childhood trauma. *J Clin Psychiatry* 2006; **67**: 1583-1590 [PMID: 17107251 DOI: 10.4088/JCP.v67n1014]
- 10 Sar V, Akyüz G, Kundakçi T, Kiziltan E, Dogan O. Childhood trauma, dissociation, and psychiatric comorbidity in patients with conversion disorder. *Am J Psychiatry* 2004; **161**: 2271-2276 [PMID: 15569899 DOI: 10.1176/appi.ajp.161.12.2271]
- 11 Rufer M, Held D, Cremer J, Fricke S, Moritz S, Peter H, Hand I. Dissociation as a predictor of cognitive behavior therapy outcome in patients with obsessive-compulsive disorder. *Psychother Psychosom* 2006; **75**: 40-46 [PMID: 16361873 DOI: 10.1159/000089225]
- 12 Freud S. Hemmung, Symptom und Angst. In: Freud A, editor. Sigmund Freud. Gesammelte Werke. Chronologisch geordnet. London: Imago, 1948; 4
- 13 Rufer M, Fricke S, Held D, Cremer J, Hand I. Dissociation and symptom dimensions of obsessive-compulsive disorder. A replication study. *Eur Arch Psychiatry Clin Neurosci* 2006; **256**: 146-150 [PMID: 16267636 DOI: 10.1007/s00406-005-0620-8]
- 14 Bellı H, Ural C, Vardar MK, Yesilyurt S, Oncu F. Dissociative symptoms and dissociative disorder comorbidity in patients with obsessive-compulsive disorder. *Compr Psychiatry* 2012; **53**: 975-980 [PMID: 22425531 DOI: 10.1016/j.comppsych.2012.02.004]
- 15 Bellı H, Ural C, Yesilyurt S, Vardart MK, Akbudak M, Oncu F. Childhood trauma and dissociation in patients with obsessive compulsive disorder. *West Indian Med J* 2013; **62**: 39-44 [PMID: 24171326]
- 16 Semiz UB, Inanc L, Bezgin CH. Are trauma and dissociation related to treatment resistance in patients with obsessive-

- compulsive disorder? *Soc Psychiatry Psychiatr Epidemiol* 2014; **49**: 1287-1296 [PMID: 24213522]
- 17 **Selvi Y**, Besiroglu L, Aydin A, Gulec M, Atli A, Boysan M, Celik C. Relations between childhood traumatic experiences, dissociation, and cognitive models in obsessive compulsive disorder. *Int J Psychiatry Clin Pract* 2012; **16**: 53-59 [PMID: 22122656 DOI: 10.3109/13651501.2011.617458]
  - 18 **Meyerson J**, Konichezky A. Hypnotically induced dissociation (HID) as a strategic intervention for enhancing OCD treatment. *Am J Clin Hypn* 2011; **53**: 169-181 [PMID: 21404953]
  - 19 **Frederick C**. Hypnotically facilitated treatment of obsessive-compulsive disorder: can it be evidence-based? *Int J Clin Exp Hypn* 2007; **55**: 189-206 [PMID: 17365073]
  - 20 **Abramowitz EG**, Bonne O. [Use of hypnosis in the treatment of combat post traumatic stress disorder (PTSD)]. *Harefuah* 2013; **152**: 490-493, 497 [PMID: 24167937]
  - 21 **Emmerson G**. The vaded ego state and the invisible bridging induction. *Int J Clin Exp Hypn* 2013; **61**: 232-250 [PMID: 23427846]
  - 22 **Broadbent DE**, Broadbent MH, Jones JL. Performance correlates of self-reported cognitive failure and of obsessional-ity. *Br J Clin Psychol* 1986; **25** (Pt 4): 285-299 [PMID: 3801732 DOI: 10.1111/j.20448260.1986.tb00708.x]
  - 23 **Svedin CG**, Nilsson D, Lindell C. Traumatic experiences and dissociative symptoms among Swedish adolescents. A pilot study using Dis-Q-Sweden. *Nord J Psychiatry* 2004; **58**: 349-355 [PMID: 15513611 DOI: 10.1080/08039480410005891]
  - 24 **Nijenhuis ER**, Spinhoven P, Van Dyck R, Van der Hart O, Vanderlinden J. The development and psychometric characteristics of the Somatoform Dissociation Questionnaire (SDQ-20). *J Nerv Ment Dis* 1996; **184**: 688-694 [PMID: 8955682 DOI: 10.1097/00005053-199611000-00006]
  - 25 **Bernstein EM**, Putnam FW. Development, reliability, and validity of a dissociation scale. *J Nerv Ment Dis* 1986; **174**: 727-735 [PMID: 3783140 DOI: 10.1097/00005053-198612000-00004]
  - 26 **Dancu CV**, Riggs DS, Hearst-Ikeda D, Shoyer BG, Foa EB. Dissociative experiences and posttraumatic stress disorder among female victims of criminal assault and rape. *J Trauma Stress* 1996; **9**: 253-267 [PMID: 8731546]
  - 27 **Draijer N**, Langeland W. Childhood trauma and perceived parental dysfunction in the etiology of dissociative symptoms in psychiatric inpatients. *Am J Psychiatry* 1999; **156**: 379-385 [PMID: 10080552]
  - 28 **Lochner C**, du Toit PL, Zungu-Dirwayi N, Marais A, van Kradenburg J, Seedat S, Niehaus DJ, Stein DJ. Childhood trauma in obsessive-compulsive disorder, trichotillomania, and controls. *Depress Anxiety* 2002; **15**: 66-68 [PMID: 11891995 DOI: 10.1002/da.10028]
  - 29 **Kaplow JB**, Saxe GN, Putnam FW, Pynoos RS, Lieberman AF. The long-term consequences of early childhood trauma: a case study and discussion. *Psychiatry* 2006; **69**: 362-375 [PMID: 17326730]
  - 30 **Janke B**. [Rational and sure way of fabrication of complete dentures]. *Zahntechnik (Zur)* 1990; **47**: 20-24 [PMID: 2142843]
  - 31 **Bernstein DP**, Fink L, Handelsman L, Foote J, Lovejoy M, Wenzel K, Sapareto E, Ruggiero J. Initial reliability and validity of a new retrospective measure of child abuse and neglect. *Am J Psychiatry* 1994; **151**: 1132-1136 [PMID: 8037246]
  - 32 **Chamberlain SR**, Blackwell AD, Fineberg NA, Robbins TW, Sahakian BJ. The neuropsychology of obsessive compulsive disorder: the importance of failures in cognitive and behavioural inhibition as candidate endophenotypic markers. *Neurosci Biobehav Rev* 2005; **29**: 399-419 [PMID: 15820546 DOI: 10.1016/j.neubiorev.2004.11.006]
  - 33 **Jonnal AH**, Gardner CO, Prescott CA, Kendler KS. Obsessive and compulsive symptoms in a general population sample of female twins. *Am J Med Genet* 2000; **96**: 791-796 [PMID: 11121183]
  - 34 **Abramowitz JS**, Taylor S, McKay D. Potentials and limitations of cognitive treatments for obsessive-compulsive disorder. *Cogn Behav Ther* 2005; **34**: 140-147 [PMID: 16195053 DOI: 10.1080/16506070510041202]
  - 35 **Frederick C**. Selected topics in Ego State Therapy. *Int J Clin Exp Hypn* 2005; **53**: 339-429 [PMID: 16120529]
  - 36 **Ross CA**, Anderson G. Phenomenological overlap of multiple personality disorder and obsessive-compulsive disorder. *J Nerv Ment Dis* 1988; **176**: 295-299 [PMID: 3367145 DOI: 10.1097/00005053-198805000-00008]
  - 37 **Cardena E**. The domain of dissociation. In: Lynn SJ, Rhue JW, editors. *Dissociation. Clinical and Theoretical Perspectives*. New York: Guilford Press, 1994: 15-31

**P-Reviewer:** Bermejo PE **S-Editor:** Ji FF  
**L-Editor:** Roemmele A **E-Editor:** Lu YJ





## Metabolic syndrome and childhood trauma: Also comorbidity and complication in mood disorder

Sermin Kesebir

Sermin Kesebir, Erenköy Mental and Neurological Disease Training and Research Hospital, Kadıköy, İstanbul 34216, Turkey  
Author contributions: Kesebir S contributed to this paper.

Correspondence to: Sermin Kesebir, Associate Professor of Psychiatry, Erenköy Mental and Neurological Disease Training and Research Hospital, Sinan Ercan C. N: 29, Kadıköy, İstanbul 34216, Turkey. [serminkesebir@hotmail.com](mailto:serminkesebir@hotmail.com)

Telephone: +90-532-5922080 Fax: +90-532-5922080

Received: April 9, 2014 Revised: May 20, 2014

Accepted: June 18, 2014

Published online: August 16, 2014

### Abstract

Studies for prevalence and causal relationship established that addressing comorbidities of mental illnesses with medical disease will be another revolution in psychiatry. Increasing number of evidence shows that there is a bidirectional connection between mood disorders and some medical diseases. Glucocorticoid/insulin signal mechanisms and immuno-inflammatory effector systems are junction points that show pathophysiology between bipolar disorder and general medical situations susceptible to stress. A subgroup of mood disorder patients are under risk of developing obesity and diabetes. Their habits and life styles, genetic predisposition and treatment options are parameters that define this subgroup. Medical disease in adults had a significant relationship to adverse life experiences in childhood. This illustrates that adverse experiences in childhood are related to adult disease by two basic etiologic mechanisms: (1) conventional risk factors that actually are compensatory behaviors, attempts at self-help through the use of agents and foods; and (2) the effects of chronic stress.

© 2014 Baishideng Publishing Group Inc. All rights reserved.

**Key words:** Obesity; Dyslipidemia; Hypertension; Diabetes; Childhood trauma; Mood disorder

**Core tip:** Psychiatric and medical diseases have a two-way relationship, and may have some effects on each other's clinical appearance and clinical course, treatment options and choices as they affect the possibility of keeping links to carry the etiologic causes. The lifespan of people with serious and chronic disorders, such as mood disorder, decrease by 30% because of untreated medical diseases.

Kesebir S. Metabolic syndrome and childhood trauma: Also comorbidity and complication in mood disorder. *World J Clin Cases* 2014; 2(8): 332-337 Available from: URL: <http://www.wjgnet.com/2307-8960/full/v2/i8/332.htm> DOI: <http://dx.doi.org/10.12998/wjcc.v2.i8.332>

### INTRODUCTION

Studies for prevalence and causal relationship established that addressing comorbidities of mental illnesses with medical disease will be another revolution in psychiatry<sup>[1]</sup>. There is a bidirectional relationship between psyche and soma, each influencing the other. Plausible biological explanations are appearing at an astonishing rate. Psychiatric comorbidity with many chronic physical disorders has remained neglected. Evidence base of prevalence and causal relationship of psychiatric comorbidities in these disorders has been highlighted and strategies to meet the challenge of comorbidity have been indicated.

In our study on 2000 outpatient population, prevalence of medical diseases in mental illnesses, temporal relationship between appearance of medical diseases and mental illnesses and, whether treatment of mental illness is suitable for medical condition were cross-sectionally analysed, the rate of calculated of third axis co-diagnosis were as follows; 56% for mood disorders (MD), 42.3% for anxiety disorders (AD), and 38.3% for schizophrenia (S)<sup>[2]</sup>. The rate of calculated of third axis co-diagnosis

were different between MD, AD and S as follows; hypertension 34.4%, diabetes 23.6%, thyroid disease 18.5%, coronary arteria disease 13% in MD, hypertension 42.4%, respiratory disease 30.7%, gastrointestinal disease 25%, autoimmune disease 7% in AD, hypertension 65.3%, diabetes 14%, respiratory disease 12%, gastrointestinal disease 8% in S. The time interval between the beginning of disease to from now was detected as follows  $6.19 \pm 7.55/7.12 \pm 8.15$ , similar in mood disorders ( $r = 0.912$ ). Co-efficient of correlation ( $r$ ) were 0.265 and 0.425 for AD and S respectively ( $3.21 \pm 3.15/8.34 \pm 5.71$  and  $13.82 \pm 11.36/8.21 \pm 8.55$ ). Our results revealed that MD and medical disease appeared simultaneously. The pharmacologically treatment of MD, AD and, S insuitable to the III. Axis diagnosis and, found as high valuable mean in.

In bipolar disorder (BD), metabolic syndrome is more prevalent than general population. A subgroup of bipolar patients have higher risk of developing metabolic syndrome. Their habits, life styles, genetic susceptibility and choices of treatment are variables determining this subgroup, childhood trauma may be another variable. Metabolic syndrome has been reported at the rate of 35%-40% in bipolar patients. Metabolic syndrome encompasses obesity, diabetes, hypertension and dyslipidemia as cardiovascular risk factors. Although they are not among diagnostic criteria of metabolic syndrome, proinflammatory and prothrombotic state are considered in the framework of metabolic syndrome<sup>[5]</sup>. In our study, ICAM and VCAM levels measured at first manic episode were found to be higher than those found in subsequent remission period and healthy individuals. As our study group included only patients at first manic episode, there was no chronic effect of psychotropics use on these results. According to these results, probable cardiovascular disease (CVD) risk, reflected by increased ICAM and VCAM levels, is already present at the onset of the disease in bipolar patients<sup>[4]</sup>.

Exploring the biological pathways that could account for the observed link show that dysregulated inflammatory background could be a common factor underlying metabolic syndrome and MD. Comorbid medical illnesses in bipolar disorder might be viewed not only as the consequence of health behaviors and of psychotropic medications, but rather as an early manifestation of a multi-systemic disorder<sup>[5]</sup>. It is also necessary to look for subgroups of MD based on their rates of comorbid disorders.

Psychiatric and medical diseases have a two-way relationship, and may have some effects on each other's clinical appearance and clinical course, treatment options and choices as they affect the possibility of keeping links to carry the etiologic causes. The lifespan of people with serious and chronic disorders, such as mood disorder, decrease by 30% because of untreated medical diseases<sup>[6]</sup>. Obesity and diabetes are most common metabolic disease, related hypertension, dyslipidemia and cardiovascular disease.

## OBESITY

Obesity is a leading cause of preventable death and the

prevalence of overweight and obesity is increasing. A survey of 4.115 adult conducted in 1999 and 2000 as part of the National Health and Nutrition Examination Survey found that 64.5% of the population is overweight and 30.5% is obese<sup>[7]</sup>. A separate, smaller study of 50 bipolar patients, found an obesity rate that was only slightly higher (32%)<sup>[8]</sup>. In this study, most of the weight gain occurred during acute rather than maintenance treatment, and the increase in body mass index (BMI) was related to severity of depressive episode. Although several studies have found significant obesity in bipolar patients<sup>[9]</sup>. It is difficult to ascertain the degree to which the obesity is secondary to medications used to treat bipolar disorder or to the illness perse<sup>[10]</sup>. In our study rate of overweight was 62% and obesity 8% of the first episode manic patients<sup>[11]</sup>. Longitudinal studies of children and adolescents have found a positive association of major depressive disorder with adult BMI. This association persisted even after controlling for age, gender, substance abuse, socioeconomic level and medication exposure<sup>[12]</sup>.

Atypical antipsychotic medications are associated specifically with central obesity, which occurs when the main deposits of body fat are localized around abdomen. Accumulating evidence suggests that central deposition of body fat is a risk factor independent of overall obesity for mortality due to cardiovascular disease and type II diabetes<sup>[13]</sup>. In our study BMI was predictive variable of the diabetes in first episode mania<sup>[11]</sup>. Other medications used the treatment affective disorders, including lithium, valproate, and some antidepressants, have also associated with weight gain. Thus far, there has been less concern regarding the development of metabolic syndrome with this drugs than with the atypical antipsychotics.

Beyond weight gain caused medications, symptoms of depressive episode itself can lead to obesity. Depressed mood leads to lower levels of activity. Depressive episodes with atypical features such as hyperphagia, hypersomnia, leaden paralysis and carbohydrate craving are more liable to lead to weight gain. In the majority of bipolar patients, however, depressive symptoms are far more frequent than manic symptoms<sup>[14]</sup>. Depression is often accompanied by hypercortisolemia, which is also associated with central obesity. Even in the context of normal body weight, hypercortisolemia has been associated with excess visceral fat deposition as measured by computed tomography scan<sup>[15]</sup>. A national survey of 40.086 adults examined the relationship between body weight was associated with major depression and suicidal ideation and suicide attempts<sup>[16]</sup>.

## DIABETES

Because overweight and obesity are associated with diabetes, many risk factors that have been linked to weight gain apply also to the development of diabetes. The prevalence of reported diabetes mellitus was found to be approximately three times higher in a sample of 345 hospitalized bipolar patients than in the general population (3.4%)<sup>[17]</sup>. Patients in this sample also had a more severe

course of their mood disorders such as rapid cycling and chronic course<sup>[18]</sup>. In a recent work which takes its sampling from the society, the ratio of present diabetes diagnosis among bipolar diagnosed cases is found to be higher than healthy individuals (10.8%)<sup>[19]</sup>.

A subgroup of bipolar disorder patients are under risk of developing diabetes<sup>[9]</sup>. Their habits and life styles, genetic predisposition and treatment options are parameters that define this sub-group<sup>[12]</sup>. Metabolic syndrome and glucose abnormalities are reported between 18% and 30% in bipolar cases<sup>[18]</sup>. Among these, 7% are diabetes, while 23 % are pre-diabetes abnormalities.

Besides, the level of HbA1c in nonmedicated bipolar cases was found to be higher than the healthy controls<sup>[20]</sup>. In another similar study, hyperglycemia was found to be 43.5% in bipolar patients evaluated at the beginning of acute episode treatment<sup>[21]</sup>. According to the same study, 4.3% of the patients are under antidiabetic treatment. In a study of cases that exhibit violent (homicidal) behavior conducted by Langevin *et al*<sup>[22]</sup>, it was reported that diabetes prevalence was found higher in the sampling group, and more importantly, diabetes diagnosis was missed out in more than 25% of the cases<sup>[22]</sup>. In the same group it was stated that manic and psychotic findings were found often and especially among the younger cases, injury crime was not rare.

In our study, DM diagnosis was determined as 18% among first manic episode bipolar cases. When evaluated with glucose metabolism abnormalities, this ratio becomes 64%<sup>[11]</sup>. In late onset bipolar cases evaluating cases aged over 50, 42% of cases have manic episode diagnosis related to general medical condition. In general medical conditions, the ratio of diabetes is 50%<sup>[12]</sup>.

Dysregulation of the hypothalamic-pituitary-adrenocortical axis occurs frequently in patients with mood disorders. Hypercortisolemia associated with depressive states can lead to insulin resistance. Elevated levels of cortisol can lead to decreased insulin receptor sensitivity through currently unknown mechanisms<sup>[14]</sup>.

A more hypothetical link between bipolar disorder and diabetes relates to intracellular signal transduction involving the enzyme glycogen synthase kinase-3-beta (GSK-3 $\beta$ ). Glycogen synthetase kinase (GSK3) is a serine/threonine kinase that is a responsible enzyme from the cyclic mechanisms of the cell, gene expression, oncogenesis and neuronal protection<sup>[23]</sup>. Hippocampal volume and BDNF level decrease in diabetes<sup>[7]</sup>. Animal studies show that in diabetes-related depression, neurogenesis is inhibited in dentate gyrus<sup>[24]</sup>.

Alterations in GSK-3 $\beta$  functioning play role in insulin resistance. Insulin inhibits GSK-3 $\beta$  which result enhanced glucose transport into skeletal muscle. Insulin mediated inhibition of GSK-3 $\beta$  leads as well to increased glucose utilization and the production of glycogen<sup>[25]</sup>. GSK-3 $\beta$  is also one of targets for lithium action. Lithium significantly inhibits brain GSK-3 $\beta$  at concentrations relevant for the treatment bipolar disorder. Disturbances in the GSK-3 $\beta$  signal transduction pathway associated with

diabetes may affect the viability of neurons that play a role in mood stabilisation. Diminished insulin mediated inhibition of GSK-3 $\beta$  may have an effect opposite to that of lithium and may ultimately lead to an accentuation of psychiatric symptoms related to bipolar disorder. Besides, in a clinical study intranasal insulin was found to be more effective than placebo on cognitive distortion in unipolar and bipolar euthymic cases<sup>[26]</sup>.

When patients with diabetes are being treated, lithium should be used with care. Patients with juvenil onset insulin dependent diabetes are susceptible to diabetic nephropathy, and the risk is increased by the presence of hypertension. On the other hand, there is evidence that when lithium is combined with an oral antidiabetics or insulin, it has an assisting hypoglycemic effect in diabetic patients<sup>[27]</sup>. Lithium increases the sensitivity of glucose transport and metabolism in skeletal muscle and adipocytes. This effects similar to the effects of exercise.

In our study, free T4 levels have been found higher in diabetic first episode manic patients than nondiabetic first episode manic patients<sup>[11]</sup>. Thyroid Releasing Hormone (TRH -which is an endogen like antidepressant neuropeptide-) decreases the expression of GSK3- $\beta$ <sup>[28]</sup>. GSK3- $\beta$  activity, which increases in the manic phase of bipolar disorder, may be causing the reactive increase of free T4 by suppressing TRH.

In diabetic bipolar cases, triglyceride and cholesterol levels and BMI are determined as higher<sup>[11]</sup>. Triglyceride level and BMI are predictors in third and fourth order in regression analysis. When diabetes is in question, these findings are not a surprise, such that diabetes development is together with lipid metabolism abnormalities<sup>[10]</sup>. Also in our study, there is a correlation between triglyceride levels with fasting blood glucose and blood glucose level at the first hour of oral glucose tolerance test<sup>[11]</sup>. There is a stronger correlation between BMI with fasting blood glucose and HbA1c. In a recent work, the prevalence of obesity among bipolar cases was reported as 39.1%<sup>[29]</sup>. In the same study, high BMI, chronic course, longer disease period, lower functionality scores are shown to be comorbid with prevalent anxiety disorder, hypertension, diabetes and other diseases frequently. Additionally, in cases that show remission with lithium, BMI was found lower. In bipolar cases evaluated by Kim *et al*<sup>[21]</sup> at the beginning of acute period treatment, the ratio of hyperglycemia was determined as 43.5%. In the same study, 4.3% of the cases are under antidiabetic treatment, while 1.1 % of the cases are under anticholesterolemic treatment. There is hypercholesterolemia in 20.7% of the cases and obesity in 30.4% of the cases. All these findings should be considered as to question if the bipolar disorder itself acts like metabolic syndrome.

Increasing number of evidence shows that there is a bidirectional connection between mood disorders and some medical diseases<sup>[30]</sup>. Glucocorticoid/insulin signal mechanisms and immunoinflammatory effector systems are junction points that show pathophysiology between bipolar disorder and general medical situations

susceptible to stress<sup>[7]</sup>. In BD, the changes in brain energy metabolism and brain glucose metabolism may be important in BD pathophysiology<sup>[31]</sup>. Noradrenalin (NA), a signal molecule in the central nervous system, which has etiologic importance for many diseases is an important neurotransmitter in BD etiology<sup>[32]</sup>. High noradrenergic tonus, which is determined mostly genetically, may develop susceptibility for more than one medical and mental diseases in a wide spectrum for many people. So that, hypertension, progressive weight gaining, diabetes and mania are all conditions in which noradrenergic tonus increases. Since 1987, the prevalence of hypertension has been reported to be elevated (14%) in bipolar patients, compared to normal population (5.6%) and to unipolar depression (5%)<sup>[5]</sup>. This was replicated in several studies in USA and in Europe. While the largest study involving 25339 bipolar patients and 113698 controls found an increased rate of new-onset cases of hypertension among bipolar patients compared to general population and to schizophrenic cases.

Impaired fatty acid and phospholipid metabolism may be a primary cause of depression in many patients and may explain the interactions with other diseases. Post-mortem analysis of brains of bipolar patients revealed that in orbitofrontal cortex of those subjects reduced DHC levels were detected due to elevated saturated fatty acids and arachydonic acid metabolism<sup>[31]</sup>. In manic patients both DHA and arachydonic acids levels were increased<sup>[33]</sup>. The same fatty acids and phospholipid mediated disruption of secondary messaging systems in BD is also operative in diabetes and vascular disease<sup>[34]</sup>.

Hepatic steatosis, is more frequent among people with diabetes and obesity, and is almost universally present amongst morbidly obese diabetic patients. the links between hypercortisolism and obesity/metabolic syndrome, they hypothesize that this low prevalence of fat accumulation in the liver of patients with Cushing's syndrome could result from the inhibition of the so-called low-grade chronic-inflammation, mainly mediated by interleukin 6, due to an excess of cortisol, a hormone characterized by an anti-inflammatory effect<sup>[35]</sup>. Moreover, insulin resistance is associated with lower serotonin levels. Visceral obesity, strictly linked to hepatic steatosis is specifically associated with mild to severe somatic affective-depressive symptom clusters. Previous data support the view that depression involves serotonergic systems, reflecting low levels of urinary 5- hydroxy-3-indoleacetic acid (5-HIAA). In Tarantino *et al's* study<sup>[36]</sup>, among metabolic indices, cholesterol, HDL-cholesterol, triglycerides and uric acid were not able to predict urinary concentrations of 5-HIAA, which were not associated with hepatic steatosis; vice versa, ferritin levels, and mainly HOMA values, were independent predictors of the urinary excretion of 5-HIAA. Dystimia/depression severity was negatively predicted by urinary 5-HIAA levels in the sense that the highest BDI values were forecast by the lowest values of urinary 5-HIAA. The importance of measuring the 24-h urinary excretion of 5-HIAA in follow-ups could rely on

a method simultaneously mirroring the well-being status, the adherence to physical activity, which leads to improved insulin sensitivity, and the eating habits acquired by dystimic/depressed overweight/obese patients. In contrast, the significance of the urinary 5-HIAA is reduced in evaluating the severity of hepatic steatosis, likely because it is a structured process.

Recently, an increasing number of susceptibility variants have been identified for complex diseases. Somatic gene conversion and deletion were shown for BD, coronary arterial disease, rheumatoid arthritis, Chron's disease, hypertension and diabetes<sup>[37]</sup>. In a study of Lehne *et al*<sup>[38]</sup>, comorbidity is mentioned between BD, Chron's disease and diabetes. At the same time, the concern of "missing heritability" has also emerged. There is however no unified way to assess the heritability explained by individual genetic variants for binary outcomes. A systemic and quantitative assessment of the degree of "missing heritability" for complex diseases is lacking. The diseases under evaluation included Alzheimer's disease, bipolar disorder, breast cancer, coronary artery disease, Crohn's disease, prostate cancer, schizophrenia, systemic lupus erythematosus (SLE), type 1 diabetes and type 2 diabetes<sup>[39]</sup>. The median total variance explained across the 10 diseases was 9.81%, while the median variance explained per associated SNP was around 0.25%. These results evaluated according to environmental impact assessment. This is because methylations and demethylations of DNA continue in primordial germ cells during of development within the terms of epigenetic principles. In fact, a substantial proportion of heritability remains unexplained for the diseases.

## CONCLUSION

Medical disease in adults had a significant relationship to adverse life experiences in childhood (ACE). Examples of the links between childhood experience and adult biomedical disease are the relationship of ACE score to obesity, diabetes, coronary artery disease chronic obstructive pulmonary disease and autoimmune disease<sup>[40]</sup>. This illustrates that adverse experiences in childhood are related to adult disease by two basic etiologic mechanisms: (1) conventional risk factors that actually are compensatory behaviors, attempts at self-help through the use of agents and foods; (2) the effects of chronic stress as mediated through the mechanisms of chronic hypercortisolemia, proinflammatory cytokines and other stress responses on the developing brain and body systems, dysregulation of the stress response and pathophysiological mechanisms yet to be discovered. There is some biological correlates for adverse life experiences of childhood in bipolar patients. Early menarche and EEG abnormalities are some of them<sup>[41-43]</sup>.

Individuals reporting a history of any childhood adversity had higher systolic and diastolic blood pressure<sup>[44]</sup>. Among subjects with a history of sexual abuse, a significant proportion met criteria for obesity, a trend



toward overweight was found for subjects with a history of physical abuse, although this relationship did not remain significant after adjusting for potential confounders. There was no statistically significant difference in the overall rate of dyslipidemia and/or metabolic syndrome between subjects with and without childhood adversity. The results herein provide preliminary evidence suggesting that childhood adversity is associated with metabolic syndrome components in individuals with mood disorders. An association between stressful events and episode recurrences has repeatedly been found in bipolar patients<sup>[45]</sup>.

Psychological stress also may activate inflammatory responses in the brain<sup>[46]</sup>. The theoretical model frames the depressive episode as being a repair response to stress induced neuronal microdamage that can grade into a chronic neuroinflammatory condition. Cardiovascular damage and atherogenic changes could be a by-product of this process. One of the mechanisms whereby psychosocial stress influences both peripheral and central inflammatory cascade, is coordinated by autonomic nervous system. Thus, the release of noradrenaline and adrenaline follows the activation of the sympathetic system and induces the activation of both alpha and beta adrenoreceptors on immune cells thereby initiating the release of pro-inflammatory cytokines *via* the nuclear factor-kappa-beta cascade<sup>[47]</sup>. The brain is now known to be directly influenced by peripherally derived cytokines and gluco-corticoids as well as immune cells, which can access the brain through leaky blood-brain barrier and/or by activation of endothelial cells that line the cerebral vasculature, or bind to cytokine receptors<sup>[48]</sup>.

A public health paradox is implicit in these observations. One sees that certain common public health problems, while being often also unconscious attempted solutions to major life problems, harken back to the developmental years. The idea of the problem being a solution, while understandably disturbing to many, is certainly in keeping with the fact that opposing forces routinely coexist in biological systems. Clinical evidence suggests that metabolism and emotion homeostasis might share common mechanisms.

## REFERENCES

- 1 **Gautam S.** Fourth revolution in psychiatry - Addressing comorbidity with chronic physical disorders. *Indian J Psychiatry* 2010; **52**: 213-219 [PMID: 21180405 DOI: 10.4103/0019-5545.70973]
- 2 **Kesebir S, Aksoy AE, Gençer AG, Usta H, Elbay RY, Şayakçı S, Bilici M.** III. Axis Comorbidity in Psychiatric Disorders. Proceedings of the 46th National Psychiatry Congress, İzmir, Turkey 2010; Oral presentation (SB) 13: 339
- 3 **Vancampfort D, Vansteelandt K, Correll CU, Mitchell AJ, De Herdt A, Sienaert P, Probst M, De Hert M.** Metabolic syndrome and metabolic abnormalities in bipolar disorder: a meta-analysis of prevalence rates and moderators. *Am J Psychiatry* 2013; **170**: 265-274 [PMID: 23361837 DOI: 10.1176/appi.ajp.2012.12050620]
- 4 **Turan Ç, Kesebir S, Süner Ö.** Are ICAM, VCAM and E-selectin levels different in first manic episode and subsequent remission? *J Affect Disord* 2014; **163**: 76-80 [DOI: 10.1016/j.jad.2014.03.052]
- 5 **Leboyer M, Soreca I, Scott J, Frye M, Henry C, Tamouza R, Kupfer DJ.** Can bipolar disorder be viewed as a multi-system inflammatory disease? *J Affect Disord* 2012; **141**: 1-10 [PMID: 22497876 DOI: 10.1016/j.jad.2011.12.049]
- 6 **Fagioli A, Goracci A.** The effects of undertreated chronic medical illnesses in patients with severe mental disorders. *J Clin Psychiatry* 2009; **70** Suppl 3: 22-29 [PMID: 19570498 DOI: 10.4088/JCP.7075su1c.04]
- 7 **Kesebir S, Gençer AG.** Bipolar Disorder and Diabetes Mellitus. *Curr Approach Psychiatry* 2010; **2**: 66-74 [DOI: 10.5455/cap.20130920014550]
- 8 **Fagioli A.** Medical monitoring in patients with bipolar disorder: a review of data. *J Clin Psychiatry* 2008; **69**: e16 [PMID: 18683991]
- 9 **McIntyre RS, Konarski JZ, Misener VL, Kennedy SH.** Bipolar disorder and diabetes mellitus: epidemiology, etiology, and treatment implications. *Ann Clin Psychiatry* 2005; **17**: 83-93 [PMID: 16075661]
- 10 **McIntyre RS, Nguyen HT, Soczynska JK, Lourenco MT, Woldeyohannes HO, Konarski JZ.** Medical and substance-related comorbidity in bipolar disorder: translational research and treatment opportunities. *Dialogues Clin Neurosci* 2008; **10**: 203-213 [PMID: 18689290]
- 11 **Gençer AG, Yılmaz ED, Kesebir S.** Diabetes in first manic episode. *JMOOD* 2013; **3**: 17-22 [DOI: 10.5455/jmood.20121003054610]
- 12 **Kesebir S, Şayakçı S, Süner Ö.** Comparison of bipolar patients with and without late onset. *Düşünen Adam J Psychiatry and Neurol Sci* 2012; **25**: 244-251 [DOI: 10.5350/DAJPN2012250307]
- 13 **Judd LL, Akiskal HS.** Depressive episodes and symptoms dominate the longitudinal course of bipolar disorder. *Curr Psychiatry Rep* 2003; **5**: 417-418 [PMID: 14609495]
- 14 **Weber-Hamann B, Hentschel F, Kniest A, Deuschle M, Colla M, Lederbogen F, Heuser I.** Hypercortisolemic depression is associated with increased intra-abdominal fat. *Psychosom Med* 2002; **64**: 274-277 [PMID: 11914443]
- 15 **Carpenter KM, Hasin DS, Allison DB, Faith MS.** Relationships between obesity and DSM-IV major depressive disorder, suicide ideation, and suicide attempts: results from a general population study. *Am J Public Health* 2000; **90**: 251-257 [PMID: 10667187]
- 16 **McIntyre RS, Danilewitz M, Liauw SS, Kemp DE, Nguyen HT, Kahn LS, Kucyi A, Soczynska JK, Woldeyohannes HO, Lachowski A, Kim B, Nathanson J, Alsuwaidan M, Taylor VH.** Bipolar disorder and metabolic syndrome: an international perspective. *J Affect Disord* 2010; **126**: 366-387 [PMID: 20541810 DOI: 10.1016/j.jad.2010.04.012]
- 17 **Ruzickova M, Slaney C, Garnham J, Alda M.** Clinical features of bipolar disorder with and without comorbid diabetes mellitus. *Can J Psychiatry* 2003; **48**: 458-461 [PMID: 12971015]
- 18 **Chien IC, Chang KC, Lin CH, Chou YJ, Chou P.** Prevalence of diabetes in patients with bipolar disorder in Taiwan: a population-based national health insurance study. *Gen Hosp Psychiatry* 2010; **32**: 577-582 [PMID: 21112448 DOI: 10.1016/j.genhosppsych.2010.09.005]
- 19 **van Winkel R, De Hert M, Van Eyck D, Hanssens L, Wampers M, Scheen A, Peuskens J.** Prevalence of diabetes and the metabolic syndrome in a sample of patients with bipolar disorder. *Bipolar Disord* 2008; **10**: 342-348 [PMID: 18271914 DOI: 10.1111/j.1399-5618.2007.00520.x]
- 20 **Castilla-Puentes R.** Effects of psychotropics on glycosylated hemoglobin (HbA1c) in a cohort of bipolar patients. *Bipolar Disord* 2007; **9**: 772-778 [PMID: 17988369]
- 21 **Kim B, Kim S, McIntyre RS, Park HJ, Kim SY, Joo YH.** Correlates of metabolic abnormalities in bipolar I disorder at initiation of acute phase treatment. *Psychiatry Investig* 2009; **6**: 78-84 [PMID: 20046379 DOI: 10.4306/pi.2009.6.2.78]
- 22 **Langevin R, Langevin M, Curnoe S, Bain J.** The prevalence of diabetes among sexual and violent offenders and its co-occurrence with cognitive impairment, mania, psychotic

- symptoms and aggressive behavior. *Int J Prison Health* 2008; **4**: 83-95 [PMID: 18464062 DOI: 10.1080/17449200802038215]
- 23 **Rayasam GV**, Tulasi VK, Sodhi R, Davis JA, Ray A. Glycogen synthase kinase 3: more than a namesake. *Br J Pharmacol* 2009; **156**: 885-898 [PMID: 19366350 DOI: 10.1111/j.1476-5381.2008.00085.x]
  - 24 **Wang SH**, Sun ZL, Guo YJ, Yuan Y, Yang BQ. Diabetes impairs hippocampal function via advanced glycation end product mediated new neuron generation in animals with diabetes-related depression. *Toxicol Sci* 2009; **111**: 72-79 [PMID: 19502549 DOI: 10.1093/toxsci/kfp126]
  - 25 **Patel DS**, Dessalew N, Iqbal P, Bharatam PV. Structure-based approaches in the design of GSK-3 selective inhibitors. *Curr Protein Pept Sci* 2007; **8**: 352-364 [PMID: 17696868]
  - 26 **McIntyre RS**, Soczynska JK, Woldeyohannes HO, Miranda A, Vaccarino A, Macqueen G, Lewis GF, Kennedy SH. A randomized, double-blind, controlled trial evaluating the effect of intranasal insulin on neurocognitive function in euthymic patients with bipolar disorder. *Bipolar Disord* 2012; **14**: 697-706 [PMID: 23107220 DOI: 10.1111/bdi.12006]
  - 27 **Hunt NJ**. Hypoglycemic effect of lithium. *Biol Psychiatry* 1987; **22**: 798-799 [PMID: 3593824]
  - 28 **Pekary AE**, Stevens SA, Blood JD, Sattin A. Rapid modulation of TRH and TRH-like peptide release in rat brain, pancreas, and testis by a GSK-3beta inhibitor. *Peptides* 2010; **31**: 1083-1093 [PMID: 20338209 DOI: 10.1016/j.peptides.2010.03.020]
  - 29 **Calkin C**, van de Velde C, Růžicková M, Slaney C, Garnham J, Hajek T, O'Donovan C, Alda M. Can body mass index help predict outcome in patients with bipolar disorder? *Bipolar Disord* 2009; **11**: 650-656 [PMID: 19689507 DOI: 10.1111/j.1399-5618.2009.00730.x]
  - 30 **Evans DL**, Charney DS, Lewis L, Golden RN, Gorman JM, Krishnan KR, Nemeroff CB, Bremner JD, Carney RM, Coyne JC, Delong MR, Frasure-Smith N, Glassman AH, Gold PW, Grant I, Gwyther L, Ironson G, Johnson RL, Kanner AM, Katon WJ, Kaufmann PG, Keefe FJ, Ketter T, Laughren TP, Leserman J, Lyketsos CG, McDonald WM, McEwen BS, Miller AH, Musselman D, O'Connor C, Petitto JM, Pollock BG, Robinson RG, Roose SP, Rowland J, Sheline Y, Sheps DS, Simon G, Spiegel D, Stunkard A, Sunderland T, Tibbits P, Valvo WJ. Mood disorders in the medically ill: scientific review and recommendations. *Biol Psychiatry* 2005; **58**: 175-189 [PMID: 16084838]
  - 31 **Regenold WT**, Hisley KC, Phatak P, Marano CM, Obuchowski A, Lefkowitz DM, Sassan A, Ohri S, Phillips TL, Dosanjh N, Conley RR, Gullapalli R. Relationship of cerebrospinal fluid glucose metabolites to MRI deep white matter hyperintensities and treatment resistance in bipolar disorder patients. *Bipolar Disord* 2008; **10**: 753-764 [PMID: 19032707 DOI: 10.1111/j.1399-5618.2008.00626.x]
  - 32 **Fitzgerald PJ**. Is elevated noradrenaline an aetiological factor in a number of diseases? *Auton Autacoid Pharmacol* 2009; **29**: 143-156 [PMID: 19740085 DOI: 10.1111/j.1474-8665.2009.00442.x]
  - 33 **McNamara RK**, Jandacek R, Rider T, Tso P, Stanford KE, Hahn CG, Richtand NM. Deficits in docosahexaenoic acid and associated elevations in the metabolism of arachidonic acid and saturated fatty acids in the postmortem orbitofrontal cortex of patients with bipolar disorder. *Psychiatry Res* 2008; **160**: 285-299 [PMID: 18715653 DOI: 10.1016/j.psychres.2007.08.021]
  - 34 **Horrobin DF**, Bennett CN. Depression and bipolar disorder: relationships to impaired fatty acid and phospholipid metabolism and to diabetes, cardiovascular disease, immunological abnormalities, cancer, ageing and osteoporosis. Possible candidate genes. *Prostaglandins Leukot Essent Fatty Acids* 1999; **60**: 217-234 [PMID: 10397403]
  - 35 **Tarantino G**, Finelli C. Pathogenesis of hepatic steatosis: the link between hypercortisolism and non-alcoholic fatty liver disease. *World J Gastroenterol* 2013; **19**: 6735-6743 [PMID: 24187449 DOI: 10.3748/wjg.v19.i40.6735]
  - 36 **Tarantino G**, Savastano S, Colao A, Polichetti G, Capone D. Urinary excretion of 5-hydroxy-3-indoleacetic acid in dystimic/depressed, adult obese women: what correlations to hepatic steatosis? *Int J Immunopathol Pharmacol* 2011; **24**: 769-779 [PMID: 21978708]
  - 37 **Ross KA**. Evidence for somatic gene conversion and deletion in bipolar disorder, Crohn's disease, coronary artery disease, hypertension, rheumatoid arthritis, type-1 diabetes, and type-2 diabetes. *BMC Med* 2011; **9**: 12 [PMID: 21291537 DOI: 10.1186/1741-7015-9-12]
  - 38 **Lehne B**, Lewis CM, Schlitt T. Exome localization of complex disease association signals. *BMC Genomics* 2011; **12**: 92 [PMID: 21284873 DOI: 10.1186/1471-2164-12-92]
  - 39 **So HC**, Gui AH, Cherny SS, Sham PC. Evaluating the heritability explained by known susceptibility variants: a survey of ten complex diseases. *Genet Epidemiol* 2011; **35**: 310-317 [PMID: 21374718 DOI: 10.1002/gepi.20579]
  - 40 **Dube SR**, Felitti VJ, Dong M, Giles WH, Anda RF. The impact of adverse childhood experiences on health problems: evidence from four birth cohorts dating back to 1900. *Prev Med* 2003; **37**: 268-277 [PMID: 12914833]
  - 41 **Kesebir S**, Yaşan Şair B, Ünübol B, Tatlıdil Yaylacı E. Is there a relationship between age at menarche and clinical and temperamental characteristics in bipolar disorder? *Ann Clin Psychiatry* 2013; **25**: 121-124 [PMID: 23638442]
  - 42 **Kesebir S**, Güven S, Topçuoğlu ÇB, Yaylacı ET. EEG Abnormalities in first episode mania: Remark of childhood trauma. *JMOOD* 2013; **3**: 100-106 [DOI: 10.5455/jmood.20130116052129]
  - 43 **Kesebir S**, Güven S, Tatlıdil Yaylacı E, Bilgin Topçuoğlu Ö, Altıntaş M. EEG Abnormality in first episode mania: is it trait or state? *Psychol Res* 2013; **3**: 563-70
  - 44 **McIntyre RS**, Soczynska JK, Liauw SS, Woldeyohannes HO, Brietzke E, Nathanson J, Alsuaidean M, Muzina DJ, Taylor VH, Cha DS, Kennedy SH. The association between childhood adversity and components of metabolic syndrome in adults with mood disorders: results from the international mood disorders collaborative project. *Int J Psychiatry Med* 2012; **43**: 165-177 [PMID: 22849038]
  - 45 **Etain B**, Henry C, Bellivier F, Mathieu F, Leboyer M. Beyond genetics: childhood affective trauma in bipolar disorder. *Bipolar Disord* 2008; **10**: 867-876 [PMID: 19594502 DOI: 10.1111/j.1399-5618.2008.00635.x]
  - 46 **Wager-Smith K**, Markou A. Depression: a repair response to stress-induced neuronal microdamage that can grade into a chronic neuroinflammatory condition? *Neurosci Biobehav Rev* 2011; **35**: 742-764 [PMID: 20883718 DOI: 10.1016/j.neubiorev.2010.09.010]
  - 47 **Leonard BE**. The concept of depression as a dysfunction of the immune system. *Curr Immunol Rev* 2010; **6**: 205-212 [PMID: 21170282 DOI: 10.2174/157339510791823835]
  - 48 **Raison CL**, Capuron L, Miller AH. Cytokines sing the blues: inflammation and the pathogenesis of depression. *Trends Immunol* 2006; **27**: 24-31 [PMID: 16316783 DOI: 10.1016/j.it.2005.11.006]

P- Reviewer: Ji G, Tarantino G S- Editor: Ji FF L- Editor: A  
E- Editor: Lu YJ



## Pseudocyesis, delusional pregnancy, and psychosis: The birth of a delusion

Mary V Seeman

Mary V Seeman, Institute of Medical Science, Department of Psychiatry, University of Toronto, Toronto, Ontario, ON M5S, Canada

Author contributions: Seeman MV solely contributed to this paper.

Correspondence to: Mary V Seeman, MD, Professor Emerita, Institute of Medical Science, Department of Psychiatry, University of Toronto, 27 King's College Cir, Toronto, Ontario, ON M5S, Canada. [mary.seeman@utoronto.ca](mailto:mary.seeman@utoronto.ca)

Telephone: +1-416-4863456

Received: March 21, 2014 Revised: June 26, 2014

Accepted: July 12, 2014

Published online: August 16, 2014

### Abstract

Both pseudocyesis and delusional pregnancy are said to be rare syndromes, but are reported frequently in developing countries. A distinction has been made between the two syndromes, but the line of demarcation is blurred. The aim of this paper is to review recent cases of pseudocyesis/delusional pregnancy in order to learn more about biopsychosocial antecedents. The recent world literature (2000-2014) on this subject (women only) was reviewed, making no distinction between pseudocyesis and delusional pregnancy. Eighty case histories were found, most of them originating in developing countries. Fifty patients had been given a diagnosis of psychosis, although criteria for making the diagnosis were not always clear. The psychological antecedents included ambivalence about pregnancy, relationship issues, and loss. Very frequently, pseudocyesis/delusional pregnancy occurred when a married couple was infertile and living in a pronatalist society. The infertility was attributed to the woman, which resulted in her experiencing substantial distress and discrimination. When antipsychotic medication was used to treat psychotic symptoms in these women, it led to high prolactin levels and apparent manifestations of pregnancy, such as amenorrhea and galactorrhea, thus

reinforcing a false conviction of pregnancy. Developing the erroneous belief that one is pregnant is an understandable process, making the delusion of pregnancy a useful template against which to study the evolution of other, less explicable delusions.

© 2014 Baishideng Publishing Group Inc. All rights reserved.

**Key words:** Pseudocyesis; Delusional pregnancy; Infertility; Prolactin; Delusion

**Core tip:** It is usually impossible to distinguish between pseudocyesis and delusional pregnancy. Both occur primarily in developing countries, and especially where there is strong familial and cultural pressure on women to be fertile. The delusion starts in a climate of apprehension and develops when sensory perceptions are interpreted as signifying pregnancy, despite evidence to the contrary. Understanding this delusion can help to understand other, more unusual false beliefs.

Seeman MV. Pseudocyesis, delusional pregnancy, and psychosis: The birth of a delusion. *World J Clin Cases* 2014; 2(8): 338-344 Available from: URL: <http://www.wjgnet.com/2307-8960/full/v2/i8/338.htm> DOI: <http://dx.doi.org/10.12998/wjcc.v2.i8.338>

### INTRODUCTION

It is not uncommon for women to believe that they are pregnant when they are not. In jest this has been called "jestation". But it ceases being a jest when the preoccupation with pregnancy becomes an over-valued idea or a delusion. In women suffering from psychosis, delusional pregnancy is not uncommon, especially since the advent of antipsychotic medications, which, by virtue of inhibiting dopamine secretion, raise prolactin levels to produce amenorrhea, breast swelling/tenderness, and ga-



lactorrhea-akin to the somatic experience of pregnancy<sup>[1]</sup>. Moreover, antipsychotic drugs are associated with considerable weight gain, distending the abdomen and adding to a misperception of pregnancy. Even when there has been no prior sexual activity, fantasy-prone women can find ways of convincing themselves that they are pregnant. They imagine the implantation occurring by magic or through the wizardry of advanced reproductive technology. Such was the case of a 17-year-old girl reported by Manoj<sup>[2]</sup>, who believed she was carrying a “test tube baby”. Cruzado describes a further case where the imagined pregnancy was a product of “artificial insemination” and two more cases where impregnation was believed to have occurred *via* telepathy<sup>[3]</sup>.

Another example was a patient (now deceased) who attended the Women’s Clinic for Psychosis in Toronto, Canada<sup>[4]</sup>.

## CASE ILLUSTRATION

AC, a single 60-year-old woman, suffered from schizophrenia since age 16. After several inpatient admissions, she was being treated with depot antipsychotic medication, and was living independently, never completely free, however, of auditory, olfactory, and somatic hallucinations, nor of delusional thinking. At different times in her life AC developed romantic fantasies about men she met, her latest fantasy involving her psychiatrist, Dr. J. She knew Dr. J. was a married man but allusions to him on TV convinced her that he reciprocated her interest. After she watched a wedding on TV, she was persuaded that she and Dr. J. were secretly married. She began wearing a wedding ring and to believe that she was pregnant.

When asked how she could be pregnant since she had never had sexual relations, she stated that the depot injection she received monthly (prescribed by Dr. J.) had successfully implanted Dr. J.’s seed in her body and that she would soon be giving birth to his child.

A distinction has been drawn between pseudocyesis, where signs of pregnancy are demonstrably present (abdominal swelling, menstrual disturbance, spotting, the report of quickening, breast tenderness and engorgement, weight gain, galactorrhea) and delusions of pregnancy, where there may be cessation of menstrual periods and abdominal distension, but no other outward signs<sup>[5]</sup>. The first is said to be a somatoform disorder while the second is a symptom of psychosis<sup>[6]</sup>. More recently, however, with the growing recognition that elevated prolactin levels can lead to many of the signs of pregnancy, the two conditions (pseudocyesis and delusional pregnancy) are conceptualized as occurring on a continuum, sometimes in women with no prior or subsequent psychiatric history, sometimes in the midst of a depressive or related illness, sometimes in women suffering from ongoing psychotic illness<sup>[3,7]</sup>. What has been written about pseudocyesis applies equally well to the psychodynamics of delusional pregnancy. It may also apply to a range of related delusions centering around procreation<sup>[8,9]</sup>, from the conviction

of having an intimate partner (when none in fact exists), of being pregnant (when one is demonstrably not), of not being pregnant when one indeed is<sup>[10]</sup>, of wrongly insisting, when in pain for other reasons, that one is undergoing labor and delivery<sup>[11]</sup>, to the false idea of being a parent, a potentially dangerous delusion that has been known to lead to the kidnapping of other people’s children<sup>[12]</sup>.

In an effort to better understand the birth of delusions in general, the aim of this review is to focus on psychological, biological, and sociocultural antecedents as described in modern case reports of pseudocyesis.

The pertinent literature (Google Scholar, Pub Med databases) after the year 2000 was searched with the following terms: pseudocyesis, delusion of pregnancy, false/imaginary/phantom/pseudo/spurious pregnancy. All languages were included. Delusional pregnancy occurring in men or in species other than human was excluded. All the papers consisted of case reports except two<sup>[7,13]</sup>, which used case control study designs.

## EPIDEMIOLOGY

The case of AC described above from the Women with Psychosis Clinic is the 80<sup>th</sup> instance of delusional pregnancy/pseudocyesis reported since 2000, the 50<sup>th</sup> in whom the delusion emerged in the context of a prior psychotic illness. Although diagnosis is not always clear in the published reports, this suggests that, in most cases described in recent years, the affected women suffer from a concomitant psychotic illness. In the past, pseudocyesis has been reported as rare but, in developing countries, India<sup>[14]</sup> or sub-Saharan Africa<sup>[15]</sup>, it is considered fairly common. It has a reported occurrence rate in Africa of 1 in every 344 pregnancies<sup>[16]</sup>. Over a period of 5 years, of 486 women with abdominal distension in Ghana who came for sonography thinking they might be pregnant, three were diagnosed with pseudocyesis (of the others, almost half had fibroids, 10% had a benign ovarian tumor, 10% had cancer of the cervix with ascites; about 7% suffered only from obesity)<sup>[17]</sup>. In Nigeria<sup>[18]</sup>, five out of 242 women who came for sonography for gynecological complaints referable to the lower abdomen were diagnosed with pseudocyesis. Out of 3200 women presenting for infertility treatment in a teaching hospital in Sudan over a five-year period, 20 were diagnosed with pseudocyesis<sup>[19]</sup>.

Though once said to occur only 1-6 times per 22000 births in the West<sup>[20]</sup>, Moselhy *et al*<sup>[21]</sup> reported in 2000 that they ascertained three cases in a six month period on an acute psychiatric ward in Birmingham, United Kingdom.

The majority of cases of pseudocyesis are described in reproductive age women and 80% of the affected women are said to be married.

## PHENOMENOLOGY

Delusional pregnancy can present as a monothematic de-



lusion<sup>[22,23]</sup> or, more commonly, in association with other delusions (polythematic delusions). Delusional pregnancy has presented in conjunction with Clerambault's syndrome, as in the case of AC, or with Capgras syndrome<sup>[24]</sup>. It can present as a form of couvade syndrome, a "copy cat pregnancy" when a loved (and/or envied) intimate becomes pregnant<sup>[25-27]</sup>. It can be transient or long lasting, corrigible (or not) by demonstrated evidence, education, cognitive behavioral therapy, or psychopharmaceutical agents. It can be primary or appear in the context of medical conditions that cause abdominal distension such as fibroids<sup>[28]</sup>, urinary retention<sup>[29]</sup>, polydipsia<sup>[30]</sup>, metabolic syndrome<sup>[31]</sup>, tubal cyst<sup>[32]</sup> or abdominal pain such as cholecystitis<sup>[11]</sup>. Sonographs have picked up a number of additional potential causes of abdominal distension that can accompany pseudocyesis<sup>[33]</sup>, such as abdominal neoplasm or enlarged liver. Neurological conditions can be associated with this delusion as, for instance, frontotemporal lobar degeneration<sup>[34,35]</sup>. Endocrine disturbance such as hypothyroidism can present as pseudocyesis<sup>[27]</sup>. It has been associated with the postpartum state<sup>[36]</sup>, with premature menopause<sup>[37]</sup> and with high progesterone levels<sup>[38]</sup>. Most especially, pseudocyesis has been tied to hyperprolactinemia because elevated prolactin levels lead to many of the symptoms of pregnancy<sup>[1]</sup>. Hyperprolactinemia can result from psychological stress, especially the stress that accompanies a psychotic episode, independent of antipsychotic medication<sup>[39]</sup>. Prolactin levels can be raised by many organic conditions and by nipple stimulation as well as by drugs such as estrogens, antidepressants, antihypertensives, protease inhibitors, opiates, benzodiazepines, cimetidine, and dopamine blockers<sup>[40]</sup>.

Antipsychotic drugs are all dopamine blockers and all raise prolactin level to some degree, some more than others, in a dose dependent fashion<sup>[41]</sup>. This means that women suffering from psychosis who are being treated with these agents often perceive body changes that they may associate with pregnancy<sup>[1]</sup>. This has been reported in several of the cases published since 2000<sup>[42-47]</sup>. Ahuja and Moorehead<sup>[13]</sup> describe six cases of pseudocyesis. Four of the six had been pregnant before and likened their current experience of high prolactin levels to the feeling they had during past pregnancies. In all six of these patients, the ideas/delusions of pregnancy disappeared soon after a change to a relatively prolactin-sparing antipsychotic.

Patient attributions-reasons given when confronted with the fact that blood tests and sonography were negative despite their own certainty that they were pregnant-vary according to cultural tradition and degree of patient education or sophistication. Absence of a fetus on sonography was explained by one patient by the probability that the fetus had migrated from her uterus to her back where he/she was hidden from view by bone and muscle<sup>[32]</sup>. A patient described by El Ouazzani<sup>[30]</sup> who had had six separate episodes of delusional pregnancy explained the pregnancies and the failure to confirm on possession by the devil. One of Dalfallah's patients<sup>[19]</sup>, one of three wives in a polygamous marriage, attributed both her orig-

inal infertility and her current "invisible" pregnancy to the envy of her husband's other wives and the witchcraft they exerted. Ruzanna and Marhani's patient<sup>[48]</sup> explained the apparent "loss" of her pregnancy by calling upon the Malay tradition of orang bunian, evil spirits taking possession of developing fetuses.

## PSYCHOLOGICAL ANTECEDENTS

According to both Koic<sup>[49]</sup> and Ibekwe<sup>[15]</sup>, pseudopregnancy always occurs in the context of a simultaneous wish and fear of pregnancy, *e.g.*, emotional conflict, stress, and ambivalence. It should be noted, as an aside, that anticipation and fear will substantially raise prolactin levels in many women, thus mimicking signs of pregnancy<sup>[50]</sup>. When there is pressure to conceive and simultaneous fear of pregnancy, the ground is laid for this form of delusion. Ambivalence may arise when a pregnancy, though unwanted, is seen as a possible means of recapturing a wayward lover, as illustrated in the case of the 15-year-old girl reported by Skrabic<sup>[51]</sup>. For women who live in societies where womanhood is defined by motherhood, as described in Dafallah<sup>[19]</sup>, pregnancy, however problematic the circumstances, may still be wished for. In societies where women are rated by the number of their sons<sup>[14]</sup>, a woman with only daughters will zealously pursue pregnancy, but ambivalently, fearing the birth of another girl. Simon<sup>[36]</sup> describe pseudocyesis among the Roma in rural Hungary where there is strong social pressure to become pregnant as soon as possible after marriage. At the same time, there is a high rate of maternal death during labor and delivery, making women ambivalent about pregnancy.

It was impossible to ascertain, in most of the case histories, whether the women described were infertile. Infertility, whether due to lack of a partner, menopause, gynecologic problems, prior sterilization, or concomitant illness, heightens the wish for pregnancy, while its very impossibility can fuel magical fantasies<sup>[15]</sup>. The timing of emergence of the delusion often coincides with the early stages of menopause<sup>[5,30,49,52,53]</sup>, inferring that infertility plays a triggering role. Sometimes the timing suggests that the delusional pregnancy serves to compensate not only for the loss of fertility, but for loss in general. In the report by Marusic, the patient came to hospital a year after the death of her father, delusionally convinced that she was about to deliver a baby<sup>[46]</sup>. In Grover<sup>[44]</sup> a 46-year-old woman developed a psychosis two months after the death of an only son. The psychosis was treated with antipsychotic drugs, resulting in hyperprolactinemia and weight gain. Still on her medication, on the first anniversary of her son's death, the patient became convinced (falsely) that she was pregnant, that she felt fetal movements, and that the new baby was a male.

Some authors have suggested other related antecedents to the delusion of pregnancy such as social isolation, so that a baby becomes a hoped-for companion<sup>[54]</sup>. Ibekwe<sup>[15]</sup> has suggested that women's perception of their inherent powerlessness in a patriarchal society leads to

the development of pseudocyesis. Women in many developing countries, cannot compensate for lack of children, as can women in the West, by succeeding in a career, or making money in business or going out to war. Being pregnant (and gaining status thereby) is their one source of power.

In fact, because pregnancy is a highly respected state and women are treated especially well during this time by their spouses, in-laws, and society in general, giving up the pregnant state may be psychologically difficult. Simon *et al*<sup>[36]</sup> describe two cases where a delusional pregnancy occurred shortly after delivery, during the postpartum period, and seemed to be motivated by the wish to continue to be treated as if pregnant. Pregnancy confers advantages. In Muslim cultures, a husband cannot divorce his wife while she is pregnant<sup>[55]</sup>. In some religious traditions, pregnancy and breast-feeding absolve women from unwanted sexual activity<sup>[56]</sup>.

From the results of their series of cases, Rosch *et al*<sup>[7]</sup> conclude that false pregnancy can be an unconscious adaptive strategy to guard against loss of a relationship. This view is seconded by Ibekwe<sup>[15]</sup> whose case describes an imagined pregnancy that brought the patient personal fulfillment, stability to her marriage and newfound acceptance from her in-laws. Ibekwe suggests that the delusion solved the dilemma faced by this infertile woman in a culture (Nigeria) that places immense value on children not only because procreation is religiously mandated, but also because it is economically necessary for survival and generational continuity. In sub-Saharan Africa, infertility is said to affect one third of all couples<sup>[57]</sup>, is always blamed on the woman, and leads to discrimination and abuse<sup>[58]</sup>. In developing countries, violence against infertile women is reported to occur in 10 to 60 percent of instances<sup>[59,60]</sup>.

## EFFECTS OF CULTURE

Although perceived infertility is not always at the heart of delusional pregnancy<sup>[61]</sup>, it contributes, more so in some social contexts than in others<sup>[62]</sup>. Infertility can cause extreme levels of distress<sup>[63,64]</sup>, especially in developing countries where childlessness is never an acceptable option for married women, and where infertility treatments are often not available. Even where they are financially available, Islamic law forbids sperm and ova donations, as well as surrogacy<sup>[65]</sup>. Adoptions are also forbidden in most interpretations of Islamic law<sup>[66]</sup> because preservation of hereditary lineage is important. Infertility, though often caused by the male partner, is attributed, almost always in developing countries, to the woman<sup>[61]</sup>. A childless woman is viewed as a failure and is rejected by her husband and his family, as described in ethnographic studies carried out in the countries where pseudocyesis appears to be relatively commonplace<sup>[67-70]</sup>.

Pronatalism, the belief that a woman's social value is linked to her production of children is strong in developing countries<sup>[71]</sup>. Only the presence of children gives a woman the right to share in her husband's property

in sub-Saharan Africa. Infertility can be just cause for divorce or, in polygamous societies, justification for the husband taking another, more fertile wife<sup>[55,61]</sup>. The paradox is that infertility is relatively common in these same countries because of the prevalence of genital infection spread by unprotected sexual contact and because of unsanitary obstetric practices. To make matters worse, infant mortality is also high in many of these regions, partly because of the popularity of consanguineous marriages<sup>[72]</sup>. This translates into pressure on couples to give birth to as many children as possible, to insure against loss. In some traditional societies, the pressure to produce children is experienced as coming not only from family members but also, importantly, from dead ancestors who may feel wronged by the lack of descendants, and take revenge<sup>[73]</sup>.

The role of cultural factors is evident in the identifications that women sometimes make when they develop a delusional pregnancy. The best illustration of this is in Battacharyya and Chaturvedi<sup>[6]</sup> who describe a woman from Bangalore India who believed that, in a previous birth, she had been the wife of the Hindu god Lord Rama and was now pregnant by him. In Hindu legend, Rama and his wife Sita are the personifications of ideal love, but are destined to be separated from each other. Furthermore, Sita (like the woman in question) gives birth to her twin sons when she is alone.

Where it is commonplace to believe that magic and evil spirits can cause disease, the distinction between a belief and a delusion can be easily blurred, as in Saudi Arabia, for instance, where many believe that pregnancy does not require sexual contact, but can be induced by spirits<sup>[55]</sup>.

## BIRTH OF A DELUSION

The delusion of pregnancy, as exemplified by the 80 cases reported since 2000, illustrates the circumstances of birth and development of a delusion. According to Conrad<sup>[74]</sup>, the first stage, which he called "das trema" is a general feeling of non-specific apprehension. This can be a result of familial and societal pressures or personal aspirations to become pregnant despite obstacles such as infertility, old age, spinsterhood, ill health, poor marital relationship, or inadequate socioeconomic conditions. The general apprehension during this first stage may follow the loss of a child, or loss of status, or loss of a love relationship. The second stage of delusion formation is a sensory perception, such as weight gain, or vaginal spotting, or abdominal movement, or frequency of urination. The same sensory perception may have occurred many times before but, this time around, as the person searches for what it might mean, it suddenly acquires extraordinary significance. This is the third stage, where meaning is attached to an otherwise neutral sensation. The meaning, seemingly of surreal importance so urgent is its message, appears "out of the blue" ("Ah, I must be pregnant")<sup>[75]</sup>. It feels convincingly true because, in one fell swoop, it resolves the difficult dilemmas with which the woman has

been struggling (“How can I live without my son?” “How can I be a woman if I’m infertile?” “How can I hold on to a man who is no longer interested?” “How can I avoid sex and still be a wife?”)<sup>[76]</sup>. How a person then deals with this momentous information depends on personal factors (health, education, reasoning ability, cognitive biases) and on situational factors (family, socioeconomics, culture, religion). Such factors may serve to dispel the delusion for want of evidence and plausibility or they may serve to reinforce it by recalling traditional beliefs and fictional accounts<sup>[77]</sup>.

## FUTURE DIRECTIONS

A better understanding of pseudocyesis/delusional pregnancy requires experimental study designs. Antecedents, onsets, and diagnoses could be compared in (1) women and men with this condition<sup>[78]</sup>; (2) fertile<sup>[61]</sup> and infertile women; and (3) pseudocyesis and other monothematic delusions such as Capgras syndrome or Cotard syndrome<sup>[79]</sup>. It may also prove interesting to compare, on the same variables, women who delusionally deny pregnancy<sup>[10]</sup> with those who delusionally insist, against all evidence, that they are pregnant. Such careful comparisons will shed more light on this and other delusional conditions.

## REFERENCES

1. **Tarín JJ**, Hermenegildo C, García-Pérez MA, Cano A. Endocrinology and physiology of pseudocyesis. *Reprod Biol Endocrinol* 2013; **11**: 39 [PMID: 23672289 DOI: 10.1186/1477-7827-11-39]
2. **Manoj PN**, John JP, Gandhi A, Kewalramani M, Murthy P, Chaturvedi SK, Isaac MK. Delusion of test-tube pregnancy in a sexually abused girl. *Psychopathology* 2004; **37**: 152-154 [PMID: 15192320 DOI: 10.1159/000078868]
3. **Cruzado-Díaz L**, Herrera-López V, Perales-Salazar M. Delusions of pregnancy and pseudocyesis: a brief approach. *Colombian J Psychiatry* 2012; **41**: 208-216. Available from: URL: <http://www.redalyc.org/articulo.oa?id=80624093015>
4. **Seeman MV**, Cohen R. A service for women with schizophrenia. *Psychiatr Serv* 1998; **49**: 674-677 [PMID: 9603575]
5. **Yadav T**, Balhara YP, Kataria DK. Pseudocyesis Versus Delusion of Pregnancy: Differential Diagnoses to be Kept in Mind. *Indian J Psychol Med* 2012; **34**: 82-84 [PMID: 22661815 DOI: 10.4103/0253-7176.96167]
6. **Battacharyya S**, Chaturvedi SK. Metamorphosis of delusion of pregnancy. *Can J Psychiatry* 2001; **46**: 561-562
7. **Rosch DS**, Sajatovic M, Sivec H. Behavioral characteristics in delusional pregnancy: a matched control group study. *Int J Psychiatry Med* 2002; **32**: 295-303 [PMID: 12489704 DOI: 10.2190/VRV7-7H3T-F5WF-A4B7]
8. **Manjunatha N**, Sarma PK, Math SB, Chaturvedi SK. Delusional procreation syndrome: A psychopathology in procreation of human beings. *Asian J Psychiatr* 2010; **3**: 84-86 [PMID: 23051198 DOI: 10.1016/j.ajp.2010.02.001]
9. **Manjunatha N**, Reddy SK, Renuka Devi NR, Rawat V, Bijjal S, Kumar NC, Kishore Kumar KV, Thirthalli J, Gangadhar BN. Delusional Procreation Syndrome: Report from TURU-VECARE Community Intervention Program. *Indian J Psychol Med* 2013; **35**: 214-216 [PMID: 24049237 DOI: 10.4103/0253-7176.116261]
10. **Walloch JE**, Klauwer C, Lanczik M, Brockington IF, Kornhuber J. Delusional denial of pregnancy as a special form of Cotard’s syndrome: case report and review of the literature. *Psychopathology* 2007; **40**: 61-64 [PMID: 17085960 DOI: 10.1159/000096685]
11. **Benzick JM**. Illusion or hallucination? Cholecystitis presenting as pseudopregnancy in schizophrenia. *Psychosomatics* 2000; **41**: 450-452 [PMID: 11015638 DOI: 10.1176/appi.psy.41.5.450]
12. **d’Orban PT**. Child stealing: A typology of female offenders. *Br J Criminology* 1976; **16**: 275-281
13. **Ahuja N**, Moorhead S, Lloyd AJ, Cole AJ. Antipsychotic-induced hyperprolactinemia and delusion of pregnancy. *Psychosomatics* 2008; **49**: 163-167 [PMID: 18354070 DOI: 10.1176/appi.psy.49.2.163]
14. **Makhal M**, Majumder U, Bandyopadhyay GK. Psychodynamic and socio-cultural perspective of pseudocyesis in a non-infertile Indian woman: a case report. *Malaysian J Psychiatry e- journal* 2013; **22**(1)
15. **Ibekwe PC**, Achor JU. Psychosocial and cultural aspects of pseudocyesis. *Indian J Psychiatry* 2008; **50**: 112-116 [PMID: 19742215 DOI: 10.4103/0019-5545.42398]
16. **Ouj U**. Pseudocyesis in a rural southeast Nigerian community. *J Obstet Gynaecol Res* 2009; **35**: 660-665 [PMID: 19751324 DOI: 10.1111/j.1447-0756.2008.00997.x]
17. **Seffah JD**. Sonography in chronic distension of the abdomen and apparent pregnancy. *Nigerian J Surgical Res* 2004; **6**: 53-55
18. **Oguntoyinbo AE**, Aboyeji AP. Clinical pattern of gynecological/early pregnancy complaints and the outcome of pelvic sonography in a private diagnostic center in Ilorin. *Niger J Clin Pract* 2011; **14**: 223-227 [PMID: 21860144 DOI: 10.4103/1119-3077.84023]
19. **Dafallah SE**. Pseudocyesis and infertility. *Saudi Med J* 2004; **25**: 964-965 [PMID: 15235713]
20. **Cohen LM**. A current perspective of pseudocyesis. *Am J Psychiatry* 1982; **139**: 1140-1144 [PMID: 7114306]
21. **Moselhy HF**, Conlon W. Delusion of pregnancy in acute psychiatric ward. *Eur J Psychiatry* 2000; **14**: 197-200
22. **Coltheart M**, Langdon R, McKay R. Schizophrenia and monothematic delusions. *Schizophr Bull* 2007; **33**: 642-647 [PMID: 17372282 DOI: 10.1093/schbul/sbm017]
23. **Coltheart M**. On the distinction between monothematic and polythematic delusions. *Mind Language* 2013; **28**: 103-11 [DOI: 10.1111/mila.12011]
24. **Kornischka J**, Schneider F. Delusion of pregnancy. A case report and review of the literature. *Psychopathology* 2003; **36**: 276-278 [PMID: 14571058 DOI: 10.1159/000073454]
25. **Basil B**, Mathews M. A couvade syndrome variant? *Psychosomatics* 2006; **47**: 363-364 [PMID: 16844901 DOI: 10.1176/appi.psy.47.4.363]
26. **Budur K**, Mathews M, Mathews M. Couvade syndrome equivalent? *Psychosomatics* 2013; **46**: 71-72 [PMID: 15765824 DOI: 10.1176/appi.psy.46.1.71]
27. **Chatterjee SS**, Nath N, Dasgupta G, Bhattacharyya K. Delusion of pregnancy and other pregnancy-mimicking conditions: Dissecting through differential diagnosis. *Med J Dr DY Patil University* 2014; **7**: 369-372 [DOI: 10.4103/0975-2870.128986]
28. **Sultana K**, Nazneen R, Ara I. Pseudocyesis: a case report on false pregnancy. *J Dhaka Med Coll* 2012; **21**: 235-237
29. **Yeh YW**, Kuo SC, Chen CY. Urinary tract infection complicated by urine retention presenting as pseudocyesis in a schizophrenic patient. *Gen Hosp Psychiatry* 2012; **34**: 101. e9-101. e10 [PMID: 21802733 DOI: 10.1016/j.genhosppsych.2011.06.008]
30. **El Ouazzani B**, El Hamaoui Y, Idrissi-Khamlichi N, Moussaoui D. [Recurrent pseudocyesis with polydipsia: a case report]. *Encephale* 2008; **34**: 416-418 [PMID: 18922245 DOI: 10.1016/j.encep.2007.09.006]
31. **Manjunatha N**, Saddichha S. Delusion of pregnancy associated with antipsychotic induced metabolic syndrome. *World*



- J Biol Psychiatry* 2009; **10**: 669-670 [PMID: 19096992 DOI: 10.1080/15622970802505800]
- 32 **Griengl H.** Delusional pregnancy in a patient with primary sterility. *J Psychosom Obstet Gynaecol* 2000; **21**: 57-59 [PMID: 10907216 DOI: 10.3109/01674820009075609]
  - 33 **Jeanty C, Ismail L, Turner CD.** Incidental findings during routine antepartum obstetrical sonography. *J Diagnostic Med Sonography* 2008; **24**: 344-360 [DOI: 10.1177/8756479308325465]
  - 34 **Larner AJ.** Delusion of pregnancy in frontotemporal lobar degeneration with motor neurone disease (FTLD/MND). *Behav Neurol* 2008; **19**: 199-200 [PMID: 19096144 DOI: 10.1155/2008/149086]
  - 35 **Larner AJ.** Delusion of pregnancy: a case revisited. *Behav Neurol* 2013; **27**: 293-294 [PMID: 23548882 DOI: 10.1155/2013/178406]
  - 36 **Simon M, Vörös V, Herold R, Fekete S, Tényi T.** Delusions of pregnancy with post-partum onset: an integrated, individualized view. *Eur J Psychiatr* 2009; **23**: 234-242 [DOI: 10.4321/S0213-61632009000400004]
  - 37 **Okeke T, Anyaehie U, Ezenyeaku C.** Premature menopause. *Ann Med Health Sci Res* 2013; **3**: 90-95 [PMID: 23634337 DOI: 10.4103/2141-9248.109458]
  - 38 **Ayakannu T, Wordsworth S, Smith R, Raghunandan R, Vine S.** Pseudocyesis in a teenager using long-term contraception. *J Obstet Gynaecol* 2007; **27**: 322-323 [PMID: 17464828 DOI: 10.1080/01443610701269119]
  - 39 **Riecher-Rössler A, Rybakowski JK, Pflueger MO, Beyrau R, Kahn RS, Malik P, Fleischhacker WW.** Hyperprolactinemia in antipsychotic-naïve patients with first-episode psychosis. *Psychol Med* 2013; **43**: 2571-2582 [PMID: 23590895 DOI: 10.1017/S0033291713000226]
  - 40 **López MAC, Rodríguez JLR, García MR.** Physiological and pathological hyperprolactinemia: can we minimize errors in the clinical practice? In: Nagy GM, Toth BE, editors. *Prolactin*. Rijeka, Croatia: InTech, 2013: 213-230 [DOI: 10.5772/54758]
  - 41 **Peuskens J, Pani L, Detraux J, De Hert M.** The effects of novel and newly approved antipsychotics on serum prolactin levels: a comprehensive review. *CNS Drugs* 2014; **28**: 421-453 [PMID: 24677189 DOI: 10.1007/s40263-014-0157-3]
  - 42 **Ahuja N, Vasudev K, Lloyd A.** Hyperprolactinemia and delusion of pregnancy. *Psychopathology* 2008; **41**: 65-68 [PMID: 17975330 DOI: 10.1159/000110628]
  - 43 **Ali JA, Desai KD, Ali LJ.** Delusions of pregnancy associated with increased prolactin concentrations produced by antipsychotic treatment. *Int J Neuropsychopharmacol* 2003; **6**: 111-115 [PMID: 12890303 DOI: 10.1017/S1461145703003365]
  - 44 **Grover S, Sharma A, Ghormode D, Rajpal N.** Pseudocyesis: A complication of antipsychotic-induced increased prolactin levels and weight gain. *J Pharmacol Pharmacother* 2013; **4**: 214-216 [PMID: 23960430 DOI: 10.4103/0976-500X.114610]
  - 45 **Levy F, Mouchabac S, Peretti CS.** [Etiopathogeny of the delusion of pregnancy using a literature review: Role of hyperprolactinemia and application of the theory of abductive inference]. *Encephale* 2014; **40**: 154-159 [PMID: 23830681 DOI: 10.1016/j.encep.2013.04.008]
  - 46 **Marusic S, Karlovic D, Zoricic Z, Martinac M, Jokanovic L.** Pseudocyesis: a case report. *Acta Clin Croat* 2005; **44**: 291-295
  - 47 **Penta ER, Lasalvia A.** Delusion of pregnancy in a drug-naïve young woman showing hyperprolactinemia and hypothyroidism: a case report. *Gen Hosp Psychiatry* 2013; **35**: 679.e1-679.e3 [DOI: 10.1016/j.genhosppsych.2013.03.001]
  - 48 **Ruzanna Z, Marhani M.** Bridging a Malay mystical belief and psychiatry: a case of fetus 'stolen' by orang bunian in advanced pregnancy. *Malaysian J Psychiatry (e-Journal)* 2010; **17**: 1-4
  - 49 **Koic E, Muzinic L, Dordevic V, Vondracek S.** Pseudocyesis and couvade syndrome. *Drustvena Istrazivanja. J Gen Soc Issues* 2002; **11**: 1031-1047
  - 50 **Lennartsson AK, Jonsdottir IH.** Prolactin in response to acute psychosocial stress in healthy men and women. *Psychoneuroendocrinology* 2011; **36**: 1530-1539 [PMID: 21621331 DOI: 10.1016/j.psyneuen.2011.04.007]
  - 51 **Skrabic V, Vlastelica Z, Vucinovic Z.** Pseudocyesis as a cause of abdomen enlargement in a female adolescent. *Central Eur J Med* 2011; **6**: 720-722 [DOI: 10.2478/s11536-011-0086-1]
  - 52 **Bianchi-Demicheli F, Lüdicke F, Chardonens D.** Imaginary pregnancy 10 years after abortion and sterilization in a menopausal woman: a case report. *Maturitas* 2004; **48**: 479-481 [PMID: 15283942 DOI: 10.1016/j.maturitas.2003.09.030]
  - 53 **Habek D.** Pseudocyesis in peri- and postmenopausal women. *Central Eur J Med* 2010; **5**: 372-374 [DOI: 10.2478/s11536-009-0084-8]
  - 54 **Lindgren BM, Sundbaum J, Eriksson M, Graneheim UH.** Looking at the world through a frosted window: experiences of loneliness among persons with mental ill-health. *J Psychiatr Ment Health Nurs* 2014; **21**: 114-120 [PMID: 23530616 DOI: 10.1111/jpm.12053]
  - 55 **Qureshi NA, Al-Habeeb TA, Al-Ghamdy YS, Abdelgadir MH, Quinn JG.** Delusions of pregnancy in Saudi Arabia: a socio-cultural perspective. *Transcult Psychiatry* 2001; **38**: 231-242 [DOI: 10.1177/136346150103800206]
  - 56 **Sule-Odu AO, Fakoya TA, Oluwole FA, Ogundahunsi OA, Olowu AO, Olanrewaju DM, Akesode FA, Dada OA, Sofekun EA.** Postpartum sexual abstinence and breastfeeding pattern in Sagamu, Nigeria. *Afr J Reprod Health* 2008; **12**: 96-100 [PMID: 20695161]
  - 57 **Adesiyun AG, Ameh N, Bawa U, Adamu H, Kolawole A.** Calabash pregnancy: a malingered response to infertility complicated by domestic violence. *West Indian Med J* 2012; **61**: 198-201 [PMID: 23155970]
  - 58 **Dyer SJ, Abrahams N, Hoffman M, van der Spuy ZM.** 'Men leave me as I cannot have children': women's experiences with involuntary childlessness. *Hum Reprod* 2002; **17**: 1663-1668 [PMID: 12042295 DOI: 10.1093/humrep/17.6.1663]
  - 59 **Stephenson R, Koenig MA, Ahmed S.** Domestic violence and symptoms of gynecologic morbidity among women in North India. *Int Fam Plan Perspect* 2006; **32**: 201-208 [PMID: 17237017 DOI: 10.1363/3220106]
  - 60 **Ameh N, Kene TS, Onuh SO, Okohue JE, Umeora OU, Anozie OB.** Burden of domestic violence amongst infertile women attending infertility clinics in Nigeria. *Niger J Med* 2007; **16**: 375-377 [PMID: 18080600]
  - 61 **Upadhyay S.** Pseudocyesis. *JNMA J Nepal Med Assoc* 2008; **47**: 147-150 [PMID: 19079383]
  - 62 **Greil AL, McQuillan J, Slauson-Blevins K.** The social construction of infertility. *Sociol Compass* 2011; **5**: 736-746 [DOI: 10.1111/j.1751-9020.2011.00397.x]
  - 63 **Chachamovich JR, Chachamovich E, Zachia S, Knauth D, Passos EP.** What variables predict generic and health-related quality of life in a sample of Brazilian women experiencing infertility? *Hum Reprod* 2007; **22**: 1946-1952 [PMID: 17428881 DOI: 10.1093/humrep/dem080]
  - 64 **Monga M, Alexandrescu B, Katz SE, Stein M, Ganiats T.** Impact of infertility on quality of life, marital adjustment, and sexual function. *Urology* 2004; **63**: 126-130 [PMID: 14751363 DOI: 10.1016/j.urolgy.2003.09.015]
  - 65 **Islam S, Nordin RB, Bin Shamsuddin AR, Mohd Nor HB, Al-Mahmood AK.** Ethics of surrogacy: a comparative study of Western secular and Islamic bioethics. *J IMA* 2012; **44**: [PMID: 23864994 DOI: 10.5915/44-1-5920]
  - 66 **Pollack D, Bleich M, Reid Jr CJ, Fadel MH.** Classical religious perspectives of adoption law. *Notre Dame Law Rev* 2004; **79**: 693-753
  - 67 **Greil AL, Slauson-Blevins K, McQuillan J.** The experience of infertility: a review of recent literature. *Sociol Health Illn* 2010; **32**: 140-162 [PMID: 20003036 DOI: 10.1111/j.1467-9566.2009.01213.x]
  - 68 **Hollos M.** Profiles of infertility in southern Nigeria: women'



- s voices from Amakiri. *Afr J Reprod Health* 2003; **7**: 46-56 [PMID: 14677300 DOI: 10.2307/3583213]
- 69 **Throsby K**, Gill R. "It's different for men" masculinity and IVF. *Men and Masculinities* 2004; **6**: 330-348 [DOI: 10.1177/1097184X03260958]
  - 70 **Upkong D**, Orji E. [Mental health of infertile women in Nigeria]. *Turk Psikiyatri Derg* 2006; **17**: 259-265 [PMID: 17183442]
  - 71 **Rouchou B**. Consequences of infertility in developing countries. *Perspect Public Health* 2013; **133**: 174-179 [PMID: 23327901 DOI: 10.1177/1757913912472415]
  - 72 **Bittles AH**. Consanguineous marriage and childhood health. *Dev Med Child Neurol* 2003; **45**: 571-576 [PMID: 12882538 DOI: 10.1111/j.1469-8749.2003.tb00959.x]
  - 73 **Mutia B**. Performer, audience, and performance context of Bakweri pregnancy rituals and incantations. *Cahiers d'Etudes Africaines* 2005; **1**: 218-237. Available from: URL: <http://etudesafricaines.revues.org/4942>
  - 74 **Mishara AL**. Klaus Conrad (1905-1961): delusional mood, psychosis, and beginning schizophrenia. *Schizophr Bull* 2010; **36**: 9-13 [PMID: 19965934 DOI: 10.1093/schbul/sbp144]
  - 75 **Schneider K**. *Clinical Psychopathology*. New York: Grune and Stratton, 1959
  - 76 **Jakes S**, Rhodes J, Issa S. Are the themes of delusional beliefs related to the themes of life problems and goals? *J Ment Health* 2004; **13**: 611-619 [DOI: 10.1080/09638230400024877]
  - 77 **Roberts G**. Delusional belief systems and meaning in life: a preferred reality? *Br J Psychiatry Suppl* 1991; **(14)**: 19-28 [PMID: 1840775]
  - 78 **Mansouri A**, Adityanjee A. Delusion of pregnancy in males. *Psychopathology* 1995; **28**: 307-311 [DOI: 10.1159/000284942]
  - 79 **Ghaemi SN**. The perils of belief: Delusions reexamined. *PPP* 2004; **11**: 49-54 [DOI: 10.1353/ppp.2004.0040]

P- Reviewer: Kahyaoglu S, Traub M S- Editor: Song XX  
L- Editor: A E- Editor: Lu YJ



## Tree stand falls: A persistent cause of neurological injury in hunting

Clifford A Pierre, Benjamin A Plog, Vasisht Srinivasan, Kaushik Srinivasan, Anthony L Petraglia, Jason H Huang

Clifford A Pierre, Benjamin A Plog, School of Medicine and Dentistry, University of Rochester, Rochester, NY 14623, United States  
Vasisht Srinivasan, Jason H Huang, Department of Neurosurgery, University of Rochester Medical Center, Rochester, NY 14642, United States

Kaushik Srinivasan, School of Law, Case Western Reserve University, Cleveland, OH 44106, United States

Anthony L Petraglia, Department of Neurosurgery, Rochester Regional Health System, Rochester, NY 14626, United States

Author contributions: Pierre CA and Plog BA were responsible for the majority of the data collection; Pierre CA wrote the manuscript; Srinivasan V and Srinivasan K were responsible for manuscript editing, data analysis, and statistical work; Petraglia AL conceived and designed the study and was involved with manuscript editing and data analysis; Huang JH helped design the study and assisted with manuscript preparation.

Correspondence to: Anthony L Petraglia, MD, Department of Neurosurgery, Rochester Regional Health System, 2655 Ridgeway Avenue, Suite 340, Rochester, NY 14626, United States. [apetraglia@unityhealth.org](mailto:apetraglia@unityhealth.org)

Telephone: +1-585-2750060 Fax: +1-585-7565183

Received: March 24, 2014 Revised: May 11, 2014

Accepted: June 18, 2014

Published online: August 16, 2014

### Abstract

**AIM:** To characterize and compare our current series of patients to prior reports in order to identify any changes in the incidence of neurological injury related to hunting accidents in Rochester, New York.

**METHODS:** All tree stand-related injuries referred to our regional trauma center from September 2003 through November 2011 were reviewed. Information was obtained from the hospital's trauma registry and medical records were retrospectively reviewed for data pertaining to the injuries.

**RESULTS:** Fifty-four patients were identified. Ninety-six percent of patients were male with a mean age of

47.9 years (range 15-69). The mean Injury Severity Score was  $12.53 \pm 1.17$  (range 2-34). The average height of fall was 18.2 feet (range 4-40 feet). All patients fell to the ground with the exception of one who landed on rocks, and many hit the tree or branches on the way down. A reason for the fall was documented in only 13 patients, and included tree stand construction (3), loss of balance (3), falling asleep (3), structural failure (2), safety harness breakage (3) or light-headedness (1). The most common injuries were spinal fractures (54%), most commonly in the cervical spine (69%), followed by the thoracic (38%) and lumbar (21%) spine. Eight patients required operative repair. Head injuries occurred in 22%. Other systemic injuries include rib/clavicular fractures (47%), pelvic fractures (11%), solid organ injury (23%), and pneumothorax or hemothorax (19%). No patient deaths were reported. The average hospital length of stay was  $6.56 \pm 1.07$  d. Most patients were discharged home without (72%) or with (11%) services and 17% required rehabilitation.

**CONCLUSION:** Falls from hunting tree stands are still common, with a high rate of neurological injury. Compared to a decade ago we have made no progress in preventing these neurological injuries, despite an increase in safety advances. Neurosurgeons must continue to advocate for increased safety awareness and participate in leadership roles to improve outcomes for hunters.

© 2014 Baishideng Publishing Group Inc. All rights reserved.

**Key words:** Neurological sports medicine; Hunting; Tree stand falls; Spine injury; Traumatic brain injury

**Core tip:** Hunting is a popular sport and hunters have devised numerous ways to increase their advantage against their quarry. Tree stands have been developed to allow hunters better sight and increased protection. However, improper use, faulty construction, and other factors can increase the risk of injury, specifically to the

central nervous system. We present the data obtained at our institution over an eight-year period cataloging the injuries obtained while using tree stands. We have begun outreach to the community with our findings, with the goal of increasing awareness and education to reduce risks and increase hunter safety.

Pierre CA, Plog BA, Srinivasan V, Srinivasan K, Petraglia AL, Huang JH. Tree stand falls: A persistent cause of neurological injury in hunting. *World J Clin Cases* 2014; 2(8): 345-350 Available from: URL: <http://www.wjgnet.com/2307-8960/full/v2/i8/345.htm> DOI: <http://dx.doi.org/10.12998/wjcc.v2.i8.345>

## INTRODUCTION

Hunting is a popular sport and recreational activity nationwide, with nearly 15 million licensed hunters in the United States and approximately 680000 in New York State according to the Fish and Wildlife Service<sup>[1]</sup>. Hunting is a favorite pastime for those in the Rochester, NY area that spans all age ranges. Hunters age 12 and above may obtain a hunting license in New York and most use bows or firearms to hunt a variety of wildlife animals. Over time, hunters have developed various methods to improve the leisure of the sport. One such method is the elevated tree stand.

Tree stands, also referred to as deer stands, are elevated platforms or seats that can be built in, nailed, locked, or rested up against a tree. Stands give hunters an advantage of wider visibility, while decreasing the chances of being detected by sight or scent<sup>[2-4]</sup>. Hunting tree stands can be commercial or homemade, and are usually installed 15 to 30 feet above ground. Commercial tree stands typically have a two-by-two feet platform seat, and may or may not be attached to the tree by safety belts, a harness, or straps. These safety straps are designed to help prevent the hunter from falling from the tree or stand.

Hunting related accidents and injuries have been largely attributed to falls from tree stands<sup>[2]</sup>. This is the most common way hunters are injured, debunking the popular misconception of intoxicated hunters sustaining self-inflicted ballistic injuries<sup>[5]</sup>. Estimates reveal that nearly 10% of hunters who use tree stands are injured annually, and more than 75% of tree stand injuries occur while using fixed position or climbing stands<sup>[6]</sup>. As much as 75% of the time spent during a hunt is spent on tree stands, and tree stands are considered an essential component of large game hunting<sup>[6]</sup>. In North America, nearly 85% of hunters pursue large game (*e.g.*, deer, elk, bear, turkey, *etc.*), suggesting that the overwhelming majority of hunters have or will at some point use a tree stand<sup>[6]</sup>. When hunters fall from tree stands, they can reach a velocity of up to 30 mph. Yet these common hunting-related accidents often go unreported as victims only present to hospitals with serious injuries<sup>[3,4,7]</sup>.

Falls from tree stands can lead to high impact injuries. One study demonstrated that 80% of fall victims required operative interventions, and nearly 10% of falls resulted in permanent neurological deficits or death<sup>[5]</sup>. The series of common injuries were fractures to the spinal cord, lower extremities, and traumatic brain injuries. The high morbidity of falls from tree stands have led to a small series of interventions to prevent devastating spinal cord injury through promoting the use of safety harnesses publicly<sup>[8]</sup>. It appears these interventions were successful as the incidence of tree-stand associated accidents was significantly reduced.

A previous study conducted nearly a decade ago at a Level I trauma center and Medical Examiner's offices in Western New York and central Maryland previously identified 51 cases of tree-stand associated injuries over a 5-year period<sup>[2]</sup>. The majority of injuries were spinal and extremity fractures. The most frequent reported reasons for falls were related to errors in placement of the stand with subsequent structural failure, and errors climbing in or out of the tree stand<sup>[2]</sup>. The need for hunter education was emphasized and the implementation of trauma prevention programs was suggested.

Our objective was to compile the current series of patients and the frequency and types of injuries they sustained. Additionally we wanted to compare our results to prior reports to identify any changes in the incidence of neurological injury related to tree stand hunting accidents.

## MATERIALS AND METHODS

All tree stand-related injuries evaluated at the University of Rochester Medical Center's Emergency Department between September 2003 and November 2011 were reviewed. Information was obtained from hospital's trauma registry, and medical records were retrospectively reviewed for data pertaining to the injuries, with particular emphasis on neurological injuries and any associated details. The patients were identified based ICD-9 codes (*e.g.*, E884.9: fall from one level to another) and further review of the charts allowed us to select only falls that were sustained while hunting from a tree stand. Further data collected from the trauma registry included age, gender, Injury Severity Score (ISS), Glasgow Coma Score at the time of patient arrival, vital signs, intensive care unit (ICU) and hospital lengths of stay (LOS), procedures, and discharge disposition. The study was approved by the University of Rochester Medical Center institutional review board, and all investigators completed training in protection of human subjects.

## RESULTS

A total of 54 patients were identified with tree stand related injuries during the study period. Ninety-six percent of tree-stand associated falls occurred in men. The mean age was 47.9 years (range, 15-69). The mean Injury Severity Score was  $12.53 \pm 1.17$  (range, 2-34). The aver-

**Table 1** Demographics and categorization of injuries

Metric	If not specified (n = 54)
Age (years with range)	47.9 (15–69)
Male gender	(96)
Average fall (ft with range)	18.2 (4–40)
Average length of stay	6.56 ± 1.07
Disposition	
Home	(72)
Home with services	(11)
Rehabilitation	(17)

**Table 2** Reasons reported cause of falls n (%)

Reported reason	Falls (n = 13)
Tree stand construction	3 (23)
Loss of balance	3 (23)
Falling asleep	3 (23)
Structural failure	2 (15)
Lightheadedness	1 (8)
Other	1 (8)

age height of fall was 18.2 feet (range, 4–40 feet) (Table 1). No correlation could be drawn from records between height of the fall and the severity of the injuries. All patients fell to the ground with exception of one patient falling onto rocks, and many hit the tree or branches on the way down. There were no patient deaths related to tree stand falls. The direct mechanism contributing to the fall were documented in only 13 patients, and included tree stand construction (3 patients), loss of balance (3 patients), falling asleep (3 patients), structural failure (2 patients), safety harness breaking (3 patients) or “light-headedness” (1 patient) (Table 2).

The most common injuries sustained were spinal fractures (54%). In these patients, fractures to the cervical spine were the most common (69%), followed by the thoracic (38%) and lumbar (21%) spine. These injuries included burst fractures, compression fractures, dislocations, and spinal cord transections. One patient sustained injuries resulting in immediate C5 quadriplegia, while another was paraplegic. Eight patients went to the operating room for fusion (Table 3). The remaining patients were treated nonoperatively with bracing and pain control.

The tree stand falls resulted in head injuries in 22% of patients (Table 3). Five patients suffered from facial lacerations. In addition, seven patients experienced loss of consciousness throughout the course of injury.

Thoracic injury was a common injury in many of the patients in this group. Pulmonary contusion was noted in four patients (7%). In 10 cases, patients developed a pneumothorax or hemothorax (19%), and eight of these patients were treated with a chest tube (Table 4). The other associated non-neurological injuries include injuries to the thorax such as rib/clavicle fractures (47%), pelvic fractures (11%), and abdominal solid organ injury involving lacerations to the liver, spleen, or kidney (23%) (Table 4).

**Table 3** Neurological injuries resulting from tree stand falls

Injury	Patients (n = 54)
Spinal column	(54)
Cervical spine	(69)
Thoracic spine	(38)
Lumbar spine	(21)
Requiring surgery	(15)
Cranial vault/brain	(22)

**Table 4** Non-neurological injuries resulting from tree stand falls n (%)

Injury	Patients (n = 54)
Orthopedic	
Upper extremity	10 (19)
Lower extremity	13 (24)
Hip/pelvis	6 (11)
Abdominal	
Liver	2 (4)
Kidney	3 (6)
Spleen	5 (9)
Other	2 (4)
Thoracic	
Pulmonary contusion	4 (7)
Pneumo-/hemothorax	10 (19)
Rib fractures	22 (41)
Clavicle fracture	3 (6)
Scapula fracture	1 (2)
Sternal fracture	3 (6)

Patients endured extremity fractures in 54% of the cases. The common injuries included fractures of the lower extremity affecting the tibia, fibula, foot, and ankle (24%), upper extremity affecting the humerus, radius, and ulna (19%), and hip and pelvis (11%) (Table 4). Fourteen patients went to the operating room for repair of extremity fractures.

The average hospital LOS was 6.56 ± 1.07. One patient required ICU care for 3 d. The discharge plans were home (72%), home with services (11%), and rehabilitation placement (17%) (Table 1).

## DISCUSSION

Hunting in the American outdoors remains a unique and popular recreational activity for all ages during various times of the year. A myriad of game animals (*e.g.*, rabbit, pheasants, deer, *etc.*) are hunted with a variety of weapons from bows to shotguns or rifles<sup>[9]</sup>. Hunters have become increasingly savvy in their techniques to evade detection from their prey; one tool has been the use of tree stands or elevated platforms. Tree stands have given hunters an advantage of wider visibility without revealing their position by sight or scent<sup>[2,3]</sup>. However, with this advantage comes the increased risk of injury associated with falls during the use of these stands. The tree stands may be difficult to carry, offer minimal room for movement, and do not protect against poor weather<sup>[10]</sup>. Tree stands are typically located 15 to 30 feet above ground and can be



attached to the tree by nails, locks, or straps. The patients in our study fell from a similar height (mean fall height of 18.2 feet). As these individuals fall, the impact surface of their landing can be on hard surfaces, logs, and parts of hunting equipment adding another factor to the injury<sup>[5]</sup>.

One particular study outlines that the duration of the impact force from the nature of the surface is the most important predictor of injury severity<sup>[3]</sup>. Several other studies in the literature report serious injuries related to tree stand fall<sup>[2,8]</sup>. By and large, the incidence of tree stand falls and related injuries has become one of the leading causes of hunting-related incidents. This information debunks the popular misconception that intoxicated hunters sustain self-inflicted ballistic injuries as a leading cause of hunting-related incidents. In 2010, Crockett *et al*<sup>[5]</sup> discovered that 50% of the patients in their series sustained falls from tree stands compared to 29% that endured gunshot wounds in central Ohio. In our study we sought to characterize a current series of patients and compare them to prior reports in order to identify any changes in the incidence of neurological injury related to such hunting accidents. These efforts would help highlight areas to prevent the dangerous injuries from tree stand falls and improve patient safety measures through education.

There are several types of tree stands available. Some are made by commercial manufacturers using metal materials and others are homemade by hunters using wood. Only stands approved by the Tree Stand Manufacturers Association should be used, as many of the homemade types are discouraged due to deterioration of wood over time<sup>[11]</sup>. The Tree Stand Manufacturers Association (TMA), a group of corporations organized for the promotion of safe hunting practices, estimates millions of tree stand units are sold each year in the United States. One limitation of our study is that the type of tree stand used by our patients was not information available to us.

We identified 54 cases of tree stand related injuries over an 8-year period at the University of Rochester Medical Center. Our result remains consistent with the previous study done at this trauma center that detected 27 cases over a 5-year period<sup>[2]</sup>. Our current study observed that tree stand falls continues to make up a significant portion of hunting related accidents. Consequently, prior efforts to reduce the morbidity and mortality associated with tree stand falls have not been successful. This evidence suggests that tree stand safety must remain a priority for hunters and health care providers. The most common mechanisms of the injury pattern noted in our study were due to tree stand construction, structural failure, loss of balance, falling asleep, structural failure, and the safety harness breaking. In some cases patients were unsure of how they had fallen as some were amnesic to the incident. All of these contributing factors of injury indicated that further instruction is required in New York State to ensure the safety of licensed hunters. New York requires a mandatory hunter education course for a minimum 10 h in length<sup>[12]</sup>. While hunters are mandated to take a course, we recommend stronger measures to

ensure hunters acquire the information needed to safely operate tree stands (*e.g.*, periodic testing of proper use by Safety Course instructors).

Due to the large number of patients injured as a result of preventable causes, an educational safety course is warranted and further instruction to hunters is necessary to ensure more compliance with these guidelines. During these Hunter's Safety Courses offered by the state or county governments the quantity and severity of these neurological injury patterns, extended hospitalizations, and permanent disability needs to be addressed in more length to provide greater awareness. Additional instruction on adherence to the regulations while hunting should be emphasized; for example, the need to exercise extreme precaution when entering or exiting the tree stand, and the need to wear a safety harness at all times. Emphasis on proper techniques need to be made to ensure hunters pay more attention when they hoist or lower items from the tree stand in a safe manner. Hunters should avoid hunting when fatigued, use communication devices, restrict alcohol or drug while hunting, hunt in groups, and only hunt during times specified by local or state regulations.

Active awareness to hunters has been proven to reduce the incidence of tree stand related trauma. In Louisiana, letters were sent to licensed hunters, hunting clubs, sporting goods stores, and hunting supply retailers across the state that detailed the risks associated with tree stand use without a safety device<sup>[3,8,13]</sup>. In the 3 years following this active awareness campaign, there were no spinal cord injuries from tree stand related incidents. Rochester, NY and other areas with active tree stand hunters will greatly benefit from similar campaign efforts.

Tree stand manufacturers add specific guidelines to the products they produce and encourage the strict use of wearing a full body safety harnesses<sup>[14]</sup>. Review of the medical records at Strong Memorial Hospital did not include information regarding safety harnesses. This may be due to recall bias from post-concussive amnesia, or insufficient information surrounding the circumstances of the injury. However prior studies have specifically documented the lack of a safety harness as a contributing mechanism<sup>[2,3]</sup>, and we speculate that the absence of this information may suggest these safety devices were not used.

Injuries sustained from tree stand falls often require operative or other interventions that can increase the total cost to the healthcare system<sup>[7]</sup>. In an era where healthcare costs are carefully monitored, any preventive efforts that can reduce the overall cost of care and diminish the long-term costs for permanently disabled patients should be investigated and pursued. Additionally early identification of injured patients and a thorough assessment of their injuries are critical to improving outcomes<sup>[3]</sup>. Though it is tempting to focus on the intracranial and spinal pathologies, non-neurological injuries must not be minimized in the evaluation of these types of patients as tree stand falls do result in significant thoracic, abdomi-

nal, and pelvic trauma. A complete trauma assessment must be performed for each patient and all injuries thoroughly documented and treated in a timely fashion.

While we attempted to catalogue and describe the incidence of all tree-stand related injuries, our work is not without limitations. First, while all injuries that were deemed by the injured party or their associates were brought for hospital evaluation, it is reasonable to assume that hunters who sustained injuries may have declined to seek medical attention. The lack of any obvious trauma following a fall also may have prevented hunters from evaluation. Our series also does not capture those patients who sustained injuries at regional, community hospitals but whose injuries were not severe enough to warrant transfer to our facility. Lastly, while a thorough search for all patients was attempted, using ICD-9 codes as an initial filter may have missed patients whose diagnoses were not accurately documented at the time of their presentation.

From an international standpoint, hunting, as both a source of food and recreation, has been enjoyed by civilizations for thousands of years. Indian emperors would routinely employ elephants to hunt for wild game, and European monarchs often enjoyed fox and boar hunting as a sport while on horseback. However, from our search, tree stands appear to be a more modern invention that are primarily used in North America. Literature searches yielded no published data on hunting accidents outside of North America, and most international hunting and safety organizations focus their attention to this area as well.

In light of this data, more awareness and education are sorely needed. To this end, the authors have utilized the findings from this paper in local print and television media to educate the local community on the continued prevalence of tree stand injuries. A campaign has been initiated in New York to better educate hunters, with the aim of formally incorporating this study's findings in novel educational material for the New York State hunter safety educational curriculum.

Hunting remains an attractive recreational activity and the methodical use of tree stands have made hunters more effective at game hunting. This study reveals that nearly 10 years later, tree stand falls remain a significant cause of life-threatening neurological injury and subsequent disability. Increased awareness by healthcare providers and implementation of prevention strategies is critical to reducing the incidence of injuries sustained while hunting with tree stands. These prevention strategies can be taught during hunter safety education courses. All hunters should be made aware of the preventable risk factors that contribute to injury (structural failure, fatigue, lack of sleep, and drug and alcohol use). Additionally, hunters should be licensed and properly educated on the safe and proper use of tree stand and associated equipment (*e.g.*, safety harness), and ensure that equipment is in proper working condition on a routine basis. Tree stand manufacturers can aid in these hunter education preven-

tion programs by giving more support to efforts for the hunter's safety. Health care providers can also aid safety and education efforts, as physicians who treat these hunters may advocate for these prevention efforts to reduce incidence of neurologic injury during hunting.

## ACKNOWLEDGMENTS

The authors thank Gina Ryan, RN, BSN and Krista Sokolowski, RN, MS, at the University of Rochester Regional Trauma Center at Strong Memorial Hospital who accumulated the data from the hospital trauma registry.

## COMMENTS

### Background

The role of tree stands in hunting accidents has been investigated to determine the incidence of injuries involving these devices. This study also compared current data with data obtained nearly a decade ago to identify any trends that have changed.

### Research frontiers

Neurotrauma, public health.

### Innovations and breakthroughs

Despite improvements in medical care, tree stand injuries continue to occur with no real abatement in incidence. Other states have instituted public health campaigns to educate hunters of the risks and these efforts have reduced rates of injury.

### Terminology

Tree stands are devices used by hunters to give them a seat at an elevated position in a tree to observe wild game.

### Peer review

This is a well-written study on hunting related injuries due to tree stand falls. The topic is interesting, important, and not sufficiently researched and the findings will hopefully raise awareness on safety issues. The study is well-designed and the findings are adequately presented. The discussion is balanced and informative.

## REFERENCES

- 1 NSSF Reports Big Jump in Hunting License Sales. "National Shooting Sports Foundation, Inc." Available from: URL: [http://www.nssf.org/share/PDF/USFWS\\_2009\\_States.pdf](http://www.nssf.org/share/PDF/USFWS_2009_States.pdf). Accessed September 10, 2012
- 2 Metz M, Kross M, Abt P, Bankey P, Koniaris LG. Tree stand falls: a persistent cause of sports injury. *South Med J* 2004; **97**: 715-719 [PMID: 15352662 DOI: 10.1097/00007611-200408000-00003]
- 3 Gates RL, Helmkamp JC, Wilson SL, Denning DA, Beaver BL. Deer stand-related trauma in West Virginia: 1994 through 1999. *J Trauma* 2002; **53**: 705-708 [PMID: 12394870 DOI: 10.1097/00005373-200210000-00014]
- 4 Urquhart CK, Hawkins ML, Howdieshell TR, Mansberger AR. Deer stands: a significant cause of injury and mortality. *South Med J* 1991; **84**: 686-688 [PMID: 2052953]
- 5 Crockett A, Stawicki SP, Thomas YM, Jarvis AM, Wang CF, Beery PR, Whitmill ML, Lindsey DE, Steinberg SM, Cook CH. Tree stands, not guns, are the midwestern hunter's most dangerous weapon. *Am Surg* 2010; **76**: 1006-1010 [PMID: 20836352]
- 6 Terry J, Griffin R, Rue LW, McGwin G. Epidemiology of tree stand-related injuries in the United States from 2000 to 2007. *J Trauma* 2010; **68**: 712-715 [PMID: 20032794 DOI: 10.1097/TA.0b013e3181a3a903]
- 7 Fayssoux RS, Tally W, Sanfilippo JA, Stock G, Ratliff JK, Anderson G, Hilibrand AS, Albert TJ, Vaccaro AR. Spinal

- injuries after falls from hunting tree stands. *Spine J* 2008; **8**: 522-528 [PMID: 18023620]
- 8 **Lawrence DW**, Gibbs LI, Kohn MA. Spinal cord injuries in Louisiana due to falls from deer stands, 1985-1994. *J La State Med Soc* 1996; **148**: 77-79 [PMID: 8746165]
- 9 **Zilkens G**, Zilkens C, Zilkens J, Jäger M. Injury pattern due to falls from hunting stands. *Orthop Rev (Pavia)* 2011; **3**: e10 [PMID: 22053251 DOI: 10.4081/or.2011.e10]
- 10 **Shields LB**, Stewart D. Deer stand fatalities in Kentucky: two cases of reverse suspension and blunt force trauma. *Am J Forensic Med Pathol* 2011; **32**: 39-43 [PMID: 21304286 DOI: 10.1097/PAF.0b013e3181eafe05]
- 11 **Christensen TL**, Brandes SB. Urologic injuries sustained after free falls from hunting tree stands. *South Med J* 2008; **101**: 383-387 [PMID: 18360347 DOI: 10.1097/SMJ.0b013e318167a851]
- 12 "New York State - Department of Environmental Conservation" Available from: URL: <http://www.dec.ny.gov/permits/6094.html>. Accessed September 2012
- 13 **Smith JL**, Lengerich EJ, Wood GC. Injuries due to falls from hunters' tree stands in Pennsylvania. *Am J Prev Med* 2009; **37**: 433-436 [PMID: 19840698 DOI: 10.1016/j.amepre.2009.06.019]
- 14 **Treestand Manufacturers Association**. Tree stand safety guidelines. Available from: URL: <http://www.tmastands.com>. Accessed Aug 2012

**P- Reviewer:** Alves J, Hortobagyi T, Terzi R **S- Editor:** Ji FF  
**L- Editor:** A **E- Editor:** Lu YJ



## Intracerebroventricular opiate infusion for refractory head and facial pain

Darrin J Lee, Gene G Gurkoff, Amir Goodarzi, J Paul Muizelaar, James E Boggan, Kiarash Shahlaie

Darrin J Lee, Gene G Gurkoff, Amir Goodarzi, J Paul Muizelaar, James E Boggan, Kiarash Shahlaie, Department of Neurological Surgery, School of Medicine, University of California, Davis, CA 95817, United States

**Author contributions:** Lee DJ, Muizelaar JP, Boggan JE and Shahlaie K contributed to substantial contributions to concept/design, acquisition of data, analysis of data, drafting/revising article, approval of final version; Gurkoff GG and Goodarzi A contributed to substantial contributions to analysis of data, drafting/revising article, approval of final version.

**Correspondence to:** Kiarash Shahlaie, MD, PhD, Assistant Professor, Department of Neurological Surgery, School of Medicine, University of California, 4860 Y Street, Suite 3740 Sacramento, Davis, CA 95817,

United States. [kiarash.shahlaie@ucdmc.ucdavis.edu](mailto:kiarash.shahlaie@ucdmc.ucdavis.edu)

Telephone: +1-916-7346342 Fax: +1-916-7345006

Received: December 17, 2013 Revised: June 6, 2014

Accepted: June 27, 2014

Published online: August 16, 2014

### Abstract

**AIM:** To study the risks and benefits of intracerebroventricular (ICV) opiate pumps for the management of benign head and face pain.

**METHODS:** Six patients with refractory trigeminal neuralgia and/or cluster headaches were evaluated for implantation of an ICV opiate infusion pump using either ICV injections through an Ommaya reservoir or external ventricular drain. Four patients received morphine ICV pumps and two patients received a hydromorphone pump. Of the four patients with morphine ICV pumps, one patient had the medication changed to hydromorphone. Preoperative and post-operative visual analog scores (VAS) were obtained. Patients were evaluated post-operatively for a minimum of 3 mo and the pump dosage was adjusted at each outpatient clinic visit according to the patient's pain level.

**RESULTS:** All 6 patients had an intracerebroventricular

opiate injection trial period, using either an Ommaya reservoir or an external ventricular drain. There was an average VAS improvement of 75.8%. During the trial period, no complications were observed. Pump implantation was performed an average of 3.7 wk (range 1-7) after the trial injections. After implantation, an average of  $20.7 \pm 8.3$  dose adjustments were made over 3-56 mo after surgery to achieve maximal pain relief. At the most recent follow-up (26.2 mo, range 3-56), VAS scores significantly improved from an average of  $7.8 \pm 0.5$  (range 6-10) to  $2.8 \pm 0.7$  (range 0-5) at the final dose (mean improvement  $5.0 \pm 1.0$ ,  $P < 0.001$ ). All patients required a stepwise increase in opiate infusion rates to achieve maximal benefit. The most common complications were nausea and drowsiness, both of which resolved with pump adjustments. On average, infusion pumps were replaced every 4-5 years.

**CONCLUSION:** These results suggest that ICV delivery of opiates may potentially be a viable treatment option for patients with intractable pain from trigeminal neuralgia or cluster headache.

© 2014 Baishideng Publishing Group Inc. All rights reserved.

**Key words:** Intracerebroventricular; Opiate; Trigeminal neuralgia; Cluster headache; Pain

**Core tip:** Chronic head and face pain remains a debilitating condition, and patients may often be refractory to traditional medical therapies or surgical intervention (*i.e.*, stereotactic radiosurgery or microvascular decompression). Alternatively, the use of intracerebroventricular (ICV) pain pumps has been used for refractory nociceptive pain from head and neck cancer; however, its use in non-cancer head and face pain has not been well described. Here, we report the potential risks and benefits of ICV opiate pain pumps for cluster headaches and trigeminal neuralgia refractory to medical and surgical treatment.



Lee DJ, Gurkoff GG, Goodarzi A, Muizelaar JP, Boggan JE, Shahlaie K. Intracerebroventricular opiate infusion for refractory head and facial pain. *World J Clin Cases* 2014; 2(8): 351-356 Available from: URL: <http://www.wjgnet.com/2307-8960/full/v2/i8/351.htm> DOI: <http://dx.doi.org/10.12998/wjcc.v2.i8.351>

## INTRODUCTION

Chronic head and face pain is a debilitating condition that affects over 3%-5% of people worldwide<sup>[1]</sup>, dramatically impacting emotional, psychological, and economic well-being. Two common etiologies of severe head and face pain are cluster headache and trigeminal neuralgia, which affect 300000 and 100000 people in the United States, respectively. Cluster headache is typically managed with medical therapies or botox injections<sup>[2,3]</sup>, and most cases of trigeminal neuralgia are successfully treated with oral medications, stereotactic radiosurgery, or microvascular decompression<sup>[4]</sup>. However, 5% of patients with cluster headache<sup>[5]</sup> and 11%-25% of patients with trigeminal neuralgia<sup>[6-10]</sup> do not achieve adequate pain relief with these therapies and may require other treatment options.

Neurosurgical treatment options for pain syndromes have generally focused on modulation of specific pain pathways by lesioning, electrical stimulation, or spinal intrathecal delivery of pharmacological agents<sup>[11,12]</sup>. Targets for electrical neuromodulation include the dorsal columns of the spinal cord, the sensory nuclei of the thalamus, the precentral motor cortex for neurogenic/neuropathic pain, and the periventricular/periaqueductal gray area for somatic or nociceptive pain<sup>[13]</sup>. Chemical neuromodulation *via* central delivery of pharmacological agents is primarily accomplished *via* spinal intrathecal delivery strategies<sup>[14]</sup>.

Intracerebroventricular (ICV) administration of opioids represents a chemical, rather than electrical, neuromodulation treatment strategy. This allows for drug delivery directly at its anatomical site of action, achieving high tissue concentrations of drug that would not be achievable with systemic drug delivery. ICV delivery of opiate medications has been previously described for management of refractory nociceptive pain from head and neck cancer<sup>[15-19]</sup>. This is typically accomplished *via* intermittent injection of opiates into an Ommaya reservoir<sup>[17,20-22]</sup>, although use of an implanted infusion pump has also been reported<sup>[19,23]</sup>. In this study, we present our institutional experience treating six patients with ICV opiate pain pumps for treatment of severe, refractory head and face pain due to cluster headache and/or trigeminal neuralgia.

## MATERIALS AND METHODS

### Patient population

Six adult patients (4 women, 2 men) underwent implantation of an ICV opiate pump into the right lateral ventricle for treatment of severe, refractory head and/or face pain at the University of California, Davis Medical Center.

The average age of symptom onset was 44.3 years (range 17-75), the average duration of symptoms was 14.8 years (range 4-31), and the average age at ICV implantation was 59.0 years (range 35-79). Four patients had facial pain, 1 patient had cluster headaches, and 1 patient had cluster headache and atypical facial pain. Patients had tried an average of 4 (range 1-9) oral pain medications prior to ICV implantation; 2 patients trialed opiate injection therapy, 2 patients had failed microvascular decompression for facial pain, and none of the patients in this series had undergone previous radiosurgery for pain (Table 1). The University of California, Davis Institutional Review Board approved this retrospective study.

### Treatment protocol

Prior to ICV opiate pump implantation, all patients demonstrated significant clinical benefit with trial injection of opiates through an Ommaya reservoir ( $n = 5$ ) or an external ventricular drain (EVD,  $n = 1$ ). Trial injections were performed in the neurosurgical intensive care unit for close monitoring of known complications of ICV opiate delivery, including mental clouding, visual hallucinations, seizures, somnolence, respiratory depression, and coma<sup>[24]</sup>. Initially, patients underwent a trial injection phase (3-15 d) at which time the dose of morphine or hydromorphone was titrated to determine an optimal dose for each individual. A Medtronic (Minnesota, United States) pain pump was implanted into a subcutaneous fat space in the abdomen within one month of the trial injections by one of two neurosurgeons (J.E.B, K.S.). In one patient (patient 6), intraoperative computed tomography was used to confirm placement of the intraventricular catheter (Figure 1). Adjustment of dose rates and/or refilling of pumps occurred monthly.

### Outcome assessment

Visual analogue scale (VAS) scores were obtained before and after intraventricular trial injections, and before and after the ICV opiate pump infusion began. VAS scores were collected on an intermittent basis during outpatient clinic visits, before and after infusion rate adjustments.

## RESULTS

There were no complications associated with placement of an Ommaya reservoir or EVD to perform trial injections. During trial injection therapy, one patient experienced a transient side effect of nausea but there were no permanent complications. An average of 9.2 doses (range 2-27) was necessary during the trial phase to provide maximum VAS improvement with trial injections (average VAS improvement 75.8%, range 50%-100%).

Pump implantation was performed an average of 3.7 wk (range 1-7) after ICU trial injections had been completed, and patients required an average of 20.7 (range 2-51) outpatient adjustments to the dose. At the most recent follow-up (26.2 mo, range 2-56, one patient transferred care to a different institution), VAS pain scores significantly im-

Table 1 Patient characteristics and outcomes

Patient	Age (at pump placement, yr)	Gender	Primary diagnosis	Prior surgeries	Pre-implantation trial	ICV pump medication	Initial dose (mg/d)	Final dose (mg/d)	Pre-op VAS	Post-op day 1 VAS	Last VAS	Last post-op visit (mo)
1	67	Male	Trigeminal neuralgia (left)		Ommaya reservoir-morphine	Morphine then dilaudid	0.1 morphine	3.27 dilaudid	6	3.5	4	145
2	35	Female	Cluster headaches		Ommaya reservoir-morphine	Morphine	0.65 morphine	19.0 morphine	8	4	0	166
3	37	Female	Trigeminal neuralgia (right), Cluster headaches		Ommaya reservoir-morphine, dilaudid	Dilaudid	0.1 dilaudid	0.2 dilaudid	8	2.5	3	9
4	74	Male	Trigeminal neuralgia (left)	Rhizotomy, Microvascular decompression	Ommaya reservoir-morphine	Morphine	0.75 morphine	1.75 morphine	8	1	1	10
5	62	Female	Trigeminal neuralgia (right)	Microvascular decompression	Ommaya reservoir-morphine	Morphine	4 morphine	4.25 morphine	10	3	2	3
6	79	Female	Trigeminal neuralgia (left)	Meningioma resection (left), radiosurgery ×2	External ventricular drain-morphine, dilaudid	Dilaudid	0.01 dilaudid	0.085 dilaudid	8	2	2	15

VAS: Visual analogue scale; ICV: Intracerebroventricular.

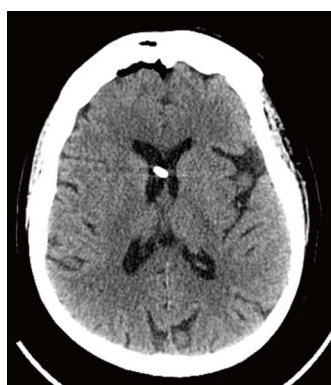

Figure 1 Intraoperative computed tomography of the head demonstrates intraventricular placement of the pump catheter (Patient 6).

proved from an average of  $7.8 \pm 0.5$  (range 6-10) to  $2.8 \pm 0.7$  (range 0-5) once reaching final dose (mean improvement  $5.0 \pm 1.0$ ,  $P < 0.001$ , Table 1, Figure 2).

All patients required stepwise increases in infusion rates to achieve maximal benefit. The average initial morphine dose was 1.4 mg/d (range 0.1-4.0 mg/d) and the average final dose was 11.7 mg/d (range 2-21.5,  $n = 4$ ). The average initial hydromorphone dose was 0.08 mg/d (range 0.01-0.2 mg/d) and the average final dose was 1.2 mg/d (range 0.1-3.3). In one patient (Patient 1), the medication was changed from morphine to hydromorphone to achieve maximal benefit; in this patient, 12 morphine dosage adjustments were made prior to converting to hydromorphone 15 mo after implantation. The final morphine dosage was 21.5 mg/d and the

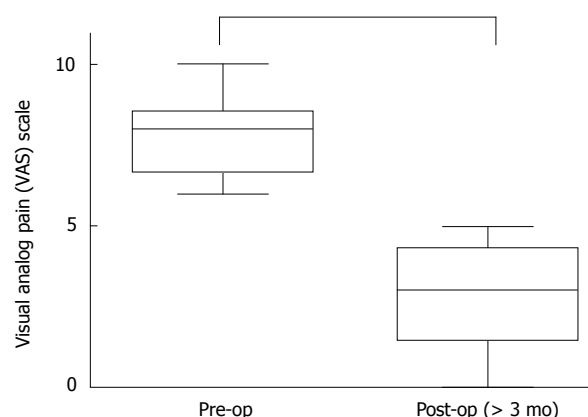


Figure 2 Preoperative visual analogue scale pain scores ranged from 6-10 out of 10 (average  $7.8 \pm 0.5$ ). Post-operative visual analogue scale (VAS) scores at > 3 mo following opioid pain pump placement were significantly lower ( $P < 0.001$  vs Post-op), ranging 0-5 out of 10 (average  $2.7 \pm 0.4$ ).

initial hydromorphone dosage was 2.1 mg/d. Following medication adjustment, an additional 12 adjustments with hydromorphone were made. On average, infusion pumps were replaced every 4-5 years.

The most common complications in this series were nausea ( $n = 2$ ) and drowsiness ( $n = 2$ ), both of which resolved with adjustments in pump settings (Table 2). One patient experienced withdrawal symptoms due to pump failure, and underwent a distal catheter revision (to clear an obstruction) with subsequent resolution of her symptoms. One patient experienced psychiatric irritability after 10 years of good pain relief and had the ICV pain pump removed.

**Table 2** Dose ranges and complications

Patient	Dose range (mg/d)	Complications
1	0.10-21.5 (morphine) 2.10-3.27 (dilaudid)	Nausea/Emesis (transient-decreased dosage) Changed medication due to inadequate pain control/nausea
2	0.65-19.0 (morphine)	Replacement of pump × 2 (q5 yr) Withdrawal symptoms (transient)
3	0.20 (dilaudid)	Psychiatric disturbances leading to removal of pain pump after 11 yr
4	0.75-2.0 (morphine)	Nausea/Emesis (transient-decreased dosage)
5	4.00-4.25 (morphine)	Lost to follow-up after 1 yr
6	0.01-0.10 (dilaudid)	

## DISCUSSION

ICV opiate infusion using an implanted pump provides significant pain relief in patients with severe, refractory head and/or face pain that have failed other medical and surgical therapies. This study adds to the existing literature on successful use of ICV opiates for management of head and neck cancer pain<sup>[25]</sup>, and suggests that ICV opiate infusion may be a prudent treatment option for select patients with severe cluster headache or trigeminal neuralgia.

While the mechanism and site of action of opioids in the brain for head and neck pain is not completely understood, it is known that morphine and its derivatives bind to receptors that are found in the periventricular and periaqueductal gray regions, medulla spinalis, substantia gelatinosa, and the hypothalamus<sup>[13,26-30]</sup>. Therefore, it is possible that ICV delivery of opioids selectively modulates activity in these brain regions, resulting in a level of analgesia that may be superior to that achieved with systemic therapies.

The efficacy of deep brain stimulation (DBS) of the periventricular/periaqueductal gray region for management of cluster headache and other central pain syndromes<sup>[11,13,26]</sup> supports the hypothesis that targeted delivery is effective for refractory cases. Due to its proximity to pain pathways in the brainstem, hypothalamus, and thalamus, ICV delivery may potentially be more prudent than intraspinal intrathecal delivery for severe, refractory head and face pain syndromes. Prospective comparative studies are needed to further explore this possibility.

Because the pathophysiology of refractory trigeminal neuralgia and cluster headaches are poorly understood, ICV infusion therapy may be more effective than DBS since its effects are more regional and affect a larger volume of tissue. Different brain areas have been implicated in refractory cluster headache<sup>[31,32]</sup>, and the anatomical basis of trigeminal neuralgia that fails medical therapy and microvascular decompression is often elusive and has been attributed to demyelination or other unknown processes. Various lesioning therapies have been proposed for failed microvascular decompression, including therapies that target the facial nerve (chemical, mechanical decompression, radiosurgery, and nerve cutting) or its brainstem pathways (nucleus caudalis dorsal root entry zone lesioning). Since these procedures are irreversible

and can carry significant risks, ICV opioid infusion may be a preferable alternative since it allows for delivery of a regional targeted therapy that can be titrated to effect and, if necessary, discontinued.

It is important to note that cluster headache and trigeminal neuralgia are very different disorders with unique clinical and pathological characteristics. For example, cluster headaches are far more common in men (8:3 ratio)<sup>[33]</sup> whereas trigeminal neuralgia affects more women than men (3:2 ratio)<sup>[34]</sup>. Since morphine is generally more potent in men than women, it is possible that different opioid infusion strategies are needed to achieve adequate analgesia in these conditions. Such differences were not evident in the current series, but larger clinical studies are needed to determine if gender-specific and/or disease-specific opioid infusion strategies will yield better clinical outcomes.

The risks associated with ICV opiate infusion therapy include neurological injury from ventricular catheter placement, implant infection, and opioid toxicity (including allergy, intolerance or significant clinical side effects). We recommend a trial therapy in an ICU setting prior to pump implantation to confirm clinical efficacy and evaluate for any signs of opioid toxicity. After implantation, a slow, step-wise titration of opioid infusion is recommended to achieve maximum clinical efficacy with minimal side effects and complications. In this series, the average number of dose adjustments was 20.7 (range 2-51). The high number of adjustments demonstrates that opioid tolerance can develop over time. Special consideration should be given to the development of opioid tolerance and the risks associated with abrupt disruption or withdrawal of therapy (in the setting of pump failure, for example). There is some evidence that co-administration of drugs may enhance analgesia and reduce the likelihood of tolerance. For example, pre-clinical animal studies suggest that co-administration of drugs like calmodulin inhibitors<sup>[35,36]</sup> or inhibitors of protein kinases<sup>[37]</sup> may reduce or prevent morphine tolerance from developing. Also, there is evidence that certain non-opioid medications, such as the voltage-gated calcium channel blocker ziconotide, are extremely effective when delivered as an intrathecal infusion<sup>[38,39]</sup> and may be appropriate alternatives to opioids or effective in a co-administration strategy.

In conclusion, severe head and facial pain syndromes that are refractory to conventional medical and surgical

therapies can be extremely debilitating and very difficult to manage. ICV opioid infusion has the potential to enhance analgesia through regional delivery of drug to brain centers that are directly responsible for processing pain signals. Using a careful clinical protocol to screen for efficacy and reduce risks, ICV opioid infusion therapy may be an effective treatment option for patients with severe head and facial pain due to cluster headache and trigeminal neuralgia.

## COMMENTS

### Background

Intracerebroventricular (ICV) opiate pumps are used for management of chronic pain due to head and neck cancers, but their use for neurological etiologies of benign head and face pain has not been well studied. This study aims to evaluate the risks and benefits of intracerebroventricular opiate pumps for management of benign head and face pain.

### Research frontiers

Here, the authors describe the use of intracerebroventricular pain pumps for benign head and face pain refractory to medical and/or surgical treatment. While neurosurgical options for pain include lesioning, electrical stimulation, or spinal intrathecal delivery of pharmacological agents, the use of intracerebroventricular opiates has not been well described.

### Innovations and breakthroughs

While intracerebroventricular pain pumps have been used for head and neck cancer pain, its use for benign head and face pain, such as trigeminal neuralgia or cluster headaches, has not been well described. This study suggests that ICV pain pumps may be a potential treatment option for patients suffering from benign head and face pain refractory to medical and/or surgical treatments.

### Applications

This study suggests that intracerebroventricular pain pumps may be a viable option for patients with benign head and face pain that are refractory to previous medical or surgical treatments. Randomized controlled trials would need to be performed to further evaluate the efficacy and safety of this modality.

### Terminology

Intracerebroventricular pain pump: Opiates can be administered into the ventricles directly via this modality. This can be distinguished from spinal catheter pain pumps. Visual analog score: 10-point pain scale used to evaluate severity of pain (0: no pain, 10 most severe pain).

### Peer review

Interesting clinical article on intracerebroventricular opiate infusion for refractory head and facial pain. The authors report on a cohort of 6 patients with refractory trigeminal neuralgia and/or cluster headaches which underwent implantation of an intracerebroventricular opiate infusion pump as a means to control intractable pain. The article is well written, the patient population is presented in detail and the same applies to treatment protocol and outcome assessment. The results are equally presented with clarity and the discussion includes up to date references that correlate with the authors clinical results.

## REFERENCES

- Gladstone J, Eross E, Dodick D. Chronic daily headache: a rational approach to a challenging problem. *Semin Neurol* 2003; **23**: 265-276 [PMID: 14722822 DOI: 10.1055/s-2003-814738]
- Beck E, Sieber WJ, Trejo R. Management of cluster headache. *Am Fam Physician* 2005; **71**: 717-724 [PMID: 15742909]
- Newman LC, Goadsby P, Lipton RB. Cluster and related headaches. *Med Clin North Am* 2001; **85**: 997-1016 [PMID: 11480270]
- Obermann M, Katsarava Z. Update on trigeminal neuralgia. *Expert Rev Neurother* 2009; **9**: 323-329 [PMID: 19271941 DOI: 10.1586/14737175.9.3.323]
- Irimia P, Palma JA, Fernandez-Torron R, Martinez-Vila E. Refractory migraine in a headache clinic population. *BMC Neurol* 2011; **11**: 94 [PMID: 21806790 DOI: 10.1186/1471-2377-11-94]
- Günther T, Gerganov VM, Stieglitz L, Ludemann W, Samii A, Samii M. Microvascular decompression for trigeminal neuralgia in the elderly: long-term treatment outcome and comparison with younger patients. *Neurosurgery* 2009; **65**: 477-482; discussion 482 [PMID: 19687692 DOI: 10.1227/01.NEU.0000350859.27751.90]
- Sanchez-Mejia RO, Limbo M, Cheng JS, Camara J, Ward MM, Barbaro NM. Recurrent or refractory trigeminal neuralgia after microvascular decompression, radiofrequency ablation, or radiosurgery. *Neurosurg Focus* 2005; **18**: e12 [PMID: 16419977]
- Barker FG, Jannetta PJ, Bissonette DJ, Larkins MV, Jho HD. The long-term outcome of microvascular decompression for trigeminal neuralgia. *N Engl J Med* 1996; **334**: 1077-1083 [PMID: 8598865 DOI: 10.1056/NEJM199604253341701]
- Bederson JB, Wilson CB. Evaluation of microvascular decompression and partial sensory rhizotomy in 252 cases of trigeminal neuralgia. *J Neurosurg* 1989; **71**: 359-367 [PMID: 2769387 DOI: 10.3171/jns.1989.71.3.0359]
- Burchiel KJ, Clarke H, Haglund M, Loeser JD. Long-term efficacy of microvascular decompression in trigeminal neuralgia. *J Neurosurg* 1988; **69**: 35-38 [PMID: 2454303 DOI: 10.3171/jns.1988.69.1.0035]
- Kumar K, Toth C, Nath RK. Deep brain stimulation for intractable pain: a 15-year experience. *Neurosurgery* 1997; **40**: 736-746; discussion 746-747 [PMID: 9092847]
- Cetas JS, Saedi T, Burchiel KJ. Destructive procedures for the treatment of nonmalignant pain: a structured literature review. *J Neurosurg* 2008; **109**: 389-404 [PMID: 18759567 DOI: 10.3171/JNS/2008/109/9/0389]
- Hosobuchi Y. Subcortical electrical stimulation for control of intractable pain in humans. Report of 122 cases (1970-1984). *J Neurosurg* 1986; **64**: 543-553 [PMID: 3485191 DOI: 10.3171/jns.1986.64.4.0543]
- Hayek SM, Deer TR, Pope JE, Panchal SJ, Patel VB. Intrathecal therapy for cancer and non-cancer pain. *Pain Physician* 2011; **14**: 219-248 [PMID: 21587327]
- Choi CR, Ha YS, Ahn MS, Lee JS, Song JU. Intraventricular or epidural injection of morphine for severe pain. *Neurochirurgia (Stuttg)* 1989; **32**: 180-183 [PMID: 2594133 DOI: 10.1055/s-2008-1054033]
- Cramond T, Stuart G. Intraventricular morphine for intractable pain of advanced cancer. *J Pain Symptom Manage* 1993; **8**: 465-473 [PMID: 7963773]
- Karavelis A, Foroglou G, Selviaridis P, Fountzilas G. Intraventricular administration of morphine for control of intractable cancer pain in 90 patients. *Neurosurgery* 1996; **39**: 57-61; discussion 61-62 [PMID: 8805140]
- Lazorthes YR, Sallerin BA, Verdié JC. Intracerebroventricular administration of morphine for control of irreducible cancer pain. *Neurosurgery* 1995; **37**: 422-428; discussion 422-428 [PMID: 7501106]
- Weigl K, Mundinger F, Chrusasik J. Continuous intraventricular morphine- or peptide-infusion for intractable cancer pain. *Acta Neurochir Suppl (Wien)* 1987; **39**: 163-165 [PMID: 3478979]
- Le MK, Shin HJ, Yang GY, Yoon YW, Han SK, Bae YC, Ahn DK. Intracisternal and intraperitoneal administration of morphine attenuates mechanical allodynia following compression of the trigeminal ganglion in rats. *J Orofac Pain* 2010; **24**: 113-121 [PMID: 20213037]
- Nurchi G. Use of intraventricular and intrathecal morphine in intractable pain associated with cancer. *Neurosurgery* 1984; **15**: 801-803 [PMID: 6549051]
- Reeve WG, Todd JG. Intraventricular diamorphine via an Ommaya shunt for intractable cancer pain. *Br J Anaesth* 1990; **65**: 544-547 [PMID: 2248824]
- Dennis GC, DeWitty RL. Long-term intraventricular infusion of morphine for intractable pain in cancer of the head



- and neck. *Neurosurgery* 1990; **26**: 404-407; discussion 404-407 [PMID: 2320208]
- 24 **Ballantyne JC**, Carwood CM. Comparative efficacy of epidural, subarachnoid, and intracerebroventricular opioids in patients with pain due to cancer. *Cochrane Database Syst Rev* 2005; **(1)**: CD005178 [PMID: 15654707 DOI: 10.1002/14651858.CD005178]
  - 25 **Ballantyne JC**, Carr DB, Berkey CS, Chalmers TC, Mosteller F. Comparative efficacy of epidural, subarachnoid, and intracerebroventricular opioids in patients with pain due to cancer. *Reg Anesth* 1996; **21**: 542-556 [PMID: 8956391]
  - 26 **Hosobuchi Y**, Adams JE, Linchitz R. Pain relief by electrical stimulation of the central gray matter in humans and its reversal by naloxone. *Science* 1977; **197**: 183-186 [PMID: 301658]
  - 27 **Lipp J**. Possible mechanisms of morphine analgesia. *Clin Neuropharmacol* 1991; **14**: 131-147 [PMID: 1849794]
  - 28 **Wall PD**. The role of substantia gelatinosa as a gate control. *Res Publ Assoc Res Nerv Ment Dis* 1980; **58**: 205-231 [PMID: 6245435]
  - 29 **Markenson JA**. Mechanisms of chronic pain. *Am J Med* 1996; **101**: 6S-18S [PMID: 8764755]
  - 30 **Grossman A**, Clement-Jones V. Opiate receptors: enkephalins and endorphins. *Clin Endocrinol Metab* 1983; **12**: 31-56 [PMID: 6303648]
  - 31 **May A**, Bahra A, Büchel C, Frackowiak RS, Goadsby PJ. PET and MRA findings in cluster headache and MRA in experimental pain. *Neurology* 2000; **55**: 1328-1335 [PMID: 11087776]
  - 32 **DaSilva AF**, Goadsby PJ, Borsook D. Cluster headache: a review of neuroimaging findings. *Curr Pain Headache Rep* 2007; **11**: 131-136 [PMID: 17367592]
  - 33 **Rozen TD**, Fishman RS. Cluster headache in the United States of America: demographics, clinical characteristics, triggers, suicidality, and personal burden. *Headache* 2012; **52**: 99-113 [PMID: 22077141 DOI: 10.1111/j.1526-4610.2011.02028.x]
  - 34 **Ji Y**, Murphy AZ, Traub RJ. Sex differences in morphine-induced analgesia of visceral pain are supraspinally and peripherally mediated. *Am J Physiol Regul Integr Comp Physiol* 2006; **291**: R307-R314 [PMID: 16556902 DOI: 10.1152/ajp-regu.00824.2005]
  - 35 **Sepehri G**, Sheibani V, Azarang A, Shamsizadeh A, Afarinesh MR, Azizollahi S, Sepehri E. The intracerebroventricular (ICV) administration of W-7, a calmodulin inhibitor, attenuates the development of morphine tolerance in rats. *Pak J Pharm Sci* 2010; **23**: 170-174 [PMID: 20363694]
  - 36 **Sánchez-Blázquez P**, Rodríguez-Muñoz M, Montero C, de la Torre-Madrid E, Garzón J. Calcium/calmodulin-dependent protein kinase II supports morphine antinociceptive tolerance by phosphorylation of glycosylated phospholipase C protein. *Neuropharmacology* 2008; **54**: 319-330 [PMID: 18006024 DOI: 10.1016/j.neuropharm.2007.10.002]
  - 37 **Gabra BH**, Bailey CP, Kelly E, Smith FL, Henderson G, Dewey WL. Pre-treatment with a PKC or PKA inhibitor prevents the development of morphine tolerance but not physical dependence in mice. *Brain Res* 2008; **1217**: 70-77 [PMID: 18501877 DOI: 10.1016/j.brainres.2008.04.036]
  - 38 **Michiels WB**, McIlthlen GL, Platt BJ, Grigsby EJ. Trigeminal neuralgia relief with intrathecal ziconotide. *Clin J Pain* 2011; **27**: 352-354 [PMID: 21494183 DOI: 10.1097/AJP.0b013e3181fb22f4]
  - 39 **Lux EA**. Case report: successful treatment of a patient with trigeminal neuropathy using ziconotide. *Anesth Analg* 2010; **110**: 1195-1197 [PMID: 20142352 DOI: 10.1213/ANE.0b013e3181cfc307]

**P- Reviewer:** Rapidis AD **S- Editor:** Song XX **L- Editor:** A  
**E- Editor:** Lu YJ



## Distal biceps tendon rupture reconstruction using muscle-splitting double-incision approach

Luigi Tarallo, Raffaele Mugnai, Francesco Zambianchi, Roberto Adani, Fabio Catani

Luigi Tarallo, Raffaele Mugnai, Francesco Zambianchi, Fabio Catani, Orthopaedics and Traumatology Department, Modena Policlinic, University of Modena and Reggio Emilia, 41124 Modena, Italy  
Roberto Adani, Department of Hand Surgery and Microsurgery, University Hospital of Verona, 37134 Verona, Italy

**Author contributions:** Tarallo L and Adani R designed the research; Tarallo L, Adani R and Catani F performed the research; Mugnai R collected the data; Mugnai R and Zambianchi F wrote the paper.

**Correspondence to:** Raffaele Mugnai, MD, Orthopaedics and Traumatology Department, Modena Policlinic, University of Modena and Reggio Emilia, Modena, Via del Pozzo 71, 41124 Modena, Italy. [raffaele.mugnai@gmail.com](mailto:raffaele.mugnai@gmail.com)

Telephone: +39-59-4224916 Fax: +39-59-4224313

Received: April 5, 2014 Revised: June 21, 2014

Accepted: July 17, 2014

Published online: August 16, 2014

respective contralateral limb, was 83%. The average patient satisfaction rating on a Likert scale (from 0 to 10) was 9.4. The following complications were observed: 3 cases of heterotopic ossification (6.4%), one (2.1%) re-rupture of the tendon at the site of reattachment and 2 cases (4.3%) of posterior interosseous nerve palsy. No complication required further surgical treatment.

**CONCLUSION:** This technique allows an anatomic reattachment of distal biceps tendon at the radial tuberosity providing full functional recovery with low complication rate.

© 2014 Baishideng Publishing Group Inc. All rights reserved.

**Key words:** Distal biceps tendon; Rupture; Double incision; Complications; Clinical outcome; Trans-osseous tunnels; Morrey

### Abstract

**AIM:** To evaluate the clinical and functional results after repair of distal biceps tendon tears, following the Morrey's modified double-incision approach.

**METHODS:** We retrospectively reviewed 47 patients with distal rupture of biceps brachii treated between 2003 and 2012 in our Orthopedic Department with muscle-splitting double-incision technique. Outcome measures included the Mayo elbow performance, the DASH questionnaire, patient's satisfaction, elbow and forearm motion, grip strength and complications occurrence.

**RESULTS:** At an average 18 mo follow-up (range, 7 mo-10 years) the average Mayo elbow performance and DASH score were respectively 97.2 and 4.8. The elbow flexion range was 94%, extension was -2°, supination was 93% and pronation 96% compared with the uninjured limb. The mean grip strength, expressed as percentage of

**Core tip:** Both single and double-incision approaches have been successfully used for distal biceps tendon lesions. At present there is no solid scientific evidence to support preference of one technique over the other. However, recently, it has been demonstrated that the 2-incision technique recreates more closely footprint position compared with that of the 1-incision approach. In the present research the Morrey's modified double-incision repair provided excellent outcome (including functional outcome, satisfaction, elbow and forearm motion, and grip strength) with few post-operative complications, mainly represented by heterotopic ossification and posterior interosseous nerve injuries.

Tarallo L, Mugnai R, Zambianchi F, Adani R, Catani F. Distal biceps tendon rupture reconstruction using muscle-splitting double-incision approach. *World J Clin Cases* 2014; 2(8): 357-361 Available from: URL: <http://www.wjgnet.com/2307-8960/full/v2/i8/357.htm> DOI: <http://dx.doi.org/10.12998/wjcc.v2.i8.357>

## INTRODUCTION

The incidence of distal biceps ruptures is estimated between 0.9 and 1.8 per 100000 population per year, and accounts for 3% of biceps brachii tendon injuries<sup>[1]</sup>. This injury is very common in men who are in their fifth or sixth decade of life, but can also occur at any age<sup>[2-4]</sup>.

Many studies demonstrated that surgical approaches allow better clinical results than conservative treatments<sup>[5,6]</sup>. In literature, various surgical methods have been described, dating back to the first report by Acquaviva in 1898<sup>[7,8]</sup>.

In 1956 Fischer *et al.*<sup>[9]</sup> used the volar Henry approach to reattach the distal biceps tendon to the radial tuberosity. This allowed a good recovery of flexion and supination strength, but radial nerve palsy occurred in several cases consequently to the extensive exposure needed using this approach<sup>[10,11]</sup>.

To decrease the risk of neurologic complications limiting the exposure needed Boyd *et al.*<sup>[12]</sup> in 1961 described a two-incision technique to access the tuberosity more easily. They felt that a second dorsal incision was necessary in order to limit the volar surgical dissection required near the radial nerve as it passes through the supinator muscle<sup>[13-15]</sup>. However, complications with special respect to heterotopic ossifications including loss of forearm rotation, radioulnar synostosis, and posterior interosseous nerve injury were described using the double-incision technique<sup>[16,17]</sup>.

In an effort to overcome any complications connected with each approach, more modern techniques have been developed in the last decades. The two-incision approach was updated by Morrey *et al.*<sup>[18]</sup>, who used a posterior muscle-splitting approach that avoids subperiosteal exposure of the ulna, and therefore reduces the possibility of radioulnar synostosis. With this adjustment, the tendon can be reattached to the radial tuberosity through transosseous drill holes.

More recently approaches that use suture anchors and a limited single anterior incision have been described<sup>[11,19,20]</sup>. Currently there is no consensus with respect to the best surgical approach and favorable results with both techniques<sup>[21-23]</sup>.

The aim of our study is to evaluate the clinical and functional outcomes after surgical repair of distal tendons tears, using a muscle-splitting double incision approach modified by Morrey<sup>[18]</sup>.

## MATERIALS AND METHODS

This study has been authorized by the local ethical committee and was carried out in accordance with the Ethical standards of the 1964 Declaration of Helsinki as updated in 2004. We retrospectively reviewed 47 patients operated by two different surgeons of distal rupture of biceps brachii, treated in our Orthopedic Department between March 2003 and September 2012 using the muscle-splitting double-incision technique. Every patient

undergoing distal biceps tendon acute rupture repair, was included in our review and informed consent was obtained. Exclusion criteria included the presence of an associated fracture, and dislocation about the elbow as etiology of biceps injury. All patients included in our cohort were treated within 15 d from trauma. We analyzed the rate of major and minor complications. Major complications included posterior interosseous nerve (PIN) palsy, heterotopic ossification and re-rupture. Minor complications included superficial infection, lateral antebrachial cutaneous nerve paresthesia and radial sensory nerve paresthesia. All 47 cases are men, with an average age of 45 (range, 28-66 years) at the time of injury. The dominant arm was involved in 43 patients, 91% of all cases. The injury mechanism was the same in every case: an eccentric load applied to a flexed elbow during daily or sport activity. Subjective outcomes included the Disability of Arm, Shoulder and Hand (DASH) questionnaire and the Mayo elbow performance score. In addition, levels of overall patient satisfaction were determined using a 10-point scale: in which 10 points denoting very satisfied and 1 point denoting very unsatisfied. All measurements were performed at an average 18 mo follow-up (range, 7 mo-10 years) by an independent assessor who measured elbow and forearm motion using a goniometer.

All patients underwent the same surgical method: the double incision technique uses a transverse incision in the antecubital fossa. After identification of the distal portion of the biceps tendon, the degenerated part is resected. Two locking Krackow sutures with N.2 fiber-wire (Arthrex, Naples, FL) are passed through the distal part of the tendon. After bicipital tuberosity identification, a curved clamp is lead through the interosseous space, forceps are then palpated on the dorsal aspect of the proximal part of the forearm, and second longitudinal incision is made over it. With the forearm in maximal pronation, the tuberosity is exposed with a muscle-splitting technique. Three drill holes are placed approximately at 1 cm intervals through the dorsal cortical margin of the tuberosity. The tendon sutures are then passed through the holes. With the elbow at 90° of flexion and the forearm pronated, the biceps tendon is pulled into the bicipital tuberosity and sutures are pulled tight and tied (Figure 1). The elbow is then splinted for 4 wk. Early active-assistive and ROM activities into elbow flexion and extension are advised 3-4 times per day. All patients were treated with indomethacin 75 mg for 3 wk as a standard protocol to prevent heterotopic ossifications.

## RESULTS

The average elbow flexion range was 94% of the uninjured limb (125° *vs* 135°). Average extension was -2°. Supination was 93 % and pronation 96% compared with the uninjured limb (supination 80° *vs* 84°; pronation 86° *vs* 82°) (Figure 2). The average Mayo elbow performance and DASH score were respectively 97.2 and 4.8. The satisfaction rating score was 9.4 points (Table 1).



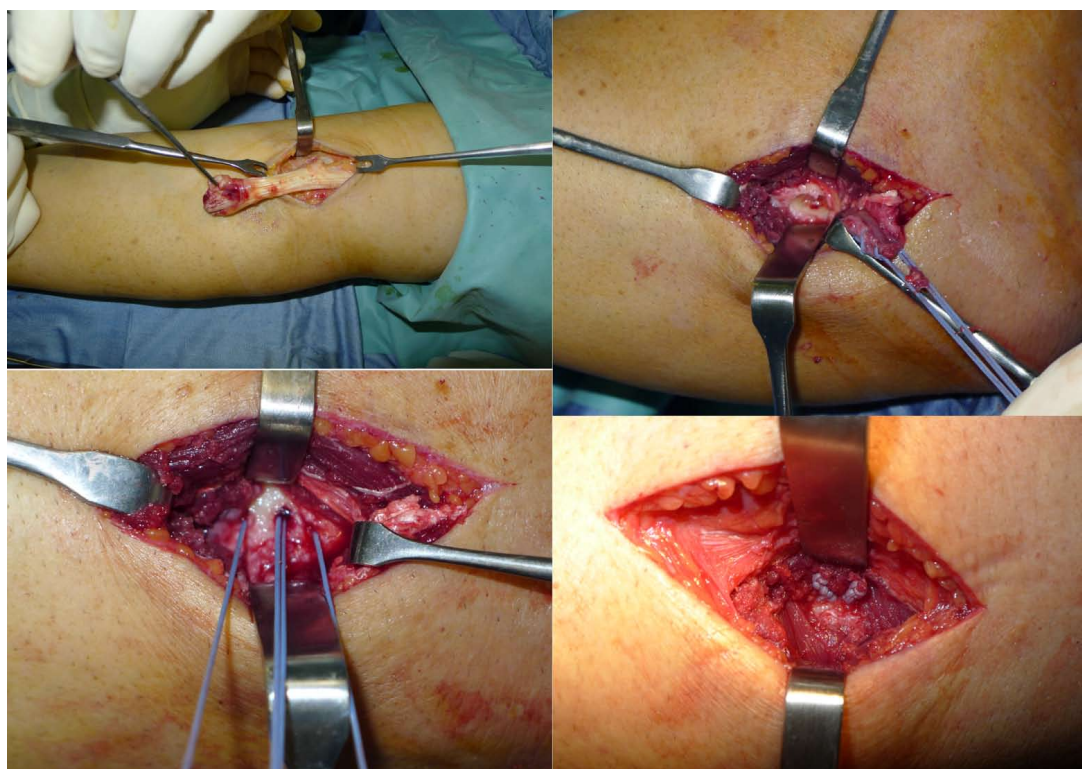


Figure 1 Intraoperative view showing the double access and the surgical procedure.



Figure 2 Clinical evaluation at 40 d after surgery showing complete recovery of the range of motion.

The reported complications included nerve dysfunction, heterotopic ossification and failure at repair site. We had 3 cases of heterotopic ossification with limited range

of movement near to complete loss of forearm rotation. Resection of heterotopic bone was associated with restoration of near-normal motion. One re-rupture of the



**Table 1 Clinical outcome and complications occurrence *n* (%)**

Clinical outcome												Complications		
Range of motion								Mayo	Dash	Grip strengTH	Satisfaction	Eterotopic ossification	Tendon re-rupture	Pin palsy
Flexion (94)		Extension (97)		Pronation (93)		Supination (96)								
125 ± 8.4	94%	-2 ± 4.3	97%	80 ± 5.7	93%	82 ± 6.5	96%	97.2 ± 12.0	4.8 ± 8.2	83%	9.4 ± 5.6	3 (6.4)	1 (2.1)	2 (4.3)

Data are expressed as absolute numbers (percentage) or mean ± SD.

tendon at the site of reattachment was found. Two cases of posterior interosseous nerve (PIN) palsy were found but both were resolved without intervention (Table 1).

## DISCUSSION

Distal biceps tendon ruptures usually arise in the dominant elbow of middle-aged male patients<sup>[24]</sup>. The clinical presentation is characteristic and radiographs, MRI or ultrasound are not necessary to diagnose an acute rupture of the distal biceps. In recent decades surgical repair of this type of lesions have shown improved functional outcomes compared with conservative treatment. Baker *et al*<sup>[2]</sup> compared operative and nonoperative treatment showing decreased supination strength of 55% and supination endurance of 86% with nonoperative approach compared with controls. Several surgical options have been described in literature: the one incision-approach, using suture anchor, endobuttons, biotenodesis screw for fixation and a two incision approach using bone tunnels<sup>[25]</sup>. The recreation of an anatomic reattachment of the distal biceps tendon to its osseous insertion at the radial tuberosity has to be the main objective of operative treatment. The modified two-incision approach has demonstrated excellent clinical results with regards to postoperative range of motion, strength, and endurance<sup>[26]</sup>. Distal biceps tendon repair sometimes lacks elbow motion, due to heterotopic ossification or radioulnar exostosis as well as neurological complications such as PIN injury<sup>[27]</sup>. Heterotopic bone formation is common following distal biceps tendon surgery and has been reported in both single and double-incision repairs. Higher rates of heterotopic ossification have been described in double-incision treatments performed using the Boyd-Anderson method, where the posterior soft tissues are elevated off the ulna to expose the radial tuberosity<sup>[16,17]</sup>. Radioulnar synostosis, although rare, is more common with the Boyd-Anderson method rather than with muscle-splitting double-incision approach, in which the periosteal surface of the ulna is not exposed. With this technique, the incidence of synostosis and heterotopic bone has substantially decreased<sup>[28,29]</sup>. In our cohort complications were reported in 12.8% of cases: 3 cases of heterotopic ossification (6.4%), one (2.1%) re-rupture of the tendon at the site of reattachment and 2 cases (4.3%) of PIN palsy, all of them resolved without intervention. Our rate of complications appears similar to the 10% of cases reported by El-Hawary *et al*<sup>[21]</sup> using the 2-incision technique, associ-

ated with 6-wk prophylaxis with indomethacin 25 mg 3 times a day for 6 wk. In particular they didn't observed any case of heterotopic ossification, and the only type of complication reported was a transient superficial radial nerve paresthesia, supporting a longer lasting prophylaxis against heterotopic ossification.

In our research tendon fixation was performed by 3 trans-osseous tunnels placed at the apex of radial tuberosity. In the last years, new fixation equipment like suture anchors, interference screws, and fixation buttons have been brought in and biomechanically tested<sup>[30-34]</sup>, demonstrating encouraging results<sup>[35-37]</sup>.

Clinical studies have found little difference between 1- and 2-incision approaches in terms of complications, re-ruptures, flexion and supination strength as well as endurance<sup>[21,23,26,38]</sup>. However, recently, it has been demonstrated that the 2-incision approach recreates more closely footprint position compared with the 1-incision approach<sup>[39]</sup>.

In conclusion, the Morrey's modified double-incision repair provided excellent outcome (including functional outcome, satisfaction, elbow and forearm motion, and grip strength) with few post-operative complications, mainly represented by heterotopic ossification and PIN injuries.

## COMMENTS

### Background

Biceps tendon ruptures occur at the distal aspect in 3% of all lesions. Both single-incision and 2-incision techniques, using various fixation methods, have been described to accomplish tendon reattachment to the bicipital tuberosity; however there is no consensus with respect to the best surgical approach.

### Research frontiers

Authors retrospectively reviewed 47 patients with distal rupture of biceps brachii treated between 2003 and 2012 in authors' Orthopedic Department with muscle-splitting double-incision technique.

### Innovations and breakthroughs

In the present research the Morrey's modified double-incision repair provided excellent outcome (including functional outcome, satisfaction, elbow and forearm motion, and grip strength) with few post-operative complications, mainly represented by heterotopic ossification and posterior interosseous nerve injuries.

### Peer review

The article is interesting, well written, documented and analyzed with tests valid and internationally recognized. Good and clear figures. The discussion and conclusions interesting and valid. The author think it can be published with high priority.

## REFERENCES

- 1 Safran MR, Graham SM. Distal biceps tendon ruptures:

- incidence, demographics, and the effect of smoking. *Clin Orthop Relat Res* 2002; **(404)**: 275-283 [PMID: 12439270]
- 2 **Baker BE**, Bierwagen D. Rupture of the distal tendon of the biceps brachii. Operative versus non-operative treatment. *J Bone Joint Surg Am* 1985; **67**: 414-417 [PMID: 3972865]
  - 3 **Dobbie RP**. Avulsion of the lower biceps brachii tendon: analysis of 51 previously unreported cases. *Am J Surg* 1941; **51**: 662-83 [DOI: 10.1016/S0002961041902039]
  - 4 **Norman WH**. Repair of avulsion of insertion of biceps brachii tendon. *Clin Orthop Relat Res* 1985; **(193)**: 189-194 [PMID: 3971622]
  - 5 **Hetsroni I**, Pilz-Burstein R, Nyska M, Back Z, Barchilon V, Mann G. Avulsion of the distal biceps brachii tendon in middle-aged population: is surgical repair advisable? A comparative study of 22 patients treated with either nonoperative management or early anatomical repair. *Injury* 2008; **39**: 753-760 [PMID: 18541242 DOI: 10.1016/j.injury.2007.11.287]
  - 6 **Miyamoto RG**, Elser F, Millett PJ. Distal biceps tendon injuries. *J Bone Joint Surg Am* 2010; **92**: 2128-2138 [PMID: 20810864 DOI: 10.2106/JBJS.I.01213]
  - 7 **DAVIS WM**, YASSINE Z. An etiological factor in tear of the distal tendon of the biceps brachii; report of two cases. *J Bone Joint Surg Am* 1956; **38-A**: 1365-1368 [PMID: 13376661]
  - 8 **McReynolds IS**. Avulsion of the insertion of the biceps brachii tendon and its surgical treatment. *J Bone Joint Surg* 1963; **45A**: 1780-1781
  - 9 **Fischer WR**, Shepanek LA. Avulsion of the insertion of the biceps brachii; report of a case. *J Bone Joint Surg Am* 1956; **38-A**: 158-159 [PMID: 13286276]
  - 10 **Meherin JM**, Kilgore ES Jr. The treatment of ruptures of the distal biceps brachii tendon. *Am J Surg* 1960; **99**: 636-638
  - 11 **Sotereanos DG**, Pierce TD, Varitimidis SE. A simplified method for repair of distal biceps tendon ruptures. *J Shoulder Elbow Surg* 2000; **9**: 222-233 [PMID: 10888168]
  - 12 **Boyd NB**, Anderson LD. A method for reinsertion of the distal biceps brachii tendon. *J Bone Joint Surg* 1961; **43A**: 1041-1043
  - 13 **Boucher PR**, Morton KS. Rupture of the distal biceps brachii tendon. *J Trauma* 1967; **7**: 626-632 [PMID: 6038592]
  - 14 **Friedmann E**. Rupture of the distal biceps brachii tendon. Report on 13 cases. *JAMA* 1963; **184**: 60-63 [PMID: 13959826]
  - 15 **Kron SD**, Satinsky VP. Avulsion of the distal biceps brachii tendon. *Am J Surg* 1954; **88**: 657-659 [PMID: 13197658]
  - 16 **Failla JM**, Amadio PC, Morrey BF, Beckenbaugh RD. Proximal radioulnar synostosis after repair of distal biceps brachii rupture by the two-incision technique. Report of four cases. *Clin Orthop Relat Res* 1990; **(253)**: 133-136 [PMID: 2317966]
  - 17 **Katzman BM**, Caligiuri DA, Klein DM, Gorup JM. Delayed onset of posterior interosseous nerve palsy after distal biceps tendon repair. *J Shoulder Elbow Surg* 1997; **6**: 393-395 [PMID: 9285880]
  - 18 **Morrey BF**, Askew LJ, An KN, Dobyns JH. Rupture of the distal tendon of the biceps brachii. A biomechanical study. *J Bone Joint Surg Am* 1985; **67**: 418-421 [PMID: 3972866]
  - 19 **Lintner S**, Fischer T. Repair of the distal biceps tendon using suture anchors and an anterior approach. *Clin Orthop Relat Res* 1996; **(322)**: 116-119 [PMID: 8542686]
  - 20 **Barnes SJ**, Coleman SG, Gilpin D. Repair of avulsed insertion of biceps. A new technique in four cases. *J Bone Joint Surg Br* 1993; **75**: 938-939 [PMID: 8245086]
  - 21 **El-Hawary R**, Macdermid JC, Faber KJ, Patterson SD, King GJ. Distal biceps tendon repair: comparison of surgical techniques. *J Hand Surg Am* 2003; **28**: 496-502 [PMID: 12772111]
  - 22 **Weinstein DM**, Ciccone WJ, Buckler MC, Balthrop PM, Busey TD, Elias JJ. Elbow function after repair of the distal biceps brachii tendon with a two-incision approach. *J Shoulder Elbow Surg* 2008; **17**: 82S-86S [PMID: 18069018]
  - 23 **Grewal R**, Athwal GS, MacDermid JC, Faber KJ, Drosdowech DS, El-Hawary R, King GJ. Single versus double-incision technique for the repair of acute distal biceps tendon ruptures: a randomized clinical trial. *J Bone Joint Surg Am* 2012; **94**: 1166-1174 [PMID: 22760383 DOI: 10.2106/JBJS.K.00436]
  - 24 **Siebenlist S**, Elser F, Sandmann GH, Buchholz A, Martetschlager F, Stöckle U, Lenich A. The double intramedullary cortical button fixation for distal biceps tendon repair. *Knee Surg Sports Traumatol Arthrosc* 2011; **19**: 1925-1929 [PMID: 21655996 DOI: 10.1007/s00167-011-1569-y]
  - 25 **Keener JD**. Controversies in the surgical treatment of distal biceps tendon ruptures: single versus double-incision repairs. *J Shoulder Elbow Surg* 2011; **20**: S113-S125 [PMID: 21281916 DOI: 10.1016/j.jse.2010.11.009]
  - 26 **Cil A**, Merten S, Steinmann SP. Immediate active range of motion after modified 2-incision repair in acute distal biceps tendon rupture. *Am J Sports Med* 2009; **37**: 130-135 [PMID: 18957526 DOI: 10.1177/0363546508323749]
  - 27 **Baratz M**, King GJ, Steinmann S. Repair of distal biceps ruptures. *J Hand Surg Am* 2012; **37**: 1462-1466 [PMID: 22480498 DOI: 10.1016/j.jhsa.2012.02.008]
  - 28 **Chavan PR**, Duquin TR, Bisson LJ. Repair of the ruptured distal biceps tendon: a systematic review. *Am J Sports Med* 2008; **36**: 1618-1624 [PMID: 18658024 DOI: 10.1177/0363546508321482]
  - 29 **Cheung EV**, Lazarus M, Taranta M. Immediate range of motion after distal biceps tendon repair. *J Shoulder Elbow Surg* 2005; **14**: 516-518 [PMID: 16194744]
  - 30 **Idler CS**, Montgomery WH, Lindsey DP, Badua PA, Wynne GF, Yerby SA. Distal biceps tendon repair: a biomechanical comparison of intact tendon and 2 repair techniques. *Am J Sports Med* 2006; **34**: 968-974 [PMID: 16476918 DOI: 10.1177/0363546505284185]
  - 31 **Kettler M**, Lunger J, Kuhn V, Mutschler W, Tingart MJ. Failure strengths in distal biceps tendon repair. *Am J Sports Med* 2007; **35**: 1544-1548 [PMID: 17395957 DOI: 10.1177/0363546507300690]
  - 32 **Lemos SE**, Ebrahimzadeh E, Kvitne RS. A new technique: in vitro suture anchor fixation has superior yield strength to bone tunnel fixation for distal biceps tendon repair. *Am J Sports Med* 2004; **32**: 406-410 [PMID: 14977665 DOI: 10.1177/0363546503261720]
  - 33 **Mazzocca AD**, Burton KJ, Romeo AA, Santangelo S, Adams DA, Arciero RA. Biomechanical evaluation of 4 techniques of distal biceps brachii tendon repair. *Am J Sports Med* 2007; **35**: 252-258 [PMID: 17192318 DOI: 10.1177/0363546506294854]
  - 34 **Pereira DS**, Kvitne RS, Liang M, Giacobetti FB, Ebrahimzadeh E. Surgical repair of distal biceps tendon ruptures: a biomechanical comparison of two techniques. *Am J Sports Med* 2002; **30**: 432-436 [PMID: 12016087]
  - 35 **Balabaud L**, Ruiz C, Nonnenmacher J, Seynaeve P, Kehr P, Rapp E. Repair of distal biceps tendon ruptures using a suture anchor and an anterior approach. *J Hand Surg Br* 2004; **29**: 178-182 [PMID: 15010168]
  - 36 **Greenberg JA**, Fernandez JJ, Wang T, Turner C. EndoButton-assisted repair of distal biceps tendon ruptures. *J Shoulder Elbow Surg* 2003; **12**: 484-490 [PMID: 14564273]
  - 37 **Khan W**, Agarwal M, Funk L. Repair of distal biceps tendon rupture with the Biotenodesis screw. *Arch Orthop Trauma Surg* 2004; **124**: 206-208 [PMID: 14758491]
  - 38 **Johnson TS**, Johnson DC, Shindle MK, Allen AA, Weiland AJ, Cavanaugh J, Noonan D, Lyman S. One- versus two-incision technique for distal biceps tendon repair. *HSS J* 2008; **4**: 117-122 [PMID: 18815854 DOI: 10.1007/s11420-008-9085-4]
  - 39 **Jobin CM**, Kippe MA, Gardner TR, Levine WN, Ahmad CS. Distal biceps tendon repair: a cadaveric analysis of suture anchor and interference screw restoration of the anatomic footprint. *Am J Sports Med* 2009; **37**: 2214-2221 [PMID: 19622792 DOI: 10.1177/0363546509337451]

P-Reviewer: Azzoni R S-Editor: Wen LL L-Editor: A  
E-Editor: Lu YJ



## Dabigatran etixilate and traumatic brain injury: Evolving anticoagulants require evolving care plans

Sam Pakraftar, Daniela Atencio, John English, Alain Corcos, Eric M Altschuler, Kurt Stahlfeld

Sam Pakraftar, Daniela Atencio, John English, Kurt Stahlfeld, Department of Surgery, UPMC Mercy, Pittsburgh, PA 15219, United States

Alain Corcos, Department of Trauma and Acute Care Surgery, UPMC Mercy, Pittsburgh, PA 15219, United States

Eric M Altschuler, Department of Neurosurgery, UPMC Mercy, Pittsburgh, PA 15219, United States

**Author contributions:** Pakraftar S, Stahlfeld K and Corcos A developed study design; Pakraftar S collected and analyzed data; Pakraftar S, Atencio D, English J and Stahlfeld K wrote manuscript; Corcos A, Stahlfeld K and Altschuler EM were involved in editing manuscript; all authors approved the final version of the manuscript.

**Correspondence to:** Kurt Stahlfeld, MD, Department of Surgery, UPMC Mercy, 1400 Locust St., Suite 6512, Pittsburgh, PA 15219, United States. [stahlfeldk@upmc.edu](mailto:stahlfeldk@upmc.edu)

Telephone: +1-412-2328097 Fax: +1-412-2328096

Received: November 26, 2013 Revised: June 25, 2014

Accepted: July 12, 2014

Published online: August 16, 2014

### Abstract

**AIM:** To investigate the outcomes of trauma patients with traumatic brain injury (TBI) on Dabigatran Etxilate (DE).

**METHODS:** Following IRB approval, all patients taking DE who were admitted to our level 1 trauma service were enrolled in the study. Injury complexity, length of stay (LOS), intensive care length of stay, operative intervention, therapeutic interventions and outcomes were analyzed retrospectively.

**RESULTS:** Twenty-eight of 4310 admissions were taking DE. Eleven patients were excluded on concurrent antiplatelet therapy. Average age was 77.14 years (64-94 years), and average LOS was 4.7 d (1-35 d). Thirty-two percent were admitted with intracranial hemorrhage. Eighteen percent received factor VII, and 22% received dialysis in attempts to correct coagulopathy. Mortality was 21%.

**CONCLUSION:** The low incidence, absence of reversal agents, and lack of practice guidelines makes managing patients with TBI taking DE frustrating and provider specific. Local practice guidelines may be helpful in managing such patients.

© 2014 Baishideng Publishing Group Inc. All rights reserved.

**Key words:** Dabigatran; Brain injury; Anticoagulation; Dabigatran reversal

**Core tip:** Dabigatran Etxilate (DE) and other novel anticoagulants that lack reversal agents complicate the care of trauma patients. Current practice guidelines should be available to aid in managing patients with traumatic brain injury on DE.

Pakraftar S, Atencio D, English J, Corcos A, Altschuler EM, Stahlfeld K. Dabigatran etixilate and traumatic brain injury: Evolving anticoagulants require evolving care plans. *World J Clin Cases* 2014; 2(8): 362-366 Available from: URL: <http://www.wjgnet.com/2307-8960/full/v2/i8/362.htm> DOI: <http://dx.doi.org/10.12998/wjcc.v2.i8.362>

### INTRODUCTION

Arterial and venous thromboembolism (VTE) is a significant cause of mortality and morbidity. Direct and indirect inhibitors of coagulation are being increasingly utilized for prophylaxis and treatment of myocardial infarction, valvular disease, deep venous thrombosis, pulmonary embolism, atrial fibrillation, and stroke<sup>[1]</sup>. Compliance rates for VTE prophylaxis are being used in pay for performance by third party payors and have been included as an independent new core measure by the Center for Medicare and Medicaid Services<sup>[2]</sup>.

Many anticoagulants are available to the clinician: an-



**Table 1** Traumatic brain injury, non-traumatic brain injury and acute care surgery patients on Dabigatran

	TBI	nonTBI	ACS	Total
<i>n</i>	9	10	9	28
Age (yr)	83.4 (8.48)	73.6 (11.6)	76 (8.87)	77.14 (10.5)
M:F	4 M: 5 F	5 M: 5 F	6 M: 3 F	15 M: 13 F
INR	1.69 (0.43)	1.3 <sup>1</sup>	1.3 <sup>1</sup>	1.45 <sup>1</sup>
PTT (s)	54.55 (18.09)	48.05 (33.18)	37 <sup>1</sup>	50.35 <sup>1</sup>
Concurrent AntiPlatelet	5	2	4	11
Hemodialysis	2	3	1	6
Factor VII	2	2	1	5
Mortality	2	1	3	6

<sup>1</sup>Median data was used due to outliers. TBI: Traumatic brain injury; PTT: Partial thromboplastin time.

tiplatelet agents, thromboxane A2 receptor antagonists, Adenosine Diphosphate (ADP) receptor antagonists, Protease Activated Receptor (PAR)-1 antagonists, inhibitors of initiation or propagation of coagulation, Factor IX-directed antibodies, direct and indirect Factor Xa inhibitors, factor Va and VIIIa inhibitors, inhibitors of fibrin formation, and medications than enhance fibrinolysis<sup>[3]</sup>. Due to the complication rate, volume of distribution, delayed onset, prolonged effect, unpredictable pharmacokinetics, food and medication interactions, and frequent monitoring associated with warfarin usage, industry has focused on developing oral thrombin and Factor Xa inhibitors for patients who require long-term anticoagulation.

Dabigatran Etxilate (DE) (Pradaxa<sup>®</sup>) 150 mg twice daily is the first orally available FDA approved direct thrombin inhibitor (DTI) in the United States. Due to predictable pharmacokinetics and pharmacodynamics, limited drug-drug interaction or effect of food, and no need for coagulation monitoring, DE was introduced enthusiastically and approved for treatment of non-valvular atrial fibrillation (AF) with a class 1 recommendation<sup>[4]</sup>. Head to head trials with warfarin showed that DE reduced the risk of stroke by more than one-half and that mortality from intracranial hemorrhage was not increased (1B)<sup>[5]</sup>. Patients on DE had a significantly higher rate of gastrointestinal bleeding and trended toward an increased number of adjudicated coronary events<sup>[5]</sup>. As no reversal agent or accurate method of measuring the clinical effect of DE exists, recommendations for patients undergoing elective surgery currently taking DE are to stop the DE 1-5 d prior to the procedure, depending on the complexity of the surgery and the patient's creatinine clearance (CrCL)<sup>[3,6,7]</sup>.

Trauma patients and those with acute surgical issues frequently do not have the luxury of waiting 1-5 d for the pharmacologic effects of DE to subside. After several frustrating patient interactions that essentially involved supportive care, we hypothesized that patients taking DE admitted with traumatic injuries would have poor outcomes due to the lack of a reversal agent. We herein report our series of patients admitted to our trauma and acute care surgery service on DE, focusing on patients with traumatic brain injury (TBI), and comment on potential treatment strategies available.

## MATERIALS AND METHODS

After receiving institutional board approval, all patients between October 2011 and September 2012 admitted through the emergency room to one health system's two Level 1 trauma centers were prospectively evaluated to include all patients who were actively taking DE on admission. Only patients over the age of 18 with vital signs on arrival were included in the study.

Patient management was directed by the trauma and acute care surgeon in conjunction with subspecialized physicians. Presence of traumatic brain injury on computed tomography (CT) was verified by a board certified radiologist, and demographic data, admission laboratory data including hemoglobin, prothrombin time (PT/INR), and partial thromboplastin time (PTT), patient acuity, therapeutic interventions, transfusion requirements, and patient outcomes were evaluated retrospectively.

### Statistical analysis

Statistical analysis was performed using Microsoft Excel Analysis ToolPak (Student *t*-Test,  $\chi^2$  Test, Anova).

## RESULTS

Of the 4310 admissions to the trauma and acute care surgery service over the twelve month period, 31 (0.7%) patients taking DE were identified. Nine of the 1259 admissions with CT evidence of TBI were taking DE. Three of the 31 patients on DE were excluded because no significant surgical pathology was present. Of the remaining 28, the average age (SD) was 77.14 (10.5), median admission INR/PTT was 1.45/50.3, 11 were on concurrent anti-platelet medications. 6 received DE directed dialysis and 6 received factor VIIa. Mortality was 21% (6/28). Results for the subgroups of patients with TBI, injury without TBI, and acute care surgery are displayed in Table 1.

The individual data for the nine TBI injured patients on DE are listed in Table 2. Eight patients (89%) were taking DE for stroke prophylaxis and one for treatment of a prior pulmonary embolism. Recorded dosage was 150mg BID for all 9 subjects. Eight of nine patients had an elevated INR (mean = 1.68) and PTT (mean = 54). Four patients were taking antiplatelet medications concomitantly. Types of intracranial hemorrhage observed in these patients were sub-arachnoid (4), sub-dural (2), combined (2), and intraparenchymal (1). Two of the three patients who received no intervention died: one presented with a non-survivable injury and the second initially appeared to have a minor injury that within hours progressed clinically and radiographically (Figure 1).

## DISCUSSION

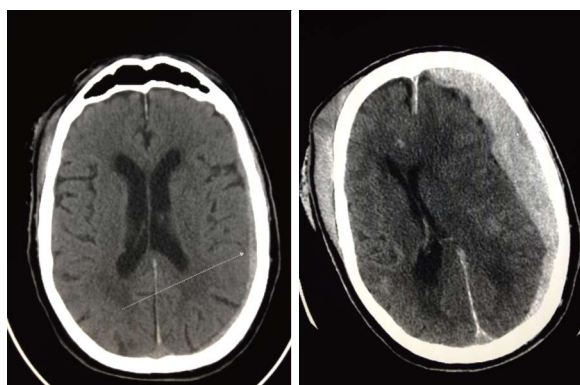
Coagulopathy and associated bleeding remain significant issues in the trauma population. Coagulopathy due to blood loss is addressed by controlling the ongoing bleed-



**Table 2** Data of patients with traumatic brain injury

Case	Age, yr	LOS	iLOS	INR	PTT	Anti-Platelet	CrCl	HD	VIIa	FFP	Anti-Platelet	Mortality
1	94	4	3	1.6	61.3	Y	24.1	N	N	Y	Y	N
2	83	1	1	2.5	69	Y	45.6	N	N	N	N	Y
3	79	2	0	1.6	54.3	N	49.8	N	N	N	N	N
4	89	6	3	1.4	35.7	N	40.2	N	N	Y	N	N
5	86	35	5	1.8	50.7	Y	32.4	Y	Y	Y	Y	N
6	64	3	2	1.7	57	Y	99	N	N	Y	N	N
7	88	1	1	1.8	61	N	61.3	N	N	N	N	Y
8	86	2	1	0.9	20	N	46	N	N	Y	N	N
9	82	4	2	1.9	82	Y	46.4	Y	Y	Y	Y	N

LOS: Length of stay; iLOS: Intensive care length of stay; PTT: Partial thromboplastin time.



**Figure 1** Rapid progression of intracerebral hemorrhage on patient on Dabigatran Etexilate.

ing, keeping the patient warm and perfused, and using accepted protocols to replace blood and blood products. Pharmacologically induced coagulopathy poses a similar risk and is becoming more prevalent, with approximately 1.5 million Americans taking a vitamin K antagonist daily<sup>[8]</sup>. Treatment of these patients is fairly straightforward as the effect of vitamin K is easily measured and the deficient clotting factors can be replaced.

With the introduction of DE, and subsequent FDA approval of direct factor Xa inhibitors rivaroxaban (Xarelto®) and apixaban (Eliquis®), the trauma surgeon faces a unique challenge in patients with ongoing bleeding who may or may not require surgery. DE is an orally available direct thrombin inhibitor that is rapidly converted to dabigatran and binds to free and clot bound thrombin. Time to maximum concentration is 2 h, half-life is 12-17 h, limited protein binding suggest DE may be dialyzed, and over 80% of the drug is excreted by the kidneys<sup>[3,7,9]</sup>. The FDA-approved indication is to reduce the risk of stroke and systemic embolism in patients with non-valvular atrial fibrillation<sup>[10]</sup>.

Advantages of DE include the significant risk reduction of stroke and systemic embolization, predictable pharmacokinetics requiring no coagulation monitoring, a fast onset and offset of action, a relatively short half-life, and limited drug-drug interaction<sup>[3,7,11]</sup>. Drug cost compared to monitoring with warfarin is revenue neutral. Worldwide there have been at least 260 episodes of

post-marketing bleeds resulting in death in patients on DE<sup>[12,13]</sup>. Our study documents the institutional complication rates of patients on DE and not the effectiveness of DE *vs* oral vitamin K antagonist. The dilemma facing the trauma surgeon is that there is no accepted laboratory test to measure the effect of DE nor are there recommended reversal agents<sup>[3,6,7,14]</sup>. Both of these factors are especially relevant in the patient with a TBI. The anticoagulant effects have attempted to be quantified in normal human subjects, laboratory animals, and *in vitro* by adding DE to human serum. Assays evaluated include PT, aPTT, factors II, VIII, IX, X, and XI, quantitative D-dimer, reptilase time, von Willebrand factor antigen, antithrombin, plasminogen, thrombin clotting time, protein C activity, ecarin clotting time, and activated protein C resistance<sup>[1,11]</sup>. Although analytes may be elevated with various concentrations of DE, most notably the aPTT and thrombin clotting time, reported levels frequently are factitiously elevated or low, display incomplete correction, do not correlate with serum levels leading to misdiagnosis and mismanagement, or are insensitive or oversensitive, making virtually any result unreliable<sup>[11]</sup>. The best determinate of DE effect is knowing the timing of administration, as peak effect is usually two hours after ingestion, the dosage and the patient's renal function (CrCl > 50 provides normal excretion)<sup>[9]</sup>.

Treatment can be simplistic and futile as no known DE counteracting agent exists, so any form of intervention in patients with life-threatening bleeding is empirical. What makes this even more frustrating is the individual trauma surgeon most likely treats a patient taking DE once every several months, has no recommended guidelines, and may be unfamiliar with the intricacies and pharmacokinetics of the most recently approved oral anticoagulant. Considering that not intervening when a patient is actively bleeding is difficult for the treating surgeon, we will discuss the rationale behind several available treatment strategies although all lack even level 3 evidence.

Excluding direct compression, topical thrombin, and simple surgical procedures to obtain hemostasis, viable options to treat extensively injured, TBI, and complex surgical patients taking DE include oral charcoal, activated prothrombin complex concentrates (aPCC), recombinant factor VIIa, concentrates of coagulation factors II,

IX, and X, and dialysis.

Oral charcoal can be used within two hours of ingestion as charcoal significantly inhibits absorption of DE<sup>[6,7]</sup>. Kcentra (CSL Behring LLC) is the only four factor prothrombin complex concentrate available in the United States, has not been shown to correct the aPTT in healthy volunteers taking DE, but high doses have been shown to limit intracranial bleeding in rats<sup>[3,14]</sup>. In a patient with life-threatening bleeding with limited therapeutic options, an INR based dose of 25-50 IU/kg may be justified<sup>[6]</sup>. Recombinant VIIa has not demonstrated any alteration in the coagulation profile or outcomes in healthy volunteers or laboratory animals taking DE and has documented higher arterial thromboembolic events<sup>[15]</sup>. Subsequently, salvage therapy with rVIIa should be used cautiously, although a case report suggests high dose therapy (7.2 mg × 2) may be beneficial<sup>[16]</sup>. Activated PCC has been shown to correct the anticoagulant effect of DE in animal models and reduces clot initiation time in humans *in vitro*. Siegal suggests using aPCC (80 U/kg) over PCC in patients taking DE, but reverses the recommendation for patients taking rivaroxaban (XareltoR) or apixaban (Eliquis), acknowledging that any such recommendation is based on limited data<sup>[17]</sup>. Kcentra has been shown to partially reverse the effects of factor Xa inhibitors<sup>[14]</sup>.

Dialysis is an attractive option as DE is not plasma bound and excreted renally, but this is the most invasive option and use may be limited due to injury severity. In patients with end-stage renal disease, dialysis removed 62% of circulating DE within two hours, although due to the volume of distribution serum levels rebounded quickly upon cessation of dialysis<sup>[9]</sup>. Selective case reports suggest that prolonged dialysis (6 h) with flow rates of 700 mL/min improve outcome<sup>[16]</sup>.

Maintaining adequate diuresis is important for all patients, but should not be overlooked as DE is excreted renally. Currently no role exists for desmopressin, protamine sulfate, tranexamic acid, or vitamin K, or fresh frozen plasma<sup>[3,6,7]</sup>. Platelet concentrates should only be used in cases with thrombocytopenia or concurrent antiplatelet therapies. Although not yet available, a monoclonal antibody directed against DE is under development<sup>[17]</sup>.

In our experience, less than one percent of trauma and acute surgical admissions were taking DE and each surgeon averaged fewer than two patients per year. The percentage of patients with TBI is remarkably similar. With such limited numbers, and reviewing the largest industry sponsored trial (18113 patients) reporting outcomes of 22 patients with TBI, level 1 management recommendations are unlikely<sup>[18]</sup>.

Subsequently, we developed an in-house protocol for patients admitted taking DE, where we obtain baseline clotting studies, a stat hematology consult for major or life-threatening hemorrhage, a nephrology consult for initiation of hemodialysis, and the option of giving a 40 mcg/kg IV dose of rfactor VIIa or Kcentra.

Our study is limited by the small sample size and

retrospective collection of the data. Additionally, recommendations extrapolated from the literature combine data from multiple laboratories and include human, animal, and *in-vitro* studies. Finally, treatment is individualized and up to the discretion of the surgeon.

In a conclusion, DE is a cost-neutral highly effective oral direct thrombin inhibitor approved recently along with two factor Xa inhibitors, rivaroxaban and apixaban. Management of the traumatic brain injury patient taking DE poses unique and confounding issues as the effect of DE is not measurable and no reversal agents are currently recommended. Trauma surgeons manage patients on DE infrequently and such encounters may be frustrating. For patients taking DE, strategies for non-operative management of bleeding are discretionary and institution dependent and include oral charcoal, maintaining adequate diuresis, PCC, aPCC, and dialysis.

## COMMENTS

### Background

Seventy million Americans will be over the age of 65 by 2030 and five percent of these patients have atrial fibrillation and are candidates for anticoagulation. In 2010, the ACC Foundation and the AHA added Dabigatran Etexilate (DE) to their treatment guidelines with a class 1 recommendation for non-valvular atrial fibrillation. DE is an attractive alternative to warfarin (WF) due to improved outcomes and the lack of need for serial monitoring. However, it poses a risk to the trauma population because of an extended half-life and the lack of a reversal agent. Therefore it was our aim to review the outcomes of patients with TBI on DE.

### Research frontiers

DE and other novel anticoagulants that lack a true reversal agent post a unique dilemma for trauma surgeons. Local care plans should be initiated until dose specific reversal agents are commercial available.

### Applications

Current practice guidelines should be available to aid in managing patients with traumatic brain injury on DE. Therapeutic options include: oral charcoal, maintaining adequate diuresis, prothrombin complex concentrates, activated prothrombin complex concentrates, and dialysis.

### Terminology

Dabigatran Etexilate is a new oral anticoagulant that works by directly inhibiting thrombin in the clotting cascade.

### Peer review

This is a single institution observation study and it is limited as such. Future research goals will be multi institution collaborations on not just DE but other novel agents in the hopes of developing nationwide guidelines for treatment of novel agents until industry specific antidotes are commercially available.

## REFERENCES

- 1 Weitz JI, Hirsh J, Samama MM. New antithrombotic drugs: American College of Chest Physicians Evidence-Based Clinical Practice Guidelines (8th Edition). *Chest* 2008; **133**: 234S-256S [PMID: 18574267 DOI: 10.1378/chest.08-0673]
- 2 Amin AN, Deitelzweig SB. Optimizing the prevention of venous thromboembolism: recent quality initiatives and strategies to drive improvement. *Jt Comm J Qual Patient Saf* 2009; **35**: 558-564 [PMID: 19947332]
- 3 Ageno W, Gallus AS, Wittkowsky A, Crowther M, Hylek EM, Palareti G. Oral anticoagulant therapy: Antithrombotic Therapy and Prevention of Thrombosis, 9th ed: American College of Chest Physicians Evidence-Based Clinical Practice Guidelines. *Chest* 2012; **141**: e44S-e88S [PMID: 22315269 DOI: 10.1378/chest.11-2292]
- 4 Wann LS, Curtis AB, Ellenbogen KA, Estes NA, Ezekowitz

- MD, Jackman WM, January CT, Lowe JE, Page RL, Slotwimer DJ, Stevenson WG, Tracy CM, Fuster V, Rydén LE, Cannom DS, Crijns HJ, Curtis AB, Ellenbogen KA, Halperin JL, Kay GN, Le Heuzey JY, Lowe JE, Olsson SB, Prystowsky EN, Tamargo JL, Wann LS, Jacobs AK, Anderson JL, Albert N, Creager MA, Ettinger SM, Guyton RA, Halperin JL, Hochman JS, Kushner FG, Ohman EM, Stevenson WG, Yancy CW. 2011 ACCF/AHA/HRS focused update on the management of patients with atrial fibrillation (update on dabigatran). A report of the American College of Cardiology Foundation/American Heart Association Task Force on Practice Guidelines. *Heart Rhythm* 2011; **8**: e1-e8 [PMID: 21324421 DOI: 10.1016/j.jacc.2011.01.010]
- 5 **Connolly SJ**, Ezekowitz MD, Yusuf S, Eikelboom J, Oldgren J, Parekh A, Pogue J, Reilly PA, Themeles E, Varrone J, Wang S, Alings M, Xavier D, Zhu J, Diaz R, Lewis BS, Darius H, Diener HC, Joyner CD, Wallentin L. Dabigatran versus warfarin in patients with atrial fibrillation. *N Engl J Med* 2009; **361**: 1139-1151 [PMID: 19717844 DOI: 10.1056/NEJMoa0905561]
- 6 **Siegal DM**, Crowther MA. Acute management of bleeding in patients on novel oral anticoagulants. *Eur Heart J* 2013; **34**: 489-498b [PMID: 23220847 DOI: 10.1093/eurheartj/ehs408]
- 7 **van Ryn J**, Stangier J, Haertter S, Liesenfeld KH, Wienen W, Feuring M, Clemens A. Dabigatran etexilate--a novel, reversible, oral direct thrombin inhibitor: interpretation of coagulation assays and reversal of anticoagulant activity. *Thromb Haemost* 2010; **103**: 1116-1127 [PMID: 20352166 DOI: 10.1160/TH09-11-0758]
- 8 **Gage BF**, Fihn SD, White RH. Management and dosing of warfarin therapy. *Am J Med* 2000; **109**: 481-488 [PMID: 11042238 DOI: 10.1016/S0002-9343(00)00545-3]
- 9 **Chang DN**, Dager WE, Chin AI. Removal of dabigatran by hemodialysis. *Am J Kidney Dis* 2013; **61**: 487-489 [PMID: 23219111 DOI: 10.1053/j.ajkd.2012.08.047]
- 10 **FDA Drug Safety Communication**. Safety review of post-market reports of serious bleeding events with the anticoagulant Pradaxa (Dabigatran Etexilate Mesylate) 2012. Available from: URL: <http://www.fda.gov/Drugs/Drug-Safety/ucm282724.htm#data>
- 11 **Adcock DM**, Gosselin R, Kitchen S, Dwyre DM. The effect of dabigatran on select specialty coagulation assays. *Am J Clin Pathol* 2013; **139**: 102-109 [PMID: 23270905 DOI: 10.1309/AJCPY6G6ZITVKPVH]
- 12 **Huang GS**, Chance EA. When dabigatran and trauma collide. *Am Surg* 2013; **79**: 113-114 [PMID: 23317625]
- 13 **Wood S**. Dabigatran: 260 fatal bleeds since approval worldwide. 2011; Medscape Multispecialty. Available from: URL: <http://www.medscape.com/viewarticle/753816>
- 14 **Eerenberg ES**, Kamphuisen PW, Sijpkens MK, Meijers JC, Buller HR, Levi M. Reversal of rivaroxaban and dabigatran by prothrombin complex concentrate: a randomized, placebo-controlled, crossover study in healthy subjects. *Circulation* 2011; **124**: 1573-1579 [PMID: 21900088 DOI: 10.1161/CIRCULATIONAHA.111.029017]
- 15 **Mayer SA**, Brun NC, Begtrup K, Broderick J, Davis S, Diringer MN, Skolnick BE, Steiner T. Efficacy and safety of recombinant activated factor VII for acute intracerebral hemorrhage. *N Engl J Med* 2008; **358**: 2127-2137 [PMID: 18480205 DOI: 10.1056/NEJMoa0707534]
- 16 **Warkentin TE**, Margetts P, Connolly SJ, Lamy A, Ricci C, Eikelboom JW. Recombinant factor VIIa (rFVIIa) and hemodialysis to manage massive dabigatran-associated post-cardiac surgery bleeding. *Blood* 2012; **119**: 2172-2174 [PMID: 22383791 DOI: 10.1182/blood-2011-11-393587]
- 17 **Siegal DM**, Cuker A. Reversal of novel oral anticoagulants in patients with major bleeding. *J Thromb Thrombolysis* 2013; **35**: 391-398 [PMID: 23389753 DOI: 10.1007/s11239-013-0885-0]
- 18 **Hart RG**, Diener HC, Yang S, Connolly SJ, Wallentin L, Reilly PA, Ezekowitz MD, Yusuf S. Intracranial hemorrhage in atrial fibrillation patients during anticoagulation with warfarin or dabigatran: the RE-LY trial. *Stroke* 2012; **43**: 1511-1517 [PMID: 22492518 DOI: 10.1161/STROKEAHA.112.650614]

P- Reviewer: Kim D S- Editor: Wen LL L- Editor: A  
E- Editor: Lu YJ



## Desmoplastic small round cell tumor with atypical immunohistochemical profile and rhabdoid-like differentiation

Li Liang, Nina Tatevian, Meenakshi Bhattacharjee, Kuojen Tsao, John Hicks

Li Liang, Nina Tatevian, Meenakshi Bhattacharjee, Department of Pathology and Laboratory Medicine, the University of Texas Health Science Center at Houston, Houston, TX 77030, United States

Kuojen Tsao, Department of Pediatric Surgery, the University of Texas Health Science Center at Houston, Houston, TX 77030, United States

John Hicks, Department of Pathology, Texas Children's Hospital, Houston, TX 77030, United States

Author contributions: Tatevian N, Hicks J and Liang L designed the report, collected the patient's clinical data and wrote the paper; Bhattacharjee M and Tsao K collected the patient's clinical data.

Supported by Department of Pathology, the University of Texas Health Science Center at Houston, United States

Correspondence to: Nina Tatevian, MD, Associate Professor, Director, Department of Pathology and Laboratory Medicine, University of Texas Health Science Center at Houston, 6431 Fannin, MSB-2230, Houston, TX 77030, United States. [nina.tatevian@uth.tmc.edu](mailto:nina.tatevian@uth.tmc.edu)

Telephone: +1-713-5005305 Fax: +1-713-5000730

Received: January 4, 2014 Revised: May 3, 2014

Accepted: June 10, 2014

Published online: August 16, 2014

### Abstract

Desmoplastic small round cell tumor (DSRCT) is a rare, aggressive malignant neoplasm of unknown origin, and is comprised of small round cells with a characteristic desmoplastic stroma. DSRCT typically expresses epithelial, mesenchymal and neural markers simultaneously. We describe a case of DSRCT with an atypical immunohistochemical profile and rhabdoid-like tumor cells on electron microscopy. In the present case, the neoplastic cells were positive only for vimentin, desmin (cytoplasmic membranous pattern) and CD56, and negative for smooth muscle actin, synaptophysin, CD117, CD45, myogenin, CAM5.2, pancytokeratin, WT1, EMA, CD99, neurofilament, CD34 and p53. Ki67 showed a low proliferative activity. Electron microscopy showed focal rhabdoid differentiation. However, INI-1

(SNF-5/BAF47) demonstrated preservation of nuclear positivity in the neoplastic cells. Cytogenetic studies showed translocation t(11;22)(p13;q12) confirming an EWSR1-WT1 translocation characteristic for DSRCT, and t(1;15)(q11;p11.2) of unknown significance. This case is a diagnostic challenge because of atypical immunohistochemical profile and cytogenetic study is crucial in rendering the correct diagnosis.

© 2014 Baishideng Publishing Group Inc. All rights reserved.

**Key words:** Desmoplastic small round cell tumor; Ultrastructure; Cytogenetics; Rhabdoid cells; EWSR1-WT1

**Core tip:** We describe a case of desmoplastic small round cell tumor (DSRCT) with an atypical immunohistochemical profile and rhabdoid-like tumor cells on electron microscopy (EM). DSRCT typically expresses epithelial, mesenchymal and neural markers simultaneously. In this case, the neoplastic cells were positive only for vimentin, desmin and CD56 and negative for epithelial and other muscle markers. EM showed focal rhabdoid differentiation, but INI-1 (SNF-5/BAF47) demonstrated preservation of nuclear positivity in the neoplastic cells. Cytogenetic studies showed translocation t(11;22)(p13;q12) confirming an EWSR1-WT1 translocation characteristic for DSRCT, and t(1;15)(q11;p11.2) of unknown significance.

Liang L, Tatevian N, Bhattacharjee M, Tsao K, Hicks J. Desmoplastic small round cell tumor with atypical immunohistochemical profile and rhabdoid-like differentiation. *World J Clin Cases* 2014; 2(8): 367-372 Available from: URL: <http://www.wjgnet.com/2307-8960/full/v2/i8/367.htm> DOI: <http://dx.doi.org/10.12998/wjcc.v2.i8.367>

### INTRODUCTION

Desmoplastic small round cell tumor (DSRCT) was first



described in 1989<sup>[1,2]</sup>. DSRCT is a rare, aggressive malignant neoplasm of unknown origin, and is comprised of small round cells with a characteristic desmoplastic stroma. DSRCT is most common in children and young adults (mean age 22 years), with a male predominance (male to female ratio 4:1)<sup>[3]</sup>. The most common location is the abdominal and/or pelvic cavity, but it has been described in many organ systems, including ovary, paratesticular region, kidney, lung, pleura, parotid gland and central nervous system<sup>[4-11]</sup>. Typically, DSRCT has a distinctive immunohistochemical profile and expresses polyphenotypic markers simultaneously. The tumor cells usually express epithelial (cytokeratin, epithelial membrane antigen), mesenchymal (desmin, vimentin) and neural (neuron-specific enolase, chromogranin, synaptophysin) markers. Desmin immunoreactive displays in a perinuclear *dot-like Golgi pattern*. DSRCTs with atypical morphology or immunohistochemical features have been reported<sup>[12,13]</sup>. Cytogenetics, FISH, RT-PCR and molecular testing are crucial in rendering the correct diagnosis<sup>[14]</sup>.

DSRCT is associated with a unique chromosomal translocation t(11;22)(p13;q12) which involves the Ewing sarcoma gene breakpoint region 1 (*EWSR1*) on 22q13 and the Wilms tumor gene (*WT1*) on chromosome 11p13<sup>[15]</sup>. *EWSR1* gene encodes EWS protein, which is a multifunctional protein associated with gene expression, cell signaling, and RNA processing and transport. *WT1* is a tumor suppressor gene that encodes a zinc finger protein which regulates several growth factors, including platelet-derived growth factor-A (PDGFA)<sup>[16]</sup>. The most common breakpoints involve the intron between *EWSR1* exon 7 and 8 and the intron between *WT1* exons 7 and 8, although breakpoint variations have been described<sup>[17-19]</sup>.

## CASE REPORT

An 8 years old male with no known significant past medical history presented with 1 wk history of vague abdominal pain. The child was afebrile, had regular bowel movements, tolerated a regular diet, and denied nausea and vomiting. Physical examination showed a mildly distended abdomen without a readily palpable mass. CT of the abdomen and pelvis revealed a 17-cm heterogeneously enhancing complex cystic lesion, which displaced the colon and small intestine laterally and superiorly. On exploratory laparotomy, the mass was adherent to the omentum. The mass was tossed, with large dilated blood vessels on the external surface of the tumor. The patient tolerated the surgical procedure well.

### Gross pathology

Upon gross examination, the mass was encapsulated, lobulated and measured 17.0 cm × 11.0 cm × 5.0 cm, with attached omental tissue (Figure 1A, B). Cross sections of the mass showed variegated cut appearance ranging from tan to red to black in color. Focal areas of hemorrhage and necrosis were noted.

### Microscopic and immunohistochemical features

Microscopic examination showed small round cell aggregates embedded in a fibromyxoid stroma (Figure 1C-F). The tumor cells were round to oval with scant cytoplasm, hyperchromatic nuclei and inconspicuous nucleoli. However, certain tumor cells have a different histomorphologic appearance with enlarged nuclei, open chromatin and prominent nucleoli. Focal tumor necrosis and hemorrhage were present, corresponding to these features seen upon gross examination. Prominent vascular proliferation was associated with the tumor. An atypical immunophenotype (Figure 2A-D) was demonstrated. The tumor cells were positive only for vimentin, desmin (cytoplasmic membranous pattern) and CD56, while being negative for smooth muscle actin, synaptophysin, CD117, CD45, myogenin, CAM5.2, pancytokeratin, WT1, EMA, CD99, neurofilament, CD34 and p53. Ki67 showed a low proliferative activity.

### Ultrastructural features

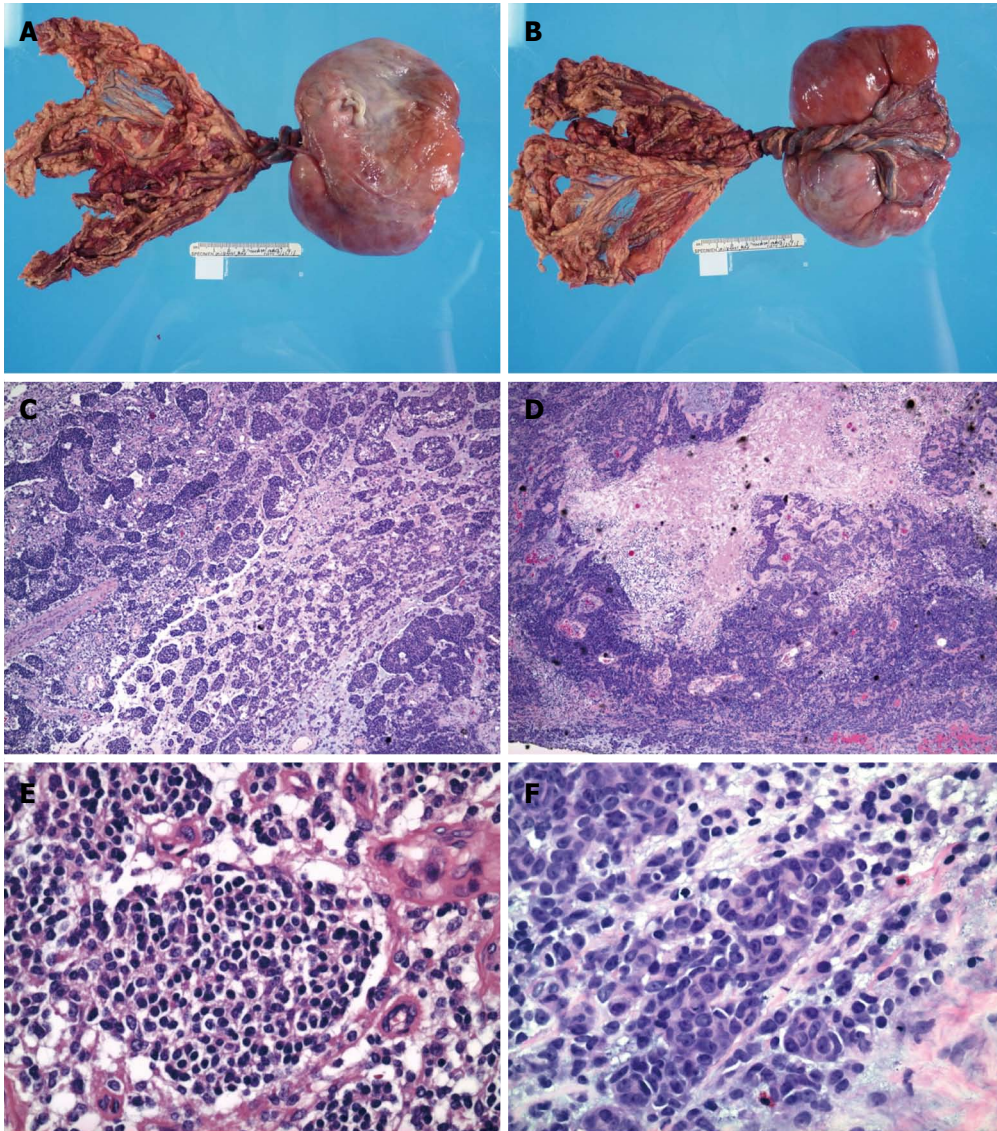
Electronic microscopy (Figure 2E, F) showed closely apposed tumor cells with rudimentary intercellular junctions and without myofilaments, dense core neurosecretory granules, cytokeratin-like intermediate filaments and no glycogen aggregates. The tumor cells had irregular nuclear outlines, prominent heterochromatin and moderate cytoplasm. There was readily identified rhabdoid differentiation within a certain population of tumor cells. These tumor cells had large aggregates of cytoplasmic filaments that displaced the nuclei to the periphery of the cell, with some tumor cells having indented nuclear profiles. There were also entrapped organelles within cytoplasmic filament whirls. Upon discovery of these rhabdoid cells on ultrastructural examination, immunohistochemical staining for INI-1 (SNF-5/BAF47) was performed. Surprisingly, all tumor cells demonstrated preservation of nuclear positivity, eliminating rhabdoid tumor from the differential diagnosis.

### Cytogenetics

Upon cytogenetic analysis, the karyotype of the cultured tumor cells was shown to be 46,XY, t(11;22)(p13;q12)[12]/92, idemx2[4] with t(1;15)(q11;p11.2). The t(11;22) translocation harbored the *EWSR1-WT1* translocation, a tumor-defining feature of DSRCT. A diagnosis of DSRCT with rhabdoid-like cell component was rendered.

## DISCUSSION

The differential diagnosis of a “small round cell tumor” includes Ewing sarcoma, Wilms tumor, neuroblastoma, medulloblastoma, rhabdomyosarcoma, small cell osteosarcoma, small cell synovial sarcoma, small cell carcinoma, lymphoma, and rhabdoid tumor. DSRCT has characteristic immunohistochemical features, with expression of epithelial, mesenchymal and neural markers simultaneously, which is helpful in differentiating DSRCT from other “small round cell tumors”. However



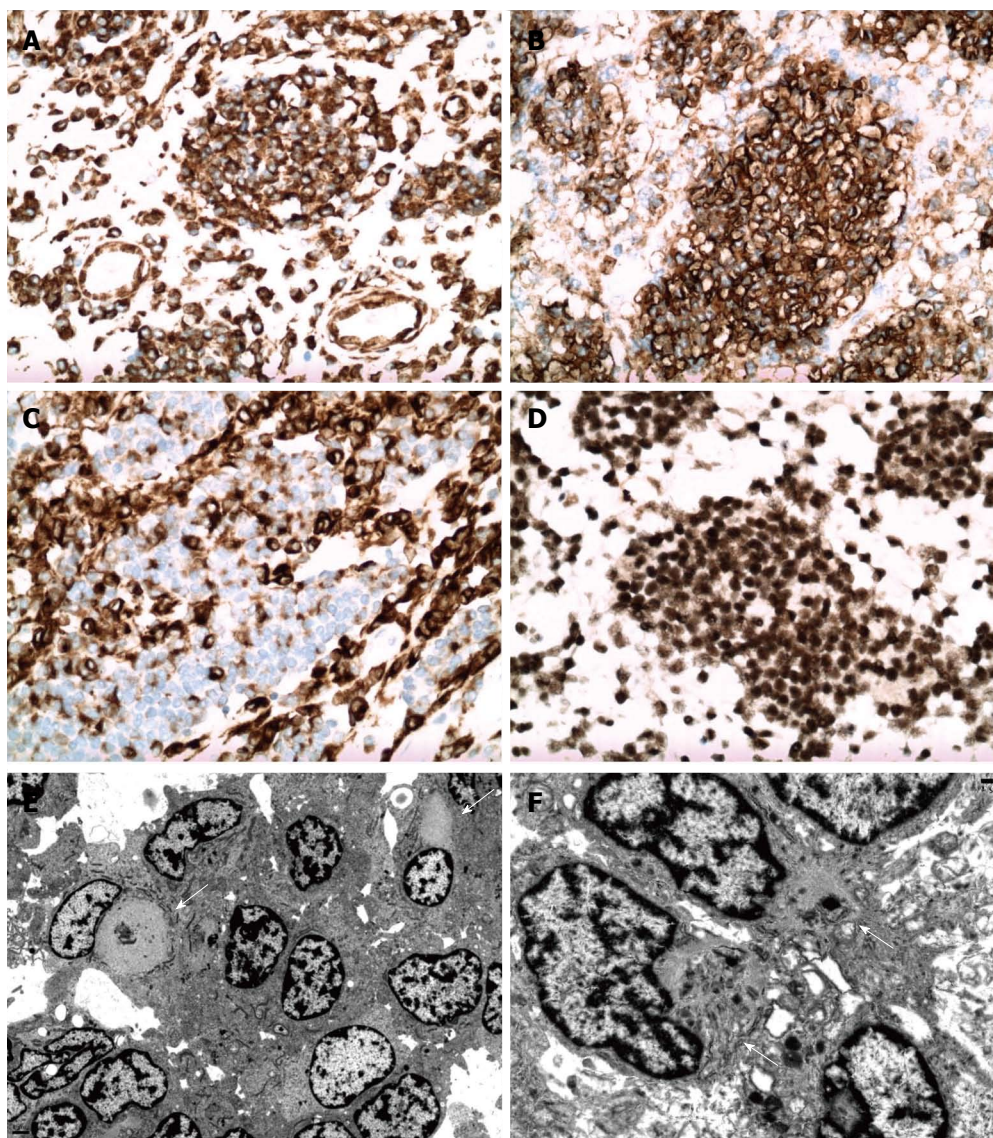
**Figure 1** Gross and microscopic feature of abdominal mass. A, B: Gross examination showed an encapsulated and lobulated soft tissue mass with attached omental tissue; C-F: The small round cell tumor possessed round to oval hyperchromatic nuclei with inconspicuous nucleoli and scant cytoplasm. Focal tumor cells with enlarged nuclei, open chromatin and prominent nucleoli, as well as rhabdoid differentiation were noted. Focal tumor necrosis and hemorrhages were present (HE staining).

in the present case, the tumor cells were negative for many epithelial, myogenic and neural markers and positive only for vimentin, CD56 and desmin. CD56 is a nonspecific marker, and expressed in many “small round cell tumors”, including alveolar rhabdomyosarcoma, embryonal rhabdomyosarcoma, neuroblastoma, Wilms tumor, neuroendocrine neoplasms and undifferentiated sarcoma<sup>[20]</sup>. Desmin showed a cytoplasmic membranous pattern, instead of the typical perinuclear dot-like Golgi pattern characteristic for DSRCT. The atypical immunohistochemical features made it difficult to make a correct diagnosis by morphologic and immunohistochemical features alone. DSRCT lacking epithelial markers and/or divergent immunophenotype has been described in several reports<sup>[12,13,21]</sup>. Cytogenetic and molecular studies are crucial in these cases in rendering an accurate diagnosis.

DSRCT can have many morphologic variations<sup>[22-24]</sup>.

In our case, focal rhabdoid differentiation was identified on EM. However, the nuclear expression of SNF-5(INI1/BAF47) was preserved in the tumor cells, which did not support a diagnosis of rhabdoid tumor. The ultrastructural features of DSRCT include intracellular whirls and packets of intermediate filaments that usually fill the cytoplasm and displace the nucleus, while entrapping cytoplasmic organelles within the filaments<sup>[25-27]</sup>. Rhabdoid differentiation, as well as focal areas with increased nuclear atypia, has been previously described in DSRCT<sup>[28]</sup>. Although DSRCT usually has a desmoplastic stroma, this was not present in our case. Prominent vascular proliferation can be seen in DSRCT, as in our case, and the differential diagnosis of infiltrating glomus tumor may be entertained. However, infiltrating glomus tumor typically expresses smooth muscle actin and variably desmin. Other morphologic variations previously described





**Figure 2** Immunohistochemical and ultrastructural features of abdominal mass. Tumor cells exhibited strong diffuse cytoplasmic vimentin expression (A), diffuse membranous CD56 expression (B), cytoplasmic and membranous desmin expression (C), and nuclear INI-1 reactivity (SNF-5/BAF47) with tumor cells and non-neoplastic cells. Electron microscopy (E, F) showed closely apposed tumor cells with irregular nuclear outlines and heterochromatin. There were intermixed tumor cells with aggregates and whirls of intermediate filaments (arrows) that displaced the nuclei and entrapped organelles.

in DSRCT, such as signet ring-like appearance, “zellballen” pattern, tubular-like structure or papillary areas were not identified in our case<sup>[23,29]</sup>.

Interestingly, our case not only had an unusual immunohistochemical profile, but also a unique karyotype. Cytogenetic study showed translocation t(11;22)(p13;q12), which is characteristic of DSRCT, and an additional translocation t(1;15)(q11;p11.2). Even though the characteristic *EWSR1/WT1* translocation can be detected by reverse transcription polymerase chain reaction (RT-PCR), cytogenetic testing is necessary to detect tumor-defining translocations, novel translocations and complex karyotypic aberrations. Of note, the *INI-1* (hSNF5) gene is located at 22q11.2 in close proximity to *EWSR1*. This close proximity may have led to dysregulation of the *INI-1* gene function without loss of *INI-1* gene protein expression. Rhabdoid tumors without *INI-1* gene loss

or mutation and expression of *INI-1* gene protein have been reported<sup>[30]</sup>. These rhabdoid tumors have loss or mutation of *SMARCA4* (19p13.2) which dysregulates a signaling pathway downstream from *INI-1* gene protein function. In an extensive search of the English language literature, the t(1;15)(q11;p11.2) has not been previously reported in pediatric neoplasia. Of interest, translocations involving 1q11 have been reported in myelodysplastic syndromes. The pericentromeric region of chromosome 1 is an unstable region involved in several chromosomal rearrangements. A possibility is that the heterochromatin of chromosome 1 may have a silencing effect, or otherwise interfering effect, with genes present in the region involved in the translocation. Few myelodysplastic syndrome cases with a der(1;15) translocation have been reported<sup>[31]</sup>.

In the present case, infrequent tumor cells also showed

tetraploid clonal evolution, which is common in many tumors and has been previously reported in DSRCT<sup>[32]</sup>. Our hypothesis is that the unusual immunohistochemical profile in our case was due to the complex karyotype. It is debatable if the tumors with complex karyotype should still be called DSRCT or a new category of “gray zone small blue cell tumor” should be created in the future. Currently, no standard oncologic therapy is available for DSRCT and the prognosis is dismal even with multimodality oncologic therapy<sup>[33-35]</sup>. The 5-year survival rate is approximately 15%<sup>[35]</sup>. The prognosis significance of DSRCT with complex karyotype is currently unclear.

## COMMENTS

### Case characteristics

An 8 years old male with no known significant past medical history presented with 1 wk history of vague abdominal pain.

### Clinical diagnosis

The child was afebrile, had regular bowel movements, tolerated a regular diet, and denied nausea and vomiting. Physical examination showed a mildly distended abdomen without a readily palpable mass.

### Differential diagnosis

Electronic computer X-ray tomography technique of the abdomen and pelvis revealed a 17-cm heterogeneously enhancing complex cystic lesion, which displaced the colon and small intestine laterally and superiorly.

### Treatment

The authors describe a case of desmoplastic small round cell tumor with an atypical immunohistochemical profile and rhabdoid-like tumor cells on electron microscopy.

### Experiences and lessons

This case is a diagnostic challenge because of atypical immunohistochemical profile and cytogenetic study is crucial in rendering the correct diagnosis.

### Peer review

The authors report an atypical small round cell tumor case. The manuscript is clearly written and the case is of interest.

## REFERENCES

- Gerald WL, Rosai J. Case 2. Desmoplastic small cell tumor with divergent differentiation. *Pediatr Pathol* 1989; **9**: 177-183 [PMID: 2473463 DOI: 10.3109/15513818909022347]
- Ordóñez NG, Zirkin R, Bloom RE. Malignant small-cell epithelial tumor of the peritoneum coexpressing mesenchymal-type intermediate filaments. *Am J Surg Pathol* 1989; **13**: 413-421 [PMID: 2469334 DOI: 10.1097/0000478-198905000-00009]
- Gerald WL, Rosai J. Desmoplastic small cell tumor with multi-phenotypic differentiation. *Zentralbl Pathol* 1993; **139**: 141-151 [PMID: 8396418]
- Young RH, Eichhorn JH, Dickersin GR, Scully RE. Ovarian involvement by the intra-abdominal desmoplastic small round cell tumor with divergent differentiation: a report of three cases. *Hum Pathol* 1992; **23**: 454-464 [PMID: 1563748 DOI: 10.1016/0046-8177(92)90094-J]
- Bian Y, Jordan AG, Rupp M, Cohn H, McLaughlin CJ, Miettinen M. Effusion cytology of desmoplastic small round cell tumor of the pleura. A case report. *Acta Cytol* 1993; **37**: 77-82 [PMID: 7679537]
- Parkash V, Gerald WL, Parma A, Miettinen M, Rosai J. Desmoplastic small round cell tumor of the pleura. *Am J Surg Pathol* 1995; **19**: 659-665 [PMID: 7755152 DOI: 10.1097/0000478-199506000-00006]
- Zaloudek C, Miller TR, Stern JL. Desmoplastic small cell tumor of the ovary: a unique polyphenotypic tumor with an unfavorable prognosis. *Int J Gynecol Pathol* 1995; **14**: 260-265 [PMID: 8600079 DOI: 10.1097/00004347-199507000-00011]
- Tison V, Cerasoli S, Morigi F, Ladanyi M, Gerald WL, Rosai J. Intracranial desmoplastic small-cell tumor. Report of a case. *Am J Surg Pathol* 1996; **20**: 112-117 [PMID: 8540602 DOI: 10.1097/0000478-199601000-00013]
- Cummings OW, Ulbright TM, Young RH, Dei Tos AP, Fletcher CD, Hull MT. Desmoplastic small round cell tumors of the paratesticular region. A report of six cases. *Am J Surg Pathol* 1997; **21**: 219-225 [PMID: 9042290 DOI: 10.1097/0000478-199702000-00013]
- Wolf AN, Ladanyi M, Paull G, Blaugrund JE, Westra WH. The expanding clinical spectrum of desmoplastic small round-cell tumor: a report of two cases with molecular confirmation. *Hum Pathol* 1999; **30**: 430-435 [PMID: 10208465 DOI: 10.1016/S0046-8177(99)90119-3]
- Cho KJ, Ro JY, Choi J, Choi SH, Nam SY, Kim SY. Mesenchymal neoplasms of the major salivary glands: clinicopathological features of 18 cases. *Eur Arch Otorhinolaryngol* 2008; **265** Suppl 1: S47-S56 [PMID: 17934743 DOI: 10.1007/s00405-007-0488-5]
- Zhang J, Dalton J, Fuller C. Epithelial marker-negative desmoplastic small round cell tumor with atypical morphology: definitive classification by fluorescence in situ hybridization. *Arch Pathol Lab Med* 2007; **131**: 646-649 [PMID: 17425400]
- Trupiano JK, Machen SK, Barr FG, Goldblum JR. Cytokeratin-negative desmoplastic small round cell tumor: a report of two cases emphasizing the utility of reverse transcriptase-polymerase chain reaction. *Mod Pathol* 1999; **12**: 849-853 [PMID: 10496592]
- Zhang PJ, Goldblum JR, Pawel BR, Fisher C, Pasha TL, Barr FG. Immunophenotype of desmoplastic small round cell tumors as detected in cases with EWS-WT1 gene fusion product. *Mod Pathol* 2003; **16**: 229-235 [PMID: 12640103 DOI: 10.1097/01.MP.0000056630.76035.F3]
- Gerald WL, Ladanyi M, de Alava E, Cuatrecasas M, Kushner BH, LaQuaglia MP, Rosai J. Clinical, pathologic, and molecular spectrum of tumors associated with t(11;22)(p13;q12): desmoplastic small round-cell tumor and its variants. *J Clin Oncol* 1998; **16**: 3028-3036 [PMID: 9738572]
- Lee SB, Kolquist KA, Nichols K, Englert C, Maheswaran S, Ladanyi M, Gerald WL, Haber DA. The EWS-WT1 translocation product induces PDGFA in desmoplastic small round-cell tumour. *Nat Genet* 1997; **17**: 309-313 [PMID: 9354795 DOI: 10.1038/ng1197-309]
- Antonescu CR, Gerald WL, Magid MS, Ladanyi M. Molecular variants of the EWS-WT1 gene fusion in desmoplastic small round cell tumor. *Diagn Mol Pathol* 1998; **7**: 24-28 [PMID: 9646031 DOI: 10.1097/00019606-199802000-00005]
- Liu J, Nau MM, Yeh JC, Allegra CJ, Chu E, Wright JJ. Molecular heterogeneity and function of EWS-WT1 fusion transcripts in desmoplastic small round cell tumors. *Clin Cancer Res* 2000; **6**: 3522-3529 [PMID: 10999739]
- Hamazaki M, Okita H, Hata J, Shimizu S, Kobayashi H, Aoki K, Nara T. Desmoplastic small cell tumor of soft tissue: molecular variant of EWS-WT1 chimeric fusion. *Pathol Int* 2006; **56**: 543-548 [PMID: 16930335 DOI: 10.1111/j.1440-1827.2006.02003.x]
- Sebire NJ, Gibson S, Rampling D, Williams S, Malone M, Ramsay AD. Immunohistochemical findings in embryonal small round cell tumors with molecular diagnostic confirmation. *Appl Immunohistochem Mol Morphol* 2005; **13**: 1-5 [PMID: 15722786 DOI: 10.1097/00129039-200503000-00001]
- Bosman C, Boldrini R. Unusual aspects of desmoplastic small round cell tumor. *Ultrastruct Pathol* 2004; **28**: 83-96 [PMID: 15205108 DOI: 10.1080/01913120490430634]
- Ordóñez NG. Desmoplastic small round cell tumor: I: a histopathologic study of 39 cases with emphasis on unusual histological patterns. *Am J Surg Pathol* 1998; **22**: 1303-1313 [PMID: 9808123 DOI: 10.1097/0000478-199811000-00001]



- 23 **Ordóñez NG**, Sahin AA. CA 125 production in desmoplastic small round cell tumor: report of a case with elevated serum levels and prominent signet ring morphology. *Hum Pathol* 1998; **29**: 294-299 [PMID: 9496834 DOI: 10.1016/S0046-8177(98)90050-8]
- 24 **Pasquinelli G**, Montanaro L, Martinelli GN. Desmoplastic small round-cell tumor: a case report on the large cell variant with immunohistochemical, ultrastructural, and molecular genetic analysis. *Ultrastruct Pathol* 2000; **24**: 333-337 [PMID: 11071572 DOI: 10.1080/019131200750035067]
- 25 **Devaney K**. Intra-abdominal desmoplastic small round cell tumor of the peritoneum in a young man. *Ultrastruct Pathol* 1994; **18**: 389-398 [PMID: 8066829 DOI: 10.3109/01913129409023209]
- 26 **Ordóñez NG**, el-Naggar AK, Ro JY, Silva EG, Mackay B. Intra-abdominal desmoplastic small cell tumor: a light microscopic, immunocytochemical, ultrastructural, and flow cytometric study. *Hum Pathol* 1993; **24**: 850-865 [PMID: 8375856 DOI: 10.1016/0046-8177(93)90135-4]
- 27 **Ordóñez NG**. Desmoplastic small round cell tumor: II: an ultrastructural and immunohistochemical study with emphasis on new immunohistochemical markers. *Am J Surg Pathol* 1998; **22**: 1314-1327 [PMID: 9808124 DOI: 10.1097/0000478-199811000-00002]
- 28 **Gerald WL**, Miller HK, Battifora H, Miettinen M, Silva EG, Rosai J. Intra-abdominal desmoplastic small round-cell tumor. Report of 19 cases of a distinctive type of high-grade polyphenotypic malignancy affecting young individuals. *Am J Surg Pathol* 1991; **15**: 499-513 [PMID: 1709557 DOI: 10.1097/00000478-199106000-00001]
- 29 **Dorsey BV**, Benjamin LE, Rauscher F, Klencke B, Venook AP, Warren RS, Weidner N. Intra-abdominal desmoplastic small round-cell tumor: expansion of the pathologic profile. *Mod Pathol* 1996; **9**: 703-709 [PMID: 8782211]
- 30 **Hasselblatt M**, Gesk S, Oyen F, Rossi S, Viscardi E, Giangaspero F, Giannini C, Judkins AR, Frühwald MC, Obser T, Schneppenheim R, Siebert R, Paulus W. Nonsense mutation and inactivation of SMARCA4 (BRG1) in an atypical teratoid/rhabdoid tumor showing retained SMARCB1 (INI1) expression. *Am J Surg Pathol* 2011; **35**: 933-935 [PMID: 21566516 DOI: 10.1097/PAS.0b013e3182196a39]
- 31 **Fogu G**, Campus PM, Cambosu F, Moro MA, Sanna R, Fozza C, Nieddu RM, Longinotti M, Montella A. Unbalanced 1q whole-arm translocation resulting in der(14)t(1;14)(q11-12; p11) in myelodysplastic syndrome. *Cytogenet Genome Res* 2012; **136**: 256-263 [PMID: 22571950 DOI: 10.1159/000338437]
- 32 **el-Kattan I**, Redline RW, el-Naggar AK, Grimes MC, Abdul-Karim FW. Cytologic features of intraabdominal desmoplastic small round cell tumor. A case report. *Acta Cytol* 1995; **39**: 514-520 [PMID: 7539203]
- 33 **Dufresne A**, Cassier P, Couraud L, Marec-Bérard P, Meeus P, Alberti L, Blay JY. Desmoplastic small round cell tumor: current management and recent findings. *Sarcoma* 2012; **2012**: 714986 [PMID: 22550424 DOI: 10.1155/2012/714986]
- 34 **Lae ME**, Roche PC, Jin L, Lloyd RV, Nascimento AG. Desmoplastic small round cell tumor: a clinicopathologic, immunohistochemical, and molecular study of 32 tumors. *Am J Surg Pathol* 2002; **26**: 823-835 [PMID: 12131150]
- 35 **Lal DR**, Su WT, Wolden SL, Loh KC, Modak S, La Quaglia MP. Results of multimodal treatment for desmoplastic small round cell tumors. *J Pediatr Surg* 2005; **40**: 251-255 [PMID: 15868593]

**P- Reviewer:** Corrales FJ, Lonardo F, Sugimura H  
**S- Editor:** Song XX **L- Editor:** A **E- Editor:** Lu YJ



## Resolution of hemolysis from pump thrombus during left ventricular assist device exchange

Shinya Unai, Hitoshi Hirose, John WC Entwistle III, Louis E Samuels

Shinya Unai, Hitoshi Hirose, John WC Entwistle III, Louis E Samuels, Division of Cardiothoracic Surgery, Department of Surgery, Thomas Jefferson University, Philadelphia, PA 19107, United States

**Author contributions:** All of the authors contributed in drafting the article, critical revision and writing the manuscript; Unai S and Hirose H collected the patient's clinical data; all the authors approved the final version of the manuscript.

**Correspondence to:** Hitoshi Hirose, MD, PhD, Division of Cardiothoracic Surgery, Department of Surgery, Thomas Jefferson University, 1025 Walnut Street, Room 605, Philadelphia, PA 19107, United States. [hitoshi.hirose@jefferson.edu](mailto:hitoshi.hirose@jefferson.edu)

Telephone: +1-215-9555654 Fax: +1-215-9556010

Received: March 2, 2014 Revised: May 20, 2014

Accepted: June 10, 2014

Published online: August 16, 2014

### Abstract

A 50-year-old male who underwent a HeartMate II left ventricular assist device placement for ischemic cardiomyopathy presented with discolored urine and hemolysis 3 mo after the operation. His hemolysis was thought to be due to thrombosis within the pump. Imaging studies were not able to visualize a left ventricular thrombus. Medical management with anticoagulation failed and he underwent surgery for a pump exchange. Intraoperatively, a firm thrombus was found within the pump of the HeartMate II, and the color of the urine changed dramatically from cola-colored to yellow which enabled us to confirm the diagnosis.

© 2014 Baishideng Publishing Group Inc. All rights reserved.

**Key words:** Cardiac surgery; Hemolysis; Left ventricular assist device; Thrombosis

**Core tip:** Diagnosis of pump thrombosis is difficult, but the intraoperative change of the color of urine may be seen almost immediately after pump exchange. This report also highlights the technical aspect of replacing the HeartMate II pump, and we believe the images are educational for the readers.

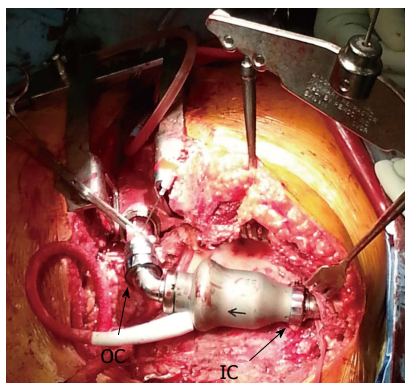
Unai S, Hirose H, Entwistle JWC, Samuels LE. Resolution of hemolysis from pump thrombus during left ventricular assist device exchange. *World J Clin Cases* 2014; 2(8): 373-376 Available from: URL: <http://www.wjgnet.com/2307-8960/full/v2/i8/373.htm> DOI: <http://dx.doi.org/10.12998/wjcc.v2.i8.373>

### INTRODUCTION

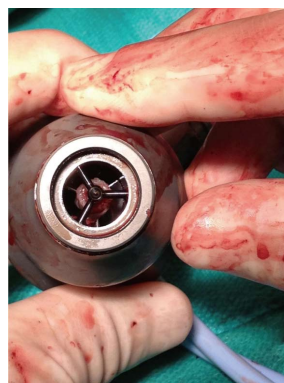HeartMate II (Thoratec, Pleasanton, CA) is a continuous flow left ventricular assist device (LVAD), which has improved the quality of life and survival of patients who have end-stage heart failure refractory to medical therapy. The device is consisted of an inflow cannula in the left ventricle, axial flow pump, and an outflow graft to the ascending aorta. It is designed for long-term usage, either bridge to transplant or destination therapy. Since 2006, more than 10000 HeartMate II LVADs have been implanted, and 2500 LVADs have been implanted in 2013, according to the INTERMACS registry<sup>[1]</sup>. Consequently, the incidence of device-related complications, such as pump thrombosis, infection, bleeding, has increased, which often require re-admission and/or surgery<sup>[2]</sup>. Pump thrombosis is one of the common causes of hemolysis in patients with LVAD. Hemolysis related to the LVAD could be due to kinking of the outflow graft, malposition of the inflow cannula, or malfunction of the pump. We present a case of an LVAD thrombosis that presented with hemolysis and discolored urine 3 mo after the LVAD placement. The patient failed conservative medical management and underwent surgery for pump exchange. Thrombus was seen in the pump and the color of the urine changed dramatically after the pump was exchanged which enabled us to confirm the diagnosis of pump thrombosis.

### CASE REPORT

A 50-year-old male with a history of axillo-bifemoral



**Figure 1** Intraoperative photo after the replacement of the pump. IC: Inflow connection; OC: Outflow connection.



**Figure 2** Inspection of the pump revealed a firm thrombus along the inlet stator.

bypass for bilateral chronic iliac artery occlusive disease, ischemic cardiomyopathy with an ejection fraction of 20%, underwent placement of a HeartMate II LVAD as a bridge to cardiac transplantation. Preoperative hematology work-up disclosed no evidence of hypercoagulability. Heparin infusion was started on postoperative day 1 and warfarin was started on postoperative day 3. Heparin drip was maintained with a goal PTT level of 60 to 70 s until the INR reached 1.8. He was discharged on postoperative day 15 on aspirin 325 mg and warfarin with a target INR of 1.8 to 2.5. Upon discharge, the LVAD was set at 9200 rpm, giving a flow of 5.7 L/min, with a pulsatility index (the pulsatility of the flow through the pump) of 5.5 and pump power (a direct measurement of motor voltage and current) of 6.7 watts.


Three months later on his scheduled office visit, his lactate dehydrogenase (LDH) was found to be elevated to 1352 IU/L (Table 1). His baseline LDH level was between 400 and 500 IU/L. Interrogation of the pump parameters revealed several episodes of elevation in the pump power a few days before the office visit that had since resolved. It was thought to be due to a small pump thrombus that resolved spontaneously. Ten days later, he was admitted to the hospital due to discolored urine. Urine analysis showed strongly positive hemoglobin, very few red blood cells, and white blood cells. He denied any chest pain, shortness of breath, or edema. There were no signs of infection. Hemoglobin was 7.6 g/dL, plasma free hemoglobin was 52.0 mg/dL. The LDH, haptoglobin, AST were unable to be measured due to severe hemolysis. Other lab values included INR 1.7, serum creatinine 1.9 mg/dL (baseline 1.2 mg/dL), total bilirubin 1.1 mg/dL. Echocardiography showed severe biventricular dysfunction and opening of the aortic valve with every heartbeat. The velocity through the inflow cannula was 1.1 m/s. The LVAD parameters showed occasional pump power elevation over 9 watts. Heparin was initiated but there was no resolution of the discolored urine over three days. Although echocardiography and chest CT scan failed to demonstrate a thrombus, he was clinically diagnosed with pump thrombosis. Due to the persistently elevated creatinine and requirement of multiple blood

transfusions for hemolytic anemia despite optimum medical therapy, the decision was made to proceed with pump exchange.

After re sternotomy, cardiopulmonary bypass (CPB) was established with ascending aorta and right femoral vein cannulation, as the femoral arteries were not able to be cannulated due to iliac artery occlusions. To gain access to the inflow portion of the LVAD, a left subcostal incision was added and the body of the HeartMate II pump was removed by unscrewing the inflow- and outflow- connections. It was replaced with a new HeartMate II pump (Figure 1). There was no thrombus in the inflow cannula or outflow conduit. Intraoperative inspection of the original LVAD interior demonstrated a firm thrombus along the inlet stator (Figure 2). The urine color was tea-colored before CPB (Figure 3A). It changed to reddish upon cessation of flow from the original LVAD and institution of CPB (Figure 3B). Following initiation of the new LVAD flow and discontinuation of CPB, it changed to a yellow color (Figure 3C). Postoperative recovery was steady and his renal function recovered with clear urine (Table 1). Anticoagulation therapy consisted of intravenous heparin with overlapping warfarin (INR 2.5 to 3.5), aspirin 325 mg, and clopidogrel 75 mg. He was discharged home on postoperative day 8. The patient was symptom free afterwards, and underwent heart transplant 2 mo later.

## DISCUSSION

LVAD therapy requires a balance between anticoagulation and hemostasis to prevent the complications of bleeding and thrombosis. There are many anticoagulation regimens to achieve this goal, and most combine inhibition of the clotting cascade with warfarin and at least one antiplatelet agent. The optimal anticoagulation/antiplatelet strategy remains elusive because of the heterogeneity in the reaction between the biological components (*i.e.*, blood) and artificial surfaces (*i.e.*, LVAD) as well as the variability in the responsiveness to anticoagulants and anti-platelet medications<sup>[3]</sup>. As a result of this imperfect coexistence between “man” and “machine”, the lead-



**Figure 3 Urine color.** A: Before CPB; B: After CPB and cessation of the old pump; C: After pump replacement. CPB: Cardiopulmonary bypass.

**Table 1 Laboratory values**

	Outpatient (1 mo prior to admission)	Outpatient (1 wk prior to admission)	Admission	Post pump exchange (POD 7)
White blood cells (B/L)	6.5	6.7	8	10.7
Hemoglobin (g/dL)	10.8	8.4	7.6	11.6
Hematocrit	35.1%	27.9%	24.5%	36.4%
Platelets (B/L)	158	139	164	162
Reticulocytes			7.4%	2.8%
Na (mEq/L)	139	136	131	137
K (mEq/L)	4	4.7	4.9	3.8
BUN (mg/dL)	17	16	28	26
Creatinine (mg/dL)	1.2	1.4	1.9	1.5
Total bilirubin (mg/dL)	0.4	0.5	1.1	0.9
Aspartate aminotransferase (IU/L)	40	60	<sup>1</sup>	34
Lactate dehydrogenase (IU/L)	707	1382	<sup>1</sup>	527
Plasma free hemoglobin (mg/dL)			52	6.4
Haptoglobin (mg/dL)			<sup>1</sup>	
Urine color			Light red	Yellow
Red blood cell in urine (/HPF)			1	< 1

<sup>1</sup>Unable to be obtained due to hemolysis.

ing causes of LVAD readmissions include bleeding and thrombosis. Thrombosis of the LVAD is a potentially lethal complication which occurs in 2% to 3% of the patients who receive the HeartMate II LVAD and the incidence is reported to be increasing<sup>[4-6]</sup>. Patients typically present with elevated pump power, heat over the pump, heart failure and signs of hemolysis. Echocardiography may show opening of the aortic valve due to inadequate decompression of the left ventricle (LV) and increased LV end-diastolic diameter. Serial recording of LV end-diastolic diameter while increasing the pump speeds may diagnose pump thrombus or other flow obstructions<sup>[7]</sup>. However, there have been reports of pump thrombosis with normal echo and pump parameters as well<sup>[8,9]</sup>. Hemolysis may be the only sign of thrombosis, although hemolysis may be due to various reasons, such as kinking of the outflow graft, malposition of the inflow cannula or the pump itself (high shear stress, *etc.*)<sup>[8,9]</sup>. The diagnostic challenge is that pump thrombus may not be visualized with contrast CT scan or echocardiography, due to artifacts caused by the metallic housing of the LVAD<sup>[8]</sup>. In our case, we were able to confirm that the hemolysis was due to pump thrombosis by intraoperative inspection of the removed pump and the resolution of the urine after pump exchange.

Change of urine color is easily noticeable to patients

and should be promptly addressed as a sign of possible pump thrombosis. In the current era of non-pulsatile LVAD therapy, it is likely that the risk of pump thrombosis and hemolysis will remain, and LVAD exchange may be necessary in cases that are refractory to medical management. Fortunately, the modular nature of LVAD technology allows for pump exchange with a reasonable degree of safety; the mortality is reported to be 6% to 7%<sup>[10,11]</sup>. In contrast, medical management; adding anti-platelet agents such as dipyridamole or clopidogrel, increasing the dose of aspirin and/or increasing the target PT-INR for anticoagulation, resulted in a 48.2% mortality in the following six months after the diagnosis of pump thrombosis<sup>[6]</sup>.

In conclusion, thrombosis during LVAD therapy is a potentially life-threatening complication requiring prompt diagnosis and management. We presented a report of LVAD thrombosis causing hemolysis and discoloration of the urine that resolved promptly after the pump exchange. The diagnosis is challenging, but we were able to confirm the diagnosis by intraoperative inspection of the pump and the prompt resolution of the discolored urine.

## COMMENTS

### Case characteristics

A 50-year-old-male with a history of HeartMate II implantation presented with



discolored urine.

### Clinical diagnosis

He denied any chest pain, shortness of breath, or edema.

### Differential diagnosis

Discolored urine and the lab values suggesting hemolysis, occasional pump power spikes were thought to be due to pump thrombosis.

### Laboratory diagnosis

Hemoglobin 7.6 g/dL; plasma free hemoglobin 52.0 mg/dL; PT-INR 1.7; serum creatinine 1.9 mg/dL; total bilirubin 1.1 mg/dL. The lactate dehydrogenase, haptoglobin, AST were not able to be measured due to severe hemolysis.

### Imaging diagnosis

Echocardiography showed severe biventricular dysfunction and opening of the aortic valve with every heartbeat.

### Treatment

The patient underwent pump exchange.

### Related reports

Medical management resulted in a 48.2% mortality in the following six months after the diagnosis of pump thrombosis.

### Experiences and lessons

The diagnosis of pump thrombosis is challenging, but the authors were able to confirm the diagnosis by intraoperative inspection of the pump and the prompt resolution of the discolored urine.

### Peer review

The manuscript describes frequent complication of left ventricular assist device. The manuscript is well written and has a good structure with excellent images.

## REFERENCES

- INTERMACS. Quarterly Statistical Report, 2013 4th Quarter. Available from: URL: <http://www.uab.edu/medicine/intermacs/research/statistical-summaries>
- Hasin T, Marmor Y, Kremers W, Topilsky Y, Severson CJ, Schirger JA, Boilson BA, Clavell AL, Rodeheffer RJ, Frantz RP, Edwards BS, Pereira NL, Stulak JM, Joyce L, Daly R, Park SJ, Kushwaha SS. Readmissions after implantation of axial flow left ventricular assist device. *J Am Coll Cardiol* 2013; **61**: 153-163 [PMID: 23219299 DOI: 10.1016/j.jacc.2012.09.041]
- Rossi M, Serraino GF, Jiritano F, Renzulli A. What is the optimal anticoagulation in patients with a left ventricular assist device? *Interact Cardiovasc Thorac Surg* 2012; **15**: 733-740 [PMID: 22761118 DOI: 10.1093/icvts/ivs297]
- Boyle AJ, Russell SD, Teuteberg JJ, Slaughter MS, Moazami N, Pagani FD, Frazier OH, Heatley G, Farrar DJ, John R. Low thromboembolism and pump thrombosis with the HeartMate II left ventricular assist device: analysis of outpatient anti-coagulation. *J Heart Lung Transplant* 2009; **28**: 881-887 [PMID: 19716039 DOI: 10.1016/j.healun.2009.05.018]
- John R, Kamdar F, Liao K, Colvin-Adams M, Miller L, Joyce L, Boyle A. Low thromboembolic risk for patients with the Heartmate II left ventricular assist device. *J Thorac Cardiovasc Surg* 2008; **136**: 1318-1323 [PMID: 19026822 DOI: 10.1016/j.jtcvs.2007.12.077]
- Starling RC, Moazami N, Silvestry SC, Ewald G, Rogers JG, Milano CA, Rame JE, Acker MA, Blackstone EH, Ehrlinger J, Thuita L, Mountis MM, Soltesz EG, Lytle BW, Smedira NG. Unexpected abrupt increase in left ventricular assist device thrombosis. *N Engl J Med* 2014; **370**: 33-40 [PMID: 24283197 DOI: 10.1056/NEJMoa1313385]
- Uriel N, Morrison KA, Garan AR, Kato TS, Yuzefpolskaya M, Latif F, Restaino SW, Mancini DM, Flannery M, Takayama H, John R, Colombo PC, Naka Y, Jorde UP. Development of a novel echocardiography ramp test for speed optimization and diagnosis of device thrombosis in continuous-flow left ventricular assist devices: the Columbia ramp study. *J Am Coll Cardiol* 2012; **60**: 1764-1775 [PMID: 23040584 DOI: 10.1016/j.jacc.2012.07.052]
- Meyer AL, Kuehn C, Weidemann J, Malehsa D, Bara C, Fischer S, Haverich A, Strüber M. Thrombus formation in a HeartMate II left ventricular assist device. *J Thorac Cardiovasc Surg* 2008; **135**: 203-204 [PMID: 18179943 DOI: 10.1016/j.jtcvs.2007.08.048]
- Bhamidipati CM, Ailawadi G, Bergin J, Kern JA. Early thrombus in a HeartMate II left ventricular assist device: a potential cause of hemolysis and diagnostic dilemma. *J Thorac Cardiovasc Surg* 2010; **140**: e7-e8 [PMID: 19945118 DOI: 10.1016/j.jtcvs.2009.09.046]
- Moazami N, Milano CA, John R, Sun B, Adamson RM, Pagani FD, Smedira N, Slaughter MS, Farrar DJ, Frazier OH. Pump replacement for left ventricular assist device failure can be done safely and is associated with low mortality. *Ann Thorac Surg* 2013; **95**: 500-505 [PMID: 23261114 DOI: 10.1016/j.athoracsurg.2012.09.011]
- Ota T, Yerebakan H, Akashi H, Takayama H, Uriel N, Colombo PC, Jorde UP, Naka Y. Continuous-flow left ventricular assist device exchange: clinical outcomes. *J Heart Lung Transplant* 2014; **33**: 65-70 [PMID: 23937885 DOI: 10.1016/j.healun.2013.07.003]

P- Reviewer: Rodriguez-Castro KI, Said SAM, Shah R  
S- Editor: Song XX L- Editor: A E- Editor: Lu YJ



## Transthoracic echo: A sensitive tool for detecting cardiac extension of renal cell carcinoma?

Michelle Bejarano, Yara L Cameron, Theodore C Koutlas, Assad Movahed

Michelle Bejarano, Yara L Cameron, Theodore C Koutlas, Assad Movahed, Department of Cardiovascular Sciences, East Carolina Heart Institute and Brody School of Medicine, Greenville, NC 27834, United States

Author contributions: Bejarano M and Cameron YL designed the report; Movahed A and Bejarano M were attending physicians for the patient; Koutlas TC performed the surgical operation; Bejarano M and Movahed A performed the image diagnosis.

Correspondence to: Assad Movahed, MD, Department of Cardiovascular Sciences, East Carolina Heart Institute and Brody School of Medicine, 115 Heart Drive, Greenville, NC 27834, United States. [movaheda@ecu.edu](mailto:movaheda@ecu.edu)

Telephone: +1-252-7444400 Fax: +1-252-7447724

Received: March 31, 2014 Revised: May 22, 2014

Accepted: June 10, 2014

Published online: August 16, 2014

### Abstract

Renal cell carcinoma is a common urological malignancy with the unique ability to invade the inferior vena cava (IVC) and to extend into the right atrium of the heart. Of those with Renal cell carcinoma only 4%-25% are found to have IVC invasion and of those only 2%-10% extend into the right atrium. If treated surgically, extension of tumor thrombus is not a determinant of survival; therefore it is imperative to determine the presence and extent of tumor thrombus in order to determine surgical approach and tumor resection. To date this has been primarily accomplished by magnetic resonance imaging and computed tomography. We present a case of 61 years old African American woman in which transthoracic echocardiography provided a more accurate determination/characterization of the presence and degree of tumor thrombus and extension.

© 2014 Baishideng Publishing Group Inc. All rights reserved.

**Key words:** Renal cell carcinoma; Tumor thrombus; Cardiac extension; Right atrial mass

**Core tip:** Renal cell carcinoma is a common urological malignancy with the ability to invade the inferior vena cava and to extend into the right atrium of the heart. If treated surgically, extension of tumor thrombus is not a determinant of survival; therefore it is imperative to determine the presence and extent of tumor thrombus. To date, this has been primarily accomplished by magnetic resonance imaging and computed tomography; however, we present a case in which transthoracic echocardiography provided a more accurate determination/characterization of the presence and degree of tumor thrombus and extension.

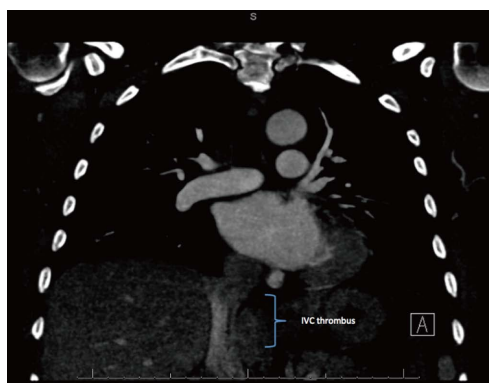Bejarano M, Cameron YL, Koutlas TC, Movahed A. Transthoracic echo: A sensitive tool for detecting cardiac extension of renal cell carcinoma? *World J Clin Cases* 2014; 2(8): 377-379 Available from: URL: <http://www.wjgnet.com/2307-8960/full/v2/i8/377.htm> DOI: <http://dx.doi.org/10.12998/wjcc.v2.i8.377>

### INTRODUCTION

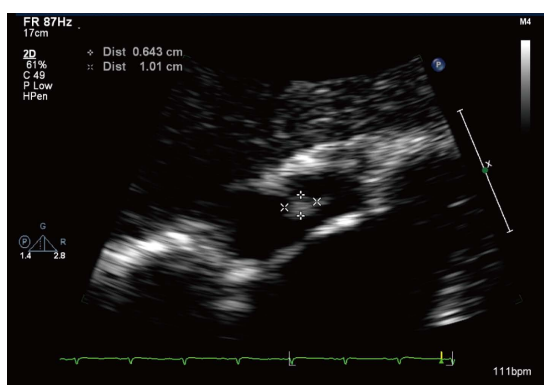
Renal cell carcinoma is a common urological malignancy with the unique ability to invade the inferior vena cava (IVC) and to extend into the right atrium of the heart. Of those with Renal cell carcinoma (RCC) only 4%-25% are found to have IVC invasion and of those only 2%-10% extend into the right atrium. If treated surgically, extension of tumor thrombus is not a determinant of survival; therefore it is imperative to determine the presence and extent of tumor thrombus in order to determine surgical approach and tumor resection. To date this has been primarily accomplished by magnetic resonance imaging (MRI) and computed tomography (CT).

### CASE REPORT

A 61 years old African-American female with past medi-

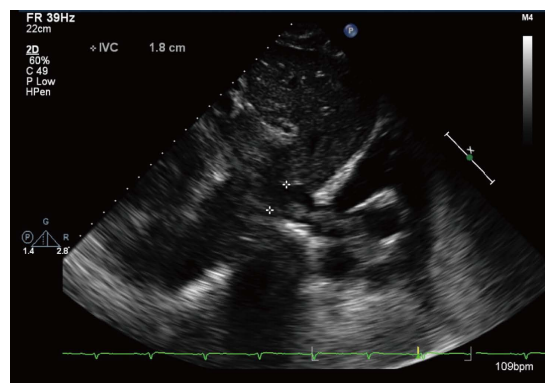


**Figure 1** Computed tomography scan (coronal view) revealing inferior vena cava thrombus with no evidence of extension into the right atrium.

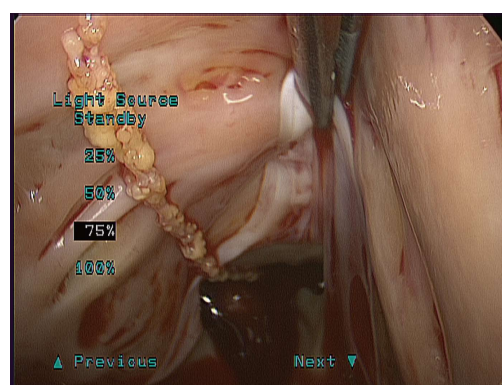


**Figure 2** Subcostal view showing the right atrial thrombus.

cal history of hypertension, hyperlipidemia, and diabetes mellitus initially presented to her primary care physician for progressively worsening fatigue, anorexia, and weight loss. As part of her work-up, she underwent an abdominal and pelvis CT scan, which revealed a large right sided renal mass with possible invasion of the right renal vein and inferior vena cava. A follow up abdominal MRI confirmed the presence of a very large right-sided renal mass consistent with renal cell carcinoma and subsequent invasion of the right renal vein and adjacent inferior vena cava. Further assessment revealed a tumor thrombus extending beyond the renal veins into the intrahepatic inferior vena cava and toward the right atrium. In order to fully characterize the extent of tumor thrombus extension, a CT angiogram (CTA) of the chest and transthoracic echocardiogram (TTE) was done. The chest CTA revealed a filling defect in the IVC in the intrahepatic and subhepatic regions consistent with known tumor thrombus, but showed no evidence of right atrium invasion (Figure 1). On the other hand, the TTE showed a large right atrial mass (Figure 2) with diastolic prolapse into the right ventricle and extension into the IVC (Figure 3). In the setting of her known history of RCC with migration and the fact that this mass was also seen to extend into the IVC, it was felt that this was indeed right atrial invasion of the tumor thrombus and less likely to be a



**Figure 3** Subcostal view showing the tumor thrombus extending from the inferior vena cava into the right atrium.



**Figure 4** Peri-operative view of the tumor thrombus within the inferior vena cava extending into the right atrium.

hematological thrombus. A preoperative left heart catheterization was also performed revealing significant mid right coronary artery disease.

After completing the aforementioned preoperative assessment and evaluation by Urology, Vascular Surgery and Cardiothoracic Surgery, the patient underwent a radical nephrectomy and resection of the inferior vena cava and right atrial tumor thrombi (Figure 4). She simultaneously underwent a single vessel coronary artery bypass for her right coronary artery disease. There were no surgical complications and the patient's postoperative course was unremarkable.

## DISCUSSION

Renal cell carcinoma tumor thrombus has a propensity to invade the main renal veins as well as the IVC and in rare circumstances can extend into the right atrium of the heart<sup>[1,2]</sup>. In order to properly classify RCC extension and plan the appropriate surgical technique and approach, one would imagine that establishing the location of the superior margin of the tumor thrombus would be essential<sup>[1,3]</sup>. At this time the mainstay or gold standard of renal mass detection and characterization (including RCC) is CT scan and MRI<sup>[1,4,5]</sup>. CT scan has shown to be

**Table 1** Classification of renal cell carcinoma tumor thrombus

Tumor thrombus level <sup>[6]</sup>	Characteristics <sup>[6]</sup>
Level I	Extension to 2 cm above the renal vein into the IVC
Level II	Extension to the subhepatic level, > 2 cm above the renal vein BUT below the diaphragm
Level III	Extension into the intrahepatic IVC BUT below the diaphragm
Level IV	Extension into the right atrium of the heart

IVC: Inferior vena cava.

most accurate in evaluating the extent of local growth as well as the presence or absence of metastasis (*i.e.*, to the pancreas, bone). On the other hand MRI has been more accurate in delineating the superior margin of any tumor thrombus, and thereby classifying RCC tumor thrombus, as well as differentiating between bland/hematologic thrombus and tumor thrombus<sup>[1,4,5]</sup>. Traditionally TTE has been used to further delineate the supradiaphragmatic extension of tumor thrombus. In our case, TTE accurately illustrated the cranial extent of tumor thrombus into the right atrium which was in fact missed on the traditionally used CT scan.

For level IV tumors (Table 1) such as was found in our patient, cardiopulmonary bypass (CPB) with or without hypothermic circulatory arrest (HCA) is necessary for safe and complete extraction of the thrombus<sup>[1,3,6]</sup>. This surgical approach provides a bloodless surgical field that allows optimal visualization of the hepatic veins, IVC and Right Atrium for complete tumor thrombus resection. As incomplete resection of these tumors confers a higher rate of metastatic recurrence and decreased postoperative survival, it is imperative to clearly delineate the superior margin of any tumor thrombus<sup>[1,3,6]</sup>.

In our case, the patient's preoperative evaluation included a CT abdomen/pelvis, CT chest, MRI abdomen, and TTE. Unexpectedly, it was the TTE that provided the most accurate determination of the cranial extent of the tumor thrombus. Proper classification of the tumor thrombus allowed for the appropriate surgical approach

to be undertaken ensuring the best patient outcome.

## COMMENTS

### Case characteristics

A 61 years old African-American female with past medical history of hypertension, hyperlipidemia, and diabetes mellitus initially presented to her primary care physician for progressively worsening fatigue, anorexia, and weight loss.

### Clinical diagnosis

A large right sided renal mass with possible invasion of the right renal vein and inferior vena cava.

### Imaging diagnosis

Chest computed tomography angiogram revealed a filling defect in the inferior vena cava (IVC) in the intrahepatic and subhepatic regions consistent with known tumor thrombus, the transthoracic echocardiogram (TTE) showed a large right atrial mass with diastolic prolapse into the right ventricle and extension into the IVC.

### Experiences and lessons

In this case, TTE accurately illustrated the cranial extent of tumor thrombus into the right atrium which was in fact missed on the traditionally used computed tomography scan.

### Peer review

The case report illustrates the diagnostic power of transthoracic echo in diagnosis of cardiac extension of renal cell carcinoma. The manuscript is well written.

## REFERENCES

- 1 Heidenreich A, Ravery V; European Society of Oncological Urology. Preoperative imaging in renal cell cancer. *World J Urol* 2004; **22**: 307-315 [PMID: 15290202 DOI: 10.1007/s00345-0040411-2]
- 2 Kallman DA, King BF, Hattery RR, Charboneau JW, Ehman RL, Guthman DA, Blute ML. Renal vein and inferior vena cava tumor thrombus in renal cell carcinoma: CT, US, MRI and venacavography. *J Comput Assist Tomogr* 1992; **16**: 240-247 [PMID: 1545020]
- 3 Posacioglu H, Ayik MF, Zeytinlu M, Amanvermez D, Engin C, Apaydin AZ. Management of renal cell carcinoma with intracardiac extension. *J Card Surg* 2008; **23**: 754-758 [PMID: 19017006 DOI: 10.1111/j.1540-8191.2008.00664.x]
- 4 Kang SK, Kim D, Chandarana H. Contemporary imaging of the renal mass. *Curr Urol Rep* 2011; **12**: 11-17 [PMID: 20949339 DOI: 10.1007/s11934-010-0148-y]
- 5 Tollefson MK, Takahashi N, Leibovich BC. Contemporary imaging modalities for the surveillance of patients with renal cell carcinoma. *Curr Urol Rep* 2007; **8**: 38-43 [PMID: 17239315]
- 6 Boorjian SA, Sengupta S, Blute ML. Renal cell carcinoma: vena caval involvement. *BJU Int* 2007; **99**: 1239-1244 [PMID: 17441917 DOI: 10.1111/j.1464-410X.2007.06826.x]

P- Reviewer: Chiu KW, Gassler N S- Editor: Song XX  
L- Editor: A E- Editor: Lu YJ





## Prucalopride-associated acute tubular necrosis

Vithika Sivabalasundaram, Flavio Habal, David Cherney

Vithika Sivabalasundaram, Flavio Habal, Department of Medicine, Division of Gastroenterology, Toronto General Hospital, University of Toronto, Toronto, M5G 2C4, Canada

David Cherney, Department of Medicine, Division of Nephrology, Toronto General Hospital, University of Toronto, Toronto, M5G 2C4, Canada

**Author contributions:** Sivabalasundaram V, Habal F and Cherney D wrote and edited the manuscript; all authors have approved the final version of this manuscript.

**Supported by** A Kidney Foundation of Canada Scholarship and a Canadian Diabetes Association-KRESCENT Program Joint New Investigator Award and receives operating support from the Canadian Institutes of Health Research and the Heart and Stroke Foundation of Canada to Cherney D

**Correspondence to:** Flavio Habal, MD, Department of Medicine, Division of Gastroenterology, Toronto General Hospital, University of Toronto, 200 Elizabeth St, 9N-977, Toronto, M5G 2C4, Canada. [flavio.habal@uhn.ca](mailto:flavio.habal@uhn.ca)

Telephone: +1-416-3405024 Fax: +1-416-5955251

Received: February 17, 2014 Revised: April 29, 2014

Accepted: June 14, 2014

Published online: August 16, 2014

prucalopride associated with acute renal failure from the literature, including previous Phase II and III trials.

© 2014 Baishideng Publishing Group Inc. All rights reserved.

**Key words:** Prucalopride; Acute kidney tubular necrosis; Renal insufficiency; Constipation; Adverse drug event

**Core tip:** Prucalopride is a novel agent used in the treatment of chronic constipation. We report the first case of acute renal failure secondary to prucalopride four months after treatment initiation. A core renal biopsy after prednisone therapy revealed interstitial fibrosis and tubular atrophy. These findings suggested acute tubular necrosis secondary to acute interstitial nephritis. There are no previous reports of prucalopride associated with acute renal failure from the literature, including previous Phase II and III trials. This case reports highlights the need for monitoring renal function in all patients treated with prucalopride.

### Abstract

We report the first case of acute renal failure secondary to prucalopride, a novel agent for the treatment of chronic constipation. The 75 years old male patient was initiated on prucalopride after many failed treatments for constipation following a Whipple's procedure for pancreatic cancer. Within four months of treatment his creatinine rose from 103 to 285  $\mu\text{mol/L}$  (eGFR 61 decrease to 19 mL/min per 1.73  $\text{m}^2$ ). He was initially treated with prednisone for presumed acute interstitial nephritis as white blood casts were seen on urine microscopy. When no improvement was detected, a core biopsy was performed and revealed interstitial fibrosis and tubular atrophy. The presence of oxalate and calcium phosphate crystals were also noted. These findings suggest acute tubular necrosis which may have been secondary to acute interstitial nephritis or hemodynamic insult. The use of prednisone may have suppressed signs of inflammation and therefore the clinical diagnosis was deemed acute interstitial nephritis causing acute tubular necrosis. There are no previous reports of

Sivabalasundaram V, Habal F, Cherney D. Prucalopride-associated acute tubular necrosis. *World J Clin Cases* 2014; 2(8): 380-384 Available from: URL: <http://www.wjgnet.com/2307-8960/full/v2/i8/380.htm> DOI: <http://dx.doi.org/10.12998/wjcc.v2.i8.380>

### INTRODUCTION

Chronic constipation is very common and affects 14% of the general population<sup>[1]</sup>. The incidence rises with age, and is higher in women and those with lower socioeconomic status<sup>[2]</sup>. It is characterized by infrequent bowel and often associated with abdominal discomfort, bloating and cramps. Patients are susceptible to complications such as hemorrhoids and anal fissures. The consequences on quality of life, health care costs and activity impairment are also significant<sup>[3]</sup>.

The treatment of constipation requires a multifaceted approach which includes lifestyle changes, dietary adjustments, stool softeners, osmotic agents and laxa-

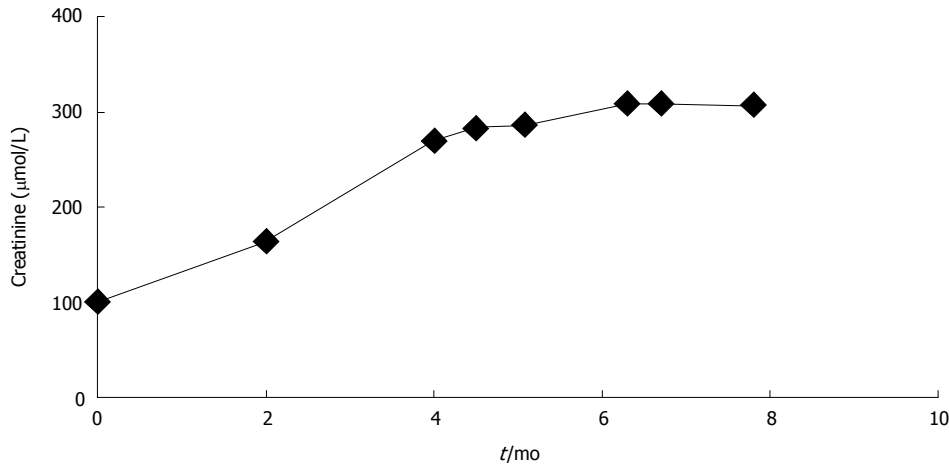


Figure 1 The level of patient's creatinine.

tives<sup>[4,5]</sup>. Another target for intervention is the 5 hydroxytryptamine-4 (5-HT<sub>4</sub>) receptor. Until recently, drugs have lacked specificity for the 5-HT<sub>4</sub> receptor resulting in an unfavourable risk-benefit ratio with side effects of serious cardiovascular arrhythmias<sup>[6,7]</sup>. Prucalopride however has demonstrated a high selectivity and affinity for this receptor in the gut with a high efficacy compared to placebo in patients with severe constipation<sup>[8-10]</sup> and in those who have failed previous laxative therapy<sup>[11,12]</sup>. The most common adverse effects were headache, nausea, diarrhea and abdominal pain, with no significant cardiovascular effects. Renal failure was not found to be associated with prucalopride and no change in chemical laboratory data was reported from baseline in all of the phase 3 studies<sup>[8,12,13]</sup>. Randomized trials in elderly patients also found prucalopride to be safe with no effect on renal or cardiac function<sup>[10,14]</sup>. We report the first case of prucalopride associated renal failure which was irreversible following discontinuation of the medication.

## CASE REPORT

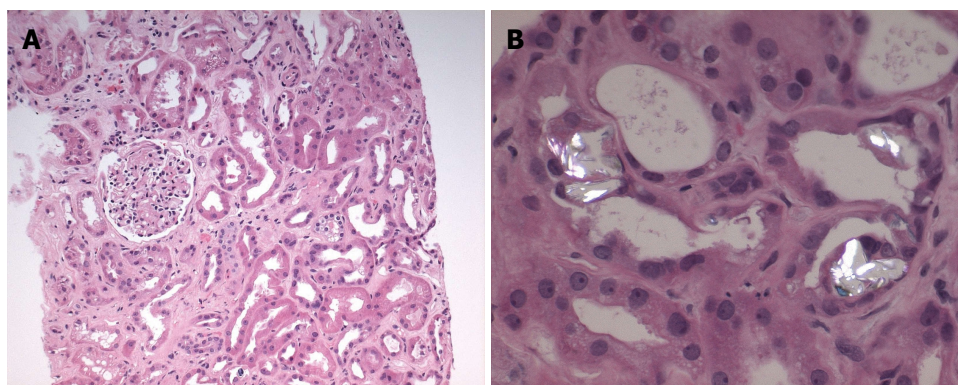
A 75 years old male developed chronic constipation following a Whipple's pancreaticoduodenectomy for pancreatic cancer 19 mo earlier. Over this period, he had multiple emergency room visits for abdominal cramps and pain which were on occasion related to severe constipation and obstipation. He required regular cleansing regimens in hospital, and repeated upper and lower endoscopies revealed no significant pathology. He was referred to a gastroenterologist and his pain resolved with discontinuation of his pancrealipase preparation. After failing several months of therapy for constipation with various bulking, osmotic and stimulant laxatives, he was initiated on prucalopride (Resotran), a new enterokinetic agent, at a dose of 2 mg once daily.

Besides his Whipple's procedure, his surgical history is also significant for an open prostatectomy nine years prior for benign prostatic hyperplasia, remote appendectomy, and a hernia repair. His medical history includes hypertension, dyslipidemia, and a cerebrovascular ischemic stroke with minimal neurologic deficits. His medica-

tions at this time were clopidogrel, pantoprazole, candesartan, indapamide, gabapentin, sennoside, as well as 30 g of fiber daily.

The patient was seen four months after the initiation of prucalopride and was now having regular bowel movements for the first time since his Whipple's surgery. He required no further admissions to hospital and his quality of life significantly improved while using prucalopride as the sole agent for management of his constipation. It was however noted that his creatinine was had risen from a baseline of 103 (eGFR baseline 61 mL/min per 1.73 m<sup>2</sup>, stable for at least 4 years) to 165 μmol/L (eGFR 35 mL/min per 1.73 m<sup>2</sup>) in two months, and further to 270 μmol/L (eGFR 19 mL/min per 1.73 m<sup>2</sup>) by four months (Figure 1). He endorsed no symptoms of decreased oral intake, oliguria, abdominal pain, nausea, vomiting, peripheral swelling, or shortness of breath. He also denied any irritative or obstructive urinary symptoms. There were no recent changes to his medications, or any use of over the counter medications such as non-steroidal anti-inflammatory drugs. His candesartan was held and he was referred to a nephrologist for an urgent assessment.

At this appointment he was found to have a normal blood pressure on examination, with no signs of a rash, peripheral edema, or volume overload. His blood work now demonstrated an elevated creatinine of 285 μmol/L at 4.5 mo following prucalopride administration. A complete work up for other renal disease including glomerular based diseases was negative and the patient did not have peripheral eosinophilia. Urinalysis showed +1 proteinuria, trace blood, and urine microscopy revealed many white blood cell casts. An ultrasound of his kidneys showed no signs of obstructive uropathy and Doppler examination of his renal arteries and veins were normal. He was diagnosed with acute interstitial nephritis secondary to his exposure to prucalopride and was instructed to stop this medication. He was started on prednisone 40 mg daily for one week, followed by a taper of 5 mg weekly. The patient was seen in follow-up two weeks later for repeat blood work. Unfortunately his creatinine remained elevated at 310 μmol/L while on prednisone at a dose of 30 mg daily. Given the lack of renal recovery, a renal biopsy



**Figure 2 Hematoxylin and eosin stain.** A: Hematoxylin and eosin stain demonstrating moderate interstitial fibrosis and tubular atrophy; B: Hematoxylin and eosin stain with polarized light demonstrating calcium oxalate deposition within the tubules.

was performed within one week.

The core biopsy specimen from the left kidney showed 11 of 39 glomeruli globally sclerosed, while the remainder of the glomeruli showed no increase in mesangial matrix or cellularity (Figure 2A). There was minimal interstitial inflammation, with moderate degenerative and regenerative changes within the tubules. There was moderate (40%) interstitial fibrosis and tubular atrophy. There was no arteriolar hyalinosis and moderate arterial sclerosis. Many of the tubules also contained oxalate and calcium phosphate crystals (Figure 2B). Immunofluorescence was negative for immunoglobulin A, G and M, as well as C3, C1q, kappa or lambda. Electron microscopy of the non-sclerosed glomeruli revealed no immune-type deposits, nor any tubuloreticular inclusions. The glomerular basement membranes were mildly wrinkled and within normal limits of thickness. There was moderate effacement of the podocyte foot processes (30%). These findings were consistent with acute tubular necrosis with no evidence for interstitial nephritis.

According to the Naranjo probability score of adverse drug reactions<sup>[15]</sup>, our patient's case was classified as a 'probable adverse drug reaction' of prucalopride induced kidney injury. Points were given for temporal causality, lack of an alternative cause of the reaction, lack of progression with drug discontinuation, and objective confirmation of kidney injury with the renal biopsy.

The patient remained on prednisone at 20 mg daily until seen in follow-up three weeks later. Repeat creatinine remained elevated at 309  $\mu\text{mol/L}$ . His prednisone taper was resumed at 5 mg per week and was ultimately discontinued since there were no signs of ongoing inflammation in the biopsy specimen. The patient unfortunately did not have any further renal recovery and his symptoms of constipation returned while off prucalopride. The search for alternative regimen to treat his chronic constipation is ongoing.

## DISCUSSION

Prucalopride is a novel highly selective 5-HT<sub>4</sub> receptor agonist developed for the treatment of chronic constipation among patients with an inadequate response to laxatives. The safety of this medication was assessed in all the Phase II trials, and in three Phase III pivotal trials.

A total of 1974 patients were evaluated in the phase III trials, with 1313 receiving prucalopride<sup>[8,12,13]</sup>. The most frequent adverse events reported were headache, abdominal pain, nausea and diarrhea, with most symptoms occurring on the first day. None of the phase III trials reported changes in renal function as measured by blood work at baseline and throughout the study. Two smaller placebo-controlled randomized trials in elderly patients with a mean age of 76 and 83, randomized a total of 301 patients to prucalopride<sup>[10,14]</sup>. The same profile of adverse events were seen in these trials with elderly patients as the larger phase III trials. However, in both trials, prucalopride was only administered for 4 wk and while no kidney injury was reported after short-term use, there is a lack of long-term data in the elderly. Numerous other smaller randomized trials with prucalopride also found no associated reports of renal impairment<sup>[9,11,16,17]</sup>. Elderly patients are at increased risk for baseline renal dysfunction. In the patient described in this report, although stable for least 4 years, the eGFR of 61 mL/min per 1.73 m<sup>2</sup>, likely reflected some degree of underlying chronic kidney disease. The elderly patient demographic and potential for underlying chronic kidney disease emphasize the importance of including this group in study trials for safety outcomes.

Our case demonstrates the first report of acute tubular necrosis associated with prucalopride administration. A thorough search on PubMed, Embase and Medline demonstrated no other reports of acute kidney injury secondary to prucalopride. A search for an association with alternative serotonin receptor agonists, such as cisapride or tegaserod, with kidney injury also found no previous case reports. Whether the acute tubular necrosis was due to acute interstitial nephritis or hemodynamic insult cannot be definitively known in this case, since the patient was treated empirically with steroids based on the prominent white blood cell casts on urinalysis. However it remains likely that interstitial inflammation was suppressed by steroid administration prior to the renal biopsy and the working clinical diagnosis was therefore acute interstitial nephritis causing acute tubular necrosis.

The key feature which differentiates prucalopride from other 5-HT<sub>4</sub> receptor agonists such as cisapride and tegaserod is its increased selectivity for its receptor<sup>[18]</sup>. The lack of selectivity of the other older agents resulted



in an appreciable affinity for other receptors, channels or transporters. For example, cisapride had an affinity for the human ether-a-go-go-related gene (hERG) K<sup>+</sup> channel found in cardiac cells<sup>[19]</sup> while tegaserod would also bind to 5-HT<sub>1</sub> and 5-HT<sub>2</sub> receptors<sup>[18]</sup>. These agents subsequently demonstrated cardiovascular side effects which were independent of their action on the 5-HT<sub>4</sub> receptor<sup>[19,20]</sup>. The characteristic of high selectivity is important as serotonin receptors are found throughout the body, including the kidney. The primary receptors in the kidney are the 5-HT<sub>2</sub> receptors on smooth muscle cells and the 5-HT<sub>1</sub> receptors on endothelial cells<sup>[21]</sup>. Stimulation of the 5-HT<sub>2</sub> receptors directly causes renal vasoconstriction, while activation of 5-HT<sub>1</sub> receptors leads to vasodilation indirectly *via* nitric oxide<sup>[22]</sup>. It has been found that administration of serotonin impairs autoregulation of the glomerular filtration rate of the kidney, leaving it vulnerable to ischemic damage<sup>[23]</sup>. While prucalopride has agonistic effects on the serotonin receptor, given that it has not been shown to activate the specific subtypes of 5-HT<sub>2</sub> and 5-HT<sub>1</sub>, this mechanism of kidney injury is less likely. It is not known whether the concurrent use of candesartan in this patient may have also played a role in the development of acute tubular necrosis, since angiotensin II blockade can also cause impaired renal autoregulation and a decline in glomerular filtration rate through post-glomerular vasodilatation.

Our patient's renal biopsy also demonstrated increased deposition of crystals, with predominantly oxalate crystals as well as calcium phosphate crystals. Increased absorption of oxalate from the colon occurs in fat malabsorption states, such as pancreatic insufficiency<sup>[24]</sup>. In such instances, calcium preferentially binds to free fatty acids instead of oxalate, which allows the free soluble oxalate to be absorbed through the colon. Other factors which can increase oxalate absorption include the presence of bile salts<sup>[25]</sup> and the absence of bacteria such as *Oxalobacter formigenes* and certain strains of *Enterococcus faecalis* which are able to degrade oxalate<sup>[26]</sup>. Our patient had discontinued his pancreatic enzyme preparation at the time prucalopride was started due to side effects of abdominal pain. Given his history of Whipple's pancreatectomy and the discontinuation of his pancreatic replacement enzymes, this fat malabsorption state may have induced hyperoxaluria.

Oxalate nephropathy can occur from tubular obstruction caused by calcium oxalate crystals, or by direct tubular injury which results in progressive tubular atrophy and interstitial fibrosis<sup>[25]</sup>. It is also common to see small numbers of oxalate crystals within tubules after acute tubular necrosis as well as in other chronic renal impairment conditions. Given the mixture of both oxalate and calcium phosphate crystals in our patient's renal biopsy, an underlying oxalate nephropathy as the etiology of the acute kidney injury is less probable. In addition, the creatinine stabilized with cessation of prucalopride and the patient did not yet resume his pancreatic enzyme preparation. Cases of oxalate nephropathy reported in the literature

are often associated with oliguria and a marked decline in renal function requiring hemodialysis<sup>[27]</sup>. Fortunately, our patient's renal failure was not as severe. Follow up urinalyses have failed to demonstrate crystals of any type, further suggesting that a crystal nephropathy is not playing an important contribution to the patient's renal failure. Furthermore, high-fluid intake and low oxalate diet recommendations along with calcium carbonate supplements have not been associated with improved renal function.

In conclusion, given the lack of literature to support prucalopride and other serotonin receptor agonists as nephrotoxins, our patient's case of acute renal failure was treated initially as allergic interstitial nephritis. However, when his renal function did not improve with discontinuation of the medication and prednisone therapy, a renal biopsy was performed to confirm the diagnosis. This case demonstrates the importance of a renal biopsy when the diagnosis is unclear or when there is lack of improvement with therapy. In addition, this case also highlights the importance of routine blood work to follow cell count, biochemistry and renal function when starting a medication which is new to both the patient and the medical community. Adverse effects which were not documented by clinical trials may still occur in our patients and reporting of such outcomes is required for ongoing drug safety and monitoring. In addition, given the limited long-term data available for elderly patients, and unreliability of serum creatinine in estimating renal function, a lower 1 mg of prucalopride should be initiated in this population. Without routine blood work, this case of renal failure may have been missed until the patient presented with more significant symptoms related to renal failure such as oliguria, vomiting, volume overload or uremia.

## COMMENTS

### Case characteristics

A 75 years old gentleman initiated on prucalopride for chronic constipation with subsequent elevation of serum creatinine from 100 µmol/L to 270 µmol/L within four months.

### Clinical diagnosis

He was treated with prednisone for presumed acute interstitial nephritis and a subsequent renal biopsy demonstrated acute tubular necrosis secondary to acute interstitial nephritis.

### Differential diagnosis

Acute interstitial nephritis secondary to a drug allergic reaction, oxalate nephropathy, and acute tubular necrosis following hemodynamic insult, angiotensin II blockade or interstitial nephritis.

### Laboratory diagnosis

Serum creatinine rose from a baseline of 103 µmol/L to a peak of 310 µmol/L and urine microscopy revealed many white cell casts.

### Imaging diagnosis

Abdominal ultrasound showed no signs of obstructive uropathy, and Doppler examination was negative for renal artery stenosis.

### Pathologic diagnosis

A renal biopsy was performed after cessation of prucalopride and administration of prednisone revealing moderate interstitial fibrosis and tubular atrophy with deposition of oxalate and calcium phosphate crystals.

### Treatment

Therapy with prednisone was initiated once white cell casts were seen on uri-



nary microscopy and prucalopride was discontinued resulting in stabilization of the serum creatinine but no further recovery of renal function.

### Related reports

This is the first case of acute renal failure reported in the literature, with no previous occurrences documented from several previous Phase II and III trials.

### Term explanation

Prucalopride is a novel highly selective 5 hydroxytryptamine-4 receptor agonist developed for the treatment of chronic constipation after failure of laxative therapy.

### Experiences and lessons

This case highlights the need for monitoring of routine blood work with cell count, biochemistry and renal function when using medications new to both the patient and the medical community as previously undocumented adverse events may develop.

### Peer review

This is an important case report in regard to clinical use of prucalopride.

## REFERENCES

- 1 **Suares NC, Ford AC.** Prevalence of, and risk factors for, chronic idiopathic constipation in the community: systematic review and meta-analysis. *Am J Gastroenterol* 2011; **106**: 1582-1591; quiz 1581, 1592 [PMID: 21606976 DOI: 10.1038/ajg.2011.164]
- 2 **Lembo A, Camilleri M.** Chronic constipation. *N Engl J Med* 2003; **349**: 1360-1368 [PMID: 14523145 DOI: 10.1056/NEJM-ra020995]
- 3 **Sun SX, Dibonaventura M, Purayidathil FW, Wagner JS, Dabous O, Mody R.** Impact of chronic constipation on health-related quality of life, work productivity, and healthcare resource use: an analysis of the National Health and Wellness Survey. *Dig Dis Sci* 2011; **56**: 2688-2695 [PMID: 21380761 DOI: 10.1007/s10620-011-1639-5]
- 4 **Tack J, Müller-Lissner S.** Treatment of chronic constipation: current pharmacologic approaches and future directions. *Clin Gastroenterol Hepatol* 2009; **7**: 502-508; quiz 496 [PMID: 19138759 DOI: 10.1016/j.cgh.2008.12.006]
- 5 **American College of Gastroenterology Chronic Constipation Task Force.** An evidence-based approach to the management of chronic constipation in North America. *Am J Gastroenterol* 2005; **100** Suppl 1: S1-S4 [PMID: 16008640 DOI: 10.1111/j.1572-0241.2005.50613.1.x]
- 6 **Gardner VY, Beckwith JV, Heyneman CA.** Cisapride for the treatment of chronic idiopathic constipation. *Ann Pharmacother* 1995; **29**: 1161-1163 [PMID: 8573964]
- 7 **Kamm MA, Müller-Lissner S, Talley NJ, Tack J, Boeckstaens G, Minushkin ON, Kalinin A, Dzieniszewski J, Haack P, Fordham F, Hugot-Courneze S, Nault B.** Tegaserod for the treatment of chronic constipation: a randomized, double-blind, placebo-controlled multinational study. *Am J Gastroenterol* 2005; **100**: 362-372 [PMID: 15667494 DOI: 10.1111/j.1572-0241.2005.40749.x]
- 8 **Camilleri M, Kerstens R, Ryckx A, Vandeplasse L.** A placebo-controlled trial of prucalopride for severe chronic constipation. *N Engl J Med* 2008; **358**: 2344-2354 [PMID: 18509121 DOI: 10.1056/NEJMoa0800670]
- 9 **Ke M, Zou D, Yuan Y, Li Y, Lin L, Hao J, Hou X, Kim HJ.** Prucalopride in the treatment of chronic constipation in patients from the Asia-Pacific region: a randomized, double-blind, placebo-controlled study. *Neurogastroenterol Motil* 2012; **24**: 999-e541 [PMID: 22882724 DOI: 10.1111/j.1365-2982.2012.01983.x]
- 10 **Müller-Lissner S, Ryckx A, Kerstens R, Vandeplasse L.** A double-blind, placebo-controlled study of prucalopride in elderly patients with chronic constipation. *Neurogastroenterol Motil* 2010; **22**: 991-998, e255 [PMID: 20529205 DOI: 10.1111/j.1365-2982.2010.01533.x]
- 11 **Coremans G, Kerstens R, De Pauw M, Stevens M.** Prucalopride is effective in patients with severe chronic constipation in whom laxatives fail to provide adequate relief. Results of a double-blind, placebo-controlled clinical trial. *Digestion* 2003; **67**: 82-89 [PMID: 12743445 DOI: 10.1159/000070202]
- 12 **Tack J, van Outryve M, Beyens G, Kerstens R, Vandeplasse L.** Prucalopride (Resolor) in the treatment of severe chronic constipation in patients dissatisfied with laxatives. *Gut* 2009; **58**: 357-365 [PMID: 18987031 DOI: 10.1136/gut.2008.162404]
- 13 **Quigley EM, Vandeplasse L, Kerstens R, Ausma J.** Clinical trial: the efficacy, impact on quality of life, and safety and tolerability of prucalopride in severe chronic constipation--a 12-week, randomized, double-blind, placebo-controlled study. *Aliment Pharmacol Ther* 2009; **29**: 315-328 [PMID: 19035970 DOI: 10.1111/j.1365-2046.2008.03884.x]
- 14 **Camilleri M, Beyens G, Kerstens R, Robinson P, Vandeplasse L.** Safety assessment of prucalopride in elderly patients with constipation: a double-blind, placebo-controlled study. *Neurogastroenterol Motil* 2009; **21**: 1256-e117 [PMID: 19751247 DOI: 10.1111/j.1365-2982.2009.01398.x]
- 15 **Naranjo CA, Busto U, Sellers EM, Sandor P, Ruiz I, Roberts EA, Janecek E, Domecq C, Greenblatt DJ.** A method for estimating the probability of adverse drug reactions. *Clin Pharmacol Ther* 1981; **30**: 239-245 [PMID: 7249508 DOI: 10.1038/clpt.1981.154]
- 16 **Sloots CE, Ryckx A, Cools M, Kerstens R, De Pauw M.** Efficacy and safety of prucalopride in patients with chronic noncancer pain suffering from opioid-induced constipation. *Dig Dis Sci* 2010; **55**: 2912-2921 [PMID: 20428949 DOI: 10.1007/s10620-010-1229-y]
- 17 **Krogh K, Jensen MB, Gandrup P, Laurberg S, Nilsson J, Kerstens R, De Pauw M.** Efficacy and tolerability of prucalopride in patients with constipation due to spinal cord injury. *Scand J Gastroenterol* 2002; **37**: 431-436 [PMID: 11989834]
- 18 **De Maeyer JH, Lefebvre RA, Schuurkes JA.** 5-HT<sub>4</sub> receptor agonists: similar but not the same. *Neurogastroenterol Motil* 2008; **20**: 99-112 [PMID: 18199093 DOI: 10.1111/j.1365-2982.2007.01059.x]
- 19 **Mohammad S, Zhou Z, Gong Q, January CT.** Blockage of the HERG human cardiac K<sup>+</sup> channel by the gastrointestinal prokinetic agent cisapride. *Am J Physiol* 1997; **273**: H2534-H2538 [PMID: 9374794]
- 20 **Busti AJ, Murillo JR, Cryer B.** Tegaserod-induced myocardial infarction: case report and hypothesis. *Pharmacotherapy* 2004; **24**: 526-531 [PMID: 15098809 DOI: 10.1592/phco.24.5.526.33351]
- 21 **Lameire NH.** Serotonin and the regulation of renal blood flow in acute renal failure. *Am J Kidney Dis* 1999; **33**: LII-LIV [PMID: 10196033 DOI: 10.1016/S0272-6386(99)70211-8]
- 22 **Van Nueten JM.** Serotonin and the blood vessel wall. *J Cardiovasc Pharmacol* 1985; **7** Suppl 7: S49-S51 [PMID: 2412058]
- 23 **Endlich K, Kühn R, Steinhäusen M.** Visualization of serotonin effects on renal vessels of rats. *Kidney Int* 1993; **43**: 314-323 [PMID: 8441228 DOI: 10.1038/ki.1993.49]
- 24 **Dobbins JW, Binder HJ.** Importance of the colon in enteric hyperoxaluria. *N Engl J Med* 1977; **296**: 298-301 [PMID: 831127 DOI: 10.1056/NEJM197702102960602]
- 25 **Wandzilak TR, Williams HE.** The hyperoxaluric syndromes. *Endocrinol Metab Clin North Am* 1990; **19**: 851-867 [PMID: 2081515]
- 26 **Allison MJ, Cook HM, Milne DB, Gallagher S, Clayman RV.** Oxalate degradation by gastrointestinal bacteria from humans. *J Nutr* 1986; **116**: 455-460 [PMID: 3950772]
- 27 **Hill P, Karim M, Davies DR, Roberts IS, Winearls CG.** Rapidly progressive irreversible renal failure in patients with pancreatic insufficiency. *Am J Kidney Dis* 2003; **42**: 842-845 [PMID: 14520637 DOI: 10.1016/S0272-6386(03)00948-X]

P- Reviewer: Du C, Gurjar M S- Editor: Song XX L- Editor: A  
E- Editor: Lu YJ



## Actinic prurigo of the lip: Two case reports

Ana MO Miranda, Thiago M Ferrari, Juliana T Werneck, Arley Silva Junior, Karin S Cunha, Eliane P Dias

Ana MO Miranda, Thiago M Ferrari, Juliana T Werneck, Arley Silva Junior, Karin SG Cunha, Eliane P Dias, Department of Pathology, Federal Fluminense University, Niteroi, Rio de Janeiro 24220-008, Brazil

**Author contributions:** Miranda AMO, Ferrari TM, Werneck JT, Silva Junior A were involved in patient care; Miranda AMO and Ferrari TM collected the patient's clinical data and wrote the paper; Miranda AMO and Dias EP designed the report; Cunha KS and Werneck JT translated the paper; Cunha KS and Dias EP drafted the article, revised it critically for important intellectual content and approved the final version to be published.

Supported by CNPq

**Correspondence to:** Ana MO Miranda, PhD Student of Pathology, Department of Pathology, Federal Fluminense University, 9-Icaraí, Niteroi, Rio de Janeiro 24220-008, Brazil. [anamiranda3@hotmail.com](mailto:anamiranda3@hotmail.com)

Telephone: +55-21-983773555 Fax: +55-21-26102916

Received: January 9, 2014 Revised: April 2, 2014

Accepted: May 16, 2014

Published online: August 16, 2014

© 2014 Baishideng Publishing Group Inc. All rights reserved.

**Key words:** Actinic prurigo; Follicular cheilitis; Photodermatosis; High-altitude; Lip diseases

**Core tip:** The diagnosis of actinic prurigo can be challenging in the absence of classic clinical manifestations. Actinic prurigo is found in high-altitude living people, mainly in indigenous descendants. Disease onset is usually in childhood and rarely presents only on the lips. This study describes two rare cases from Rio de Janeiro city, Brazil, which is located at sea level. The patients were unaware of possible Indian ancestry. Moreover, actinic prurigo appeared in adulthood and lip lesions were the only manifestation. The associated clinical and histological exams are determinants for the correct diagnosis and successful treatment of this disease.

### Abstract

Actinic prurigo is a photodermatosis that can affect the skin, conjunctiva and lips. It is caused by an abnormal reaction to sunlight and is more common in high-altitude living people, mainly in indigenous descendants. The diagnosis of actinic prurigo can be challenging, mainly when lip lesions are the only manifestation, which is not a common clinical presentation. The aim of this article is to report two cases of actinic prurigo showing only lip lesions. The patients were Afro-American and were unaware of possible Indian ancestry. Clinical exam, photographs, videoroscopy examination and biopsy were performed, and the diagnosis of actinic prurigo was established. Topical corticosteroid and lip balm with ultra-violet protection were prescribed with excellent results. The relevance of this report is to show that although some patients may not demonstrate the classical clinical presentation of actinic prurigo, the associated clinical and histological exams are determinants for the correct diagnosis and successful treatment of this disease.

Miranda AMO, Ferrari TM, Werneck JT, Silva Junior A, Cunha KS, Dias EP. Actinic prurigo of the lip: Two case reports. *World J Clin Cases* 2014; 2(8): 385-390 Available from: URL: <http://www.wjgnet.com/2307-8960/full/v2/i8/385.htm> DOI: <http://dx.doi.org/10.12998/wjcc.v2.i8.385>

### INTRODUCTION

Actinic prurigo (AP) is a type of photodermatosis, and is a rare familial inflammatory disease that primarily affects areas of skin exposed to the sun and can affect the lips and ocular conjunctiva (pseudopterygium formation)<sup>[1]</sup>. Pseudopterygium does not appear as a unique lesion in patients with AP, it is always preceded by skin and lip lesions, suggesting that this expression tends to appear later in the disease course. For this reason, the diagnosis of AP in its early stages is important to prevent subsequent complications<sup>[2]</sup>. AP of the lip, also known as follicular cheilitis, is mainly found on the vermillion of the lower lip. Lip lesions may appear early in the development of

this disease and, consequently, its observation and accurate diagnosis can alert physicians or dentists to the possible development of other more severe lesions on the skin or conjunctiva<sup>[2]</sup>. AP occurs mainly in residents of high altitudes and affects ethnic groups, particularly in North and South America, who express major histocompatibility complex class I and II (HLA I and II), suggesting a genetic predisposition<sup>[3]</sup>. The aim of this article is to describe two cases of AP of the lips without the classical features of this disease (young age at onset, familial history, high-altitude living people, and an association with skin lesions).

## CASE REPORT

### Case one

A 63-year-old Afro-American woman presented to our Oral Diagnostic clinic complaining of lower lip lesions of 10 mo evolution, which had worsened in the last 6 mo. She was referred by two centers that had failed to establish the diagnosis. During physical exam, the lower lip showed edema, as well as multiple ulcers covered with yellowish crusts on the semimucosa (Figure 1A). The slightest touch or mouth opening resulted in significant bleeding, which, according to the patient was commonly observed. No alterations during intraoral examination were observed. The lesions were documented by clinical and videoroscopy images (Figure 1B) and were scraped for cytopathologic evaluation, which revealed moderate inflammation. Lip balm with ultraviolet (UV) protection was prescribed.

On the second visit, debridement of the lesions was performed, as well as a biopsy (the selected area was chosen by clinical and videoroscopy exam) (Figure 1C). The clinical diagnostic hypotheses were erythema multiforme and contact cheilitis. Microscopically (Figure 1E-H), the surface epithelium showed orthokeratosis, with some areas of parakeratosis, atrophy and areas of acanthosis, as well as basal layer degeneration and lymphocytic exocytosis. Ulceration was also present. The connective tissue exhibited pigmentary incontinence close to the overlying epithelium, dilated blood vessels, edema and intense and diffuse lymphocytic inflammatory infiltrate, with some plasma cells, extending deep into the fatty tissue. Some secondary lymphoid follicles were also present. Several mast cells were present predominantly in the deeper area of the connective tissue, mainly in the perivascular and perineural areas. Nonspecific chronic sialadenitis with ductal ectasia was also observed. There was no solar elastosis. The diagnosis of follicular cheilitis was established.

Following diagnosis, a combination of triamcinolone acetate cream, neomycin sulfate, gramicidin and nystatin cream was prescribed three times a day. The patient was instructed to use gauze compresses with cold physiological saline and to continue using lip balm with UV protection. The patient was also referred to the dermatology and ophthalmology service for evaluation of signs and symptoms of AP. No ocular or skin lesions were

observed.

Complete remission of the lip ulcers and crusts was observed after one month of treatment (Figure 1D). The patient was followed-up monthly for three months without evidence of recurrence. Two months after diagnosis and during the follow-up period, the patient reported she was of indigenous Brazilian descent. After the third consecutive monthly follow-up, the patient was followed-up every 4 mo to date (2 years after the first visit), and showed no lip lesions (Figure 1D). The patient did not develop any skin or ophthalmic lesions.

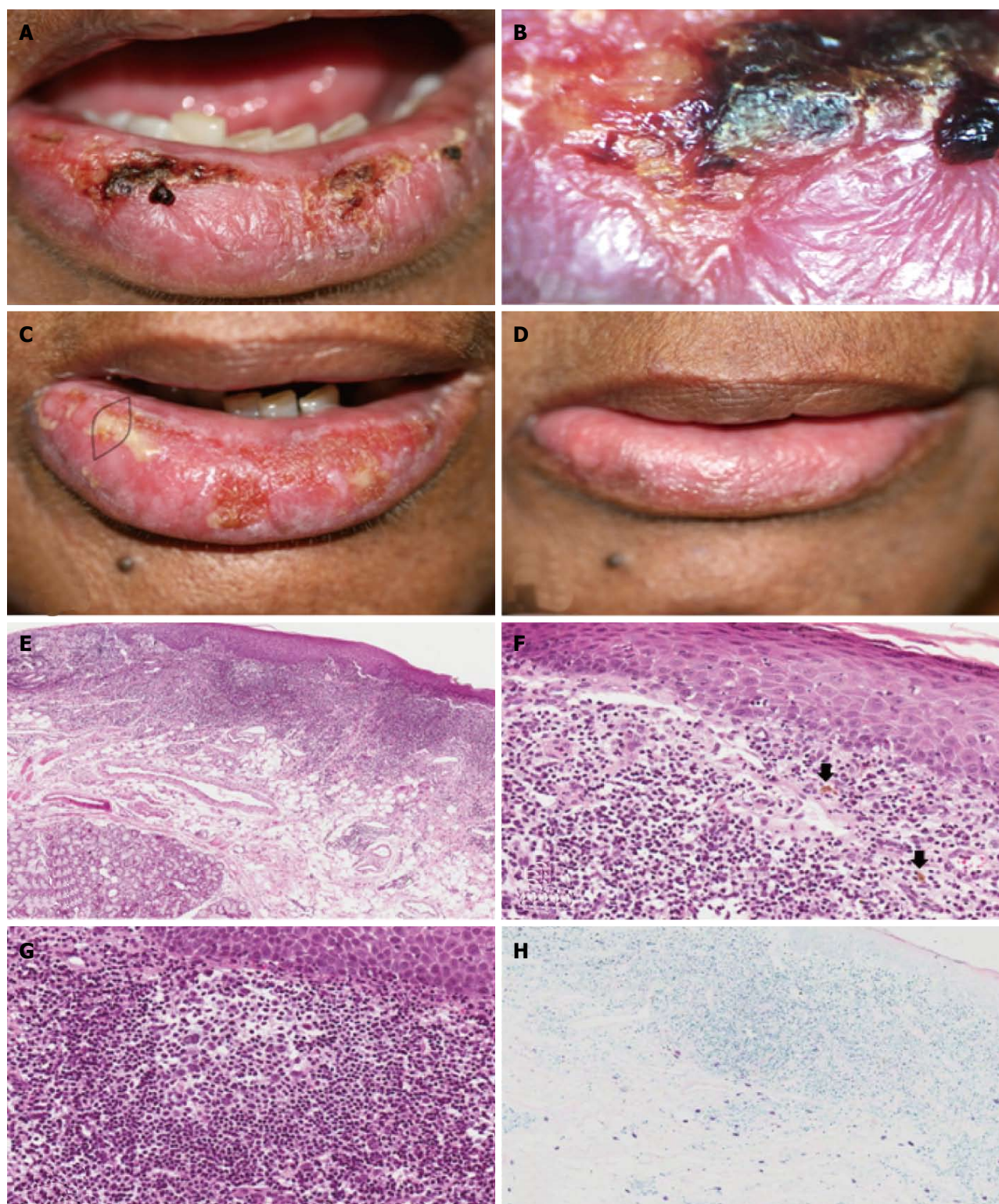
### Case two

A 58-year-old Afro-American woman, presented to our Oral Diagnostic clinic complaining of a painful lesion on the lower lip of four years evolution. Physical examination showed the presence of a yellowish crust of 1.3 cm × 0.8 cm, on the left side, which was easily seen during the examination, revealing an ulcerated area. The lips were swollen and dry (Figure 2A). The lesions were documented by clinical and videoroscopy images (Figure 2B) and were scraped for cytopathologic evaluation, which revealed moderate inflammation. No alterations were observed during the intraoral examination. Lip balm with UV protection was prescribed. On the second visit, a biopsy was performed (the selected area was chosen by clinical and videoroscopy exam). The diagnostic hypotheses were erythema multiforme and acute actinic cheilitis. Microscopically (Figure 2C and D), the lesion was covered by stratified orthokeratinized squamous epithelium showing atrophy, ulceration, spongiosis and hydropic degeneration of the basal layer. The underlying connective tissue showed pigmentary incontinence close to the overlying epithelium, dilated blood vessels with areas of intense inflammatory infiltrate, mainly composed of lymphoplasmacytic cells, and the formation of well-formed secondary lymphoid follicles. Mast cells were also observed between the lymphocytes and plasma cells. The inflammatory infiltration extended deep into the fatty tissue. There was no solar elastosis. The diagnosis of follicular cheilitis was established.

The patient was followed-up (one month after the first visit) and showed remission of the ulceration on the left side, with only a small ulcer on the right side of the lip (Figure 2B). She was referred for dermatological and ophthalmological evaluation and asked to return to our clinic one month later. The patient did not return.

A search of the medical literature was performed by two authors separately, using Pubmed, Lilacs, Scielo and Cochrane databases, without year and language restriction, using the terms: (1) prurigo AND actinic; and (2) follicular AND cheilitis. The last search was performed in November 2013. A paper considered eligible for inclusion on review had to include a case report or a study with at least one case under the name “actinic prurigo” or “follicular cheilitis” and with lip lesions as the only manifestation (Table 1). Only two papers satisfied the criteria: Vega-Memije *et al*<sup>[2]</sup> and Mounsdon *et al*<sup>[4]</sup>. In the



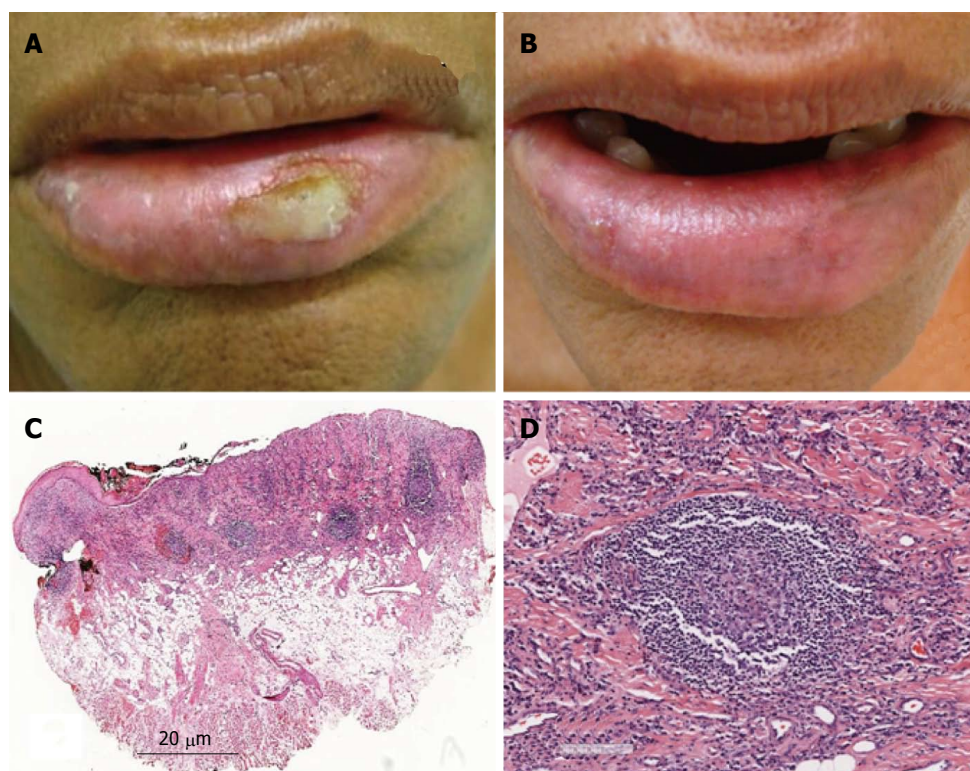


**Figure 1 Case 1.** A: Clinical aspect at the first appointment, showing lower lip edema, ulcers and crusts; B: Videoroscopy image showing in detail the presence of ulcer and crust; C: Clinical aspect at the second appointment showing the area of biopsy; D: Clinical aspect one month after treatment, showing remission of the lip edema, ulcers and crusts; E: Histological aspects. Epithelial atrophy and intense diffuse lymphoplasmacytic inflammatory infiltrate extending deep into the fatty tissue ( $\times 10$ , HE); F: Epithelium showing spongiosis, hydropic degeneration of the basal layer cells and lymphocytic exocytosis. In the connective tissue, lymphocytic inflammatory infiltrate and pigmentary incontinence (arrows) were observed ( $\times 40$ , HE). G: Secondary lymphoid follicle ( $\times 40$ , HE); H: Mast cells mainly in the deeper area of the connective tissue ( $\times 20$ , Giemsa).

study by Vega-Memije *et al*<sup>[2]</sup>, 116 patients presented with actinic prurigo cheilitis; of these, 74 (63.8%) were female, aged from 9 to 82 years (mean, 27.8 years). Ninety-nine

percent of the patients lived in areas more than 1000 m above sea level and only one case was from a geographic area below this altitude. AP cheilitis was the only manifes-





**Figure 2 Case 2.** A: Clinical aspect at the first appointment, showing lower lip edema, dryness and ulcer on the left side of the semimucosa; B: Clinical aspect at the second appointment, showing remission of the ulceration on the left side, and only a small ulcer on the right side of the semimucosa; C: Histological aspects. Lower power view showing epithelial atrophy and ulceration. In the connective tissue, an intense, diffuse inflammatory infiltrate extending deep into the fatty tissue, with some lymphoid follicles was observed (HE); D: Secondary lymphoid follicle (HE).

**Table 1 Results of the literature search for “actinic prurigo” or “follicular cheilitis” of the lip**

	Actinic prurigo	Follicular cheilitis	Eligible paper <sup>1</sup>
Pubmed	143	9	2
Lilacs	25	0	0
Scielo	3	0	0
Cochrane	7	1	0

<sup>1</sup>A paper considered eligible for inclusion in the review had to include a case report or a study with at least one case under the name “actinic prurigo” or “follicular cheilitis”, and show lip lesions as the only manifestation.

tation of the disease in 32 (27.6%) patients. Mounsdon *et al*<sup>[4]</sup> described two North American Indians, one man and one woman, who showed only lip lesions, however, there was no information on their place of residence. In addition, a thesis describing a study of 43 patients with actinic prurigo of the lips was found in Google Scholar<sup>[5]</sup>. Although this study was carried out in Brazil, it was a retrospective analysis of patients resident in Mexico, where this disease is very common. In 17 (39.54%) cases, the lesion was located only on the lips. To make comparative analyses with the cases presented in our paper, 16 patients in this study were included; one was excluded because the age of the patient was not provided. Patient age ranged from 11 to 63 (mean 26 years). Information on where the patients lived was not provided (Table 2).

## DISCUSSION

Photodermatoses form an important group of skin diseases, which can be disabling to the patient, and represent a challenge in diagnosis and treatment<sup>[6]</sup>. Although dark skin has larger quantities of melanin compared to white skin, which gives greater protection against the sun’s rays, photodermatoses are common in dark-skinned people<sup>[7]</sup>. AP is an example of a photodermatosis that affects mostly Mestizos in the Americas. This is the result of miscegenation between Europeans and Indians, which prevails in Mexico, Guatemala, Honduras, Colombia, Ecuador, Peru, Bolivia, and Argentina, and in some indigenous communities in North America and Canada<sup>[8-10]</sup>. AP usually begins in childhood, around 4-5 years old<sup>[5]</sup>, although it can manifest at any age, affecting more women than men (2:1), and in some cases with familial history<sup>[11]</sup>.

The severity of the disease is altitude-dependent, presumably because of the sustained intensity of sun exposure. It is believed that this is the reason why AP is found mostly in regions with altitude above 1000 m<sup>[3]</sup>. These data make our cases interesting, as both patients lived in Brazil, in cities at sea level, and did not report being indigenous descendants during anamnesis, did not have a positive familial history, and showed the first signs and symptoms in adulthood.

AP lesions are mainly found in sun-exposed areas<sup>[3,12,13]</sup>. Lips and conjunctiva can also be affected<sup>[3,12]</sup>.

**Table 2** Data from patients with actinic prurigo, with only lip lesions

	Vega-Memije <i>et al</i> <sup>[2]</sup>	Rizo <i>et al</i> <sup>[5]</sup>	Mounsdon <i>et al</i> <sup>[4]</sup>	Maga-a <i>et al</i> <sup>[1]</sup>
Age	9-82 (mean 27.8 yr)	11-63 (mean 26 yr)	61 and 69 yr old	58 and 63 yr old
Country	Mexico	Mexico	United States (North American Indians)	Brazil
High altitude	99% more than 1000 m	Unknown	Unknown	Sea level

Nevertheless, in Asians, conjunctivitis and cheilitis are not common<sup>[14]</sup>. The patients presented in this paper showed lip lesions as the only manifestation of AP. Although there are few reports and studies in the literature regarding patients with AP showing only lip lesions, this may occur in up 40% of cases<sup>[5]</sup>. In cases of AP with lip lesions as the only manifestation it is more difficult to establish an accurate diagnosis, which should alert clinicians to the possibility of the development of other more severe lesions, such as skin or conjunctival lesions. Therefore, it is important to refer these patients for ophthalmological and dermatological evaluation.

AP lip lesions are characterized by swelling, peeling, cracking, crusting, itching, exudation, and secondary ulceration<sup>[3,12]</sup>. Cheilitis intensity is variable. In the acute phase, yellow crusts adhered to the surface are observed, whereas in the chronic phase, the lesions are covered with dry scales, and the course is generally prolonged, with relapses worsened by constant sun exposure<sup>[2,8,5]</sup>.

During the evaluation of our patients, we used videoroscopy which enabled better visualization of the lip lesions. As both patients showed extensive lesions, the choice of the biopsy area was difficult and videoroscopy was used to help choose the best biopsy area. The lesions were similar to those of AP lip lesions described in the literature.

Clinical differential diagnoses regarding AP include actinic cheilitis, frictional contact cheilitis and granulomatous cheilitis<sup>[5]</sup>. In the present cases, we also considered the possibility of acute actinic cheilitis, which was later rejected due the evolution time and because the patients did not report intense sunlight exposure. The other clinical diagnoses were erythema multiforme, which was rejected due to the course of the lesions, and contact cheilitis, but we were unable to identify a substance which could cause the lip lesions, especially over such a long time. Although several clinical factors associated with follicular cheilitis were not observed in the present cases, the clinical exam associated with the histopathological diagnosis was a determinant in establishing the final diagnosis.

Studies in the literature define the histopathological pattern of AP lip lesions as showing acanthosis, spongiosis and basal layer hydropic degeneration<sup>[2]</sup>. Areas of ulceration may also be seen. Edema, dilated and congested vessels, with dense predominantly lymphocytic inflammatory infiltrate, which may contain lymphoid follicles and eosinophils are also seen in the connective tissue<sup>[2,4,12]</sup>. Furthermore, some studies report that discrete exocytosis in the basal epithelium and pigmentary incontinence in the sub epithelial connective tissue may be observed<sup>[2]</sup>.

The presence of lymphoid follicles is considered by some authors to be a pathognomonic feature of AP and this is the reason why the term follicular cheilitis is used<sup>[12]</sup>. Mast cells and macrophages may be found in the inflammatory infiltrate<sup>[5]</sup>. The histopathological findings in our cases are consistent with the description in the literature. The identification of lymphoid follicles in both cases was important in establishing the diagnosis.

No solar elastosis was found in the AP lesions, which facilitates the differential diagnosis from actinic cheilitis<sup>[2,4,5,12]</sup>. It is necessary to differentiate AP from polymorphic light eruption, which is clinically similar, but microscopically does not show lymphocytic infiltrate with lymphoid follicles<sup>[12]</sup>.

With regard to the treatment of AP, as a general measure, it is recommended to reduce sun exposure, use protective clothing including hats, and sunscreen. However, these measures are not sufficient to treat AP. There is evidence that AP is an autoimmune disease, and therefore immunosuppressive drugs produce good results<sup>[3]</sup>. Treatment of AP varies according to the severity and extent of the lesions, and includes topical and systemic corticosteroids to reduce the inflammation and itching of active lesions, antibiotics for secondary infections, antihistamines, antimalarials and thalidomide, which have been shown to be the most effective drugs for the treatment of AP<sup>[12,15-18]</sup>.

AP prognosis is not good, despite several treatment options, the lesions may have a chronic course and are difficult to control if patients live in sunny areas, are occupationally exposed to the sun or live in high altitudes<sup>[19]</sup>. In case 1, the patient responded well to treatment with a topical corticosteroid and prevention measures; she had no lesions up to the last follow-up (14 mo after diagnosis). The patient in case 2 was treated only with prevention measures (including the use of lip balm with UV protection). In the follow-up, one month after diagnosis, the lesions disappeared, but she did not return for her follow-up appointment.

AP is a well-known disease, occurring mainly in Mestizos, living in high altitudes with onset during childhood. The cases presented here were a challenge to diagnose as the clinical characteristics were different from the classical manifestations of AP: the lesions began in adulthood, the patients lived at sea level and did not report, at least during the interview, being indigenous descendants, and neither reported having a familial history of alterations. In these cases, without skin lesions, the diagnosis of AP in the early stages is important, as it can alert the clinician to the possible development of other more severe le-

sions, and, thus, referring the patients for an ophthalmologic and dermatologic evaluation is mandatory.

## COMMENTS

### Case characteristics

This paper reports two cases of actinic prurigo in which the lower lips were the only sites of involvement.

### Clinical diagnosis

The relevance of these cases is that, although some important aspects do not follow the classical features of actinic prurigo, the associated clinical and histological exams can be determinants of the correct diagnosis and successful treatment.

### Imaging diagnosis

Clinical exam, photographs, videoroscopy examination and biopsy were performed, and the diagnosis of actinic prurigo was established.

### Peer review

It is an interesting case, it is well written.

## REFERENCES

- 1 **Maga-a M**, Domínguez R, Vázquez R, González N, Cazarín J. Prurigo solar en la ni-ez: manifestaciones cutáneas, oculares y labiales; Actinic prurigo in childhood: cutaneous, ocular and labial manifestations. *Bol méd Hosp Infant Méx junho de 1999*; **56**: 326-331
- 2 **Vega-Memije ME**, Mosqueda-Taylor A, Irigoyen-Camacho ME, Hojyo-Tomoka MT, Domínguez-Soto L. Actinic prurigo cheilitis: clinicopathologic analysis and therapeutic results in 116 cases. *Oral Surg Oral Med Oral Pathol Oral Radiol Endod* 2002; **94**: 83-91 [PMID: 12193899]
- 3 **Mesa AMS**. Prurigo actínico em la ninez. *Dermatol Pediatr Lat* 2005; **3**: 193-200
- 4 **Mounsdon T**, Kratochvil F, Auclair P, Neale J, Lee L. Actinic prurigo of the lower lip. Review of the literature and report of five cases. *Oral Surg Oral Med Oral Pathol* 1988; **65**: 327-332 [PMID: 3281085]
- 5 **Rizo VHT**. Estudo clinicopatológico e imunoistoquímico de prurigo actínico de lábio [dissertation]. [Piracicaba]: Universidade Estadual de Campinas; 2009
- 6 **Gambichler T**, Al-Muhammadi R, Boms S. Immunologically mediated photodermatoses: diagnosis and treatment. *Am J Clin Dermatol* 2009; **10**: 169-180 [PMID: 19354331 DOI: 10.2165/00128071-200910030-00003]
- 7 **Sharma VK**, Sahni K, Wadhwani AR. Photodermatoses in pigmented skin. *Photochem Photobiol Sci* 2013; **12**: 65-77 [PMID: 23123922 DOI: 10.1039/c2pp25182e]
- 8 **Hojyo-Tomoka T**, Vega-Memije E, Granados J, Flores O, Cortés-Franco R, Teixeira F, Domínguez-Soto L. Actinic prurigo: an update. *Int J Dermatol* 1995; **34**: 380-384 [PMID: 7657433]
- 9 **Hojyo-Tomoka MT**, Cortés-Franco R, Domínguez-Soto L, Vega-Memije E, Teixeira F, Reyes M. Follicular cheilitis. *Am J Dermatopathol* 1996; **18**: 330-331 [PMID: 8806972]
- 10 **Duran MM**, Bernal J. HLA typing in actinic prurigo. *J Am Acad Dermatol* 1992; **26**: 658 [PMID: 1597562]
- 11 **Arrese JE**, Dominguez-Soto L, Hojyo-Tomoka MT, Vega-Memije E, Cortés-Franco R, Guevara E, Piérard GE. Effectors of inflammation in actinic prurigo. *J Am Acad Dermatol* 2001; **44**: 957-961 [PMID: 11369907]
- 12 **Hojyo-Tomoka MT**, Vega-Memije ME, Cortes-Franco R, Domínguez-Soto L. Diagnosis and treatment of actinic prurigo. *Dermatol Ther* 2003; **16**: 40-44 [PMID: 12919125 DOI: 10.1046/j.1529-8019.2003.01606.x]
- 13 **Lane PR**, Hogan DJ, Martel MJ, Reeder B, Irvine J. Actinic prurigo: clinical features and prognosis. *J Am Acad Dermatol* 1992; **26**: 683-692 [PMID: 1583166]
- 14 **Ker KJ**, Chong WS, Theng CT. Clinical characteristics of adult-onset actinic prurigo in Asians: a case series. *Indian J Dermatol Venereol Leprol* 2013; **79**: 783-788 [PMID: 24177610 DOI: 10.4103/0378-6323.120726]
- 15 **Domínguez-Soto L**, Hojyo-Tomoka MT, Vega-Memije E, Cortés-Franco R, Waxtein L, Guevara E. Photodermatoses in tropical countries. *Clin Dermatol* 1999; **17**: 237-243; discussion 105-106 [PMID: 10330605]
- 16 **Ng JC**, Foley PA, Crouch RB, Baker CS. A case of severe actinic prurigo successfully treated with thalidomide. *Australas J Dermatol* 2001; **42**: 192-195 [PMID: 11488714]
- 17 **Crouch R**, Foley P, Baker C. Actinic prurigo: a retrospective analysis of 21 cases referred to an Australian photobiology clinic. *Australas J Dermatol* 2002; **43**: 128-132 [PMID: 11982570]
- 18 **Ross G**, Foley P, Baker C. Actinic prurigo. *Photodermatol Photoimmunol Photomed* 2008; **24**: 272-275 [PMID: 18811871 DOI: 10.1111/j.1600-0781.2008.00375.x]
- 19 **Akaraphanth R**, Sindhavananda J, Gritiyarangsana P. Adult-onset actinic prurigo in Thailand. *Photodermatol Photoimmunol Photomed* 2007; **23**: 234-237 [PMID: 17986059]

**P- Reviewer:** Chong WS, Ozyigit MT, Torres-álvarez MB  
**S- Editor:** Wen LL **L- Editor:** Webster JR **E- Editor:** Lu YJ





## Appendicitis in double cecal appendix: Case report

José Roberto Alves, Ícaro Godeiro de Oliveira Maranhão, Patrick Vanttinny Vieira de Oliveira

José Roberto Alves, Department of Integrated Medicine, University Hospital Onofre Lopes, Federal University of Rio Grande do Norte, 59012-300 Natal - Rio Grande do Norte, Brazil  
Ícaro Godeiro de Oliveira Maranhão, Patrick Vanttinny Vieira de Oliveira, University Hospital Onofre Lopes, Federal University of Rio Grande do Norte, 59012-300 Natal - Rio Grande do Norte, Brazil

**Author contributions:** Alves JR conducted the patient care in the emergency, surgery and photography service during the intra-operative period (Figure 1) and the postoperative medical care, was in charge of general supervision of students, writing, translation, final review and article submission; Maranhão IGO, Oliveira PVV performed the literature review on the anatomical variations of the cecal appendix, and are co-authors of the manuscript. All the authors read and approved the final manuscript.

**Correspondence to:** José Roberto Alves, PhD, Department of Integrated Medicine, University Hospital Onofre Lopes, Federal University of Rio Grande do Norte. Av. Nilo Peçanha, 620 - Petrópolis, 59012-300 Natal - Rio Grande do Norte, Brazil. [joserobertoalves1980@gmail.com](mailto:joserobertoalves1980@gmail.com)

Telephone: +55-84-81661115 Fax: +55-84-32153270

Received: March 9, 2014 Revised: April 16, 2014

Accepted: May 25, 2014

Published online: August 16, 2014

anatomopathological examination of the surgical samples showed acute inflammation in the two cecal appendices. So, performing a routine retroperitoneal release and a complete cecum evaluation during such surgical procedures is recommended and suggested due to the possibility of not identifying a second cecal appendix.

© 2014 Baishideng Publishing Group Inc. All rights reserved.

**Key words:** Appendix; Anatomic variation; Appendicitis; Appendectomy; General surgery

**Core tip:** Double cecal appendix is a rare (about 100 cases reported worldwide) anatomical variation often incidentally diagnosed in the face of inflammation in the organ. The current paper presents the first case reported in South America. The case is extremely important for the study of this possible anatomical variation since the lack of a diagnosis in a second cecal appendix can cause further complications for the patient and the physician. Moreover, it is associated with the presence of other anatomical variations, such as intestinal, genitourinary and bone. Such variations will be investigated in cases of the aforementioned diagnosis.

### Abstract

Double cecal appendix is a rare anatomical variation. Approximately 100 cases have been reported worldwide. It is usually diagnosed incidentally during emergency appendectomies due to inflammatory processes in the cecal appendix. Case presentation: male, white, 36 years old, obese, presenting with pain in the lower abdomen for 24 h followed by nausea, vomiting and mild fever. He was subjected to additional tests, with the leukogram showing leukocytosis and abdominal ultrasonography depicting cecal appendix with thickened wall, locally associated with small quantities of liquid and intestinal loop obstruction. He underwent laparotomy, revealing acute appendicitis. Another intestinal loop obstruction was identified next to the ileum, leading to recognizing another cecal appendix after local dissection. Double appendectomy and segmental ileectomy were performed although not needed. Results of the

Alves JR, Maranhão IGO, Oliveira PVV. Appendicitis in double cecal appendix: Case report. *World J Clin Cases* 2014; 2(8): 391-394  
Available from: URL: <http://www.wjgnet.com/2307-8960/full/v2/i8/391.htm> DOI: <http://dx.doi.org/10.12998/wjcc.v2.i8.391>

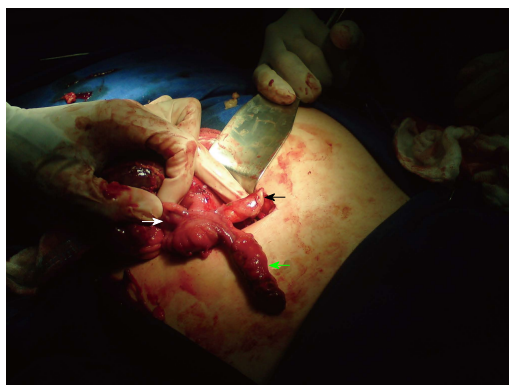### INTRODUCTION

Double cecal appendix is a rare anatomical variation, found in 0.004%<sup>[1]</sup> to 0.009%<sup>[2]</sup> of performed appendectomies. Approximately 100 cases of double cecal appendix<sup>[3-5]</sup> have been described worldwide so far, with no case reports in South America<sup>[2,3,6-37]</sup>.

### CASE REPORT

A male, white, 36 years old, slightly obese [body mass





**Figure 1** A photograph taken during a laparotomy procedure depicting an inflamed double cecal appendix. Minor (black arrow) and major (green arrow) inflamed cecal appendix. Surgeon's hand is on the left side of the picture, holding the proximal segment of the ileum (arrow with white edges).

index (BMI) = 31.1 kg/m<sup>2</sup>], presented with abdominal pain in the lower abdomen for 24 h, followed by nausea, vomiting and mild fever (axillary temperature = 37.9 °C). He was subjected to blood tests that only showed leukocytosis without left shift. In addition, abdominal ultrasonography depicted cecal appendix with thickened wall, locally associated with small quantities of intra-abdominal fluid and local obstruction of intestinal loops.

He underwent laparotomy with a McBurney's incision. The presence of an inflamed cecal appendix in its usual position after lysis of adhesions and cecum release was identified. Another intestinal loop obstruction was identified near the ileum. After the release of dense adhesions, it was possible to recognize the presence of a second cecal appendix, also with an inflammatory aspect (Figure 1), with its origin along the taenia coli.

A double appendectomy and segmental ileectomy in the part of the devascularized intestinal loop, resulting from ileum dissection, was performed in order to provide the release and excision of the second cecal appendix. Both appendices showed no sign of perforation despite the inflammatory aspect, *i.e.*, the occurrence of increased dimensions, thickened and erythematous wall, associated with fibrin and local tissue fragility.

The anatomopathological examination of the surgical samples corroborated the diagnosis of inflammation in both cecal appendices and resected segment of small intestine (ileum), with subserosal congestion and acute fibrinous serositis with eosinophils.

The patient had no postoperative complications and was discharged on the third day after surgery.

## DISCUSSION

Since 1892 after the first case of double cecal appendix<sup>[27]</sup> was reported, less than 100 cases have been reported worldwide<sup>[3]</sup>. It demonstrates the rarity of such variations and why the current reported case is the first one to be described in South America<sup>[2,3,6-37]</sup>.

Over time, some authors have presented classifica-

tions to categorize anatomical variations of cecal appendix. The first classification was developed in 1936 by Cave<sup>[28]</sup>. His classification was modified in 1962 by Wallbridge<sup>[29]</sup>. Since then, a number of authors have made some changes to it, leading to the modified classification by Cave-Wallbridge, which is now the most widely used<sup>[17,30]</sup>.

The classification modified by Cave-Wallbridge categorizes double cecal appendix into three types: A, B and C. Type A is characterized by the presence of two cecal appendices with a common origin in a single cecum. In type B, two appendices emerge from different cecal origins from a single cecum. This type is also subdivided into B1 and B2. In subtype B1, the two appendices emerge from a single cecum, one from each side of the ileocecal valve, symmetrically. On the other hand, in subtype B2, one of the appendices is in its usual position and the second one is located alongside the taenia coli. Finally, type C is characterized by the existence of two caeca, each with a cecal appendix (Figure 2).

The present reported case describes the occurrence of a patient with double cecal appendix type B. There are reports of other rarer forms presenting with anatomic variations of the cecal appendix, such as the horseshoe appendix<sup>[31]</sup> and the triple appendix<sup>[32]</sup>.

The existence of an cecal appendix duplication is asymptomatic and its diagnosis only comes during investigations on inflammation processes<sup>[3,17,33,34]</sup>. This is what happened in our patient's case. According to clinical data, he had no complaints related to his cecal appendix duplication until the occurrence of acute appendicitis.

Despite the rarity of anatomical variations in the cecal appendix, the awareness of them is of great importance to surgeons. An inadequate surgical evaluation of the cecum due to unawareness of such variations can leave a second or third cecal appendix<sup>[17,30]</sup> unidentified. This may lead to further reoperations, diagnostic difficulties and medicolegal problems regarding malpractice because of the possibility of new inflammation in the remaining appendices<sup>[17,30]</sup>.

For instance, this happened in a child whose cecal appendix duplication was not identified in the first appendectomy. Five months later, another laparotomy was needed in order to remove a second appendix which had also become inflamed<sup>[35]</sup>. Such a situation is most commonly found in patients with double cecal appendix type B<sup>[30]</sup>. It is worth mentioning that there is an increase in the postoperative morbidity and mortality<sup>[17,30]</sup> in patients in whom anatomical variations of the cecal appendix are not identified.

Finally, the importance of being aware of the association between double or triple cecal appendix and other anatomical variations, intestinal, genitourinary and osseous, should be highlighted<sup>[36,37]</sup>. These are most often associated with duplications of the cecal appendix types B1 and C<sup>[3]</sup>. Thus, when two or three cecal appendices are identified, investigating these other anatomical variations is recommended<sup>[3]</sup>.

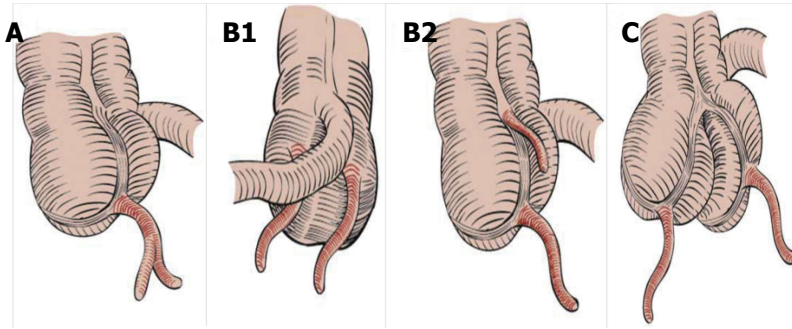


Figure 2 Classification modified by Cave-Wallbridge<sup>[30]</sup>, including type A, subtype B1, subtype B2 and type C.

As a final conclusion, although double or triple cecal appendices are rare, surgeons must be aware of them and identify cecal appendix anatomical variations. Such a procedure is recommended when doctors surgically approach a patient with acute appendicitis. They should perform a complete cecum evaluation after the retroperitoneal release in order to avoid further complications. Surgeons should remember that in the face of such changes, they will need to investigate the presence of intestinal, genitourinary or bone anatomic variations.

## ACKNOWLEDGEMENTS

We thank the patient for allowing the disclosure of his medical report and intraoperative photographic records.

## COMMENTS

### Case characteristics

Male, white, 36 years old, slightly obese, presenting with acute appendicitis.

### Clinical diagnosis

Abdominal pain in the lower abdomen for 24 h, followed by nausea, vomiting and mild fever (axillary temperature = 37.9 °C).

### Differential diagnosis

Causes of acute inflammatory abdomen.

### Laboratory diagnosis

Leukocytosis without left shift.

### Imaging diagnosis

Abdominal ultrasonography depicting cecal appendix with thickened wall, locally associated with small quantities of intra-abdominal fluid and intestinal loop local obstruction.

### Pathological diagnosis

Inflammation in both cecal appendices.

### Treatment

Laparotomy with a McBurney's incision, followed by the performance of a double appendectomy and segmental ilectomy.

### Related reports

Double cecal appendix is a rare (about 100 cases reported worldwide) anatomic variation most often incidentally diagnosed in face of inflammation of that organ.

### Term explanation

The classification modified by Cave-Wallbridge categorizes double cecal appendix.

### Experiences and lessons

The surgeon must be aware and identify cecal appendix anatomical variations. The procedure is recommended when surgeons surgically approach a patient with acute appendicitis. It is worth performing a complete cecum evaluation after the retroperitoneal release.

### Peer review

This case report is well designed and presents a wide range of information

about the subject, spreading the right messages and broadly contributing to the literature.

## REFERENCES

- 1 Collins DC. A study of 50,000 specimens of the human vermiform appendix. *Surg Gynecol Obstet* 1955; **101**: 437-445 [PMID: 13256319]
- 2 Kjossev KT, Losanoff JE. Duplicated vermiform appendix. *Br J Surg* 1996; **83**: 1259 [PMID: 8983623]
- 3 Griffiths EA, Jagadeesan J, Fasih T, Mercer-Jones M. Bifid vermiform appendix: a case report. *Curr Surg* 2006; **63**: 176-178 [PMID: 16757368]
- 4 Sobhian B, Mostegel M, Kunc C, Karner J. [Appendix vermiformis duplex--a rare surprise]. *Wien Klin Wochenschr* 2005; **117**: 492-494 [PMID: 16091877]
- 5 Oğuzkurt P, Oğuzkurt L, Kayaselcuk F, Oz S. An unusual cause of acute abdomen: torsion of colonic duplication over a duplicated appendix. *Pediatr Surg Int* 2004; **20**: 722-723 [PMID: 15449085]
- 6 McNeill SA, Rance CH, Stewart RJ. Fecolith impaction in a duplex vermiform appendix: an unusual presentation of colonic duplication. *J Pediatr Surg* 1996; **31**: 1435-1437 [PMID: 8906682]
- 7 Eroglu E, Erdogan E, Gundogdu G, Dervisoglu S, Yeker D. Duplication of appendix vermiformis: a case in a child. *Tech Coloproctol* 2002; **6**: 55-57 [PMID: 12077643]
- 8 Mahmood A, Mahmood NF, Williams JL. Acute abdominal pain presenting as a rare appendiceal duplication: a case report. *J Med Case Rep* 2012; **6**: 79 [PMID: 22397591 DOI: 10.1186/1752-1947-6-79]
- 9 Barreto FT, Alonso JRC, Blanco DP, Reyes DS, Casanova AD. Appendicular duplication. *Rev Cubana Cir* 2011; **50**: 348-352
- 10 De Lagausie P, Billing A, Eymeri JC, Tavakoli D. [Hypotrophic and duplicated appendix. A case in a child]. *Chir Pediatr* 1989; **30**: 216-217 [PMID: 2620390]
- 11 Kim EP, McClenathan JH. Unusual duplication of appendix and cecum: extension of the Cave-Wallbridge classification. *J Pediatr Surg* 2001; **36**: E18 [PMID: 11528635]
- 12 López-Deogracias M, Naranjo-Gozalo S, Sánchez-Moreno L, Gómez-Fleitas M. [Duplicated appendix in the presence of an adenocarcinoma]. *Cir Esp* 2008; **83**: 333 [PMID: 18570855]
- 13 Theodoropoulos GE, Tsamis D, Linardoutsos D, Stamopoulos P, Zoumpouli C, Zagouri F, Michalopoulos NV. Ruptured cystadenoma of a duplicated appendix. *Am Surg* 2010; **76**: 341-343 [PMID: 20349673]
- 14 Freeman HJ. Duplicated appendix complicated by appendiceal cancer. *World J Gastroenterol* 2011; **17**: 135-136 [PMID: 21218095 DOI: 10.3748/wjg.v17.i1.135]
- 15 Christodoulidis G, Symeonidis D, Spyridakis M, Koukoulis G, Manolakis A, Triantafylidis G, Tepetes K. Acute appendicitis in a duplicated appendix. *Int J Surg Case Rep* 2012; **3**: 559-562 [PMID: 22922359 DOI: 10.1016/j.ijscr.2012.08.004]
- 16 Oruç C, Işık O, Ureyen O, Kahyaoglu OS, Köseoğlu A. An extremely rare appendiceal anomaly: horseshoe appendici-

- tis. *Ulus Travma Acil Cerrahi Derg* 2013; **19**: 385-386 [PMID: 23884686 DOI: 10.5505/tjtes.2013.67424]
- 17 **Tutcu Şahin S**, Erhan Y, Aydede H. Double acute appendicitis in appendical duplication. *Ulus Travma Acil Cerrahi Derg* 2013; **19**: 83-85 [PMID: 23588988 DOI: 10.5505/tjtes.2013.80557]
- 18 **Marshall AP**, Issar NM, Blakely ML. Appendiceal duplication in children presenting as an appendiceal tumor and as recurrent intussusception. *J Pediatr Surg* 2013; **48**: e9-e12 [PMID: 23583164 DOI: 10.1016/j.jpedsurg.2013.01.036]
- 19 **Canbay E**, Akman E. Appendix perforation in appendix duplication in a man: a case report. *J Med Case Rep* 2011; **5**: 162 [PMID: 21513538 DOI: 10.1186/1752-1947-5-162]
- 20 **Sani R**, Harouna Y, Hama Y, Nouhou H, Faucheron JL. First case of double appendicitis complicating duplication of a vermiform appendix in an adult patient. *Colorectal Dis* 2010; **12**: 1162-1163 [PMID: 20070333 DOI: 10.1111/j.1463-1318.2010.02200.x]
- 21 **Geurts BA**, van Rijn AB, Koelma IA. [Acute appendicitis in a boy with an earlier appendectomy and a second appendix]. *Ned Tijdschr Geneesk* 2006; **150**: 2876-2879 [PMID: 17319221]
- 22 **Yanar H**, Ertekin C, Unal ES, Taviloglu K, Guloglu R, Mete O. The case of acute appendicitis and appendiceal duplication. *Acta Chir Belg* 2004; **104**: 736-738 [PMID: 15663287]
- 23 **Hennekinne S**, Pessaix P, Regenet N, Fauvet R, Tuech JJ, Arnaud JP. [Double appendicitis: a rare clinical form in appendix duplication]. *Presse Med* 2001; **30**: 23-24 [PMID: 11210582]
- 24 **Mazziotti MV**, Marley EF, Winthrop AL, Fitzgerald PG, Walton M, Langer JC. Histopathologic analysis of interval appendectomy specimens: support for the role of interval appendectomy. *J Pediatr Surg* 1997; **32**: 806-809 [PMID: 9200074]
- 25 **Konstantinov PI**, Titarenko IaA. [Duplication of the appendix in a child]. *Vestn Khir Im I I Grek* 1997; **156**: 109 [PMID: 9163180]
- 26 **Lin BC**, Chen RJ, Fang JF, Lo TH, Kuo TT. Duplication of the vermiform appendix. *Eur J Surg* 1996; **162**: 589-591 [PMID: 8874171]
- 27 **Khanna AK**. Appendix vermiformis duplex. *Postgrad Med J* 1983; **59**: 69-70 [PMID: 6866880]
- 28 **Cave AJ**. Appendix Vermiformis Duplex. *J Anat* 1936; **70**: 283-292 [PMID: 17104589]
- 29 **Wallbridge PH**. Double appendix. *Br J Surg* 1962; **50**: 346-347 [PMID: 13998581]
- 30 **Travis JR**, Weppner JL, Paugh JC. Duplex vermiform appendix: case report of a ruptured second appendix. *J Pediatr Surg* 2008; **43**: 1726-1728 [PMID: 18779015 DOI: 10.1016/j.jpedsurg.2008.04.023]
- 31 **Mesko TW**, Lugo R, Breitholtz T. Horseshoe anomaly of the appendix: a previously undescribed entity. *Surgery* 1989; **106**: 563-566 [PMID: 2772830]
- 32 **Tinckler LF**. Triple appendix vermiformis--a unique case. *Br J Surg* 1968; **55**: 79-81 [PMID: 5635427]
- 33 **Kabay S**, Yucel M, Yaylak F, Hacıoglu A, Algin MC, Olgun EG, Sahin L, Aydin T. Combined duplication of the colon and vermiform appendix in an adult patient. *World J Gastroenterol* 2008; **14**: 641-643 [PMID: 18203303]
- 34 **Akhtar J**, Ejaz T, Guiney EJ. Appendix vermiformis duplex - a lesson for the unwary. *Pediatr Surg Int* 1994; **9**: 429-30 [DOI: 10.1007/BF01686027]
- 35 **Maizels G**. Duplication of the vermiform appendix. *S Afr Med J* 1966; **40**: 1123-1125 [PMID: 5957812]
- 36 **Gilchrist BF**, Scriven R, Nguyen M, Nguyen V, Klotz D, Ramenofsky ML. Duplication of the vermiform appendix in gastroschisis. *J Am Coll Surg* 1999; **189**: 426 [PMID: 10509468]
- 37 **Scarff JE**, Harrold MW, Wylie JH. Duplication of the vermiform appendix: new variant of a rare anomaly. *South Med J* 1982; **75**: 860-862 [PMID: 7089658]

**P- Reviewer:** Haveman JW, Ince V, Karateke F, Tsuda M  
**S- Editor:** Ding Y **L- Editor:** Roemmele A **E- Editor:** Lu YJ



## Rare large homozygous *CFTR* gene deletion in an Iranian patient with cystic fibrosis

Shirin Farjadian, Mozghan Moghtaderi, Roberta Zuntini, Simona Ferrari

Shirin Farjadian, Department of Immunology, Allergy Research Center, Shiraz University of Medical Sciences, 71348-45794 Shiraz, Iran

Mozghan Moghtaderi, Allergy Research Center, Shiraz University of Medical Sciences, 71348-45794 Shiraz, Iran

Roberta Zuntini, Simona Ferrari, Unità Operativa di Genetica Medica, Dipartimento di Scienze Mediche e Chirurgiche Policlinico Sant'Orsola-Malpighi, 40138 Bologna, Italy

**Author contributions:** Farjadian S designed, organized, and carried out the molecular genetic studies and drafted the manuscript; Moghtaderi M collected the medical data on the patient and reviewed the manuscript; Zuntini R and Ferrari S carried out some molecular tests and reviewed the manuscript; all authors read and approved the final manuscript.

**Supported by** Shiraz University of Medical Sciences, Shiraz, Iran and Bologna University, Bologna, Italy

**Correspondence to:** Shirin Farjadian, PhD, Department of Immunology, Allergy Research Center, Shiraz University of Medical Sciences, Zand Avenue, 71348-45794 Shiraz, Iran. [farjadsh@sums.ac.ir](mailto:farjadsh@sums.ac.ir)

Telephone: +98-711-2351575 Fax: +98-711-2351575

Received: April 9, 2014 Revised: May 11, 2014

Accepted: June 10, 2014

Published online: August 16, 2014

a homozygous deletion spanning exons 4 to 10 of the *CFTR* gene. We predict an in-frame deletion removing 373 amino acids based on our sequencing results. Determining *CFTR* gene mutations in patients and their family members would be helpful to prevent the occurrence of new cases, especially in populations in which consanguinity is common.

© 2014 Baishideng Publishing Group Inc. All rights reserved.

**Key words:** Cystic fibrosis; Transmembrane conductance regulatory gene; Homozygous deletion

**Core tip:** Genetic analysis of the transmembrane conductance regulatory (*CFTR*) gene is helpful to characterize patients with cystic fibrosis, but sequencing and multiplex ligation-dependent probe amplification-based testing are only done to diagnose rare or unknown variants. Here we report a 16-year-old boy, the son of consanguineous healthy parents, who lacked both the normal and mutant forms of the  $\Delta F508$  alleles in initial molecular tests. Further analysis disclosed a rare large homozygous *CFTR* gene deletion in this patient.

### Abstract

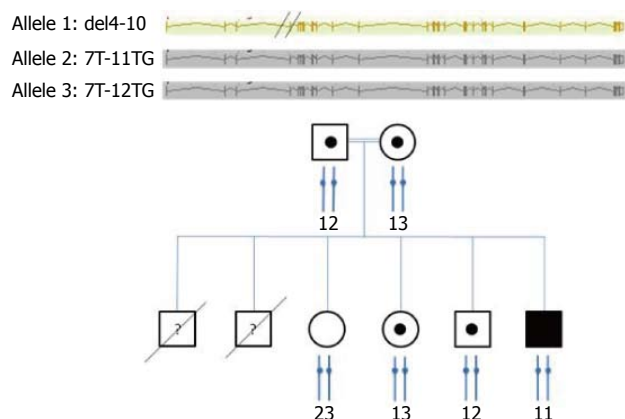
Cystic fibrosis, a common autosomal recessive genetic disorder among Caucasians, is caused by defects in the transmembrane conductance regulatory (*CFTR*) gene. The analysis of *CFTR* gene mutations is useful to better characterize the disease, and for preconceptional screening, prenatal and preimplantation genetic diagnosis. Here we report the results of a genetic analysis in a 16-year-old boy from southwestern Iran diagnosed as having cystic fibrosis in infancy based on gastrointestinal and pulmonary manifestations, with positive sweat chloride tests. He lacked both normal and mutant forms of the fragment corresponding to the  $\Delta F508$  allele in initial genetic studies. Multiplex ligation-dependent probe amplification-based testing revealed

Farjadian S, Moghtaderi M, Zuntini R, Ferrari S. Rare large homozygous *CFTR* gene deletion in an Iranian patient with cystic fibrosis. *World J Clin Cases* 2014; 2(8): 395-397 Available from: URL: <http://www.wjgnet.com/2307-8960/full/v2/i8/395.htm> DOI: <http://dx.doi.org/10.12998/wjcc.v2.i8.395>

### INTRODUCTION

Cystic fibrosis (CF), a common autosomal recessive genetic disorder among Caucasians, is caused by defects in the transmembrane conductance regulatory (*CFTR*) gene. This gene spans more than 250 kb on chromosome 7q31.2 and comprises 27 exons encoding a 170 kDa chloride channel expressed exclusively in secretory epithelial





**Figure 1** Pedigree of a family of a 16-year-old boy with cystic fibrosis, showing the three transmembrane conductance regulatory alleles transmitted to the sibs. Allele 1 carries the deletion of exons 4 to 10; alleles 2 and 3 are distinguishable by the different numbers of TG associated to the polypyrimidine tract in intron 8.

cells<sup>[1]</sup>. To date, more than 1969 sequence variations have been identified in the *CFTR* gene, including mutations that are involved in disease expression and polymorphisms which have no effect on the phenotype<sup>[2]</sup>. The rate of *CFTR* gene mutations varies greatly among different populations. Although the prevalence of CF in Iran is not known, current data suggest that the disease is not rare in this country. The most common mutation is  $\Delta F508$  with a frequency of 16% to 24% in different parts of Iran; these rates are much lower than in European countries<sup>[3]</sup>.

The clinical presentations of CF varies widely from atypical mild disease to the classical form characterized by multiorgan involvement. The highly variable presentation depends on specific mutations, gene penetrance, the presence of genetic modifiers and environmental factors<sup>[4]</sup>. The diagnosis of classical CF is straightforward and based on specific clinical features, family history and positive sweat chloride tests, whereas the diagnosis of nonclassical CF is often delayed because of its unusual presentation or the late onset of symptoms. Delays in the diagnosis usually lead to progressive disease and even irreversible multiorgan damage<sup>[5]</sup>. The analysis of *CFTR* gene mutations is useful to better characterize the disease, especially when the results of sweat chloride tests are uncertain or variable. DNA-based testing is also useful for preconceptional screening, prenatal diagnosis for couples with a family history of CF, and preimplantation genetic diagnosis for couples with known *CFTR* genetic mutations who hope to have a healthy child by *in vitro* fertilization<sup>[5,6]</sup>. These tests are usually performed with a panel of known *CFTR* mutations for the ethnic group of interest. Sequencing the *CFTR* gene and multiplex ligation-dependent probe amplification (MLPA)-based testing are only done to diagnose rare or unknown variants<sup>[4]</sup>.

## CASE REPORT

A 16-year-old boy from Southwestern Iran with chronic

productive cough and dyspnea was diagnosed as having CF in infancy based on typical findings of gastrointestinal and pulmonary manifestations with a positive sweat chloride test. He was the sixth child of healthy consanguineous parents and had two healthy older sisters and one healthy brother. The results of sweat chloride tests were normal for the parents and siblings, and none of them reported any symptoms or problems related with CF. Two of the patient's older brothers had died at the age of 6 mo; their medical history was unremarkable.

This patient had been hospitalized several times during infancy due to severe dehydration. He suffered from numerous recurrent pulmonary infections and greasy stools, which required frequent visits to his physician. Physical examination showed scattered bilateral coarse crackles, increased anteroposterior diameter of chest and digital clubbing.

At his most recent visit his bone age was estimated at about 12-year-old based on left-hand X-ray, and he also had symptoms compatible with delayed sexual maturation and delayed puberty. Laboratory parameters including blood cell count, fasting blood glucose, blood urea nitrogen, serum creatinine, calcium, phosphorus, erythrocyte sedimentation rate, C-reactive protein levels and liver function tests were normal at this visit, but his sweat chloride test results were higher than normal ( $> 100$  mEq/L). Chest X-ray revealed bilateral infiltration and bronchiectasis in both lung fields. Abdominal and pelvic ultrasound examination disclosed no abnormal findings. Because of his abnormal heart sounds, echocardiography was performed which showed mild pulmonary artery hypertension. The patient was advised to continue treatment with antibiotics, chest physiotherapy, pancreatic enzyme replacement and vitamin supplementation.

An initial genetic study was done with the Elucigene CF29 v.2 kit (Tepnel, Oxfordshire, United Kingdom). Our patient lacked of both the normal and mutant forms of the fragment corresponding to the  $\Delta F508$  allele, whereas all his first-degree relatives carried the normal allele. This test was repeated three times with new blood samples, and the results were consistent across tests. Genetic analysis was then performed with the Elucigene CF-EU2 v.1 kit (Gen-Probe Life Science Ltd., Manchester, United Kingdom), which is designed to identify 50 mutations. This kit is also able to identify the number of TG repeats associated to the polythymidine tract at the junction of intron 8 and exon 9, which affects the splicing efficiency of exon 9 and influences the gene transcription rate. This analysis showed the absence of PCR amplification products for all fragments mapping to exons 4-10, suggesting that he was homozygous for a deletion spanning exons 4 to 10 of the *CFTR* gene (*CFTR* del 4-10), as a result of first-degree consanguinity between his parents. This homozygous deletion was confirmed by MLPA and was detected in the heterozygous state in both parents (Figure 1), in one of the sisters and in his brother. The 40-kb del 4-10 CF mutation was previously reported in compound heterozygous patterns in two patients with CF: an 8-year-old French girl with the  $\Delta F508$ /

CF 40-kb del 4-10 genotype combination<sup>[7]</sup> and a 19-year-old Caucasian female with the c.1220del20/CF 40-kb del 4-10 genotype combination<sup>[8]</sup>. In contrast to the latter patient with a frameshift mutation in the *CFTR* gene because of a 40-kb deletion, in our patient we predict an in-frame deletion removing 373 amino acids based on our sequencing results.

In conclusion, although there is no evidence to prove the relationship between *CFTR* gene mutations and disease severity or response to therapy, determining *CFTR* gene mutations in patients and their family members would be helpful to prevent the occurrence of new cases, especially in populations in which consanguinity is common.

## ACKNOWLEDGEMENTS

The authors thank Professor Romeo G for coordinating this collaboration, the Institute of Advanced Studies, University of Bologna, Italy for providing accommodations for Dr. Farjadian S while she was in Bologna for the molecular analysis and Shashok K (Author AID in the Eastern Mediterranean) for improving the use of English in the manuscript.

## COMMENTS

### Case characteristics

A 16-year-old boy with chronic productive cough and dyspnea was diagnosed as having cystic fibrosis (CF) in infancy based on gastrointestinal and pulmonary manifestations with a positive sweat chloride test.

### Clinical diagnosis

Hospitalization during infancy due to severe dehydration and recurrent pulmonary infections and greasy stools.

### Differential diagnosis

Celiac disease, primary immunodeficiency disorders.

### Laboratory diagnosis

Positive sweat chloride test and lack of both normal and mutant forms of the fragment corresponding to the  $\Delta F508$  allele in molecular analysis.

### Imaging diagnosis

Left-hand X-ray: bone age about 12-year-old based on. Chest X-ray: bilateral infiltration and bronchiectasis in both lung fields. Echocardiography: mild pulmonary artery hypertension.

### Treatment

Antibiotics therapy, chest physiotherapy, pancreatic enzyme replacement and vitamin supplementation.

## Related reports

Homozygous 40-kb del 4-10 in cystic fibrosis transmembrane regulatory (*CFTR*) gene was detected in this patient by multiplex ligation-dependent probe amplification (MLPA).

## Experiences and lessons

Determining *CFTR* gene mutations in CF patients and their family members would be helpful to prevent the occurrence of new cases, especially in populations in which consanguinity is common.

## Term explanation

MLPA is a technique for detecting deletions or duplications of one or more parts of a gene.

## Peer review

The manuscript reports a patient with homozygous exon 4-10 *CFTR* gene deletion mutation. Overall, this manuscript is well written and suitable as a case-report.

## REFERENCES

- 1 **Tousson A**, Van Tine BA, Naren AP, Shaw GM, Schwiebert LM. Characterization of CFTR expression and chloride channel activity in human endothelia. *Am J Physiol* 1998; **275**: C1555-1564 [PMID: 9843717]
- 2 Cystic fibrosis mutation database. Available from: URL: <http://www.genet.sickkids.on.ca/cftr/StatisticsPage.html>
- 3 **Farjadian S**, Moghtaderi M, Kashef S, Alyasin S, Najib K, Saki F. Clinical and genetic features in patients with cystic fibrosis in southwestern Iran. *Iran J Pediatr* 2013; **23**: 212-215 [PMID:23724185]
- 4 **Cooper DN**, Krawczak M, Polychronakos C, Tyler-Smith C, Kehrer-Sawatzki H. Where genotype is not predictive of phenotype: towards an understanding of the molecular basis of reduced penetrance in human inherited disease. *Hum Genet* 2013; **132**: 1077-1130 [PMID: 23820649 DOI: 10.1007/s00439-013-1331-2]
- 5 **Karczeski B**, Cutting GR. Diagnosis of Cystic Fibrosis, CFTR-Related Disease and Screening. In: Bush A, Alton EFWF, Davies JC, Griesenbach U, Jaffe A. *Cystic Fibrosis in the 21st Century*. Basel: Karger, 2006: 69-76 [PMID: 20301540]
- 6 **Rechitsky S**, Verlinsky O, Kuliev A. PGD for cystic fibrosis patients and couples at risk of an additional genetic disorder combined with 24-chromosome aneuploidy testing. *Reprod Biomed Online* 2013; **26**: 420-430 [PMID: 23523379 DOI: 10.1016/j.rbmo.2013.01.006]
- 7 **Chevalier-Porst F**, Bonardot AM, Chazalotte JP, Mathieu M, Bozon D. 40 kilobase deletion (CF 40 kb del 4-10) removes exons 4 to 10 of the Cystic Fibrosis Transmembrane Conductance Regulator gene. *Hum Mutat* 1998; **Suppl 1**: S291-294 [PMID: 9452112]
- 8 **Hantash FM**, Rebuyon A, Peng M, Redman JB, Sun W, Strom CM. Apparent homozygosity of a novel frame shift mutation in the *CFTR* gene because of a large deletion. *J Mol Diagn* 2009; **11**: 253-256 [PMID: 19324987 DOI: 10.2353/jmoldx.2009.080117]

P- Reviewer: Bener A S- Editor: Ji FF L- Editor: A  
E- Editor: Lu YJ



## Gastric conduit perforation

Nilesh Patil, Arvind Kaushal, Amit Jain, Sundeep Singh Saluja, Pramod Kumar Mishra

Nilesh Patil, Arvind Kaushal, Amit Jain, Sundeep Singh Saluja, Pramod Kumar Mishra, Department of Gastrointestinal Surgery, Academic Block, GB Pant Hospital and Maulana Azad Medical College, New Delhi 110002, India

Author contributions: Patil N, Saluja SS and Mishra PK contributed equally to this paper; Patil N wrote the paper; Jain A and Kaushal A contributed to the management of the patient; Saluja S and Mishra PK managed the patient and revised the paper.

Correspondence to: Sundeep Singh Saluja, MCh, Associate Professor, Department of Gastrointestinal Surgery, 2<sup>nd</sup> floor, Academic Block, GB Pant Hospital and Maulana Azad Medical College, 2, Jawaharlal Nehru Marg, New Delhi 110002, India. [sundeepsaluja@yahoo.co.in](mailto:sundeepsaluja@yahoo.co.in)

Telephone: +91-971-8599259 Fax: +91-11-23239442

Received: January 11, 2014 Revised: February 8, 2014

Accepted: June 13, 2014

Published online: August 16, 2014

### Abstract

As patients with carcinoma of the esophagus live longer, complications associated with the use of a gastric conduit are increasing. Ulcers form in the gastric conduit in 6.6% to 19.4% of patients. There are a few reports of perforation of a gastric conduit in the English literature. Almost all of these were associated with serious complications. We report a patient who developed a tension pneumothorax consequent to spontaneous perforation of an ulcer in the gastric conduit 7 years after the index surgery in a patient with carcinoma of the gastroesophageal junction. He responded well to conservative management. Complications related to a gastric conduit can be because of multiple factors. Periodic endoscopic surveillance of gastric conduits should be considered as these are at a higher risk of ulcer formation than a normal stomach. Long term treatment with proton pump inhibitors may decrease complications. There are no guidelines for the treatment of a perforated gastric conduit ulcer and the management should be individualized.

**Key words:** Gastric conduit; Ulcer formation; Perforation; Carcinoma of the esophagus; Proton pump inhibitors

**Core tip:** We report a patient with a spontaneous perforation of an ulcer in the gastric conduit of a patient who had surgery for carcinoma of the gastroesophageal junction. He responded to conservative management with continuous decompression of the conduit with Ryle's tube aspiration, proton pump inhibitors and enteral nutrition through a feeding jejunostomy for 4 wk. Periodic endoscopic surveillance should be considered as gastric conduits are at a higher risk of ulcer formation than a normal stomach and management of a perforated gastric conduit ulcer should be individualized.

Patil N, Kaushal A, Jain A, Saluja SS, Mishra PK. Gastric conduit perforation. *World J Clin Cases* 2014; 2(8): 398-401 Available from: URL: <http://www.wjgnet.com/2307-8960/full/v2/i8/398.htm> DOI: <http://dx.doi.org/10.12998/wjcc.v2.i8.398>

### INTRODUCTION

The stomach is preferred as the conduit after esophageal resection. Complications following gastric conduits are being reported more often as patients with carcinoma of the esophagus are living longer after resection. The incidence of an ulcer occurring in a gastric conduit is reported to be between 6.6% and 19.4%<sup>[1,2]</sup>. Perforation of a gastric conduit ulcer, although rare, may be catastrophic. The ulceration in a gastric conduit is often due to tumor recurrence. However, it may be due to other causes too. We report a patient with spontaneous perforation of a gastric conduit ulcer into the right pleural cavity that was successfully managed conservatively.

### CASE REPORT

A 50-year-old man underwent a transhiatal esophagec-

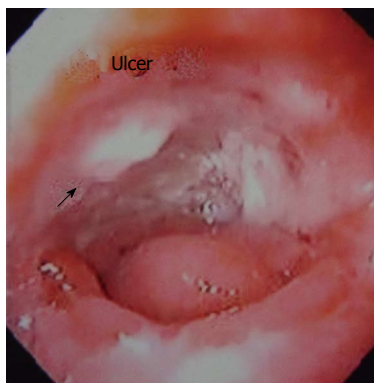


Figure 1 Endoscopic view of gastric conduit ulcer.

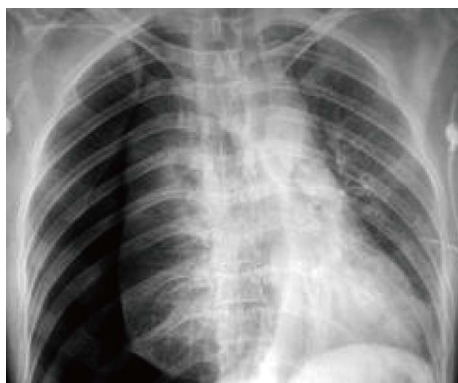

Figure 2 Chest X-ray showing right sided tension pneumothorax with mediastinal shift.

tomy and stapled cervical esophagogastric anastomosis without pyloromyotomy for carcinoma of the gastroesophageal junction in 2005. He had a minor anastomotic leak in the immediate postoperative period which was managed conservatively. The histology revealed a well differentiated adenocarcinoma of the gastroesophageal junction, infiltrating the adventitia. The resected margins were free of tumor and metastasis was seen in one of six lymph nodes. He did not receive any adjuvant treatment. In January 2006 he presented with dysphagia. A barium swallow revealed a stricture at the anastomotic site and an endoscopic biopsy did not show any local recurrence. The stricture was dilated with Savary-Gilliard dilators (Wilson Cook) up to 14 mm in two sessions and the patient became euphagic. He remained asymptomatic until June 2012 when he started complaining of pain in the neck and epigastric region. Endoscopy showed a large ulcer in the gastric conduit just below the anastomotic site. A biopsy from the ulcer did not reveal any malignancy (Figure 1). He was started on proton pump inhibitors (PPI) and *Helicobacter pylori* (*H. pylori*) eradication therapy. In July 2012, he had sudden onset of difficulty breathing and pain in the right side of the chest. At the time of presentation to our hospital the patient was hemodynamically stable. His hemoglobin was 13 g/dL, total leukocyte count of 16000 per cumm, and the blood urea and serum creatinine was 45 mg/dL and 1.2

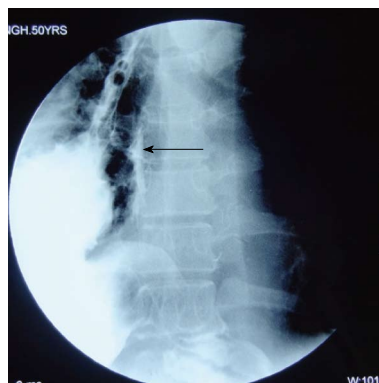

Figure 3 Oral Gastrografin study showing leak of contrast from the medial aspect of upper part of the conduit (arrow).

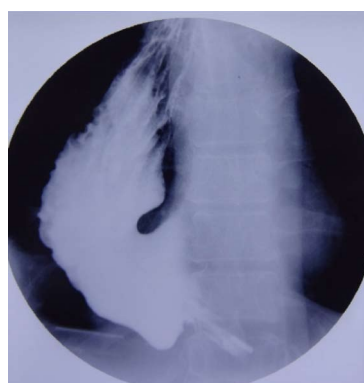


Figure 4 Repeat study after 4 wk shows no evidence of contrast leak.

mg/dL, respectively. The chest X-ray showed a tension pneumothorax on the right side with mediastinal shift to the left (Figure 2). The week before the patient had taken non-steroidal anti-inflammatory drugs for pain. A liter of purulent fluid with gastric contents was drained from the right hemithorax after insertion of an intercostal drainage (ICD) tube and his respiratory distress subsided. An oral Gastrografin study revealed a leak from the proximal part of the gastric conduit into the right hemithorax (Figure 3). A feeding jejunostomy was done because of the poor nutritional status of the patient. He was managed conservatively with continuous decompression of the gastric conduit using a Ryle's tube (Romsins), antibiotics, PPIs, enteral nutrition through the feeding jejunostomy, serial chest X-rays and monitoring the ICD output. A follow up oral Gastrografin study at 4 wk revealed no evidence of any contrast leak from the gastric conduit (Figure 4). He was then allowed oral nutrition which he tolerated. There was no change in the nature and amount of the ICD fluid output. The ICD tube was subsequently removed and chest X-ray did not show any pleural effusion or pneumothorax. He is doing well with no symptoms at the 6 mo follow up. We did not manage this patient with insertion of an endoscopic stent as the leak was from the proximal part of the gastric conduit and the stent would have impinged on the cricopharynx. Stent migration was also likely because of the large diameter of the gastric



conduit.

## DISCUSSION

Increasing use of the stomach as a conduit has led to increasing reports of peptic ulcers in the conduit. In a prospective study of annual endoscopic evaluations in 114 patients who underwent gastric tube reconstruction after esophagectomy, 47% of patients had secondary gastric tube diseases, including gastritis [35.1% (40/114)], benign gastric tumors [10.5% (12/114)], gastric ulcers [6.1% (7/114)] and gastric adenocarcinoma [3.5% (4/114)]<sup>[1]</sup>. Gastric tubes are reported to be at a higher risk of developing an ulcer than the normal stomach. The cause of a gastric conduit ulcer remains controversial. Several mechanisms have been postulated for the formation of gastric conduit ulcers, including normalization of the intraluminal pH profile over time, *H. pylori* infection (especially in patients with a history of peptic ulcer before surgery), delayed gastric emptying as a result of vagal denervation, bile reflux, ischemia due to mobilization of the gastric conduit, radiation, use of non-absorbable sutures and intake of non-steroidal anti-inflammatory drugs (NSAIDs), aspirin or steroids<sup>[3]</sup>. Most ulcers develop within 20 cm of the esophagogastric anastomosis, as in our patient, because the microcirculation is most disturbed in the upper part of the conduit<sup>[2]</sup>. The time for development of these ulcers has varied widely, from one month to as long as 150 mo.

Peptic ulcer of the gastric conduit can present with anemia, retrosternal or epigastric pain, fullness after eating or dysphagia<sup>[3]</sup>. It could be asymptomatic and vagotomy may be one of the reasons for the absence of pain<sup>[4]</sup>. A gastric conduit ulcer often causes serious complications, such as bleeding and perforation<sup>[5]</sup>. It may penetrate into any adjacent organ (left ventricular or atrial wall, thoracic aorta and other major vessels) or cavity, including the right pleural cavity, bronchi and pericardial cavity<sup>[5]</sup>.

Only a few cases of gastric conduit perforation have been reported in the English literature and almost all of them had serious complications. More than half the patients were treated conservatively and all of them died<sup>[5]</sup>. All patients whose conduit ulcer perforated into the tracheobronchial tree or cardiovascular system died. Only patients with perforation into the sternum and thoracic cavity survived. Patients who had a gastric conduit perforation in the thoracic cavity underwent either primary closure of the perforated ulcer or resection of the ulcer followed by an interrupted closure buttressed with a pleural patch. Both these procedures are associated with high leak rates and mortality. In our case, the patient responded to conservative treatment, although we cannot recommend this for all cases.

Endoscopic surveillance should be done at least once every 6 mo as gastric conduits are at a higher risk of ulcer formation than a normal stomach and many such ulcers tend to be asymptomatic. Successful healing of a gastric

ulcer by PPIs has been reported<sup>[1]</sup>. This could prevent potentially lethal complications associated with it.

While complications in the gastric conduit are being reported increasingly, there are no guidelines for the treatment of a perforated gastric conduit ulcer. These patients are usually sick and may not tolerate major surgery. The conservative management protocol cited above resulted in a good outcome in our case, showing that surgery is not always required and the management should be individualized. Avoidance of analgesics and periodic surveillance of the conduit may prevent complications.

## COMMENTS

### Case characteristics

The patient presented with sudden onset chest pain and difficulty breathing.

### Clinical diagnosis

On clinical examination, decreased breath sounds in the right hemithorax with hyper resonant note on percussion.

### Differential diagnosis

Differential diagnoses were pneumothorax secondary to spontaneous rupture of pulmonary bullae, acute myocardial infarction and recurrence of disease.

### Laboratory diagnosis

Laboratory investigations were inconclusive.

### Imaging diagnosis

On imaging, chest X-ray revealed right sided tension pneumothorax with mediastinal shift to left, gastric contents on insertion of intercostal drainage tube and oral Gastrografin study showed leak from the gastric conduit.

### Pathological diagnosis

Previous endoscopy showed a large ulcer in the proximal part of gastric conduit, biopsy was consistent with peptic ulcer and also ruled out any recurrence.

### Treatment

He was treated conservatively with continuous decompression of the conduit through Ryle's tube aspiration, proton pump inhibitors and enteral nutrition through feeding jejunostomy for 4 wk.

### Experiences and lessons

The possibility that ulceration in the gastric conduit may be due to causes other than tumor recurrence deserves greater recognition. Periodic endoscopic surveillance should be considered as gastric conduits are at a higher risk of ulcer formation than a normal stomach.

### Peer review

This is a rare morbid complication of gastric conduit which responded to conservative management. However, a firm conclusion cannot be drawn on the management guidelines of perforated gastric conduit ulcer and treatment should be individualized.

## REFERENCES

- 1 **Motoyama S**, Saito R, Kitamura M, Suzuki H, Nakamura M, Okuyama M, Imano H, Inoue Y, Ogawa J. Prospective endoscopic follow-up results of reconstructed gastric tube. *Hepatogastroenterology* 2003; **50**: 666-669 [PMID: 12828056]
- 2 **Suzuki H**, Saito R, Sasaki S, Okuyama M. Analysis of the cases with peptic ulcer of gastric tube after esophageal replacement for esophageal cancer. *Rinsho* 1999; **54**: 1075-1079
- 3 **Piessen G**, Lamblin A, Triboulet JP, Mariette C. Peptic ulcer of the gastric tube after esophagectomy for cancer: clinical implications. *Dis Esophagus* 2007; **20**: 542-545 [PMID: 17958733 DOI: 10.1111/j.1442-2050.2007.00706.x]
- 4 **Texter EC**. Ulcer pain mechanisms. The clinical features of active peptic ulcer disease and implications for therapy. *Scand J Gastroenterol Suppl* 1987; **134**: 1-20 [PMID: 3310199 DOI: 10.3109/00365528709090135]
- 5 **Ubukata H**, Nakachi T, Tabuchi T, Nagata H, Takemura

A, Shimazaki J, Konishi S, Tabuchi T. Gastric tube perforation after esophagectomy for esophageal cancer. *Surg*

*Today* 2011; **41**: 612-619 [PMID: 21533931 DOI: 10.1007/s00595-010-4476-9]

**P- Reviewer:** Abd Ellatif ME, Boyacioglu AS, Gonzalez AM, Marangoni G **S- Editor:** Ma YJ **L- Editor:** Roemmele A  
**E- Editor:** Lu YJ



# World Journal of *Clinical Cases*

*World J Clin Cases* 2014 September 16; 2(9): 402-487





## Contents

Monthly Volume 2 Number 9 September 16, 2014

- |                                  |     |   |
|----------------------------------|-----|---|
| <b>EDITORIAL</b>                 | 402 | Interspinous posterior devices: What is the real surgical indication?<br><i>Landi A</i>   |
| <b>REVIEW</b>                    | 409 | Review of tumoral calcinosis: A rare clinico-pathological entity<br><i>Fathi I, Sakr M</i>  |
| <b>MINIREVIEWS</b>               | 415 | Subclinical cardiovascular disease in type 2 diabetes mellitus: To screen or not to screen<br><i>Chillarón JJ, Flores-Le Roux JA, Benaiges D, Pedro-Botet J</i>                                 |
|                                  | 422 | Extraskelatal symptoms and comorbidities of diffuse idiopathic skeletal hyperostosis<br><i>Terzi R</i>  |
|                                  | 426 | Clinical usefulness and current problems of pancreatic duct stenting for preventing post-ERCP pancreatitis<br><i>Sakai Y, Tsuyuguchi T, Yokosuka O</i>  |
| <b>THERAPEUTICS<br/>ADVANCES</b> | 432 | Targeting EGFR and sonic hedgehog pathways for locally advanced eyelid and periocular carcinomas<br><i>Yin VT, Merritt H, Esmali B</i>  |
| <b>ORIGINAL ARTICLE</b>          | 439 | To explore and develop a model to maintain and build upon a dental clinic open for all in developing regions, with a primary focus on India<br><i>Sugandhi A, Mangal B, Mishra AK, Sethia B</i> |
| <b>RETROSPECTIVE STUDY</b>       | 448 | Upper esophageal sphincter abnormalities are strongly predictive of treatment response in patients with achalasia<br><i>Mathews SC, Ciarleglio M, Chavez YH, Clarke JO, Stein E, Roland BC</i>  |
| <b>CASE REPORT</b>               | 455 | Incidental findings of pericardial calcification<br><i>Nguyen T, Phillips C, Movahed A</i>  |
|                                  | 459 | Tattooing: A potential novel risk factor for iliopsoas abscess<br><i>Gulati S, Jain A, Sattari M</i>  |





- 463 Unusual presentation of glomus tympanicum tumour: New bone formation in the middle ear  
*Kumar G, Andreou Z, Virk JS, Owa A*
- 466 Coronary artery bypass graft surgery in a patient with ureterosigmoidostomy  
*Haberal I, Ozsoy D, Sipahi E, Mert M*
- 469 Pneumatosis cystoides intestinalis associated with toxic epidermal necrolysis: A case report  
*Yao SY, Seo R, Nagano T, Yamazaki K*
- 474 Champagne bottle neck sign in a patient with Moyamoya syndrome  
*Shimogawa T, Morioka T, Sayama T, Hamamura T, Yasuda C, Arakawa S*
- 478 Splenic lymphoma with massive splenomegaly: Case report with review of literature  
*Ingle SB, Ingle CRH*
- 482 Cranioplasty with custom made alloplastic prosthetic implant: A case report  
*Gupta L, Aparna IN, Balakrishnan D, Deenadayalan L, Hegde P, Agarwal P*

## Contents

*World Journal of Clinical Cases*  
Volume 2 Number 9 September 16, 2014

**APPENDIX** I-V Instructions to authors

**ABOUT COVER** Editorial Board Member of *World Journal of Clinical Cases*, Assad Movahed, MD, FACC, FACP, Professor of Medicine, Radiology and Cardiovascular Sciences, Director of Nuclear Cardiology, Department of Cardiovascular Sciences, East Carolina University Brody School of Medicine, East Carolina Heart Institute, 115 Heart Drive, Greenville, NC 27858-4354, United States

**AIM AND SCOPE** *World Journal of Clinical Cases* (*World J Clin Cases*, *WJCC*, online ISSN 2307-8960, DOI: 10.12998) is a peer-reviewed open access academic journal that aims to guide clinical practice and improve diagnostic and therapeutic skills of clinicians.

The primary task of *WJCC* is to rapidly publish high-quality Autobiography, Case Report, Clinical Case Conference (Clinicopathological Conference), Clinical Management, Diagnostic Advances, Editorial, Field of Vision, Frontier, Medical Ethics, Original Articles, Clinical Practice, Meta-Analysis, Minireviews, Review, Therapeutics Advances, and Topic Highlight, in the fields of allergy, anesthesiology, cardiac medicine, clinical genetics, clinical neurology, critical care, dentistry, dermatology, emergency medicine, endocrinology, family medicine, gastroenterology and hepatology, geriatrics and gerontology, hematology, immunology, infectious diseases, internal medicine, obstetrics and gynecology, oncology, ophthalmology, orthopedics, otolaryngology, pathology, pediatrics, peripheral vascular disease, psychiatry, radiology, rehabilitation, respiratory medicine, rheumatology, surgery, toxicology, transplantation, and urology and nephrology.

**INDEXING/ABSTRACTING** *World Journal of Clinical Cases* is now indexed in PubMed Central, PubMed, Digital Object Identifier.

**FLYLEAF** I-V Editorial Board

## EDITORS FOR THIS ISSUE

Responsible Assistant Editor: *Xiang Li*  
Responsible Electronic Editor: *Ya-Jing Liu*  
Proofing Editor-in-Chief: *Lian-Sheng Ma*

Responsible Science Editor: *Fang-Fang Ji*  
Proofing Editorial Office Director: *Jin-Lei Wang*

**NAME OF JOURNAL**  
*World Journal of Clinical Cases*

**ISSN**  
ISSN 2307-8960 (online)

**LAUNCH DATE**  
April 16, 2013

**FREQUENCY**  
Monthly

**EDITORS-IN-CHIEF**  
**Giuseppe Di Lorenzo, MD, PhD, Professor**, Genitourinary Cancer Section and Rare-Cancer Center, University Federico II of Napoli, Via Sergio Pansini, 5 Ed. 1, 80131, Naples, Italy

**Jan Jacques Michiels, MD, PhD, Professor**, Primary Care, Medical Diagnostic Center Rijnmond Rotterdam, Bloodcoagulation, Internal and Vascular Medicine, Erasmus University Medical Center, Rotterdam, Goodheart Institute and Foundation, Erasmus Tower, Veenmos 13, 3069 AT, Erasmus City, Rotterdam, The Netherlands

**Sandro Vento, MD**, Department of Internal Medicine, University of Botswana, Private Bag 00713, Gaborone,

Botswana

**Shuhei Yoshida, MD, PhD**, Division of Gastroenterology, Beth Israel Deaconess Medical Center, Dana 509, Harvard Medical School, 330 Brookline Ave, Boston, MA 02215, United States

**EDITORIAL OFFICE**  
Jin-Lei Wang, Director  
Xiu-Xia Song, Vice Director  
*World Journal of Clinical Cases*  
Room 903, Building D, Ocean International Center, No. 62 Dongsihuan Zhonglu, Chaoyang District, Beijing 100025, China  
Telephone: +86-10-85381891  
Fax: +86-10-85381893  
E-mail: [editorialoffice@wjgnet.com](mailto:editorialoffice@wjgnet.com)  
Help Desk: <http://www.wjgnet.com/csp/helpdesk.aspx>  
<http://www.wjgnet.com>

**PUBLISHER**  
Baishideng Publishing Group Inc  
8226 Regency Drive,  
Pleasanton, CA 94588, USA  
Telephone: +1-925-223-8242  
Fax: +1-925-223-8243  
E-mail: [bpgoffice@wjgnet.com](mailto:bpgoffice@wjgnet.com)  
Help Desk: <http://www.wjgnet.com/csp/helpdesk.aspx>

<http://www.wjgnet.com>

**PUBLICATION DATE**  
September 16, 2014

**COPYRIGHT**  
© 2014 Baishideng Publishing Group Inc. Articles published by this Open Access journal are distributed under the terms of the Creative Commons Attribution Non-commercial License, which permits use, distribution, and reproduction in any medium, provided the original work is properly cited, the use is non commercial and is otherwise in compliance with the license.

**SPECIAL STATEMENT**  
All articles published in journals owned by the Baishideng Publishing Group (BPG) represent the views and opinions of their authors, and not the views, opinions or policies of the BPG, except where otherwise explicitly indicated.

**INSTRUCTIONS TO AUTHORS**  
Full instructions are available online at [http://www.wjgnet.com/2307-8960/g\\_info\\_20100722180909.htm](http://www.wjgnet.com/2307-8960/g_info_20100722180909.htm)

**ONLINE SUBMISSION**  
<http://www.wjgnet.com/csp/>

## Interspinous posterior devices: What is the real surgical indication?

Alessandro Landi

Alessandro Landi, Department of Neurology and Psychiatry, Division of Neurosurgery, University of Rome Sapienza, 00181 Rome, Italy

Author contributions: Landi A solely contributed to this paper.  
Correspondence to: Alessandro Landi, MD, PhD, Department of Neurology and Psychiatry, Division of Neurosurgery, University of Rome Sapienza, Viale del Policlinico 155, 00181 Rome, Italy. [dott.alessandro.landi@gmail.com](mailto:dott.alessandro.landi@gmail.com)

Telephone: +39-06-49979105 Fax: +39-06-49979105

Received: January 10, 2014 Revised: June 17, 2014

Accepted: July 12, 2014

Published online: September 16, 2014

### Abstract

Interspinous posterior device (IPD) is a term used to identify a relatively recent group of implants used to treat lumbar spinal degenerative disease. This kind of device is classified as part of the group of the dynamic stabilization systems of the spine. The concept of dynamic stabilization has been replaced by that of dynamic neutralization of hypermobility, with the intention of clarifying that the primary aim of this kind of system is not the preservation of the movement, but the dynamic neutralization of the segmental hypermobility which is at the root of the pathological condition. The indications for the implantation of an IPD are spinal stenosis and neurogenic claudication, assuming that its function is the enlargement of the neural foramen and the decompression of the roots forming the cauda equina in the central part of the vertebral canal. In the last 10 years, use of these implants has been very common but to date, no long-term clinical follow-up regarding clinical and radiological aspects are available. The high rate of reoperation, recurrence of symptoms and progression of degenerative changes is evident in the literature. If these devices are effectively a miracle cure for lumbar spinal stenosis, why do the utilization and implantation of IPD remain extremely controversial and should they be investigated further? Excluding the

problems related to the high cost of the device, the main problem remains the pathological substrate on which the device is explicit in its action: the degenerative pathology of the spine.

© 2014 Baishideng Publishing Group Inc. All rights reserved.

**Key words:** Interspinous posterior device; Interspinous fusion device; Interspinous distraction; Motion preservation surgery; Spine surgery; Minimally invasive surgery

**Core tip:** If interspinous posterior devices are effectively a miracle cure for lumbar spinal stenosis, why does their use and implantation remain extremely controversial and should they be investigated further? The aim of this editorial is to analyze and underline why these devices have poor outcomes, focusing on a biomechanical point of view, trying to define indications and limits. Is important to underline that these implants must not become a trend but only a weapon in the surgeon's hands and, as with every weapon, is extremely dangerous in the wrong hands. So the spinal surgeon is the only one who can decide when to use it and must know the effects of this weapon in detail to use it correctly with no damage for the patient.

Landi A. Interspinous posterior devices: What is the real surgical indication? *World J Clin Cases* 2014; 2(9): 402-408 Available from: URL: <http://www.wjgnet.com/2307-8960/full/v2/i9/402.htm> DOI: <http://dx.doi.org/10.12998/wjcc.v2.i9.402>

### INTRODUCTION

Interspinous posterior device (IPD) is a term used to identify a relatively recent group of implants used to treat lumbar spinal degenerative disease. This kind of device is classified as part of the group of the dynamic

stabilization systems of the spine. The concept of dynamic stabilization has been replaced by that of dynamic neutralization of hypermobility, with the intention of clarifying that the primary aim of this kind of system is not the preservation of the movement, but the dynamic neutralization of the segmental hypermobility which is at the root of the pathological condition<sup>[1-9]</sup>.

The indications for the implantation of an IPD are spinal stenosis and neurogenic claudication, assuming that its function is the enlargement of the neural foramen and the decompression of the roots forming the cauda equina in the central part of the vertebral canal.

IPDs have evolved, being classified into not restricted and restricted, based on the presence or the absence of a dynamic control of movements only in extension or flexion and extension respectively<sup>[10-27]</sup>.

A further evolution has brought the development of the interspinous fusion device (IFD), another group of implants, whose aim is interspinous bone fusion. The aim of these devices is not the dynamic neutralization of the hypermovement, but bone fusion with a complete block of the metameric movement. In light of this, in my opinion, IFDs cannot be classified as movement dynamic control systems because their aim is the osseous fusion of the segment, so are completely different from IPD<sup>[16-21]</sup>.

In the last 10 years, use of these implants has been very common but to date, no long-term clinical follow-up are available regarding clinical and radiological aspects. The high rate of reoperation, recurrence of symptoms and progression of degenerative changes is evident in the literature. But the real question is this: If these devices are effectively a miracle cure for lumbar spinal stenosis, why does the utilization and implantation of IPD remain extremely controversial and should they be investigated further? Excluding the problems related to the high cost of the device, the main problem remains the pathological substrate on which the device is explicit in its action: the degenerative pathology of the spine.

## BIOMECHANICAL CONSIDERATIONS

If we consider that IPD can be implanted in stenosis of a mild and moderate degree in central or foraminal stenosis, or in low grade spondylolisthesis without spondylolysis (with poor or at least controversial results), we take for granted that the degenerative lumbar cascade, as described by Kirkaldy-Willis, is in the active phase<sup>[22-27]</sup>.

Degenerative lumbar spondylosis in the active phase as a first step has the damage of the intervertebral disc, whose degree of degeneration is related to the entity of the damage and the persistency of the damage itself in time<sup>[22-27]</sup>.

Normally, the biomechanical behavior of the lumbar spine is subject to the rule of spine loading. According to this rule, the axial load of the body is discharged and consequently neutralized on the intervertebral disc and the posterior structures (articulations, ligaments and

muscles) in proportions of 80% and 20% respectively<sup>[27]</sup>.

Any disc degeneration transfers the axial load to the posterior elements of the spine, determining an inversion in the distribution of the axial load related to the loss of viscoelastic and shock absorber properties of the disc itself. This condition promotes the insurgence of a functional overload of the facet joints, determining a greater mechanical stress than the physiological one, with consequent hyperlaxity of the facet joints, reduced competence of the articular capsule and hypermobility of the lumbar segment<sup>[22-27]</sup>.

The hypermobility stimulates the inflammatory reaction in the adjacent tissues, activating chemokines (fractalkine in particular) in the ligamentum flavum, promoting chemotaxis in the ligamentum itself. The inflammatory cells cause extracellular matrix degradation of the ligamentum, determining loss of elasticity and hypertrophy. The role of fractalkine is well documented in the development of numerous inflammatory diseases (rheumatoid arthritis, dermatitis, *etc.*) and in ligaments and joints involved in inflammatory processes caused by instability (*e.g.*, joint capsules, ligaments and synovium). The inflammatory process involves these tissues so the fractalkine overexpression is activated, thus causing the recruitment of mononuclear cells within the LF, feeding the inflammation and causing vascular injury and angiogenesis<sup>[20]</sup>. Moreover, the increase in mononuclear activity causes a proliferation of fibroblasts (for overexpression of TGF beta mRNA resulting in increased collagen fibers) and inflammatory cells in LF. This inflammatory cell activity in the LF causes rupture of the extracellular matrix (for activation of metalloproteinase MMP2) due to the elastin degradation, resulting in loss of elasticity of the ligament and subsequent hypertrophy<sup>[22-27]</sup>.

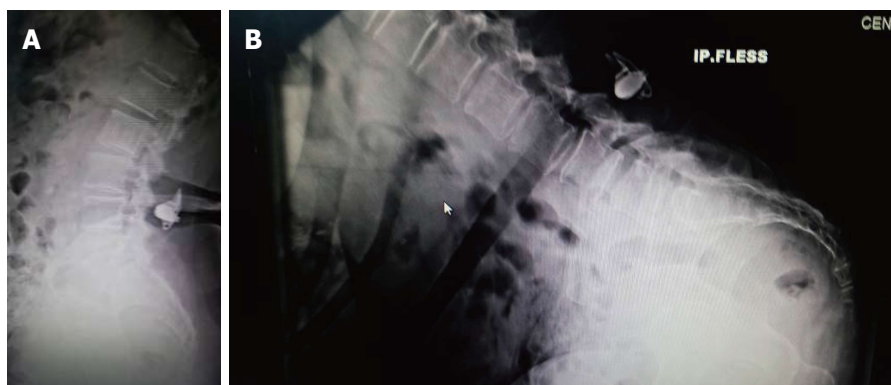The collapse of the intervertebral disc causes ligamentum flavum redundancy and its prominence in the vertebral canal reduces the diameter of the canal itself, determining spinal stenosis.

Only in this phase, the articular hypertrophy generates foraminal stenosis, the collapse of the disc generates ligamentous stenosis and the stenosis becomes symptomatic, but the main pathological substrate remains the hypermobility<sup>[22-27]</sup>. The treatment of a hard or soft stenosis has to be strictly linked to the concept of vertebral instability as a basic pathological condition. Relating to this concept, the commercialized IPDs have many biomechanical weaknesses that, in my opinion, should make their use extremely rare if not contraindicated.

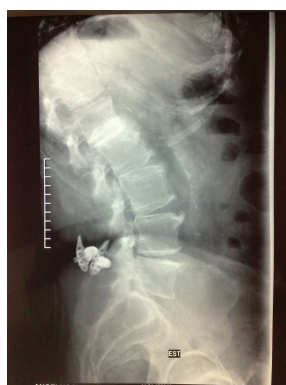## MECHANICAL PROPERTIES OF IPD

Non-restricted IPD is a heterogeneous and very populous group of implants (X-STOP, Aperius, Bacjac, Ellipse *etc.*). When implanted, their main aim is the interspinous posterior distraction to open the intervertebral foramina. Their primary effect is the decompression of nerve roots in their passage through the foramina. From a biomechanical point of view, the implant of this device has





**Figure 1 Dynamic X-ray.** A: Patient treated for L3-L4 disc herniation (without instability at the dynamic X-rays) with an interspinous posterior device (IPD) implant. The Dynamic X-ray in extension showed a metameric instability at L3-L4 developed 1 year after an IPD implantation; B: Dynamic X-ray in flexion that showed an increase in L3-L4 slipping, developing a 1° grade spondylolisthesis, due to the IPD implantation. The patient underwent revision surgery with removal of the IPD, decompressive laminectomy and L3-L4 stabilization with screws and rods.



**Figure 2 Dislocation of the L3-L4 interspinous posterior device in a patient with double level implant.** The patient underwent revision surgery with removal of both interspinous posterior devices followed by decompression and stabilization with screws and rods.

consequences on the involved and adjacent segments: (1) The axial load is shifted anteriorly on a degenerated intervertebral disc in which degeneration promotes the lumbar stenosis. The anterior load statically and dynamically over-solicits a degenerated disc, which has partially lost its features of shock absorber and elastic resistance against movements, promoting a faster degeneration of the disc; and (2) The distraction needed to open the intervertebral foramina causes an alteration of the lumbar spine sagittal balance<sup>[28-42]</sup>.

Sagittal balance is the axial equilibrium that the whole spine has towards the outside world; its integrity provides elastic properties to the spine and tolerance to loads. Sagittal balance is based mainly on an adequate equilibrium of the physiological curvatures of the spine so that they can transfer the axial load to the floor, passing through the hips and the heads of the femora. The load line of the axial load is a vertical vector perpendicular to the floor passing through the external acoustic meatus, the midpoint of the endplate of L5 and the head of the femur. This vector has to always be posterior to the line connecting the two heads of the femora: to achieve this aim, the spine curvatures have to be maintained physiologically as much as possible. In particular, the preservation of physiological lumbar lordosis is fundamental<sup>[36-42]</sup>.

The purpose of these devices is their implant between the spinous processes and their distraction; this move-

ment of distraction transfers the axial load in the anterior compartment on a degenerated disc and alters the biomechanics of the whole spine, with a negative impact on the sagittal balance. This action has consequences on the spine, determining postural alterations, rotations of the spino-pelvic alignment and alterations in the thoracic and cervical curvatures, trying to compensate the alteration of the sagittal balance but actually accelerating the progression of the spinal degeneration. These patients are in a condition of spinal imbalance<sup>[36-42]</sup>.

Initially, patients can have an improvement of their symptoms due to the foraminal decompression but long-term the alteration of the spinal biomechanics can only accelerate the degenerative process, with involvement of the treated and adjacent segments (Figure 1).

Furthermore, the overload applied to the spinous processes can cause a fracture of the processes themselves or lacerations of the posterior longitudinal ligament, causing the mobilization of the device (Figure 2)<sup>[36-49]</sup>.

The restricted IPDs (such as Wallis, Diam, Intraspine, *etc.*) have the presumed function of neutralizing the movements of flexion and extension at excessive degrees. These implants have the distraction of the spinous processes to widen the intervertebral foramina as a fundamental step, altering the biomechanics of the lumbar spine and determining sagittal imbalance, with the same mechanism as the non restricted IPD. Although these devices can control the excessive degrees of movements in flexion and extension, they cause a non physiological alteration in the movements of the spinal motor unit, with the same consequences described before. Furthermore, the segmental instability is not limited to the simple movements of flexion and extension, but also the movements of lateral bending and axial rotation, often associated with the movements of flexion and extension while the spine executes complex movements.

An interspinous device cannot control the movements of axial rotation and lateral bending, highly solicited after the implant of the device, accelerating and fastening the degenerative process.

IPDs are defined as movement preserving devices, but they are not explicit in this action for many reasons: (1) Their implantation puts the lumbar spine in a kyphotic posture so that it cannot move in a physiological

way. In light of this, the movement cannot be intended as preserved; (2) The movement of the spinal motor unit depends greatly on the articular masses, the inter- and supraspinous ligament and the muscles of the posterior tension band, and all the components of the spinal motor unit tend to degeneration; for these reasons, all IPDs are not capable of controlling the movements in all three directions of the space and substituting all the components of the motor unit, so they cannot be defined as dynamic stabilization<sup>[28-35,43-46,50]</sup>; and (3) The materials and biomechanical concepts of construction of these devices are not fully respectful of the biological characteristics of human tissues<sup>[28-35,43-46,50-63]</sup>.

Different considerations have to be made for interspinous fusion devices (IFD) (Aspen, Axle, *etc*). Described in the past, this technique has been brought to the fore in the last few years with the development of new spinous-anchoring devices whose aim is an interspinous bone fusion.

The main goal of IPD is motion preservation, while IFDs have a different root concept: if the substrate of lumbar stenosis is the hypermotion, the only way to stop the degeneration is to block it; this goal is achieved through the bone fusion. So IFD's aim is not motion preservation but bone fusion and the immobilization of the metamere. These devices have a double function, related to their possible association with TLIF interbody fusion<sup>[38-42]</sup>.

### Stand-alone

Spinous process fusion of a spinal motor unit occurs after placement of the device in distraction or in neutral position. If the device is implanted in distraction, the biomechanical alteration persists because the axial load is altered, but the pathological segment is stabilized by the osseous fusion. The degenerative process can progress towards the adjacent segments with the development of an adjacent segment disease.

### TLIF interbody fusion

In my opinion, this is the best use for IFD. This surgery is recommended in cases of monolateral radiculopathy with foraminal stenosis due to facet hypertrophy. The surgical procedure includes artrectomy to perform a TLIF and complete decompression of the foramen and the nerve root, associated with the implant of a device in neutral position (not in distraction)<sup>[38-42]</sup>.

This technique offers several advantages: (1) The execution of a TLIF allows performing a monolateral decompression and the insertion of an anterior intersomatic cage. The cage, in relationship with its width, can restore the physiological lumbar lordosis and leave the sagittal balance of the lumbar spine unaltered; (2) The insertion of the cage in the TLIF technique allows a higher fusion rate than the one obtained in a PLIF technique, in relationship with the most anterior position of the cage and of the width of the cage itself; (3) The insertion of the device in neutral position stabilizes the segment in its

physiological position without distracting the segment; and (4) This procedure allows performing a circumferential fusion with an exclusively posterior and monolateral approach, preserving muscular insertions and the posterior tension band.

Recently, these devices have gone through an evolution, with the creation of expansion devices and cardanic compression devices that allow the distraction and the compression of the segment during the surgical procedure. These new devices allow modelling the orientation of the segment towards compression, increasing the pressure on the cage and assuring a better interbody fusion.

## INDICATIONS AND LIMITS

The surgical conditions in which restricted and non restricted IPD are recommended are fully described in the literature: foraminal and/or central stenosis, soft stenosis, I grade spondylolisthesis (actually debated), low back pain, black disc<sup>[64-69]</sup>.

In the last few years, many authors have reported the high rate of surgical revision and symptom recrudescence in patients who have had these devices implanted<sup>[28-35,43-46,50]</sup>. In my opinion, from the literature review and my personal experience, surgical indications for the use of these interspinous devices are basically absent: (1) In foraminal stenosis, their only action is to accelerate the segmental degenerative process; (2) In central stenosis, they have no indication because their action is not resolutive for claudication, with its gold standard treatment the central decompression obtained with laminectomy; (3) In spondylolisthesis they are not indicated because the shear stress acting on the disc is high and the slippage would be augmented<sup>[28-35,43-46]</sup>; and (4) In low back pain due to micro-instability and in black disc conditions these devices would not be implanted because they do not reduce micro-instability but increase it, overloading the disc and augmenting pain.

In my opinion, interspinous devices have no clinical indication at the moment.

Interspinous stabilizers generating fusion, such as IFD, have a small range of surgical indications instead: monolateral or bilateral foraminal stenosis without evidence of spondylolisthesis in X-ray dynamic projections. These implants, which in my opinion have to be associated with TLIF and be inserted in neutral position or in slight compression, can allow the decompression of the stenotic nerve root with the TLIF technique, explicit in a slight compression supporting a contact between cage and endplates to promote a better intersomatic osseous fusion and promoting an interspinous and intersomatic osseous fusion, blocking the segmental degenerative process, responsible for the pathology and the symptoms<sup>[64-77]</sup>.

## COSTS

The costs of the device and its surgical revision should

not be underestimated. In a 2012 review concerning the post-op status of IPD, Epstein *et al*<sup>[74]</sup> reported a 11.6%-38% complication rate, 4.6%-85% reoperation rate and a 66.7%-77% incidence of poor outcomes. Furthermore, the cost of every single device is very high. So, high cost, high rate of complications, reoperation rates and poor outcomes make the choice of implantation of an IPD really controversial. In light of the points expressed previously, I think that IPD can be summarized as follows: highly expensive and poorly effective<sup>[64-69]</sup>.

## CONCLUSION

Dynamic neutralization systems should be studied, built and then implanted in order to preserve spinal biomechanics. The preservation of the physiological characteristics of the spine should particularly be aimed towards the whole motor unit (disc, facets, posterior tension band, ligaments) intended to be responsible for the segmental movement. IPD, as they are conceived today, do not seem to respect the biomechanical characteristics of the motor unit, accelerating the degenerative process and worsening the pathological process at the root of the clinical symptoms of patients. So this kind of device does not seem to have a definite and correct clinical indication at the moment. The IFD with their main aim as the treatment of the root of the pathological condition (instability) have a restricted range of clinical indications and their use can definitely be a source both for the patient and the surgeon. It is important to underline that these implants must not become a trend but only a weapon in the surgeon's hands and, as with every weapon, is extremely dangerous in wrong hands. So the spinal surgeon is the only one who can decide when to use it and must know in detail the effects of this weapon to use it correctly with no damage for the patient.

## ACKNOWLEDGMENTS

The author wants to thank Professor R Delfini, MD, PhD, Chief of Neurosurgery A, University of Rome "Sapienza" and Dr. N Marotta, MD, PhD, neurosurgeon from Neurosurgery A, University of Rome "Sapienza".

## REFERENCES

- 1 **Przybyla AS**, Skrzypiec D, Pollintine P, Dolan P, Adams MA. Strength of the cervical spine in compression and bending. *Spine* (Phila Pa 1976) 2007; **32**: 1612-1620 [PMID: 17621208]
- 2 **Shirazi-Adl A**. Analysis of large compression loads on lumbar spine in flexion and in torsion using a novel wrapping element. *J Biomech* 2006; **39**: 267-275 [PMID: 16321628 DOI: 10.1016/j.jbiomech.2004.11.022]
- 3 **Gillespie KA**, Dickey JP. Biomechanical role of lumbar spine ligaments in flexion and extension: determination using a parallel linkage robot and a porcine model. *Spine* (Phila Pa 1976) 2004; **29**: 1208-1216 [PMID: 15167660]
- 4 **Adams MA**, Hutton WC, Stott JR. The resistance to flexion of the lumbar intervertebral joint. *Spine* (Phila Pa 1976) 1980; **5**: 245-253 [PMID: 7394664]
- 5 **Gudavalli MR**, Triano JJ. An analytical model of lumbar motion segment in flexion. *J Manipulative Physiol Ther* 1999; **22**: 201-208 [PMID: 10367755 DOI: 10.1016/S0161-4754(99)70045-X]
- 6 **Solomonow M**, Zhou BH, Harris M, Lu Y, Baratta RV. The ligamento-muscular stabilizing system of the spine. *Spine* (Phila Pa 1976) 1998; **23**: 2552-2562 [PMID: 9854754]
- 7 **Hindle RJ**, Percy MJ, Cross A. Mechanical function of the human lumbar interspinous and supraspinous ligaments. *J Biomed Eng* 1990; **12**: 340-344 [PMID: 2395361 DOI: 10.1016/0141-5425(90)90010-K]
- 8 **Anderson AL**, McIlff TE, Asher MA, Burton DC, Glattes RC. The effect of posterior thoracic spine anatomical structures on motion segment flexion stiffness. *Spine* (Phila Pa 1976) 2009; **34**: 441-446 [PMID: 19247164 DOI: 10.1097/BRS.0b013e318198c62d]
- 9 **Sharma M**, Langrana NA, Rodriguez J. Role of ligaments and facets in lumbar spinal stability. *Spine* (Phila Pa 1976) 1995; **20**: 887-900 [PMID: 7644953]
- 10 **Ploumis A**, Christodoulou P, Kapoutsis D, Gelalis I, Vraggalas V, Beris A. Surgical treatment of lumbar spinal stenosis with microdecompression and interspinous distraction device insertion. A case series. *J Orthop Surg Res* 2012; **7**: 35 [PMID: 23107358 DOI: 10.1186/1749-799X-7-35]
- 11 **Buric J**, Pulidori M, Sinan T, Mehraj S. DIAM device for low back pain in degenerative disc disease : 24 months follow-up. *Acta Neurochir Suppl* 2011; **108**: 177-182 [PMID: 21107955 DOI: 10.1007/978-3-211-99370-5\_26]
- 12 **Nardi P**, Cabezas D, Rea G, Pettorini BL. Aperius PercLID stand alone interspinous system for the treatment of degenerative lumbar stenosis: experience on 152 cases. *J Spinal Disord Tech* 2010; **23**: 203-207 [PMID: 20065864 DOI: 10.1097/BSD.0b013e31819b08da]
- 13 **Anderson PA**, Tribus CB, Kitchel SH. Treatment of neurogenic claudication by interspinous decompression: application of the X STOP device in patients with lumbar degenerative spondylolisthesis. *J Neurosurg Spine* 2006; **4**: 463-471 [PMID: 16776357 DOI: 10.3171/spi.2006.4.6.463]
- 14 **Postacchini R**, Ferrari E, Cinotti G, Menchetti PP, Postacchini F. Aperius interspinous implant versus open surgical decompression in lumbar spinal stenosis. *Spine J* 2011; **11**: 933-939 [PMID: 22005077 DOI: 10.1016/j.spinee.2011.08.419]
- 15 **Lauryssen C**. Appropriate selection of patients with lumbar spinal stenosis for interspinous process decompression with the X STOP device. *Neurosurg Focus* 2007; **22**: E5 [PMID: 17608339 DOI: 10.3171/foc.2007.22.1.5]
- 16 **Tecky F**, Mageswaran P, Colbrunn RW, Bonner TF, McLain RF. Properties of an interspinous fixation device (ISD) in lumbar fusion constructs: a biomechanical study. *Spine J* 2013; **13**: 572-579 [PMID: 23498926 DOI: 10.1016/j.spinee.2013.01.042]
- 17 **Gonzalez-Blohm SA**, Doulgeris JJ, Aghayev K, Lee WE, Volkov A, Vrionis FD. Biomechanical analysis of an interspinous fusion device as a stand-alone and as supplemental fixation to posterior expandable interbody cages in the lumbar spine. *J Neurosurg Spine* 2014; **20**: 209-219 [PMID: 24286528]
- 18 **Karahalios DG**, Kaibara T, Porter RW, Kakarla UK, Reyes PM, Baaj AA, Yaqoobi AS, Crawford NR. Biomechanics of a lumbar interspinous anchor with anterior lumbar interbody fusion. *J Neurosurg Spine* 2010; **12**: 372-380 [PMID: 20367372 DOI: 10.3171/2009.10.SPINE09305]
- 19 **Tian NF**, Zhang XL, Wu YS, Jiang LB, Xu HZ, Chi YL. Fusion after interspinous device placement. *Orthopedics* 2012; **35**: e1822-e1825 [PMID: 23218645 DOI: 10.3928/01477447-20121120-33]
- 20 **Pradhan BB**, Turner AW, Zatushevsky MA, Cornwall GB, Rajae SS, Bae HW. Biomechanical analysis in a human ca-



- daveric model of spinous process fixation with an interlaminar allograft spacer for lumbar spinal stenosis: Laboratory investigation. *J Neurosurg Spine* 2012; **16**: 585-593 [PMID: 22519928 DOI: 10.3171/2012.3.SPINE11631]
- 21 **Kaibara T**, Karahalios DG, Porter RW, Kakarla UK, Reyes PM, Choi SK, Yaqoobi AS, Crawford NR. Biomechanics of a lumbar interspinous anchor with transforaminal lumbar interbody fixation. *World Neurosurg* 2010; **73**: 572-577 [PMID: 20920945 DOI: 10.1016/j.wneu.2010.02.025]
  - 22 **Yong-Hing K**, Kirkaldy-Willis WH. The pathophysiology of degenerative disease of the lumbar spine. *Orthop Clin North Am* 1983; **14**: 491-504 [PMID: 6346204]
  - 23 **Sairyo K**, Biyani A, Goel V, Leaman D, Booth R, Thomas J, Gehling D, Vishnubhotla L, Long R, Ebraheim N. Pathomechanism of ligamentum flavum hypertrophy: a multidisciplinary investigation based on clinical, biomechanical, histologic, and biologic assessments. *Spine (Phila Pa 1976)* 2005; **30**: 2649-2656 [PMID: 16319751]
  - 24 **Kosaka H**, Sairyo K, Biyani A, Leaman D, Yeasting R, Higashino K, Sakai T, Kato S, Sano T, Goel VK, Yasui N. Pathomechanism of loss of elasticity and hypertrophy of lumbar ligamentum flavum in elderly patients with lumbar spinal canal stenosis. *Spine (Phila Pa 1976)* 2007; **32**: 2805-2811 [PMID: 18246001 DOI: 10.1097/BRS.0b013e31815b650f]
  - 25 **Zhong ZM**, Zha DS, Xiao WD, Wu SH, Wu Q, Zhang Y, Liu FQ, Chen JT. Hypertrophy of ligamentum flavum in lumbar spine stenosis associated with the increased expression of connective tissue growth factor. *J Orthop Res* 2011; **29**: 1592-1597 [PMID: 21484860]
  - 26 **Honsawek S**, Poonpukdee J, Chalermpanpipat C, Payungporn S, Limthongkul W, Yingsakmongkol W, Thanakit V, Parkpian V. Hypertrophy of the ligamentum flavum in lumbar spinal canal stenosis is associated with increased bFGF expression. *Int Orthop* 2013; **37**: 1387-1392 [PMID: 23519824]
  - 27 **Landi A**, Delfini R. Soft stenosis of the lumbar spine: Thickness vs Hypertrophy of the ligamentum flavum. A pathogenetic and molecular point of view. *J Spine* 2013; **2**: e11 [DOI: 10.4172/2165-7939.1000e111]
  - 28 **Barbagallo GM**, Olindo G, Corbino L, Albanese V. Analysis of complications in patients treated with the X-Stop Interspinous Process Decompression System: proposal for a novel anatomic scoring system for patient selection and review of the literature. *Neurosurgery* 2009; **65**: 111-119; discussion 119-200 [PMID: 19574832 DOI: 10.1227/01.NEU.0000346254.07116.31]
  - 29 **Epstein NE**. X-Stop: foot drop. *Spine J* 2009; **9**: e6-e9 [PMID: 18809360 DOI: 10.1016/j.spinee.2008.08.004]
  - 30 **Bowers C**, Amini A, Dailey AT, Schmidt MH. Dynamic interspinous process stabilization: review of complications associated with the X-Stop device. *Neurosurg Focus* 2010; **28**: E8 [PMID: 20568923 DOI: 10.3171/2010.3.FOCUS1047]
  - 31 **Chung KJ**, Hwang YS, Koh SH. Stress fracture of bilateral posterior facet after insertion of interspinous implant. *Spine (Phila Pa 1976)* 2009; **34**: E380-E383 [PMID: 19404170 DOI: 10.1097/BRS.0b013e31819fd3a0]
  - 32 **Sobottke R**, Schlüter-Brust K, Kaulhausen T, Röllinghoff M, Joswig B, Stützer H, Eysel P, Simons P, Kuchta J. Interspinous implants (X Stop, Wallis, Diam) for the treatment of LSS: is there a correlation between radiological parameters and clinical outcome? *Eur Spine J* 2009; **18**: 1494-1503 [PMID: 19562386 DOI: 10.1007/s00586-009-1081-y]
  - 33 **Hartmann F**, Dietz SO, Kuhn S, Hely H, Rommens PM, Gercek E. Biomechanical comparison of an interspinous device and a rigid stabilization on lumbar adjacent segment range of motion. *Acta Chir Orthop Traumatol Cech* 2011; **78**: 404-409 [PMID: 22094153]
  - 34 **Korovessis P**, Papazisis Z, Lambiris E. The role of rigid vs. dynamic instrumentation for stabilization of the degenerative lumbosacral spine. *Stud Health Technol Inform* 2002; **91**: 457-461 [PMID: 15457776]
  - 35 **Barbagallo GM**, Corbino LA, Olindo G, Foti P, Albanese V, Signorelli F. The "sandwich phenomenon": a rare complication in adjacent, double-level X-stop surgery: report of three cases and review of the literature. *Spine (Phila Pa 1976)* 2010; **35**: E96-100 [DOI: 10.1097/BRS.0b013e3181c83820]
  - 36 **Chou D**, Lau D, Hermsmeyer J, Norvell D. Efficacy of interspinous device versus surgical decompression in the treatment of lumbar spinal stenosis: a modified network analysis. *Evid Based Spine Care J* 2011; **2**: 45-56 [PMID: 22956936 DOI: 10.1055/s-0030-1267086]
  - 37 **Sun HL**, Li CD, Liu XY, Lin JR, Yi XD, Liu H, Lu HL. [Mid-term follow-up and analysis of the failure cases of interspinous implants for degenerative lumbar diseases]. *Beijing Da Xue Xue Bao* 2011; **43**: 690-695 [PMID: 22008677]
  - 38 **Li CD**, Sun HL, Yu ZR. [Biomechanical study of interspinous fixation effect on the stiffness of adjacent segments]. *Beijing Da Xue Xue Bao* 2011; **43**: 657-660 [PMID: 22008670]
  - 39 **Le Huec JC**, Aunoble S, Philippe L, Nicolas P. Pelvic parameters: origin and significance. *Eur Spine J* 2011; **20** Suppl 5: 564-571 [PMID: 21830079 DOI: 10.1007/s00586-011-1940-1]
  - 40 **Le Huec JC**, Charosky S, Barrey C, Rigal J, Aunoble S. Sagittal imbalance cascade for simple degenerative spine and consequences: algorithm of decision for appropriate treatment. *Eur Spine J* 2011; **20** Suppl 5: 699-703 [PMID: 21811823 DOI: 10.1007/s00586-011-1938-8]
  - 41 **Le Huec JC**, Saddiki R, Franke J, Rigal J, Aunoble S. Equilibrium of the human body and the gravity line: the basics. *Eur Spine J* 2011; **20** Suppl 5: 558-563 [PMID: 21809013 DOI: 10.1007/s00586-011-1939-7]
  - 42 **Faundez A**, Roussouly P, Le Huec JC. [Sagittal balance of the spine: a therapeutic revolution]. *Rev Med Suisse* 2011; **7**: 2470-2474 [PMID: 22288284]
  - 43 **Schulte TL**, Hurschler C, Haversath M, Liljenqvist U, Bullmann V, Filler TJ, Osada N, Fallenberg EM, Hackenberg L. The effect of dynamic, semi-rigid implants on the range of motion of lumbar motion segments after decompression. *Eur Spine J* 2008; **17**: 1057-1065 [PMID: 18493802 DOI: 10.1007/s00586-008-0667-0]
  - 44 **Liu HY**, Gu AQ, Zhu ZQ, Zhou J. [The efficacy and complication analysis of interspinous dynamic device (Wallis) in patients of degenerative lumbar disease]. *Zhonghua Wai Ke Za Zhi* 2012; **50**: 788-791 [PMID: 23157952]
  - 45 **Kaulhausen T**, Zarghooni K, Stein G, Knifka J, Eysel P, Koebke J, Sobottke R. The interspinous spacer: a clinicoanatomical investigation using plastination. *Minim Invasive Surg* 2012; **2012**: 538697 [PMID: 22900164 DOI: 10.1155/2012/538697]
  - 46 **Maida G**, Marcati E, Sarubbo S. Heterotopic ossification in vertebral interlaminar/interspinous instrumentation: report of a case. *Case Rep Surg* 2012; **2012**: 970642 [PMID: 22888459 DOI: 10.1155/2012/970642]
  - 47 **Zucherman JF**, Telles CJ. Commentary: Interspinous devices, spondylolisthesis, and spinous process-related complications. *Spine J* 2012; **12**: 473-475 [PMID: 22857646 DOI: 10.1016/j.spinee.2012.07.011]
  - 48 **Krauss WE**. Interspinous distraction devices: too good to be true? Yes. *World Neurosurg* 2013; **80**: 78-79 [PMID: 22705755 DOI: 10.1016/j.wneu.2012.06.012]
  - 49 **Hsieh PC**. Efficacy of surgical treatment for lumbar stenosis with the X-STOP: an issue in need of closer inspection. *World Neurosurg* 2013; **80**: 74-77 [PMID: 22634461 DOI: 10.1016/j.wneu.2012.05.005]
  - 50 **Barz T**, Lange J, Melloh M, Staub LP, Merk HR, Klötting I, Follak N. Histomorphometric and radiographical changes after lumbar implantation of the PEEK nonfusion interspinous device in the BB.4S rat model. *Spine (Phila Pa 1976)* 2013; **38**: E263-E269 [PMID: 23222648 DOI: 10.1097/BRS.0b013e318280c710]
  - 51 **Kim DH**, Shanti N, Tantorski ME, Shaw JD, Li L, Martha JF, Thomas AJ, Parazin SJ, Rencus TC, Kwon B. Associa-



- tion between degenerative spondylolisthesis and spinous process fracture after interspinous process spacer surgery. *Spine J* 2012; **12**: 466-472 [PMID: 22622239 DOI: 10.1016/j.spinee.2012.03.034]
- 52 **Mayer HM**. [Discogenic low back pain and degenerative lumbar spinal stenosis - how appropriate is surgical treatment?]. *Schmerz* 2001; **15**: 484-491 [PMID: 11793155]
  - 53 **Siddiqui M**, Karadimas E, Nicol M, Smith FW, Wardlaw D. Effects of X-STOP device on sagittal lumbar spine kinematics in spinal stenosis. *J Spinal Disord Tech* 2006; **19**: 328-333 [PMID: 16826003 DOI: 10.1097/01.bsd.0000211297.52260.d5]
  - 54 **Korovessis P**, Repantis T, Zacharatos S, Zafiroopoulos A. Does Wallis implant reduce adjacent segment degeneration above lumbosacral instrumented fusion? *Eur Spine J* 2009; **18**: 830-840 [PMID: 19387697 DOI: 10.1007/s00586-009-0976-y]
  - 55 **Kim KA**, McDonald M, Pik JH, Khoueir P, Wang MY. Dynamic intraspinal spacer technology for posterior stabilization: case-control study on the safety, sagittal angulation, and pain outcome at 1-year follow-up evaluation. *Neurosurg Focus* 2007; **22**: E7 [PMID: 17608341 DOI: 10.3171/foc.2007.22.1.7]
  - 56 **Patil CG**, Sarmiento JM, Ugiliweneza B, Mukherjee D, Nuño M, Liu JC, Walia S, Lad SP, Boakye M. Interspinous device versus laminectomy for lumbar spinal stenosis: a comparative effectiveness study. *Spine J* 2014; **14**: 1484-1492 [PMID: 24291409]
  - 57 **Moojen WA**, Arts MP, Jacobs WC, van Zwet EW, van den Akker-van Marle ME, Koes BW, Vleggeert-Lankamp CL, Peul WC. Interspinous process device versus standard conventional surgical decompression for lumbar spinal stenosis: randomized controlled trial. *BMJ* 2013; **347**: f6415 [PMID: 24231273 DOI: 10.1136/bmj.f6415]
  - 58 **Schizas C**, Pralong E, Tzioupis C, Kulik G. Interspinous distraction in lumbar spinal stenosis: a neurophysiological perspective. *Spine (Phila Pa 1976)* 2013; **38**: 2113-2117 [PMID: 24026157 DOI: 10.1097/01.brs.0000435031.96058.f6]
  - 59 **Tian NF**, Wu AM, Wu LJ, Wu XL, Wu YS, Zhang XL, Xu HZ, Chi YL. Incidence of heterotopic ossification after implantation of interspinous process devices. *Neurosurg Focus* 2013; **35**: E3 [PMID: 23905954 DOI: 10.3171/2013.3.FOCUS12406]
  - 60 **Yao Q**, Wang S, Shin JH, Li G, Wood K. Motion characteristics of the lumbar spinous processes with degenerative disc disease and degenerative spondylolisthesis. *Eur Spine J* 2013; **22**: 2702-2709 [PMID: 23903997 DOI: 10.1007/s00586-013-2918-y]
  - 61 **Xu C**, Ni WF, Tian NF, Hu XQ, Li F, Xu HZ. Complications in degenerative lumbar disease treated with a dynamic interspinous spacer (Coflex). *Int Orthop* 2013; **37**: 2199-2204 [PMID: 23892467 DOI: 10.1007/s00264-013-2006-2]
  - 62 **Zang L**, DU P, Hai Y, Su QJ, Lu SB, Liu T. Device related complications of the Coflex interspinous process implant for the lumbar spine. *Chin Med J (Engl)* 2013; **126**: 2517-2522 [PMID: 23823827]
  - 63 **Nachanakian A**, El Helou A, Alaywan M. The interspinous spacer: a new posterior dynamic stabilization concept for prevention of adjacent segment disease. *Adv Orthop* 2013; **2013**: 637362 [PMID: 23662209 DOI: 10.1155/2013/637362]
  - 64 **Kong DS**, Kim ES, Eoh W. One-year outcome evaluation after interspinous implantation for degenerative spinal stenosis with segmental instability. *J Korean Med Sci* 2007; **22**: 330-335 [PMID: 17449945 DOI: 10.3346/jkms.2007.22.2.330]
  - 65 **Kuchta J**, Sobottke R, Eysel P, Simons P. Two-year results of interspinous spacer (X-Stop) implantation in 175 patients with neurologic intermittent claudication due to lumbar spinal stenosis. *Eur Spine J* 2009; **18**: 823-829 [PMID: 19387698 DOI: 10.1007/s00586-009-0967-z]
  - 66 **Galarza M**, Fabrizio AP, Maina R, Gazzeri R, Martínez-Lage JF. Degenerative lumbar spinal stenosis with neurogenic intermittent claudication and treatment with the Aperius PercLID System: a preliminary report. *Neurosurg Focus* 2010; **28**: E3 [PMID: 20568919 DOI: 10.3171/2010.3.FOCUS1034]
  - 67 **Floman Y**, Millgram MA, Smorgick Y, Rand N, Ashkenazi E. Failure of the Wallis interspinous implant to lower the incidence of recurrent lumbar disc herniations in patients undergoing primary disc excision. *J Spinal Disord Tech* 2007; **20**: 337-341 [PMID: 17607096 DOI: 10.1097/BSD.0b013e318030a81d]
  - 68 **Kim DH**, Tantsorski M, Shaw J, Martha J, Li L, Shanti N, Rencu T, Parazin S, Kwon B. Occult spinous process fractures associated with interspinous process spacers. *Spine (Phila Pa 1976)* 2011; **36**: E1080-E1085 [PMID: 21343860 DOI: 10.1097/BRS.0b013e318204066a]
  - 69 **Verhoof OJ**, Bron JL, Wapstra FH, van Royen BJ. High failure rate of the interspinous distraction device (X-Stop) for the treatment of lumbar spinal stenosis caused by degenerative spondylolisthesis. *Eur Spine J* 2008; **17**: 188-192 [PMID: 17846801 DOI: 10.1007/s00586-007-0492-x]
  - 70 **Borg A**, Nurboja B, Timothy J, Choi D. Interspinous distractor devices for the management of lumbar spinal stenosis: a miracle cure for a common problem? *Br J Neurosurg* 2012; **26**: 445-449 [PMID: 22582741 DOI: 10.3109/02688697.2012.680630]
  - 71 **Patil S**, Burton M, Storey C, Glenn C, Marino A, Nanda A. Evaluation of interspinous process distraction device (X-STOP) in a representative patient cohort. *World Neurosurg* 2013; **80**: 213-217 [PMID: 22484765 DOI: 10.1016/j.wneu.2012.03.034]
  - 72 **Shabat S**, Miller LE, Block JE, Gepstein R. Minimally invasive treatment of lumbar spinal stenosis with a novel interspinous spacer. *Clin Interv Aging* 2011; **6**: 227-233 [PMID: 21966217 DOI: 10.2147/CIA.S23656]
  - 73 **Heyrani N**, Picinic Norheim E, Elaine Ku Y, Nick Shamie A. Interspinous process implantation for the treatment of neurogenic intermittent claudication. *Anesth Pain Med* 2012; **2**: 36-41 [PMID: 24223332 DOI: 10.5812/aapm.5173]
  - 74 **Epstein NE**. A review of interspinous fusion devices: High complication, reoperation rates, and costs with poor outcomes. *Surg Neurol Int* 2012; **3**: 7 [PMID: 22347676 DOI: 10.4103/2152-7806.92172]
  - 75 **Malter AD**, McNeney B, Loeser JD, Deyo RA. 5-year reoperation rates after different types of lumbar spine surgery. *Spine (Phila Pa 1976)* 1998; **23**: 814-820 [PMID: 9563113]
  - 76 **Yuzawa Y**. The interspinous ligament should be removed for the decompression surgery with the case of lumbar spinal canal stenosis. *Arch Orthop Trauma Surg* 2011; **131**: 753-758 [PMID: 21161255 DOI: 10.1007/s00402-010-1207-z]
  - 77 **Kaulhausen T**, Siewe J, Eysel P, Knifka J, Notermans HP, Koebke J, Sobottke R. The role of the inter-/supraspinous ligament complex in stand-alone interspinous process devices: a biomechanical and anatomic study. *J Neurol Surg A Cent Eur Neurosurg* 2012; **73**: 65-72 [PMID: 22467478 DOI: 10.1055/s-0031-1297250]

**P- Reviewer:** Lakhdar F, Kasai Y **S- Editor:** Wen LL  
**L- Editor:** Roemmele A **E- Editor:** Lu YJ



## Review of tumoral calcinosis: A rare clinico-pathological entity

Ibrahim Fathi, Mahmoud Sakr

Ibrahim Fathi, Mahmoud Sakr, Department of Surgery, Faculty of Medicine, University of Alexandria, Raml Station, Alexandria 21500, Egypt

**Author contributions:** Fathi I reviewed the articles dealing with tumoral calcinosis and wrote the manuscript; Sakr M reviewed the articles dealing with tumoral calcinosis and revised the manuscript.

**Correspondence to:** Mahmud Sakr, MD, PhD, FACS, Professor of Surgery, Faculty of Medicine, University of Alexandria, Shamlion st., Raml Station, Alexandria 21500,

Egypt. mah\_sakr@yahoo.com

Telephone: +20-10-07834993 Fax: +20-20-34841189

Received: April 10, 2014 Revised: June 8, 2014

Accepted: June 27, 2014

Published online: September 16, 2014

### Abstract

Tumoral calcinosis (TC) has long been a controversial clinico-pathological entity. Its pathogenesis and genetic background have been gradually unravelled since its first description in 1943. According to the presence or absence of an underlying calcifying disease process, TC has been divided into primary and secondary varieties. Two subtypes of the primary variety exist; a hyperphosphatemic type with familial basis represented by mutations in GalNAc transferase 3 gene (*GALNT3*), *KLOTHO* or Fibroblast growth factor 23 (*FGF23*) genes, and a normo-phosphatemic type with growing evidence of underlying familial base represented by mutation in *SAMD9* gene. The secondary variety is mainly associated with chronic renal failure and the resulting secondary or tertiary hyperparathyroidism. Diagnosis of TC relies on typical radiographic features (on plain radiographs and computed tomography) and the biochemical profile. Magnetic resonance imaging can be done in difficult cases, and scintigraphy reflects the disease activity. Treatment is mainly surgical for the primary variety; however, a stage-oriented conservative approach using phosphate binders, phosphate restricted diets

and acetazolamide should be considered before the surgical approach is pursued due to the high rate of recurrences and complications after surgical intervention. Medical treatment is the mainstay for treatment of the secondary variety, with failure warranting subtotal or total parathyroidectomy. Surgical intervention in these patients should be kept as a last resort.

© 2014 Baishideng Publishing Group Inc. All rights reserved.

**Key words:** Tumoral calcinosis; Primary; Secondary; Calcification; Surgical excision; *FGF23*; *GALNT3*; *KLOTHO*; Phosphate binders

**Core tip:** This review of literature on tumoral calcinosis, describes the current understanding of the pathogenesis and classifications of this relatively rare clinico-pathological entity. It discusses the different current diagnostic modalities and treatment options.

Fathi I, Sakr M. Review of tumoral calcinosis: A rare clinico-pathological entity. *World J Clin Cases* 2014; 2(9): 409-414 Available from: URL: <http://www.wjgnet.com/2307-8960/full/v2/i9/409.htm> DOI: <http://dx.doi.org/10.12998/wjcc.v2.i9.409>

### INTRODUCTION

Tumoral calcinosis (TC) is a rare clinical and histopathologic syndrome characterized by calcium salt deposition in different peri-articular soft tissue regions<sup>[1,2]</sup>. It mainly manifests in childhood or adolescence as painless, firm, tumour-like masses around the joints that may lead to joint function limitations specially when large in size<sup>[1,3,4]</sup>.

Regions most commonly involved by this pathology are soft tissues of peri-articular upper limb (shoulder and elbow) and hip regions. Still; spinal<sup>[5-7]</sup>, temporo-mandibular joint<sup>[8,9]</sup>, metacarpals/metatarsals<sup>[10]</sup>, and popliteal

space<sup>[11]</sup> involvement has also been reported.

## HISTORICAL REVIEW

The term “tumoral calcinosis” was first stated by Inclan *et al*<sup>[3]</sup> in 1943 for a disease characterized by large juxta-articular lobular calcified masses without visceral or skin calcifications in patients showing normal serum calcium and phosphorus levels. The characteristic pathological features of these lesions were the presence of multiple cysts filled with calcified deposits lined by histiocytes, giant cells, and xanthomatous histiocytes. Earlier, Giard<sup>[12]</sup> and Duret<sup>[13]</sup> reported a similar condition in the European medical literature in 1898 and 1899, respectively. This disease process was a subject of Teutschlaender<sup>[14,15]</sup> studies from 1930 to 1950, known as the Teutschlaender disease in the European literature by that time<sup>[16]</sup>.

Since its first description by Inclan *et al*<sup>[3]</sup>, the term tumoral calcinosis has been widely used in the literature and has been sometimes broadened to include other conditions resulting in similar clinico-pathologic features, or even imprecisely used to describe any massive collection of peri-articular calcifications<sup>[17]</sup>. In this article, we are aiming at reviewing pathogenesis of the disease and the current diagnostic and treatment options.

## ETIOLOGY, PATHOGENESIS AND CLASSIFICATION

Etiology of TC remains uncertain despite the several theories that have been proposed. In 1996, Smack *et al*<sup>[18]</sup>, retrospectively reviewed 122 cases of TC ending in a proposed pathogenesis-based classification as follows: (1) Primary normo-phosphatemic TC. Normo-calcemia and normo-phosphatemia are the hallmark of this entity. The majority of patients present before the 2<sup>nd</sup> decade of life and almost half of them live in tropical or subtropical regions. It is usually characterized by solitary calcifications. Although Smack *et al*<sup>[18]</sup>, mentioned that there was no evident familial pattern in this entity, recent literature showed growing evidence of familial basis for this type of pathology, involving mutations in the gene encoding for SAMD9 protein<sup>[19]</sup>; (2) Primary hyper-phosphatemic TC. Normo-calcemia and hyper-phosphatemia are the hallmark of this entity. This type usually presents during the first and second decades<sup>[17,20]</sup> with predominance in people of African descent (some authors suggested confining the term TC to this variety)<sup>[17]</sup>. Genetic predisposition is a feature of this type of TC where hyper-phosphatemia arises due to reduced urinary phosphate excretion caused by recessive mutations in GalNAc transferase 3 gene, *GALNT3*, and *KLOTHO*, that causes the inactivation of *FGF23*, a phosphaturic hormone<sup>[21-24]</sup>; and (3) Secondary TC. Chronic renal failure (CRF) is the most common identifiable condition in this entity.

The histology of the TC lesions in these 3 groups is identical. The reason behind this similarity has not yet

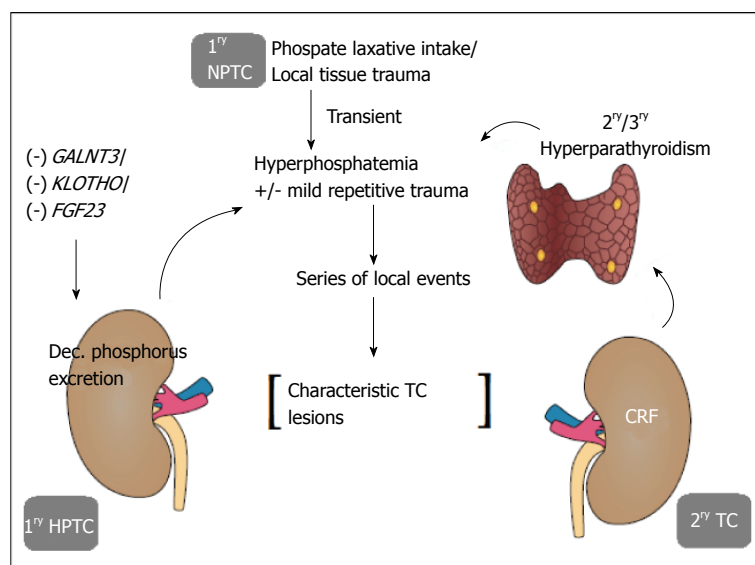
been resolved<sup>[25]</sup>. This classification although bringing clarity to the diagnosis of TC and being widely propagated in the literature is still facing some debates<sup>[17]</sup> including the dissociation between the lesion and its underlying etiology resulting from dealing with the term as a clinico-pathological description rather than a separate disease entity as described by Inclan *et al*<sup>[3]</sup>.

Although Smack *et al*<sup>[18]</sup> described this classification as a pathogenesis based one, they actually classified the condition according to the presence or absence of underlying disease associated with calcification and the biochemical profile of the patients rather than actual pathogenesis of the lesions.

A stepwise approach to the pathogenesis of TC lesions has been proposed<sup>[26]</sup>. Although this approach has been described for the familial type of TC, it has been later enlarged to contain the other types of this pathology as a common pathway, which eventually results in the formation of the characteristic TC lesions<sup>[25]</sup> as follows: (1) Minimal repetitive trauma leading to hemorrhages in the peri-articular tissue initiating a foamy histiocytic response. Traumatic Injury preceding the development of TC lesions has been frequently reported specially in the normo-phosphatemic variety<sup>[18]</sup>. Trauma in the form of chronic pressure has also been accused<sup>[27]</sup>. The presence of hemosiderin pigment near TC lesions fortifies this theory<sup>[28]</sup>; and (2) A reparative process is initiated which together with friction forces, lead towards neobursae formation. However, an interplay between multifactorial calcification process and collagenolysis due to proteolytic enzymes produced from disintegrating histiocytes prevents functional bursae and bone formation. This results in the characteristic lesions of TC, representing the active stage of the process<sup>[26]</sup>.

This multifactorial calcification is initiated by elevated calcium phosphorus product with hyper-phosphatemia as the overwhelming component. This hyper-phosphatemia can be explained by genetic mutations in the *FGF23*, *GALNT3* or *KLOTHO* gene resulting in inactivation of the phosphaturic protein *FGF23* in the primary hyper-phosphatemic variety. In the secondary type, this hyper-phosphatemic state is explained by the association with secondary hyperparathyroidism resulting from CRF. On the other hand, in the primary normo-phosphatemic variety, transient hyper-phosphatemia is the proposed mechanism. This transient hyper-phosphatemia is either produced locally due to tissue injury leading to release of phosphate from injured cells into extracellular space specially when injury involves muscles (main phosphate store in soft tissue), or induced by excessive oral or rectal use of a phosphate-saline laxatives<sup>[25,29]</sup>. This hypothesis still needs to be augmented. Figure 1 shows a schematic illustration of the pathogenesis of the different types of TC.

Finally, calcified debris fills the loculi leading to bone formation with arrest of bursae forming activity and decline in collagenolysis activity, ending in fibrosis that surrounds the TC lesions. Here, the lesions become rela-



**Figure 1** Schematic diagram showing pathogenesis of different types of tumoral calcinosis. HPTC: Hyperphosphatemic tumoral calcinosis; NPTC: Normo-phosphatemic TC; CRF: Chronic renal failure; GALNT3: GalNAc transferase 3 gene; FGF23: Fibroblast growth factor 23.

tively quiescent<sup>[26]</sup>.

## DIAGNOSIS AND DIFFERENTIAL DIAGNOSIS

Diagnosis of TC involves differentiating the condition from its mimics and further classifying it into one of the aforementioned categories.

Patients with TC usually present with multiple or solitary swellings related to the joints, discomfort, pain, and joint movement limitation<sup>[28,30]</sup> most commonly affecting the hip, elbow, shoulder, foot, and wrist<sup>[17]</sup>. Growth of such lesions is mostly slow and progressive in nature over several years<sup>[31]</sup>. Sometimes, ulceration of the overlying skin occurs with superadded secondary infection<sup>[32,33]</sup>. Huge bilateral cases of TC though rare, have been described in the literature<sup>[34]</sup>.

Diagnosis of TC is mainly based on imaging modalities. *Plain radiographs* show the typical appearance of amorphous, multilobulated and cystic calcifications in a peri-articular location<sup>[17]</sup>. Computed tomography helps in determining the extent and relations of individual lesions, and as a guide for surgical planning. It usually shows cystic loculi with fluid-fluid levels caused by calcium layering giving rise to "the sedimentation sign"<sup>[35]</sup>. In other instances, the lesion may appear homogenous denoting decreased activity in the quiescent stage<sup>[36,37]</sup>. Erosion or osseous destruction by adjacent soft-tissue masses is consistently absent; another hallmark of this pathology<sup>[17]</sup>. Magnetic resonance imaging shows inhomogeneous high signal intensity on T2-weighted sequences with two patterns frequently observed; diffuse lower-signal-intensity pattern, or nodular pattern with alternating areas of high signal intensity and signal void. The lesions appear inhomogeneous with low-signal intensity on T1-weighted sequences<sup>[37]</sup>.

Scintigraphy using radiolabeled phosphate compounds (technetium-99m methylene diphosphonate) is

of great value in detecting multiple lesions, newly-forming lesions, bone marrow affection, and for monitoring therapy reflecting the activity of the lesions. Ultrasonography can also be of value in detecting loculated fluid collections, thus helping in determining the disease activity<sup>[17,37,38]</sup>.

Other conditions including calcinosis universalis, calcinosis circumscripta, calcific tendonitis, synovial osteochondromatosis, synovial sarcoma, osteosarcoma, myositis ossificans, tophaceous gout, and calcific myonecrosis can confuse both the radiologists and the clinicians regarding the nature of these lesions. This can be resolved through combining typical radiological features of TC with the serum biochemical profile (including serum calcium level, serum phosphorus levels, renal function tests, serum parathormone level and 1,25-dihydroxy-vitamin D levels)<sup>[17,38]</sup>. Detailed family, drug and past history should also be obtained.

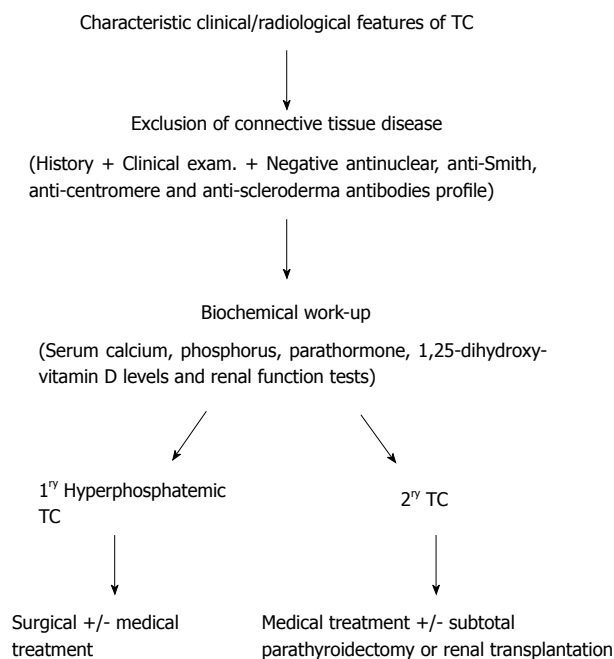
It should be emphasized that connective tissue diseases should be excluded before settling the diagnosis as primary TC specially in the setting of normal calcium and phosphorus levels. This can be achieved with a negative antinuclear, anti-Smith, anti-centromere and anti-scleroderma antibodies profile<sup>[17]</sup>.

Although biopsy is better avoided for fear of infection<sup>[34]</sup>. It may still be done in difficult cases to settle the diagnosis<sup>[39]</sup>. Histopathological examination of TC lesions after biopsy or surgical excision shows certain characteristic morphologic features differentiating it from other calcifying processes. This includes formation of the characteristic compartments, which contain liquid chalky content together with calcifications. Such compartmentalized configuration frequently remains even in the quiescent stage<sup>[25]</sup>.

## TREATMENT MODALITIES

Treatment of TC should be tailored according to the type of the lesion, stage of the pathology together with the





**Figure 2** Schematic diagram showing the diagnostic and treatment approach for tumoral calcinosis. TC: Tumoral calcinosis.

site, size and relations of the lesion, as well as symptoms of the patient.

Considering the primary variety, primary treatment is early surgical excision<sup>[40]</sup>. However, the high rate of recurrence warrants repeated excisions<sup>[2,33]</sup>. During surgery, TC lesions show a cystic nature with white and yellow chalky material formed by calcium hydroxyapatite crystals, calcium carbonate and calcium phosphate<sup>[18]</sup>. The presence of a hyper-vascular region beyond the periphery of the calcified mass as proven by angiography raises the possibility that a wider surgical resection margin may lead to fewer recurrences. Confirmation of this theory is however, still needed<sup>[41]</sup>. Slavin *et al.*<sup>[26]</sup>, reported that immobilization after resection may also have a role in decreasing new lesion formation in the adjacent tissues.

Huge lesions may require extensive surgical excision and reconstruction<sup>[42]</sup>. Relations to important neurovascular structures may be challenging, resulting mostly in partial excision and rapid recurrence. However, partial excision of large symptomatic lesions can be helpful providing significant pain relief<sup>[43,44]</sup>. Indications for surgical excision also include recurrent infection, ulceration, and functional impairment<sup>[34,45]</sup>.

According to a literature review done by King *et al.*<sup>[45]</sup>, surgical complications of TC excision include postoperative prolonged drainage which can lead to delayed wound healing and sinus tract formation, secondary infections caused by chronic wound problems specially with extensive disease or incomplete resection, and recurrence, which is frequent after incomplete excision and usually has a faster rate of growth.

Medical treatment through phosphate depletion (dietary deprivation of phosphorus and phosphate binding

chelating agents such as oral aluminium hydroxide has shown variable success rates in both normo- and hyper-phosphatemic cases<sup>[10,33,46]</sup>. The combination with acetazolamide to induce phosphaturia may have a valuable synergistic effect in lowering hyper-phosphatemia<sup>[47,48]</sup>. In-view of the high rate of recurrence after surgical excision, medical treatment in the primary variety could be reasonably considered before the surgical approach, especially in the hyper-phosphatemic entity.

From a pathogenetic point of view, medical treatment during the active stage maybe superior to surgery which is usually doomed with recurrence in this stage. On the other hand, surgical treatment may be more effective in the relatively quiescent stage where encapsulation occurs and hinders the ion exchange process leading to failure of phosphate depletion treatment<sup>[26]</sup>. Some authors advocate a combination therapy that includes surgical excision and medical treatment as a necessity in some resistant cases<sup>[49,50]</sup>. Alternative treatment modalities including the administration of steroids, diphosphonates, or calcitonin and radiation therapy have not proven to be effective<sup>[2,3,51-53]</sup>.

On the other hand, treatment of secondary TC (end stage renal disease-related, hemodialysis-related TC) is mainly medical. Surgical excision is associated with more profound complications (infection, fistula formation) aggravated by the patient medical condition, together with the persistence of the etiology<sup>[34]</sup>. Surgical interventions or biopsies should be kept as a last resort in these patients. Medical treatment includes calcium and phosphorus restricted diets, dialysates, and phosphate binders (except aluminium containing binders). Several other medical treatments including Vinpocetine, Sodium thiosulfate, intravenous Pamidronate, have been used in treatment of the secondary variety of TC with variable success rates<sup>[54-58]</sup>.

Given the underlying secondary or tertiary hyperparathyroidism in most of these patients, subtotal or total parathyroidectomy is the next logical step in the setting of medical treatment failure. This approach has demonstrated significant response<sup>[59-61]</sup>. Kidney transplantation may also be considered. Figure 2 shows a schematic diagram of the diagnostic and treatment approach for TC.

## CONCLUSION

In view of growing understanding of the pathogenesis of TC and evidence of the familial origin in the normo-phosphatemic, an agreement regarding the clinico-pathological entities to which the term TC should be coined should be sought. Such an agreement may necessitate preserving the term for the familial type of the condition including its two variants after exclusion of underlying disease process, or at least limiting the secondary variant to conditions sharing the same pathogenesis on ultra-structural level. This should be propagated to radiologists, clinicians and pathologists in order to avoid a misleading imprecise diagnosis. The exact diagnosis of TC relies on

typical radiologic features and biochemical profile, with the exclusion of connective tissue diseases. Treatment plans should be tailored to individual cases. Generally, conservative treatment is better considered prior to the surgical approach in primary patients, reserving surgical excision to patients with disabling symptoms. In secondary cases, medical treatment in the mainstay. Treatment failure warrants parathyroidectomy, and surgical excision should be the last resort in these cases.

## REFERENCES

- 1 McClatchie S, Bremner AD. Tumoral calcinosis—an unrecognized disease. *Br Med J* 1969; **1**: 153-155 [PMID: 5762276 DOI: 10.1136/bmj.1.5637.142-a]
- 2 Lafferty FW, Reynolds ES, Pearson OH. Tumoral calcinosis: a metabolic disease of obscure etiology. *Am J Med* 1965; **38**: 105-118 [PMID: 14251895 DOI: 10.1016/0002-9343(65)90164-6]
- 3 Inclan A, Leon PP, Camejo M. Tumoral calcinosis. *J Am Med Ass* 1943; **121**: 490-495 [DOI: 10.1001/jama.1943.02840070018005]
- 4 Slavin G, Klenerman L, Darby A, Bansal S. Tumoral calcinosis in England. *Br Med J* 1973; **1**: 147-149 [PMID: 4145235 DOI: 10.1136/bmj.1.5846.147]
- 5 Durant DM, Riley LH, Burger PC, McCarthy EF. Tumoral calcinosis of the spine: a study of 21 cases. *Spine (Phila Pa 1976)* 2001; **26**: 1673-1679 [PMID: 11474354 DOI: 10.1097/0007632-200108010-00009]
- 6 Kokubun S, Ozawa H, Sakurai M, Tanaka Y. Tumoral calcinosis in the upper cervical spine: a case report. *Spine (Phila Pa 1976)* 1996; **21**: 249-252 [PMID: 8720412 DOI: 10.1097/0007632-199601150-00017]
- 7 Ohashi K, Yamada T, Ishikawa T, Yamaguchi S, Nakajima H, Takagi M. Idiopathic tumoral calcinosis involving the cervical spine. *Skeletal Radiol* 1996; **25**: 388-390 [PMID: 8738007 DOI: 10.1007/s002560050101]
- 8 Gal G, Metzker A, Garlick J, Gold Y, Calderon S. Head and neck manifestations of tumoral calcinosis. *Oral Surg Oral Med Oral Pathol* 1994; **77**: 158-166 [PMID: 8139834 DOI: 10.1016/0030-4220(94)90279-8]
- 9 Shirasuna K, Sugiyama M, Yasui Y. Tumoral calcinosis around the mandibular condyle. *Int J Oral Maxillofac Surg* 1991; **20**: 36-37 [PMID: 2019781 DOI: 10.1016/S0901-5027(05)80692-7]
- 10 Mozaffarian G, Lafferty FW, Pearson OH. Treatment of tumoral calcinosis with phosphorus deprivation. *Ann Intern Med* 1972; **77**: 741-745 [PMID: 4538804 DOI: 10.7326/0003-4819-77-5-741]
- 11 Giardina F, Sudanese A, Bertoni F, Guerra E, Paderni S. Tumoral calcinosis of the popliteal space. *Orthopedics* 2004; **27**: 1104-1107 [PMID: 15553954]
- 12 Giard A. Sur la calcification hibernale. *C R Soc Biol* 1898; **10**: 1013-1015
- 13 Duret MH. Tumeurs multiples et singulieres des bourses sereuses. *Bull Mem Soc Anat Paris* 1899; **74**: 725-733
- 14 Teutschlaender O. Die lipoido-calcinosis oder lipoidkalkgicht. *Beitr Pathol Ana* 1949; **110**: 402-432
- 15 TEUTSCHLAENDER O. [On progressive lipoidocalcinosis; a differentiation of two types]. *Zentralbl Allg Pathol* 1951; **87**: 1-15 [PMID: 14828927]
- 16 Barrière H, Welin J, Lenne Y, Visset J, Vigier P. [Teutschlaender lipo-calcino-granulomatosis or tumoral calcinosis of Inclan (author's transl)]. *Ann Dermatol Venereol* 1977; **104**: 136-140 [PMID: 869449]
- 17 Olsen KM, Chew FS. Tumoral calcinosis: pearls, polemics, and alternative possibilities. *Radiographics* 2006; **26**: 871-885 [PMID: 16702460 DOI: 10.1148/rg.263055099]
- 18 Smack D, Norton SA, Fitzpatrick JE. Proposal for a pathogenesis-based classification of tumoral calcinosis. *Int J Dermatol* 1996; **35**: 265-271 [PMID: 8786184 DOI: 10.1111/j.1365-4362.1996.tb02999.x]
- 19 Hershkovitz D, Gross Y, Nahum S, Yehezkel S, Sarig O, Uitto J, Sprecher E. Functional characterization of SAMD9, a protein deficient in normophosphatemic familial tumoral calcinosis. *J Invest Dermatol* 2011; **131**: 662-669 [PMID: 21160498 DOI: 10.1038/jid.2010.387]
- 20 Prince MJ, Schaeffer PC, Goldsmith RS, Chausmer AB. Hyperphosphatemic tumoral calcinosis: association with elevation of serum 1,25-dihydroxycholecalciferol concentrations. *Ann Intern Med* 1982; **96**: 586-591 [PMID: 6896123 DOI: 10.7326/0003-4819-96-5-586]
- 21 Topaz O, Shurman DL, Bergman R, Indelman M, Ratajczak P, Mizrahi M, Khamaysi Z, Behar D, Petronius D, Friedman V, Zelikovic I, Raimer S, Metzker A, Richard G, Sprecher E. Mutations in GALNT3, encoding a protein involved in O-linked glycosylation, cause familial tumoral calcinosis. *Nat Genet* 2004; **36**: 579-581 [PMID: 15133511 DOI: 10.1038/ng1358]
- 22 Benet-Pagès A, Orlík P, Strom TM, Lorenz-Depiereux B. An FGF23 missense mutation causes familial tumoral calcinosis with hyperphosphatemia. *Hum Mol Genet* 2005; **14**: 385-390 [PMID: 15590700 DOI: 10.1093/hmg/ddi034]
- 23 Larsson T, Yu X, Davis SI, Draman MS, Mooney SD, Cullen MJ, White KE. A novel recessive mutation in fibroblast growth factor-23 causes familial tumoral calcinosis. *J Clin Endocrinol Metab* 2005; **90**: 2424-2427 [PMID: 15687325 DOI: 10.1210/jc.2004-2238]
- 24 Ichikawa S, Imel EA, Kreiter ML, Yu X, Mackenzie DS, Sorenson AH, Goetz R, Mohammadi M, White KE, Econs MJ. A homozygous missense mutation in human KLOTHO causes severe tumoral calcinosis. *J Musculoskelet Neuronal Interact* 2007; **7**: 318-319 [PMID: 18094491 DOI: 10.1172/JCI31330]
- 25 Slavin RE, Wen J, Barmada A. Tumoral calcinosis—a pathogenetic overview: a histological and ultrastructural study with a report of two new cases, one in infancy. *Int J Surg Pathol* 2012; **20**: 462-473 [PMID: 22614164 DOI: 10.1177/1066896912444925]
- 26 Slavin RE, Wen J, Kumar D, Evans EB. Familial tumoral calcinosis. A clinical, histopathologic, and ultrastructural study with an analysis of its calcifying process and pathogenesis. *Am J Surg Pathol* 1993; **17**: 788-802 [PMID: 8338191 DOI: 10.1097/0000478-199308000-00004]
- 27 Thomson JG. Calcifying collagenolysis (tumoural calcinosis). *Br J Radiol* 1966; **39**: 526-532 [PMID: 5942000 DOI: 10.1259/0007-1285-39-463-526]
- 28 Pakasa NM, Kalengayi RM. Tumoral calcinosis: a clinicopathological study of 111 cases with emphasis on the earliest changes. *Histopathology* 1997; **31**: 18-24 [PMID: 9253620 DOI: 10.1046/j.1365-2559.1997.6050831.x]
- 29 Markowitz GS, Perazella MA. Acute phosphate nephropathy. *Kidney Int* 2009; **76**: 1027-1034 [PMID: 19675530 DOI: 10.1038/ki.2009.308]
- 30 Asuncion GF, Tzarnas CD. Uremic tumoral calcinosis: acute hand presentations mimicking infection. *J Hand Surg Am* 1994; **19**: 809-812 [PMID: 7806807 DOI: 10.1016/0363-5023(94)90190-2]
- 31 Meltzer CC, Fishman EK, Scott WW. Tumoral calcinosis causing bone erosion in a renal dialysis patient. *Clin Imaging* 1992; **16**: 49-51 [PMID: 1540864 DOI: 10.1016/0899-7071(92)90091-M]
- 32 Geirnaerd MJ, Kroon HM, van der Heul RO, Herfkens HF. Tumoral calcinosis. *Skeletal Radiol* 1995; **24**: 148-151 [PMID: 7747184 DOI: 10.1007/BF00198081]
- 33 Kirk TS, Simon MA. Tumoral calcinosis. Report of a case with successful medical management. *J Bone Joint Surg Am* 1981; **63**: 1167-1169 [PMID: 6268638]

- 34 **Farzan M**, Farhoud AR. Tumoral calcinosis: what is the treatment? Report of two cases of different types and review of the literature. *Am J Orthop* (Belle Mead NJ) 2011; **40**: E170-E176 [PMID: 22022679]
- 35 **Hug I**, Guncaga J. Tumoral calcinosis with sedimentation sign. *Br J Radiol* 1974; **47**: 734-736 [PMID: 4433987 DOI: 10.1259/0007-1285-47-562-734]
- 36 **Harkess JW**, Peters HJ. Tumoral calcinosis. A report of six cases. *J Bone Joint Surg Am* 1967; **49**: 721-731 [PMID: 6026005]
- 37 **Martinez S**, Vogler JB, Harrelson JM, Lyles KW. Imaging of tumoral calcinosis: new observations. *Radiology* 1990; **174**: 215-222 [PMID: 2294551 DOI: 10.1148/radiology.174.1.2294551]
- 38 **Huang YT**, Chen CY, Yang CM, Yao MS, Chan WP. Tumoral calcinosis-like metastatic calcification in a patient on renal dialysis. *Clin Imaging* 2006; **30**: 66-68 [PMID: 16377490 DOI: 10.1016/j.clinimag.2005.06.024]
- 39 **Petscavage JM**, Richardson ML. Tumoral calcinosis mimicking recurrent osteosarcoma. *J Radiol Case Rep* 2009; **4**: 336
- 40 **Steinbach LS**, Johnston JO, Tepper EF, Honda GD, Martel W. Tumoral calcinosis: radiologic-pathologic correlation. *Skeletal Radiol* 1995; **24**: 573-578 [PMID: 8614855 DOI: 10.1007/BF00204854]
- 41 **Neeman Z**, Wood BJ. Angiographic findings in tumoral calcinosis. *Clin Imaging* 2003; **27**: 184-186 [PMID: 12727056 DOI: 10.1016/S0899-7071(02)00523-5]
- 42 **Lykoudis EG**, Seretis K, Ristanis S. Huge recurrent tumoral calcinosis needing extensive excision and reconstruction: report of a rare case and brief literature review. *Aesthetic Plast Surg* 2012; **36**: 1194-1197 [PMID: 22653143 DOI: 10.1007/s00266-012-9923-0]
- 43 **Tezelman S**, Siperstein AE, Duh QY, Clark OH. Tumoral calcinosis. Controversies in the etiology and alternatives in the treatment. *Arch Surg* 1993; **128**: 737-744; discussion 744-745 [PMID: 8317954 DOI: 10.1001/archsurg.1993.01420190027004]
- 44 **Arikawa J**, Higaki Y, Mizushima J, Nogita T, Kawashima M. Tumoral calcinosis: a case report with an electron microscopic study. *Eur J Dermatol* 2000; **10**: 52-54 [PMID: 10694300]
- 45 **King JJ**, Brennan KB, Crawford EA, Fox EJ, Ogilvie CM. Surgical complications associated with extensive tumoral calcinosis. *Am J Orthop* 2011; **40**: 247-252 [PMID: 21734933]
- 46 **Davies M**, Clements MR, Mawer EB, Freemont AJ. Tumoral calcinosis: clinical and metabolic response to phosphorus deprivation. *Q J Med* 1987; **63**: 493-503 [PMID: 3659264]
- 47 **Yamaguchi T**, Sugimoto T, Imai Y, Fukase M, Fujita T, Chihara K. Successful treatment of hyperphosphatemic tumoral calcinosis with long-term acetazolamide. *Bone* 1995; **16**: 247S-250S [PMID: 7626311 DOI: 10.1016/S8756-3282(95)80001-8]
- 48 **Lufkin EG**, Wilson DM, Smith LH, Bill NJ, DeLuca HF, Dousa TP, Knox FG. Phosphorus excretion in tumoral calcinosis: response to parathyroid hormone and acetazolamide. *J Clin Endocrinol Metab* 1980; **50**: 648-653 [PMID: 7364922 DOI: 10.1210/jcem-50-4-648]
- 49 **Hamada J**, Tamai K, Ono W, Saotome K. Uremic tumoral calcinosis in hemodialysis patients: clinicopathological findings and identification of calcific deposits. *J Rheumatol* 2006; **33**: 119-126 [PMID: 16395759]
- 50 **Walentynowicz JE**, Mahoney MD, Saldana MJ. Tumoral calcinosis. Case report with treatment failure. *Orthop Rev* 1989; **18**: 687-690 [PMID: 2664669]
- 51 **Thomson JE**, Tanner FH. Tumoral calcinosis. *J Bone Joint Surg Am* 1949; **31A**: 132-140 [PMID: 18122879]
- 52 **Gregosiewicz A**, Warda E. Tumoral calcinosis: successful medical treatment. A case report. *J Bone Joint Surg Am* 1989; **71**: 1244-1249 [PMID: 2777854]
- 53 **Kallmeyer JC**, Seimon LP, MacSearraigh ET. The effect of thyrocalcitonin therapy and phosphate deprivation on tumoral calcinosis. *S Afr Med J* 1978; **54**: 963-966 [PMID: 746428]
- 54 **Seyahi A**, Atalar AC, Ergin HK. Tumoral calcinosis: Clinical and biochemical aspects of a patient treated with vinpocetine. *Eur J Intern Med* 2006; **17**: 436-438 [PMID: 16962954 DOI: 10.1016/j.ejim.2006.02.015]
- 55 **Ueyoshi A**, Ota K. Clinical appraisal of vinpocetine for the removal of intractable tumoral calcinosis in haemodialysis patients with renal failure. *J Int Med Res* 1992; **20**: 435-443 [PMID: 1451924]
- 56 **Minisola S**, Romagnoli E, Rosso R. Massive tumoral calcinosis in a patient on long-term hemodialysis. *J Bone Miner Res* 2000; **15**: 2056-2057 [PMID: 11028461 DOI: 10.1359/jbmr.2000.15.10.2056]
- 57 **Drüeke TB**. A clinical approach to the uraemic patient with extraskeletal calcifications. *Nephrol Dial Transplant* 1996; **11** Suppl 3: 37-42 [PMID: 8840310 DOI: 10.1093/ndt/11.suppl3.37]
- 58 **Phanish MK**, Kallarackal G, Ramanan R, Lawson TM, Baboolal K. Tumoral calcinosis associated with pyrexia and systemic inflammatory response in a haemodialysis patient: successful treatment using intravenous pamidronate. *Nephrol Dial Transplant* 2000; **15**: 1691-1693 [PMID: 11007844 DOI: 10.1093/ndt/15.10.1691]
- 59 **Möckel G**, Buttgereit F, Labs K, Perka C. Tumoral calcinosis revisited: pathophysiology and treatment. *Rheumatol Int* 2005; **25**: 55-59 [PMID: 13680142 DOI: 10.1007/s00296-003-0387-z]
- 60 **Pecovnik-Balon B**, Kramberger S. Tumoral calcinosis in patients on hemodialysis. Case report and review of the literature. *Am J Nephrol* 1997; **17**: 93-95 [PMID: 9057960 DOI: 10.1159/000169078]
- 61 **Tarrass F**, Benjelloun M. Tumoral calcinosis of the elbow in a long-term hemodialysis patient. *Saudi J Kidney Dis Transpl* 2008; **19**: 105-106 [PMID: 18087136]

**P- Reviewer:** Schoenhagen P, Takahashi M **S- Editor:** Ji FF  
**L- Editor:** A **E- Editor:** Lu YJ



## Subclinical cardiovascular disease in type 2 diabetes mellitus: To screen or not to screen

Juan J Chillarón, Juana A Flores-Le Roux, David Benaiges, Juan Pedro-Botet

Juan J Chillarón, Juana A Flores-Le Roux, David Benaiges, Juan Pedro-Botet, Department of Endocrinology and Nutrition, Hospital del Mar, Passeig Marítim 25-29, 08003 Barcelona, Spain  
Juan J Chillarón, Juana A Flores-Le Roux, David Benaiges, Juan Pedro-Botet, Institut Municipal d'Investigacions Mèdiques, Passeig Marítim 25-29, 08003 Barcelona, Spain  
Juan J Chillarón, Juana A Flores-Le Roux, David Benaiges, Juan Pedro-Botet, Departament de Medicina, Universitat Autònoma de Barcelona, 08193 Cerdanyola (NOT Sardañola) del Vallès, Barcelona, Spain

Author contributions: All the authors contributed to this paper.  
Correspondence to: Dr. Juan J Chillarón, Department of Endocrinology and Nutrition, Hospital del Mar, Passeig Marítim, 25-29, 08003 Barcelona, Spain. [jchillaron@parcdesalutmar.cat](mailto:jchillaron@parcdesalutmar.cat)  
Telephone: +34-93-2483902 Fax: +34-93-2483337  
Received: March 26, 2014 Revised: April 30, 2014  
Accepted: July 12, 2014  
Published online: September 16, 2014

### Abstract

The prevalence of type 2 diabetes mellitus (T2DM) has risen in recent decades, and cardiovascular disease remains the leading cause of death in this population. Several clinical trials have demonstrated the benefit of tight control of risk factors on the incidence and mortality of cardiovascular disease. However, in clinical practice, few patients achieve the therapeutic goals. The current diagnostic procedures for subclinical cardiovascular disease in T2DM patients have not been shown to improve prognosis or mortality, probably because they do not categorize cardiovascular risk. Thus, clinical practice guidelines do not systematically recommend screening for subclinical atherosclerosis in these patients, although it is known that patients with extra-coronary atherosclerosis, microangiopathy and poorly-controlled cardiovascular risk factors are at high risk for cardiovascular disease. Improvements in the reliability of diagnostic tests, with fewer side effects and better cost efficiency, may better help to stratify cardiovascular risk in this group of patients, and further evaluation

on this topic should be considered.

© 2014 Baishideng Publishing Group Inc. All rights reserved.

**Key words:** Cardiovascular disease; Type 2 diabetes mellitus; Cardiovascular risk

**Core tip:** The prevalence of type 2 diabetes mellitus (T2DM) has risen in recent decades, and cardiovascular disease remains the leading cause of death in this population. Several clinical trials have demonstrated the benefit of tight control of risk factors on the incidence and mortality of cardiovascular disease. The current diagnostic procedures for subclinical cardiovascular disease in T2DM patients have not been shown to improve prognosis or mortality, probably because they do not categorize cardiovascular risk. Improvements in the reliability of diagnostic tests, with fewer side effects and better cost efficiency, may better help to stratify cardiovascular risk in this group of patients, and further evaluation on this topic should be considered.

Chillarón JJ, Flores-Le Roux JA, Benaiges D, Pedro-Botet J. Subclinical cardiovascular disease in type 2 diabetes mellitus: To screen or not to screen. *World J Clin Cases* 2014; 2(9): 415-421  
Available from: URL: <http://www.wjgnet.com/2307-8960/full/v2/i9/415.htm> DOI: <http://dx.doi.org/10.12998/wjcc.v2.i9.415>

### INTRODUCTION

The prevalence of type 2 diabetes mellitus (T2DM) is rising dramatically in industrialized countries<sup>[1]</sup>. According to the National Health and Nutritional Examination Survey, 19.7 million Americans had diagnosed diabetes, representing 8.3% of the adult population, and an additional 8.2 million were undiagnosed<sup>[2]</sup>. In Europe, population studies report a T2DM prevalence of 13.8%, although many cases are undiagnosed<sup>[3]</sup>. Cardiovascular



disease is the leading cause of mortality and morbidity in this specific population and is responsible for most of the increased health care costs<sup>[4]</sup>. Traditionally, T2DM has been considered a coronary risk equivalent<sup>[5]</sup>. Although this topic is the subject of debate<sup>[6-10]</sup>, there is unanimous agreement that strict control of cardiovascular risk factors in T2DM patients reduces the incidence of cardiovascular disease<sup>[11]</sup>.

T2DM is often associated with several other cardiovascular risk factors. Therefore, cardiovascular prevention in these patients should be multifactorial. Studies assessing the impact of multifactorial risk factor intervention obtained substantial improvements compared with those evaluating single risk factor interventions<sup>[12,13]</sup>.

The effectiveness of a multifactorial intervention was demonstrated in the Steno-2 study, where patients with T2DM and microalbuminuria were randomized to intensive or conventional multifactorial intervention over 7.8 years. A target-driven, long-term, intensified intervention aimed at multiple risk factors, particularly through low-density lipoprotein (LDL) cholesterol lowering and blood pressure control, achieved a 50% reduction in vascular events in this specific population<sup>[11]</sup>.

In addition, many of the benefits of controlling risk factors in patients with T2DM disappear when control ceases, at a similar rate as the benefits are obtained<sup>[13-15]</sup>. For example, in the UKPDS study, patients with newly-diagnosed T2DM who presented an increase in blood pressure levels during follow-up almost immediately had an increase in the risk of cardiovascular episodes<sup>[14]</sup>. Furthermore, intravascular ultrasound studies have shown that coronary atherosclerosis regression is more difficult to attain in patients with diabetes than in those without<sup>[16]</sup>, and therefore prevention and early treatment of the disease are essential.

The proportion of patients achieving therapeutic goals in cardiovascular risk factors in clinical practice<sup>[17]</sup> is very low, mainly in those at high cardiovascular risk, as is the case of patients with T2DM. In this respect, only 28% of T2DM patients reach a blood pressure level < 140/90 mmHg, and 22% less than 130/90 mmHg. Of greater concern is the fact that among known hypertensive patients, 40% did not follow a specific therapeutic strategy. Regarding lipid goals, only 35% of T2DM patients reached on LDL cholesterol concentration below 100 mg/dL. Another alarming fact is that 62% of patients requiring lipid-lowering therapy do not receive pharmacologic treatment<sup>[18]</sup>.

Given the poor risk factor control in clinical practice, it is essential to evaluate strategies for early diagnosis of cardiovascular disease in T2DM patients, especially since the disease is often asymptomatic and has worse prognosis in these subjects than in non-diabetics<sup>[19]</sup>. A substantial percentage of patients with T2DM have silent myocardial ischemia, and these patients are at greater risk for cardiovascular events<sup>[20]</sup>. Therefore, the diagnosis of silent coronary disease may help to identify subjects at very high risk and consequently aid the implementation of

more aggressive risk reduction strategies in this subgroup of patients.

Recent American Diabetes Association (ADA) guidelines<sup>[17]</sup> recommend only advanced or invasive cardiac tests in the presence of typical or atypical symptoms or abnormal baseline electrocardiogram (ECG). The rationale for not indicating screening tests in asymptomatic patients at high cardiovascular risk is simply because these patients are already supposed to be being treated to attain strict metabolic goals, although as previously stated, this is not so in the majority of cases<sup>[18]</sup>. Moreover, we must take into account that technologic progress renders diagnostic techniques increasingly sensitive and less invasive and thus their applicability may vary in the short-mid term. Therefore, we considered it of interest to carry out a review of factors that may predispose to silent cardiovascular disease in T2DM and of diagnostic tests that can be considered in selected cases.

## RISK FACTORS FOR CARDIOVASCULAR DISEASE IN T2DM PATIENTS

The expert consensus published by the ADA in 2007<sup>[21]</sup> defines asymptomatic T2DM patients as being at high risk for myocardial ischemia if they display any of the characteristics shown in Tables 1 and 2.

### *Evidence of other atherosclerotic vascular disease*

Atherosclerosis is a systemic process, and patients with T2DM have a greater atherosclerotic burden at any level of the arterial tree<sup>[22,23]</sup>; therefore, involvement of only one vascular territory is highly unlikely.

Screening for peripheral arterial disease (PAD) is widely accepted and has been extensively implemented in clinical practice. Thus, patients diagnosed with T2DM require an annual evaluation of their feet, including inspection, examination of sensitivity and palpation of pedal pulses and a questionnaire addressed to identify intermittent claudication. Periodic determination of the ankle-brachial index is also recommended<sup>[17]</sup>. Ninety per cent of patients with established PAD have coronary atherosclerosis on angiography<sup>[24]</sup>. In accordance with this observation, the presence of PAD is a predictor of symptomatic coronary artery disease, with a relative risk of 6.6 (95%CI: 2.9-15)<sup>[25]</sup>. Studies in patients who have suffered a stroke showed an 18%-38% prevalence of asymptomatic heart disease<sup>[26-28]</sup>. Thus, patients with extra-coronary atherosclerosis are at high risk of coronary involvement, and therefore screening strategies should be considered along with aggressive treatment of cardiovascular risk factors.

### *Microalbuminuria*

Microalbuminuria and chronic kidney disease are clearly associated with cardiovascular disease. The incidence of coronary heart disease or cardiac death 5 years after kidney failure diagnosis is 40%<sup>[29]</sup>, and the age-adjusted hazard ratio for the development of coronary heart dis-

**Table 1 Clinical characteristics of diabetic patients with increased risk of coronary heart disease**

Evidence of other atherosclerotic vascular disease
Renal disease
Abnormal resting electrocardiogram
Diabetes complications including autonomic neuropathy
Age > 45 yr
Male sex
Traditional risk factors
Blood pressure
Dyslipidemia
Smoking
Inactivity
Abdominal obesity
Novel cardiac risk factors
C-reactive protein
Homocysteine
Lipoprotein(a)

ease is 1.66 (95%CI: 1.24-1.92) when microalbuminuria is present, and may rise to 2.84 (95%CI: 1.80-4.46) in the case of macroalbuminuria<sup>[30]</sup>. Although the pathophysiologic explanation for this association is not fully understood, factors associated with the development of microalbuminuria or renal failure, such as a nocturnal rise in blood pressure, increased lipoprotein(a) and homocysteine levels or elevation of inflammatory markers and insulin resistance could play a role.

In any event, multiple observational studies confirmed this association, and thus patients with T2DM and any renal impairment stage should be considered at high risk for asymptomatic coronary artery disease.

### ECG

Baseline ECG is a rapid, cheap, simple and accessible method of screening for coronary heart disease. The finding of pathologic Q waves, ST-segment changes or left bundle branch block requires further testing to evaluate coronary artery disease in these patients, who should no longer be classified as “asymptomatic”. Unfortunately, the number of cases detected with a baseline ECG alone is very low.

The exercise stress test is widely available in most hospitals and provides useful information regarding the ST-segment abnormalities suggestive of ischemia, although it does not constitute a very powerful marker of prevalent or incident coronary heart disease<sup>[28,31]</sup>. In patients with T2DM, sensitivity for detecting coronary artery disease is 47% and specificity 81%<sup>[32]</sup>. In addition to low sensitivity, the exercise stress test may have a limited role in diabetic patients who are typically deconditioned, overweight and possibly ataxic from peripheral neuropathy. In some studies, over 50% of subjects are not able to complete the exercise stress test<sup>[33]</sup>.

Exercise capacity is probably a more relevant factor, since decreased exercise capacity has been linked to increased mortality and cardiovascular events in healthy people<sup>[34]</sup> and in patients with T2DM, with an odds ratio for coronary heart disease of 2.21 (95%CI: 1.41-3.46)<sup>[35]</sup>.

**Table 2 Key messages**

Cardiovascular disease is the leading cause of mortality in patients with T2DM
Control of cardiovascular risk factors has been shown to significantly reduce the incidence of cardiovascular disease in T2DM patients
Control level of cardiovascular risk factors in patients with T2DM in clinical practice is poor
Systematic screening of cardiovascular disease has not been shown to improve the prognosis of patients with T2DM
In patients with atypical symptoms or ECG abnormalities, cardiovascular disease screening is warranted

T2DM: Type 2 diabetes mellitus; ECG: Electrocardiogram.

### Autonomic neuropathy

Systematic screening for autonomic neuropathy at the time of T2DM diagnosis<sup>[17]</sup> is recommended; however, it is probably the most underdiagnosed chronic complication of diabetes. It is usually associated with other microvascular complications such as retinopathy or nephropathy, and its major clinical manifestations include resting tachycardia, exercise intolerance, orthostatic hypotension, constipation, gastroparesis, erectile dysfunction, sudoriparous dysfunction and hypoglycemia unawareness. In patients with at least one microvascular complication it may be indicated to perform a Valsalva or deep breathing test to assess the presence of cardiac autonomic neuropathy.

Since 1962, it has been assumed that patients with T2DM may have coronary episodes with few or no symptoms, and this has been attributed, at least in part, to possible cardiac denervation due to neuropathy<sup>[36]</sup>. As previously mentioned, the presence of diabetic autonomic neuropathy is a significant predictor of coronary ischemia<sup>[37]</sup>; conversely, between 65% and 92% of diabetic patients with myocardial ischemia have autonomic neuropathy<sup>[38,39]</sup>. Thus, in all T2DM patients, but especially those with other cardiovascular risk factors, it is important to perform routine screening for autonomic neuropathy. Patients with diabetic autonomic neuropathy should undergo cardiac evaluation before initiating more intense physical activity than their usual.

### Retinopathy

As in other microangiopathic complications, the presence of retinopathy is also related to the incidence of coronary artery disease in these patients<sup>[40,41]</sup>. In this regard, after adjusting for age, body mass index, waist circumference, smoking status, lipids, glycosylated hemoglobin, T2DM duration and treatment, the odds ratio for the development of heart disease was 3.75 (95%CI: 2.0-7.4) in men and 3.81 (95%CI: 2.2-7.3) in women with proliferative retinopathy or who had received laser therapy<sup>[41]</sup>. Statistical significance was also maintained after adjustment for the presence of hypertension and nephropathy. In accordance with these results, the relative risk for the prevalence of symptomatic coronary artery disease in patients with established retinopathy was 1.98 (95%CI: 1.44-2.74)<sup>[42]</sup>.

### Traditional risk factors

Typically, patients with T2DM have other classic associated cardiovascular risk factors such as hypertension or dyslipidemia which increase their cardiovascular risk. Therapeutic intervention for these factors contributes to a reduction in vascular risk<sup>[11]</sup>; however, previous studies demonstrated that in clinical practice it is very difficult to achieve the therapeutic goals for these risk factors recommended by clinical guidelines<sup>[18]</sup>.

On the other hand, previous studies suggested that traditional cardiac risk factors are not associated with abnormal stress tests in asymptomatic diabetic patients<sup>[37]</sup>. The Detection of Ischemia in Asymptomatic Diabetics (DIAD) study concluded that markedly abnormal myocardial perfusion results occurred with equal frequency among patients with two or more and less than two risk factors. Thus, the presence or absence of major cardiovascular risk factors is not a suitable parameter to determine which T2DM patients require screening for asymptomatic coronary artery disease.

## SCREENING TESTS

No validated algorithm for the screening of asymptomatic coronary artery disease in T2DM patients has been established. In this respect, choice of the diagnostic procedure will depend on the available scientific evidence, experience in each center and degree of coronary heart disease suspicion, based on the variables mentioned previously. The scientific evidence on the available diagnostic procedures for coronary heart disease: echocardiography, myocardial perfusion imaging and computed tomography for coronary calcium, will be reviewed.

### Echocardiography

Resting echocardiogram is not routinely recommended in normotensive patients since its sensitivity and specificity for coronary heart disease detection are low<sup>[43]</sup>. Severe changes in contractility are more typical of the acute phase of myocardial infarction; moreover, segmental wall abnormalities do not exclusively constitute an ischemic etiology, since they may also be present in patients with non-ischemic heart diseases.

Therefore, resting or stress echocardiography after exercise or dobutamine is not routinely recommended in asymptomatic T2DM patients since no studies have provided data on its benefits. The usefulness of this test is limited to patients with known coronary heart disease to assess reversible ischemia, myocardial viability and risk stratification.

### Myocardial perfusion imaging

Single-photon emission computed tomography after exercise or pharmacologic administration is one of the most widely performed screening tests in asymptomatic T2DM patients. The presence of a fixed or reversible perfusion defect is associated with a three-fold increased risk for cardiovascular episodes in patients over 60 years of age<sup>[44]</sup>. In the DIAD study, participants with type

2 diabetes and no symptoms of CAD were randomly assigned to be screened with adenosine-stress radio-nuclide myocardial perfusion imaging (MPI) or not to be screened and be prospectively followed for a mean period of 5 years. Patients with a normal/low-risk scan showed an annual cardiovascular event incidence of 0.4% compared with 2.4% in those with a moderate to large perfusion defect<sup>[45]</sup>. Therefore, if the benefits of this test, which is minimally invasive and of acceptable cost are considered, it should probably be recommended as a first-line diagnostic procedure for silent myocardial ischemia in T2DM patients.

### Computed tomography

The use of Multi-detector computed tomography (CT) as a noninvasive assessment of the coronary artery tree is becoming more frequent in addition to angiographic methods in patients with or without T2DM diabetes who have had an acute myocardial infarction.

In asymptomatic patients or in those with mild symptoms the assessment of coronary artery calcium (CAC) is most commonly used, which is a specific marker of atherosclerosis. It can be visualized and measured non-invasively by computed tomography. The quantity of calcium within coronary arteries is typically scored as the area affected on the scan, multiplied by a weighting factor depending on the Hounsfield unit density of the calcium deposits<sup>[46]</sup>. Given the radiation exposure, careful patient selection for this test is mandatory. Coronary calcification in men < 40 years of age and in women < 50 years of age is infrequent; therefore, CT scanning is generally not recommended in these age groups. Several studies have shown the coronary artery calcium score to be valuable in identifying patients at high risk of inducible myocardial ischemia<sup>[47,48]</sup>. These studies consistently observed that the likelihood of ischemia in patients with a calcium score  $\leq 100$  is negligible, whereas the probability of inducible ischemia in those with a score of  $\geq 400$  is relatively high, even in oligoasymptomatic patients<sup>[49]</sup>.

The presence of CAC is predictive for future cardiovascular events in both asymptomatic diabetic individuals and in nondiabetic subjects. However, for every increase in CAC, there is a greater increase in the mortality rate for diabetic than for nondiabetic subjects<sup>[50]</sup>. Moreover, diabetic patients with low CAC scores (Agatston Score  $\leq 10$ ) had a low prevalence of inducible myocardial ischemia and a low cardiovascular event rate<sup>[49,50]</sup>. Therefore, assessment of CAC might be useful in identifying diabetic individuals with a low risk of silent myocardial ischemia. Nevertheless, the use of CAC scoring for risk stratification in asymptomatic diabetic patients is not currently endorsed by the ADA recommendations<sup>[17]</sup> since there is insufficient evidence of the long-term benefits of early diagnosis.

## CAN EARLY DIAGNOSIS OF CARDIOVASCULAR DISEASE IMPROVE CARDIOVASCULAR OUTCOMES?

Despite all this evidence, the possible benefits of early



detection of cardiovascular disease in asymptomatic T2DM patients have not been confirmed in randomized trials. In the DIAD study, the cardiac event rates were not significantly reduced by MPI screening for myocardial ischemia<sup>[45]</sup>. Additionally, observational studies have shown that, on occasions, alterations in the coronary arteries of these patients can become spontaneously reversible<sup>[51]</sup>. Finally, studies comparing intensive medical treatment with revascularization procedures showed similar results<sup>[52,53]</sup>. Therefore, from a clinical and cost-benefit point-of-view, there is not enough evidence at present to recommend screening in these patients.

However, it should be taken into account that these studies were conducted in asymptomatic patients diagnosed early with cardiovascular disease. Therefore, both patient compliance and the intensity of monitoring by the physician were higher than those observed in real life, and this fact may have influenced the results. On the other hand, the DIAD study found a six-fold increased incidence of cardiac events in patients with moderate to large perfusion defects compared to those with a normal/low-risk scan<sup>[45]</sup>, which supports the hypothesis that screening for asymptomatic coronary disease can be useful even though the low prevalence could have influenced the statistical power to demonstrate the possible benefits, including cost-benefit.

## DIAGNOSTIC STRATEGY

In the absence of categorical scientific evidence to date, the sequence of tests to be performed in high-risk patients is not established. In this sense, after performing a baseline ECG, the availability of technical and financial resources, and experience in each center can play a role in choosing the most appropriate diagnostic management. Overall, the most common recommendation is to start with a resting ECG and then a myocardial perfusion imaging by SPECT, although the increasingly widespread and cheap use of multi-detector CT can change this trend in the coming years.

## CONCLUSION

Systematic screening for cardiovascular disease in asymptomatic patients with T2DM is not recommended since there is insufficient evidence at present that the benefits of early detection outweigh the costs and side effects of the different diagnostic tests. However, as mentioned previously, this situation may change in the near future given the advances in reliability and efficiency of the different diagnostic tests.

Professionals responsible for the medical care of patients with T2DM should focus on optimizing the control of cardiovascular risk factors and evaluate, only in selected cases, the need to further investigate the presence of cardiovascular disease.

## ACKNOWLEDGMENTS

We thank Miss Christine O'Hara for review of the English version of the manuscript.

## REFERENCES

- 1 Wild S, Roglic G, Green A, Sicree R, King H. Global prevalence of diabetes: estimates for the year 2000 and projections for 2030. *Diabetes Care* 2004; **27**: 1047-1053 [PMID: 15111519 DOI: 10.2337/diacare.27.5.1047]
- 2 Go AS, Mozaffarian D, Roger VL, Benjamin EJ, Berry JD, Blaha MJ, Dai S, Ford ES, Fox CS, Franco S, Fullerton HJ, Gillespie C, Hailpern SM, Heit JA, Howard VJ, Huffman MD, Judd SE, Kissela BM, Kittner SJ, Lackland DT, Lichtman JH, Lisabeth LD, Mackey RH, Magid DJ, Marcus GM, Marelli A, Matchar DB, McGuire DK, Mohler ER, Moy CS, Mussolino ME, Neumar RW, Nichol G, Pandey DK, Paynter NP, Reeves MJ, Sorlie PD, Stein J, Towfighi A, Turan TN, Virani SS, Wong ND, Woo D, Turner MB. Executive summary: heart disease and stroke statistics--2014 update: a report from the American Heart Association. *Circulation* 2014; **129**: 399-410 [PMID: 24446411 DOI: 10.1161/01.cir.0000442015.53336.12]
- 3 Soriguer F, Goday A, Bosch-Comas A, Bordiú E, Calle-Pascual A, Carmena R, Casamitjana R, Castaño L, Castell C, Catalá M, Delgado E, Franch J, Gaztambide S, Gírbés J, Gomis R, Gutiérrez G, López-Alba A, Martínez-Larrad MT, Menéndez E, Mora-Peces I, Ortega E, Pascual-Manich G, Rojo-Martínez G, Serrano-Rios M, Valdés S, Vázquez JA, Vendrell J. Prevalence of diabetes mellitus and impaired glucose regulation in Spain: the Di@bet.es Study. *Diabetologia* 2012; **55**: 88-93 [PMID: 21987347 DOI: 10.1007/s00125-011-2336-9]
- 4 Hogan P, Dall T, Nikolov P. Economic costs of diabetes in the US in 2002. *Diabetes Care* 2003; **26**: 917-932 [PMID: 12610059 DOI: 10.2337/diacare.26.3.917]
- 5 Haffner SM, Lehto S, Rönkämaa T, Pyörälä K, Laakso M. Mortality from coronary heart disease in subjects with type 2 diabetes and in nondiabetic subjects with and without prior myocardial infarction. *N Engl J Med* 1998; **339**: 229-234 [PMID: 9673301 DOI: 10.1056/NEJM199807233390404]
- 6 Cano JF, Baena-Diez JM, Franch J, Vila J, Tello S, Sala J, Elosua R, Marrugat J; REGICOR and GEDAPS Investigators. Long-term cardiovascular risk in type 2 diabetic compared with nondiabetic first acute myocardial infarction patients: a population-based cohort study in southern Europe. *Diabetes Care* 2010; **33**: 2004-2009 [PMID: 20530746 DOI: 10.2337/dc10-0560]
- 7 Evans JM, Wang J, Morris AD. Comparison of cardiovascular risk between patients with type 2 diabetes and those who had had a myocardial infarction: cross sectional and cohort studies. *BMJ* 2002; **324**: 939-942 [PMID: 11964337 DOI: 10.1136/bmj.324.7343.939]
- 8 Lee CD, Folsom AR, Pankow JS, Brancati FL; Atherosclerosis Risk in Communities [ARIC] Study Investigators. Cardiovascular events in diabetic and nondiabetic adults with or without history of myocardial infarction. *Circulation* 2004; **109**: 855-860 [PMID: 14757692 DOI: 10.1161/01.CIR.0000116389.61864.DE]
- 9 Pajunen P, Koukkunen H, Ketonen M, Jerkkola T, Immonen-Räihä P, Kärjä-Koskenkari P, Kuulasmaa K, Palomäki P, Mustonen J, Lehtonen A, Arstila M, Vuorenmaa T, Lehto S, Miettinen H, Torppa J, Tuomilehto J, Kesäniemi YA, Pyörälä K, Salomaa V. Myocardial infarction in diabetic and non-diabetic persons with and without prior myocardial infarction: the FINAMI Study. *Diabetologia* 2005; **48**: 2519-2524 [PMID: 16247597 DOI: 10.1007/s00125-005-0019-0]
- 10 Natarajan S, Liao Y, Sinha D, Cao G, McGee DL, Lipsitz SR. Sex differences in the effect of diabetes duration on coronary



- heart disease mortality. *Arch Intern Med* 2005; **165**: 430-435 [PMID: 15738373 DOI: 10.1001/archinte.165.4.430]
- 11 **Gaede P**, Vedel P, Larsen N, Jensen GV, Parving HH, Pedersen O. Multifactorial intervention and cardiovascular disease in patients with type 2 diabetes. *N Engl J Med* 2003; **348**: 383-393 [PMID: 12556541 DOI: 10.1056/NEJMoa021778]
  - 12 **Yusuf S**. Two decades of progress in preventing vascular disease. *Lancet* 2002; **360**: 2-3 [PMID: 12114031 DOI: 10.1016/S0140-6736(02)09358-3]
  - 13 **Stratton IM**, Cull CA, Adler AI, Matthews DR, Neil HA, Holman RR. Additive effects of glycaemia and blood pressure exposure on risk of complications in type 2 diabetes: a prospective observational study (UKPDS 75). *Diabetologia* 2006; **49**: 1761-1769 [PMID: 16736131 DOI: 10.1007/s00125-006-0297-1]
  - 14 **Gaede P**, Pedersen O. Intensive integrated therapy of type 2 diabetes: implications for long-term prognosis. *Diabetes* 2004; **53** Suppl 3: S39-S47 [PMID: 15561920 DOI: 10.2337/diabetes.53.suppl\_3.S39]
  - 15 **Vaag AA**. Glycemic control and prevention of microvascular and macrovascular disease in the Steno 2 study. *Endocr Pract* 2006; **12** Suppl 1: 89-92 [PMID: 16627389 DOI: 10.4158/EP.12.S1.89]
  - 16 **Nicholls SJ**, Tuzcu EM, Kalidindi S, Wolski K, Moon KW, Sipahi I, Schoenhagen P, Nissen SE. Effect of diabetes on progression of coronary atherosclerosis and arterial remodeling: a pooled analysis of 5 intravascular ultrasound trials. *J Am Coll Cardiol* 2008; **52**: 255-262 [PMID: 18634979 DOI: 10.1016/j.jacc.2008.03.051]
  - 17 **American Diabetes Association**. Standards of medical care in diabetes--2014. *Diabetes Care* 2014; **37** Suppl 1: S14-S80 [PMID: 24357209 DOI: 10.2337/dc14-S014]
  - 18 **Navarro-Vidal B**, Banegas JR, León-Muñoz LM, Rodríguez-Artalejo F, Graciani A. Achievement of cardiometabolic goals among diabetic patients in Spain. A nationwide population-based study. *PLoS One* 2013; **8**: e61549 [PMID: 23637851]
  - 19 **Jouven X**, Lemaître RN, Rea TD, Sotoodehnia N, Empana JP, Siscovick DS. Diabetes, glucose level, and risk of sudden cardiac death. *Eur Heart J* 2005; **26**: 2142-2147 [PMID: 15980034 DOI: 10.1093/eurheartj/ehi376]
  - 20 **Cosson E**, Nguyen MT, Chanu B, Banu I, Chiheb S, Balta C, Takkou K, Valensi P. Cardiovascular risk prediction is improved by adding asymptomatic coronary status to routine risk assessment in type 2 diabetic patients. *Diabetes Care* 2011; **34**: 2101-2107 [PMID: 21775753 DOI: 10.2337/dc11-0480]
  - 21 **Bax JJ**, Young LH, Frye RL, Bonow RO, Steinberg HO, Barrett EJ. Screening for coronary artery disease in patients with diabetes. *Diabetes Care* 2007; **30**: 2729-2736 [PMID: 17901530 DOI: 10.2337/dc07-9927]
  - 22 **Nicholls SJ**, Tuzcu EM, Crowe T, Sipahi I, Schoenhagen P, Kapadia S, Hazen SL, Wun CC, Norton M, Ntanos F, Nissen SE. Relationship between cardiovascular risk factors and atherosclerotic disease burden measured by intravascular ultrasound. *J Am Coll Cardiol* 2006; **47**: 1967-1975 [PMID: 16697312 DOI: 10.1016/j.jacc.2005.12.058]
  - 23 **Gorter PM**, Visseren FL, Algra A, van der Graaf Y; SMART Study Group. The impact of site and extent of clinically evident cardiovascular disease and atherosclerotic burden on new cardiovascular events in patients with Type 2 diabetes. The SMART study. *Diabet Med* 2007; **24**: 1352-1360 [PMID: 18042079 DOI: 10.1111/j.1464-5491.2007.02323.x]
  - 24 **Golomb BA**, Dang TT, Criqui MH. Peripheral arterial disease: morbidity and mortality implications. *Circulation* 2006; **114**: 688-699 [PMID: 16908785 DOI: 10.1161/CIRCULATIONAHA.105.593442]
  - 25 **Criqui MH**, Langer RD, Fronek A, Feigelson HS, Klauber MR, McCann TJ, Browner D. Mortality over a period of 10 years in patients with peripheral arterial disease. *N Engl J Med* 1992; **326**: 381-386 [PMID: 1729621 DOI: 10.1056/NEJM199202063260605]
  - 26 **Ahn SS**, Nam HS, Heo JH, Kim YD, Lee SK, Han KH, Choi BW, Kim EY. Ischemic stroke: measurement of intracranial artery calcifications can improve prediction of asymptomatic coronary artery disease. *Radiology* 2013; **268**: 842-849 [PMID: 23674788 DOI: 10.1148/radiol.13122417]
  - 27 **Calvet D**, Touzé E, Varenne O, Sablayrolles JL, Weber S, Mas JL. Prevalence of asymptomatic coronary artery disease in ischemic stroke patients: the PRECORIS study. *Circulation* 2010; **121**: 1623-1629 [PMID: 20351236 DOI: 10.1161/CIRCULATIONAHA.109.906958]
  - 28 **Amarenco P**, Lavallée PC, Labreuche J, Ducrocq G, Juliard JM, Feldman L, Cabrejo L, Meseguer E, Guidoux C, Adraï V, Ratani S, Kusmirek J, Lapergue B, Klein IF, Gongora-Rivera F, Jaramillo A, Mazighi M, Touboul PJ, Steg PG. Prevalence of coronary atherosclerosis in patients with cerebral infarction. *Stroke* 2011; **42**: 22-29 [PMID: 21088246 DOI: 10.1161/STROKEAHA.110.584086]
  - 29 **Mann JF**, Gerstein HC, Pogue J, Bosch J, Yusuf S. Renal insufficiency as a predictor of cardiovascular outcomes and the impact of ramipril: the HOPE randomized trial. *Ann Intern Med* 2001; **134**: 629-636 [PMID: 11304102 DOI: 10.7326/0003-4819-134-8-200104170-00007]
  - 30 **Yuyun MF**, Khaw KT, Luben R, Welch A, Bingham S, Day NE, Wareham NJ. A prospective study of microalbuminuria and incident coronary heart disease and its prognostic significance in a British population: the EPIC-Norfolk study. *Am J Epidemiol* 2004; **159**: 284-293 [PMID: 14742289 DOI: 10.1093/aje/kwh037]
  - 31 **Gianrossi R**, Detrano R, Mulvihill D, Lehmann K, Dubach P, Colombo A, McArthur D, Froelicher V. Exercise-induced ST depression in the diagnosis of coronary artery disease. A meta-analysis. *Circulation* 1989; **80**: 87-98 [PMID: 2661056 DOI: 10.1161/01.CIR.80.1.87]
  - 32 **Lee DP**, Fearon WF, Froelicher VF. Clinical utility of the exercise ECG in patients with diabetes and chest pain. *Chest* 2001; **119**: 1576-1581 [PMID: 11348969 DOI: 10.1378/chest.119.5.1576]
  - 33 **Vanzetto G**, Halimi S, Hammoud T, Fagret D, Benhamou PY, Cordonnier D, Denis B, Machecourt J. Prediction of cardiovascular events in clinically selected high-risk NIDDM patients. Prognostic value of exercise stress test and thallium-201 single-photon emission computed tomography. *Diabetes Care* 1999; **22**: 19-26 [PMID: 10333898 DOI: 10.2337/diacare.22.1.19]
  - 34 **Kodama S**, Saito K, Tanaka S, Maki M, Yachi Y, Asumi M, Sugawara A, Totsuka K, Shimano H, Ohashi Y, Yamada N, Sone H. Cardiorespiratory fitness as a quantitative predictor of all-cause mortality and cardiovascular events in healthy men and women: a meta-analysis. *JAMA* 2009; **301**: 2024-2035 [PMID: 19454641 DOI: 10.1001/jama.2009.681]
  - 35 **Lyerly GW**, Sui X, Church TS, Lavie CJ, Hand GA, Blair SN. Maximal exercise electrocardiography responses and coronary heart disease mortality among men with diabetes mellitus. *Circulation* 2008; **117**: 2734-2742 [PMID: 18490521 DOI: 10.1161/CIRCULATIONAHA.107.729277]
  - 36 **Bradley RF**, Schonfeld A. Diminished pain in diabetic patients with acute myocardial infarction. *Geriatrics* 1962; **17**: 322-326 [PMID: 13872329]
  - 37 **Wackers FJ**, Young LH, Inzucchi SE, Chyun DA, Davey JA, Barrett EJ, Taillefer R, Wittlin SD, Heller GV, Filipchuk N, Engel S, Ratner RE, Iskandrian AE. Detection of silent myocardial ischemia in asymptomatic diabetic subjects: the DIAD study. *Diabetes Care* 2004; **27**: 1954-1961 [PMID: 15277423 DOI: 10.2337/diacare.27.8.1954]
  - 38 **Murray DP**, O'Brien T, Mulrooney R, O'Sullivan DJ. Autonomic dysfunction and silent myocardial ischaemia on exercise testing in diabetes mellitus. *Diabet Med* 1990; **7**: 580-584 [PMID: 2146063 DOI: 10.1111/j.1464-5491.1990.tb01452.x]

- 39 **O'Sullivan JJ**, Conroy RM, MacDonald K, McKenna TJ, Maurer BJ. Silent ischaemia in diabetic men with autonomic neuropathy. *Br Heart J* 1991; **66**: 313-315 [PMID: 1747285 DOI: 10.1136/hrt.66.4.313]
- 40 **Cheung N**, Wang JJ, Klein R, Couper DJ, Sharrett AR, Wong TY. Diabetic retinopathy and the risk of coronary heart disease: the Atherosclerosis Risk in Communities Study. *Diabetes Care* 2007; **30**: 1742-1746 [PMID: 17389333 DOI: 10.2337/dc07-0264]
- 41 **Targher G**, Bertolini L, Zenari L, Lippi G, Pichiri I, Zoppini G, Muggeo M, Arcaro G. Diabetic retinopathy is associated with an increased incidence of cardiovascular events in Type 2 diabetic patients. *Diabet Med* 2008; **25**: 45-50 [PMID: 18199131 DOI: 10.1111/j.1464-5491.2007.02327.x]
- 42 **Kawasaki S**, Misawa H, Tamura Y, Kondo Y, Satoh S, Hasegawa O, Kato S, Terauchi Y. Relationship between coronary artery disease and retinopathy in patients with type 2 diabetes mellitus. *Intern Med* 2013; **52**: 2483-2487 [PMID: 24240785 DOI: 10.2169/internalmedicine.52.9444]
- 43 **Greenland P**, Alpert JS, Beller GA, Benjamin EJ, Budoff MJ, Fayad ZA, Foster E, Hlatky MA, Hodgson JM, Kushner FG, Lauer MS, Shaw LJ, Smith SC, Taylor AJ, Weintraub WS, Wenger NK, Jacobs AK, Smith SC, Anderson JL, Albert N, Buller CE, Creager MA, Ettinger SM, Guyton RA, Halperin JL, Hochman JS, Kushner FG, Nishimura R, Ohman EM, Page RL, Stevenson WG, Tarkington LG, Yancy CW. 2010 ACCF/AHA guideline for assessment of cardiovascular risk in asymptomatic adults: a report of the American College of Cardiology Foundation/American Heart Association Task Force on Practice Guidelines. *J Am Coll Cardiol* 2010; **56**: e50-103 [PMID: 21144964 DOI: 10.1016/j.jacc.2010.09.001]
- 44 **Valensi P**, Pariès J, Brulport-Cerisier V, Torremocha F, Sachs RN, Vanzetto G, Cosson E, Lormeau B, Attali JR, Maréchaud R, Estour B, Halimi S. Predictive value of silent myocardial ischemia for cardiac events in diabetic patients: influence of age in a French multicenter study. *Diabetes Care* 2005; **28**: 2722-2727 [PMID: 16249546 DOI: 10.2337/diabetes.28.11.2722]
- 45 **Young LH**, Wackers FJ, Chyun DA, Davey JA, Barrett EJ, Taillefer R, Heller GV, Iskandrian AE, Wittlin SD, Filipchuk N, Ratner RE, Inzucchi SE. Cardiac outcomes after screening for asymptomatic coronary artery disease in patients with type 2 diabetes: the DIAD study: a randomized controlled trial. *JAMA* 2009; **301**: 1547-1555 [PMID: 19366774 DOI: 10.1001/jama.2009.476]
- 46 **Nasir K**, Budoff MJ, Post WS, Fishman EK, Mahesh M, Lima JA, Blumenthal RS. Electron beam CT versus helical CT scans for assessing coronary calcification: current utility and future directions. *Am Heart J* 2003; **146**: 969-977 [PMID: 14660987 DOI: 10.1016/S0002-8703(03)00450-2]
- 47 **Berman DS**, Wong ND, Gransar H, Miranda-Peats R, Dahlbeck J, Hayes SW, Friedman JD, Kang X, Polk D, Hachamovitch R, Shaw L, Rozanski A. Relationship between stress-induced myocardial ischemia and atherosclerosis measured by coronary calcium tomography. *J Am Coll Cardiol* 2004; **44**: 923-930 [PMID: 15312881 DOI: 10.1016/j.jacc.2004.06.042]
- 48 **He ZX**, Hedrick TD, Pratt CM, Verani MS, Aquino V, Roberts R, Mahmarian JJ. Severity of coronary artery calcification by electron beam computed tomography predicts silent myocardial ischemia. *Circulation* 2000; **101**: 244-251 [PMID: 10645919 DOI: 10.1161/01.CIR.101.3.244]
- 49 **Anand DV**, Lim E, Hopkins D, Corder R, Shaw LJ, Sharp P, Lipkin D, Lahiri A. Risk stratification in uncomplicated type 2 diabetes: prospective evaluation of the combined use of coronary artery calcium imaging and selective myocardial perfusion scintigraphy. *Eur Heart J* 2006; **27**: 713-721 [PMID: 16497686 DOI: 10.1093/eurheartj/ehi808]
- 50 **Raggi P**, Shaw LJ, Berman DS, Callister TQ. Prognostic value of coronary artery calcium screening in subjects with and without diabetes. *J Am Coll Cardiol* 2004; **43**: 1663-1669 [PMID: 15120828 DOI: 10.1016/j.jacc.2003.09.068]
- 51 **Wackers FJ**, Chyun DA, Young LH, Heller GV, Iskandrian AE, Davey JA, Barrett EJ, Taillefer R, Wittlin SD, Filipchuk N, Ratner RE, Inzucchi SE. Resolution of asymptomatic myocardial ischemia in patients with type 2 diabetes in the Detection of Ischemia in Asymptomatic Diabetics (DIAD) study. *Diabetes Care* 2007; **30**: 2892-2898 [PMID: 17682123 DOI: 10.2337/dc07-1250]
- 52 **Boden WE**, O'Rourke RA, Teo KK, Hartigan PM, Maron DJ, Kostuk WJ, Knudtson M, Dada M, Casperson P, Harris CL, Chaitman BR, Shaw L, Gosselin G, Nawaz S, Title LM, Gau G, Blaustein AS, Booth DC, Bates ER, Spertus JA, Berman DS, Mancini GB, Weintraub WS. Optimal medical therapy with or without PCI for stable coronary disease. *N Engl J Med* 2007; **356**: 1503-1516 [PMID: 17387127 DOI: 10.1056/NEJMoa070829]
- 53 **BARI 2D Study Group**; Frye RL, August P, Brooks MM, Hardison RM, Kelsey SF, MacGregor JM, Orchard TJ, Chaitman BR, Genuth SM, Goldberg SH, Hlatky MA, Jones TL, Molitch ME, Nesto RW, Sako EY, Sobel BE. A randomized trial of therapies for type 2 diabetes and coronary artery disease. *N Engl J Med* 2009; **360**: 2503-2515 [PMID: 19502645 DOI: 10.1056/NEJMoa0805796]

**P- Reviewer:** Okumura K, Toro R, Vasarhelyi B, Wan Y  
**S- Editor:** Song XX **L- Editor:** A **E- Editor:** Lu YJ



## Extraskkeletal symptoms and comorbidities of diffuse idiopathic skeletal hyperostosis

Rabia Terzi

Rabia Terzi, Derince Training and Research Hospital, Department of Physical Medicine and Rehabilitation, Kocaeli 41 300, Turkey

Author contributions: Terzi R solely contributed to this article.  
Correspondence to: Rabia Terzi, MD, Derince Training and Research Hospital, Department of Physical Medicine and Rehabilitation, Orhan Mh. Devran Caddesi.Bağkule Evleri B2 blok İzmit, Kocaeli 41 300, Turkey. [drabia1@yahoo.com](mailto:drabia1@yahoo.com)

Telephone: +90-505-3515572

Receive: April 12, 2014 Revised: June 30, 2014

Accepted: July 25, 2014

Published online: September 16, 2014

established, limited data on extraskkeletal signs and comorbidities are available. In this article, we review extraskkeletal symptoms and associated comorbidities in patients with DISH in the light of the literature.

Terzi R. Extraskkeletal symptoms and comorbidities of diffuse idiopathic skeletal hyperostosis. *World J Clin Cases* 2014; 2(9): 422-425 Available from: URL: <http://www.wjgnet.com/2307-8960/full/v2/i9/422.htm> DOI: <http://dx.doi.org/10.12998/wjcc.v2.i9.422>

### Abstract

Diffuse idiopathic skeletal hyperostosis (DISH) is a non-inflammatory disease characterized by calcification and ossification of soft tissues, mainly entheses and spinal ligaments. The clinical presentation primarily includes spinal involvement-induced pain and range of motion. Although rare, life-threatening gastrointestinal, respiratory or neurological events or severe morbidity due to bone compression on the adjacent structures may develop. There is a limited amount of data on DISH-related events in the literature. In recent years, comorbid metabolic disorders are of great interest in patients with DISH. The early diagnosis of these conditions as well as rare entities allows an effective multidisciplinary approach for the treatment of DISH. In this article, we review extraskkeletal symptoms and associated comorbidities in patients with DISH.

© 2014 Baishideng Publishing Group Inc. All rights reserved.

**Key words:** Diffuse idiopathic skeletal hyperostosis; Swallowing; Respiratory symptoms; Neurological symptoms; Comorbidities

**Core tip:** Although diffuse idiopathic skeletal hyperostosis (DISH)-related skeletal symptoms are well-

### INTRODUCTION

Diffuse idiopathic skeletal hyperostosis (DISH) is a non-inflammatory disease characterized by calcification and ossification of soft tissues such as ligaments, tendons and fasciae with an unknown etiology<sup>[1]</sup>. The prevalence which increases with age<sup>[1]</sup> has been reported to be 2.8% and 2.6% in men and women aged  $\geq 40$  years, respectively<sup>[2]</sup>. The diagnosis is based on the presence of involvement of at least four contiguous thoracic vertebral segments, preservation of intervertebral disc spaces, and the absence of apophyseal joint degeneration or sacroiliac inflammatory changes<sup>[3]</sup>.

Clinical manifestations of the disease vary depending on the involvement site. It may also present asymptotically. The axial skeleton is the most commonly affected site at 70%. Thoracic involvement is the most common manifestation of DISH, while the cervical spine is minimally involved<sup>[4,5]</sup>. In addition, DISH is not limited to axial skeleton involvement. Other anatomical structures affected by the disease include the pelvis, patella, calcaneus bone or olecranon<sup>[5]</sup>. The majority of symptoms occurs due to altered biomechanics of the skeleton, leading to pain, stiffness and restricted range of motion (ROM) of the axial or peripheral joints. Moreover, respiratory, gastrointestinal and neurological symptoms may develop

due to bone compression of the adjacent structures<sup>[6,7]</sup>. The incidence of metabolic disorders, such as metabolic syndrome, diabetes and obesity, has been reported to be increased in patients with DISH<sup>[8]</sup>. Therefore, it is of the utmost importance that symptoms other than pain and limited ROM and comorbidities should be identified and a multisystemic therapy should be tailored for each patient. In this article, we review extraskelatal symptoms and associated comorbidities in patients with DISH.

## SWALLOWING AND RESPIRATORY SYMPTOMS

Cervical involvement has been reported to be 75% in patients with DISH<sup>[9]</sup>. Cervical osteophytes are usually asymptomatic<sup>[10]</sup>. The swallowing function is primarily affected in cases of symptomatic manifestations. The size and location of the bone spurs may vary. In the presence of upper cervical spine involvement (C3-4), laryngeal functions are mostly affected<sup>[11]</sup>. However, spasm or obstruction of the esophageal sphincter may occur in the presence of distal involvement<sup>[12]</sup>. McCaffrey showed that there was no relationship between the size of the bone spurs and severity of the symptoms<sup>[13]</sup>. Dysphagia is the most common complaint in these patients. Dysphagia typically results from esophageal compression by the osteophytes exerting a mass effect<sup>[14]</sup>, recurrent laryngeal nerve injury-related neuropathy<sup>[15]</sup>, and esophageal fibrosis and inflammation secondary to osteophyte irritation<sup>[16]</sup>. As the incidence of DISH increases with age, dysphagia should be considered particularly in the elderly<sup>[17]</sup>.

Furthermore, tracheal compression of the giant osteophytes may lead to acute or progressive airway obstruction. Caminos *et al*<sup>[18]</sup> reported a case admitted with acute onset respiratory failure and diagnosed with DISH. The patient suffered from shortness of breath in the supine position. Cervical lateral X-ray revealed a large osteophyte which compressed the trachea. The authors concluded that DISH should be kept in mind particularly in elderly patients with unexplained respiratory distress<sup>[18]</sup>. In another study, Nelson *et al*<sup>[19]</sup> reported three cases requiring tracheotomy due to acute airway obstruction. Gokce *et al*<sup>[20]</sup> also described a case of DISH with postoperative stridor and respiratory distress due to cricoarytenoid joint fixation and right vocal cord paresis following total knee arthroplasty. Respiratory distress was reported to be induced by venous compression, nerve compression, cricoarytenoid joint fixation, post-cricoid ulceration and edema<sup>[21]</sup>.

In a study including 204 patients with DISH between 1980 and 2009, Verlaan *et al*<sup>[8]</sup> reported dysphagia and airway obstruction in the study population. However, the authors found no relationship between age and the degree of dysphagia or airway obstruction. One or more of the imaging studies including cervical X-ray, barium swallow, computed tomography (CT), laryngoscopy and magnetic resonance imaging (MRI) were performed.

As DISH is mostly seen in the elderly, endoscopic in-

spection of the upper gastrointestinal system is critical in the differential diagnosis of malignancies. However, caution should be exercised during endoscopy with a gentle pressure. Otherwise, iatrogenic pharyngoesophageal perforation may occur<sup>[22]</sup>. Non-surgical treatments include dietary modification (fluid and soft food intake), anti-reflux medications, gastroprotectants and percutaneous endoscopic gastrostomy tube placement<sup>[8]</sup>. On the other hand, surgical treatment options are anterolateral, lateral or transpharyngeal resection of the ossification. Also, spinal decompression, discectomy and spinal fusion are additional surgical procedures. There are no statistically significant differences in the sex, duration of symptoms, and the number of affected vertebrae between surgically and non-surgically treated patients<sup>[8]</sup>. However, a higher number of younger patients with severe symptoms were primarily operated on. Respiratory and swallowing functions were improved in most patients following surgery<sup>[8]</sup>.

## NEUROLOGICAL SYMPTOMS

Neurological symptoms which are rarely seen include decreased flexibility of the spine and narrowed spinal canal-related myelopathy due to anterior and posterior longitudinal ligament calcification<sup>[23]</sup>. Myelopathy is often associated with narrowing of the lower cervical vertebral canal<sup>[23]</sup>. Lumbar spinal canal stenosis was also reported in the literature<sup>[24]</sup>. The craniocervical junction is rarely involved. It is mainly caused by atlantoaxial dislocation or pseudoarthrosis between the spinal process of the axis and the posterior tubercle of the atlas<sup>[25]</sup>. In addition, there is a case of DISH with retro-odontoid pseudotumor-induced progressive myelopathy in the literature<sup>[26]</sup>. Retro-odontoid pseudotumors can be defined as lesions caused by inflammatory granulation or reactive soft tissue hypertrophy from chronic atlantoaxial subluxation. These patients may present with post-traumatic neurological symptoms<sup>[26]</sup>. Eser *et al*<sup>[27]</sup> described a surgically-treated case of central cord syndrome after a minor trauma. The patient had no cervical dislocation or fracture. However, MRI demonstrated spinal cord edema and myelomalacic segments. Koizumi *et al*<sup>[28]</sup> reported another case of myelopathy due to multilevel cervical canal stenosis. Such patients may suffer from spinal fractures and neurological deficit after a minor trauma. These fractures can be easily overlooked since they progress to a neurological deficit over time with a limited initial clinical presentation. This can be attributed to the fact that the mortality rate of DISH patients with spinal fractures has been reported to be nearly 20%<sup>[29]</sup>. Vengust *et al*<sup>[30]</sup> reported a case of DISH in whom post-trauma fracture dislocation developed at the third and fourth cervical vertebrae. Respiratory failure was triggered by vocal cord paralysis due to laryngeal nerve entrapment at six months<sup>[30]</sup>.

In addition to neurological complications, the incidence of stroke was reported to be increased in patients with DISH<sup>[31]</sup>. In a study including a total of 90 patients, 45 with DISH and 45 with cervical spondylosis, MRI



revealed a higher incidence of infarction in patients with DISH. Magnetic resonance angiography also showed a higher incidence of major cerebral artery stenosis and occlusion in these patients. Based on these data, the authors concluded that patients with DISH had an increased risk for stroke as well<sup>[31]</sup>. In another report, a 53-year-old case with DISH was admitted with motor and sensory polyneuropathy<sup>[32]</sup>. It was associated with the metabolic disturbance in this patient population. Moreover, another case with DISH presenting with thoracic outlet syndrome-associated findings is available in the literature<sup>[33]</sup>.

## MISCELLANEOUS SYMPTOMS

Other symptoms of DISH include dysphonia, weight loss, odynophagia, reflux disease, snoring, aphonia, choking, pharyngeal perforation, difficult intubation and aspiration pneumonia<sup>[8]</sup>.

## DIFFUSE IDIOPATHIC SKELETAL HYPEROSTOSIS-ASSOCIATED METABOLIC COMORBIDITIES

The relationship between DISH and metabolic status has been shown. The incidence of DISH is higher in patients with diabetes, hypertension, hyperlipidemia, hyperinsulinemia, metabolic syndrome or obesity<sup>[34]</sup>. Vezyroglo *et al*<sup>[35]</sup> determined that metabolic abnormalities occurred in 70% of patients diagnosed with DISH and 45% in the control group. Hyperlipidemia and hyperuricemia associated with diabetes have been found frequently in patients diagnosed with DISH. Combined metabolic features of diabetes mellitus and dyslipidemia, diabetes mellitus and hyperuricemia, or diabetes mellitus and dyslipidemia and hyperuricemia were shown to be the main risk factor for DISH<sup>[35]</sup>. Mader<sup>[35]</sup> reported that patients diagnosed with DISH have a higher metabolic syndrome rate than the control group. Eckertova *et al*<sup>[36]</sup> reported that non-esterified fatty acids, insulinogenic index and insulin/C-peptide ratio decrease in patients diagnosed with nondiabetic DISH. These patients have identified impaired pancreatic beta-cell stimulation and increased hepatic insulin extraction. Eckertova *et al*<sup>[36]</sup> suggested that if these conditions persist for a long time, it might lead to a decreased ability of insulin to maintain a normal serum glucose level and consequently to insulin resistance which is highly prevalent in symptomatic DISH patients.

## DIFFUSE IDIOPATHIC SKELETAL HYPEROSTOSIS-ASSOCIATED CARDIOVASCULAR COMORBIDITIES

It has been reported that hypertension, atrial fibrillation, left ventricular hypertrophy and peripheral arterial disease increased<sup>[10,37,38]</sup> in patients diagnosed with DISH. Mader *et al*<sup>[16]</sup> reported that the 10 year coronary heart

disease risk of patients with DISH is significantly higher than the control group. Zincarell *et al*<sup>[39]</sup> suggest that DISH prevalence was found to be 30.3% in patients with severe cardiovascular disease. A lot of studies reported that DISH carries a risk for stroke and cerebrovascular diseases.

## REFERENCES

- Holton KF, Denard PJ, Yoo JU, Kado DM, Barrett-Connor E, Marshall LM. Diffuse idiopathic skeletal hyperostosis and its relation to back pain among older men: the MrOS Study. *Semin Arthritis Rheum* 2011; **41**: 131-138 [PMID: 21377195 DOI: 10.1016/j.semarthrit.2011.01.001]
- Julkunen H, Heinonen OP, Knekt P, Maatela J. The epidemiology of hyperostosis of the spine together with its symptoms and related mortality in a general population. *Scand J Rheumatol* 1975; **4**: 23-27 [PMID: 1153976 DOI: 10.3109/03009747509095610]
- Resnick D, Niwayama G. Radiographic and pathologic features of spinal involvement in diffuse idiopathic skeletal hyperostosis (DISH). *Radiology* 1976; **119**: 559-568 [PMID: 935390 DOI: 10.1148/119.3.559]
- Utsinger PD. Diffuse idiopathic skeletal hyperostosis. *Clin Rheum Dis* 1985; **11**: 325-351 [PMID: 3899489]
- Cammisa M, De Serio A, Guglielmi G. Diffuse idiopathic skeletal hyperostosis. *Eur J Radiol* 1998; **27** Suppl 1: S7-11 [PMID: 9652495 DOI: 10.1016/S0720-048X(98)00036-9]
- Hassard AD. Cervical ankylosing hyperostosis and airway obstruction. *Laryngoscope* 1984; **94**: 966-968 [PMID: 6738279 DOI: 10.1288/00005537-198407000-00021]
- Kurtaran A, Özdemir S, Selçuk B, Yildirim O, Degirmenci I, Akyüz M. Servikal Bölgedeki Yaygın İdiopatik İskelet Hipertostozuna Bağlı Gelişen Santral Kord Sendromu Türk. *J Phys Med Rehab* 2012; **58**: 326-8 [DOI: 10.4274/tftr.64872]
- Verlaan JJ, Boswijk PF, de Ru JA, Dhert WJ, Oner FC. Diffuse idiopathic skeletal hyperostosis of the cervical spine: an underestimated cause of dysphagia and airway obstruction. *Spine J* 2011; **11**: 1058-1067 [PMID: 22015236 DOI: 10.1016/j.spinee.2011.09.014]
- Sreedharan S, Li YH. Diffuse idiopathic skeletal hyperostosis with cervical spinal cord injury -a report of 3 cases and a literature review. *Ann Acad Med Singapore* 2005; **34**: 257-261 [PMID: 15902347]
- Kos MP, van Royen BJ, David EF, Mahieu HF. Anterior cervical osteophytes resulting in severe dysphagia and aspiration: two case reports and literature review. *J Laryngol Otol* 2009; **123**: 1169-1173 [PMID: 19393122 DOI: 10.1017/S0022215109005246]
- Jones B, Donner MW. Imaging in Diagnosis and Therapy. New-York, NY: Springer Verlag, 1991: Normal and Abnormal Swallowing
- Giger R, Dulguerov P, Payer M. Anterior cervical osteophytes causing dysphagia and dyspnea: an uncommon entity revisited. *Dysphagia* 2006; **21**: 259-263 [PMID: 17216390 DOI: 10.1007/s00455-006-9049-0]
- McCafferty RR, Harrison MJ, Tamas LB, Larkins MV. Ossification of the anterior longitudinal ligament and Forestier's disease: an analysis of seven cases. *J Neurosurg* 1995; **83**: 13-17 [PMID: 7782829 DOI: 10.3171/jns.1995.83.1.0013]
- Masiero S, Padoan E, Bazzi M, Ponzoni A. Dysphagia due to diffuse idiopathic skeletal hyperostosis: an analysis of five cases. *Rheumatol Int* 2010; **30**: 681-685 [PMID: 19466417 DOI: 10.1007/s00296-009-0967-7]
- Carlson ML, Archibald DJ, Graner DE, Kasperbauer JL. Surgical management of dysphagia and airway obstruction in patients with prominent ventral cervical osteophytes. *Dysphagia* 2011; **26**: 34-40 [PMID: 20099000 DOI: 10.1007/

- s00455-009-9264-6]
- 16 **Mader R.** Clinical manifestations of diffuse idiopathic skeletal hyperostosis of the cervical spine. *Semin Arthritis Rheum* 2002; **32**: 130-135 [PMID: 12430101 DOI: 10.1053/sarh.2002.33726]
- 17 **Karadag B,** Cat H, Aksoy S, Ozulu B, Ozturk AO, Oguz S, Altuntas Y. A geriatric patient with diffuse idiopathic skeletal hyperostosis. *World J Gastroenterol* 2010; **16**: 1673-1675 [PMID: 20355249 DOI: 10.3748/wjg.v16.i13.1673]
- 18 **Caminos CB,** Cenoz IZ, Louis CJ, Otano TB, Esáin BF, Pérez de Ciriza MT. Forestier disease: an unusual cause of upper airway obstruction. *Am J Emerg Med* 2008; **26**: 1072.e1-1072.e3 [PMID: 19091295 DOI: 10.1016/j.ajem.2008.03.048]
- 19 **Nelson RS,** Urquhart AC, Faciszewski T. Diffuse idiopathic skeletal hyperostosis: a rare cause of Dysphagia, airway obstruction, and dysphonia. *J Am Coll Surg* 2006; **202**: 938-942 [PMID: 16735209 DOI: 10.1016/j.jamcollsurg.2006.02.030]
- 20 **Gokce A,** Beyzadeoglu T, Hanci L, Erdogan F. Diffuse idiopathic skeletal hyperostosis as a cause of acute respiratory distress in early postoperative period of total knee arthroplasty. *Arch Orthop Trauma Surg* 2007; **127**: 553-555 [PMID: 17347831 DOI: 10.1007/s00402-007-0311-1]
- 21 **Anand V,** Vikram Vel VR, Purushothaman PK, Rajesh Kumar MS. Crico Arytenoid Joint Fixation in Diffuse Idiopathic Skeletal Hyperostosis (DISH): A Case Report. *Indian J Otolaryngol Head Neck Surg* 2011; **63**: 55-57 [PMID: 22754839 DOI: 10.1007/s12070-011-0193-y]
- 22 **Akhtar S,** O'Flynn PE, Kelly A, Valentine PM. The management of dysphasia in skeletal hyperostosis. *J Laryngol Otol* 2000; **114**: 154-157 [PMID: 10748839 DOI: 10.1258/0022215001904950]
- 23 **Epstein NE.** Simultaneous cervical diffuse idiopathic skeletal hyperostosis and ossification of the posterior longitudinal ligament resulting in dysphagia or myelopathy in two geriatric North Americans. *Surg Neurol* 2000; **53**: 427-431; discussion 431 [PMID: 10874140 DOI: 10.1016/S0090-3019(00)00227-5]
- 24 **Karpman RR,** Weinstein PR, Gall EP, Johnson PC. Lumbar spinal stenosis in a patient with diffuse idiopathic skeletal hypertrophy syndrome. *Spine (Phila Pa 1976)* 1982; **7**: 598-603 [PMID: 7167833]
- 25 **Kawabori M,** Hida K, Akino M, Yano S, Saito H, Iwasaki Y. Cervical myelopathy by C1 posterior tubercle impingement in a patient with DISH. *Spine (Phila Pa 1976)* 2009; **34**: E709-E711 [PMID: 19730204 DOI: 10.1097/BRS.0b013e3181aa26a4]
- 26 **Castro-Castro J,** Castro-Bouzas D, Pinzón-Millán A, Pastor-Zapata A. [Retro-odontoid pseudotumor in diffuse idiopathic skeletal hyperostosis]. *Neurocirugia (Astur)* 2014; **25**: 25-28 [PMID: 23465746 DOI: 10.1016/j.neucir.2013.01.001]
- 27 **Eser O,** Karavelioglu E, Boyacı MG, Ayçiçek A. Diffuse idiopathic skeletal hyperostosis and central cord syndrome after minor trauma: a case report. *Ulus Travma Acil Cerrahi Derg* 2013; **19**: 73-76 [PMID: 23588985 DOI: 10.5505/tjtes.2013.81593]
- 28 **Koizumi S,** Yamaguchi-Okada M, Namba H. Myelopathy due to multilevel cervical canal stenosis with Forestier disease: case report. *Neurol Med Chir (Tokyo)* 2010; **50**: 942-945 [PMID: 21030813 DOI: 10.2176/nmc.50.942]
- 29 **Westerveld LA,** Verlaan JJ, Oner FC. Spinal fractures in patients with ankylosing spinal disorders: a systematic review of the literature on treatment, neurological status and complications. *Eur Spine J* 2009; **18**: 145-156 [PMID: 18791749 DOI: 10.1007/s00586-008-0764-0]
- 30 **Vengust R,** Mihalic R, Turel M. Two different causes of acute respiratory failure in a patient with diffuse idiopathic skeletal hyperostosis and ankylosed cervical spine. *Eur Spine J* 2010; **19** Suppl 2: S130-S134 [PMID: 19798518 DOI: 10.1007/s00586-009-1159-6]
- 31 **Miyazawa N,** Akiyama I. Diffuse idiopathic skeletal hyperostosis associated with risk factors for stroke: a case-control study. *Spine (Phila Pa 1976)* 2006; **31**: E225-E29; discussion E230 [PMID: 16622366]
- 32 **Osoegawa M,** Araki E, Arakawa K, Okayama A, Yamada T, Ohnishi A, Kira J. [A case of motor and sensory polyneuropathy with retinitis pigmentosa and diffuse idiopathic skeletal hyperostosis]. *Rinsho Shinkeigaku* 1999; **39**: 542-545 [PMID: 10424146]
- 33 **Kritzer RO,** Rose JE. Diffuse idiopathic skeletal hyperostosis presenting with thoracic outlet syndrome and dysphagia. *Neurosurgery* 1988; **22**: 1071-1074 [PMID: 3262204 DOI: 10.1227/00006123-198806010-00017]
- 34 **Mazières B.** Diffuse idiopathic skeletal hyperostosis (Forestier-Rotes-Querol disease): what's new? *Joint Bone Spine* 2013; **80**: 466-470 [PMID: 23566663 DOI: 10.1016/j.jbspin.2013.02.011]
- 35 **Vezyroglou G,** Mitropoulos A, Antoniadis C. A metabolic syndrome in diffuse idiopathic skeletal hyperostosis. A controlled study. *J Rheumatol* 1996; **23**: 672-676 [PMID: 8730125]
- 36 **Eckertova M,** Krskova K, Penesova A, Radikova Z, Zlnay D, Rovensky J, Zorad S. Impaired insulin secretion and uptake in patients with diffuse idiopathic skeletal hyperostosis. *Endocr Regul* 2009; **43**: 149-155 [PMID: 19908933]
- 37 **Kannel WB,** Abbott RD, Savage DD, McNamara PM. Epidemiologic features of chronic atrial fibrillation: the Framingham study. *N Engl J Med* 1982; **306**: 1018-1022 [PMID: 7062992 DOI: 10.1056/NEJM198204293061703]
- 38 **Vaziri SM,** Larson MG, Benjamin EJ, Levy D. Echocardiographic predictors of nonrheumatic atrial fibrillation. The Framingham Heart Study. *Circulation* 1994; **89**: 724-730 [PMID: 8313561 DOI: 10.1161/01.CIR.89.2.724]
- 39 **Zincarelli C,** Iervolino S, Di Minno MN, Miniero E, Rengo C, Di Gioia L, Vitale D, Nicolino A, Furgi G, Pappone N. Diffuse idiopathic skeletal hyperostosis prevalence in subjects with severe atherosclerotic cardiovascular diseases. *Arthritis Care Res (Hoboken)* 2012; **64**: 1765-1769 [PMID: 22623449 DOI: 10.1002/acr.21742]

**P- Reviewer:** Mishra AK, Siu PM **S- Editor:** Ji FF  
**L- Editor:** Roemmele A **E- Editor:** Lu YJ



## Clinical usefulness and current problems of pancreatic duct stenting for preventing post-ERCP pancreatitis

Yuji Sakai, Toshio Tsuyuguchi, Osamu Yokosuka

Yuji Sakai, Toshio Tsuyuguchi, Osamu Yokosuka, Department of Gastroenterology and Nephrology, Graduate School of Medicine, Chiba University, Chiba 260-8677, Japan

Author contributions: Sakai Y wrote the paper; Tsuyuguchi T and Yokosuka O revised the manuscript.

Correspondence to: Yuji Sakai, MD, Department of Gastroenterology and Nephrology, Graduate School of Medicine, Chiba University, Inohana 1-8-1, Chuou-ku, Chiba 260-8670, Japan. [sakai4754@yahoo.co.jp](mailto:sakai4754@yahoo.co.jp)

Telephone: +81-43-2262083 Fax: +81-43-2262088

Received: April 16, 2014 Revised: May 21, 2014

Accepted: June 27, 2014

Published online: September 16, 2014

### Abstract

Endoscopic retrograde cholangiopancreatography (ERCP) is an endoscopic procedure with high frequency of accidental symptoms, and particularly some patients who develop and aggravate pancreatitis due to the procedure may need treatment of surgery or die. Various attempts were performed so far to prevent post-ERCP pancreatitis, however, it is impossible to completely prevent pancreatitis at this time because there are various factors for occurrence of post-ERCP pancreatitis. One of the most frequent causes of post-ERCP pancreatitis is considered to be congestion of pancreatic juice associated with duodenal papilledema after examination or treatment. Recently it is often reported that use of a pancreatic duct stent may prevent occurrence of pancreatitis which occurs because of an increased inner pressure of the pancreatic duct caused by congestion of pancreatic juice associated with duodenal papilledema. However, there are some patients who develop pancreatitis even if treated with the pancreatic duct stent, thus further clarification of the pathology and advancement of the prophylactic method will be needed.

© 2014 Baishideng Publishing Group Inc. All rights reserved.

**Key words:** Endoscopic retrograde cholangiopancrea-

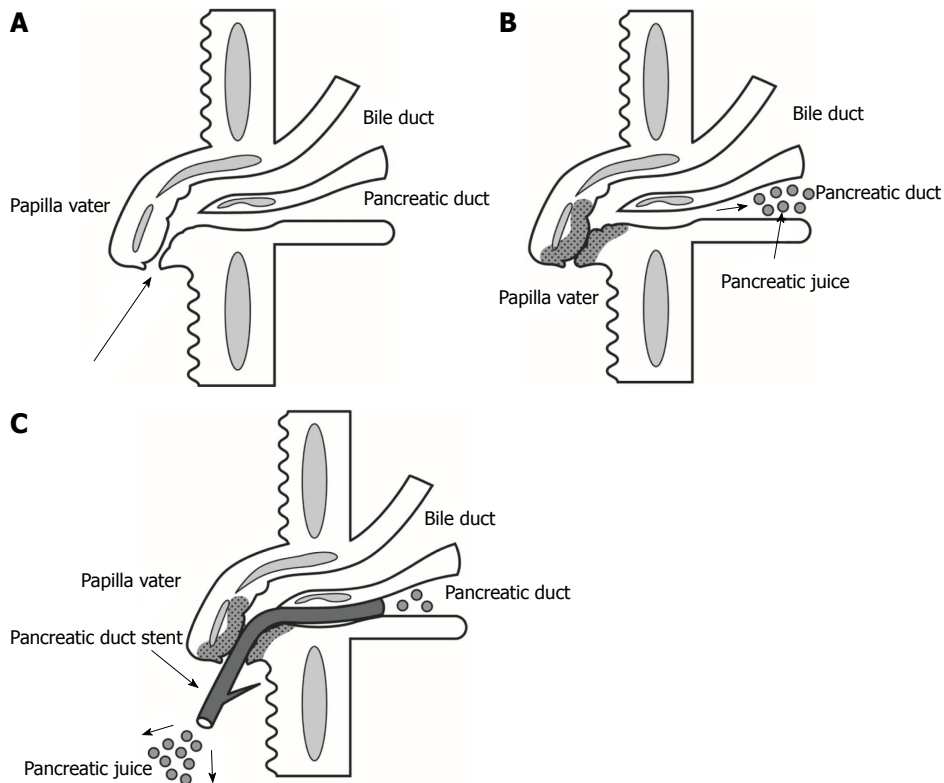
tography; Post-endoscopic retrograde cholangiopancreatography pancreatitis; Pancreatic duct stent; Pancreatic stenting

**Core tip:** There are some patients who can avoid occurrence of post-endoscopic retrograde cholangiopancreatography pancreatitis (ERCP) pancreatitis by pancreatic duct stenting. However, it is impossible to prevent all post-ERCP pancreatitides by pancreatic duct stenting, and further examination will be needed.

Sakai Y, Tsuyuguchi T, Yokosuka O. Clinical usefulness and current problems of pancreatic duct stenting for preventing post-ERCP pancreatitis. *World J Clin Cases* 2014; 2(9): 426-431 Available from: URL: <http://www.wjgnet.com/2307-8960/full/v2/i9/426.htm> DOI: <http://dx.doi.org/10.12998/wjcc.v2.i9.426>

### INTRODUCTION

Endoscopic retrograde cholangiopancreatography (ERCP) plays a very important role in diagnosis and treatment for pancreatic and biliary tract diseases. Post-ERCP pancreatitis is the early accidental symptom which occurs most frequently after ERCP. Although its frequency differs depending on the treated patients, procedure performed, definition of pancreatitis, or the investigation method, it is generally reported to occur in about 4.5% of treated patients based on the results of the large scale prospective studies<sup>[1-7]</sup> (Table 1). Although many cases of post-ERCP pancreatitis are alleviated by admission and treatment for a few days, some are aggravated, and about 0.04% need surgery and about 0.03% die<sup>[1,2,4,5]</sup>. Prophylaxis of post-ERCP pancreatitis is the great task which has not been resolved yet since introduction of ERCP, and various attempts have been performed. As one of such attempts, pancreatic duct stent is used to prevent occurrence of pancreatitis caused by duodenal papillede-



**Figure 1** Pancreatic duct stenting for preventing post-endoscopic retrograde cholangiopancreatography pancreatitis. A: Duodenal papilla before cannulation is performed; B: Duodenal papilledema occurs by frequent cannulation manipulation; C: Pancreatic duct stent is placed to regulate the passage of pancreatic juice.

ma due to the procedure, and its usefulness is frequently reported. In this article, we will describe the usefulness and problems of pancreatic duct stenting aiming at prophylaxis of post-ERCP pancreatitis.

## **PATHOGENIC MECHANISM OF POST-ERCP PANCREATITIS**

Post-ERCP pancreatitis is considered to occur due to various factors. The factors are broadly classified into five categories: (1) Increased inner pressure of the pancreatic duct by congestion of pancreatic juice caused by postoperative papilledema; (2) Mechanical irritation such as damaged pancreatic duct due to deep insertion of the catheter into the pancreatic duct or insertion of the device such as the guidewire; (3) Hydrostatic injury such as increased inner pressure of the pancreatic duct due to frequent pancreatography, manometry, or reflux water of pancreatoscopy; (4) Chemical injury due to infusion of the contrast medium or intestinal juice into the pancreatic duct; and (5) Thermal injury due to papilledema by radio-frequency radiation or thermal damages of the pancreas itself. Among them, one of the most frequent causes may be congestion of pancreatic juice associated with papilledema after examination or treatment<sup>[1,4,8]</sup>. There is a mechanism that congestion of pancreatic juice increases viscosity of pancreatic juice, aggravates obstruction of discharge of pancreatic juice, decreases the outflow of pancreatic juice into the small intestine, and promotes se-

cretion of pancreatic juice from the pancreatic acinar cell through increased cholecystokinin production. Through these processes, congestion of pancreatic juice is further aggravated, and eventually brings about activation of trypsinogen into trypsin within the acinar cell, and develops pancreatitis<sup>[8]</sup>.

## **REPORT ON PANCREATIC DUCT STENTING TO PREVENT POST-ERCP PANCREATITIS**

Although the pathogenic mechanism of post-ERCP pancreatitis has not been sufficiently clarified, various factors may be involved<sup>[1-6]</sup>. One of the pathogenic mechanisms of post-ERCP pancreatitis includes obstruction of discharge of pancreatic juice caused by papilledema or spasm of the sphincter of Oddi associated with the procedure. In order to regulate the passage of pancreatic juice for prophylaxis of post-ERCP pancreatitis, the pancreatic duct stent is used (Figure 1). Past articles comparing the pancreatic duct stenting group and non-pancreatic duct stenting group for prophylaxis of post-ERCP pancreatitis are shown<sup>[8-26]</sup> (Table 2). Review by RCT revealed that five of eight articles describe that post-ERCP pancreatitis occurred less in the stenting group with significant difference. Of other eleven articles, five articles describe that post-ERCP pancreatitis occurred less in the stenting group with significant differ-



**Table 1** Frequency of post-endoscopic retrograde cholangiopancreatography pancreatitis *n*(%)

Ref.	No. of patients	Post-ERCP pancreatitis	Surgery	Death
Freeman <i>et al</i> <sup>[1]</sup> , 1996	2347	127 (5.4)	3	1
Loperfido <i>et al</i> <sup>[2]</sup> , 1998	2769	36 (1.3)	2	1
Masci <i>et al</i> <sup>[3]</sup> , 2001	2444	44 (1.8)	-	0
Freeman <i>et al</i> <sup>[4]</sup> , 2001	1963	131 (6.7)	1	1
Cheng <i>et al</i> <sup>[5]</sup> , 2006	1115	168 (15.1)	-	1
Wang <i>et al</i> <sup>[6]</sup> , 2009	2691	116 (4.3)	0	0
Sakai <i>et al</i> <sup>[7]</sup> , 2013	720	14 (1.9)	0	0
Total	14049	636 (4.5)	6 (0.04)	4 (0.03)

ERCP: Endoscopic retrograde cholangiopancreatography pancreatitis.

ence. In seven articles of nine articles without significant difference, incidence of pancreatitis tends to be low in the pancreatic duct stenting group, thus pancreatic duct stenting is considered useful for prophylaxis of post-ERCP pancreatitis. Interestingly, as reported by Tsuchiya *et al*<sup>[18]</sup>, even if *p*-value of incidence of pancreatitis does not reach the value with significant difference, amylase value has become significantly low after ERCP in the stenting group. According to the review by Tsuchiya *et al*<sup>[18]</sup>, there were significantly less patients with abdominal pain in the stenting group, and there were no serious patients, which may be the effect of stenting. In addition, in the review of Sakai *et al*<sup>[23]</sup>, incidence of abdominal pain and post-operative amylase value are significantly low in the pancreatic duct stenting group, which is validly thought to be the effect of the pancreatic duct stent, taking into consideration that the background factors of both groups do not vary.

## INDICATION AND PROBLEMS OF PROPHYLACTIC PANCREATIC DUCT STENT

The risk factors of post-ERCP pancreatitis include young female, history of post-ERCP pancreatitis, recurrent pancreatitis, sphincter of Oddi dysfunction (SOD), and uncomplicated chronic pancreatitis as patient factors, and difficulty in insertion into the biliary duct, pancreatography, incision of the opening of the pancreatic duct, endoscopic papillary balloon dilation, and precut papillotomy as procedure factors<sup>[1-6]</sup>. However, it is hard to say it necessary to perform pancreatic duct stenting for all these patients, and it is necessary to select candidate patients for pancreatic duct stenting. Since pancreatic duct stenting regulates the passage of pancreatic juice, occurrence of occlusive pancreatitis is expected to be prevented. The procedure to indicate pancreatic duct stenting based on the past reports or theoretical thought includes: (1) Pancreatic duct guidewire-indwelling method or implementation of precut papillotomy from the opening of the pancreatic duct in patients with difficulty in insertion into the biliary duct, which may lead to papill-

edema<sup>[20,22,23,25]</sup>; (2) After endoscopic removal of duodenal papilla<sup>[17]</sup>; (3) Endoscopic sphincterotomy for SOD<sup>[13]</sup>; (4) Invasive procedure against pancreas such as the cytological diagnosis of pancreatic juice or biopsy of the pancreatic duct; and (5) Indwelling of the thick biliary duct stent instead of endoscopic sphincterotomy.


As for whether it is necessary to indwell the pancreatic duct stent in young females who are identified as the risk factor of post-ERCP pancreatitis or in patients with history of post-ERCP pancreatitis when there is no erroneous pancreatography or erroneous insertion of the guidewire, currently there is no clear evidence. Prophylaxis of pancreatitis by pancreatic duct stenting is frequently reported for patients with difficulty in insertion into the biliary duct. According to the past report, pancreatic duct stenting leads to less incidence of pancreatitis<sup>[20,22,23,25]</sup>, which is a good indication when considering to regulate the passage of pancreatic juice. However, discussion will be needed as to indication of pancreatic duct stenting in patients with difficulty in insertion into the biliary duct. It may be possible to perform pancreatic duct stenting in the comparatively stable situation in patients who underwent erroneous pancreatography or erroneous insertion of the guidewire into the pancreatic duct or in patients who underwent pancreatic duct guidewire-indwelling method which is the procedure performed by indwelling the guidewire in the pancreatic duct of patients with difficulty in inserting into the biliary duct. However, there remain patients with difficulty in pancreatic duct stenting. We give an example that in the case of patients who underwent pancreatography and had difficulty in advancing the guidewire caudally due to flexion or stenosis of the pancreatic duct or patients with difficulty in cannulation both into the biliary duct and pancreatic duct, although insertion into the biliary duct has become possible through precut papillotomy, it is still difficult to identify the opening of the pancreatic duct. If approach to the pancreatic duct in such patients for pancreatic duct stenting is attempted and failed, a possibility to induce or aggravate pancreatitis becomes high. Thus, discussion may be still needed as to timing or subjects or implementation judgment of pancreatic duct stenting in the patients with difficulty in insertion into the biliary duct.

What stent should be used is examined. Currently, there is no definite information regarding material quality, diameter, length, or shape of the stent. The stent is used only for drainage of the papillary edge, thus it is not always necessary to use a long stent, and those 3-4 cm in length are often used<sup>[18-26]</sup>. The stent with the flap in one duodenal side having no flap within the pancreatic duct (Figure 2) or one with the pig tail in the duodenal side having no flap within the pancreatic duct is expected to be spontaneously dislodged later after being indwelled. The stent with the flap in the pancreatic duct side is unlikely to deviate or be aberrant after stenting, however, it is necessary to perform endoscopy for removal several days later (Figure 3). Although currently it is difficult to set the strict term, if the pancreatic duct spontaneous dis-

**Table 2** Pathogenic frequency of post-endoscopic retrograde cholangiopancreatography pancreatitis in the pancreatic duct stenting group and the non-pancreatic duct stenting group

Ref.	No. of patients	Study design	No-stent (%)	Stent group (%)	P-value
Smithline <i>et al</i> <sup>[8]</sup> , 1993	93	RCT	18	14	0.299
Tarnasky <i>et al</i> <sup>[9]</sup> , 1998	80	RCT	26	7	0.03
Elton <i>et al</i> <sup>[10]</sup> , 1998	194	Retrospective c.c.	12.5	0.7	< 0.003
Vandervoot <i>et al</i> <sup>[11]</sup> , 1999	42	Prospective c.c.	28.1	0	0.08
Aizawa <i>et al</i> <sup>[12]</sup> , 2001	40	Retrospective c.c.	6	0	0.11
Fogel <i>et al</i> <sup>[13]</sup> , 2002	436	Retrospective c.c.	28.2	13.5	< 0.05
Norton <i>et al</i> <sup>[14]</sup> , 2002	28	Retrospective c.c.	11.1	20	> 0.05
Fazel <i>et al</i> <sup>[15]</sup> , 2002	76	RCT	28	5	< 0.05
Freeman <i>et al</i> <sup>[16]</sup> , 2004	225	Prospective c.c.	66.7	14.4	0.06
Catalano <i>et al</i> <sup>[17]</sup> , 2004	103	Retrospective c.c.	16.7	3.3	0.1
Tsuchiya <i>et al</i> <sup>[18]</sup> , 2007	64	RCT	12.5	3.1	> 0.05
Sofuni <i>et al</i> <sup>[19]</sup> , 2007	201	RCT	13.6	3.2	0.019
Ito <i>et al</i> <sup>[20]</sup> , 2008	113	Retrospective c.c.	22	4.7	0.01
Harada <i>et al</i> <sup>[21]</sup> , 2010	121	Retrospective c.c.	5.2	12.7	0.21
Ito <i>et al</i> <sup>[22]</sup> , 2010	70	RCT	23	2.9	0.0096
Sakai <i>et al</i> <sup>[23]</sup> , 2011	55	Retrospective c.c.	25	0	0.03
Sofuni <i>et al</i> <sup>[24]</sup> , 2011	425	RCT	14.6	9.4	0.076
Sakai <i>et al</i> <sup>[25]</sup> , 2011	198	Retrospective c.c.	11.1	3	0.049
Kawaguchi <i>et al</i> <sup>[26]</sup> , 2012	120	RCT	13.3	1.7	0.03

RCT: Randomized controlled trial; C.C.: Case controlled study; ERCP: Endoscopic retrograde cholangiopancreatography pancreatitis.



**Figure 2** Pancreatic duct stent with the flap in one duodenal side having no flap within the pancreatic duct (Pancreatic duct stent: Geenen®-COOK): Spontaneous dislodgement type.

lodgement stent indwelled is not spontaneously dislodged for a long time after stenting, there is a possibility that the stent is aberrant within the pancreatic duct, or pancreatitis occurs due to stent occlusion. Therefore, it should be endoscopically removed similarly to the pancreatic duct stent with the flap within in the pancreatic duct. It is important that the stent fits the shape of the pancreatic duct, and in the case of Z-shape pancreatic duct it is better to perform stenting beyond flexion depending on the case, and a long stent 7cm or greater is used in some cases. However, the longer stent tends to straddle the flexed portion of the pancreatic duct at the pancreas head, thus the stent made of the flexible material with high tracking ability is needed. The shorter spontaneous dislodgement stent less than 3cm may be dislodged after the procedure, thus attention should be paid. As for stent diameter, although the thicker stent gives impression of excellent drainage efficiency, to the contrary, such a stent



**Figure 3** Pancreatic duct stent with the flap in the pancreatic duct side (Pancreatic duct stent Zimmon®-COOK).

blocks the thinner branches of the pancreatic duct causing pancreatitis, or it is suggested that the stent itself may give mechanical irritation to the pancreatic duct<sup>[27]</sup>. For the thin stent with a diameter of 3Fr. or 4Fr., 0.018-0.025 inch guidewires are available<sup>[27]</sup>. Therefore, the guidewire has no resilience in inserting the pancreatic duct stent, and its insertion is difficult in some cases. Hereinafter multi-center RCTs on what pancreatic duct stent should be used is expected to be performed.

Furthermore, there is a problem that pancreatic duct stent should be inserted into what patients by doctors with what experience. Most of reports so far are performed in the expert centers, and even in such facilities, failure rate of insertion of the pancreatic duct stent is reported to be 5%-10%<sup>[9,13,28]</sup>. Freeman reported that failure of insertion of the pancreatic duct stent is very dangerous, and two thirds of patients develop moderate to severe pancreatitis<sup>[29]</sup>. Thus, Fazel *et al*<sup>[15]</sup> described that insertion of the pancreatic duct stent for prophylaxis

of post-ERCP pancreatitis should not be performed by doctors with less experience. Since pancreatitis, when being aggravated, may lead to fatal subsequence, pancreatic duct stenting should be performed by doctors with sufficient experience, and even the doctors with sufficient experience should perform with sufficient attention for stenting.

## CONCLUSION

In order to prevent post-ERCP pancreatitis, pancreatic duct stenting is considered useful. However, there are patients who fail to prevent post-ERCP pancreatitis. Development of complete prophylactic methods of post-ERCP pancreatitis is expected in the future.

## REFERENCES

- Freeman ML, Nelson DB, Sherman S, Haber GB, Herman ME, Dorsher PJ, Moore JP, Fennerty MB, Ryan ME, Shaw MJ, Lande JD, Pheley AM. Complications of endoscopic biliary sphincterotomy. *N Engl J Med* 1996; **335**: 909-918 [PMID: 8782497 DOI: 10.1056/NEJM199609263351301]
- Loperfido S, Angelini G, Benedetti G, Chilovi F, Costan F, De Berardinis F, De Bernardin M, Ederle A, Fina P, Fratton A. Major early complications from diagnostic and therapeutic ERCP: a prospective multicenter study. *Gastrointest Endosc* 1998; **48**: 1-10 [PMID: 9684657]
- Masci E, Toti G, Mariani A, Curioni S, Lomazzi A, Dinelli M, Minoli G, Crosta C, Comin U, Fertitta A, Prada A, Passoni GR, Testoni PA. Complications of diagnostic and therapeutic ERCP: a prospective multicenter study. *Am J Gastroenterol* 2001; **96**: 417-423 [PMID: 11232684 DOI: 10.1111/j.1572-0241]
- Freeman ML, DiSario JA, Nelson DB, Fennerty MB, Lee JG, Bjorkman DJ, Overby CS, Aas J, Ryan ME, Bochna GS, Shaw MJ, Snady HW, Erickson RV, Moore JP, Roel JP. Risk factors for post-ERCP pancreatitis: a prospective, multicenter study. *Gastrointest Endosc* 2001; **54**: 425-434 [PMID: 11577302]
- Cheng CL, Sherman S, Watkins JL, Barnett J, Freeman M, Geenen J, Ryan M, Parker H, Frakes JT, Fogel EL, Silverman WB, Dua KS, Aliperti G, Yaksh P, Uzer M, Jones W, Goff J, Lazzell-Pannell L, Rashdan A, Temkit M, Lehman GA. Risk factors for post-ERCP pancreatitis: a prospective multicenter study. *Am J Gastroenterol* 2006; **101**: 139-147 [PMID: 16405547 DOI: 10.1111/j.1572-0241.2006.00380.x]
- Wang P, Li ZS, Liu F, Ren X, Lu NH, Fan ZN, Huang Q, Zhang X, He LP, Sun WS, Zhao Q, Shi RH, Tian ZB, Li YQ, Li W, Zhi FC. Risk factors for ERCP-related complications: a prospective multicenter study. *Am J Gastroenterol* 2009; **104**: 31-40 [PMID: 19098846 DOI: 10.1038/ajg.2008.5]
- Sakai Y, Tsuyuguchi T, Hirata N, Nakaji S, Shimura K, Fujimoto T, Tsuchiya S, Nishino T, Nishikawa T, Sugiyama H, Yokosuka O. Can endoscopic sphincterotomy be performed safely in elderly patients aged 80 years or older with pancreatic and biliary diseases? *Hepatogastroenterology* 2013; **60**: 1251-1256 [PMID: 23340278]
- Smithline A, Silverman W, Rogers D, Nisi R, Wiersema M, Jamidar P, Hawes R, Lehman G. Effect of prophylactic main pancreatic duct stenting on the incidence of biliary endoscopic sphincterotomy-induced pancreatitis in high-risk patients. *Gastrointest Endosc* 1993; **39**: 652-657 [PMID: 8224687]
- Tarnasky PR, Palesch YY, Cunningham JT, Mauldin PD, Cotton PB, Hawes RH. Pancreatic stenting prevents pancreatitis after biliary sphincterotomy in patients with sphincter of Oddi dysfunction. *Gastroenterology* 1998; **115**: 1518-1524 [PMID: 9834280]
- Elton E, Howell DA, Parsons WG, Qaseem T, Hanson BL. Endoscopic pancreatic sphincterotomy: indications, outcome, and a safe stentless technique. *Gastrointest Endosc* 1998; **47**: 240-249 [PMID: 9540876]
- Vandervoort J, Soetikno RM, Montes H, Lichtenstein DR, Van Dam J, Ruymann FW, Cibas ES, Carr-Locke DL. Accuracy and complication rate of brush cytology from bile duct versus pancreatic duct. *Gastrointest Endosc* 1999; **49**: 322-327 [PMID: 10049415]
- Aizawa T, Ueno N. Stent placement in the pancreatic duct prevents pancreatitis after endoscopic sphincter dilation for removal of bile duct stones. *Gastrointest Endosc* 2001; **54**: 209-213 [PMID: 11474392]
- Fogel EL, Eversman D, Jamidar P, Sherman S, Lehman GA. Sphincter of Oddi dysfunction: pancreaticobiliary sphincterotomy with pancreatic stent placement has a lower rate of pancreatitis than biliary sphincterotomy alone. *Endoscopy* 2002; **34**: 280-285 [PMID: 11932782]
- Norton ID, Gostout CJ, Baron TH, Geller A, Petersen BT, Wiersema MJ. Safety and outcome of endoscopic snare excision of the major duodenal papilla. *Gastrointest Endosc* 2002; **56**: 239-243 [PMID: 12145603]
- Fazel A, Quadri A, Catalano MF, Meyerson SM, Geenen JE. Does a pancreatic duct stent prevent post-ERCP pancreatitis? A prospective randomized study. *Gastrointest Endosc* 2003; **57**: 291-294 [PMID: 12612504]
- Freeman ML, Overby C, Qi D. Pancreatic stent insertion: consequences of failure and results of a modified technique to maximize success. *Gastrointest Endosc* 2004; **59**: 8-14 [PMID: 14722540 DOI: 10.1016/S0016-5107(03)02530-6]
- Catalano MF, Linder JD, Chak A, Sivak MV, Rajman I, Geenen JE, Howell DA. Endoscopic management of adenoma of the major duodenal papilla. *Gastrointest Endosc* 2004; **59**: 225-232 [PMID: 14745396 DOI: 10.1016/S0016-5107(03)02366-6]
- Tsuchiya T, Itoi T, Sofuni A, Itokawa F, Kurihara T, Ishii K, Tsuji S, Kawai T, Moriyasu F. Temporary pancreatic stent to prevent post endoscopic retrograde cholangiopancreatography pancreatitis: a preliminary, single-center, randomized controlled trial. *J Hepatobiliary Pancreat Surg* 2007; **14**: 302-307 [PMID: 17520207 DOI: 10.1007/s00534-006-1147-8]
- Sofuni A, Maguchi H, Itoi T, Katanuma A, Hisai H, Niido T, Toyota M, Fujii T, Harada Y, Takada T. Prophylaxis of post-endoscopic retrograde cholangiopancreatography pancreatitis by an endoscopic pancreatic spontaneous dislodgement stent. *Clin Gastroenterol Hepatol* 2007; **5**: 1339-1346 [PMID: 17981247 DOI: 10.1016/j.cgh.2007.07.008]
- Ito K, Fujita N, Noda Y, Kobayashi G, Obana T, Horaguchi J, Takasawa O, Koshita S, Kanno Y. Pancreatic guidewire placement for achieving selective biliary cannulation during endoscopic retrograde cholangio-pancreatography. *World J Gastroenterol* 2008; **14**: 5595-5600; discussion 5599 [PMID: 18810780 DOI: 10.3748/wjg.14.5595]
- Harada R, Kawamoto H, Fukatsu H, Kato H, Hirao K, Kurihara N, Mizuno O, Ogawa T, Ishida E, Okada H, Yamamoto K, Yamamoto H. Nonprevention of post-endoscopic retrograde cholangiopancreatographic pancreatitis by pancreatic stent after aspiration of pure pancreatic juice in patients with intraductal papillary mucinous neoplasms of the pancreas. *Pancreas* 2010; **39**: 340-344 [PMID: 19823100 DOI: 10.1097/MPA]
- Ito K, Fujita N, Noda Y, Kobayashi G, Obana T, Horaguchi J, Takasawa O, Koshita S, Kanno Y, Ogawa T. Can pancreatic duct stenting prevent post-ERCP pancreatitis in patients who undergo pancreatic duct guidewire placement for achieving selective biliary cannulation? A prospective randomized controlled trial. *J Gastroenterol* 2010; **45**: 1183-1191 [PMID: 20607310 DOI: 10.1007/s00535-010-0268-7]
- Sakai Y, Tsuyuguchi T, Mikata R, Sugiyama H, Yasui S, Eto R, Fujimoto T, Tamura R, Togo S, Tada M, Ishihara T, Yokosuka O. Pancreatic duct guidewire-indwelling method for patients resistant to selective biliary cannulation and usefulness of

- pre-cut papillotomy following unsuccessful biliary cannulation with pancreatic duct guidewire-indwelling method. *Hepatogastroenterology* 2011; **58**: 698-704 [PMID: 21830372]
- 24 **Sofuni A**, Maguchi H, Mukai T, Kawakami H, Irisawa A, Kubota K, Okaniwa S, Kikuyama M, Kutsumi H, Hanada K, Ueki T, Itoi T. Endoscopic pancreatic duct stents reduce the incidence of post-endoscopic retrograde cholangiopancreatography pancreatitis in high-risk patients. *Clin Gastroenterol Hepatol* 2011; **9**: 851-858; quiz e110 [PMID: 21749851 DOI: 10.1016/j.cgh.2011.06.033]
  - 25 **Sakai Y**, Tsuyuguchi T, Mikata R, Tawada K, Tada M, Togo S, Tamura R, Saito M, Kurosawa J, Ishihara T, Yokosuka O. Utility of placement of pancreatic duct spontaneous dislodgement stent for prevention of post-ERCP pancreatitis in patients with difficulty in selective biliary cannulation. *Hepatogastroenterology* 2011; **58**: 687-693 [PMID: 21830369]
  - 26 **Kawaguchi Y**, Ogawa M, Omata F, Ito H, Shimosegawa T, Mine T. Randomized controlled trial of pancreatic stenting to prevent pancreatitis after endoscopic retrograde cholangiopancreatography. *World J Gastroenterol* 2012; **18**: 1635-1641 [PMID: 22529693 DOI: 10.3748/wjg.v18.i14.1635]
  - 27 **Rashdan A**, Fogel EL, McHenry L, Sherman S, Temkit M, Lehman GA. Improved stent characteristics for prophylaxis of post-ERCP pancreatitis. *Clin Gastroenterol Hepatol* 2004; **2**: 322-329 [PMID: 15067627 DOI: 10.1016/s1542-3565(04)00062-x]
  - 28 **Cha SW**, Leung WD, Lehman GA, Watkins JL, McHenry L, Fogel EL, Sherman S. Does leaving a main pancreatic duct stent in place reduce the incidence of precut biliary sphincterotomy-associated pancreatitis? A randomized, prospective study. *Gastrointest Endosc* 2013; **77**: 209-216 [PMID: 23084272 DOI: 10.1016/j.gie.2012.08.022]
  - 29 **Freeman ML**. Role of pancreatic stents in prevention of post-ERCP pancreatitis. *JOP* 2004; **5**: 322-327 [PMID: 15365198]

**P- Reviewer:** Kamisawa T, Nakazawa T, Tang WF

**S- Editor:** Ji FF **L- Editor:** A **E- Editor:** Lu YJ





## Targeting EGFR and sonic hedgehog pathways for locally advanced eyelid and periocular carcinomas

Vivian T Yin, Helen Merritt, Bitá Esmaeli

Vivian T Yin, Bitá Esmaeli, Orbital Oncology and Ophthalmic Plastic Surgery Program, Department of Plastic Surgery, The University of Texas MD Anderson Cancer Center, Houston, TX 77030, United States

Helen Merritt, Department of Ophthalmology and Visual Science, The University of Texas Medical School, Houston, TX 77030, United States

Author contributions: Yin VT and Esmaeli B were involved in the writing and editing of the manuscript; Merritt H co-ordinated and provided writing and literature review.

Correspondence to: Bitá Esmaeli, MD, FACS, Orbital Oncology and Ophthalmic Plastic Surgery, Department of Plastic Surgery, The University of Texas MD Anderson Cancer Center, 1515 Holcombe Blvd, Unit 1488, Houston, TX 77030, United States. [besmaeli@mdanderson.org](mailto:besmaeli@mdanderson.org)

Telephone: +1-713-7924457 Fax: +1-713-5638041

Received: February 16, 2014 Revised: July 24, 2014

Accepted: August 27, 2014

Published online: September 16, 2014

ma; Sonic hedgehog; Epithelial growth factor receptor inhibition; Periocular squamous cell carcinoma

**Core tip:** Targeted therapies provide a novel and potentially effective treatment alternative for patients with eyelid carcinoma not amenable for surgery, including those with metastatic, locally advanced disease, advanced age, and significant comorbidities. High cost, need for long-term treatment, and toxicity are relative limitations.

Yin VT, Merritt H, Esmaeli B. Targeting EGFR and sonic hedgehog pathways for locally advanced eyelid and periocular carcinomas. *World J Clin Cases* 2014; 2(9): 432-438 Available from: URL: <http://www.wjgnet.com/2307-8960/full/v2/i9/432.htm> DOI: <http://dx.doi.org/10.12998/wjcc.v2.i9.432>

### Abstract

For patients with metastatic or locally advanced eyelid and periocular carcinoma not amenable to surgical excision, targeted therapies have shown efficacy with better tolerability compared to cytotoxic chemotherapy. Overexpression of epithelial growth factor receptor was found in squamous cell carcinomas. Vismodegib targets the mutation in the hedgehog pathway identified in basal cell carcinoma and basal cell nevus syndrome. Targeted therapies provide a novel and potentially effective treatment alternative for patients with eyelid carcinoma not amenable for surgery, including those with metastatic, locally advanced disease, advanced age, and significant comorbidities. High cost, need for long-term treatment, and toxicity are relative limitations.

© 2014 Baishideng Publishing Group Inc. All rights reserved.

**Key words:** Vismodegib; Periocular basal cell carcinoma;

### INTRODUCTION

Eyelid malignancies have been reported with yearly incidence as high as 15.7 cases per 100000 individuals in the United States<sup>[1]</sup>. The most common type of eyelid carcinoma is basal cell carcinoma (BCC), accounting for 86% to 96% of all cases, followed by squamous cell carcinoma (SCC), 3.4% to 12.6%, sebaceous carcinoma (SebCa), 0.6% to 10.2%, and melanoma, less than 1%<sup>[1-3]</sup>. Distant metastasis from eyelid carcinoma is not common, reported in up to 6% of squamous cell carcinoma<sup>[4]</sup>. Furthermore, the integrity of the eyelids are essential for protection and function of the globe making locally advanced disease difficult if not impossible to resect completely without disruption of globe function.

Traditional cytotoxic chemotherapy for treatment of metastatic or unresectable disease targets all rapidly dividing cells, whether cancerous or not. This results in an unfavorable toxicity profile. With the discovery of the common mutations in BCC and SCC, drug therapies targeted

against these mutations can potentially block only the growth of cancer cells and thus lead to less wide spread toxicity. In addition, many of these targeted therapies are administered orally rather than by the intravenous route. The ease of administration and lower toxicity generates momentous interest in these new classes of drugs.

## EGFR INHIBITION IN SQUAMOUS CELL CARCINOMA

Epithelial growth factor receptor (EGFR), also known as HER-1 or ErbB-1, is a transmembrane protein with an extracellular receptor domain for multiple ligands, including EGF, TGF- $\alpha$  and epiregulin, and an intracellular kinase domain with tyrosine autophosphorylation site<sup>[5]</sup>. Upon activation, the EGFR forms homodimer with another EGFR or heterodimer with another ErbB family receptor. Multiple pathways can be activated by these dimer formations, including RAS/RAF/MEK/MAPK, PI3K/AKT and STAT. The resultant effect of EGFR activation in both normal and malignant human skin is severe epidermal disorganization and invasion<sup>[6]</sup>.

Squamous cell carcinoma has been shown to have overexpression of EGFR. In a series of 13 metastatic SCC of the skin, all showed strong expression of EGFR whereas normal skin close to the tumor had weak EGFR expression that was limited to the basal layer of the epidermis<sup>[7]</sup>. EGFR overexpression has been found in up to 78% (25 of 32) of cutaneous SCC cells and 62% (13 of 21) of actinic keratoses (AKs)<sup>[8]</sup>. In conjunctival SCC, EGFR had either moderate or strong expression of EGFR on all (5 out of 5) epithelial cell of conjunctiva<sup>[9]</sup>. Furthermore, *EGFR* numerical aberration was found 77% (27 out of 35) SCC and 52% (13 out of 25) of AKs<sup>[8]</sup>. Analysis of 3 lymph nodes of metastatic SCC all showed amplification of 7p12-13, location of *EGFR* gene<sup>[10]</sup>.

EGFR expression level is also shown to be associated with metastasis in 45 cases of head and neck SCC<sup>[11]</sup>. In 25 cases without metastasis, only 9 (36%) showed strong expression for EGFR, compared to 11 of 14 cases (79%) with metastasis<sup>[11]</sup>.

## EFFICACY OF EGFR INHIBITORS

Cetuximab (C225, Erbitux) is a chimeric mouse-human IgG1 monoclonal antibody that primarily competitively inhibits EGF binding at the same affinity as the natural ligand<sup>[12]</sup>. It was approved for use by the Food and Drug Administration (FDA) on March 1, 2006 for locally or regionally advanced head and neck cancer SCC (HNSCC) in combination with radiation therapy or as single agent for recurrent or metastatic HNSCC after failing platinum-based therapy. It was the first EGFR inhibitor studied in clinical trials and to be approved by FDA. In vivo study with A431 model epidermoid carcinoma cells had shown that even in the presence of EGF, cetuximab

completely inhibits the activation of EGFR<sup>[13]</sup>. It is also able to induce dimerization of EGFR and down regulation and further activation by ligands<sup>[14]</sup>. In a phase 2 study of 36 patients with unresectable (locally advanced or metastatic) SCC of the skin with confirmed strong or moderate expression of EGFR in the primary tumor, the overall tumor response rate was 69% (95%CI: 52%-84%) base on intent-to-treat and 81% (95%CI: 63%-93%) base on actual treatment received<sup>[15]</sup>. Cetuximab was given as an intravenous infusion at 400 mg/m<sup>2</sup> dose followed by weekly 1-hour infusion at a dose of 250 mg/m<sup>2</sup>. The median number of infusion received during the 48-week study was 15 (range 1 to 47 infusions)<sup>[15]</sup>. There is currently no published study on the effect of cetuximab compared to or in combination with standard cytotoxic chemotherapy. However, in a study of 424 head and neck squamous cell carcinoma (HNSCC) randomized to high dose radiation with or without cetuximab has shown superior median survival (54 mo *vs* 28 mo) with the addition of cetuximab<sup>[16]</sup>.

Gefitinib (ZD1839, Iressa) was the first orally administered EGFR inhibitor shown to selectively inhibit EGFR tyrosine kinase activity through blockage of autophosphorylation<sup>[17]</sup>. Gefitinib was approved in 2003 as monotherapy for non-small cell lung cancer (NSCLC), but the approval was amended to only in patients who had previously benefited from the drug due to lack of survival benefit especially when compared to erlotinib. In vitro incubation of gefitinib with EGF and cutaneous SCC cells showed a dose-dependent reduction in EGFR and MAPK phosphorylation between IC<sub>50</sub> of 0.02 and 0.2  $\mu$ M<sup>[18]</sup>. In 22 patients with locally aggressive or recurrent cutaneous SCC, neoadjuvant use of gefitinib 250 mg per day showed overall response rate of 45.5% (95%CI: 24.4%-67.8%) and 2-year overall survival of 72.1% (95%CI: 55.4%-93.9%)<sup>[19]</sup>. Of the 4 patients who showed complete response in this study, all were alive and were disease free at last follow-up<sup>[19]</sup>. In addition, 3 of these 4 patients with complete response showed pathologic complete response with no evidence of SCC in their resected surgical tissue<sup>[19]</sup>. There is currently only 1 case report of use of gefitinib as primary treatment for metastatic cutaneous SCC of the foot showed maintained clinical response for 30 mo and an additional 12 mo with the addition of sirolimus<sup>[20]</sup>.

Erlotinib (OSI-744, Tarceva) is similar to gefitinib in that it inhibits EGFR activity through reduction of autophosphorylation causing cell cycle arrest at G1 phase; however, it does this through competitive inhibition with ATP<sup>[21]</sup>. FDA first approved its use on November 18, 2004, for treatment of patients with locally advanced or metastatic NSCLC after failure of at least one prior chemotherapy regimen. It was later approved for use in locally advanced or metastatic pancreatic carcinoma in combination with gemcitabine and most recently as first-line therapy for metastatic NSCLC in the presence of EGFR mutation. To our knowledge the use of erlotinib in cutaneous SCC has only been investigated in one phase

1 study of erlotinib plus radiation therapy after surgical resection. The 2-year overall survival was 65% with median time to recurrence of 10.5mo (range 1 to 14 mo) in the 15 Stage III cutaneous SCC patients included in this study<sup>[22]</sup>. Palliative treatment of metastatic cutaneous SCC with erlotinib has been reported in multiple case reports with initial tumor response<sup>[23-25]</sup>. In phase 2 studies of locally advanced HNSCC, the addition of erlotinib to cisplatin and 70Gy of radiation showed improved clinical response rate, 52% compared to 40%, however, this was not statistically significant,  $P = 0.08$ <sup>[26]</sup>.

## USE OF EGFR INHIBITORS FOR ORBITAL AND PERIORBITAL SCC

EGFR expression has been shown in 5 patients with conjunctival SCC as moderate or strongly expressed in both in situ and invasive components of SCC<sup>[9]</sup>. In contrast, study of periocular sebaceous carcinoma showed lower intensity of EGFR expression with only 2 (11%) of 19 patients showing 3+ intensity of staining<sup>[27]</sup>.

Our group has also reported good clinical and radiological tumor response to EGFR inhibitors in three patients who presented with locally advanced cutaneous SCC of the periocular skin with orbital extension<sup>[25, 28]</sup>. Two of the three patients were treated with cetuximab at the standard dosage of 400 mg/m<sup>2</sup> followed by 250 mg/m<sup>2</sup> weekly and the third was treated with erlotinib 150 mg daily. One of the patients treated with cetuximab had involvement in the cavernous sinus, Meckel's cave, trigeminal tract and infraorbital nerve and showed improvement in motility and sensation after 4 weeks of treatment. This patient's tumor was also analyzed for 182 cancer-related genes and found to have EGFR P753S mutation along with *CDKN2A* mutation, *MYC* amplification and *TP53* mutation<sup>[28]</sup>.

## SIDE EFFECTS OF EGFR INHIBITORS

The most common side effect of EGFR inhibitors is skin toxicity in the form of an acne-like rash, papular and/or pustular follicular eruption, in 32% to 78% of patient with a median time to onset of 14 d<sup>[7, 19]</sup>. Interestingly, the presence rash as a side effect during treatment was significantly correlated with higher overall response rate, median overall survival and progression-free survival in patients treated with erlotinib for NSCLC<sup>[29]</sup>. The lower incidence of acne-like rash with gefitinib is believed to be due to its attenuation instead of complete blockage of EGFR tyrosine kinase. Instead, toxicity from gefitinib is most commonly diarrhea and fatigue before rash<sup>[19]</sup>. Erlotinib is also associated with mucositis (87%), esophagitis (40%)<sup>[22]</sup>, and ocular side effects including trichomegaly leading to corneal ulceration<sup>[30]</sup>, conjunctivitis and ectropion<sup>[31]</sup>. Discontinuation of EGFR inhibitors due to toxicity varied from 9% with gefitinib<sup>[19]</sup>, 11% in cetuximab<sup>[7]</sup>, and 13% in erlotinib<sup>[22]</sup>.

## COST OF EGFR INHIBITORS

Cetuximab costs from \$2.94 per milligram in Switzerland to \$6.73 per milligram in the United States<sup>[32]</sup>. At the dosage used in the phase 2 clinical trials, the cost would be approximately \$28000/m<sup>2</sup> or for an average white male the cost of the course of cetuximab would be approximately \$37500. Cetuximab is approved in Europe and Asia, specifically Japan, and available in central and south America as well. In comparison, Iressa costs on average \$79 per 250 mg tablet<sup>[33]</sup> and Tarceva cost on average \$100 per 150 mg tablet<sup>[34]</sup>, or cost of \$2370 and \$3000 per month, respectively. Iressa and Tarceva are both available in Europe and Asia in addition to the United States.

## PTCH1 GENE AND BASAL CELL CARCINOMA

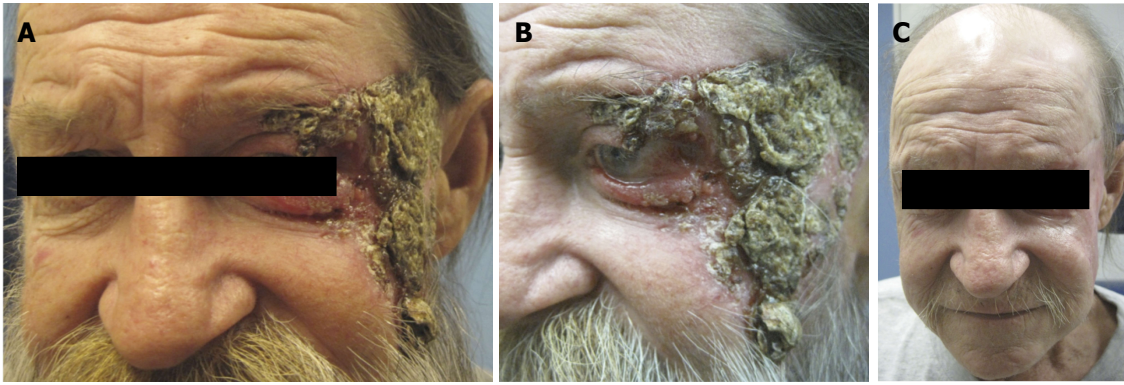
Basal cell carcinoma (BCC) has been linked to disruption in the Hedgehog (Hh) signaling cascade, a pathway important during embryogenesis but normally inactive in the adult<sup>[35, 36]</sup>. Patched-1 (Ptch-1) is a transmembrane receptor that normally has inhibitory effects on downstream receptor Smoothened (Smo)<sup>[37]</sup>. When Ptch-1 is activated, upon binding by Hh protein, the constitutive inhibition on Smo is reversed and produces angiogenesis and cellular proliferation in tumorigenesis<sup>[38]</sup>. Specifically, expression of the downstream product GLI1 in basal cells is proposed to induce formation of BCC<sup>[39]</sup>. Mutations both in PTCH-1 and Smo have been identified in basal cell nevus syndrome and sporadic basal cell carcinomas<sup>[35,36,40,41]</sup>. Additionally, continued signaling of the Hh pathway is needed for sustained growth of established BCCs in the mouse model<sup>[42]</sup>.

## INHIBITION OF HEDGEHOG PATHWAY IN BCC

Vismodegib (GDC-0449, Erivedge) is a first-in-class small molecule oral Hh signaling pathway inhibitor approved January 2012 for the treatment of locally advanced or metastatic BCC. Vismodegib directly binds to and inhibits Smo<sup>[43]</sup>. Vismodegib's inhibition at this point in the cascade prevents formation of GLI1 and therefore targets BCCs related to both constitutively activated Smo mutations and mutations in the upstream PTCH-1. Hedgehog gene expression was reduced by 90% at 1 month after vismodegib treatment in *in vivo* studies<sup>[44]</sup>. Biopsy samples from patients treated with vismodegib showed decrease in GLI1 expression by more than two folds after treatment compared to baseline<sup>[45]</sup>.

At a dose of 150mg daily, vismodegib has shown no dose-limiting toxicities in Phase 1 trials<sup>[43,45,46]</sup>. Initial Phase I trial of 68 patients with advanced BCC and medulloblastoma compared doses of 150 mg/d to 270 mg/d and 540 mg/d and demonstrated no increase in steady





**Figure 1** A 55 year-old man with locally advanced neglected basal cell carcinoma. A-B: The lesion involves the left lateral canthus, upper and lower eyelids, left temple and midface; C: After 29 wk of vismodegib 150 mg daily, there is significant resolution of clinically visible tumor. The only surgical intervention that the patient had undergone at this point was reconstructive surgery to repair the left lower lid cicatricial ectropion via a lateral tarsal strip procedure, a lateral tarsorrhaphy and full-thickness skin graft.

state plasma concentrations associated with vismodegib efficacy with higher doses<sup>[43,45]</sup>. In the cohort of patients from the phase I trial, overall response was shown in 18/33 patients (55%) with locally advanced or metastatic BCC, 2/18 demonstrating complete response and 16/18 demonstrating partial response<sup>[45]</sup>.

A phase 2 trial of 33 patients with metastatic BCC and 63 patients with locally advanced BCC also showed tumor response when given 150 mg of vismodegib daily for a mean duration of 10 mo<sup>[47]</sup>. Investigators found a 30% objective response rate in the group with metastatic basal-cell carcinoma as defined by a decrease of 30% or more in the dimension or complete resolution of ulceration. The overall objective response rate in the group with locally advanced BCC was 43% with 21% of these patients demonstrating a complete response. By independent review, none of patients in the metastatic cohort had complete response, 10 (30%) patients had partial response and disease progression was noted in 1 (3%) patient with metastatic disease.

Vismodegib has also demonstrated promise in treatment of basal-cell nevus syndrome. Tang *et al*<sup>[44]</sup> demonstrated reduction of existing BCC tumor burden and prevention of new BCC in patients with basal-cell nevus syndrome. The vismodegib treatment group had a per-patient average rate of 2 per year while the placebo group had a rate of 29 per patient per year. The investigators also found a greater decrease (-65%) in the size of existing basal cell carcinomas in the vismodegib group compared to the placebo group (-11%). There was no progression of tumors in the treatment group during vismodegib administration and no signs of resistance to the drug during the study. The response was so significant in the treatment arm that the DSMB (Data Safety Monitoring Board) discontinued the study after the first interim analysis. Biopsies sampled from sites of flat-appearing, clinically-regressed basal cell lesions showed residual tumor in 1/6 samples (17%)<sup>[44]</sup>. Although discontinuation of vismodegib led to expected return of BCC at original sites, significant decrease in the incidence of new surgi-

cally eligible BCCs was noted even after cessation for several mo; 0.69 new lesions per month in the treated group compared to 2.4 per month in the placebo group.

## VISMODEGIB FOR ADVANCED PERIOULAR BCC

The use of vismodegib specifically for periocular BCC was first reported in a review by Yin *et al*<sup>[48]</sup> in which some of the patients treated with vismodegib in our practice at MD Anderson Cancer Center were highlighted. In this report, a 30-year-old male patient with advanced basal cell nevus syndrome and numerous large BCCs throughout his periocular and facial region including all four eyelids, experienced near complete resolution of his periocular lesions after 16 wk of treatment with durable response during the more than 2 years of follow-up. Subsequently Gill *et al*<sup>[49]</sup> highlighted the results of vismodegib in 7 patients with advanced periocular or orbital BCC for a mean duration of 11 wk. With the study's mean follow-up duration of 7.3 mo, two out of seven patients (29%) had complete regression, 2 out of 7 patients (29%) had partial clinical regression greater than 80%, and 2 out of 7 patients had partial clinical regression less than 35%, and 1 patient progressed.

The histologic effects of vismodegib on a single case of periocular BCC was demonstrated by Kahana *et al*<sup>[50]</sup> in a patient with recurrent orbital BCC. After 5 mo of vismodegib, the patient opted for surgical excision due to drug side effects. The surgical specimen showed lack of Ki-67 expression, a marker for proliferation, and mitotic index < 1%.

The use of vismodegib in the periocular region can yield impressive responses in patients with locally advanced disease that would otherwise need major disfiguring surgery such as orbital exenteration or would experience loss of major parts of their face during surgical resection. An example of impressive response in a recent such patient in our practice is shown in Figure 1.



## SIDE EFFECTS OF VISMODEGIB

Adverse reactions to vismodegib of any grade are reported in 86% to 100% of patients during treatment<sup>[46,47,49]</sup>. The most common adverse events associated with vismodegib use are mild to moderate nausea, alopecia, dysgeusia, anorexia, and muscle spasms<sup>[44-47]</sup>. In the phase I trial by Tang *et al.*<sup>[44]</sup> 27% of patients receiving vismodegib had stopped the drug due to these adverse events by 8 mo, increasing to 54% cessation a year later. Resolution of dysgeusia, muscle cramps and regrowth of hair was noted within 3 mo after cessation of therapy. No serious adverse events or dose-limiting toxicities have been observed with the recommended 150 mg dosage<sup>[43,46]</sup>.

## COST OF VISMODEGIB

The cost of vismodegib (Erivedge) is set by Genetech at \$7500 monthly or \$250 per capsule<sup>[51]</sup>. Besides the United States, vismodegib is also approved in Switzerland, United Kingdom, the EU, Australia, Israel, South Korea, Mexico and Ecuador.

## CONCLUSION

The treatment of surgically unresectable eyelid and periocular carcinoma is no longer limited to radical disfiguring surgery or the use of high dose radiation therapy with its feared ocular toxicity. The use of drugs that target sonic hedgehog or EGFR pathways for advanced cutaneous carcinomas of the periorbital region should be viewed as palliative but can be associated with long-term and durable response and may be an option for older individuals who would otherwise need radical surgery with significant morbidity. Although specific published data on use of these agents for eyelid or periocular carcinomas are currently limited to few case reports, these relatively new drugs should be further studied for their efficacy in locally advanced BCC or SCC of periocular region. Correlation of response to mutational profile of each tumor would be intriguing and should be further evaluated. These newly available treatments should be considered only in patients with locally advanced unresectable or metastatic disease, multiple tumors, advanced age or multiple comorbidities. Future treatment strategies to decrease the duration of treatment with Hedgehog inhibitors or EGFR inhibitors and the use of these drugs in the neoadjuvant setting before surgery may be interesting to explore as a means of decreasing morbidity associated with periocular surgery.

## REFERENCES

- 1 Cook BE, Bartley GB. Epidemiologic characteristics and clinical course of patients with malignant eyelid tumors in an incidence cohort in Olmsted County, Minnesota. *Ophthalmology* 1999; **106**: 746-750 [PMID: 10201597 DOI: 10.1016/S0161-6420(99)90161-6]
- 2 Crawford C, Fernelius C, Young P, Groo S, Ainbinder D. Application of the AJCC 7th edition carcinoma of the eyelid

- staging system: a medical center pathology based, 15-year review. *Clin Ophthalmol* 2011; **5**: 1645-1648 [PMID: 22140312 DOI: 10.2147/OPTH.S26418]
- 3 Deprez M, Uffer S. Clinicopathological features of eyelid skin tumors. A retrospective study of 5504 cases and review of literature. *Am J Dermatopathol* 2009; **31**: 256-262 [PMID: 19384066 DOI: 10.1097/DAD.0b013e3181961861]
- 4 Faustina M, Diba R, Ahmadi MA, Esmaeli B. Patterns of regional and distant metastasis in patients with eyelid and periocular squamous cell carcinoma. *Ophthalmology* 2004; **111**: 1930-1932 [PMID: 15465559 DOI: 10.1016/j.opht.2004.02.009]
- 5 Jost M, Kari C, Rodeck U. The EGF receptor - an essential regulator of multiple epidermal functions. *Eur J Dermatol* 2000; **10**: 505-510 [PMID: 11056418]
- 6 Commandeur S, van Drongelen V, de Gruij FR, El Ghalbzouri A. Epidermal growth factor receptor activation and inhibition in 3D in vitro models of normal skin and human cutaneous squamous cell carcinoma. *Cancer Sci* 2012; **103**: 2120-2126 [PMID: 22974223 DOI: 10.1111/cas.12026]
- 7 Maubec E, Duvillard P, Velasco V, Crickx B, Avril MF. Immunohistochemical analysis of EGFR and HER-2 in patients with metastatic squamous cell carcinoma of the skin. *Anticancer Res* 2005; **25**: 1205-1210 [PMID: 15865067 DOI: 10.1111/jop.12111]
- 8 Toll A, Salgado R, Yébenes M, Martín-Ezquerria G, Gilaberte M, Baró T, Solé F, Alameda F, Espinet B, Pujol RM. Epidermal growth factor receptor gene numerical aberrations are frequent events in actinic keratoses and invasive cutaneous squamous cell carcinomas. *Exp Dermatol* 2010; **19**: 151-153 [PMID: 20156290 DOI: 10.1111/j.1600-0625.2009.01028.x]
- 9 Shepler TR, Prieto VG, Diba R, Neuhaus RW, Shore JW, Esmaeli B. Expression of the epidermal growth factor receptor in conjunctival squamous cell carcinoma. *Ophthalm Plast Reconstr Surg* 2006; **22**: 113-115 [PMID: 16550055 DOI: 10.1097/01.iop.0000202609.92772.c3]
- 10 Shimizu T, Izumi H, Oga A, Furumoto H, Murakami T, Ofuji R, Muto M, Sasaki K. Epidermal growth factor receptor overexpression and genetic aberrations in metastatic squamous-cell carcinoma of the skin. *Dermatology* 2001; **202**: 203-206 [PMID: 11385224 DOI: 10.1159/000051637]
- 11 Ch'ng S, Low I, Ng D, Brasch H, Sullivan M, Davis P, Tan ST. Epidermal growth factor receptor: a novel biomarker for aggressive head and neck cutaneous squamous cell carcinoma. *Hum Pathol* 2008; **39**: 344-349 [PMID: 18045646 DOI: 10.1016/s0093-3619(08)79044-0]
- 12 Sato JD, Kawamoto T, Le AD, Mendelsohn J, Polikoff J, Sato GH. Biological effects in vitro of monoclonal antibodies to human epidermal growth factor receptors. *Mol Biol Med* 1983; **1**: 511-529 [PMID: 6094961]
- 13 Gill GN, Kawamoto T, Cochet C, Le A, Sato JD, Masui H, McLeod C, Mendelsohn J. Monoclonal anti-epidermal growth factor receptor antibodies which are inhibitors of epidermal growth factor binding and antagonists of epidermal growth factor-stimulated tyrosine protein kinase activity. *J Biol Chem* 1984; **259**: 7755-7760 [PMID: 6330079]
- 14 Fan Z, Lu Y, Wu X, Mendelsohn J. Antibody-induced epidermal growth factor receptor dimerization mediates inhibition of autocrine proliferation of A431 squamous carcinoma cells. *J Biol Chem* 1994; **269**: 27595-27602 [PMID: 7961676]
- 15 Maubec E, Petrow P, Scheer-Senarich I, Duvillard P, Lacroix L, Gelly J, Certain A, Duval X, Crickx B, Buffard V, Basset-Seguín N, Saez P, Duval-Modeste AB, Adamski H, Mansard S, Grange F, Domp Martin A, Faivre S, Mentré F, Avril MF. Phase II study of cetuximab as first-line single-drug therapy in patients with unresectable squamous cell carcinoma of the skin. *J Clin Oncol* 2011; **29**: 3419-3426 [PMID: 21810686 DOI: 10.1200/jco.2010.34.1735]
- 16 Bonner J, Giralt J, Harari P. Cetuximab prolongs survival

- in patients with locoregionally advanced squamous cell carcinoma of head and neck: A phase III study of high dose radiation therapy with or without cetuximab. *J Clin Oncol* (Meeting Abstracts) 2004; **22**: 5507a
- 17 **Wakeling AE**, Guy SP, Woodburn JR, Ashton SE, Curry BJ, Barker AJ, Gibson KH. ZD1839 (Iressa): an orally active inhibitor of epidermal growth factor signaling with potential for cancer therapy. *Cancer Res* 2002; **62**: 5749-5754 [PMID: 12384534]
  - 18 **Barnes CJ**, Bagheri-Yarmand R, Mandal M, Yang Z, Clayman GL, Hong WK, Kumar R. Suppression of epidermal growth factor receptor, mitogen-activated protein kinase, and Pak1 pathways and invasiveness of human cutaneous squamous cancer cells by the tyrosine kinase inhibitor ZD1839 (Iressa). *Mol Cancer Ther* 2003; **2**: 345-351 [PMID: 12700278]
  - 19 **Lewis CM**, Glisson BS, Feng L, Wan F, Tang X, Wistuba II, El-Naggar AK, Rosenthal DI, Chambers MS, Lustig RA, Weber RS. A phase II study of gefitinib for aggressive cutaneous squamous cell carcinoma of the head and neck. *Clin Cancer Res* 2012; **18**: 1435-1446 [PMID: 22261807 DOI: 10.1158/1078-0432.ccr-11-1951]
  - 20 **Bossi P**, Resteghini C, Perrone F, Cortelazzi B, Pilotti S, Maurichi A, Locati LD, Licitra L. Prolonged response using gefitinib followed by sirolimus for advanced cutaneous squamous cell carcinoma. *J Am Acad Dermatol* 2012; **67**: e226-e228 [PMID: 23062928 DOI: 10.1016/j.jaad.2012.04.029]
  - 21 **Moyer JD**, Barbacci EG, Iwata KK, Arnold L, Boman B, Cunningham A, DiOrio C, Doty J, Morin MJ, Moyer MP, Neveu M, Pollack VA, Pustilnik LR, Reynolds MM, Sloan D, Theleman A, Miller P. Induction of apoptosis and cell cycle arrest by CP-358,774, an inhibitor of epidermal growth factor receptor tyrosine kinase. *Cancer Res* 1997; **57**: 4838-4848 [PMID: 9354447]
  - 22 **Heath CH**, Deep NL, Nabell L, Carroll WR, Desmond R, Clemons L, Spencer S, Magnuson JS, Rosenthal EL. Phase 1 study of erlotinib plus radiation therapy in patients with advanced cutaneous squamous cell carcinoma. *Int J Radiat Oncol Biol Phys* 2013; **85**: 1275-1281 [PMID: 23182701 DOI: 10.1016/j.ijrobp.2012.09.030]
  - 23 **Read W**. Squamous carcinoma of the skin responding to erlotinib: Three cases. *J Clin Oncol* (Meeting Abstracts) 2007; **25**: 16519
  - 24 **Engelhardt C**, Curiel-Lewandrowski C, Warneke J, Cranmer L. Metastatic cutaneous squamous cell carcinoma responding to erlotinib therapy. *J Am Acad Dermatol* 2011; **65**: 237-238 [PMID: 21679836 DOI: 10.1016/j.jaad.2009.12.042]
  - 25 **El-Sawy T**, Sabichi AL, Myers JN, Kies MS, William WN, Glisson BS, Lippman S, Esmaili B. Epidermal growth factor receptor inhibitors for treatment of orbital squamous cell carcinoma. *Arch Ophthalmol* 2012; **130**: 1608-1611 [PMID: 23229707 DOI: 10.1001/archophthalmol.2012.2515]
  - 26 **Martins RG**, Parvathaneni U, Bauman JE, Sharma AK, Raez LE, Papagikos MA, Yunus F, Kurland BF, Eaton KD, Liao JJ, Mendez E, Futran N, Wang DX, Chai X, Wallace SG, Austin M, Schmidt R, Hayes DN. Cisplatin and radiotherapy with or without erlotinib in locally advanced squamous cell carcinoma of the head and neck: a randomized phase II trial. *J Clin Oncol* 2013; **31**: 1415-1421 [PMID: 23460709 DOI: 10.1200/jco.2012.46.3299]
  - 27 **Ivan D**, Prieto VG, Esmaili B, Wistuba II, Tang X, Lazar AJ. Epidermal growth factor receptor (EGFR) expression in periocular and extraocular sebaceous carcinoma. *J Cutan Pathol* 2010; **37**: 231-236 [PMID: 19614729 DOI: 10.1111/j.1600-0560.2009.01316.x]
  - 28 **Ganesan P**, Ali SM, Blumenschein GR. EGFR P735S mutation in cutaneous squamous cell carcinoma responsive to cetuximab-based therapy. *J Clin Oncol* 2012; In press
  - 29 **Fiala O**, Pesek M, Finek J, Krejci J, Ricar J, Bortlicek Z, Benesova L, Minarik M. Skin rash as useful marker of erlotinib efficacy in NSCLC and its impact on clinical practice. *Neoplasma* 2013; **60**: 26-32 [PMID: 23067213 DOI: 10.1016/j.lungcan.2012.05.055]
  - 30 **Lane K**, Goldstein SM. Erlotinib-associated trichomegaly. *Ophthalm Plast Reconstr Surg* 2007; **23**: 65-66 [PMID: 17237698 DOI: 10.1097/iop.0b013e31802d9802]
  - 31 **Methvin AB**, Gausas RE. Newly recognized ocular side effects of erlotinib. *Ophthalm Plast Reconstr Surg* 2007; **23**: 63-65 [PMID: 17237697 DOI: 10.1097/iop.0b013e31802d97f0]
  - 32 Report on new patented drugs - erbitux. Patented Medicine Prices Review Board, 2011. Available from: URL: <http://www.pmprb-cepmb.gc.ca/english/View.asp?x=669&mP=572>
  - 33 Report on new patented drugs - iressa. Patented Medicine Prices Review Board, 2011. Available from: URL: <http://www.pmprb-cepmb.gc.ca/ENGLISH/View.asp?x=1201&mP=572>
  - 34 **Gardner A**. "Tarceva battles lung cancer in some". U.S. News. July 22, 2011. Available from: URL: <http://health.usnews.com/health-news/family-health/cancer/articles/2011/07/22/tarceva-battles-lung-cancer-in-some>
  - 35 **Hahn H**, Wicking C, Zaphiropoulos PG, Gailani MR, Shanley S, Chidambaram A, Vorechovsky I, Holmberg E, Undén AB, Gillies S, Negus K, Smyth I, Pressman C, Leffell DJ, Gerrard B, Goldstein AM, Dean M, Toftgård R, Chenevix-Trench G, Wainwright B, Bale AE. Mutations of the human homolog of Drosophila patched in the nevoid basal cell carcinoma syndrome. *Cell* 1996; **85**: 841-851 [PMID: 8681379]
  - 36 **Gailani MR**, Stähle-Bäckdahl M, Leffell DJ, Glynn M, Zaphiropoulos PG, Pressman C, Undén AB, Dean M, Brash DE, Bale AE, Toftgård R. The role of the human homologue of Drosophila patched in sporadic basal cell carcinomas. *Nat Genet* 1996; **14**: 78-81 [PMID: 8782823]
  - 37 **Marigo V**, Davey RA, Zuo Y, Cunningham JM, Tabin CJ. Biochemical evidence that patched is the Hedgehog receptor. *Nature* 1996; **384**: 176-179 [PMID: 8906794]
  - 38 **Undén AB**, Holmberg E, Lundh-Rozell B, Stähle-Bäckdahl M, Zaphiropoulos PG, Toftgård R, Vorechovsky I. Mutations in the human homologue of Drosophila patched (PTCH) in basal cell carcinomas and the Gorlin syndrome: different in vivo mechanisms of PTCH inactivation. *Cancer Res* 1996; **56**: 4562-4565 [PMID: 8840960]
  - 39 **Dahmane N**, Lee J, Robins P, Heller P, Ruiz i Altaba A. Activation of the transcription factor Gli1 and the Sonic hedgehog signalling pathway in skin tumours. *Nature* 1997; **389**: 876-881 [PMID: 9349822]
  - 40 **Undén AB**, Zaphiropoulos PG, Bruce K, Toftgård R, Stähle-Bäckdahl M. Human patched (PTCH) mRNA is overexpressed consistently in tumor cells of both familial and sporadic basal cell carcinoma. *Cancer Res* 1997; **57**: 2336-2340 [PMID: 9192803]
  - 41 **Xie J**, Murone M, Luoh SM, Ryan A, Gu Q, Zhang C, Bonifas JM, Lam CW, Hynes M, Goddard A, Rosenthal A, Epstein EH, de Sauvage FJ. Activating Smoothed mutations in sporadic basal-cell carcinoma. *Nature* 1998; **391**: 90-92 [PMID: 9422511]
  - 42 **Hutchin ME**, Kariapper MS, Grachtchouk M, Wang A, Wei L, Cummings D, Liu J, Michael LE, Glick A, Dlugosz AA. Sustained Hedgehog signaling is required for basal cell carcinoma proliferation and survival: conditional skin tumorigenesis recapitulates the hair growth cycle. *Genes Dev* 2005; **19**: 214-223 [PMID: 15625189 DOI: 10.1101/gad.1258705]
  - 43 **LoRusso PM**, Rudin CM, Reddy JC, Tibes R, Weiss GJ, Borad MJ, Hann CL, Brahmer JR, Chang I, Darbonne WC, Graham RA, Zerivitz KL, Low JA, Von Hoff DD. Phase I trial of hedgehog pathway inhibitor vismodegib (GDC-0449) in patients with refractory, locally advanced or metastatic solid tumors. *Clin Cancer Res* 2011; **17**: 2502-2511 [PMID: 21300762 DOI: 10.1158/1078-0432.ccr-10-2745]
  - 44 **Tang JY**, Mackay-Wiggan JM, Aszterbaum M, Yauch RL,

- Lindgren J, Chang K, Coppola C, Chanana AM, Marji J, Bickers DR, Epstein EH. Inhibiting the hedgehog pathway in patients with the basal-cell nevus syndrome. *N Engl J Med* 2012; **366**: 2180-2188 [PMID: 22670904 DOI: 10.1056/nejmoa1113538]
- 45 **Von Hoff DD**, LoRusso PM, Rudin CM, Reddy JC, Yauch RL, Tibes R, Weiss GJ, Borad MJ, Hann CL, Brahmer JR, Mackey HM, Lum BL, Darbonne WC, Marsters JC, de Sauvage FJ, Low JA. Inhibition of the hedgehog pathway in advanced basal-cell carcinoma. *N Engl J Med* 2009; **361**: 1164-1172 [PMID: 19726763 DOI: 10.1056/nejmoa0905360]
- 46 **Lorusso PM**, Jimeno A, Dy G, Adjei A, Berlin J, Leichman L, Low JA, Colburn D, Chang I, Cheeti S, Jin JY, Graham RA. Pharmacokinetic dose-scheduling study of hedgehog pathway inhibitor vismodegib (GDC-0449) in patients with locally advanced or metastatic solid tumors. *Clin Cancer Res* 2011; **17**: 5774-5782 [PMID: 21753154 DOI: 10.1158/1078-0432.ccr-11-0972]
- 47 **Sekulic A**, Mangold AR, Northfelt DW, LoRusso PM. Advanced basal cell carcinoma of the skin: targeting the hedgehog pathway. *Curr Opin Oncol* 2013; **25**: 218-223 [PMID: 23493193 DOI: 10.1097/cco.0b013e32835ff438]
- 48 **Yin VT**, Pfeiffer ML, Esmali B. Targeted therapy for orbital and periocular basal cell carcinoma and squamous cell carcinoma. *Ophthalm Plast Reconstr Surg* 2013; **29**: 87-92 [PMID: 23446297 DOI: 10.1097/iop.0b013e3182831bf3]
- 49 **Gill HS**, Moscato EE, Chang AL, Soon S, Silkiss RZ. Vismodegib for periocular and orbital basal cell carcinoma. *JAMA Ophthalmol* 2013; **131**: 1591-1594 [PMID: 24136169 DOI: 10.1001/jamaophthalmol.2013.5018]
- 50 **Kahana A**, Worden FP, Elnor VM. Vismodegib as eye-sparing adjuvant treatment for orbital basal cell carcinoma. *JAMA Ophthalmol* 2013; **131**: 1364-1366 [PMID: 23907144 DOI: 10.1001/jamaophthalmol.2013.4430]
- 51 **Fellner C**. Vismodegib (erivedge) for advanced Basal cell carcinoma. *P T* 2012; **37**: 670-682 [PMID: 23319845]

P- Reviewer: Inan UU S- Editor: Wen LL L- Editor: A  
E- Editor: Lu YJ



## To explore and develop a model to maintain and build upon a dental clinic open for all in developing regions, with a primary focus on India

Ayushi Sugandhi, Brijesh Mangal, Amit Kumar Mishra, Bhavna Sethia

Ayushi Sugandhi, Index Dental College and Research Centre, Indore, Madhya Pradesh 452001, India

Brijesh Mangal, Bhavna Sethia, Modern Dental College and Research Centre, Indore, Madhya Pradesh 452001, India

Amit Kumar Mishra, ESIC Hospital, Nanda Nagar, Indore, (M.P) Madhya Pradesh 452001, India

Author contributions: All authors contributed to this paper.

Correspondence to: Dr. Brijesh Mangal, MDS (Master of Dental Surgery), Periodontics, Senior Lecturer, Modern Dental College and Research Centre, LG-21, 3-Urvashi Complex, Jaora Compound, Indore, Madhya Pradesh 452001, India. [brijeshmangal2000@gmail.com](mailto:brijeshmangal2000@gmail.com)

Telephone: +91-0731-4215248 Fax: +91-0731-2882700

Received: April 29, 2014 Revised: June 27, 2014

Accepted: July 25, 2014

Published online: September 16, 2014

found in the population younger than 20 years of age and mobile teeth in those older than 50 years of age; (3) Dental caries and mobile teeth are almost equally found in people of the age group 20-50 years old; (4) A significantly large proportion of those older than 50 years old have had all their teeth extracted; and (5) A significantly large proportion of the 20-30 years of age group has had no teeth extracted.

**CONCLUSION:** The model which we propose works well for low income patients; however, it places a lot of extra burden on the higher income group. A lot of effort can be put into generating revenue from other sources, including events and donations.

© 2014 Baishideng Publishing Group Inc. All rights reserved.

**Key words:** Dental clinic; Dentist; Dental health; Population; Dental treatment

### Abstract

**AIM:** To study a service model that enables a clinic to be open to all members of the community, irrespective of their ability to pay.

**METHODS:** Sampling methodology was used to gather information in two phases, with the city of Indore as the target region. In the first phase, dental professionals were surveyed to gather the cost of the facility, land and equipment and the cost of sustaining the practice. In the second phase, the residents of Indore were surveyed to collect information regarding their oral health problems and their expenditure for the same. Assessing the current situation, the questions to answer are related to the issues of dental health care access problems and the resources required, human and financial.

**RESULTS:** (1) People younger than 20 years of age form a large proportion (43%) of the population of the city and also a large proportion (54%) of people who visit dental clinics; (2) Dental caries are commonly

**Core tip:** One of the primary reasons for the challenges faced by dental health care in a developing country like India is that when primary health care systems were being implemented, dental health care was not included. Also, although expenditure on health care systems form a significant percentage of the gross domestic product (nearly 5%), it is very small compared to the total population of the country. On top of that, the amount of money spent on dental health care is less compared to some other nations. This has left dental health care in India far behind other health services. The following are some of the challenges faced by dental health care in India: (1) expensive treatment; (2) imbalanced distribution of clinics; (3) unawareness; (4) skewed population to dentist ratio; and (5) changing disease pattern and treatment needs. People in developing regions suffer from different types of dental diseases, which are curable with treatment but not affordable by most people. In this study, a service model



was developed that enables a clinic to be open to all members of the community, irrespective of their ability to pay.

Sugandhi A, Mangal B, Mishra AK, Sethia B. To explore and develop a model to maintain and build upon a dental clinic open for all in developing regions, with a primary focus on India. *World J Clin Cases* 2014; 2(9): 439-447 Available from: URL: <http://www.wjgnet.com/2307-8960/full/v2/i9/439.htm> DOI: <http://dx.doi.org/10.12998/wjcc.v2.i9.439>

## INTRODUCTION

In developing nations such as India, 70% of people live in rural areas and nearly 35% of population is below poverty line. In 2004-2005, around 39 million (30.6 and 8.4 million in rural and urban areas, respectively) of Indians fell into poverty as a result of out of pocket expenditures each year<sup>[1,2]</sup>. People do not have funds for eating, let alone dental and other medical health care. The impact of health expenditures are greater in rural areas and in poorer states where a greater proportion of the population live near the poverty line<sup>[2]</sup>. The total expenditure on health was estimated to be 4.13% of the gross domestic product (GDP) in 2008-2009, with public expenditure on health at 1.10% of the share of GDP<sup>[3]</sup>. Private expenditures on health have remained high over the last decade<sup>[4]</sup>. A greater proportion of resources are directed towards urban-based services and higher level services, with 29.2% of public expenditures (both central and state) allocated to urban allopathic services compared to 11.8% of public expenditures allocated to rural allopathic services in 2004-2005. This imbalanced allocation is compounded by the private sector's bias toward higher level curative services which, determined by market forces, tends to be centered in wealthier urban areas<sup>[5]</sup>. Most public health facilities lack efficiency, are understaffed and have poorly maintained or outdated medical equipment. In addition to the lack of funds and poor infrastructure, India faces a shortage of medical staff for these facilities, especially in rural regions where access to medical care is limited. Thus, it is important to build a model clinic that does not attempt to segregate the poor but is open to all with a sliding-fee schedule to make dental care affordable for the poor and uninsured.

### **What do we mean by developing regions?**

Development of a country is measured with the help of statistical indexes, such as per capita income (GDP), life expectancy, the rate of literacy, educational attainment, etc. The UN developed the *Human Development Index* (HDI)<sup>[6]</sup>, a standard mean of measuring human development. Thus, it helps to determine whether a country is a developed, developing or underdeveloped country.

A developing country has a low standard of democratic government, industrialization, social programs and

human rights guarantees. In other words, it can be said that a developing country has an undeveloped or developing industrial base and an inconsistent varying HDI. However, countries that have more advanced economies than other developing nations but have not fully demonstrated the signs of a developed country are called newly industrialized countries. Countries that have sustained good economic growth over a long period of time and have a good economic potential are termed emerging markets. India falls under this category of big emerging markets, the target of this study.

### **Why India**

Over the years, the Indian economy has grown a lot but differences between the rich and poor have widened. In India, the government and private sector provide health care jointly. The poor who were not able to afford expensive medical treatment earlier are still not able to afford it. Since oral health care is still in the developing stage in India, it is expensive compared to other medical treatments, putting it out of the reach of the common man. Private sector hospitals are primarily motivated by profit, thus leaving a majority of population unattended to with public health institutions as the only hope for such underprivileged people. Since these people form a large chunk of the Indian population (over 35%), the cost of treatment becomes all the more important.

### **Challenges to dental health care in India**

One of the primary reasons for the challenges faced by dental health care in India is that when primary health care systems were being implemented, dental health care was not included. Also, although expenditure on health care systems forms a significant percentage of the GDP (nearly 5%), it is very small compared to the total population of the country. On top of that, the amount of money spent on dental health care is much less compared to some other nations. This has left dental health care in India far behind other health services. The following are some of the challenges faced by dental health care in India.

**Expensive treatment:** The increasing cost of oral healthcare that is paid as "out of pocket" payments makes oral healthcare unaffordable for a growing number of people. The number of people who could not seek oral care because of a lack of money increased significantly between 1986 and 1995 and the proportion of people unable to afford basic oral healthcare has doubled in the last decade. Over 20 million Indians are pushed below the poverty line every year because of the effect of out of pocket spending on health care<sup>[7]</sup>.

**Imbalanced distribution of clinics:** In India, up to 80% of the population lives in rural areas without any access to dental health care<sup>[8]</sup>. Community oriented health programs are seldom found in rural areas. For any type of dental health care, they need to go to urban areas, thus

**Table 1** Demographics of Indore

Variable	n (%)
Population	
Total	2465827 (-)
Males	1289352 (53)
Females	1176475 (47)
Rural	735464 (29.7)
Males	379624 (15.3)
Females	355840 (14.4)
Urban	1730363 (70.3)
Males	909728 (36.9)
Females	820635 (33.4)
Age Distribution	
< 10 yr	538943 (21.8)
10-20 yr	524116 (21.2)
20-30 yr	460948 (18.6)
30-50 yr	625071 (25.3)
> 50 yr	309070 (12.5)

compounding the cost of treatment, which makes them unwilling to go for treatment.

**Unawareness:** It has been found that 30% of population were unaware of the ideal ways of avoiding tooth decay, gum diseases and oral cancer<sup>[9]</sup>. Only a small number of people go to a dentist on a regular basis or even in a medical emergency.

**Skewed population to dentist ratio:** The current dentist to population ratio in India is 1:10000<sup>[10]</sup> in urban and 1:2.5 lakh in rural areas<sup>[11]</sup>. This is a significant improvement from the 1980s when it was 1:80000. However, with the geographical imbalance of the situation of dental colleges, the ratio varies significantly in rural and urban areas.

**Changing disease pattern and treatment needs:** The effectiveness of preventive dentistry is leading to a change in the disease pattern as well as people becoming more aware and concerned about dental health care. Although this number is small it is increasing, thus it has led to a decrease in demand for tooth extraction to an increase in demand for conservative modalities, such as root canal treatment. This puts a lot of pressure on an already stressed out system to introduce different specializations in postgraduate courses.

#### **Fundamental causes of high cost of treatment**

The cost of treatment is one of the major concerns of the Indian population, forcing them to avoid treatment if at all possible. The following are some of the major reasons for the high cost of dental treatment in India: (1) a skewed dentist to population ratio, leading to a high demand for care; (2) rapidly changing technology and the cost to keep up with it; (3) more remuneration for qualified professionals; (4) high demand for better care; and (5) a large aging population needing special attention.

#### **Objectives of the study**

**Primary objective:** The primary objective is to explore

and develop a model to maintain and build upon a dental clinic open for all in the developing regions, with a primary focus on India.

**Secondary objective:** The secondary objectives are: to study the challenges in dental health care in India; to study the cost of setting up and maintaining a dental health care clinic; to study the common dental ailments prevailing in Indian patients; and to study the needs of different types of patients.

## **MATERIALS AND METHODS**

### **Methodology**

The underlying challenge to our study was to understand how to achieve a balance between providing dental care to low income patients and financial stability of the clinic. Thus, factors that affect patient care revenue, including the start-up and maintenance cost, needed to be assessed. This sequence of steps was followed to achieve this goal: (1) in assessing the current situation, the questions related to dental health care access problems and human and financial resources required need to be answered; and (2) the need to envision the desired solution and define what is to be achieved.

All our studies and surveys were carried out in the city of Indore, the most populous city in Madhya Pradesh, with a population of about 3600000<sup>[12]</sup>. Its population is a mix of low and high income. Although there are no specific data regarding the income of people in Indore, a survey of the population of Madhya Pradesh indicated that 38% of the urban population<sup>[13]</sup> lives below the poverty line. Thus, assuming that this data can be extended to the population in Indore, this number is a significantly large proportion of the population. There are four dental colleges and several public and private dental clinics around the city.

### **How do we assess the needs for such a clinic?**

As a first step, the needs of a dental clinic were determined. The assessment considered the following factors: (1) population demographics: collecting information regarding poverty, age and insurance is helpful to provide a perspective about the underlying population as dental disparities occur in many population subgroups. This information is available in the 2001 census of India<sup>[14]</sup> (Table 1); (2) dental needs of the target population; (3) accessibility of current dental care resources for the target population, including availability and utilization of public and private dental care units; and (4) community perceptions of the need for dental care resources.

In order to determine the dental needs of the people of Indore and status of the current dental health care in the city, a survey at four medical hospitals and several dental clinics was conducted to collect responses from 40 dentists across the city. The survey included a questionnaire (Table 2) to be filled in by the dentist.

The survey was carried out to identify the dental

**Table 2 Questionnaire to determine health care status and needs**

Age group	%
1 Percentage distribution of different age groups that have visited the dentist in the previous year	
< 10 yr	
10-20 yr	
20-30 yr	
30-50 yr	
> 50 yr	
2 Percentage distribution of different age groups needing dental treatment according to urgency of need	
< 10 yr	
10-20 yr	
20-30 yr	
30-50 yr	
> 50 yr	
3 Percentage distribution of children < 20 yr of age with the following diseases or dental ailments	
Caries	
Mobile teeth	
Gums pyorrhea	
Pulpal infection	
Others	
4 Percentage distribution of people between 20-50 yr of age with the following diseases or dental ailments	
Caries	
Mobile teeth	
Gums pyorrhea	
Pulpal infection	
Others	
5 Percentage distribution of people above 50 yr of age with the following diseases or dental ailments	
Caries	
Mobile teeth	
Gums pyorrhea	
Pulpal infection	
Others	
6 Percentage of different age groups who had all their teeth extracted	
< 10 yr	
10-20 yr	
20-30 yr	
30-50 yr	
> 50 yr	
7 Percentage of different age groups who had no teeth extracted	
< 10 yr	
10-20 yr	
20-30 yr	
30-50 yr	
> 50 yr	

health care needs and problems of different age groups and to identify the minimum level of care needed to be provided at the clinic.

The following section summarizes the results of the survey.

## RESULTS

Tables 3-6 and Figures 1-2 contain an average of the responses received from various sources for questions 1-7 in the survey (Table 2). The results from the data are: (1) people < 20 years of age form a large proportion (43%)

**Table 3 Percentage distribution by age of people visiting the dentist**

Age group	%
< 10 yr	23
10-20 yr	31
20-30 yr	19
30-50 yr	16
> 50 yr	11

**Table 4 Percentage distribution by age of people needing dental treatment according to urgency of need**

Age group	%
< 10 yr	15
10-20 yr	24
20-30 yr	13
30-50 yr	19
> 50 yr	29

**Table 5 Percentage distribution**

Disease	%
Children < 20 yrs of age with the following diseases or dental ailments	
Caries	61
Mobile teeth	20
Gums pyorrhea	4
Pulpal infection	12
Others	3
People between 20-50 yrs of age with the following diseases or dental ailments	
Caries	34
Mobile teeth	25
Gums pyorrhea	18
Pulpal infection	23
Others	10
People above 50 yrs of age with the following diseases or dental ailments	
Caries	24
Mobile teeth	59
Gums pyorrhea	3
Pulpal infection	12
Others	2

of the population of the city and a large proportion (54%) of the people who visit dental clinics; (2) dental caries is the most widespread dental disease (or ailment) faced by the population < 20 years of age; (3) mobile teeth is the most wide spread disease (or ailment) faced by the population > 50 years of age; (4) dental caries and mobile teeth are almost equally found in people in the 20-50 years of age group and together they form the most widespread disease (or ailment) in the age group; (5) A significantly large proportion of the > 50 years age group has had all their teeth extracted; and (6) a significantly large proportion of the 20-30 years age group had no teeth extracted.

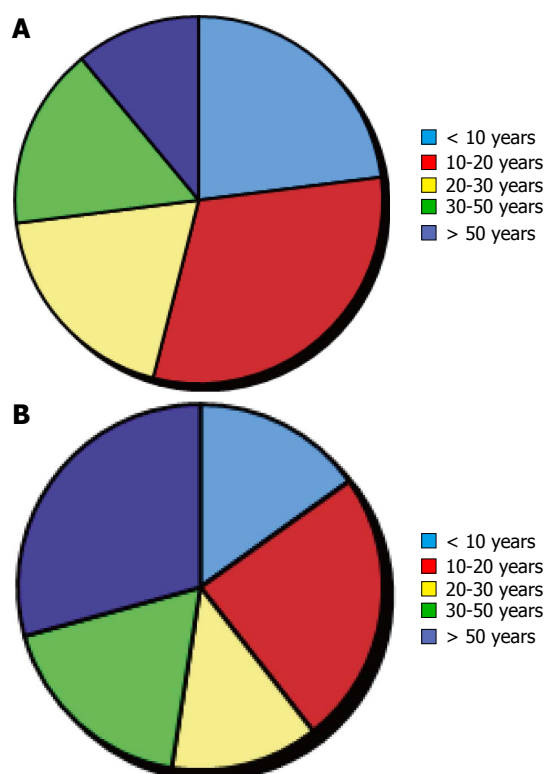
Based on these results, the following level of service to be provided at the clinic was identified.

### Basic oral health care service

Services are provided early in the disease process which

**Table 6 Percentage of different age groups**

Age group	%
Different age groups who had all their teeth extracted	
< 10 yr	3
10-20 yr	4
20-30 yr	3
30-50 yr	7
> 50 yr	42
Different age groups who had no teeth extracted	
< 10 yr	21
10-20 yr	33
20-30 yr	67
30-50 yr	8
> 50 yr	2



**Figure 1 Percentage distribution by age.** A: Percentage distribution by age of people visiting the dentist; B: Percentage distribution by age of people needing dental treatment according to urgency of need.

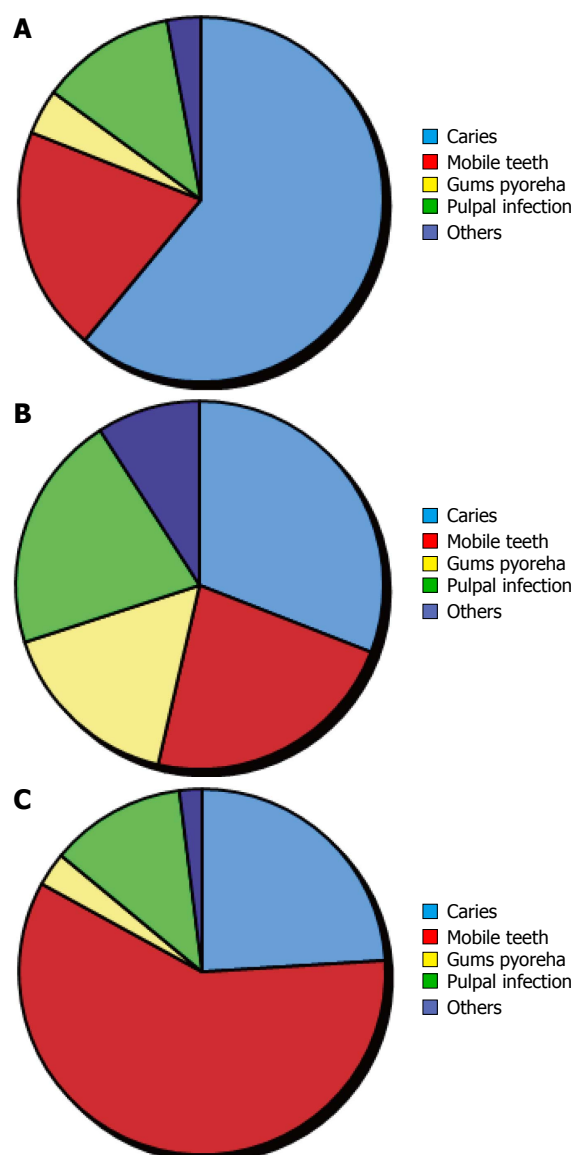
limits the disease from progressing further. These include diagnostic procedures, simple restoration of diseased teeth, early treatment of periodontal disease and many surgical procedures needed to treat oral pathologies.

### Preventive oral health services

These include the services which prevent the onset of the dental disease process.

### Methodology for expenses of a dental clinic

The next step was to estimate the expenses of a dental clinic. We conducted another survey (Table 7) to estimate start up and operational cost of a dental clinic. This survey was conducted with the suppliers for each of these



**Figure 2 Percentage distribution.** A: Percentage distribution of children < 20 year of age with the following diseases or dental ailments; B: Percentage distribution of people between 20-50 years of age with the following diseases or dental ailments; C: Percentage distribution of people over 50 years of age with the following diseases or dental ailments.

commodities to determine the costs and dentists were asked about average operational costs. Table 8 summarizes the result of the expense survey.

The equipment reserve fund is the money set apart for buying expensive equipment in the future. The list of essential dental equipment (Table 9) was determined from a list of the supplies and instruments from a dental clinic in Indore. As well as these dental instruments and supplies, a dental chair is also present at the clinic.

### Methodology for revenue from all source

In order to design a sliding fee model, the expected revenue from the clinic should be known in order to be able to sustain the clinic. Thus, a survey was conducted (Table 10) to determine the revenue from the clinic from sources at all the hospitals and clinics where the first survey



**Table 7 Questionnaire to determine expense of a dental clinic**

Expense	Cost
Start-up costs	
Construction (or remodeling cost)	
Dental equipment cost (including supplies and instruments)	
Furniture	
Record filling system	
Phone / intercom system	
Computer / data / billing	
Operating Expenses	
Dental assistant	
Billing Clerk (or Secretary or Receptionist)	
Clinical supplies	
Office supplies	
Equipment maintenance	
Housekeeping	
Laundry	
Communications	
Equipment reserve fund	

was conducted. Table 11 contains the results of dental clinic revenue survey.

#### **Do we need a mobile or fixed dental clinic?**

While calculating the expense of a clinic, we observed that the initial cost of starting the clinic was a major component (nearly 66%). Thus, the question was asked if it was necessary to have a fixed dental clinic or if a mobile clinic was sufficient, thus reducing the initial start-up cost. Mobile clinics are used to serve small pockets of patients scattered over a geographic area. The greatest advantage of such a clinic is that initial cost of setup is low but the future cost of maintenance is high and the life of a mobile facility is shorter than a fixed facility. One of the aims of the open-to-all clinic is to provide care to as many people as possible so as to maximize the revenue, which would be otherwise difficult in a mobile clinic. Thus, it makes more sense to have a fixed facility that can serve a large number of people.

#### **How to determine the patient charges?**

Once we had determined the expenses and revenue of a dental clinic had been determined, the next step was to develop a sliding fee model for patient charges, which was our initial goal. However, to build such a model we still needed information such as the average number patients from different income groups who visit dental clinics (Table 12). Another survey was conducted to determine this and the results are presented in Table 13.

After gathering all the relevant data, a sliding fee model that can be used for a dental clinic in India was developed. Figure 3 shows a graph from the G20 report<sup>[15]</sup> on poverty and inequality, showing the distribution of population and their income. It can be seen that less than one-fifth of the population lies below the two dollar (Rs. 100) line and around 1% lies below the one dollar (Rs. 50) line. The maximum percentage of the population earns close to Rs. 300-350 (per day).

**Table 8 Result of dental clinic expenses survey**

Expense	Cost
Start-up costs	
Construction (or remodeling cost)	Rs. 1205000
Dental equipment cost (including supplies and instruments)	Rs. 924500
Furniture	Rs. 45900
Record filling system	Rs. 12500
Phone / intercom system	Rs. 9300
Computer / data / billing	Rs. 35200
Total start-up costs	Rs. 2232400
Operating expenses	
Dentist	Rs. 750000
Dental assistant	Rs. 24000
Billing clerk (or secretary or receptionist)	Rs. 5000
Clinical supplies	Rs. 107900
Office supplies	Rs. 12500
Equipment maintenance	Rs. 21400
Housekeeping	Rs. 13600
Laundry	Rs. 26700
Communications	Rs. 24000
Equipment reserve fund	Rs. 10000
Total operating expenses	Rs. 995100
Total expenses	Rs. 3227500

The per visit charge for patients was determined, which was taken as the basis for providing a discount to the low income group. This had to be greater than the average per visit charge we estimated from our survey in order to sustain the clinic financially. The extra amount of money being charged to the high income group will help to subsidize the fees for the low income group. The population was then divided into five different groups on the basis of their income: (1) low income group, earning < Rs. 100/d; (2) lower-middle income group, earning > Rs. 100 but < Rs. 300/d; (3) middle income group, earning > Rs. 300 but < Rs. 400/d; (4) higher-middle income group, earning > Rs. 400 but < Rs. 1000/d; and (5) higher income group, earning > Rs. 1000/d.

Well off patients (including the higher middle and higher income group) constitute a significant proportion of the population that visits dental clinics (Table 13) and is nearly thrice as large as the low income patients that visit dental clinics. So, in order to provide X% discount to the lower income group, X /3% more is charged to the higher income group. The baseline charge of Rs. 400 per visit is fixed. It was estimated that the low income group would form approximately 10% of the total patients, lower middle income group nearly 16%, middle income nearly 35%, higher middle income nearly 22% and higher income nearly 17% of the total population. Discounts are now provided to various income groups (Table 14).

The bottom line in establishing various discounts is that the weighted sum of the discount and proportion of the population that group forms should not be negative if the clinic is to be sustained financially. The sliding fee schedule is used by totaling the full fees, multiplying the discount factor and subtracting to determine the charge to the patient. Note that the negative discount for the higher income group means that they have an extra fee

Table 9 List of essential dental equipments and supplies

Operative Instruments	Handpieces	Other Instruments	Operative supplies	Disposables	Infection control supplies	Standard oral surgery kit	Oral surgery instruments	Oral surgery supplies
Mouth Mirrors #5	High-Speed Handpiece	Dental Mirrors #5 for Exam Kits	Lidocaine 2% 1:100000 epi/ can	Tray Covers -Mauve IOOO/ Box	Latex Exam Gloves, pick size	Surgical Handles, #3	150 Forceps	3-0Silk Sutures, 18" Cutting Needle C-612/Box
Mirror Handles	Low-Speed Handpiece	Mirror Handles for Exam Kits	3% Mepivacaine/ can	2 x 2 gauze 8 ply 200/ Pkg	Sterile Surgeons Gloves, pick size	#9 Molt Periosteal Elevator	151 Forceps	3-0 Chromic Gut Sutures, 27", C-6 12/Box
23 Explorer/PSR	Ball-Bearing Contra Angle Assembly (Latch)	Explorer/PSR Periodontal Probes epi/can	5% Marcaine 1:200000	4 x 4 gauze 8 ply 200/ Pkg	Utility Gloves, Large	Needle Holder, Crile-Wood 6 inch	17 Forceps	Biopsy Bottles
Scissors, Iris 41/2"	Prophy Contra Angle Head Assembly	Cement Spatulas #24	27 gauge Long Needles/box	Dry-Gard Patient Bibs (rose) 500/ Case	Face Masks, 50 per box	301 Elevator	23 Forceps	Dry Socket Paste, 1 oz
Straight Economy	Contra Angle	Aspirating Syringe CW Type Composite	30 gauge Short Needles/ box	Napkin Holder	Safety Glasses	34 Elevator	88R Forceps	Iodoform Gauze 11/4" x 5 yd
College #317	Sheath	Instruments, Set of 3	Topical Anesthetic	Cotton Tip Applicators 6"	Disposable Cover Gowns, pick size	Minnesota Retractor	88L Forceps	Gelfoam
Spoon Excavator #38-39	Straight Attachment	Rubber Dam Punch	Sharps Container	Cotton Pellets #2 2000/Box	Antiseptic Hand Soap,	Curette	#1 Forceps	#15 Blades 100/Box
Amalgam Carrier Double Ended I	Spray and Clean Handpiece Lubricant	Rubber Dam Clamps, Starter Kit	Accu Film II/ box	Cotton Pellets #4 3000/Box	Cleaning Solution	Kelly Hemostats, Curved 51/2"	Cryer 30	
Amalgam Pluggers 1/2 Black			Amalgam -Regular Set/can	Cotton Rolls 2000/Box	Banicide Plus, 3.4%	Mouth Mirror 1 Mouth Handle	Cryer 31	
Cleoid-Discooid 89/92			Glass Ionomer Kit	Cotton Roll Dispenser	Disinfectant	Scissors Kelly 61/4", Curved	Crane Pick	
Cleoid-Discooid 3/6			IRM Caps 50/ Pkg. Clear Matrix Strips/box	Plastic Cups, 1000/ Case Cup Holder	Self Seal Sterilization Pouches 31/2" x 51/4",	Mouth Prop (adult) 2/ Box	Periosteal Elevator #9 Molt Heidbrink #1 Root Tip Pick	
Hollenbach Interproximal Carver			Safe-Tips EZ 150/ Pouch	High Speed Evacuation Tips SO/ Bag	Self Seal Sterilization Pouches 51/4" x 10"	Heidbrink #2 Root Tip Pick		
Articulatitilg Paper Forceps			Finishing Strips Coarse/ Medium 150/Box	Saliva Ejectors White Opaque 100/ Bag	Self Seal Sterilization Pouches 71/2 x 13",	Heidbrink #3 Root Tip Pick		
Rubber Dam Frame			Lightening Strips Medium 12/ tube	Dappen Dishes IOOO/Box	Chair Covers 48" x 56"	Tissue Forceps		
Rubber Dam Clamp Forceps			Polishing Paste/ can Toilemire Matrix Bands #1, .0015 12/ Pkg	Oral Evacuation Cleaner	Air/ Water Syringe Covers Light Handle Covers	Rongeurs Bone File, 12 Howard		
Dycal Instrument Tofflemire(s) 2 per kit, universal			Tofflemire Matrix Bands #2, .0015 12/ Pkg	Disposable Spatulas 100/ Box	ALLRAP 1200 Sheets/ Roll	Straight Hemostat, Crile 51/2"		
			Dycal Ivory Shade/ tube	Benda Brush 144/ Box	Mouthwash, may want to order pump	Needle Holder, Crile-Wood		
			Copalite 1/2oz/ bottle	Disposable Mirrors 72/Box	Periogard 16 oz	Surgical Handle		
			Vitrebond 3M/ box	Disposable Traps Dental Unit 144/ Box, pick size needed	Cure Sleeve, Steri Shield 500/ Box	Dental Mirror for Post-Op Kit		
				Disposable Traps Central Suction 8/ Box, pick size needed	Tube Sleeve 2"	Mirror Handles for Post-Op Kit		
				Paper Towels	X-ray sleeve 14" W x 13" D x 24 1/2" L	Iris Scissors for Post-Op Kit		
					Biological Monitoring System	Cotton forceps for Post-Op Kit		
					Biological Indicators (25/ box)			

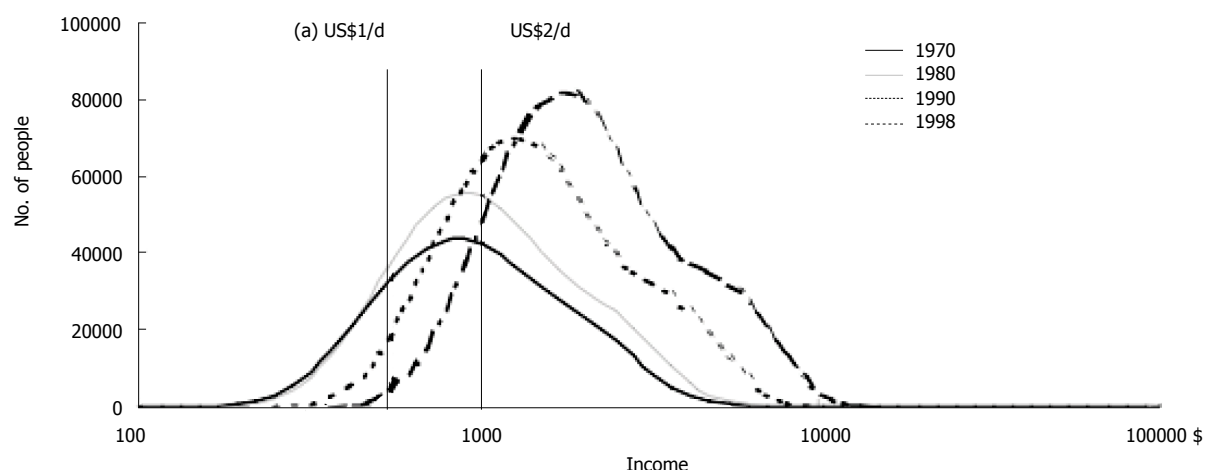


Figure 3 Income distribution in India

**Table 10** Questionnaire to determine revenue of a dental clinic

Source	Income
Patient care revenue - self pay	
Patient care revenue - insurance	
Patient care revenue - total	
Donations and other sources	
Individual donations	
Corporate donations	
Events	

**Table 11** Result of dental clinic revenue survey

Source	Income
Patient care revenue	
Patient care revenue - self pay	Rs. 866050
Patient care revenue - insurance	Rs. 166450
Patient care revenue - total	Rs. 1032500
Donations and other sources	
Individual donations	Rs. 9000
Corporate donations	Rs. 13000
Events	Rs. 6000
Donations - total	Rs. 28000
Total revenue (all sources)	Rs. 1060500

compared to the other income groups. There are fees for cases that would not be discounted in the case of a very high cost of treatment to the higher income group or giving a very large discount to a lower income group.

## DISCUSSION

These dental clinics address dental access problems and barriers in several ways and should be distributed throughout the state in urban and rural locations. They will serve communities for many years and maintain adequate hours of practice. Such dental clinics provide the most common dental services and, when additional services are needed, referrals to dental colleges are made. The clinic treated low income patients living below the poverty line at a very

**Table 12** Questionnaire to determine patient visits at a dental clinic

Variable	Value
Patient Visits	
Total number of patient visits:	
Well off patients <sup>1</sup>	
Low income patients <sup>2</sup>	
Patients with insurance	
Per patient visit charge	

<sup>1</sup>Well off patients are way above the poverty line and have no money constraints on the cost of treatment; <sup>2</sup>Low income patients are either below the poverty line or belong to a middle class that cannot afford expensive treatment.

**Table 13** Summary of patient visit survey

Variable	Value	%
Patient visits <sup>1</sup>		
Total number of patient visits: 3550		
Well off patients <sup>2</sup>	2610	74%
Low income patients <sup>3</sup>	940	26%
Patients with insurance	284	8%
Per visit patient charge	350	-

<sup>1</sup>All visits are expressed per year; <sup>2</sup>Well off patients are way above the poverty line and do not have any money constraints on the cost of treatment; <sup>3</sup>Low income patients are either below the poverty line or belong to a middle class that cannot afford expensive treatment.

low cost and also treated low middle and middle income group patients with a sufficient discount. Because most of the clinics are located within facilities that provide oral health care service at very low cost, especially for the low income group, patients might perceive them as being more accessible and familiar. This assistance and familiarity will reduce important nonfinancial access barriers. These dental clinics will offer a variety of oral health outreach and educational programs designed to reach broader groups and expand the oral health message, possibly preventing further dental problems.

**Table 14 Discounts to different income groups**

Income group	Discount
Lower income	75%
Lower-middle income	50%
Middle income	12.50%
Higher-middle income	0%
Higher income	-75%

In this study, it was found that the middle and higher income group constituted a significant portion of the population who visit the dental clinic, about thrice as large as the low income group, according to the result of survey given in Table 13. So, by giving 1/3% of discount to low income group, a better oral health service is provided for them (Table 14). The almost 75% discount to the low income group and 50% discount to lower middle income group allows problem free thinking in approaching oral health care. A slightly higher fee is charged to patients with insurance to increase revenue and reduce the burden on the higher income group patients. The study limitations are that the higher income group is charged an extra fee compared to other income groups.

One of the important aims of developing such a clinic was to provide dental care to low income populations who have poor access to health care. However, it should not be forgotten that a clinic is of no use if it cannot keep its door open. The more inclusive a clinic seeks to be in providing access, the greater the risk of operating in the red because of uncompensated care. By the same token, the more a clinic limits uncompensated care, the greater its risk of limiting access to dental care for people with low income. Thus, it is always important to achieve a balance between the two. The model which we have proposed in Table 14 works well for low income patients in terms of providing them dental care at low and affordable cost; however, it places a lot of extra burden on the higher income group, which may not be acceptable to them. In this case, effort can be put into generating revenue from other sources, including events and donations.

## COMMENTS

### Background

This model has been used to open a dental clinic in a developing region in India, providing access irrespective of the patient's ability to pay. So far, however, no such survey has taken place before opening a dental clinic in which both lower income and higher income group are considered.

### Research frontiers

The model given is good for giving dental care at low and affordable cost to the low income group but it places an extra burden on the higher income group which may not be acceptable to them.

### Innovation and breakthroughs

This is a pioneering study in which the authors used sampling methodology for

a survey conducted in two phases. The first phase was to ascertain the cost of the facility, land and equipment and the cost of sustaining the practice. In the second phase, a survey of the residents of Indore was carried out to collect information regarding their oral health problems and their expenditure for the same.

### Applications

In developing regions like India, this model may have success for people with low income and the extra burden on the higher income group can be distributed by generating funds by events and donations.

### Terminology

GDP: Gross Domestic Product; HDI: Human Development Index.

### Peer review

The paper is acceptable in its current form.

## REFERENCES

- 1 Selvaraj S, Karan A. Deepening Health Insecurity in India: Evidence from National Sample Surveys since 1980s. *E PVV* 2009; **44**: 55-60
- 2 Garg CC, Karan AK. Reducing out-of-pocket expenditures to reduce poverty: a disaggregated analysis at rural-urban and state level in India. *Health Policy Plan* 2009; **24**: 116-128 [PMID: 19095685 DOI: 10.1093/heapol/czn046]
- 3 India Go. New Delhi: Ministry of Health and Family Welfare; 2009. National Health Accounts India, 2004-2005
- 4 WHO. National Health Accounts. 2009 [EPB003(9-10)\_WHO\_India\_National 1 1]
- 5 Balarajan Y, Selvaraj S, Subramanian SV. Health care and equity in India. *Lancet* 2011 February 5; **377**: 505-511 [DOI: 10.1016/S0140-6736(10)61894-6]
- 6 United Nations Development Programme. Human development Report. 2010 Nov 4
- 7 Nanda Kishor KM. Public health implications of oral health -inequity in India. *JAMDSR* 2010; **1**
- 8 Sharma Rohit. India launches oral health strategy. *BMJ* 2000; **320**: 1030 [DOI: 10.1136/bmj.320.7241.1030/f (Published 15 April 2000)]
- 9 Bhat KP, Kumar A, Aruna CN. Preventive oral health knowledge, practice and behaviour of patients attending dental institution in Bangalore, India. *J Int Oral Health* 2010; **2**
- 10 Ahuja NK, Parmar R. Demographies & current scenario with respect to dentist, dental institutions & dental practice in India. *Ind J Dent Sciences* 2011; **2**: 8-14
- 11 Tandon S. Challenges to the oral health workforce in India. *J Dent Educ* 2004; **68**: 28-33 [PMID: 15282249]
- 12 Census of India. Madhya Pradesh: Directorate of census operations; Ministry of Home affairs, 2011. Available from: URL: [http://www.censusindia.gov.in/2011-prov-results/data\\_files/mp/00-1PPT\\_Madhya\\_P\\_cover.pdf](http://www.censusindia.gov.in/2011-prov-results/data_files/mp/00-1PPT_Madhya_P_cover.pdf)
- 13 SP Batra, Chitransh Singh and Mangesh tyagi. District wise poverty estimates for Madhya Pradesh; Poverty Monitoring and Policy Support Unit, 2004-05. Available from: URL: <http://mpplanningcommission.gov.in/international-aided-projects/pmpsu/outputs to be upload 08.11.10/District Wise Poverty Estimates.pdf>
- 14 Census of India. Madhya Pradesh: Directorate of census operations. Ministry of Home affairs, 2001
- 15 Xavier Sala-i-Martin, Mohapatra Sanket. Poverty, inequality & the distribution of income in the group of 20; Dept of Economics: Columbia university, 2002. Available from: URL: [http://archive.treasury.gov.au/documents/580/HTML/docshell.asp?URL=Poverty\\_Inequality.asp](http://archive.treasury.gov.au/documents/580/HTML/docshell.asp?URL=Poverty_Inequality.asp)

P- Reviewer: Oji C, Ozcan M S- Editor: Ji FF L- Editor: A  
E- Editor: Lu YJ





## Upper esophageal sphincter abnormalities are strongly predictive of treatment response in patients with achalasia

Simon C Mathews, Maria Ciarleglio, Yamile Haito Chavez, John O Clarke, Ellen Stein, Bani Chander Roland

Simon C Mathews, Department of Medicine, Johns Hopkins University School of Medicine, Baltimore, MD 21224, United States

Maria Ciarleglio, School of Public Health, Yale University, New Haven, CT 06520, United States

Yamile Haito Chavez, John O Clarke, Ellen Stein, Bani Chander Roland, Division of Gastroenterology and Hepatology, Johns Hopkins University School of Medicine, Baltimore, MD 21224, United States

**Author contributions:** Roland B designed the study; Roland B and Chavez YH enrolled patients, collected data, and performed chart review; Ciarleglio M performed the statistical analysis; Mathews S and Roland B wrote the manuscript; Stein E, Clarke J, and Roland B interpreted manometry; Stein E and Clarke J provided critical review of manuscript.

**Correspondence to:** Bani Chander Roland, MD, Assistant Professor of Medicine, Division of Gastroenterology and Hepatology, Johns Hopkins University School of Medicine, 4940 Eastern Avenue A-501, Baltimore, MD 21224, United States. [bchandle1@jhmi.edu](mailto:bchandle1@jhmi.edu)

Telephone: +1-410-5508124 Fax: +1-410-5507861

Received: January 5, 2014 Revised: March 29, 2014

Accepted: April 28, 2014

Published online: September 16, 2014

### Abstract

**AIM:** To investigate the relationship between upper esophageal sphincter abnormalities achalasia treatment

**METHODS:** We performed a retrospective study of 41 consecutive patients referred for high resolution esophageal manometry with a final manometric diagnosis of achalasia. Patients were sub-divided by presence or absence of Upper esophageal sphincter (UES) abnormality, and clinical and manometric profiles were compared. Correlation between UES abnormality and sub-type (*i.e.*, hypertensive, hypotensive or impaired relaxation) and a number of variables, including qualitative treatment response, achalasia sub-type, co-morbid medical illness, psychiatric illness, surgical history, dominant presenting

symptom, treatment type, age and gender were also evaluated.

**RESULTS:** Among all 41 patients, 24 (58.54%) had a UES abnormality present. There were no significant differences between the groups in terms of age, gender or any other clinical or demographic profiles. Among those with UES abnormalities, the majority were either hypertensive (41.67%) or had impaired relaxation (37.5%) as compared to hypotensive (20.83%), although this did not reach statistical significance ( $P = 0.42$ ). There was no specific association between treatment response and treatment type received; however, there was a significant association between UES abnormalities and treatment response. In patients with achalasia and concomitant UES abnormalities, 87.5% had poor treatment response, while only 12.5% had favorable response. In contrast, in patients with achalasia and no UES abnormalities, the majority (78.57%) had good treatment response, as compared to 21.43% with poor treatment response ( $P = 0.0001$ ). After controlling for achalasia sub-type, those with UES abnormality had 26 times greater odds of poor treatment response than those with no UES abnormality ( $P = 0.009$ ). Similarly, after controlling for treatment type, those with UES abnormality had 13.9 times greater odds of poor treatment response compared to those with no UES abnormality ( $P = 0.017$ ).

**CONCLUSION:** The presence of UES abnormalities in patients with achalasia significantly predicted poorer treatment response as compared to those with normal UES function.

© 2014 Baishideng Publishing Group Inc. All rights reserved.

**Key words:** Upper esophageal sphincter; Achalasia; Motility; Dysphagia; Esophageal disorders

**Core tip:** Our study highlights how the presence of

Upper esophageal sphincter (UES) abnormalities in patients with achalasia significantly predicted poorer treatment response as compared to those with normal UES function, irrespective of the type of treatment received or achalasia sub-type. We believe this finding is novel and represents an opportunity to more fully characterize upper esophageal sphincter pathology in a clinical context.

Mathews SC, Ciarleglio M, Chavez YH, Clarke JO, Stein E, Roland BC. Upper esophageal sphincter abnormalities are strongly predictive of treatment response in patients with achalasia. *World J Clin Cases* 2014; 2(9): 448-454 Available from: URL: <http://www.wjgnet.com/2307-8960/full/v2/i9/448.htm> DOI: <http://dx.doi.org/10.12998/wjcc.v2.i9.448>

## INTRODUCTION

Esophageal manometry has primarily been used to evaluate disorders of the esophageal body and lower esophageal sphincter. The introduction of high resolution esophageal manometry (HREM) has allowed the additional ability to assess the function of the upper esophageal sphincter (UES). While a wide spectrum of abnormalities such as alterations of resting UES pressures and impaired relaxation have been described in association with various motility disorders, the current Chicago Classification for manometric disorders<sup>[1]</sup> does not comment on UES findings. In addition, these abnormalities are often interpreted as incidental findings with no clearly defined clinical significance<sup>[2]</sup>.

Manometric abnormalities of the UES have been documented in numerous settings, including as a function of aging<sup>[3-6]</sup>. They have also been reported in association with specific motility disorders and symptoms including achalasia<sup>[7-10]</sup>, dysphagia<sup>[11-13]</sup>, Parkinson's disease<sup>[14-16]</sup>, oculopharyngeal muscular dystrophy<sup>[17]</sup>, cricopharyngeal bar<sup>[18]</sup>, globus<sup>[19]</sup>, Zenker's diverticulum<sup>[20]</sup>, and scleroderma<sup>[21]</sup>. However, the relationship and role of UES abnormalities in the context of motility disorders, specifically achalasia, remain unclear. While prior studies have demonstrated manometric UES abnormalities in achalasia<sup>[7-10]</sup>, its clinical relevance and effects on therapeutic outcomes has not been fully characterized and remains poorly understood<sup>[22]</sup>.

We hypothesized that UES abnormalities in association with achalasia may have significant clinical implications and may be useful as a predictor of treatment response. The primary aim of this study was therefore to assess the frequency and type of UES abnormalities in patients referred for HREM with a manometric diagnosis of achalasia. The secondary aims were to further characterize the correlation of specific UES abnormalities with achalasia sub-type and clinical characteristics and to additionally assess for differences in treatment response based on the presence or absence of UES abnormality.

## MATERIALS AND METHODS

### Subjects and study protocol

We performed a retrospective study of consecutive patients from October 2011 to November 2012 who underwent high resolution esophageal manometry at the Johns Hopkins Center for Neurogastroenterology and were subsequently diagnosed with Achalasia (Type I, II, or III) defined as based per the current Chicago Classification. Patients with a manometric diagnosis that was consistent with achalasia were subsequently sub-divided into those with normal and abnormal UES function. Primary indications for HREM in these patients included dysphagia, atypical chest pain, cough, belching, globus, regurgitation, nausea and vomiting. The study protocol was approved by the John Hopkins University School of Medicine Institutional Review Board (IRB). Our protocol was in compliance with the Health Insurance Portability and Accountability Act (HIPAA).

### Manometric protocol

Manometric studies were performed with the patients in the supine position after a minimum 6 h fasting period. A solid-state high-resolution manometer was used for all data collection (ManoScan360 High Resolution Manometry System, Sierra Scientific Instruments, and Los Angeles, CA). The manometric catheter has an outer diameter of 4 mm and 36 circumferential pressure sensors spaced 1 cm apart. The system is calibrated to record pressures between -20 and 600 mmHg, with fidelity of 2 mmHg. The catheter was positioned so that at least 2 distal sensors were in the stomach and 2 proximal sensors were located above the UES. The manometric protocol included a 5-min baseline recording, followed by 10 wet swallows of 5 cc water.

### Manometric data analysis

All manometry studies were analyzed using ManoView software (*Sierra Scientific Instruments*) and were appropriately corrected for thermal sensitivity of the pressure-sensing elements using thermal compensation. The esophageal pressure topography plot of each swallow in the HRM study was subsequently analyzed based on the current Chicago Classification scheme<sup>[1]</sup>. Sub-classification of achalasia was defined based on the scheme put forth by Pandolfino *et al.*<sup>[23]</sup> after the introduction of Chicago Classification: Type I representing classic achalasia with minimal esophageal contractility and low intraesophageal pressure, type II representing absent peristalsis and pan-esophageal pressure elevations, and type III representing lumen-obliterating esophageal spasm.

### Definition of UES pressure and abnormalities

UES pressures were measured throughout the study prior to each of the 10 wet swallows and abnormalities recorded included: hypotensive upper esophageal sphincter pressure, hypertensive upper esophageal sphincter pressure, and impaired UES relaxation. UES resting pressure

during the first 5 min of the study (while establishing the baseline), was excluded from our study. While there is some discrepancy in the literature regarding normal UES baseline values, normal ranges were established based on a prior study that sought the UES pressures in 73 healthy subjects. The normal range was defined by the 5<sup>th</sup> and / or 95<sup>th</sup> percentile value of the parameters found<sup>[24]</sup>. Based on these values, our patients were divided into those with normal UES function and abnormal function including: impaired UES relaxation (residual pressure > 12 mmHg), hypertensive resting UES pressure (> 104 mmHg), and hypotensive resting UES pressure (< 34 mmHg). While there is currently no well-established normal range for UES pressure, for the purposes of this study, we used the normal ranges (as referenced above) put forth by GIVEN imaging for their high resolution esophageal manometry ManoView software (*Sierra Scientific Instruments*).

The frequency of UES abnormalities and sub-type of UES abnormality present (*e.g.*, hypotensive, hypertensive, or impaired relaxation) was evaluated in this population of patients with achalasia. Additionally, we looked at the association between sub-types of achalasia (*e.g.*, I, II, or III) and the presence of specific UES abnormalities. In addition, clinical and demographic profiles were also examined and correlated with type of UES abnormality present including dominant presenting symptom, age, gender, race, co-morbid medical illness, psychiatric illness, and surgical history.

Lastly, we sought to determine whether or not the presence of an UES abnormality was predictive of either treatment received or treatment response in our patient population. Types of treatment included: endoscopic pneumatic dilation (PD), targeted endoscopic botulinum toxin (Botox) injections to the lower esophageal sphincter, medical therapy (*e.g.*, calcium channel blockers), Surgical myotomy with fundoplication, and Per Oral Endoscopic Myotomy (POEM). The majority of patients underwent surgical (*e.g.*, Heller myotomy) or endoscopic myotomy (*e.g.*, POEM) for definitive treatment. Only those patients deemed “higher risk” for invasive procedures were treated with PD, pharmacotherapy or LES botox injections. All treatment decisions were made by the primary gastroenterologist who evaluated the patient and discussed treatment options which each individual at the time of a clinical office visit. Also of note, individual therapeutic options were decided by the gastroenterologist and patient independent of the presence of a UES abnormality on their manometry study.

Treatment response was defined qualitatively by patients as being either “favorable” or “poor,” as based on significant improvement in post-treatment dysphagia rates and other primary associated symptoms (*e.g.*, regurgitation, weight loss, chest pain) with satisfactory improvement in symptoms and/or Eckardt score. This response was assessed in each individual patient by a gastroenterologist during a clinical office visit. A single gastroenterologist subsequently reviewed charts to document outcome data; this individual was blinded to the

presence or absence of UES abnormalities.

### Statistical analysis

Counts and percentages are reported. Fisher’s exact test was used to investigate the association between presence of UES abnormality and categorical variables of interest. Age was compared using a two-sample *t*-test. A multivariate logistic regression model was used to assess the relationship between presence of UES abnormality and treatment response, while controlling for the type of achalasia, given that Type II achalasia is known to have the best treatment response. Two-sided *P*-values ≤ 0.05 were considered statistically significant. All analyses were conducted using SAS v. 9.3 (SAS Institute; Cary, NC).

## RESULTS

A total of 41 patients with a diagnosis of achalasia were identified during the study period, of which 24 (58.5%) had an upper esophageal sphincter abnormality present on their HREM. There were no significant differences between the groups in terms of age or gender. When comparing individuals with no UES abnormality to individuals with UES abnormality, there were no significant differences in terms of age or gender [mean age 55.81 *vs* 53.32 (*P* = 0.6492) and 53.94% male *vs* 50.00% respectively (*P* = 1.0000)]

Among those patients with UES dysfunction present, the majority of those with abnormalities had a hypertensive basal UES pressure (41.67%) followed by impaired UES relaxation (37.5%) and a hypotensive basal UES pressure (20.83%). Patients with achalasia were also significantly more likely to have either a hypertensive UES resting pressure or have impaired UES relaxation as compared to having low UES basal pressures (20.83% *vs* 79.17%, *P* = 0.004).

The majority of our cohort with UES abnormalities had type II achalasia (Type II 65% *vs* Type I 20 % *vs* Type III 15%), which was also the case in patients with no UES abnormalities (Type II 56.25% *vs* Type I 18.75% *vs* Type III 25%). There was no significant association seen between sub-type of achalasia and the presence or absence of UES abnormality (*P* = 0.8916). There was no significant association between type of achalasia and sub-type of UES abnormality (*e.g.*, hypertensive, hypotensive, or impaired relaxation, *p* = 0.3345) (Table 1).

There were no significant differences observed between presence or absence of UES abnormality and type of treatment that patients received (*e.g.*, endoscopic dilatation, endoscopic Botulinum toxin injections, medical therapy, POEM, or surgical myotomy) (*P* = 0.40). Similarly, there was no association when examining therapeutic treatment response when each treatment was compared individually (endoscopic dilatation, *P* = 0.69; endoscopic Botox, *P* = 0.63; medical therapy, *p* = 0.21; POEM, *p* = 1.00; surgical myotomy, *P* = 0.08). Additionally, there was no association between type of UES abnormality and specific treatment type of received (*P* = 0.79) (Table 2).



**Table 1** Distribution of upper esophageal sphincter abnormality by achalasia sub-type

Type of achalasia	UES abnormality			P-value
	Hypertensive (%)	Hypotensive (%)	Impaired relaxation (%)	
Type I	22.22	50	0.00	0.3345
Type II	55.56	50	85.71	
Type III	22.22	0	14.29	

UES: Upper esophageal sphincter.

With respect to treatment response, patients with achalasia and a UES abnormality present had a significantly poorer treatment response as compared to those with no UES abnormality present. Specifically, in patients with achalasia and a concomitant UES abnormality, 87.5% rated their treatment response as poor, while only 12.5% rated it favorable ( $P < 0.0001$ ). In contrast, in patients with achalasia and no UES abnormality present, only 21.43% reported a poor treatment response while the majority (78.57%) rated it favorable ( $P = 0.0001$ ) (Table 3). However, individual UES abnormality type was not significantly associated with treatment response ( $P = 0.70$ ). In addition, after controlling for achalasia sub-type, those with UES abnormality had a 26 times greater odds of poor treatment response than those with no UES abnormality ( $P = 0.0099$ ). Similarly, after controlling for treatment type, those with a UES abnormality present had a 13.9 times greater odds of poor treatment response compared to those without ( $P = 0.0173$ ). There was no significant relationship observed when comparing treatment response with achalasia sub-type ( $P = 0.2163$ ).

There was no significant association between initial dominant symptom presentation (dysphagia, chest pain, GERD, globus sensation, hiccups, or “other” dominant symptom) and presence or absence of UES abnormality ( $P = 0.87$ ). Similarly, when examining these symptoms individually, there was no association between presence of UES abnormalities with any primary symptoms (dysphagia,  $P = 0.7289$ ; chest pain,  $P = 1.000$ ; GERD,  $P = 0.5598$ ; globus sensation,  $P = 1.000$ ; hiccups,  $P = 1.0000$ ; other dominant symptom,  $P = 1.000$ ).

The relationship between underlying medical co-morbidities with presence or absence of UES abnormalities was also assessed, and no significant associations were observed (diabetes,  $P = 0.2072$ ; scleroderma,  $P = 1.0000$ ; asthma,  $P = 1.0000$ ; stroke,  $P = 0.4146$ ; dementia,  $P = 0.4146$ ; gastroparesis,  $P = 1.0000$ ; achalasia,  $P = 0.4328$ ). Additionally, we found no association between psychiatric disorders and presence or absence of UES abnormalities (psychiatric disorders,  $P = 0.7364$ ; depression,  $P = 1.0000$ ; anxiety,  $P = 0.6293$ ; other psychiatric disorders [including bipolar disorder and schizophrenia],  $P = 1.0000$ ). There was also no significant association observed between history of prior esophageal or other relevant surgeries and presence or absence of UES abnormality (History of any prior surgery,  $P = 0.752$ ; larynx surgery,  $P = 1.0000$ ;

esophageal surgery,  $P = 0.3725$ ; spine surgery,  $P = 0.5024$ ; all additional surgeries,  $P = 1.0000$ ).

## DISCUSSION

The pathophysiology of disorders affecting the upper esophageal sphincter is incompletely understood. The advent of solid state, high resolution esophageal manometry has improved our understanding and ability to evaluate the UES and pharyngeal region. In the present study, upper esophageal sphincter abnormalities were not only a frequent finding in patients with achalasia, but additionally were useful in predicting treatment response. The association of UES abnormalities with treatment response remained even after adjusting for type of treatment received. Interestingly, among patients with achalasia, UES abnormalities were more common than normal UES function in this population. Further, the presence of UES abnormalities in patients with achalasia significantly predicted poorer treatment response when compared to those with normal UES function, irrespective of the type of treatment received or the sub-type of achalasia that was being treated. Similar to prior studies, the present study also demonstrated that in patients with UES abnormalities, Type II achalasia was the most common sub-type<sup>[24-26]</sup>; however, there was no association observed between sub-type of achalasia and presence of UES dysfunction.

Malhi-Chowla *et al*<sup>[22]</sup> previously reported that UES abnormalities are a common incidental finding on manometric studies, even in the absence of abnormal radiographic signs or upper esophageal sphincter symptoms. These authors concluded that routine UES manometry with esophageal manometry was therefore not always useful, particularly when UES dysfunction was not suspected clinically. In contrast to their findings, with our assessment of clinical outcomes in a large group of patients with achalasia, the present study provides direct evidence that UES abnormalities may be clinically relevant, specifically in predicting treatment response in individuals with achalasia. As a result, our findings suggest a direct association between UES dysfunction and poorer outcomes in this patient population, and further provide support for careful manometric UES evaluation even when a motility disorder with a predominantly lower esophageal pathology (*i.e.*, achalasia) is suspected.

The finding that UES abnormalities in achalasia is strongly predictive of poorer treatment response suggests that this sub-population with UES dysfunction may have more severe disease with potentially more extensive and further proximal esophageal involvement. While prior studies have suggested that UES abnormalities appear to be associated with achalasia and other esophageal motility disorders<sup>[11-21]</sup>, none of those studies directly assessed clinical significance or response to treatment.

Better treatment response in patients with type II achalasia has been well described in several studies<sup>[26-28]</sup>. It is additionally well known that patients with type III



**Table 2** Type of treatment received based on upper esophageal sphincter abnormality sub-type

Treatment	UES abnormality			P-value
	Hypertensive (%)	Hypotensive (%)	Impaired relaxation (%)	
Pneumatic dilatation	0	25	11.11	0.3967
Endoscopic botox treatment	25	0	22.22	
Medical therapy	0	0	22.22	
POEM	12.5	0	11.11	
Surgical myotomy	62.5	75	33.33	

UES: Upper esophageal sphincter.

**Table 3** Treatment response based on presence of upper esophageal sphincter abnormality

Treatment response	No UES abnormality	UES abnormality	P-value
Favorable	78.57%	12.50%	< 0.0001
Poor	21.43%	87.50%	

UES: Upper esophageal sphincter.

achalasia have the worst response to all therapies. However, even after controlling for type of achalasia, our results still demonstrated that treatment response was significantly better in all types of achalasia without UES abnormalities as compared to patients with concurrent achalasia and UES dysfunction. In other words, UES dysfunction appeared to independently predict treatment failure and normal UES function independently predicted better treatment response, regardless of achalasia sub-type.

UES dysfunction in achalasia has previously been described, specifically with impaired UES relaxation reported as the most common abnormality among patients with achalasia. Yoneyama *et al*<sup>[10]</sup> compared the UES manometric characteristics of 15 patients with diagnosis of achalasia as compared to 10 healthy volunteers and concluded that UES relaxation in patients with achalasia is incomplete. In the present study, we found a very high frequency of concomitant UES abnormalities among patients with achalasia (54%). Further, these individuals with UES abnormalities were more likely to have either impairment of UES relaxation or a hypertensive resting pressure as compared to being hypotensive. Although achalasia classically spares striated muscle, both prior literature and the results of the present study demonstrate a high frequency of upper esophageal sphincter involvement in this specific patient population.

In exploring what may account for this finding, it is plausible that increased UES pressure represents a compensatory or protective effect toward inadequate esophageal clearance in achalasia. Prior studies have also reported a reflexive hypertensive upper esophageal resting pressures after intraesophageal distension<sup>[29]</sup>. These investigators proposed that this may be a result of the UES serving as a dynamic barrier to esophagopharyngeal reflux and subsequent bronchial aspiration. Another

possibility is that a neural feedback mechanism exists between UES relaxation and tension in the esophageal wall, such that increased resting pressure in the esophageal body transmits directly to the UES.

A paradoxical increase in UES pressure may also result from the loss of inhibitory neurons more proximally in patients with achalasia who may have more extensive esophageal involvement. A subset of patients with achalasia may also have more significant vagal involvement with Wallerian degeneration in the vagal fibers that supply the esophagus. In this context, the presence or severity of UES abnormalities may potentially be useful as a predictor to treatment response in achalasia. It is also possible that UES dysfunction in achalasia is simply a reflection of more severe disease and may reverse with treatment. In fact, prior studies have demonstrated that UES abnormalities disappear after pneumatic dilation<sup>[13]</sup>, suggesting that reversal of UES dysfunction may be used as one of the predictors of treatment response. Lastly, although it is generally believed that the upper third of the esophagus is composed primarily of striated muscle, this may not necessarily be the case in all individuals. Interestingly, in one autopsy study, smooth muscle fibers in the circular muscle up to the level of the upper esophageal sphincter were found in 45% of specimens<sup>[30]</sup>.

Our study is the first to directly report on the potential clinical significance of UES abnormalities in treatment outcome in patients with achalasia; however, the authors acknowledge that there were significant limitations to the present study. First, this was a retrospective analysis which inherently limits the ability to draw causative conclusions. However, given the limited literature on UES abnormalities and clinical outcomes in patients with achalasia, it adds significant value in identifying key areas of further study in a larger, prospective evaluation. Another limitation is that treatment response was based on subjective evaluation by the patient of improvement in primary symptoms (and Eckardt scores were not assessed in all patients), which was collected by chart review based on the assessment of the clinical provider. A more objective measure such as a pre and post-treatment Eckardt score, barium esophogram, or repeat manometric study would have provided more objective outcome data; however, this was not possible given the retrospective nature of the study. In addition, further correlation with presence or resolution of UES abnormality post proce-

dures would have been ideal, but this was not feasible in this retrospective setting. Nevertheless, our subjective measure was able to reliably demonstrate a significant clinical difference. It is also important to note that this study took place at a tertiary care/motility referral center. Consequently, the results of this study may not be as generalizable to the general patient population. However, the demographics and presentation profile of our patient population appear largely similar to those in non-academic settings. Lastly, given that UES findings are not routinely reported on esophageal manometry studies and not formally included in any manometry classification systems at this time, it is likely that some studies that were interpreted as “normal,” actually had UES abnormalities present. Thus, this study may even under-represent the true frequency of UES dysfunction among patients with achalasia.

In conclusion, our study illustrates that upper esophageal sphincter abnormalities in patients with achalasia have significant value in predicting treatment outcome. Our findings not only suggest a direct association between UES dysfunction and poorer outcomes in this population, but additionally provide support for manometric UES evaluation in all patients referred for HREM in whom an esophageal motility is suspected. Further, large scale studies are needed to determine whether specific UES abnormalities have additional prognostic value and may also clarify the underlying pathophysiologic mechanism driving the poorer outcomes seen in our study. Prospective evaluation is also needed to further delineate the underlying mechanism and natural history of UES dysfunction in achalasia in order to optimize therapeutic treatment modalities.

## COMMENTS

### Background

High resolution esophageal manometry has allowed the ability to assess the upper esophageal sphincter (UES). However, UES abnormalities are often interpreted as incidental findings with no defined clinical significance.

### Research frontiers

The way in which UES abnormalities impact clinical outcomes in achalasia is unknown. We hypothesized that UES abnormalities have clinical significance and may predict treatment response in patients with achalasia.

### Innovations and breakthroughs

The authors found that UES abnormalities were associated with worse treatment outcomes in achalasia patients. Prior studies do not focus on specific clinical outcomes.

### Applications

These results, in combination with future studies, could aid in identifying which patients are more likely to succeed with achalasia treatment and could further direct treatment of UES conditions.

### Terminology

UES refers to the upper esophageal sphincter.

### Peer review

This manuscript assesses the function of UES in patients with achalasia. It is interesting. Manuscript is well written and easy to follow.

## REFERENCES

- 1 Bredenoord AJ, Fox M, Kahrilas PJ. International High

Resolution Manometry Working Group. Chicago classification criteria of esophageal motility disorders defined in high resolution esophageal pressure topography. *Neurogastroenterol Motil* 2012; **24** Suppl 1: 57-65 [PMID: 22248109 DOI: 10.1111/j.1365-2982.2011.01834.x]

- 2 Wang YT, Yazaki E, Sifrim D. High-resolution Manometry: Esophageal Disorders Not Addressed by the “Chicago Classification”. *J Neurogastroenterol Motil* 2012; **18**: 365-372 [PMID: 23105996 DOI: 10.5056/jnm.2012.18.4.365]
- 3 Meier-Ewert HK, Van Herwaarden MA, Gideon RM, Castelli JA, Achem S, Castell DO. Effect of age on differences in upper esophageal sphincter and pharynx pressures between patients with dysphagia and control subjects. *Am J Gastroenterol* 2001; **96**: 35-40 [PMID: 11197284 DOI: 10.1111/j.1572-0241.2001.03448.x]
- 4 Fulp SR, Dalton CB, Castell JA, Castell DO. Aging-related alterations in human upper esophageal sphincter function. *Am J Gastroenterol* 1990; **85**: 1569-1572 [PMID: 2252018]
- 5 Ribeiro AC, Klingler PJ, Hinder RA, DeVault K. Esophageal manometry: a comparison of findings in younger and older patients. *Am J Gastroenterol* 1998; **93**: 706-710 [PMID: 9625113 DOI: 10.1111/j.1572-0241.1998.210\_a.x]
- 6 Ren J, Shaker R, Zamir Z, Dodds WJ, Hogan WJ, Hoffmann RG. Effect of age and bolus variables on the coordination of the glottis and upper esophageal sphincter during swallowing. *Am J Gastroenterol* 1993; **88**: 665-669 [PMID: 8480728]
- 7 DeVault KR. Incomplete upper esophageal sphincter relaxation: association with achalasia but no other esophageal motility disorders. *Dysphagia* 1997; **12**: 157-60 [PMID: 9190101 DOI: 10.1007/PL00009530]
- 8 Dudnick RS, Castell JA, Castell DO. Abnormal upper esophageal sphincter function in achalasia. *Am J Gastroenterol* 1992; **87**: 1712-1715 [PMID: 1449131]
- 9 Zhang ZG, Diamant NE. Repetitive contractions of the upper esophageal body and sphincter in achalasia. *Dysphagia* 1994; **9**: 12-19 [PMID: 8131419 DOI: 10.1007/BF00262753]
- 10 Yoneyama F, Miyachi M, Nimura Y. Manometric findings of the upper esophageal sphincter in esophageal achalasia. *World J Surg* 1998; **22**: 1043-1046; discussion 1043-1046 [PMID: 9747164 DOI: 10.1007/s002689900514]
- 11 Hila A, Castell JA, Castell DO. Pharyngeal and upper esophageal sphincter manometry in the evaluation of dysphagia. *J Clin Gastroenterol* 2001; **33**: 355-361 [PMID: 11606849 DOI: 10.1097/00004836-200111000-00003]
- 12 Xue S, Katz PO, Castell JA, Castell DO. Upper esophageal sphincter and pharyngeal manometry: which patients? American Gastroenterological Association Annual Meeting. USA, CA: San Diego, 2000; 118: A410
- 13 Hatlebakk JG, Castell JA, Spiegel J, Paoletti V, Katz PO, Castell DO. Dilatation therapy for dysphagia in patients with upper esophageal sphincter dysfunction--manometric and symptomatic response. *Dis Esophagus* 1998; **11**: 254-259 [PMID: 10071809]
- 14 Ali GN, Wallace KL, Schwartz R, DeCarle DJ, Zagami AS, Cook IJ. Mechanisms of oral-pharyngeal dysphagia in patients with Parkinson's disease. *Gastroenterology* 1996; **110**: 383-392 [PMID: 8566584 DOI: 10.1053/gast.1996.v110.pm8566584]
- 15 Johnston BT, Li Q, Castell JA, Castell DO. Swallowing and esophageal function in Parkinson's disease. *Am J Gastroenterol* 1995; **90**: 1741-1716 [PMID: 7572887]
- 16 Higo R, Tayama N, Watanabe T, Niimi S. Abnormal elevation of resting pressure at the upper esophageal sphincter of Parkinson's disease patients. *Eur Arch Otorhinolaryngol* 2001; **258**: 552-556 [PMID: 11829195 DOI: 10.1007/s004050100401]
- 17 Castell JA, Castell DO, Duranceau CA, Topart P. Manometric characteristics of the pharynx, upper esophageal sphincter, esophagus, and lower esophageal sphincter in patients with oculopharyngeal muscular dystrophy. *Dysphagia* 1995; **10**: 22-26 [PMID: 7859528 DOI: 10.1007/BF00261275]

- 18 **Hirano I**, Kahrilas PJ. A 78-year-old man with difficulty swallowing. *Clin Gastroenterol Hepatol* 2011; **9**: 470-474 [PMID: 21320642 DOI: 10.1016/j.cgh.2011.02.001]
- 19 **Corso MJ**, Pursnani KG, Mohiuddin MA, Gideon RM, Castell JA, Katzka DA, Katz PO, Castell DO. Globus sensation is associated with hypertensive upper esophageal sphincter but not with gastroesophageal reflux. *Dig Dis Sci* 1998; **43**: 1513-1517 [PMID: 9690388 DOI: 10.1023/A:1018862814873]
- 20 **Cook IJ**, Gabb M, Panagopoulos V, Jamieson GG, Dodds WJ, Dent J, Shearman DJ. Pharyngeal (Zenker's) diverticulum is a disorder of upper esophageal sphincter opening. *Gastroenterology* 1992; **103**: 1229-1235 [PMID: 1397879]
- 21 **Yarze JC**, Varga J, Stampfl D, Castell DO, Jimenez SA. Esophageal function in systemic sclerosis: a prospective evaluation of motility and acid reflux in 36 patients. *Am J Gastroenterol* 1993; **88**: 870-876 [PMID: 8503383]
- 22 **Malhi-Chowla N**, Achem SR, Stark ME, DeVault KR. Manometry of the upper esophageal sphincter and pharynx is not useful in unselected patients referred for esophageal testing. *Am J Gastroenterol* 2000; **95**: 1417-1421 [PMID: 10894573 DOI: 10.1111/j.1572-0241.2000.02072.x]
- 23 **Pandolfino JE**, Kwiatek MA, Nealis T, Bulsiewicz W, Post J, Kahrilas PJ. Achalasia: a new clinically relevant classification by high-resolution manometry. *Gastroenterology* 2008; **135**: 1526-1533 [PMID: 18722376 DOI: 10.1053/j.gastro.2008.07.022]
- 24 **Khandelwal S**, Costarella D, Parks T. Normal Values of Analytical Parameters for ManoScan/Mano View High-Resolution Esophageal Manometry System, 2007: 1-4
- 25 **Roman S**, Zerbib F, Quenehervé L, Clermidy H, Varannes SB, Mion F. The Chicago classification for achalasia in a French multicentric cohort. *Dig Liver Dis* 2012; **44**: 976-980 [PMID: 22938702 DOI: 10.1016/j.dld.2012.07.019]
- 26 **Min M**, Peng LH, Yang YS, Hou XH, Guo RB, Wang WF, Sun G, Wang XX. Characteristics of achalasia subtypes in untreated Chinese patients: a high-resolution manometry study. *J Dig Dis* 2012; **13**: 504-509 [PMID: 22988923 DOI: 10.1111/j.1751-2980.2012.00622.x]
- 27 **Rohof WO**, Salvador R, Annese V, Bruley des Varannes S, Chaussade S, Costantini M, Elizalde JL, Gaudric M, Smout AJ, Tack J, Busch OR, Zaninotto G, Boeckxstaens GE. Outcomes of treatment for achalasia depend on manometric subtype. *Gastroenterology* 2013; **144**: 718-725; quiz e13-e14 [PMID: 23277105 DOI: 10.1053/j.gastro.2012.12.027]
- 28 **Pratap N**, Kalapala R, Darisetty S, Joshi N, Ramchandani M, Banerjee R, Lakhtakia S, Gupta R, Tandan M, Rao GV, Reddy DN. Achalasia cardia subtyping by high-resolution manometry predicts the therapeutic outcome of pneumatic balloon dilatation. *J Neurogastroenterol Motil* 2011; **17**: 48-53 [PMID: 21369491 DOI: 10.5056/jnm.2011.17.1.48]
- 29 **Enzmann DR**, Harell GS, Zboralske FF. Upper esophageal responses to intraluminal distention in man. *Gastroenterology* 1977; **72**: 1292-1298 [PMID: 858473]
- 30 **Meyer GM**, Castell DO. Anatomy and physiology of the esophageal body. In: Castell DO, Johnson LF, editors. *Esophageal Function in Health and Disease*. New York: Elsevier Biomedical, 1983: 1-16

**P- Reviewer:** Fujino Y, Kim JS, Morales-Gonzalez JA

**S- Editor:** Qi Y **L- Editor:** A **E- Editor:** Lu YJ



## Incidental findings of pericardial calcification

Tin Nguyen, Charles Phillips, Assad Movahed

Tin Nguyen, Charles Phillips, Assad Movahed, Department of Cardiovascular Sciences, East Carolina University, Brody School of Medicine, East Carolina Heart Institute, Greenville, NC 27834, United States

Author contributions: Nguyen T, Phillips C and Movahed A contributed to the manuscript writing and revision.

Supported by The "East Carolina Heart Institute"

Correspondence to: Assad Movahed, MD, FACC, FACP, Department of Cardiovascular Sciences, East Carolina University, Brody School of Medicine, East Carolina Heart Institute, 115 Heart Drive, Mail Stop 651, Greenville, NC 27834, United States. [movaheda@ecu.edu](mailto:movaheda@ecu.edu)

Telephone: +1-252-7444400 Fax: +1-252-7447724

Received: May 2, 2014 Revised: May 22, 2014

Accepted: June 27, 2014

Published online: September 16, 2014

**Core tip:** Pericardial calcification is rare but may be found more often due to the widespread use of cardiac computed tomography for the assessment of coronary atherosclerosis. Pericardial calcification can be seen in the absence of constrictive physiology and therefore, it should be evaluated with full clinical knowledge.

Nguyen T, Phillips C, Movahed A. Incidental findings of pericardial calcification. *World J Clin Cases* 2014; 2(9): 455-458  
Available from: URL: <http://www.wjgnet.com/2307-8960/full/v2/i9/455.htm> DOI: <http://dx.doi.org/10.12998/wjcc.v2.i9.455>

### Abstract

Calcification of the pericardium is a relatively rare finding and often has an uncertain etiology. Incidental findings of pericardial calcification may increase due to widespread application of cardiac computed tomography for the assessment of coronary atherosclerosis in the appropriate clinical setting using coronary artery calcium scoring and/or coronary angiography. Pericardial calcification alone is asymptomatic and is neither necessary nor sufficient for the diagnosis of pericardial constriction. Its presence may suggest of diffused pericardial scarring and consequently, its pathological involvement with pericardial constriction. Calcification of the pericardium must be evaluated with full clinical knowledge to facilitate an accurate diagnosis and an appropriate therapy when required. Our objective is to present a case of asymptomatic pericardial calcification and to discuss the importance of its clinical implications.

© 2014 Baishideng Publishing Group Inc. All rights reserved.

**Key words:** Pericardial calcification; Constrictive pericarditis; Cardiac computed tomography

### INTRODUCTION

Calcification of the pericardium is relatively rare and often has an uncertain etiology<sup>[1]</sup>. Incidental findings of pericardial calcification may increase in the asymptomatic subjects due to the widespread use of cardiac computed tomography for coronary artery calcium scoring (CACS) with and without contrast cardiac computed tomography angiography (CCTA) for the assessment of coronary atherosclerosis. Although detecting pericardial calcification may have important clinical implication for confirming the diagnosis of constrictive pericarditis, its presence should be evaluated with full clinical knowledge to facilitate an accurate diagnosis and an appropriate medical management when it is required. Avoiding inaccurate diagnosis of constrictive pericarditis based only on the presence of calcium in an asymptomatic subject relieves patient's concern and prevents unnecessary, expensive diagnostic testing.

### CASE REPORT

A 58-year-old Caucasian man with hypertension, hyperlipidemia but nonsmoker, and no remarkable history of heart disease, presented to cardiology clinic for cardiovascular risk assessment. He denied chest pain,



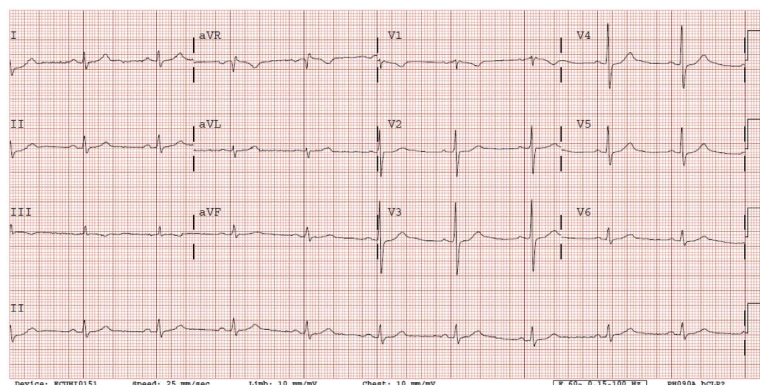


Figure 1 Electrocardiogram showed sinus bradycardia with a heart rate of 59 bpm and RSR' in V1.

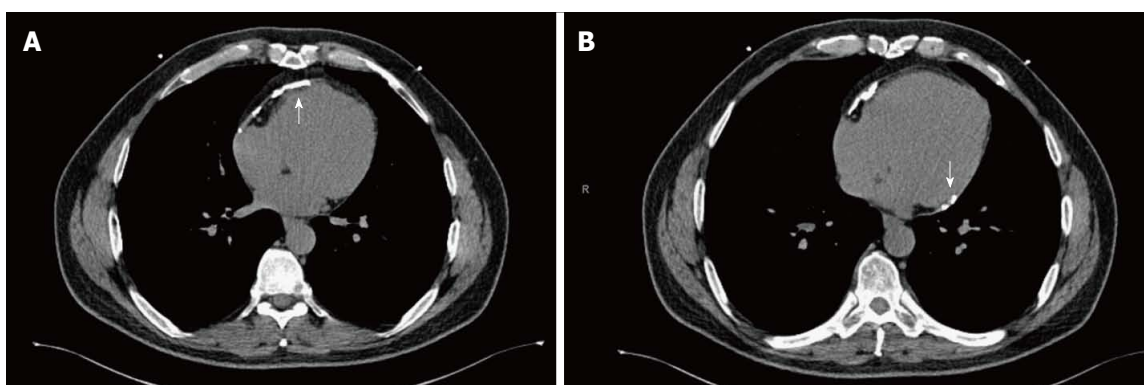


Figure 2 Non-contrast cardiac computed tomography for coronary artery calcium scoring showed moderate pericardial calcification mostly involving anterior (A) and inferobasal (B) portion of the pericardium.

shortness of breath, palpitation, or dyspnea on exertion. He weighed 97 kg with a body mass index (BMI) of 29 kg/m<sup>2</sup>. Physical examination revealed a blood pressure of 138/85 mmHg, pulse of 59 bpm, and respiration rate of 16 breaths per minute. Lungs were clear to auscultation. There was no jugular venous distention. Normal heart sounds, no S3 or S4, no murmurs, and no rubs. No hepatomegaly or extremity edema. Electrocardiography (ECG) showed sinus bradycardia with a heart rate of 59 bpm and RSR' in V1 (Figure 1). Due to his intermediate cardiovascular risk, he underwent non-contrast cardiac computed tomography for CACS for further risk stratification, which showed a low Agatston score of 25.5. This study also revealed an incidental finding of moderate pericardial calcification, mostly involving the anterior and inferobasal portion of the pericardium with no pericardial effusion (Figure 2). Transthoracic echocardiogram showed grade II left ventricular diastolic dysfunction with pseudonormalization pattern, normal valves and normal biventricular size and systolic function. Exercise ECG stress testing demonstrated no evidence of exercise-induced myocardial ischemia at adequate heart rate, achieving 13 metabolic equivalents.

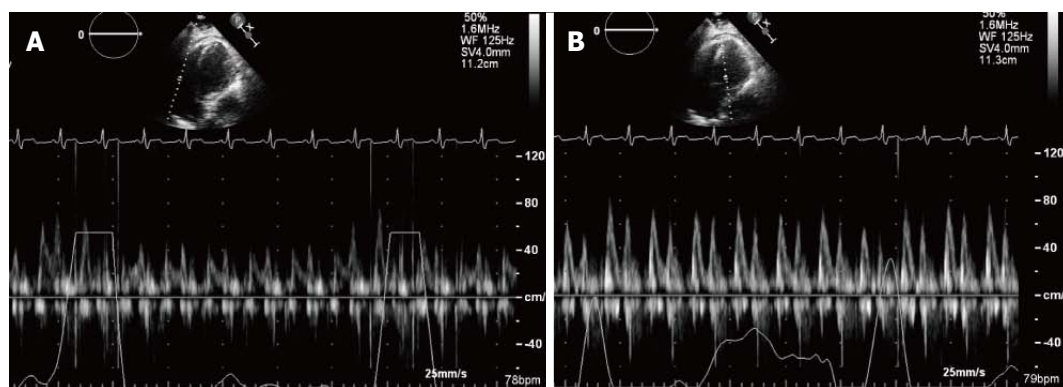
## DISCUSSION

Calcium deposit does not form in a healthy pericardium, but tends to be prominent in the fibrous and scarring

pericardium in response to inflammation<sup>[1]</sup>. Historically, tuberculosis pericarditis is frequently reported as the primary cause of pericardial calcification. More recent cases of pericardial calcifications have been thought to be “idiopathic” and are likely to represent a sequelae of viral pericarditis. Other major known causes include trauma, cardiac surgery, radiation, connective tissue diseases and malignancy<sup>[2]</sup>.

Pericardial calcification alone is asymptomatic. Signs and symptoms are secondary to associate processes such as constrictive pericarditis, which is typically insidious in onset and develops weeks to decades after an episode of pericarditis or chest trauma<sup>[3]</sup>. Patient usually present with signs and symptoms of right heart failure or low cardiac output including hepatomegaly, ascites, bilateral leg edema, exertion dyspnea, orthopnea, fatigue, elevated JVP, hepatojugular reflux, Kussmaul's sign, and pulsus paradoxus<sup>[2,3]</sup>.

Evaluating patients with symptomatic pericardial calcification or a high suspicion of constrictive pericarditis may involve multiple imaging modalities. Electrocardiogram may show decreased QRS voltage and flattened T waves<sup>[2]</sup>. On chest radiographs, calcification may be seen as curvilinear opacities follow expected pericardial contour located predominantly over right atrium and ventricle, diaphragmatic surface, and atrioventricular grooves<sup>[4,5]</sup>. Computed tomography (CT) scan is useful to define pericardial disease and to distinguish coronary,



**Figure 3** Apical four chamber view of transthoracic echocardiogram and pulse wave Doppler's recording. A: Tricuspid valve inflow in a patient with constrictive pericarditis; B: Mitral valve inflow in a patient with constrictive pericarditis. Note with inspiration, the E-wave velocity of mitral valve inflow decreases significantly. This reflects the hemodynamic changes in constrictive pericarditis, resulting from the lack of intrathoracic pressure transmission to the cardiac chambers and the exaggerated ventricular interdependence.

pericardial, myocardial, and intraluminal calcification. In many cases of constrictive pericarditis, CCTA signs of pericardial constriction will be presented and help to confirm the diagnosis. This includes global or focal pericardial thickening ( $> 4$  mm) or calcification, tube-like configuration of ventricles, narrowing of atrioventricular groove, and sinuous appearance of the intraventricular septum<sup>[6]</sup>. CCTA scan may also shows enlargement of atriums, and enlargement of SVC ( $>$  the diameter of descending aorta) and IVC ( $>$  twice the diameter of descending aorta)<sup>[6]</sup>. Magnetic resonance imaging can accurately demonstrates pericardial thickening and provides additional functional analysis of constrictive physiology. Similarly, echocardiogram may demonstrate pericardial thickening or echogenic shadowing from calcium, and an enlargement of one or both atrium, IVC and hepatic veins<sup>[3]</sup>. Respiratory variation of  $\geq 25\%$  of early mitral inflow velocity is a well-recognized echocardiographic feature of constrictive pericarditis, which does not exhibits in those with restrictive cardiomyopathy<sup>[7]</sup>. Right heart catheterization (RHC) provides documentation of the hemodynamics of constrictive physiology and assists in discriminating between constrictive pericarditis and restrictive cardiomyopathy. RHC demonstrates preserved  $x$  descent and a prominent  $y$  descent, elevated right atrial pressure and right ventricular end diastolic pressure. Left atrial and left ventricular pressures are usually elevated. The equalization of diastolic pressures of all chambers (within less than 5 mmHg) with impaired diastolic filling pattern is a hallmark of constrictive physiology<sup>[3]</sup>. In our case, pericardial calcification was discovered incidentally without imaging findings suggestive of constrictive physiology. An example illustrating respiratory variation of mitral and tricuspid inflow velocity of a patient with constrictive pericarditis is shown in Figure 3.

The 2010 Appropriate Use Criteria for Cardiac Computed Tomography found that CACS use is appropriate in asymptomatic, intermediate-risk CHD patients, and this unanimous advocacy by the American College of Cardiology Foundation could have a significant impact

on therapeutic decision-making and intervention<sup>[8]</sup>. In our case, pericardial calcification was discovered incidentally on non-contrast cardiac CT for CACS for further coronary artery risk stratification. Our patient has an intermediate 10-year risk (17%) for hard CHD events such as myocardial infarction and CHD death, using the Framingham risk scoring<sup>[9]</sup>. As detailed in the 2010 ACC/AHA Guideline for assessment of cardiovascular risk in asymptomatic adults, CACS use is appropriate for evaluating this patient's elevated risk for future cardiovascular events<sup>[10]</sup>. Ultimately, the goal of our assessment is to refine targeted preventative efforts based on patient risk.

Although detecting and recognizing pericardial calcification on chest radiography and other imaging modalities such as CT, and echocardiography may have important clinical implications, it requires further investigations and multimodal cardiac imaging in expediting the diagnosis. Pericardial calcification is thought to occur after extensive scarring of the pericardium, and the fibrotic change in the pericardium may produce pericardial constriction. However, asymptomatic pericardial calcifications may be increasingly encountered by the use of cardiac computed tomography<sup>[11,12]</sup>. In a study of 1812 consecutive patients underwent electron-beam tomography for CACS, Hunold *et al*<sup>[12]</sup> found that approximately 1% (17/1812) had pericardial calcification without sign of pericardial constriction on the echocardiogram. Approximately 30% of patients with calcified pericardium may have signs and symptoms of constrictive pericarditis, and up to 50% of patients with constrictive pericarditis demonstrate pericardial calcification on plain chest radiographs<sup>[1,5]</sup>. Hence, the absence of calcification does not exclude constrictive pericarditis.

Due to the increase use of CACS and CCTA for the assessment of coronary atherosclerosis, incidental findings of pericardial calcification may become increasingly apparent, with or without significant clinical implications. The presence of pericardial calcification may suggest of diffused pericardial scarring and raises concerns for secondary associated processes and complications such as

pericardial constriction. However, a thickened pericardium or calcification per se is not diagnostic of constrictive pericarditis. Pericardial constriction can occur without pericardial thickening or calcification, and calcification can be seen in the absence of constrictive physiology. If constriction is strongly suggested on clinical contexts, it should only be undertaken after careful consideration to establish or exclude the diagnosis. Calcification of the pericardium must be evaluated with full clinical knowledge to facilitate an accurate diagnosis and an appropriate therapy when required.

## COMMENTS

### Case characteristics

A 58-year-old Caucasian man with hypertension, hyperlipidemia but nonsmoker, and no remarkable history of heart disease presented to cardiology clinic for cardiovascular risk assessment without having any symptoms.

### Clinical diagnosis

Lungs were clear to auscultation. Normal heart sounds, no S3 or S4, no murmurs, and no rubs. No hepatomegaly or extremity edema.

### Imaging diagnosis

Non-contrast cardiac computed tomography for coronary artery calcium scoring revealed a low agatston score of 25.5 and incidental finding of moderate pericardial calcification.

### Differential diagnosis

Pericardial calcification with and without constrictive pericarditis.

### Treatment

Monitoring for signs and symptoms of pericardial constrictions is sufficient for asymptomatic pericardial calcification.

### Related reports

Incidental pericardial calcification is rare but may become more apparent due to the widespread application of cardiac computed tomography.

### Experiences and lessons

Calcification of the pericardium must be evaluated with full clinical knowledge to facilitate an accurate diagnosis and an appropriate therapy when required.

### Peer review

Pericardial calcification is an occasional finding in patients undergoing computed tomography (CT) scan for coronary artery assessment or calcium score. Its clinical meaning remains unsettled and unless causing pericardial constriction, does not require any therapeutic intervention. In this manuscript, moving from the observation of a patient with pericardial calcification, authors address this fortuitous and serendipitous finding in patients undergoing CT scan for other purposes. The manuscript is interesting and minor changes would improve its readability.

## REFERENCES

- 1 Mathewson FA. Calcification of the pericardium in apparently healthy people; electrocardiographic abnormalities found in tracings from apparently healthy persons with calcification of the pericardium. *Circulation* 1955; **12**: 44-51 [PMID: 14390698]
- 2 Isaacs D, Stark P, Nichols C, Antevil J, Shabetai R. Post-traumatic pericardial calcification. *J Thorac Imaging* 2003; **18**: 250-253 [PMID: 14561912]
- 3 Sengupta PP, Eleid MF, Khandheria BK. Constrictive pericarditis. *Circ J* 2008; **72**: 1555-1562 [PMID: 18762706]
- 4 Ling LH, Oh JK, Breen JF, Schaff HV, Danielson GK, Mahoney DW, Seward JB, Tajik AJ. Calcific constrictive pericarditis: is it still with us? *Ann Intern Med* 2000; **132**: 444-450 [PMID: 10733443]
- 5 Ferguson EC, Berkowitz EA. Cardiac and pericardial calcifications on chest radiographs. *Clin Radiol* 2010; **65**: 685-694 [PMID: 20696295 DOI: 10.1016/j.crad.2009.12.016]
- 6 Reinmüller R, Gürgen M, Erdmann E, Kemkes BM, Kreutzer E, Weinhold C. CT and MR evaluation of pericardial constriction: a new diagnostic and therapeutic concept. *J Thorac Imaging* 1993; **8**: 108-121 [PMID: 8315706]
- 7 Hatle LK, Appleton CP, Popp RL. Differentiation of constrictive pericarditis and restrictive cardiomyopathy by Doppler echocardiography. *Circulation* 1989; **79**: 357-370 [PMID: 2914352]
- 8 Taylor AJ, Cerqueira M, Hodgson JM, Mark D, Min J, O'Gara P, Rubin GD. ACCF/SCCT/ACR/AHA/ASE/ASNC/NASCI/SCAI/SCMR 2010 Appropriate Use Criteria for Cardiac Computed Tomography. A Report of the American College of Cardiology Foundation Appropriate Use Criteria Task Force, the Society of Cardiovascular Computed Tomography, the American College of Radiology, the American Heart Association, the American Society of Echocardiography, the American Society of Nuclear Cardiology, the North American Society for Cardiovascular Imaging, the Society for Cardiovascular Angiography and Interventions, and the Society for Cardiovascular Magnetic Resonance. *J Cardiovasc Comput Tomogr* 2010; **4**: 407.e1-407.33 [PMID: 21232696 DOI: 10.1016/j.jcct.2010.11.001.]
- 9 Grundy SM, Cleeman JI, Merz CN, Brewer HB, Clark LT, Hunninghake DB, Pasternak RC, Smith SC, Stone NJ. Implications of recent clinical trials for the National Cholesterol Education Program Adult Treatment Panel III guidelines. *Circulation* 2004; **110**: 227-239 [PMID: 15249516]
- 10 Greenland P, Alpert JS, Beller GA, Benjamin EJ, Budoff MJ, Fayad ZA, Foster E, Hlatky MA, Hodgson JM, Kushner FG, Lauer MS, Shaw LJ, Smith SC, Taylor AJ, Weintraub WS, Wenger NK, Jacobs AK, Smith SC, Anderson JL, Albert N, Buller CE, Creager MA, Ettinger SM, Guyton RA, Halperin JL, Hochman JS, Kushner FG, Nishimura R, Ohman EM, Page RL, Stevenson WG, Tarkington LG, Yancy CW. 2010 ACCF/AHA guideline for assessment of cardiovascular risk in asymptomatic adults: a report of the American College of Cardiology Foundation/American Heart Association Task Force on Practice Guidelines. *J Am Coll Cardiol* 2010; **56**: e50-103 [PMID: 21144964 DOI: 10.1016/j.jacc.2010.09.001.]
- 11 Lewis WM, Killip T. Traumatic calcific nonconstrictive pericarditis. *Am J Cardiol* 1965; **16**: 901-905 [PMID: 5846013]
- 12 Hunold P, Schmermund A, Seibel RM, Grönemeyer DH, Erbel R. Prevalence and clinical significance of accidental findings in electron-beam tomographic scans for coronary artery calcification. *Eur Heart J* 2001; **22**: 1748-1758 [PMID: 11511125]

P- Reviewer: Schoenhagen P, Sicari R, Said SAM S- Editor: Ji FF  
L- Editor: A E- Editor: Lu YJ





## Tattooing: A potential novel risk factor for iliopsoas abscess

Sweny Gulati, Ankur Jain, Maryam Sattari

Sweny Gulati, Ankur Jain, Maryam Sattari, Department of Medicine, University of Florida College of Medicine, Gainesville, FL 32610, United States

Author contributions: Gulati S, Jain A and Sattari M contributed equally to this work;

Correspondence to: Maryam Sattari, MD, MS, Department of Medicine, University of Florida College of Medicine, 1600 SW Archer Rd, PO Box 100277, Gainesville, FL 32610, United States. [maryam.sattari@medicine.ufl.edu](mailto:maryam.sattari@medicine.ufl.edu)

Telephone: +1-352-2650651 Fax: +1-352-2650653

Received: April 27, 2014 Revised: July 10, 2014

Accepted: July 18, 2014

Published online: September 16, 2014

Staphylococcus aureus IPA after tattooing and review the epidemiology, etiology, clinical features, and management of IPA. Maintaining a high clinical suspicion for this condition in patients with risk factors is important for prompt and accurate diagnosis and prevention of complications, such as sepsis and death.

Gulati S, Jain A, Sattari M. Tattooing: A potential novel risk factor for iliopsoas abscess. *World J Clin Cases* 2014; 2(9): 459-462  
Available from: URL: <http://www.wjgnet.com/2307-8960/full/v2/i9/459.htm> DOI: <http://dx.doi.org/10.12998/wjcc.v2.i9.459>

### Abstract

Iliopsoas abscess (IPA) is an uncommon infection. The clinical presentation is usually insidious. Most patients present with nonspecific symptoms, leading to difficulty in prompt and accurate diagnosis. Delay in diagnosis can lead to complications, such as sepsis and death. Tattooing has become more popular over the recent years and has been associated with tattooing-related and blood-borne infections. We present two related cases of methicillin-resistant *Staphylococcus aureus* IPA after tattooing and review the epidemiology, etiology, clinical features, and management of IPA.

© 2014 Baishideng Publishing Group Inc. All rights reserved.

**Key words:** Iliopsoas abscess; Methicillin-resistant *Staphylococcus aureus*; Intravenous drug abuse; Tattooing; Primary iliopsoas abscess; Secondary iliopsoas abscess

**Core tip:** Iliopsoas abscess (IPA), a collection of pus in the iliopsoas compartment, is classified as primary or secondary depending on the source of infection. While immunocompromise and intravenous drug abuse are the most common known risk factors for primary IPA, tattooing may represent a novel risk factor as well. We present two related cases of methicillin-resistant

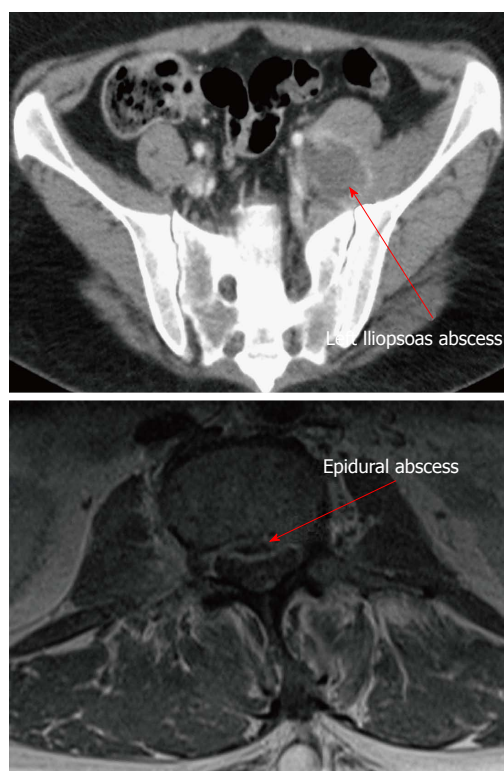
### INTRODUCTION

Iliopsoas abscess (IPA) is a collection of pus in the iliopsoas compartment<sup>[1]</sup>. The unique anatomy of the psoas muscle predisposes it to infections by both direct extension and hematogenous spread<sup>[2]</sup>. The close proximity of the psoas muscle to sigmoid colon, jejunum, appendix, ureters, aorta, renal pelvis, pancreas, iliac lymph nodes, and spine makes it susceptible to contiguous spread of infections from these organs<sup>[3]</sup>. The abundant vascular supply of the muscle predisposes it to hematogenous spread of infections from occult sites<sup>[4]</sup>. The insidious onset and occult characteristics of IPAs can cause diagnostic delays and result in high mortality and morbidity<sup>[2]</sup>.

### CASE REPORT

A 48-year-old female with past medical history of gastroesophageal reflux disease and migraines presented with 4 d of abdominal and back pain, dysuria, nausea, and vomiting. She denied alcohol use, but admitted to cigarettes (34 pack-years) and previous intravenous (IV) drugs (most recent use 2 mo prior to presentation). Vitals included temperature of 98.3 degrees Fahrenheit, heart rate 103 beats per minute, blood pressure 138/84 mmHg, and respiratory rate 28 per minute. Physical exam was unremarkable. Laboratory data revealed a white blood cell

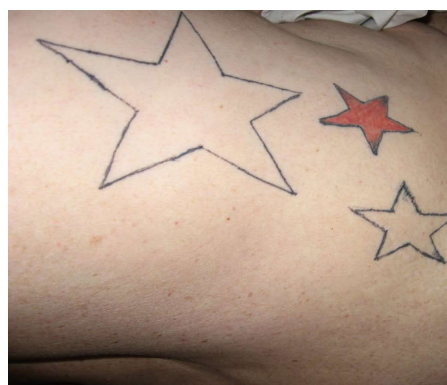



**Figure 1** Above: left iliopsoas abscess on contrast-enhanced computed tomography scan, below: epidural abscess on magnetic resonance imaging.

count (WBC) of  $34.6 \times 10^3$  cells per microliter, 92.8% neutrophils, 2% bands, hemoglobin of 12.4 g per deciliter, sodium of 135 mmol per liter, chloride of 97 mmol per liter, blood urea nitrogen (BUN) of 19 mg per deciliter, AST of 53 IU per liter, and ALT of 42 IU per liter. Urinalysis revealed cloudy urine with pH of 5.5, specific gravity of  $> 1.030$ ,  $> 25$  squamous epithelial cells, 11-17 WBC, 9-15 red blood cells, moderate bacteria, positive nitrites, negative leukocyte esterase, 2+ bilirubin, and 3+ urine protein, blood, and ketones. Urine toxicology screen was positive only for tricyclic antidepressants. Viral hepatitis panel was positive for Hepatitis C antibody. Human immunodeficiency virus (HIV) serology was negative. Initial blood gram stain revealed gram positive cocci in clusters, blood cultures grew methicillin-resistant *Staphylococcus aureus* (MRSA), and urine culture remained negative. Vancomycin was initiated.

Transthoracic echocardiogram did not show evidence of endocarditis. Computed tomography (CT) of abdomen and pelvis with IV contrast revealed abscess formation in the left posterior paraspinal muscles with retroperitoneal extension along the left iliopsoas and pelvis (Figure 1). Follow-up magnetic resonance imaging (MRI) of lumbar spine with and without contrast showed epidural abscess spanning the lumbar spine along the anterior epidural compartment (from T12 to S1), a small epidural abscess in the left posterolateral epidural compartment in the sacrum, left psoas abscess, left retroperitoneal abscess, left paraspinal abscess, a tiny intra psoas abscess on



**Figure 2** Home-made tattoo placed on the patient's back by her husband with shared equipment.

the right, and inflammatory changes in the right posterior paraspinal muscles without an associated abscess (Figure 1). Neurosurgery did not recommend surgical intervention. Interventional radiology performed CT-guided aspiration of the left paraspinal and left psoas abscesses, draining 14 and 15 milliliters of purulent material, which grew MRSA.

Interestingly, patient's husband was also admitted to the same hospital at the same time and diagnosed with IPA due to MRSA. Our patient gave further history that her husband had used the same ink and equipment to tattoo his own arm and her back (Figure 2). Shortly afterwards, he had developed a superficial infection at his tattoo site which resolved prior to admission. Of note, comparison of MRSA isolated from our patient and her husband revealed identical sensitivities to antibiotics, suggesting the same strain (Table 1). Our patient was eventually discharged with outpatient IV antibiotics. At discharge, she was stable and afebrile with negative blood cultures and normal WBC.

## DISCUSSION

IPA is an uncommon infection<sup>[5]</sup>. There are two types of IPA: primary and secondary<sup>[2]</sup>. Primary IPAs are caused by hematogenous or lymphatic spread of bacteria, usually from occult distant sources<sup>[4]</sup>. While *Staphylococcus aureus* is responsible for the majority of primary IPAs<sup>[6]</sup>, infections from other organisms such as *Streptococci*, *Escherichia coli*, *Enterobacter*, and *Salmonella* have also been reported<sup>[7,8]</sup>. Risk factors for primary IPAs include IV drug use (IVDU), HIV/acquired immune deficiency syndrome, active malignancy, diabetes mellitus, receipt of steroids or chemotherapy, and renal failure<sup>[2,5]</sup>. Secondary IPAs result from local extension of adjacent sources of infection<sup>[5]</sup>. Risk factors for secondary IPAs include inflammatory or neoplastic diseases of the bowel, kidney, and spine, such as Crohn's disease, appendicitis, spinal pathology, trauma, or instrumentation in the groin, lumbar, or hip areas<sup>[3,4]</sup>. While secondary IPAs caused by *Staphylococcus aureus* have been reported<sup>[5]</sup>, they are thought to be predominantly caused by enteric organisms, such as *Escherichia coli*, *En-*

**Table 1 Antibiotic sensitivities of methicillin-resistant staphylococcus aureus isolated from iliopsoas abscesses of both the wife (Patient 1) and the husband (Patient 2) reveal identical strains**

Antibiotic	Patient 1	Patient 2
Ciprofloxacin	Resistant	Resistant
Clindamycin	Sensitive	Sensitive
Daptomycin	Sensitive	Sensitive
Erythromycin	Resistant	Resistant
Gentamicin	Sensitive	Sensitive
Inducible Clindamycin	Sensitive	Sensitive
Levofloxacin	Intermediate	Intermediate
Linezolid	Sensitive	Sensitive
Minocycline	Sensitive	Sensitive
Moxifloxacin	Sensitive	Sensitive
Oxacillin	Resistant	Resistant
Penicillin	Resistant	Resistant
Rifampin	Sensitive	Sensitive
Synercid	Sensitive	Sensitive
Tetracycline	Sensitive	Sensitive
Tigecycline A	Sensitive	Sensitive
Trimethoprim/Sulfamethoxazole	Sensitive	Sensitive
Vancomycin	Sensitive	Sensitive

*terobacter*, *Klebsiella*, *Streptococcus*, *Bacteroides*, and *Salmonella*<sup>[3]</sup>.

The clinical presentation of IPA is often variable. Symptoms are non-specific and include pain in back, abdomen, flank, hip, or thigh, as well as fever, limp, malaise, nausea, weight loss, and lump in the groin<sup>[2]</sup>. These unusual clinical features and subacute or chronic nature of symptoms may lead to delay in diagnosis<sup>[9]</sup>. Laboratory investigations may reveal leukocytosis, anemia, elevations in C-reactive protein, erythrocyte sedimentation rate, and BUN, as well as positive blood cultures<sup>[8,10]</sup>. While CT is considered the gold standard for definitive diagnosis<sup>[11]</sup>, use of MRI has also been advocated because of better discrimination of soft tissues and the ability to visualize the abscess wall and surrounding structures without an intravenous contrast medium<sup>[12,13]</sup>. Characteristic radiographic features include focal hypodense lesion(s) within the psoas muscle, presence of gas within the muscle, and CT enhancement of the rim of the abscess with contrast<sup>[11]</sup>. In addition to confirming diagnosis of an IPA, imaging studies can demonstrate co-existing causative retro- or intra-peritoneal disease in secondary IPA<sup>[11]</sup>.

Once IPA is diagnosed, treatment involves the use of appropriate antibiotics and drainage of the abscess<sup>[2]</sup>. If primary IPA is suspected, antibiotics with staphylococcal coverage should be selected<sup>[14]</sup>. In secondary IPA, broad spectrum antibiotics with both aerobic and anaerobic coverage should be considered<sup>[15]</sup>. Antibiotic therapy can subsequently be tailored to the results of the abscess fluid culture and sensitivity. Drainage of the abscess may be done percutaneously or surgically<sup>[2]</sup>. CT-guided percutaneous drainage is less invasive and has been proposed as the draining method of choice<sup>[16]</sup>. Surgical intervention for drainage can be considered in cases of failure of percutaneous drainage, multiloculated abscesses, inability or contraindication to undergo percutaneous drainage, or

presence of surgical indication for another intra-abdominal pathology<sup>[2,17]</sup>.

In our patient, radiological investigations led to the diagnosis, which was later confirmed by microbiological reports. While our patient was diagnosed with primary IPA, she did not have evidence of associated risk factors, such as HIV or active malignancy. Both she and her husband denied IVDU in the previous two months. Interestingly, there has been a previous case report of a patient developing IPA two months after cessation of IVDU<sup>[16]</sup>. However, our patient and her husband also reported sharing the same equipment for home-made tattoos. The identical antibiotic sensitivities of both patients' MRSA strain as well as the reported superficial infection of husband's tattoo site prior to developing IPA suggest that tattooing might have been the etiology of IPA development in these 2 cases. While the temporal relationship as well as biological plausibility makes this a possibility, we cannot confirm a causal relationship since we did not phenotype the MRSA strains or obtain environmental sampling (*e.g.*, culture of the tattooing equipment).

This potential risk factor for IPA is important to recognize as tattooing has become more popular over the recent years. In 2012, 21% of adults in the United States had one or more tattoos, compared to 14% in 2008<sup>[18]</sup>. There have been reports of outbreaks of tattooing-related infections, including mycobacterial and MRSA infections from contaminated ink<sup>[18-20]</sup>. Tattooing is also associated with blood-borne infections such as Hepatitis C, independent of IVDU or blood transfusions prior to 1992<sup>[20]</sup>. It is conceivable that tattooing with potentially contaminated equipment caused transient bacteremia in our patient and her husband, leading to MRSA IPA. To our knowledge, IPA secondary to tattooing has not been reported in the literature. This case report demonstrates importance of recognition of tattooing as a possible risk factor for IPA, which along with maintaining a high clinical suspicion and meticulous clinical examination, can lead to prompt diagnosis, timely initiation of treatment, and reduction of morbidity and mortality.

## COMMENTS

### Case characteristics

A 48-year-old female presented with abdominal and back pain, nausea, and vomiting. Physical exam revealed fever, tachycardia, and tachypnea.

### Differential diagnosis

An inflammatory or infectious process involving the gastrointestinal (*e.g.*, cholecystitis) or genitourinary system (*e.g.*, pyelonephritis).

### Laboratory diagnosis

Labs were only remarkable for leukocytosis, elevated BUN, mild transaminitis, and abnormal urinalysis.

### Imaging diagnosis

Computed tomography (CT) of abdomen and pelvis with IV contrast revealed iliopsoas abscess (IPA). CT-guided aspiration of the IPA drained purulent material, which grew methicillin-resistant *Staphylococcus aureus*. Patient was treated successfully with a prolonged course of intravenous vancomycin.

### Peer review

Very well documented. Excellent diagnostic approach and treatment. Important

description of potential risks from the tattooing process, especially when strict antiseptic measures are not followed.

## REFERENCES

- 1 Mynter H. Acute psoitis. *Buffalo Med Surg J*; 1881: 202-210
- 2 Mallick IH, Thoufeeq MH, Rajendran TP. Iliopsoas abscesses. *Postgrad Med J* 2004; **80**: 459-462 [PMID: 15299155]
- 3 Tasci T, Zencirci B. A female presenting with prolonged fever, weakness, and pain in the bilateral pelvic region: a case report. *Cases J* 2009; **2**: 194 [PMID: 20062763]
- 4 Adelekan M. A review of psoas abscess. *Afr J Clin Exp Microbiol* 2004; **5**. Available from: URL: <http://dx.doi.org/10.4314/ajcem.v5i1.7360>
- 5 Alonso CD, Barclay S, Tao X, Auwaerter PG. Increasing incidence of iliopsoas abscesses with MRSA as a predominant pathogen. *J Infect* 2011; **63**: 1-7 [PMID: 21641042]
- 6 Olson DP, Soares S, Kanade SV. Community-acquired MRSA pyomyositis: case report and review of the literature. *J Trop Med* 2011; **2011**: 970848 [PMID: 21461362 DOI: 10.1155/2011/970848]
- 7 Ricci MA, Rose FB, Meyer KK. Pyogenic psoas abscess: worldwide variations in etiology. *World J Surg* 1986; **10**: 834-843 [PMID: 3776220]
- 8 Santaella RO, Fishman EK, Lipsett PA. Primary vs secondary iliopsoas abscess. Presentation, microbiology, and treatment. *Arch Surg* 1995; **130**: 1309-1313 [PMID: 7492279]
- 9 Vaz AP, Gomes J, Esteves J, Carvalho A, Duarte R. A rare cause of lower abdominal and pelvic mass, primary tuberculous psoas abscess: a case report. *Cases J* 2009; **2**: 182 [PMID: 19946492]
- 10 Taiwo B. Psoas abscess: a primer for the internist. *South Med J* 2001; **94**: 2-5 [PMID: 11213936]
- 11 Zissin R, Gayer G, Kots E, Werner M, Shapiro-Feinberg M, Hertz M. Iliopsoas abscess: a report of 24 patients diagnosed by CT. *Abdom Imaging* 2001; **26**: 533-539 [PMID: 11503095]
- 12 Qureshi NH, O'Brien DP, Allcutt DA. Psoas abscess secondary to discitis: a case report of conservative management. *J Spinal Disord* 2000; **13**: 73-76 [PMID: 10710154]
- 13 Wu TL, Huang CH, Hwang DY, Lai JH, Su RY. Primary pyogenic abscess of the psoas muscle. *Int Orthop* 1998; **22**: 41-43 [PMID: 9549580]
- 14 Gruenwald I, Abrahamson J, Cohen O. Psoas abscess: case report and review of the literature. *J Urol* 1992; **147**: 1624-1626 [PMID: 1593704]
- 15 Bresee JS, Edwards MS. Psoas abscess in children. *Pediatr Infect Dis J* 1990; **9**: 201-206 [PMID: 2186352]
- 16 Cantasdemir M, Kara B, Cebi D, Selcuk ND, Numan F. Computed tomography-guided percutaneous catheter drainage of primary and secondary iliopsoas abscesses. *Clin Radiol* 2003; **58**: 811-815 [PMID: 14521893]
- 17 Wong OF, Ho PL, Lam SK. Retrospective review of clinical presentations, microbiology, and outcomes of patients with psoas abscess. *Hong Kong Med J* 2013; **19**: 416-423 [PMID: 23603777 DOI: 10.12809/hkmj133793]
- 18 LeBlanc PM, Hollinger KA, Klontz KC. Tattoo ink-related infections--awareness, diagnosis, reporting, and prevention. *N Engl J Med* 2012; **367**: 985-987 [PMID: 22913662]
- 19 Kennedy BS, Bedard B, Younge M, Tuttle D, Ammerman E, Ricci J, Doniger AS, Escuyer VE, Mitchell K, Noble-Wang JA, O'Connell HA, Lanier WA, Katz LM, Betts RF, Mercurio MG, Scott GA, Lewis MA, Goldgeier MH. Outbreak of *Mycobacterium chelonae* infection associated with tattoo ink. *N Engl J Med* 2012; **367**: 1020-1024 [PMID: 22913660]
- 20 Carney K, Dhalla S, Aytaman A, Tenner CT, Francois F. Association of tattooing and hepatitis C virus infection: a multicenter case-control study. *Hepatology* 2013; **57**: 2117-2123 [PMID: 23315899]

P- Reviewer: Fett JD, Wong OF S- Editor: Song XX  
L- Editor: A E- Editor: Lu YJ



## Unusual presentation of glomus tympanicum tumour: New bone formation in the middle ear

Gaurav Kumar, Zenon Andreou, Jagdeep Singh Virk, Anthony Owa

Gaurav Kumar, Zenon Andreou, Jagdeep Singh Virk, Anthony Owa, ENT Department, Queen's Hospital, Romford, Essex RM7 0AG, United Kingdom

**Author contributions:** Kumar G was the primary author of the manuscript; Andreou Z and Virk JS edited and provided literature searches; Owa A was the senior clinician and contributed to proof reading.

**Correspondence to:** Gaurav Kumar, FRCS, ORL-HNS, ENT Department, Queen's Hospital, Barking, Havering and Redbridge University Hospitals NHS Trust, Rom Valley Way, Romford, Essex RM7 0AG, United Kingdom. [dr.gauravkr@yahoo.co.uk](mailto:dr.gauravkr@yahoo.co.uk)

Telephone: +44-1708-435000 Fax: +44-1708-596959

Received: April 9, 2014 Revised: May 23, 2014

Accepted: June 18, 2014

Published online: September 16, 2014

### Abstract

The objective of this study is to increase awareness of the rare presentation, diagnostic difficulties and management of glomus tympanicum of the middle ear. A 49 years old male, with a background of hypertension and epilepsy, presented with a two month history of left sided conductive hearing loss, pulsatile tinnitus and headache. Clinically and radiologically a diagnosis of glomus tympanicum was made. Intraoperatively, extensive osteogenesis of the middle ear resulting in ossicular fixation and erosion was found. This patient required a two stage operation for full clearance of disease. A stapedectomy drill was used to drill off the bony overgrowth surrounding the ossicles resulting in improved hearing thresholds and full clearance of the disease at two year follow up. Glomus tympanicum can result in new bone formation in the middle ear with resultant ossicular fixation and conductive hearing loss. This can be effectively treated surgically with restoration of hearing.

© 2014 Baishideng Publishing Group Inc. All rights reserved.

**Key words:** Glomus; Tympanicum; Osteogenesis; conductive hearing loss

**Core tip:** Glomus tympanicum can result in new bone formation in the middle ear with resultant ossicular fixation and conductive hearing loss. This can be effectively treated surgically with restoration of hearing. We describe this previously unreported presentation of glomus tympanicum in the world literature (with reactive osteogenesis and resultant severe conductive hearing loss). We therefore believe our findings would be of interest to the readers of your journal and raise awareness of this as a differential diagnosis which may be under-recognised.

Kumar G, Andreou Z, Virk JS, Owa A. Unusual presentation of glomus tympanicum tumour: New bone formation in the middle ear. *World J Clin Cases* 2014; 2(9): 463-465 Available from: URL: <http://www.wjgnet.com/2307-8960/full/v2/i9/463.htm> DOI: <http://dx.doi.org/10.12998/wjcc.v2.i9.463>

### INTRODUCTION

Glomus tumours or paragangliomas are benign neoplasms that arise from paraganglionic tissue throughout the body with glomus tympanicum being the most common primary soft tissue tumour arising in the middle ear<sup>[1,2]</sup>. The paraganglionic system is a collection of cells derived from the neural crest and are found in the autonomic nervous system. They act as a source of catecholamines before the development of the adrenal medulla. The term "glomus" is a historical misnomer which was applied to these tumors before a true understanding of the characteristics of these tumors was understood. Extra-adrenal or craniocervical paraganglioma are distributed along the arteries and cranial nerves in head and neck region. Craniocervical paragangliomas can be broadly classified into temporal and vagal.

Temporal paragangliomas commonly arise from "paraganglion cells" along the course of Jacobson's nerve



or Arnold's nerve<sup>[2]</sup>. They present as a soft tissue mass in the middle ear cavity which is often visible on otoscopy. Patients classically complain of pulsatile tinnitus and conductive hearing loss although depending on the extent of the disease they can experience imbalance, facial nerve palsy, otorrhoea or endocrine symptoms if the tumour is releasing catecholamines<sup>[3]</sup>. These clinical features lead to a need for further radiological investigations in the form of computed tomography and magnetic resonance imaging of the temporal bones to confirm the likely diagnosis and assess severity. A 24 h urine collection should be performed and analysed for vanillylmandelic acid (VMA) levels to determine whether indeed the lesion is endocrine-active<sup>[1-3]</sup>.

We present a rare variant of a glomus tympanicum tumour that induced extensive osteogenesis in the middle ear causing severe conductive hearing loss secondary to ossicular fixation and erosion.

## CASE REPORT

A 49 years old male presented to otolaryngology outpatient department with a 2 mo history of left-sided "throbbing" earache. He also complained of pulsatile tinnitus and worsening left sided hearing loss. His general practitioner initially diagnosed him with otitis externa and when his symptoms failed to improve he was referred for further specialist management. His past medical history included epilepsy and hypertension.

Examination revealed a red mass arising from behind his tympanic membrane in the attic area and a diagnosis of glomus tympanicum was suspected although the position of the lesion was slightly unusual for a glomus. A pure tone audiogram revealed a mild conductive deafness of 20db especially on high frequencies. A computed tomography (CT) scan of his temporal bone revealed a non-gravity dependent opacification with bony erosion and 24 h urine collection did not show elevated VMA levels indicating a non-secretory glomus tumour.

Multidisciplinary team and patient choice resulted in surgical management of this lesion. Intraoperatively, after exposing the middle ear, apart from inflamed mucosa there was no obvious soft tissue mass found. There was however a bony growth arising from the medial wall of the middle ear and extending between the incus and malleus handle encasing the anterior crura of stapes (Figure 1). After careful dissection the extra bone was peeled of the ossicles and sent for histology leaving the ossicular chain intact. The patient made a very good recovery and his conductive hearing loss improved with closure of the air-bone gap to 5db. Histology revealed thickened and sclerotic bone. The intervening connecting tissue traversing the bone was infiltrated by tumour consisting of hyperchromatic cells with rich vascular stroma and no signs of atypia or mitosis. A diagnosis of benign glomus tumour was made.

During follow up, (ADD COMMA) despite an initial mild improvement in his hearing, the patient developed

a worsening conductive hearing loss with thresholds of 60-70db across most frequencies. Computed tomography imaging, 18 mo after his initial operation, (ADD COMMA) suggested recurrent disease and the patient required revision surgery.

Intra-operatively a recurrent bony overgrowth was identified which this time had encased the stapes superstructure and was causing malleo-incudal fixation. The disease could not be removed with a curette and so a stapedectomy drill was used to drill the overgrowth off the stapes superstructure. The malleus and incus were sacrificed and the ossicular chain was reconstructed with conchal cartilage. Histology once again demonstrated bone overgrowth with intervening tumour cells. The patient made a very good recovery and he has a sustained improved hearing of 40db two years postoperatively.

## DISCUSSION

Glomus tumours are fairly rare with an incidence of around 1 per 1 million<sup>[4]</sup>. They are usually hypervascular tumours that arise within the jugular foramen of the temporal bone<sup>[1-4]</sup>. They characteristically present with conductive hearing loss and a pulsatile tinnitus as demonstrated in our case. Histologically, chief or granular cells (Type I) and sustentacular cells or satellite cells (Type II) are present in glomus tumours<sup>[2]</sup>. Management is dependent on the tumour extent and the patient's fitness with the mainstay being surgery and radiotherapy<sup>[1-4]</sup>. Small tumours can be accessed *via* a transcanal approach with larger ones necessitating a post-auricular approach with mastoid exploration. The tumour is commonly a highly vascular soft tissue lesion which may require pre-operative embolization.

Bony overgrowth over a glomus tumour has not been previously reported in the world literature and as such represents a new clinical entity. The only other incidence of bone in the middle ear associated with a glomus tumour was reported by Yanagisawa *et al*<sup>[5]</sup>, where a glomus tumour coexisted with otosclerosis in a patient. However, our patient did not show any histological features of otosclerosis in that his conductive hearing loss was unilateral, his ossicular chain was mobile after resection of the extra bone in the middle ear and his hearing improved post-operatively without the need for a stapes prosthesis. Furthermore, histology from the bone overgrowth confirmed glomus tumour cells intervening the bony overgrowth. All Fisch class I mesotympanic paragangliomas involve careful resection of tumour around the ossicles. We cleared osteogenesis around the stapes suprastructure using a stapedectomy drill, thus improving upon the incumbent conductive hearing loss. Another management option available in such cases would be removal of the glomus along with stapes suprastructure and reconstructing hearing using a total ossicular replacement prosthesis. Our treatment option, of drilling the bone around the ossicular chain and in particular the stapes, with a stapedectomy drill, proved successful in terms of hearing

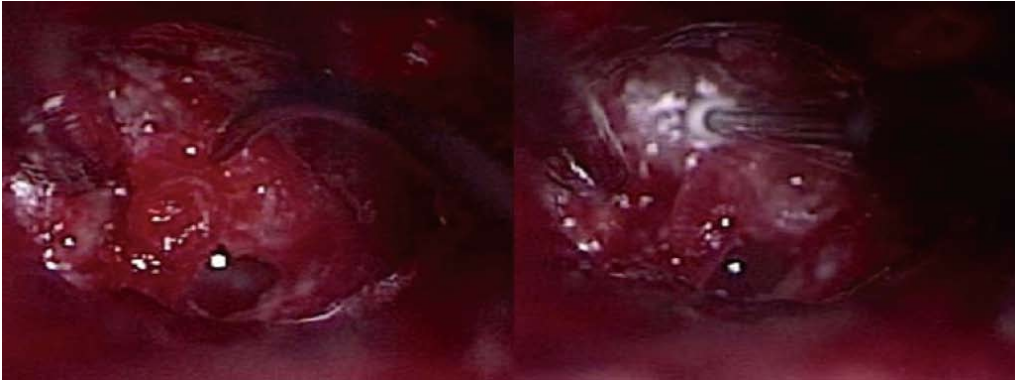


Figure 1 Microscopic intraoperative view of mesotympanum.

restoration (whilst ensuring tumour removal) and we propose this as a treatment modality for such rare cases.

In conclusion: (1) Glomus tumours or paragangliomas are rare tumours arising from paraganglionic tissue; (2) Glomus tympanicum tumours are the commonest soft tissue tumour of the middle ear; (3) These lesions typically present with pulsatile tinnitus and hearing loss; (4) A new clinical entity of osteogenesis in the middle ear is described - leading to ossicular fixation and erosion; and (5) Bony overgrowth can be managed by careful dissection off the ossicles or by use of a stapedectomy drill, resulting in improved hearing thresholds.

## COMMENTS

### Case characteristics

A 49 years old male with a two month history of left sided conductive hearing loss, pulsatile tinnitus and headache.

### Clinical diagnosis

Examination revealed a red mass arising from behind his tympanic membrane in the attic area with an associated mild conductive deafness.

### Differential diagnosis

Differentials included glomus tympanicum although the mass was unusually located meaning cholesteatoma, schwannoma and meningioma remained possible.

### Laboratory diagnosis

Twenty-four hour urine collection did not show elevated VMA levels indicating a non-secretory glomus tumour.

### Imaging diagnosis

Computed tomography scan of his temporal bone revealed a non-gravity dependent opacification with bony erosion.

### Pathological diagnosis

Histology revealed thickened and sclerotic bone with intervening connecting tissue traversing the bone infiltrated by tumour consisting of hyperchromatic cells with rich vascular stroma and no signs of atypia or mitosis, leading to a diagnosis of benign glomus tumour.

### Treatment

Surgical excision with drilling of newly formed bone and reconstruction of hearing mechanism.

### Related reports

Glomus tumours are rare, hypervascular tumour that arises within the jugular foramen of the temporal bone. New bone formation in the middle ear has not previously been reported in the world literature.

### Term explanation

VMA is Vanillylmandelic Acid, a metabolic by-product of norepinephrine and epinephrine.

### Experiences and lessons

Glomus tympanicum can result in new bone formation in the middle ear with resultant ossicular fixation and conductive hearing loss which can be effectively treated surgically with restoration of hearing.

### Peer review

The manuscript reports a clinical case about glomus tympanicum tumour related bone formation in middle ears leading to conductive hearing loss.

## REFERENCES

- 1 Sanna M, Fois P, Pasanisi E, Russo A, Bacciu A. Middle ear and mastoid glomus tumors (glomus tympanicum): an algorithm for the surgical management. *Auris Nasus Larynx* 2010; **37**: 661-668 [PMID: 20400250 DOI: 10.1016/j.anl.2010.03.006]
- 2 Kaylie DM, O'Malley M, Aulino JM, Jackson CG. Neurotologic surgery for glomus tumors. *Otolaryngol Clin North Am* 2007; **40**: 625-649, x [PMID: 17544699]
- 3 Fayad JN, Keles B, Brackmann DE. Jugular foramen tumors: clinical characteristics and treatment outcomes. *Otol Neurotol* 2010; **31**: 299-305 [PMID: 19779386 DOI: 10.1097/MAO.0b013e3181be6495]
- 4 Moffat DA, Hardy DG. Surgical management of large glomus jugulare tumours: infra- and trans-temporal approach. *J Laryngol Otol* 1989; **103**: 1167-1180 [PMID: 2559134]
- 5 Yanagisawa E, Principato JJ. Glomus tympanicum tumor in an otosclerotic ear. *Arch Otolaryngol* 1970; **91**: 299-301 [PMID: 4313113]

P- Reviewer: Cai KY, Horii A S- Editor: Ji FF L- Editor: A  
E- Editor: Lu YJ



## Coronary artery bypass graft surgery in a patient with ureterosigmoidostomy

Ismail Haberal, Deniz Ozsoy, Ege Sipahi, Murat Mert

Ismail Haberal, Deniz Ozsoy, Ege Sipahi, Murat Mert, Department of Cardiovascular Surgery, Cardiology Institute, Istanbul University, 34116 Istanbul, Turkey

**Author contributions:** Haberal I, Ozsoy D and Mert M designed the report; Sipahi E collected the patient's clinical data; Haberal I and Ozsoy D analyzed the data and wrote the paper.

**Correspondence to:** Ismail Haberal, MD, Department of Cardiovascular Surgery, Cardiology Institute, Istanbul University, Semsettin Gunaltay cad. Bengi sok. Derya Apt. No:12 D:34 Erenkoy, Kadikoy, 34116 Istanbul, Turkey. [doktorhaberal@hotmail.com](mailto:doktorhaberal@hotmail.com)

Telephone: +90-216-3868252

Received: March 13, 2014 Revised: April 25, 2014

Accepted: July 12, 2014

Published online: September 16, 2014

### Abstract

A 75-year-old male patient had stable angina pectoris. After coronary angiography we decided to perform a coronary artery bypass graft surgery. Twenty years ago the patient underwent radical cystectomy and bilateral ureterosigmoidostomy because of bladder cancer. After that, his micturition was via the rectum. We did not experience that before. As is known, monitoring of urine output is very important after cardiac surgery. The patient was consulted with an urologist for how to monitor urine output in him. Transrectal catheterization was recommended for our follow-up, but before the catheterization bowel cleansing is necessary. Four-vessel on-pump coronary artery bypass graft surgery was performed without any problem. Peroperative urine volume and arterial blood gas results were normal. Urine output is a sensitive variable reflecting the patient's effective blood volume and tissue perfusion. Urinary catheterization is a standard for all cardiac surgeries, and it allows the patients' urine to drain freely from the bladder for collection. Monitoring of urine output in patients with ureterosigmoidostomy is impossible by standard urinary catheterization method. In this case

we performed transrectal catheterization for Urine flow follow-up. Urine flow follow-up is essential after the open-heart surgery and it can be measured in different ways, as in our case.

© 2014 Baishideng Publishing Group Inc. All rights reserved.

**Key words:** Open heart surgery; Urine output follow-up; Catheterization; Ureterosigmoidostomy; Coronary artery bypass graft

**Core tip:** With this case, we had experience that we can monitor urine output in different ways rather than urethral catheterization such as catheterization in a transrectal way that we had to do in a patient who had ureterosigmoidostomy.

Haberal I, Ozsoy D, Sipahi E, Mert M. Coronary artery bypass graft surgery in a patient with ureterosigmoidostomy. *World J Clin Cases* 2014; 2(9): 466-468 Available from: URL: <http://www.wjgnet.com/2307-8960/full/v2/i9/466.htm> DOI: <http://dx.doi.org/10.12998/wjcc.v2.i9.466>

### INTRODUCTION

Urine output is a sensitive variable reflecting the patient's effective blood volume and tissue perfusion<sup>[1]</sup>. Urinary catheterization is a standard for all cardiac surgeries, and it allows the patients' urine to drain freely from the bladder for collection. Monitoring of urine output in patients with ureterosigmoidostomy is impossible by standard urinary catheterization method. We could not find any such case report in the literature. Hence we decided to write this case report to explain how we can monitor urine output and which complications may occur after coronary artery bypass graft surgery operation in patients with ureterosigmoidostomy.

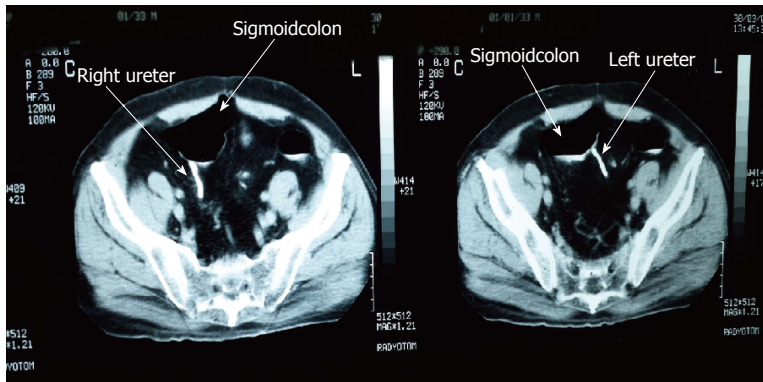


Figure 1 Bilateral ureterosigmoidostomy revealed by an abdominal computed tomographic scan.

## CASE REPORT

A 75-year-old male patient had stable angina pectoris. After coronary angiography we decided to perform a coronary artery bypass graft surgery. Preoperative laboratory tests were normal. Twenty years ago the patient underwent radical cystectomy and bilateral ureterosigmoidostomy because of bladder cancer (Figure 1). His urologist confirmed that, he was fully cured after this surgery. After that, his micturition was *via* the rectum. We did not experience that before. As is known, monitoring of urine output is very important after cardiac surgery. The patient was consulted with an urologist for how to monitor urine output in him. Transrectal catheterization was recommended for our follow-up, but before the catheterization bowel cleansing is necessary. After this recommendation we performed a high enema the night before the operation. A 24F urinary catheter was applied in a transrectal way as much as possible to the distal end. A 24F Foley urethral catheter with a 30 cc balloon was inflated to 50 cc in order to minimize the chance that the catheter will be pulled down through the sigmoid colon and then we could monitor urine output by this method perfectly. Four-vessel on-pump coronary artery bypass graft surgery was performed without any problem. Peroperative urine volume and arterial blood gas results were normal. The patient had respiratory problems postoperatively but hemodynamic parameters were normal. Third generation cephalosporins were used to prevent possible urosepsis during the catheterization. During the catheterization the patient was not fed *via* the enteral route. Urine flow was followed for three days until hemodynamic stability was achieved. The catheter was removed three days after the operation and the patient was transferred from intensive care unit to the ward four days after the operation. The patient was discharged from hospital nine days after the surgery without any problem.

## DISCUSSION

Monitoring of urine output could improve the clinical management of cardiac patients and enable clinicians to early recognition of volume status, cardiac output and kidney injury. A urinary catheter is inserted preoperatively in the operation room and kept in place for a minimum

of 24-48 h to monitor hourly urine flow. Catheterization is difficult in some patients such as those with prostatic hypertrophy. In some cases, consideration should be given to use of a trocar-introduced suprapubic catheter in adults, rather than a urethral catheter. Our patient was operated 20 years ago because of bladder cancer. Today, orthotopic urinary diversion is an essential component of the surgical procedure after cystectomy. Replacement with an orthotopic ileal neobladder should be the first choice if external urethral sphincter sparing surgery is possible, offering good long-term function, quality of life and patient's acceptance with few complications<sup>[2,3]</sup>. However in our case, radical cystectomy and bilateral ureterosigmoidostomy were performed because of bladder cancer. Patients undergoing this procedure must be closely monitored for the development of hyperchloremic acidosis. This will occur in the majority of instances, and it is wise to initiate a bicarbonate replacement program at the outset<sup>[4]</sup>. After the coronary artery bypass graft surgery, apparent acidosis did not occur at the postoperative arterial blood gas follow-up, and this may be because ureterosigmoidostomy was performed 20 years ago. Obviously, all of such patients have exposure of the urinary tract to fecal flora. Most authors would advocate chronic antibacterial agent administration in all patients<sup>[5]</sup>. Third generation cephalosporins were used in our case to prevent possible urosepsis during the catheterization. Because of the definite concern for the occurrence of rectal cancer some 5 to 50 years (average 21 years) after ureterosigmoidostomy<sup>[6]</sup>, it is suggested that patients with long-term ureterosigmoidostomy be subjected to annual colonic investigation. His urologist confirmed that he was fully cured after radical cystectomy and bilateral ureterosigmoidostomy. At colonoscopic investigations we could not determine any pathological results. In this case, paying particular attention to a few details both preoperatively and postoperatively, coronary artery bypass graft surgery was performed without any problem.

In conclusion, urine flow follow-up is essential after the open-heart surgery and it can be measured in different ways, as in our case.

## COMMENTS

### Case characteristics

A 75-year-old male patient with a history of ischemic heart disease presented



with dyspnea and angina.

### Clinical diagnosis

Scar to inspection over suprapubic area.

### Differential diagnosis

Aortic dissection, pericarditis, and pneumothorax.

### Laboratory diagnosis

Hematologic and metabolic panels were normal.

### Imaging diagnosis

Coronary angiography revealed multi-vessel coronary artery disease and computed tomography scan showed bilateral ureterosigmoidostomy.

### Pathological diagnosis

Coronary artery disease with radical cystectomy and bilateral ureterosigmoidostomy operation because of bladder cancer.

### Treatment

Four-vessel on-pump coronary artery bypass graft surgery was performed without any problem.

### Related reports

Catheterization is difficult in some patients such as those with prostatic hypertrophy. In some cases, consideration should be given to use of a trocar-introduced suprapubic catheter in adults, rather than a urethral catheter.

### Term explanation

Ureterosigmoidostomy is not widely used in patients with bladder cancer. Nowadays, orthotopic urinary diversion is an essential component of the surgical procedure after cystectomy.

### Experiences and lessons

Urinary output can be monitored transrectally in patients with ureterosigmoidostomy.

### Peer review

Authors describe the case of a patient undergoing CABG who had undergone radical cystectomy with ureterosigmoidostomy. Monitoring urine output is important in these patients, which was performed using a Foley catheter in the colon after bowel cleaning in this case. It is an unusual interesting clinical dilemma with good discussion.

## REFERENCES

- 1 **Legrand M**, Payen D. Understanding urine output in critically ill patients. *Ann Intensive Care* 2011; **1**: 13 [PMID: 21906341 DOI: 10.1186/2110-5820-1-13]
- 2 **Lee RK**, Abol-Enein H, Artibani W, Bochner B, Dalbagni G, Daneshmand S, Fradet Y, Hautmann RE, Lee CT, Lerner SP, Pycha A, Sievert KD, Stenzl A, Thalmann G, Shariat SF. Urinary diversion after radical cystectomy for bladder cancer: options, patient selection, and outcomes. *BJU Int* 2014; **113**: 11-23 [PMID: 24330062 DOI: 10.1111/bju.12121]
- 3 **Nagele U**, Sievert KD, Merseburger AS, Anastasiadis AG, Stenzl A. Urinary Diversion Following Cystectomy. *EAU Update Series* 3 2005: 129-137
- 4 **Miller K**, Matsui U, Hautmann R. The functional rectal bladder—prevention of hyperchloremic acidosis following vesico-sigmoidostomy in dogs. *Urology* 1990; **144**: 375-380
- 5 **Spirnak JP**, Caldamone AA. Ureterosigmoidostomy. *Urol Clin North Am* 1986; **13**: 285-294 [PMID: 3515726]
- 6 **Stewart M**, Hill MJ, Pugh RC, Williams JP. The role of N-nitrosamine in carcinogenesis at the ureterocolic anastomosis. *Br J Urol* 1981; **53**: 115-118 [PMID: 7237041]

**P-Reviewer:** Mehta Y **S-Editor:** Song XX **L-Editor:** Wang TQ  
**E-Editor:** Lu YJ



## Pneumatosis cystoides intestinalis associated with toxic epidermal necrolysis: A case report

Si-Yuan Yao, Ryutaro Seo, Tohru Nagano, Kazuo Yamazaki

Si-Yuan Yao, Departments of Surgery, Kobe City Medical Center General Hospital, Chuo-ku, Kobe 650-0047, Japan

Ryutaro Seo, Kazuo Yamazaki, Departments of Anesthesiology, Kobe City Medical Center General Hospital, Chuo-ku, Kobe 650-0047, Japan

Tohru Nagano, Departments of Dermatology, Kobe City Medical Center General Hospital, Chuo-ku, Kobe 650-0047, Japan

Author contributions: Yao SY, Seo R, Nagano T and Yamazaki K contributed to the manuscript writing and revision.

Correspondence to: Si-Yuan Yao, MD, Departments of Surgery, Kobe City Medical Center General Hospital, 2-1-1, Minatogima-Minamimachi, Chuo-ku, Kobe 650-0047, Japan. [siyuan@kobe-nishishimin-hospi.jp](mailto:siyuan@kobe-nishishimin-hospi.jp)

Telephone: +81-78-3024321 Fax: +81-78-3027537

Received: April 30, 2014 Revised: June 3, 2014

Accepted: June 27, 2014

Published online: September 16, 2014

presenting with PCI associated with TEN.

© 2014 Baishideng Publishing Group Inc. All rights reserved.

**Key words:** Toxic epidermal necrolysis; Intestinal involvement; Pneumatosis cystoids intestinalis; Septic shock; Conservative treatment

**Core tip:** Toxic epidermal necrolysis is a severe adverse drug reaction, which affects skin and mucosa of whole body. However, intestinal involvement is rare documented. We report the case of a 55-year-old man with toxic epidermal necrolysis caused by phenobarbital. He was diagnosed with pneumatosis cystoides intestinalis during the clinical course. Although septic shock was accompanied, conservative treatment was effective. To our knowledge, this article describes the first patient presenting with pneumatosis cystoides intestinalis associated with toxic epidermal necrolysis.

### Abstract

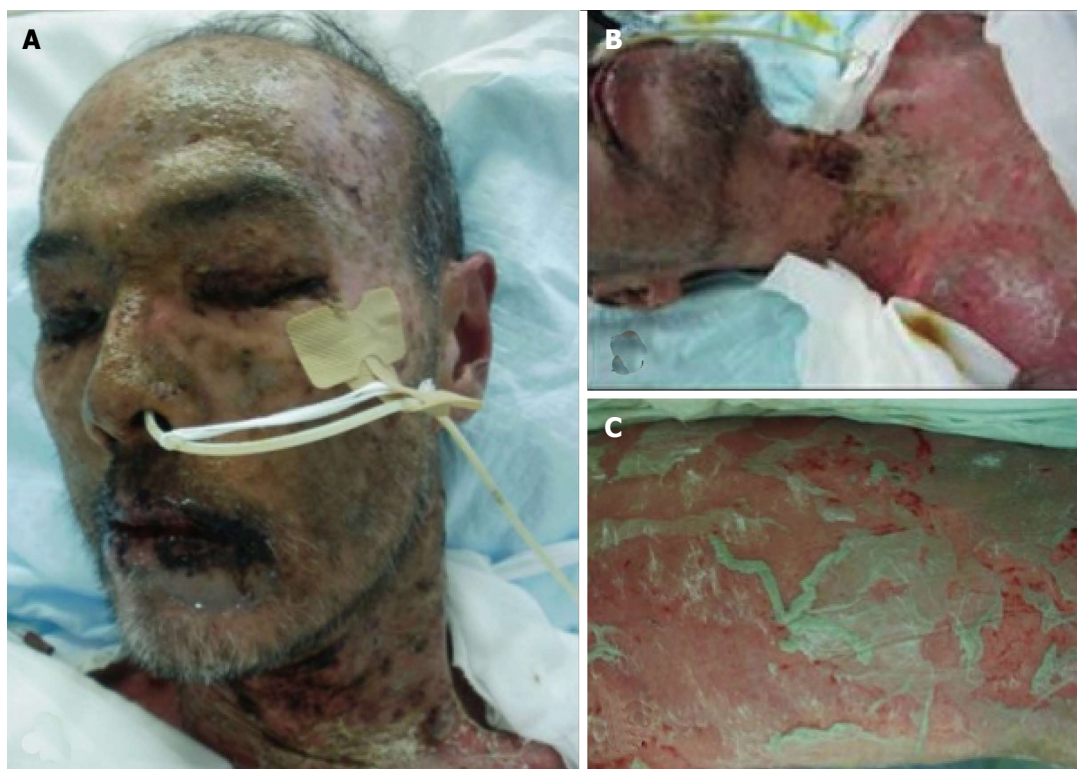Toxic epidermal necrolysis (TEN) is a severe adverse drug reaction, which is characterized by erythema, blisters, and/or erosions of the mucous membranes and skin, but intestinal involvement is rare. In contrast, pneumatosis cystoides intestinalis (PCI) is a rare condition associated with a wide variety of underlying diseases, but to date no patient has presented with PCI associated with TEN. A 55-year-old man was admitted to intensive care unit for treatment of TEN caused by phenobarbital. On day 8 after admission, he presented with progressive abdominal distention and hypotension. Computed tomography (CT) showed gas in the superior mesenteric vein and air filled cysts in the walls of the small intestine. He was suspected of having septic shock due to PCI. As there were no indications of bowel ischemia or necrosis, the patient was managed conservatively with antibiotics and oxygen therapy. On day 10 after admission, he was weaned off catecholamines, with CT on day 11 showing complete resolution of gas in the superior mesenteric vein and air filled cysts. To our knowledge, this article describes the first patient

Yao SY, Seo R, Nagano T, Yamazaki K. Pneumatosis cystoides intestinalis associated with toxic epidermal necrolysis: A case report. *World J Clin Cases* 2014; 2(9): 469-473 Available from: <http://www.wjgnet.com/2307-8960/full/v2/i9/469.htm> DOI: <http://dx.doi.org/10.12998/wjcc.v2.i9.469>

### INTRODUCTION

Toxic epidermal necrolysis (TEN) is a rare but potentially fatal condition often caused by adverse drug reactions. TEN is characterized by high fever, widespread blistering of the exanthematous macules and atypical target-like lesions of the skin, as well as mucosal involvement. However, there have been few reports of intestinal involvement of TEN<sup>[1]</sup>.

Pneumatosis cystoides intestinalis (PCI) is a rare condition, in which submucosal or subserosal gas cysts are found in the walls of the small and/or large intestines.



**Figure 1** Skin findings in this patient. A and B: Wide-spread blistering exanthemas of macules around the face and neck; C: Nikolsky phenomenon (slight rubbing of the skin resulting in exfoliation of the outermost layer) of the lower leg.

The pathogenesis of PCI remains unclear, and the role of emergency surgical intervention in patients with PCI accompanied by portal vein gas or peritoneal irritation remains controversial.

We describe here a patient with PCI encountered during the clinical course of TEN, with the former condition successfully treated by conservative management. To our knowledge, this is the first such patient described to date.

## CASE REPORT

A 55-year-old man with a previous medical history of alcohol-induced epilepsy presented to our dermatology department with complaints of fever and a rapidly evolving rash over his face and trunk. He had been taking two antiepileptic agents, carbamazepine and phenobarbital, for one month. Drug induction was suspected, and oral antihistamine and steroids were started after discontinuation of the antiepileptics.

Despite this treatment, the rash did not improve, spreading to his back, arms, and legs after one week. He was admitted to our hospital with a presumed diagnosis of Stevens-Johnson syndrome (SJS). On the day of admission, he was started on intravenous steroid pulse therapy with prednisolone plus immunoglobulin. However, blister and erosion continued to spread throughout the entire body (Figure 1). The patient was diagnosed with TEN and transferred to intensive care unit (ICU) on day 6 of hospitalization. During his stay in the ICU, his skin

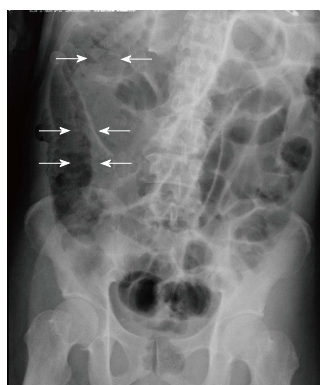
condition gradually improved with continuous intravenous steroids. He was also administered a first generation cefem for antibiotic prophylaxis.

Abdominal distension was also observed, beginning on the third day of admission. CT scan performed on day 5 showed no specific findings except for pneumocolon. The patient was put on a bowel regimen, consisting of laxatives and enemas, to regulate his bowel movements.

On day 8, the condition of this patient suddenly deteriorated. His abdominal distension became exacerbated and his blood pressure decreased rapidly. He became less responsive and scored 11 (E2V4M5) on the Glasgow Coma Scale.

Physical examination showed a temperature of 37.2 °C, blood pressure of 60/28 mmHg, pulse of 110 beats per minute, and oxygen saturation 97% in ambient air. Abdominal examination showed marked fullness and diffuse rebound tenderness throughout the entire abdomen. Laboratory examinations revealed severe acidosis and elevated lactic acid concentration. The results of laboratory examinations are shown in Table 1. A blood culture was positive for a species of *Corynebacterium*.

Plain abdominal radiography showed small-bowel distension and a low-density linear and bubbly pattern of gas in the small-bowel wall (Figure 2). A non-contrast CT scan revealed gas in the superior mesenteric vein (SMV) and intramural air, but no free air, in the small-bowel wall (Figure 3). The patient was preliminarily diagnosed with septic shock associated with pneumatosis cystoides intes-



**Figure 2** Plain supine abdominal radiography of patient on day 8 of admission to the intensive care unit, showing small-bowel distension and pneumatosis cystoides intestinalis (arrows).

tinalis. He was started immediately on oxygen treatment, followed by intravenous broad-spectrum antibiotics and catecholamine. Although an emergency laparotomy was considered, the patient's general condition was too poor to tolerate an operation, and there was no sign of bowel ischemia or necrosis. Therefore, the patient was managed conservatively.

The patient progressed well, recovering from a catecholamine-dependent state two days later. A CT scan, performed three days later, showed that the gas in the small bowel wall had completely disappeared. The abdominal fullness gradually remitted and he was discharged from the ICU after sixteen days. Several days later, a drug lymphocyte stimulating test (DLST) was positive for phenobarbital, indicating that phenobarbital had caused TEN in this patient.

The patient's skin condition completely resolved sixty-two days after admission. No recurrence of PCI and TEN have been observed for three years.

## DISCUSSION

Stevens-Johnson syndrome and TEN are rare diseases, affecting approximately 1 or 2 per million individuals annually. Both of these diseases are considered medical emergencies as they are potentially fatal<sup>[2]</sup>.

Currently, TEN and SJS are considered to be at the two ends of a spectrum of severe epidermolytic adverse cutaneous drug reactions, differing only in their extent of skin detachment. Symptoms of SJS include acute conditions characterized by mucous membrane erosions and skin lesions (described as macules, atypical target-like lesions, bulla, and erosions) involving less than 10% of the total skin surface area, whereas TEN involves more than 10% of the total skin surface area. In addition to skin symptoms, both diseases are often accompanied by complications in numerous organs, including the liver, kidneys, and lungs. The mortality rate for patients with TEN has been reported to range from 25% to 35%<sup>[2,3]</sup>.

Certain drugs, including sulfonamides, non-steroidal anti-inflammatory drugs, cephem antibiotics, barbiturates,

**Table 1** Laboratory data on day 8

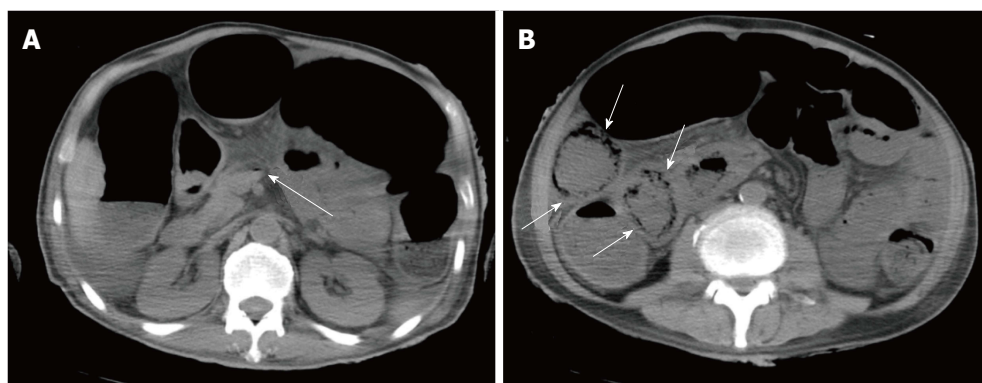
Laboratory investigation	Results	Reference ranges
Arterial blood gas		
Blood pH	7.121	7.42 ± 0.04
PaCO <sub>2</sub> (mmHg)	24.5	32-46
PaO <sub>2</sub> (mmHg)	83.6	74-100
Base excess (mmol/L)	-7.3	-2-2
Lactic acid (mmol/L)	2.6	0.44-1.78
Plasma bicarbonate (mmol/L)	15.6	21-29
Serum chemistry		
Serum albumin (g/dL)	1.6	3.8-5.1
Aspartate aminotransferase (IU/mL)	28	9-35
Alanine aminotransferase (IU/mL)	14	5-36
Blood urea nitrogen (mg/dL)	85	6-22
Creatine (mg/dL)	2.61	0.47-0.79
C-reactive protein (mg/dL)	10.3	0-0.5
Blood glucose (mg/dL)	104	70-109
Blood count		
WBC (/μL)	7.4 × 10 <sup>3</sup>	3.9-9.8
Hemoglobin (g/dL)	9.5	13.4-17.6
Hematocrit (%)	30.4	39-52
Platelet count (/μL)	7.9 × 10 <sup>4</sup>	13-37
Prothrombin time-INR	1.17	0.9-1.1

and antiepileptics are the most frequent triggers of TEN. A DLST for phenobarbital was positive in this patient, and the TEN was retrospectively determined to be a drug eruption caused by phenobarbital, with the condition progressing to TEN from SJS during its clinical course.

Pneumatosis cystoides intestinalis (PCI) is an unusual intestinal condition characterized by the presence of gas within the intestinal wall, usually in the mucosa and sub-mucosa of the small and large intestines. PCI has been classified as primary or secondary, with most patients having secondary PCI due to an underlying condition<sup>[4]</sup>. These underlying conditions have been classified as (1) traumatic and mechanical (*e.g.*, pyloric stenosis, endoscopy, enteric tube placement volvulus, surgical anastomosis, carcinoma); (2) inflammatory and auto-immune (*e.g.*, Crohn's disease, ulcerative colitis, diverticular disease, necrotizing enterocolitis, polydermatomyositis, scleroderma, mixed connective tissue disease, multiple sclerosis); (3) infectious (*e.g.*, *Clostridium difficile*, HIV/AIDS, cytomegalovirus, *Mycobacterium* species); (4) pulmonary (*e.g.*, chronic obstructive pulmonary disease, asthma, cystic fibrosis); (5) drug induced (*e.g.*, cytotoxic agents, immunosuppressants, corticosteroids); or (6) other conditions, such as transplantation, graft versus host disease, leukemia, or intestinal infarction<sup>[5]</sup>.

The pathogenesis of PCI is unclear, although several hypotheses have been suggested. The gas within the intestine wall may be intraluminal, pulmonary or produced by bacteria<sup>[5,6]</sup>. Mechanical features thought to be responsible for intrusion of intraluminal gas into the bowel wall are mucosal injury and/or increased intraluminal pressure. The possibility of pulmonary gas as a source for PCI is based on the hypothesis that air migrates along vessels within the mediastinum, retroperitoneum and mesentery after alveolar rupture in pulmonary diseases.





**Figure 3** Abdominal computed tomography of patient on day 8 of admission to the intensive care unit, showing. A: Gas in the superior mesenteric vein (arrow); B: Extraluminal gas along the small bowel mesentery (arrows).

PCI may be asymptomatic or may manifest symptoms and signs associated with life threatening complications, such as bowel ischemia, perforation and peritonitis. Generally, however, the symptoms of PCI are mild and include abdominal pain, diarrhea or constipation, abdominal distension, bloody stools and/or weight loss. About 3% of patients experience more serious symptoms, including bleeding, ileus, volvulus, intussusception, and/or pneumoperitoneum<sup>[7]</sup>.

Treatment for PCI depends on its symptoms, with no specific treatment standardized. PCI may be detected incidentally by radiographic imaging, screening colonoscopy, or during laparotomy. Intramural gas cysts in asymptomatic patients usually resolve spontaneously over time. Patients with mild to moderate symptoms are usually treated conservatively, with antibiotics, oxygen, and hyperbaric oxygen therapy reported effective<sup>[8,9]</sup>. Emergency surgical exploration is indicated for patients with suspected intestinal necrosis or abdominal sepsis<sup>[10]</sup>. Immediate surgery has been indicated for patients with elevated C-reactive protein or WBC, or the signs of sepsis, bowel perforation or portal venous gas. Conservative therapy has been recommended for patients with normal or slightly increased inflammatory parameters in blood samples and no signs of sepsis, bowel perforation or free gas<sup>[11]</sup>.

Since the first report of PCI in France in the 18<sup>th</sup> century, numerous case reports and reviews have appeared worldwide. However, intestinal lesions in patients with TEN have rarely been reported. To our knowledge, our patient is the first reported to have TEN associated with PCI. Four patients with TEN were reported to present with digestive symptoms, including abdominal pain and bloody diarrhea. Pathological examination of mucosal biopsy specimens revealed that the superficial epithelium was severely damaged by necrosis, while the lamina propria was relatively unaffected<sup>[1]</sup>.

PCI has been reported associated with collagen skin diseases, including scleroderma and dermatomyositis<sup>[10,12]</sup>. These patients are often treated with corticosteroids, which can induce atrophy of the mucosa and mucosal defects facilitating the intrusion of gas and bacteria<sup>[13]</sup>.

Our patient was treated intravenously with high dose corticosteroids for 15 d, which may have exacerbated the atrophy and necrosis of the intestinal mucosa, which had been damaged by TEN. Persistent constipation may result in chronically elevated intra-luminal pressure, inducing the invasion of intramural compartments by gas and bacteria. The fragility of his intestinal mucosa allowed bacterial translocation and resulted in septic shock of *Corynebacterium*.

The signs of peritoneal irritation and gas in the SMV suggested the need for an emergency laparotomy, but his poor general condition did not allow surgery. In addition, we were unable to identify any underlying disease that could have induced ischemia or necrosis of the intestine. Conservative treatment with antibiotics, catecholamine, and oxygen therapy was successful. His abdominal symptoms disappeared and he discharged from the ICU after 8 d. In general, patients with signs of peritonitis in addition to metabolic acidosis indicating septic shock are candidates for surgery. However, in the absence of life-threatening situations such as perforation or necrosis, PCI can be managed conservatively. PCI is a clinical sign, and is not itself a diagnosis. Careful evaluation of the underlying disease and accompanying symptoms is essential.

## ACKNOWLEDGEMENTS

The authors thank edanz.Ltd who provided medical writing services.

## COMMENTS

### Case characteristics

A 55-year-old male patient under the treatment of toxic epidermal necrolysis presented abdominal distension and fell into state of shock.

### Clinical diagnosis

The patient was diagnosed with pneumatosis cystoides intestinalis.

### Differential diagnosis

Perforative peritonitis, acute mesenteric artery occlusion.

### Laboratory diagnosis

The patient had severe acidosis (a blood pH of 7.121), acute renal damage (blood urea nitrogen 85 mg/dL, creatine 2.61 mg/dL) and elevated C-reactive protein (10.3 mg/dL).

### Imaging diagnosis

A non-contrast computed tomography scan revealed gas in the superior mesenteric vein and intramural air in the small-bowel wall.

### Pathological diagnosis

No pathological specimen was obtained but a blood culture was positive for a species of *Corynebacterium*, showing that the patient had been in the state of sepsis due to pneumatosis cystoides intestinalis.

### Treatment

Conservative management including oxygen treatment, intravenous broad-spectrum antibiotics and catecholamine was successful.

### Related reports

Toxic epidermal necrolysis is a severe adverse drug reaction, which is characterized by erythema, blisters, and/or erosions of the mucous membranes and skin in whole body, but intestinal involvement is rarely reported.

### Experiences and lessons

Pneumatosis cystoides intestinalis can be observed during the treatment course of toxic epidermal necrolysis and conservative management is possibly effective when there are no signs of ischemia or necrosis of the intestine.

### Peer review

This is an interesting case report of pneumatosis cystoides intestinalis associated with toxic epidermal necrolysis. The manuscript is clearly written, and this unusual presentation has clinical relevance.

## REFERENCES

- 1 Chosidow O, Delchier JC, Chaumette MT, Wechsler J, Wolkenstein P, Bourgault I, Roujeau JC, Revuz J. Intestinal involvement in drug-induced toxic epidermal necrolysis. *Lancet* 1991; **337**: 928 [PMID: 1673016 DOI: 10.1016/0140-6736(91)90273-R]
- 2 Harr T, French LE. Toxic epidermal necrolysis and Stevens-Johnson syndrome. *Orphanet J Rare Dis* 2010; **5**: 39 [PMID: 21162721 DOI: 10.1186/1750-1172-5-39]
- 3 Yamane Y, Aihara M, Ikezawa Z. Analysis of Stevens-Johnson syndrome and toxic epidermal necrolysis in Japan from 2000 to 2006. *Allergol Int* 2007; **56**: 419-425 [PMID: 17713361 DOI: 10.2332/allergolint.O-07-483]
- 4 KOSS LG. Abdominal gas cysts (pneumatosis cystoides intestinalis); an analysis with a report of a case and a critical review of the literature. *AMA Arch Pathol* 1952; **53**: 523-549 [PMID: 14923068]
- 5 St Peter SD, Abbas MA, Kelly KA. The spectrum of pneumatosis intestinalis. *Arch Surg* 2003; **138**: 68-75 [PMID: 12511155 DOI: 10.1001/archsurg.138.1.68]
- 6 Pear BL. Pneumatosis intestinalis: a review. *Radiology* 1998; **207**: 13-19 [PMID: 9530294]
- 7 Galandiuk S, Fazio VW. Pneumatosis cystoides intestinalis. A review of the literature. *Dis Colon Rectum* 1986; **29**: 358-363 [PMID: 3516602 DOI: 10.1007/BF02554132]
- 8 Tak PP, Van Duinen CM, Bun P, Eulderink F, Kreuning J, Gooszen HG, Lamers CB. Pneumatosis cystoides intestinalis in intestinal pseudoobstruction. Resolution after therapy with metronidazole. *Dig Dis Sci* 1992; **37**: 949-954 [PMID: 1587203 DOI: 10.1007/BF01300397]
- 9 Togawa S, Yamami N, Nakayama H, Shibayama M, Mano Y. Evaluation of HBO2 therapy in pneumatosis cystoides intestinalis. *Undersea Hyperb Med* 2004; **31**: 387-393 [PMID: 15686270]
- 10 Braumann C, Menenakos C, Jacobi CA. Pneumatosis intestinalis--a pitfall for surgeons? *Scand J Surg* 2005; **94**: 47-50 [PMID: 15865117]
- 11 Schröpfer E, Meyer T. Surgical aspects of pneumatosis cystoides intestinalis: two case reports. *Cases J* 2009; **2**: 6452 [PMID: 19918585 DOI: 10.4076/1757-1626-2-6452]
- 12 Balbir-Gurman A, Brook OR, Chermesh I, Braun-Moscovici Y. Pneumatosis cystoides intestinalis in scleroderma-related conditions. *Intern Med J* 2012; **42**: 323-329 [PMID: 22432985 DOI: 10.1111/j.1445-5994.2011.02557.x]
- 13 Höer J, Truong S, Virnich N, Füzesi L, Schumpelick V. Pneumatosis cystoides intestinalis: confirmation of diagnosis by endoscopic puncture a review of pathogenesis, associated disease and therapy and a new theory of cyst formation. *Endoscopy* 1998; **30**: 793-799 [PMID: 9932761 DOI: 10.1055/s-2007-1001424]

P- Reviewer: Bourgoin SG, Chen GS S- Editor: Ji FF

L- Editor: A E- Editor: Lu YJ



## Champagne bottle neck sign in a patient with Moyamoya syndrome

Takafumi Shimogawa, Takato Morioka, Tetsuro Sayama, Takeshi Hamamura, Chiharu Yasuda, Shuji Arakawa

Takafumi Shimogawa, Takato Morioka, Tetsuro Sayama, Takeshi Hamamura, Department of Neurosurgery, Kyushu Rosai Hospital, Fukuoka 800-0296, Japan

Chiharu Yasuda, Shuji Arakawa, Department of Cerebrovascular Disease, Kyushu Rosai Hospital, Fukuoka 800-0296, Japan

Author contributions: All authors contributed to this work

Correspondence to: Takafumi Shimogawa, MD, Department of Neurosurgery, Kyushu Rosai Hospital, 1-1 Sonekitamachi, Kokura Minami-Ku, Kitakyushu, Fukuoka 800-0296, Japan. [shimogawa28@gmail.com](mailto:shimogawa28@gmail.com)

Telephone: +81-93-4711121 Fax: +81-93-4730627

Received: January 12, 2014 Revised: June 24, 2014

Accepted: July 15, 2014

Published online: September 16, 2014

flects a reduction in the diameter of the proximal portion of the internal carotid artery that resembles a CBN, and is a characteristic feature of Moyamoya disease. This case describes the first report of bilateral CBN signs in a 43-year-old woman diagnosed with Moyamoya syndrome associated with Graves' disease. Cerebral revascularization surgery was performed on the patient, and the CBN signs remained unchanged throughout four years of follow-up.

Shimogawa T, Morioka T, Sayama T, Hamamura T, Yasuda C, Arakawa S. Champagne bottle neck sign in a patient with Moyamoya syndrome. *World J Clin Cases* 2014; 2(9): 474-477 Available from: URL: <http://www.wjgnet.com/2307-8960/full/v2/i9/474.htm> DOI: <http://dx.doi.org/10.12998/wjcc.v2.i9.474>

### Abstract

The champagne bottle neck (CBN) sign refers to a reduction in the diameter of the proximal portion of the internal carotid artery that resembles a CBN, and is a characteristic feature of Moyamoya disease. A 43-year-old woman with an infarction of the posterior limb of the left internal capsule was diagnosed with Moyamoya syndrome associated with Graves' disease. The CBN sign was observed bilaterally. Cerebral revascularization surgery was performed, including left-sided superficial temporal artery to middle cerebral artery anastomosis. During four years of follow-up, she maintained a euthyroid state and did not have any further cerebral ischemic events. The CBN signs remained unchanged on both sides during this time. This is the first report of the CBN sign in a patient with Moyamoya syndrome associated with Graves' disease.

© 2014 Baishideng Publishing Group Inc. All rights reserved.

**Key words:** Champagne bottle neck sign; Moyamoya disease; Moyamoya syndrome; Graves' disease; Revascularization

**Core tip:** The champagne bottle neck (CBN) sign re-

### INTRODUCTION

Moyamoya disease (MMD) is a cerebrovascular disorder characterized by progressive bilateral stenosis or occlusion of the distal portion of the internal carotid artery (ICA) and proximal portions of the middle cerebral artery (MCA) and anterior cerebral artery (ACA), together with the formation of net-like collateral vessels in the basal ganglia<sup>[1,2]</sup>. The rarely observed vasculopathy that is characteristic of this disease is seen associated with pathologic conditions such as arteriosclerosis, Down's syndrome, von Recklinghausen's disease, and X-ray irradiation in Moyamoya syndrome (MMS)<sup>[3]</sup>. Several cases of Moyamoya vasculopathy associated with Graves' disease have been reported<sup>[4-7]</sup>. Graves' disease is a female-dominant autoimmune thyroid disease characterized by the formation of autoantibodies to thyroid-stimulating hormone (TSH) receptors, resulting in continuous stimulation of the thyroid gland and hyperthyroidism<sup>[4]</sup>.

In 2006, Yasaka *et al*<sup>[8]</sup> reported that ultrasonography in patients with MMD showed a rapid reduction in the diameter of the proximal ICA to less than half of the

diameter of the common carotid artery, giving the appearance of a champagne bottle neck (CBN). The CBN sign occurred in 74% of patients with MMD, but has not been reported in patients with MMS. We report a case involving a patient with MMS associated with Graves' disease, in whom the CBN sign was observed. The results of long-term follow-up after cerebral revascularization surgery are also presented.

## CASE REPORT

A 43-year-old Japanese woman presented with weakness of the right extremities, which she first noticed when she awoke in the morning. She had a six-month history of fatigue and weight loss. On admission, her blood pressure was 117/72 mmHg and her heart rate was 125 beats/min. Physical examination revealed a right-sided carotid bruit. No goiter or exophthalmos was observed. A neurologic examination showed mild right hemiparesis and dysarthria.

Laboratory data demonstrated hyperthyroidism with a TSH level of 0.015  $\mu$ U/mL (normal range: 0.35–4.94  $\mu$ U/mL), free T3 level of 26.42 pg/mL (normal range: 1.71–3.71 pg/mL), and free T4 level of 4.37 ng/dL (normal range: 0.70–1.48 ng/dL). Her TSH receptor antibody level was 36.7% (normal: < 15%). Ultrasonography of the thyroid gland showed a diffuse goiter, and thyroid scintigraphy was positive. She was diagnosed with hyperthyroidism due to Graves' disease, and antithyroid drug treatment with methimazole and potassium iodide was started.

Diffusion-weighted magnetic resonance imaging on admission showed a hyperintense area at the left posterior limb of the internal capsule (Figure 1A). Magnetic resonance angiography (MRA) and three-dimensional computed tomography angiography showed bilateral severe stenosis of the distal ICA and proximal MCA and ACA (Figure 1B). Digital subtraction angiography showed Moyamoya vessels in the left basal ganglia and bilateral stenosis of the distal ICA and proximal MCA and ACA (Figure 1C). No Moyamoya vessels were observed on the right side. Bilateral narrowing of the proximal ICA consistent with the CBN sign was also observed on digital subtraction angiography (Figure 1D), three-dimensional computed tomography angiography (Figure 1E), and ultrasonography (Figure 1F).

The patient was diagnosed with an acute infarction of the posterior limb of the internal capsule due to Moyamoya syndrome (Suzuki stage 3 on the right side and stage 1 on the left side<sup>[4]</sup>) associated with Graves' disease. She was treated with ozagrel, edaravone and heparin, and subsequently with aspirin and warfarin. Antithyroid drug treatment with methimazole and potassium iodide was continued.

The patient's right hemiparesis and dysarthria were resolved two months later. She had experienced no additional cerebral ischemic events and was euthyroid with a TSH level of < 0.016  $\mu$ U/mL and a free T3 level of 3.02

pg/mL. MRA showed no change in the bilateral CBN signs (Figure 1G) or the bilateral severe stenosis of the distal ICA and proximal MCA and ACA. Single-photon emission computed tomography with N-isopropyl-p-[<sup>123</sup>I]-iodoamphetamine (IMP-SPECT) showed a markedly compromised vascular reserve in the left MCA territory and slightly decreased cerebral blood flow (41.69 and 43.80 mL/100 g/min in the left and right MCA territories, respectively). The regional cerebrovascular reactivity after acetazolamide loading was 7.10% in the left MCA territory and 11.79% in the right MCA territory.

To treat the perfusion insufficiency in the left MCA territory, left superficial temporal artery to MCA anastomosis, encephalo-duro-arterio-synangiosis and encephalo-myo-synangiosis were performed. The antiplatelet and anticoagulation medications were discontinued postoperatively.

MRA at one month after the cerebral revascularization surgery showed a patent bypass (Figure 1H). There was no change in the bilateral stenosis of the distal ICA and proximal MCA and ACA. IMP-SPECT showed that cerebral blood flow was improved in the left MCA territory (45.75 and 44.41 mL/100 g/min in the left and right MCA territories, respectively) and that regional cerebrovascular reactivity was improved in the left MCA territory (13.07% and 17.45% in the left and right MCA territories, respectively).

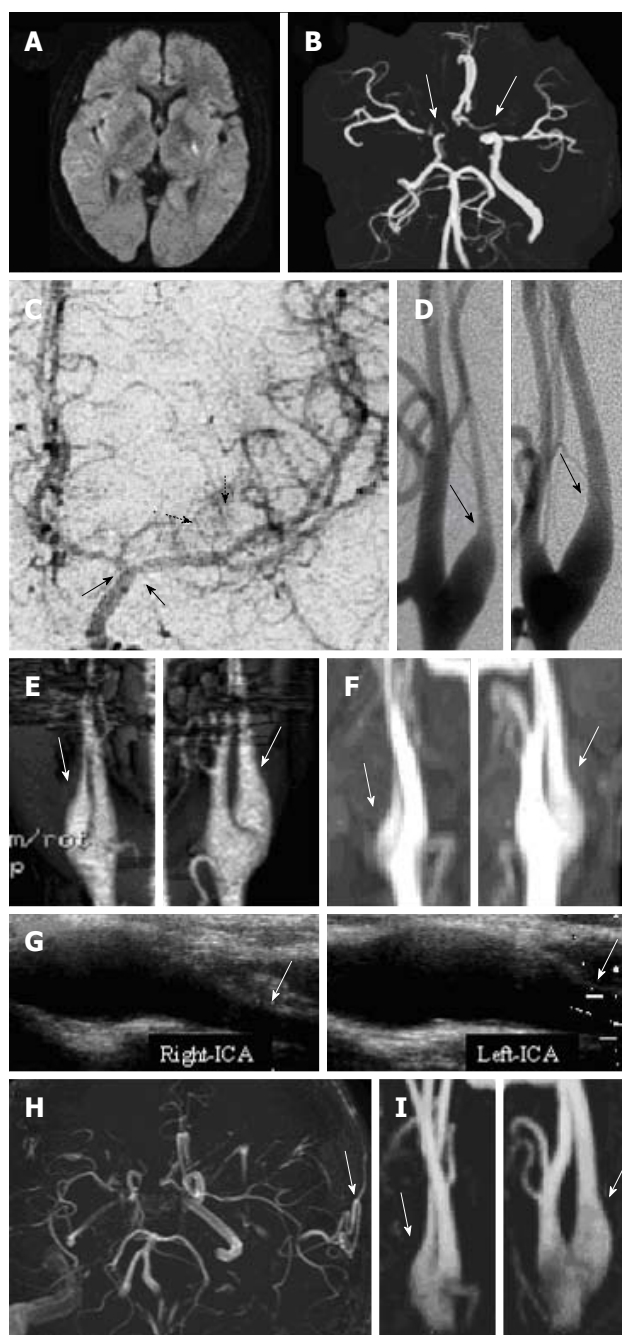
During four years of follow-up after surgery, the patient's euthyroid state was maintained with antithyroid therapy and she experienced no additional cerebral ischemic events. An MRA at four years after surgery showed no change in the bilateral CBN signs (Figure 1I).

## DISCUSSION

Although the CBN sign is a characteristic feature of MMD<sup>[8]</sup>, no previous reports have described the clinical significance of this sign or the specific underlying pathophysiologic mechanisms. Histopathologic examination shows eccentrically laminated thickening of the intima of the major intracranial arteries in patients with MMD<sup>[9]</sup>. Fibrocellular intimal thickening is also observed in other arteries such as the extracranial ICAs, external carotid arteries, pulmonary arteries, renal arteries and coronary arteries<sup>[10–12]</sup>. At the carotid bifurcation, there is a transitional zone between the elastic portion of the carotid arteries (located > 5 mm proximal to the bifurcation) and the muscular portion of the carotid arteries (located > 15 mm distal to the bifurcation)<sup>[13,14]</sup>. It is speculated that the muscular portion is more commonly affected than the elastic portion because of its thinner intimal membrane<sup>[13]</sup>, and that the stenosis extends from the distal to the proximal ICA. The narrowing at the transitional zone results in the CBN sign.

This is the first report of the CBN sign in a patient with MMS. Although the association between MMS and Graves' disease is not well understood<sup>[3–7]</sup>, it has been hypothesized that the increased vascular reactivity resulting





**Figure 1 Imaging results.** A: Diffusion-weighted magnetic resonance imaging three hours after the onset of right hemiparesis revealed a hyperintense area in the posterior limb of the left internal capsule; B: Magnetic resonance angiography (MRA) showing bilateral severe stenosis of the distal portion of the internal carotid artery (ICA) and proximal portions of the middle cerebral artery (MCA) and anterior cerebral artery (ACA); C: Left carotid angiography (anteroposterior view), showing Moyamoya-like vascular changes around the circle of Willis (black dotted arrows) as well as stenosis of the distal left ICA and proximal left MCA and ACA (black arrows); D: Bilateral champagne bottle neck (CBN) signs at the proximal ICAs (arrows) were observed with digital subtraction angiography; E: Three-dimensional computed tomography angiography; and F: Ultrasonography; G: MRA in the euthyroid state, showing no changes in the bilateral CBN signs (white arrows); H: MRA at four years after superficial temporal artery to MCA anastomosis, showing that the anastomosis remained patent (white arrow); I: No change was observed in the bilateral CBN signs after four years (white arrows)

leading to MMD<sup>[15-17]</sup>. The CBN sign may reflect intimal thickening of the extracranial ICA.

In the series of patients with MMD reported by Yasaka *et al.*<sup>[8]</sup>, the relationships among the stage of MMD, the presence of the CBN sign, and chronologic changes in the CBN sign, were not reported. In our patient, the stage of MMS was more advanced on the left (the symptomatic side) than on the right. Moyamoya vessels were not observed on the right side, and perfusion reserve was impaired in the left MCA territory. However, the CBN sign was observed equally on both sides, and did not change between the hyperthyroid and euthyroid states. During the four years after cerebral revascularization surgery, no changes were observed in the CBN signs. It has previously been reported that Moyamoya-like vascular changes and stenosis of the intracranial arteries and do not occur in patients with MMS associated with Graves' disease after antithyroid treatment and cerebral revascularization<sup>[3-5,18]</sup>. Likewise, the changes causing the CBN sign are irreversible.

## COMMENTS

### Case characteristics

A 43-year-old Japanese woman presented with weakness of the right extremities and had a six-month history of fatigue and weight loss.

### Clinical diagnosis

The patient's heart rate was 125 beats/min and a neurologic examination showed mild right hemiparesis and dysarthria.

### Differential diagnosis

Brain infarction; Intracerebral hemorrhage; Brain tumor.

### Laboratory diagnosis

Laboratory data demonstrated hyperthyroidism with a thyroid-stimulating hormone level of 0.015  $\mu$ U/mL, free T3 level of 26.42 pg/mL, free T4 level of 4.37 ng/dL, and a thyroid-stimulating hormone receptor antibody level of 36.7%.

### Imaging diagnosis

Diffusion-weighted magnetic resonance imaging on admission showed a hyperintense area at the left posterior limb of the internal capsule, and digital subtraction angiography showed Moyamoya vessels in the left basal ganglia and bilateral stenosis of the distal internal carotid artery and proximal middle and anterior cerebral arteries. Bilateral narrowing of the proximal internal carotid artery consistent with the champagne bottle neck (CBN) sign was also observed on three-dimensional computed tomography angiography and ultrasonography.

### Pathological diagnosis

The patient was diagnosed with acute infarction of the posterior limb of the internal capsule due to Moyamoya syndrome associated with Graves's disease.

### Treatment

Revascularization was performed following antithyroid drug treatment.

### Related reports

Ultrasonography in patients with Moyamoya disease showed a rapid reduction in the diameter of the proximal internal carotid artery to less than half of the diameter of the common carotid artery (giving the appearance of a CBN), although the relationships among the disease stage, presence of the CBN sign, and chronologic changes in the CBN sign were not reported.

### Experiences and lessons

The CBN signs were not affected by the change between the hyperthyroid and euthyroid states. Furthermore, no changes in the CBN signs were observed after cerebral revascularization surgery, demonstrating their irreversibility.

### Peer review

This is the first report of the CBN sign in a patient with Moyamoya syndrome associated with Graves' disease.

## REFERENCES

- 1 Kuroda S, Houkin K. Moyamoya disease: current concepts

- and future perspectives. *Lancet Neurol* 2008; **7**: 1056-1066 [PMID: 18940695 DOI: 10.1016/S1474-4422(08)70240-0]
- 2 **Burke GM**, Burke AM, Sherma AK, Hurley MC, Batjer HH, Bendok BR. Moyamoya disease: a summary. *Neurosurg Focus* 2009; **26**: E11 [PMID: 19335127 DOI: 10.3171/2009.1.FOCUS08310]
  - 3 **Endo H**, Fujimura M, Niizuma K, Shimizu H, Tominaga T. Efficacy of revascularization surgery for moyamoya syndrome associated with Graves' disease. *Neurol Med Chir (Tokyo)* 2010; **50**: 977-983 [PMID: 21123980 DOI: 10.2176/nmc.50.977]
  - 4 **Im SH**, Oh CW, Kwon OK, Kim JE, Han DH. Moyamoya disease associated with Graves disease: special considerations regarding clinical significance and management. *J Neurosurg* 2005; **102**: 1013-1017 [PMID: 16028759 DOI: 10.3171/jns.2005.102.6.1013]
  - 5 **Tokimura H**, Tajitsu K, Takashima H, Hirayama T, Tsuchiya M, Takayama K, Arita K. Familial moyamoya disease associated with Graves' disease in a mother and daughter. Two case reports. *Neurol Med Chir (Tokyo)* 2010; **50**: 668-674 [PMID: 20805652 DOI: 10.2176/nmc.50.668]
  - 6 **Malik S**, Russman AN, Katramados AM, Silver B, Mitsias PD. Moyamoya syndrome associated with Graves' disease: a case report and review of the literature. *J Stroke Cerebrovasc Dis* 2011; **20**: 528-536 [PMID: 21130668 DOI: 10.1016/j.jstrokecerebrovasdis.2010.03.006.]
  - 7 **Li D**, Yang W, Xian P, Liu P, Bao X, Zong R, Duan L. Co-existence of moyamoya and Graves' diseases: the clinical characteristics and treatment effects of 21 Chinese patients. *Clin Neurol Neurosurg* 2013; **115**: 1647-1652 [PMID: 23518423 DOI: 10.1016/j.clineuro.2013.02.018.]
  - 8 **Yasaka M**, Ogata T, Yasumori K, Inoue T, Okada Y. Bottle neck sign of the proximal portion of the internal carotid artery in moyamoya disease. *J Ultrasound Med* 2006; **25**: 1547-1552; quiz 1547-1552; [PMID: 17121949]
  - 9 **Yamashita M**, Oka K, Tanaka K. Histopathology of the brain vascular network in moyamoya disease. *Stroke* 1983; **14**: 50-58 [PMID: 6823686 DOI: 10.1161/01.STR.14.1.50]
  - 10 **Hoshimaru M**, Kikuchi H. Involvement of the external carotid arteries in moyamoya disease: neuroradiological evaluation of 66 patients. *Neurosurgery* 1992; **31**: 398-400 [PMID: 1407420 DOI: 10.1227/00006123-199209000-00002]
  - 11 **Ou P**, Dupont P, Bonnet D. Fibromuscular dysplasia as the substrate for systemic and pulmonary hypertension in the setting of Moya-Moya disease. *Cardiol Young* 2006; **16**: 495-497 [PMID: 16984702 DOI: 10.1017/S104795110600045X]
  - 12 **Yang SH**, Li B, Wang CC, Zhao JZ. Angiographic study of moyamoya disease and histological study in the external carotid artery system. *Clin Neurol Neurosurg* 1997; **99** Suppl 2: S61-S63 [PMID: 9409408 DOI: 10.1016/S0303-8467(97)00035-8]
  - 13 **Hori E**, Hayashi N, Hamada H, Masuoka T, Kuwayama N, Hirashima Y, Origasa H, Ohtani O, Endo S. A development of atheromatous plaque is restricted by characteristic arterial wall structure at the carotid bifurcation. *Surg Neurol* 2008; **69**: 586-590; discussion 590-591 [PMID: 18261781 DOI: 10.1016/j.surneu.2007.05.033.]
  - 14 **Janzen J**, Lanzer P, Rothenberger-Janzen K, Vuong PN. Variable extension of the transitional zone in the medial structure of carotid artery tripod. *Vasa* 2001; **30**: 101-106 [PMID: 11417279 DOI: 10.1024/0301-1526.30.2.101]
  - 15 **Honda H**, Iwata T, Mochizuki T, Kogo H. Changes in vascular reactivity induced by acute hyperthyroidism in isolated rat aortae. *Gen Pharmacol* 2000; **34**: 429-434 [PMID: 11483292 DOI: 10.1016/S0306-3623(01)00080-5]
  - 16 **Inaba M**, Henmi Y, Kumeda Y, Ueda M, Nagata M, Emoto M, Ishikawa T, Ishimura E, Nishizawa Y. Increased stiffness in common carotid artery in hyperthyroid Graves' disease patients. *Biomed Pharmacother* 2002; **56**: 241-246 [PMID: 12199623 DOI: 10.1016/S0753-3322(02)00195-6]
  - 17 **Squizzato A**, Gerdes VE, Brandjes DP, Büller HR, Stam J. Thyroid diseases and cerebrovascular disease. *Stroke* 2005; **36**: 2302-2310 [PMID: 16179578 DOI: 10.1161/01.STR.0000181772.78492.07]
  - 18 **Utku U**, Asil T, Celik Y, Tucer D. Reversible MR angiographic findings in a patient with autoimmune Graves disease. *AJNR Am J Neuroradiol* 2004; **25**: 1541-1543 [PMID: 15502134]

P- Reviewer: Starke R S- Editor: Wen LL L- Editor: A  
E- Editor: Lu YJ



## Splenic lymphoma with massive splenomegaly: Case report with review of literature

Sachin B Ingle, Chitra R Hinge Ingle

Sachin B Ingle, Department of Pathology, MIMSR Medical College, Latur, Maharashtra 4132512, India

Chitra R Hinge Ingle, Department of Physiology, MIMSR Medical College, Latur, Maharashtra 4132512, India

Author contributions: Ingle SB and Ingle CRH prepared the manuscript; Ingle SB critically revised the intellectual content and gave final approval of manuscript.

Correspondence to: Sachin B Ingle, Professor, Department of Pathology, MIMSR Medical College, Ambajogai Road, vishwanathpuram Latur, Maharashtra 413512, India. [dr.sachiningle@gmail.com](mailto:dr.sachiningle@gmail.com)

Telephone: +91-2382-227424 Fax: +91-2382-228939

Received: April 18, 2014 Revised: June 10, 2014

Accepted: June 27, 2014

Published online: September 16, 2014

### Splenectomy; Anticoagulation

**Core tip:** Primary splenic lymphoma is a rare entity, can present with grave complications like hypersplenism and splenic rupture. In such circumstances, emergency splenectomy is an effective therapeutic and diagnostic tool. Now a days laparoscopic splenectomy is emerging because of minimal complications. Postoperative anti-coagulation is important to prevent portal splenic vein thrombosis.

Ingle SB, Ingle CRH. Splenic lymphoma with massive splenomegaly: Case report with review of literature. *World J Clin Cases* 2014; 2(9): 478-481 Available from: URL: <http://www.wjgnet.com/2307-8960/full/v2/i9/478.htm> DOI: <http://dx.doi.org/10.12998/wjcc.v2.i9.478>

### Abstract

As per strict criteria of Das Gupta *et al*, primary splenic lymphoma is very rare. Herein, we are reporting an unusual case of primary large cell splenic lymphoma of B lineage in a middle aged female presenting with massive splenomegaly (3.8 kg) and hypersplenism. After performing therapeutic splenectomy for hypersplenism, a precise diagnosis of diffuse large B cell lymphoma was made on histopathology and confirmed by immunohistochemistry. The patient responded well to standard (Cyclophosphamide, Hydroxydaunorubicin, Oncovin (vincristine), Prednisone or prednisolone) regimen last year and is now in full remission. The splenectomy thereby has prevented the potential grave complications related to hypersplenism and splenic rupture. Our aim behind highlighting the topic is to specify that emergency splenectomy followed by anticoagulation therapy is an effective plan of management to prevent untoward complications related to disease and treatment.

© 2014 Baishideng Publishing Group Inc. All rights reserved.

**Key words:** Huge splenic lymphoma; Pancytopenia;

### INTRODUCTION

Primary splenic lymphoma is a very unusual entity if strict diagnostic criteria proposed by Das Gupta *et al*<sup>[1]</sup> are applied. According to their views diagnosis of Primary Splenic Lymphoma should be made when the disease is confined to spleen or at the most involves hilar lymph nodes with no recurrence of disease after splenectomy<sup>[1,2]</sup>. Herein, we present such an unusual case of Primary Splenic Lymphoma of diffuse large B cell type diagnosed on histopathology and confirmed by immunohistochemistry in a patient presenting with massive splenomegaly and hypersplenism. Splenectomy was followed by anticoagulation therapy and chemotherapy [with standard Cyclophosphamide, Hydroxydaunorubicin, Oncovin (vincristine), Prednisone or prednisolone (CHOP) regimen]. The patient responded well and as on today, is in complete remission preventing grave complications of disease and splenectomy thus justifying both diagnostic and therapeutic utility of splenectomy and effective anticoagulation therapy is must to prevent portal vein splenic



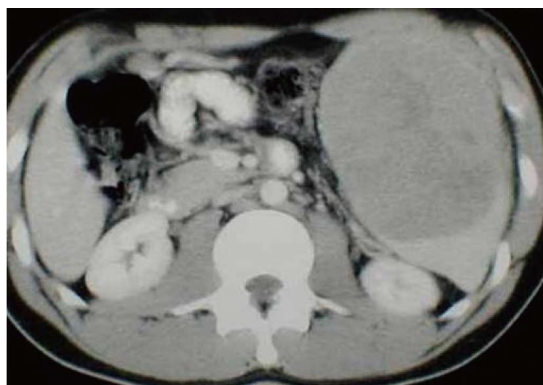

Figure 1 Computed tomography showing massive splenomegaly without mass lesion.

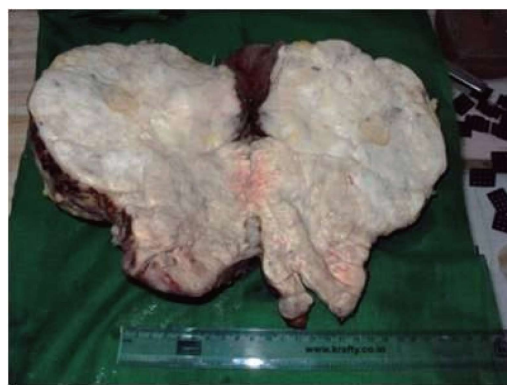

Figure 3 Cut surface was grey white.

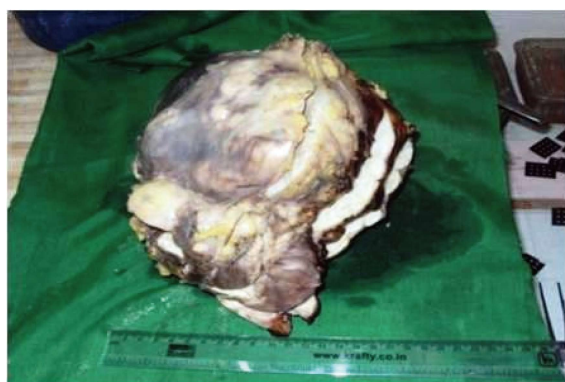

Figure 2 Encapsulated huge massive splenic mass.

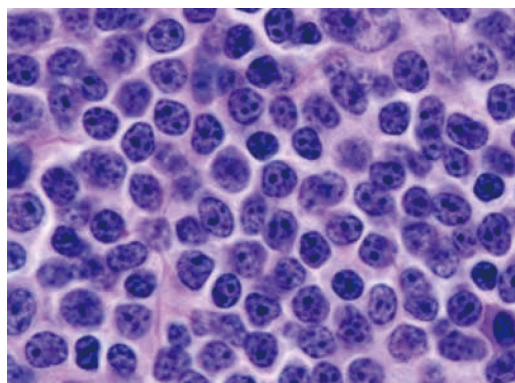


Figure 4 Diffuse monotonous population of neoplastic lymphoid cells.

vein thrombosis(PVST).

## CASE REPORT

A 41-year-old female, complained of weight loss and abdominal pain. She was afebrile and physical examination revealed no palpable peripheral lymphadenopathy. Head and neck examination revealed moderate anemia, no jaundice and a clear oropharynx. Heart and lung examination were normal. She had a protuberant abdomen with a firm palpable spleen that extended below the navel. There was no ascites or hepatomegaly. Abdominal ultrasonography and plain computed tomography scanning showed massive splenomegaly without a mass lesion (Figure 1). Blood examination revealed pancytopenia: WBC  $1.9 \times 10^9/L$  (neutrophils 48.0%, eosinophils 0%, basophils 0%, monocytes 4.0%, lymphocytes 48.0%), Hb 10.3 g/dL, platelet count  $99 \times 10^9/L$ , LDH 127 U/L (normal range 100-220 U/L). Air-dried peripheral blood smear showed no abnormal lymphocytes including hairy cells or villous lymphocytes. Liver and renal functions were within normal limits. Bone marrow aspiration and biopsy revealed normocellular bone marrow without abnormal cell involvement, fibrosis, dysplasia or hemophagocytosis. Liver cirrhosis and idiopathic portal hypertension were ruled out. Whole body computed tomography (CT) scanning revealed no abnormal lesions in other organs. Therefore,

emergency splenectomy was planned and performed. The operation progressed without complications. The resected spleen weighed 3.8 kg. The cut surface was almost totally effaced by a huge greywhite homogenous tumor soft rubbery in consistency (Figures 2 and 3) Microscopy revealed diffuse proliferation of monotonous population of large neoplastic lymphoid cells [Large B cell lymphoma (DLBCL)] (Figure 4), The tumor cells were immunopositive for CD 20 and immunonegative for T cell markers (Figure 5). Intraoperative findings did not reveal any lymph node swelling or tumor. Therefore, the patient was diagnosed as stage I splenic lymphoma. Four days after the operation, the patient recovered from the pancytopenia: WBC of  $7.6 \times 10^9/L$ , Hb 13.0 g/dL and platelet count  $330 \times 10^9/L$  although CRP increased to 8.21 mg/dL owing to postoperative infection. 24 h after surgery, received subcutaneous injection of LMWH (Low Molecular Weight Heparin) routinely, 0.3 mL per 12 h for 5 d and then maintained by oral therapy with warfarin for one month to keep the target prothrombin time/international normalized ratio (PT/INR) at a level between 1.25 and 1.5 to prevent PSVT.

Three courses of standard CHOP plus rituximab chemotherapy were given. Complete remission has continued for 12 mo post operatively without any grave complications related to disease and splenectomy. Thus, the case was finally confirmed as primary splenic lymphoma of B



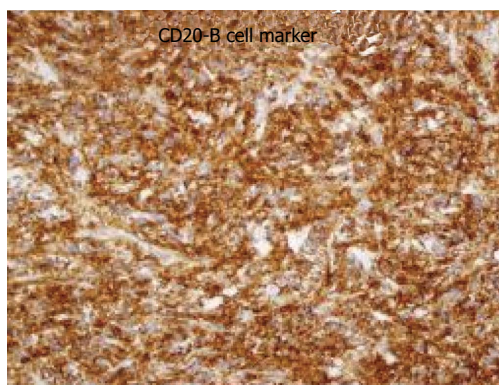


Figure 5 CD20 positive lymphoid cells.

cell lineage as per the strict criteria of Das Gupta *et al*<sup>[1]</sup>.

## DISCUSSION

Primary lymphoma of the spleen is very rare if strict criteria for diagnosis suggested by Das Gupta *et al*<sup>[1]</sup> are applied<sup>[2]</sup>.

Solitary splenic non Hodgkin Lymphoma (NHL) is rare; the incidence is less than 1%<sup>[3]</sup>. Some solitary lymphomas cannot be discerned by plain CT scanning alone or US alone. Consequently, enhanced CT scanning and Gallium scintigraphy are absolutely required to identify splenic tumor. Splenectomy is often chosen to diagnose solitary splenic lymphoma.

However, several previous reports discussed the risk of splenectomy for massive (greater than 1500 gm) splenomegaly. Splenectomy for massive splenomegaly showed a high rate of perioperative mortality (about 20%)<sup>[4,5]</sup>. In some cases with poor general status, bleeding tendency, complications due to infection or organ failure, one should be hesitant to use an invasive diagnostic method. On the other hand, splenic needle biopsy may provide an adequate diagnosis without severe complications. Tam *et al*<sup>[6]</sup> reported percutaneous image guided splenic needle biopsy in 156 consecutive cases and concluded that splenic needle biopsy in the evaluation of new or recurrent neoplasm is a minimally invasive procedure with low complication rates and a high diagnostic yield. If it is institutionally and technically possible, splenic needle biopsy should be taken into consideration for high risk patients<sup>[6]</sup>. Recently, laparoscopic splenectomy has often been used for splenic masses because of fewer complications and since it is rather appropriate for moderate splenomegaly<sup>[7,8]</sup>.

This patient underwent splenectomy because she had no complications. Splenectomy was done to: (1) establish a correct pathological diagnosis; (2) reduce the hypersplenism; (3) reduce the radiation field; (4) relieving symptoms; and (5) prevent splenic rupture and prevented PSVT with effective anticoagulant therapy

Generally speaking, the localized indolent lymphoma is expected to have good prognosis despite the absence of further treatment with chemotherapy. In contrast,

most cases of aggressive lymphoma such as DLBCLs show disease expansion and progression, requiring immediate chemotherapy. It is speculated that the high rate of perioperative mortality in massive splenomegaly could be due to rapid progression of disease and such patients should be subjected to less invasive diagnostic methods and treated immediately.

Splenic lymphoma and splenomegaly secondary to lymphoma or other hematological malignancies are often reported as a cause of hypersplenism and the cytopenias resolved after splenectomy in most cases<sup>[4,9]</sup>. Therefore, splenectomy is useful not only for diagnosis but also for treatment of the underlying hematologic malignancy.

It is an unusual case of primary splenic lymphoma presenting with massive splenomegaly (3.8 kg) and hypersplenism. In such a critical clinical situation, clinician should keep in mind splenectomy supported by anticoagulation therapy as an effective therapeutic and diagnostic method to prevent grave complications related to disease (hypersplenism, splenic rupture) and splenectomy, *i.e.*, PSVT that could prove fatal. Recently splenic needle biopsy can be used to diagnose the condition earlier.

## COMMENTS

### Case characteristics

Massive splenomegaly, hypersplenism.

### Clinical diagnosis

Primary splenic lymphoma presenting with huge splenic mass and hypersplenism.

### Differential diagnosis

Causes of hypersplenism, lymphoma, leukemia, Malaria, Kala azar.

### Laboratory diagnosis

Hypersplenism presenting with thrombocytopenia.

### Imaging diagnosis

Computed tomography scan revealing massive splenomegaly without mass lesion.

### Pathological diagnosis

Biopsy findings are confirmatory for diffuse large B cell lymphoma.

### Treatment

Emergency splenectomy is an effective therapeutic and diagnostic tool in such critical circumstances.

### Peer review

This manuscript is very interesting.

## REFERENCES

1. Das Gupta T, Goombes B, Brosfeld RD. Primary malignant neoplasms of the spleen. *Surg Gynecol Obstet* 1969; **120**: 947-60
2. Cavanna L, Artioli F, Vallisa D, Di Donato C, Bertè R, Carapezzi C, Foroni R, Del Vecchio C, Lo Monaco B, Prati R. Primary lymphoma of the spleen. Report of a case with diagnosis by fine-needle guided biopsy. *Haematologica* 1995; **80**: 241-243 [PMID: 7672717]
3. Brox A, Shustik C. Non-Hodgkin's lymphoma of the spleen. *Leuk Lymphoma* 1993; **11**: 165-171 [PMID: 8260891 DOI: 10.3109/10428199309086992]
4. Han B, Yang Z, Yang T, Gao W, Sang X, Zhao Y, Shen T. Diagnostic splenectomy in patients with fever of unknown origin and splenomegaly. *Acta Haematol* 2008; **119**: 83-88 [PMID: 18305380 DOI: 10.1159/000118632]
5. Danforth DN, Fraker DL. Splenectomy for the massively

- 6 enlarged spleen. *Am Surg* 1991; **57**: 108-113 [PMID: 1992865]  
**Tam A**, Krishnamurthy S, Pillsbury EP, Ensor JE, Gupta S, Murthy R, Ahrar K, Wallace MJ, Hicks ME, Madoff DC. Percutaneous image-guided splenic biopsy in the oncology patient: an audit of 156 consecutive cases. *J Vasc Interv Radiol* 2008; **19**: 80-87 [PMID: 18192471 DOI: 10.1016/j.jvir.2007.08.025]
- 7 **Tessier DJ**, Pierce RA, Brunt LM, Halpin VJ, Eagon JC, Frisella MM, Czerniejewski S, Matthews BD. Laparoscopic splenectomy for splenic masses. *Surg Endosc* 2008; **22**: 2062-2066 [PMID: 18246392 DOI: 10.1007/s00464-008-9748-8]
- 8 **Shimizu I**, Ichikawa N, Yotsumoto M, Sumi M, Ueno M, Kobayashi H. Asian variant of intravascular lymphoma: aspects of diagnosis and the role of rituximab. *Intern Med* 2007; **46**: 1381-1386 [PMID: 17827836 DOI: 10.2169/internal-medicine.46.0066]
- 9 **Pottakkat B**, Kashyap R, Kumar A, Sikora SS, Saxena R, Kapoor VK. Redefining the role of splenectomy in patients with idiopathic splenomegaly. *ANZ J Surg* 2006; **76**: 679-682 [PMID: 16916382 DOI: 10.1111/j.1445-2197.2006.03828.x]

**P- Reviewer:** Yoshida H   **S- Editor:** Ji FF   **L- Editor:** A  
**E- Editor:** Lu YJ



## Cranioplasty with custom made alloplastic prosthetic implant: A case report

Lokendra Gupta, IN Aparna, Dhanasekar Balakrishnan, Lingeshwar Deenadayalan, Puneeth Hegde, Priyanka Agarwal

Lokendra Gupta, IN Aparna, Dhanasekar Balakrishnan, Puneeth Hegde, Department of Prosthodontics, Manipal College of Dental Sciences, Manipal 576104, India  
Lingeshwar Deenadayalan, Flat No. 5 Purushotam Flat No. 64, Second Main, Gandhi Nagar, Chennai 20, India  
Priyanka Agarwal, Department of Pedodontics, Manipal College of Dental Sciences, Manipal 576104, India

Author contributions: Agarwal P helping in manuscript preparation; Gupta L, Aparna IN and Balakrishnan D contributed to devise the treatment planning and prosthesis fabrication; Deenadayalan L and Hegde P helped Neurosurgeons for prosthesis adjustment and fitting, during surgical rehabilitation.

Correspondence to: Dr. Lokendra Gupta, Assistant Professor, Department of Prosthodontics, Manipal College of Dental Sciences, Karnataka, Manipal 576104, India. [lokinse@gmail.com](mailto:lokinse@gmail.com)

Telephone: +91-820-2922183

Received: March 20, 2014 Revised: May 30, 2014

Accepted: June 27, 2014

Published online: September 16, 2014

sidual monomer or the heat of polymerization. The other advantages are low content of residual monomer in prosthesis because of long curing cycle and prolonged immersion in water. Old orthopantomogram films were used during impression. It is an easy and economical method for recording the defect. In order to reduce the bulk of the prosthesis, the defect area was contoured with plaster. After try in, the wax pattern was covered with an aluminum foil, to check the contour radiographically. Gutta percha points were incorporated as radiopaque marker.

Gupta L, Aparna IN, Balakrishnan D, Deenadayalan L, Hegde P, Agarwal P. Cranioplasty with custom made alloplastic prosthetic implant: A case report. *World J Clin Cases* 2014; 2(9): 482-487 Available from: <http://www.wjgnet.com/2307-8960/full/v2/i9/482.htm> DOI: <http://dx.doi.org/10.12998/wjcc.v2.i9.482>

### Abstract

Cranial defects often occur due to trauma. The treatment of such defects is a challenge to the skill and knowledge of the practitioner. This article presents one such case, where a 15-year-old boy had suffered extensive loss of the right cranium following a road traffic accident. The patient required rehabilitation of the right fronto-temporal cranial anatomy and was managed using a custom made heat polymerized acrylic alloplastic implant.

© 2014 Baishideng Publishing Group Inc. All rights reserved.

**Key words:** Cranioplasty; Cranial implant; Acquired defect; Heat cure poly methyl methacrylate resin

**Core tip:** Prefabricated heat-polymerized acrylic prosthesis, offers the benefits of reducing the tissues to re-

### INTRODUCTION

The loss of a body part reflects significantly on a patient's life. Not only does it have a huge influence on their physical and mental state, it makes social integration difficult; often dampening their expectations to return to normalcy.

Cranial defects may result from trauma, disease or due to congenital malformations. Repair of cranial defects is indicated to protect the underlying brain tissue, provide pain relief at the defect site, improve aesthetics and minimize patient anxiety<sup>[1,2]</sup>. Humans lack the ability to regenerate a lost body part, but reconstruction can be achieved through prosthetic means and a multidisciplinary approach.

Cranioplasty is one of the oldest known neurosurgical procedures, dating back to 3000 B. C.<sup>[3,4]</sup>. For centuries, various materials have been tried for covering bony de-

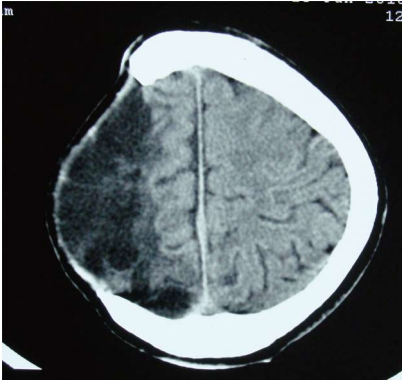


Figure 1 Computed tomography scan showing right cranial defect.

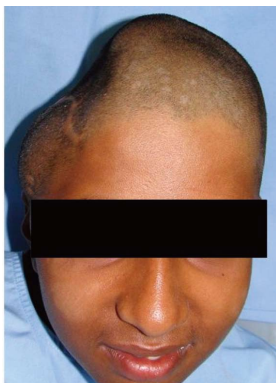

Figure 2 Frontal view of the cranial defect.

fects, including coconut shells, bones from both human and non-human donors, metals<sup>[5,6]</sup> and more recently, bio-synthetic materials such as resins and ceramics.

Cranioplasty can be performed using a range of procedures. When plastic materials are used, the main requirement for an effective cranioplasty, is the preoperative shaping of the implant to fit the bony defect precisely<sup>[7]</sup>. Acrylic cranioplasty is frequently used for patients who have a cranial defect after trauma or an infected craniotomy or meningiomas<sup>[8,9]</sup>. Two basic methods of cranioplasty are widely accepted - osteoplastic reconstruction and restoration with alloplastic material. This article describes a patient whose cranial defect has been restored with a prefabricated acrylic resin prosthesis.

## CASE REPORT

A 15 years old male patient was referred to the Department of Prosthodontics, from the Department of Neurosurgery for the management of an acquired cranial defect. The patient had a significant medical history of a road traffic accident (RTA), resulting in an open head injury with right temporo-parietal contusion and a fracture of the squamous part of the temporal bone. The patient was treated immediately with a right fronto-temporo parietal craniotomy by the neurosurgeons (Figure 1). Post-operatively it was found that the patient had a lateral hemiplegia on the left side and a large bony defect on the

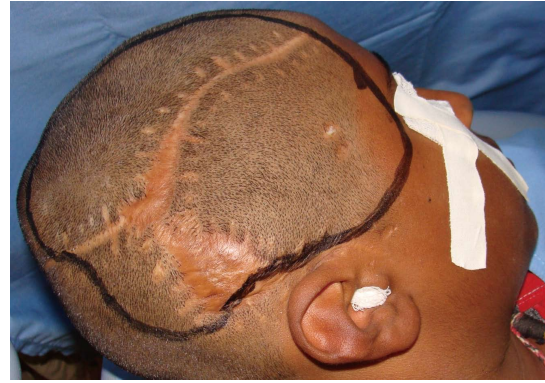

Figure 3 Patient preparation before impression making.

right side of the skull (Figure 2). On examination, the defect was found to be 15 cm × 12 cm in size. The defect that was to be restored was large and a CAD/CAM or a metal prosthesis would have been the most probable option, but considering the economic background of the patient, a custom-made heat-cured acrylic resin cranial prosthesis was planned.

## Procedure

The construction of any maxillofacial prosthesis with alloplastic material consists of four stages, each of which is equally important to the success of the rehabilitation effort. These stages include mouldage impression and working cast fabrication, Sculpture and formation of the pattern, mould fabrication, and processing of the prosthesis<sup>[10]</sup>. Patch testing for acrylic was done prior to the prosthesis fabrication to rule out any acrylic allergy<sup>[11]</sup>. (1) The patient preparation for impression was done by covering the eye and the external auditory meatus with gauze to prevent the ingress of material into the palpebral fissure and the ear canal respectively (Figure 3); (2) Because of the large defect, old orthopantomograms were used as a tray, to confine the impression material during the impression procedure; (3) The defect was outlined and an impression of the defect was made with irreversible hydrocolloid (Dentsply Zelgan Plus irreversible hydrocolloid, India). L-shaped paper clips were inserted for the stabilization of plaster of Paris which was used for reinforcement of the impression material; (4) Once the impression material was set, it was removed carefully and poured with dental stone (Kalstone, laboratory stone, Kalabhai, Mumbai, India) to obtain a cast of the defect (Figure 4); (5) The outline of the defect was marked for the fabrication of onlay type of cranial prosthesis. The marked stone cast was contoured with plaster of Paris so as to obtain the arbitrary shape of the cranium, and a wax pattern (Hindustan dental product, Hyderabad, India) was fabricated over the contoured cast. The wax pattern was then tried on the patient (Figure 5); (6) The contour of the wax pattern was corrected from all sides viz. the frontal, sagittal and occipital, to restore the normal contour and appearance. After the try-in of the wax pattern on the defect, the contours were verified radio-





Figure 4 Tissue surface of the impression with defect marking.

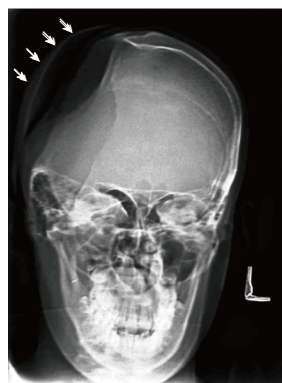

Figure 6 Radiographic verification of the wax pattern.

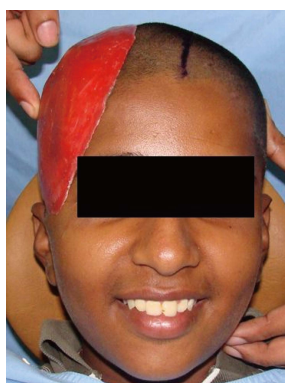

Figure 5 Wax pattern try in.

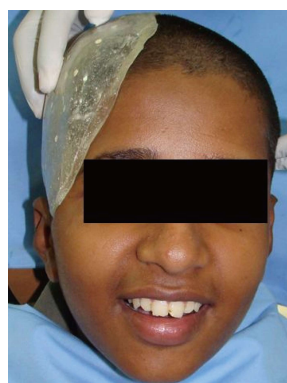

Figure 7 Try in of final heat cure alloplastic cranial implant.

graphically, by covering the wax pattern with aluminum foil. (Caremate Aluminium foil, Maharashtra India) (Figure 6); (7) The contoured wax pattern was then invested in a maxillofacial flask, using plaster of paris. It was dewaxed using boiling water for 4 min<sup>[12]</sup>; (8) Following this, clear heat cure acrylic resin (Trevalon, denture base materials, Dentsply India) was packed in the mold space and was then cured using a constant temperature water bath at 74 °C for 10 h<sup>[13]</sup>. A long curing cycle was selected in order to reduce the residual monomer content of the cured prosthesis; (9) The processed prosthesis was removed from the flask carefully. The excess was trimmed and the prosthesis was polished, using pumice and cotton buff. Trial of the contoured and polished prosthesis was done on the patient and checked from all the anatomical aspects (the frontal, sagittal and occipital) (Figure 7); (10) The prosthesis was sterilized with ethylene oxide gas prior to the insertion; (11) The surgical procedure involved the preparation of the scalp with an antiseptic solution and the reflection of the scalp with a U shaped incision to completely expose the bony margins of the defect; (12) Adjustment of the prosthesis was done with an acrylic trimmer so as to fit as closely as possible in the cranial defect. The prosthesis was then secured with titanium plates and screws (Surgiwear, Sharjahanpur, India) to the surrounding bony margins and the defect was then closed (Figure 8); (13) The closed system suction drain (Hemovac, Zimmer United States) was placed immediately

after the surgery to reduce the postoperative hematoma; (14) The drain was removed on the 2<sup>nd</sup> postoperative day and the patient had a good recovery (Figures 9 and 10); (15) The patient and parents were instructed for the care of the reconstructed area; and (16) During the follow-up visits (6 mo, 1 year and 1½ years), the contour of the defect was satisfactory from all the anatomical aspects (Figures 11-13).

## DISCUSSION

Cranioplasties have been performed since the early 1950s<sup>[10]</sup>. Acrylic resin materials have been used as bone substitutes in dentistry, neurosurgery and orthopedic surgery for decades. Interest in acrylic resins among neurosurgeons increased considerably following Spence's 1954 report of a simple method for fabricating implants at the time of surgery, using auto polymerizing methyl methacrylate<sup>[14]</sup>. Acrylic implants are dimensionally stable, non-conductive, inexpensive, and can be easily modified and placed<sup>[15]</sup>. Acrylic resin has some advantages over metal substances; it is easy to shape, lighter in weight, radiates less heat, and radiolucent<sup>[16]</sup>. In a study, Kumar *et al*<sup>[17]</sup> in 2011, have proved that large defects, like war defects, can be successfully restored with alloplastic materials. A pre-fabricated implant can save valuable time in the operating room and better cosmetic results can be achieved, since any adjustments required can be made before the patient

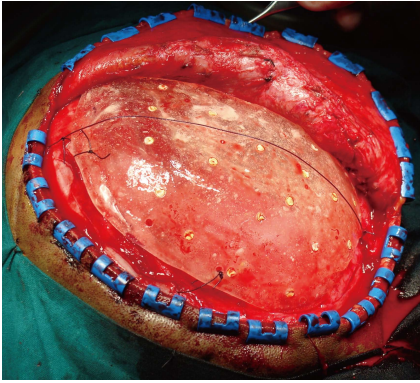


Figure 8 Placement and suturing of the final prosthesis.

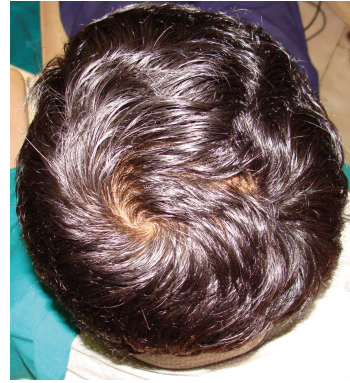

Figure 11 Restored cranial defect.

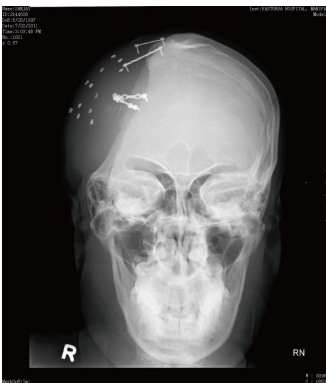

Figure 9 Post-operative postero-anterior view.

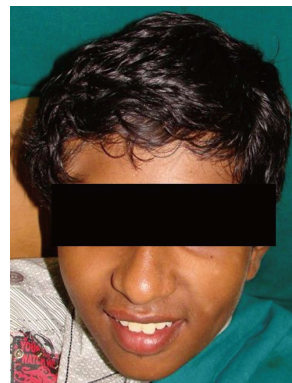

Figure 12 Frontal view of the restored cranial defect.

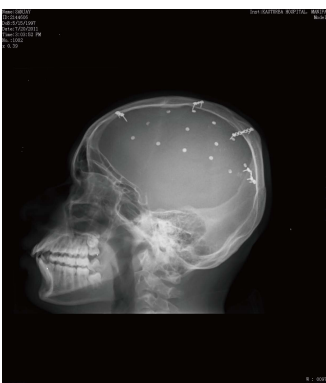

Figure 10 Post-operative lateral view.

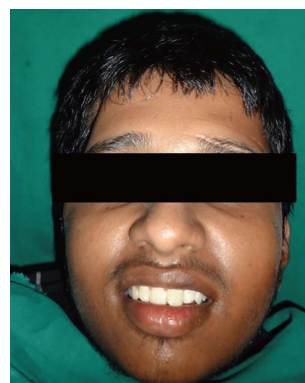

Figure 13 Follow up frontal profile.

undergoes surgery. Fabricating cranial implants before surgery, using moulds and heat-polymerized methyl methacrylate, offers the benefits of using auto polymerizing acrylic resin, without exposing the tissues to residual monomer or the heat of polymerization<sup>[18,19]</sup>. Heat-polymerized resin is 50% stronger than auto polymerizing resin<sup>[20]</sup> and contains less than 0.3% residual monomer. Excess free monomer is removed because of the long curing cycle and preparation before implantation. Apart from these advantages, in the present case report, old orthopantomogram films were used during impression. This was an easy and economical method for recording the defect. In order to reduce the bulk of the prosthesis,

the defect area of the master cast was contoured with plaster. After try in, the wax pattern was covered with an aluminum foil, which made it possible to check the contour of the prosthesis radiographically. Gutta percha points were incorporated in the final PMMA prosthesis so as to serve as a radiopaque marker. A patch test was performed to rule out any allergic reactions to PMMA. Lee *et al*<sup>[21]</sup> in 2009 suggested that the infection rate associated with prefabricated PMMA prostheses was lower than that for intra-operatively molded PMMA prostheses and was comparable to that for auto graft bone flaps. Complications such as swelling, infection<sup>[18,22]</sup> headache, hemianopia were not seen during the follow up period

of one and a half years duration for the same patient. Other complications such as implant mobilisation<sup>[23]</sup> were also not reported by the patient. Recently, CAD CAM generated cranial prostheses or titanium plates have been introduced for a precise fit<sup>[24-28]</sup> however, the high cost of these prostheses makes their use rare in patients, due to economic reasons.

Prefabricated custom made craniofacial prostheses simplify the restoration of complex cranial defects, reduce the surgical time necessary for implant placement and decrease the risk of contamination that can occur when large implants are shaped intraoperatively. Cranioplasty with prefabricated poly-methyl methacrylate prosthesis is inexpensive and enables shorter operative time with good esthetic results.

## COMMENTS

### Case characteristic

Patient had a lateral hemiplegia on the left side and a large bony defect on the right side of the skull.

### Clinical diagnosis

Fifteen cm × 12 cm size cranial defect after right fronto-temporo parietal craniotomy.

### Imaging diagnosis

Computed tomography, Orthopantomogram showed right fronto-temporo parietal craniotomy defect

### Treatment

Prosthetic rehabilitation of the cranial defect with custom made alloplastic heat cure acrylic implant.

### Related reports

A 15 years old male patient was referred to the Department of Prosthodontics, from the Department of Neurosurgery for the management of an acquired cranial defect. The patient had a significant medical history of a road traffic accident (RTA), resulting in an open head injury with right temporo-parietal contusion and a fracture of the squamous part of the temporal bone. The patient was treated immediately with a right fronto-temporo parietal craniotomy by the neurosurgeons. Post-operatively it was found that the patient had a lateral hemiplegia on the left side and a large bony defect on the right side of the skull. On examination, the defect was found to be 15 cm × 12 cm in size. The defect was restored with a custom-made heat-cured acrylic resin cranial prosthesis.

### Term explanation

Craniotomy-surgical removal of a portion of the skull. Cranioplasty is a surgical repair of a defect or deformity of a skull. Alloplastic: graft of a relatively inert synthetic material. Generally metal, ceramic or polymeric material. Facial Moulage: face impression

### Innovations and breakthroughs

A prefabricated implant can save valuable time in the operating room and better cosmetic results can be achieved. Fabricating cranial implants before surgery, using moulds and heat-polymerized methyl methacrylate, offers the benefits of using auto polymerizing acrylic resin, without exposing the tissues to residual monomer or the heat of polymerization. Heat-polymerized resin is 50% stronger than auto polymerizing resin and contains less than 0.3% residual monomer. Excess free monomer is removed because of the long curing cycle and preparation before implantation. In the present case report, old orthopantomogram films were used during impression. This was an easy and economical method for recording the defect. In order to reduce the bulk of the prosthesis, the defect area of the master cast was contoured with plaster. After try in, the wax pattern was covered with an aluminum foil, which made it possible to check the contour of the prosthesis radiographically. Gutta percha points were incorporated in the final PMMA prosthesis so as to serve as a radiopaque marker.

### Peer review

This case report provided a good example of the method being used in clinical practice with 18 mo clinical follow-up. The case is particularly well documented with extensive figures and photographs.

## REFERENCES

- 1 **Dumbrigue HB**, Arcuri MR, LaVelle WE, Ceynar KJ. Fabrication procedure for cranial prostheses. *J Prosthet Dent* 1998; **79**: 229-231 [PMID: 9513113 DOI: 10.1016/S0022-3913(98)70222-7]
- 2 **Beumer J**, Firtell DN, Curtis TA. Current concepts in cranioplasty. *J Prosthet Dent* 1979; **42**: 67-77 [PMID: 379310]
- 3 **William S**, Pietrzak. Musculoskeletal Tissue Regeneration: Biological Materials and Methods, Chapter 1, Musculoskeletal and wound treatment through ages: a brief historical tour, Springer Humana press publishers Totowa NJ 07512 USA. 2008: 3-18. Available from: URL: <http://books.google.co.in/books?id=2qq56LYomagC&pg=PR3&lpg=PR3&dq>
- 4 **Abdulai A**, Iddrissu M, Dakurah T. Cranioplasty using polymethyl methacrylate implant constructed from an alginate impression and wax elimination technique. *Ghana Med J* 2006; **40**: 18-21 [PMID: 17299559]
- 5 **Gordon DS**, Blair GA. Titanium cranioplasty. *Br Med J* 1974; **2**: 478-481 [PMID: 4834099]
- 6 **SCOTT M**, WYCIS H, MURTAGH F. Long term evaluation of stainless steel cranioplasty. *Surg Gynecol Obstet* 1962; **115**: 453-461 [PMID: 13909953]
- 7 **Chiarini L**, Figurelli S, Pollastri G, Torcia E, Ferrari F, Albanese M, Nocini PF. Cranioplasty using acrylic material: a new technical procedure. *J Craniomaxillofac Surg* 2004; **32**: 5-9 [PMID: 14729042]
- 8 **Prolo DJ**, Oklund SA. The use of bone grafts and alloplastic materials in cranioplasty. *Clin Orthop Relat Res* 1991; **268**: 270-278 [PMID: 2060219]
- 9 **Jordan RD**, White JT, Schupper N. Technique for cranioplasty prosthesis fabrication. *J Prosthet Dent* 1978; **40**: 230-233 [PMID: 278842]
- 10 **Martin JW**, Ganz SD, King GE, Jacob RF, Kramer DC. Cranial implant modification. *J Prosthet Dent* 1984; **52**: 414-416 [PMID: 6592339]
- 11 **Wiltshire WA**, Ferreira MR, Ligthelm AJ. Allergies to dental materials. *Quintessence Int* 1996; **27**: 513-520 [PMID: 9161254]
- 12 **Anusavice Phillips'** science of dental materials. 10th ed. Harcourt publishers, 2003: 241
- 13 **Anusavice Phillips'** science of dental materials. 10th ed. Harcourt publishers, 2003: 249
- 14 **SPENCE WT**. Form-fitting plastic cranioplasty. *J Neurosurg* 1954; **11**: 219-225 [PMID: 13163718]
- 15 **Firtell DN**, Grisius RJ. Cranioplasty of the difficult frontal region. *J Prosthet Dent* 1981; **46**: 425-429 [PMID: 7028958]
- 16 **Aydin S**, Kucukyuruk B, Abuzayed B, Aydin S, Sanus GZ. Cranioplasty: Review of materials and techniques. *J Neurosci Rural Pract* 2011; **2**: 162-167 [PMID: 21897681 DOI: 10.4103/0976-3147.83584]
- 17 **Kumar AR**, Bradley JP, Harshbarger R, Stevens F, Bell R, Moores L, Armonda R. Warfare-related craniectomy defect reconstruction: early success using custom alloplast implants. *Plast Reconstr Surg* 2011; **127**: 1279-1287 [PMID: 21364428 DOI: 10.1097/PRS.0b013e318205f47c]
- 18 **Taub PJ**, Rudkin GH, Clearihue WJ, Miller TA. Prefabricated alloplastic implants for cranial defects. *Plast Reconstr Surg* 2003; **111**: 1233-1240 [PMID: 12621197 DOI: 10.1097/01.PRS.0000046048.77472.23]
- 19 **Cooper PR**, Schechter B, Jacobs GB, Rubin RC, Wille RL. A pre-formed methyl methacrylate cranioplasty. *Surg Neurol* 1977; **8**: 219-221 [PMID: 897995]
- 20 **Stafford GD**, Huggett R, Causton BE. Fracture toughness of denture base acrylics. *J Biomed Mater Res* 1980; **14**: 359-371 [PMID: 7400192 DOI: 10.1002/jbm.820140403]
- 21 **Lee SC**, Wu CT, Lee ST, Chen PJ. Cranioplasty using polymethyl methacrylate prostheses. *J Clin Neurosci* 2009; **16**: 56-63 [PMID: 19046734 DOI: 10.1016/j.jocn.2008.04.001]
- 22 **Sabin H**. Cranial implant problems. *J Prosthet Dent* 1975; **34**:

- 659-665 [PMID: 1059768]
- 23 **Hallur N**, Goudar G, Sikkerimath B, Gudi SS, Patil RS. Reconstruction of large cranial defect with alloplastic material (bone cement-cold cure polymethyl-methacrylate resin). *J Maxillofac Oral Surg* 2010; **9**: 191-194 [PMID: 22190785 DOI: 10.1007/s12663-010-0062-3]
- 24 **Eppley BL**. Craniofacial reconstruction with computer-generated HTR patient-matched implants: use in primary bony tumor excision. *J Craniofac Surg* 2002; **13**: 650-657 [PMID: 12218793]
- 25 **van Putten MC**, Yamada S. Alloplastic cranial implants made from computed tomographic scan-generated casts. *J Prosthet Dent* 1992; **68**: 103-108 [PMID: 1403895]
- 26 **Kasprzak P**, Tomaszewski G, Kotwica Z, Kwinta B, Zwoliński J. Reconstruction of cranial defects with individually formed cranial prostheses made of polypropylene polyester knitwear: an analysis of 48 consecutive patients. *J Neurotrauma* 2012; **29**: 1084-1089 [PMID: 22320208 DOI: 10.1089/neu.2011.2247]
- 27 **Wiggins A**, Austerberry R, Morrison D, Ho KM, Honeybul S. Cranioplasty with custom-made titanium plates--14 years experience. *Neurosurgery* 2013; **72**: 248-256; discussion 256 [PMID: 23149967 DOI: 10.1227/NEU.0b013e31827b98f3]
- 28 **Schebesch KM**, Höhne J, Gassner HG, Brawanski A. Prefomed titanium cranioplasty after resection of skull base meningiomas - a technical note. *J Craniomaxillofac Surg* 2013; **41**: 803-807 [PMID: 23434238 DOI: 10.1016/j.jcms.2013.01.030]

**P- Reviewer:** Homolkova H, Lichtor T, Morrison DA, Ozkaya O

**S- Editor:** Ji FF **L- Editor:** A **E- Editor:** Lu YJ





# World Journal of *Clinical Cases*

*World J Clin Cases* 2014 October 16; 2(10): 488-607





## Contents

Monthly Volume 2 Number 10 October 16, 2014

### REVIEW

- 488 Diabetes mellitus and electrolyte disorders  
*Liamis G, Liberopoulos E, Barkas F, Elisaf M*
- 497 Practical strategies for modulating foam cell formation and behavior  
*Uitz E, Bahadori B, McCarty MF, Moghadasian MH*
- 507 Marjolin's ulcers in the post-burned lesions and scars  
*Saaq M, Ashraf B*
- 515 Gallbladder cancer: Clinical and pathological approach  
*Kai K, Aishima S, Miyazaki K*

### MINIREVIEWS

- 522 Endoscopic retrograde cholangiopancreatography-related perforation: Management and prevention  
*Prachayakul V, Aswakul P*
- 528 Primary intestinal lymphangiectasia: Minireview  
*Ingle SB, Hinge (Ingle) CR*

### CASE CONTROL STUDY

- 534 Comparison of semilunar coronally repositioned flap with gingival massaging using an Ayurvedic product (irimedadi taila) in the treatment of class- I gingival recession: A clinical study  
*Mishra AK, Kumathalli K, Sridhar R, Maru R, Mangal B, Kedia S, Shrihatti R.*

### CLINICAL TRIALS STUDY

- 541 HLA antigens in individuals with down syndrome and alopecia areata  
*Estefan JL, Oliveira JC, Abad ED, Saintive SB, Porto LCMS, Ribeiro M*

### OBSERVATIONAL STUDY

- 546 He had always wanted to ask an andrologist but had never done so  
*Foresta C, Pizzol D*

### SYSTEMATIC REVIEWS

- 552 Reporting of dental status from full-arch radiographs: Descriptive analysis and methodological aspects  
*Huettig F, Axmann D*

### CASE REPORT

- 565 Chemotherapy induced Takotsubo cardiomyopathy  
*Goel S, Sharma A, Garg A, Chandra A, Shetty V*

- 569** Intensive outpatient comprehensive behavioral intervention for tics: A case series  
*Blount TH, Lockhart AT, Garcia RV, Raj JJ, Peterson AL*
- 578** Challenging rescue of a 4 years old boy with H1N1 infection by extracorporeal membrane oxygenator: A case report  
*Papadopoulos N, Martens S, Keller H, El-Sayed Ahmad A, Moritz A, Zierer A*
- 581** Left ventricular pseudoaneurysm formation: Two cases and review of the literature  
*Petrou E, Vartela V, Kostopoulou A, Georgiadou P, Mastorakou I, Kogerakis N, Sfyrakis P, Athanassopoulos G, Karatasakis G*
- 587** Importance of defining the best treatment of a genital gunshot wound: A case report  
*García-Perdomo HA*
- 591** Bladder paraganglioma: A report of case series and critical review of current literature  
*Ranaweera M, Chung E*
- 596** Haemostatic management for aortic valve replacement in a patient with advanced liver disease  
*Weinberg L, Kearsey I, Tjoakarfa C, Matalanis G, Galvin S, Carson S, Bellomo R, McNicol L, McCall P*
- 604** Liver abscess caused by *Burkholderia pseudomallei* in a young man: A case report and review of literature  
*Pal P, Ray S, Moulick A, Dey S, Jana A, Banerjee K*

## Contents

*World Journal of Clinical Cases*  
Volume 2 Number 10 October 16, 2014

**APPENDIX** I-V Instructions to authors

**ABOUT COVER** Editorial Board Member of *World Journal of Clinical Cases*, Keita Kai, MD, PhD, Associate Professor, Department of Pathology & Microbiology, Faculty of Medicine, Saga University, Nabesima 5-1-1, Saga City, Saga 849-8501, Japan

**AIM AND SCOPE** *World Journal of Clinical Cases* (*World J Clin Cases*, *WJCC*, online ISSN 2307-8960, DOI: 10.12998) is a peer-reviewed open access academic journal that aims to guide clinical practice and improve diagnostic and therapeutic skills of clinicians.

The primary task of *WJCC* is to rapidly publish high-quality Autobiography, Case Report, Clinical Case Conference (Clinicopathological Conference), Clinical Management, Diagnostic Advances, Editorial, Field of Vision, Frontier, Medical Ethics, Original Articles, Clinical Practice, Meta-Analysis, Minireviews, Review, Therapeutics Advances, and Topic Highlight, in the fields of allergy, anesthesiology, cardiac medicine, clinical genetics, clinical neurology, critical care, dentistry, dermatology, emergency medicine, endocrinology, family medicine, gastroenterology and hepatology, geriatrics and gerontology, hematology, immunology, infectious diseases, internal medicine, obstetrics and gynecology, oncology, ophthalmology, orthopedics, otolaryngology, pathology, pediatrics, peripheral vascular disease, psychiatry, radiology, rehabilitation, respiratory medicine, rheumatology, surgery, toxicology, transplantation, and urology and nephrology.

**INDEXING/ABSTRACTING** *World Journal of Clinical Cases* is now indexed in PubMed Central, PubMed, Digital Object Identifier.

**FLYLEAF** I-V Editorial Board

## EDITORS FOR THIS ISSUE

Responsible Assistant Editor: *Xiang Li*  
Responsible Electronic Editor: *Su-Qing Lin*  
Proofing Editor-in-Chief: *Lian-Sheng Ma*

Responsible Science Editor: *Fang-Fang Ji*  
Proofing Editorial Office Director: *Jin-Lei Wang*

**NAME OF JOURNAL**  
*World Journal of Clinical Cases*

**ISSN**  
ISSN 2307-8960 (online)

**LAUNCH DATE**  
April 16, 2013

**FREQUENCY**  
Monthly

**EDITORS-IN-CHIEF**  
**Giuseppe Di Lorenzo, MD, PhD, Professor**, Genitourinary Cancer Section and Rare-Cancer Center, University Federico II of Napoli, Via Sergio Pansini, 5 Ed. 1, 80131, Naples, Italy

**Jan Jacques Michiels, MD, PhD, Professor**, Primary Care, Medical Diagnostic Center Rijnmond Rotterdam, Bloodcoagulation, Internal and Vascular Medicine, Erasmus University Medical Center, Rotterdam, Goodheart Institute and Foundation, Erasmus Tower, Veennos 13, 3069 AT, Erasmus City, Rotterdam, The Netherlands

**Sandro Vento, MD**, Department of Internal Medicine, University of Botswana, Private Bag 00713, Gaborone,

Botswana

**Shuhei Yoshida, MD, PhD**, Division of Gastroenterology, Beth Israel Deaconess Medical Center, Dana 509, Harvard Medical School, 330 Brookline Ave, Boston, MA 02215, United States

**EDITORIAL OFFICE**  
Jin-Lei Wang, Director  
Xiu-Xia Song, Vice Director  
*World Journal of Clinical Cases*  
Room 903, Building D, Ocean International Center, No. 62 Dongsihuan Zhonglu, Chaoyang District, Beijing 100025, China  
Telephone: +86-10-85381891  
Fax: +86-10-85381893  
E-mail: [editorialoffice@wjnet.com](mailto:editorialoffice@wjnet.com)  
Help Desk: <http://www.wjnet.com/csp/helpdesk.aspx>  
<http://www.wjnet.com>

**PUBLISHER**  
Baishideng Publishing Group Inc  
8226 Regency Drive,  
Pleasanton, CA 94588, USA  
Telephone: +1-925-223-8242  
Fax: +1-925-223-8243  
E-mail: [bpgoffice@wjnet.com](mailto:bpgoffice@wjnet.com)  
Help Desk: <http://www.wjnet.com/csp/helpdesk.aspx>

<http://www.wjnet.com>

**PUBLICATION DATE**  
October 16, 2014

**COPYRIGHT**  
© 2014 Baishideng Publishing Group Inc. Articles published by this Open Access journal are distributed under the terms of the Creative Commons Attribution Non-commercial License, which permits use, distribution, and reproduction in any medium, provided the original work is properly cited, the use is non commercial and is otherwise in compliance with the license.

**SPECIAL STATEMENT**  
All articles published in journals owned by the Baishideng Publishing Group (BPG) represent the views and opinions of their authors, and not the views, opinions or policies of the BPG, except where otherwise explicitly indicated.

**INSTRUCTIONS TO AUTHORS**  
Full instructions are available online at [http://www.wjnet.com/2307-8960/g\\_info\\_20100722180909.htm](http://www.wjnet.com/2307-8960/g_info_20100722180909.htm)

**ONLINE SUBMISSION**  
<http://www.wjnet.com/csp/>



## Diabetes mellitus and electrolyte disorders

George Liamis, Evangelos Liberopoulos, Fotios Barkas, Moses Elisaf

George Liamis, Evangelos Liberopoulos, Fotios Barkas, Moses Elisaf, Department of Internal Medicine, School of Medicine, University of Ioannina, Stavrou Niarchou Avenue, 45110 Ioannina, Greece

Author contributions: Liamis G, Liberopoulos E, Barkas F and Elisaf M contributed to this paper.

Correspondence to: George Liamis, MD, PhD, Assistant Professor of Internal Medicine, Department of Internal Medicine, School of Medicine, University of Ioannina, Stavrou Niarchou Avenue, 45110 Ioannina, Greece. [gliamis@cc.uoi.gr](mailto:gliamis@cc.uoi.gr)  
 Telephone: +30-26-51007509 Fax: +30-26-51007016

Received: December 25, 2013 Revised: July 24, 2014

Accepted: September 23, 2014

Published online: October 16, 2014

**Core tip:** Diabetic patients frequently develop a constellation of electrolyte disorders. These patients are often potassium-, magnesium- and phosphate-depleted, especially in the context of diabetic ketoacidosis or nonketotic hyperglycemic hyperosmolar syndrome. Diabetes is linked to both hypo- and hyper-natremia, as well as to chronic hyperkalemia which may be due to hyporeninemic hypoaldosteronism. This article provides an overview of the electrolyte disturbances occurring in diabetes and describes the underlying mechanisms. This insight should pave the way for pathophysiology-directed therapy, thus contributing to the avoidance of the several deleterious effects associated with electrolyte disorders and their treatment.

### Abstract

Diabetic patients frequently develop a constellation of electrolyte disorders. These disturbances are particularly common in decompensated diabetics, especially in the context of diabetic ketoacidosis or nonketotic hyperglycemic hyperosmolar syndrome. These patients are markedly potassium-, magnesium- and phosphate-depleted. Diabetes mellitus (DM) is linked to both hypo- and hyper-natremia reflecting the coexistence of hyperglycemia-related mechanisms, which tend to change serum sodium to opposite directions. The most important causal factor of chronic hyperkalemia in diabetic individuals is the syndrome of hyporeninemic hypoaldosteronism. Impaired renal function, potassium-sparing drugs, hypertonicity and insulin deficiency are also involved in the development of hyperkalemia. This article provides an overview of the electrolyte disturbances occurring in DM and describes the underlying mechanisms. This insight should pave the way for pathophysiology-directed therapy, thus contributing to the avoidance of the several deleterious effects associated with electrolyte disorders and their treatment.

© 2014 Baishideng Publishing Group Inc. All rights reserved.

**Key words:** Glucose; Osmotic diuresis; Hyponatremia; Hyperkalemia; Hypomagnesemia

Liamis G, Liberopoulos E, Barkas F, Elisaf M. Diabetes mellitus and electrolyte disorders. *World J Clin Cases* 2014; 2(10): 488-496 Available from: URL: <http://www.wjgnet.com/2307-8960/full/v2/i10/488.htm> DOI: <http://dx.doi.org/10.12998/wjcc.v2.i10.488>

### INTRODUCTION

Electrolyte disorders are common in clinical practice. They are mainly encountered in hospital populations occurring in a broad spectrum of patients (from asymptomatic to critically ill) and being associated with increased morbidity and mortality<sup>[1-3]</sup>. The disturbances of electrolyte homeostasis are also frequently observed in community subjects. Community-acquired electrolyte disorders, even chronic and mild, are related to poor prognosis<sup>[3]</sup>. Electrolyte disorders are usually multifactorial in nature. Various pathophysiological factors, such as nutritional status, gastrointestinal absorption capacity, coexistent acid-base abnormalities, pharmacological agents, other comorbid diseases (mainly renal disease) or acute illness, alone or in combination, play a key role.

Diabetes mellitus (DM) is included among the diseases with increased frequency of electrolyte abnormali-

**Table 1 Principal causes of electrolyte disorders in diabetic patients**

Sodium disorders <sup>1</sup>
Hyponatremia
Pseudohyponatremia (marked hyperlipidemia)
Hyperglycemia (hypertonicity)-induced movement of water out of the cells (dilutional hyponatremia)
Osmotic diuresis-induced hypovolemic hyponatremia
Drug-induced hyponatremia: hypoglycemic agents (chlorpropamide, tolbutamide, insulin) or other medications ( <i>e.g.</i> , diuretics, amitriptyline)
Pseudonormonatremia (marked hyperlipidemia, severe hypoproteinemia)
Hypernatremia
Pseudohypernatremia (severe hypoproteinemia)
Loss of water in excess of sodium and potassium (osmotic diuresis), if this water loss is replaced insufficiently
Potassium disorders
Hypokalemia
Shift hypokalemia: insulin administration
Gastrointestinal loss of K <sup>+</sup> : malabsorption syndromes (diabetic-induced motility disorders, bacterial overgrowth, chronic diarrheal states)
Renal loss of K <sup>+</sup> : osmotic diuresis, hypomagnesemia, diuretics (thiazides, thiazide-like agents, furosemide)
Hyperkalemia
Shift hyperkalemia: acidosis, insulin deficiency, hypertonicity, rhabdomyolysis, drugs ( <i>e.g.</i> , beta blockers)
Reduced glomerular filtration of K <sup>+</sup> : acute and chronic kidney disease
Reduced tubular secretion of K <sup>+</sup> : hyporeninemic hypoaldosteronism, drugs (angiotensin-converting enzyme inhibitors, angiotensin II receptor blockers, renin inhibitors, beta blockers, potassium-sparing diuretics)
Magnesium disorders
Hypomagnesemia
Pseudohypomagnesemia: hypoalbuminemia
Shift hypomagnesemia: insulin administration
Poor dietary Mg <sup>2+</sup> intake
Gastrointestinal Mg <sup>2+</sup> losses: diarrhea as a result of diabetic autonomic neuropathy
Increased renal Mg <sup>2+</sup> losses due to osmotic diuresis, glomerular hyperfiltration, diuretic administration
Recurrent metabolic acidosis
Calcium disorders
Hypocalcemia
Pseudohypocalcemia: hypoalbuminemia <sup>2</sup>
Acute renal failure due to accompanying hyperphosphatemia
Advanced chronic renal insufficiency due to hyperphosphatemia and low levels of vitamin D
Nephrotic syndrome: loss of 25-hydroxyvitamin D3 and its binding protein in the urine
Hypomagnesemia
Vitamin D deficiency
Drug-mediated: loop diuretics
Hypercalcemia
Concurrent hyperparathyroidism
Thiazide therapy
Phosphorus disorders
Hypophosphatemia
Osmotic diuresis
Drugs: thiazides, loop diuretics, insulin
Malabsorption syndromes
Primary hyperthyroidism
Vitamin D deficiency

<sup>1</sup>Spurious sodium disorders occur when sodium is measured with indirect ion-selective electrodes; <sup>2</sup>The ionized serum calcium levels are normal.

ties given that the aforementioned factors (especially impaired renal function, malabsorption syndromes, acid-base disorders and multidrug regimens) are often present in diabetics<sup>[4]</sup>.

This article provides an overview of the electrolyte disturbances occurring in DM and describes possible underlying mechanisms (Table 1). This insight should pave the way for pathophysiology-directed therapy, possibly contributing to the avoidance of several deleterious effects associated with electrolyte disorders and their treatment.

## DYSNATREMIAS (HYPONATREMIA AND HYPERNATREMIA)

DM is a well-known cause of dysnatremias *via* several

underlying mechanisms<sup>[3,5]</sup>. Glucose is an osmotically active substance. Hyperglycemia increases serum osmolality, resulting in movement of water out of the cells and subsequently in a reduction of serum sodium levels ( $[Na^+]$ ) by dilution. Therefore, in hyperglycemic patients, the corrected  $[Na^+]$  should be taken into account, which is calculated by adding to measured  $[Na^+]$  1.6 mmol/L for every 100 mg/dL (5.55 mmol/L) increment of serum glucose above normal; a correction factor by 2.4 mmol/L is used when serum glucose concentrations are higher than 400 mg/dL (22.2 mmol/L)<sup>[6,7]</sup>. It is worth mentioning that the corrected  $[Na^+]$  after adjustment for the dilutional effect of hyperglycemia should be considered as a useful tool for the monitoring of treatment in hyperglycemic states<sup>[8]</sup>. Uncontrolled DM can also induce hypovolemic-hypo-

natremia due to osmotic diuresis. Moreover, in diabetic ketoacidosis ketone bodies (b-hydroxybutyrate and acetate) obligate urinary electrolyte losses and aggravate the renal sodium wasting<sup>[7,9]</sup>. It should be emphasized, however, that hypotonic renal losses (loss of water in excess of sodium and potassium) due to osmotic diuresis can lead to hypernatremia if this water loss is replaced insufficiently. In a study in 113 hypernatremic patients hospitalized in an internal medicine clinic, poorly controlled DM was implicated in the development of hypernatremia in one third of cases (34.5%)<sup>[5]</sup>. Consequently, in patients with uncontrolled DM serum concentration of  $[\text{Na}^+]$  is variable, reflecting the balance between the hyperglycemia-induced water movement out of the cells that lowers  $[\text{Na}^+]$ , and the glucosuria-induced osmotic diuresis, which tends to raise  $[\text{Na}^+]$ .

Drug-induced hyponatremia due to hypoglycemic agents (chlorpropamide, tolbutamide, insulin) or other medications (*e.g.*, diuretics, amitriptyline for the treatment of diabetic neuropathy) should be considered in every diabetic patient with low  $[\text{Na}^+]$ <sup>[10,11]</sup>. Chlorpropamide, which is now rarely used in the treatment of patients with DM, can induce hyponatremia in approximately 4% to 6% by potentiating the effect of antidiuretic hormone. Elderly patients concomitantly using diuretics have greater risk of developing hyponatremia<sup>[12,13]</sup>. Tolbutamide can lead to hyponatremia by decreasing renal free water clearance<sup>[13]</sup>. Noteworthy, despite fluid retention being a common adverse effect of thiazolidinediones (pioglitazone and rosiglitazone), hyponatremia related to these drugs was reported only once<sup>[14]</sup>. There is experimental evidence that glucagon-like peptide 1 receptor agonists influence water and electrolyte balance<sup>[15]</sup>. However, to the best of our knowledge, dysnatremias (or other electrolyte disorders) related to these drugs have not reported in humans. Moreover, the new class of oral antidiabetic agents known as sodium-glucose cotransporter type 2 (SGLT2) inhibitors does not appear to be associated with electrolyte abnormalities in early clinical studies<sup>[16,17]</sup>.

It has been reported that DM *per se* (independently of drugs or hyperglycemia) is associated with hyponatremia<sup>[11]</sup>. Recently, in a study in 5179 community subjects aged 55 years or more DM was associated with hyponatremia (OR = 1.98; 95%CI: 1.47-2.68), with the serum glucose levels being too low to fully explain the degree of hyponatremia<sup>[3]</sup>. Altered vasopressin metabolism, interaction between insulin and vasopressin, both of which act in the renal collecting duct, and the reabsorption of more hypotonic fluid due to slower stomach emptying have been proposed as possible underlying mechanisms of this association<sup>[18-20]</sup>. Although rare, the inverse etiological relation between hyponatremia and DM also exists. In fact, brain edema in the setting of untreated symptomatic hyponatremia may induce cerebral herniation and infarction of pituitary and hypothalamus, leading to central DM and insipidus<sup>[21]</sup>.

DM is also associated with an artificially decreased or elevated serum sodium value, that is different compared

with the actual systemic level. In normal subjects, serum is composed of water (approximately 93%), with fats and proteins accounting for the remaining 7%. Sodium is located in the serum water phase only. A reduction in serum water fraction (< 80%) may occur in patients with marked hyperlipidemia as with lactescent serum in uncontrolled DM. In these settings, the serum sodium concentration, measured per liter of serum, not serum water, is artificially reduced (pseudohyponatremia). The presence of normal serum sodium levels in a patient with hyperlipidemia should also raise the suspicion that hypernatremia may be present (pseudonormonatremia). The opposite phenomenon of pseudohypernatremia and pseudonormonatremia may also occur as a result of severe hypoproteinemia, not infrequently observed in diabetics with nephrotic or malabsorption syndromes. In lipemic or hypoproteinemic samples the direct ion-selective electrodes (ISE) method for the measurement of serum sodium should be used, since the indirect ISE is prone to spurious dysnatremias<sup>[22]</sup>.

It is known that rapid correction of serum sodium may be followed by development of central demyelinating lesions, particularly in the pons (a disorder called central pontinemyelinolysis or osmotic demyelination) with major disability or even fatal outcome<sup>[2]</sup>. Diabetics may have an increased risk for the osmotic demyelination syndrome (ODS) during correction of hyponatremia since risk factors for this disorder (thiazide diuretics, malnutrition, hypokalemia, and hypoxia)<sup>[23]</sup> are not infrequently present in such patients. Hypokalemia is also associated with a poor outcome in patients who develop the syndrome<sup>[24]</sup>.

It should be emphasized that ODS is mainly observed during overly rapid correction of chronic hyponatremia. However, in diabetic patients hypernatremia and hypokalemia (in the absence of hyponatremia or hyperosmolality) are rarely associated with ODS. The mechanism by which these electrolyte disorders may cause ODS in the diabetic state is not yet known<sup>[25,26]</sup>.

It has been suggested that in cases of nonketotic hyperglycemic hyperosmolar syndrome (HHS) altered mental status is predicted best by  $[\text{Na}^+]$ ; serum glucose concentration alone is considered a poor indicator. In fact, there is evidence that hyperglycemic patients with hypertonicity are symptomatic only if hypernatremia is present<sup>[5,27]</sup>. On the contrary, neurological symptoms may be absent in the context of severe gradually developing hyperglycemia<sup>[27,28]</sup>. This could be attributed to the capacity of the brain tissue to restore intracellular water by accumulating electrolytes and the so-called idiogenic osmoles. Furthermore, the brain cells are relatively permeable to glucose even in the absence of insulin<sup>[28,29]</sup>. Therefore, hyperglycemia by itself does not create severe hypertonicity in central nervous system (CNS)<sup>[28]</sup>. On the other hand, hypernatremia induces severe cellular dehydration in CNS cells. This state is associated with a rather slow compensatory accumulation of brain osmolar content<sup>[28]</sup>.

The development of hypernatremia is associated with endocrine dysfunction. There is some evidence in

animals and man that hypernatremia and hyperosmolality are associated with impairment of both insulin-mediated glucose metabolism and glucagon-dependent glucose release<sup>[30-33]</sup>. Thus, hypernatremia and hyperosmolality should be considered as contributing factors to the occurrence of hyperglycemia in critically ill patients<sup>[34]</sup>. Moreover, hypernatremia is implicated in the profound inhibition of gonadotrophin release in postmenopausal diabetic women with HHS. Although the underlying mechanisms remain unknown, it appears that hypernatremia induces a decrease in gonadotrophin-releasing hormone expression in GT1-7 neurons<sup>[35]</sup>.

Rhabdomyolysis, though uncommon, has been described in the diabetic state<sup>[36]</sup>. It appears that high serum sodium and glucose levels represent the most important determinants for the occurrence of this complication<sup>[37]</sup>.

## HYPOKALEMIA

The causes of hypokalemia in diabetics include: (1) redistribution of potassium [ $K^+$ ] from the extracellular to the intracellular fluid compartment (shift hypokalemia due to insulin administration); (2) gastrointestinal loss of  $K^+$  due to malabsorption syndromes (diabetic-induced motility disorders, bacterial overgrowth, chronic diarrheal states); and (3) renal loss of  $K^+$  (due to osmotic diuresis and/or coexistent hypomagnesemia). Hypomagnesemia can cause hypokalemia possibly because a low intracellular magnesium [ $Mg^{2+}$ ] concentration activates the renal outer medullary  $K^+$  channel to secrete more  $K^+$ <sup>[38]</sup>.

Exogenous insulin can induce mild hypokalemia because it promotes the entry of  $K^+$  into skeletal muscles and hepatic cells by increasing the activity of the  $Na^+-K^+-ATPase$  pump<sup>[39]</sup>. The increased secretion of epinephrine due to insulin-induced hypoglycemia may also play a contributory role<sup>[40]</sup>. The major setting in which insulin administration leads to hypokalemia is during the treatment of severe hyperglycemia. The majority of patients with diabetic ketoacidosis (DKA) and HHS are markedly  $K^+$ -depleted. The average  $K^+$  deficit is 3-5 mEq/kg, but it can exceed 10 mEq/kg in some cases<sup>[41,42]</sup>. A number of factors contribute to the DKA- and HHS-associated potassium depletion, including vomiting, increased renal losses due to the osmotic diuresis and ketoacid anion excretion, and the loss of  $K^+$  from the cells due to glycogenolysis and proteolysis<sup>[41,43]</sup>. On admission, however, the serum  $K^+$  levels are usually normal, or, in about one-third of patients, increased despite the  $K^+$  depletion<sup>[41,43]</sup>. It is thought that hyperosmolality and insulin deficiency are primarily responsible for the relative rise in the serum potassium concentration in this setting. As mentioned, hyperglycemia increases serum osmolality resulting in movement of water out of cells. The loss of intracellular water leads to an increased intracellular  $K^+$  concentration, favoring a gradient for  $K^+$  to move out of the cells. Simultaneously, the friction forces between solvent (water) and solute can result in  $K^+$  being carried along with water through the water pores in the cell membrane<sup>[43]</sup>.

In contrast, acidemia probably does not play a major role given that organic acids are much less likely to influence the internal  $K^+$  distribution<sup>[44]</sup>. Insulin therapy lowers  $K^+$  concentration driving  $K^+$  into cells (both directly and indirectly by reversing hyperglycemia). Therefore, insulin therapy may cause severe hypokalemia, particularly in patients with a normal or low serum  $K^+$  concentration at presentation. Insulin administration in patients with massive  $K^+$  deficits who are hypokalemic prior to therapy should be delayed until the serum  $K^+$  is above 3.3 mEq/L to avoid possible arrhythmias, cardiac arrest and respiratory muscle weakness<sup>[42,45,46]</sup>. It is obvious that the risk of hypokalemia-related complications is particularly higher in diabetic subjects who have hypertension, myocardial infarction/ischemia, or heart failure as comorbidities. In addition, since diabetics are frequently on diuretics, diuretic-associated hypokalemia (as well as hypomagnesemia and hypophosphatemia) should be taken into account in this setting.

Hypokalemia is associated with impaired insulin secretion and decreased peripheral glucose utilization resulting in carbohydrate intolerance and hyperglycemia<sup>[47]</sup>. This is particularly problematic in diabetic patients causing a vicious circle where low serum  $K^+$  levels lead to poorly controlled DM and vice versa.

## HYPERKALEMIA

The incidence of hyperkalemia is higher in diabetic patients than in the general population<sup>[48,49]</sup>. Redistribution of potassium from the intracellular to the extracellular compartment (shift hyperkalemia) can induce hyperkalemia with no net total body  $K^+$  increase. Examples of shift hyperkalemia in DM include acidosis (for each 0.1 fall in pH, potassium increases by approximately 0.4 mmol/L), insulin deficiency, hypertonicity, cell lysis (rhabdomyolysis), and drugs (*e.g.*, beta blockers). Reduced glomerular filtration of  $K^+$  (due to acute kidney injury and chronic kidney disease) and many drugs that interfere with  $K^+$  excretion are associated with hyperkalemia. These include angiotensin-converting enzyme inhibitors, angiotensin II receptor blockers, renin inhibitors, beta blockers and potassium-sparing diuretics. Of note, the typical healthy diabetic diet is often rich in  $K^+$  and low in sodium contributing to the occurrence of hyperkalemia in susceptible individuals<sup>[48,49]</sup>. Nevertheless, the most common causal factor of chronic hyperkalemia in diabetics is the reduced tubular secretion of  $K^+$  due to the syndrome of hyporeninemic hypoaldosteronism<sup>[50]</sup>. This syndrome is characterized by mild to moderate renal insufficiency and patients typically present with asymptomatic hyperkalemia. The development of overt hyperkalemia is most common in patients with other risk factors that further impair the efficiency of potassium excretion, such as renal insufficiency, volume depletion, or the use of medications that interfere with potassium handling (see above).

Of note, dapagliflozin (a SGLT2 inhibitor) may be protective from the development of hyperkalemia in



patients with moderate renal impairment due to osmotic diuresis<sup>[17]</sup>. However, the administration of SGLT2 inhibitors in hypovolemic patients may cause elevated serum creatinine levels and decreases in glomerular filtration rate due to deterioration of intravascular volume contraction. Indeed, worsening renal function and hyperkalemia may occur in patients on canagliflozin, particularly those predisposed to hyperkalemia due to impaired renal function, medications or other medical conditions<sup>[51]</sup>. Hyporeninemic hypoaldosteronism is more frequently observed in diabetic and elderly patients as well as in those with chronic renal impairment. Diabetic nephropathy accounts for 43%-63% of cases comprising the most common cause of hyporeninemic hypoaldosteronism<sup>[33,50,52]</sup>. Normal ageing, especially after the sixth decade, is associated with a decline in renin production. Moreover, elderly patients may have decreased renal function even without significant elevations in serum creatinine levels [ $< 1.2$  mg/dL ( $106 \mu\text{mol/L}$ )]. Consequently, diabetics (especially the elderly) on medications known to interfere with  $\text{K}^+$  homeostasis are at increased risk for hyperkalemia<sup>[33,53]</sup>. In such cases, close  $\text{K}^+$  monitoring is fully warranted<sup>[54]</sup>. Clinicians must also be alert that hyperkalemia in patients with type 1 DM may be due to concurrent adrenal insufficiency in the setting of autoimmune polyglandular syndrome<sup>[55]</sup>.

## HYPOMAGNESEMIA

Hypomagnesemia is a frequent electrolyte disorder in diabetic patients<sup>[56]</sup>. Recently, DM was identified as an independent risk factor for hypomagnesemia in community subjects aged 55 years or more (OR = 3.32; 95%CI: 2.00-5.50)<sup>[3]</sup>. In a recent prospective study in hypomagnesemic patients (either on admission or during hospitalization in an internal medicine clinic) DM was evident in a considerable proportion (40%), mainly as a contributing factor. Osmotic diuresis accompanied by inappropriate magnesuria was the prominent underlying mechanism of hypomagnesemia in these diabetic patients<sup>[57]</sup>. Except for glucosuria, several other possible explanations for hypomagnesemia in DM have been reported. These include poor dietary intake, glomerular hyperfiltration, altered insulin metabolism, diuretic administration and recurrent metabolic acidosis<sup>[56]</sup>. Increased gastrointestinal  $\text{Mg}^{2+}$  losses due to diarrhea as a result of diabetic autonomic neuropathy can also cause low serum  $\text{Mg}^{2+}$  levels. Of note, a case of symptomatic hypomagnesemia [serum  $\text{Mg}^{2+}$  concentration 0.66 mEq/L ( $0.33 \text{ mmol/L}$ ), reference range 1.42-1.84 mEq/L ( $0.71\text{-}0.94 \text{ mmol/L}$ )] was attributed to metformin-induced diarrhea<sup>[58]</sup>. Furthermore, insulin promotes net shift of  $\text{Mg}^{2+}$  from extracellular to intracellular space and can contribute to hypomagnesemia<sup>[59,60]</sup>. The increased secretion of epinephrine due to insulin-induced hypoglycemia may also play a role. The risk of hypomagnesemia related to insulin therapy is increased in poorly controlled diabetic patients given that hyperglycemia induces increased renal  $\text{Mg}^{2+}$  loss *via* os-

motric diuresis. Hypokalemia, hypophosphatemia as well as acidosis-related urinary  $\text{Mg}^{2+}$  losses contribute to the high incidence of hypomagnesemia in the setting of diabetic ketoacidosis<sup>[61,62]</sup>. It should be noted that hypoalbuminemia is associated with spurious hypomagnesemia. In hypoalbuminemic states (serum albumin  $< 4 \text{ g/dL}$ ) the corrected serum  $\text{Mg}^{2+}$  should be calculated using the formula: corrected  $\text{Mg}^{2+}$  (mEq/L) = measured  $\text{Mg}^{2+}$  (mEq/L) +  $0.01 \times (40 - \text{albumin in g/L})$ <sup>[63]</sup>.

$\text{Mg}^{2+}$  is essential for life being involved in numerous enzymatic reactions, including ATP use, cell membrane, ion channels and mitochondrial function, as well as protein synthesis. The most clinically significant consequences of hypomagnesemia are ascribed to alterations in the function of excitable membranes in nerve, muscle, and the cardiac conducting system. Moreover, low serum  $\text{Mg}^{2+}$  levels can secondarily induce hypokalemia, hypocalcemia, and hypophosphatemia, potentially causing further derangements in neuromuscular and cardiovascular physiology. Hypomagnesemia has been implicated in various long-term complications of DM, such as hypertension, increased carotid wall thickness, coronary artery disease, dyslipidemia, diabetic retinopathy, neuropathy, ischemic stroke, and foot ulcerations<sup>[56]</sup>. Hypomagnesemia has also been linked to diabetic nephropathy (from microalbuminuria to advanced renal disease)<sup>[64-66]</sup>. It has been proposed that hypomagnesemia is a predictor of end-stage renal disease in patients with diabetic nephropathy<sup>[66]</sup>. In addition, magnesium deficit is associated with carbohydrate intolerance and insulin resistance, thus inducing or worsening existing DM<sup>[67,68]</sup>. On the contrary, increased dietary  $\text{Mg}^{2+}$  intake has been associated with a reduced risk of type 2 DM<sup>[69]</sup>.

## HYPOCALCEMIA

Patients with DM have an increased risk for development of acute renal failure due to volume depletion, sepsis, rhabdomyolysis and drugs (*e.g.*, radiographic contrast media). In this setting severe hyperphosphatemia may occur when phosphorus cannot be excreted by the malfunctioning kidney either with or without increased cell catabolism, thus resulting in hypocalcemia. Advanced chronic renal insufficiency may be associated with hypocalcemia due to accompanying hyperphosphatemia and low levels of vitamin D. Patients with nephrotic syndrome may exhibit hypocalcemia, even if the glomerular filtration rate is well preserved. This is attributed to the loss of 25-hydroxyvitamin  $\text{D}_3$  and its binding protein in the urine. Hypomagnesemia is another potential cause of hypocalcemia in diabetics.  $\text{Mg}^{2+}$  depletion leads to hypocalcemia mainly because of impaired release of parathyroid hormone (PTH) or skeletal and renal tubule resistance to the action of PTH<sup>[1]</sup>. Vitamin D deficiency and furosemide administration may also play a role in the occurrence of hypocalcemia<sup>[70]</sup>. There is evidence that diabetic patients are relatively hypoparathyroid<sup>[71]</sup>. In fact, a mild shift downwards in the set-point for PTH secretion in patients

with insulin-dependent DM as well as a diminished parathyroid gland responsiveness to hypocalcemia in uremic diabetic patients have been reported<sup>[72,73]</sup>.

Hypoalbuminemia is associated with pseudohypocalcemia defined as a reduction of total serum calcium concentration in the presence of normal ionized serum calcium levels. In hypoalbuminemic states, one of the commonly used formulas to correct total calcium levels is by adding 0.8 mg/dL (0.2 mmol/L) to measured calcium values for every 1 g/dL decrease in serum albumin from normal value (assumed to be 4 g/dL). Given that the accuracy of this method is poor (particularly among critically ill and geriatric patients), the biologically active ionized calcium concentration should be measured when possible<sup>[1,74]</sup>.

## HYPERCALCEMIA

The incidence of DM in primary hyperparathyroidism and that of primary hyperparathyroidism in DM is approximately 8% and 1%, respectively. Both values are about three-fold higher than that anticipated in the general population<sup>[75]</sup>. Hyperparathyroidism is related to long-term insulin resistance and relative insulin insufficiency, leading to overt DM or deterioration of glycemic control of established DM<sup>[75,76]</sup>. It is thought that an elevated intracellular free calcium concentration (by decreasing normal insulin-stimulated glucose transport) increases the requirement for insulin, resulting in hyperparathyroidism-mediated insulin resistance<sup>[75]</sup>. Diabetic patients should be evaluated for hypercalcemia given that untreated hyperparathyroidism is linked to hypertension<sup>[75,77]</sup>. The detection of high serum calcium levels in a patient with type 1 DM should raise the suspicion that autoimmune hyperparathyroidism associated with anti-calcium-sensing receptor autoantibodies may be present<sup>[78]</sup>. Recently, a case of severe hypercalcemia [15 mg/dL (3.75 mmol/L)] in DKA was reported<sup>[79]</sup>. Dehydration might represent the most important causative factor for the occurrence of hypercalcemia in this case. A decreased bone formation due to metabolic acidosis and an increased bone mineral dissolution and resorption due to severe insulin deficiency and metabolic acidosis may also play a role<sup>[80]</sup>. Hyperglycemia-mediated inhibition of bone mineralization, insulin growth factor-1 deficiency, hypophosphatemia and immobilization are also included among the potential contributory factors of hypercalcemia in DKA<sup>[79,81,82]</sup>. Also, diabetic patients on thiazide diuretics are more prone to exhibit hypercalcemia.

## HYPOPHOSPHATEMIA

Diabetic patients have underlying conditions that predispose to the development of hypophosphatemia. These include primary hyperthyroidism, vitamin D deficiency, malabsorption, and the use of diuretics (thiazides and furosemide)<sup>[83]</sup>. It is known that increased insulin levels promote the transport of both glucose and phosphate into the skeletal muscle and liver cells. However, in nor-

mal subjects the administration of insulin leads only to a slight decrement of serum phosphate levels. The risk of severe hypophosphatemia is increased in cases of underlying phosphate depletion<sup>[62,84]</sup>. Decompensated DM with ketoacidosis associated with excessive phosphate loss due to osmotic diuresis. Despite phosphate depletion, the serum phosphate concentration at presentation is usually normal or even high because both insulin deficiency and metabolic acidosis cause a shift of phosphate out of cells<sup>[85]</sup>. Administration of insulin and fluids, and correction of ketoacidosis may reveal phosphate deficiency and cause a sharp decrease in plasma phosphate concentration due to intracellular shift<sup>[83]</sup>.

In a study of 69 patient with DKA, the incidence of hyperphosphatemia was 94.7% at presentation. The mean serum phosphate concentration fell from 9.2 mg/dL (3 mmol/L) to 2.8 mg/dL (0.9 mmol/L) 12 h after initiating treatment, while some patients exhibited values as low as 1.0 mg/dL (0.32 mmol/L)<sup>[85]</sup>.

The routine administration of phosphate during treatment of DKA and HHS is not recommended since randomized trials failed to show any clinical benefit from phosphate administration<sup>[42,83,86,87]</sup>. What is more, correction of hypophosphatemia may have adverse effects, such as hypocalcemia and hypomagnesemia<sup>[42,83,88]</sup>. Careful phosphate replacement is required in patients with severe hypophosphatemia of less than 1.0 mg/dL (0.32 mmol/L) and in patients who develop cardiac dysfunction, hemolytic anemia, or respiratory depression<sup>[42,89,90]</sup>.

## CONCLUSION

Electrolyte abnormalities are common in diabetic patients and may be associated with increased morbidity and mortality. These disturbances are particularly common in decompensated DM, in the elderly as well as in the presence of renal impairment. Patients with DM may receive complex drug regimens some of which may be associated with electrolyte disorders. Discontinuation of these medications, when possible, as well as strict control of glycemia are of paramount importance to prevent electrolyte abnormalities in diabetic patients. The successful management of these disorders can best be accomplished by elucidating the underlying pathophysiologic mechanisms.

## REFERENCES

- 1 Liamis G, Milionis HJ, Elisaf M. A review of drug-induced hypocalcemia. *J Bone Miner Metab* 2009; **27**: 635-642 [PMID: 19730969 DOI: 10.1007/s00774-009-0119-x]
- 2 Liamis G, Kalogirou M, Saugos V, Elisaf M. Therapeutic approach in patients with dysnatraemias. *Nephrol Dial Transplant* 2006; **21**: 1564-1569 [PMID: 16449285 DOI: 10.1093/ndt/gfk090]
- 3 Liamis G, Rodenburg EM, Hofman A, Zietse R, Stricker BH, Hoorn EJ. Electrolyte disorders in community subjects: prevalence and risk factors. *Am J Med* 2013; **126**: 256-263 [PMID: 23332973 DOI: 10.1016/j.amjmed.2012.06.037]
- 4 Elisaf MS, Tsatsoulis AA, Katopodis KP, Siamopoulos KC. Acid-base and electrolyte disturbances in patients with diabetic ketoacidosis. *Diabetes Res Clin Pract* 1996; **34**: 23-27

- [PMID: 8968687]
- 5 **Liamis G**, Tsimihodimos V, Doumas M, Spyrou A, Bairaktari E, Elisaf M. Clinical and laboratory characteristics of hypernatraemia in an internal medicine clinic. *Nephrol Dial Transplant* 2008; **23**: 136-143 [PMID: 17932111 DOI: 10.1093/ndt/gfm376]
  - 6 **Hillier TA**, Abbott RD, Barrett EJ. Hyponatremia: evaluating the correction factor for hyperglycemia. *Am J Med* 1999; **106**: 399-403 [PMID: 10225241]
  - 7 **Liamis G**, Milionis HJ, Elisaf M. Hyponatremia in patients with infectious diseases. *J Infect* 2011; **63**: 327-335 [PMID: 21835196 DOI: 10.1016/j.jinf.2011.07.013]
  - 8 **Liamis G**, Gianoutsos C, Elisaf MS. Hyperosmolar nonketotic syndrome with hyponatremia: how can we monitor treatment? *Diabetes Metab* 2000; **26**: 403-405 [PMID: 11119020]
  - 9 **Chiasson JL**, Aris-Jilwan N, Bélanger R, Bertrand S, Beauregard H, Ekoé JM, Fournier H, Havrankova J. Diagnosis and treatment of diabetic ketoacidosis and the hyperglycemic hyperosmolar state. *CMAJ* 2003; **168**: 859-866 [PMID: 12668546]
  - 10 **Liamis G**, Milionis H, Elisaf M. A review of drug-induced hyponatremia. *Am J Kidney Dis* 2008; **52**: 144-153 [PMID: 18468754 DOI: 10.1053/j.ajkd.2008.03.004]
  - 11 **Beukhof CM**, Hoorn EJ, Lindemans J, Zietse R. Novel risk factors for hospital-acquired hyponatraemia: a matched case-control study. *Clin Endocrinol (Oxf)* 2007; **66**: 367-372 [PMID: 17302870 DOI: 10.1111/j.1365-2265.2007.02741.x]
  - 12 **Kadowaki T**, Hagura R, Kajinuma H, Kuzuya N, Yoshida S. Chlorpropamide-induced hyponatremia: incidence and risk factors. *Diabetes Care* 1983; **6**: 468-471 [PMID: 6443808]
  - 13 **Moses AM**, Howanitz J, Miller M. Diuretic action of three sulfonylurea drugs. *Ann Intern Med* 1973; **78**: 541-544 [PMID: 4632790]
  - 14 **Berker D**, Aydin Y, Arduç A, Ustün I, Ergün B, Guler S. Severe hyponatremia due to rosiglitazone use in an elderly woman with diabetes mellitus: a rare cause of syndrome of inappropriate antidiuretic hormone secretion. *Endocr Pract* 2008; **14**: 1017-1019 [PMID: 19095602 DOI: 10.4158/EP.14.8.1017]
  - 15 **Filippatos TD**, Elisaf MS. Effects of glucagon-like peptide-1 receptor agonists on renal function. *World J Diabetes* 2013; **4**: 190-201 [PMID: 24147203 DOI: 10.4239/wjd.v4.i5.190]
  - 16 **Shah NK**, Deeb WE, Choksi R, Epstein BJ. Dapagliflozin: a novel sodium-glucose cotransporter type 2 inhibitor for the treatment of type 2 diabetes mellitus. *Pharmacotherapy* 2012; **32**: 80-94 [PMID: 22392830 DOI: 10.1002/PHAR.1010]
  - 17 **Kohan DE**, Fioretto P, Tang W, List JF. Long-term study of patients with type 2 diabetes and moderate renal impairment shows that dapagliflozin reduces weight and blood pressure but does not improve glycemic control. *Kidney Int* 2014; **85**: 962-971 [PMID: 24067431 DOI: 10.1038/ki.2013.356]
  - 18 **Bankir L**, Bardoux P, Ahloulay M. Vasopressin and diabetes mellitus. *Nephron* 2001; **87**: 8-18 [PMID: 11174021]
  - 19 **Bustamante M**, Hasler U, Kotova O, Chibalin AV, Mordasini D, Rousselot M, Vandewalle A, Martin PY, Féraille E. Insulin potentiates AVP-induced AQP2 expression in cultured renal collecting duct principal cells. *Am J Physiol Renal Physiol* 2005; **288**: F334-F344 [PMID: 15494547 DOI: 10.1152/ajprenal.00180.2004]
  - 20 **Davis FB**, Davis PJ. Water metabolism in diabetes mellitus. *Am J Med* 1981; **70**: 210-214 [PMID: 7457488]
  - 21 **Fraser CL**, Arief AI. Fatal central diabetes mellitus and insipidus resulting from untreated hyponatremia: a new syndrome. *Ann Intern Med* 1990; **112**: 113-119 [PMID: 2294815]
  - 22 **Liamis G**, Liberopoulos E, Barkas F, Elisaf M. Spurious electrolyte disorders: a diagnostic challenge for clinicians. *Am J Nephrol* 2013; **38**: 50-57 [PMID: 23817179 DOI: 10.1159/000351804]
  - 23 **Lauriat SM**, Berl T. The hyponatremic patient: practical focus on therapy. *J Am Soc Nephrol* 1997; **8**: 1599-1607 [PMID: 9335390]
  - 24 **Kallakatta RN**, Radhakrishnan A, Fayaz RK, Unnikrishnan JP, Kesavadas C, Sarma SP. Clinical and functional outcome and factors predicting prognosis in osmotic demyelination syndrome (central pontine and/or extrapontine myelinolysis) in 25 patients. *J Neurol Neurosurg Psychiatry* 2011; **82**: 326-331 [PMID: 20826870 DOI: 10.1136/jnnp.2009.201764]
  - 25 **Hegazi MO**, Mashankar A. Central pontine myelinolysis in the hyperosmolar hyperglycaemic state. *Med Princ Pract* 2013; **22**: 96-99 [PMID: 22922267 DOI: 10.1159/000341718]
  - 26 **Shintani M**, Yamashita M, Nakano A, Aotani D, Maeda K, Yamamoto T, Nishimura H. Central pontine and extrapontine myelinolysis associated with type 2 diabetic patient with hypokalemia. *Diabetes Res Clin Pract* 2005; **68**: 75-80 [PMID: 15811568 DOI: 10.1016/j.diabres.2004.08.005]
  - 27 **Popli S**, Leehey DJ, Dargatzas JT, Bansal VK, Ho DS, Hano JE, Ing TS. Asymptomatic, nonketotic, severe hyperglycemia with hyponatremia. *Arch Intern Med* 1990; **150**: 1962-1964 [PMID: 2393329]
  - 28 **Milionis HJ**, Liamis G, Elisaf MS. Appropriate treatment of hypernatraemia in diabetic hyperglycaemic hyperosmolar syndrome. *J Intern Med* 2001; **249**: 273-276 [PMID: 11285047]
  - 29 **Lund-Andersen H**. Transport of glucose from blood to brain. *Physiol Rev* 1979; **59**: 305-352 [PMID: 375257]
  - 30 **Komjati M**, Kastner G, Waldhäusl W, Bratusch-Marrain P. Detrimental effect of hyperosmolality on insulin-stimulated glucose metabolism in adipose and muscle tissue in vitro. *Biochem Med Metab Biol* 1988; **39**: 312-318 [PMID: 3293636]
  - 31 **Komjati M**, Kastner G, Waldhäusl W, Bratusch-Marrain P. Effect of hyperosmolality on basal and hormone-stimulated hepatic glucose metabolism in vitro. *Eur J Clin Invest* 1989; **19**: 128-134 [PMID: 2499470]
  - 32 **Bratusch-Marrain PR**, DeFronzo RA. Impairment of insulin-mediated glucose metabolism by hyperosmolality in man. *Diabetes* 1983; **32**: 1028-1034 [PMID: 6416909]
  - 33 **Liamis G**, Milionis H, Elisaf M. Blood pressure drug therapy and electrolyte disturbances. *Int J Clin Pract* 2008; **62**: 1572-1580 [PMID: 18822027 DOI: 10.1111/j.1742-1241.2008.01860.x]
  - 34 **Lindner G**, Funk GC. Hyponatremia in critically ill patients. *J Crit Care* 2013; **28**: 216.e11-216.e20 [PMID: 22762930 DOI: 10.1016/j.jcrc.2012.05.001]
  - 35 **Lado-Abeal J**, Lorenzo-Solar M, Lago-Lestón R, Palos-Paz F, Dominguez-Gerpe L. Hyperglycaemic hyperosmolar nonketotic state as a cause of low gonadotrophin levels in postmenopausal diabetic women: a role for severe hypernatraemia. *J Neuroendocrinol* 2007; **19**: 983-987 [PMID: 18001328 DOI: 10.1111/j.1365-2826.2007.01614.x]
  - 36 **Lord GM**, Scott J, Pusey CD, Rees AJ, Walport MJ, Davies KA, Bulpitt C, Bloom SR, Muntoni FM. Diabetes and rhabdomyolysis. A rare complication of a common disease. *BMJ* 1993; **307**: 1126-1128 [PMID: 8251814]
  - 37 **Singhal PC**, Abramovici M, Ayer S, Desroches L. Determinants of rhabdomyolysis in the diabetic state. *Am J Nephrol* 1991; **11**: 447-450 [PMID: 1819210]
  - 38 **Yang L**, Frindt G, Palmer LG. Magnesium modulates ROMK channel-mediated potassium secretion. *J Am Soc Nephrol* 2010; **21**: 2109-2116 [PMID: 21030597 DOI: 10.1681/ASN.2010060617]
  - 39 **Minaker KL**, Rowe JW. Potassium homeostasis during hyperinsulinemia: effect of insulin level, beta-blockade, and age. *Am J Physiol* 1982; **242**: E373-E377 [PMID: 6124125]
  - 40 **Petersen KG**, Schlüter KJ, Kerp L. Regulation of serum potassium during insulin-induced hypoglycemia. *Diabetes* 1982; **31**: 615-617 [PMID: 6761199]
  - 41 **Kreisberg RA**. Diabetic ketoacidosis: new concepts and trends in pathogenesis and treatment. *Ann Intern Med* 1978; **88**: 681-695 [PMID: 417652]
  - 42 **Kitabchi AE**, Umpierrez GE, Murphy MB, Kreisberg RA. Hyperglycemic crises in adult patients with diabetes: a consensus statement from the American Diabetes Association. *Diabetes Care* 2006; **29**: 2739-2748 [PMID: 17130218 DOI: 10.2337/dc06-9916]
  - 43 **Adrogué HJ**, Lederer ED, Suki WN, Eknoyan G. Determinants of plasma potassium levels in diabetic ketoacidosis.



- Medicine* (Baltimore) 1986; **65**: 163-172 [PMID: 3084904]
- 44 **Adrogué HJ**, Madias NE. Changes in plasma potassium concentration during acute acid-base disturbances. *Am J Med* 1981; **71**: 456-467 [PMID: 7025622]
  - 45 **Kitabchi AE**, Umpierrez GE, Miles JM, Fisher JN. Hyperglycemic crises in adult patients with diabetes. *Diabetes Care* 2009; **32**: 1335-1343 [PMID: 19564476 DOI: 10.2337/dc09-9032]
  - 46 **Beigelman PM**. Potassium in severe diabetic ketoacidosis. *Am J Med* 1973; **54**: 419-420 [PMID: 4633105]
  - 47 **Wilcox CS**. Metabolic and adverse effects of diuretics. *Semin Nephrol* 1999; **19**: 557-568 [PMID: 10598543]
  - 48 **Palmer BF**. Managing hyperkalemia caused by inhibitors of the renin-angiotensin-aldosterone system. *N Engl J Med* 2004; **351**: 585-592 [PMID: 15295051 DOI: 10.1056/NEJMra035279]
  - 49 **Uribarri J**, Oh MS, Carroll HJ. Hyperkalemia in diabetes mellitus. *J Diabet Complications* 1990; **4**: 3-7 [PMID: 2141843]
  - 50 **DeFronzo RA**. Hyperkalemia and hyporeninemic hypoaldosteronism. *Kidney Int* 1980; **17**: 118-134 [PMID: 6990088]
  - 51 **Cada DJ**, Ingram KT, Levien TL, Baker DE. Canagliflozin. *Hosp Pharm* 2013; **48**: 855-867 [PMID: 24421439 DOI: 10.1310/hpj4810-855]
  - 52 **Arruda JA**, Batlle DC, Sehly JT, Roseman MK, Baronowski RL, Kurtzman NA. Hyperkalemia and renal insufficiency: role of selective aldosterone deficiency and tubular unresponsiveness to aldosterone. *Am J Nephrol* 1981; **1**: 160-167 [PMID: 6758577]
  - 53 **Oxlund CS**, Henriksen JE, Tarnow L, Schousboe K, Gram J, Jacobsen IA. Low dose spironolactone reduces blood pressure in patients with resistant hypertension and type 2 diabetes mellitus: a double blind randomized clinical trial. *J Hypertens* 2013; **31**: 2094-2102 [PMID: 24107738 DOI: 10.1097/HJH.0b013e3283638b1a]
  - 54 **Raebel MA**, Ross C, Xu S, Roblin DW, Cheetham C, Blanchette CM, Saylor G, Smith DH. Diabetes and drug-associated hyperkalemia: effect of potassium monitoring. *J Gen Intern Med* 2010; **25**: 326-333 [PMID: 20087674 DOI: 10.1007/s11606-009-1228-x]
  - 55 **Van den Driessche A**, Eenkhoorn V, Van Gaal L, De Block C. Type 1 diabetes and autoimmune polyglandular syndrome: a clinical review. *Neth J Med* 2009; **67**: 376-387 [PMID: 20009114]
  - 56 **Pham PC**, Pham PM, Pham SV, Miller JM, Pham PT. Hypomagnesemia in patients with type 2 diabetes. *Clin J Am Soc Nephrol* 2007; **2**: 366-373 [PMID: 17699436 DOI: 10.2215/CJN.02960906]
  - 57 **Liamis G**, Liberopoulos E, Alexandridis G, Elisaf M. Hypomagnesemia in a department of internal medicine. *Magn Res* 2012; **25**: 149-158 [PMID: 23261516 DOI: 10.1684/mrh.2012.0325]
  - 58 **Svare A**. A patient presenting with symptomatic hypomagnesemia caused by metformin-induced diarrhoea: a case report. *Cases J* 2009; **2**: 156 [PMID: 19946527 DOI: 10.1186/1757-1626-2-156]
  - 59 **Paolisso G**, Sgambato S, Passariello N, Giugliano D, Scheen A, D'Onofrio F, Lefèbvre PJ. Insulin induces opposite changes in plasma and erythrocyte magnesium concentrations in normal man. *Diabetologia* 1986; **29**: 644-647 [PMID: 3539681]
  - 60 **Matsumura M**, Nakashima A, Tofuku Y. Electrolyte disorders following massive insulin overdose in a patient with type 2 diabetes. *Intern Med* 2000; **39**: 55-57 [PMID: 10674850]
  - 61 **Bauza J**, Ortiz J, Dahan M, Justiniano M, Saenz R, Vélez M. Reliability of serum magnesium values during diabetic ketoacidosis in children. *Bol Asoc Med P R* 1998; **90**: 108-112 [PMID: 10224681]
  - 62 **Liamis G**, Milonis HJ, Elisaf M. Medication-induced hypophosphatemia: a review. *QJM* 2010; **103**: 449-459 [PMID: 20356849 DOI: 10.1093/qjmed/hcq039]
  - 63 **Kroll MH**, Elin RJ. Relationships between magnesium and protein concentrations in serum. *Clin Chem* 1985; **31**: 244-246 [PMID: 3967355]
  - 64 **Corsonello A**, Ientile R, Buemi M, Cucinotta D, Mauro VN, Macaione S, Corica F. Serum ionized magnesium levels in type 2 diabetic patients with microalbuminuria or clinical proteinuria. *Am J Nephrol* 2000; **20**: 187-192 [PMID: 10878399 DOI: 10.1159/000013582]
  - 65 **Pham PC**, Pham PM, Pham PA, Pham SV, Pham HV, Miller JM, Yanagawa N, Pham PT. Lower serum magnesium levels are associated with more rapid decline of renal function in patients with diabetes mellitus type 2. *Clin Nephrol* 2005; **63**: 429-436 [PMID: 15960144]
  - 66 **Sakaguchi Y**, Shoji T, Hayashi T, Suzuki A, Shimizu M, Mitsumoto K, Kawabata H, Niihata K, Okada N, Isaka Y, Rakugi H, Tsubakihara Y. Hypomagnesemia in type 2 diabetic nephropathy: a novel predictor of end-stage renal disease. *Diabetes Care* 2012; **35**: 1591-1597 [PMID: 22498805 DOI: 10.2337/dc12-0226]
  - 67 **Weisinger JR**, Bellorín-Font E. Magnesium and phosphorus. *Lancet* 1998; **352**: 391-396 [PMID: 9717944 DOI: 10.1016/S0140-6736(97)10535-9]
  - 68 **Barbagallo M**, Dominguez LJ. Magnesium metabolism in type 2 diabetes mellitus, metabolic syndrome and insulin resistance. *Arch Biochem Biophys* 2007; **458**: 40-47 [PMID: 16808892 DOI: 10.1016/j.abb.2006.05.007]
  - 69 **Dong JY**, Xun P, He K, Qin LQ. Magnesium intake and risk of type 2 diabetes: meta-analysis of prospective cohort studies. *Diabetes Care* 2011; **34**: 2116-2122 [PMID: 21868780 DOI: 10.2337/dc11-0518]
  - 70 **Takiishi T**, Gysemans C, Bouillon R, Mathieu C. Vitamin D and diabetes. *Endocrinol Metab Clin North Am* 2010; **39**: 419-446, table of contents [PMID: 20511061 DOI: 10.1016/j.ecl.2010.02.013]
  - 71 **McNair P**, Christensen MS, Madsbad S, Christiansen C, Transbøl I. Hypoparathyroidism in diabetes mellitus. *Acta Endocrinol (Copenh)* 1981; **96**: 81-86 [PMID: 7456985]
  - 72 **Schwarz P**, Sørensen HA, Mømsen G, Friis T, Transbøl I, McNair P. Hypocalcemia and parathyroid hormone responsiveness in diabetes mellitus: a tri-sodium-citrate clamp study. *Acta Endocrinol (Copenh)* 1992; **126**: 260-263 [PMID: 1574956]
  - 73 **Heidbreder E**, Götz R, Schafferhans K, Heidland A. Diminished parathyroid gland responsiveness to hypocalcemia in diabetic patients with uremia. *Nephron* 1986; **42**: 285-289 [PMID: 3960240]
  - 74 **Byrnes MC**, Huynh K, Helmer SD, Stevens C, Dort JM, Smith RS. A comparison of corrected serum calcium levels to ionized calcium levels among critically ill surgical patients. *Am J Surg* 2005; **189**: 310-314 [PMID: 15792757 DOI: 10.1016/j.jamjsurg.2004.11.017]
  - 75 **Taylor WH**, Khaleeli AA. Coincident diabetes mellitus and primary hyperparathyroidism. *Diabetes Metab Res Rev* 2005; **17**: 175-180 [PMID: 11424230]
  - 76 **Procopio M**, Borretta G. Derangement of glucose metabolism in hyperparathyroidism. *J Endocrinol Invest* 2003; **26**: 1136-1142 [PMID: 15008255]
  - 77 **Gulcelik NE**, Bozkurt F, Tezel GG, Kaynaroglu V, Erbas T. Normal parathyroid hormone levels in a diabetic patient with parathyroid adenoma. *Endocrine* 2009; **35**: 147-150 [PMID: 19116787 DOI: 10.1007/s12020-008-9135-1]
  - 78 **Pelletier-Morel L**, Fabien N, Mouhoub Y, Boitard C, Larger E. Hyperparathyroidism in a patient with autoimmune polyglandular syndrome. *Intern Med* 2008; **47**: 1911-1915 [PMID: 18981636]
  - 79 **Makaya T**, Chatterjee S, Arundel P, Bevan C, Wright NP. Severe hypercalcemia in diabetic ketoacidosis: a case report. *Diabetes Care* 2013; **36**: e44 [PMID: 23520372 DOI: 10.2337/dc12-1845]
  - 80 **Topaloglu AK**, Yildizdas D, Yilmaz HL, Mungan NO, Yuksel B, Ozer G. Bone calcium changes during diabetic ketoacidosis: a comparison with lactic acidosis due to volume depletion. *Bone* 2005; **37**: 122-127 [PMID: 15869925 DOI: 10.1016/j.bone.2005.03.012]
  - 81 **Balint E**, Szabo P, Marshall CF, Sprague SM. Glucose-



- induced inhibition of in vitro bone mineralization. *Bone* 2001; **28**: 21-28 [PMID: 11165939]
- 82 **Bereket A**, Wilson TA, Kolasa AJ, Fan J, Lang CH. Regulation of the insulin-like growth factor system by acute acidosis. *Endocrinology* 1996; **137**: 2238-2245 [PMID: 8641171]
- 83 **Fisher JN**, Kitabchi AE. A randomized study of phosphate therapy in the treatment of diabetic ketoacidosis. *J Clin Endocrinol Metab* 1983; **57**: 177-180 [PMID: 6406531]
- 84 **Moe SM**. Disorders involving calcium, phosphorus, and magnesium. *Prim Care* 2008; **35**: 215-237, v-vi [PMID: 18486714 DOI: 10.1016/j.pop.2008.01.007]
- 85 **Kebler R**, McDonald FD, Cadnapaphornchai P. Dynamic changes in serum phosphorus levels in diabetic ketoacidosis. *Am J Med* 1985; **79**: 571-576 [PMID: 3933341]
- 86 **Keller U**, Berger W. Prevention of hypophosphatemia by phosphate infusion during treatment of diabetic ketoacidosis and hyperosmolar coma. *Diabetes* 1980; **29**: 87-95 [PMID: 6766411]
- 87 **Wilson HK**, Keuer SP, Lea AS, Boyd AE, Eknoyan G. Phosphate therapy in diabetic ketoacidosis. *Arch Intern Med* 1982; **142**: 517-520 [PMID: 6802095]
- 88 **Winter RJ**, Harris CJ, Phillips LS, Green OC. Diabetic ketoacidosis. Induction of hypocalcemia and hypomagnesemia by phosphate therapy. *Am J Med* 1979; **67**: 897-900 [PMID: 116547]
- 89 **Kreisberg RA**. Phosphorus deficiency and hypophosphatemia. *Hosp Pract* 1977; **12**: 121-128 [PMID: 402311]
- 90 **Evans KJ**, Thompson J, Spratt SE, Lien LF, Vorderstrasse A. The implementation and evaluation of an evidence-based protocol to treat diabetic ketoacidosis: a quality improvement study. *Adv Emerg Nurs J* 2014; **36**: 189-198 [PMID: 24785671]

**P- Reviewer:** Gillesen A, Haidara M,  
Swierczynski JT, Tziomalos K

**S- Editor:** Ji FF **L- Editor:** A **E- Editor:** Liu SQ



## Practical strategies for modulating foam cell formation and behavior

Elisabeth Uitz, Babak Bahadori, Mark F McCarty, Mohammed H Moghadasian

Elisabeth Uitz, Babak Bahadori, Department of Internal Medicine 2, University Hospital of St. Poelten, Karl Landsteiner Private University of Health and Life Sciences, Probst-Fuehrer-Str. 4, Austria

Mark F McCarty, Catalytic Longevity, Carlsbad, CA 92009, United States

Mohammed H Moghadasian, Department of Human Nutritional Sciences, University of Manitoba, Winnipeg, R2H 2A6 Manitoba, Canada

**Author contributions:** Uitz E designed and wrote the manuscript and performed the majority of data analysing; Bahadori B and McCarty MF provided analytical tools and were also involved in data analysing and editing the manuscript; Moghadasian MH coordinated and provided the data collection of all the human material in addition to providing mental support for this work.

**Correspondence to:** Elisabeth Uitz, MD, Department of Internal Medicine 2, University Hospital of St. Poelten, Karl Landsteiner Private University of Health and Life Sciences, 3100 St. Poelten, Probst-Fuehrer-Str. 4, Austria. [elisabeth.uitz@aon.at](mailto:elisabeth.uitz@aon.at)  
Telephone: +43-2742-900472221 Fax: +43-2742-900419006

Received: February 10, 2014 Revised: August 5, 2014

Accepted: August 27, 2014

Published online: October 16, 2014

### Abstract

Although high density lipoprotein (HDL)-mediated reverse cholesterol transport is crucial to the prevention and reversal of atheroma, a recent meta-analysis makes evident that current pharmaceutical strategies for modulating HDL cholesterol levels lower cardiovascular risk only to the extent that they concurrently decrease low density lipoprotein (LDL) cholesterol. This corresponds well with findings of a recent Mendelian randomization analysis, in which genetic polymorphisms associated with HDL cholesterol but no other known cardiovascular risk factors failed to predict risk for myocardial infarction. Although it is still seems appropriate to search for therapies that could improve the efficiency with which HDL particles induce reverse cholesterol transport, targeting HDL cholesterol levels *per se* with current measures appears to be futile. It

may therefore be more promising to promote reverse cholesterol transport with agents that directly target foam cells. Macrophage expression of the cholesterol transport proteins adenosine triphosphate binding cassette transporter A1, adenosine triphosphate binding cassette transporter G1, and scavenger receptor class B member 1 is transcriptionally up-regulated by activated liver X receptors (LXR), whereas nuclear factor (NF)-kappaB antagonizes their expression. Taurine, which inhibits atherogenesis in rodent studies, has just been discovered to act as a weak agonist for LXRalpha. Conversely, it may be possible to oppose NF-kappaB activation in macrophages with a range of measures. Induction of heme oxygenase-1, which can be attained with phase 2 inducer phytochemicals such as lipoic acid and green tea catechins, promotes reverse cholesterol transport in macrophages and inhibits atherogenesis in rodents, likely due to, in large part, NF-kappaB antagonism. Inhibition of macrophage nicotinamide adenine dinucleotide phosphate (NADPH) oxidase activity with the spirulina-derived bilirubin-mimetic phycocyanobilin may also oppose NF-kappaB activation, and salicylic acid similarly should be useful for this purpose. The 5' adenosine monophosphate-activated protein kinase activator berberine promotes macrophage reverse cholesterol transport in cell culture; metformin probably shares this property. Many of these measures could also be expected to promote plaque stability by suppressing foam cell production of inflammatory cytokines and matrix metalloproteinases, and to reduce intimal monocyte infiltration by anti-inflammatory effects on vascular endothelium. Direct targeting of foam cells with agents such as phase 2 inducers, spirulina, salicylate, taurine, and berberine or metformin, may hence have considerable potential for preventing and reversing atheroma, and for preventing the plaque rupture that triggers vascular thrombosis.

© 2014 Baishideng Publishing Group Inc. All rights reserved.

**Key words:** Atherosclerosis; Cholesterol; Inflammation;

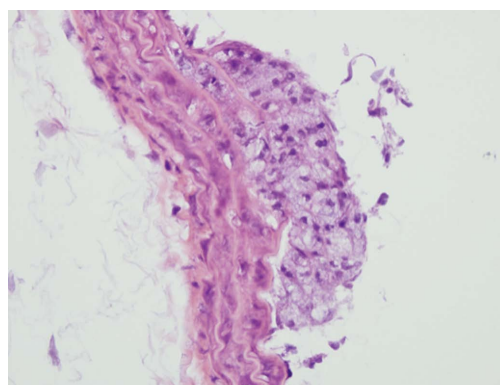
Phytochemical; Nutraceutical; Atherogenesis; Plaque; Cytokine; Antioxidant

**Core tip:** Reverse cholesterol transport from foam cells is of key importance to prevention and control of atherosclerosis. This essay reviews the molecular biology of foam cell regulation, and proposes that certain agents may be capable of acting directly on foam cells to amplify reverse cholesterol transport while also promoting plaque stability by limiting foam cell production of inflammatory cytokines and matrix metalloproteinases. Phase 2 inducers such as lipoic acid and green tea catechins, spirulina, salicylate, taurine, and 5' adenosine monophosphate-activated protein kinase activators such as metformin or berberine, appear to have potential in this regard-while acting in additional ways to benefit vascular health.

Uitz E, Bahadori B, McCarty MF, Moghadasian MH. Practical strategies for modulating foam cell formation and behavior. *World J Clin Cases* 2014; 2(10): 497-506 Available from: URL: <http://www.wjgnet.com/2307-8960/full/v2/i10/497.htm> DOI: <http://dx.doi.org/10.12998/wjcc.v2.i10.497>

## PHARMACEUTICAL HIGH DENSITY LIPOPROTEIN MODULATION HAS PROVED DISAPPOINTING

Although reverse cholesterol transport from foam cells mediated by high density lipoprotein (HDL) particles clearly plays a key role in the prevention and control of atherosclerosis (Figure 1) and its complications<sup>[1-3]</sup>, a recent meta-analysis strongly suggests that current pharmaceutical measures for increasing HDL cholesterol (*e.g.*, niacin, fibrates, cholesteryl ester transfer protein inhibitors) do not enhance health outcomes in at-risk subjects- or rather, only do so to the extent that, like niacin, they favorably influence other determinants of atherogenesis such as low density lipoprotein (LDL) and apoB-bearing lipoproteins<sup>[4]</sup>. The failure of niacin in the AIM-HIGH trial-despite evidence of benefit in other studies<sup>[5,6]</sup>- might then be explained by the fact that patients in the control group received a higher dose of statin such that reductions of LDL cholesterol were equivalent in each group<sup>[7]</sup>. Analogously, a Mendelian randomization analysis has determined that genotypes associated with elevated HDL cholesterol (but no other known determinants of cardiovascular risk), are not associated with a decline in risk for myocardial infarction<sup>[8]</sup>. A similar analysis focusing on genetic determinants of LDL cholesterol provides striking confirmation of LDL's pathogenicity<sup>[9]</sup>. The well-established epidemiological association of low HDL cholesterol with increased cardiovascular risk might therefore reflect the fact that low HDL cholesterol levels can serve as a marker for metabolic states-such as the metabolic syndrome-that are truly pathogenic; a



**Figure 1** An atherosclerotic plaque at its early stage of development in the thoracic aorta of an apolipoprotein E-KO mouse is illustrated. The plaque is primarily composed of apparent foam cells. HE staining × 400.

similar analysis applies to moderately elevated homocysteine. There still may be scope for developing new drugs or procedures that improve the capacity of HDL particles to achieve reverse transport<sup>[10-13]</sup>-but available pharmaceutical agents capable of elevating HDL cholesterol do not seem to have that property. As the authors of the recent meta-analysis note: "Raising high density lipoprotein cholesterol without considering effects on high density lipoprotein function seem to have little promise for the prevention of cardiovascular events"<sup>[4]</sup>.

It bears mentioning that the low HDL cholesterol levels seen in subjects carrying the Milano variant of apoA-1 are not associated with aggravated cardiovascular risk<sup>[14]</sup>; perhaps this reflects the efficiency with which Milano HDL delivers cholesterol to the liver for catabolism. Conversely, the elevation of HDL cholesterol associated with niacin therapy may reflect the fact that clinical concentrations of niacin impede the liver's ability to catabolize holo-HDL particles<sup>[15]</sup>; while this increases the circulating apoA-1 pool, the amount of cholesterol per HDL particle also rises. Whether the increase in HDL associated with moderate alcohol consumption-likely attributable to enhanced hepatic synthesis of apoA-1<sup>[16]</sup>- is partially responsible for the decrease in cardiovascular risk observed in by prudent drinkers, is not yet clear; activation of 5' adenosine monophosphate-activated protein kinase (AMPK) by ethanol-derived acetate may contribute to alcohol's vascular benefits<sup>[17]</sup>.

## TARGETING FOAM CELLS DIRECTLY TO MODULATE FOAM CELL FORMATION AND BEHAVIOUR

Despite the seeming inutility of current efforts to modulate HDL, it may still be feasible to promote reverse cholesterol transport with agents that act directly on foam cells to enhance their capacity to export cholesterol. Moreover, some of these agents could be expected to decrease foam cell uptake of modified LDL particles, and to work in other ways to promote plaque stabilization.

Egress of cholesterol from macrophages and foam

cells is mediated by several membrane transport proteins, namely adenosine triphosphate binding cassette transporter A1 (ABCA1), adenosine triphosphate binding cassette transporter G1 (ABCG1), and scavenger receptor class B member 1 (SRB-1); ABCA1 preferentially interacts with lipid-poor apoA-1, ABCG1 can transfer cholesterol to all HDL particles, and SRB-1 interacts with a wide range of lipoproteins<sup>[18]</sup>. The transcription of ABCA1 and ABCG1 is promoted by the liver X receptors (LXR) receptor, a transcription factor whose physiological activation is mediated by certain hydroxylated metabolites of cholesterol produced within macrophages which can function as ligands for LXR<sup>[19,20]</sup>. Increased intracellular cholesterol in macrophages also promotes increased expression of SRB-1, although this effect does not seem to be mediated *via* LXR<sup>[21]</sup>. In this way, increased cholesterol uptake by macrophages provokes a compensatory increase in cholesterol export induced by cholesterol metabolites. This LXR-mediated promotion of reverse cholesterol transport *via* HDL can be antagonized by a number of pro-inflammatory cytokines and agonists which have the common effect of activating nuclear factor (NF)-kappaB; concurrent suppression of NF-kappaB activity largely eliminates this inhibition of reverse cholesterol transport<sup>[22-27]</sup>. NF-kappaB activity somehow opposes the transcription of ABCA1, ABCG1, and SRB-1; how this occurs is still unclear. The balance between LXR and NF-kappaB activities is hence a key determinant of foam cell formation. NF-kappaB activation also is a mediator of inflammatory cytokine production by foam cells, and can promote plaque destabilization by inducing production of matrix metalloproteinases (MMP)<sup>[25,28]</sup>-whereas LXR suppresses production of MMP-9<sup>[29]</sup>.

### **Heme oxygenase-1, phase 2 inducers, bilirubin, and spirulina**

A number of studies reveal that induction of heme oxygenase-1 (HO-1) in foam cells promotes reverse cholesterol transport, induces increased expression of ABCA1, ABCG1, and SRB-1, and acts in other ways to suppress foam cell production of pro-inflammatory cytokines and plaque-destabilizing metalloproteinases<sup>[30-37]</sup>. Hence, HO-1 induction can aid prevention of plaque formation, promote plaque regression, and render plaque more stable. Suppression of NF-kappaB activation appears likely to underlie many of these protective effects, since HO-1 activity has been shown to impede NF-kappaB activation in a number of circumstances<sup>[38-47]</sup>. There appears to be no evidence that HO-1 could influence LXR function. Macrophage HO-1 induction can also oppose AP-1 activation, an effect which could be expected to reduce uptake of modified LDL by diminishing expression of the SR-A receptor<sup>[32,33]</sup>. The respective roles of HO-1 products carbon monoxide and biliverdin/bilirubin in favorable modulation of foam cell function have not yet been clarified. As HO-1 can be induced by phase 2-inductive phytochemicals *via* the Nrf2 transcription fac-

tor<sup>[48]</sup>, such agents evidently have potential for promoting reverse cholesterol transport and aiding prevention, regression, and stabilization of plaque. Lipoic acid, a broad range of flavanoids (including notably green tea catechins), isothiocyanates from crucifera, and organosulfur compounds from garlic and onions, can serve as phase 2 inducers<sup>[49-57]</sup>-albeit what intakes of these might have a functionally significant impact on HO-1 in foam cells is unknown. Lipoic acid is of particular interest in this regard, inasmuch as well-defined dose schedules (600-1800 mg daily) exert protective effects in diabetic neuropathy, which seem likely to reflect phase 2 induction<sup>[58]</sup>. Not surprisingly, lipoic acid exerts anti-atherosclerotic activity in rodents<sup>[59-62]</sup>.

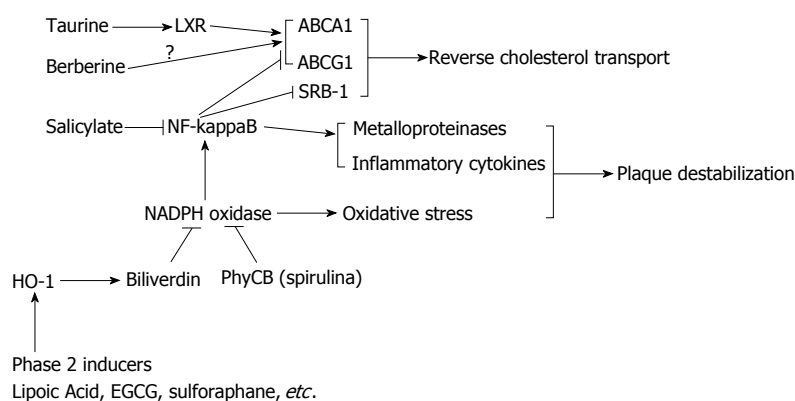
The antioxidant effects of HO-1 are mediated largely by bilirubin, which functions physiologically to inhibit certain isoforms of nicotinamide adenine dinucleotide phosphate (NADPH) oxidase<sup>[63-66]</sup>. The inverse correlation of serum bilirubin levels with cardiovascular risk observed in many epidemiological studies<sup>[67-69]</sup> may well reflect the antioxidant impact of free bilirubin on the vascular wall-endothelium, foam cells, and smooth muscle cells. A number of agonists which stimulate NF-kappaB activity in macrophages concurrently activate NADPH oxidase, which boosts NF-kappaB activation *via* oxidant mechanisms<sup>[70-79]</sup>. It is therefore reasonable to suspect that HO-1 induction promotes reverse cholesterol transport, in part, by suppressing the up-regulatory impact of NADPH oxidase on NF-kappaB activity. Consistent with this possibility, the ability of advanced glycation end-products to suppress expression of ABCA1 and ABCG1 expression in macrophages is blocked by inhibitors of NADPH oxidase<sup>[80,81]</sup>. Macrophage NADPH oxidase activity could also be expected to promote foam cell formation by promoting oxidative modification of LDL.

Recent studies indicate that bilirubin's antioxidant effect can be mimicked by phycocyanobilin (PhyCB), a prominent light-absorbing chromophore in cyanobacteria such as spirulina; PhyCB is a metabolite and close structural analog of biliverdin, the precursor of bilirubin<sup>[82,83]</sup>. Not surprisingly, the only study to date which has evaluated oral administration of spirulina or its PhyCB-bearing protein phycocyanin in a rodent model of atherogenesis (cholesterol-fed hamsters) observed a profound anti-atherosclerotic effect<sup>[84]</sup>. An anti-inflammatory impact on vascular endothelial cells, coupled with a suppressive impact on intimal foam cell formation, seems likely to account for this observation. The ability of bilirubin and of PhyCB to maintain reverse cholesterol transport in macrophages stimulated with various pro-inflammatory agonists that otherwise would inhibit it, should be assessed.

### **Salicylate suppresses NF-kappaB activity**

Activation of NF-kappaB can often be suppressed more directly with salicylate, a direct inhibitor of inhibit the inhibitor of nuclear factor kappa-B kinase beta (IKK-beta), in clinical doses that do not entail important inhibition of cyclooxygenase, and hence are relatively safe<sup>[85-88]</sup>. In foam





**Figure 2 Nutraceutical/drug regulation of foam cell cholesterol transport and plaque stability.** LXR: Liver X receptors; HO-1: Heme oxygenase-1; NF-kappaB: Nuclear factor-kappaB; ABCA1: Adenosine triphosphate binding cassette transporter A1; ABCG1: Adenosine triphosphate binding cassette transporter G1; SRB-1: Scavenger receptor class B member 1; NADPH oxidase: Nicotinamide adenine dinucleotide phosphate oxidase; EGCG: Epigallocatechin gallate; HO-1: Heme oxygenase-1; PhyCB: Phycocyanobilin.

cells *in vitro*, aspirin (which shares salicylate's capacity to inhibit IKK-beta) was found to suppress the transcriptional activity of NF-kappaB and-likely as a result - boost expression of ABCA1 and SRB-1 while suppressing that of matrix metalloproteinase-9 (a mediator of plaque instability)<sup>[25]</sup>. In doses of 3-4.5 g daily, salicylate (preferably as salsalate) has been shown to modestly aid glycemic control in diabetics, likely *via* its inhibition of IKK-beta<sup>[89-91]</sup>; it might be feasible to employ salicylate in comparable doses to promote reverse cholesterol transport and stabilize plaque in patients with atheroma.

### Taurine as an LXR agonist

Pharmaceutical LXR agonists can promote reverse cholesterol transport in macrophages, and some of these are being evaluated as potential new drugs for control of atherosclerosis<sup>[92-94]</sup>. Unfortunately, most such agents also boost hepatic lipogenesis *via* LXR activity, an effect viewed as undesirable<sup>[94]</sup>. A particularly intriguing recent discovery is that the essential cofactor taurine can act as a weak agonist for LXRA; moreover, taurine can enhance the expression of ABCA1 and ABCG1, and promote reverse cholesterol transport, in cultured macrophages<sup>[95]</sup>. Curiously, owing to a countervailing effect, taurine fails to promote hepatic lipogenesis, and is very well tolerated<sup>[95]</sup>. A number of studies have demonstrated that dietary taurine can impede atherogenesis in rodent models of this disorder<sup>[96-103]</sup>; this effect is stronger than could be predicted from the modest hypolipidemic effects of taurine in rodents, and it would be of interest to know whether a favorable impact on the function of intimal macrophages plays a role in taurine's anti-atherosclerotic activity. If so, taurine-which appears to have minimal impact on serum lipids in humans-might have clinical utility for preventing and controlling atherosclerosis<sup>[104,105]</sup>. Of related interest is the possibility that taurine's antioxidant activity may be helpful for preventing LDL modification mediated by hypochlorous acid, a myeloperoxidase product<sup>[106]</sup>. Moreover, rodent and limited clinical studies suggest that taurine supplementation has the potential to

favorably influence platelet stability, blood pressure, and the failing heart<sup>[107]</sup>. The continuing neglect of this inexpensive and well tolerated nutrient by clinical researchers is mystifying.

### AMPK activators

The anti-diabetic nutraceutical berberine, whose clinical efficacy resembles that of metformin in being contingent on activation of AMPK, has exerted anti-atherogenic effects in some but not all rodent models of this disorder<sup>[108-110]</sup>. The AMPK activator AICAR has been shown to promote reverse cholesterol transport in cultured macrophages by boosting expression of ABCG1<sup>[111]</sup>. Studies examining the impact of berberine on cultured macrophages report that it can exert a range of effects likely to antagonize foam cell formation and stabilize plaque-inhibiting activation of NADPH oxidase and NF-kappaB, inhibiting MMP-9 expression, and antagonizing cholesterol accumulation by inducing expression of ABCA1 or SRB-1, or suppressing expression of the LOX-1 LDL receptor for oxidized LDL<sup>[112-114]</sup>. On the other hand, one study found that berberine exposure increased macrophage uptake of modified LDL by increasing expression of the SRA-1 receptor<sup>[115]</sup>. The impact of metformin on foam cell function appears to have received little or no study. *In vivo*, berberine could also be expected to reduce foam cell formation by decreasing circulating LDL; it boosts hepatocyte expression of the LDL receptor by a mechanism that is complementary to that of statins<sup>[116]</sup>.

## CONCLUSION

It should not go unnoted that many of the agents discussed here-notably phase 2 inducers<sup>[117-122]</sup>, PhyCB<sup>[123-125]</sup>, salsalate<sup>[126-128]</sup>, and berberine or metformin<sup>[129-134]</sup>-have the potential to impede foam cell formation by exerting anti-inflammatory effects on endothelial cells that would be expected to impede monocyte migration across the endothelial barrier into arterial intima. Each of these agents can work in various ways to inhibit endothelial NF-kap-

paB activity, which promotes the adhesion of monocytes to the endothelial surface and their subsequent transmigration (Figure 2)<sup>[135-137]</sup>.

In summation-whereas current pharmaceutical strategies for increasing HDL cholesterol appear to have little clinical utility (aside from those which concurrently lower LDL levels), other clinically feasible measures which directly influence intimal macrophages have the potential to promote reverse cholesterol transport, and hence achieve the primary purpose intended for HDL elevation. These measures include administration of phase 2-inducing nutraceuticals (such as lipoic acid, green tea catechins, and cruciferous isothiocyanates), spirulina or PhyCB, salsalate, taurine, and berberine. These effects are mediated primarily by inhibition of NF-kappaB activation or by LXRA agonism. Moreover, most of these agents might be expected to impact foam cell function in other complementary ways that would be clinically useful-suppressing macrophage uptake of modified LDL, and inhibiting macrophage production of inflammatory cytokines and matrix metalloproteinases that could destabilize plaque. And most of them, *via* direct anti-inflammatory effects on vascular endothelium, should also impede foam cell formation by suppressing transendothelial migration of monocytes. These agents evidently merit further evaluation, both in animal models and ultimately clinical trials, as measures for preventing, reversing, and stabilizing arterial plaque. And the fact that most of these agents are nutraceuticals suggests that they might be especially feasible for use in primary prevention.

## REFERENCES

- Poglitsch CL**, Thompson NL. Interaction of antibodies with Fc receptors in substrate-supported planar membranes measured by total internal reflection fluorescence microscopy. *Biochemistry* 1990; **29**: 248-254 [PMID: 2138914 DOI: 10.1210/jc.2010-0163]
- Oram JF**. Tangier disease and ABCA1. *Biochim Biophys Acta* 2000; **1529**: 321-330 [PMID: 11111099]
- Kolovou GD**, Mikhailidis DP, Anagnostopoulou KK, Daskalopoulou SS, Cokkinos DV. Tangier disease four decades of research: a reflection of the importance of HDL. *Curr Med Chem* 2006; **13**: 771-782 [PMID: 16611066]
- Briel M**, Ferreira-Gonzalez I, You JJ, Karanickolas PJ, Akl EA, Wu P, Blechacz B, Bassler D, Wei X, Sharmar A, Whitt I, Alves da Silva S, Khalid Z, Nordmann AJ, Zhou Q, Walter SD, Vale N, Bhatnagar N, O'Regan C, Mills EJ, Bucher HC, Montori VM, Guyatt GH. Association between change in high density lipoprotein cholesterol and cardiovascular disease morbidity and mortality: systematic review and meta-regression analysis. *BMJ* 2009; **338**: b92 [PMID: 19221140 DOI: 10.1136/bmj.b92]
- Bruckert E**, Labreuche J, Amarenco P. Meta-analysis of the effect of nicotinic acid alone or in combination on cardiovascular events and atherosclerosis. *Atherosclerosis* 2010; **210**: 353-361 [PMID: 20079494 DOI: 10.1016/j.atherosclerosis.2009.12.023]
- Phan BA**, Muñoz L, Shadzi P, Isquith D, Triller M, Brown BG, Zhao XQ. Effects of niacin on glucose levels, coronary stenosis progression, and clinical events in subjects with normal baseline glucose levels (< 100 mg/dl): a combined analysis of the Familial Atherosclerosis Treatment Study (FATS), HDL-Atherosclerosis Treatment Study (HATS), Armed Forces Regression Study (AFREGS), and Carotid Plaque Composition by MRI during lipid-lowering (CPC) study. *Am J Cardiol* 2013; **111**: 352-355 [PMID: 23168285 DOI: 10.1016/j.amjcard.2012.09.034]
- Boden WE**, Probstfield JL, Anderson T, Chaitman BR, Desvignes-Nickens P, Koprowicz K, McBride R, Teo K, Weintraub W. Niacin in patients with low HDL cholesterol levels receiving intensive statin therapy. *N Engl J Med* 2011; **365**: 2255-2267 [PMID: 22085343 DOI: 10.1056/NEJMoa1107579]
- Voight BF**, Peloso GM, Orho-Melander M, Frikke-Schmidt R, Barbalic M, Jensen MK, Hindy G, Hólm H, Ding EL, Johnson T, Schunkert H, Samani NJ, Clarke R, Hopewell JC, Thompson JF, Li M, Thorleifsson G, Newton-Cheh C, Musunuru K, Pirruccello JP, Saleheen D, Chen L, Stewart A, Schillert A, Thorsteinsdottir U, Thorgeirsson G, Anand S, Engert JC, Morgan T, Spertus J, Stoll M, Berger K, Martinelli N, Girelli D, McKeown PP, Patterson CC, Epstein SE, Devaney J, Burnett MS, Mooser V, Ripatti S, Surakka I, Nieminen MS, Sinisalo J, Lokki ML, Perola M, Havulinna A, de Faire U, Gigante B, Ingelsson E, Zeller T, Wild P, de Bakker PI, Klungel OH, Maitland-van der Zee AH, Peters BJ, de Boer A, Grobbee DE, Kamphuisen PW, Deneer VH, Elbers CC, Onland-Moret NC, Hofker MH, Wijmenga C, Verschuren WM, Boer JM, van der Schouw YT, Rasheed A, Frossard P, Demissie S, Willer C, Do R, Ordovas JM, Abecasis GR, Boehnke M, Mohlke KL, Daly MJ, Guiducci C, Burt NP, Surti A, Gonzalez E, Purcell S, Gabriel S, Marrugat J, Peden J, Erdmann J, Diemert P, Willenborg C, König IR, Fischer M, Hengstenberg C, Ziegler A, Buysschaert I, Lambrechts D, Van de Werf F, Fox KA, El Mokhtari NE, Rubin D, Schrezenmeier J, Schreiber S, Schäfer A, Danesh J, Blankenberg S, Roberts R, McPherson R, Watkins H, Hall AS, Overvad K, Rimm E, Boerwinkle E, Tybjaerg-Hansen A, Cupples LA, Reilly MP, Melander O, Mannucci PM, Ardissino D, Siscovick D, Elosua R, Stefansson K, O'Donnell CJ, Salomaa V, Rader DJ, Peltonen L, Schwartz SM, Altshuler D, Kathiresan S. Plasma HDL cholesterol and risk of myocardial infarction: a mendelian randomisation study. *Lancet* 2012; **380**: 572-580 [PMID: 22607825 DOI: 10.1016/S0140-6736(12)60312-2]
- Ference BA**, Yoo W, Alesh I, Mahajan N, Mirowska KK, Mewada A, Kahn J, Afonso L, Williams KA, Flack JM. Effect of long-term exposure to lower low-density lipoprotein cholesterol beginning early in life on the risk of coronary heart disease: a Mendelian randomization analysis. *J Am Coll Cardiol* 2012; **60**: 2631-2639 [PMID: 23083789 DOI: 10.1016/j.jacc.2012.09.017]
- Khera AV**, Cuchel M, de la Llera-Moya M, Rodrigues A, Burke MF, Jafri K, French BC, Phillips JA, Mucksavage ML, Wilensky RL, Mohler ER, Rothblat GH, Rader DJ. Cholesterol efflux capacity, high-density lipoprotein function, and atherosclerosis. *N Engl J Med* 2011; **364**: 127-135 [PMID: 21226578 DOI: 10.1056/NEJMoa1001689]
- Nissen SE**, Tsunoda T, Tuzcu EM, Schoenhagen P, Cooper CJ, Yasin M, Eaton GM, Lauer MA, Sheldon WS, Grines CL, Halpern S, Crowe T, Blankenship JC, Kerensky R. Effect of recombinant ApoA-I Milano on coronary atherosclerosis in patients with acute coronary syndromes: a randomized controlled trial. *JAMA* 2003; **290**: 2292-2300 [PMID: 14600188 DOI: 10.1001/jama.290.17.2292]
- Waksman R**, Torguson R, Kent KM, Pichard AD, Suddath WO, Satler LF, Martin BD, Perlman TJ, Maltais JA, Weissman NJ, Fitzgerald PJ, Brewer HB. A first-in-man, randomized, placebo-controlled study to evaluate the safety and feasibility of autologous delipidated high-density lipoprotein plasma infusions in patients with acute coronary syndrome. *J Am Coll Cardiol* 2010; **55**: 2727-2735 [PMID: 20538165 DOI: 10.1016/j.jacc.2009.12.067]
- Roberts CK**, Ng C, Hama S, Eliseo AJ, Barnard RJ. Effect of a short-term diet and exercise intervention on inflammatory/anti-inflammatory properties of HDL in overweight/obese

- men with cardiovascular risk factors. *J Appl Physiol* (1985) 2006; **101**: 1727-1732 [PMID: 16902063]
- 14 **Sirtori CR**, Calabresi L, Franceschini G, Baldassarre D, Amato M, Johansson J, Salvetti M, Monteduro C, Zulli R, Muiesan ML, Agabiti-Rosei E. Cardiovascular status of carriers of the apolipoprotein A-I(Milano) mutant: the Limone sul Garda study. *Circulation* 2001; **103**: 1949-1954 [PMID: 11306522]
- 15 **Zhang LH**, Kamanna VS, Zhang MC, Kashyap ML. Niacin inhibits surface expression of ATP synthase beta chain in HepG2 cells: implications for raising HDL. *J Lipid Res* 2008; **49**: 1195-1201 [PMID: 18316796 DOI: 10.1194/jlr.M700426-JLR200]
- 16 **Amarasuriya RN**, Gupta AK, Civen M, Horng YC, Maeda T, Kashyap ML. Ethanol stimulates apolipoprotein A-I secretion by human hepatocytes: implications for a mechanism for atherosclerosis protection. *Metabolism* 1992; **41**: 827-832 [PMID: 1640859]
- 17 **Sakakibara S**, Murakami R, Takahashi M, Fushimi T, Murohara T, Kishi M, Kajimoto Y, Kitakaze M, Kaga T. Vinegar intake enhances flow-mediated vasodilatation via upregulation of endothelial nitric oxide synthase activity. *Biosci Biotechnol Biochem* 2010; **74**: 1055-1061 [PMID: 20460711]
- 18 **Berrougui H**, Khalil A. Age-associated decrease of high-density lipoprotein-mediated reverse cholesterol transport activity. *Rejuvenation Res* 2009; **12**: 117-126 [PMID: 19405812 DOI: 10.1089/rej.2008.0840]
- 19 **Tontonoz P**, Mangelsdorf DJ. Liver X receptor signaling pathways in cardiovascular disease. *Mol Endocrinol* 2003; **17**: 985-993 [PMID: 12690094]
- 20 **Beyea MM**, Heslop CL, Sawyez CG, Edwards JY, Markle JG, Hegele RA, Huff MW. Selective up-regulation of LXR-regulated genes ABCA1, ABCG1, and APOE in macrophages through increased endogenous synthesis of 24(S),25-epoxycholesterol. *J Biol Chem* 2007; **282**: 5207-5216 [PMID: 17186944]
- 21 **Yu L**, Cao G, Repa J, Stangl H. Sterol regulation of scavenger receptor class B type I in macrophages. *J Lipid Res* 2004; **45**: 889-899 [PMID: 14967816]
- 22 **Baranova I**, Vishnyakova T, Bocharov A, Chen Z, Remaley AT, Stonik J, Eggerman TL, Patterson AP. Lipopolysaccharide down regulates both scavenger receptor B1 and ATP binding cassette transporter A1 in RAW cells. *Infect Immun* 2002; **70**: 2995-3003 [PMID: 12010990]
- 23 **Ferreira V**, van Dijk KW, Groen AK, Vos RM, van der Kaa J, Gijbels MJ, Havekes LM, Pannekoek H. Macrophage-specific inhibition of NF-kappaB activation reduces foam-cell formation. *Atherosclerosis* 2007; **192**: 283-290 [PMID: 16938301]
- 24 **Chen M**, Li W, Wang N, Zhu Y, Wang X. ROS and NF-kappaB but not LXR mediate IL-1beta signaling for the down-regulation of ATP-binding cassette transporter A1. *Am J Physiol Cell Physiol* 2007; **292**: C1493-C1501 [PMID: 17135302]
- 25 **Lu L**, Liu H, Peng J, Gan L, Shen L, Zhang Q, Li L, Zhang L, Su C, Jiang Y. Regulations of the key mediators in inflammation and atherosclerosis by aspirin in human macrophages. *Lipids Health Dis* 2010; **9**: 16 [PMID: 20137092 DOI: 10.1186/1476-511X-9-16]
- 26 **Jiang J**, Mo ZC, Yin K, Zhao GJ, Lv YC, Ouyang XP, Jiang ZS, Fu Y, Tang CK. Epigallocatechin-3-gallate prevents TNF- $\alpha$ -induced NF- $\kappa$ B activation thereby upregulating ABCA1 via the Nrf2/Keap1 pathway in macrophage foam cells. *Int J Mol Med* 2012; **29**: 946-956 [PMID: 22367622 DOI: 10.3892/ijmm.2012.924]
- 27 **Yu XH**, Jiang HL, Chen WJ, Yin K, Zhao GJ, Mo ZC, Ouyang XP, Lv YC, Jiang ZS, Zhang DW, Tang CK. Interleukin-18 and interleukin-12 together downregulate ATP-binding cassette transporter A1 expression through the interleukin-18R/nuclear factor- $\kappa$ B signaling pathway in THP-1 macrophage-derived foam cells. *Circ J* 2012; **76**: 1780-1791 [PMID: 22498566]
- 28 **Chase AJ**, Bond M, Crook MF, Newby AC. Role of nuclear factor-kappa B activation in metalloproteinase-1, -3, and -9 secretion by human macrophages in vitro and rabbit foam cells produced in vivo. *Arterioscler Thromb Vasc Biol* 2002; **22**: 765-771 [PMID: 12006388]
- 29 **Castrillo A**, Joseph SB, Marathe C, Mangelsdorf DJ, Tontonoz P. Liver X receptor-dependent repression of matrix metalloproteinase-9 expression in macrophages. *J Biol Chem* 2003; **278**: 10443-10449 [PMID: 12531895]
- 30 **Ishikawa K**, Sugawara D, Wang Xp K, Itabe H, Maruyama Y, Lusis AJ. Heme oxygenase-1 inhibits atherosclerotic lesion formation in ldl-receptor knockout mice. *Circ Res* 2001; **88**: 506-512 [PMID: 11249874]
- 31 **Ishikawa K**, Sugawara D, Goto J, Watanabe Y, Kawamura K, Shiomi M, Itabe H, Maruyama Y. Heme oxygenase-1 inhibits atherogenesis in Watanabe heritable hyperlipidemic rabbits. *Circulation* 2001; **104**: 1831-1836 [PMID: 11591622]
- 32 **Ma JL**, Yang PY, Rui YC, Lu L, Kang H, Zhang J. Hemin modulates cytokine expressions in macrophage-derived foam cells via heme oxygenase-1 induction. *J Pharmacol Sci* 2007; **103**: 261-266 [PMID: 17341845]
- 33 **Orozco LD**, Kapturczak MH, Barajas B, Wang X, Weinstein MM, Wong J, Deshane J, Bolisetty S, Shaposhnik Z, Shih DM, Agarwal A, Lusis AJ, Araujo JA. Heme oxygenase-1 expression in macrophages plays a beneficial role in atherosclerosis. *Circ Res* 2007; **100**: 1703-1711 [PMID: 17495224]
- 34 **Tsai JY**, Su KH, Shyue SK, Kou YR, Yu YB, Hsiao SH, Chiang AN, Wu YL, Ching LC, Lee TS. EGB761 ameliorates the formation of foam cells by regulating the expression of SR-A and ABCA1: role of haem oxygenase-1. *Cardiovasc Res* 2010; **88**: 415-423 [PMID: 20615914 DOI: 10.1093/cvr/cvq226]
- 35 **Kuhn AM**, Tzieply N, Schmidt MV, von Knethen A, Namgaladze D, Yamamoto M, Brüne B. Antioxidant signaling via Nrf2 counteracts lipopolysaccharide-mediated inflammatory responses in foam cell macrophages. *Free Radic Biol Med* 2011; **50**: 1382-1391 [PMID: 21382476 DOI: 10.1016/j.freeradbiomed.2011.02.036]
- 36 **Araujo JA**, Zhang M, Yin F. Heme oxygenase-1, oxidation, inflammation, and atherosclerosis. *Front Pharmacol* 2012; **3**: 119 [PMID: 22833723 DOI: 10.3389/fphar.2012.00119]
- 37 **Li XY**, Kong LX, Li J, He HX, Zhou YD. Kaempferol suppresses lipid accumulation in macrophages through the downregulation of cluster of differentiation 36 and the upregulation of scavenger receptor class B type I and ATP-binding cassette transporters A1 and G1. *Int J Mol Med* 2013; **31**: 331-338 [PMID: 23232972 DOI: 10.3892/ijmm.2012.1204]
- 38 **Sasaki T**, Takahashi T, Maeshima K, Shimizu H, Toda Y, Morimatsu H, Takeuchi M, Yokoyama M, Akagi R, Morita K. Heme arginate pretreatment attenuates pulmonary NF-kappaB and AP-1 activation induced by hemorrhagic shock via heme oxygenase-1 induction. *Med Chem* 2006; **2**: 271-274 [PMID: 16948473]
- 39 **Zabalgaitia M**, Colston JT, Reddy SV, Holt JW, Regan RF, Stec DE, Rimoldi JM, Valente AJ, Chandrasekar B. Carbon monoxide donors or heme oxygenase-1 (HO-1) overexpression blocks interleukin-18-mediated NF-kappaB-PTEN-dependent human cardiac endothelial cell death. *Free Radic Biol Med* 2008; **44**: 284-298 [PMID: 18215737 DOI: 10.1016/j.freeradbiomed.2007.08.012]
- 40 **Chaea HJ**, Kim HR, Kang YJ, Hyun KC, Kim HJ, Seo HG, Lee JH, Yun-Choi HS, Chang KC. Heme oxygenase-1 induction by (S)-enantiomer of YS-51 (YS-51S), a synthetic isoquinoline alkaloid, inhibits nitric oxide production and nuclear factor-kappaB translocation in ROS 17/2.8 cells activated with inflammatory stimulants. *Int Immunopharmacol* 2007; **7**: 1559-1568 [PMID: 17920533]
- 41 **Jadhav A**, Torlakovic E, Ndisang JF. Interaction among heme oxygenase, nuclear factor-kappaB, and transcription activating factors in cardiac hypertrophy in hypertension. *Hypertension* 2008; **52**: 910-917 [PMID: 18824663 DOI: 10.1161/HYPERTENSIONAHA.108.114801]



- 42 **Kim KM**, Pae HO, Zhung M, Ha HY, Ha YA, Chai KY, Cheong YK, Kim JM, Chung HT. Involvement of anti-inflammatory heme oxygenase-1 in the inhibitory effect of curcumin on the expression of pro-inflammatory inducible nitric oxide synthase in RAW264.7 macrophages. *Biomed Pharmacother* 2008; **62**: 630-636 [PMID: 18325727 DOI: 10.1016/j.biopha.2008.01.008]
- 43 **Yeh CH**, Chen TP, Wang YC, Lin YM, Lin PJ. HO-1 activation can attenuate cardiomyocytic apoptosis via inhibition of NF-kappaB and AP-1 translocation following cardiac global ischemia and reperfusion. *J Surg Res* 2009; **155**: 147-156 [PMID: 19181338 DOI: 10.1016/j.jss.2008.07.044]
- 44 **Park SY**, Lee SW, Baek SH, Lee SJ, Lee WS, Rhim BY, Hong KW, Kim CD. Induction of heme oxygenase-1 expression by cilostazol contributes to its anti-inflammatory effects in J774 murine macrophages. *Immunol Lett* 2011; **136**: 138-145 [PMID: 21256160 DOI: 10.1016/j.imlet.2011.01.003]
- 45 **Leung PO**, Wang SH, Lu SH, Chou WH, Shiao CY, Chou TC. Simvastatin inhibits pro-inflammatory mediators through induction of heme oxygenase-1 expression in lipopolysaccharide-stimulated RAW264.7 macrophages. *Toxicol Lett* 2011; **207**: 159-166 [PMID: 21925249 DOI: 10.1016/j.toxlet.2011.09.004]
- 46 **Park SY**, Park da J, Kim YH, Kim Y, Choi YW, Lee SJ. Schisandra chinensis  $\alpha$ -iso-cubebenol induces heme oxygenase-1 expression through PI3K/Akt and Nrf2 signaling and has anti-inflammatory activity in Porphyromonas gingivalis lipopolysaccharide-stimulated macrophages. *Int Immunopharmacol* 2011; **11**: 1907-1915 [PMID: 21840424 DOI: 10.1016/j.intimp.2011.07.023]
- 47 **Kim CK**, Cho DH, Lee KS, Lee DK, Park CW, Kim WG, Lee SJ, Ha KS, Goo Taeg O, Kwon YG, Kim YM. Ginseng Berry Extract Prevents Atherogenesis via Anti-Inflammatory Action by Upregulating Phase II Gene Expression. *Evid Based Complement Alternat Med* 2012; **2012**: 490301 [PMID: 23243449 DOI: 10.1155/2012/490301]
- 48 **Alam J**, Cook JL. Transcriptional regulation of the heme oxygenase-1 gene via the stress response element pathway. *Curr Pharm Des* 2003; **9**: 2499-2511 [PMID: 14529549]
- 49 **Flier J**, Van Muiswinkel FL, Jongenelen CA, Drukarch B. The neuroprotective antioxidant alpha-lipoic acid induces detoxication enzymes in cultured astroglial cells. *Free Radic Res* 2002; **36**: 695-699 [PMID: 12180195]
- 50 **Cao Z**, Tsang M, Zhao H, Li Y. Induction of endogenous antioxidants and phase 2 enzymes by alpha-lipoic acid in rat cardiac H9C2 cells: protection against oxidative injury. *Biochem Biophys Res Commun* 2003; **310**: 979-985 [PMID: 14550301]
- 51 **Jia Z**, Hallur S, Zhu H, Li Y, Misra HP. Potent upregulation of glutathione and NAD(P)H: quinone oxidoreductase 1 by alpha-lipoic acid in human neuroblastoma SH-SY5Y cells: protection against neurotoxicant-elicited cytotoxicity. *Neurochem Res* 2008; **33**: 790-800 [PMID: 17940886]
- 52 **Na HK**, Surh YJ. Modulation of Nrf2-mediated antioxidant and detoxifying enzyme induction by the green tea polyphenol EGCG. *Food Chem Toxicol* 2008; **46**: 1271-1278 [PMID: 18082923]
- 53 **Romeo L**, Intrieri M, D'Agata V, Mangano NG, Oriani G, Ontario ML, Scapagnini G. The major green tea polyphenol, (-)-epigallocatechin-3-gallate, induces heme oxygenase in rat neurons and acts as an effective neuroprotective agent against oxidative stress. *J Am Coll Nutr* 2009; **28** Suppl: 492S-499S [PMID: 20234037]
- 54 **Fahey JW**, Zhang Y, Talalay P. Broccoli sprouts: an exceptionally rich source of inducers of enzymes that protect against chemical carcinogens. *Proc Natl Acad Sci USA* 1997; **94**: 10367-10372 [PMID: 9294217]
- 55 **Riedl MA**, Saxon A, Diaz-Sanchez D. Oral sulforaphane increases Phase II antioxidant enzymes in the human upper airway. *Clin Immunol* 2009; **130**: 244-251 [PMID: 19028145 DOI: 10.1016/j.clim.2008.10.0079]
- 56 **Kensler TW**, Curphey TJ, Maxiutenko Y, Roebuck BD. Chemoprotection by organosulfur inducers of phase 2 enzymes: dithiolethiones and dithiins. *Drug Metabol Drug Interact* 2000; **17**: 3-22 [PMID: 11201301]
- 57 **Chen C**, Pung D, Leong V, Hebbar V, Shen G, Nair S, Li W, Kong AN. Induction of detoxifying enzymes by garlic organosulfur compounds through transcription factor Nrf2: effect of chemical structure and stress signals. *Free Radic Biol Med* 2004; **37**: 1578-1590 [PMID: 15477009]
- 58 **Ziegler D**, Ametov A, Barinov A, Dyck PJ, Gurieva I, Low PA, Munzel U, Yakhno N, Raz I, Novosadova M, Maus J, Samigullin R. Oral treatment with alpha-lipoic acid improves symptomatic diabetic polyneuropathy: the SYDNEY 2 trial. *Diabetes Care* 2006; **29**: 2365-2370 [PMID: 17065669]
- 59 **Yi X**, Maeda N. alpha-Lipoic acid prevents the increase in atherosclerosis induced by diabetes in apolipoprotein E-deficient mice fed high-fat/low-cholesterol diet. *Diabetes* 2006; **55**: 2238-2244 [PMID: 16873686]
- 60 **Zulkhairi A**, Zaiton Z, Jamaluddin M, Sharida F, Mohd TH, Hasnah B, Nazmi HM, Khairul O, Zanariyah A. Alpha lipoic acid possess dual antioxidant and lipid lowering properties in atherosclerotic-induced New Zealand White rabbit. *Biomed Pharmacother* 2008; **62**: 716-722 [PMID: 18538528 DOI: 10.1016/j.biopha.2006.12.003]
- 61 **Ying Z**, Kherada N, Farrar B, Kampfrath T, Chung Y, Simonetti O, Deiuliis J, Desikan R, Khan B, Villamena F, Sun Q, Parthasarathy S, Rajagopalan S. Lipoic acid effects on established atherosclerosis. *Life Sci* 2010; **86**: 95-102 [PMID: 19944706]
- 62 **Lee WR**, Kim A, Kim KS, Park YY, Park JH, Kim KH, Kim SJ, Park KK. Alpha-lipoic acid attenuates atherosclerotic lesions and inhibits proliferation of vascular smooth muscle cells through targeting of the Ras/MEK/ERK signaling pathway. *Mol Biol Rep* 2012; **39**: 6857-6866 [PMID: 22302393 DOI: 10.1007/s11033-012-1511-5]
- 63 **Lanone S**, Bloc S, Foresti R, Almolkai A, Taillé C, Callebort J, Conti M, Govin D, Aubier M, Dureuil B, El-Benna J, Motterlini R, Boczkowski J. Bilirubin decreases nos2 expression via inhibition of NAD(P)H oxidase: implications for protection against endotoxic shock in rats. *FASEB J* 2005; **19**: 1890-1892 [PMID: 16129699]
- 64 **Matsumoto H**, Ishikawa K, Itabe H, Maruyama Y. Carbon monoxide and bilirubin from heme oxygenase-1 suppresses reactive oxygen species generation and plasminogen activator inhibitor-1 induction. *Mol Cell Biochem* 2006; **291**: 21-28 [PMID: 16625420]
- 65 **Jiang F**, Roberts SJ, Datla Sr, Disting GJ. NO modulates NADPH oxidase function via heme oxygenase-1 in human endothelial cells. *Hypertension* 2006; **48**: 950-957 [PMID: 16982957]
- 66 **Datla SR**, Disting GJ, Mori TA, Taylor CJ, Croft KD, Jiang F. Induction of heme oxygenase-1 in vivo suppresses NADPH oxidase derived oxidative stress. *Hypertension* 2007; **50**: 636-642 [PMID: 17679649]
- 67 **Schwertner HA**, Vitek L. Gilbert syndrome, UGT1A1\*28 allele, and cardiovascular disease risk: possible protective effects and therapeutic applications of bilirubin. *Atherosclerosis* 2008; **198**: 1-11 [PMID: 18343383 DOI: 10.1016/j.atherosclerosis.2008.01.001]
- 68 **Lin JP**, Vitek L, Schwertner HA. Serum bilirubin and genes controlling bilirubin concentrations as biomarkers for cardiovascular disease. *Clin Chem* 2010; **56**: 1535-1543 [PMID: 20693308]
- 69 **Horsfall LJ**, Nazareth I, Petersen I. Cardiovascular events as a function of serum bilirubin levels in a large, statin-treated cohort. *Circulation* 2012; **126**: 2556-2564 [PMID: 23110860 DOI: 10.1161/CIRCULATIONAHA.112.114066]
- 70 **Bonizzi G**, Piette J, Schoonbroodt S, Greimers R, Havard L, Merville MP, Bours V. Reactive oxygen intermediate-de-



- pendent NF-kappaB activation by interleukin-1beta requires 5-lipoxygenase or NADPH oxidase activity. *Mol Cell Biol* 1999; **19**: 1950-1960 [PMID: 10022882]
- 71 **Kono H**, Rusyn I, Yin M, Gäbele E, Yamashina S, Dikalova A, Kadiiska MB, Connor HD, Mason RP, Segal BH, Bradford BU, Holland SM, Thurman RG. NADPH oxidase-derived free radicals are key oxidants in alcohol-induced liver disease. *J Clin Invest* 2000; **106**: 867-872 [PMID: 11018074]
- 72 **Yoshida M**, Korfhagen TR, Whitsett JA. Surfactant protein D regulates NF-kappa B and matrix metalloproteinase production in alveolar macrophages via oxidant-sensitive pathways. *J Immunol* 2001; **166**: 7514-7519 [PMI: 11390505]
- 73 **Sadikot RT**, Zeng H, Yull FE, Li B, Cheng DS, Kernodle DS, Jansen ED, Contag CH, Segal BH, Holland SM, Blackwell TS, Christman JW. p47phox deficiency impairs NF-kappa B activation and host defense in *Pseudomonas pneumonia*. *J Immunol* 2004; **172**: 1801-1808 [PMID: 14734763]
- 74 **Park HS**, Jung HY, Park EY, Kim J, Lee WJ, Bae YS. Cutting edge: direct interaction of TLR4 with NAD(P)H oxidase 4 isozyme is essential for lipopolysaccharide-induced production of reactive oxygen species and activation of NF-kappa B. *J Immunol* 2004; **173**: 3589-3593 [PMID: 15356101]
- 75 **Yamashina S**, Takei Y, Ikejima K, Enomoto N, Kitamura T, Sato N. Ethanol-induced sensitization to endotoxin in Kupffer cells is dependent upon oxidative stress. *Alcohol Clin Exp Res* 2005; **29**: 246S-250S [PMID: 16385231]
- 76 **Au-Yeung KK**, Yip JC, Siow YL, O K. Folic acid inhibits homocysteine-induced superoxide anion production and nuclear factor kappa B activation in macrophages. *Can J Physiol Pharmacol* 2006; **84**: 141-147 [PMID: 16845898]
- 77 **Higai K**, Sano R, Satake M, Azuma Y, Matsumoto K. Glycated human serum albumin induces interleukin 8 mRNA expression through reactive oxygen species and NADPH oxidase-dependent pathway in monocyte-derived U937 cells. *Biol Pharm Bull* 2007; **30**: 1833-1837 [PMID: 17917246]
- 78 **San José G**, Bidegain J, Robador PA, Díez J, Fortuño A, Zalba G. Insulin-induced NADPH oxidase activation promotes proliferation and matrix metalloproteinase activation in monocytes/macrophages. *Free Radic Biol Med* 2009; **46**: 1058-1067 [PMID: 19439231 DOI: 10.1016/j.freeradbiomed.2009.01.009]
- 79 **Kim SY**, Moon KA, Jo HY, Jeong S, Seon SH, Jung E, Cho YS, Chun E, Lee KY. Anti-inflammatory effects of apocynin, an inhibitor of NADPH oxidase, in airway inflammation. *Immunol Cell Biol* 2012; **90**: 441-448 [PMID: 21709687 DOI: 10.1038/icb.2011.60]
- 80 **Mo ZC**, Xiao J, Liu XH, Hu YW, Li XX, Yi GH, Wang Z, Tang YL, Liao DF, Tang CK. AOPPs inhibits cholesterol efflux by down-regulating ABCA1 expression in a JAK/STAT signaling pathway-dependent manner. *J Atheroscler Thromb* 2011; **18**: 796-807 [PMID: 21670559]
- 81 **Ishibashi Y**, Matsui T, Takeuchi M, Yamagishi S. Rosuvastatin blocks advanced glycation end products-elicited reduction of macrophage cholesterol efflux by suppressing NADPH oxidase activity via inhibition of geranylgeranylation of Rac-1. *Horm Metab Res* 2011; **43**: 619-624 [PMID: 21823057 DOI: 10.1055/s-0031-128314]
- 82 **McCarty MF**. Clinical potential of Spirulina as a source of phycocyanobilin. *J Med Food* 2007; **10**: 566-570 [PMID: 18158824]
- 83 **Zheng J**, Inoguchi T, Sasaki S, Maeda Y, McCarty MF, Fujii M, Ikeda N, Kobayashi K, Sonoda N, Takayanagi R. Phycocyanin and phycocyanobilin from *Spirulina platensis* protect against diabetic nephropathy by inhibiting oxidative stress. *Am J Physiol Regul Integr Comp Physiol* 2013; **304**: R110-R120 [PMID: 23115122]
- 84 **Riss J**, Décorde K, Sutra T, Delage M, Baccou JC, Jouy N, Brune JP, Oréal H, Cristol JP, Rouanet JM. Phycobiliprotein C-phycocyanin from *Spirulina platensis* is powerfully responsible for reducing oxidative stress and NADPH oxidase expression induced by an atherogenic diet in hamsters. *J Agric Food Chem* 2007; **55**: 7962-7967 [PMID: 17696484]
- 85 **Yin MJ**, Yamamoto Y, Gaynor RB. The anti-inflammatory agents aspirin and salicylate inhibit the activity of I(kappa)B kinase-beta. *Nature* 1998; **396**: 77-80 [PMID: 9817203]
- 86 **Pierce GL**, Lesniewski LA, Lawson BR, Beske SD, Seals DR. Nuclear factor-{kappa}B activation contributes to vascular endothelial dysfunction via oxidative stress in overweight/obese middle-aged and older humans. *Circulation* 2009; **119**: 1284-1292 [PMID: 19237660 DOI: 10.1161/CIRCULATIONAHA.108.804294]
- 87 **Morris HG**, Sherman NA, McQuain C, Goldlust MB, Chang SF, Harrison LI. Effects of salsalate (nonacetylated salicylate) and aspirin on serum prostaglandins in humans. *Ther Drug Monit* 1985; **7**: 435-438 [PMID: 3866409]
- 88 **McCarty MF**. Salsalate may have broad utility in the prevention and treatment of vascular disorders and the metabolic syndrome. *Med Hypotheses* 2010; **75**: 276-281 [PMID: 20080359 DOI: 10.1016/j.mehy.2009.12.027]
- 89 **Goldfine AB**, Silver R, Aldhahi W, Cai D, Tatro E, Lee J, Shoelson SE. Use of salsalate to target inflammation in the treatment of insulin resistance and type 2 diabetes. *Clin Transl Sci* 2008; **1**: 36-43 [PMID: 19337387 DOI: 10.1111/j.1752-8062.2008.00026.x]
- 90 **Goldfine AB**, Fonseca V, Jablonski KA, Pyle L, Staten MA, Shoelson SE. The effects of salsalate on glycemic control in patients with type 2 diabetes: a randomized trial. *Ann Intern Med* 2010; **152**: 346-357 [PMID: 20231565 DOI: 10.7326/0003-4819-152-6-201003160-00004]
- 91 **Desouza CV**. An overview of salsalate as a potential antidiabetic therapy. *Drugs Today (Barc)* 2010; **46**: 847-853 [PMID: 21225023 DOI: 10.1358/dot.2010.46.11.1534820]
- 92 **Calkin AC**, Tontonoz P. Liver x receptor signaling pathways and atherosclerosis. *Arterioscler Thromb Vasc Biol* 2010; **30**: 1513-1518 [PMID: 20631351]
- 93 **Li X**, Yeh V, Molteni V. Liver X receptor modulators: a review of recently patented compounds (2007 - 2009). *Expert Opin Ther Pat* 2010; **20**: 535-562 [PMID: 20302451 DOI: 10.1517/13543771003621269]
- 94 **Zhu Y**, Li Y. Liver X receptors as potential therapeutic targets in atherosclerosis. *Clin Invest Med* 2009; **32**: E383-E394 [PMID: 19796580]
- 95 **Hoang MH**, Jia Y, Jun HJ, Lee JH, Hwang KY, Choi DW, Um SJ, Lee BY, You SG, Lee SJ. Taurine is a liver X receptor- $\alpha$  ligand and activates transcription of key genes in the reverse cholesterol transport without inducing hepatic lipogenesis. *Mol Nutr Food Res* 2012; **56**: 900-911 [PMID: 22707265 DOI: 10.1002/mnfr.201100611]
- 96 **Petty MA**, Kintz J, DiFrancesco GF. The effects of taurine on atherosclerosis development in cholesterol-fed rabbits. *Eur J Pharmacol* 1990; **180**: 119-127 [PMID: 2364997]
- 97 **Kondo Y**, Toda Y, Kitajima H, Oda H, Nagate T, Kameo K, Murakami S. Taurine inhibits development of atherosclerotic lesions in apolipoprotein E-deficient mice. *Clin Exp Pharmacol Physiol* 2001; **28**: 809-815 [PMID: 11553020]
- 98 **Murakami S**, Kondo Y, Nagate T. Effects of long-term treatment with taurine in mice fed a high-fat diet: improvement in cholesterol metabolism and vascular lipid accumulation by taurine. *Adv Exp Med Biol* 2000; **483**: 177-186 [PMID: 11787596]
- 99 **Murakami S**, Kondo Y, Sakurai T, Kitajima H, Nagate T. Taurine suppresses development of atherosclerosis in Watanabe heritable hyperlipidemic (WHHL) rabbits. *Atherosclerosis* 2002; **163**: 79-87 [PMID: 12048124]
- 100 **Balkan J**, Kanbaglı O, Hatipoğlu A, Küçük M, Cevikbaş U, Aykaç-Toker G, Uysal M. Improving effect of dietary taurine supplementation on the oxidative stress and lipid levels in the plasma, liver and aorta of rabbits fed on a high-cholesterol diet. *Biosci Biotechnol Biochem* 2002; **66**: 1755-1758 [PMID: 12353642]

- 101 **Matsushima Y**, Sekine T, Kondo Y, Sakurai T, Kameo K, Tachibana M, Murakami S. Effects of taurine on serum cholesterol levels and development of atherosclerosis in spontaneously hyperlipidaemic mice. *Clin Exp Pharmacol Physiol* 2003; **30**: 295-299 [PMID: 12680850]
- 102 **Zulli A**, Lau E, Wijaya BP, Jin X, Sutarga K, Schwartz GD, Learmont J, Wookey PJ, Zinellu A, Carru C, Hare DL. High dietary taurine reduces apoptosis and atherosclerosis in the left main coronary artery: association with reduced CCAAT/enhancer binding protein homologous protein and total plasma homocysteine but not lipidemia. *Hypertension* 2009; **53**: 1017-1022 [PMID: 19398656]
- 103 **Murakami S**. Taurine and atherosclerosis. *Amino Acids* 2014; **46**: 73-80 [PMID: 23224908 DOI: 10.1007/s00726-012-1432-6]
- 104 **Wójcik OP**, Koenig KL, Zeleniuch-Jacquotte A, Costa M, Chen Y. The potential protective effects of taurine on coronary heart disease. *Atherosclerosis* 2010; **208**: 19-25 [PMID: 19592001 DOI: 10.1016/j.atherosclerosis.2009.06.002]
- 105 **Yamori Y**, Taguchi T, Hamada A, Kunimasa K, Mori H, Mori M. Taurine in health and diseases: consistent evidence from experimental and epidemiological studies. *J Biomed Sci* 2010; **17** Suppl 1: S6 [PMID: 20804626 DOI: 10.1186/1423-0127-17-S1-S6]
- 106 **Jerlich A**, Fritz G, Kharrazi H, Hammel M, Tschabuschnig S, Glatter O, Schaur RJ. Comparison of HOCl traps with myeloperoxidase inhibitors in prevention of low density lipoprotein oxidation. *Biochim Biophys Acta* 2000; **1481**: 109-118 [PMID: 11004581]
- 107 **McCarty MF**. Rationale for a novel nutraceutical complex 'K-water': potassium taurine bicarbonate (PTB). *Med Hypotheses* 2006; **67**: 65-70 [PMID: 16516402]
- 108 **Lee S**, Lim HJ, Park HY, Lee KS, Park JH, Jang Y. Berberine inhibits rat vascular smooth muscle cell proliferation and migration in vitro and improves neointima formation after balloon injury in vivo. Berberine improves neointima formation in a rat model. *Atherosclerosis* 2006; **186**: 29-37 [PMID: 16098530]
- 109 **Wang Q**, Zhang M, Liang B, Shirwany N, Zhu Y, Zou MH. Activation of AMP-activated protein kinase is required for berberine-induced reduction of atherosclerosis in mice: the role of uncoupling protein 2. *PLoS One* 2011; **6**: e25436 [PMID: 21980456 DOI: 10.1371/journal.pone.0025436]
- 110 **Li K**, Yao W, Zheng X, Liao K. Berberine promotes the development of atherosclerosis and foam cell formation by inducing scavenger receptor A expression in macrophage. *Cell Res* 2009; **19**: 1006-1017 [PMID: 19546885 DOI: 10.1038/cr.2009.76]
- 111 **Li D**, Wang D, Wang Y, Ling W, Feng X, Xia M. Adenosine monophosphate-activated protein kinase induces cholesterol efflux from macrophage-derived foam cells and alleviates atherosclerosis in apolipoprotein E-deficient mice. *J Biol Chem* 2010; **285**: 33499-33509 [PMID: 20713354 DOI: 10.1074/jbc.M110.159772]
- 112 **Lee TS**, Pan CC, Peng CC, Kou YR, Chen CY, Ching LC, Tsai TH, Chen SF, Lyu PC, Shyue SK. Anti-atherogenic effect of berberine on LXRA $\alpha$ -ABCA1-dependent cholesterol efflux in macrophages. *J Cell Biochem* 2010; **111**: 104-110 [PMID: 20506155 DOI: 10.1002/jcb.22667]
- 113 **Guan S**, Wang B, Li W, Guan J, Fang X. Effects of berberine on expression of LOX-1 and SRB-1 in human macrophage-derived foam cells induced by ox-LDL. *Am J Chin Med* 2010; **38**: 1161-1169 [PMID: 21061468]
- 114 **Huang Z**, Dong F, Li S, Chu M, Zhou H, Lu Z, Huang W. Berberine-induced inhibition of adipocyte enhancer-binding protein 1 attenuates oxidized low-density lipoprotein accumulation and foam cell formation in phorbol 12-myristate 13-acetate-induced macrophages. *Eur J Pharmacol* 2012; **690**: 164-169 [PMID: 22796454]
- 115 **Liu M**, Wu H, Liu T, Li Y, Wang F, Wan H, Li X, Tang H. Regulation of the cell cycle gene, BTG2, by miR-21 in human laryngeal carcinoma. *Cell Res* 2009; **19**: 828-837 [PMID: 19546886]
- 116 **Kong W**, Wei J, Abidi P, Lin M, Inaba S, Li C, Wang Y, Wang Z, Si S, Pan H, Wang S, Wu J, Wang Y, Li Z, Liu J, Jiang JD. Berberine is a novel cholesterol-lowering drug working through a unique mechanism distinct from statins. *Nat Med* 2004; **10**: 1344-1351 [PMID: 15531889]
- 117 **Wu L**, Noyan Ashraf MH, Facci M, Wang R, Paterson PG, Ferrie A, Juurlink BH. Dietary approach to attenuate oxidative stress, hypertension, and inflammation in the cardiovascular system. *Proc Natl Acad Sci USA* 2004; **101**: 7094-7099 [PMID: 15103025 DOI: 10.1016/j.freeradbiomed.2012.04.019]
- 118 **Kim JH**, Choi YK, Lee KS, Cho DH, Baek YY, Lee DK, Ha KS, Choe J, Won MH, Jeoung D, Lee H, Kwon YG, Kim YM. Functional dissection of Nrf2-dependent phase II genes in vascular inflammation and endotoxic injury using Keap1 siRNA. *Free Radic Biol Med* 2012; **53**: 629-640 [PMID: 22609006]
- 119 **Chen XL**, Dodd G, Kunsch C. Sulforaphane inhibits TNF- $\alpha$ -induced activation of p38 MAP kinase and VCAM-1 and MCP-1 expression in endothelial cells. *Inflamm Res* 2009; **58**: 513-521 [PMID: 19277846 DOI: 10.1007/s00011-009-0017-7]
- 120 **Liao BC**, Hsieh CW, Liu YC, Tzeng TT, Sun YW, Wung BS. Cinnamaldehyde inhibits the tumor necrosis factor- $\alpha$ -induced expression of cell adhesion molecules in endothelial cells by suppressing NF- $\kappa$ B activation: effects upon IkappaB and Nrf2. *Toxicol Appl Pharmacol* 2008; **229**: 161-171 [PMID: 18304597 DOI: 10.1016/j.taap.2008.01.021]
- 121 **Chen XL**, Dodd G, Thomas S, Zhang X, Wasserman MA, Rovin BH, Kunsch C. Activation of Nrf2/ARE pathway protects endothelial cells from oxidant injury and inhibits inflammatory gene expression. *Am J Physiol Heart Circ Physiol* 2006; **290**: H1862-H1870 [PMID: 16339837]
- 122 **Zhang WJ**, Frei B. Alpha-lipoic acid inhibits TNF- $\alpha$ -induced NF- $\kappa$ B activation and adhesion molecule expression in human aortic endothelial cells. *FASEB J* 2001; **15**: 2423-2432 [PMID: 11689467]
- 123 **Soares MP**, Seldon MP, Gregoire IP, Vassilevskaia T, Berberat PO, Yu J, Tsui TY, Bach FH. Heme oxygenase-1 modulates the expression of adhesion molecules associated with endothelial cell activation. *J Immunol* 2004; **172**: 3553-3563 [PMID: 15004156]
- 124 **Bellner L**, Martinelli L, Halilovic A, Patil K, Puri N, Dunn MW, Regan RF, Schwartzman ML. Heme oxygenase-2 deletion causes endothelial cell activation marked by oxidative stress, inflammation, and angiogenesis. *J Pharmacol Exp Ther* 2009; **331**: 925-932 [PMID: 19773531 DOI: 10.1124/jpet.109.15835]
- 125 **Mazzone GL**, Rigato I, Ostrow JD, Tiribelli C. Bilirubin effect on endothelial adhesion molecules expression is mediated by the NF- $\kappa$ B signaling pathway. *Biosci Trends* 2009; **3**: 151-157 [PMID: 20103840]
- 126 **Pierce JW**, Read MA, Ding H, Luscinskas FW, Collins T. Salicylates inhibit I  $\kappa$ B- $\alpha$  phosphorylation, endothelial-leukocyte adhesion molecule expression, and neutrophil transmigration. *J Immunol* 1996; **156**: 3961-3969 [PMID: 8621937]
- 127 **Zünd G**, Dzusz AL, Prêtre R, Niederhäuser U, Vogt P, Turina M. Endothelial cell injury in cardiac surgery: salicylate may be protective by reducing expression of endothelial adhesion molecules. *Eur J Cardiothorac Surg* 1998; **13**: 293-297 [PMID: 9628380]
- 128 **Lesniewski LA**, Durrant JR, Connell ML, Folian BJ, Donato AJ, Seals DR. Salicylate treatment improves age-associated vascular endothelial dysfunction: potential role of nuclear factor  $\kappa$ B and forkhead Box O phosphorylation. *J Gerontol A Biol Sci Med Sci* 2011; **66**: 409-418 [PMID: 21303813 DOI: 10.1093/gerona/gdq233]
- 129 **Isoda K**, Young JL, Zirlik A, MacFarlane LA, Tsuboi N, Gerdes N, Schönbeck U, Libby P. Metformin inhibits proin-

- inflammatory responses and nuclear factor-kappaB in human vascular wall cells. *Arterioscler Thromb Vasc Biol* 2006; **26**: 611-617 [PMID: 16385087]
- 130 **Cacicedo JM**, Yagihashi N, Keaney JF, Ruderman NB, Ido Y. AMPK inhibits fatty acid-induced increases in NF-kappaB transactivation in cultured human umbilical vein endothelial cells. *Biochem Biophys Res Commun* 2004; **324**: 1204-1209 [PMID: 15504342]
- 131 **Hattori Y**, Suzuki K, Hattori S, Kasai K. Metformin inhibits cytokine-induced nuclear factor kappaB activation via AMP-activated protein kinase activation in vascular endothelial cells. *Hypertension* 2006; **47**: 1183-1188 [PMID: 16636195]
- 132 **Huang NL**, Chiang SH, Hsueh CH, Liang YJ, Chen YJ, Lai LP. Metformin inhibits TNF-alpha-induced IkappaB kinase phosphorylation, IkappaB-alpha degradation and IL-6 production in endothelial cells through PI3K-dependent AMPK phosphorylation. *Int J Cardiol* 2009; **134**: 169-175 [PMID: 18597869 DOI: 10.1016/j.ijcard.2008.04.010]
- 133 **Wang Y**, Huang Y, Lam KS, Li Y, Wong WT, Ye H, Lau CW, Vanhoutte PM, Xu A. Berberine prevents hyperglycemia-induced endothelial injury and enhances vasodilatation via adenosine monophosphate-activated protein kinase and endothelial nitric oxide synthase. *Cardiovasc Res* 2009; **82**: 484-492 [PMID: 19251722 DOI: 10.1093/cvr/cvp078]
- 134 **Wu YH**, Chuang SY, Hong WC, Lai YJ, Chang GJ, Pang JH. Berberine reduces leukocyte adhesion to LPS-stimulated endothelial cells and VCAM-1 expression both in vivo and in vitro. *Int J Immunopathol Pharmacol* 2012; **25**: 741-750 [PMID: 23058024]
- 135 **Weber KS**, Draude G, Erl W, de Martin R, Weber C. Monocyte arrest and transmigration on inflamed endothelium in shear flow is inhibited by adenovirus-mediated gene transfer of IkappaB-alpha. *Blood* 1999; **93**: 3685-3693 [PMID: 10339475]
- 136 **Devaraj S**, Davis B, Simon SI, Jialal I. CRP promotes monocyte-endothelial cell adhesion via Fcgamma receptors in human aortic endothelial cells under static and shear flow conditions. *Am J Physiol Heart Circ Physiol* 2006; **291**: H1170-H1176 [PMID: 16603696]
- 137 **Piga R**, Naito Y, Kokura S, Handa O, Yoshikawa T. Short-term high glucose exposure induces monocyte-endothelial cells adhesion and transmigration by increasing VCAM-1 and MCP-1 expression in human aortic endothelial cells. *Atherosclerosis* 2007; **193**: 328-334 [PMID: 17097661]

**P- Reviewer:** Mihaila RG, Nasu K, Yang H **S- Editor:** Wen LL  
**L- Editor:** A **E- Editor:** Liu SQ



## Marjolin's ulcers in the post-burned lesions and scars

Muhammad Saaq, Bushra Ashraf

Muhammad Saaq, Bushra Ashraf, Pakistan Institute of Medical Sciences, Shaheed Zulfiqar Ali Bhutto Medical University, Islamabad 44000, Pakistan

**Author contributions:** Saaq M conceived and designed the format of the review; Saaq M and Ashraf B performed the literature search and participated in the analysis, interpretation and contextualization of the literature in writing the manuscript; the two authors critically reviewed, refined and approved the manuscript. Correspondence to: Muhammad Saaq, MBBS, FCPS, Assistant Professor, Pakistan Institute of Medical Sciences, Shaheed Zulfiqar Ali Bhutto Medical University, Room No. 20, MOs Hostel, Islamabad 44000, Pakistan. [muhammadsaaq5@gmail.com](mailto:muhammadsaaq5@gmail.com)  
Telephone: +92-341-5105173

Received: April 23, 2014 Revised: May 21, 2014

Accepted: August 27, 2014

Published online: October 16, 2014

### Abstract

Marjolin's ulcer (MU) represents malignant degeneration that typically ensues over a period of time in the post-burned lesions and scars or any other chronic wound. This review highlights various facets of the presentation and management of MUs that originate from post-burned lesions. The incidence of MUs in such lesions is reported to be 0.77%-2%. This malignancy characteristically develops in the areas of full thickness skin burns that had been allowed for weeks to months to heal spontaneously by secondary intention, or burn wounds which never healed completely over years and the unstable post-burned scars. In the majority of cases, the MU is a squamous cell carcinoma (SCC). The MUs contribute to an overall 2% of all SCCs and 0.03% of all basal cell carcinomas of the skin. Clinically MUs present in two major morphologic forms. The commoner form is the flat, indurated, ulcerative variety while the less common form is the exophytic papillary variety. Lower limbs represent the most frequently affected body parts. Surgical resection of the primary tumor with 2-4 cm horizontal clearance margin, nodal clearance and radiotherapy constitute the cornerstones of effective oncologic management. Despite best efforts, the overall mortality is reported to

be 21%.

© 2014 Baishideng Publishing Group Inc. All rights reserved.

**Key words:** Marjolin's ulcer; Malignant degeneration; Post-burned scars and wounds; Sentinel lymph node dissection; Squamous cell carcinoma; Full thickness skin burns; Healing by secondary intention

**Core tip:** This review on Marjolin's ulcer (MU) provides a comprehensive account of the key conceptual issues, historic background as well as recent updates on the management of MU developing in the post-burned lesions and scars. New concepts in the management in general and the evolving concepts in the prophylactic nodal treatment such as the sentinel lymph node mapping are highlighted. The epidemiologic and pathophysiologic factors that surround the development of MU in the post-burned lesions are described in vertical depth with subsequent emphasis on the preventive aspects, which certainly hold the key to eradication of this dreadful menace.

Saaq M, Ashraf B. Marjolin's ulcers in the post-burned lesions and scars. *World J Clin Cases* 2014; 2(10): 507-514 Available from: URL: <http://www.wjgnet.com/2307-8960/full/v2/i10/507.htm> DOI: <http://dx.doi.org/10.12998/wjcc.v2.i10.507>

### INTRODUCTION

Malignant degeneration of post-burned lesions and scars is an inevitable eventuality, afflicting at least 0.77%-2% of the deep burns that had been allowed to heal by secondary intention, those which never healed completely and the unstable post-burned scars that frequently ulcerate on trivial traumatic insults of daily life activities<sup>[1-3]</sup>. Celsus AC deserves acknowledgment for his earliest recognition of this phenomenon in the first century AD<sup>[4]</sup>. Later on in 1828, the French physician Marjolin JN etiologically classified ulcers as those due to "local" causes



and those secondary to “internal” causes, however he couldn't specifically recognize the malignant potential of these lesions<sup>[5,6]</sup>. Dupuytren<sup>[7]</sup> in 1839 provided full description of a case of amputation for a cancer in a patient who had suffered a sulfuric acid burn injury. Da Costa<sup>[8]</sup> in 1903 was the first to coin the term Marjolin's ulcer (MU) to describe malignant degeneration of skin scars particularly the post-burned scars.

Not surprisingly, MUs can emanate from any chronic wound or unhealed scar, however the neglected burn wounds constitute their commonest seats of origin<sup>[9-11]</sup>. The following review focuses on the epidemiological and clinical details of MU emanating in the aftermath of burn injuries with a view to provide a comprehensive summary of the key conceptual issues as well as recent updates on management for those who happen to be the frontline care providers for the patients with MU.

## EPIDEMIOLOGIC CONSIDERATIONS

Whereas 0.77%-2% of the post-burned wounds and scars are reported to undergo malignant degeneration<sup>[3]</sup>, overall the post-burned wounds and scars contribute to 2% of all squamous cell carcinomas (SCCs) and 0.03% of all basal cell carcinomas (BCCs) of the skin<sup>[4]</sup>.

MU is relatively commoner among males than females<sup>[12-15]</sup>. The exact explanation for this is not yet known, however more frequent initial burn trauma among males as well as their more prolonged exposure to sunlight are some of the possible contributors to this higher frequency of MU among males. No age is immune to MU with individuals from almost all age groups including children being afflicted worldwide<sup>[1-5]</sup>. MU has been reported among individuals of all races<sup>[16-20]</sup>.

There is usually a prolonged latency period between sustaining initial burn insult and developing MU in the post-burned wounds and scars. There is considerable variation in this lag period reported in the published literature<sup>[1,2,13,14]</sup>, ranging from as short as 6 wk<sup>[15]</sup> to as prolonged as 70 years<sup>[18]</sup>. The average latency period to malignant transformation is 35 years<sup>[1,21,22]</sup>. Based on the latency period, the MUs are subdivided into acute and chronic subtypes. The former type refers to the scar carcinoma that evolves within a year of sustaining burn injury, while the later type refers to those that develop from then on<sup>[22]</sup>. The acute MU usually develops in association with more superficial burn scars and is often a basal cell carcinoma on histology<sup>[23]</sup>. The latency period of MU inversely relates to the patient's age at the time of sustaining initial burn insult<sup>[24]</sup>. The younger the patient is at the time of initial burn insult, the longer the time it takes to undergo the malignant transformation. Contrary to this, the older the patient at the time of burn injury the shorter the lag period and more is the chance of acute MU. Understandably, a newly acquired burn injury in an adult of advancing age is more likely to evolve an acute MU, hence a biopsy of all such lesions (of a duration of > 6 wk) is imperative.

Although all underlying mechanisms of burn injury pose an equal risk for subsequent malignant transformation, MU has been reported more frequently among those who had sustained flame burns as compared to the other burn injury mechanisms such as scalds, electric burn injuries, chemical burns, and contact burns. Except for the BCC where contact is the most frequent underlying burn injury mechanism, the other histological types of MU occur with equal frequency amongst flame, scalds and contact burn injuries<sup>[2]</sup>.

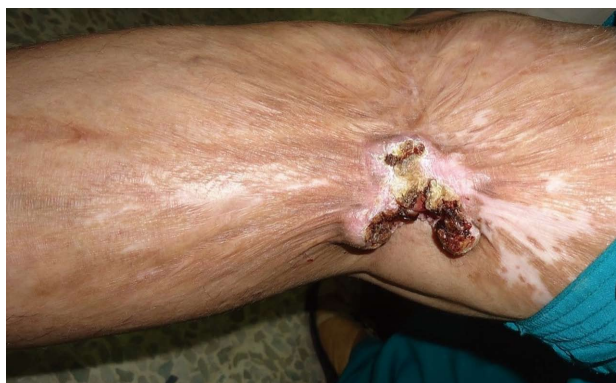Given the global statistics, the burden of burn injuries is disproportionately shared across the globe with most of its brunt being taken by the developing nations such as India, Bangladesh and Pakistan<sup>[25]</sup>. These countries together with other south Asian countries like Sri Lanka, Bhutan, Nepal, Maldives, and Afghanistan collectively constitute 20% of the world's population, however they contributed only 1.1% of the total PubMed publications during the 25 years period from 1985-2009<sup>[26]</sup>. One can easily imagine the magnitude of MU that certainly exists in these burn injury endemic countries but is under-reported. These developing nations have recognized limitations of their health care systems where the ideal treatment for acute burn injuries is often not instituted<sup>[27]</sup>. Also many of the patients in these developing countries present late, when the MU is not amenable to curative resection.

## PATHOLOGIC CONSIDERATIONS

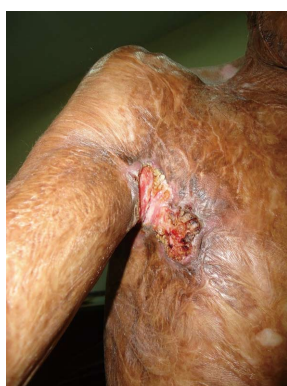### *Etioopathogenesis of MU*

MUs originating from post-burned scars possess certain peculiarities that make them distinct from other cutaneous malignancies. The exact mechanism of how the malignant transformation supervenes the post-burned scars continues to be explored. Many theories have been proposed to provide possible explanations of the mechanisms involved, however no single theory alone can provide a satisfactory answer to all questions that surround this complex process of malignant degeneration.

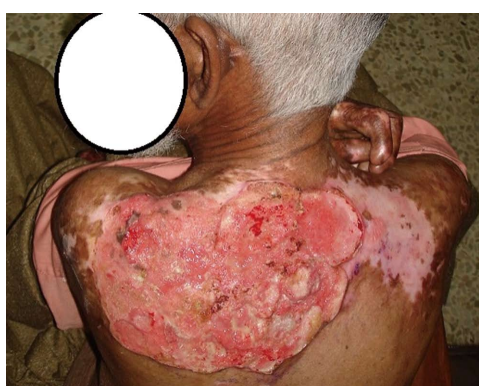As per Ewing J's postulates<sup>[2,28]</sup>, MU of post-burned scars would meet the criteria such as evidence of a burn scar, tumour within the boundaries of the scar, no previous tumour in that location, tumour histology being compatible with the cell types found in the skin/scar and presence of a lag period between the burn injury and the tumour development. The post-burned scars is certainly a mutogenic focus with continuous mitotic activity of regeneration and repair being in progress. The same represents the key mechanism that eventually triggers the malignant transformation<sup>[10,29,30]</sup>. A myriad of factors have been postulated as possible contributors toward the process of malignant transformation. Among these include chronic irritation, repeated trauma, impaired immunologic reactivity of the scar tissue to tumour cells, release of toxins from the unhealthy scar, relative avascularity of the scar tissue, lymphatic obstruction within the scar tissue making it an inaccessible site for the body's natural



**Figure 1** Marjolin's ulcer in the left popliteal fossa region in a 45 years old lady who had sustained flame burn injury at the age of 13. There is characteristic ulcer with everted edges and poorly granulating floor. The surrounding skin shows post-burned sequel. Histopathology confirmed it to be well differentiated squamous cell carcinoma.



**Figure 2** A 46 years male with 3 years history of ulceration and bleeding in right axilla. He had sustained scald burns at the age of 3. Biopsy confirmed it to be squamous cell carcinoma while computed tomography scan revealed metastasis in the axilla as well as chest.



**Figure 3** A 63 years old male presented with two years history of slowly progressive ulceration in the post burned white skin on his upper back. He had childhood scald burns at the age of 3 years, and had received burn injury treatment with months of dressings without skin grafting. Multiple biopsies revealed squamous cell carcinoma, while computed tomography scan revealed axillary nodal invasion without chest metastasis. Culture sensitivity revealed Methicillin resistant staphylococcus and pseudomonas aeruginosa.

immunosurveillance<sup>[2,10,31,32]</sup>. When the full thickness skin loss areas are allowed to heal by secondary intention,

there is formation of unstable depigmented substitution tissue which lacks the qualities of normal skin. These unstable depigmented scars have reduced ability to withstand carcinogens<sup>[4,32]</sup>. Whether genetics or heredity have any contribution to the malignant degeneration of the post-burned scars is not exactly known, however abnormalities in the *p53* gene among these patients have been reported<sup>[33,34]</sup>.

The major risk factors for the development of post-burn MU include healing of full thickness skin burns by secondary intention, non-healing burn wounds, and fragile scars that ulcerate and are easily traumatized<sup>[1,2]</sup>. The post-burned scars is typically less resistant to injuries, heals poorly especially in body areas such as the joints.

### Histopathology of MU

In most cases, the MU is an SCC (71%), followed by BCC (12%), melanoma (6%), sarcoma (5%), squamo-basal cell carcinoma (1%), SCC-melanoma (1%) and other rare neoplasms (4%)<sup>[2]</sup>. A variety of rare tumours may emerge in the post-burned wounds and scars and include fibrosarcoma, liposarcoma, dermatofibrosarcoma protuberans, and mesenchymal tumors<sup>[2,3,35,36]</sup>. The grade of the MU can be defined as follows: grade I : more than 75% of the cells are differentiated; grade II : 25%-75% of the cells are differentiated; grade III: less than 25% of the cells are differentiated<sup>[10]</sup>. Grade of the tumour has bearing on the prognosis of MU. In general, the incidence of metastasis increases with increasing grade and so is the worsening of prognosis.

## CLINICAL COSIDERATIONS

### Clinical presentation

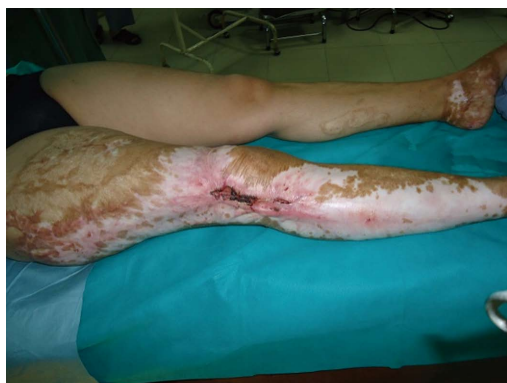Clinically MU presents in two major morphologic forms<sup>[18,37]</sup>. The commoner form is the flat, indurated, infiltrative, ulcerative variant while the other less frequent form is the exophytic papillary variety which is generally less severe. The well-differentiated exophytic lesions have a better prognosis than the poorly differentiated, ulcerated and infiltrating forms. Typically the edge of the ulcerated lesion is everted and the floor has poor granulation tissue (Figures 1-9 are representative photographs of some patients with MUs secondary to burn injuries).

A history of a non healing post-burned wound of full thickness skin loss should alert the clinician of the possibility of an MU. It is usually painless. The easy bleeding fragile areas may at times present with unprovoked bleeding, offensive discharge or increasing pain. Superadded infection of the wound may at times be the first clinical presentation<sup>[18,38,39]</sup>.

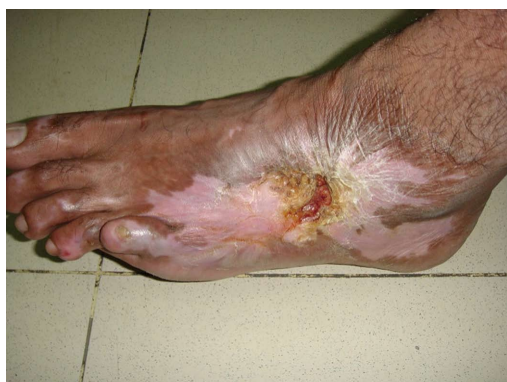### Anatomic sites affected by MUs

Lower limbs constitute the most frequent site of MUs. The other sites affected in order of reducing frequency include head and neck region (face, scalp, neck), upper limbs and other body parts<sup>[2,3,35]</sup>. MU has been reported in post burned scars at rare locations such as the nose<sup>[40]</sup>.

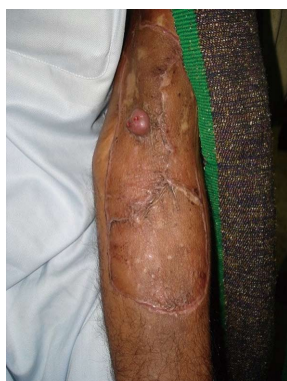



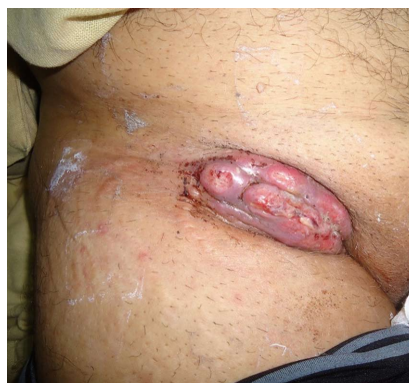**Figure 4** A lady aged 41, had sustained burn injury secondary to lightning 3 years ago. She had her burn injuries managed with months of dressing without skin grafting. Subsequently she had recurrent ulceration with bleeding from the unhealed wounds around the knee. Multiple biopsies of the lesions revealed well differentiated squamous cell carcinoma. The groin nodal basin was negative clinically as well as radiologically.



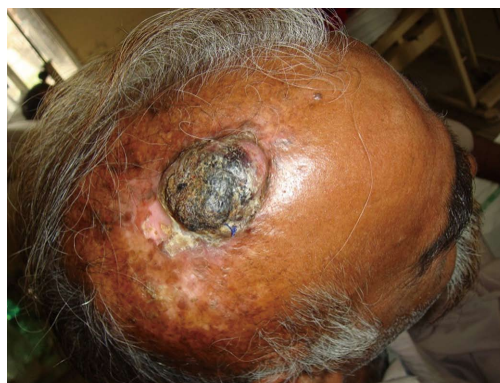**Figure 5** A 41 years male who had sustained flame burn injury to his left foot in childhood at the age of 4. The burn injury was managed with months of dressings and the wound never healed completely. There was history of recurrent bleeding and ulceration on the affected site. Multiple biopsies revealed moderately differentiated squamous cell carcinoma. The groin was clinically node positive.



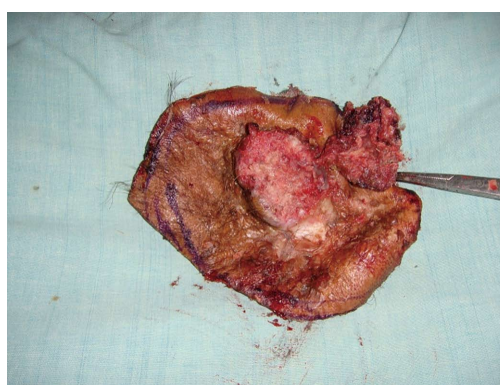
**Figure 6** A 36 years male had sustained chemical burn injury to his left cubital fossa 7 years ago. The initial burn injury was managed with dressings and had never healed completely. The patient had undergone wide local excision and split thickness skin grafting for Marjolin's ulcer three months ago. Later he presented with a recurrent nodule which was confirmed as squamous cell carcinoma on histopathology while the axilla was node negative clinically.



**Figure 7** Right groin metastasis secondary to Marjolin's ulcer on the right side of ankle in 57 years male. Metastatic work up revealed ascites and lung metastasis. The patient had sustained flame burn injury to the right ankle at the age of 2 years and was managed with wound dressings without skin grafting.



**Figure 8** A 47 years male had sustained flame burn injury to his scalp at the age of 3. The initial burn injury was managed with months of dressings without skin grafting. Histopathology confirmed it as well differentiated squamous cell carcinoma. Computed tomography scan head and neck did not show deep structures invasion.



**Figure 9** Same patient (as in Figure 8), the resected Marjolin's ulcer with wide local margins.

Lower limbs are the commonest sites of MU primarily owing to their more frequent involvement in burn injury insults involving full thickness skin loss. Additionally these patients often present with lesions around the knee

joints as the joints are frequently moved and recurrent ulcerations commonly ensue and persist without healing.

### Diagnosis of MU

The diagnosis of MU is based on the suggestive findings in the patient's history, detailed examination of the ulcer and its draining nodal basin, and the histology of the lesion.

The classic triad of nodule formation, induration, and ulceration at the post-burned scars should prompt a biopsy to confirm the diagnosis<sup>[41]</sup>. Other clinical signs suggestive of MU include everted or rolled margins, exophytic granulation tissue formation, increasing size, bleeding and regional lymphadenopathy<sup>[1-10]</sup>.

Once the biopsy confirms the diagnosis of MU, determination of the local extent of the lesion and staging comes to the fore. An magnetic resonance imaging (MRI) or computed tomography (CT scan) is performed to determine the local extent of the lesion and invasion of any underlying structures. MRI is certainly the ideal imaging tool for evaluation of the status of the soft-tissues, infiltration of any underlying bone and the involvement of adjacent neurovascular structures<sup>[42-44]</sup>.

The draining lymphatic basin is staged clinically as well as radiologically with either high resolution ultrasonography, MRI or CT scan. Given the aggressive nature of MU, distant metastasis are ruled out with metastatic work up that includes chest CT scan, abdominal ultrasonography and CT scan brain (for lesions on the scalp and face)<sup>[1-10]</sup>.

### Metastatic spread of the MU and the stage of the MU disease

By and large, as long as the MU is confined to the scar it shows typically slow growth and is amenable to curative resection. However when the MU breaks free of the scar it metastasises rapidly *via* lymphatic spread<sup>[31]</sup>. Once broken free of the confines of the primary lesion, an SCC of the MU variety is known to possess greater metastatic potential than the SCC occurring *de novo*<sup>[18]</sup>. At presentation, regional lymph nodes are involved in 20%-36% of the patients<sup>[2,18,37,45]</sup>. Aydoğdu *et al.*<sup>[18]</sup> have reported even higher percentage of patients (66.66%) with involved regional lymph nodes, dura or bone at initial presentation. Distant metastases are reported among 14% of the patients<sup>[2]</sup>. Although metastatic spread is primarily to the regional lymph nodes, metastasis to organs such as the liver, lung, brain, kidney may also occur<sup>[18]</sup>.

Stage of the MU has implications for the management as well as the prognosis. As is the case with other malignancies, staging is performed by considering the size of the primary lesion (T), lymph node involvement (N), and distant metastasis (M). As yet there is no MU specific TNM classification of the Union for International cancer control, however the TNM classification for SCC is commonly applied to the MU.

## TREATMENT OF MU

### Role of surgery

Surgery constitutes the mainstay of treatment of the MU.

The oncologic clearance entails excision of the primary lesion with a 2-4 cm horizontal clearance margins, and vertical clearance of the un-involved next barrier structure. All the wide local excisions are preferably performed initially with cautery dissection to prevent seeding of the tumor cells and their iatrogenic spread into the blood and lymphatic streams. Additionally a small margin of skin is then excised with a surgical scalpel to ensure good healing<sup>[14,20,35]</sup>. It is prudent to have the histopathologist on-board when performing such crucial resections to ensure resection of tumour free margins with the help of frozen section studies performed simultaneously with surgery. The defects resulting from MU extirpation are either skin grafted or flap covered. Anecdotally we are now preferring flap coverage of the resultant defects where ever possible and subsequently offer the patients radiotherapy for the tumor bed with the help of radiation oncologist.

As is the established norm of surgical oncology, the clinically or radiologically confirmed involved nodal basins are managed with therapeutic lymph node dissection.

Although there is lack of general consensus regarding management of the clinically negative nodal basins in MU, yet given the aggressive biologic behavior of MU, prophylactic nodal treatment with either elective lymph node dissection or regional nodal irradiation sounds rational<sup>[31,37,46-48]</sup>. Long term studies are certainly needed to confirm if this aggressive approach offers real benefits in terms of disease free survival or not, as the formal nodal clearance has its own morbidity (particularly lymphedema) attended to the procedure.

The sentinel lymph node dissection (SLND) has been primarily employed for staging the regional nodal basins in malignant melanoma of the limbs, however there is a recent growing recognition of its utility among patients with non-melanoma skin cancers also<sup>[49-54]</sup>. SLND technique holds the potential to be used more frequently in MU patients as it on one hand will save MU patients from the unnecessary morbidity of formal nodal clearance for negative nodes and on the other hand identify the MU patients who are clinically node negative but have subclinical nodal metastasis.

### Role of radiotherapy

Given the aggressive biological behaviour of the MU and the frequent squamous cell histology, radiotherapy finds an important adjunctive role in managing these malignancies. The indications for radiotherapy include: (1) inoperable regional lymph node metastasis; (2) grade 3 lesions with positive lymph nodes after nodal dissection; (3) tumors with a diameter greater than 10 cm and with positive lymph nodes after regional lymph node dissection; (4) grade 3 lesions with a tumor diameter greater than 10 cm and negative lymph nodes after regional lymph node dissection; and (5) lesions of the head and neck with positive lymph nodes after regional lymph node dissection<sup>[46]</sup>.

### Role of chemotherapy

The exact role of chemotherapy or indications thereof in managing MU are not yet established, however che-



motherapy constitutes part of the aggressive multimodal therapy which is often instituted among patients when surgical extirpation of the MU is not possible because of the unfit patient, presence of distant metastasis, recurrent disease, and patients not consenting for surgery.

The chemotherapy is usually based on 5-Fluorouracil with a combination of cisplatin, methotrexate and bleomycin. It may be in the form of adjuvant or neo adjuvant therapy<sup>[18]</sup>.

## PROGNOSIS

Generally speaking, the MU tends to be more aggressive and rapidly spreading as compared to other skin carcinomas of similar histotypes<sup>[1,55]</sup>. The overall mortality rate of MU is reported to be at least 21%<sup>[2]</sup>. The survival rates of MU are 52%, 34% and 23% at 5, 10 and 20 years<sup>[56]</sup>.

Poor prognostic clinical features in MU include regional nodal spread, local extension of lesion, lower limb lesions (as these have a greater propensity for nodal involvement), infiltrative variety, primary lesions of  $\geq 2$  cm, latency period of  $\geq 5$  years, recurrent MU, and the presence of distant metastasis. The poor prognostic indicators on histology include poor differentiation, scarce or absent peritumour T cell infiltration, invasion of reticular dermis or deeper structures, and  $\geq 4$  mm vertical thickness of the neoplastic lesion<sup>[4,37,46,55-60]</sup>.

## PREVENTION

Although MU constitutes a formidable foe for reconstructive and burns surgeons around the globe, it is still surmountable to primary as well as secondary prevention. Early excision and grafting of deep burns adequately averts all the wound problems that otherwise predispose the post-burned scars to malignant transformation<sup>[61]</sup>. Moreover even if an initially neglected or mismanaged burn wound presents later with ulceration or frequent wounding, before any malignancy has set in, the choice of excision and grafting of these unstable scars should still be availed. So primary prevention is ensured by provision of adequate surgical care in the acute phase of burn injury management, while secondary prevention can be instituted where a patient had an initial mismanagement but seeks medical advice before MU has established.

## CONCLUSION

MU is a largely preventable dreadful menace of considerable morbidity and mortality. Although over the years, significant progress has been made in managing MU, the key to successful eradication lies in prevention by ensuring adequate surgical care (with early excision and grafting) of the deep burns in their acute phase.

There is need for randomized controlled trials and high quality evidence on the not yet fully established aspects of the MU management such as the oncologically safe horizontal clearance margins of resection, prophylactic management of the negative nodal basins and MU

specific TNM staging system. All these issues need be adequately addressed by future clinical studies.

## REFERENCES

- 1 **Copcu E.** Marjolin's ulcer: a preventable complication of burns? *Plast Reconstr Surg* 2009; **124**: 156e-164e [PMID: 19568055 DOI: 10.1097/PRS.0b013e3181a8082e]
- 2 **Kowal-Vern A, Criswell BK.** Burn scar neoplasms: a literature review and statistical analysis. *Burns* 2005; **31**: 403-413 [PMID: 15896501 DOI: 10.1016/j.burns.2005.02.015]
- 3 **Fleming MD, Hunt JL, Purdue GF, Sandstad J.** Marjolin's ulcer: a review and reevaluation of a difficult problem. *J Burn Care Rehabil* 1990; **11**: 460-469 [PMID: 2246317]
- 4 **Treves N, Pack GT.** The development of cancer in burn scars: An analysis and report of thirty-four cases. *Surg Gynecol Obstet* 1930; **51**: 749-751
- 5 **Marjolin JN.** *Ulcere Dictionnaire de medecine.* Paris: Bechet, 1828: 21
- 6 **Steffen C.** Marjolin's ulcer. Report of two cases and evidence that Marjolin did not describe cancer arising in scars of burns. *Am J Dermatopathol* 1984; **6**: 187-193 [PMID: 6375422]
- 7 **Dupuytren G.** *Lecons orales de clinique chirurgicale.* 2nd ed. Paris, 1839
- 8 **Da Costa JC.** III. Carcinomatous Changes in an Area of Chronic Ulceration, or Marjolin's Ulcer. *Ann Surg* 1903; **37**: 496-502 [PMID: 17861272]
- 9 **Yu N, Long X, Lujan-Hernandez JR, Hassan KZ, Bai M, Wang Y, Wang X, Zhao R.** Marjolin's ulcer: a preventable malignancy arising from scars. *World J Surg Oncol* 2013; **11**: 313 [PMID: 24341890]
- 10 **Pekarek B, Buck S, Osher L.** A Comprehensive Review on Marjolin's Ulcers: Diagnosis and Treatment. *J Am Col Certif Wound Spec* 2011; **3**: 60-64 [PMID: 24525526 DOI: 10.1016/j.jcws.2012.04.001]
- 11 **Kerr-Valentic MA, Samimi K, Rohlen BH, Agarwal JP, Rockwell WB.** Marjolin's ulcer: modern analysis of an ancient problem. *Plast Reconstr Surg* 2009; **123**: 184-191 [PMID: 19116552 DOI: 10.1097/PRS.0b013e3181904d86]
- 12 **Lawrence EA.** Carcinoma arising in the scars of thermal burns, with special reference to the influence of the age at burn on the length of the induction period. *Surg Gynecol Obstet* 1952; **95**: 579-588 [PMID: 12995250]
- 13 **Saraiya HA.** A very large Marjolin's ulcer on back without lymph node metastasis. *Indian J Plast Surg* 2013; **46**: 156-158 [PMID: 23960332 DOI: 10.4103/0970-0358.113744]
- 14 **Daya M, Balakrishnan T.** Advanced Marjolin's ulcer of the scalp in a 13-year-old boy treated by excision and free tissue transfer: Case report and review of literature. *Indian J Plast Surg* 2009; **42**: 106-111 [PMID: 19881030 DOI: 10.4103/0970-0358.53020]
- 15 **Mohammadi AA, Seyed Jafari SM, Hosseinzadeh M.** Early Marjolin's Ulcer after Minimal Superficial Burn. *Iran J Med Sci* 2013; **38**: 69-70 [PMID: 23645962]
- 16 **Al-Zacko SM.** Malignancy in chronic burn scar: a 20 year experience in Mosul-Iraq. *Burns* 2013; **39**: 1488-1491 [PMID: 23768719]
- 17 **Nthumba PM.** Marjolin's ulcers in sub-Saharan Africa. *World J Surg* 2010; **34**: 2272-2277 [PMID: 20645092]
- 18 **Aydoğdu E, Yildirim S, Aköz T.** Is surgery an effective and adequate treatment in advanced Marjolin's ulcer? *Burns* 2005; **31**: 421-431 [PMID: 15896503]
- 19 **Pieptu D, Luchian S, Copăceanu M, Popa M, Hriscu M, Stătescu C.** [Marjolin's ulcer on burn scar, a curable but neglected disease]. *Rev Med Chir Soc Med Nat Iasi* 2000; **104**: 95-99 [PMID: 12089970]
- 20 **Ghalambor A.** Marjolin ulcer: How much of safety margin needs resection along Marjolin ulcer squamous cell carcinoma in recurrence cases? *Pak J Med Sci* 2007; **23**: 394-397
- 21 **Kasse AA, Betel E, Dem A, Diop M, Fall MC, Diop PS, Dem**

- bele B, Drabo B, Timbely G, Neloum J, Toure P. [Cancers in the scars of thermal burns (apropos of 67 cases)]. *Dakar Med* 1999; **44**: 206-210 [PMID: 11957286]
- 22 **Guenther N**, Menenakos C, Braumann C, Buettemeyer R. Squamous cell carcinoma arising on a skin graft 64 years after primary injury. *Dermatol Online J* 2007; **13**: 27 [PMID: 17498446]
- 23 **Love RL**, Breidahl AF. Acute squamous cell carcinoma arising within a recent burn scar in a 14-year-old boy. *Plast Reconstr Surg* 2000; **106**: 1069-1071 [PMID: 11039378 DOI: 10.1097/00006534-200010000-00017]
- 24 **Copcu E**, Aktas A, Sisman N, Oztan Y. Thirty-one cases of Marjolin's ulcer. *Clin Exp Dermatol* 2003; **28**: 138-141 [PMID: 12653697 DOI: 10.1046/j.1365-2230.2003.01210.x.PubMed]
- 25 **Saaiq M**, Ashraf B. Epidemiology and Outcome of Self-Inflicted Burns at Pakistan Institute of Medical Sciences, Islamabad. *World J Plast Surg* 2014; **3**: 107-114 Available from: URL: [http://www.wjps.ir/browse.php?a\\_code=A-10-53-2&slc\\_lang=en&sid=1](http://www.wjps.ir/browse.php?a_code=A-10-53-2&slc_lang=en&sid=1)
- 26 **Azim Majumder MA**, Shaban SF, Rahman S, Rahman N, Ahmed M, Bin Abdulrahman KA, Islam Z. PubMed-based quantitative analysis of biomedical publications in the SAA-RC countries: 1985-2009. *J Coll Physicians Surg Pak* 2012; **22**: 560-564 [PMID: 22980608]
- 27 **Saaiq M**, Zaib S, Ahmad S. The menace of post-burn contractures: a developing country's perspective. *Ann Burns Fire Disasters* 2012; **25**: 152-158 [PMID: 23466805]
- 28 **Ewing J**. Neoplastic disease. 3rd ed. Philadelphia: WB Saunders, 1928: 862
- 29 **Asuquo M**, Ugare E, Ebughe G, Jibril P. Marjolin's ulcer: the importance of surgical management of chronic cutaneous ulcers. *Int J Dermatol* 2007; **46** Suppl 2: 29-32 [PMID: 17958627]
- 30 **Türegün M**, Nişanci M, Güler M. Burn scar carcinoma with longer lag period arising in previously grafted area. *Burns* 1997; **23**: 496-497 [PMID: 9429029]
- 31 **Bostwick J**, Pendergrast WJ, Vasconez LO. Marjolin's ulcer: an immunologically privileged tumor? *Plast Reconstr Surg* 1976; **57**: 66-69 [PMID: 1244613]
- 32 **Sirsat MV**, Shrikhande SS. Histochemical studies on squamous cell carcinoma of the skin arising in burn scars with special reference to histogenesis. *Indian J Cancer* 1966; **3**: 157-169 [PMID: 5917023]
- 33 **Harland DL**, Robinson WA, Franklin WA. Deletion of the p53 gene in a patient with aggressive burn scar carcinoma. *J Trauma* 1997; **42**: 104-107 [PMID: 9003266]
- 34 **Hayashi M**, Tamura G, Kato N, Ansai S, Kondo S, Motoyama T. Genetic analysis of cutaneous squamous cell carcinomas arising from different areas. *Pathol Int* 2003; **53**: 602-607 [PMID: 14507317]
- 35 **Ochenduszkiewicz U**, Matkowski R, Szynglarewicz B, Kornafel J. Marjolin's ulcer: malignant neoplasm arising in scars. *Rep Pract Oncol Radiother* 2006; **11**: 135-138
- 36 **Gamatsi IE**, McCulloch TA, Bailie FB, Srinivasan JR. Malignant melanoma in a skin graft: burn scar neoplasm or a transferred melanoma? *Br J Plast Surg* 2000; **53**: 342-344 [PMID: 10876262]
- 37 **Novick M**, Gard DA, Hardy SB, Spira M. Burn scar carcinoma: a review and analysis of 46 cases. *J Trauma* 1977; **17**: 809-817 [PMID: 909123]
- 38 **Nancarrow JD**. Cicatricial cancer in the South-West of England: a regional plastic surgery unit's experience over a 20-year period. *Br J Surg* 1983; **70**: 205-208 [PMID: 6831171]
- 39 **Hahn SB**, Kim DJ, Jeon CH. Clinical study of Marjolin's ulcer. *Yonsei Med J* 1990; **31**: 234-241 [PMID: 2281683]
- 40 **Copcu E**, Culhaci N. Marjolin's ulcer on the nose. *Burns* 2002; **28**: 701-704 [PMID: 12417171]
- 41 **Beachkofsky TM**, Wisco OJ, Owens NM, Hodson DS. Verrucous nodules on the ankle: the scaly nodules appeared over the staple sites of a previous surgery. But did one have anything to do with the other? *J Fam Pract* 2009; **58**: 427-430
- 42 **Sawhney S**, Jain R, Kakaria A, Chopra P. Marjolin's Ulcer: Radiographic and magnetic resonance appearances in two cases. *Sultan Qaboos Univ Med J* 2009; **9**: 162-166 [PMID: 21509294]
- 43 **Chiang KH**, Chou AS, Hsu YH, Lee SK, Lee CC, Yen PS, Ling CM, Lee WH, Lin CC, Chang PY. Marjolin's ulcer: MR appearance. *AJR Am J Roentgenol* 2006; **186**: 819-820 [PMID: 16498113]
- 44 **Smith J**, Mello LF, Nogueira Neto NC, Meohas W, Pinto LW, Campos VA, Barcellos MG, Fiod NJ, Rezende JF, Cabral CE. Malignancy in chronic ulcers and scars of the leg (Marjolin's ulcer): a study of 21 patients. *Skeletal Radiol* 2001; **30**: 331-337 [PMID: 11465774]
- 45 **Dupree MT**, Boyer JD, Cobb MW. Marjolin's ulcer arising in a burn scar. *Cutis* 1998; **62**: 49-51 [PMID: 9675536]
- 46 **Ozek C**, Cankayali R, Bilkay U, Guner U, Gundogan H, Songur E, Akin Y, Cagdas A. Marjolin's ulcers arising in burn scars. *J Burn Care Rehabil* 2001; **22**: 384-389 [PMID: 11761388]
- 47 **Ozek C**, Celik N, Bilkay U, Akalin T, Erdem O, Cagdas A. Marjolin's ulcer of the scalp: report of 5 cases and review of the literature. *J Burn Care Rehabil* 2001; **22**: 65-69 [PMID: 11227688]
- 48 **Wagner JD**, Evdokimow DZ, Weisberger E, Moore D, Chuang TY, Wenck S, Coleman JJ. Sentinel node biopsy for high-risk nonmelanoma cutaneous malignancy. *Arch Dermatol* 2004; **140**: 75-79 [PMID: 14732663]
- 49 **Cobey FC**, Engrav LH, Klein MB, Isom CN, Byrd DR. Brief report: sentinel lymph node dissection and burn scar carcinoma sentinel node and burn scar carcinoma. *Burns* 2008; **34**: 271-274 [PMID: 17374455]
- 50 **Eastman AL**, Erdman WA, Lindberg GM, Hunt JL, Purdue GF, Fleming JB. Sentinel lymph node biopsy identifies occult nodal metastases in patients with Marjolin's ulcer. *J Burn Care Rehabil* 2004; **25**: 241-245 [PMID: 15273464]
- 51 **Michl C**, Starz H, Bachter D, Balda BR. Sentinel lymphonodectomy in nonmelanoma skin malignancies. *Br J Dermatol* 2003; **149**: 763-769 [PMID: 14616367]
- 52 **Reschly MJ**, Messina JL, Zaulyanov LL, Cruse W, Fenske NA. Utility of sentinel lymphadenectomy in the management of patients with high-risk cutaneous squamous cell carcinoma. *Dermatol Surg* 2003; **29**: 135-140 [PMID: 12562341]
- 53 **Shoaib T**, Soutar DS, MacDonald DG, Camilleri IG, Dunaway DJ, Gray HW, McCurrach GM, Bessent RG, MacLeod TI, Robertson AG. The accuracy of head and neck carcinoma sentinel lymph node biopsy in the clinically N0 neck. *Cancer* 2001; **91**: 2077-2083 [PMID: 11391588]
- 54 **de Hullu JA**, Hollema H, Piers DA, Verheijen RH, van Diest PJ, Mourits MJ, Aalders JG, van Der Zee AG. Sentinel lymph node procedure is highly accurate in squamous cell carcinoma of the vulva. *J Clin Oncol* 2000; **18**: 2811-2816 [PMID: 10920128]
- 55 **Møller R**, Reymann F, Hou-Jensen K. Metastases in dermatological patients with squamous cell carcinoma. *Arch Dermatol* 1979; **115**: 703-705 [PMID: 453871]
- 56 **Edwards MJ**, Hirsch RM, Broadwater JR, Netscher DT, Ames FC. Squamous cell carcinoma arising in previously burned or irradiated skin. *Arch Surg* 1989; **124**: 115-117 [PMID: 2910238]
- 57 **Fishman JR**, Parker MG. Malignancy and chronic wounds: Marjolin's ulcer. *J Burn Care Rehabil* 1991; **12**: 218-223 [PMID: 1885637]
- 58 **Friedman HI**, Cooper PH, Wanebo HJ. Prognostic and therapeutic use of microstaging of cutaneous squamous cell carcinoma of the trunk and extremities. *Cancer* 1985; **56**: 1099-1105 [PMID: 4016700]
- 59 **Phillips TJ**, Salman SM, Bhawan J, Rogers GS. Burn scar carcinoma. Diagnosis and management. *Dermatol Surg* 1998; **24**: 561-565 [PMID: 9598012]
- 60 **Nthumba PM**. Marjolin's ulcers: theories, prognostic factors

and their peculiarities in spina bifida patients. *World J Surg Oncol* 2010; **8**: 108 [PMID: 21129225]

61 **Saaq M**, Zaib S, Ahmad S. Early excision and grafting ver-

sus delayed excision and grafting of deep thermal burns up to 40% total body surface area: a comparison of outcome. *Ann Burns Fire Disasters* 2012; **25**: 143-147 [PMID: 23467391]

**P- Reviewer:** Stanojevic GZ **S- Editor:** Wen LL  
**L- Editor:** A **E- Editor:** Liu SQ



## Gallbladder cancer: Clinical and pathological approach

Keita Kai, Shinichi Aishima, Kohji Miyazaki

Keita Kai, Shinichi Aishima, Department of Pathology and Microbiology, Faculty of Medicine, Saga University, Saga City, Saga 849-8501, Japan

Keita Kai, Department of Pathology, Saga University Hospital, Saga City, Saga 849-8501, Japan

Kohji Miyazaki, Department of Surgery, Faculty of Medicine, Saga University, Saga City, Saga 849-8501, Japan

Author contributions: Kai K, Aishima S and Miyazaki K contributed to this paper.

Correspondence to: Dr. Keita Kai, Department of Pathology, Saga University Hospital, 5-1-1 Nabesima, Saga City, Saga 849-8501, Japan. [kaikit@cc.saga-u.ac.jp](mailto:kaikit@cc.saga-u.ac.jp)

Telephone: +81-952-342234 Fax: +81-952-342055

Received: March 22, 2014 Revised: May 15, 2014

Accepted: July 18, 2014

Published online: October 16, 2014

### Abstract

Gallbladder cancer (GBC) shows a marked geographical variation in its incidence. Middle-aged and elderly women are more commonly affected. Risk factors for its development include the presence of gallstones, chronic infection and pancreaticobiliary maljunction. Controversy remains in regard to the theory of carcinogenesis from adenomyomatosis, porcelain gallbladder and adenoma of the gallbladder. The surgical strategy and prognosis after surgery for GBC differ strikingly according to T-stage. Discrimination of favorable cases, particularly T2 or T3 lesions, is useful for the selection of surgical strategies for individual patients. Although many candidate factors predicting disease progression, such as depth of subserosal invasion, horizontal tumor spread, tumor budding, dedifferentiation, Ki-67 labeling index, p53 nuclear expression, CD8+ tumor-infiltrating lymphocytes, mitotic counts, Laminin-5-gamma-2 chain, hypoxia-inducible factor-1a, cyclooxygenase-2 and the Hedgehog signaling pathway have been investigated, useful prognostic makers or factors have not been established. As GBC is often discovered incidentally after routine cholecystectomy and accurate preoperative diagnosis is difficult, close mutual cooperation between surgeons and pathologists is essential for developing a

rational surgical strategy for GBC.

© 2014 Baishideng Publishing Group Inc. All rights reserved.

**Key words:** Gallbladder cancer; Surgical strategy; Pathology; Prognostic factors

**Core tip:** This review has documented the basic knowledge and surgical strategies for gallbladder cancer (GBC) based on the clinical and pathological data from previous studies. Discrimination of favorable cases, particularly T2 or T3 lesions, is useful for the selection of surgical strategies for individual patients. As GBC is often discovered incidentally after routine cholecystectomy and accurate preoperative diagnosis is difficult, close mutual cooperation between surgeons and pathologists is essential for developing a rational surgical strategy for GBC.

Kai K, Aishima S, Miyazaki K. Gallbladder cancer: Clinical and pathological approach. *World J Clin Cases* 2014; 2(10): 515-521 Available from: URL: <http://www.wjgnet.com/2307-8960/full/v2/i10/515.htm> DOI: <http://dx.doi.org/10.12998/wjcc.v2.i10.515>

### EPIDEMIOLOGY

Gallbladder cancer (GBC) has a distinctly higher incidence in certain demographic groups and areas. Women are affected three times more often than men, and the vast majority of patients with GBC are older than 40 years of age. A high incidence has been reported in women in countries such as Chile, Poland, India, Israel, Pakistan, Ecuador, South Korea and Japan, whereas GBC is considered a rare neoplasm in most Western countries and the United States<sup>[1-4]</sup>.

### RISK FACTORS

Gallstones are a well-known risk factor for GBC<sup>[5,6]</sup>. It has been reported that a large stone size of more than 3



cm, a family history of GBC, and prolonged cholelithiasis are potential risk factors for GBC<sup>[7-9]</sup>. These factors could be used in the decision making when performing a cholecystectomy for asymptomatic gallstones. However, no definite evidence of a direct causal relationship between gallstones and gallbladder cancer has been presented and biases of other risk factors remain unsolved problems<sup>[10]</sup>. The composition and mutagenicity of gallstones have previously been studied with inconclusive results<sup>[11]</sup>. A prospective study of 123 consecutive patients with asymptomatic gallstones who were followed-up for 10 years or longer revealed no cases of GBC<sup>[12]</sup>.

Historically, an association between calcified gallbladder (porcelain gallbladder) and GBC has been reported<sup>[13,14]</sup>, although there has also been a report suggesting that porcelain gallbladder is not associated with GBC<sup>[15]</sup>. Therefore, the causal association of porcelain gallbladder and GBC remains controversial.

Pancreaticobiliary maljunction (PBM) is considered an established risk factor for biliary tract cancers involving GBC<sup>[16,17]</sup>, especially in relatively young female patients without gallbladder stones<sup>[18,19]</sup>. It is generally accepted that pancreatic juice reflux into the biliary tract due to PBM plays a pathogenic role in biliary tract cancers. K-ras mutations are more common in biliary tract carcinomas associated with PBM<sup>[20]</sup>.

Adenomyomatosis of the gallbladder has not been considered to have malignant potential; however, several reports have suggested that gallbladder cancer may originate from adenomyomatosis<sup>[21-24]</sup> or have insisted that segmental-type adenomyomatosis shows an increased risk of progression to gallbladder cancer<sup>[25]</sup>. Recently, a study showed that gross features of adenomyomatosis were found in approximately a quarter of gallbladders resected under the diagnosis of GBC<sup>[26]</sup>. Although the magnitude of risk for GBC in patients with adenomyomatosis remains unclear, studies suggesting a correlation between adenomyomatosis and GBC have been gradually accumulating.

In regard to the development of GBC, several theories have been proposed, including the adenoma-carcinoma sequence and dysplasia-carcinoma sequence theories<sup>[27-30]</sup>. However, recently reported articles have suggested that the vast majority of adenomas and/or polypoid lesions do not become GBC<sup>[31,32]</sup>. Therefore, the validity of the adenoma-carcinoma sequence theory remains controversial. Other risk factors recently receiving attention include bacterial infections. Although the supporting evidence for an association is weak, *Salmonella*<sup>[33,34]</sup> and *Helicobacter* species<sup>[35]</sup> would be prime candidates for a bacterial predisposition to GBC.

## SURVIVAL AND GENERAL SURGICAL STRATEGIES ACCORDING TO T-STAGE

The surgical strategy for GBC depends on the extent of the disease, particularly the T-stage from the TNM classification<sup>[36]</sup>. The prognosis after surgery for GBC differs

strikingly according to T-stage. Five-year survival rates after surgery for T1, T2, T3, and T4 stage tumors in 73 cases at our institution were 100%, 78.3%, 16.7%, and 25.0%, respectively<sup>[37]</sup>. The survival rates of our series were consistent with the results of other previous reports<sup>[38-41]</sup>.

The survival of patients with T1a lesions (invasion restricted to the lamina propria) is particularly good, and lymph node metastasis is extremely rare in such cases. Simple cholecystectomy with or without lymphadenectomy is thus widely accepted as sufficient for T1a lesions<sup>[38,42,43]</sup>. Intraoperative perforation of the gallbladder and positive surgical margins around the cystic duct are important prognostic factors in surgery for T1a lesions<sup>[44]</sup>.

Survival rates and strategies for T1b (invasion to the muscle layer) remain somewhat controversial. Several studies have reported LN metastasis in up to 20% of cases, with recurrence rates of 30%-60% following simple cholecystectomy<sup>[45-51]</sup>. In addition, distinguishing T1b lesions from T2 lesions pre- or intraoperatively is usually difficult. Therefore, it seems reasonable to perform cholecystectomy combined with lymphadenectomy with or without liver resection in patients with pre- or intraoperative presumption of T1b GBC. However, T1b GBC is often discovered after laparoscopic cholecystectomy for presumed benign disease. In our T1b series ( $n = 8$ ), lymph vessel invasion was found only one case and no LN metastases or recurrences were observed, and thus additional operation of lymphadenectomy was not always needed in patients with T1b lesions diagnosed after routine cholecystectomy. However, caution is required in that the pathological work for resected specimens must be performed intensively with sections from the whole specimen, in order to minimize the possibility that a more invasive site or findings of residual lesion remain present in the resected specimen.

The prognosis for T2 (invasion to the subserosal layer) lesions varies widely, with the 5-year survival rates being approximately 20%-70% after simple cholecystectomy, compared to 60%-100% after radical surgery<sup>[37,43,52-55]</sup>. The surgical strategy for T2 lesions thus remains unclear. The conventional opinion is that patients with T2 lesions should be treated using radical cholecystectomy, including en bloc resection of the adjacent liver as well as regional lymphadenectomy with or without extrahepatic bile duct resection (BDR)<sup>[38,56]</sup>. Pathologists should pay close attention in order not to misdiagnose a T1a tumor with spreading into the Rokitansky-Aschoff sinuses (RAS) as a T2 tumor with invasion of the subserosal layer.

The prognosis is poor for most patients with T3 tumor, which shows perforation of the serosa and/or direct invasion of the liver and/or one other adjacent organ or structure. Surgery for T3 lesions is only appropriate if there is potential to achieve a curative resection. T3 lesions require hepatic resection with regional lymphadenectomy at a minimum. This can include major hepatectomy if there is extensive spreading into the liver or major vascular structures. In addition, if direct invasion

into an adjacent organ (duodenum, pancreas, stomach or colon) is suspected, *en bloc* resection would be required for curative resection<sup>[56]</sup>. Because of the high degree of surgical stress involved, the utility of aggressive surgery with extended resection for T3 lesions is often debated in clinical practice, and case-by-case selection is required with due consideration for the patient's performance status, complications, and age.

Chemotherapy or palliation is typically appropriate for T4 disease (tumor invading into the main portal vein or two or more extrahepatic organs or structures), except in rare cases where *en bloc* resection of multiple organs is possible. This is because of the unfortunate prognosis and difficulty of achieving curative resection. Unresectability discovered at the time of laparotomy may be treated with bypass surgery to relieve symptoms related to biliary obstruction. Cases identified preoperatively as unresectable may be considered for percutaneous biliary drainage or endoscopic stenting to address biliary obstruction<sup>[38]</sup>.

## CLINICAL CHALLENGES FOR T2 AND T3 TUMORS

As mentioned above, T2 and T3 tumors are indications for radical surgery. However, which type of radical surgery is most appropriate remains unclear. Although regional lymphadenectomy is widely accepted as necessary at a minimum, the efficacy of extended resection, such as hepatectomy, BDR or pancreatoduodenectomy (PD), remains controversial. BDR is usually necessary in cases with biliary infiltration associated with perineural invasion and complete lymphadenectomy and eradication of the connective tissue around the common bile duct<sup>[57-60]</sup>. In terms of hepatectomy for GBC, the resection may vary from a small wedge resection near the gallbladder fossa to an extended right hepatectomy. The appropriateness of segment 4a+5 (S4a+5) hepatectomy for advanced GBC is supported by the drainage of the cystic vein into anatomic Couinaud's segments IVa and V and the frequency of liver metastases in this anatomical area<sup>[61]</sup>. The results of our previous study support the use of S4a+5 hepatectomy combined with BDR and regional lymphadenectomy for the treatment of T2 or T3 GBC<sup>[37]</sup>. However, additional PD achieved no significant difference in survival in patients with T2 or T3 GBC. Indications for PD in these cases were obvious duodenal or pancreatic invasion, or infiltrating LN metastases at the retro-pancreatic head portion<sup>[37]</sup>.

## ATTEMPTS TO DISCRIMINATE FAVORABLE CASES IN T2 GBC

T2 GBC shows a wide variety of tumor spread. Some T2 tumors show none of the histological invasive factors of LN metastasis, lymphatic or venous invasion, but others show prominent LN metastases, along with venous,

lymphatic, or perineural invasion, resulting in poor prognosis. This issue indicates that patients with T2 GBC can be allocated to a favorable prognosis group or a poor prognosis group. If discrimination of favorable cases is appropriately performed, patients with favorable prognosis could be spared excessive extended radical surgery. To identify cases with a favorable prognosis, subset analyses of patients with T2 tumor according to certain pathological criteria have been performed. Several studies, including one from our institution, reported the usefulness of discrimination of T2 GBC according to the depth of subserosal invasion and horizontal tumor spread in the subserosal layer with or without a scoring system<sup>[62-65]</sup>. Our study focused on the phenomena of dedifferentiation (DD) and tumor budding (BD) demonstrated a significant prognostic impact of both BD and DD in patients with T2 tumor<sup>[66]</sup>.

## INVESTIGATION OF USEFUL PROGNOSTIC MARKERS AND FACTORS

Although prognostic markers of GBC have been widely investigated, promising prognostic markers or factors have not yet been established. Ki-67 labeling index (LI), p53 nuclear expression, CD8+ tumor-infiltrating lymphocytes (TIL) and mitotic count (MC) have classically been considered as candidates for prognostic markers. However, several previous studies have reported no prognostic impact of p53 overexpression in GBC<sup>[67-71]</sup>, although reports of poor prognosis in cases with p53 overexpression are also available in the literature<sup>[72,73]</sup>. A previous study showed that patients with GBC and high Ki-67 exhibited worse postoperative prognosis than those with low Ki-67<sup>[40]</sup>, although here again, several previous studies also reported that Ki-67 LI of cancer cells was not correlated with patient survival<sup>[68,70,71]</sup>. Therefore, the prognostic impact of p53 overexpression and Ki-67 LI in GBC remains controversial. In regard to CD8+ TIL, there is little evidence that this is a prognostic indicator. Only one study has reported that CD8+ TIL was correlated with prolonged survival in a univariate analysis<sup>[74]</sup>. A study from our institution concerning Ki-67 LI, p53 nuclear expression, CD8+ TIL and MC status in a series of 101 GBC patients indicated that only MC reflected the prognosis of GBC. In that study, MC showed a particularly strong prognostic impact in patients with T3 tumor and was identified as an independent prognostic factor in multivariate analyses that included the N and M factors of the TNM system of classification<sup>[75]</sup>. It is difficult to distinguish the extension of carcinoma in situ (CIS) from invasive carcinoma along the RAS. Laminin-5-gamma-2 chain, which is expressed in various types of invasive carcinoma, can be detected in the invasive fronts of invasive GBC, but is not expressed in CIS with extension along the RAS<sup>[76]</sup>. The results indicate that laminin-5-gamma-2 chain is a useful marker of determining the T factor. Heparanase and its transcriptional factor, hypoxia-inducible factor-1a, contribute to the invasion and meta-

static potentials, and are correlated with poor survival in GBC<sup>[77]</sup>. Cyclooxygenase-2, a well-known oxidative stress factor expressed in invasive fronts, is also related with poor prognosis of GBC<sup>[78]</sup>. The Hedgehog signaling pathway is considered to be a potential therapeutic target for various cancers, and hedgehog signaling factor Gli1 may be involved in the invasive phenotype through the matrix metalloproteinases<sup>[79]</sup>. Other, more recently reported factors that may have a prognostic impact in GBC based on multivariate analyses include transmembrane protease/serine 4<sup>[80]</sup>, loss of microRNA-335<sup>[81]</sup>, aldehyde dehydrogenase-1A3 overexpression, and decreased glutathione peroxidase-3 expression<sup>[82]</sup>.

## PATHOLOGICAL EXAMINATION FOR OPTIMAL SURGERY

Preoperative diagnosis using an imaging study is very important for selecting the optimal surgery according to T-stage. However, preoperative diagnosis of the T-stage in T1 or T2 GBC is not easy, and it is especially difficult in GBC arising in the gallbladder concomitant with adenomyomatosis, despite advances in medical imaging<sup>[83]</sup>. As a result, stage T1 or T2 GBC is often discovered incidentally after routine cholecystectomy. In such cases, pathological evaluations of prognostic factors using entire tumor sections can be used to determine the need for additional extended radical surgery. Intraoperative histological examination is usually performed during surgery for lesions preoperatively diagnosed as “suspected GBC” or “possible T1 or T2 GBC”. In such cases, the resected specimen from cholecystectomy with or without en bloc liver resection (S4a+5 or liver bed) is submitted for intraoperative histological examination. However, diagnosis of the depth of invasion from frozen sections of GBC is a difficult task, and care must be taken to avoid obstructing the pathological diagnosis of formalin-fixed specimens when the tumor lesion is small.

## CONCLUSION

This review has documented the basic knowledge and surgical strategies for GBC based on clinical and pathological data from previous studies. Discrimination of favorable cases, particularly T2 or T3 lesions, is useful for the selection of surgical strategies for individual patients. To establish useful prognostic markers or factors, further accumulation of studies is needed. As GBC is often discovered incidentally after routine cholecystectomy and definite preoperative diagnosis is often difficult, close cooperation between surgeons and pathologists is essential for developing a rational surgical strategy for GBC.

## REFERENCES

- 1 **Randi G**, Franceschi S, La Vecchia C. Gallbladder cancer worldwide: geographical distribution and risk factors. *Int J Cancer* 2006; **118**: 1591-1602 [PMID: 16397865 DOI: 10.1002/ijc.21683]
- 2 **Medina E**, Kaempffer AM. [Cancer mortality in Chile: epidemiological considerations]. *Rev Med Chil* 2001; **129**: 1195-1202 [PMID: 11775349 DOI: 10.4067/S0034-98872001001000014]
- 3 **Lazcano-Ponce EC**, Miquel JF, Muñoz N, Herrero R, Ferrecio C, Wistuba II, Alonso de Ruiz P, Aristi Urista G, Nervi F. Epidemiology and molecular pathology of gallbladder cancer. *CA Cancer J Clin* 2001; **51**: 349-364 [PMID: 11760569 DOI: 10.3322/canjclin.51.6.349]
- 4 **Roa I**, Araya JC, Wistuba I, Villaseca M, de Aretxabala X, Burgos L. [Gallbladder cancer in the IX Region of Chile. Impact of the anatomopathological study of 474 cases]. *Rev Med Chil* 1994; **122**: 1248-1256 [PMID: 7659894]
- 5 **Sheth S**, Bedford A, Chopra S. Primary gallbladder cancer: recognition of risk factors and the role of prophylactic cholecystectomy. *Am J Gastroenterol* 2000; **95**: 1402-1410 [PMID: 10894571]
- 6 **Miyazaki M**, Takada T, Miyakawa S, Tsukada K, Nagino M, Kondo S, Furuse J, Saito H, Tsuyuguchi T, Chijiwa K, Kimura F, Yoshitomi H, Nozawa S, Yoshida M, Wada K, Amano H, Miura F. Risk factors for biliary tract and ampullary carcinomas and prophylactic surgery for these factors. *J Hepatobiliary Pancreat Surg* 2008; **15**: 15-24 [PMID: 18274840 DOI: 10.1007/s00534-007-1276-8]
- 7 **Hsing AW**, Bai Y, Andreotti G, Rashid A, Deng J, Chen J, Goldstein AM, Han TQ, Shen MC, Fraumeni JF, Gao YT. Family history of gallstones and the risk of biliary tract cancer and gallstones: a population-based study in Shanghai, China. *Int J Cancer* 2007; **121**: 832-838 [PMID: 17450525 DOI: 10.1002/ijc.22756]
- 8 **Diehl AK**. Gallstone size and the risk of gallbladder cancer. *JAMA* 1983; **250**: 2323-2326 [PMID: 6632129 DOI: 10.1001/jama.1983.03340170049027]
- 9 **Roa I**, Ibacache G, Roa J, Araya J, de Aretxabala X, Muñoz S. Gallstones and gallbladder cancer-volume and weight of gallstones are associated with gallbladder cancer: a case-control study. *J Surg Oncol* 2006; **93**: 624-628 [PMID: 16724353 DOI: 10.1002/jso.20528]
- 10 **Csendes A**, Becerra M, Rojas J, Medina E. Number and size of stones in patients with asymptomatic and symptomatic gallstones and gallbladder carcinoma: a prospective study of 592 cases. *J Gastrointest Surg* 2000; **4**: 481-485 [PMID: 11077323 DOI: 10.1016/S1091-255X(00)80090-6]
- 11 **Mano H**, Roa I, Araya JC, Ohta T, Yoshida K, Araki K, Kinebuchi H, Ishizu T, Nakadaira H, Endoh K, Yamamoto M, Watanabe H. Comparison of mutagenic activity of bile between Chilean and Japanese female patients having cholelithiasis. *Mutat Res* 1996; **371**: 73-77 [PMID: 8950352 DOI: 10.1016/S0165-1218(96)90096-8]
- 12 **Gracie WA**, Ransohoff DF. The natural history of silent gallstones: the innocent gallstone is not a myth. *N Engl J Med* 1982; **307**: 798-800 [PMID: 7110244 DOI: 10.1056/NEJM198209233071305]
- 13 **Stephen AE**, Berger DL. Carcinoma in the porcelain gallbladder: a relationship revisited. *Surgery* 2001; **129**: 699-703 [PMID: 11391368 DOI: 10.1067/msy.2001.113888]
- 14 **Tazuma S**, Kajiyama G. Carcinogenesis of malignant lesions of the gall bladder. The impact of chronic inflammation and gallstones. *Langenbecks Arch Surg* 2001; **386**: 224-229 [PMID: 11382326 DOI: 10.1007/s004230100220]
- 15 **Towfigh S**, McFadden DW, Cortina GR, Thompson JE, Tompkins RK, Chandler C, Hines OJ. Porcelain gallbladder is not associated with gallbladder carcinoma. *Am Surg* 2001; **67**: 7-10 [PMID: 11206901]
- 16 **Tashiro S**, Imaizumi T, Ohkawa H, Okada A, Katoh T, Kawaharada Y, Shimada H, Takamatsu H, Miyake H, Todani T; Committee for Registration of the Japanese Study Group on Pancreaticobiliary Maljunction. Pancreaticobiliary maljunction: retrospective and nationwide survey in Japan. *J Hepatobiliary Pancreat Surg* 2003; **10**: 345-351 [PMID: 14598134 DOI: 10.1007/s00534-002-0741-7]
- 17 **Sasatomi E**, Tokunaga O, Miyazaki K. Precancerous condi-



- tions of gallbladder carcinoma: overview of histopathologic characteristics and molecular genetic findings. *J Hepatobiliary Pancreat Surg* 2000; **7**: 556-567 [PMID: 11180887 DOI: 10.1007/s005340070004]
- 18 **Kang CM**, Kim KS, Choi JS, Lee WJ, Kim BR. Gallbladder carcinoma associated with anomalous pancreaticobiliary duct junction. *Can J Gastroenterol* 2007; **21**: 383-387 [PMID: 17571173]
  - 19 **Tanaka K**, Nishimura A, Yamada K, Ishibe R, Ishizaki N, Yoshimine M, Hamada N, Taira A. Cancer of the gallbladder associated with anomalous junction of the pancreaticobiliary duct system without bile duct dilatation. *Br J Surg* 1993; **80**: 622-624 [PMID: 8518907 DOI: 10.1002/bjs.1800800527]
  - 20 **Chao TC**, Wang CS, Jan YY, Chen HM, Chen MF. Carcinogenesis in the biliary system associated with APDJ. *J Hepatobiliary Pancreat Surg* 1999; **6**: 218-222 [PMID: 10526055 DOI: 10.1007/s005340050110]
  - 21 **Aldridge MC**, Gruffaz F, Castaing D, Bismuth H. Adenomyomatosis of the gallbladder. A premalignant lesion? *Surgery* 1991; **109**: 107-110 [PMID: 1984629]
  - 22 **Funabiki T**, Matsumoto S, Tsukada N, Kimura T, Yoshizaki S, Horibe Y. A patient with early gallbladder cancer derived from a Rokitanski-Aschoff sinus. *Surg Today* 1993; **23**: 350-355 [PMID: 8318790 DOI: 10.1007/BF00309054]
  - 23 **Kawarada Y**, Sanda M, Mizumoto R, Yatani R. Early carcinoma of the gallbladder, noninvasive carcinoma originating in the Rokitanski-Aschoff sinus: a case report. *Am J Gastroenterol* 1986; **81**: 61-66 [PMID: 3942125]
  - 24 **Terada T**. Gallbladder adenocarcinoma arising in Rokitanski-Aschoff sinus. *Pathol Int* 2008; **58**: 806-809 [PMID: 19067858 DOI: 10.1111/j.1440-1827.2008.02316.x]
  - 25 **Nabatame N**, Shirai Y, Nishimura A, Yokoyama N, Wakai T, Hatakeyama K. High risk of gallbladder carcinoma in elderly patients with segmental adenomyomatosis of the gallbladder. *J Exp Clin Cancer Res* 2004; **23**: 593-598 [PMID: 15743029]
  - 26 **Kai K**, Ide T, Masuda M, Kitahara K, Miyoshi A, Miyazaki K, Noshiro H, Tokunaga O. Clinicopathologic features of advanced gallbladder cancer associated with adenomyomatosis. *Virchows Arch* 2011; **459**: 573-580 [PMID: 22038508 DOI: 10.1007/s00428-011-1155-1]
  - 27 **Roa I**, de Aretxabala X, Araya JC, Roa J. Preneoplastic lesions in gallbladder cancer. *J Surg Oncol* 2006; **93**: 615-623 [PMID: 16724345 DOI: 10.1002/jso.20527]
  - 28 **Yamagiwa H**. Mucosal dysplasia of gallbladder: isolated and adjacent lesions to carcinoma. *Jpn J Cancer Res* 1989; **80**: 238-243 [PMID: 2498259 DOI: 10.1111/j.1349-7006.1989.tb02299.x]
  - 29 **Kubota K**, Bandai Y, Noie T, Ishizaki Y, Teruya M, Makuuchi M. How should polypoid lesions of the gallbladder be treated in the era of laparoscopic cholecystectomy? *Surgery* 1995; **117**: 481-487 [PMID: 7740417 DOI: 10.1016/S0039-6060(05)80245-4]
  - 30 **Ishikawa O**, Ohhigashi H, Imaoka S, Nakaizumi A, Kitamura T, Sasaki Y, Shibata T, Wada A, Iwanaga T. The difference in malignancy between pedunculated and sessile polypoid lesions of the gallbladder. *Am J Gastroenterol* 1989; **84**: 1386-1390 [PMID: 2683741]
  - 31 **Ito H**, Hann LE, D'Angelica M, Allen P, Fong Y, Dematteo RP, Klimstra DS, Blumgart LH, Jarnagin WR. Polypoid lesions of the gallbladder: diagnosis and followup. *J Am Coll Surg* 2009; **208**: 570-575 [PMID: 19476792 DOI: 10.1016/j.jamcollsurg.2009.01.011]
  - 32 **Pilgrim CH**, Groeschl RT, Christians KK, Gamblin TC. Modern perspectives on factors predisposing to the development of gallbladder cancer. *HPB (Oxford)* 2013; **15**: 839-844 [DOI: 10.1111/hpb.12046]
  - 33 **Eslick GD**. Epidemiology of gallbladder cancer. *Gastroenterol Clin North Am* 2010; **39**: 307-330, ix [PMID: 20478488 DOI: 10.1016/j.gtc.2010.02.011]
  - 34 **Nath G**, Gulati AK, Shukla VK. Role of bacteria in carcinogenesis, with special reference to carcinoma of the gallbladder. *World J Gastroenterol* 2010; **16**: 5395-5404 [PMID: 21086555 DOI: 10.3748/wjg.v16.i43.5395]
  - 35 **Mishra RR**, Tewari M, Shukla HS. Helicobacter species and pathogenesis of gallbladder cancer. *Hepatobiliary Pancreat Dis Int* 2010; **9**: 129-134 [PMID: 20382581]
  - 36 **Sobin L**, Gospodarowicz M, Wittekind C. TNM Classification of malignant tumors. 7th ed. John Wiley & Sons, Inc., Hoboken, NJ, 2009
  - 37 **Kohya N**, Miyazaki K. Hepatectomy of segment 4a and 5 combined with extra-hepatic bile duct resection for T2 and T3 gallbladder carcinoma. *J Surg Oncol* 2008; **97**: 498-502 [PMID: 18314875 DOI: 10.1002/jso.20982]
  - 38 **Pilgrim C**, Usatoff V, Evans PM. A review of the surgical strategies for the management of gallbladder carcinoma based on T stage and growth type of the tumour. *Eur J Surg Oncol* 2009; **35**: 903-907 [PMID: 19261430 DOI: 10.1016/j.ejso.2009.02.005]
  - 39 **Bartlett DL**, Fong Y, Fortner JG, Brennan MF, Blumgart LH. Long-term results after resection for gallbladder cancer. Implications for staging and management. *Ann Surg* 1996; **224**: 639-646 [PMID: 8916879 DOI: 10.1097/0000658-199611000-00008]
  - 40 **Kai M**, Chijiwa K, Ohuchida J, Nagano M, Hiyoshi M, Kondo K. A curative resection improves the postoperative survival rate even in patients with advanced gallbladder carcinoma. *J Gastrointest Surg* 2007; **11**: 1025-1032 [PMID: 17508256 DOI: 10.1007/s11605-007-0181-4]
  - 41 **Misra S**, Chaturvedi A, Misra NC, Sharma ID. Carcinoma of the gallbladder. *Lancet Oncol* 2003; **4**: 167-176 [PMID: 12623362 DOI: 10.1016/S1470-2045(03)01021-0]
  - 42 **Mekeel KL**, Hemming AW. Surgical management of gallbladder carcinoma: a review. *J Gastrointest Surg* 2007; **11**: 1188-1193 [PMID: 17712596 DOI: 10.1007/s11605-007-0115-1]
  - 43 **Wakai T**, Shirai Y, Yokoyama N, Nagakura S, Watanabe H, Hatakeyama K. Early gallbladder carcinoma does not warrant radical resection. *Br J Surg* 2001; **88**: 675-678 [PMID: 11350438 DOI: 10.1046/j.1365-2168.2001.01749.x]
  - 44 **Eguchi H**, Ishikawa O, Ohigashi H, Kasugai T, Yokoyama S, Yamada T, Doki Y, Murata K, Miyashiro I, Sasaki Y, Imaoka S. Surgical significance of superficial cancer spread in early gallbladder cancer. *Jpn J Clin Oncol* 2005; **35**: 134-138 [PMID: 15741303 DOI: 10.1093/jjco/hyi042]
  - 45 **Yildirim E**, Celen O, Gulben K, Berberoglu U. The surgical management of incidental gallbladder carcinoma. *Eur J Surg Oncol* 2005; **31**: 45-52 [PMID: 15642425 DOI: 10.1016/j.ejso.2004.09.006]
  - 46 **de Aretxabala X**, Roa I, Burgos L, Araya JC, Fonseca L, Wisnub I, Flores P. Gallbladder cancer in Chile. A report on 54 potentially resectable tumors. *Cancer* 1992; **69**: 60-65 [PMID: 1727676 DOI: 10.1002/1097-0142(19920101)69:1<60::AID-CNCR2820690112>3.0.CO;2-N]
  - 47 **Ogura Y**, Mizumoto R, Isaji S, Kusuda T, Matsuda S, Tabata M. Radical operations for carcinoma of the gallbladder: present status in Japan. *World J Surg* 1991; **15**: 337-343 [PMID: 1853612 DOI: 10.1007/BF01658725]
  - 48 **Cucinotta E**, Lorenzini C, Melita G, Iapichino G, Currò G. Incidental gall bladder carcinoma: does the surgical approach influence the outcome? *ANZ J Surg* 2005; **75**: 795-798 [PMID: 16173995 DOI: 10.1111/j.1445-2197.2005.03528.x]
  - 49 **Waghlikar GD**, Behari A, Krishnani N, Kumar A, Sikora SS, Saxena R, Kapoor VK. Early gallbladder cancer. *J Am Coll Surg* 2002; **194**: 137-141 [PMID: 11848630 DOI: 10.1016/S1072-7515(01)01136-X]
  - 50 **Ouchi K**, Suzuki M, Tominaga T, Saijo S, Matsuno S. Survival after surgery for cancer of the gallbladder. *Br J Surg* 1994; **81**: 1655-1657 [PMID: 7827897 DOI: 10.1002/bjs.1800811131]
  - 51 **Matsumoto Y**, Fujii H, Aoyama H, Yamamoto M, Sugahara K, Suda K. Surgical treatment of primary carcinoma of the gallbladder based on the histologic analysis of 48 surgical



- specimens. *Am J Surg* 1992; **163**: 239-245 [PMID: 1739180 DOI: 10.1016/0002-9610(92)90109-5]
- 52 **Shirai Y**, Yoshida K, Tsukada K, Muto T, Watanabe H. Early carcinoma of the gallbladder. *Eur J Surg* 1992; **158**: 545-548 [PMID: 1360827]
- 53 **Fong Y**, Brennan MF, Turnbull A, Colt DG, Blumgart LH. Gallbladder cancer discovered during laparoscopic surgery. Potential for iatrogenic tumor dissemination. *Arch Surg* 1993; **128**: 1054-1056 [PMID: 8368924 DOI: 10.1001/archsurg.1993.01420210118016]
- 54 **Chijiwa K**, Kai M, Nagano M, Hiyoshi M, Ohuchida J, Kondo K. Outcome of radical surgery for stage IV gallbladder carcinoma. *J Hepatobiliary Pancreat Surg* 2007; **14**: 345-350 [PMID: 17653631 DOI: 10.1007/s00534-006-1186-1]
- 55 **Principe A**, Del Gaudio M, Ercolani G, Golfieri R, Cucchetti A, Pinna AD. Radical surgery for gallbladder carcinoma: possibilities of survival. *Hepatogastroenterology* 2006; **53**: 660-664 [PMID: 17086863]
- 56 **Miller G**, Jarnagin WR. Gallbladder carcinoma. *Eur J Surg Oncol* 2008; **34**: 306-312 [PMID: 17964753 DOI: 10.1016/j.ejso.2007.07.206]
- 57 **Kaneoka Y**, Yamaguchi A, Isogai M, Harada T, Suzuki M. Hepatoduodenal ligament invasion by gallbladder carcinoma: histologic patterns and surgical recommendation. *World J Surg* 2003; **27**: 260-265 [PMID: 12607048 DOI: 10.1007/s00268-002-6702-0]
- 58 **Shimizu Y**, Ohtsuka M, Ito H, Kimura F, Shimizu H, Togawa A, Yoshidome H, Kato A, Miyazaki M. Should the extrahepatic bile duct be resected for locally advanced gallbladder cancer? *Surgery* 2004; **136**: 1012-1017; discussion 1018 [PMID: 15523394 DOI: 10.1016/j.surg.2004.04.032]
- 59 **Kosuge T**, Sano K, Shimada K, Yamamoto J, Yamasaki S, Makuuchi M. Should the bile duct be preserved or removed in radical surgery for gallbladder cancer? *Hepatogastroenterology* 1999; **46**: 2133-2137 [PMID: 10521955]
- 60 **Burdiles P**, Csendes A, Diaz JC, Maluenda F, Avila S, Jorquera P, Aldunate M. Factors affecting mortality in patients over 70 years of age submitted to surgery for gallbladder or common bile duct stones. *Hepatogastroenterology* 1989; **36**: 136-139 [PMID: 2753458]
- 61 **Araida T**, Higuchi R, Hamano M, Kodera Y, Takeshita N, Ota T, Yoshikawa T, Yamamoto M, Takasaki K. Hepatic resection in 485 R0 pT2 and pT3 cases of advanced carcinoma of the gallbladder: results of a Japanese Society of Biliary Surgery survey--a multicenter study. *J Hepatobiliary Pancreat Surg* 2009; **16**: 204-215 [PMID: 19219399 DOI: 10.1007/s00534-009-0044-3]
- 62 **Kohya N**, Kitahara K, Miyazaki K. Rational therapeutic strategy for T2 gallbladder carcinoma based on tumor spread. *World J Gastroenterol* 2010; **16**: 3567-3572 [PMID: 20653066 DOI: 10.3748/wjg.v16.i28.3567]
- 63 **Wakai T**, Shirai Y, Yokoyama N, Ajioka Y, Watanabe H, Hatakeyama K. Depth of subserosal invasion predicts long-term survival after resection in patients with T2 gallbladder carcinoma. *Ann Surg Oncol* 2003; **10**: 447-454 [PMID: 12734095 DOI: 10.1245/ASO.2003.06.014]
- 64 **Oertli D**, Herzog U, Tondelli P. Primary carcinoma of the gallbladder: operative experience during a 16 year period. *Eur J Surg* 1993; **159**: 415-420 [PMID: 8218552]
- 65 **Sasaki R**, Uesugi N, Itabashi H, Fujita T, Takeda Y, Hoshikawa K, Takahashi M, Funato O, Nitta H, Sugai T, Kanno S, Saito K. Clinicopathological study of depth of subserosal invasion in patients with pT2 gallbladder carcinoma. *J Surg Oncol* 2005; **92**: 83-88 [PMID: 16231372 DOI: 10.1002/jso.20377]
- 66 **Kai K**, Kohya N, Kitahara K, Masuda M, Miyoshi A, Ide T, Tokunaga O, Miyazaki K, Noshiro H. Tumor budding and dedifferentiation in gallbladder carcinoma: potential for the prognostic factors in T2 lesions. *Virchows Arch* 2011; **459**: 449-456 [PMID: 21785869 DOI: 10.1007/s00428-011-1131-9]
- 67 **Ajiki T**, Onoyama H, Yamamoto M, Asaka K, Fujimori T, Maeda S, Saitoh Y. p53 protein expression and prognosis in gallbladder carcinoma and premalignant lesions. *Hepatogastroenterology* 1996; **43**: 521-526 [PMID: 8799388]
- 68 **Hidalgo Grau LA**, Badia JM, Salvador CA, Monsó TS, Canaleta JF, Nogués JM, Sala JS. Gallbladder carcinoma: the role of p53 protein overexpression and Ki-67 antigen expression as prognostic markers. *HPB (Oxford)* 2004; **6**: 174-180 [PMID: 18333072 DOI: 10.1080/13651820410025110]
- 69 **Kim YW**, Huh SH, Park YK, Yoon TY, Lee SM, Hong SH. Expression of the c-erb-B2 and p53 protein in gallbladder carcinomas. *Oncol Rep* 2001; **8**: 1127-1132 [PMID: 11496329]
- 70 **Jarnagin WR**, Klimstra DS, Hezel M, Gonen M, Fong Y, Roggin K, Cymes K, DeMatteo RP, D'Angelica M, Blumgart LH, Singh B. Differential cell cycle-regulatory protein expression in biliary tract adenocarcinoma: correlation with anatomic site, pathologic variables, and clinical outcome. *J Clin Oncol* 2006; **24**: 1152-1160 [PMID: 16505435 DOI: 10.1200/JCO.2005.04.6631]
- 71 **Kim WB**, Han HJ, Lee HJ, Park SS, Song TJ, Kim HK, Suh SO, Kim YC, Choi SY. Expression and clinical significance of cell cycle regulatory proteins in gallbladder and extrahepatic bile duct cancer. *Ann Surg Oncol* 2009; **16**: 23-34 [PMID: 18979138 DOI: 10.1245/s10434-008-0182-x]
- 72 **Lee CS**, Pirdas A. p53 protein immunoreactivity in cancers of the gallbladder, extrahepatic bile ducts and ampulla of Vater. *Pathology* 1995; **27**: 117-120 [PMID: 7567135 DOI: 10.1080/00313029500169692]
- 73 **Chang HJ**, Yoo BC, Kim SW, Lee BL, Kim WH. Significance of PML and p53 protein as molecular prognostic markers of gallbladder carcinomas. *Pathol Oncol Res* 2007; **13**: 326-335 [PMID: 18158568 DOI: 10.1007/BF02940312]
- 74 **Nakakubo Y**, Miyamoto M, Cho Y, Hida Y, Oshikiri T, Suzuoki M, Hiraoka K, Itoh T, Kondo S, Katoh H. Clinical significance of immune cell infiltration within gallbladder cancer. *Br J Cancer* 2003; **89**: 1736-1742 [PMID: 14583778 DOI: 10.1038/sj.bjc.6601331]
- 75 **Kai K**, Masuda M, Ide T, Takase Y, Miyoshi A, Kitahara K, Miyazaki K, Noshiro H, Tokunaga O. Mitotic count reflects prognosis of gallbladder cancer particularly among patients with T3 tumor. *Mol Clin Oncol* 2013; **1**: 633-638
- 76 **Eguchi T**, Inoue T, Fujii K, Yamaguchi H, Nishiyama K, Yonemasu H, Yao T, Tanaka M, Tsuneyoshi M. Laminin-5 (gamma2 chain) is a marker of invading cancer cells in human gallbladder carcinoma: special emphasis on extension of carcinoma in situ along Rokitsky-Aschoff sinuses. *Oncol Rep* 2008; **20**: 33-39 [PMID: 18575715]
- 77 **Wu W**, Pan C, Yu H, Gong H, Wang Y. Heparanase expression in gallbladder carcinoma and its correlation to prognosis. *J Gastroenterol Hepatol* 2008; **23**: 491-497 [PMID: 17524042 DOI: 10.1111/j.1440-1746.2007.04945.x]
- 78 **Kim H**, Song JY, Cho JY, Yoon YS, Han HS, Lee HS, Ryu HS, Choe G. Strong cytoplasmic expression of COX2 at the invasive fronts of gallbladder cancer is associated with a poor prognosis. *J Clin Pathol* 2010; **63**: 1048-1053 [PMID: 20924037]
- 79 **Matsushita S**, Onishi H, Nakano K, Nagamatsu I, Imaizumi A, Hattori M, Oda Y, Tanaka M, Katano M. Hedgehog signaling pathway is a potential therapeutic target for gallbladder cancer. *Cancer Sci* 2014; **105**: 272-280 [PMID: 24438533]
- 80 **Wu XY**, Zhang L, Zhang KM, Zhang MH, Ruan TY, Liu CY, Xu JY. Clinical implication of TMPRSS4 expression in human gallbladder cancer. *Tumour Biol* 2014; **35**: 5481-5486 [PMID: 24532432]
- 81 **Peng HH**, Zhang YD, Gong LS, Liu WD, Zhang Y. Increased expression of microRNA-335 predicts a favorable prognosis in primary gallbladder carcinoma. *Onco Targets Ther* 2013; **6**: 1625-1630 [PMID: 24250228]
- 82 **Yang ZL**, Yang L, Zou Q, Yuan Y, Li J, Liang L, Zeng G, Chen S. Positive ALDH1A3 and negative GPX3 expressions are biomarkers for poor prognosis of gallbladder cancer. *Dis*

- 83 **Kai K**, Irie H, Ide T, Masuda M, Kitahara K, Miyoshi A, Miyazaki K, Noshiro H, Tokunaga O. Actual status of clinical

diagnosis in patients with primary gallbladder cancer associated with adenomyomatosis. *Indian J Gastroenterol* 2013; **32**: 386-391 [PMID: 24214664 DOI: 10.1007/s12664-013-0355-9]

**P-Reviewer:** Oshiro Y, Rege RV, Xu Z **S-Editor:** Song XX  
**L-Editor:** A **E-Editor:** Liu SQ



## Endoscopic retrograde cholangiopancreatography-related perforation: Management and prevention

Varayu Prachayakul, Pitulak Aswakul

Varayu Prachayakul, Siriraj GI Endoscopy Center, Division of Gastroenterology, Department of Internal Medicine, Siriraj Hospital, Faculty of Medicine, Mahidol University, Bangkok 10700, Thailand

Pitulak Aswakul, Liver and Digestive Institute, Samitivej-Sukhumvit Hospital, Bangkok 10120, Thailand

**Author contributions:** Prachayakul V and Aswakul P contributed equally to this work; Prachayakul V designed the concept; Prachayakul V and Aswakul P reviewed the literature, wrote and revised the paper.

**Correspondence to:** Varayu Prachayakul, Assist Professor, Siriraj GI Endoscopy Center, Division of Gastroenterology, Department of Internal Medicine, Siriraj Hospital, Faculty of Medicine, Mahidol University, 7 Prannok Rd., Bangkoknoi, Bangkok 10700, Thailand. [kaiyjr@gmail.com](mailto:kaiyjr@gmail.com)

Telephone: +66-2-4121088 Fax: +66-2-4199610

Received: May 1, 2014 Revised: July 7, 2014

Accepted: July 25, 2014

Published online: October 16, 2014

### Abstract

Endoscopic retrograde cholangiopancreatography (ERCP) is a procedure that can result in serious complications, and thus should be handled by a skilled endoscopist to minimize the risk of complications and to enhance the success rate. The incidence of ERCP-related complications is 5%-10%, most commonly involving post-ERCP pancreatitis and clinically significant post-endoscopic sphincterotomy bleeding. Although ERCP-related perforation has a relatively lower incidence of 0.14%-1.6%, this complication is associated with a high mortality rate of 4.2%-29.6%. A classification of perforation type based on the instrument that caused the perforation was recently described that we postulated could affect the implementation of perforation management. In the present article, an algorithm for management and prevention of ERCP-related perforations is proposed that is based on the perforation type and delay of diagnosis. Available evidence demonstrates that a delayed diagnosis and/or treatment of perforation re-

sults in a poorer prognosis, and thus should be at the forefront of procedural consideration. Furthermore, this review provides steps and recommendations from the pre-procedural stage through the post-procedural evaluation with consideration of contributing factors in order to minimize ERCP-related complication risk and improve patient outcome. To avoid perforation, endoscopists must evaluate the risks related to the individual patient and the procedure and perform the procedure gently. Once a perforation occurs, immediate diagnosis and early management are key factors to minimize mortality.

© 2014 Baishideng Publishing Group Inc. All rights reserved.

**Key words:** Endoscopic retrograde cholangiopancreatography; Endoscopic retrograde cholangiopancreatography; Perforation; Prevention; Management; Classification

**Core tip:** Endoscopic retrograde cholangiopancreatography (ERCP)-related perforation, is a rare complication with a high morbidity and mortality. An immediate diagnosis and early management of ERCP-related perforation are key factors to minimize mortality. In this review article, the authors shared their experiences and propose an algorithm to avoid perforation and for management once a perforation occurs.

Prachayakul V, Aswakul P. Endoscopic retrograde cholangiopancreatography-related perforation: Management and prevention. *World J Clin Cases* 2014; 2(10): 522-527 Available from: URL: <http://www.wjgnet.com/2307-8960/full/v2/i10/522.htm> DOI: <http://dx.doi.org/10.12998/wjcc.v2.i10.522>

### INTRODUCTION

Endoscopic retrograde cholangiopancreatography (ERCP)

**Table 1** Previous classifications of endoscopic retrograde cholangiopancreatography-related perforations

	According to Stapfer <i>et al</i> <sup>[12]</sup>	According to Howard <i>et al</i> <sup>[13]</sup>
Type I	Lateral or medial wall perforation	Duodenal perforation remote from the papilla
Type II	Perivaterian injury	Periampullary retroperitoneal perforation
Type III	Distal bile duct injury related to wire/basket instrumentation	Guidewire perforation
Type IV	Retroperitoneal air alone	None

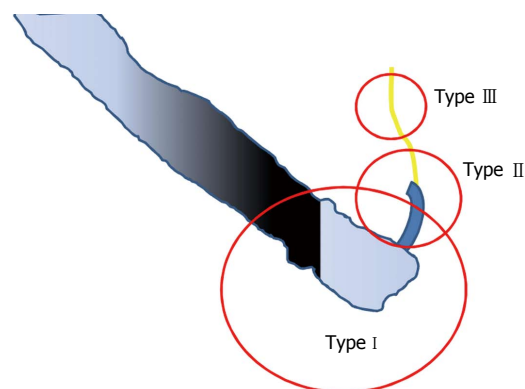
is a procedure that should be performed by a skilled endoscopist to maximize the success rate and minimize complications, which occur in 5%-10% of cases<sup>[1,2]</sup>. The most common complications are post-ERCP pancreatitis (1.0%-3.5% of cases)<sup>[3-5]</sup> and clinically significant post-endoscopic sphincterotomy bleeding (0.1%-2.0% incidence)<sup>[6-9]</sup>. ERCP-related perforations are relatively uncommon (incidence of 0.14%-1.6%), though associated with a high mortality rate of 4.2%-29.6%<sup>[10,11]</sup>. Whereas delayed recognition and treatment of this complication contribute to fatality, early detection and management confer a better prognosis. This review focuses on the classification, early diagnosis, management, and prevention of ERCP-related perforations.

## CLASSIFICATIONS OF ERCP-RELATED PERFORATION

ERCP-related perforations were previously classified into 3-4 types, regardless of the site of perforation<sup>[12,13]</sup> (Table 1). In 2011, Kim *et al*<sup>[14]</sup> proposed a new classification based on the instrument that caused the perforation. A type I perforation results from the scope itself, which always causes a large perforation with heavy contamination (Figure 1). A type II perforation can be caused by the needle-knife used during the sphincterotomy, from the ERCP cannula or the sphincterotome, which cause a moderate-sized hole with less contamination. Type III refers to a perforation caused by the guidewire and is associated with the least risk of contamination. A review of cases presented by Kim *et al*<sup>[14]</sup> and an additional 62 cases from Kwon *et al*<sup>[15]</sup> that were reevaluated using the new classification, revealed that 80% of patients with type I perforations (20/25 cases) required surgery, compared to 19% (7/37) of those with type II perforations. We therefore postulated that this classification could be used to direct the management of patients with perforations.

## EARLY RECOGNITION OF PERFORATIONS

Most type I perforations are immediately recognized by the endoscopist during the procedure. Large perforations can be definitively indicated by visualization of intra-abdominal organs, whereas smaller perforations may

**Figure 1** Classification of endoscopic retrograde cholangiopancreatography-related perforation (based on Kim *et al*<sup>[14]</sup>).

show only yellowish tissue of intra/retroperitoneal fat or by bleeding from other sites such as a lateral wall of the duodenum (Figure 2). If the endoscopist who performed the procedure suspects a perforation, evaluation of the pneumoperitoneum by fluoroscopy can be very helpful (Figure 3A). Some experts also recommend changing the duodenoscope to an end-view type for better mucosal visualization.

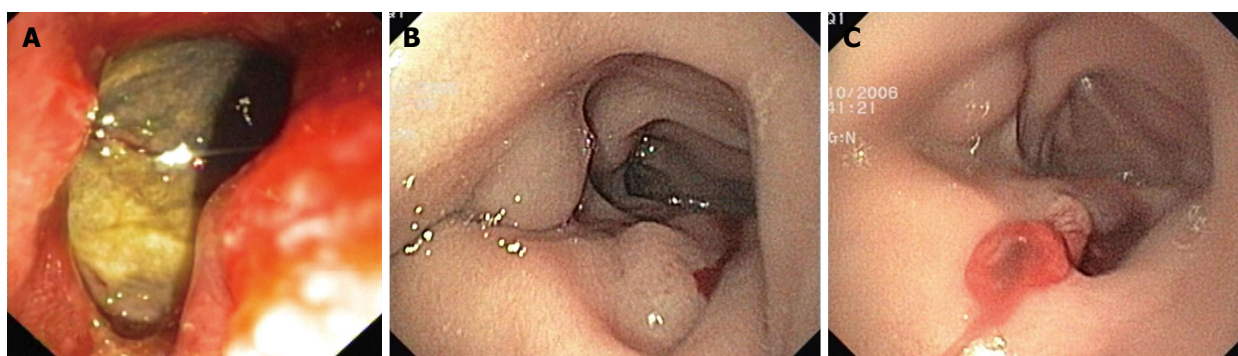
Type II's are typically retroperitoneal perforations that occur during treatment interventions. In some cases, the endoscopist may recognize that an injury is "too deep" with increased bleeding, abnormal positioning of the guidewire, skin emphysema, and a clear kidney shadow. When this type of perforation is suspected, it should be confirmed by fluoroscopy, which can help identify unexplainable air in the retroperitoneum (Figure 3B), or by contrast injection, which will show contrast leakage into the retroperitoneal cavity (Figure 3C).

Type III perforations can be recognized by an unusual guidewire position. If recognized in a timely manner, this type of perforation can be adequately managed by simply pulling the guidewire back into a safe position. However, the perforation can become a type II if the endoscopist does not recognize the perforation and continues pushing the instrument further. Up to 20%-30% of type II and III perforations are not immediately diagnosed, and patients may report abdominal pain and discomfort, which are followed by fever and leukocytosis. These perforations can be confirmed by a computed scan of the abdomen, which reveals retroperitoneal air (Figure 4) or fluid collection<sup>[16]</sup>.

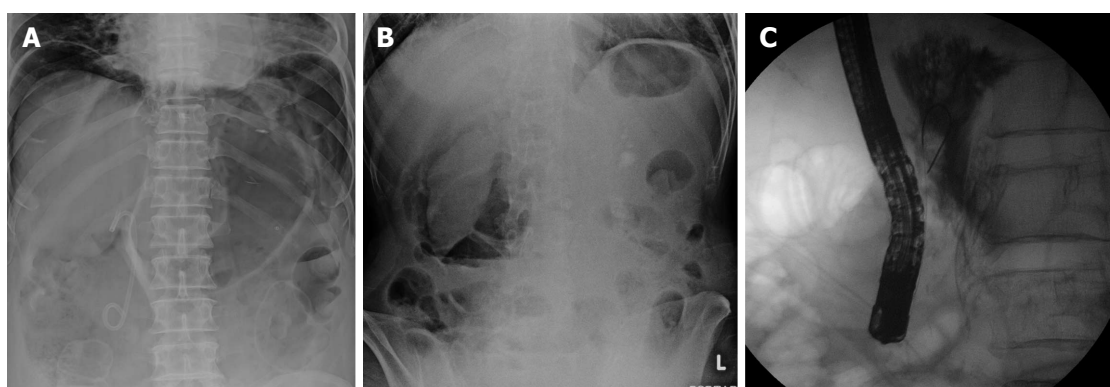
## MANAGEMENT

General principles of management for ERCP-related perforation include a *nil per os* directive, *iv* fluid resuscitation, administration of antibiotics to decrease intra/retroperitoneal contamination or fluid collection, pneumoperitoneal decompression, and, if possible, endoscopic closure. In some cases, surgical consultation may also be needed to control sepsis and repair the perforation, depending on the site and degree of leakage, the patient's condition, and mechanism of injury. Radiologic interventions were

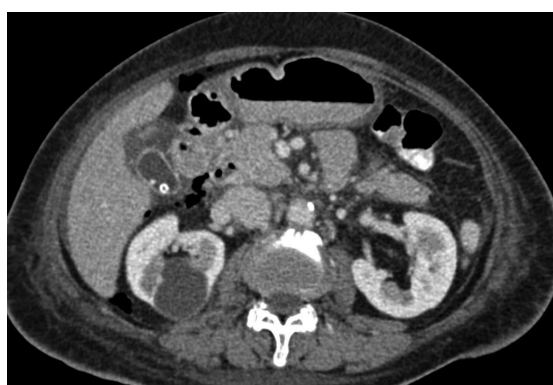



**Figure 2** Endoscopic visualization of perforations. A: Image of yellowish tissue in the retroperitoneum; B and C: Bleeding from a lateral wall of the duodenum.



**Figure 3** Fluoroscopy showing pneumoperitoneum (A), retroperitoneal air (B) and leakage of contrast media into the retroperitoneal cavity (C). The kidney outline (clear region on the right side of the image) showing retroperitoneal air.



**Figure 4** Computed tomography showing retroperitoneal air.

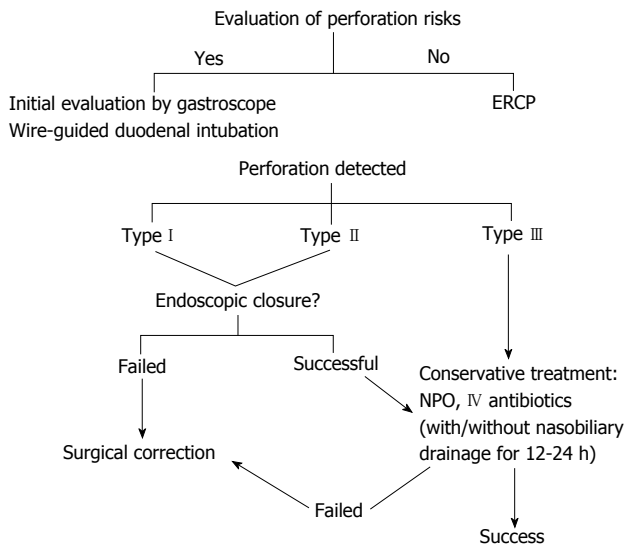
found to be useful in some particular cases, particularly those with localized retroperitoneal fluid collection and without clinical sign of peritonitis<sup>[17]</sup>. However, the management of ERCP perforation in that particular study was based upon whether the perforation was diagnosed immediately after it occurred, or delayed by at least 24 h after the procedure (recognized by abnormal vital or abdominal signs).

### Immediate diagnosis

Type I perforations, which are typically 1.0-1.3 cm wide, have been successfully treated during ERCP with hemostatic clips either through the gastroscope (with or

without cap assistance)<sup>[18,19]</sup> or with an endoloop<sup>[20]</sup>, or with over-the-scope clips<sup>[21]</sup>. Contrast injections should be administered to rule out leakage, as 30%-60% of type I perforations fail endoscopic closure and require surgery. Patients who undergo immediate surgical correction typically remain in the hospital for 12-16 d. Prompt diagnosis is crucial, as evidenced by a study of Miller *et al*<sup>[11]</sup> that reported two deaths out of five cases involving type I perforations, resulting from delayed diagnosis in one case, and delayed operation in the other, and six deaths from delayed surgical repair of type II perforations that were initially managed with a conservative treatment strategy<sup>[11]</sup>. Thus, some surgeons recommend immediate diagnosis and early surgery for ERCP-related perforations<sup>[22-24]</sup>. In our endoscopic center (within a tertiary care, university-based hospital), 4082 ERCP procedures were performed between January 2009 and June 2013, with a post-ERCP perforation rate of 0.29% ( $n = 10$  type I;  $n = 2$  type II perforation cases). All of the patients (65-91 years old) were diagnosed during or immediately upon finishing the ERCP procedures. Eighty-three percent of these cases underwent surgical correction while only 17% received conservative treatment, with no deaths.

Mao *et al*<sup>[25]</sup> reported on nine cases of ERCP-related perforation (mostly type II), six of which were managed conservatively with hospital stays ranging from 4 to 75 d. Subcutaneous emphysema was a significant clinical sign



**Figure 5** Algorithm for prevention and management of endoscopic retrograde cholangiopancreatography-related perforations.

found in seven of the nine patients. To aid in the success of conservative treatments, which included antibiotics, endoscopic treatment (when possible), intensive observation and follow-up imaging, nasobiliary and gastrointestinal drainage was recommended to reduce the leakage of digestive juices. However, very high success rates were also reported with conservative treatment (with or without nasobiliary drainage) by Park *et al*<sup>[26]</sup> and Vezakis *et al*<sup>[27]</sup>, using fully covered self-expandable metal stents for closure of perforated sites at the ampullary region.

The majority of type III perforations involve only mild contrast leakage or pneumoperitoneum without contrast leakage, and can be managed conservatively, requiring hospitalization for only 5-6 d<sup>[11,24]</sup>. Genzlinger *et al*<sup>[28]</sup> found that up to 29% of patients who underwent ERCP showed pneumoperitoneum on plain radiography without clinical significance. However, further investigation is recommended in patients who have pneumoperitoneum and clinical signs of infection.

The surgical indications in the studies mentioned here differed from recommendations stated by Stapfer *et al*<sup>[12]</sup>, which include large extravasation of contrast, fluid collection in the peritoneal or retroperitoneal space on follow-up computed tomography scan, massive subcutaneous emphysema, or retained choledocholithiasis. Our recommendation is to perform salvage surgery in patients with: (1) failure of initial endoscopic closure, especially type I or type II perforations; (2) no improvement in clinical signs of sepsis, or follow-up abdominal signs worsening within 12-24 h after successful endoscopic closure (type I) or conservative management (type II); and (3) retained instruments or choledocholithiasis requiring surgical removal.

### Delayed diagnosis

The prognosis is generally worse for any type of perforation with a delayed diagnosis, and most patients develop

**Table 2** Factors associated with increased risk of post-endoscopic retrograde cholangiopancreatography perforation (from Enns *et al*<sup>[24]</sup>)

Factors	Results of multivariate analysis [OR (95%CI)]
Dilated common bile duct	2.32 (1.02-5.03)
Sphincter of oddi dysfunction	3.20 (1.64-8.94)
Longer duration of procedure	1.02 (1.00-1.04)
Biliary stricture dilatation	7.29 (1.84-28.11)
Performance of sphincterotomy	6.94 (2.43-19.77)

clinical signs of peritonitis and sepsis within 1-5 d after the procedure<sup>[26-28]</sup>. It is important to note that abdominal signs might be relatively benign within the first few hours, even for type I perforations, however the presentation of peritoneal signs as a late finding is related to a poor clinical outcome<sup>[11]</sup>. Surgical drainage and correction is recommended in cases of delayed type II diagnosis with clinical sepsis<sup>[11,21,26,27]</sup>. However, most patients (50%-90%) having type II perforations with minimal leakage or type III perforations will respond to conservative treatment.

## PREVENTION OF ERCP-RELATED PERFORATION

There are several factors that have been associated with an increased risk for ERCP-related perforation (Table 2). Nonetheless, there are steps that can be taken to avoid causing ERCP-related perforations, beginning before the procedure, and continuing through the follow-up stage (Figure 5).

### Pre-procedural evaluation

Some patients have a higher risk of perforation because of surgically altered anatomy. Such patients should undergo "endoscopic scanning" using an end-view gastroscope before starting ERCP. In cases of failure to pass the end-view scope owing to anastomotic stricture or too much resistance, continuation with the ERCP procedure should first be discussed with the patients and their families. If the endoscopist decides to follow through with the procedure, a duodenoscope should be inserted in an "over-the-guidewire" fashion to minimize duodenal wall injury. When narrowing of the anastomosis site is encountered, balloon dilatation over the guidewire can be helpful prior to duodenoscope insertion. However, this is not recommended for cases with malignant strictures, but rather duodenal stenting with a self-expandable metal stent followed by ERCP in the subsequent weeks is more appropriate.

### During bile duct cannulation and intervention

There are several comments and recommendations concerning the procedure that should be kept in mind: (1) Patients with periampullary diverticula have a higher risk of perforation, especially from sphincterotomy. Therefore, the endoscopist must be very careful during this

process. A balloon sphincteroplasty is recommended in such cases, rather than endoscopic sphincterotomy; (2) Insertion of any ERCP instruments into the bile duct should be performed in an “over-the-guidewire” fashion to prevent a “false track.” Furthermore, the endoscopist should perform ERCP as gently as possible to minimize tissue injury; (3) Endoscopic sphincterotomy should be carried out in the suggested direction of 11 to 12 o’ clock for the common bile duct and 12 to 2 o’clock for pancreatic sphincterotomy. Over-bowing of the sphincterotomy should be avoided to prevent a “zipper cut,” and cutting should not go beyond the second fold above the papilla. Adequate knowledge and intensive observation of ampulla anatomy are essential for all endoscopists who perform ERCP; (4) Needle-knife sphincterotomy should be performed only by experienced endoscopists. Those who are less experienced should recognize their limitations and be responsible enough to request assistance; and (5) Dilatation of the ampulla increases the risk of perforation. Therefore, the endoscopist should consider the length of sphincterotomy or the size of balloon sphincteroplasty suitable for the objective of the maneuver, such as limited or no sphincterotomy for stenting, dilating the ampulla no more than the size of the common bile duct above, and an appropriately sized sphincterotomy depending on the size of the stone.

### During fluoroscopy

The endoscopist should observe the patient’s abdominal signs and perform fluoroscopy intermittently during the ERCP procedure. A diagnosis can be immediately made upon recognition of an abnormal guidewire position, extravasation of contrast, or pneumoperitoneum, which can allow for prompt treatment. Furthermore, a fluoroscopic abdominal scan should be performed after any difficult procedure to identify possible complications.

### Post-procedural care

Patients should be encouraged to promptly report any abdominal symptoms and should be watched for abnormal clinical signs after the ERCP procedure. The ward staff should be notified to maintain special observation of patients with difficult cases for early detection of possible complications.

## CONCLUSION

As ERCP-related perforations are a serious complication with a high mortality rate, endoscopists should perform the procedure with caution. To avoid perforation, endoscopists must evaluate the risks related to the patient and the procedure and perform the procedure with care. Once a perforation occurs, immediate diagnosis and early management are key factors to minimize mortality.

## REFERENCES

- 1 Loperfido S, Angelini G, Benedetti G, Chilovi F, Costan F, De Berardinis F, De Bernardin M, Ederle A, Fina P, Frattin

- A. Major early complications from diagnostic and therapeutic ERCP: a prospective multicenter study. *Gastrointest Endosc* 1998; **48**: 1-10 [PMID: 9684657 DOI: 10.1016/S0016-5107(98)70121-X]
- 2 Wu HM, Dixon E, May GR, Sutherland FR. Management of perforation after endoscopic retrograde cholangiopancreatography (ERCP): a population-based review. *HPB (Oxford)* 2006; **8**: 393-399 [PMID: 18333093]
- 3 Maranki J, Yeaton P. Prevention of post-ERCP pancreatitis. *Curr Gastroenterol Rep* 2013; **15**: 352 [PMID: 24193373 DOI: 10.1007/s11894-013-0352-2]
- 4 Masci E, Toti G, Mariani A, Curioni S, Lomazzi A, Dinelli M, Minoli G, Crosta C, Comin U, Fertitta A, Prada A, Passoni GR, Testoni PA. Complications of diagnostic and therapeutic ERCP: a prospective multicenter study. *Am J Gastroenterol* 2001; **96**: 417-423 [PMID: 11232684 DOI: 10.1111/j.1572-0241.2001.03594.x]
- 5 Jeurnink SM, Siersema PD, Steyerberg EW, Dees J, Poley JW, Haringsma J, Kuipers EJ. Predictors of complications after endoscopic retrograde cholangiopancreatography: a prognostic model for early discharge. *Surg Endosc* 2011; **25**: 2892-2900 [PMID: 21455806 DOI: 10.1007/s00464-011-1638-9: 21455806]
- 6 Zippi M, De Felici I, Pica R, Agus MA, Solinas A, Occhigrossi G, Traversa G. Self-expandable metal stent placement for treatment of severe sphincterotomy bleeding. *Clin Ter* 2013; **164**: e27-e29 [PMID: 23455748 DOI: 10.7417/CT.2013.1517]
- 7 Dunne R, McCarthy E, Joyce E, McEniff N, Guiney M, Ryan JM, Beddy P. Post-endoscopic biliary sphincterotomy bleeding: an interventional radiology approach. *Acta Radiol* 2013; **54**: 1159-1164 [PMID: 23892235 DOI: 10.1177/0284185113491567]
- 8 Balmadrid B, Kozarek R. Prevention and management of adverse events of endoscopic retrograde cholangiopancreatography. *Gastrointest Endosc Clin N Am* 2013; **23**: 385-403 [PMID: 23540966 DOI: 10.1016/j.giec.2012.12.007]
- 9 Yang XM, Hu B. Endoscopic sphincterotomy plus large-balloon dilation vs endoscopic sphincterotomy for choledocholithiasis: a meta-analysis. *World J Gastroenterol* 2013; **19**: 9453-9460 [PMID: 24409076 DOI: 10.3748/wjg.v19.i48.9453]
- 10 Alfieri S, Rosa F, Cina C, Tortorelli AP, Tringali A, Perri V, Bellantone C, Costamagna G, Doglietto GB. Management of duodeno-pancreato-biliary perforations after ERCP: outcomes from an Italian tertiary referral center. *Surg Endosc* 2013; **27**: 2005-2012 [PMID: 23299135 DOI: 10.1007/s00464-012-2702-9:23299135]
- 11 Miller R, Zbar A, Klein Y, Buyeviz V, Melzer E, Mosenkis BN, Mavor E. Perforations following endoscopic retrograde cholangiopancreatography: a single institution experience and surgical recommendations. *Am J Surg* 2013; **206**: 180-186 [PMID: 23870391 DOI: 10.1016/j.amjsurg.2012.07.050]
- 12 Stapfer M, Selby RR, Stain SC, Katkhouda N, Parekh D, Jabbour N, Garry D. Management of duodenal perforation after endoscopic retrograde cholangiopancreatography and sphincterotomy. *Ann Surg* 2000; **232**: 191-198 [PMID: 10903596 DOI: 10.1097/0000658-200008000-00007]
- 13 Howard TJ, Tan T, Lehman GA, Sherman S, Madura JA, Fogel E, Swack ML, Kopecky KK. Classification and management of perforations complicating endoscopic sphincterotomy. *Surgery* 1999; **126**: 658-663; discussion 664-665 [PMID: 10520912 DOI: 10.1016/S0039-6060(99)70119-4]
- 14 Kim BS, Kim IG, Ryu BY, Kim JH, Yoo KS, Baik GH, Kim JB, Jeon JY. Management of endoscopic retrograde cholangiopancreatography-related perforations. *J Korean Surg Soc* 2011; **81**: 195-204 [PMID: 22066121]
- 15 Kwon W, Jang JY, Ryu JK, Kim YT, Yoon YB, Kang MJ, Kim SW. Proposal of an endoscopic retrograde cholangiopancreatography-related perforation management guideline based on perforation type. *J Korean Surg Soc* 2012; **83**: 218-226 [PMID: 23091794]
- 16 Ruiz-Tovar J, Lobo E, Sanjuanbenito A, Martínez-Molina E.



- Case series: pneumoretroperitoneum secondary to duodenal perforation after endoscopic retrograde cholangiopancreatography. *Can J Surg* 2009; **52**: 68-69 [PMID: 19234656]
- 17 **Krishna RP**, Singh RK, Behari A, Kumar A, Saxena R, Kapoor VK. Post-endoscopic retrograde cholangiopancreatography perforation managed by surgery or percutaneous drainage. *Surg Today* 2011; **41**: 660-666 [PMID: 21533938 DOI: 10.1007/s00595-009-4331-z]
  - 18 **Lee TH**, Bang BW, Jeong JI, Kim HG, Jeong S, Park SM, Lee DH, Park SH, Kim SJ. Primary endoscopic approximation suture under cap-assisted endoscopy of an ERCP-induced duodenal perforation. *World J Gastroenterol* 2010; **16**: 2305-2310 [PMID: 20458771 DOI: 10.3748/wjg.v16.i18.2305]
  - 19 **Solomon M**, Schlachterman A, Morgenstern R. Iatrogenic duodenal perforation treated with endoscopic placement of metallic clips: a case report. *Case Rep Med* 2012; **2012**: 609750 [PMID: 22431936 DOI: 10.1155/2012/609750]
  - 20 **Kwon CI**, Song SH, Hahm KB, Ko KH. Unusual complications related to endoscopic retrograde cholangiopancreatography and its endoscopic treatment. *Clin Endosc* 2013; **46**: 251-259 [PMID: 23767036 DOI: 10.5946/ce.2013.46.3.251]
  - 21 **Salord S**, Gornals JB, Maisterra S, Pons C, Busquets J, Fabregat J. Endoscopic closure of duodenal perforation with an over-the-scope clip during endoscopic ultrasound-guided cholangiopancreatography. *Rev Esp Enferm Dig* 2012; **104**: 489-490 [PMID: 23130857 DOI: 10.4321/S1130-01082012000900007]
  - 22 **Dubecz A**, Ottmann J, Schweigert M, Stadlhuber RJ, Feith M, Wiessner V, Muschweck H, Stein HJ. Management of ERCP-related small bowel perforations: the pivotal role of physical investigation. *Can J Surg* 2012; **55**: 99-104 [PMID: 22564521]
  - 23 **Palanivelu C**, Jategaonkar PA, Rangarajan M, Anand NV, Senthilnathan P. Laparoscopic management of a retroperitoneal duodenal perforation following ERCP for periampullary cancer. *JSLs* 2008; **12**: 399-402 [PMID: 19275857]
  - 24 **Enns R**, Eloubeidi MA, Mergener K, Jowell PS, Branch MS, Pappas TM, Baillie J. ERCP-related perforations: risk factors and management. *Endoscopy* 2002; **34**: 293-298 [PMID: 11932784 DOI: 10.1055/s-2002-23650]
  - 25 **Mao Z**, Zhu Q, Wu W, Wang M, Li J, Lu A, Sun Y, Zheng M. Duodenal perforations after endoscopic retrograde cholangiopancreatography: experience and management. *J Laparoendosc Adv Surg Tech A* 2008; **18**: 691-695 [PMID: 18803511 DOI: 10.1089/lap.2008.0020]
  - 26 **Park WY**, Cho KB, Kim ES, Park KS. A case of ampullary perforation treated with a temporally covered metal stent. *Clin Endosc* 2012; **45**: 177-180 [PMID: 22866262 DOI: 10.5946/ce.2012.45.2.177]
  - 27 **Vezakis A**, Fragulidis G, Nastos C, Yiallourou A, Polydorou A, Voros D. Closure of a persistent sphincterotomy-related duodenal perforation by placement of a covered self-expandable metallic biliary stent. *World J Gastroenterol* 2011; **17**: 4539-4541 [PMID: 22110286 DOI: 10.3748/wjg.v17.i40.4539]
  - 28 **Genzlinger JL**, McPhee MS, Fisher JK, Jacob KM, Helzberg JH. Significance of retroperitoneal air after endoscopic retrograde cholangiopancreatography with sphincterotomy. *Am J Gastroenterol* 1999; **94**: 1267-1270 [PMID: 10235205 DOI: 10.1111/j.1572-0241.1999.00996.x]

**P- Reviewer:** Murata A, Thomopoulos KC **S- Editor:** Ji FF

**L- Editor:** A **E- Editor:** Liu SQ





## Primary intestinal lymphangiectasia: Minireview

Sachin B Ingle, Chitra R Hinge (Ingle)

Sachin B Ingle, Department of Pathology, MIMSR Medical College, Latur, Maharashtra 4132512, India

Chitra R Hinge (Ingle), Department of Physiology, MIMSR Medical College, Latur, Maharashtra 4132512, India

**Author contributions:** Ingle SB and Hinge (Ingle) CR prepared the manuscript; Ingle SB critically revised the intellectual content and gave final approval of manuscript.

**Correspondence to:** Sachin B Ingle, Professor, Department of Pathology, MIMSR Medical College, Ambajogai road, Vishwanathpuram, Latur, Maharashtra 4132512, India. [dr.sachiningle@gmail.com](mailto:dr.sachiningle@gmail.com)

Telephone: +91-2382-227424 Fax: +91-2382-228939

Received: April 18, 2014 Revised: June 28, 2014

Accepted: July 25, 2014

Published online: October 16, 2014

### Abstract

Primary idiopathic intestinal lymphangiectasia is an unusual disease featured by the presence of dilated lymphatic channels which are located in the mucosa, submucosa or subserosa leading to protein losing enteropathy. Most often affected were children and generally diagnosed before third year of life but may be rarely seen in adults too. Bilateral pitting oedema of lower limb is the main clinical manifestation mimicking the systemic disease and posing a real diagnostic dilemma to the clinicians to differentiate it from other common systemic diseases like Congestive cardiac failure, Nephrotic Syndrome, Protein Energy Malnutrition, *etc.* Diagnosis can be made on capsule endoscopy which can localise the lesion but unable to take biopsy samples. Thus, recently double-balloon enteroscopy and biopsy in combination can be used as an effective diagnostic tool to hit the correct diagnosis. Patients respond dramatically to diet constituting low long chain triglycerides and high protein content with supplements of medium chain triglyceride. So early diagnosis is important to prevent untoward complications related to disease or treatment for the sake of accurate pathological diagnosis.

**Key words:** Primary idiopathic intestinal lymphangiectasia; Mucosa-submucosa; Protein losing enteropathy; Double balloon endoscopy; Biopsy

**Core tip:** Waldmann's disease is an unusual primary idiopathic intestinal lymphangiectasia, which results in protein losing enteropathy. Recently, double balloon endoscopy and biopsy in combination is an effective diagnostic tool to hit the correct diagnosis to avoid untoward complications related to disease and treatment due to misdiagnosis. Thus, the clinician should keep in mind this rare condition as a differential diagnosis of oedema.

Ingle SB, Hinge (Ingle) CR. Primary intestinal lymphangiectasia: Minireview. *World J Clin Cases* 2014; 2(10): 528-533 Available from: URL: <http://www.wjgnet.com/2307-8960/full/v2/i10/528.htm> DOI: <http://dx.doi.org/10.12998/wjcc.v2.i10.528>

### INTRODUCTION

Primary Intestinal lymphangiectasia (PIL) was originally described in 1961 by Waldmann *et al*<sup>[1]</sup>. It is an unusual cause of protein losing enteropathy either due to congenital malformation or obstruction of lymphatics of intestine<sup>[2]</sup>. Lymphangiectasia is characterised by dilated and proliferating lymphatic channels located in mucosa, submucosa or subserosa leading to protein losing enteropathy and loss of lymph into gut resulting in to hypo-proteinemia, hypogammaglobulinemia, hypoalbuminemia and lymphopenia<sup>[3-5]</sup>. Peripheral oedema usually symmetrical (lower limb oedema) is the main clinical feature posing a real diagnostic dilemma to the clinicians to differentiate it from other common conditions like congestive cardiac failure, nephrotic syndrome, protein energy malnutrition, *etc*<sup>[3]</sup>. Other symptoms are ascites, pleural effusion, weight loss and abdominal pain, diarrhoea with increased faecal loss of protein and fat with increased serum levels of  $\alpha$ 1-antitrypsin<sup>[2,5]</sup>. Diagnosis is defined by endoscopic evaluation and confirmed on histopathologi-

cal evaluation of biopsy of small intestine<sup>[1]</sup>.

Now a day double balloon endoscopy and biopsy is the mainstay to arrive at correct diagnosis.

## EPIDEMIOLOGY

The worldwide incidence and prevalence of PIL is not known<sup>[2,6]</sup>. After 1961, as per available literature less than 200 cases were reported<sup>[7,8]</sup>. Very few familial forms are reported<sup>[1,2,9]</sup>. There is no specific predilection for sex and race<sup>[6]</sup>. Most commonly, it has been seen in children and majority of the cases were diagnosed at or before 3 years of age but can be seen in adults also<sup>[5,6]</sup>.

## PATHOPHYSIOLOGY

Waldmann's disease is also called as exudative enteropathy. The pathogenesis is not clear. The proposed hypothetical theories for pathogenesis are.

### Lymphatic obstruction theory

The basic cause for protein loss in PIL is poorly understood although lymphatic channel malformation/lymphatic hypoplasia leads to obstruction in lymph flow with resultant increase in intraluminal pressure in lymphatic channels<sup>[6,10,11]</sup>. This, increased intraluminal pressure will cause dilatation of the submucosal, subserosal lymphatic vessels in the intestine finally leading to the rupture of the cystically dilated channels and leading to discharge of the lymph into the bowel lumen<sup>[6,12]</sup>. Thus, net result is hypoalbuminemia, hypogammaglobulinemia and lymphopenia.

**Genetic theory:** There are mutations in genes that regulate the process of lymphogenesis<sup>[5]</sup>. Multiple genes, *e.g.*, vascular endothelial growth factor receptor 3, prospero-related homeobox-transcriptional factor, forkhead transcriptional factor and *SOX18* play vital role in lymphogenesis<sup>[13]</sup>. Mutation of the *CCBE1* gene has been identified as a cause of intestinal lymphangiectasia in Hennekam syndrome.

## CLINICAL PRESENTATION

Age-PIL is mainly seen in paediatric age group (usually before 3 years of age) and young adults but may be diagnosed in adults too<sup>[2,14-16]</sup>.

Oedema is the main clinical manifestation. The patient may present with ascites, pleural effusion and pericarditis. Other symptoms are lymphedema, abdominal pain, fatigue, moderate diarrhoea, weight loss and deficiency of fat soluble vitamins may also be present.

Oedema is of pitting type and usually symmetrical in distribution involving lower limb. Sometimes severe oedema involving face, scrotum or vagina<sup>[5]</sup>.

Rarely lymphedema have been described which is elicited by "stemmer's sign" and it is difficult to differentiate from other systemic causes of oedema<sup>[2,5]</sup>. Sonographic

evidence of fetal ascites had also been reported<sup>[2,5,17]</sup>.

Non-specific clinical features such as fatigue, nausea, vomiting, abdominal pain, weight loss, failure to thrive, moderate diarrhoea with faecal loss of fat along with increased faecal loss of protein, leading to rise in alpha-1-antitrypsin levels and there is deficiency of fat soluble vitamins<sup>[5,18]</sup>.

Hypocalcemia-patients can also develop hypocalcemia and tetany due to vitamin D deficiency<sup>[2,6,19]</sup>. A case of digital clubbing in PIL was reported<sup>[20]</sup>. Osteomalacia and osteoporosis associated with PIL was reported<sup>[21]</sup>.

**Rare Associations-**An association of PIL with celiac sprue was described<sup>[5,22]</sup>. PIL has been reported as a rare cause of lower gastrointestinal bleeding. In addition iron deficiency may occur<sup>[5,18]</sup>. Recently proved association with angiodysplasia leading to occult blood loss in PIL<sup>[5,23,24]</sup>.

A case of intestinal lymphangiectasia presenting as abdominal mass was reported<sup>[2,5,25]</sup>. Recurrent haemolytic uraemic syndrome has been described in association with intestinal lymphangiectasia<sup>[2,26]</sup>. Patients with PIL are prone to develop infections due to lymphopenia and hypogammaglobulinemia<sup>[18,27]</sup>.

Only two cases of disseminated cryptococcal meningitis and osteomyelitis in-patient with lymphangiectasia have been reported in the literature so far<sup>[28-30]</sup>. Recently another case of cryptococcal meningitis as primary manifestation in a patient with intestinal lymphangiectasia has been reported<sup>[30]</sup>. Lymphoma may complicate the long term outcome of PIL patients<sup>[5,31]</sup>.

PIL may exist as a part of a genetic syndromes, *i.e.*, Noonan, Von Recklinghausen, Hennekam and Yellow nail syndrome<sup>[2,5,14]</sup>. Finally, an association with autoimmune poly glandular disease type 1 has been described<sup>[5,32,33]</sup>. Recently a case of intestinal lymphangiectasia in a patient with infantile systemic hyalinosis syndrome has been reported<sup>[34]</sup>.

## DIAGNOSTIC EVALUATION

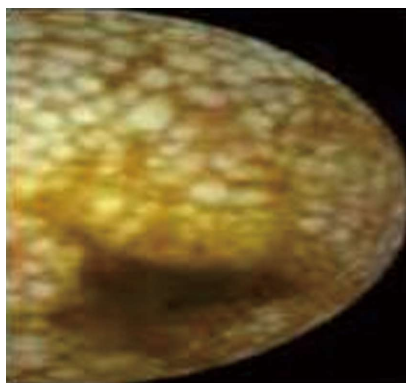
Now days, diagnosis of Intestinal lymphangiectasia is based on characteristic findings during a double-balloon enteroscopy with further confirmation by histopathological examination of corresponding biopsy specimens<sup>[6,35]</sup>. To confirm the primary nature of waldmanns disease we must first exclude the secondary causes of intestinal lymphangiectasia<sup>[6]</sup>.

### Capsule endoscopy

Capsule endoscopy provides complete examination of small bowel mucosa thus can evaluate the extent of lymphangiectasia<sup>[36,37]</sup>. However, the drawback of capsular endoscopy is the inability to obtain biopsies. So recently double balloon enteroscopy is evolved.

### Double balloon enteroscopy

In view of the drawback of capsular endoscopy, its inability to obtain biopsies, double balloon enteroscopy was



**Figure 1** Snow flake appearance.

evolved which allowed obtaining biopsies from lesions detected by capsular endoscopy<sup>[35,36]</sup>.

Endoscopy reveals scattered white spots, which have been described as a characteristic snowflake appearance, (Figure 1) overlying the small intestinal mucosa<sup>[4,38]</sup>.

### On endoscopy

Histopathological examination of biopsies shows dilated lymphatic vessels in mucosa, submucosa and serosa with polyclonal plasma cells confirming the intestinal lymphangiectasia (Figures 2).

Although various methods are available to investigate PIL, careful histopathological examination of biopsies is must to confirm the diagnosis. Various methods to investigate PIL are <sup>99</sup>Tc-HSA, 24 h stool alfa-1-antitrypsin clearance, lymphoscintigraphy, ultrasonography (USG), computed tomography (CT) scan, magnetic resonance imaging (MRI).

<sup>99</sup>Techetium-labelled scintigraphy is useful to arrive at the diagnosis of PIL. Due to high cost and infectious risk, it has replaced with alfa-1-antitrypsin method<sup>[2,39]</sup>.

Lymphoscintigraphy identifies abnormality in lymphatic tree but at present is not a routine method for PIL diagnosis<sup>[2,40,41]</sup>.

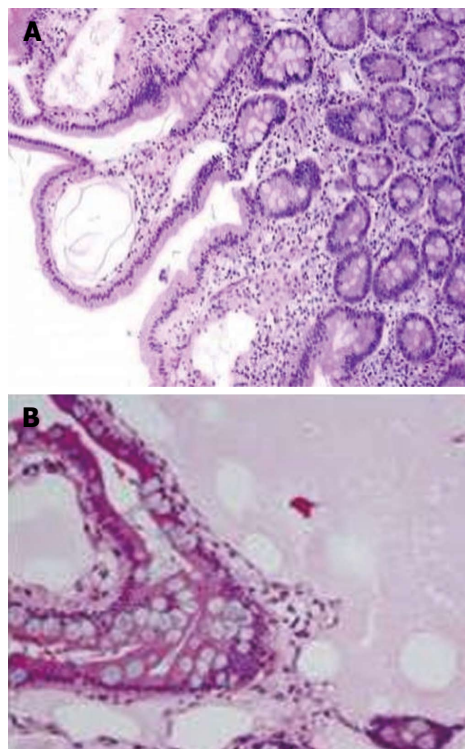
On radiographic barium studies, thickened irregular mucosal fold with tiny nodules representing dilated lymphatic suggest the intestinal lymphangiectasia<sup>[42]</sup>.

### Non-invasive modalities

Imaging with USG/CT scan has shown diffuse thickening of small bowel wall because of engorgement of villi that contain the dilated lymphatic channels<sup>[5,43]</sup>. CT scan may show "halo sign". A halo sign that consist of thickened, low-attenuation inner ring representing dilated lymphatics and higher attenuation outer ring, which consist of muscularis propria and serosa<sup>[43-45]</sup>. Nonenhanced, fluid-sensitive MRI may show bright signal intensity, which corresponds to lymphangiectasia in the mucosa<sup>[42,44]</sup>.

### Other laboratory investigations

PIL is associated with many laboratory findings which include decreased albumin and total protein levels<sup>[2,5,45]</sup>.



**Figure 2** Histopathological examination of biopsies. A: Dilated lymphatics in mucosa and submucosa; B: 40 ×; showing dilated lymphatic channels filled with lymph.

In Addition diminished immunoglobulins IgG, IgA and IgM suggesting B cell depletion and reduced numbers of CD4<sup>+</sup> cells as naive CD45RA<sup>+</sup> lymphocytes and CD45RO<sup>+</sup>CD8<sup>+</sup>T cells reflecting T-cell depletion seen<sup>[2,5,46,47]</sup>.

Finally, a recent report indicates there is failure of compensatory mechanism of production of T lymphocytes by the thymus to overcome the enteric loss of T lymphocytes leading to lymphopenia associated with lymphangiectasia<sup>[5,48]</sup>.

## DIFFERENTIAL DIAGNOSIS

The differential diagnosis of PIL is large and involves many conditions producing protein-losing gastroenteropathy. Much closer differential are those, which involve protein loss associated with impaired intestinal lymphatic drainage. Such conditions include cardiac causes like congestive cardiac failure, constrictive pericarditis and cardiomyopathy<sup>[49-52]</sup>. Surgical repair of complex congenital heart disease (such as the Fontan procedure for a functional single ventricle), other conditions like lymphenteric fistula<sup>[10,53]</sup>, Whipple's disease<sup>[54]</sup>, Crohn's disease<sup>[55]</sup>, sarcoidosis<sup>[56]</sup>, human immunodeficiency virus-related enteropathy<sup>[57]</sup>, intestinal tuberculosis<sup>[58]</sup>, radiation and/or chemotherapy with retroperitoneal fibrosis<sup>[59]</sup> and portal hypertension or hepatic venous outflow obstruction after liver transplantation and in congenital hepatic fibrosis due to phosphomannose isomerase deficiency<sup>[60]</sup>.



## TREATMENT

The principal treatment for PIL is diet rich in protein, low in fat with supplementation of medium chain triglyceride. Medium chain triglyceride is directly absorbed in portal venous circulation by passing the intestinal lymphatics, thus provides the energy and lessens lacteal engorgement and lymph loss. A low fat diet reduces lymphatic flow and pressure preventing the lacteal dilation and lymph leakage resulting from their rupture. In some, reversal of clinical and biochemical changes has been seen with this dietary modification. In most patients, dietary treatment is permanently needed. This is found to be more effective in children than adults. In some cases, total parenteral nutrition is needed. Supportive therapy includes albumin infusion and paracentesis.

In patients, not responding to such therapy other options may be used after or in combination with dietary modification. These are octreotide, antiplasmin, tranexemic acid, vitamin D supplementation and surgical resection of segmental or localised intestinal lymphangiectasia<sup>[8,11,61]</sup>.

To conclude PIL is an idiopathic protein losing enteropathy either due to genetic defect or due to lymphatic obstruction. Careful endoscopic examination and meticulous histopathological evaluation is mandatory to arrive at correct pathological diagnosis to decide the proper treatment plan. One should keep in mind this rare condition as a differential diagnosis of oedema.

## REFERENCES

- 1 **Waldmann TA**, Steinfeld JL, Dutcher TF, Davidson JD, Gordon RS. The role of the gastrointestinal system in "idiopathic hypoproteinemia". *Gastroenterology* 1961; **41**: 197-207 [PMID: 13782654]
- 2 **Vignes S**, Bellanger J. Primary intestinal lymphangiectasia (Waldmann's disease). *Orphanet J Rare Dis* 2008; **3**: 5 [PMID: 18294365 DOI: 10.1186/1750-1172-3-5]
- 3 **Katoch P**, Bhardwaj S. Lymphangiectasia of small intestine presenting as intussusception. *Indian J Pathol Microbiol* 2008; **51**: 411-412 [PMID: 18723975]
- 4 **Abramowsky C**, Hupertz V, Kilbridge P, Czinn S. Intestinal lymphangiectasia in children: a study of upper gastrointestinal endoscopic biopsies. *Pediatr Pathol* 1989; **9**: 289-297 [PMID: 2748490]
- 5 **Freeman HJ**, Nimmo M. Intestinal lymphangiectasia in adults. *World J Gastrointest Oncol* 2011; **3**: 19-23 [PMID: 21364842]
- 6 **Lai Y**, Yu T, Qiao XY, Zhao LN, Chen QK. Primary intestinal lymphangiectasia diagnosed by double-balloon enteroscopy and treated by medium-chain triglycerides: a case report. *J Med Case Rep* 2013; **7**: 19 [PMID: 23316917 DOI: 10.1186/1752-1947-7-19]
- 7 **Lee J**, Kong MS. Primary intestinal lymphangiectasia diagnosed by endoscopy following the intake of a high-fat meal. *Eur J Pediatr* 2008; **167**: 237-239 [PMID: 17453239 DOI: 10.1007/s00431-007-0445-8]
- 8 **Wen J**, Tang Q, Wu J, Wang Y, Cai W. Primary intestinal lymphangiectasia: four case reports and a review of the literature. *Dig Dis Sci* 2010; **55**: 3466-3472 [PMID: 20198428 DOI: 10.1007/s10620-010-1161-1]
- 9 **Le Bougeant P**, Delbrel X, Grenouillet M, Leou S, Djossou F, Beylot J, Lebras M, Longy-Boursier M. Familial Waldmann's disease. *Ann Med Interne (Paris)* 2000; **151**: 511-512 [PMID: 11104932]
- 10 **Mistilis SP**, Skyring AP, Stephen DD. Intestinal lymphangiectasia mechanism of enteric loss of plasma-protein and fat. *Lancet* 1965; **1**: 77-79 [PMID: 14234205 DOI: 10.1016/S0140-6736(65)91657-0]
- 11 **Jeffries GH**, Chapman A, Sleisenger MH. Low-fat diet in intestinal lymphangiectasia. its effect on albumin metabolism. *N Engl J Med* 1964; **270**: 761-766 [PMID: 14107315 DOI: 10.1056/NEJM196404092701503]
- 12 **Toskes P**. Gastrointestinal diseases: malabsorption. In Cecil Textbook of Medicine. 18th edition. Wyngaarden J, Smith L (eds). Philadelphia: WB Saunders, 1988: 732-745
- 13 **Hokari R**, Kitagawa N, Watanabe C, Komoto S, Kurihara C, Okada Y, Kawaguchi A, Nagao S, Hibi T, Miura S. Changes in regulatory molecules for lymphangiogenesis in intestinal lymphangiectasia with enteric protein loss. *J Gastroenterol Hepatol* 2008; **23**: e88-95 [PMID: 18005011]
- 14 **Al Sinani S**, Rawahi YA, Abdoon H. Octreotide in Hennekam syndrome-associated intestinal lymphangiectasia. *World J Gastroenterol* 2012; **18**: 6333-6337 [PMID: 23180957 DOI: 10.3748/wjg.v18.i43.6333]
- 15 **Boursier V**, Vignes S. [Limb lymphedema as a first manifestation of primary intestinal lymphangiectasia (Waldmann's disease)]. *J Mal Vasc* 2004; **29**: 103-106 [PMID: 15229406 DOI: 10.1016/S0398-0499(04)96858-8]
- 16 **Tift WL**, Lloyd JK. Intestinal lymphangiectasia. Long-term results with MCT diet. *Arch Dis Child* 1975; **50**: 269-276 [PMID: 50050 DOI: 10.1136/adc.50.4.269]
- 17 **Schmider A**, Henrich W, Reles A, Vogel M, Dudenhausen JW. Isolated fetal ascites caused by primary lymphangiectasia: a case report. *Am J Obstet Gynecol* 2001; **184**: 227-228 [PMID: 11174507 DOI: 10.1067/mob.2001.106756]
- 18 **Xinias I**, Mavroudi A, Sapountzi E, Thomaidou A, Fotoulaki M, Kalambakas A, Karypidou E, Kollios K, Pardalos G, Imvrios G. Primary intestinal lymphangiectasia: is it always bad? Two cases with different outcome. *Case Rep Gastroenterol* 2013; **7**: 153-163 [PMID: 23626516 DOI: 10.1159/000348763]
- 19 **Lu YY**, Wu JF, Ni YH, Peng SS, Shun CT, Chang MH. Hypocalcemia and tetany caused by vitamin D deficiency in a child with intestinal lymphangiectasia. *J Formos Med Assoc* 2009; **108**: 814-818 [PMID: 19864203]
- 20 **Wiedermann CJ**, Kob M, Benvenuti S, Carella R, Lucchin L, Piazzzi L, Chilovi F, Mazzoleni G. Digital clubbing in primary intestinal lymphangiectasia: a case report. *Wien Med Wochenschr* 2010; **160**: 431-436 [PMID: 20812055 DOI: 10.1007/s10354-010-0815-0]
- 21 **Li XP**, Shen WB, Long MQ, Meng XW, Lian XL, Yu M. Osteomalacia and osteoporosis associated with primary intestinal lymphangiectasis. *Chin Med J (Engl)* 2012; **125**: 1836-1838 [PMID: 22800909]
- 22 **Perisic VN**, Kokai G. Coeliac disease and lymphangiectasia. *Arch Dis Child* 1992; **67**: 134-136 [PMID: 1739329]
- 23 **Maamer AB**, Baazaoui J, Zaafouri H, Soualah W, Cherif A. Primary intestinal lymphangiectasia or Waldmann's disease: a rare cause of lower gastrointestinal bleeding. *Arab J Gastroenterol* 2012; **13**: 97-98 [PMID: 22980601 DOI: 10.1016/j.ajg.2012.03.001]
- 24 **Macdonald J**, Porter V, Scott NW, McNamara D. Small bowel lymphangiectasia and angiodysplasia: a positive association; novel clinical marker or shared pathophysiology? *J Clin Gastroenterol* 2010; **44**: 610-614 [PMID: 20535025]
- 25 **Rao R**, Shashidhar H. Intestinal lymphangiectasia presenting as abdominal mass. *Gastrointest Endosc* 2007; **65**: 522-523, discussion 523 [PMID: 17321261]
- 26 **Kalman S**, Bakkaloğlu S, Dalgıç B, Ozkaya O, Söylemezoğlu O, Buyan N. Recurrent hemolytic uremic syndrome associated with intestinal lymphangiectasia. *J Nephrol* 2007; **20**: 246-249 [PMID: 17514630]
- 27 **Dierselhuys MP**, Boelens JJ, Versteegh FG, Weemaes C,



- Wulffraat NM. Recurrent and opportunistic infections in children with primary intestinal lymphangiectasia. *J Pediatr Gastroenterol Nutr* 2007; **44**: 382-385 [PMID: 17325562]
- 28 **Cole SL**, Ledford DK, Lockey RF, Dass A, Kooper J. Primary gastrointestinal lymphangiectasia presenting as cryptococcal meningitis. *Ann Allergy Asthma Immunol* 2007; **98**: 490-492 [DOI: 10.1016/S1081-1206(10)60765-X]
- 29 **Oehler RL**, Maldonado A, Mastorides SM, Reed JL. Cryptococcal osteomyelitis complicating intestinal lymphangiectasia. *Infect Dis Clin Pract* 2007; **15**: 125-128
- 30 **Jabeen SA**, Murthy A, Kandadai RM, Meena AK, Borgohain R, Uppin MS. Cryptococcal meningitis as a primary manifestation in a patient with intestinal lymphangiectasia. *Ann Indian Acad Neurol* 2012; **15**: 218-220 [PMID: 22919199 DOI: 10.4103/0972-2327.99725]
- 31 **Bouhnik Y**, Etienney I, Nemeth J, Thevenot T, Lavergne-Slove A, Matuchansky C. Very late onset small intestinal B cell lymphoma associated with primary intestinal lymphangiectasia and diffuse cutaneous warts. *Gut* 2000; **47**: 296-300 [PMID: 10896925]
- 32 **Bereket A**, Lowenheim M, Blethen SL, Kane P, Wilson TA. Intestinal lymphangiectasia in a patient with autoimmune polyglandular disease type I and steatorrhea. *J Clin Endocrinol Metab* 1995; **80**: 933-935 [PMID: 7883852]
- 33 **Makharia GK**, Tandon N, Stephen Nde J, Gupta SD, Tandon RK. Primary intestinal lymphangiectasia as a component of autoimmune polyglandular syndrome type I: a report of 2 cases. *Indian J Gastroenterol* 2007; **26**: 293-295 [PMID: 18431016]
- 34 **Alreheili K**, AlMehaidib A, Alsaleem K, Banemi M, Aldekhail W, Al-Mayouf SM. Intestinal lymphangiectasia in a patient with infantile systemic hyalinoses syndrome: a rare cause of protein-losing enteropathy. *Ann Saudi Med* 2012; **32**: 206-208 [PMID: 22366835]
- 35 **Oh TG**, Chung JW, Kim HM, Han SJ, Lee JS, Park JY, Song SY. Primary intestinal lymphangiectasia diagnosed by capsule endoscopy and double balloon enteroscopy. *World J Gastrointest Endosc* 2011; **3**: 235-240 [PMID: 22110841]
- 36 **Gay G**, Delvaux M, Frederic M. Capsule endoscopy in non-steroidal anti-inflammatory drugs-enteropathy and miscellaneous, rare intestinal diseases. *World J Gastroenterol* 2008; **14**: 5237-5244 [PMID: 18785273]
- 37 **Chamouard P**, Nehme-Schuster H, Simler JM, Finck G, Baumann R, Pasquali JL. Videocapsule endoscopy is useful for the diagnosis of intestinal lymphangiectasia. *Dig Liver Dis* 2006; **38**: 699-703 [PMID: 16527553]
- 38 **Asakura H**, Miura S, Morishita T, Aiso S, Tanaka T, Kitahara T, Tsuchiya M, Enomoto Y, Watanabe Y. Endoscopic and histopathological study on primary and secondary intestinal lymphangiectasia. *Dig Dis Sci* 1981; **26**: 312-320 [PMID: 7238258 DOI: 10.1007/BF01308371]
- 39 **Chiu NT**, Lee BF, Hwang SJ, Chang JM, Liu GC, Yu HS. Protein-losing enteropathy: diagnosis with 99mTc-labeled human serum albumin scintigraphy. *Radiology* 2001; **219**: 86-90
- 40 **So Y**, Chung JK, Seo JK, Ko JS, Kim JY, Lee DS, Lee MC. Different patterns of lymphoscintigraphic findings in patients with intestinal lymphangiectasia. *Nucl Med Commun* 2001; **22**: 1249-1254 [PMID: 11606892 DOI: 10.1097/00006231-20011000-00013]
- 41 **Burnand KG**, McGuinness CL, Lagattolla NR, Browse NL, El-Arabi A, Nunan T. Value of isotope lymphography in the diagnosis of lymphoedema of the leg. *Br J Surg* 2002; **89**: 74-78 [PMID: 11851667 DOI: 10.1046/j.0007-1323.2001.01964.x]
- 42 **Steines JC**, Larson JH, Wilkinson N, Kirby P, Goodheart MJ. Intestinal lymphangiectasia mimicking primary peritoneal carcinoma. *Am J Obstet Gynecol* 2010; **203**: e9-e11 [PMID: 20801422]
- 43 **Yang DM**, Jung DH. Localized intestinal lymphangiectasia: CT findings. *AJR Am J Roentgenol* 2003; **180**: 213-214 [PMID: 12490507]
- 44 **Holznecht N**, Helmberger T, Beuers U, Rust C, Wiebecke B, Reiser M. Cross-sectional imaging findings in congenital intestinal lymphangiectasia. *J Comput Assist Tomogr* 2002; **26**: 526-528 [PMID: 12218814 DOI: 10.1097/00004728-200207000-00009]
- 45 **Strober W**, Wochner RD, Carbone PP, Waldmann TA. Intestinal lymphangiectasia: a protein-losing enteropathy with hypogammaglobulinemia, lymphocytopenia and impaired homograft rejection. *J Clin Invest* 1967; **46**: 1643-1656 [PMID: 4168730 DOI: 10.1172/JCI105656]
- 46 **Heresbach D**, Raoul JL, Genetet N, Noret P, Siproudhis L, Ramée MP, Bretagne JF, Gosselin M. Immunological study in primary intestinal lymphangiectasia. *Digestion* 1994; **55**: 59-64 [PMID: 7509299 DOI: 10.1159/000201124]
- 47 **Fuss IJ**, Strober W, Cuccherini BA, Pearlstein GR, Bossuyt X, Brown M, Fleisher TA, Horgan K. Intestinal lymphangiectasia, a disease characterized by selective loss of naive CD45RA+ lymphocytes into the gastrointestinal tract. *Eur J Immunol* 1998; **28**: 4275-4285 [PMID: 9862365]
- 48 **Vignes S**, Carcelain G. Increased surface receptor Fas (CD95) levels on CD4+ lymphocytes in patients with primary intestinal lymphangiectasia. *Scand J Gastroenterol* 2009; **44**: 252-256 [PMID: 18855225 DOI: 10.1080/00365520802321220]
- 49 **Davidson JD**, Waldmann TA, Goodman DS, Gordon RS. Protein-losing gastroenteropathy in congestive heart-failure. *Lancet* 1961; **1**: 899-902 [PMID: 13720056 DOI: 10.1016/S0140-6736(61)91768-8]
- 50 **Valberg LS**, Corbett WE, McCorriston JR, Parker JO. Excessive loss of plasma protein into the gastrointestinal tract associated with primary myocardial disease. *Am J Med* 1965; **39**: 668-673 [PMID: 5831904 DOI: 10.1016/0002-9343(65)90088-4]
- 51 **Müller C**, Globits S, Glogar D, Klepetko W, Knoflach P. Constrictive pericarditis without typical haemodynamic changes as a cause of oedema formation due to protein-losing enteropathy. *Eur Heart J* 1991; **12**: 1140-1143 [PMID: 1782939]
- 52 **Wilkinson P**, Pinto B, Senior JR. Reversible protein-losing enteropathy with intestinal lymphangiectasia secondary to chronic constrictive pericarditis. *N Engl J Med* 1965; **273**: 1178-1181 [PMID: 5847556 DOI: 10.1056/NEJM19651125273202]
- 53 **Feldt RH**, Driscoll DJ, Offord KP, Cha RH, Perrault J, Schaff HV, Puga FJ, Danielson GK. Protein-losing enteropathy after the Fontan operation. *J Thorac Cardiovasc Surg* 1996; **112**: 672-680 [PMID: 8800155]
- 54 **Laster L**, Waldmann TA, Fenster LF, Singleton JW. Albumin metabolism in patients with Whipple's disease. *J Clin Invest* 1966; **45**: 637-644 [PMID: 4160668 DOI: 10.1172/JCI105379]
- 55 **Steinfeld JL**, Davidson JD, Gordon RS, Greene FE. The mechanism of hypoproteinemia in patients with regional enteritis and ulcerative colitis. *Am J Med* 1960; **29**: 405-415 [PMID: 13834226 DOI: 10.1016/0002-9343(60)90036-X]
- 56 **Popović OS**, Brkić S, Bojić P, Kenić V, Jović N, Djurić V, Djordjević N. Sarcoidosis and protein losing enteropathy. *Gastroenterology* 1980; **78**: 119-125 [PMID: 7350018]
- 57 **Stockmann M**, Fromm M, Schmitz H, Schmidt W, Riecken EO, Schulzke JD. Duodenal biopsies of HIV-infected patients with diarrhoea exhibit epithelial barrier defects but no active secretion. *AIDS* 1998; **12**: 43-51 [PMID: 9456254 DOI: 10.1097/00002030-199801000-00006]
- 58 **Ploddi A**, Atisook K, Hargrove NS. Intestinal lymphangiectasia in intraabdominal tuberculosis. *J Med Assoc Thai* 1988; **71**: 518-523 [PMID: 3249186]
- 59 **Rao SS**, Dundas S, Holdsworth CD. Intestinal lymphangiectasia secondary to radiotherapy and chemotherapy. *Dig Dis Sci* 1987; **32**: 939-942 [PMID: 3608736 DOI: 10.1007/BF01296718]
- 60 **de Koning TJ**, Dorland L, van Berge Henegouwen GP. Phosphomannose isomerase deficiency as a cause of congenital hepatic fibrosis and protein-losing enteropathy. *J Hepatol*

- 1999; **31**: 557 [DOI: 10.1016/S0168-8278(99)80052-X]  
61 **Aoyagi K**, Iida M, Matsumoto T, Sakisaka S. Enteral nutrition as a primary therapy for intestinal lymphangiectasia:

value of elemental diet and polymeric diet compared with total parenteral nutrition. *Dig Dis Sci* 2005; **50**: 1467-1470 [PMID: 16110837 DOI: 10.1007/s10620-005-2863-7]

**P- Reviewer:** Kai K, Mubarak M **S- Editor:** Ji FF  
**L- Editor:** A **E- Editor:** Liu SQ



## Comparison of semilunar coronally repositioned flap with gingival massaging using an Ayurvedic product (irimedadi taila) in the treatment of class- I gingival recession: A clinical study

Amit Kumar Mishra, Kanteshwari Kumathalli, Raja Sridhar, Rahul Maru, Brijesh Mangal, Sameer Kedia, Ravi Shrihatti

Amit Kumar Mishra, ESIC Hospital, Nanda Nagar, Indore (M.P), 125-A, Sai Bagh Colony, Indore, Madhya Pradesh 452001, India  
Kanteshwari Kumathalli, Sri Aurobindo College of Dentistry, Village, Bhawrasala, Indore, Madhya Pradesh 453112, India  
Raja Sridhar, Brijesh Mangal, Sameer Kedia, Modern Dental College and Research Centre, Gandhinagar, Indore, Madhya Pradesh 453112, India

Rahul Maru, Index Dental College, Indore (M.P) 452001, India  
Ravi Shrihatti, Dr. D Y Patil Dental College and Hospital, Pune, Maharashtra 411018, India

**Author contributions:** Mishra AK contributed substantially to conception and design, acquisition of data, analysis and interpretation of data; study design, surgical treatment follow up and data collection; Kumathalli K guided throughout the study and final approval of the version to be published; Sridhar R contributed to first draft of the article and revision as suggested by reviewers; Maru R contributed to the drafting, corrections, second revision for important intellectual content; Mangal B and Kedia S contributed to the drafting the article, revising it critically for important intellectual content, corrections and third revision; Shrihatti R contributed substantially to the statistical analysis of the study.

**Correspondence to:** Dr. Brijesh Mangal, Modern Dental College and Research Centre, LG-21, 3-Urvashi Complex, Jaora Compound, Gandhinagar, Indore, Madhya Pradesh 453112, India. [brijeshmangal2000@gmail.com](mailto:brijeshmangal2000@gmail.com)

Telephone: +91-0731-4215248 Fax: +91-0731-4231010

Received: April 21, 2014 Revised: June 20, 2014

Accepted: August 27, 2014

Published online: October 16, 2014

### Abstract

**AIM:** To study the comparison in terms of root coverage the effect of gingival massaging using an ayurvedic product and semilunar coronally repositioned flap (SCRF) to assess the treatment outcomes in the management of Miller's class I gingival recessions over a-6

mo period.

**METHODS:** The present study comprised of total of 90 sites of Miller's class- I gingival recessions in the maxillary anteriors, the sites were divided into three groups each comprising 30 sites, Group I -were treated by massaging using a Placebo (Ghee) Group II -were treated by massaging using an ayurvedic product (irimedadi taila). Group III -were treated by SCRF. Clinical parameters assessed included recession height, recession width, probing pocket depth, width of attached gingiva, clinical attachment level and thickness of keratinized tissue. Clinical recordings were performed at baseline and 6 mo later. The results were analyzed to determine improvements in the clinical parameters. The comparison was done using Wilcoxon signed rank test. The overall differences in the clinical improvements between the three groups was done using Kruskal-Wallis test. The probability value (*P*-value) of less than 0.01 was considered as statistically significant.

**RESULTS:** Non-surgical periodontal therapy and gingival massaging improves facial gingival recessions and prevents further progression of mucogingival defects. Root coverage was achieved in both the experimental groups. The SCRF group proved to be superior in terms of all the clinical parameters.

**CONCLUSION:** Root coverage is significantly better with semilunar coronally repositioned flap compared with the gingival massaging technique in the treatment of shallow maxillary Miller class I gingival recession defects.

© 2014 Baishideng Publishing Group Inc. All rights reserved.

**Key words:** Gingival recession; Semilunar flaps; Gingi-

val massaging; Non-surgical

**Core tip:** Gingival recession is the migration of the gingival margin apical to the cemento-enamel junction. A variety of surgical procedures have been described for the correction and management of mucogingival deformities and defects, with a variable degree of success. However, it should be emphasized that shallow recessions are subject to progression, but there are no case reports or controlled clinical trials to compare the effects of gingival massaging in the treatment of gingival recessions. The aim of our study was to compare in terms of root coverage the effect of gingival massaging using an ayurvedic product and semilunar coronally repositioned flap to assess the treatment outcomes in the management of Miller's class I gingival recessions over a 6 mo period.

Mishra AK, Kumathalli K, Sridhar R, Maru R, Mangal B, Kedia S, Shrihatti R. Comparison of semilunar coronally repositioned flap with gingival massaging using an Ayurvedic product (irimedadi taila) in the treatment of class- I gingival recession: A clinical study. *World J Clin Cases* 2014; 2(10): 534-540 Available from: URL: <http://www.wjgnet.com/2307-8960/full/v2/i10/534.htm> DOI: <http://dx.doi.org/10.12998/wjcc.v2.i10.534>

## INTRODUCTION

Gingival recession is defined as the migration of the marginal tissue apical to the cemento-enamel junction (CEJ). Its occurrence is common and its prevalence increases with age. The recession of the gingiva resultant of attachment loss and root exposure may be associated with one or more tooth surfaces and lead to clinical problems such as dentinal hypersensitivity, root caries, cervical root abrasions and diminished cosmetic appeal<sup>[1,2]</sup>.

Miller<sup>[3]</sup> (1985) in his classification of recession has described class I recession as marginal tissue recession that does not extend up to the mucogingival junction and not accompanied by any loss of bone or soft tissue in the interdental area. Very often, it is the most coronal millimeter of recession which is visible when the patient smiles. Thus even a marginal gingival recession, can account for major aesthetic problems and persistent dentinal hypersensitivity<sup>[4]</sup>. In order to combat these clinical problems, various treatment modalities have been proposed that have in due course evolved based on the knowledge of healing of the gingiva and the attachment system.

Aimetti *et al.*<sup>[5]</sup> (2005) proposed non-surgical therapy *viz* periodic scaling and polishing for the treatment of shallow gingival recession. It was hypothesized that reduction of root convexity and elimination of microbial toxins from the root surface by scaling and root planing promotes creeping attachment of gingival margin. Tarnow<sup>[6]</sup> (1986) introduced the semilunar coronally repositioned flap (SCRF) procedure as one of the surgical

approaches to treat Class I gingival recessions. It entails coronal advancement of a semilunar flap without any tension or disturbance to the subjacent tissues. The flap is stabilized in the desirable position under gravity, hence a sutureless technique.

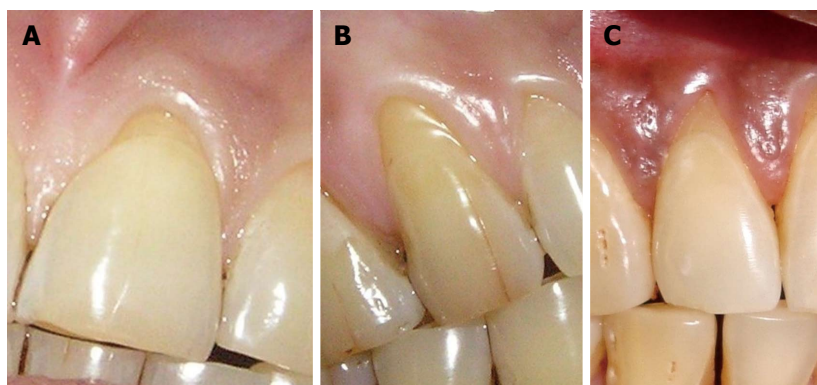
Gingival massaging an age old practice is said to increase capillary gingival microcirculation, thereby increasing oxygen sufficiency, gingival fibroblastic proliferation, keratinization of oral and sulcular epithelium, and formation of dense bundles of collagenous connective tissue all of which are attributable to creeping attachment<sup>[5,7]</sup>. Gingival massaging is carried out using various agents that aid lubrication as well as medication of the tissues. IrimedadiTaila an ayurvedic product is said to have been used for centuries by many communities in the Middle East and North Africa as a massaging agent<sup>[8]</sup>. It consists mainly of *Acacia arabica* a complex mixture of the calcium, magnesium and potassium salts of Arabic acid. Its antiplaque properties are said to create right conditions for gingiva to recapture its biologic dimensions<sup>[5,8]</sup>.

However no much of information is available upon an electronic or manual search concerning the effects of gingival massaging in the treatment of gingival recessions. There is a dearth of information as to by what exact mechanisms the non-surgical approaches help root coverage and to what extent if at all. Given that many patients are skeptical about surgical treatment, scaling/root planing followed by gingival massaging with an agent could be a better option provided their benefits are proved. This study is one such attempt to evaluate the effect of gingival massaging using an ayurvedic product in comparison with SCRF to assess the treatment outcomes in the management of Miller's class I gingival recessions. Hence the aim of the present study was to assess the efficacy of SCRF and gingival massaging (by placebo and IrimedadiTaila) in terms of root coverage in Miller's Class I recession, with respect to clinical parameters [Recession height (RH), recession width (RW), probing depth (PD), clinical attachment level (CAL), thickness of keratinized tissue (TKT) and width of attached gingiva]. Further, intergroup which comparisons of treatment outcomes to assess advantages or disadvantages of one technique over the other was also assessed.

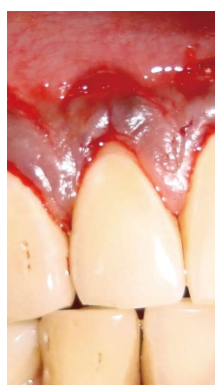## MATERIALS AND METHODS

A total of 90 sites of Miller's class- I gingival recessions on labial aspects of maxillary anteriors, were selected from the patients reporting to the out-patient department of Periodontics, Modern Dental College and Research Centre, Indore. Teeth associated with inadequate width of attached gingiva, caries/restorations were excluded. Pregnant females and individuals afflicted by systemic disease, tobacco/alcohol abuse, parafunctional habits were excluded from the study. Individuals who were already on the regimen of gingival massage or had undergone mucogingival surgery were dropped out of the study.





**Figure 1** Miller's class- I gingival recession. A: Miller's class- I gingival recession with 11; B: Miller's class- I gingival recession with 13; C: Miller's class- I gingival recession with 12.



**Figure 2** Coronally repositioned flap with 12.

The study protocol was approved by the ethical committee of Modern Dental College and Research Centre, Indore and study sites were randomly allocated to three different study groups after obtaining an informed consent. Group I (control group) comprised of 30 sites that were treated by massaging with placebo (clarified butter). Group II (test group) included 30 sites that were treated by massaging with an ayurvedic oil (Irmedadi Taila). Group III (test group) included 30 sites to be treated by SCRF<sup>[6]</sup>.

### Clinical evaluation

The sites were subjected to clinical assessments as follows: RH was measured as the distance from the CEJ to the gingival margin (GM), calculated in millimeters. RW was recorded as horizontal width of CEJ. Probing pocket depth was measured as the distance from the GM to the bottom of the gingival sulcus. CAL was calculated as recession height and probing depth (RH + PD). Width of attached gingiva was recorded as the distance between the free gingival groove and the MGJ. All the readings were recorded using a manual pressure-sensitive periodontal probe DB 764 R, (Aesculap, Tuttlingen, Germany) calibrated at a force of 0.2 N. Readings for TKT were obtained by penetrating the tissue with a 15 number endodontic spreader under lidocaine 15 gm spray and subsequently the penetration depth was measured with an electronic caliper of 0.01 mm resolution. The gingival

thickness was assessed at midbuccal level in the attached gingiva, half way between the mucogingival junction and free gingival groove<sup>[9]</sup>. These readings were recorded pre-operatively as well as 6 mo post-operatively and then subjected to statistical analysis.

### Clinical procedures

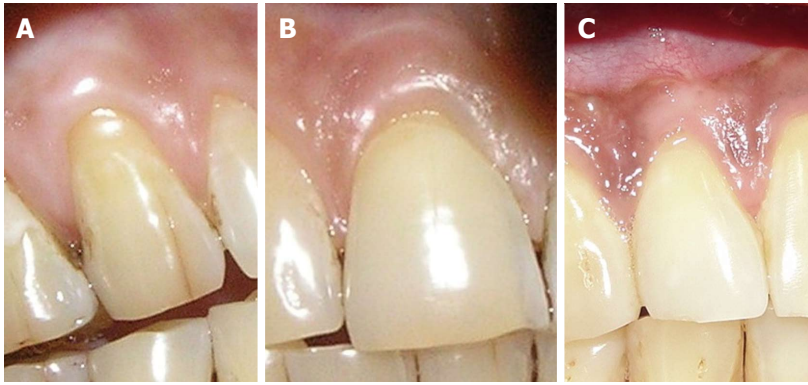
After a detailed examination and diagnosis, scrupulous oral prophylaxis was accomplished to ensure that local etiological factors are eliminated; followed by oral care instructions and patient motivation towards compliance. Patients belonging to group I (Figure 1A) and group II (Figure 1B) were trained to master the technique of gingival massaging with either of the agents as the case may be. The technique involved massaging their gums with finger three times daily for two minutes in the concerned area and then rinse away with water. Patients were instructed to comply with gingival massaging for the span of 6 mo, after which to report back for post-operative evaluation. Sites belonging to group III (Figure 1C) were treated surgically by semilunar coronally repositioned flap (Figure 2) as recommended by Tarnow<sup>[6]</sup>, followed by suitable postoperative surgical care and oral care instructions. The patients were recalled at 1, 3 and 6 mo post-operatively. One and 3 mo postoperative recall visits were utilized for reinforcement of oral care regimen and massaging techniques, wherein, readings at 6 mo postoperative follow up only were utilized for statistical analysis.

### Statistical analysis

Shapiro-Wilk test was applied to test for the Normalcy of the data. The parameters significantly differed from normal distribution, and therefore, all the comparisons were tabulated using Non-Parametric tests, *i.e.*, wilcoxon signed rank test, Kruskal Wallis and Mann Whitney *U* test. All comparisons were done using SPSS Statistical Software Package Version 10.0 and probability value (*P*-value) of less than 0.01 was considered as statistically significant.

## RESULTS

Gingival massaging with placebo (Ghee) (Figure 3A)



**Figure 3** Six months post-operative view. A: Six months post-operative view of 12; B: Six months post-operative view of 11; C: Six months post-operative view of 13.

**Table 1** Evaluation of clinical parameters from pre-operative to 6 mo post-operative period for group I -gingival massaging using a placebo (Clarified butter) ( $n = 30$ )

Clinical parameters	Baseline (mean $\pm$ SD)	6 mo (mean $\pm$ SD)	P-value (significance)
Recession height	1.7 $\pm$ 0.65	1.5 $\pm$ 0.51	0.034
Recession width	3.8 $\pm$ 0.66	3.57 $\pm$ 0.63	0.100
Probing pocket depth	1.9 $\pm$ 0.40	1.5 $\pm$ 0.51	0.001 <sup>b</sup> (S)
Clinical attachment level	3.5 $\pm$ 0.82	3 $\pm$ 0.87	0.002 <sup>b</sup> (S)
Thickness of keratinized tissue	0.84 $\pm$ 0.18	0.97 $\pm$ 0.21	< 0.001 <sup>b</sup> (S)
Width of attached gingiva	2.53 $\pm$ 0.57	2.8 $\pm$ 0.55	0.011

<sup>b</sup> $P < 0.01$ , clinical parameters from pre-operative vs 6 mo post-operative period. S: Significant.

**Table 3** Evaluation of clinical parameters from pre-operative to 6 mo post-operative period for Group-III semilunar coronally repositioned flap ( $n = 30$ )

Clinical parameters	Baseline (mean $\pm$ SD)	6 mo (mean $\pm$ SD)	P-value (significance)
Recession height	2.33 $\pm$ 0.55	0.57 $\pm$ 0.50	< 0.001 <sup>b</sup> (S)
Recession width	3.33 $\pm$ 0.76	1.1 $\pm$ 0.66	< 0.001 <sup>b</sup> (S)
Probing pocket depth	1.57 $\pm$ 0.50	1.33 $\pm$ 0.48	0.071
Clinical attachment level	3.87 $\pm$ 0.73	1.9 $\pm$ 0.66	< 0.001 <sup>b</sup> (S)
Thickness of keratinized tissue	0.97 $\pm$ 0.19	1.38 $\pm$ 0.23	< 0.001 <sup>b</sup> (S)
Width of attached gingiva	2.63 $\pm$ 0.71	3.37 $\pm$ 0.56	0.001 (S)

<sup>b</sup> $P < 0.01$ , clinical parameters from pre-operative vs 6 mo post-operative period. S: Significant.

resulted in a statistically significant reduction in probing pocket depth ( $P = 0.001$ ), gain in clinical attachment level ( $P = 0.002$ ) and increase in thickness of keratinized tissue ( $P < 0.001$ ). The clinical improvements with respect to recession height, recession width and width of attached gingiva were statistically nonsignificant (Table 1). Gingival massaging using an ayurvedic product (Irimedadi Taila) (Figure 3B), on the contrary resulted in to statistically significant reductions in recession height and recession width ( $P < 0.003$  and  $P < 0.001$  respectively); also a significant gain in thickness of keratinized tissue and width of attached gingiva ( $P < 0.001$ ) and ( $P = 0.001$ ) respectively. But reductions in probing pocket depth and clinical

**Table 2** Evaluation of clinical parameters from pre-operative to 6 mo post-operative period for group-II gingival massaging using an ayurvedic oil (Irimedadi Taila) ( $n = 30$ )

Clinical parameters	Baseline (mean $\pm$ SD)	6 mo (mean $\pm$ SD)	P-value (significance)
Recession height	1.77 $\pm$ 0.63	1.27 $\pm$ 0.58	0.003 <sup>b</sup> (S)
Recession width	3.3 $\pm$ 0.46	2.23 $\pm$ 0.43	< 0.001 <sup>b</sup> (S)
Probing pocket depth	1.47 $\pm$ 0.50	1.63 $\pm$ 0.49	0.096 (NS)
Clinical attachment level	3.23 $\pm$ 0.82	2.9 $\pm$ 0.76	0.064 (NS)
Thickness of keratinized tissue	0.85 $\pm$ 0.17	1.07 $\pm$ 0.19	< 0.001 <sup>b</sup> (S)
Width of attached gingiva	2.37 $\pm$ 0.56	2.9 $\pm$ 0.66	0.001 <sup>b</sup> (S)

<sup>b</sup> $P < 0.01$ , clinical parameters from pre-operative vs 6 mo post-operative period. S: Significant; NS: Non significant.

attachment level were statistically nonsignificant (Table 2). Sites treated by semilunar coronally repositioned flap (Figure 3C) exhibited highly significant improvements with respect to all the clinical parameters except probing pocket depth (Table 3).

Intergroup comparisons (Table 4) *via* Kruskal Wallis test aided in the determination of advantages of one technique over the other. Sites treated by SCRF exhibited highly significant improvements with respect to recession height ( $P < 0.001$ ), recession width ( $P < 0.001$ ), CAL ( $P < 0.001$ ), thickness of keratinized tissue ( $P < 0.004$ ) as compared to those treated by gingival massaging with the ayurvedic substance. However no significant difference was observed in relation to probing pocket depth between the groups (Table 5). Sites treated by SCRF had similar advantages when compared with sites treated by gingival massaging using a placebo (Table 6).

When compared between gingival massaging with an ayurvedic substance and placebo, former showed remarkable improvements only with respect to recession width ( $P < 0.001$ ), probing pocket depth ( $P < 0.001$ ) and thickness of keratinized tissue ( $P < 0.001$ ). However there was no significant difference with respect to CAL, recession height and width of keratinized gingiva (Table 7).

## DISCUSSION

Gingival recession is a common condition whose extent and prevalence has been noted to increase with age. It

**Table 4 Comparison of clinical parameters from pre-operative to 6 mo post-operative period between the three groups using Kruskal Wallis test<sup>1</sup>**

Clinical parameter	Group I	Group II	Group III	$\chi^2$	P-value (significance)
Recession height	0.2 ± 0.48	0.5 ± 0.78	1.77 ± 0.73	47.56	< 0.001 <sup>b</sup> (S)
Recession width	0.23 ± 0.77	1.07 ± 0.58	2.23 ± 0.82	51.28	< 0.001 <sup>b</sup> (S)
Probing pocket depth	0.4 ± 0.49	-0.17 ± 0.53	0.23 ± 0.68	13.29	< 0.001 <sup>b</sup> (S)
Clinical attachment level	0.5 ± 0.73	0.33 ± 0.96	1.97 ± 0.81	42.01	< 0.001 <sup>b</sup> (S)
Thickness of keratinized tissue	-0.13 ± 0.12	-0.23 ± 0.15	-0.41 ± 0.27	22.86	< 0.001 <sup>b</sup> (S)
Width of attached gingiva	-0.27 ± 0.52	-0.53 ± 0.68	-0.73 ± 0.98	7.03	0.03 (NS)

<sup>1</sup>Degree of freedom: 2. <sup>b</sup>P < 0.01, clinical parameters from pre-operative *vs* 6 mo post-operative period. S: Significant; NS: Non significant.

**Table 5 Comparison of clinical parameters between group 3 *vs* group 2 using Mann-Whitney U test**

Clinical parameter	Z value	P value (significance)
Recession height	-5.064	< 0.001 <sup>b</sup> (S)
Recession width	-4.996	< 0.001 <sup>b</sup> (S)
Probing pocket depth	-2.455	0.014
Clinical attachment level	-5.390	< 0.001 <sup>b</sup> (S)
Thickness of keratinized tissue	-2.841	0.004 (S)
Width of attached gingiva		

<sup>b</sup>P < 0.01, clinical parameters of group 3 *vs* group 2. S: Significant.

**Table 6 Comparison of clinical parameters between group 3 *vs* group 1 using Mann-Whitney U test**

Clinical parameter	Z value	P value (significance)
Recession height	-6.366	< 0.001 <sup>b</sup> (S)
Recession width	-6.141	< 0.001 <sup>b</sup> (S)
Probing pocket depth	-0.855	0.392
Clinical attachment level	-5.682	< 0.001 <sup>b</sup> (S)
Thickness of keratinized tissue	-4.441	< 0.001 <sup>b</sup> (S)
Width of attached gingiva		

<sup>b</sup>P < 0.01, clinical parameters of group 3 *vs* group 1. S: Significant.

**Table 7 Comparison of clinical parameters between group 2 *vs* group 1 using Mann-Whitney U test**

Clinical parameter	Z value	P value (significance)
Recession height	-1.772	0.076
Recession Width	-4.330	< 0.001 <sup>b</sup> (S)
Probing pocket depth	-3.734	< 0.001 <sup>b</sup> (S)
Clinical attachment level	-1.494	0.135
Thickness of keratinized tissue	-2.579	0.01 <sup>b</sup> (S)
Width of attached gingiva		

<sup>b</sup>P < 0.01, clinical parameters of group 2 *vs* group 1. S: Significant.

has been estimated that 50% of the population has one or more sites with 1mm or more of such root exposure. This prevalence rate increases to 88% for individuals above 65 years of age<sup>[10]</sup>.

Given the high prevalence rate of gingival recession defects among the general population, it is imperative that dental practitioners have an understanding of the etiology, complications and treatment options of the condition. Even in this era, when sophisticated techniques and materials are available, non-invasive approaches to treatment of recessions remain in practice with paramount importance. This study was carried out to assess the viability of surgical and non-surgical techniques for management of gingival recessions.

Numerous studies reported the efficacy and predictability of proposed surgical techniques. Several factors govern the selection of a surgical technique to treat recessed teeth such as the anatomy of the defect site, such as the size of the recession, width of keratinized tissue adjacent to the defect, dimensions of the interdental soft tissue, and the depth of the vestibule or the presence

of frenula and evidence based predictability of various procedures<sup>[11-13]</sup>. The SCRF surgical procedure is easy to perform and highly reproducible in shallow recession defects (class I) when gingival augmentation is not needed. Case reports<sup>[2,14,15]</sup> have shown a high success rate for this procedure.

Gingival massaging, an age old traditional oral hygiene practice which has been used for centuries by many communities have two quite separate effects on gingival keratinization. One, the direct effect of frictional stimulation leading to an increased mitotic rate and greater thickness of both the malpighian region and the stratum corneum of the gingival epithelium and the other, an indirect effect of the more efficient removal of dental plaque which leads to a reduction in inflammation, allows the gingival epithelium to express more fully its keratinizing potential<sup>[16]</sup>. The other effects of gingival massaging is said to increase capillary gingival microcirculation<sup>[17,18]</sup> thereby increasing oxygen sufficiency<sup>[19]</sup>, gingival fibroblastic proliferation<sup>[7]</sup>, and formation of dense bundles of collagenous connective tissue<sup>[20]</sup>. However, only one case is available in the literature<sup>[21]</sup> showing successful root coverage at multiple sites resulting from gingival massage. To our knowledge, there have been no long term controlled studies to provide outcome assessment data with regard to predictability and percentage of recession coverage by gingival massaging using ayurvedicoil. Hence this study was undertaken to compare benefits of gingival massaging using ayurvedic oil with those of SCRF technique in the treatment of class I recession.

This study witnessed that, although SCRF technique proved to be far superior, the clinical outcomes of gingival massaging by an ayurvedic oil (IrimedadiTaila) were



almost close to it (Tables 1, 2 and 3). Both the procedures produced statistically significant improvement with relation to recession height, recession width, thickness of keratinized tissue and width of attached gingiva, implying that both the methods are equivalent in root coverage and increasing width and thickness of attached gingiva. The significant root coverage achieved with of SCRF technique in the present study is almost in accordance with numerous other studies with only slight differences<sup>[12,22-26]</sup>. Some of those studies with higher success in root coverage have notably used additional methods of flap fixation such as sutures/adhesives or microsurgical techniques that may have enhanced clinical outcomes. Thus the differences in surgical protocols and measurement methods adapted in the study could be held responsible for variations in the results. The significant increase in width of attached gingiva with SCRF technique could be attributed to the granulation tissue that fills the semilunar area. Other studies too have presented similar observation although with slight variations<sup>[24,25,27-29]</sup>. This variability could be attributed to the bias in the methods used to identify the mucogingival position, surgical approach and improper case selection. The significant increase in the thickness of keratinized tissue in our study goes well in accordance with Bittencourt *et al*<sup>[26]</sup>. Increase in the thickness of gingival tissue is desirable since it can resist gingival recession resulting from faulty tooth brushing and inflammatory reactions<sup>[29,30]</sup>. But some authors have questioned the ability of thick gingival tissue in the prevention of recession. Based on a 2 year prospective clinical study authors recommend the practice of correct brushing technique to prevent recession instead of relying on the ability of thickness of gingiva<sup>[31]</sup>. Only long term follow up studies can determine the sound basis for this association. SCRF technique also leads to significant gain in CAL in the study sample. Similar observations have been reported by other studies too<sup>[24,26,32]</sup>. The probing depth reductions were non-significant.

In this study, an attempt was made to elucidate the role of creeping attachment in root coverage following gingival massaging with ayurvedic oil. Gain in CAL was assumed to be reflecting creeping attachment but the gain in CAL following gingival massaging were negligible (0.4-0.89 mm) and statistically non-significant (Table 2). These results are weak to support the hypothesis that, gingival massaging brings root coverage *via* creeping attachment. The available literature also lacks exact details as to when and how the creeping attachment starts and progresses. Certain studies have observed that creeping attachment occurs between 1 mo to 1 year.

In contrast, there was increase in the probing depths although negligible. This leads us to speculate that, massaging action may have lead to flattening and adaptation of gingival margin, or even marginal hypertrophy that majorly attributes to reduction in width and height of visible recession. Though this speculation may not hold strong consideration, it cannot be denied.

Intergroup comparisons (Table 4) demonstrated clear advantages of SCRF over gingival massaging with ay-

urvedic oil, which inturn is advantageous over gingival massaging with placebo (clarified butter). This clearly states the superior nature of SCRF in the treatment of class I recessions, while, gingival massaging with ayurvedic oil maintains close proximity to SCRF in terms of its clinical outcomes. Unfortunately no such data is available in the literature against which our observations could be compared.

Nevertheless SCRF procedure is a gold standard approach in terms of all the clinical parameters except for probing pocket depth and width of attached gingiva compared to the gingival massaging group. Under the circumstances where SCRF procedure remains contraindicated, or in patients who are skeptical on having to undergo surgical therapy for recession coverage, gingival massaging with an ayurvedic substance (IrmedadiTaila) offers a best alternative with almost equivalent benefits. Even the simple gingival massaging using an inert lubricant (such as Ghee) can be opted for as an adjunct to Scaling and root planing in areas of recession during maintenance phase.

## COMMENTS

### Background

The Semilunar coronally repositioned flap (SCRF) is one of the procedure described in the *Journal of Clinical Periodontology* in 1986 for the treatment of shallow recession. So far, however, no controlled clinical study has evaluated the SCRF performed as originally described and compared it with gingival massaging using an Ayurvedic product.

### Research frontiers

Root coverage was achieved in both the groups and was stable during the evaluation period of 6 mo.

### Innovations and breakthroughs

This is the pioneer study, where authors have used Ayurvedic product for massaging and results were significant when compared with SCRF technique.

### Applications

Daily home care by the patient and gingival massaging might play an important role in improving gingival recessions and prevents further progression of mucogingival defects.

### Terminology

IrmedadiTaila: Name of Ayurvedic massaging oil, with ingrediants like Acacia Arabica, etc., which is used for maintaining plaque free environment in the oral cavity.

### Peer review

The authors have chosen a very interesting and inexhaustible theme for the article.

## REFERENCES

- 1 Løe H, Anerud A, Boysen H. The natural history of periodontal disease in man: prevalence, severity, and extent of gingival recession. *J Periodontol* 1992; **63**: 489-495 [PMID: 1625148 DOI: 10.1902/JOP.1992.63.6.489]
- 2 Bouchard P, Malet J, Borghetti A. Decision-making in aesthetics: root coverage revisited. *Periodontol 2000* 2001; **27**: 97-120 [PMID: 11551302 DOI: 10.1034/J.1600-0757.2001.027001097.x]
- 3 Miller PD. A classification of marginal tissue recession. *Int J Periodontics Restorative Dent* 1985; **5**: 8-13 [PMID: 3858267]
- 4 Clauser C, Nieri M, Franceschi D, Pagliaro U, Pini-Prato G. Evidence-based mucogingival therapy. Part 2: Ordinary and individual patient data meta-analyses of surgical treatment of recession using complete root coverage as the outcome



- variable. *J Periodontol* 2003; **74**: 741-756 [PMID: 12816306 DOI: 10.1902/JOP.2003.74.5.741]
- 5 **Aimetti M**, Romano F, Peccolo DC, Debernardi C. Non-surgical periodontal therapy of shallow gingival recession defects: evaluation of the restorative capacity of marginal gingiva after 12 months. *J Periodontol* 2005; **76**: 256-261 [PMID: 15974850 DOI: 10.1902/JOP.2005.76.2.256]
  - 6 **Tarnow DP**. Semilunar coronally repositioned flap. *J Clin Periodontol* 1986; **13**: 182-185 [PMID: 3457805 DOI: 10.1111/J.1600-051X.1986.tb01456.x]
  - 7 **Horiuchi M**, Yamamoto T, Tomofuji T, Ishikawa A, Morita M, Watanabe T. Toothbrushing promotes gingival fibroblast proliferation more effectively than removal of dental plaque. *J Clin Periodontol* 2002; **29**: 791-795 [PMID: 12423290 DOI: 10.1034/J.1600-051X.2002.290901.x]
  - 8 **Gazi MI**. The finding of antiplaque features in Acacia Arabica type of chewing gum. *J Clin Periodontol* 1991; **18**: 75-77 [PMID: 2045522 DOI: 10.1111/j.1600-051X.1991.tb01123.x]
  - 9 **Goasind GD**, Robertson PB, Mahan CJ, Morrison WW, Olson JV. Thickness of facial gingiva. *J Periodontol* 1977; **48**: 768-771 [PMID: 271223 DOI: 10.1902/JOP.1977.48.12.768]
  - 10 **Kassab MM**, Cohen RE. The etiology and prevalence of gingival recession. *J Am Dent Assoc* 2003; **134**: 220-225 [PMID: 12636127 DOI: 10.14219/JADA.ARCHIVE.2003.0137]
  - 11 **Zucchelli G**, Testori T, De Sanctis M. Clinical and anatomical factors limiting treatment outcomes of gingival recession: a new method to predetermine the line of root coverage. *J Periodontol* 2006; **77**: 714-721 [PMID: 16584355 DOI: 10.1902/JOP.2006.050038]
  - 12 **Haghighati F**, Mousavi M, Moslemi N, Kebria MM, Golestani B. A comparative study of two root-coverage techniques with regard to interdental papilla dimension as a prognostic factor. *Int J Periodontics Restorative Dent* 2009; **29**: 179-189 [PMID: 19408480 DOI: 10.11607/PRD.00.0851]
  - 13 **Kerner S**, Sarfati A, Katsahian S, Jaumet V, Micheau C, Mora F, Monnet-Corti V, Bouchard P. Qualitative cosmetic evaluation after root-coverage procedures. *J Periodontol* 2009; **80**: 41-47 [PMID: 19228088 DOI: 10.1902/jop.2009.080413]
  - 14 **Thompson BK**, Meyer R, Singh GB, Mitchell W. Desensitization of exposed root surfaces using a semilunar coronally positioned flap. *Gen Dent* 2000; **48**: 68-71; quiz 72-73 [PMID: 11199557]
  - 15 **Casati MZ**, Nociti FH jr, Sallum Enilson A. Treatment of gingival recessions by semilunar coronally positioned flap. *Rev Assoc Paul Cir Dent* 2001; **55**: 169-172
  - 16 **Ekuni D**, Yamanaka R, Yamamoto T, Miyauchi M, Takata T, Watanabe T. Effects of mechanical stimulation by a powered toothbrush on the healing of periodontal tissue in a rat model of periodontal disease. *J Periodontol Res* 2010; **45**: 45-51 [PMID: 19602119 DOI: 10.1111/J.1600-0765.2009.01195.X]
  - 17 **Hanioka T**, Nagata H, Murakami Y, Tamagawa H, Shizukuishi S. Mechanical stimulation by toothbrushing increases oxygen sufficiency in human gingivae. *J Clin Periodontol* 1993; **20**: 591-594 [PMID: 8408721 DOI: 10.1111/J.1600-051X.1993.TB00776.X]
  - 18 **Perry DA**, McDowell J, Goodis HE. Gingival microcirculation response to tooth brushing measured by laser Doppler flowmetry. *J Periodontol* 1997; **68**: 990-995 [PMID: 9358366 DOI: 10.1902/JOP.1997.68.10.990]
  - 19 **Tanaka M**, Hanioka T, Kishimoto M, Shizukuishi S. Effect of mechanical toothbrush stimulation on gingival microcirculatory functions in inflamed gingiva of dogs. *J Clin Periodontol* 1998; **25**: 561-565 [PMID: 9696256 DOI: 10.1111/J.1600-051X.1998.tb02488.x]
  - 20 **Fraleigh CM**. Tissue changes with manual and electric brushes. *J Am Dent Assoc* 1965; **70**: 380-387 [PMID: 14232288]
  - 21 **Ando K**, Ito K, Murai S. Improvement of multiple facial gingival recession by non-surgical and supportive periodontal therapy: a case report. *J Periodontol* 1999; **70**: 909-913 [PMID: 10476900 DOI: 10.1902/JOP.1999.70.8.909]
  - 22 **Marggraf E**. A direct technique with a double lateral bridging flap for coverage of denuded root surface and gingiva extension. Clinical evaluation after 2 years. *J Clin Periodontol* 1985; **12**: 69-76 [PMID: 3855873 DOI: 10.1111/J.1600-051X.1985.tb01355.x]
  - 23 **Jahangirnezhad M**. Semiluncoronally repositioned flap for the treatment of gingival recession with and without tissue adhesives: a pilot study. *J Dent (Tehran)* 2006; **3**: 36-39
  - 24 **Bittencourt S**, Del Peloso Ribeiro E, Sallum EA, Sallum AW, Nociti FH, Casati MZ. Comparative 6-month clinical study of a semilunar coronally positioned flap and subepithelial connective tissue graft for the treatment of gingival recession. *J Periodontol* 2006; **77**: 174-181 [PMID: 16460241 DOI: 10.1902/JOP.2006.050114]
  - 25 **Bittencourt S**, Ribeiro Edel P, Sallum EA, Sallum AW, Nociti FH, Casati MZ. Root surface biomodification with EDTA for the treatment of gingival recession with a semilunar coronally repositioned flap. *J Periodontol* 2007; **78**: 1695-1701 [PMID: 17760538 DOI: 10.1902/JOP.2007.060507]
  - 26 **Bittencourt S**, Ribeiro Edel P, Sallum EA, Sallum AW, Nociti FH, Casati MZ. Semilunar coronally positioned flap or subepithelial connective tissue graft for the treatment of gingival recession: a 30-month follow-up study. *J Periodontol* 2009; **80**: 1076-1082 [PMID: 19563287 DOI: 10.1902/JOP.2009.080498]
  - 27 **Pini Prato G**, Tinti C, Vincenzi G, Magnani C, Cortellini P, Clauser C. Guided tissue regeneration versus mucogingival surgery in the treatment of human buccal gingival recession. *J Periodontol* 1992; **63**: 919-928 [PMID: 1453307 DOI: 10.1902/JOP.1992.63.11.919]
  - 28 **Rosetti EP**, Marcantonio RA, Rossa C, Chaves ES, Goissis G, Marcantonio E. Treatment of gingival recession: comparative study between subepithelial connective tissue graft and guided tissue regeneration. *J Periodontol* 2000; **71**: 1441-1447 [PMID: 11022773 DOI: 10.1902/JOP.2000.71.9.1441]
  - 29 **Müller HP**, Stahl M, Eger T. Root coverage employing an envelope technique or guided tissue regeneration with a bioabsorbable membrane. *J Periodontol* 1999; **70**: 743-751 [PMID: 10440635 DOI: 10.1902/jop.1999.70.7.743]
  - 30 **Paolantonio M**, Dolci M, Esposito P, D'Archivio D, Lisanti L, Di Luccio A, Perinetti G. Subpedicle acellular dermal matrix graft and autogenous connective tissue graft in the treatment of gingival recessions: a comparative 1-year clinical study. *J Periodontol* 2002; **73**: 1299-1307 [PMID: 12479634 DOI: 10.1902/JOP.2002.73.11.1299]
  - 31 **Wennström JL**, Zucchelli G. Increased gingival dimensions. A significant factor for successful outcome of root coverage procedures? A 2-year prospective clinical study. *J Clin Periodontol* 1996; **23**: 770-777 [PMID: 8877664 DOI: 10.1111/J.1600-051X.1996.tb00608.x]
  - 32 **Santana RB**, Mattos CM, Dibart S. A clinical comparison of two flap designs for coronal advancement of the gingival margin: semilunar versus coronally advanced flap. *J Clin Periodontol* 2010; **37**: 651-658 [PMID: 20528963 DOI: 10.1111/J.1600-051X.2010.01582.x]

P- Reviewer: Mishra AK, Pejic A, Zucchelli G  
S- Editor: Ji FF L- Editor: A E- Editor: Liu SQ



## HLA antigens in individuals with down syndrome and alopecia areata

Juliany L Estefan, Juliana C Oliveira, Eliane D Abad, Simone B Saintive, Luis Cristóvão MS Porto, Marcia Ribeiro

Juliany L Estefan, Eliane D Abad, Simone B Saintive, Pediatric Dermatology Service, Martagão Gesteira Pediatric Institute, Federal University of Rio de Janeiro, Rio de Janeiro, RJ 21941-901, Brazil

Juliany L Estefan, Marcia Ribeiro, Medical Genetics Service, Martagão Gesteira Pediatric Institute, Federal University of Rio de Janeiro, Rio de Janeiro, RJ 21941-901, Brazil

Juliana C Oliveira, Luis Cristóvão MS Porto, Histocompatibility and Cryopreservation-HLA Laboratory, State University of Rio de Janeiro, Policlinica Piquet Carneiro/UERJ, Rio de Janeiro, RJ 21941-901, Brazil

**Author contributions:** Estefan JL contributed to research design, analysis and interpretation of data, drafting the paper and revising it critically; Oliveira JC, Abad ED and Saintive SB contributed to drafting the paper and revising it critically; Porto LCMS contributed to substantial contributions to research conception and design; drafting the paper and revising it critically; Ribeiro M contributed to substantial contributions to research conception and design, analysis and interpretation of data, drafting the paper and revising it critically; all authors contributed to final approval of the version to be published.

**Correspondence to:** Juliany L Estefan, MD, Msc, Medical Genetics Service, Martagão Gesteira Pediatrics Institute, Federal University of Rio de Janeiro, Rua Bruno Lobo, 50, Cidade Universitária, Ilha do Fundão, Rio de Janeiro, RJ 21941-901, Brazil. [ju\\_estefan@yahoo.com.br](mailto:ju_estefan@yahoo.com.br)

Telephone: +55-21-25626148

Received: April 2, 2014 Revised: June 3, 2014

Accepted: August 27, 2014

Published online: October 16, 2014

### Abstract

**AIM:** To describe human leukocyte antigen (HLA) alleles in individuals with Down syndrome and alopecia areata.

**METHODS:** A cross-sectional study was conducted, which evaluated 109 individuals. Ten with down syndrome (DS) and alopecia areata (AA), ten with DS without AA and ten with AA without DS, and their fami-

lies. The individuals were matched by gender and age. The following data were computed: gender, age, ethnic group, karyotype, clinical presentation and family history of alopecia areata. Descriptive analysis: measures of central tendency and frequency distribution. Inferential analysis: Fisher's exact test to compare categorical data between the three groups and Kruskal-Wallis ANOVA test for numerical data.

**RESULTS:** Seventy per cent of evaluated individuals in the DS and AA group were male; presented mean age of 18.6 (SD  $\pm$  7.2) years and 70% were Caucasian. We observed involvement of the scalp, with a single lesion in 10% and multiple in 90% of subjects. It was observed that there is no significant difference in the frequency distributions of the alleles HLA loci A, B, C, DRB1 and DQB1 of subjects studied. However, according to Fisher's exact test, there is a trend ( $P = 0.089$ ) of DS group to present higher proportions of HLA-A 36 and HLA-B 15 than the AA group and AA and DS group.

**CONCLUSION:** There was a tendency for the DS group, to present proportion of HLA-A 36 and HLA-B 15 higher than the AA group and group of individuals with AA and DS. However, there was no significant difference in the frequency distribution of the alleles.

© 2014 Baishideng Publishing Group Inc. All rights reserved.

**Key words:** Down syndrome; Alopecia areata; Human leukocyte antigen antigens; Immunology; Genetic

**Core tip:** The prevalence of alopecia areata (AA) in down syndrome (DS) individuals ranges from 1% to 11%, higher than in general population. The frequency distribution of human leukocyte antigen alleles in the groups was heterogeneous; there was a tendency of alleles A-36 and B-15 in DS group. The cause of AA in DS remains unknown.

Estefan JL, Oliveira JC, Abad ED, Saintive SB, Porto LCMS, Ribeiro M. HLA antigens in individuals with down syndrome and alopecia areata. *World J Clin Cases* 2014; 2(10): 541-545 Available from: URL: <http://www.wjgnet.com/2307-8960/full/v2/i10/541.htm> DOI: <http://dx.doi.org/10.12998/wjcc.v2.i10.541>

## INTRODUCTION

Down syndrome (DS) is the most frequent chromosomal anomaly and common cause of mental retardation<sup>[1,2]</sup>. The prevalence of DS is approximately 1:770 births, with a slight preponderance in the male gender<sup>[3]</sup>.

This syndrome presents an increased prevalence of autoimmune disorders<sup>[4]</sup>. The prevalence of alopecia areata (AA) in DS ranges from 1% to 11%, more frequent in this group than the general population<sup>[5-11]</sup>. Some studies conducted with DS patients with and without AA showed changes related to the immune system. There are few studies involving the histocompatibility antigens (HLA), DS and AA<sup>[12-14]</sup>.

The purpose of this study was to describe HLA alleles (loci A, B, C, DRB1 and DQB1) in individuals with DS and AA.

## MATERIALS AND METHODS

A cross-sectional study was conducted, in which 109 individuals were evaluated; 10 individuals with DS without AA (Group A) and 10 individuals with AA without DS (Group B), 10 individuals with DS and AA (Group C) and their families (Figure 1). The individuals were matched by gender and age. The clinical research protocol was approved by the Ethical Research Committee of the Martagão Gesteira Pediatric Institute (IPPMG) and all participants or their caregivers signed the informed consent.

All DS individuals were diagnosed clinically, most by cytogenetic analysis, and presented a documented medical history of AA or presented alopecia at the time of a consultation at the Medical Genetics Service. AA was considered to be hair loss leading to a "flaw" on any hairy body surface.

All the participants of the study were submitted to anamnesis and clinical exam to confirm DS and/or AA diagnosis by a clinical geneticist and by a dermatologist respectively. Exclusion criteria included: trichotillomania and presence of polycystic ovaries (evaluated by pelvic ultrasound in post-menarche female DS and/or AA patients).

The following data were computed: (1) gender and age; (2) cytogenetic exam; (3) ethnic group; (4) clinical picture of AA; (5) family history of AA; (6) HLA alleles; and (7) evaluation of family.

The HLA typing was performed using commercial kits: LABType® Typing sequence specific oligonucleotide probes (SSO) Tests (One Lambda, Inc. CA, United States), which are based on the use of SSO which are connected on the microbeads encoded by fluorescence identifying alleles encoded by the DNA sample.

A descriptive analysis with measures of central tendency and frequency distribution was made and an inferential analysis on exploratory level was made by Fisher's exact test to compare categorical data between the three groups by ANOVA and Kruskal-Wallis test for numerical data. Nonparametric test was used because the variables were not normally distributed (Gaussian), due to the dispersion of the data and rejection of the hypothesis of normality according to the Kolmogorov-Smirnov test. The criterion for determination of significance level was 5%.

## RESULTS

Table 1 provides the frequency (*n*) and percentage (%) of categorical variables and disease according to demographic groups (A, B and C) and the corresponding descriptive level (*P* value) of Fisher's exact test. The age in months and the number of family members were expressed as mean, median and standard deviation and compared by Kruskal-Wallis ANOVA.

Table 2 provides the frequency (*n*) and the percentage (%) of the loci of HLA-A, B, C, DQB1 and DRB1 alleles, in the groups (DS, AA and DS + AA) and corresponding descriptive level (*P* value) of Fisher's exact test.

Regarding the relatives evaluation of first and second degrees, it was observed that the majority of alleles showed a low frequency. We emphasize some alleles such as HLA-C 07 (21/55), HLA-DQB1 03 (28/55) and HLA-DQB1 06 (22/55) which had a high frequency (> 50%) in the first-degree relatives of all groups.

## DISCUSSION

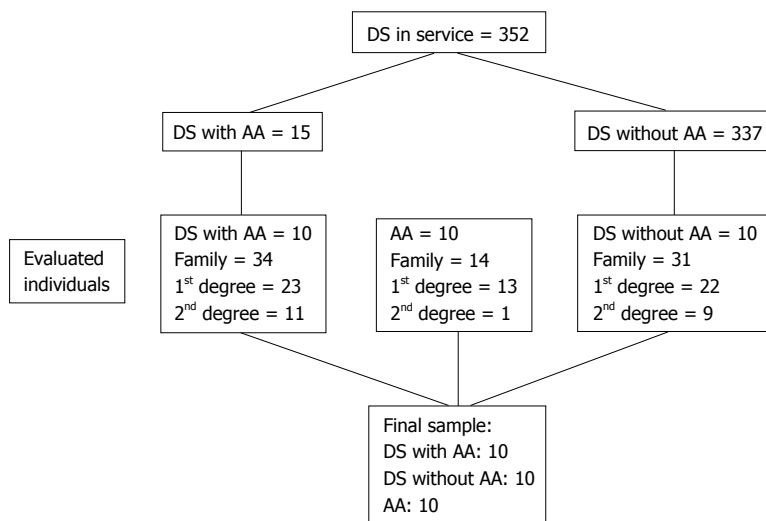
This study reflects an unpublished investigation in patients with DS. However, there was no statistical significance in the distribution of HLA in DS with or without AA. Although the sample size reflected a small number of patients, in general, the groups did not differ (Table 1), reflecting the selection criteria used. Several studies have focused on the association of HLA and AA; some of them correlating prognosis, extent, chance of recurrence and family history with HLA<sup>[15-17]</sup>. These studies report that HLADQB1\*03 allele was presented in 80% of all patients with AA, independently of the phenotype, and in 92% of individuals with total or universal AA. It was also demonstrated that the frequency of HLA-DRB1\*1104 was increased in all sorts of AA<sup>[15,16]</sup>. These data were not reported in this study.

Although the literature reports that the AA in individuals with DS is more common in females<sup>[5,18]</sup>, the sample was predominantly male (70.0%). Schepis *et al*<sup>[19]</sup> (2005) studied individuals with DS and AA, and also identified more men with AA (92.3%). Concerning the 352 DS cases recorded in IPPMG, 15 of them presented AA; the most frequently occurrence of AA in males was not significant (*P* > 0.05). AA can occur as a single and self-limited episode, but also can recur in DS patients<sup>[20,21]</sup>. In this study, 90% (9/10) individuals with DS and AA had

**Table 1** Demographic and disease variables according the group *n* (%)

Variable	Category	DS group (A)		AA group (B)		DS + AA group (C)		P value <sup>1</sup>
Gender	Male	7	(70.0)	7	(70.0)	7	(30.0)	1.000
	Female	3	(30.0)	3	(30.0)	3	(30.0)	
Age, mo	Average $\pm$ SD (median)	224.1 $\pm$ 86.0 (233.5)		217.3 $\pm$ 90.2 (197.0)		224.3 $\pm$ 86.9 (223.5)		0.970 <sup>2</sup>
Clinical presentation	1 lesion S			1	(10.0)	1	(10.0)	Descriptive
	1 lesion S/cilium			1	(10.0)	0	0.0	
	Lesions S			6	(60.0)	9	(90.0)	
	Lesion S/total			1	(10.0)	0	0.0	
	Lesion S/total/eyebrow			1	(10.0)	0	0.0	
Family history of alopecia	Yes	0	0	2	(20.0)	0	0	0.230
	No	10	(100.0)	8	(80.0)	10	(100.0)	
Karyotype	free trisomy	7	(100.0)			6	(85.7)	0.500
	Translocation	0	0			1	(14.3)	
Ethnic group	Caucasian	6	(60.0)	3	(30.0)	7	(70.0)	0.270
	Non-Caucasian	4	(40.0)	7	(70.0)	3	(30.0)	
Family ( <i>n</i> )	0	0	0	2	(20.0)	1	(10.0)	Descriptive
	1	3	(30.0)	5	(50.0)	3	(30.0)	
	2	2	(20.0)	1	(10.0)	0	0.0	
	3	2	(20.0)	1	(10.0)	0	0.0	
	4	0	0.0	1	(10.0)	2	(20.0)	
	5	1	(10.0)	0	0.0	2	(20.0)	
	6	1	(10.0)	0	0.0	1	(10.0)	
	7	1	(10.0)	0	0.0	1	(10.0)	
Family ( <i>n</i> )	Average $\pm$ SD (median)	3.1 $\pm$ 2.2 (2.5)		1.4 $\pm$ 1.3 (1)		3.4 $\pm$ 2.5 (4)		0.085 <sup>2</sup>

<sup>1</sup>Fisher exact test; <sup>2</sup>Kruskal-Wallis ANOVA. S: Scalp; DS: Down syndrome; AA: Alopecia areata.

**Figure 1** Structure of selected sample. DS: Down syndrome; AA: Alopecia areata.

more than one lesion on the scalp, and 10% (1/10) presented single lesion on the scalp. This finding was similar which is reported in the literature<sup>[19]</sup>. AA can affect any hairy area and the most affected is scalp (90%)<sup>[22-25]</sup>. All evaluated individuals presented scalp lesion.

Regarding family history, it is present in 10%-25% of cases of AA<sup>[10,26]</sup>. In this study we observed two cases (20%) of family history (first degree relative) in AA without DS group.

Genetic studies of AA have focused on HLA antigens due to immunological aspects of the disease<sup>[15,17,27,28]</sup>. Some have demonstrated that major complex of histocompatibility genes are the major determinants for dis-

eases mediated by T cells, including AA<sup>[29,30]</sup>. In this study, no significant difference was observed at the level of 5% on the proportion of HLA-A between groups. According to Fisher's exact test, there is a trend ( $P = 0.089$ ) of the DS group, present proportion of HLA-A 36 (30%) higher than the AA (0%) and DS with AA (0%) group. Xiao *et al*<sup>[17]</sup> (2006) evaluated Chinese individuals, 192 with AA and 252 controls and found higher frequency of HLA-A\*02 and A\*03 in patients than in controls. Despite not being the same allele, we can see that the distribution is in fact heterogeneous.

In the same study<sup>[17]</sup>, comparing patients and controls, a higher frequency of HLA-B\*18 and HLA-B\*27



**Table 2** Distribution of the most frequent human leukocyte antigen A, B, C, DQB1 and DRB1 alleles

Alleles	DS group (A)	AA group (B)	DS + AA group (C)	P value <sup>1</sup>
HLA-A 02	4 (40.0)	3 (30.0)	5 (50.0)	0.890
HLA-A 24	1 (10.0)	0	3 (30.0)	0.290
HLA-A 36	3 (30.0)	0	0	0.089
HLA-B 15	4 (40.0)	0	1 (10.0)	0.094
HLA-B 35	1 (10.0)	2 (20.0)	3 (30.0)	0.850
HLA-B 44	0	2 (20.0)	4 (40.0)	0.120
HLA-B 53	3 (30.0)	1 (10.0)	1 (10.0)	0.570
HLA-C 02	4 (40.0)	0	2 (20.0)	0.120
HLA-C 07	4 (40.0)	3 (30.0)	5 (50.0)	0.890
HLA-C 15	1 (10.0)	3 (30.0)	0	0.290
HLA-DQB1 02	6 (60.0)	3 (30.0)	4 (40.0)	0.530
HLA-DQB1 03	2 (20.0)	6 (60.0)	5 (50.0)	0.270
HLA-DRB1 01	1 (10.0)	2 (20.0)	3 (30.0)	0.850
HLA-DRB1 03	4 (40.0)	3 (30.0)	2 (20.0)	0.880
HLA-DRB1 04	0	1 (10.0)	2 (20.0)	0.750
HLA-DRB1 11	1 (10.0)	3 (30.0)	3 (30.0)	0.640
HLA-DRB1 13	3 (30.0)	2 (20.0)	4 (40.0)	0.880

<sup>1</sup>Fisher Exact test. HLA-A 01, -03, -11, -23, -25, -30, -31, -32, -33, -66, -68, -80. HLA-B 07, -08, -13, -14, -27, -37, -40, -42, -48, -49, -50, -51, -52, -57, -58, -81. HLA-C 01, -03, -04, -05, -06, -08, -14, -16, -17. HLA-DQB1 04, -05, -06. HLA-DRB1 01, -07, -08, -10, -12, -15, -16 alleles had a frequency less than 1 and were not included in the Table 2. HLA: Human leukocyte antigen; DS: Down syndrome; AA: Alopecia areata.

was found in patients. In this study there was no significant difference at 5% in the proportion of HLA-B and between groups. According to Fisher's exact test, there is a trend ( $P = 0.094$ ) in DS group presenting a higher proportion of HLA-B 15 (40%) than the others groups. There is few published data on HLA-C and AA. It was described in literature the highest frequency of HLA-Cw\*0704 in patients with AA. In this study, it was observed that there is no significant difference at 5%, proportion of HLA-C, HLA-DQB1 and HLA-DRB1 alleles between groups.

This finding was different from some studies reported in the literature, conducted in patients with AA without DS, which showed a predisposition to develop AA in cases with HLA-DRB1\*03, HLA-DRB1\*04, HLA-DQB1\*06, HLA-DRB1\*13, HLA-DRw52a, DQ7, HLA-DQB1\*03, HLA-DRB1\*11<sup>[15-17,27,31,32]</sup>.

Different HLA types are found in the population and it is rare to find two individuals having the same HLA<sup>[33]</sup>. The frequencies of alleles tend to be different among populations racially and ethnically distinct. The Brazilian population is genetically very different and it is justified by the contribution of three groups: Caucasians, Africans and Native Americans<sup>[34]</sup>. This fact may explain the heterogeneous distribution in this study and the differences found in earlier studies.

This study was conducted with a small sample. Moreover, it was difficult to collect some relatives of the subjects, especially the second degree, who refused to participate. These two factors were found limitations in this research.

In a conclusion, The frequency distribution of HLA

alleles (loci A, B, C, DRB1 and DQB1) was heterogeneous in the three groups, with no significant difference in the proportion. There was a trend ( $P = 0.089$ ) of the DS group to present higher proportion of HLA-A 36 than the others groups and a trend ( $P = 0.094$ ) of the DS group to present higher proportion of HLA-B 15 than the others groups. HLA-C 07, HLA-DQB1 03 and HLA-DQB1 06 alleles showed high frequency (> 50%) in first-degree relatives of the total sample.

This study was conducted with a small sample. We suggest further studies with larger sample.

## ACKNOWLEDGMENTS

Medical students: Marcela, Erika, Patrícia and Annalu.

## COMMENTS

### Background

The prevalence of alopecia areata (AA) in down syndrome (DS) individuals ranges from 1% to 11%, higher than in general population.

### Research frontiers

This study was undertaken to describe human leukocyte antigen (HLA) alleles in individuals with DS and AA, and try to explain the higher prevalence of AA in these individuals.

### Innovations and breakthroughs

The frequency distribution of HLA alleles in the groups was heterogeneous; there was a tendency of alleles A-36 and B-15 in DS group. The cause of AA in DS remains unknown. The authors suggest further studies with a larger sample.

### Peer review

The work presented in the paper provides an indication that individuals with Down syndrome exhibit a higher prevalence of AA than the general population. In spite a small sample size, the manuscript provides some interesting insights into the immune system disturbances in DS individuals.

## REFERENCES

- Bertolini DL, Vitale MSS, Fisberg M. Morbimortalidade em indivíduos portadores da Síndrome de Down. *Pediatr Atual São Paulo* 1993; 6: 42-49
- Gelehrter TD, Collins FS. Citogenética. In: Fundamentos de Genética Médica. Guanabara Koogan, 1992: 135-160
- Fryns JP. Chromosome 21, trisomy 21. In: Buyse ML. Birth Defects Encyclopedia. Blackwell Scientific Publications, 1990: 391-393
- Karlsson B, Gustafsson J, Hedov G, Ivarsson SA, Annerén G. Thyroid dysfunction in Down's syndrome: relation to age and thyroid autoimmunity. *Arch Dis Child* 1998; 79: 242-245 [PMID: 9875020 DOI: 10.1136/adc.79.3.242]
- Carter DM, Jegasothy BV. Alopecia areata and Down syndrome. *Arch Dermatol* 1976; 112: 1397-1399 [PMID: 134671 DOI: 10.1001/archderm.1976.01630340015003]
- Du Vivier A, Munro DD. Alopecia areata, autoimmunity, and Down's syndrome. *Br Med J* 1975; 1: 191-192 [PMID: 122906 DOI: 10.1136/bmj.1.5951.191]
- Garg S, Messenger AG. Alopecia areata: evidence-based treatments. *Semin Cutan Med Surg* 2009; 28: 15-18 [PMID: 19341938 DOI: 10.1016/j.sder.2008.12.002]
- Daneshpazhooh M, Nazemi TM, Bigdeloo L, Yoosefi M. Mucocutaneous findings in 100 children with Down syndrome. *Pediatr Dermatol* 2007; 24: 317-320 [PMID: 17542890 DOI: 10.1111/j.1525-1470.2007.00412.x]
- Dourmishev A, Miteva L, Mitev V, Pramatarov K, Schwartz RA. Cutaneous aspects of Down syndrome. *Cutis* 2000; 66: 420-424 [PMID: 11138359]

- 10 **Roselino AM**, Almeida AM, Hippolito MA, Cerqueira BC, Maffei CM, Menezes JB, Vieira RE, Assis SL, Ali SA. Clinical-epidemiologic study of alopecia areata. *Int J Dermatol* 1996; **35**: 181-184 [PMID: 8655233 DOI: 10.1111/j.1365-4362.1996.tb01635.x]
- 11 **Wunderlich C**, Braun-falco O. [Mongolism and alopecia areata]. *Med Welt* 1965; **10**: 477-481 [PMID: 14276234]
- 12 **Bertotto A**, Crupi S, Fabietti GM, Troiani S, Parente C, Mezzetti D, Vaccaro R. CD3+/CD30+ circulating T lymphocytes are markedly increased in older subjects with Down's syndrome (Trisomy 21). *Pathobiology* 1999; **67**: 108-110 [PMID: 10023139 DOI: 10.1159/000028058]
- 13 **Bertotto A**, Gerli R, Spinozzi F, Muscat C, Fabietti GM, Crupi S, Castellucci G, De Benedictis FM, De Giorgi G, Britta R. CD26 surface antigen expression on peripheral blood T lymphocytes from children with Down's syndrome (trisomy 21). *Scand J Immunol* 1994; **39**: 633-636 [PMID: 7912005 DOI: 10.1111/j.1365-3083.1994.tb03424.x]
- 14 **Miller ME**, Mellman WJ, Kohn G, Dietz WH. Qualitative and quantitative deficiencies of immunoglobulin G (IgG) in newborns with Down syndrome. *Ann NY Acad Sci* 1970; **171**: 512-516 [DOI: 10.1111/j.1749-6632.1970.tb39360.x]
- 15 **Colombe BW**, Price VH, Khoury EL, Garovoy MR, Lou CD. HLA class II antigen associations help to define two types of alopecia areata. *J Am Acad Dermatol* 1995; **33**: 757-764 [PMID: 7593774]
- 16 **Welsh EA**, Clark HH, Epstein SZ, Reveille JD, Duvic M. Human leukocyte antigen-DQB1\*03 alleles are associated with alopecia areata. *J Invest Dermatol* 1994; **103**: 758-763 [PMID: 7798612 DOI: 10.1111/1523-1747.ep12412584]
- 17 **Xiao FL**, Yang S, Yan KL, Cui Y, Liang YH, Zhou FS, Du WH, Gao M, Sun LD, Fan X, Chen JJ, Wang PG, Zhu YG, Zhou SM, Zhang XJ. Association of HLA class I alleles with alopecia areata in Chinese Hans. *J Dermatol Sci* 2006; **41**: 109-119 [PMID: 16185849 DOI: 10.1016/j.jdermsci.2005.07.008]
- 18 **Muller SA**, Winkelmann RK. Alopecia areata. An evaluation of 736 patients. *Arch Dermatol* 1963; **88**: 290-297 [PMID: 14043621 DOI: 10.1001/archderm.1963.01590210048007]
- 19 **Schepis C**, Barone C, Lazzaro Danzuso GC, Romano C. Alopecia areata in Down syndrome: a clinical evaluation. *J Eur Acad Dermatol Venereol* 2005; **19**: 769-770 [PMID: 16268894 DOI: 10.1111/j.1468-3083.2005.01259.x]
- 20 **Alves R**, Ferrando J. Alopecia areata and Down's syndrome. *Rev Med Int Sindr Down* 2011; **15**: 34-36 [DOI: 10.1016/S2171-9748(11)70012-5]
- 21 **Whiting DA**. Histopathologic features of alopecia areata: a new look. *Arch Dermatol* 2003; **139**: 1555-1559 [PMID: 14676070 DOI: 10.1001/archderm.139.12.1555]
- 22 **Alkhalifah A**, Alsantali A, Wang E, McElwee KJ, Shapiro J. Alopecia areata update: part I. Clinical picture, histopathology, and pathogenesis. *J Am Acad Dermatol* 2010; **62**: 177-188, quiz 189-190 [PMID: 20115945 DOI: 10.1016/j.jaad.2009.10.032]
- 23 **Pereira JM**. Propedêutica das Doenças dos Cabelos e do Couro Cabeludo. São Paulo: Atheneu, 2001: 163-175
- 24 **Rivitti EA**. Alopecia areata: revisão e atualização. *An Bras Dermatol* 2005; **80**: 57-68 [DOI: 10.1590/S0365-05962005000100009]
- 25 **Wasserman D**, Guzman-Sanchez DA, Scott K, McMichael A. Alopecia areata. *Int J Dermatol* 2007; **46**: 121-131 [PMID: 17269961 DOI: 10.1111/j.1365-4632.2007.03193.x]
- 26 **Duarte AA**, Cucé LC, Machado DS, Fukugava MFN, Gomes PA. Alopecia areata familiar. *An Bras Dermatol* 1996; **71**: 356-360
- 27 **Entz P**, Blaumeiser B, Betz RC, Lambert J, Seymons K, Eigelshoven S, Hanneken S, Kruse R, Nürnberg P, Nagy M, Nöthen MM. Investigation of the HLA-DRB1 locus in alopecia areata. *Eur J Dermatol* 2006; **16**: 363-367 [PMID: 16935791]
- 28 **Tazi-Ahnini R**, di Giovine FS, McDonagh AJ, Messenger AG, Amadou C, Cox A, Duff GW, Cork MJ. Structure and polymorphism of the human gene for the interferon-induced p78 protein (MX1): evidence of association with alopecia areata in the Down syndrome region. *Hum Genet* 2000; **106**: 639-645 [PMID: 10942113]
- 29 **Barahmani N**, de Andrade M, Slusser JP, Zhang Q, Duvic M. Major histocompatibility complex class I chain-related gene A polymorphisms and extended haplotypes are associated with familial alopecia areata. *J Invest Dermatol* 2006; **126**: 74-78 [PMID: 16417220 DOI: 10.1038/sj.jid.5700009]
- 30 **Nair RP**, Stuart P, Henseler T, Jenisch S, Chia NV, Westphal E, Schork NJ, Kim J, Lim HW, Christophers E, Voorhees JJ, Elder JT. Localization of psoriasis-susceptibility locus PSORS1 to a 60-kb interval telomeric to HLA-C. *Am J Hum Genet* 2000; **66**: 1833-1844 [PMID: 10801386 DOI: 10.1086/302932]
- 31 **Attia EA**, El Shennawy D, Sefin A. Serum Interleukin-4 and Total Immunoglobulin E in Nonatopic Alopecia Areata Patients and HLA-DRB1 Typing. *Dermatol Res Pract* 2010; **2010**: 503587 [PMID: 20671941 DOI: 10.1155/2010/503587]
- 32 **Duvic M**, Hordinsky MK, Fiedler VC, O'Brien WR, Young R, Reveille JD. HLA-D locus associations in alopecia areata. DRw52a may confer disease resistance. *Arch Dermatol* 1991; **127**: 64-68 [PMID: 1670917 DOI: 10.1001/archderm.1991.01680010074011]
- 33 **Abbas AK**, Lichtman AH, Pillai S. O complexo de histocompatibilidade principal. In: Abbas AK, Lichtman AH, Pillai S. Imunologia celular e molecular. Elsevier, 2011: 109-138
- 34 **Moraes ME**, Fernandez-Viña M, Salatiel I, Tsai S, Moraes JR, Stastny P. HLA class II DNA typing in two Brazilian populations. *Tissue Antigens* 1993; **41**: 238-242 [PMID: 8236236 DOI: 10.1111/j.1399-0039.1993.tb02012.x]

**P- Reviewer:** Husein-ElAhmed H, Romani A, Slomiany BL

**S- Editor:** Wen LL **L- Editor:** A **E- Editor:** Liu SQ



## He had always wanted to ask an andrologist but had never done so

Carlo Foresta, Damiano Pizzol

Carlo Foresta, Damiano Pizzol, Department of Medicine, Section of Endocrinology and Centre for Human Reproduction Pathology, University of Padua, 35121 Padova, Italy

Author contributions: All authors contributed equally to this work.

Correspondence to: Dr. Pizzol Damiano, Department of Medicine, Section of Endocrinology and Centre for Human Reproduction Pathology, University of Padua, Via Gabelli 63, 35121 Padova, Italy. [damiano.pizzol@uniroma1.it](mailto:damiano.pizzol@uniroma1.it)

Telephone: +39-49-8218573 Fax: +39-49-8218520

Received: March 31, 2014 Revised: June 4, 2014

Accepted: July 27, 2014

Published online: October 16, 2014

### Abstract

**AIM:** To understand and analyze what young Italian males attending high school would like to ask andrologists but do not know how to or do not have the courage to do so.

**METHODS:** As part of our "Androlife" campaign, we invited 1565 students attending the last year of high school to participate in our research. Firstly, they attended a lesson on general and andrological health and then, on a voluntary basis, they responded to a survey and were subjected to a preventive andrological visit.

**RESULTS:** The data analysis showed that the main topics in which young people are interested are: sexual activity and sexuality, sexually transmitted diseases, andrological health and fertility, and lifestyle.

**CONCLUSION:** This study highlights that young people are very interested in sexual health issues and that they have specific needs and interests with regard to sexual health information. Public education campaigns such as Androlife should be supported and further improved on the basis of the advice received by young participants. Sexual and reproductive health education

targeting adolescents and young adults represent the basis both for wellness and for fertility preservation, and thus benefits of increased support to educational campaigns would be apparent not only in terms of individual health but also in terms of cost reduction in public spending.

© 2014 Baishideng Publishing Group Inc. All rights reserved.

**Key words:** Men's health; Adolescence; Prevention; Education; Sexual health; Andrologist

**Core tip:** This article considers the questions young people are most frequently asking. It can be considered an innovative paper because in Italy and other countries many of these topics are considered taboo. Moreover, in this article we underline that the benefits of increased support for educational campaigns would be apparent not only in terms of individual health but also in terms of cost reduction in public spending.

Foresta C, Pizzol D. He had always wanted to ask an andrologist but had never done so. *World J Clin Cases* 2014; 2(10): 546-551 Available from: URL: <http://www.wjgnet.com/2307-8960/full/v2/i10/546.htm> DOI: <http://dx.doi.org/10.12998/wjcc.v2.i10.546>

### INTRODUCTION

Sexual health, sexual disorders and everything related to sex have often been considered a taboo topic in Italy for many reasons, including cultural, social and religious factors. Furthermore, while the specialist in gynecology is now both well known and readily accepted, the specialist in andrology is not yet fully established among the public. However, both in Italy and all over the world, societies are becoming increasingly aware that men as well as women need sexual health care services, while at the same time services that are available are underutilized<sup>[1]</sup>.

The absence of a referring specialist for men adds to the lack of health education and prevention programs with the result that young people, particularly males, often are not knowledgeable of diseases and risk factors related to sexual health. This situation inevitably leads to difficulties in implementing preventive measures. Moreover, the difficulty that young people encounter in talking to parents and seeking medical attention for sex-related problems motivates adolescents to attempt to solve problems by using the web or by relying on word of mouth and often on urban myths. Consequently, if the user is unable to select and identify the correct information there exists a major risk that not only problems are seldom solved, but also that they are often aggravated<sup>[2]</sup>. However, the tendency to high-risk behavior and to low utilization of sexual health services is not only characteristic of young males but also extends to adult men, and it may contribute to lower male life expectancy<sup>[3]</sup>. Some authors have already taken into account social, behavioral and psychosocial factors associated with sexual activity among young adolescents in order to create effective and enforceable prevention programs<sup>[4-6]</sup>, and in many countries these programs have already been activated<sup>[7-9]</sup>. In Italy, male sexual health has received growing attention in recent years and a previous study on young men has identified a number of risk factors for adolescents, highlighting a strong influence of body mass index (BMI) on skeletal proportions and penis length and identifying a large proportion of subjects with testicular hypotrophy at risk of future fertility problems<sup>[10]</sup>. A strong impetus to andrological health prevention was given by the campaign “Androlife”. This was a project aimed mainly at young people with the aim of providing information, promoting prevention and collecting data. In this project, an anonymous questionnaire was administered to young participants selected among high school students. This paper focuses on just one section of this survey. In particular, we wanted to understand and analyze what young Italian males attending high school would like to ask andrologists but do not know how to or do not have the courage to do so.

## MATERIALS AND METHODS

### *Androlife campaign*

Androlife is a project that has the following objectives: (1) to sensitize and to inform young people on general and andrological health; (2) to promote primary prevention of diseases, especially concerning the male reproductive system; (3) to collect information on the habits, lifestyles, general and sexual health status of young people through an anonymous questionnaire; and (4) to highlight pathological conditions detectable by a free medical examination performed only in volunteers.

To achieve these objectives the “Androlife team” organized social and cultural events, free clinics dedicated to andrological prevention, and interventions by specialists in high schools for students in their final year in order to inform, educate and provide a free medical preventive evaluation for those who wished it.

### *Patients and setting*

A total of 1565 students attending the final year of high school in 2012-2013 in the Veneto Region of North-East Italy were enrolled in the study. All students, aged 18-19 years, attended an informative session held by a physician of the University of Padua. Of all participants, 1492 agreed to complete an anonymous survey. On a voluntary basis, 1083 participants then elected to undergo an on-site clinical examination. The study was approved by the local Ethics Committee with the protocol number 2208P.

### *Information session*

The sessions focused on 5 main topics: sexually transmitted diseases, andrological diseases, lifestyle, drugs and alcohol and cybersex. For each topic, the specialist explained the risk factors, how to prevent them, how to take care of one's own health, the forms of self examination such as testicular self-examination, and possible solutions to existing problems. Students could also ask questions in public and/or ask further information in private on the topics covered.

### *Survey*

The anonymous survey included a general family history and a number of questions on lifestyle, with particular attention to smoking, diet, physical activity and the use and, or, abuse of drugs. Moreover, a large section focused on sexual activity, such as number of partners, sexual orientation, use of condoms, and use and/or abuse of pornography on the web. Finally, the last section of the survey contained an empty space where each participant was invited to write questions they might have wanted to ask an andrologist but had never done so. This section represented the topic of this paper.

### *Visit*

On-site clinical examination was aimed at collecting anthropometric and penile measurements that included: height, weight, BMI, waist circumference, arm span, pubis-to-floor and crown-to-pubis length, penis length, penis circumference and testicular examination.

## RESULTS

Among 1492 subjects who completed the survey, 1184 provided a question that they had always wanted to ask a specialist but had never done so. Of these, 793 (67%) claimed to already know the word andrologist, but only 274 (23.1%) had already undergone an andrological check. After collecting all the questions, we clustered them into four main groups, taking into account the frequency with which questions were asked (Table 1): 475 (40.2%) adolescents had asked questions about sexuality and sexual activity, 242 (20.4%) about sexually transmitted diseases, 216 (18.2%) about andrological health and fertility, and 142 (12%) about lifestyle. A further 109 (9.2%) questions did not fit into one of these groups and were combined into a generic group. The first 3 clusters were further divided into subgroups. The first cluster on



**Table 1** The main and most frequent questions of 1184 young Italian men *n* (%)

Sexuality and sexual activity 475 (40.2)	Masturbation 223 (46.9)	Is masturbation normal? Can a frequent masturbation cause damage to the penis and/or to the body? Can masturbation be useful before a sexual intercourse? Can masturbation have negative effects on sports performance? Can masturbation reduce the risk of prostate cancer?		
	Sexual intercourses 199 (41.9)	Which are the safest contraceptive methods? The oral sex cause oral cancer? Can anal sex be risky? What is the right age for the first sexual intercourse?		
	Drugs for sex 53 (11.2)	Are there effective drugs to treat premature ejaculation? At what age can you use phosphodiesterase inhibitors? <sup>1</sup> Are there drugs to help penis growth? Are web products, to improve sexual performance, effective and safe?		
	Sexually transmitted diseases 242 (20.4)	HIV 95 (39.3)	Is HIV treatable? Is a single sexual intercourse, with an HIV positive subject, enough to acquire the infection? Is HIV transmissible through masturbation? Why there is no cure for HIV?	
		HPV 79 (32.6)	Is HPV a virus that can also affect men? How is HPV transmitted? Is it possible, and how, heal from HPV infection?	
		Generic questions 68 (28.1)	Is the birth control pill effective against STD? Is sexual intercourse the only way of transmission of STD? What should you do in case of STD? Can those who have never had sexual intercourse have a STD?	
			Andrological health and fertility 216 (18.2)	Varicocele 91 (42.1)
	Testicular tumours 80 (37.1)			Which are the symptoms of testicular cancer? Is it possible to prevent testicular cancer? Is it possible to heal from testicular cancer? Does testicular cancer always cause infertility?
		Generic questions 45 (20.8)		Does andropause exist? What age? Which are the consequences of testicular trauma? Is short frenulum dangerous? Can you return fertile after vasectomy?
			Lifestyle 142 (12)	Can illicit drugs and alcohol interfere with sexual health? Does physical activity improve andrological health? Is the use of androgens helpful or harmful to the andrological health?
Generic questions 109 (9.2)	Can virginity be established for a man? Can web pornography cause addiction? Has the partner a role in sexual desire? To keep your cell phone in your pocket can damage fertility and or sexuality? How can an issue of sexual orientation be addressed?			

<sup>1</sup>Students did not know the active ingredient of these drugs and, in the questions, they used the most famous trade names. HIV: Human immunodeficiency virus; STD: Sexually transmitted disease; HPV: Human papillomavirus virus.

sexuality and sexual activity was divided into masturbation, sexual intercourse and drug use for sex; the sexually transmitted diseases group into human immunodeficiency virus, human papillomavirus virus and into a third generic group; andrological health and fertility was divided into varicocele, testicular tumors, and a final generic one. Table 1 shows the main and most frequent questions that young men provided in the survey, while in Table 2 we have given short answers to the received questions.

## DISCUSSION

### Sexuality and sexual activity

The issue of sexuality is still a difficult topic to discuss with young people, and too little is being done to provide correct information to adolescents who are just starting to explore their sexuality. In this context, the Androlife

campaign intended to be helpful to the largest number of young men not only in giving information but also in facilitating the promotion of health, and in particular andrological health. This campaign, aimed at high school students, highlighted, on the one hand, much interest and active participation by adolescents in the topic, and, on the other hand, a fundamental difficulty in dealing with these issues and a fundamental lack of knowledge of many basic facts on the part of the participants. The worst consequences are a lack of preventative measures, and a reliance on the web for addressing problems, with the result that such problems are not always approached properly, nor are they effectively solved. In this paper we have considered the main topics on which young men would like to receive information or clarification but do not know how to or where to find it. In particular, the largest number of questions was related to masturba-

**Table 2** Answers to the most frequent questions of young Italian men

Sexuality and sexual activity	Yes, masturbation is normal
	Masturbation doesn't cause damage to the penis and/or to the body
	There is no evidence that masturbation is useful before sexual intercourse
	There is no evidence that masturbation has negative effects on sports performance
	It has not been demonstrated that masturbation reduces the risk of prostate cancer
	The safest considered contraceptives are condoms, the contraceptive pill and intrauterine devices
	The risk of cancer caused by oral sex is related to the transmission of HPV
	Anal sex can be risky due to the transmission of STD
	There isn't a "right age" for the first sexual intercourse because everyone reaches maturity at different ages
	There are effective drugs to treat premature ejaculation, but not all cases require drug treatment
Sexually transmitted diseases	The clinic, not the age determine the use of phosphodiesterase inhibitors
	Drugs are useful for the growth of the genitals only in the case of some diseases ( <i>e.g.</i> , certain hormone deficiencies)
	Is not safe, and often even effective, to rely on the web to improve sexual performance
	HIV is treatable but not curable
	Even a single sexual intercourse, with an HIV positive subject, is enough to acquire the infection
	HIV is transmissible through masturbation only if the biological produced fluids come into contact with wounds
	The complexity of the virus causes the current treatment options to treat but not to heal from infection by HIV
	Yes, HPV can also affect men
	HPV is transmitted through all forms of sexual activity
	It is possible heal from HPV infection reducing risk factors (smoking, unprotected sex, low hygiene...)
Andrological health and fertility	The birth control pill is absolutely not effective against STDs
	Sexual intercourse is not the only way of transmission of STD
	In case of STDs the first thing to do is consult a doctor as soon as possible
	STDs can also be present in people who have not had sex but have been in contact in other ways ( <i>e.g.</i> , transfusions with infected blood)
	A varicocele can be diagnosed by clinical examination or ultrasound
	A varicocele may be asymptomatic, present with scrotal symptoms or pains, and in some cases worse spermatogenesis and testicular function
	It is not always necessary to operate in the presence of a varicocele
	In some cases, after operation, varicocele may recur
	Symptoms of testicular cancer: presence of a mass, change in size, change in texture, scrotal and/or inguinal pain, scrotal weight feeling
	It is necessary to prevent testicular cancer
Lifestyle	Yes, it is possible to heal from testicular cancer
	If early treated, testicular cancer not always cause infertility
	There is no well-defined andropause but fertility and sexual potency decrease with age
	Severe testicular trauma may have consequences on testicular function and fertility
	A short frenulum is not dangerous and it is easily solved
	Regaining fertility after vasectomy is sometimes possible but difficult
	It is well established that drugs and alcohol negatively interfere with sexual health
	Physical activity is necessary to maintain and improve andrological health
	If not necessary, the use of androgens is harmful to the andrological health
	Male virginity can not be established
Generic questions	Yes, web pornography can cause addiction
	Yes, also the partner plays a very important role in sexual desire
	To date there are conflicting data on the role of cell phone on fertility and or sexuality
	It is good to deal with issues relating to sexual orientation with trained and professional doctors and psychologists

HIV: Human immunodeficiency virus; STD: Sexually transmitted disease; HPV: Human papillomavirus virus.

tion, denoting ignorance in this respect and highlighting widespread beliefs in popular myths. In fact, many young males are not aware of the fact that masturbation is integral to normal sexual development and that it represents a dynamic process during adolescence, and only compulsive masturbation should be considered a problem<sup>[11,12]</sup>. The other issue of great interest was, unsurprisingly, sexual intercourse. Interestingly, the main concern in this regard, was in contraceptives and methods for optimal performance, as well as about oral and anal sex while the risk of sexually transmitted disease (STD) did not seem to be prominent. Although previous studies have highlighted that there are a number of different pathways that may lead to either voluntary or involuntary adult sexual inexperience<sup>[13]</sup>, it is more likely that many of the

concerns voiced by the participants arise from actual voluntary practice, considering the growing proportion of adolescents engaged in oral and anal sex practices<sup>[14]</sup>.

### Sexually transmitted diseases

In our opinion, what should be worrisome is the lack of interest and concern displayed by the participants in STDs. In fact, the questions show that adolescents are poorly informed about the transmission pathways, consequences, and possible treatments for infections, and at the same time, they do not seem to give considerable thought to these issues. This observation is in agreement with the data collected by other authors who have highlighted the need for effective interventions to reduce adolescent STD infection<sup>[15]</sup>. Moreover, STDs also represent

the most significant modifiable risk factors for this age group with regard to fertility<sup>[16]</sup>. This topic does not seem to be a priority for adolescents, but this may only be the consequence of a lack of sexual health education and not of indifference toward these issues.

### Andrological health and fertility

STDs do not seem to be of great interest, but when made aware of these issues, students expressed the will to learn more both in terms of the most common diseases and of those they are more afraid of, such as varicoceles and testicular tumors. A varicocele is one of the most common pathologies but despite numerous studies concerning its evaluation and treatment, uncertainties remain. Both overtreatment and undertreatment are particularly costly. Expensive ultrasound, office visits and surgery must be avoided in those who do not need these treatments, while a careful follow-up and eventual intervention must be guaranteed to subjects who may be in need of them<sup>[17]</sup>. Another disease of great interest to students is testicular cancer, which represents the most common malignancy in young men, with the highest incidence among men in Nordic countries. Known risk factors are cryptorchidism, a previous history of testicular cancer and a family history of testicular cancer, and early detection and appropriate treatment are the only methods to decrease mortality<sup>[18,19]</sup>. In fact, if adequately treated and followed up it represents the most curable solid tumour and survival rate exceeds 90% in young males<sup>[20]</sup>. Unfortunately, the majority of young males is not aware of this information, which is critical for successful health prevention. Therefore, this survey, in accordance with data collected by other authors, underscores the continued need for comprehensive sexual and reproductive health education for adolescents and young adults<sup>[21]</sup>.

### Lifestyle

A widespread social problem all over the world is the use and abuse of alcohol and illicit drugs<sup>[22]</sup>. This represents the main topic of lifestyle in which young people are involved and on which they focus their interest, and prevention and treatment efforts would benefit from more careful attention in preventive health programs. Another matter to consider is physical activity during adolescence. The long-term benefits of habitual physical activity are recognized<sup>[23]</sup>, but it is necessary to inform adolescents about the risks of using doping substances, particularly considering the increased consumption of such substances by young people who practice sport<sup>[24,25]</sup>.

### Generic questions

In the last cluster, we collected less frequent but perhaps more topical and current questions asked by the participants. In addition to the issue about the possible negative effects of the use of mobile phones on fertility, questions asked by participants were commonly questions to which there are conflicting answers<sup>[26]</sup>, and questions on topics of interest concerning web pornography and sexual orientation. Web pornography is a phenomenon of such in-

creasing interest as to be defined by some authors as the new sexual revolution<sup>[27]</sup>. To date, a number of studies have highlighted the reasons why web pornography has such widespread use, and considered the characteristics of this new form of sexuality<sup>[28,29]</sup>. However, no one has yet taken into account the possible negative effects of the use or abuse of web pornography in terms of an increase or decrease in interest in real sexuality and in real sexual intercourse. Sexual orientation represents a difficult topic for adolescents to bring up, particularly because of the family and social context in Italy. It is demonstrated that homosexual young people face different developmental challenges during adolescence than those faced by heterosexual youths or individuals who recognize their homosexual orientation later in life<sup>[30]</sup>. Though sexuality has acquired new dimensions in many countries including Italy, religions and cultures consider sexuality almost exclusively as focused on reproduction<sup>[31]</sup>. Hence, there exists a difficulty for young people to deal with the issue of sexual orientation and therefore, the necessity to provide an adequate and qualified service for information and assistance. In conclusion, this study highlights not only that young people are very interested in general health issues, but also that they have very specific needs and interests on sexual health and sexual health information. In our opinion, public education campaigns such as Androlife should be increased in number and frequency and improved on the basis of the view of young participants. Sexual and reproductive health education and promotion for adolescents and young adults represents the basis both for wellness and for fertility preservation. Finally, the benefits of increased support for educational campaigns would be apparent not only in terms of individual health but also in terms of a reduction in public spending costs.

## ACKNOWLEDGMENTS

The authors thank Dr. Pelizzon Alessandro, School of Law and Justice, Southern Cross University-East Lismore NSW 2480-Australia, for his kindly and careful editing.

## COMMENTS

### Background

Sexual activity, sexual health and sexual disorders are open issues and current problems especially among adolescents.

### Innovations and breakthroughs

This study highlights not only that young people are very interested in general health issues, but also that they have very specific needs and interests on sexual health and sexual health information.

### Applications

This is an interesting and meaningful topic which brings attention to the health care providers and raises public awareness for the importance of education in reproductive health.

### Peer review

This is an interesting and meaningful topic.

## REFERENCES

- 1 Kalmuss D, Austrian K. Real men do...real men don't:

- Young Latino and African American men's discourses regarding sexual health care utilization. *Am J Mens Health* 2010; **4**: 218-230 [PMID: 19477755 DOI: 10.1177/1557988309331797]
- 2 **Shoveller J**, Knight R, Davis W, Gilbert M, Ogilvie G. Online sexual health services: examining youth's perspectives. *Can J Public Health* 2012; **103**: 14-18 [PMID: 22338322]
  - 3 **Pinkhasov RM**, Wong J, Kashanian J, Lee M, Samadi DB, Pinkhasov MM, Shabsigh R. Are men shortchanged on health? Perspective on health care utilization and health risk behavior in men and women in the United States. *Int J Clin Pract* 2010; **64**: 475-487 [PMID: 20456194 DOI: 10.1111/j.1742-1241.2009.02290.x]
  - 4 **Marston M**, Beguy D, Kabiru C, Cleland J. Predictors of sexual debut among young adolescents in Nairobi's informal settlements. *Int Perspect Sex Reprod Health* 2013; **39**: 22-31 [PMID: 23584465 DOI: 10.1363/3902213]
  - 5 **Shoveller JA**, Knight R, Johnson J, Oliffe JL, Goldenberg S. 'Not the swab!' Young men's experiences with STI testing. *Sociol Health Illn* 2010; **32**: 57-73 [PMID: 20415807 DOI: 10.1111/j.1467-9566.2009.01222.x]
  - 6 **Kimmel A**, Williams TT, Veinot TC, Campbell B, Campbell TR, Valacak M, Kruger DJ. 'I make sure I am safe and I make sure I have myself in every way possible': African-American youth perspectives on sexuality education. *Sex Educ* 2013; **13**: 172-185 [PMID: 23585729 DOI: 10.1080/14681811.2012.709840]
  - 7 **Carvalho FT**, Gonçalves TR, Faria ER, Shoveller JA, Piccinini CA, Ramos MC, Medeiros LR. Behavioral interventions to promote condom use among women living with HIV. *Cochrane Database Syst Rev* 2011; **(9)**: CD007844 [PMID: 21901711]
  - 8 **Story M**, Nannery MS, Schwartz MB. Schools and obesity prevention: creating school environments and policies to promote healthy eating and physical activity. *Milbank Q* 2009; **87**: 71-100 [PMID: 19298416 DOI: 10.1111/j.1468-0009.2009.00548.x]
  - 9 **Khan LK**, Sobush K, Keener D, Goodman K, Lowry A, Kakietek J, Zaro S. Recommended community strategies and measurements to prevent obesity in the United States. *MMWR Recomm Rep* 2009; **58**: 1-26 [PMID: 19629029]
  - 10 **Foresta C**, Garolla A, Frigo AC, Carraro U, Isidori AM, Lenzi A, Ferlin A. Anthropometric, penile and testis measures in post-pubertal Italian males. *J Endocrinol Invest* 2013; **36**: 287-292 [PMID: 22776895]
  - 11 **Robbins CL**, Schick V, Reece M, Herbenick D, Sanders SA, Dodge B, Fortenberry JD. Prevalence, frequency, and associations of masturbation with partnered sexual behaviors among US adolescents. *Arch Pediatr Adolesc Med* 2011; **165**: 1087-1093 [PMID: 21810625 DOI: 10.1001/archpediatrics.2011.142]
  - 12 **Calabrò RS**, Gali A, Marino S, Bramanti P. Compulsive masturbation and chronic penile lymphedema. *Arch Sex Behav* 2012; **41**: 737-739 [PMID: 21792689 DOI: 10.1007/s10508-011-9812-7]
  - 13 **Haydon AA**, Cheng MM, Herring AH, McRee AL, Halpern CT. Prevalence and predictors of sexual inexperience in adulthood. *Arch Sex Behav* 2014; **43**: 221-230 [PMID: 23900992 DOI: 10.1007/s10508-013-0164-3]
  - 14 **Cherie A**, Berhane Y. Oral and anal sex practices among high school youth in Addis Ababa, Ethiopia. *BMC Public Health* 2012; **12**: 5 [PMID: 22216887 DOI: 10.1186/1471-2458-12-5]
  - 15 **Newbern EC**, Anschuetz GL, Eberhart MG, Salmon ME, Brady KA, De Los Reyes A, Baker JM, Asbel LE, Johnson CC, Schwarz DF. Adolescent sexually transmitted infections and risk for subsequent HIV. *Am J Public Health* 2013; **103**: 1874-1881 [PMID: 23947325 DOI: 10.2105/AJPH.2013.301463]
  - 16 **Remes O**, Whitten AN, Sabarre KA, Phillips KP. University students' perceptions of environmental risks to infertility. *Sex Health* 2012; **9**: 377-383 [PMID: 22877598 DOI: 10.1071/SH11090]
  - 17 **Kolon TF**. The adolescent varicocele--a Shakespearean tragedy or much ado about nothing? *J Urol* 2013; **189**: 2024-2025 [PMID: 23500035]
  - 18 **Manecksha RP**, Fitzpatrick JM. Epidemiology of testicular cancer. *BJU Int* 2009; **104**: 1329-1333 [PMID: 19840008 DOI: 10.1111/j.1464-410X.2009.08854.x]
  - 19 **Ondrusova M**, Ondrus D. Epidemiology and treatment delay in testicular cancer patients: a retrospective study. *Int Urol Nephrol* 2008; **40**: 143-148 [PMID: 17634758 DOI: 10.1007/s11255-007-9245-3]
  - 20 **Travis LB**, Beard C, Allan JM, Dahl AA, Feldman DR, Oldenburg J, Daugaard G, Kelly JL, Dolan ME, Hannigan R, Constine LS, Oeffinger KC, Okunieff P, Armstrong G, Wiljer D, Miller RC, Gietema JA, van Leeuwen FE, Williams JP, Nichols CR, Einhorn LH, Fossa SD. Testicular cancer survivorship: research strategies and recommendations. *J Natl Cancer Inst* 2010; **102**: 1114-1130 [PMID: 20585105 DOI: 10.1093/jnci/djq216]
  - 21 **Sabarre KA**, Khan Z, Whitten AN, Remes O, Phillips KP. A qualitative study of Ottawa university students' awareness, knowledge and perceptions of infertility, infertility risk factors and assisted reproductive technologies (ART). *Reprod Health* 2013; **10**: 41 [PMID: 23962162 DOI: 10.1186/1742-4755-10-41]
  - 22 **Swendsen J**, Burstein M, Case B, Conway KP, Dierker L, He J, Merikangas KR. Use and abuse of alcohol and illicit drugs in US adolescents: results of the National Comorbidity Survey-Adolescent Supplement. *Arch Gen Psychiatry* 2012; **69**: 390-398 [PMID: 22474107 DOI: 10.1001/archgenpsychiatry.2011.1503]
  - 23 **Duckham RL**, Baxter-Jones AD, Johnston JD, Vatanparast H, Cooper D, Kontulainen S. Does physical activity in adolescence have site-specific and sex-specific benefits on young adult bone size, content, and estimated strength? *J Bone Miner Res* 2014; **29**: 479-486 [PMID: 23907819 DOI: 10.1002/jbmr.2055]
  - 24 **El Scheich T**, Weber AA, Klee D, Schweiger D, Mayatepek E, Karenfort M. Adolescent ischemic stroke associated with anabolic steroid and cannabis abuse. *J Pediatr Endocrinol Metab* 2013; **26**: 161-165 [PMID: 23382306 DOI: 10.1515/jpem-2012-0057]
  - 25 **Fürhapter C**, Blank C, Leichtfried V, Mair-Raggautz M, Müller D, Schobersberger W. Evaluation of West-Austrian junior athletes' knowledge regarding doping in sports. *Wien Klin Wochenschr* 2013; **125**: 41-49 [DOI: 10.1007/s00508-012-0318-7]
  - 26 **Merhi ZO**. Challenging cell phone impact on reproduction: a review. *J Assist Reprod Genet* 2012; **29**: 293-297 [PMID: 22350528 DOI: 10.1007/s10815-012-9722-1]
  - 27 **Garlick S**. A new sexual revolution? Critical theory, pornography, and the Internet. *Can Rev Sociol* 2011; **48**: 221-239 [PMID: 22214041]
  - 28 **Daneback K**, Ross MW. The complexity of internet sexuality. *Adv Psychosom Med* 2011; **31**: 121-134 [PMID: 22005208 DOI: 10.1159/000328920]
  - 29 **Ross MW**. Typing, doing, and being: sexuality and the internet. *J Sex Res* 2005; **42**: 342-352 [PMID: 19827239 DOI: 10.1080/00224490509552290]
  - 30 **Rotheram-Borus MJ**, Fernandez MI. Sexual orientation and developmental challenges experienced by gay and lesbian youths. *Suicide Life Threat Behav* 1995; **25** Suppl: 26-34; discussion 35-39 [PMID: 8553426]
  - 31 **Benagiano G**, Carrara S, Filippi V. Social and ethical determinants of sexuality: 4. Sexuality and families. *Eur J Contracept Reprod Health Care* 2012; **17**: 329-339 [PMID: 22974432 DOI: 10.3109/13625187.2012.702810]

P- Reviewer: Nowicki S, Zhao Y S- Editor: Wen LL

L- Editor: Cant MR E- Editor: Liu SQ





## Reporting of dental status from full-arch radiographs: Descriptive analysis and methodological aspects

Fabian Huettig, Detlef Axmann

Fabian Huettig, Detlef Axmann, Department of Prosthodontics with Section "Medical Materials and Technology" at the Centre of Dentistry, Oral Medicine, Maxillofacial Surgery of Eberhard-Karls-University Hospital, D-72076 Tuebingen, Germany  
Author contributions: Huettig F and Axmann D established the search strategy, selection criteria and methodology of report; Huettig F performed the literature research, selected the articles and performed the full text review; Axmann D reviewed the data acquisition by spot tests; Huettig F wrote and Axmann D reviewed the paper.

Supported by The "Walter and Anna Koerner-Scholarship" as part of the Land of Baden-Wuerttemberg's Dentists Chamber (Stuttgart, Germany) within the cooperation of Tuebingen University and Peking University Dental Schools; by Mrs. Barbara Welder of Dental Clinics Library at Eberhard-Karls-University (Tuebingen, Germany); by Lucas M Leister for English proof-reading

Correspondence to: Dr. Fabian Huettig, Department of Prosthodontics with Section "Medical Materials and Technology" at the Centre of Dentistry, Oral Medicine, Maxillofacial Surgery of Eberhard-Karls-University Hospital, Oslanderstrasse 2-8, D-72076 Tuebingen, Germany. [fabian.huettig@med.uni-tuebingen.de](mailto:fabian.huettig@med.uni-tuebingen.de)  
Telephone: +49-7071-2986183 Fax: +49-7071-295917

Received: April 10, 2014 Revised: July 11, 2014

Accepted: August 27, 2014

Published online: October 16, 2014

### Abstract

**AIM:** To identify standards, how entities of dental status are assessed and reported from full-arch radiographs of adults.

**METHODS:** A PubMed (Medline) search was performed in November 2011. Literature had to report at least one out of four defined entities using radiographs: number of teeth or implants; caries, fillings or restorations; root-canal fillings and apical health; alveolar bone level. Cohorts included to the study had to be of adult age. Methods of radiographic assessment were noted and checked for the later mode of report in text, tables or diagrams. For comparability, the encountered mode

of report was operationalized to a logical expression.

**RESULTS:** Thirty-seven out of 199 articles were evaluated *via* full-text review. Only one article reported all four entities. Eight articles reported at the maximum 3 comparable entities. However, comparability is impeded because of the usage of absolute or relative frequency, mean or median values as well as grouping. Furthermore the methods of assessment were different or not described sufficiently. Consequently, established sum scores turned out to be highly questionable, too. The amount of missing data within all studies remained unclear. It is even so remitted to mention supernumerary and aplased teeth as well as the count of third molars.

**CONCLUSION:** Data about dental findings from radiographs is, if at all possible, only comparable with serious limitations. A standardization of both, assessing and reporting entities of dental status from radiographs is missing and has to be established within a report guideline.

© 2014 Baishideng Publishing Group Inc. All rights reserved.

**Key words:** Research design; Guideline; Dental radiography; Epidemiology; Public health; EQUATOR

**Core tip:** Full mouth dental radiographs are in world-wide daily use and contain various informations about dental and oral health of adult patients. This is why it is often used for epidemiologic research or to augment clinical data. But, when reported, data is presented in multifarious ways. Thus no or only little comparison of research outcome is possible. Existing standards of evaluation and reporting should be fixed in a reporting guideline regarding: number of teeth and implants; caries, fillings and restorations; root-canal fillings and apical health; alveolar bone level. Application of sum scores turned out to be very questionable.

Huettig F, Axmann D. Reporting of dental status from full-arch

radiographs: Descriptive analysis and methodological aspects. *World J Clin Cases* 2014; 2(10): 552-564 Available from: URL: <http://www.wjgnet.com/2307-8960/full/v2/i10/552.htm> DOI: <http://dx.doi.org/10.12998/wjcc.v2.i10.552>

## INTRODUCTION

Beside diagnosis support, X-rays are an established method to follow up treatments with surrogate characteristics, such as: bone loss in implantology, periodontology and maxillo-facial surgery, or apical flare up and loss of teeth in endodontology, or caries prevalence in operative dentistry.

Moreover, it is used for assessment of skeletal changes focussing orthodontic or temporo-mandibular-disorders. It is even possible to find approaches of forensic medicine, *i.e.*, for non-invasive age determination *via* orthopantomograms.

The quality of panoramic radiographs has enhanced during the last years. Namely their sensitivity and specificity to diagnose findings, as mentioned before, is considered to be satisfying. Problems of underestimation are discussed commonly. Nevertheless, determining oral health by radiographic presentable dimensions of the dental status is possible. That is why panoramic radiographs are often used for epidemiologic and retrospective analysis of dental status and oral health respectively. Recently, a review subsumed the competence and application of panoramic radiographs for epidemiologic studies of oral health<sup>[1]</sup>. However, it remains uncertain, whether standards are established to report radiographic findings which describe dental status or oral health data in general. No results, neither in Pubmed/Medline, EQUATOR-Network ([www.equator-network.com](http://www.equator-network.com)) or Cochrane Library could be identified searching a relevant guideline. Therefore, this systematic review was launched, to find out, which approaches are commonly used, to assess and report the entities: decay, missing, restorative, endodontic and periodontal status as surrogate dimensions of oral health (Table 1).

## MATERIALS AND METHODS

### Search and identification/inclusion and exclusion

A Medline/PubMed search was performed for articles reporting findings from full arch radiographs, focused on oral health and dental status of adults. This search was conducted in November 2011. No time limit was set. Panoramic X-ray or a full-mouth radiographic survey with periapical radiographs of all remaining teeth were defined as “Full arch radiograph”. In the following, the term “radiograph” will be only used in this sense.

To find and include such papers the following search-string was constructed stepwise and applied finally as: (“radiographic study” or “panoramic”) and (“oral health” or “dental status” or “dental health” or “dentition”) not (children OR review OR edentulous)

The following inclusion and exclusion criteria were set for a full text review of findings: All peer-reviewed reports with dental findings obtained from full arch radiographs are included, even if there had been additional clinical examination or patient chart reviews. These reports had to focus on at least one surrogate of “dental status” or “oral health” (Table 1), whereas reports handling edentulous or partially edentulous patients were disregarded.

Only articles written in English were included. Studied cohorts had to be of adult age, respectively the mean age had to be at least 18 years.

If it was not determinable in the abstract, which kind of radiography was applied or which variables of dental status were reported, the article was included to full-text review.

Excluded was all literature handling radiometric issues only [*i.e.*, bone density, cephalometric angles of jaw and joint, subjected to soft-tissues (carotis, lymphal-nodes)] or focusing on specific teeth/tooth types only (such as caries in third molars) as well as anthropologic analysis. Articles were also excluded, if they turned out to report on the basis of bitewing radiographs or specific single radiographs to fulfill their objective.

### Definition of variables of interest

Every previously included paper was reviewed towards the report of at least one out of the following eight variables (I a-IV), which reflect the surrogates listed in Table 1. If inclusion was validated, information about: (1) Bibliography and focus of study; (2) Number of patients studied and country of origin; (3) Number and kind of radiographs studied was noted first. Then the materials and method section (MMS) and results were checked for the following 8 variables of interest: I a: remaining/missing teeth (also included in DMFT/S); I b: implants or implant-loss; II a: fillings (also included in DMFT/S); II b: decay/caries (also included in DMFT/S); II c: restorations (*i.e.*, crowns); III a: root canal treatment; III b: apical status; IV: alveolar bone level on teeth or implants.

These variables were recorded by their mode of report. Further statistical analyses applied to these variables within the articles were disregarded, due to the different focus of the studies. Regarding the application of these variables, it was noted if additional arrangements, exclusion or inclusion criteria towards the report were mentioned by the authors. For example: how to handle the “third molars”, supernumerary teeth or teeth not depicted clearly on radiographs.

If a variable was mentioned in the section “methods” but not reported, it was mentioned not reported “(NR)”. If a variable was not mentioned within the method section, it was noted as not defined “(ND)”. Furthermore it was recorded, if the authors applied a special method of evaluation and how it was described or whom they cited. A “?” was assigned to indicate an assumption by the reviewers throughout the data, whenever there was no clear statement within the context of the article. For lon-

**Table 1** Entities of dental status and their surrogates in oral health: Left column notes the entities of dental status, which can be assessed from a full-arch radiograph

Focused entities	Subject of clinical dentistry	Surrogate of oral health
Alveolar bone loss, furcation and vertical bony defects	Periodontology, implantology	Periodontitis/inflammation, risk of tooth loss
Fillings/inlays	Operative dentistry	Oral hygiene, caries, decay, risk for massive fillings/partial crowns
Massive filling/partial crown	Operative dentistry, prosthodontics	Risk of root canal treatment, risk for crown-treatment
Crowns and fixed dental prosthesis/pontics	Prosthodontics, periodontology	Massive decay (even of healthy teeth), risen risk for caries and endodontic problems, risk for bone loss and fracture (missing teeth), missing teeth
Root canal filling and root posts	Operative dentistry, endodontology, prosthodontics	High number of life events of intervention, risk of tooth loss by fracture/inflammation, need for crown
Apical lesion	Endodontology, oral surgery	High risk of tooth loss, poor root canal treatment, inflammation
Missing teeth	Prosthodontics, implantology	High number of life events of interventions, former inflammations, trauma, hypodontia, malocclusion
Implants	Periodontology, prosthodontics	Missing teeth, higher risk for inflammation (periimplantitis), occlusal rehabilitation
Edentoullism	Prosthodontics, oral surgery	High number of life events, no further risk of odontogenic inflammation (caries, periodontitis, apical lesions)

Their possible relation as a surrogate of oral health is shown in the right column. The involved subjects of Dental Medicine are noted in the middle column. Reading the table from top to down, it has to be considered, that surrogates include content of cells above.

gitudinal studies, the different comparisons between the dates of results were not considered, as far as no other way of report was applied. Information about removable dentures had been neglected, because these are generally not allowed to be seen on radiographs at all. If results of a study or cohort were published twice, first, the longer observation period and, secondly, the higher impact factor in year of publication gave favor for inclusion.

### Operationalization of findings

The report of variables I to IV was reduced to a simple logic expression. Every expression, shown in Table 2, can be translated with the following “keys-words” and abbreviations: “ND” or “NR” indicates “not defined” or “not reported”.

“N” = “number”; “[ ]” = “of/in”; “()” = “expressed as”; “/” = “by presenting values”; “;” = “and”; “+” = “with”; “G” = “in group (s)”; “F” = frequency, “%” = percentage, “SD” = standard deviation, “Q” = quartiles, “rg” = range, “al” = “all patients/teeth/surfaces”, “tot” = “total”, “pat” = “patient(s)”, “grades” = “declared graduation or scaling of measurements”, “FDP” = “fixed dental prosthesis”.

Variable I refers to “r” = remaining, “m” = missing or “f” = lost/failed teeth. Variables II-IV always refer to affected patients, teeth, lesions, surfaces or sites. Following groups were standardized: age, gender, jaw, tooth-type, age-group, grades (of a previously defined classification).

If authors introduce special groupings (*i.e.*, diseased/healthy, baseline/follow-up and so on), it was abbreviated “spec” for “special”. This was mandatory due to the different outcome-variables of the studies.

For dental terms following abbreviations were used: “ABL” = “alveolar bone level/loss”, “apH” = “apical health”, “RCF” = “root canal filled”, “FDI” = “FDI-tooth code”, “FDP” = “fixed dental prosthesis”.

**Two examples of this operationalization:** The following expression in the column “II b Caries/Decay”: “N[surface](mean, SD)[pat]/G[age, gender]” is translated to “The number of carious surfaces is expressed as mean and standard deviation in a patient, by presenting values in groups of age and gender”.

Another exemplary expression in the column “III a RCT” is “N[pat + teeth](F)” translated to “Number of patients with affected teeth is expressed as frequency”.

### Subsumption

All included papers were ordered according to their objective. Bibliography as well as number and origin of patients were described by frequency distributions. To discuss the consistency, the findings were subsumed for all papers towards each entity of interest. Therefore cited methods of radiographic evaluation were full-text reviewed, as far as these were written in English or German and obtainable *via* library services.

## RESULTS

Following Figure 1, thirty-seven studies were evaluated and can be found in Table 2.

The years of publication of all results are shown in Figure 2. In whole 27447 (median = 191) X-rays have been evaluated and reported within 37 studies including 27772 (median = 215) patients. Figure 3 shows the shares of patients towards their origin. Ninety-four percent of the patients studied were from United States and Europe.

For nine journals no Impact Factor (IF) was noted at *Journal Citation Report* (JCR) of “Web of Knowledge” ([www.webofknowledge.com](http://www.webofknowledge.com)). The 5-year IF in 2010 of all JCR-listed and evaluated journals was median = 2.23, range: 0.89-6.39, SD = 1.16. So the included articles represent an extract of high ranked journals, regarding an average IF of about 1.3 (median = 1.2, mean = 1.5) for

Table 2 Evaluated articles and encountered mode of report: All full-text reviewed articles are sorted by the year of publication

Ref.	Number of X-rays evaluated	I a: Number of teeth	II a: Fillings	II b: Caries	II c: Restorations	III a: RCF	III b: apF	IV: ABL
Helenius-Hietala <i>et al</i> <sup>[17]</sup> 2011 <sup>b</sup>	212	N[r-teeth](mean,SD)[pat]	ND	N[pat](mean)/G[spec]	ND	ND	NR	mm(mean,SD)/pat; meanABL[pat]/G[spec]; N[teeth+G[ABL]] (mean,SD)/G[spec]
Yoshihara <i>et al</i> <sup>[40]</sup> 2011 <sup>a</sup>	177	N[r-teeth](mean,SD)[pat]/G[spec,gender]	ND	ND	ND	ND	ND	ND
Andersen <i>et al</i> <sup>[26]</sup> 2011 <sup>b</sup>	52	N[r-teeth](mean,SD, median,Q)[pat]/G[age]	ND	ND	Combined: N[teeth](mean,SD,median,Q)[pat]/G[age]; N[teeth](F, %)[toothtype]/G[age]	ND	ND	ND
Seppänen <i>et al</i> <sup>[81]</sup> 2011 <sup>b</sup>	84	N[r-teeth](median,rg)[pat]	ND	N[pat](F, %)[all pat], G[spec]	ND	ND	ND	N[pat](F)[ND]/G[spec]
Willershausen <i>et al</i> <sup>[49]</sup> 2011 <sup>a</sup>	2374?	N[r-teeth](mean?)/G[age,spec], N[m-teeth](mean)/G[age]	N[teeth](mean,SD)[pat]/G[spec], N[pat](%)/G[age]	N[teeth](mean,SD)[pat]/G[spec], N[pat](%)/G[age]	N[teeth](mean,SD)[pat]/G[spec], N[pat](%)/G[age]	ND	ND	ND
Kirkevang <i>et al</i> <sup>[21]</sup> 2009 <sup>b</sup>	470	N[r-teeth](mean,rg)[pat]/G[age, toothtype]	N[teeth+1,2,3 surfaces](median,range)[pat]/G[age, toothtype]	N[teeth](mean,rg)[pat]/G[age, tooth-type]	ND	ND	ND	ND
Saevæs <i>et al</i> <sup>[10]</sup> 2009 <sup>a</sup>	93	N[m-teeth](mean)[pat]/G[age,spec]	N[teeth](mean)[pat]/G[age,spec]	ND	"Some"	N[teeth](%)[all teeth]; N[pat](F)[spec]	ND	ND
Tarkkila <i>et al</i> <sup>[13]</sup> 2008 <sup>b</sup>	161	N[r-teeth](mean,SD)[pat]/G[spec]	Combined with clinical examination: N[DMFT,DT,FT](mean,SD)[pat]/G[spec]	ND	ND	NR	NR	ND
Buhlin <i>et al</i> <sup>[49]</sup> 2007 <sup>b</sup>	51	N[r-teeth](mean,SD)[pat]/G[spec,all]	N[DMFT](mean,SD)[pat]/G[spec,all]	ND	ND	ND	N[teeth](F, %)[pat]/G[spec]	ND
Nalçaci <i>et al</i> <sup>[26]</sup> 2007 <sup>a</sup>	190	N[r-m-teeth](mean,SD)[pat]/G[gender, tooth-type]	N[teeth](mean,SD)[pat]/G[gender,all]	N[FPD](F, %)/G[gender,jaw]	N[teeth](median,SD)[pat]/G[gender,all]	ND	ND	N[pat](median,SD)[ND ABL]/G[gender]
Huunonen <i>et al</i> <sup>[3]</sup> 2007 <sup>b</sup>	95	N[m-teeth](F)/G[spec]	ND	N[teeth](F)/G[spec]; N[findings?](F)/G[spec]	N[teeth](F)/G[spec]	ND	ND	N[pat](F)/G[spec]
Jansson <i>et al</i> <sup>[36]</sup> 2006 <sup>c</sup>	191?	N[r-teeth](mean,SD)[pat]/G[spec]	ND	ND	ND	ND	ND	N[pat](F)/G[spec]
Tabrizi <i>et al</i> <sup>[11]</sup> 2006 <sup>c</sup>	20	N[r-teeth](F,mean,SD)[pat]	N[DMFT,DMFT](mean,SD)[pat]/G[spec]	Included to DMFT?	ND	ND	ND	ABL(mean)[pat]
Skudutyte-Rysstad <i>et al</i> <sup>[30]</sup> 2006 <sup>a</sup>	146	ND	ND	ND	N[pat+tooth](F, %)[all]; N[pat]/N[teeth](F); N[teeth](F, %)/G[spec]	ND	ND	ND
Peltola <i>et al</i> <sup>[31]</sup> 2006 <sup>a</sup>	307	NR <i>via</i> DMFT	NR <i>via</i> DMFT	N[teeth](mean,SD)[pat]/G[spec]	ND	ND	ND	NR



Ma <i>et al</i> <sup>[2]</sup> 2005 <sup>a</sup>	1232	N[pat+m-teeth](%)/G[tooth-type]; N[m-teeth](%)[tooth-type]	ND	ND	ND	ND	ND	ND	ND	ND
Olze <i>et al</i> <sup>[14]</sup> 2005 <sup>1</sup>	275	NR	NR	NR	NR	NR	NR	NR	NR	NR
Cabrera <i>et al</i> <sup>[4]</sup> 2005 <sup>c</sup>	1417	N[pat](F)/G[m-teeth,spec]	ND	ND	ND	ND	ND	ND	ND	ND
Rosenquist <i>et al</i> <sup>[5]</sup> 2005 <sup>b</sup>	452	N[pat](F)[G[m-teeth]/G[spec]	ND	ND	ND	ND	ND	ND	ND	ND
Montebugnoli <i>et al</i> <sup>[44]</sup> 2004 <sup>c</sup>	113	NR <i>via</i> pantomography index	ND	ND	ND	ND	ND	ND	NR	NR
Abou-Raya <i>et al</i> <sup>[44]</sup> 2002 <sup>a</sup>	50	N[pat+m-teeth](%)/G[spec]	ND	ND	ND	ND	ND	ND	NR <i>via</i> pantomography index	NR <i>via</i> pantomography index
Enberg <i>et al</i> <sup>[21]</sup> 2001 <sup>a</sup>	137?	N[r-teeth](mean,SD)[pat]/G[spec]	ND	ND	ND	ND	ND	ND	N[teeth](mean,SD)[pat]/G[spec]	N[teeth](mean,SD)[pat]/G[spec]
Närhi <i>et al</i> <sup>[6]</sup> 2000 <sup>a</sup>	396	N[pat+r-teeth]; N[r-teeth](mean,SD)[pat]/G[spec]	ND	ND	ND	ND	ND	ND	N[teeth](mean,SD)[pat]/G[spec]	N[teeth](mean,SD)[pat]/G[spec]
Aartman <i>et al</i> <sup>[43]</sup> 1999 <sup>a</sup>	211	N[r-teeth](mean,SD)[pat]/G[spec]	ND	ND	ND	ND	ND	ND	N[teeth](mean,SD)[pat]/G[spec]	N[teeth](mean,SD)[pat]/G[spec]
Taylor <i>et al</i> <sup>[38]</sup> 1998 <sup>b</sup>	362	N[r-teeth?](median)/G[spec]	ND	ND	ND	ND	ND	ND	N[teeth](mean,SD)[pat]/G[spec]	N[teeth](mean,SD)[pat]/G[spec]
Grau <i>et al</i> <sup>[48]</sup> 1997 <sup>c</sup>	126	NR <i>via</i> pantomography index	ND	ND	ND	ND	ND	ND	NR <i>via</i> pantomography index	NR <i>via</i> pantomography index
Peltola <i>et al</i> <sup>[19]</sup> 1993 <sup>c</sup>	990?	N[pat](%)[DMFT = 0]	ND	ND	ND	ND	ND	ND	N[pat](%)	N[pat+ND G[ABLI]](F,%)
Hakeberg <i>et al</i> <sup>[33]</sup> 1993 <sup>c</sup>	180	N[m-teeth](mean,SD,rg)[pat]/G[spec,gender,age]	ND	ND	ND	ND	ND	ND	N[lesions](mean,SD,rg)[pat]/G[spec,gender,age]	N[lesions](mean)[pat]/G[spec]
Corbet <i>et al</i> <sup>[24]</sup> 1992 <sup>b</sup>	165	N[m-teeth](mean,SD)[pat]/G[age]; N[m-teeth](%)[FDI]	ND	ND	ND	ND	ND	ND	ND	ND
Lindqvist <i>et al</i> <sup>[15]</sup> 1989 <sup>d</sup>	50	N[r-teeth](mean,rg)[pat]	ND	ND	ND	ND	ND	ND	N[teeth,pat](F); N["Inadequate" RCF](F,%)	N[pat](F,%) / G["periodontitis"]; N[pat?](F)[spec]
Stermer Beyer-Olsen <i>et al</i> <sup>[37]</sup> 1989 <sup>c</sup>	141	ND	ND	ND	ND	ND	ND	ND	N[teeth,RCF-teeth](F,%)	N[pat](F,%)
Grover <i>et al</i> <sup>[7]</sup> 1982 <sup>a</sup>	5000	N[pat](F,%) / G[m-teeth]	ND	ND	ND	ND	ND	ND	N[findings,pat](F,%)	N[pat+G[periodontitis]](F,%)
Langland <i>et al</i> <sup>[16]</sup> 1980 <sup>b</sup>	2921	ND	ND	ND	ND	ND	ND	ND	N[pat+tooth](F,%)	N[pat+G[periodontitis]](F,%)
Meister <i>et al</i> <sup>[25]</sup> 1977 <sup>b</sup>	5783	ND	ND	ND	ND	ND	ND	ND	N[findings](F,%)	N[pat+G[periodontitis]](F,%)

Pelton <i>et al.</i> <sup>[20]</sup>	200	ND	ND	N[findings](F)/ G[jaw,spec]	ND	ND	ND	ND	ND
1973 <sup>d</sup>									
Christen <i>et al.</i> <sup>[21]</sup> 1967 <sup>b</sup>	1338	ND	ND	ND	ND	ND	ND	N[pat+tooth](F)	N[pat+gross periodontitis](F, %)
Lilly <i>et al.</i> <sup>[8]</sup>	1285	N[pat](F, %)/G[r-teeth]	ND	ND	ND	N[teeth](F)/G[tooth- type]; N[pat.canals](F)	ND	N[teeth](F)G[spec]	ND
1967 <sup>d</sup>									

The date is followed by a discretionary index for the 5 year Impact Factor of the journal in 2010 (a < 1.5; b < 3; c > 3; d: None). Please see caption: Operationalization of findings in "Materials and Methods" section to decipher content in columns I a-IV. Column II b "Implants" is not shown for a comprehensive view and due to the lack of noteworthy reports. RCF: Root-canal-fillings; apf: Apical findings; ABL: Alveolar bone loss; ND: Not defined; NR: Not reported.

Dental Journals listed in the JCR in 2011.

All modes of report are shown-according to the scheme of operationalization-in Table 2. The following subheadings subsume these findings and focus on the methodic of radiographic assessment.

### Missing/remaining teeth and implants

Thirty/37 (81%) of all studies reported remaining and/or missing teeth. Four articles intended a report of these values within their material and method section, but did not so. Beside mean-and median values, two artificial approaches were found: Ma *et al.*<sup>[2]</sup> reported the prevalence of missing tooth types (first molars). Other authors gave the number of absolute frequency of missing teeth within their studied cohort<sup>[3]</sup>. In addition to this the following groupings were found: "< 10 missing teeth"<sup>[4]</sup>, "0, 1-5, 6-14, 15-20, > 20 missing teeth", "1-7, 8-20, 21-32 teeth"<sup>[6]</sup>, "1-2, 3-5, 6-9, 10-14, 15-20, 21-27 missing teeth"<sup>[7]</sup>, "0, 1-11, 21-12, 22-27, 28-31, 32"<sup>[8]</sup>.

This approach of grouping allowed the authors mentioned above to report only the "number of patients" within their established groups. Before 1990 absolute frequencies were reported more frequently. Due to the variety of dentition, especially existence of 3<sup>rd</sup> molars, the problem of report is thoroughly discussed below.

Only 3 articles considered and reported dental implants. That is why this column is not shown in Table 2. The modes of report were: "N[pat + implants](%) / G[age]"<sup>[9]</sup>, "N[implants](F)[all pat]/G[spec]"<sup>[3]</sup> and worded "some"<sup>[10]</sup>.

### Caries, fillings and restorations

Due to the clinical DMFT-index decayed (caries) and filled (restored) teeth are often pooled and mixed up. Six authors did so-three out of these using the DMFT/DMFS-Index<sup>[11-13]</sup>. Overall 19 out of 37 papers mentioned to evaluate "caries problem", "lesions", "-teeth" or "defective teeth". One did not report their announced findings<sup>[14]</sup> and two remained unclear<sup>[15,16]</sup>. Four authors got more specific towards their assessment by mentioning the following criteria: "deep caries cavities"<sup>[17]</sup>, "caries pulpal exposure lesions"<sup>[18]</sup>, "lesions clearly perforating the enamel and clear radiolucencies under old fillings were recorded. Enamel caries was excluded"<sup>[19]</sup>, "gross carious lesions ... in posterior teeth"<sup>[7]</sup>.

Pelton *et al.*<sup>[20]</sup> classified caries lesions within a reliability study of panoramic and periapical radiographs as "C1: radiographically viewed that involved the enamel, but did not penetrate the dentin; C2: ... involved the enamel and the dentin, but not the pulp; C3: ... said to involve the pulp".

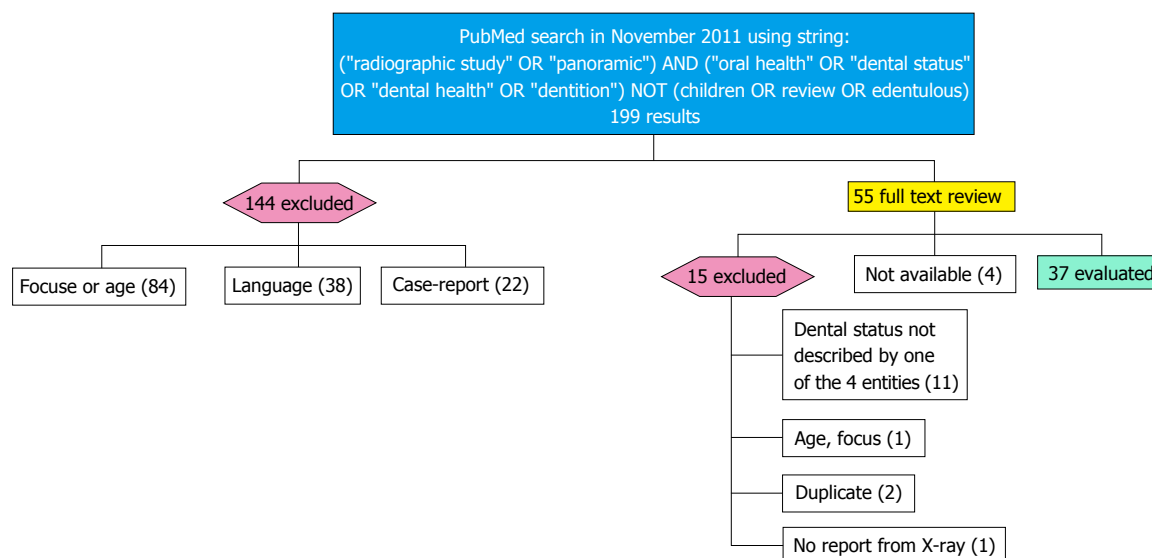
Two other authors explained more concrete: "Caries was judged to be present in the radiograph when a clearly defined reduction in mineral content of the proximal, occlusal, and/or restored surfaces was evident"<sup>[6]</sup>, and "(Caries was) present when the lesion reached the dentin proximally or occlusally or was found at restored surfaces"<sup>[21]</sup>.

Kirkevang *et al.*<sup>[22]</sup> used a method published by Wenzel<sup>[23]</sup> described as follows: "A surface was assessed as having a caries lesion if a radiolucency, exhibiting the shape of a caries lesion and observed at a caries-susceptible site", and augmented with "extended into dentine; radiolucencies confined to the enamel were ignored".

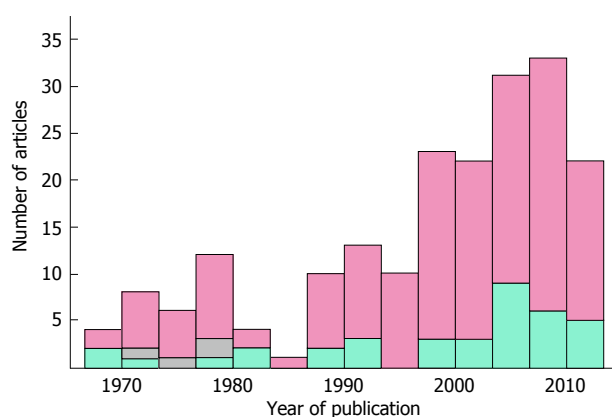
In the same article Kirkevang *et al.*<sup>[22]</sup> gave concrete information about fillings: "Registrations were performed on mesial, distal and occlusal or incisal surfaces. Fillings in pits and fissures in oral and buccal surfaces were not registered".

Tabrizi *et al.*<sup>[11]</sup> stated "Restorations and dental caries were also calculated for each participant", but owes the data by presenting only DMFT-values.

Reporting is also structured by using absolute frequencies of patients with "lesions"<sup>[18,19]</sup>, or "affected teeth" in all patients<sup>[3]</sup>. In addition to this, following groupings were found: "0,



**Figure 1** Flow chart of review strategy and finally evaluated articles: The flow chart shows the systematic exclusion of search results towards the finally evaluated studies. The primary reasons for exclusion are mentioned including the number of concerned articles.



**Figure 2** Distribution of included and excluded articles: Distribution of the 37 evaluated (green) and 159 excluded (red) studies of the search results ordered by their date of publication. Shaded fractions represent the 4 articles which were not available as full text version.

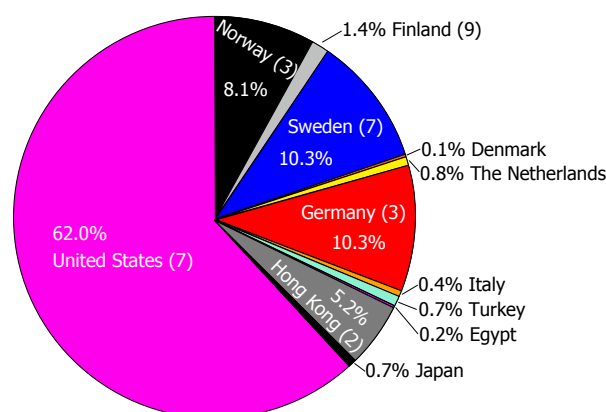
< 5, > 5 defective teeth<sup>[5]</sup>, “0, 1-2, ≥ 3 carious lesions<sup>[19]</sup>. Restorations were reported six times<sup>[9,10,16,24-26]</sup>, but 2 articles did insufficiently<sup>[10,27]</sup>. Within three out of seven articles restorations, fillings and decay were merged<sup>[5,11,15]</sup>.

### Root canal fillings and apical health

Identification of root canal filled teeth was taken for granted in 15 out of the 18 papers. Within 3 papers it was clarified in more detail within the MMS as “ongoing or completed root canal treatment, ..., pulp amputation”, “teeth with pulp amputation, endodontic fillings, or both<sup>[3,6,21]</sup>. One article merged root canal fillings and apical health<sup>[28]</sup>.

Seventeen further articles focused on apical health. The periapical index (PAI) by Orstavik *et al.*<sup>[29]</sup> was used for diagnosis of periapical health by only three authors, who regarded the PAI-scores 3-5 as positive finding<sup>[3,28,30]</sup>.

For Peltola *et al.*<sup>[31]</sup> “A radiolucency measuring > 2 mm in the apical bone was considered to be an apical rarefac-



**Figure 3** Shares of patients in the 37 evaluated studies with respect to the country of origin: The number of contributing studies is noted in brackets behind the country. Preponderance of United States is due to two reports of “mass X-ray evaluation” in the years 1977 and 1982. If these two are left out of consideration the median value of studied subjects in a paper is 212 (mean = 485).

tion”. Nalçaci *et al.*<sup>[26]</sup> cited Soikkonen *et al.*<sup>[32]</sup> method: “A periapical lesion, interpreted as apical periodontitis, was recorded if there was a clearly discernible local widening of the apical periodontal membrane space”. But, this approach is not described within this referred citation (handling edentulous patients at all). Hakeberg *et al.*<sup>[33]</sup> divided “Periradicular destructions ... into three different classes according to size; 1 = pathologically altered lamina dura and radiolucency less than 2 mm, 2 = radiolucency of 2-10 mm, 3 = radiolucency > 10 mm<sup>[33]</sup>, and set grade 2 as cut-off for affection. The earliest grading found was in Lilly *et al.*<sup>[8]</sup> 1967: “less than 5 mm and 5-10 mm apical translucency<sup>[8]</sup>”.

The remaining five articles only mentioned to evaluate “apical radiolucencies<sup>[17]</sup>, “periapical lesions<sup>[5]</sup>, without further criteria or mentioning additions like: “radicular cysts as well as sclerotic periapical lesions indicating con-

densifying osteitis<sup>[6,21]</sup>, or “sign of osteolysis”<sup>[12]</sup>.

### Alveolar bone level

The most various methods in assessment and reporting were found for alveolar bone level.

Metric measurements were used by five authors<sup>[6,7,17,21,33]</sup>. In addition to this following groupings were found: “ $\geq 6$  mm,  $\geq 4$  mm”<sup>[17]</sup>, “ $> 1-3$  mm,  $> 3-6$  mm,  $> 6$  mm”<sup>[6]</sup>, “ $< 2$  mm,  $2-4$  mm,  $> 4$  mm”<sup>[33]</sup>. “ $< 4$  mm = moderate periodontitis,  $> 4$  mm = severe periodontitis”<sup>[7]</sup>.

To relativize metric measures the following formula for alveolar bone loss is used: “total bone height divided by total root length [the distance from the radiographic apex to the cemento-enamel junction (CEJ)] multiplied by 100.”, and applied *i.e.*, by Tabrizi *et al.*<sup>[11]</sup>.

Rosenquist<sup>[5,12]</sup> decided to use a modified criterion of Lindhe<sup>[34]</sup>: “ $< 1/3$  of the root length,  $> 1/3$  of the root length, and horizontal loss supporting tissues,  $> 1/3$  of the root length, angular bony defects and/or furcation involvement” which is similar to Nyman *et al.*<sup>[35]</sup> cited by Tabrizi *et al.*<sup>[11]</sup>. Two authors used a relative root length, but went for an overall approach and added a criterion for “diseased” *via* their amount of findings: “ $\geq 30\%$  of the sites with  $\geq 1/3$  bone loss”<sup>[36]</sup> and “including one or more teeth”<sup>[37]</sup>.

Semiquantitative approaches were found specified: “classified as extension to: (1) to the coronal third of the root; (2) the middle third of the root; and (3) the apical third of the root”<sup>[18,21]</sup>. Graduations apart from thirds exist also: *i.e.*, as an ordinal scale with five grades: “0%, 1%-24%, 25%-49%, 50%-74%, or  $\geq 75\%$ ”<sup>[38]</sup> or with only one cut-off point as: “one-fourth or more of the normal bone height”<sup>[37]</sup>.

A direct measurement of ABL-percentages was developed by Schei *et al.*<sup>[39]</sup> and used by only one author<sup>[38]</sup>.

For two authors “A healthy horizontal bone level was considered to be 2 mm”<sup>[21,31]</sup>. Huuonen *et al.*<sup>[3]</sup> graded into “(1) No bone loss, bone level within 2-3 mm of the cemento-enamel junction area; (2) Slight bone loss, bone level at the cervical third of the roots; and (3) Moderate to advanced bone loss, bone level between the middle third of the roots at or beyond the apex”<sup>[3]</sup>. Slightly different graduation-starting out the same with level 0-Nalçaci *et al.*<sup>[26]</sup> continues: “(1) Moderate bone loss, bone level at the middle third of the roots; (2) Advanced bone loss, bone level at the apical third of the roots; and (3) Severe bone loss, bone level at or beyond the apex”, but did not mention a cut-off. So it remains unclear (ND) what the reported “horizontal bone loss” is intended to be.

In three cases the results were presented with previously not defined expressions like “periodontal problem”<sup>[18]</sup> or undefined graduations like “Slight marginal bone loss ... and vertical bone loss”<sup>[19]</sup>. The definition lacks what exactly is supposed to mean “affected” in this context. Likewise less helpful is a more historical graduation we came over: “If considerable bone loss was seen, this was called ‘gross periodontal disease’. If there was pronounced ‘arclike’ bone loss limited to the molar and incisor regions,

this was designated as periodontosis”<sup>[25]</sup>.

One methodical article on forensics was coping with the calculation of DMFT and DFT-Index. They stated within their material and method section to grade ABL of 2<sup>nd</sup> premolars towards the criteria “0, less than half of first third, up to third of root, more than a third”. But the findings were not reported at all<sup>[14]</sup>.

## DISCUSSION

The diversity of assessments and report modes is found to be alarming. The applied search strategy covers only a small, but high-ranked, sample of articles handling radiographic findings. It has to be assumed, that diagnosis and report of the entities studied here are not standardized at all, as it is for clinical dental status, namely the DMFT-, CPITN-, PI-, or BOP-Index for example.

In the following, each above mentioned and studied entity is discussed critically towards assessment and report. Further consequences are subsumed.

### Number of teeth and implants

The method to identify teeth from a radiograph is quite simple. Not so the communication of amounts and values.

Commonly, every time when the descriptive level of absolute frequencies (*i.e.*, number of affected patients) is not used, the calculation has to be relative to a standardized data-set (*i.e.*, all patients studied, all patients with root canal treatment). It gets even more complicated, if the complete dentition is handled as an entity: When median-or mean values are used, the calculation base has to be clear. For the first: including the third molars to the calculation, or not? For the second: how to handle missing or supernumerary teeth? For the third: are edentulous patients excluded<sup>[17,40]</sup>, or included to the calculation-or have there been other selection criteria like “at least 15 remaining own teeth”<sup>[9]</sup>?

Unfortunately this was not clear for 9 out of the 37 studied papers. Twenty-three included, 4 excluded, the third molars for evaluation. Two articles presented both approaches. Due to the variety of third molars dental history (retention, extraction) it make sense-similar to DMFT Index-to exclude these, if these are not primary focus of a study. Please follow the subheading “report of values” below, where more inherent details are addressed.

Against the backdrop of costly dental implants as a routine therapy after about 40 years now, their presence in oral status should be reported. Their number can give not only important dental input, but also ideas towards the financial background of an individual patient, a group, a whole cohort or even the social system.

### Carious lesions, fillings and restorations

The detection of carious lesions within radiographs is discussed and researched by operative dentistry, foremost. Searching “detecting caries and X-ray” *via* Pubmed/Medline results around 100 findings. The definitions used by the authors studied herein are inconsistent. This is why



a clear statement which definition can be used as a gold standard to assess a tooth as affected by caries, would be favorable. We found the approach of Pelton and Bethart the most reproducible<sup>[20]</sup>.

As fillings are made from radiopaque resin, cement, compomer, or metal, these can be easily seen on radiographs. If a restoration material is only slightly radiopaque, like silicate ceramic, the used adhesive composite or luting cements is clearly visible. However, the size of restorations can only be guessed, due to the 2-dimensional projection. But, the amount of decay could be derived from the ratio of filling and remaining coronal tooth substance.

These remarks are valid for fixed restorations (crowns, pontics) too. For all of these 3 findings, the mode of report as a comparable number and the report of missing values has to be standardized.

### Root canal fillings

Root canal fillings can be recognized just as easily as a tooth or restoration itself can be, because radiopaque materials are used around the world very commonly. Two authors judged the quality of root canal fillings<sup>[3,30]</sup>. If the quality or length of root canal fillings should be regarded or not, remains to be discussed by endodontologist. Works about the potential already exist<sup>[41]</sup>. Furthermore the existence of root canal posts has to be taken into account. Some of these are either not radiolucent (Fiber-posts) or radiopaque and due to their form not possible to distinct from a perfect root canal filling.

Regarding the reporting mode as frequency or percentage is same as discussed for missing/remaining teeth. Furthermore reporting authors should care about the problem that the number of teeth is easier to compare than the number of roots or even root canals. Moreover the values of root canal treatments should be reported separately from apical affection(s) of a tooth or root.

### Apical health

Beside the controversy of detection capability with peri-apical and panoramic radiographs (augmented with the problem: digital *vs* analog), the key point is to diagnose the affection in awareness of healthy variations without a clinical examination. This is analog to the detection of caries. The method of the PAI by Orstavik *et al.*<sup>[29]</sup> is a good example for standardization and should be used more often. This 5-grade assessment tool is based on standardized pictures. It might be most reliable if used with a cut-off at Grade 3.

Confusing is the usage of “lesion” or “finding” in contrast to “affected tooth”, because *i.e.*, a lower first molar may have 2 apical or carious lesions (mesial and distal), but is only 1 affected tooth. As for the above-mentioned root-canal fillings, at this point of time no consensus could be found. But, we found one possibility for clarification: “For multi-rooted teeth, the root presenting the highest PAI-score and the quality of the corresponding root filling was used”<sup>[30]</sup>.

### Alveolar bone loss

The “radiographic alveolar bone loss” is one classical

research dimension of periodontology and implantology. Thereby it has been of interest for ages-expressed in hundreds of publications. Thus radiographic assessment of this entity is just as many-faceted. Two general approaches could be identified: metric measuring and proportions of bone height towards root length. The latter might be the better choice due to the variety of root length by anatomy and radiographic projection. Moreover, approaches including the age dependence of bone loss are described<sup>[42]</sup>.

Beside bone level, furcation and vertical defects might be taken into account, too. The authors do not want to judge, which way is the best. But, even if a standard can be found in the future, also the cut off values for healthy and affected shall be defined by the authorities (see caption “grading and cut-offs”). Until then, the authors find the relative approach coping with the “first third of the root”, described by Nyman *et al.*<sup>[35]</sup>, the most reliable.

### Missing values/misinterpretation

Depiction problems of X-rays may lead to missing values, because it is not always possible to state a finding (*i.e.*, the vertical alveolar bone height by overlapped projection of two teeth, carious lesion at a filling by a “burn out” artifact). Only 5 papers mentioned depiction problems right in their material and methods section as follows: “If the image of the permanent teeth was blurred, supplementary digital intraoral radiographs were taken of these teeth”<sup>[28]</sup>, “For areas poorly visible in the panoramic radiograph, intraoral radiographs were made”<sup>[6,26,37]</sup>, “A tooth was judged as non-measurable if the CEJ or bone crest could not be identified properly because of overlapping caries or restorations. In cases where any one of the dental or bony landmarks could not be identified on one aspect (mesial or distal), the tooth was excluded”<sup>[11]</sup>. Projection artifacts may also lead to misinterpretation, which is mostly ruled out by the use of 2 examiners and/or reliability assurance. Such problems were solved differently: “In case of disagreement between the observers, their mean is used in the calculation”<sup>[43]</sup>.

“Only panoramic radiographs that displayed the whole dentition without asymmetry, distortion or error in patient positioning were included”<sup>[2]</sup>, “The radiographs were assessed twice, the first time by each dentist separately and next time by all in cooperation”<sup>[10]</sup>.

One article announced within materials and method section: “Missing values were registered with suitable so-called ‘missing values’<sup>[9]</sup>, but-it was true for all articles above mentioned, these values were not reported.

One of the articles revealed depiction problems while studying the X-rays and stated: “A total of 54 teeth, most often maxillary pre-molars, were excluded”<sup>[11]</sup>.

Discussions about sensitivity and specificity of panoramic radiographs were only anecdotal, not concrete. Montebugnoli *et al.*<sup>[44]</sup> dropped an important sentence, which was unfortunately not discussed further or towards their findings: “Other factors that could affect the outcomes include differences in the way of measuring ... dental status (the measures used to assess the oral status seem to be related to the strength and significance of the

associations reported)<sup>[44]</sup>.

Beside this, Langland *et al*<sup>[16]</sup> mentioned within their comparative study in 1980: “Discrepancies in the percentages of periodontal disease may be attributed to variance in the classification of each disease entity each year ....”<sup>[16]</sup> and also Grover *et al*<sup>[7]</sup> did so in 1982: “Several discrepancies in findings ... explained by variance ... in diagnostic methods”. One author explicitly complained about the absence of guidelines and stated: “We found it difficult to clearly define what a short root was and how to define early obliteration of the pulp. There are no guidelines in the literature, which defined what is a short root, and what is obliteration. For that reason it was difficult to compare our data with earlier studies”<sup>[10]</sup>.

In summary, it has to be pointed out again, that panoramic radiographs can be regarded as sufficient diagnosis instrument. During the past 5 years digital imaging made great strides. But, sufficient comprehensive data about quality progress is not published yet. Nonetheless, the assessment of dental findings within a radiograph is restricted by anatomical deviations of oral structures, such as dislocation or rotation of teeth. That implies missing data are common in radiographic based studies—especially for alveolar bone loss, apical health and caries. The option of an “indiscernible/unclear” criteria will reduce bias since firstly, no accidental attribution as “affected” or “healthy” have to take place, secondly an idea about overall image quality is given.

Such missing values may be handled statistically, but have to be reported and how these were regarded in calculation.

### **Report of values: Mean and median, absolute frequencies and percentages**

The number of remaining and missing teeth is reported most frequently (see caption “missing/remaining teeth and implants”). But even in this case, comparability is difficult due to the different modes of reporting. 4 authors decided for the report of median-number, 16 for mean, 6 for absolute frequencies. The same utilization can be found across the other studied entities: caries, root-canal-filled teeth, apical lesions and even alveolar bone level.

For the report of frequencies the use of median values can be assigned as the better choice due to its lower susceptibility towards extreme single values and the non-normal distribution of remaining and missing teeth in patients. To clarify the distribution of data we recommend the report of both: mean and medium value, augmented with SD, range and quartiles.

### **Dichotomization, groups, grades and cut-offs**

A grouping of age, findings, measures are often necessary for further analyses, especially to calculate odd-ratios or only to compare such “self-made” groups. Grouping with a cut-off allows additionally to report absolute and relative frequencies of teeth or patients, instead of mean or median values. Examples for the last mentioned would be “1-10 missing teeth” or “< 20 remaining teeth”. Especially

the rationales behind the cut-offs points are questionable. Sometimes these are set following previous analysis of the same sample, such as: “Each group comprised one-third of the dentate subjects in the baseline study”<sup>[6]</sup>, or “Each dental index was dichotomized at the mean value”<sup>[44]</sup>. It can also be empirical reasons as: “The cut-off point (< 45 and > 45 years) was selected in accordance with the introduction of a new social-security law”<sup>[21]</sup>. However, cut-off points for “healthy” and “diseased” varied, especially if diagnosis of alveolar bone height and apical lesions are dichotomized for analyses, graphic art and report.

With such intervention to data, these are not universally valid anymore. Further comparability is hindered, if the crude data are not available from the paper.

### **The DMFT and other sum scores**

Three authors reported DMFT-values<sup>[11-13]</sup>. One team reported only the number of patients (one time as percentage, one time as an absolute frequency) with a DMFT value of zero<sup>[19,31]</sup>. The DMFT would be helpful for a comparison with existing epidemiological data, but it hinders to extract missing/remaining teeth if only given as a sum score. If not separated by the author, no more information can be extracted from the DMFT; the DMFS is even worse. Furthermore alveolar bone level and apical health are not covered within this (exclusively) clinical index.

Within our review other indices could be found: six authors cited Mattila *et al*<sup>[45]</sup>: “Association between dental health and acute myocardial infarction” and their sum score of a “Total Dental Index” or “Pantomographic Index”<sup>[6,12,18,46]</sup>. This is also cited as panoramic tomography score, which is “the sum of radiolucent periapical lesions, third-degree caries lesions, vertical bone pockets, radiolucent lesions in furcation areas<sup>[47]</sup>” and was applied by Montebugnoli *et al*<sup>[44]</sup>. Even if published and cited in high-ranked journals, we found this system neither comprehensible in development nor validated for multipurpose application. Its focus is both: infective oral lesions in a combination of oral and radiographic evaluation as well as from radiographic assessment itself. Furthermore the description of index does not contain either methods of oral nor radiographic assessment for its entities. Despite of this fact, the sum of total dental index (TDI) can reach values “between zero and 10”<sup>[45]</sup>. Nevertheless, the scale of this cited index varies between publication due to modification by the authors: “0-14”<sup>[48]</sup>, “0-8”<sup>[49]</sup>, “0-10”<sup>[18,50]</sup>, 0-15<sup>[6]</sup>. Seppänen *et al*<sup>[18]</sup> used a classification of the sum scores “good, moderate and poor” which was not established by Mattila *et al*<sup>[45]</sup> 1989 as cited in this very article. Montebugnoli *et al*<sup>[44]</sup> decided to dicomize “each dental index ... at the mean value”. Buhlin *et al*<sup>[49]</sup> separated the index according to the statement “TDI of 0 or 1 are considered to have good oral health and those with TDI 4-8 have poor”. Especially these inconsistencies left this tool highly questionable. However, further investigation is needed for a concluding evaluation of this approach. Beside, and discussed for the DMFT, a sum score-with such complexity of terms-might not be

useful for report. Foremost because, the values of each contained entity are not given to the reader and for future comparison.

### Limitations of this report

This report is only based on articles indexed at PubMed/Medline. The variety of applied approaches was expected to grow if further databases (*i.e.*, EMBASE or MED-PILOT) are searched. Although this might harden the presented conclusion, it would not rise the informative content of this report.

Detailed information about type of X-ray and films used as well as acts of calibration of examiners was not included to this review. We took into account, that journal reviewers have already checked the applied intervention and found these appropriate. Furthermore, the widespread use of dental radiographs implies standardization on a reasonable level and quality. Findings in adults were favored, due to the variety of radiographic studies and dentition in children and adolescents. The variety of the mixed dentition is in fact a problem of standardization. The authors are aware that for every entity studied within this review, hundreds of other articles exist and there might be even standards scientists agree on. But, this can only be figured out by further systematic reviews-one for each entity and a final harmonization in a reporting guideline. Such a general guideline would support the authors preparing their studies and manuscripts as well as the scientists to compare data.

Only one article covered all entities studied in this review<sup>[26]</sup>. Nevertheless, all researches would have been enabled to report all these entities. Evidently it is often not of interest to report about *i.e.*, alveolar bone loss while presenting results about the prevalence of apical lesions. Nonetheless, such data would contrast and illustrate findings by thorough information about the studied cohort. More accompanied information could be conveyed about dental status of studied subjects. Thus, comparability and multi-variate analyses would be simplified generally. The authors think it would be worthwhile to have an easy reporting system of all entities. Today's possibilities to provide such data digital *via* online publication would enable authors and publishers to share data without expensive printed pages.

There are established but not generally accepted and enforced standards to assess and report findings from radiographic surveys. Thereby comparability of published findings is only possible with chief limitations. There is need to agree on standardized assessment and diagnosis first, and about the mode of report secondly. An easy and validated multi-term report-system of dental status would allow a widespread application, especially for dental public health and epidemiology. In consequence: there is need for a reporting guideline.

## COMMENTS

### Background

Reporting standards are necessary to compare research outcomes especially

in medical science. Full-mouth radiographic surveys allow information about the dental status. These are: number of teeth, caries, fillings/restorations, root canal treatments/filling, apical health and alveolar bone loss. But findings have to be evaluated and reported in such a way, that a comparison between published results is possible. There is no reporting guideline, yet. Which mode of report could be proper is neither finally discussed nor published. The paper shows shortcomings in current acquisition and presentation of data, hereinafter it recommends suitable methodical approaches.

### Research frontiers

Dental radiology, epidemiology, research methodology in dentistry and medical statistics for oral health variables.

### Innovations and breakthroughs

Only 8 out of 37 scientifically papers are at the maximum comparable towards 3 out of 7 entities of dental status. Evaluation of radiographs differ is widely. Reporting with statistical tools like mean and median or grouping and dichotomization did not allow further comparison, due to a lack of raw data. Also sum scores or indices like Decayed, Missing and Filled Teeth (DMFT) impede comparability of data. Thus no standard could be identified. Besides, missing values are underreported.

### Applications

A guideline of standards for evaluation, report and cut-off points is needed. So far it can be advised, that: (1) depicting problems and resulting missing values are reported; (2) it must be stated, if third molars are included or not when reporting the number of missing or remaining teeth; (3) implants should be taken into account; (4) sum scores are only present with crude data of the study. In case of DMFT the decayed teeth, missing teeth, filled teeth and decayed and filled teeth should be given separately, too; (5) apical health should be evaluated with a validated tool preferably the Peri-Apical-Index; (6) alveolar bone loss should be evaluated and reported in exact percentage or "in thirds" (Lindhe) not in absolute millimeters; (7) all distributions of data are presented with mean and medium value, augmented with SD, range and quartiles; and (8) the reader is given the rational for grouping or a cut-off point if data is dichotomized.

### Terminology

"Full-arch radiographs" are radiographs taken mostly in dental office and depicting all teeth (including the complete root) of a human dentition. Mostly a so called "panoramic radiograph" is taken; but also a survey with intraoral radiographs can be applied. "Apical health" describes the situation around the tip of the tooth root inside the bone of the jaw. This area might be retreat for bacteria causing a painless infection, which is relevant for systemic health and inflammation parameters. Such infections can be detected by radiographs. "Alveolar bone loss" describes the loss of jaw bone around teeth. The amount of lost bone correlates with the infection of tissues around teeth, which is a multifactorial disease promoted by bacteria. As seen in the radiograph the occurrence of a so called "periodontitis" (inflammation of the gums) can be anticipated by the loss of bone. "DMFT" is the World Health Organization-standard to report a clinically assessed dental status. It is namely the sum of Decayed, Missing and Filled Teeth in a dentition. "Reporting guideline" is a standardization for scientific reporting of findings. Today many such guideline exists in Medicine ([www.equator-network.com](http://www.equator-network.com)).

### Peer review

It is a well organized and written paper.

## REFERENCES

- 1 Choi JW. Assessment of panoramic radiography as a national oral examination tool: review of the literature. *Imaging Sci Dent* 2011; **41**: 1-6 [PMID: 21977466 DOI: 10.5624/isd.2011.41.1.1]
- 2 Ma EC, Mok WH, Islam MS, Li TK, MacDonald-Jankowski DS. Patterns of tooth loss in young adult Hong Kong Chinese patients in 1983 and 1998. *J Can Dent Assoc* 2005; **71**: 473 [PMID: 16026633]
- 3 Huuononen S, Sipilä K, Zitting P, Raustia AM. Panoramic findings in 34-year-old subjects with facial pain and pain-free controls. *J Oral Rehabil* 2007; **34**: 456-462 [PMID: 17518981 DOI: 10.1111/j.1365-2842.2007.01739.x]
- 4 Cabrera C, Hakeberg M, Ahlqvist M, Wedel H, Björkelund C, Bengtsson C, Lissner L. Can the relation between tooth loss and chronic disease be explained by socio-economic status? A 24-year follow-up from the population study of



- women in Gothenburg, Sweden. *Eur J Epidemiol* 2005; **20**: 229-236 [PMID: 15921040]
- 5 **Rosenquist K.** Risk factors in oral and oropharyngeal squamous cell carcinoma: a population-based case-control study in southern Sweden. *Swed Dent J Suppl* 2005; **(179)**: 1-66 [PMID: 16335030]
- 6 **Närhi TO,** Leinonen K, Wolf J, Ainamo A. Longitudinal radiological study of the oral health parameters in an elderly Finnish population. *Acta Odontol Scand* 2000; **58**: 119-124 [PMID: 10933560]
- 7 **Grover PS,** Carpenter WM, Allen GW. Panoraphic survey of US Army recruits: analysis of dental health status. *Mil Med* 1982; **147**: 1059-1061 [PMID: 6817201]
- 8 **Lilly GE,** Steiner M, Alling CC, Tiecke RW. Oral health of dentists: analysis of panoramic radiographs. *J Oral Med* 1967; **22**: 23-29 [PMID: 5230961]
- 9 **Willershausen B,** Witzel S, Schuster S, Kasaj A. Influence of gender and social factors on oral health, treatment degree and choice of dental restorative materials in patients from a dental school. *Int J Dent Hyg* 2010; **8**: 116-120 [PMID: 20522134 DOI: 10.1111/j.1601-5037.2009.00401.x]
- 10 **Saevæs R,** Lande Wekre L, Ambjørnsen E, Axelsson S, Nordgarden H, Storhaug K. Oral findings in adults with osteogenesis imperfecta. *Spec Care Dentist* 2009; **29**: 102-108 [PMID: 19284510 DOI: 10.1111/j.1754-4505.2008.00070.x]
- 11 **Tabrizi F,** Buhlin K, Gustafsson A, Klinge B. Oral health of monozygotic twins with and without coronary heart disease: a pilot study. *J Clin Periodontol* 2007; **34**: 220-225 [PMID: 17257161 DOI: 10.1111/j.1600-051X.2006.01041.x]
- 12 **Buhlin K,** Bárány P, Heimbürger O, Stenvinkel P, Gustafsson A. Oral health and pro-inflammatory status in end-stage renal disease patients. *Oral Health Prev Dent* 2007; **5**: 235-244 [PMID: 17977296]
- 13 **Tarkkila L,** Furuholm J, Tiitinen A, Meurman JH. Oral health in perimenopausal and early postmenopausal women from baseline to 2 years of follow-up with reference to hormone replacement therapy. *Clin Oral Investig* 2008; **12**: 271-277 [PMID: 18299902 DOI: 10.1007/s00784-008-0190-z]
- 14 **Olze A,** Mahlow A, Schmidt S, Wernecke KD, Geserick G, Schmeling A. Combined determination of selected radiological and morphological variables relevant for dental age estimation of young adults. *Homo* 2005; **56**: 133-140 [PMID: 16130836]
- 15 **Lindqvist C,** Söderholm AL, Slätis P. Dental X-ray status of patients admitted for total hip replacement. *Proc Finn Dent Soc* 1989; **85**: 211-215 [PMID: 2594748]
- 16 **Langland OE,** Langlais RP, Morris CR, Preece JW. Panoramic radiographic survey of dentists participating in ADA health screening programs: 1976, 1977, and 1978. *J Am Dent Assoc* 1980; **101**: 279-282 [PMID: 6931166]
- 17 **Helenius-Hietala J,** Meurman JH, Höckerstedt K, Lindqvist C, Isoniemi H. Effect of the aetiology and severity of liver disease on oral health and dental treatment prior to transplantation. *Transpl Int* 2012; **25**: 158-165 [PMID: 22054477 DOI: 10.1111/j.1432-2277.2011.01381.x]
- 18 **Seppänen L,** Lemberg KK, Lauhio A, Lindqvist C, Rautemaa R. Is dental treatment of an infected tooth a risk factor for locally invasive spread of infection? *J Oral Maxillofac Surg* 2011; **69**: 986-993 [PMID: 20950917 DOI: 10.1016/j.joms.2010.05.015]
- 19 **Peltola JS.** A panoramatomographic study of the teeth and jaws of Finnish university students. *Community Dent Oral Epidemiol* 1993; **21**: 36-39 [PMID: 8432103]
- 20 **Pelton WJ,** Bethart H. Student dental health program of the University of Alabama in Birmingham. X. The value of panoramic radiographs. *Ala J Med Sci* 1973; **10**: 21-25 [PMID: 4703032]
- 21 **Enberg N,** Wolf J, Ainamo A, Alho H, Heinälä P, Lenander-Lumikari M. Dental diseases and loss of teeth in a group of Finnish alcoholics: a radiological study. *Acta Odontol Scand* 2001; **59**: 341-347 [PMID: 11831482]
- 22 **Kirkevåg LL,** Vaeth M, Wenzel A. Prevalence and incidence of caries lesions in relation to placement and replacement of fillings: a longitudinal observational radiographic study of an adult Danish population. *Caries Res* 2009; **43**: 286-293 [PMID: 19439950 DOI: 10.1159/000217861]
- 23 **Wenzel A.** Dental caries. In White SC, Pharoah MJ (eds): *Oral Radiology. Principles and Interpretation*, 6th ed. St Louis: Mosby, 2009: 270-281
- 24 **Corbet EF,** Holmgren CJ, Pang SK. Use of shell crowns in Hong Kong dental hospital attenders. *J Oral Rehabil* 1992; **19**: 137-143 [PMID: 1517875]
- 25 **Meister F,** Simpson J, Davies EE. Oral health of airmen: analysis of panoramic radiographic and Polaroid photographic survey. *J Am Dent Assoc* 1977; **94**: 335-339 [PMID: 264490]
- 26 **Nalçacı R,** Erdemir EO, Baran I. Evaluation of the oral health status of the people aged 65 years and over living in near rural district of Middle Anatolia, Turkey. *Arch Gerontol Geriatr* 2007; **45**: 55-64 [PMID: 17097161 DOI: 10.1016/j.archger.2006.09.002]
- 27 **Christen AG,** Meffert RM, Cornyn J, Tiecke RW. Oral health of dentists: analysis of panoramic radiographic survey. *J Am Dent Assoc* 1967; **75**: 1167-1168 [PMID: 5233332]
- 28 **Andersen MG,** Beck-Nielsen SS, Haubek D, Hintze H, Gjørup H, Poulsen S. Periapical and endodontic status of permanent teeth in patients with hypophosphatemic rickets. *J Oral Rehabil* 2012; **39**: 144-150 [PMID: 21902707 DOI: 10.1111/j.1365-2842.2011.02250.x]
- 29 **Orstavik D,** Kerekes K, Eriksen HM. The periapical index: a scoring system for radiographic assessment of apical periodontitis. *Endod Dent Traumatol* 1986; **2**: 20-34 [PMID: 3457698 DOI: 10.1111/j.1600-9657.1986.tb00119.x]
- 30 **Skudutyte-Rysstad R,** Eriksen HM. Endodontic status amongst 35-year-old Oslo citizens and changes over a 30-year period. *Int Endod J* 2006; **39**: 637-642 [PMID: 16872458 DOI: 10.1111/j.1365-2591.2006.01129.x]
- 31 **Peltola JS,** Ventä I, Haahtela S, Lakoma A, Ylipaavalniemi P, Turtola L. Dental and oral radiographic findings in first-year university students in 1982 and 2002 in Helsinki, Finland. *Acta Odontol Scand* 2006; **64**: 42-46 [PMID: 16428182 DOI: 10.1080/00016350500419800]
- 32 **Soikkonen K,** Ainamo A, Wolf J, Xie Q, Tilvis R, Valvanne J, Erkinjuntti T. Radiographic findings in the jaws of clinically edentulous old people living at home in Helsinki, Finland. *Acta Odontol Scand* 1994; **52**: 229-233 [PMID: 7985508 DOI: 10.3109/00016359409029051]
- 33 **Hakeberg M,** Berggren U, Gröndahl HG. A radiographic study of dental health in adult patients with dental anxiety. *Community Dent Oral Epidemiol* 1993; **21**: 27-30 [PMID: 8432101 DOI: 10.1111/j.1600-0528.1993.tb00714.x]
- 34 **Lindhe J.** *Clinical Periodontology and Implant Dentistry*. Copenhagen: Munksgaard, 1998
- 35 **Nyman S,** Lindhe J. Examination of patients with periodontal disease. In: Lindhe J, Karring T, Lang NP, editors. *Clinical Periodontology and Implant Dentistry*. Copenhagen: Munksgaard, 2003: 403-413
- 36 **Jansson H,** Lindholm E, Lindh C, Groop L, Bratthall G. Type 2 diabetes and risk for periodontal disease: a role for dental health awareness. *J Clin Periodontol* 2006; **33**: 408-414 [PMID: 16677329 DOI: 10.1111/j.1600-051X.2006.00929.x]
- 37 **Stermer Beyer-Olsen EM,** Bjertness E, Eriksen HM, Hansen BF. Comparison of oral radiographic findings among 35-year-old Oslo citizens in 1973 and 1984. *Community Dent Oral Epidemiol* 1989; **17**: 68-70 [PMID: 2920542 DOI: 10.1111/j.1600-0528.1989.tb00590.x]
- 38 **Taylor GW,** Burt BA, Becker MP, Genco RJ, Shlossman M, Knowler WC, Pettitt DJ. Non-insulin dependent diabetes mellitus and alveolar bone loss progression over 2 years. *J Periodontol* 1998; **69**: 76-83 [PMID: 9527565 DOI: 10.1902/jop.1998.69.1.76]
- 39 **Schei O,** Waerhaug J, Lövdal A, Arno A. Alveolar bone loss



- as related to oral hygiene and age. *J Periodontol* 1959; **30**: 7-16
- 40 **Yoshihara A**, Deguchi T, Miyazaki H. Relationship between bone fragility of the mandibular inferior cortex and tooth loss related to periodontal disease in older people. *Community Dent Health* 2011; **28**: 165-169 [PMID: 21780357]
- 41 **Eriksen HM**, Berset GP, Hansen BF, Bjertness E. Changes in endodontic status 1973-1993 among 35-year-olds in Oslo, Norway. *Int Endod J* 1995; **28**: 129-132 [PMID: 8626195 DOI: 10.1111/j.1365-2591.1995.tb00286.x]
- 42 **Hardt CR**, Gröndahl K, Lekholm U, Wennström JL. Outcome of implant therapy in relation to experienced loss of periodontal bone support: a retrospective 5- year study. *Clin Oral Implants Res* 2002; **13**: 488-494 [PMID: 12453125 DOI: 10.1034/j.1600-0501.2002.130507.x]
- 43 **Aartman IH**, de Jongh A, Makkes PC, Hoogstraten J. Treatment modalities in a dental fear clinic and the relation with general psychopathology and oral health variables. *Br Dent J* 1999; **186**: 467-471 [PMID: 10365496 DOI: 10.1038/sj.bdj.4800142]
- 44 **Montebugnoli L**, Servidio D, Miaton RA, Prati C, Tricoci P, Melloni C. Poor oral health is associated with coronary heart disease and elevated systemic inflammatory and haemostatic factors. *J Clin Periodontol* 2004; **31**: 25-29 [PMID: 15058371 DOI: 10.1111/j.0303-6979.2004.00432.x]
- 45 **Mattila KJ**, Nieminen MS, Valtonen VV, Rasi VP, Kesäniemi YA, Syrjälä SL, Jungell PS, Isoluoma M, Hietaniemi K, Jokinen MJ. Association between dental health and acute myocardial infarction. *BMJ* 1989; **298**: 779-781 [PMID: 2496855 DOI: 10.1136/bmj.298.6676.779]
- 46 **Abou-Raya S**, Naeem A, Abou-El KH, El BS. Coronary artery disease and periodontal disease: is there a link? *Angiology* 2002; **53**: 141-148 [PMID: 11952103 DOI: 10.1177/000331970205300203]
- 47 **Mattila KJ**, Asikainen S, Wolf J, Jousimies-Somer H, Valtonen V, Nieminen M. Age, dental infections, and coronary heart disease. *J Dent Res* 2000; **79**: 756-760 [PMID: 10728977 DOI: 10.1177/00220345000790020901]
- 48 **Grau AJ**, Buggle F, Ziegler C, Schwarz W, Meuser J, Tasman AJ, Bühler A, Benesch C, Becher H, Hacke W. Association between acute cerebrovascular ischemia and chronic and recurrent infection. *Stroke* 1997; **28**: 1724-1729 [PMID: 9303015 DOI: 10.1161/01.STR.28.9.1724]
- 49 **Buhlin K**, Gustafsson A, Ahnve S, Janszky I, Tabrizi F, Klinge B. Oral health in women with coronary heart disease. *J Periodontol* 2005; **76**: 544-550 [PMID: 15857094 DOI: 10.1902/jop.2005.76.4.544]
- 50 **Abou-Raya S**, Abou-Raya A, Naim A, Abuelkheir H. Rheumatoid arthritis, periodontal disease and coronary artery disease. *Clin Rheumatol* 2008; **27**: 421-427 [PMID: 17763921 DOI: 10.1007/s10067-007-0714-y]

**P- Reviewer:** Arisan V, Kamburoglu K **S- Editor:** Ji FF

**L- Editor:** A **E- Editor:** Liu SQ



## Chemotherapy induced Takotsubo cardiomyopathy

Sunny Goel, Abhishek Sharma, Aakash Garg, Abhinav Chandra, Vijay Shetty

Sunny Goel, Abhishek Sharma, Abhinav Chandra, Vijay Shetty, Department of Medicine, Maimonides Medical Center, Brooklyn, NY 11219, United States

Aakash Garg, Department of Internal Medicine, James J. Peters VA Medical Center, Mount Sinai School of Medicine, Bronx, NY 10468, United States

**Author contributions:** All the authors contributed to this work.  
**Correspondence to:** Abhishek Sharma, MD, Department of Medicine, Maimonides Medical Center, 4802 Tenth Avenue, Brooklyn, NY 11219,

United States. [abhisheksharma4mamc@gmail.com](mailto:abhisheksharma4mamc@gmail.com)

Telephone: +1-201-8926548

Received: May 24, 2014 Revised: June 23, 2014

Accepted: July 18, 2014

Published online: October 16, 2014

[org/10.12998/wjcc.v2.i10.565](http://www.wjgnet.com/esps/helpdesk.aspx)

### INTRODUCTION

Chemotherapeutic drugs have a wide range of cardiotoxic effects. Recently, there have been case reports of chemotherapy [namely 5-fluorouracil (5-FU)] induced Takotsubo cardiomyopathy (TC)<sup>[1-5]</sup>. However, to the best of our knowledge, there has been no published literature on cytarabine and/or daunorubicin causing TC. In this report, we describe the case of a 55-year-old Chinese male who developed TC while receiving dual chemotherapy with cytarabine and daunorubicin for non M3 acute myeloid leukemia.

### CASE REPORT

A 55-year-old male with past medical history of diabetes mellitus (type II) presented to our hospital with complaints of pleuritic chest pain with non-productive cough and fever (Tmax 101.2 °F) for 3 d. Chest X-ray showed right-sided lung infiltrates. Patient was admitted to the medical floor with the diagnosis of community-acquired pneumonia and was started on moxifloxacin. The patient's blood work showed an incidental finding of 12% blast cells with a total white cell count of 9.9. Electrocardiogram performed on the day of admission revealed sinus tachycardia with abnormal R wave progression. Echocardiogram showed ejection fraction (EF) of 60%-65%, with normal chamber size and mild diastolic dysfunction. Three sets of cardiac enzymes including cardiac Troponin I and creatine kinase-MB were negative. Patient was evaluated by the hematology and oncology team for the incidental finding of blast cells on peripheral blood smear. The next day, as per the hematologist's recommendation, the patient underwent a bone marrow biopsy which showed the presence of pro-myelocytes, suggestive of M3 acute myeloid leukemia. The patient was started on All Trans-Retinoic Acid induction chemotherapy regimen. Prophylactic valacyclovir, omeprazole and intrave-

### Abstract

Chemotherapy has been linked with Takotsubo cardiomyopathy. Most of the literature on chemotherapy associated Takotsubo cardiomyopathy is on the drug 5-fluorouracil. In this report, we describe the case of a 55-year-old Asian male who developed Takotsubo cardiomyopathy while receiving dual chemotherapy with cytarabine and daunorubicin for acute myeloid leukemia. To our knowledge, it is the first case of Takotsubo cardiomyopathy associated with daunorubicin and/or cytarabine.

© 2014 Baishideng Publishing Group Inc. All rights reserved.

**Key words:** Takotsubo cardiomyopathy; Chemotherapy; Cytarabine; Daunorubicin

**Core tip:** In this case report, we describe first case of Takotsubo cardiomyopathy associated with daunorubicin and/or cytarabine.

Goel S, Sharma A, Garg A, Chandra A, Shetty V. Chemotherapy induced Takotsubo cardiomyopathy. *World J Clin Cases* 2014; 2(10): 565-568 Available from: URL: <http://www.wjgnet.com/2307-8960/full/v2/i10/565.htm> DOI: <http://dx.doi.org/10.12998/wjcc.v2.i10.565>

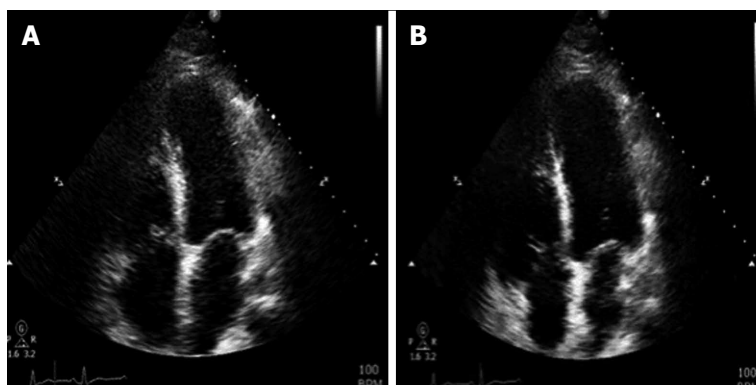


Figure 1 Echocardiogram showing ballooning of the apex with hyper contracted basal segment at end systole (A) end diastolic phase (B).

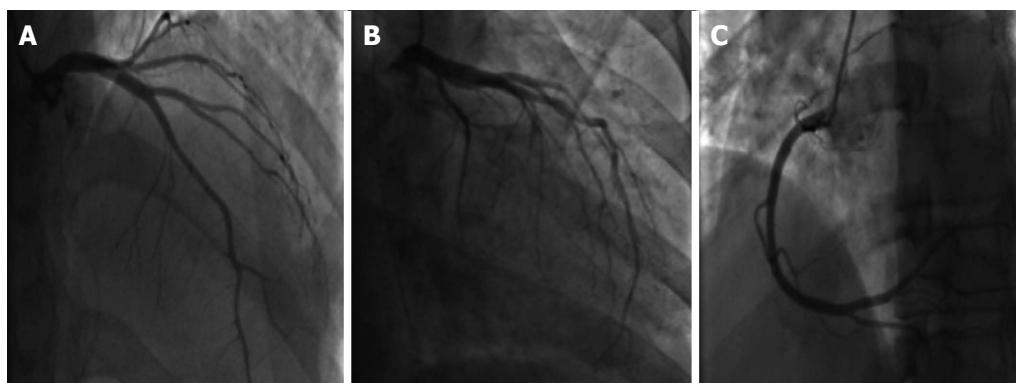


Figure 2 Coronary angiogram showing clean coronaries with thrombolysis in myocardial infarction 3 blood flow left main and left anterior descending (A), left circumflex (B) and right coronary artery(C).

nous (*in situ*) fluids were also started.

Two days after the initiation of chemotherapy, fluorescent *in situ* hybridization results demonstrated a negative translocation of chromosomes 15, 17, thus confirming the diagnosis of non-M3. As a result, the chemotherapy regimen was changed to cytarabine 100 mg/m<sup>2</sup> and daunorubicin 60 mg/m<sup>2</sup>. On day 6 of chemotherapy with cytarabine and daunorubicin, the patient began to experience non-radiating sub sternal chest pain associated with palpitations. Electrocardiogram obtained at that time showed sinus tachycardia of 170 bpm with ST segment elevation in leads I, aVL, V5, V6; consistent with anterolateral wall ST elevation myocardial infarction (STEMI). The patient was transferred to the cardiac intensive care unit (CCU) with a diagnosis of STEMI. Cardiac enzymes were obtained which showed Cardiac Troponin I of 8.54 upon initial transfer to the CCU, reaching a maximum of 38.64 after 18 h (normal values 0-0.1 ng/mL). Given the patient's immunocompromised state, cardiac catheterization was deferred and he was managed medically with aspirin, clopidogrel, rosuvastatin, and aggressive *in situ* hydration. Echocardiogram done on day 6 of chemotherapy showed an EF of 30%-35% with segmental wall motion abnormalities: mild anterior, septal, apical, inferior and lateral wall hypokinesia, with normal diastolic function consistent with mid-left anterior descending artery occlusion (Figure 1). On day 20 of admission, patient

underwent an elective cardiac angiogram, which showed non-obstructive coronary vasculature, mildly decreased left ventricular systolic function, EF of 50% with mild anterolateral and anterobasal hypokinesia (Figure 2).

## DISCUSSION

This case report demonstrates a strong causal relationship between chemotherapy and the development of TC as evidenced in the patient's presentation on day 6 of chemotherapy induction. Symptomatic recovery of the patient after supportive medical management, with the concomitant discontinuation of the chemotherapeutic agent, also strengthens this causal relationship. The patient's repeat echocardiogram (performed 2 wk after discontinuation of the chemotherapeutic agents) showed a complete recovery of the EF with no wall motion abnormalities. In addition, a coronary angiogram demonstrated non-obstructed coronary vasculature. Given the patient's clinical presentation and the diagnostic evidence obtained, there is no alternative justification for the clinical course observed other than Takotsubo cardiomyopathy. This is the first case report of daunorubicin and/or cytarabine induced TC.

Most of the literature on chemotherapy associated TC is published on the drug 5-FU, a widely used chemotherapeutic agent for solid tumors. One case report from

Japan described daunorubicin-induced TC in a patient with refractory multiple myeloma<sup>[6]</sup>. However, to our knowledge, this is the first case report of daunorubicin and/or cytarabine induced TC in the United States.

Chemotherapy induces increased sympathetic tone with resulting elevation of cytokine, free radical, prostaglandin, catecholamine and growth factor levels. The excess of these modulators can potentiate worsening adrenoceptor sensitivity, and can contribute to the clinical presentation of TC<sup>[1-5]</sup>. Daunorubicin belongs to the anthracycline class of chemotherapeutic agents, which remains among the most active anti-cancer drugs for solid tumor and hematologic malignancies. The exact pathogenic mechanisms responsible for the underlying cardiotoxic effects of anthracycline agents has yet to be elucidated. The current postulated mechanism supports the role of free radical induced cardiac damage (known to be caused by the excessive production of hydrogen peroxide, hydroxyl radicals and reactive oxygen species)<sup>[6-10]</sup>. These free radicals promote lipid peroxidation which contributes to cell membrane damage, and thus results in the activation of pro-apoptotic enzymes, such as Bax, Cytochrome-c and caspase-3, in myocyte mitochondria, triggering apoptosis and resulting in cardiac myocyte cell death<sup>[6-10]</sup>. Cardiac myocytes are more susceptible to lipid peroxidation due the presence of a high mitochondrial density with resultant high-energy requirements and the lack of anti-oxidant enzymes, which are required for the detoxification of superoxide anions and hydrogen peroxide. As a result of this cardiac myocyte susceptibility, a dose-related and irreversible loss of cardiac myocytes occurs, resulting in cardiomyopathy<sup>[11]</sup>. Though the exact mechanism of cardiotoxicity caused by cytarabine has yet to be elucidated, it is postulated that this drug can result in a hypersensitivity reaction or possible immune-mediated damage of cardiac myocyte<sup>[12]</sup>.

In conclusion, we suggest that physicians be vigilant when treating patients with daunorubicin and/or cytarabine and should be aware of a possible association of these chemotherapeutic agents with TC.

## COMMENTS

### Case characteristics

A 55-year-old male receiving treatment with Daunorubicin and Cytarabine for non M3 acute myeloid leukemia (AML) experience non-radiating sub sternal chest pain associated with palpitations on 6<sup>th</sup> day after chemotherapy.

### Clinical diagnosis

Acute coronary syndrome.

### Differential diagnosis

ST segment elevation myocardial infarction (STEMI), non-STEMI, Unstable Angina, Aortic Dissection, Pulmonary embolism, cardiomyopathy, Ventricular wall rupture.

### Laboratory diagnosis

Cardiac troponin I and creatine kinase-MB elevation with continued uptrend, consistent with myocardial ischemia.

### Imaging diagnosis

Electrocardiogram-anterolateral STEMI; Echocardiogram (ECHO) at day 6 of therapy-ejection fraction (EF) of 30%-35% with segmental wall motion abnormalities; repeat ECHO (two weeks later)-Normalization of EF and no wall mo-

tion abnormalities; cardiac catheterization (two weeks later)-clean coronaries. Pt diagnosed with Takotsubo cardiomyopathy.

### Treatment

Due to patient's immunocompromised state, he was medically managed with aspirin, clopidogrel, rosuvastatin, and aggressive intravenous hydration in cardiac intensive care unit.

### Related reports

Patient initially thought to have acute coronary syndrome but was eventually found to have Takotsubo cardiomyopathy. Patient had clean coronaries on Cardiac catheterization and on repeat ECHO, his EF normalized and wall motion abnormalities resolved.

### Term explanation

Non M3 AML-According to French-American-British classification acute myeloid leukemia are sub grouped in to 8 categories M0-M7. This classification guides the therapy and prognosis in patients diagnosed with AML.

### Experiences and lessons

Vigilance should be observed while treating patients with daunorubicin and/or cytarabine.

### Peer review

This is first case report of takotsubo cardiomyopathy associated with daunorubicin and/or cytarabine.

## REFERENCES

- 1 **Pai VB**, Nahata MC. Cardiotoxicity of chemotherapeutic agents: incidence, treatment and prevention. *Drug Saf* 2000; **22**: 263-302 [PMID: 10789823 DOI: 10.2165/00002018-200022040-00002]
- 2 **Smith SA**, Auseon AJ. Chemotherapy-induced takotsubo cardiomyopathy. *Heart Fail Clin* 2013; **9**: 233-242, x [PMID: 23562124 DOI: 10.1016/j.hfc.2012.12.009]
- 3 **Y-Hassan S**, Tornvall P, Törnerud M, Henareh L. Capecitabine caused cardiogenic shock through induction of global Takotsubo syndrome. *Cardiovasc Revasc Med* 2013; **14**: 57-61 [PMID: 23218901 DOI: 10.1016/j.carrev.2012.10.001]
- 4 **Grunwald MR**, Howie L, Diaz LA. Takotsubo cardiomyopathy and Fluorouracil: case report and review of the literature. *J Clin Oncol* 2012; **30**: e11-e14 [PMID: 22147738 DOI: 10.1200/JCO.2011.38.5278]
- 5 **Stewart T**, Pavlakis N, Ward M. Cardiotoxicity with 5-fluorouracil and capecitabine: more than just vasospastic angina. *Intern Med J* 2010; **40**: 303-307 [PMID: 20529041 DOI: 10.1111/j.1445-5994.2009.02144.x]
- 6 **Mitsumori T**, Nakajima K, Nozaki Y, Hamanaka S, Nagashima T, Kirito K, Iwao N, Komatsu N. [Multiple myeloma complicated with Takotsubo cardiomyopathy]. *Rinsho Ketsueki* 2010; **51**: 291-296 [PMID: 20467228]
- 7 **Gewirtz DA**. A critical evaluation of the mechanisms of action proposed for the antitumor effects of the anthracycline antibiotics adriamycin and daunorubicin. *Biochem Pharmacol* 1999; **57**: 727-741 [PMID: 10075079 DOI: 10.1016/S0006-2952(98)00307-4]
- 8 **Chua CC**, Liu X, Gao J, Hamdy RC, Chua BH. Multiple actions of pifithrin-alpha on doxorubicin-induced apoptosis in rat myoblastic H9c2 cells. *Am J Physiol Heart Circ Physiol* 2006; **290**: H2606-H2613 [PMID: 16687611 DOI: 10.1152/ajp-heart.01138.2005]
- 9 **Childs AC**, Phaneuf SL, Dirks AJ, Phillips T, Leeuwenburgh C. Doxorubicin treatment in vivo causes cytochrome C release and cardiomyocyte apoptosis, as well as increased mitochondrial efficiency, superoxide dismutase activity, and Bcl-2: Bax ratio. *Cancer Res* 2002; **62**: 4592-4598 [PMID: 12183413]
- 10 **Wang GW**, Klein JB, Kang YJ. Metallothionein inhibits doxorubicin-induced mitochondrial cytochrome c release and caspase-3 activation in cardiomyocytes. *J Pharmacol Exp Ther* 2001; **298**: 461-468 [PMID: 11454906]
- 11 **Goormaghtigh E**, Huart P, Praet M, Brasseur R, Ruyschaert



JM. Structure of the adriamycin-cardiolipin complex. Role in mitochondrial toxicity. *Biophys Chem* 1990; **35**: 247-257 [PMID: 2204444 DOI: 10.1016/0301-4622(90)80012-V]

12 **Williams SF**, Larson RA. Hypersensitivity reaction to high-dose cytarabine. *Br J Haematol* 1989; **73**: 274-275 [PMID: 2530999 DOI: 10.1111/j.1365-2141.1989.tb00267.x]

**P-Reviewer:** de Botton S, Kurpisz MK, Tobita K  
**S-Editor:** Song XX **L-Editor:** A **E-Editor:** Liu SQ



## Intensive outpatient comprehensive behavioral intervention for tics: A case series

Tabatha H Blount, Ann-Louise T Lockhart, Rocio V Garcia, Jeslina J Raj, Alan L Peterson

Tabatha H Blount, Jeslina J Raj, Alan L Peterson, Department of Psychiatry, The University of Texas Health Science Center at San Antonio, San Antonio, TX 78229, United States

Ann-Louise T Lockhart, Rocio V Garcia, Child and Adolescent Psychology, San Antonio Military Medical Center, Joint Base San Antonio, Ft. Sam Houston, TX 78234, United States

**Author contributions:** Blount TH and Lockhart AT made equal contributions to the manuscript; Peterson AL designed the report; Blount TH collected patient data and wrote Introduction, Patient A, and assisted with overall editing; Lockhart AT and Garcia RV collected clinical data and wrote Patient B and Discussion; Raj JJ helped write introduction and methods for Patient A.

**Correspondence to:** Alan L Peterson, Professor, Department of Psychiatry, The University of Texas Health Science Center at San Antonio, 7550 IH-10 West, Suite 1325, San Antonio, TX 78229, United States. [petersona3@uthscsa.edu](mailto:petersona3@uthscsa.edu)

Telephone: +1-210-5677000

Received: April 22, 2014 Revised: May 29, 2014

Accepted: August 27, 2014

Published online: October 16, 2014

### Abstract

Recent randomized clinical trials have established the efficacy of Comprehensive Behavioral Intervention for Tics (CBIT) in treating children and adults with Tourette syndrome and persistent tic disorders. However, the standard CBIT protocol uses a weekly outpatient treatment format (*i.e.*, 8 sessions over 10 wk), which may be inconvenient or impractical for some patients, particularly patients, who are required to travel long distances in order to receive care. In contrast, an intensive outpatient program may increase accessibility to evidence-based behavioral treatments for Tourette syndrome and other persistent tic disorders by eliminating the necessity of repeated travel. This case series evaluated the use of an intensive outpatient program CBIT (IOP CBIT) for the treatment of 2 preadolescent males (ages 10 and 14 years) with Tourette syndrome. The IOP CBIT treatment protocol included several hours of daily treatment over a 4-d period. Both children evi-

denced notable reductions in their tics and maintained treatment gains at follow-up. Moreover, both patients and their parents expressed treatment satisfaction with the IOP CBIT format. This case series addresses an important research gap in the behavioral treatment of tic disorders literature. The patients' treatment outcomes indicate that IOP CBIT is a promising treatment that warrants more systematic investigation.

© 2014 Baishideng Publishing Group Inc. All rights reserved.

**Key words:** Tourette syndrome; Tics; Habit reversal; Intensive outpatient; Behavior therapy

**Core tip:** Comprehensive Behavioral Intervention for Tics (CBIT) is an empirically supported treatment for individuals with Tourette syndrome. However, the standard, weekly outpatient format of CBIT may preclude some from receiving care. This is the first case series to examine the treatment outcomes of intensive outpatient CBIT (Intensive Outpatient Program CBIT) in children. Despite marked differences between the two boy's presentations, outcomes for both cases were positive.

Blount TH, Lockhart AT, Garcia RV, Raj JJ, Peterson AL. Intensive outpatient comprehensive behavioral intervention for tics: A case series. *World J Clin Cases* 2014; 2(10): 569-577 Available from: URL: <http://www.wjgnet.com/2307-8960/full/v2/i10/569.htm> DOI: <http://dx.doi.org/10.12998/wjcc.v2.i10.569>

### INTRODUCTION

Tourette syndrome (TS) is a disorder characterized by multiple motor tics and at least one vocal tic that occur regularly and are present for at least 12 mo<sup>[1]</sup>. On average, tics emerge between the ages of 3 and 8 years, peak between 10 and 12 years, and decrease in adulthood<sup>[2,3]</sup>. An estimated 60% of children with Tourette syndrome also

meet diagnostic criteria for at least one psychological disorder, with attention deficit hyperactive disorder (ADHD) being the most common comorbid condition<sup>[4]</sup>, followed by obsessive compulsive disorder (OCD), social anxiety, depression, and externalizing behaviors<sup>[4-6]</sup>.

### **Standard treatments for tourette syndrome and persistent tics**

Historically, pharmacologic interventions have been used as the first-line treatment for symptom management in Tourette syndrome patients<sup>[7]</sup>. However, medications require long-term continuous use and are associated with negative side effects that frequently lead to discontinuation of treatment (for review, see<sup>[7-9]</sup>). Alternatively, behavioral interventions reduce concerns regarding negative side effects and potential long-term consequences of prolonged medication use. A number of behavioral interventions have been examined (for review, see<sup>[10]</sup>) with habit reversal therapy<sup>[11]</sup> garnering the most support (for review, see<sup>[12]</sup>). Habit reversal consists of awareness training, contingency management, relaxation training, competing response training, social support, and generalization training.

Comprehensive Behavioral Intervention for Tics (CBIT)<sup>[13]</sup> is a multiple-component behavioral treatment for Tourette syndrome and persistent tic disorders that expands on the original habit reversal therapy protocol and includes additional emphasis on psychoeducation, functional interventions, and relapse prevention. Recently, two large randomized controlled trials examined the efficacy of CBIT compared to supportive therapy in adults and children diagnosed with Tourette syndrome and persistent tic disorders. The child study ( $n = 126$ ; mean age 11.7 years) found that CBIT was superior to a psychoeducation and supportive therapy comparison condition in reducing tics (52.5% *vs* 18.5%, respectively)<sup>[14]</sup>. The adult study ( $n = 122$ ; 16-69 years) also found superior results for CBIT, with 38.1% of the participants who received CBIT *vs* 6.4% in the psychoeducation and supportive therapy condition experiencing a significant improvement in their tics symptoms at post-treatment<sup>[15]</sup>. Importantly, both adults and children in the CBIT condition maintained treatment gains and reported decreased psychological symptoms at the six-month follow-up.

Taken together, these findings indicate that CBIT produces similar outcomes as medication without the side effects and that patients continue to experience benefits after treatment is completed<sup>[14]</sup>. In response to mounting evidence, CBIT is now considered a first-line treatment for persistent tic disorders in Europe<sup>[12]</sup> and Canada<sup>[16]</sup>.

### **Rationale for intensive outpatient CBIT**

The standard outpatient CBIT protocol is comprised of eight sessions that are completed over 10 wk, followed by three monthly booster sessions. However, weekly sessions may be inconvenient or impractical for some patients depending on the complexity of their symptoms or their accessibility to care. Instead, these patients may benefit from an intensive outpatient program (IOP) that

compresses CBIT into a week-long protocol. An IOP can help extend treatment catchment areas and compensate for the current lack of CBIT providers. Importantly, IOP also allows for patients to practice CBIT without the distraction of school or work. This is particularly relevant to the use of the competing response procedure, which is to be implemented upon the detection of a premonitory urge to tic or the actual occurrence of a tic. The IOP CBIT allows patients to dedicate time specifically to detecting urges and tics and implementing the competing responses without the distractions of day-to-day life. To date, no studies have been published evaluating the effectiveness of an IOP CBIT. However, Flancbaum *et al.*<sup>[17]</sup> presented a case study detailing the outcome of a 25-year-old male diagnosed with TS who traveled to the United States in order to receive seven sessions of adapted CBIT over two weeks<sup>[13]</sup>. The patient reported notable decreases in tic frequency and subjective distress and high treatment satisfaction at posttreatment, although he also reported a lapse in his tic symptoms when he returned home.

Little is known about the benefits of IOP CBIT, but there is precedence for treating children with an IOP behavioral program. For example, Whiteside and colleagues<sup>[18]</sup> present a case series of three adolescents who received 10 sessions of exposure and response prevention for OCD over five days. Each of the three adolescents experienced a decrease in OCD symptoms at post-treatment, and two maintained gains after three months. Moreover, an IOP (one session) protocol has been used to treat specific phobia in children and has demonstrated efficacy in three randomized controlled trials (for review, see<sup>[19]</sup>).

### **Goals of the case series**

The current case series addresses an important limitation in the literature by examining whether IOP CBIT can help quickly reduce tic severity in two youth diagnosed with TS. Although the boys in the case series differed markedly by age, ethnicity, psychological symptoms, behavioral distress, and tic severity, and although they were treated by different treatment teams (see Table 1), both evidenced a notable reduction in tics and maintained their treatment gains. The patients and their parents provided written informed consent for this case series.

## **CASE REPORT**

### **Patient A**

Patient A (see Table 1) was a 10-year-old Asian-American male in the fourth grade. He was placed in the gifted-and-talented program and advanced mathematics. He maintained good grades but had occasional behavioral problems at school. He had several friends and was involved in piano, karate, and chess.

Patient A's tics were first noticed by his second grade teacher when he was 7 years old. He was evaluated by a neurologist and a psychologist a year prior to receiving IOP CBIT. Both diagnosed him with Tourette syndrome.

**Table 1 Summary of patient information**

	Patient A	Patient B
Age (yr)	10	14
Ethnicity	Asian-American	African-American
Academic history	4 <sup>th</sup> grade Gifted and talented	9 <sup>th</sup> grade Dysgraphia, low-intellectual functioning, and disorder of written expression
Psychological history	Tourette syndrome	Tourette syndrome, ADHD, specific phobia, anxiety, insomnia, and stuttering
Tic interference	Minimal	Significant
Type (number) of tics	Motor (5)	Motor (6) and vocal (4)
Treatment teams	Psychologist, psychology postdoctoral fellow, and psychology intern	Psychologist and two psychology postdoctoral fellows
Length of treatment	4 d, 8 treatment sessions	4 d, 3 treatment sessions

ADHD: Attention deficit hyperactive disorder.

**Table 2 Patient A and B's outcome assessment scores**

Measures	Baseline	1 wk posttreatment	1 mo follow-up	7 mo follow-up	Baseline	1 wk posttreatment	1 mo follow-up	6 mo follow-up
	Patient A				Patient B			
	M	M	M	M	M	P	M	P
YGTSS								
Total	15	9	6	5	21	18	15	13
Number	2	1	1	2	5	4	4	2
Frequency	4	4	2	2	3	3	3	2
Intensity	4	3	2	1	4	4	2	2
Complexity	3	0	0	0	4	3	2	2
Interference	2	1	1	0	5	4	4	2
CGI-SI	4	3	2	2	5		3-4	3
CGI-I		1	1	1	-		2	2

M: Motor tic; P: Phonic tic; YGTSS: Yale Global Tic Severity Scale (Clinical Cut-off: 14); YGTSS subscales are out 5, with 0: None, 5: Severe; CGI-SI: Clinical Global Impressions-Severity of Illness (0: Not assessed; 1: Normal; 2: Borderline; 3: Mild; 4: Moderate; 5: Mark; 6: Severe; 7: Extreme); CGI-I: Clinical Global Impression-Improvement (0: Not assessed; 1: Very much improved; 2: Much improved; 3: Improved; 4: Minimal improvement; 5: No change; 6: Minimal worse; 7: Much worse; 8: Very much worse).

The neurologist recommended medication, which his parents decided against, and the psychologist recommended yoga and family therapy. They attended two sessions of family therapy but discontinued treatment after deciding that it was not helpful. After researching behavioral treatments on the Internet, Patient A's mother contacted one of the authors (ALP) to inquire about receiving CBIT for her son. Since the family would be required to travel to another city to receive CBIT, the staff and his mother agreed to use an IOP CBIT protocol. The patient presented for care in March 2013. At baseline, he and his mother reported that he experienced frequent facial tics that interfered with piano practice and chess competitions, but the tics did not interfere with his academic or social functioning. However, his mother was concerned that he would have tic-related social difficulties when he started middle school the following year.

### Baseline assessment

A baseline assessment was conducted by a master's level independent evaluator (IE), who was not involved in the patient's treatment. The Yale Global Tic Severity Scale (YGTSS)<sup>[20]</sup> and the Clinical Global Impression Scale (CGI)<sup>[21]</sup> were administered at baseline, posttreatment, and follow-up and were the main outcome measures for treat-

ment (see Table 2). The YGTSS, a semi-structured clinical interview, is routinely used in the TS literature and has well established psychometric properties (*e.g.*,<sup>[14, 20, 22, 23]</sup>). It provides a Total Motor Tic Score (range: 0-25), Total Phonic Tic Score (range: 0-25), Total Tic Score (range: 0-50); past studies have used YGTSS Total Scores greater than 13 as a cut-off for clinically significant tics (> 9 if patient has only motor or vocal tics; *e.g.*,<sup>[14]</sup>). A decrease of 4 points on the YGTSS is considered clinically meaningful in children<sup>[14]</sup>. The YGTSS was conducted by the IE and was completed by the patient with the help of his mother. The CGI-S and CGI-I scales are well-established rating tools applicable to all psychiatric disorders<sup>[21]</sup>. The CGI-S scale is used to assess treatment response in patients. The CGI-S requires the clinician to rate the severity of the patient's illness at the time of the assessment, relative to the clinician's past experience with patients who have the same diagnosis. The CGI-I requires the clinician to rate how much the patient's illness has improved or worsened relative to a baseline state.

The IE also administered the Kiddie Schedule for Affective Disorders and Schizophrenia-Present and Lifetime Version<sup>[24]</sup>, a semi-structured clinical interview designed to determine present episode and lifetime history of psychiatric illness based on the diagnostic criteria of the



**Table 3 Overview of Patient A's treatment schedule**

	Day 1	Day 2	Day 3	Day 4
Session	1:90 min	3:60 min	5:60 min	7:60 min
Number	Review history	Review OOSAs	Review OOSAs	Review OOSAs
	Treatment rationale	Inconvenience review	Inconvenience review	Inconvenience review
	Psychoeducation	Review treatment tic 1	Review treatment tic 1-3	Review treatment tic 1-3
	Tic hierarchy	Functional intervention	Functional intervention	Functional intervention
	Introduce function-based interventions	Competing response tic 2	Competing response tic 2	Competing response tic 2 Review relaxation
	Introduce reward program	Reward review	PMR	Relapse prevention
	Teach tic monitoring		Reward review	Reward review
Lunch (2 h)	Monitor tic 1	Monitor tics 1, 2	Monitor tics 1-3	Monitor tics 1-3
	Functional assessment	Practice CRs 1, 2	Practice CRs 1-3	Practice CRs 1-3
Session	2:90 min	4:60 min	6:60 min	8:60 min
Number	Review OOSAs	Review OOSAs	Review OOSAs	Review OOSAs
	Inconvenience review	Inconvenience review	Inconvenience review	Inconvenience review
	Functional assessment and treatment tic 1	Review treatment tic 1 and 2	Review treatment tic 1-3	Review treatment tic 1-3
	Competing response tic 1	Functional intervention tic 3	Functional intervention tic 2	Functional intervention
	Reward review	Competing response tic 3	Competing response tic 2	Competing response tic 2
		Introduce relaxation	Review relaxation	Review relaxation
		Diaphragmatic breathing	Reward review	Relapse prevention
		Reward review		Reward review
OOSAs	Practice CR for tic 1	Practice CRs tics 1-3	Practice CRs tics 1-3	Posttreatment assessment
	Monitor 30 min	Monitor 30 min	Monitor 30 min	
		Relaxed breathing	Relaxation	

CR: Competing response; OOSA: Out of session assignment; PMR: Progressive muscle relaxation.

**Table 4 Patient's A tic symptom hierarchy tracker ratings**

	S1	S3	S4	S5	S6	S7	S8	1 mo	6 mo
Eye Blink	6	6	4	4	3	1	2	0	1
Upper Lip	4	4	4	1	1	0	1	0	0
Facial Grimace	6	6	0	1	1	0	0	0	0
Neck Jerk	9	3	2	1	1	0	1	1	0
Nose Flair	4	4	0	0	0	0	0	0	0

Session 2 (S2) scores were not recorded; Subjective Unit of Distress Scale range from 0 to 10, with 0: No Distress; 10: Extreme distress.

Diagnostic and Statistical Manual of Mental Disorders, fourth edition, text revision<sup>[25]</sup>. In addition, the patient completed the Premonitory Urge Scale<sup>[26]</sup>, the Child Yale-Brown Obsessive Compulsive Scale<sup>[27,28]</sup>, and the ADHD Interview<sup>[29]</sup> at baseline. These commonly used measures were selected to provide a comprehensive evaluation of the patient's tic-related symptoms and psychiatric functioning.

The assessment confirmed a diagnosis of Tourette syndrome with evidence of clinically meaningful motor tics. He had a history of vocal tics but was not experiencing them at the time of the assessment. He did not endorse OCD symptoms and reported only minimal ADHD symptoms. Patient did not meet diagnostic criteria for other Axis I diagnoses.

### Formulation, rationale, and treatment plan

Environmental and social factors are believed to play a significant role in tic manifestation<sup>[22]</sup>. CBIT is an evidence-based behavioral treatment that recognizes and targets these factors. The patient completed eight ses-

sions (60 to 90 min each) of CBIT over four consecutive days (see Table 3). The protocol was administered by a treatment team, including two licensed psychologists and a pre-doctoral psychology intern.

### Course of treatment

Psychosocial and tic history were gathered and treatment rationale was provided in Session 1. Consistent with the CBIT manual, Session 1 focused on information gathering and providing a treatment overview and rationale. Patient A's mother was already well versed on TS. Patient A and his mother identified five current motor tics (neck jerk, eye blink, upper lip tic, facial grimace, and nose flair) that occurred in isolation and as a single complex tic (see Table 4). Tic monitoring and the role of social support to encourage skill use were introduced and a reward program was established to reinforce treatment compliance.

The Tic Hassle worksheet<sup>[30]</sup>, the functional assessment procedure, and the competing response procedure were introduced in Session 2 and were conducted each session for the remainder of treatment. The Tic Hassle worksheet uses a Subjective Units of Distress Scale (SUDS), in which patients verbally rate their level of distress on an 11-point scale, with 0 representing minimal distress and 10 representing extreme distress. In Session 2, Patient A identified neck pain (SUDS = 9), people noticing (SUDS = 3), his grandfather staring at him (SUDS = 4), interruption of piano practice (SUDS = 6), and increasing the time it takes to complete school work (SUDS = 5) as tic hassles. By the end of the eighth session, he no longer experienced distress from these hassles. Patient A and his mother had difficulty completing the functional

assessment for the individual tics throughout treatment. They reported that the tics occurred with equal frequency across all settings and denied consequences following tic occurrence. Moreover, due to the format of treatment, they had little to no opportunity to implement relevant function-based interventions at home.

Competing response training focused on one tic at a time, starting with his most distressing tic (*i.e.*, neck jerk tic). This component of treatment requires that patients become more aware of their tics and premonitory urges. Consequently, Patient A was asked to describe his tic and its corresponding premonitory urge, identify each time he engaged in the tic during the training, and then identify each time he experienced the premonitory urge. Next, the patient and the provider collaboratively selected an appropriate competing response. Effective competing responses are physically incompatible with and less conspicuous than the tic, can be performed for at least 60 s, and do not disrupt normal activity<sup>[13]</sup>. For example, the competing response for the patient's neck jerk tic involved having him gently move his chin forward and focusing on one spot each time he experience the tic or the premonitory urge. Self-monitoring indicated that his neck jerk tic occurred frequently (30 times in 5 min). By Session 4, he described decreased neck pain, and his mother reported a notable decrease in the neck jerk tic. The competing response training was implemented for his eye-blink and lip tics in Sessions 3 and 4, respectively. His competing responses included slow, rhythmic blinking for the eye tic and pursing his lips gently together for the lip tic. He demonstrated quick mastery over the lip tic but continued to have difficulty with his eye-blink tic. Consequently, the eye-blink tic remained the focus of CBIT for Sessions 5 to 8. By Session 8, both he and his mother reported improvement in his eye-blink tic, although his mother still occasionally had to prompt him to engage in his competing response.

Relaxation training was initiated in Session 4, and relapse prevention was discussed in Sessions 7 and 8. Since they had previously disagreed about what constituted a tic, both the patient and his mother were asked to discuss how they would handle new tics should they emerge. Ways to communicate about potential tics were explored, and a plan for this type of conversation was developed. At the end of treatment, both Patient A and his mother expressed high treatment satisfaction.

### Patient B

Patient B (see Table 1) was a 14-year-old African-American male. He participated in a home school program in which he attended classes several times per week outside his home and was also involved in track and field. At the time of the intervention, Patient B had not shared information about his diagnosis with peers. As a result, he often suppressed his vocal and motor tics when around peers and then released his urges to tic at home. At intake, Patient B's vocal and motor tics had occurred for approximately six months. He had already been evaluated

by pediatric neurology and developmental pediatrics and was prescribed methylphenidate for ADHD, clonidine for tics, and melatonin for sleep. Patient B completed an magnetic resonance imaging and electroencephalography with pediatric neurology, and it was determined that he did not present with epilepsy or other neurological concerns. When the tics were unresponsive to medication intervention, Patient B and his family were referred for behavioral treatment. Patient B's psychological history was positive for developmental delays, ADHD, and learning difficulties, with no prior history of tics. He had previously undergone treatment for specific phobia and stuttering.

Patient B presented for behavioral treatment in Spring 2012. Given the severity of his behaviors at his initial appointment (*i.e.*, grabbing his mother's arm, punching the floor, and difficulty starting and stopping movements), consultation with ALP was sought regarding the appropriateness of outpatient services. It was determined that he might benefit from an intensive outpatient treatment protocol, which started in Summer 2012.

### Baseline assessment

A baseline assessment of Patient B's current functioning was conducted by a master's level IE, who was not involved in the treatment delivery, and included the YGTSS<sup>[20]</sup> and the clinician-rated CGI<sup>[21]</sup> and the Hopkins Motor/Vocal Tic Scale (HMVTS)<sup>[31]</sup>. Only the YGTSS and CGI were used as outcome assessments, and additional information about their psychometric properties can be found under Patient A's baseline assessment section. The assessment confirmed the diagnosis of TS and indicated that Patient B was experiencing clinically significant vocal and motor tics (as defined<sup>[14]</sup>). Specifically, Patient B and his parents reported six motor and four vocal tics, which significantly interfered with family interactions and had begun to interfere with his peer relationships.

### Formulation, rationale, and treatment plan

The treatment team met with Patient B and his family to discuss treatment options including IOP CBIT. The family had already exhausted many other options in the community with little to no success, and his parents were hopeful that this alternative approach would alleviate his symptoms. Given the severity of his symptoms, Patient B continued to take clonidine during his participation in IOP CBIT.

Patient B and his parents attended one baseline assessment session and three IOP CBIT sessions over the course of four consecutive days. Although only three IOP CBIT sessions were conducted, the total amount of time spent for the intervention was comparable to that of the standard eight session CBIT protocol. During the course of treatment, Patient B's parents observed through a one-way mirror. Treatment was administered by a team consisting of a board certified child and adolescent psychologist and two child and adolescent post-doctoral fellows (see Table 5 for a summary of the specific treatment schedule).

**Table 5** Overview of Patient B's treatment schedule

	Day 1	Day 2	Day 3	Day 4
Session	S1: (1.5 h)	S2: (3.5 h)	S3: (3.5 h)	S4: (3.5 h)
Number	Baseline assessment	Psychoeducation	Review relaxation OOSAs	Competing response
		Introduce relaxation	Tic hassles form	Inconvenience review
	Meet therapists	Stress <i>vs</i> relaxation	Competing responses	Relaxation practice
		Relaxation postures	Inconvenience review	Review OOSAs
	Introductions	PMR + 12	Review tic 1 and 2	Review CR for all tics
	Treatment overview	Diaphragmatic breathing	Competing responses 1, 2	Summarize progress
		Visual imagery	Review treatment tic 1	Emphasize social support
		Awareness training	Practice relaxation	Reward review
		Psychoeducation about tics	Competing response 1 and 2	
		Rationale for treatment	Assign homework	
		Tic Sx hierarchy		
		Feedback about assessment		
OOSAs		Practice relaxation	CR tics 1-2	F(x) based interventions
		Practice PRM + 12	Monitor 15 min, 3-4x	Relaxation
		Practice visual imagery	F(x) based interventions	Family and social support
			Relaxed breathing	

PMR: Progressive muscle relaxation; Sx: Symptoms; CR: Competing response; OOSA: Out of session assignment; F(x) = Function.

### Course of treatment

During the baseline assessment, Patient B and his parents identified six current motor tics (grabbing/touching, putting napkins in mouth, full-body twitches, open mouth with head nodding, "closing" self into small spaces, tapping surfaces) and four vocal tics (screaming, humming, repeating self, and "Aahh" sounds). The treatment agenda, rationale, tic monitoring, and family support were discussed with Patient B and his parents.

CBIT was initiated in Session 2. The treatment team provided psychoeducation about tic disorders, the rationale for competing response training, awareness training, and the stress and relaxation responses. The team also engaged the patient in several relaxation strategies and progressive muscle relaxation, which yielded a notable decrease in his tics. A hierarchy of the patient's current tics was developed. Patient B was assigned relaxation and tic monitoring homework, which was reviewed at the start of the next session (see Table 5).

The following day, Patient B reported some benefit with homework while his mother reported a reduction in the severity and intensity of the grabbing tic in public places. Session 3 focused on completing the tic hassles worksheet<sup>[30]</sup>, in which Patient B described the grabbing tic and vocal tic as most bothersome. He identified arm pain (SUDS = 9), parental dependence (SUDS = 11), and annoying others (SUDS = 7) as tic hassles. Patient B reported that his vocal tic was embarrassing (SUDS = 10). Competing response training was implemented with one tic at a time, starting with the most distressing tic (grabbing), followed by the vocal tic. For the grabbing tic, Patient B was asked to practice squeezing his hands together and pushing them down as a competing response. For the vocal tic, Patient B was instructed to clench his teeth and push his tongue against the roof of his mouth as his competing response.

On Day 4, the treatment team reviewed the homework, in which the patient's mother observed only one

vocal tic during several discrete tic observation periods. Patient B reported not having any tics or urges while at a friend's house, and he stated that he did not feel as though he was suppressing his tics. Because Patient B was still reporting some difficulty identifying premonitory urges, a token economy was also implemented during the session whereby Patient B earned points towards a desirable reward for detecting a premonitory urge by notifying the provider (*i.e.*, raising his finger) and engaging in the appropriate competing response. Patient B responded positively to the token economy and was motivated to identify premonitory urges. He was also able to resist the urge to tic or engaged in the tic for markedly less time compared to pretreatment. At the end of the session, Patient B and his mother reported improvement in the awareness of his tics and premonitory urges. The treatment team also practiced relaxation strategies, summarized treatment progress, and discussed relapse prevention during the last part of the session. Providers emphasized the importance of ongoing social and family support.

Over four days of assessment and treatment, behavioral improvement was observed and noted by all three providers, Patient B, and his parents. Patient B reported feeling skeptical at the beginning of the week about whether this treatment would be effective, but at the last session he stated, "I stand corrected." Patient B was able to control his tics by either stopping them from occurring, notifying providers when he was about to have one, and/or decreasing the length of time spent engaging in specific tic behaviors. Overall, Patient B and his parents verbally reported high treatment satisfaction.

### Results

**Patient A:** By the end of treatment, Patient A and his mother reported a clinically meaningful decrease in his tic severity as assessed by the YGTSS and the CGI. Importantly, his tic severity scores had decreased further by the

one-month follow-up (see Table 2). Following their one-month follow-up assessment, Patient A and his mother attended a 60-min booster session, in which his mother reported that she only occasionally noticed a slight eye-blink tic. Patient A disagreed with his mother that this was a tic. He also reported that although he still experienced an urge to tic, the urge was less severe and occurred less frequently. Both Patient A and his mother reported continued treatment satisfaction with IOP CBIT at follow-up. Patient A and his mother reported continued treatment gains at the seven-month follow-up and high treatment satisfaction. More specifically, he reported that he continued to occasionally experience a slight eye tic. However, both he and his mother agreed that the tic was not noticeable to others and did not cause him interference. No new tics emerged from the time of treatment completion through the seven-month follow-up period.

**Patient B:** The YGTSS (see Table 5) and HMVTS were administered by the same IE and completed by Patient B with the help of his parents at one week, one month, and six months. Overall, the assessments revealed clinically meaningful improvement in Patient B's functioning (see Table 2). At the one-week follow up, there was an overall reduction in number of tics (10 *vs* 2). The parents reported that Patient B had not engaged in the grabbing tic in the previous week, that he was more aware of the urge to grab, and that he was able to apply a more appropriate competing response (*i.e.*, walking away, distraction, breathing). During follow-up interviews, Patient B was observed using several appropriate competing responses (*i.e.*, crossing his arms, sitting on his hands) in reaction to the urge to grab others. Patient B also reported feeling "a lot better," stating, "I don't really tic as much." He also reported that the duration of his tics had decreased, that he was less bothered by his tics, and that the tics were less noticeable to others in public. The parents confirmed his impressions. Patient B was also provided with additional suggestions on competing responses to use for the remaining tics. The treatment team reviewed the follow-up plan with parents, which included booster sessions.

At the one-month follow-up, the YGTSS revealed that treatment gains had been maintained, and Patient B demonstrated a reduction in tic number, frequency, and interference of both motor and vocal tics. By the six-month follow-up, Patient B was exhibiting a slight increase in the frequency of vocal tics and an increase in the complexity and interference of motor tics (see Table 2); however, Patient B admitted to not practicing the breathing and relaxation strategies. Therefore, booster sessions were scheduled to review IOP CBIT components.

Although Patient B's presentation at six months post-treatment revealed some regression (as seen in Table 2), the family expressed their appreciation for Patient B's progress and his ability to function better at home and at school. The family also stated that the tics had become "so subtle" that he was no longer concerned or upset by them.

## DISCUSSION

The current case series describes the implementation of an intensive outpatient behavioral treatment with two preadolescents who presented with Tourette syndrome. Despite their different presentations, both patients demonstrated treatment gains following the IOP CBIT intervention. The generalizability of the current case series is unknown at this time. However, IOP CBIT may be appropriate for individuals who present with moderate to severe tics, those who are experiencing clinically significant impairment in daily academic and social functioning, and for individuals and their families who desire to experience a quick reduction in motor and/or vocal tics. On the other hand, individuals who might not be good candidates for CBIT include those with oppositional and/or defiant behaviors, since adherence to the treatment protocol would likely prove to be a challenge. In addition, because it is important for individuals with Tourette's to receive adequate psychosocial support in monitoring and reducing their tics, those with chaotic or limited family and social support systems may find this protocol challenging.

It should be noted that many individuals with Tourette syndrome experience a waxing and waning of symptoms over time and that many tics resolve on their own<sup>[2,3]</sup>. Although CBIT is not a cure for Tourette syndrome, based on the current case series, individuals who follow the treatment protocol can expect to learn tools and skills to better manage their tics, understand their premonitory urges, reduce the negative impact of the tics on their lives, and experience improvement in their overall academic and social functioning<sup>[14]</sup>.

### Limitations and future directions

Despite addressing an important gap in the literature pertaining to the use of an intensive outpatient CBIT approach with children and adolescents, there are several limitations to the current case series that should be noted. First, an intensive treatment approach requires a time commitment from parents and patients that would likely require a parent to request time away from work and/or a child to be absent from school. This might present a financial challenge for some parents and possibly create academic stressors for some children. It also raises the question about the most convenient time to deliver an intensive outpatient intervention for children and adolescents. That is, Patient A received his treatment during a planned school break, while Patient B was seen during the summer. Clinicians should consider and discuss the time commitment it takes for families to participate in this type of intensive treatment approach.

Second, both patients received treatment at academic medical centers without individual fee-for-service costs as a part of psychology internship and postdoctoral training programs. It is possible that many families might find paying out-of-pocket for an intensive outpatient treatment to be a financial burden. Moreover, with the increased limitations placed on behavioral health services by managed



care organizations, insurance companies might be unable or unwilling to pay for an intensive outpatient program. Future research should examine the generalizability of a comprehensive behavioral intervention for TS in the community at large. Third, receiving treatment as part of a research study or through a military treatment facility would also facilitate access to services for this population. While members of the current treatment teams received training, consultation, and/or supervision from one of the leading researchers (ALP) in the field of TS, accessibility of behavioral health providers who are trained in CBIT might be more limited in other geographical areas. Both families reported feeling grateful that they had access to the current treatment teams. Agencies and educational institutions would greatly benefit the community by offering more training opportunities for behavioral health providers in the treatment of TS. The Tourette Syndrome Association has sponsored many CBIT training programs.

Finally, the intensive outpatient program implemented in the current treatment protocol might compromise the external validity of the intervention. Both patients received the intensive treatment at a much faster pace compared to traditional therapy, creating an artificial environment in which to practice the skills learned. This limited both patients' ability to practice the functional based interventions in their everyday environments at a more natural pace. Future research should continue to examine the generalizability and long-term benefits of IOP CBIT. Future research should also consider a single subject research design or an experimental research design to include a control group receiving traditional weekly CBIT with the experimental group receiving IOP CBIT over 3-4 d.

The current case series adds an important piece to the scientific literature on the behavioral treatment of Tourette syndrome and persistent tic disorders by demonstrating that Cognitive Behavioral Intervention for Tics employed as part of an intensive outpatient program can reduce tic severity. The use of an intensive outpatient program incorporating Comprehensive Behavioral Intervention for Tics appears to offer several benefits. First, the patients in this case study were able to make notable progress over the span of 1 wk *vs* 10 wk. Additionally, IOP CBIT allows patients to focus almost exclusively on developing and practicing their competing responses without the interference of work or school. IOP CBIT also expands the potential treatment catchment areas, which would make CBIT more accessible to a wider range of patients who would otherwise be limited by geography or expense. Importantly, an IOP CBIT has the potential to help compensate for the current lack of CBIT providers.

## COMMENTS

### Case characteristics

Both Patients A (10-year-old male) and B (14-year-old male) experienced multiple tics that were consistent with Tourette syndrome.

### Clinical diagnosis

Patients A and B both met diagnostic criteria for Tourette syndrome.

### Differential diagnosis

Patients A and B were both assessed for attention deficit hyperactive disorder and obsessive compulsive disorder.

### Treatment

Patients completed intensive outpatient Comprehensive Behavioral Interventions for Tics (CBIT).

### Related reports

Although previous studies support the use of CBIT, when delivered in eight weekly sessions, more research is needed to determine whether an intensive outpatient format can improve tic management in children with a persistent tic disorders; however, the treatment outcome of these two cases are promising.

### Experiences and lessons

This case series represents the first report of treatment outcomes following an intensive outpatient CBIT protocol for children. Although future research is required before more definitive conclusions can be reached, the findings of this case series suggest that Intensive Outpatient Program CBIT may reduce tic symptoms in children with Tourette syndrome.

### Peer review

This is a template for a valuable modification of CBIT for those who desire thorough management in a short period of time. This represents a promising approach that merits confirmation by other investigators in other settings.

## REFERENCES

- 1 **American Psychiatric Association.** Diagnostic and statistical manual of mental disorders, Fifth edition. Arlington, VA: American Psychiatric Association, 2013
- 2 **Jankovic J.** Tourette's syndrome. *N Engl J Med* 2001; **345**: 1184-1192 [PMID: 11642235 DOI: 10.1056/NEJMra010032]
- 3 **Leckman JF, Zhang H, Vitale A, Lahnin F, Lynch K, Bondi C, Kim YS, Peterson BS.** Course of tic severity in Tourette syndrome: the first two decades. *Pediatrics* 1998; **102**: 14-19 [PMID: 9651407 DOI: 10.1542/peds.102.1.14]
- 4 **Specht M, Woods D, Piacentini J, Scahill L, Wilhelm S, Peterson A, Walkup J.** Clinical characteristics of children and adolescents with a primary tic disorder. *J Dev Phys Disabil* 2011; **23**: 15-31 [DOI: 10.1007/s10882-010-9223-z]
- 5 **Bloch MH, Leckman JF.** Clinical course of Tourette syndrome. *J Psychosom Res* 2009; **67**: 497-501 [PMID: 19913654 DOI: 10.1016/j.jpsychores.2009.09.002]
- 6 **Rizzo R, Gulisano M, Cali PV, Curatolo P.** Long term clinical course of Tourette syndrome. *Brain Dev* 2012; **34**: 667-673 [PMID: 22178151 DOI: 10.1016/j.braindev.2011.11.006]
- 7 **Scahill L, Erenberg G, Berlin CM, Budman C, Coffey BJ, Jankovic J, Kiessling L, King RA, Kurlan R, Lang A, Mink J, Murphy T, Zinner S, Walkup J.** Contemporary assessment and pharmacotherapy of Tourette syndrome. *NeuroRx* 2006; **3**: 192-206 [PMID: 16554257 DOI: 10.1016/j.nurx.2006.01.009]
- 8 **Peterson AL, Azrin NH.** Behavioral and pharmacological treatments for Tourette syndrome: A review. *Appl Prev Psychol* 1993; **2**: 231-242 [DOI: 10.1016/S0962-1849(05)80093-9]
- 9 **Peterson AL, Campise RL, Azrin NH.** Behavioral and pharmacological treatments for tic and habit disorders: a review. *J Dev Behav Pediatr* 1994; **15**: 430-441 [PMID: 7884015 DOI: 10.1097/00004703-199412000-00007]
- 10 **Peterson AL.** Psychosocial management of tics and intentional repetitive behaviors associated with Tourette syndrome. In Woods DW, Piacentini JC, Walkup JT (Eds), *Treating Tourette syndrome and tic disorders: A guide for practitioners* (pp. 154-184). New York: Guilford Press, 2007
- 11 **Azrin NH, Nunn RG.** Habit reversal: A method of eliminating nervous habits and tics. *Behav Res Ther* 1973; **11**: 619-628 [DOI: 10.1016/0005-7967(73)90119-8]
- 12 **Verdellen C, van de Griendt J, Hartmann A, Murphy T.** European clinical guidelines for Tourette syndrome and other tic disorders. Part III: behavioural and psychosocial interven-

- tions. *Eur Child Adolesc Psychiatry* 2011; **20**: 197-207 [PMID: 21445725 DOI: 10.1007/s00787-011-0167-3]
- 13 **Woods DW**, Piacentini JC, Chang SW, Deckersbach T, Ginsburg GS, Peterson AL, Wilhelm S. Managing Tourette syndrome: A behavioral intervention for children and adults. Therapist guide. New York: Oxford University Press, 2008
  - 14 **Piacentini J**, Woods DW, Scahill L, Wilhelm S, Peterson AL, Chang S, Ginsburg GS, Deckersbach T, Dziura J, Levi-Pearl S, Walkup JT. Behavior therapy for children with Tourette disorder: a randomized controlled trial. *JAMA* 2010; **303**: 1929-1937 [PMID: 20483969 DOI: 10.1001/jama.2010.607]
  - 15 **Wilhelm S**, Peterson AL, Piacentini J, Woods DW, Deckersbach T, Sukhodolsky DG, Chang S, Liu H, Dziura J, Walkup JT, Scahill L. Randomized trial of behavior therapy for adults with Tourette syndrome. *Arch Gen Psychiatry* 2012; **69**: 795-803 [PMID: 22868933 DOI: 10.1001/archgenpsychiatry.]
  - 16 **Steeves T**, McKinlay BD, Gorman D, Billingshurst L, Day L, Carroll A, Dion Y, Doja A, Luscombe S, Sandor P, Pringsheim T. Canadian guidelines for the evidence-based treatment of tic disorders: behavioural therapy, deep brain stimulation, and transcranial magnetic stimulation. *Can J Psychiatry* 2012; **57**: 144-151 [PMID: 22398000]
  - 17 **Flancbaum M**, Rockmore L, Franklin ME. Intensive behavior therapy for tics: Implications for clinical practice and overcoming barriers to treatment. *J Dev Phys Disabil* 2011; **23**: 61-69 [DOI: 10.1007/s10882-010-9222-0]
  - 18 **Whiteside SP**, Brown AM, Abramowitz JS. Five-day intensive treatment for adolescent OCD: a case series. *J Anxiety Disord* 2008; **22**: 495-504 [PMID: 17543497 DOI: 10.1016/j.janxdis.2007.05.001]
  - 19 **Davis TE 3<sup>rd</sup>**, Ollendick TH, Ost LG. Intensive Treatment of Specific Phobias in Children and Adolescents. *Cogn Behav Pract* 2009; **16**: 294-303 [PMID: 20161063 DOI: 10.1016/j.cbpra.2008.12.008]
  - 20 **Leckman JF**, Riddle MA, Hardin MT, Ort SI, Swartz KL, Stevenson J, Cohen DJ. The Yale Global Tic Severity Scale: initial testing of a clinician-rated scale of tic severity. *J Am Acad Child Adolesc Psychiatry* 1989; **28**: 566-573 [PMID: 2768151 DOI: 10.1097/00004583-198907000-00015]
  - 21 **Guy W**, Bonato R. Manual for the ECDEU Assessment Battery (2nd ed.). Chevy Chase, MD: U.S. Department of Health, Education, and Welfare, National Institute of Mental Health, 1970
  - 22 **Caurin B**, Serrano M, Fernández-Alvarez E, Campistol J, Pérez-Dueñas B. Environmental circumstances influencing tic expression in children. *Eur J Paediatr Neurol* 2014; **18**: 157-162 [PMID: 24210363 DOI: 10.1016/j.ejpn.2013.10.002]
  - 23 **Storch EA**, Murphy TK, Geffken GR, Sajid M, Allen P, Roberti JW, Goodman WK. Reliability and validity of the Yale Global Tic Severity Scale. *Psychol Assess* 2005; **17**: 486-491 [PMID: 16393016 DOI: 10.1037/1040-3590.17.4.486.]
  - 24 **Kaufman J**, Birmaher B, Brent D, Rao U, Flynn C, Moreci P, Williamson D, Ryan N. Schedule for Affective Disorders and Schizophrenia for School-Age Children-Present and Lifetime Version (K-SADS-PL): initial reliability and validity data. *J Am Acad Child Adolesc Psychiatry* 1997; **36**: 980-988 [PMID: 9204677 DOI: 10.1097/00004583-199707000-00021]
  - 25 **American Psychiatric Association**. Diagnostic and statistical manual of mental disorders (4th ed., text rev.). Washington, DC: Author, 2000
  - 26 **Woods DW**, Piacentini J, Himle MB, Chang S. Premonitory Urge for Tics Scale (PUTS): initial psychometric results and examination of the premonitory urge phenomenon in youths with Tic disorders. *J Dev Behav Pediatr* 2005; **26**: 397-403 [PMID: 16344654 DOI: 10.1097/00004703-200512000-00001]
  - 27 **Goodman WK**, Price LH, Rasmussen SA, Mazure C, Fleischmann RL, Hill CL, Heninger GR, Charney DS. The Yale-Brown Obsessive Compulsive Scale. I. Development, use, and reliability. *Arch Gen Psychiatry* 1989; **46**: 1006-1011 [PMID: 2684084 DOI: 10.1001/archpsyc.1989.01810110048007]
  - 28 **Goodman WK**, Price LH, Rasmussen SA, Mazure C, Delgado P, Heninger GR, Charney DS. The Yale-Brown Obsessive Compulsive Scale. II. Validity. *Arch Gen Psychiatry* 1989; **46**: 1012-1016 [PMID: 2510699 DOI: 10.1001/archpsyc]
  - 29 **Scahill L**, Chappell PB, Kim YS, Schultz RT, Katsovich L, Shepherd E, Arnsten AF, Cohen DJ, Leckman JF. A placebo-controlled study of guanfacine in the treatment of children with tic disorders and attention deficit hyperactivity disorder. *Am J Psychiatry* 2001; **158**: 1067-1074 [PMID: 11431228 DOI: 10.1176/appi.ajp.158.7.1067]
  - 30 **Woods D**, Piacentini J, Chang S, Deckersbach T, Ginsburg GS, Peterson A, Wilhelm S. Managing Tourette Syndrome: A Behavioral Intervention. Parent Workbook. New York: Oxford University Press, 2008
  - 31 **Walkup JT**, Rosenberg LA, Brown J, Singer HS. The validity of instruments measuring tic severity in Tourette's syndrome. *J Am Acad Child Adolesc Psychiatry* 1992; **31**: 472-477 [PMID: 1592779 DOI: 10.1097/00004583-199205000-00013]

P- Reviewer: Brasic JR S- Editor: Wen LL

L- Editor: A E- Editor: Liu SQ



## Challenging rescue of a 4 years old boy with H1N1 infection by extracorporeal membrane oxygenator: A case report

Nestoras Papadopoulos, Sven Martens, Harald Keller, Ali El-Sayed Ahmad, Anton Moritz, Andreas Zierer

Nestoras Papadopoulos, Harald Keller, Ali El-Sayed Ahmad, Anton Moritz, Andreas Zierer, Division of Thoracic and Cardiovascular Surgery, Johann-Wolfgang-Goethe University, 60590 Frankfurt/Main, Germany

Sven Martens, Division of Thoracic and Cardiovascular Surgery, University Hospital Muenster, 48419 Muenster, Germany

**Author contributions:** Martens S performed the ECMO implantation; Keller H was the perfusionist; El-Sayed Ahmad A performed data analysis; Papadopoulos N, Moritz A and Zierer A were the major contributors in writing the manuscript; all authors read and approved the final manuscript.

**Correspondence to:** Nestoras Papadopoulos, MD, Division of Thoracic and Cardiovascular Surgery, Johann-Wolfgang-Goethe University, Theodor Stern Kai 7, 60590 Frankfurt/Main, Germany. [nestoras.papadopoulos@gmail.com](mailto:nestoras.papadopoulos@gmail.com)

Telephone: + 49-69-630183601 Fax: + 49-69-63017582

Received: April 4, 2014

Revised: June 23, 2014

Accepted: July 27, 2014

Published online: October 16, 2014

### Abstract

**Introduction:** World Health Organization announced on April 2009 a public health emergency of international concern caused by swine-origin influenza A (H1N1) virus. Acute respiratory distress syndrome (ARDS) has been reported to be the most devastating complications of this pathogen. Extracorporeal membrane oxygenator (ECMO) therapy for patients with H1N1 related ARDS has been described once all other therapeutic options have been exhausted. Here, we report the case of a child (German, male) with H1N1-associated fulminate respiratory and secondary hemodynamic deterioration who was rescued by initial emergent ECMO established through a dialysis catheter and subsequent switch to central cannulation following median sternotomy. This report highlights several important issues. First, it describes a successful use of a dialysis catheter for the establishment of a veno-venous ECMO in an emergency case by child. Second, it highlights the importance of a closely monitoring of clotting parameters during ECMO

therapy and third, if severe respiratory failure is complicated by cardiogenic shock, veno-atrial ECMO support *via* median sternotomy should be considered as a viable treatment option without further delay.

© 2014 Baishideng Publishing Group Inc. All rights reserved.

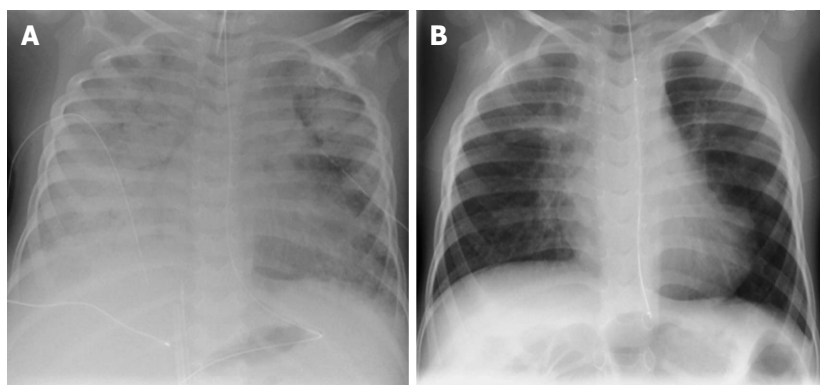
**Key words:** Airway; Circulatory temporary support; Coagulants; Extracorporeal membrane oxygenation; Infection

**Core tip:** Here, we report the case of a child with swine-origin influenza A-associated fulminate respiratory and secondary hemodynamic deterioration, who was rescued by initial emergent extracorporeal membrane oxygenator (ECMO) established through a dialysis catheter and subsequent switch to veno-atrial ECMO (VA-ECMO) *via* central cannulation. This report highlights several important issues. First, it describes a successful use of a dialysis catheter for the veno-venous ECMO-establishment in an emergency case by child. Second, it highlights the importance of a closely monitoring of clotting parameters and third, if severe respiratory failure is complicated by cardiogenic shock, VA-ECMO support *via* median sternotomy should be considered as a viable treatment option without further delay.

Papadopoulos N, Martens S, Keller H, El-Sayed Ahmad A, Moritz A, Zierer A. Challenging rescue of a 4 years old boy with H1N1 infection by extracorporeal membrane oxygenator: A case report. *World J Clin Cases* 2014; 2(10): 578-580 Available from: URL: <http://www.wjgnet.com/2307-8960/full/v2/i10/578.htm> DOI: <http://dx.doi.org/10.12998/wjcc.v2.i10.578>

### INTRODUCTION

Establishment of extracorporeal membrane oxygenation (ECMO) through percutaneous placement of cannulas in



**Figure 1 Anterior-posterior chest radiograph.** A: Postintubation anterior-posterior chest radiograph of a 4 years old boy before Extracorporeal membrane oxygenator (ECMO) support with acute respiratory distress syndrome caused by proven novel 2009 H1N1 influenza virus; B: Anterior-posterior chest radiograph of the same patients after successful veno-atrial ECMO weaning and successful decanulation.

children can be difficult because of the small vessel size<sup>[1]</sup>. Median sternotomy may be necessary in selected cases to cannulate the ascending aorta and right atrium for sufficient ECMO flow<sup>[1,2]</sup>.

## CASE REPORT

A 4 years old German boy presented in our emergency room with a 24 h history of shortness of breathe following several days of an influenza-like illness. At presentation, he suffered from respiratory failure requiring urgent intubation and mechanical ventilation. After his admission to our intensive care unit the initial chest radiograph revealed bilateral patchy infiltrates (Figure 1A). H1N1 influenza virus was confirmed by the reverse transcriptase-polymerase chain reaction assay of respiratory secretions. Bacterial cultures were negative. He was treated empirically with Oseltamivir. Within 24 h after hospital admission the patient had severely impaired gas exchange despite maximum respiratory support on the ventilator. For this reason high frequency oscillation ventilation (HFOV) was initiated. Since there was no improvement of the respiratory situation within 4 d of HFOV-treatment, venovenous ECMO (VV-ECMO) had to be established.

Because of the small vessel size of the child, safe cannulation sites for percutaneous placement of the ECMO cannulas were limited and included the internal jugular veins and the femoral veins. Placement of a cannula through the jugular vein was not successful. The child was in critical clinical condition and we decided to start VV-ECMO support *via* an 11 Fr dialysis catheter (Dolphin Protect, Gambo, Hechingen, Germany) placed into the left femoral vein. We established ECMO outflow of oxygenated blood *via* the arterial lumen and inflow of deoxygenated blood *via* the venous lumen of the dialysis catheter. We connected ECMO-tubes with the dialysis catheter *via* a connector (1/4 × LLm, Maquet GET-INGE GROUP, Hirrlingen, Germany). ECMO circuit consisted of a Quadrox id pediatric (Maquet Cardiovascular, Wayne, NJ, United States) polymethylpentene oxygenator and a Rotaflow (Maquet Cardiovascular) centrifugal pump. This setting allowed for a flow of 400-mil-

liliter per min. Despite the rather low circuit flow, the combination of VV-ECMO and HFOV allowed for an immediate improvement of oxygenation and weaning of vasopressor support.

Three days later, following an initial course of stabilization a sudden exchange of the VV-ECMO-system had to be performed due to massive clot-formations in the oxygenator. Notably there was an exponential elevation of fibrinogen and D-Dimer, as a result of disseminated intravascular coagulation (DIC), which could be detected from the establishment of the VV-ECMO support on until the system change. In order to avoid further clotting formations continuous application of heparin directly in the venous cannula of the new ECMO circuit has been established.

One day after the system change a sudden hemodynamic instability required high inotropic and vasopressor support. Therefore we decided to switch the VV-ECMO to veno-atrial ECMO (VA-ECMO). In order to reliably maintain adequate flow in this critical situation we performed a median sternotomy and established VA-ECMO support *via* the right atrial appendage and the ascending aorta. A Bio-Medicus (Medtronic, Inc., Minneapolis, MI, United States) arteria cannula was used as the return cannula for oxygenated blood. For venous drainage a multiport Bio-Medicus (Medtronic, Inc.) cannula was used. Circuit flow of 1.2 liters min<sup>-1</sup> led to a stabilization of the hemodynamic situation with immediate weaning from the vasopressor and inotropic support.

VA-ECMO was provided for a total of 10 d and could afterwards be successfully explanted. The patient could be successfully decannulated and control chest radiograph showed normal lung morphology (Figure 1B). The 4-year-old boy could be discharged from the hospital after a total of 38 d with full resolution of symptoms.

## DISCUSSION

This report highlights several important issues. First, it describes a successful use of a dialysis catheter for the establishment of a VV-ECMO in an emergency case, in which, due to the small vessel size of the child, the



percutaneous placement of routine ECMO cannulas was not possible. Second, as clotting formations in the ECMO-oxygenator is a possible and devastating complication especially in critically ill patients with H1N1 infection suffering a DIC, it is vital that clotting parameters, especially fibrinogen and D-Dimer, of such patients are closely monitored. Third, if severe respiratory failure is complicated by cardiogenic shock, VA-ECMO support *via* median sternotomy should be considered as a viable treatment option without further delay<sup>[3-9]</sup>.

## COMMENTS

### Case characteristics

The 4 years old patient presented in the emergency room with the main symptom of dyspnoea.

### Clinical diagnosis

Clinical diagnosis of acute respiratory failure leads to an urgent intubation and mechanical ventilation of the young boy.

### Differential diagnosis

Bacterial infection could be excluded once the bacterial cultures were negative.

### Laboratory diagnosis

Swine-origin influenza A (H1N1) influenza virus was confirmed by the reverse transcriptase-polymerase chain reaction assay of respiratory secretions.

### Imaging diagnosis

After his admission to the authors intensive care unit the initial chest radiograph revealed bilateral patchy infiltrates.

### Pathological diagnosis

Within 24 h after hospital admission the patient had severely impaired gas exchange despite maximum respiratory support on the ventilator.

### Treatment

For this reason high frequency oscillation ventilation (HFOV) was initiated. Due to the fulminate respiratory and secondary hemodynamic deterioration, initial emergent veno-venous extracorporeal membrane oxygenator (VV-ECMO) (extracorporeal membrane oxygenator) established through a dialysis catheter and subsequent switches to veno-atrial ECMO (VA-ECMO) through central cannulation following median sternotomy, has to be performed.

### Term explanation

ECMO therapy for patients with H1N1 related acute respiratory distress syndrome (ARDS) has been described once all other therapeutic options have been exhausted. This report highlights several important issues. First, it describes a successful use of a dialysis catheter for the establishment of a VV-ECMO in an emergency case by child. Second, it highlights the importance of a closely monitoring of clotting parameters during ECMO therapy and third, if severe respiratory failure is complicated by cardiogenic shock, VA-ECMO sup-

port *via* median sternotomy should be considered as a viable treatment option without further delay.

### Peer review

This manuscript lights on the problem of the ECMO cannulation in emergency and in the pediatric patient, and indicate as a solution the use of the dialysis catheter instead of the double lumen pediatric ECMO's cannula.

## REFERENCES

- 1 **Shuhaiber J**, Thiagarajan RR, Laussen PC, Fynn-Thompson F, del Nido P, Pigula F. Survival of children requiring repeat extracorporeal membrane oxygenation after congenital heart surgery. *Ann Thorac Surg* 2011; **91**: 1949-1955 [PMID: 21514563 DOI: 10.1016/j.athoracsur.2011.01.078]
- 2 **Alsoufi B**, Al-Radi OO, Gruenwald C, Lean L, Williams WG, McCrindle BW, Caldarone CA, Van Arsdel GS. Extracorporeal life support following cardiac surgery in children: analysis of risk factors and survival in a single institution. *Eur J Cardiothorac Surg* 2009; **35**: 1004-1011; discussion 1011 [PMID: 19356943 DOI: 10.1016/j.ejcts.2009.02.015]
- 3 New influenza A (H1N1) virus: global epidemiological situation, June 2009. *Wkly Epidemiol Rec* 2009; **84**: 249-257 [PMID: 19537358]
- 4 **Novel influenza A(H1N1) investigation team**. Description of the early stage of pandemic (H1N1) 2009 in Germany, 27 April-16 June 2009. *Euro Surveill* 2009; **14**: pii: 19295 [PMID: 19660249]
- 5 **Poggensee G**, Gilsdorf A, Buda S, Eckmanns T, Claus H, Altmann D, Krause G, Haas W. The first wave of pandemic influenza (H1N1) 2009 in Germany: from initiation to acceleration. *BMC Infect Dis* 2010; **10**: 155 [PMID: 20525408 DOI: 10.1186/1471-2334-10-155]
- 6 **Sihler KC**, Park PK. Extracorporeal membrane oxygenation in the context of the 2009 H1N1 influenza A pandemic. *Surg Infect (Larchmt)* 2011; **12**: 151-158 [PMID: 21545282 DOI: 10.1089/sur.2010.082]
- 7 **Papadopoulos N**, Ahmad Ael-S, Marinos S, Moritz A, Zierer A. Extracorporeal membrane oxygenation for influenza-associated acute respiratory distress syndrome. *Thorac Cardiovasc Surg* 2013; **61**: 516-521 [PMID: 23225509 DOI: 10.1055/s-0032-1330923]
- 8 **Extracorporeal Life Support Organization (ELSO)**. H1N1 Specific Supplements to the ELSO General Guidelines (Extracorporeal Life Support Organization). 2009: 1-4
- 9 **Riscili BP**, Anderson TB, Prescott HC, Exline MC, Sopirala MM, Phillips GS, Ali NA. An assessment of H1N1 influenza-associated acute respiratory distress syndrome severity after adjustment for treatment characteristics. *PLoS One* 2011; **6**: e18166 [PMID: 21464952 DOI: 10.1371/journal.pone.0018166]

P- Reviewer: Belliato M, Guo YZ, Pocar M S- Editor: Ji FF

L- Editor: A E- Editor: Liu SQ



## Left ventricular pseudoaneurysm formation: Two cases and review of the literature

Emmanouil Petrou, Vasiliki Vartela, Anna Kostopoulou, Panagiota Georgiadou, Irene Mastorakou, Nektarios Kogerakis, Petros Sfyraakis, George Athanassopoulos, George Karatasakis

Emmanouil Petrou, Vasiliki Vartela, Anna Kostopoulou, Panagiota Georgiadou, George Athanassopoulos, George Karatasakis, Division of Cardiology, Onassis Cardiac Surgery Center, GR-17674 Athens, Greece

Irene Mastorakou, Imaging Department, Onassis Cardiac Surgery Center, GR-17674 Athens, Greece

Nektarios Kogerakis, Petros Sfyraakis, Third Department of Cardiac Surgery and Transplantation Services, Onassis Cardiac Surgery Center, GR-17674 Athens, Greece

Author contributions: Petrou E and Vartela V designed and wrote the paper; Kostopoulou A designed the paper; Georgiadou P collected the patients' clinical data; Mastorakou I performed and assessed the computed tomography images; Kogerakis N and Sfyraakis P operated the one of the two patients described; Athanassopoulos G and Karatasakis G first diagnosed the nosological entity described and drafted the manuscript and revised it critically for important intellectual content.

Correspondence to: Emmanouil Petrou, MD, Division of Cardiology, Onassis Cardiac Surgery Center, 356 Sygrou Ave., Kallithea, GR-17674 Athens, Greece. [emmgpetrou@hotmail.com](mailto:emmgpetrou@hotmail.com)  
Telephone: +30-21-09493000 Fax: +30-21-02751028

Received: April 17, 2014 Revised: June 21, 2014

Accepted: July 25, 2014

Published online: October 16, 2014

and subsequent pseudoaneurysm formation. In parallel, we review the aforementioned condition.

© 2014 Baishideng Publishing Group Inc. All rights reserved.

**Key words:** Pseudoaneurysm; Left ventricle rupture; Myocardial infarction

**Core tip:** Ventricular wall rupture (LVWR) comprises a complication of acute myocardial infarction. Acute LVWR is a fatal condition, unless the formation of a pseudoaneurysm occurs.

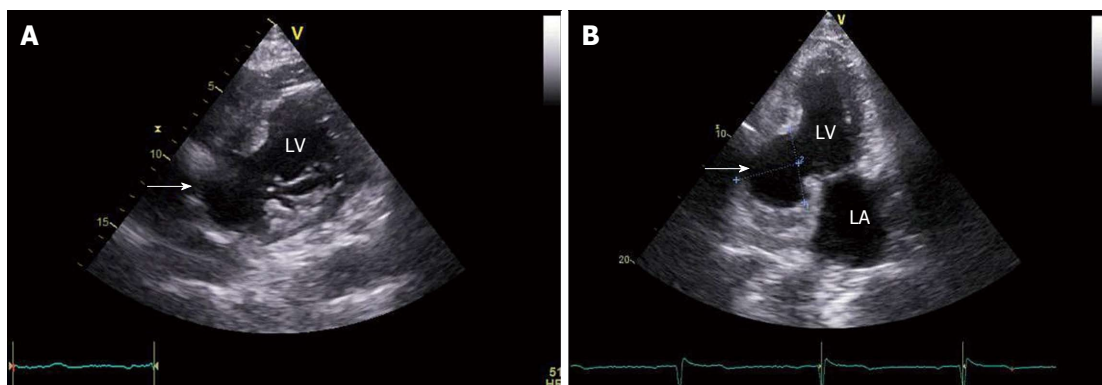
Petrou E, Vartela V, Kostopoulou A, Georgiadou P, Mastorakou I, Kogerakis N, Sfyraakis P, Athanassopoulos G, Karatasakis G. Left ventricular pseudoaneurysm formation: Two cases and review of the literature. *World J Clin Cases* 2014; 2(10): 581-586 Available from: URL: <http://www.wjgnet.com/2307-8960/full/v2/i10/581.htm> DOI: <http://dx.doi.org/10.12998/wjcc.v2.i10.581>

### Abstract

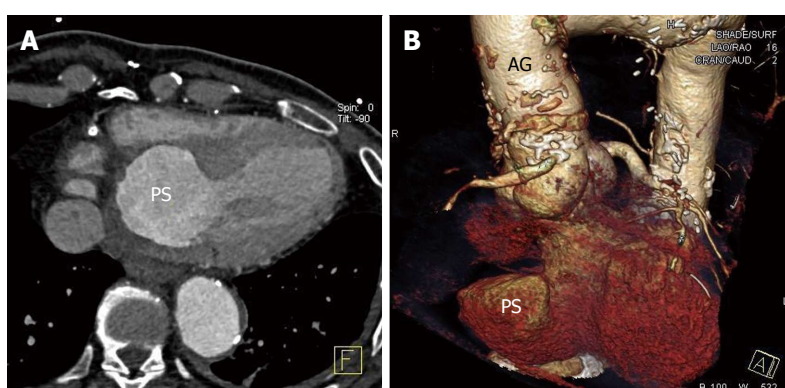
Left ventricular wall rupture (LVWR) comprises a complication of acute myocardial infarction (AMI). Acute LVWR is a fatal condition, unless the formation of a pseudoaneurysm occurs. Several risk factors have been described, predisposing to LVWR. High index of suspicion and imaging techniques, namely echocardiography and computed tomography, are the cornerstones of timely diagnosis of the condition. As LVWR usually leads to death, emergency surgery is the treatment of choice, resulting in significant reduction in mortality and providing favorable short-term outcomes and adequate prognosis during late follow-up. Herein, we present two patients who were diagnosed with LVWR following AMI,

### INTRODUCTION

Cardiac rupture as a pathophysiological entity was first described by Harvey<sup>[1]</sup> in 1647. It is a complication of acute myocardial infarction (AMI) with an overall incidence of 6.2%<sup>[2,3]</sup>. It represents the second cause of death after cardiogenic shock, and accounts for as much as 15% of in-hospital mortality<sup>[4-6]</sup>. Rupture may involve any cardiac structure, *i.e.*, atria, ventricles, interatrial or interventricular septum, papillary muscles or chordae tendineae, or one of the heart valves. Left ventricular wall rupture (LVWR) occurs up to 10 times more frequently than septal rupture, affecting up to 11% of patients after AMI and is almost invariably fatal, with death occurring within minutes after the development of chest pain<sup>[6]</sup>. In contrast, subacute LVWR and containment by false aneu-



**Figure 1** Echocardiography: Parasternal short axis and 2-Chamber view of the left ventricle posterior wall pseudoaneurysm (A and B, arrows). LA: Left atrium; LV: Left ventricle.



**Figure 2** Cardiac computed tomographic angiography (A) and volume rendering (B): Left ventricle posterior wall pseudoaneurysm. PS: Pseudoaneurysm; AG: Aortic graft.

rysm formation of the pericardial layers may lead to patient's survival for hours or even days, but rarely weeks<sup>[7-9]</sup>.

## CASE REPORT

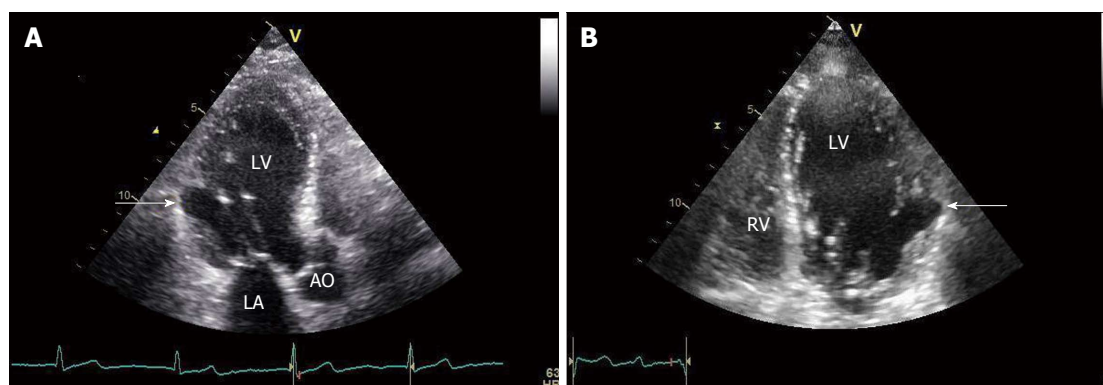
### Case 1

A 62-year-old man was referred for echocardiographic evaluation. Two weeks ago, he had been admitted to another hospital for a non-ST segment elevation myocardial infarction for which he had undergone coronary arteriography. Coronary angiography revealed a 60% occlusion of the left anterior descending artery (LAD), a totally occluded right coronary artery (RCA), and a totally occluded left internal mammary artery (LIMA) graft to the LAD. The patient's history included coronary artery bypass grafting operation, with a LIMA graft to the LAD, and an ascending aorta replacement with an aortic graft (Hemashield straight tube, Boston Scientific) due to aneurysm, twelve years earlier. Moreover, nine years ago, he had undergone percutaneous coronary angioplasty and had received a drug-eluting stent to the RCA. Echocardiography revealed rupture of the left ventricular posterior wall which was contained by pericardium, thus forming a sizeable pseudoaneurysm (Figure 1). There was no significant pericardial effusion and the overall systolic function of both ventricles was found within normal lim-

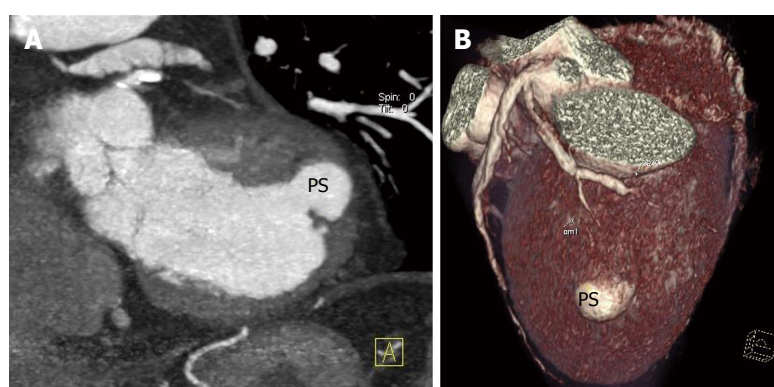
its. Based on the echocardiographic diagnosis the patient was admitted to our hospital for further investigation and treatment. The patient's admission 12-lead surface electrocardiogram (ECG) showed ischemic changes in the inferior leads (II, III, aVF). Cardiac computed tomographic angiography (Figure 2A) and volume rendering technique (Figure 2B) confirmed the presence of a pseudoaneurysm, with 50 mm × 50 mm dimensions, at the posterior wall of the left ventricle. The patient was referred to Surgery and a surgical repair of the defect with application of a Dacron patch with continuous suture was performed. Repeat echocardiography demonstrated a well-placed patch at the site of the rupture, enforcing the walls of the pseudoaneurysm. The patient had an uneventful postoperative recovery and was discharged on day 6 with explicit instructions and medication.

### Case 2

An 86-year-old man presented with exertional dyspnea of five months duration. He had a history consistent with chronic atrial fibrillation under acenocoumarol and atenolol, and dyslipidemia under simvastatin. He had no history of documented coronary artery disease the 12-lead ECG showed Q waves in leads III and aVF. He was hemodynamically stable with normal vital signs. The echocardiographic study demonstrated a pseudoaneu-



**Figure 3** Echocardiography: Modified 4- and 3-Chamber view of the left ventricle lateral wall pseudoaneurysm (A and B, arrows). RV: Right ventricle; LA: Left atrium; AO: Ascending aorta; LV: Left ventricle.



**Figure 4** Cardiac computed tomographic angiography and volume rendering: Left ventricle lateral wall pseudoaneurysm (A and B). PS: Pseudoaneurysm.

rysm at the akinetic basal inferior lateral wall of the left ventricle, close to the base of the anterolateral papillary muscle (Figure 3). The overall function of the left ventricle was preserved. Cardiac computed tomographic angiography and volume rendering technique revealed significant atherosclerosis and coronary arteries narrowing. The echocardiographic findings were confirmed; a circular opacified 19 mm × 16 mm protrusion originating from the lateral wall of the left ventricle was observed (Figure 4). The patient's clinical condition and echocardiographic findings remained stable over his 3 years follow-up.

## DISCUSSION

### *Time of occurrence and factors related to LVWR in AMI*

The traditional risk factors for LVWR include older age (> 60 years), female sex, first lateral or anterior wall AMI, severe one-vessel coronary artery disease with lack of collateral circulation, and absence of previous angina<sup>[4,10,11]</sup>. On the contrary, the presence of multivessel disease may exert a protective effect, probably linked to development of greater collateral circulation<sup>[12]</sup>. Furthermore, it has been reported that the majority of patients with LVWR had suffered ST segment elevation AMI, with positive cardiac biomarkers, and a higher heart rate, lower blood pressure, and higher GRACE risk score at admission than patients without LVWR<sup>[13-15]</sup>. Chronic hypertension and

diabetes mellitus do not seem to modify the incidence of LVWR<sup>[16]</sup>, and contrary to a previous report<sup>[17]</sup>, steroid use and late thrombolysis do not appear to increase the risk of LVWR<sup>[18,19]</sup>. Concerning thrombolysis, three mechanisms have been proposed as been responsible for occurrence of LVWR: hemorrhage to the ischemic zone resulting in loss of muscular tissue strength<sup>[20,21]</sup>, increased collagen degradation and synthesis restrain by thrombolytic agents<sup>[22]</sup>, lymphocytic migration to the infarct zone initiating absorption of collagen and proteolysis<sup>[21]</sup>. Depending on the time of its occurrence, LVWR may be classified as early, when it develops within the first 48 h post-AMI, or late, when it occurs beyond 48 h post-AMI. The early form represents 40%-50% of cases<sup>[23]</sup>, however it is generally accepted that the true proportion is likely to be higher when including patients who die suddenly from LVWR before reaching hospital<sup>[24]</sup>.

### *Differentiating true aneurysm from pseudoaneurysm*

Rarely, LVWR is contained by an adherent pericardium, creating a pseudoaneurysm. Differentiation between left ventricular aneurysm and pseudoaneurysm is difficult, yet it is the most important task to carry out in order to facilitate therapeutic decision making. Pericardial friction rub, decreased heart sounds, sinus bradycardia or junctional rhythm, are all signs of pseudoaneurysm<sup>[25]</sup>. However, chest pain, dyspnea and hypotension, as well as persistent



ST segment elevation in the area of AMI on the surface ECG, are common for both true aneurysm and pseudoaneurysm<sup>[26]</sup>. Thus, distinguishing between these two entities is very difficult merely on a clinical basis, because many characteristics are common. Especially concerning electrocardiographic predictors of LVWR and aneurysm or pseudoaneurysm formation, a deviation of the ST segment or T wave, or both, from the usual evolutionary pattern after AMI has been observed<sup>[27]</sup>. Furthermore, differing opinions exist concerning the most common site of LVWR. Some reports indicate the anterior wall as the most frequent site of aneurysm and pseudoaneurysm formation, where areas more recent series have observed a predominance of lateral and posterior wall ruptures<sup>[27]</sup>.

### Imaging modalities in the diagnosis of LVWR in AMI

The most available and sensitive diagnostic tool to establish the different types of cardiac rupture is echocardiography<sup>[28]</sup>. In patients with LVWR the most frequent echocardiographic finding is pericardial effusion; in fact, the absence of pericardial effusion has a high negative predictive value and excludes cardiac rupture in patients with AMI<sup>[29]</sup>. However, in our cases no pericardial effusion was found. The presence of pericardial effusion has a low positive predictive value for LVWR as it may be present in 28% of patients with AMI without cardiac rupture<sup>[30]</sup>. The absence of pericardial effusion in our patients could be due to the lack of rupture of the left ventricular wall. The presence of echogenic masses in the effusion fluid is a relevant sign, particularly in patients with subacute LVWR, since these signs may be found in fibrinous pericarditis associated with AMI<sup>[31]</sup>. Direct visualization of the myocardial tear, true aneurysm or pseudoaneurysm is diagnostic, however, it is possible in only one third of LVWR cases<sup>[32]</sup>. Recently, cardiac magnetic resonance (CMR) imaging, especially with contrast enhancement, has emerged as a valuable diagnostic tool providing visualization of the entire heart, and clear differentiation of structures such as the pericardium, myocardium, thrombus and epicardial fat<sup>[33]</sup>, as well as the pathological scar tissue substrates for life-threatening ventricular arrhythmias in AMI patients<sup>[34]</sup>. CMR can provide morphological definition of LVWR and pseudoaneurysm location, extension and relation to adjacent structures. Furthermore, CMR has an enormous value in differentiating between left ventricular aneurysms and pseudoaneurysms, in stable patients, with the ability to obtain cross sectional views in any plane<sup>[35]</sup>.

We presented two patients who survived LVWR following an AMI. The patients' survival was clearly due to the containment of the rupture by the pericardial sac and the formation of the pseudoaneurysm. As LVWR usually leads to death, emergency surgery is the treatment of choice regardless the patient's condition. Surgical repair, enforcing the pericardial layers at the ventricular locus resistens minoris, results in significant reduction in mortality and provides favorable short-term outcomes and adequate prognosis during late follow-up<sup>[36]</sup>. Interest-

ingly, our second patient survives for 3 years after diagnosis without surgery. Early diagnosis of LVWR is based on clinical suspicion. Echocardiography is of paramount importance, while computed tomography and CMR can be used to confirm diagnosis in stable patients.

## COMMENTS

### Case characteristics

Two patients who were diagnosed with left ventricular wall rupture (LVWR) following acute myocardial infarction (AMI), and subsequent pseudoaneurysm formation.

### Clinical diagnosis

Variable clinical presentation, ranging from asymptomatic forms of the condition to more typical angina pectoris or dyspnea.

### Differential diagnosis

Cardiac ischemia, pulmonary disease and heart failure are the main differential diagnoses.

### Laboratory diagnosis

There are no specific laboratory findings in the condition described. However, negative cardiac enzymes could exclude novel myocardial infarction.

### Imaging diagnosis

Echocardiography is the most useful and available imaging method in the diagnosis of left ventricular aneurysm and pseudoaneurysm formation. Computed tomography and cardiac magnetic resonance are complementary modalities, however of paramount importance in differentiating between the two aforementioned entities.

### Treatment

Surgery is the treatment of choice for post-myocardial infarction left ventricular pseudoaneurysms.

### Related reports

Left ventricular rupture and pseudoaneurysm formation have been described in the literature. However, long-term follow-up in an untreated patient (the authors' second case) is quite rare.

### Term explanation

LVWR following an AMI and containment by false aneurysm formation of the pericardial layers may lead to patient's survival for hours or even days, but rarely weeks.

### Experience and lessons

LVWR may be a rare condition in the era of primary percutaneous interventions, however it should always be a consideration in post-myocardial infarction patients.

### Peer review

This is an interesting manuscript.

## REFERENCES

- 1 **Harvey W.** Cited by Morgagni JB: The Seats and Causes of Disease (translated by B. Alexander). London, Millar A, Cadell T, 1769; letter 27, vol 1 (book 2): 830
- 2 **Becker RC,** Gore JM, Lambrew C, Weaver WD, Rubison RM, French WJ, Tiefenbrunn AJ, Bowlby LJ, Rogers WJ. A composite view of cardiac rupture in the United States National Registry of Myocardial Infarction. *J Am Coll Cardiol* 1996; **27**: 1321-1326 [PMID: 8626938 DOI: 10.1016/0735-1097(96)00008-3]
- 3 **Blinc A,** Noc M, Pohar B, Cernic N, Horvat M. Subacute rupture of the left ventricular free wall after acute myocardial infarction. Three cases of long-term survival without emergency surgical repair. *Chest* 1996; **109**: 565-567 [PMID: 8620740 DOI: 10.1378/chest.109.2.565]
- 4 **Sobkowicz B,** Lenartowska L, Nowak M, Hirnle T, Borys D, Kosicki M, Prajs P, Wrabec K. Trends in the incidence of the free wall cardiac rupture in acute myocardial infarction. observational study: experience of a single center. *Rocz Akad Med Białymst* 2005; **50**: 161-165 [PMID: 16358958]

- 5 **Purcaro A**, Costantini C, Ciampani N, Mazzanti M, Silenzi C, Gili A, Belardinelli R, Astolfi D. Diagnostic criteria and management of subacute ventricular free wall rupture complicating acute myocardial infarction. *Am J Cardiol* 1997; **80**: 397-405 [PMID: 9285648 DOI: 10.1016/S0002-9149(97)00385-8]
- 6 **Reddy SG**, Roberts WC. Frequency of rupture of the left ventricular free wall or ventricular septum among necropsy cases of fatal acute myocardial infarction since introduction of coronary care units. *Am J Cardiol* 1989; **63**: 906-911 [PMID: 2929464 DOI: 10.1016/0002-9149(89)90137-9]
- 7 **Shirani J**, Berezowski K, Roberts WC. Out-of-hospital sudden death from left ventricular free wall rupture during acute myocardial infarction as the first and only manifestation of atherosclerotic coronary artery disease. *Am J Cardiol* 1994; **73**: 88-92 [PMID: 8279385 DOI: 10.1016/0002-9149(94)90733-1]
- 8 **O'Rourke MF**. Subacute heart rupture following myocardial infarction. Clinical features of a correctable condition. *Lancet* 1973; **2**: 124-126 [PMID: 4124045 DOI: 10.1016/S0140-6736(73)93065-1]
- 9 **Pollak H**, Diez W, Spiel R, Enenkel W, Mlczoch J. Early diagnosis of subacute free wall rupture complicating acute myocardial infarction. *Eur Heart J* 1993; **14**: 640-648 [PMID: 8508857 DOI: 10.1093/eurheartj/14.5.640]
- 10 **Lateef F**, Nimbkar N. Ventricular free wall rupture after myocardial infarction. *Hong Kong J Emerg Med* 2003; **10**: 238-246
- 11 **López-Sendón J**, Gurfinkel EP, Lopez de Sa E, Agnelli G, Gore JM, Steg PG, Eagle KA, Cantador JR, Fitzgerald G, Granger CB. Factors related to heart rupture in acute coronary syndromes in the Global Registry of Acute Coronary Events. *Eur Heart J* 2010; **31**: 1449-1456 [PMID: 20231153 DOI: 10.1093/eurheartj/ehq061]
- 12 **Slater J**, Brown RJ, Antonelli TA, Menon V, Boland J, Col J, Dzavik V, Greenberg M, Menegus M, Connery C, Hochman JS. Cardiogenic shock due to cardiac free-wall rupture or tamponade after acute myocardial infarction: a report from the SHOCK Trial Registry. Should we emergently revascularize occluded coronaries for cardiogenic shock? *J Am Coll Cardiol* 2000; **36**: 1117-1122 [PMID: 10985714 DOI: 10.1016/S0735-1097(00)00845-7]
- 13 **Figueras J**, Alcalde O, Barrabés JA, Serra V, Alguersuari J, Cortadellas J, Lidón RM. Changes in hospital mortality rates in 425 patients with acute ST-elevation myocardial infarction and cardiac rupture over a 30-year period. *Circulation* 2008; **118**: 2783-2789 [PMID: 19064683 DOI: 10.1161/CIRCULATIONAHA.108.776690]
- 14 **Nakatani D**, Sato H, Kinjo K, Mizuno H, Hishida E, Hirayama A, Mishima M, Ito H, Matsumura Y, Hori M. Effect of successful late reperfusion by primary coronary angioplasty on mechanical complications of acute myocardial infarction. *Am J Cardiol* 2003; **92**: 785-788 [PMID: 14516876 DOI: 10.1016/S0002-9149(03)00883-X]
- 15 **Yamaguchi J**, Kawaguchi M, Kawana M, Asano R, Sumiyoshi T, Kasanuki H. [Risk factors and effect of reperfusion therapy on left ventricular free wall rupture following acute myocardial infarction]. *J Cardiol* 2000; **35**: 257-265 [PMID: 10791269]
- 16 **Melchior T**, Hildebrandt P, Køber L, Jensen G, Torp-Pedersen C. Do diabetes mellitus and systemic hypertension predispose to left ventricular free wall rupture in acute myocardial infarction? *Am J Cardiol* 1997; **80**: 1224-1225 [PMID: 9359558 DOI: 10.1016/S0002-9149(97)00646-2]
- 17 **Nakano T**, Konishi T, Takezawa H. Potential prevention of myocardial rupture resulting from acute myocardial infarction. *Clin Cardiol* 1985; **8**: 199-204 [PMID: 3987108 DOI: 10.1002/clc.4960080403]
- 18 **Silverman HS**, Pfeifer MP. Relation between use of anti-inflammatory agents and left ventricular free wall rupture during acute myocardial infarction. *Am J Cardiol* 1987; **59**: 363-364 [PMID: 3812291 DOI: 10.1016/0002-9149(87)90817-4]
- 19 **Honan MB**, Harrell FE, Reimer KA, Califf RM, Mark DB, Pryor DB, Hlatky MA. Cardiac rupture, mortality and the timing of thrombolytic therapy: a meta-analysis. *J Am Coll Cardiol* 1990; **16**: 359-367 [PMID: 2142705 DOI: 10.1016/0735-1097(90)90586-E]
- 20 **Becker RC**, Charlesworth A, Wilcox RG, Hampton J, Skene A, Gore JM, Topol EJ. Cardiac rupture associated with thrombolytic therapy: impact of time to treatment in the Late Assessment of Thrombolytic Efficacy (LATE) study. *J Am Coll Cardiol* 1995; **25**: 1063-1068 [PMID: 7897117 DOI: 10.1016/0735-1097(94)00524-T]
- 21 **Kawano H**, Miyauchi K, Okada R, Daida H, Yokoi H, Miyano H, Takaya J, Satoh H, Yamaguchi H, Suda K. Histopathological study of cardiac rupture following myocardial infarction with and without thrombolytic therapy. *J Cardiol* 1994; **24**: 249-255 [PMID: 8057236]
- 22 **Peuhkurinen K**, Risteli L, Jounela A, Risteli J. Changes in interstitial collagen metabolism during acute myocardial infarction treated with streptokinase or tissue plasminogen activator. *Am Heart J* 1996; **131**: 7-13 [PMID: 8554022 DOI: 10.1016/S0002-8703(96)90044-7]
- 23 **Dellborg M**, Held P, Swedberg K, Vedin A. Rupture of the myocardium. Occurrence and risk factors. *Br Heart J* 1985; **54**: 11-16 [PMID: 4015910 DOI: 10.1136/hrt.54.1.11]
- 24 **Batts KP**, Ackermann DM, Edwards WD. Postinfarction rupture of the left ventricular free wall: clinicopathologic correlates in 100 consecutive autopsy cases. *Hum Pathol* 1990; **21**: 530-535 [PMID: 2338333 DOI: 10.1016/0046-8177(90)90010-3]
- 25 **Balakumaran K**, Verbaan CJ, Essed CE, Nauta J, Bos E, Haalebos MM, Penn O, Simoons ML, Hugenoltz PG. Ventricular free wall rupture: sudden, subacute, slow, sealed and stabilized varieties. *Eur Heart J* 1984; **5**: 282-288 [PMID: 6734637]
- 26 **Zoffoli G**, Mangino D, Venturini A, Terrini A, Asta A, Zanchettin C, Polesel E. Diagnosing left ventricular aneurysm from pseudo-aneurysm: a case report and a review in literature. *J Cardiothorac Surg* 2009; **4**: 11 [PMID: 19239694 DOI: 10.1186/1749-8090-4-11]
- 27 **Oliva PB**, Hammill SC, Edwards WD. Cardiac rupture, a clinically predictable complication of acute myocardial infarction: report of 70 cases with clinicopathologic correlations. *J Am Coll Cardiol* 1993; **22**: 720-726 [PMID: 8354804 DOI: 10.1016/0735-1097(93)90182-Z]
- 28 **Sutherland FW**, Guell FJ, Pathi VL, Naik SK. Postinfarction ventricular free wall rupture: strategies for diagnosis and treatment. *Ann Thorac Surg* 1996; **61**: 1281-1285 [PMID: 8607710 DOI: 10.1016/0003-4975(95)01160-9]
- 29 **López-Sendón J**, González A, López de Sá E, Coma-Canella I, Roldán I, Domínguez F, Maqueda I, Martín Jadraque L. Diagnosis of subacute ventricular wall rupture after acute myocardial infarction: sensitivity and specificity of clinical, hemodynamic and echocardiographic criteria. *J Am Coll Cardiol* 1992; **19**: 1145-1153 [PMID: 1564213 DOI: 10.1016/0735-1097(92)90315-E]
- 30 **Galve E**, Garcia-Del-Castillo H, Evangelista A, Battlle J, Permanyer-Miralda G, Soler-Soler J. Pericardial effusion in the course of myocardial infarction: incidence, natural history, and clinical relevance. *Circulation* 1986; **73**: 294-299 [PMID: 3943164 DOI: 10.1161/01.CIR.73.2.294]
- 31 **Carey JS**, Cukingnan RA, Eugene J. Myocardial rupture in expanded infarcts: repair using pericardial patch. *Clin Cardiol* 1989; **12**: 157-160 [PMID: 2647328 DOI: 10.1002/clc.4960120309]
- 32 **Figueras J**, Cortadellas J, Evangelista A, Soler-Soler J. Medical management of selected patients with left ventricular free wall rupture during acute myocardial infarction. *J Am Coll Cardiol* 1997; **29**: 512-518 [PMID: 9060886 DOI: 10.1016/S0735-1097(96)00542-6]
- 33 **Mavrogeni S**, Rademakers F, Cokkinos DV. Clinical application of cardiovascular magnetic resonance. *Hellenic J Cardiol*

- 2004; **45**: 401-405
- 34 **Mavrogeni S**, Petrou E, Kolovou G, Theodorakis G, Iliodromitis E. Prediction of ventricular arrhythmias using cardiovascular magnetic resonance. *Eur Heart J Cardiovasc Imaging* 2013; **14**: 518-525 [PMID: 23324829 DOI: 10.1093/ehjci/jes302]
- 35 **Alapati L**, Chitwood WR, Cahill J, Mehra S, Movahed A. Left ventricular pseudoaneurysm: A case report and review of the literature. *World J Clin Cases* 2014; **2**: 90-93 [PMID: 24749118 DOI: 10.12998/wjcc.v2.i4.90]
- 36 **Solis C**, Pujol D, Mauro V. Left ventricular free wall rupture after acute myocardial infarction. *Rev Argent Cardiol* 2009; **77**: 395-404

**P- Reviewer:** Gao XM, Palmucci S, Schoenhagen P

**S- Editor:** Ji FF **L- Editor:** A **E- Editor:** Liu SQ



## Importance of defining the best treatment of a genital gunshot wound: A case report

Herney Andrés García-Perdomo

Herney Andrés García-Perdomo, School of Medicine, Faculty of Health, University of Valle, 25360 Cali, Colombia

Author contributions: García-Perdomo HA contributed to this paper.

Correspondence to: Herney Andrés García-Perdomo, MD, MSc, EdDc, PhDc, Professor, School of Medicine, Faculty of Health, University of Valle, Cll 4B #36-00, 25360 Cali, Colombia. [herney.garcia@correounivalle.edu.co](mailto:herney.garcia@correounivalle.edu.co)

Telephone: +57-321-2195102 Fax: +57-251-85686

Received: May 3, 2014 Revised: June 30, 2014

Accepted: August 27, 2014

Published online: October 16, 2014

focus the clinical case and how to treat patients with this condition. The impact on functional and aesthetic aspects calls our attention to treat these patients correctly.

García-Perdomo HA. Importance of defining the best treatment of a genital gunshot wound: A case report. *World J Clin Cases* 2014; 2(10): 587-590 Available from: URL: <http://www.wjgnet.com/2307-8960/full/v2/i10/587.htm> DOI: <http://dx.doi.org/10.12998/wjcc.v2.i10.587>

### Abstract

Twenty percent of genital traumas are caused by penetrating injuries; accordingly gunshot and stab wounds have increased in the last couple of years around the globe, even in Colombia. A 67-year-old male patient was admitted to the emergency room because he received multiple gunshot wounds. On physical examination, multiple wounds on his penis with loss of tissue in the foreskin, glans, anterior urethra (distal third) and cavernous corpora were found. The urologist performed a partial penectomy with a penis reconstruction, he debrided the cutaneous flap of the dorsal foreskin and its glans, sutured the distal cavernous corpora and dissected the urethra. Penetrating genital injuries are extremely important due to their impact on the functional, psychological and the aesthetic consequences. It is necessary to define the best possible treatment to minimize the damage.

© 2014 Baishideng Publishing Group Inc. All rights reserved.

**Key words:** Genital; Penile; Injuries; Trauma; Amputation

**Core tip:** Genital injuries are a common problem in civil war. For example, in developing countries its incidence is increasing, so it is of vital importance to notice how to

### INTRODUCTION

Twenty percent of genital traumas are caused by penetrating injuries<sup>[1-3]</sup>; with traumatic amputations-as part of genital traumas-usually happening in acute psychotic events<sup>[4-6]</sup>. In only a small percentage they are caused by agricultural and industrial accidents or even by gunshot or stab wounds<sup>[4-6]</sup>. Due to a raise of civil war conflicts, gunshot and stab wounds have increased in the last couple of years, especially in Columbia<sup>[7]</sup>, making this type of injuries prevalently seen at Hospital Universitario del Valle (Cali, Colombia). In both males and females, the penetrating genital injuries occur with other associated injuries in 70% of cases<sup>[8,9]</sup>.

It is therefore important to know that the injured persons will have a different degree of damage and that the urologists will have to determine the probability of reattaching the part of the amputated or reconstructing the injured penis<sup>[4]</sup>.

The purpose of this report is to describe an interesting case of a genital gunshot wound associated with a literature review to support the case and treatment, according to CARE guidelines for Case Reports.

### CASE REPORT

A 67-year-old male patient was admitted to the emergen-



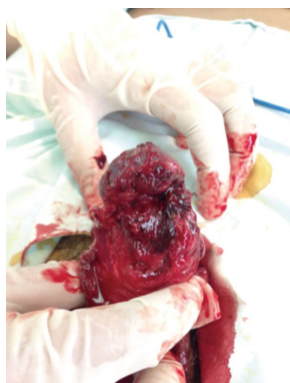

Figure 1 Glans and cavernous corpora injured.

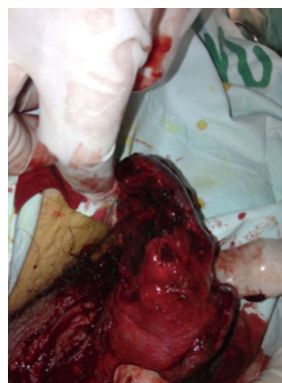

Figure 2 Injured urethra.

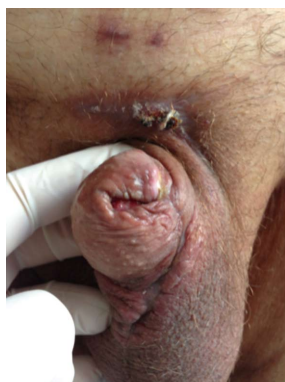

Figure 3 Left sided retraction.

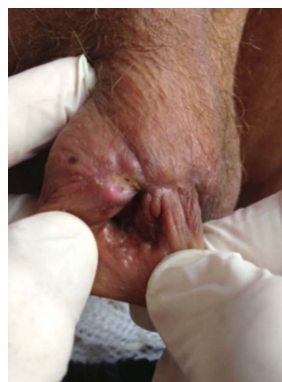

Figure 4 Mild meatus stenosis.

cy room because he received multiple gunshot wounds. On physical examination, a suprapubic and multiple wounds on his penis were found, with loss of tissue in the foreskin, glans, anterior urethra (distal third) and cavernous corpora on the left side (Figures 1 and 2). Because of the extent of injuries and the inability to have a permeable urinary tract, a suprapubic tube (cystostomy) was placed and a surgical cleansing and debridement were performed.

On the next hospitalization day, he was taken to the operating room, where following conditions were found: devitalized glans with some necrosis areas, loss of the pendulous urethra up to its middle third, and a partial loss of its foreskin, but with some good cutaneous flap remaining. The urologist decided to perform a partial penectomy with a penis reconstruction, he debrided the cutaneous flap of the dorsal foreskin and its glans, sutured the distal cavernous corpora and dissected the urethra. Following the reconstruction a urethral Foley catheter was placed.

Three days after his admission, on his second postop day, he was managed as an outpatient due to good clinical status.

As an outpatient, two months later, he showed up with good clinical status, the surgical wound was healed but some left-sided retraction of the neomeatus was found (Figures 3 and 4).

## DISCUSSION

In an emergency room, a patient with multiple injuries or even with isolated genital damage requires prompt assessment and course of action<sup>[3]</sup>. Sometimes it is important to assess the range, caliber and type of weapon to evaluate the amount of the damage, before the treatment can be initiated<sup>[1]</sup>. Primarily physicians should focus on life threatening conditions and their treatment; and only then focus on genital and associated trauma. The surgical approach will depend on the site of the damage but a lateral or a sub-coronal degloving should supply a good exposure<sup>[3]</sup>.

The first principles of caring of genitalia are debridement of devitalized tissue, preservation of as much viable tissue as possible, diversion of urine, hemostasis and removal of foreign bodies if necessary<sup>[3]</sup>; the conservative management is election for most cases<sup>[10]</sup>. If some tissue is not completely viable, the conservative management is encouraged for a delayed penile repair, perhaps 4 wk after trauma<sup>[3]</sup>. A tunica albuginea defect could be repaired easily but if bigger damage is found, the surgeon should use an autologous or xenograft<sup>[3]</sup>.

When loss of genital skin is mild to moderate, reconstruction with the same skin is preferable but when an extensive injury is encountered, a full-thickness skin graft should be established for reconstruction<sup>[10,11]</sup>. This could

be taken from the abdomen, buttock, thigh or axilla, depends of the preference of the surgeon<sup>[11]</sup>.

According to the grade of damage, there are a variety of treatments, for example: closure of residual stump, surgical reanastomosis or total phallic substitution with reconstruction<sup>[4,12]</sup>.

The penis and the amputated part should be washed out and debrided with saline or ringer solution<sup>[3,13]</sup> in every case. If replantation is attempted, it should be done within 24 h with proper maneuvers and conservation of the amputated part (usually the glans) because success has been reported within this time<sup>[14]</sup> and this could be performed in a micro or non-microvascular approach with better results in the first one<sup>[3]</sup>.

Particularly in this case, the patient had a genital gunshot wound with loss and devitalized tissue: the glans, the urethra and the cavernous corpora, so the replantation was not indicated, then the second choice of treatment was used as literature says: a closure of the penile stump was performed (cavernous corpora) and the urethra was spatulated as in a standard partial penectomy<sup>[4]</sup>. The phallic substitution with reconstruction is usually recommended for patients with a good mental status and after the episode has passed and the patient is stable<sup>[4]</sup>, but this is not going to be discussed in this article.

The postoperative management should include: antibiotics for the risk of infection, a Foley catheter for the urethral reconstruction, and some dressings over the penis<sup>[4]</sup>. These recommendations are based on descriptive studies due to the lack of clinical trials to assess the best treatment possible.

Based on the aesthetic and functional results the patient could need a second or third surgery accompanied by the plastic surgeon<sup>[4,15]</sup>, for example, this patient will need a reconstructive surgery to place the parts where they go and also perhaps an urethral reconstruction to assure the functional status.

It is important to recognize the need to interact with different specialists for example the plastic surgeon, the psychologist/psychiatrist, and the urologist for sure<sup>[4]</sup>. This is not something easy to treat, so the general physician, the urologist and every doctor involved in the treatment should recognize, diagnose and treat according to the damage to minimize the sequels.

This case allows us to recognize and to keep in mind how important and relevant these injuries are due to their impact on the functional, psychological and the aesthetic consequences. It is necessary to wash out and debride the injured tissue and consequently, defining the best possible treatment to minimize the damage.

## COMMENTS

### Case characteristics

A male patient received multiple gunshot wounds.

### Clinical diagnosis

Multiple wounds caused tissue lost in the foreskin, glans, anterior urethra and

cavernous corpora.

### Differential diagnosis

There are not differential diagnosis, but according to the findings urologists need to check for damage to the urethra, glans and cavernous corpora.

### Treatment

The treatment offered to this patient was a partial penectomy along with penis and urethral reconstruction.

### Term explanation

Partial penectomy: to take a part of the penis off. Cystostomy: to put a suprapubic tube to permit drainage of urine from the bladder.

### Experiences and lessons

The author confirmed how important and relevant these injuries are due to their impact on the functional, psychological and the aesthetic consequences.

### Peer review

This paper is well-written, and this case report is informative for readers.

## REFERENCES

- 1 Brandes SB, Buckman RF, Chelsky MJ, Hanno PM. External genitalia gunshot wounds: a ten-year experience with fifty-six cases. *J Trauma* 1995; **39**: 266-271; discussion 271-272 [PMID: 7674395]
- 2 Phonsombat S, Master VA, McAninch JW. Penetrating external genital trauma: a 30-year single institution experience. *J Urol* 2008; **180**: 192-195; discussion 195-196 [PMID: 18499189 DOI: 10.1016/j.juro.2008.03.041]
- 3 Summerton DJ, Djakovic N, Kitrey ND, Kuehhas F, Lumen N, Serafetinidis E, Sharma DM. Guidelines on Urological Trauma. *Eur Urol* 2014. Available from: URL: [http://www.uroweb.org/gls/pdf/24Urological Trauma\\_LR.pdf](http://www.uroweb.org/gls/pdf/24Urological%20Trauma_LR.pdf)
- 4 Chang AJ, Brandes SB. Advances in diagnosis and management of genital injuries. *Urol Clin North Am* 2013; **40**: 427-438 [PMID: 23905941 DOI: 10.1016/j.ucl.2013.04.013]
- 5 Aboseif S, Gomez R, McAninch JW. Genital self-mutilation. *J Urol* 1993; **150**: 1143-1146 [PMID: 8371374]
- 6 Jezior JR, Brady JD, Schlossberg SM. Management of penile amputation injuries. *World J Surg* 2001; **25**: 1602-1609 [PMID: 11775199 DOI: 10.1007/s00268-001-0157-6]
- 7 Dogra PN, Gautam G, Ansari MS. Penile amputation and emasculation: hazards of modern agricultural machinery. *Int Urol Nephrol* 2004; **36**: 379-380 [PMID: 15783110 DOI: 10.1007/s11255-004-0918-x]
- 8 Tiguert R, Harb JF, Hurley PM, Gomes De Oliveira J, Castillo-Frontera RJ, Triest JA, Gheiler EL. Management of shotgun injuries to the pelvis and lower genitourinary system. *Urology* 2000; **55**: 193-197 [PMID: 10688077 DOI: 10.1016/S0090-4295(99)00384-2]
- 9 Jolly BB, Sharma SK, Vaidyanathan S, Mandal AK. Gunshot wounds of the male external genitalia. *Urol Int* 1994; **53**: 92-96 [PMID: 7801424 DOI: 10.1159/000282643]
- 10 McAninch JW, Kahn RI, Jeffrey RB, Laing FC, Krieger MJ. Major traumatic and septic genital injuries. *J Trauma* 1984; **24**: 291-298 [PMID: 6368854 DOI: 10.1097/00005373-198404000-00002]
- 11 Summerton DJ, Campbell A, Minhas S, Ralph DJ. Reconstructive surgery in penile trauma and cancer. *Nat Clin Pract Urol* 2005; **2**: 391-397 [PMID: 16474736 DOI: 10.1038/ncpu-ro0261]
- 12 Charlesworth P, Campbell A, Kamaledeen S, Joshi A. Surgical repair of traumatic amputation of the glans. *Urology* 2011; **77**: 1472-1473 [PMID: 21256558 DOI: 10.1016/j.urol.2010.08.034]
- 13 Jordan GH. Initial management and reconstruction of male genital amputation injuries. In: McAninch JW, editor. *Traumatic and reconstructive urology*. Philadelphia: WB Saunders, 1996: 673-681
- 14 Roche NA, Vermeulen BT, Blondeel PN, Stillaert FB. Techni-

cal recommendations for penile replantation based on lessons learned from penile reconstruction. *J Reconstr Microsurg* 2012; **28**: 247-250 [PMID: 22399258 DOI: 10.1055/s-0032-1306373]

- 15 **Garaffa G**, Raheem AA, Ralph DJ. An update on penile reconstruction. *Asian J Androl* 2011; **13**: 391-394 [PMID: 21540867 DOI: 10.1038/aja.2011.29]

**P- Reviewer:** Hori T **S- Editor:** Ji FF  
**L- Editor:** A **E- Editor:** Liu SQ



## Bladder paraganglioma: A report of case series and critical review of current literature

Matheesha Ranaweera, Eric Chung

Matheesha Ranaweera, Eric Chung, Department of Urology, University of Queensland, Princess Alexandra Hospital, Brisbane QLD 4102, Australia

Eric Chung, St Andrew's Pelvic Medicine Centre, St Andrew's War Memorial Hospital, Wickham Tce, Brisbane QLD 4102, Australia

Author contributions: Ranaweera M and Chung E designed and wrote the report; Chung E was responsible for proof read and final approval of submission.

Correspondence to: Eric Chung, Professor, Department of Urology, University of Queensland, Princess Alexandra Hospital, Ipswich Rd, Brisbane QLD 4102, Australia. [ericchg@hotmail.com](mailto:ericchg@hotmail.com)  
Telephone: +61-7-33242468 Fax: +61-7-33242546

Received: May 5, 2014 Revised: July 2, 2014

Accepted: July 25, 2014

Published online: October 16, 2014

patients can present with various clinical presentations. Biochemical profiling and nuclear imaging study can assist in the identification of this lesion. Preoperative care with volume hydration and adrenergic blockade are often necessary and surgery remains the only cure for these patients.

Ranaweera M, Chung E. Bladder paraganglioma: A report of case series and critical review of current literature. *World J Clin Cases* 2014; 2(10): 591-595 Available from: URL: <http://www.wjgnet.com/2307-8960/full/v2/i10/591.htm> DOI: <http://dx.doi.org/10.12998/wjcc.v2.i10.591>

### Abstract

Extra-adrenal chromaffin cell-related tumours or paragangliomas are rare, especially in the bladder. In this article, we reported three different clinical cases of bladder paraganglioma, followed by a review of current literature on the pathophysiology and management of bladder paraganglioma. Case 1 involved a 23 years old female patient who complained of a 10-year history of micturition-related headaches, palpitations and diaphoresis; while in case 2, a 58 years old female patient presented with history of painless haematuria and an incidentally diagnosis of a functioning paraganglioma during endoscopic transurethral resection of bladder tumour; and lastly in case 3, a 54 years old male renal transplant recipient was referred to the urology outpatient with a suspicious bladder mass found incidentally on routine transplant workshop.

© 2014 Baishideng Publishing Group Inc. All rights reserved.

**Key words:** Bladder paraganglioma; Bladder mass; Catecholamine and its metabolites; Nuclear imaging

**Core tip:** Bladder paraganglioma is a rare condition and

### INTRODUCTION

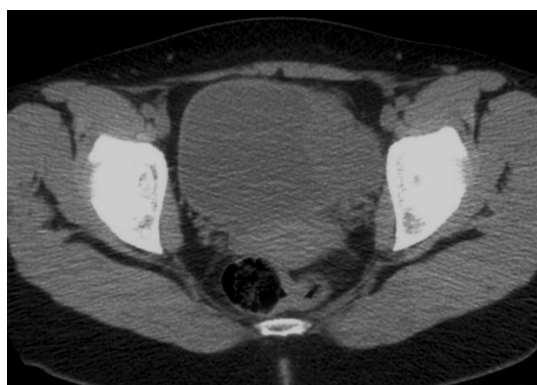
Paragangliomas are rare tumours that arises from extra-adrenal paraganglia and consists of specialized neural crest-derived cells (catecholamine-secreting chromaffin cells)<sup>[1]</sup>. Of all chromaffin cell-related tumours, paraganglioma accounts for less than a quarter of cases<sup>[1,2]</sup>. The sympathetic paraganglia are symmetrically distributed along the paravertebral axis and small sympathetic paraganglia can also be found in other organs such as the bladder. Primary paraganglioma of the urinary bladder is very rare making up less than 0.05% of all bladder malignancy. Paragangliomas can present with clinical symptoms secondary to catecholamine hypersecretion or mass effect, incidental finding on radiographic imaging, and/or on routine family screening for hereditary paraganglioma. We explore three different clinical cases of bladder paraganglioma that were treated at our institution.

### CASE REPORT

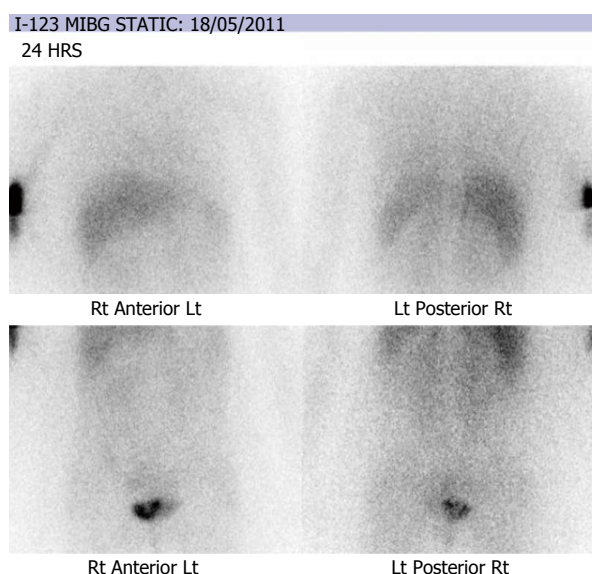
#### Case report 1

A 23 years old female was referred by her general practitioner with history of urinary urgency and an incidental finding of bladder mass on urinary tract ultrasound.

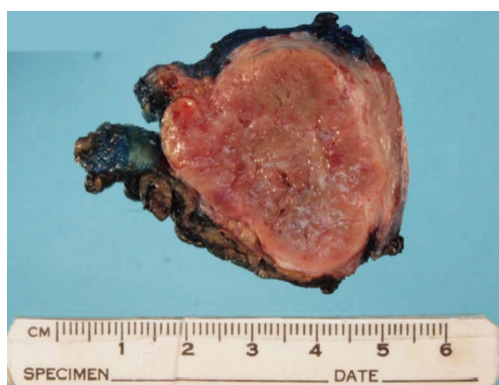



**Figure 1** Computer tomography showing an avidly enhancing mass in the left urinary bladder wall.



**Figure 2** Iodine-123-meta-iodobenzylguanidine scintiscan showing intense tracer uptake in the left side of the bladder consistent with bladder paraganglioma as well as injection artefact in the right cubital fossa. I-123 MIBG: Iodine-123-meta-iodobenzylguanidine.



**Figure 3** Macroscopic view of bladder paraganglioma. The tumour is red-brown in colour and well-circumscribed.

When enquired further, she described a long-standing history of episodic severe throbbing headaches lasting few minutes, dating back to as early as the age of 12

years. These paroxysmal attacks of headache coincided with her bladder emptying and over the last few years, she also experienced palpitations, nausea, sweat and facial pallor post-micturition. In addition, she recalled the presence of microscopic hematuria in her urine dipstick since the age of 12 years. She has been diagnosed with borderline hypertension in her late teens but is not on anti-hypertensive medication. There was no family history to suggest a hereditary endocrine disorder.

Urinary tract ultrasonography revealed a large vascular soft tissue mass on the left bladder wall and her urine cytology revealed mildly atypical urothelial cells in two out of three samples. There was a marked elevation of urinary noradrenaline (4748 nmol/dL, Reference: [50-600]) and its metabolites on 24 h urine collection. Plasma metanephrine was also significantly elevated (8500 pmol/L, reference < 900 pmol/L). Staging computed tomography of the abdomen and pelvis showed a 6.2 cm × 4 cm × 4.9 cm solid and enhancing, loculated mass near to the left vesicoureteric junction (Figure 1). Following consultation with the endocrinologist, alpha (α)-adrenergic and beta (β)-adrenergic blockade was achieved with a combination of phenoxybenzamine and metoprolol for a minimum of 2 wk prior to surgery. During this time, further imaging with Iodine-123-meta-iodobenzylguanidine (I-123 MIBG) scintiscan confirmed the presence of bladder phaeochromocytoma without metastatic disease (Figure 2).

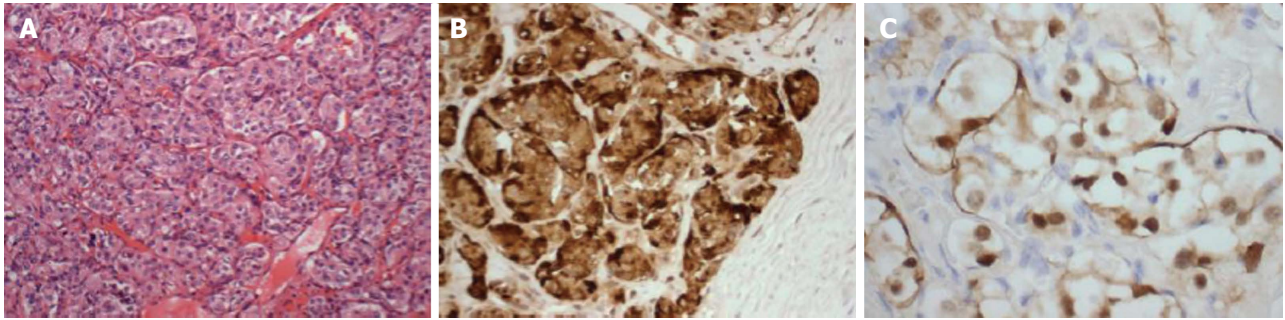
A formal rigid cystoscopy, left retrograde pyelogram and examination under anesthesia were performed and showed a firm, irregular, well circumscribed lesion in the left bladder that was not fixed to the pelvis and a normal distal left ureter configuration. She was hypertensive intraoperative and required α-adrenergic blockade with phentolamine. Discussion ensued about her condition and she underwent partial cystectomy 2 wk later with volume hydration and antihypertensive medication. A combination of adrenergic blockade with phentolamine, esmolol and metaraminol were utilised intraoperatively during her partial cystectomy.

The histopathology of the bladder wall specimen sections showed a 35 mm × 32 mm well-circumscribed, lobulated, red-brown tumour (Figure 3). Microscopically, the tumour was composed of nests of cells with eosinophilic cytoplasm and round nuclei with vesicular chromatin. It was encapsulated with no evidence of extracapsular invasion and surgical margins were clear (Figure 4). The tumour cells stained positive for chromogranin, patchy for S-100 and negative for cytokeratin consistent with urinary bladder paraganglioma.

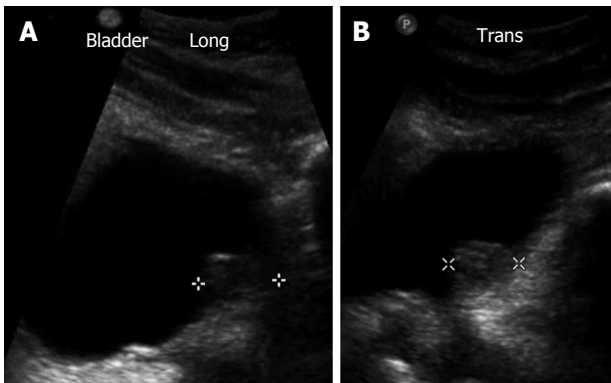
Further immunohistochemistry on the tumour specimen revealed the tumour was negative for succinate dehydrogenase subunit B (SDHB). She was subsequently discharged and remained asymptomatic at 36 mo of follow up.

## Case report 2

A 58 years old female underwent a routine uneventful resection of bladder mass found during investigation for



**Figure 4** Haematoxylin and eosin staining of bladder paraganglioma tumour (A) showing characteristic nests of cells with eosinophilic cytoplasm and round nuclei. Chromogranin staining (B) was strongly positive, whilst S100 staining (C) was positive in patches.



**Figure 5** Longitudinal and transverse views of a paraganglioma protruding into the bladder.

painless macroscopic haematuria. The histopathology of this mass showed solid nests of plump epithelial cells with granular to foamy cytoplasm and enlarged, moderate pleomorphic nuclei. Immunohistochemical staining was strongly positive for chromogranin, neuron-specific enolase (NSE), synaptophysin and protein gene product 9.5, consistent with a neuroendocrine tumour. On retrospect history, she had been taking atenolol and oxazepam for her moderate hypertension and anxiety disorder. Given that the patient's younger sister had a history of poorly controlled hypertension, both sisters underwent genetic testing and von Hippel Lindau (VHL), SDHB and succinate dehydrogenase screening, but were negative.

Further investigations showed an elevated creatinine ratio of urinary normetanephrine (0.40 mmol/mmol creatinine) and metanephrine (0.13 mmol/mmol creatinine), and an increased 24-h excretion of normetanephrine (3.2  $\mu$ mol/24 h). Nuclear imaging study with I-123 MIBG scan showed a discrete round focus on the left side of the bladder with no further evidence of metastases.

The patient was commenced on phenoxybenzamine and propranolol preoperatively for 2 wk and underwent open partial cystectomy and re-implantation of her left ureter. Intra-operatively the patient remained haemodynamically stable. Histopathology confirmed bladder paraganglioma with multiple nodules found predominately within the muscularis propria but not extending into the peri-vesicle soft tissue and a clear of the surgical margins.

The tumour showed focal moderate nuclear pleomorphism with no lymphovascular invasion. She remained asymptomatic with normal imaging test at 60 mo of follow up.

### Case report 3

A 54 years old male renal transplant recipient for end-stage renal failure (secondary to Alport's syndrome) was referred for investigation of an asymptomatic bladder mass. After having undergone a left sided radical nephrectomy for papillary renal cell carcinoma 12 mo earlier, this bladder mass was discovered on surveillance urinary tract ultrasonography (Figure 5). He underwent routine cystoscopy which revealed a submucosal polyp at the anterior bladder suspicious for urothelial tumour and this bladder "tumour" was completely resected.

Histological examination revealed tumour cells arranged in nested architecture with circumscribed margin and focal areas of smooth muscle invasion. Interestingly the immunohistochemistry staining of the tumour cells were positive for synaptophysin and chromogranin but negative for cytokeratin.

The patient subsequently underwent an I-123 MIBG scan and metastatic disease was excluded. Serum and urinary catecholamines were negative too. Follow-up flexible cystoscopy at 1 year post-resection showed no evidence of disease recurrence.

## DISCUSSION

Bladder paraganglioma is rare and accounts for less than 1% of all catecholamine secreting neoplasms and only 0.5% of all bladder tumours<sup>[3]</sup>. They are thought to arise from embryonic rests of chromaffin cells within the bladder wall and often occur in young women in their second to fourth decade of life<sup>[4]</sup>. Paragangliomas that secrete catecholamine may give rise to clinical presentation similar to a hyperfunctioning adrenal pheochromocytoma. Episodic symptoms may occur in spells or paroxysms, and can be highly variable. The position of these tumours within the bladder results in characteristic symptom complex related to micturition or over-distension of the bladder with catecholamine release. The majority of patients will experience micturition related hypertension, cold

sweats, palpitations, headaches, dizziness and sweating much like the Case 1 in our series<sup>[5]</sup>. Systemic catecholamine secretion occurs with increased bladder pressure after bladder contraction, triggering these sympathomimetic attacks<sup>[6]</sup>. These symptoms may also be precipitated by defaecation, sexual activity, ejaculation or bladder instrumentation. Approximately 55%-60% of patients will also experience painless haematuria, although it is mostly microscopic in nature<sup>[7]</sup>. While hematuria is commonly reported in patient with bladder mass, this is not specific for paraganglioma. Only a minority of patients will experience weight loss, nausea, tremor, postural hypotension, syncope, chest pain, blurred vision, laryngismus, high blood sugar levels or symptoms associated with catecholamine cardiomyopathy<sup>[5]</sup>.

Suspected cases of paragangliomas should first be investigated by measuring the level of catecholamine and its metabolites such as metanephrine and vanillylmandelic acid secretion in either the blood or urine. The measurement of serum adrenaline and noradrenaline can be costly and is usually unnecessary<sup>[8]</sup>. The majority of paragangliomas are not hormonally active, thus preoperative catecholamine levels may be normal<sup>[1,8]</sup>. Bladder paraganglioma can often be difficult to distinguish radiologically from other bladder lesions<sup>[8]</sup>. The use of intravenous contrast may precipitate a hypertensive crisis although non-ionic contrast is reported to be safe<sup>[9]</sup>. In contrast to the hyperintense T2 signalling on magnetic resonance imaging with adrenal pheochromocytoma, paraganglioma is likely to be homogenous on T2 signal<sup>[10]</sup>. Both I-131 MIBG and <sup>18</sup>F-fluorodeoxyglucose, positron emission tomography are useful for localization of potential metastatic disease. I-123 MIBG can be used as an alternative to I-131 MIBG for accurate preoperative localization of small lymph node<sup>[11]</sup>.

As many as half of the cases of paraganglioma share a genetic basis and can be related to a number of hereditary conditions including VHL, neurofibromatosis type 1, Carney triad, Multiple Endocrine Neoplasia types 2a and 2b and familial paraganglioma<sup>[1]</sup>. Therefore, genetic testing should be offered in cases of young patient (under 50 years old) with a positive family history or with history of bilateral, extra-adrenal or multifocal pheochromocytoma, a positive genetic mutation as well as those tumours with negative SDHB staining<sup>[12]</sup>.

Since paraganglia are distributed throughout the bladder wall, paraganglioma can be found in any part of the bladder. These tumours are mostly well circumscribed and usually form nodules or small mass. Placing the tumour in a Zenker's fixative will turn the tumour black; a positive chromaffin reaction. Histologically, paraganglioma is often misdiagnosed as urothelial carcinoma<sup>[13]</sup> and paraganglioma may mimic high grade urothelial carcinoma with a nest pattern. Features of paraganglioma include Zellballen architecture where tumour cells are arranged into nests and lobules, a delicate fibrovascular stroma and eosinophilic cytoplasm. Immunohistochemistry is usually positive for NSE, chromogranin and

synaptophysin and negative for cytokeratin. There are no definitive characteristics which reliably distinguish benign from malignant tumour, and desmoplastic reaction is often absent<sup>[12]</sup>. The distinction between benign and malignant paraganglioma has long been contentious, with the only widely accepted and definitive proof of malignancy being metastasis to other organs. Some histological features such as tumour necrosis, a mitotic rate greater than 3/30 high power field, capsular invasion, large nests with central degeneration, a lack of hyaline globules, a high nuclear/cytoplasmic ration, monotony of a cytological pattern and spindle cells patterns are suggestive of increased malignant predilection<sup>[14]</sup>. Immunohistochemistry stains are often useful in helping to establish the diagnosis and those with SDHB negative-stain may indicate a succinate dehydrogenase subunit-mutated tumour. Urothelial carcinoma and carcinoid tumours are positive for cytokeratin, while melanoma cells show positivity for S100, HMB45 and Melan A stains.

Complete surgical removal of the tumour is the treatment of choice<sup>[1,4,6]</sup>. If the paraganglioma is a catecholamine secreting tumour, the effects of excess circulating catecholamines should be reversed prior to surgical extirpation. Combined preoperative  $\alpha$ - and  $\beta$ -adrenergic blockade are required to control the blood pressure in order to prevent intra-operative hypertensive crisis. An  $\alpha$ -adrenergic blockade should be commenced prior to  $\beta$ -adrenergic blockade, to allow for volume expansion of the contracted blood volume and a liberal salt diet and adequate hydration are also advised. Once adequate  $\alpha$ -adrenergic blockade is achieved,  $\beta$ -adrenergic blockade can be initiated. Localised tumours can be removed in partial cystectomy while transurethral resection is adequate in superficial and small bladder lesion<sup>[8]</sup>. Postoperative 24 h urinary catecholamine and its metabolites should be conducted at week 2 and if the levels are normal, the resection of paraganglioma is considered complete.

As discussed earlier, malignant pheochromocytoma remains a challenging entity to diagnose and treat. Up to 15% of bladder paraganglioma can become metastasis, and metastasis is the only reliable indicator of malignancy. Young age, extensive local disease and micturition attacks are risk factors for malignancy while features such as vascular invasion, a deeply invasive growth patterns and recurrence are often poor prognostic signs. Metastatic potential is often unclear and thus long-term annual follow up is suggested<sup>[13]</sup>. In patients with metastatic disease, complete cystectomy and pelvic lymph node dissection is the preferred option<sup>[16]</sup>. Nuclear imaging such as I-131 MIBG radiotherapy has also been shown to be useful for palliative control of tumour function in metastatic disease, but the current chemotherapy and radiotherapy treatment options are limited<sup>[17]</sup>.

Bladder paraganglioma is a rare condition and patients can present with various clinical presentations. Biochemical profiling and nuclear imaging study can assist in the identification of this lesion. Preoperative care with volume hydration and adrenergic blockade are often nec-



essary to control the blood pressure and to prevent intra-operative hypertensive crisis. Surgical extirpation remains the only cure for these patients and further research into this rare condition is warranted.

## COMMENTS

### Case characteristic

All patients presented with bladder mass with various clinical symptoms.

### Clinical diagnosis

Bladder paraganglioma is diagnosed through biochemical hormonal profiling and nuclear imaging study.

### Differential diagnosis

Urothelial cancer, benign bladder lesion.

### Laboratory diagnosis

Measurement of catecholamine and its metabolites levels such as metanephrine and vanillylmandelic acid secretion in either the blood or urine.

### Imaging diagnosis

Nuclear imaging study using iodine-131-meta-iodobenzylguanidine and <sup>18</sup>F-fluorodeoxyglucose, positron emission tomography.

### Pathological diagnosis

Features of paraganglioma include Zellballen architecture where tumour cells are arranged into nests and lobules, a delicate fibrovascular stroma and eosinophilic cytoplasm. Immunohistochemistry is usually positive for neuron-specific enolase, chromogranin and synaptophysin and negative for cytokeratin.

### Treatment

Preoperative care with volume hydration and adrenergic blockade are often necessary to control the blood pressure and to prevent intra-operative hypertensive crisis. Surgical extirpation remains the only cure.

### Related reports

Bladder paraganglioma is a rare condition and patients can present with various clinical presentations. Malignant pheochromocytoma remains a challenging entity to diagnose and treat, and further research into this rare condition is warranted.

### Experiences and lessons

This case series highlights the various clinical presentation of bladder paraganglioma and provides a clinical review of the current literature on management of this rare condition.

### Peer review

This is a well-written report of three cases of bladder paraganglioma. Bladder paraganglioma is very rare. Their pathological diagnosis is quite proper and clinical practice is also well-summarized.

## REFERENCES

- 1 Young WF. Paragangliomas: clinical overview. *Ann N Y Acad Sci* 2006; **1073**: 21-29 [PMID: 17102068 DOI: 10.1196/annals.1353.002]
- 2 Whalen RK, Althausen AF, Daniels GH. Extra-adrenal pheochromocytoma. *J Urol* 1992; **147**: 1-10 [PMID: 1729490]
- 3 Siatelis A, Konstantinidis C, Volanis D, Leontara V, Thomas Tsagli E, Delakas D. Pheochromocytoma of the urinary bladder: report of 2 cases and review of literature. *Minerva Urol Nefrol* 2008; **60**: 137-140 [PMID: 18500228]
- 4 Cheng L, Leibovich BC, Cheville JC, Ramnani DM, Sebo TJ, Neumann RM, Nascimento AG, Zincke H, Bostwick DG. Paraganglioma of the urinary bladder: can biologic potential be predicted? *Cancer* 2000; **88**: 844-852 [PMID: 10679654]
- 5 Deng JH, Li HZ, Zhang YS, Liu GH. Functional paragangliomas of the urinary bladder: a report of 9 cases. *Chin J Cancer* 2010; **29**: 729-734 [PMID: 20663319 DOI: 10.5732/cjc.009.10703]
- 6 Pastor-Guzmán JM, López-García S, Giménez-Bachs JM, Ruiz-Mondejar R, Cañamares-Pabolaza L, Atiénzar-Tobarrá M, Casado-Moragón L, Virseda-Rodríguez JA. Paraganglioma of the bladder: controversy regarding treatment. *Urol Int* 2004; **73**: 270-275 [PMID: 15539850]
- 7 Tsai CC, Wu WJ, Chueh KS, Li WM, Huang CH, Wu CC, Lee MH, Chen SM. Paraganglioma of the urinary bladder first presented by bladder bloody tamponade: two case reports and review of the literatures. *Kaohsiung J Med Sci* 2011; **27**: 108-113 [PMID: 21421199 DOI: 10.1016/j.kjms.2010.05.005]
- 8 Bhalani SM, Casalino DD, Manvar AM. Paraganglioma of the bladder. *J Urol* 2011; **186**: 279-280 [PMID: 21600612 DOI: 10.1016/j.juro.2011.04.032]
- 9 Bessell-Browne R, O'Malley ME. CT of pheochromocytoma and paraganglioma: risk of adverse events with i.v. administration of nonionic contrast material. *AJR Am J Roentgenol* 2007; **188**: 970-974 [PMID: 17377032 DOI: 10.2214/AJR.06.0827]
- 10 Qiao HS, Feng XL, Yong L, Yong Z, Lian ZJ, Ling LB. The MRI of extraadrenal pheochromocytoma in the abdominal cavity. *Eur J Radiol* 2007; **62**: 335-341 [PMID: 17408898 DOI: 10.1016/j.ejrad.2007.02.041]
- 11 Furuta N, Kiyota H, Yoshigoe F, Hasegawa N, Ohishi Y. Diagnosis of pheochromocytoma using [123I]-compared with [131I]-metaiodobenzylguanidine scintigraphy. *Int J Urol* 1999; **6**: 119-124 [PMID: 10226821 DOI: 10.1046/j.1442-2042.1999.06310.x]
- 12 Huang KH, Chung SD, Chen SC, Chueh SC, Pu YS, Lai MK, Lin WC. Clinical and pathological data of 10 malignant pheochromocytomas: long-term follow up in a single institute. *Int J Urol* 2007; **14**: 181-185 [PMID: 17430251 DOI: 10.1111/j.1442-2042.2007.01687.x]
- 13 Zhou M, Epstein JI, Young RH. Paraganglioma of the urinary bladder: a lesion that may be misdiagnosed as urothelial carcinoma in transurethral resection specimens. *Am J Surg Pathol* 2004; **28**: 94-100 [PMID: 14707870 DOI: 10.1097/00000478-200401000-00011]
- 14 Eisenhofer G, Bornstein SR, Brouwers FM, Cheung NK, Dahia PL, de Krijger RR, Giordano TJ, Greene LA, Goldstein DS, Lehnert H, Manger WM, Maris JM, Neumann HP, Pacak K, Shulkin BL, Smith DI, Tischler AS, Young WF. Malignant pheochromocytoma: current status and initiatives for future progress. *Endocr Relat Cancer* 2004; **11**: 423-436 [PMID: 15369446 DOI: 10.1677/erc.1.00829]
- 15 Kappers MH, van den Meiracker AH, Alwani RA, Kats E, Baggen MG. Paraganglioma of the urinary bladder. *Neth J Med* 2008; **66**: 163-165 [PMID: 18424864]
- 16 Ansari MS, Goel A, Goel S, Durairajan LN, Seth A. Malignant paraganglioma of the urinary bladder. A case report. *Int Urol Nephrol* 2001; **33**: 343-345 [PMID: 12092652 DOI: 10.1023/A:1015269830795]
- 17 Gedik GK, Hoefnagel CA, Bais E, Olmos RA. 131I-MIBG therapy in metastatic pheochromocytoma and paraganglioma. *Eur J Nucl Med Mol Imaging* 2008; **35**: 725-733 [PMID: 18071700 DOI: 10.1007/s00259-007-0652-6]

P- Reviewer: El-Ghar MA, Kai K S- Editor: Ji FF

L- Editor: A E- Editor: Liu SQ





## Haemostatic management for aortic valve replacement in a patient with advanced liver disease

Laurence Weinberg, Irene Kearsey, Clarissa Tjoakarfa, George Matalanis, Sean Galvin, Scott Carson, Rinaldo Bellomo, Larry McNicol, Peter McCall

Laurence Weinberg, Irene Kearsey, Clarissa Tjoakarfa, Larry McNicol, Peter McCall, Department of Anaesthesia, Austin Hospital, Melbourne, Victoria 3084, Australia  
George Matalanis, Sean Galvin, Scott Carson, Department of Cardiac Surgery, Austin Hospital, Melbourne, Victoria 3084, Australia

Rinaldo Bellomo, Department of Intensive Care, Austin Hospital, Melbourne, Victoria 3084, Australia

**Author contributions:** Weinberg L and McCall P were the principal anaesthetists who managed the case; both were responsible for the planning and writing of the case report; Kearsey I and Tjoakarfa C were responsible for all the data collection, collation of pictures and the writing of the case report; Matalanis G and Galvin S were the cardiac surgeons that performed the operation and were responsible for the writing of the case report; Carson S was the clinical perfusionist that managed the case and was responsible for the writing of the case report; McNicol L and Bellomo R were responsible for the co-management of the patient in the preoperative and postoperative period and were responsible for the writing of the manuscript.

**Supported by** Department of Anaesthesia Research Fund, Department of Anaesthesia, Austin Hospital, Melbourne, Victoria 3084, Australia

**Correspondence to:** Laurence Weinberg, MBBCH, BSc, MRCP, DipCritCareEcho, FANZCA, Department of Anaesthesia, Austin Hospital, 145 Studley Rd, Melbourne, Victoria 3084, Australia. [laurence.weinberg@austin.org.au](mailto:laurence.weinberg@austin.org.au)

Telephone: +61-3-94965000 Fax: +61-3-94965000

Received: May 23, 2014 Revised: June 26, 2014

Accepted: July 25, 2014

Published online: October 16, 2014

let activation and dysfunction, haemodilution, surgical trauma, hepatic decompensation and hypothermia. Management can be further complicated by right heart dysfunction, porto-pulmonary hypertension, poor myocardial protection, and hepato-renal syndrome. Complex interactions between coagulation/fibrinolysis and systemic inflammatory response syndrome reactions like "post-perfusion-syndrome" also compound haemostatic failure. Given the limited information available for the specific management and prevention of cardiopulmonary bypass-induced haemostatic failure, this report serves to guide the anaesthesia and medical management of future cases of a similar kind. We discuss our multimodal management of haemostatic failure using pharmacological strategies, thromboelastography, continuous cerebral and liver oximetry, and continuous cardiac output monitoring.

© 2014 Baishideng Publishing Group Inc. All rights reserved.

**Key words:** Cardiac surgery; Liver failure; Coagulopathy; Cardiopulmonary bypass

**Core tip:** Cardiac surgery in patients with advanced liver disease is associated with significant morbidity and mortality. Refractory coagulopathy is common and requires a proactive multidisciplinary haemostatic management strategy. Given the limited information available for the specific management and prevention of cardiopulmonary bypass induced haemostatic failure, this report serves to guide the anaesthesia and medical management of future cases of a similar kind. We discuss our multimodal management of haemostatic failure using pharmacological strategies, thromboelastography, continuous cerebral and liver oximetry, and continuous cardiac output monitoring.

### Abstract

Redo-sternotomy and aortic valve replacement in patients with advanced liver disease is rare and associated with a prohibitive morbidity and mortality. Refractory coagulopathy is common and a consequence of intense activation of the coagulation system that can be triggered by contact of blood with the cardiopulmonary bypass circuitry, bypass-induced fibrinolysis, plate-

Weinberg L, Kearsey I, Tjoakarfa C, Matalanis G, Galvin S, Carson S, Bellomo R, McNicol L, McCall P. Haemostatic man-

agement for aortic valve replacement in a patient with advanced liver disease. *World J Clin Cases* 2014; 2(10): 596-603 Available from: URL: <http://www.wjgnet.com/2307-8960/full/v2/i10/596.htm> DOI: <http://dx.doi.org/10.12998/wjcc.v2.i10.596>

## INTRODUCTION

Redo-sternotomy and aortic valve replacement (AVR) in patients with advanced liver disease is rare and associated with a prohibitive morbidity and mortality. Refractory coagulopathy is common and a consequence of intense activation of the coagulation system that can be triggered by contact of blood with the cardiopulmonary bypass (CPB) circuitry, CPB-induced fibrinolysis, platelet activation and dysfunction, haemodilution, surgical trauma, hepatic decompensation and hypothermia. Management can be further complicated by right heart dysfunction, porto-pulmonary hypertension, poor myocardial protection, and hepato-renal syndrome. Complex interactions between coagulation/fibrinolysis and systemic inflammatory response syndrome (SIRS) reactions like “post-perfusion-syndrome” also compound haemostatic failure.

We present a patient with critical aortic stenosis who underwent redo-sternotomy and AVR prior to being listed for orthotopic liver transplantation. In this context, there is little information on the specific management of CPB-induced haemostatic failure. Therefore, we discuss our multimodal management of haemostatic failure using pharmacological strategies, thromboelastography (TEG), continuous cerebral and liver oximetry, and continuous cardiac output monitoring.

## CASE REPORT

A 46-year-old male (weight 68 kg, height 183 cm) presented to our institution with acute pulmonary oedema secondary to severe aortic stenosis. The patient consented for a redo-sternotomy and AVR, with an estimated perioperative mortality of 50%. Previous cardiac history included open valvotomy *via* median sternotomy for a congenital calcified bicuspid aortic valve at age 6. The patient had a 10-year history of chronic liver disease secondary to alcohol abuse, with a Child Pugh Score of 8 (Child Class B), and a Model for End-Stage Liver Disease (MELD) Score of 12. The liver disease was further complicated by severe portal hypertension with ascites, thrombocytopaenia, oesophageal varices and portal hypertensive gastropathy. Two years prior, he underwent an emergency laparotomy for bleeding umbilical varices, which required intensive care unit (ICU) admission and an 8-unit red blood cell transfusion for hemorrhagic shock.

On this admission a transthoracic echocardiogram revealed preserved systolic left and right ventricular function, a severely calcified bicuspid valve (aortic valve area: 0.7 cm<sup>2</sup>; mean aortic valve pressure gradient of 60 mmHg), moderate aortic regurgitation, mild mitral regurgitation, moderate pulmonary hypertension and a dilated

ascending aorta (5.4 cm). Other cardiovascular risk factors included IgA nephropathy (creatinine 110 µmol/L, estimated glomerular filtration rate 73 mL/min per 1.73 m<sup>2</sup>). There was no history of smoking or diabetes. The pulmonary oedema settled with conservative medical therapy. A coronary angiogram and right heart catheter study revealed no occlusive coronary artery disease, with a cardiac index of 3.4 L/min per square meter and a pulmonary artery pressure of 71/30 mmHg (mean 33 mmHg). Preoperative investigations including TEG are summarised in Tables 1-3. A detailed perioperative haemostatic coagulation strategy was formulated by a team composed of anaesthetist, haematologist, cardiac surgeon and intensivist.

The day before surgery, terlipressin [1 mg intravenous (*iv*) every 6 h] was commenced. Prior to induction of anaesthesia, an 8-French Rapid Infuser Catheter (Arrow) was inserted into each arm. Invasive monitoring included a 20 Gauge arterial line, 4-lumen central venous catheter, continuous cardiac output and continuous mixed venous oximetry measured with a fiberoptic pulmonary artery catheter (Edwards Lifesciences, Irvine CA) (Figure 1). External defibrillator pads were applied as a safety precaution. Bispectral index monitoring and cerebral and hepatic tissue oxygenation (Invos, Somanetics®) were measured with a cerebral/somatic oximeter, by placing disposable transducers over the right and left forehead (Figure 1), and on the skin overlying the lower right costal margin (Figure 2). The oximeters provided real-time monitoring of brain and liver oxygen saturations, measuring oxygen consumption and delivery. This allowed for detection and correction of cerebral and hepatic oxygen desaturation to optimise haemodynamic intervention. Tranexamic acid (1 g *iv* load then 500 g/h infusion) was commenced to minimize fibrinolysis during and after CPB. Octreotide (100 mcg bolus, then 25 mcg/h) was commenced to control portal hypertension and minimise hepatic ischaemia reperfusion injury from CPB. Vancomycin (1 g *iv*) and ceftriaxone (1 g *iv*) were administered for antimicrobial prophylaxis.

Redo-sternotomy was performed using an oscillating saw while lifting up the sternal wires. Dense adhesions of the right ventricle and posterior table of the sternum precluded access to the heart for central venous cannulation. Consequently, the femoral artery and vein were cannulated and the venous cannula carefully positioned using transoesophageal echocardiography guidance in the right atrium. After careful dissection around the heart and full heparinisation, the standard on-pump AVR technique was applied. A second venous cannula was added *via* the superior vena cava to the venous circuit to allow venous drainage, further minimizing hepatic congestion. After aortic cross clamp, pulsatile CPB was established, complete with haemofiltration to prevent fluid overload and maintain electrolyte neutrality. During CPB the patient was severely vasoplegic requiring escalating doses of nor-adrenaline (20 µg/min *iv*) and vasopressin (0.4 IU/min *iv*) to maintain a mean arterial pressure of 50 mmHg. Optimal pump flow rates and vasopressor use were

Table 1 Perioperative laboratory values and heparinase thromboelastography results

	Ref. ranges	Pre-operative	Pre-CPB	Rewarming Haemostatic intervention: FFP 15 mg/kg	Immediately post separation from CPB Haemostatic intervention: DDAVP 0.3 mg/kg; Concentrated fibrinogen 4 g; Platelets 2 pooled doses; 2 units packed RBC	15 min post separation from CPB Haemostatic intervention: Prothrombin × 1000 IU; then continuous infusion at 100 IU /h	30-min post separation from CPB Haemostatic intervention:	Arrival intensive care unit
R (min)	4-8	6.4	5.0	6.7	6.9	28.9	7.8	6.7
K (min)	0-4	2.0	1.8	1.8	1.8	4.9	1.5	1.6
Angle (deg)	47-74	62.7	63.5	65.6	65.2	49.6	68.5	65.5
MA (mm)	54-72	53.7	61.9	61.3	57.6	71.8	69.0	70.1
LY30 (%)	0-8	0.7	0.3	0.0	0.0	1.4	0.0	0.0
INR	-	1.3	1.2	1.4	1.7	1.5	1.4	1.4
PT	11-15 s	13 s	14 s	15 s	19 h	17 h	16 h	16 h
APPT	22-38 s	36 s	39 h	> 200 h	49 h	50 h	45 h	38 s
Fib claus	2.0-4.0 g/L		2.3 g/L	1.3 L	2.6 g/L	2.0 g/L	1.6 L	1.8 g/L
D-dimer	< 0.23 mg/L	1.05 h	Not measured	0.94 h		1.15 mg/L	Not measured	Not measured
Hb	130-180/L	90 L	83 L	73 L	55 L	85 L	Not measured	71 L
WBC	4.0-11.0 × 10 <sup>9</sup>	3.9 L	4.2 × 10 <sup>9</sup>	10.8 × 10 <sup>9</sup>	8.2 × 10 <sup>9</sup>	11.7 h	Not measured	9.4 × 10 <sup>9</sup>
Platelets	150-400 × 10 <sup>9</sup>	76 L	64 L	57 L	140 L	120 L	Not measured	73 L

The thromboelastography was performed after each of haemostatic interventions described. CPB: Cardiopulmonary bypass; FFP: Fresh frozen plasma; DDAVP: Desmopressin acetate; INR: International normalised ratio; PT: Prothrombin time; APPT: Activated partial prothrombin time; WBC: White blood cells; RBC: Red blood cells; MA: Maximum amplitude; K: Clot formation time; R: Reaction time.

Table 2 Perioperative arterial blood gases

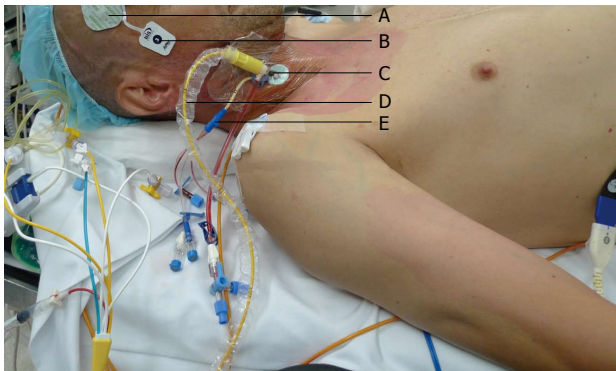
	Ref. ranges	Pre-operation	Pre-cardiopulmonary bypass	Rewarming	Post separation	Closure	Post-op day 1	Post-op day 2 (venous)
pH	7.35-7.45	7.34 <sup>1</sup>	7.32 <sup>1</sup>	7.37 <sup>1</sup>	7.24 <sup>1</sup>	7.34 <sup>1</sup>	7.34 <sup>1</sup>	7.33 <sup>1</sup>
pCO <sub>2</sub> (mmHg)	35-45	37	38	35	50 <sup>2</sup>	42	39	45
pO <sub>2</sub> (mmHg)	80-110	105	230 <sup>2</sup>	388 <sup>2</sup>	385 <sup>2</sup>	404 <sup>2</sup>	111 <sup>2</sup>	33 <sup>1</sup>
HCO <sub>3</sub> <sup>-</sup> (mmol/L)	-	19	19	20	20	22	20	23
Base excess (mmol/L)	-3/ +3	-6 <sup>1</sup>	-6 <sup>1</sup>	-4 <sup>1</sup>	-6 <sup>1</sup>	-3	-5 <sup>1</sup>	-2
O <sub>2</sub> sat (%)	> 94	98	100	100	100	100	100	56 <sup>1</sup>
Na <sup>+</sup> (mmol/L)	135-148	132 <sup>1</sup>	132 <sup>2</sup>	136	138	138	138	130 <sup>1</sup>
K <sup>+</sup> (mmol/L)	3.5-5.3	4.0	4.0	4.9	3.9	3.9	4.6	4.5
Cl <sup>-</sup> (mmol/L)	95-106	107 <sup>1</sup>	107 <sup>2</sup>	106	108 <sup>2</sup>	108 <sup>2</sup>	106	99
Ionised Ca <sup>2+</sup> (mmol/L)	1.13-1.32	1.16	1.07 <sup>1</sup>	0.92 <sup>1</sup>	0.83 <sup>1</sup>	1.06 <sup>1</sup>	1.10 <sup>1</sup>	1.10 <sup>1</sup>
Haemoglobin (g/L)	120-180	80 <sup>1</sup>	78 <sup>1</sup>	71 <sup>1</sup>	77 <sup>1</sup>	86 <sup>1</sup>	71 <sup>1</sup>	63 <sup>1</sup>
Glucose (mmol/L)	0.0-5.0	5.9 <sup>2</sup>	6.3 <sup>2</sup>	8.3 <sup>2</sup>	6.2 <sup>2</sup>	3.8 <sup>1</sup>	8.0 <sup>2</sup>	8.9 <sup>2</sup>
Lactate (mmol/L)	3.9-5.8	0.9	0.6	4.0 <sup>2</sup>	2.9 <sup>2</sup>	2.0 <sup>2</sup>	1.5	1.3

<sup>1</sup>Value below reference range; <sup>2</sup>Value above reference range.

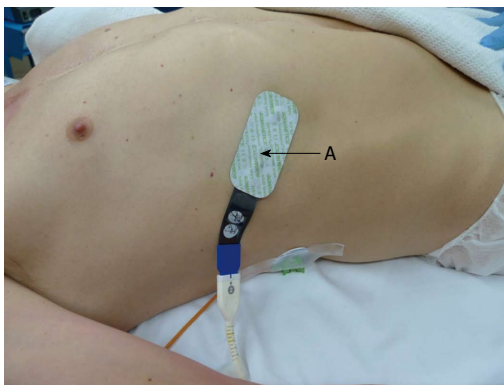
**Table 3** Perioperative renal function and liver function tests

	Ref. ranges	Pre-op	Arrival in ICU	Day 1 post op
Urea (mmol/L)	3.2-7.3	8.7 <sup>2</sup>	6.3	7.6 <sup>2</sup>
Creatinine (μmol/L)	62-106	110 <sup>2</sup>	91	125 <sup>2</sup>
Albumin (g/L)	35-52	31	25 <sup>1</sup>	36
Globulins (g/L)	25-35	46 <sup>2</sup>	19 <sup>1</sup>	20 <sup>1</sup>
Bilirubin (μmol/L)	< 18	40	35 <sup>2</sup>	47 <sup>2</sup>
ALP (IU)	40-130	99	51	49
ALT (IU)	< 41	30	21	22
GGT (U/L)	< 60	100 <sup>2</sup>	40	40

<sup>1</sup>Value below reference range; <sup>2</sup>Value above reference range. ICU: Intensive care unit; ALP: Alkaline phosphatase; ALT: Alanine aminotransferase; GGT: Gamma-glutamyl transpeptidase.

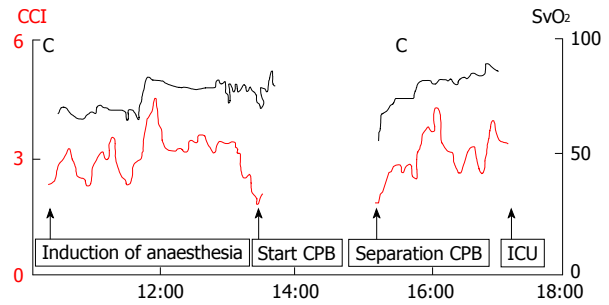


**Figure 1** Monitoring used for redo-stenotomy and aortic valve replacement. A: Cerebral oximeter (Invos, Somanetics®); B: Bispectral index; C: 9 French Internal jugular sheath; D: Continuous cardiac output and mixed venous oximetry measured with a fiberoptic pulmonary artery catheter (Edwards Lifesciences, Irvine CA); E: 4-lumen central venous catheter.



**Figure 2** Hepatic tissue oxygenation measured by positioning an oximetry disposable transducer between the ribs and over the liver. A: Hepatic oximeter (Invos, Somanetics).

guided by cerebral and liver oximetry. There was excellent correlation between cardiac output, mixed venous saturations and cerebral and liver oximetry throughout the case (Figures 3 and 4). In response to progressive refractory vasoplegia, methylene blue (1 mg/kg *iv*) was administered, which rapidly re-established an acceptable mean arterial pressure. The noradrenaline and vasopressin requirements were weaned to 3 μg/min and 0.05 IU/min



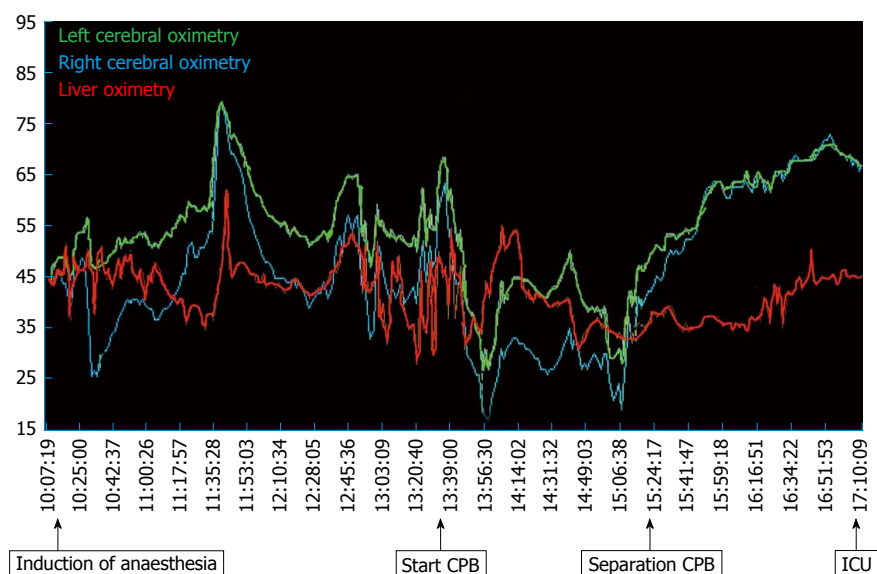
**Figure 3** Intraoperative continuous cardiac index and mixed venous oxygenations tracings measured from the pulmonary artery catheter displayed on a Vigilance™ Monitor (Edwards Lifesciences, Irvine CA). ICU: Intensive care unit; CPB: Cardiopulmonary bypass; CCI: Continuous cardiac index.

respectively. A 25 mm Mitroflow® aortic pericardial valve (Sorin, Milan, Italy) was inserted without complication.

Prior to separation from CPB, a rewarming heparinase TEG was performed (Table 1, Figure 5). Desmopressin acetate (0.3 mcg/kg *iv* over 20 min) was administered to increase the plasma levels of factor VIII and von Willebrand factor to minimize post-operative blood loss. Based on the rewarming TEG (Table 2 and Figure 5), fresh frozen plasma (15 mg/kg) was added to the CPB circuit to avoid volume overload and right ventricular distension during bypass separation. Glyceryl trinitrate (5 μg/min *iv*), and frusemide (20 mg *iv*) were administered to further reduce right ventricular preload and hepatic congestion.

After successful separation from CPB, haemostatic management focused on minimizing intraoperative bleeding and maintaining normothermia. Protamine (500 mg *iv*) was given to reverse the effects of heparin and correct activated clotting time to baseline values, followed by two bags of pooled platelets and *iv* administration of concentrated fibrinogen (4 g *iv*) (Riastap®, *iv* Behring, Australia). The dose of fibrinogen was calculated according to the patient's body weight (68 kg) and his estimated blood volume (4.8 L). Based on a preoperative haemoglobin of 9.8 g/L, a haematocrit of 30% of plasma volume (3.4 L), and a preoperative fibrinogen level of 2.5 g/L, we calculated that a dose of 4 g of fibrinogen would be needed to increase plasma fibrinogen levels by an estimated 1.2 g/L. With haemodilution on bypass, we expected the fibrinogen to fall by approximately 1-1.5 g/L. Following administration of concentrated fibrinogen, a heparinase TEG revealed significant prolongation of the R-time, confirming an underlying coagulopathy (Figure 5). Human prothrombin complex® (500 IU *iv* bolus, then 100 IU/h *iv* infusion) (CSL Behring, Australia) was administered, which corrected the R-time and improved haemostasis (Figure 5). Calcium chloride (1-2 g *iv*) was also administered. The total CPB time was 141 min and aortic cross-clamp time 61 min. Temporary epicardial pacing wires were not used to avoid the small risk of cardiac bleeding on wire removal additional. A topical haemostatic matrix (FLOSEAL™, Baxter, Pty) was used to control bleeding





**Figure 4** Cerebral and hepatic tissue oxygenation tracings measured with a cerebral/somatic oximeter (Invos Somanetics®) throughout the surgery and during cardiopulmonary bypass. ICU: Intensive care unit; CPB: Cardiopulmonary bypass.

from the suture lines, and thrombin dried powder (GEL-FOAM®, Baxter, Pty) was applied to the bone marrow of the sternum, which allowed sternal closure with minimal bleeding. Mediastinal and bilateral pleural drains were placed so that volume losses could be measured in ICU, and collection of blood around the heart avoided during the postoperative period.

In ICU, the octreotide (25 mcg/h *iv*) and prothrombinex (100 IU/h *iv*) infusions were continued for 8 h. Haemodynamic stability was maintained and the nor-adrenaline and vasopressin infusions weaned after 6 h, and the patient was extubated. Terlipressin (1 mg *iv*) was continued every 6 h for a further 24 h. The patient was transferred to the ward the following day, and discharged home ten days later without complications. There were no further requirements for coagulation or blood product intervention. Postoperatively, renal, haematological and liver function tests remained stable, and are summarised in Tables 1-3.

Three months post discharge, and at the time of writing, the patient continues to make satisfactory cardiac progress and is currently awaiting liver transplantation.

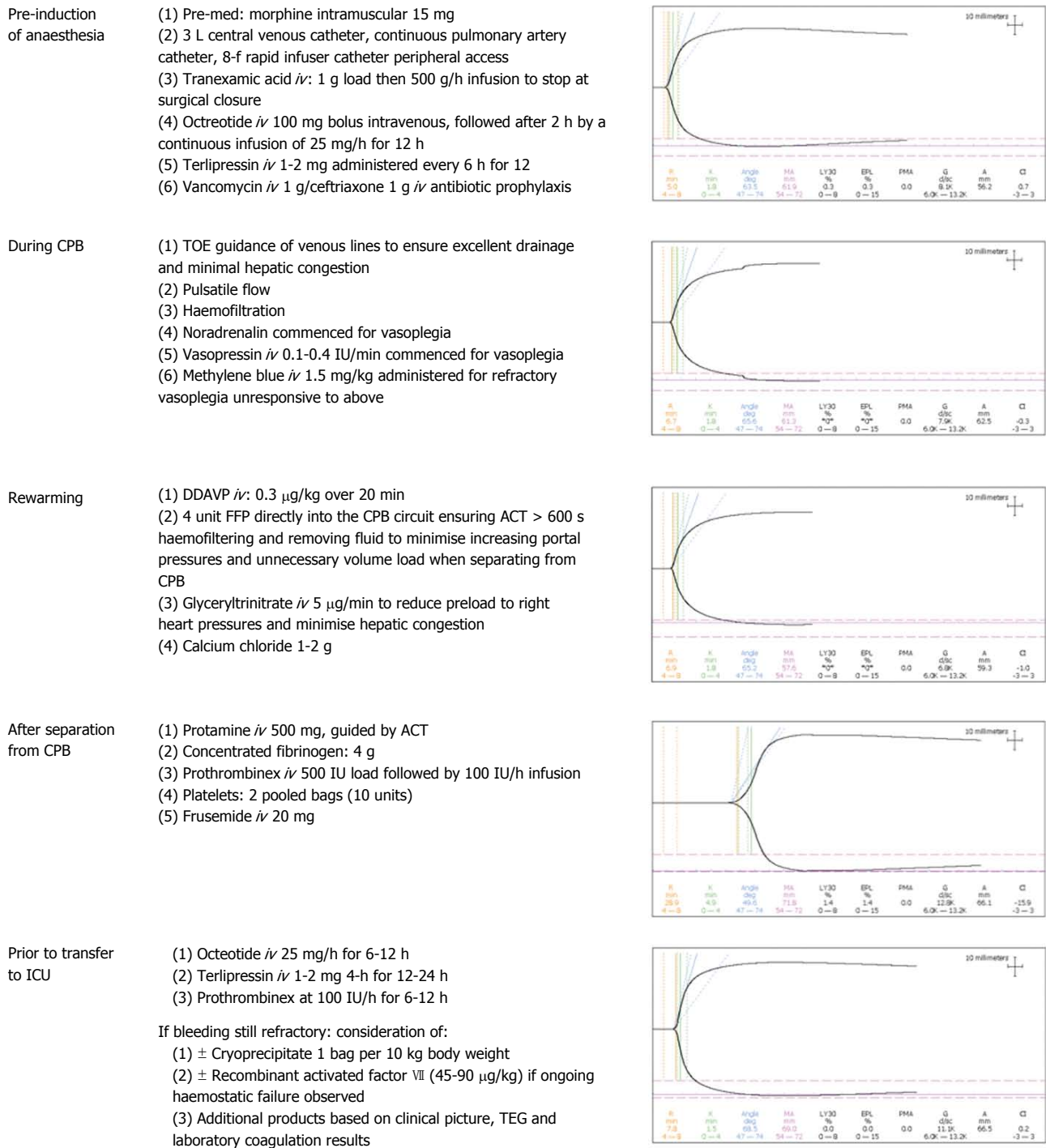
## DISCUSSION

This case illustrates that redo-sternotomy and aortic valve AVR in the setting of advanced liver disease is feasible but requires careful planning. The central management decisions for such cases include to either (1) replace the valve first and then proceed with liver transplantation at a later date; (2) offer a combined procedure, *i.e.*, AVR and liver transplantation simultaneously; and (3) proceed with liver transplantation first, and then replace the valve at a later stage. In the case described here, after extensive multidisciplinary discussion a consensus was reached that the risks of liver transplantation in the setting of uncorrected symptomatic severe aortic stenosis were prohibitive. In

view of the bicuspid valve and dilated ascending aorta, a transcatheter AVR was not a consideration. A combined AVR and liver transplant was considered but there were concerns that there may be further cardiac decompensation during the waiting period. Given that the patient was progressively symptomatic, a redo-sternotomy and AVR was considered to afford the best chance of survival, with activation for liver transplantation initiated at a later stage if the outcome was successful.

As shown in this case, redo cardiac surgery provides several technical challenges that distinguish it from primary cardiac surgery. These obstacles include repeat sternotomy, injury to the heart during dissection, quality and availability of conduits if required, a calcified ascending aorta, and more-advanced coronary disease involving the native vessels. As a result, operative mortality in most re-operations is 3 to 5 times that for a primary AVR. Adding in the ensuing complications of advanced liver disease, perioperative mortality increases with an estimated perioperative risk of mortality of 50%<sup>[1]</sup>. Each patient's condition and presentation is unique, and thus requires individualized management delivered by a multidisciplinary team. Consideration must be given to the sequence of procedures, cardiac surgical technique, and management of anticoagulation.

Combined cardiac and liver transplantation was first reported by Starzl *et al*<sup>[2]</sup> in 1984, but has remained uncommon because of the unique medical and surgical challenges it poses. In two descriptive reports of outcomes in patients with advanced liver cirrhosis undergoing cardiac surgery<sup>[3,4]</sup>, hepatic decompensation, respiratory and renal failure, gastrointestinal haemorrhagic events, sepsis and mediastinitis were among the most common postoperative complications. The association of MELD scores and Child-Turcotte-Pugh classification, and adverse outcomes is less clear. In the study by Filsoufi *et al*<sup>[4]</sup>, mortality rate increased significantly according to the



**Figure 5 Perioperative thromboelastography tracings observed in this case with corresponding haemostatic management action or planned strategy.** DDAVP: Desmopressin acetate; FFP: Fresh frozen plasma; CPB: Cardiopulmonary bypass; TEG: Thromboelastography; TOE: Transoesophageal echocardiography; *IV*: Intravenous; ACT: Activated clotting time.

Child-Turcotte-Pugh classification (class A, 10%; B, 18%; and C, 67%). The reported mortality of redo cardiac surgery was approximately 50%<sup>[3]</sup>. Similarly, the rate of complications was higher in class B (50%) and C (100%) compared to class A (20%). Suman *et al*<sup>[5]</sup> reported that a cutoff Child-Pugh score > 7 had a sensitivity and specificity of 86% and 92% for mortality, although there was no association between mortality and MELD scores. In contrast, Morimoto *et al*<sup>[3]</sup> reported that Child-Pugh class

score did not correlate with hospital mortality, although MELD score was significantly higher in patients who died immediately post cardiac surgery. To date, there have been several reports of combined AVR and liver transplantation<sup>[6]</sup>. Postoperative outcomes are variable; the majority of cases have been successful however, mortality due to clotting disturbances has also been reported. As a result, careful preoperative preparation must be conducted in such highly complex cases to prevent catastrophic

outcomes.

As seen in this case, a common yet serious complication of CPB is vasoplegic syndrome, a post-perfusion syndrome characterised by low systemic vascular resistance, significant hypotension, and a high cardiac output. It has an incidence of 5%-25% and a mortality rate as high as 25%<sup>[7]</sup>. In this case, we used the standard first line vasoactive treatment (noradrenaline and vasopressin) to maintain a mean arterial pressure of 50 mmHg<sup>[8]</sup>. However methylene blue was required during CPB to reduce the severity of vasoplegia. Use of methylene blue had been used effectively for the treatment of refractory vasoplegia in two randomised control trials<sup>[9,10]</sup>, acting through its inhibitory effect on cyclic guanosine 3',5'-monophosphate-mediated vasodilatation. Despite restoring vascular tone intraoperatively, discontinuation of vasopressin has been associated with postoperative refractory vasoplegia, therefore in the case described here, vasopressin was for continued for 6 h postoperatively.

AVR performed in the context of advanced liver disease added an additional layer of complexity in preventing further decline of hepatic and renal function. The patient's history of significant portal hypertension justified the use of both terlipressin and octreotide to prevent variceal bleeding<sup>[11-13]</sup>. Terlipressin has also been shown to improve hepatorenal syndrome, thought to be due to arteriolar vasoconstriction in the splanchnic area, which was an important consideration for the patient's underlying IgA nephropathy. Its effects are mediated *via* V1 receptors on vascular smooth muscle<sup>[13]</sup>. In animal models, octreotide has been shown to improve hepatic ischaemia-reperfusion injury by down-regulating inflammatory cytokines (tumor necrosis factor alpha and interleukin-1 beta) and inhibition of hepatocellular apoptosis<sup>[14]</sup>, and in this case, served an added benefit when separating from bypass.

Coagulopathy is a frequent occurrence during CPB and is due to a number of factors including excessive fibrinolysis, platelet dysfunction, coagulation factor consumption, and coagulation factor dilution from intravascular volume replacement. We used a variety of multimodal pharmacological agents to prevent intraoperative and postoperative bleeding. Hypofibrinogenemia is common in cardiac surgery, which was minimized preoperatively with tranexamic acid, and intraoperatively with concentrated fibrinogen<sup>[15,16]</sup>. Desmopressin acetate<sup>[17,18]</sup>, Human Prothrombin-X complex<sup>[19]</sup> and protamine were also implemented as described previously.

In this case, we employed several haemostatic and haemodynamic monitoring methods to guide our management. TEG, commonly used in cardiac surgery, is a useful tool in denoting a patient's clotting profile at landmark time points to influence specific pharmacologic decisions<sup>[20,21]</sup>. Figure 5 summarizes consecutive TEG readings and the subsequent interventions undertaken. It should also be noted that TEG requires trained personnel to operate and therefore poses as a limiting factor for its use<sup>[20]</sup>. Additional haemodynamic monitoring included pulmonary artery catheter sampling of mixed venous

blood (SvO<sub>2</sub>) and tissue oximetry. Intraoperatively, we were primarily concerned about the key factors that influence oxygen delivery, namely haemoglobin, oxygenation, and cardiac output. Continuous liver, cerebral and mixed venous oximetry enabled immediate detection of adverse changes, prompting correction and subsequent visualization of improvements of haemodynamic trends. Continuous recordings of cardiac output and global oxygenation status are presented in Figure 3. The brain and liver tissue oxygenation tracings are shown in Figure 4. In the context of low liver oximetry, in addition to the aforementioned factors that influence tissue oxygenation, hepatic congestion secondary to the outflow obstruction was also carefully monitored. Then, depending on the determined underlying cause, suitable corrections were made in the form of red cell transfusion, adjustment pump flow rates, and ensuring adequate venous drainage at all times. Although hepatic oximetry is predominantly used in the paediatric setting<sup>[22,23]</sup>, we justified its use to intensively monitor the already compromised liver, and guide therapy as above. Interestingly, the liver oximeter tracing tracked the cerebral oximeter tracing very accurately (Figure 4), providing reassurance of continual intact hepatic perfusion.

In conclusion, we report a case of AVR in a patient with advanced liver disease. Given the limited information available for specific management and prevention of haemostatic failure, this report serves to guide future cases of a similar kind.

## COMMENTS

### Case characteristics

A 46-year-old male with a history of chronic liver disease secondary to alcohol abuse, presents with acute pulmonary oedema secondary to left ventricular failure.

### Clinical diagnosis

Severe aortic stenosis.

### Differential diagnosis

Non cardiogenic causes of pulmonary oedema include pulmonary contusion, acute respiratory distress syndrome, transfusion-related acute lung injury, aspiration, hypertensive crisis, upper airway obstruction, and neurogenic causes (seizures, intracranial haemorrhage).

### Laboratory diagnosis

Plasma creatinine 110 µmol/L; albumin 31 g/L; bilirubin 40 µmol/L; haemoglobin 90 g/L; prothrombin time 1.3 s; platelets 76 ( $\times 10^9$ ).

### Imaging diagnosis

Transthoracic echocardiogram a severely calcified bicuspid valve, with an aortic valve area of 0.7 cm<sup>2</sup>; mean aortic valve pressure gradient of 60 mmHg with moderate pulmonary hypertension.

### Treatment

The patients underwent redo-aortic valve replacement requiring aggressive haemostatic therapy for coagulopathy and refractory vasoplegia.

### Related reports

Combined cardiac surgery in patients with advanced liver disease.

### Experiences and lessons

Cardiac surgery in patients with advanced liver disease is associated with significant morbidity and mortality. Refractory coagulopathy is common and requires a proactive multidisciplinary haemostatic management strategy.

### Peer review

Weinberg *et al* present an interesting and complex case report of a patient with critical aortic stenosis and advanced liver disease who underwent redo-

sternotomy and aortic valve replacement prior to being listed for orthotopic liver transplantation.

## REFERENCES

- 1 **Nemati MH**, Astanah B, Zamirian M. Aortic valve replacement in a patient with liver cirrhosis and coagulopathy. *Gen Thorac Cardiovasc Surg* 2008; **56**: 430-433 [PMID: 18696213 DOI: 10.1007/s11748-008-0270-7]
- 2 **Starzl TE**, Iwatsuki S, Shaw BW, Van Thiel DH, Gartner JC, Zitelli BJ, Malatack JJ, Schade RR. Analysis of liver transplantation. *Hepatology* 1984; **4**: 47S-49S [PMID: 6363258 DOI: 10.1002/hep.1840040714]
- 3 **Morimoto N**, Okada K, Okita Y. Results of cardiac surgery in advanced liver cirrhosis. *Gen Thorac Cardiovasc Surg* 2013; **61**: 79-83 [PMID: 23115002 DOI: 10.1007/s11748-012-0175-3]
- 4 **Filsoofi F**, Salzberg SP, Rahmanian PB, Schiano TD, Elsiey H, Squire A, Adams DH. Early and late outcome of cardiac surgery in patients with liver cirrhosis. *Liver Transpl* 2007; **13**: 990-995 [PMID: 17427174 DOI: 10.1002/lt.21075]
- 5 **Suman A**, Barnes DS, Zein NN, Levinthal GN, Connor JT, Carey WD. Predicting outcome after cardiac surgery in patients with cirrhosis: a comparison of Child-Pugh and MELD scores. *Clin Gastroenterol Hepatol* 2004; **2**: 719-723 [PMID: 15290666 DOI: 10.1016/S1542-3565(04)00296-4]
- 6 **Diaz GC**, Renz JF, Nishanian E, Kinkhabwala M, Emond JC, Wagener G. Anesthetic management of combined heart-liver transplantation. *J Cardiothorac Vasc Anesth* 2007; **21**: 253-256 [PMID: 17418742 DOI: 10.1053/j.jvca.2006.01.030]
- 7 **Gomes WJ**, Carvalho AC, Palma JH, Teles CA, Branco JN, Silas MG, Buffolo E. Vasoplegic syndrome after open heart surgery. *J Cardiovasc Surg (Torino)* 1998; **39**: 619-623 [PMID: 9833722]
- 8 **Fischer GW**, Levin MA. Vasoplegia during cardiac surgery: current concepts and management. *Semin Thorac Cardiovasc Surg* 2010; **22**: 140-144 [PMID: 21092891 DOI: 10.1053/j.semtcvs.2010.09.007]
- 9 **Maslow AD**, Stearns G, Butala P, Schwartz CS, Gough J, Singh AK. The hemodynamic effects of methylene blue when administered at the onset of cardiopulmonary bypass. *Anesth Analg* 2006; **103**: 2-8, table of contents [PMID: 16790616 DOI: 10.1213/01.ane.0000221261.25310.fe]
- 10 **Ozal E**, Kuralay E, Yildirim V, Kilic S, Bolcal C, Küçükarslan N, Günay C, Demirkilic U, Tatar H. Preoperative methylene blue administration in patients at high risk for vasoplegic syndrome during cardiac surgery. *Ann Thorac Surg* 2005; **79**: 1615-1619 [PMID: 15854942 DOI: 10.1016/j.athoracsur.2004.1.038]
- 11 **Fayed N**, Refaat EK, Yassein TE, Alwaraqy M. Effect of perioperative terlipressin infusion on systemic, hepatic, and renal hemodynamics during living donor liver transplantation. *J Crit Care* 2013; **28**: 775-782 [PMID: 23618777 DOI: 10.1016/j.jcrc.2013.02.016]
- 12 **Ludwig D**, Schädel S, Brüning A, Schiefer B, Stange EF. 48-hour hemodynamic effects of octreotide on postprandial splanchnic hyperemia in patients with liver cirrhosis and portal hypertension: double-blind, placebo-controlled study. *Dig Dis Sci* 2000; **45**: 1019-1027 [PMID: 10795771 DOI: 10.1023/A:1005553914878]
- 13 **Mukhtar A**, Salah M, Aboulfetouh F, Obayah G, Samy M, Hassani A, Bahaa M, Abdelaal A, Fathy M, Saeed H, Rady M, Mostafa I, El-Meteini M. The use of terlipressin during living donor liver transplantation: Effects on systemic and splanchnic hemodynamics and renal function. *Crit Care Med* 2011; **39**: 1329-1334 [PMID: 21336108 DOI: 10.1097/CCM.0b013e3182120842]
- 14 **Yang J**, Sun H, Takacs P, Zhang Y, Liu J, Chang Y, Candiotti KA. The effect of octreotide on hepatic ischemia-reperfusion injury in a rabbit model. *Transplant Proc* 2013; **45**: 2433-2438 [PMID: 23953560 DOI: 10.1016/j.transproceed.2013.02.112]
- 15 **Rahe-Meyer N**, Hanke A, Schmidt DS, Hagl C, Pichlmaier M. Fibrinogen concentrate reduces intraoperative bleeding when used as first-line hemostatic therapy during major aortic replacement surgery: results from a randomized, placebo-controlled trial. *J Thorac Cardiovasc Surg* 2013; **145**: S178-S185 [PMID: 23410777 DOI: 10.1016/j.jtcvs.2012.12.083]
- 16 **Rahe-Meyer N**, Solomon C, Hanke A, Schmidt DS, Knoerzer D, Hochleitner G, Sørensen B, Hagl C, Pichlmaier M. Effects of fibrinogen concentrate as first-line therapy during major aortic replacement surgery: a randomized, placebo-controlled trial. *Anesthesiology* 2013; **118**: 40-50 [PMID: 23249928 DOI: 10.1097/ALN.0b013e3182715d4d]
- 17 **Steinlechner B**, Zeidler P, Base E, Birkenberg B, Ankersmit HJ, Spannagl M, Quehenberger P, Hiesmayr M, Jilma B. Patients with severe aortic valve stenosis and impaired platelet function benefit from preoperative desmopressin infusion. *Ann Thorac Surg* 2011; **91**: 1420-1426 [PMID: 21439546 DOI: 10.1016/j.athoracsur.2011.01.052]
- 18 **Wademan BH**, Galvin SD. Desmopressin for reducing postoperative blood loss and transfusion requirements following cardiac surgery in adults. *Interact Cardiovasc Thorac Surg* 2014; **18**: 360-370 [PMID: 24263581 DOI: 10.1093/icvts/itv491]
- 19 **Song HK**, Tibayan FA, Kahl EA, Sera VA, Slater MS, Deloughery TG, Scanlan MM. Safety and efficacy of prothrombin complex concentrates for the treatment of coagulopathy after cardiac surgery. *J Thorac Cardiovasc Surg* 2014; **147**: 1036-1040 [PMID: 24365268 DOI: 10.1016/j.jtcvs.2013.11.020]
- 20 **Gorton H**, Lyons G. Is it time to invest in a thromboelastograph? *Int J Obstet Anesth* 1999; **8**: 171-178 [PMID: 15321140 DOI: 10.1016/S0959-289X(99)80133-2]
- 21 **Salooja N**, Perry DJ. Thrombelastography. *Blood Coagul Fibrinolysis* 2001; **12**: 327-337 [PMID: 11505075]
- 22 **Hampton DA**, Schreiber MA. Near infrared spectroscopy: clinical and research uses. *Transfusion* 2013; **53** Suppl 1: 52S-58S [PMID: 23301973 DOI: 10.1111/trf.12036]
- 23 **Schulz G**, Weiss M, Bauersfeld U, Teller J, Haensse D, Bucher HU, Baenziger O. Liver tissue oxygenation as measured by near-infrared spectroscopy in the critically ill child in correlation with central venous oxygen saturation. *Intensive Care Med* 2002; **28**: 184-189 [PMID: 11907662 DOI: 10.1007/s00134-001-1182-5]

P- Reviewer: Can M, Petix NR S- Editor: Song XX

L- Editor: A E- Editor: Liu SQ





## Liver abscess caused by *Burkholderia pseudomallei* in a young man: A case report and review of literature

Partha Pal, Sayantan Ray, Avijit Moulick, Subhasis Dey, Anirban Jana, Kokila Banerjee

Partha Pal, Avijit Moulick, Subhasis Dey, Department of General Medicine, Calcutta National Medical College and Hospital, Kolkata 700014, West Bengal, India

Sayantan Ray, Department of Endocrinology, IPGMER and SSKM Hospital, Kolkata 700020, West Bengal, India

Anirban Jana, Department of General Medicine, Bankura Sammilani Medical College and Hospital, Bankura 722101, West Bengal, India

Kokila Banerjee, Department of Microbiology, Drs. Tribedi and Roy Diagnostic Laboratory, Kolkata 700016, West Bengal, India

**Author contributions:** Pal P, Ray S and Moulick A contributed to conception and design; Pal P, Dey S and Jana A contributed to drafting of the article; Dey S and Jana A contributed to literature search; Ray S and Banerjee K contributed to analysis and interpretation of data; Ray S, Moulick A and Banerjee K contributed to critical revision of the article for important intellectual content; all the authors give final approval of the article.

**Correspondence to:** Dr. Sayantan Ray, Department of Endocrinology, IPGMER and SSKM Hospital, 244, AJC Bose Road, Kolkata 700020, West Bengal, India. [sayantan.ray30@gmail.com](mailto:sayantan.ray30@gmail.com)  
Telephone: +91-923-1674135 Fax: +91-923-1674135

Received: February 17, 2014 Revised: June 14, 2014

Accepted: July 25, 2014

Published online: October 16, 2014

### Abstract

Pyogenic liver abscess is a common entity in Indian subcontinent and is mostly caused by gram negative bacteria. Melioidosis is not commonly seen in India and only a few cases are reported. It can give rise to multiple abscesses at different sites including liver. We report a case of isolated liver abscess caused by *Burkholderia pseudomallei* (*B. pseudomallei*) in a 29-year-old recently diagnosed diabetic, immunocompetent male. Diagnosis was made by imaging and culture of pus aspirated from the abscess and he was treated with percutaneous pigtail catheter drainage followed by antibiotics (meropenem and trimethoprim-sulphamethoxazole). Melioidosis is an emerging infection in India and has high mortality rate, so early diagnosis and prompt

management is warranted which requires clinical vigilance and an intensive microbiological workup. Clinicians should be aware of isolated liver abscess caused by *B. pseudomallei* in appropriate clinical settings.

© 2014 Baishideng Publishing Group Inc. All rights reserved.

**Key words:** Liver abscess; Diabetes; *Burkholderia pseudomallei*; Emerging infection; India

**Core tip:** Liver abscess due to *Burkholderia pseudomallei* (*B. pseudomallei*) is extremely rare and is mostly reported from Taiwan. In India, most of the reports of are from southern coastal India and this entity is exceedingly rare in eastern India. The actual magnitude of this emerging infection may be under reported due to non-availability of confirmatory tests. Accurate diagnosis is necessary as outcome is fatal with ineffective treatment. We report a case of multiple liver abscesses caused by *B. pseudomallei* in a 29-year-old diabetic male, who was referred as a case of recurrence of pyogenic liver abscess which was previously caused by pseudomonas not responding to antibiotic therapy and aspiration. Diagnosis was made by imaging and culture of aspirated pus revealed *B. pseudomallei* and he was treated successfully with surgical drainage and prolonged course of intravenous and oral antibiotics. So, in a case of pyogenic liver abscess not responding to conventional antibiotics, *B. pseudomallei* should always be thought as a possibility which can be identified by its characteristic appearance on culture and microscopy or direct immunofluorescence testing as well as unique imaging features.

Pal P, Ray S, Moulick A, Dey S, Jana A, Banerjee K. Liver abscess caused by *Burkholderia pseudomallei* in a young man: A case report and review of literature. *World J Clin Cases* 2014; 2(10): 604-607 Available from: URL: <http://www.wjcn.net.com/2307-8960/full/v2/i10/604.htm> DOI: <http://dx.doi.org/10.12998/wjcc.v2.i10.604>

## INTRODUCTION

Liver abscess is the commonest intra-abdominal abscess, which may be of biliary tract origin (commonest) or hematogenous spread from a distant site, and rarely traumatic. Pyogenic liver abscess is a rare but potentially lethal condition, with a reported incidence of 20 per 100000 hospital admissions in a western population<sup>[1]</sup>. Both gram positive and gram negative aerobes and anaerobes have been found on culture of aspirated pus, among them *Escherichia coli* (*E. coli*) is cultured most frequently in Western countries<sup>[2]</sup> and *Klebsiella* in Asian countries<sup>[3]</sup>.

*Burkholderia pseudomallei* (*B. pseudomallei*), a category II bioterrorism agent, is the causative organism melioidosis and is endemic in Southeast Asia and northern Australia<sup>[4]</sup>. *B. pseudomallei* is found in soil and water and infection occurs by inoculation, inhalation, or ingestion<sup>[4]</sup>. Melioidosis is most commonly known to present as pneumonia followed by abscesses in the skin. Abscesses in internal organs like spleen, kidney, prostate and liver have also been reported as part of disseminated disease. Isolated liver abscess in melioidosis is a rare clinical condition.

Cases of melioidosis have been reported from southern coastal part of India, but melioidosis causing liver abscess is rare. In cases of liver abscess not responding to conventional anti-microbial the possibility of melioidosis should always be kept in mind. Because of high relapse and mortality rate, early diagnosis and prolonged treatment is a must in this case.

## CASE REPORT

A 29-year-old male was referred to us with high grade fever for 20 d and cough for 2 wk. He had no history of tuberculosis, foreign travel or animal exposure and is farmer by occupation. He had a pyogenic liver abscess by *Pseudomonas aeruginosa* along with pancytopenia about one year back. On admission patient was toxic with high grade fever (37.7 °C-39.4 °C) with a pulse rate of 126/min and blood pressure of 100/76 mmHg. Liver was enlarged, tender with a liver span of 15 cm and spleen was just palpable. There was no free fluid in abdomen clinically.

Investigations revealed hemoglobin 10.3 gm/dL, total leucocyte count of 9400/ $\mu$ L, neutrophil 88%, lymphocyte 10%, eosinophil 2% and platelet count of  $175 \times 10^9$ / $\mu$ L. Fasting plasma glucose was 164 mg/dL and HbA1c was 8.1%. So he was newly diagnosed of having diabetes mellitus and started on treatment with insulin. Renal function and liver function tests were within normal limits. Human immunodeficiency virus serology was negative. Acid fast bacilli were not found in sputum and sputum culture showed no growth of any pathogenic organism. Chest radiograph showed elevation of right dome of diaphragm (Figure 1A). Abdominal ultrasound revealed hepatomegaly with a large hypoechoic space occupying lesion (88 mm  $\times$  91 mm) in right lobe of liver with splenomegaly. Contrast enhanced computed tomography of abdomen showed hepatomegaly with loculated hypodense lesion (8.5 cm  $\times$  7.4 cm) in the anterior part

of right lobe (Figure 1B), and multiple small hypodense lesions with confluence in the posterior part of right lobe (Figure 1C). Pus was aspirated from the abscess which on culture showed dry, wrinkled colonies (Figure 2A) on 5% sheep blood agar and McConkey's agar after 48 h of incubation at 37 °C. Gram-negative, oxidase-positive, motile, aerobic bacilli with typical bipolar "Safety pin" appearance (Figure 2B) was seen on gram stain suggestive of *B. pseudomallei*, which was identified by Vitek 2 compact system. Culture sensitivity was done, which was sensitive to ceftazidime, piperacillin-tazobactam, meropenem, trimethoprim-sulphamethoxazole and minocycline.

Patient was treated with percutaneous catheter drainage, antibiotics and strict glycemic control. Intravenous meropenem was continued for two weeks followed by trimethoprim-sulphamethoxazole for 20 wk after which follow up computed tomography (CT) scan showed complete resolution of the liver abscess.

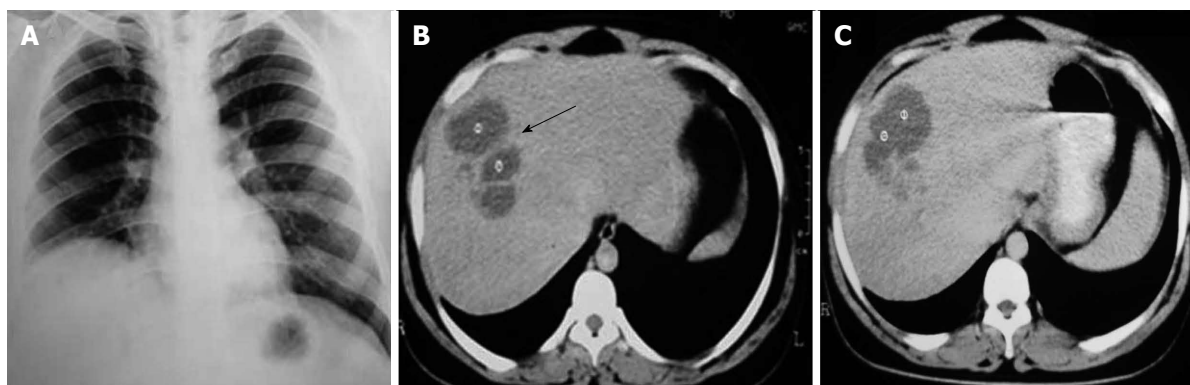
## DISCUSSION

Liver abscess is a common entity in India; among which pyogenic liver abscess is a rare variety. Ascending infection from biliary tract is the most common cause, followed by hematogenous spread<sup>[4]</sup>. *E. coli*, is the most often cultured bacteria, accounting for about 33% of the cases followed by streptococcal group<sup>[5]</sup>.

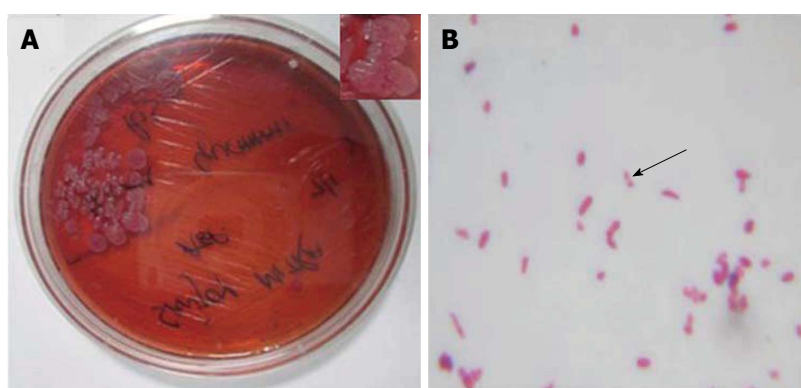
Melioidosis varies from asymptomatic infections and localized skin abscess without systemic illness to fulminant diseases with abscesses involving lungs and other internal organs especially when the host immunity is compromised. Cases of isolated liver abscess are not very common and rarely reported. It is an environmental saprophyte and is endemic in Southeast Asia and northern Australia. In India it is found in southern parts in the states of Karnataka, Tamil Nadu, Kerala and Maharashtra<sup>[6]</sup>. Twenty eight cases of septicemic melioidosis were reported from a tertiary care hospital in south India between 1993 and 2002<sup>[7]</sup> and it is an emerging infection in India. Liver abscess caused by *B. pseudomallei* is rare and only 9 cases have been reported in India<sup>[6,8-10]</sup> till now, and few cases have been reported in Taiwan<sup>[11-13]</sup>. Gopalakrishnan *et al*<sup>[14]</sup>, in a series of 32 cases of culture proven Melioidosis found localized infections in 14 patients but did not encounter even a single case of liver abscess.

The most important risk factors are diabetes, renal disease, liver cirrhosis, thalassemia, alcoholism, use of immunosuppressive agents, cystic fibrosis and kava (a Hawaiian drink) consumption<sup>[15]</sup>. The presenting symptoms may vary from fever, dry cough due to irritation of diaphragm by abscess, abdominal pain, localized swelling to septicemia shock. Lung is most commonly involved in melioidosis. Abscess in other internal organs such as liver and spleen may be a presenting feature in an immunocompromised host. The risk factor for our patient was diabetes but isolated liver abscess without any other organ involvement has seldom been reported previously.

A positive culture of *B. pseudomallei* from the aspirated pus from liver abscess is the definitive diagnosis. It is



**Figure 1 Computed tomography.** A: Chest radiograph shows elevation of right hemi-diaphragm; B: Contrast enhanced computed tomography of upper abdomen shows one loculated hypodense lesion (8.5 cm × 7.4 cm) with irregular inner margin noted in the right lobe of liver (black arrow); C: Multiple small hypodense lesions with confluences also seen in posterior part of right lobe.



**Figure 2 Identification of bacteria.** A: Showing dry wrinkled colonies on 5% sheep blood agar (48 h of incubation at 37%). Inset: colonies in enlarged view; B: Gram negative oxidase positive bacillus with typical bipolar “safety-pin” appearance on gram stain (black arrow).

difficult to differentiate *B. pseudomallei* from other gram negative bacilli. Direct immunofluorescence microscopy is 98% specific and 70% sensitive compared to culture<sup>[7]</sup>. Chest radiograph may show elevation of right dome of diaphragm as in our case. CT scan findings will include liver abscesses with a “honeycomb” pattern of multiseptate, multiloculated lesions and a “necklace sign” with multiple peripheral radial loculations contained within the larger hypodense honeycomb lesions<sup>[16]</sup>. These findings were shown in a retrospective study in a small number of cases of liver abscess with melioidosis.

*B. pseudomallei* is characteristically resistant to penicillin other than ureidopenicillins, ampicillin, first- and second-generation cephalosporins, gentamicin, tobramycin, streptomycin and macrolides. It is only susceptible to chloramphenicol, tetracyclines, trimethoprim-sulfamethoxazole, ureidopenicillins, third-generation cephalosporins, carbapenems and amoxicillin-clavulanate<sup>[14]</sup>. The antibiotic of choice for melioidosis is ceftazidime (40 mg/kg every 8 h)<sup>[17]</sup>. Imipenem or intravenous amoxicillin-clavulanate is the alternative choices<sup>[18]</sup>. Parenteral antibiotics should be continued for at least 10–14 d, or until patient is able to take oral medications. Oral maintenance therapy for at least 20 wk with amoxicillin-clavulanate (amoxicillin 27 mg/kg per day divided into three doses) or trimethoprim-

sulfamethoxazole (trimethoprim 8 mg/kg per day and sulfamethoxazole 40 mg/kg per day) should be given in patients with abscess for complete resolution<sup>[14]</sup>. Patients need to be followed up for at least 6 mo after complete resolution of abscess.

In conclusion, *E. coli* is the commonest cause of pyogenic liver abscess in India, but *B. pseudomallei* should also be kept in mind because of its rising incidence and misdiagnosis can lead to treatment failure and high mortality rate. Diabetes and immunosuppressed state are the important risk factors. Prolonged treatment with antibiotic is necessary for complete resolution in *B. pseudomallei* liver abscess. Liver abscess in a diabetic not responding to aminoglycosides and penicillins should be dealt with rigorous attention or otherwise the outcome will be fatal.

## COMMENTS

### Case characteristics

A 29-year-old farmer presented with high grade fever and cough for 3 wk.

### Clinical diagnosis

High grade pyrexia, tachycardia, just palpable splenomegaly and tender hepatomegaly.

### Differential diagnosis

An infectious etiology common in tropical countries such as pyogenic liver abscess, malaria, tuberculosis and an immunocompromised state [e.g., human



immunodeficiency virus (HIV)] have been considered.

### Laboratory diagnosis

Mild anemia, neutrophilia, fasting hyperglycemia, raised glycosylated hemoglobin was present whereas sputum for Acid-fast bacilli, HIV serology, blood for malaria parasite were negative.

### Imaging diagnosis

Chest X-ray, abdominal ultrasound and abdominal contrast enhanced computed tomography were done which showed elevated hemidiaphragm on X-ray and hypodense loculated lesion in right lobe of liver on ultrasound and tomography.

### Pathological diagnosis

Aspirated pus from the abscess inoculated on 5% sheep blood agar and McConkey's agar showed gram-negative, oxidase-positive, motile, aerobic bacilli with typical bipolar "Safety pin" appearance on gram stain suggestive of *Burkholderia pseudomallei* (*B. Pseudomallei*), later confirmed via automated Vitek-2 compact system and was sensitive to ceftazidime, piperacillin-tazobactam, meropenem, trimethoprim-sulphamethoxazole and minocycline.

### Treatment

Patient was treated with percutaneous catheter drainage, strict glycemic control with insulin, intravenous meropenem for 2 wk followed by trimethoprim-sulphamethoxazole for 20 wk which led to resolution of abscess.

### Term explanation

"Safety Pin" appearance: bipolar staining of *B. Pseudomallei* on gram stain as if the organism resembles a "Safety Pin", "Necklace sign" on computed tomography scan: multiple peripheral radial loculations contained within the larger hypodense honeycomb lesions of liver abscess.

### Experiences and lessons

Isolated liver abscess due to *B. Pseudomallei* can occur specially in immunosuppressed and diabetic patients who need prolonged treatment with antibiotics for resolution and misdiagnosis may lead to treatment failure and high mortality rates.

### Peer review

This paper is interesting and it could be accepted pending review.

## REFERENCES

- Huang CJ, Pitt HA, Lipsett PA, Osterman FA, Lillemoe KD, Cameron JL, Zuidema GD. Pyogenic hepatic abscess. Changing trends over 42 years. *Ann Surg* 1996; **223**: 600-607; discussion 607-609 [PMID: 8651751 DOI: 10.1097/0000658-199605000-00016]
- Alvarez Pérez JA, González JJ, Baldonado RF, Sanz L, Carreño G, Junco A, Rodríguez JJ, Martínez MD, Jorge JJ. Clinical course, treatment, and multivariate analysis of risk factors for pyogenic liver abscess. *Am J Surg* 2001; **181**: 177-186 [PMID: 11425062 DOI: 10.1016/S0002-9610(00)00564-X]
- Chou FF, Sheen-Chen SM, Chen YS, Chen MC. Single and multiple pyogenic liver abscesses: clinical course, etiology, and results of treatment. *World J Surg* 1997; **21**: 384-388; discussion 388-389 [PMID: 9143569 DOI: 10.1007/PL00012258]
- Ramphal R. Chapter 152. Infections Due to *Pseudomonas* Species and Related Organisms. In: Longo DL, Fauci AS, Kasper DL, Hauser SL, Jameson JL, Loscalzo J, editors. *Harrison's Principles of Internal Medicine*. 18th ed. New York: McGraw-Hill, 2012
- Branum GD, Tyson GS, Branum MA, Meyers WC. Hepatic abscess. Changes in etiology, diagnosis, and management. *Ann Surg* 1990; **212**: 655-662 [PMID: 2256756 DOI: 10.1097/0000658-199012000-00002]
- Mukhopadhyaya A, Balaji V, Jesudason MV, Amte A, Jeyamani R, Kurian G. Isolated liver abscesses in melioidosis. *Indian J Med Microbiol* 2007; **25**: 150-151 [PMID: 17582188 DOI: 10.4103/0255-0857.32724]
- Jesudason MV, Anbarasu A, John TJ. Septicaemic melioidosis in a tertiary care hospital in south India. *Indian J Med Res* 2003; **117**: 119-121 [PMID: 14575177]
- Banerjee S. Liver abscess due to unusual gram negative bacilli; *Burkholderia pseudomallei*? *IJM* 2009; **6** [DOI: 10.5580/1f3a]
- Sengupta S, Murthy R, Kumari GR, Rahana K, Vidhyasagar S, Bhat BKS, Shivananda PG. *Burkholderia pseudomallei* in a case of hepatic abscess. *Indian J Med Microbiol* 1998; **16**: 88-89
- Saravu K, Mukhopadhyay C, Vishwanath S, Valsalan R, Docherla M, Vandana KE, Shastry BA, Bairy I, Rao SP. Melioidosis in southern India: epidemiological and clinical profile. *Southeast Asian J Trop Med Public Health* 2010; **41**: 401-409 [PMID: 20578524]
- Lee YL, Lee SS, Tsai HC, Chen YS, Wann SR, Kao CH, Liu YC. Pyogenic liver abscess caused by *Burkholderia pseudomallei* in Taiwan. *J Formos Med Assoc* 2006; **105**: 689-693 [PMID: 16935773 DOI: 10.1016/S0929-6646(09)60171-6]
- Wang CZ, Hung MZ. [Liver melioidosis: case report and literature review]. *Taiwan Med J* 2004; **47**: 32-34
- Ben RJ, Tsai YY, Chen JC, Feng NH. Non-septicemic *Burkholderia pseudomallei* liver abscess in a young man. *J Microbiol Immunol Infect* 2004; **37**: 254-257
- Gopalakrishnan R, Sureshkumar D, Thirunarayan MA, Ramasubramanian M. Melioidosis: An Emerging Infection in India. *J Assoc Physicians India* 2013; **61**: 612-14
- White NJ. Melioidosis. *Lancet* 2003; **361**: 1715-1722 [PMID: 12767750 DOI: 10.1016/S0140-6736(03)13374-0]
- Apisarnthanarak A, Apisarnthanarak P, Mundy LM. Computed tomography characteristics of *Burkholderia pseudomallei* liver abscess. *Clin Infect Dis* 2006; **42**: 989-993 [PMID: 16511765 DOI: 10.1086/501017]
- White NJ, Dance DA, Chaowagul W, Wattanagoon Y, Wuthiekanun V, Pitakwatchara N. Halving of mortality of severe melioidosis by ceftazidime. *Lancet* 1989; **2**: 697-701 [PMID: 2570956 DOI: 10.1016/S0140-6736(89)90768-X]
- Smith MD, Wuthiekanun V, Walsh AL, White NJ. Susceptibility of *Pseudomonas pseudomallei* to some newer beta-lactam antibiotics and antibiotic combinations using time-kill studies. *J Antimicrob Chemother* 1994; **33**: 145-149 [PMID: 7512547 DOI: 10.1093/jac/33.1.145]

P- Reviewer: Ferraioli G S- Editor: Song XX

L- Editor: A E- Editor: Liu SQ





# World Journal of *Clinical Cases*

*World J Clin Cases* 2014 November 16; 2(11): 608-731





### EDITORIAL

- 608 Important of case-reports/series, in rare diseases: Using neuroendocrine tumors as an example  
*Nakamura T, Igarashi H, Ito T, Jensen RT*

### REVIEW

- 614 Evolution of endovascular mechanical thrombectomy for acute ischemic stroke  
*Przybyłowski CJ, Ding D, Starke RM, Durst CR, Crowley RW, Liu KC*
- 623 Epilepsy associated tumors: Review article  
*Giulioni M, Marucci G, Martinoni M, Marliani AF, Toni F, Bartiromo F, Volpi L, Riguzzi P, Bisulli F, Naldi I, Michelucci R, Baruzzi A, Tinuper P, Rubboli G*
- 642 Pathways of fear and anxiety in dentistry: A review  
*Carter AE, Carter G, Boschen M, AlShwaimi E, George R*

### MINIREVIEWS

- 654 Squamous cell carcinoma of the scrotum: A look beyond the chimneystacks  
*Vyas R, Zargar H, Trolia RD, Lorenzo GD, Autorino R*
- 661 Olfactory dysfunction in dementia  
*Alves J, Petrosyan A, Magalhães R*
- 668 Promising new treatment targets in patients with fibrosing lung disorders  
*Sterclova M, Vasakova M*
- 676 Recurrent anterior shoulder instability: Review of the literature and current concepts  
*Sofu H, Gürsu S, Koçkara N, Öner A, Issin A, Çamurcu Y*
- 683 Evaluation of anatomical considerations in the posterior maxillae for sinus augmentation  
*Lee JE, Jin SH, Ko Y, Park JB*
- 689 Value of temporary stents for the management of perivaterian perforation during endoscopic retrograde cholangiopancreatography  
*Lee SM, Cho KB*

- |                            |            |   |
|----------------------------|------------|---|
| <b>ORIGINAL ARTICLE</b>    | <b>698</b> | <p>Simultaneous vs staged treatment of urolithiasis in patients undergoing radical prostatectomy</p> <p><i>Viers BR, Tollefson MK, Patterson DE, Gettman MT, Krambeck AE</i></p>  |
| <hr/>                      |            |   |
| <b>RETROSPECTIVE STUDY</b> | <b>705</b> | <p>Adjuvant chemotherapy and acute toxicity in hypofractionated radiotherapy for early breast cancer</p> <p><i>Kouloulis V, Zygogianni A, Kypraiou E, Georgakopoulos J, Thrapsanioti Z, Beli I, Mosa E, Psyrris A, Antypas C, Armbilia C, Tolia M, Platoni K, Papadimitriou C, Arkadopoulos N, Gennatas C, Zografos G, Kyrgias G, Dilvoi M, Patatoucas G, Kelekis N, Kouvaris J</i></p> |
| <hr/>                      |            |   |
| <b>CASE REPORT</b>         | <b>711</b> | <p>Concomitant achondroplasia and Chiari II malformation: A double-hit at the cervicomedullary junction</p> <p><i>Awad AW, Aleck KA, Bhardwaj RD</i></p>  |
|                            | <b>717</b> | <p>Bevacizumab maintenance in metastatic colorectal cancer: How long?</p> <p><i>De Stefano A, Moretto R, Cella CA, Romano FJ, Raimondo L, Fiore G, Di Pietro F, Pepe S, De Placido S, Carlomagno C</i></p>  |
|                            | <b>724</b> | <p>Acute abdomen in pregnancy due to isolated Fallopian tube torsion: The laparoscopic treatment of a rare case</p> <p><i>Sidiropoulou Z, Setibal A</i></p>   |
|                            | <b>728</b> | <p>Rare etiology of mechanical intestinal obstruction: Abdominal cocoon syndrome</p> <p><i>Uzunoglu Y, Altintoprak F, Yalkin O, Gunduz Y, Cakmak G, Ozkan OV, Celebi F</i></p>  |

## Contents

*World Journal of Clinical Cases*  
Volume 2 Number 11 November 16, 2014

**APPENDIX** I-V Instructions to authors

**ABOUT COVER** Editorial Board Member of *World Journal of Clinical Cases*, Orhan Veli Ozkan, MD, Associate Professor of General Surgery, Department of General Surgery, Sakarya University, Faculty of Medicine, Adnan Menderes Caddesi, 193 Sağlık Sokak, 54100 Sakarya, Turkey

**AIM AND SCOPE** *World Journal of Clinical Cases* (*World J Clin Cases*, *WJCC*, online ISSN 2307-8960, DOI: 10.12998) is a peer-reviewed open access academic journal that aims to guide clinical practice and improve diagnostic and therapeutic skills of clinicians.

The primary task of *WJCC* is to rapidly publish high-quality Autobiography, Case Report, Clinical Case Conference (Clinicopathological Conference), Clinical Management, Diagnostic Advances, Editorial, Field of Vision, Frontier, Medical Ethics, Original Articles, Clinical Practice, Meta-Analysis, Minireviews, Review, Therapeutics Advances, and Topic Highlight, in the fields of allergy, anesthesiology, cardiac medicine, clinical genetics, clinical neurology, critical care, dentistry, dermatology, emergency medicine, endocrinology, family medicine, gastroenterology and hepatology, geriatrics and gerontology, hematology, immunology, infectious diseases, internal medicine, obstetrics and gynecology, oncology, ophthalmology, orthopedics, otolaryngology, pathology, pediatrics, peripheral vascular disease, psychiatry, radiology, rehabilitation, respiratory medicine, rheumatology, surgery, toxicology, transplantation, and urology and nephrology.

**INDEXING/ABSTRACTING** *World Journal of Clinical Cases* is now indexed in PubMed Central, PubMed, Digital Object Identifier.

**FLYLEAF** I-V Editorial Board

## EDITORS FOR THIS ISSUE

Responsible Assistant Editor: *Xiang Li*  
Responsible Electronic Editor: *Ya-Jing Lu*  
Proofing Editor-in-Chief: *Lian-Sheng Ma*

Responsible Science Editor: *Fang-Fang Ji*  
Proofing Editorial Office Director: *Xiu-Xia Song*

**NAME OF JOURNAL**  
*World Journal of Clinical Cases*

**ISSN**  
ISSN 2307-8960 (online)

**LAUNCH DATE**  
April 16, 2013

**FREQUENCY**  
Monthly

**EDITORS-IN-CHIEF**  
**Giuseppe Di Lorenzo, MD, PhD, Professor**, Genitourinary Cancer Section and Rare-Cancer Center, University Federico II of Napoli, Via Sergio Pansini, 5 Ed. 1, 80131, Naples, Italy

**Jan Jacques Michiels, MD, PhD, Professor**, Primary Care, Medical Diagnostic Center Rijnmond Rotterdam, Bloodcoagulation, Internal and Vascular Medicine, Erasmus University Medical Center, Rotterdam, Goodheart Institute and Foundation, Erasmus Tower, Veenmos 13, 3069 AT, Erasmus City, Rotterdam, The Netherlands

**Sandro Vento, MD**, Department of Internal Medicine, University of Botswana, Private Bag 00713, Gaborone,

Botswana

**Shuhei Yoshida, MD, PhD**, Division of Gastroenterology, Beth Israel Deaconess Medical Center, Dana 509, Harvard Medical School, 330 Brookline Ave, Boston, MA 02215, United States

**EDITORIAL OFFICE**  
Jin-Lei Wang, Director  
Xiu-Xia Song, Vice Director  
*World Journal of Clinical Cases*  
Room 903, Building D, Ocean International Center, No. 62 Dongsihuan Zhonglu, Chaoyang District, Beijing 100025, China  
Telephone: +86-10-85381891  
Fax: +86-10-85381893  
E-mail: [editorialoffice@wjgnet.com](mailto:editorialoffice@wjgnet.com)  
Help Desk: <http://www.wjgnet.com/csp/helpdesk.aspx>  
<http://www.wjgnet.com>

**PUBLISHER**  
Baishideng Publishing Group Inc  
8226 Regency Drive,  
Pleasanton, CA 94588, USA  
Telephone: +1-925-223-8242  
Fax: +1-925-223-8243  
E-mail: [bpgoffice@wjgnet.com](mailto:bpgoffice@wjgnet.com)  
Help Desk: <http://www.wjgnet.com/csp/helpdesk.aspx>

<http://www.wjgnet.com>

**PUBLICATION DATE**  
November 16, 2014

**COPYRIGHT**  
© 2014 Baishideng Publishing Group Inc. Articles published by this Open Access journal are distributed under the terms of the Creative Commons Attribution Non-commercial License, which permits use, distribution, and reproduction in any medium, provided the original work is properly cited, the use is non commercial and is otherwise in compliance with the license.

**SPECIAL STATEMENT**  
All articles published in journals owned by the Baishideng Publishing Group (BPG) represent the views and opinions of their authors, and not the views, opinions or policies of the BPG, except where otherwise explicitly indicated.

**INSTRUCTIONS TO AUTHORS**  
Full instructions are available online at [http://www.wjgnet.com/2307-8960/g\\_info\\_20100722180909.htm](http://www.wjgnet.com/2307-8960/g_info_20100722180909.htm)

**ONLINE SUBMISSION**  
<http://www.wjgnet.com/csp/>



## Important of case-reports/series, in rare diseases: Using neuroendocrine tumors as an example

Taichi Nakamura, Hisato Igarashi, Tetsuhide Ito, Robert T Jensen

Taichi Nakamura, Robert T Jensen, Cell Biology Section, NIDDK, National Institutes of Health, Bethesda, Maryland, MD 20814, United States

Hisato Igarashi, Tetsuhide Ito, Department of Medicine and Bioregulatory Science, Kyushu University, Fukuoka 812-8581, Japan

**Author contributions:** All authors contributed to all phases of the paper including the formulation of the ideas, writing, literature research and proofing the final paper.

**Supported by** Intramural Research Funds of NIDDK, NIH

**Correspondence to:** Dr. Robert T Jensen, Cell Biology Section, NIDDK, National Institutes of Health, 10 Center Dr., Bldg. 10, Room 9C103, Bethesda, Maryland, MD 20814, United States. [robertj@bdg10.nidk.nih.gov](mailto:robertj@bdg10.nidk.nih.gov)

**Telephone:** +1-301-4964201 **Fax:** +1-301-4020600

**Received:** June 30, 2014 **Revised:** September 3, 2014

**Accepted:** September 16, 2014

**Published online:** November 16, 2014

**Key words:** Case report; Case series; Neuroendocrine tumors; Carcinoids; Pancreatic neuroendocrine tumor

**Core tip:** A review of neuroendocrine tumors, which are rare diseases, strongly supports the prominent role and value of reporting of rare cases or small case series in uncommon disorders.

Nakamura T, Igarashi H, Ito T, Jensen RT. Important of case-reports/series, in rare diseases: Using neuroendocrine tumors as an example. *World J Clin Cases* 2014; 2(11): 608-613 Available from: URL: <http://www.wjgnet.com/2307-8960/full/v2/i11/608.htm> DOI: <http://dx.doi.org/10.12998/wjcc.v2.i11.608>

### Abstract

At present the publishing of case reports or case series involving small numbers of cases is controversial. While in the past they were commonly published by most journals, recently a number of prominent journals have either stopped publishing them or markedly reduced the numbers published. However, recently an increasing case is being made for their value and a number of new journals have been started devoted specifically to their publication. One of the arguments used for their value is their prominent role in rare diseases either in their recognition, full description or development of treatments. However this aspect has not been specifically studied. In this editorial this aspect is specifically examined using their role in neuroendocrine tumors as an example. Furthermore, the background of the controversy is briefly reviewed to better understand the context of this editorial.

Case reports (1 patient) or case series (> 1 patient) reporting are not without controversy: held in high regard by some<sup>[1-4]</sup> and looked down on by others as occupying the lowest rung in the evidence pyramid hierarchy<sup>[5-10]</sup>. It is necessary to understand a little more of this controversy to understand why this editorial is being written, which will be covered briefly in the next paragraph. The purpose of this editorial is to demonstrate, how in the case of an uncommon disease, such as clinically important gastrointestinal (GI) neuroendocrine tumors [carcinoids (incidence-7-13 cases/million per year) and pancreatic neuroendocrine tumors (pNETs) (incidence-1-5 cases/million per year)]<sup>[11,12]</sup>, case reports and case series reports have played, and are still playing, a vital and essential role in their recognition and also management/treatment.

Case or case series reports are controversial because an increasing number of prominent journals, starting in the 1980's no longer regularly published them<sup>[9,13,14]</sup>. In a survey in 1979<sup>[15]</sup> of three prominent medical journals (NEJM, JAMA, Lancet) of articles published between 1946-1974, the frequency of case reports/series (< 10 patients) remained unchanged, at 38% of all articles.

However, analyzing the same journals from 1971-1991<sup>[14]</sup>, found that case reports/series frequency, as a percentage of all articles, decreased 86% from 30% to 4% of all articles, replaced by an increase in primarily clinical trials and other evidence based medicine (EBM) reports [randomized clinical trials (RCT), *etc.*]. In another study in 2006<sup>[16]</sup> of 25 journals covering various aspect of medicine, only 32% regularly published case reports/series and 33% never published them. Furthermore, other publications including areas as diverse as psychiatry and anesthesia, found that journals prominent in their field, either stopping reporting case reports/series or only infrequently published them<sup>[5,9,10,13]</sup>. This change in policy is generally attributed primarily to two factors: a general conclusion that case reports/series represent a lower level of evidence [compared to randomized clinical trials (RCT), systematic reviews, meta-analyses, cohort studies, case control studies]<sup>[6,10]</sup> and the rise of the importance of impact factors (IF)<sup>[6,10]</sup>.

In general case reports/series are ranked as providing one of the lowest levels (Level 3) in the evidence based hierarchy<sup>[2,6,9,10]</sup>. They have a denominator of only one (or a small number); the results can not be used for predictive value, and they can be notoriously affected by publication bias<sup>[6,10,17,18]</sup>. For example, one study<sup>[17]</sup> demonstrated in a review of case reports/series, successes were reported in 90% and failures in only 10%. It has been stated that nearly all discarded once-popular therapies were likely supported by a series of favorable cases<sup>[18]</sup>. Over the last few years, the impact factor of journals (which is determined by the citation rate) is assuming increasing importance. This is occurring because, not only is it widely used as a measure of a journal's quality, which can not only have an economic influence on the journal and the quality of the papers submitted, but also have an affect on authors, because it is increasingly used in assessing an individual's academic credentials in terms of assessing quality of publications for possible placement, promotion or other advancement<sup>[6,9,10]</sup>. The problem here is that case reports/series are generally cited less than evidence-based medicine (EBM) articles with the result they can decrease the IF of the journal<sup>[2,6,8-10,19]</sup>. This is well shown in a 2005 study<sup>[8]</sup> comparing the impact factor of various types of articles (2646 articles published in 1991, 2001). This study<sup>[8]</sup> showed case reports were the most poorly cited compared to EBM studies (meta-analysis, RCTs, epidemiological studies, case control studies). Similar results were found in a study assessing the citation rate in 2008 of papers published in *Am J Medical Genetics*, Part A in 2006, which found that the non-citation rate was 2.3 fold higher in the case reports/series than in EBM articles, and the citation rate in the case reports/series was not > 6 citations for any article, whereas in the EBM articles, many had rates higher than this.

While the presence of these negative factors discussed above, might be assumed to be leaving the case report/series in its terminal throes, in the last few years an increasing argument in their defense has been made

by many<sup>[1-3,6,7,17,19-21]</sup> and for its restoration, as a prominent and useful medical reporting method. This is evidenced by both the recent appearance of numerous publications devoted to case reports/series such as the *World J of Clinical Cases*, as well as the re-institution of the case report/series format in some prominent journals<sup>[19,20,22]</sup>. One study<sup>[17]</sup> assessed one aspect of the re-inclusion of case reports into the journal *Lancet*<sup>[20]</sup> by studying the impact of case reports/series of innovative treatments reported in 1995/1996. This approach was taken because it is recognized that for a clinical study to be funded, evidence must be provide that proposed treatments may have merit, and case reports/series are often the first line of such evidence<sup>[17]</sup>. Of the 64 cases reports and 39 case series identified, it was found the cases were clearly read because they had an average citation rate of 17 times (range 0-336), and they also affect subsequent approaches because 22% of the cases lead to followup trials (9%-controlled trials)<sup>[17]</sup>. Other important points raised in their defense include that case reports/series: have a long tradition in teaching in medicine; they often report and establish the cause of various disorders with few observations; they provide the clinical foundation for postulating the possible pathogenesis of disorders; for therapies they are often the first evidence of the effectiveness of a new therapy, as well as often the major source of initially reporting adverse effects of different therapies; are an important teaching, education and career vehicle for young physicians (students, residents, fellows, starting faculty) to publish and contribute to the medical literature; and are important in recognizing new diseases, particularly in the case of rare diseases or rare variations of more common diseases<sup>[2,6,10,17,19,21-23]</sup>. While numerous articles have mentioned the importance of case reports/series reporting in rare diseases, this point has not been specifically examined and emphasized. It occurred to us that the study of GI-NETs (carcinoids, pNETs) offers a very good example of this assertion and thus will be briefly reviewed here and in Table 1.

Both GI- carcinoids and pNETs are classified as neuroendocrine tumors (NETs)<sup>[24-26]</sup> and although they have a different pathogenesis, they share similar histological features, aspects of their biological behavior, and many features of their management including localization methods, treatment approaches, and their abilities to be associated with hormonal-excess states due to ectopic production of biologically active substances<sup>[24,25,27-29]</sup>. There are 10 well-established pNET syndromes of which 9 are associated with specific hormone excess syndromes [Gastrinomas; insulinomas; VIPomas; glucagonomas; somatostatinomas; GRFomas; pancreatic ACTHomas; pNETs causing carcinoid syndrome, or hypercalcemia and nonfunctional pNETs (NF-pNETs)]<sup>[11,26]</sup>. In addition to these 10 established pNET syndromes there are 5 other very rare (< 5 cases reported) syndromes associated with pNETs<sup>[26]</sup>, which also likely represent a functional pNET syndrome. These include: pNETs secreting erythropoietin causing erythroblastosis<sup>[30]</sup>; pNETs secreting

**Table 1 Sentinel case reports/series defining syndromes of disease aspects in patients with gastrointestinal neuroendocrine tumors**

Year	Author	Pt#	Type of report	Syndrome	Importance	Ref.
1890	Ranson	1	Case report	Carcinoid	First description of ileal carcinoid	[50]
1902	Nichols	1	Case report	Insulinoma	First islet tumor	[49]
1922	Banting <i>et al</i>	7	Case report	Insulin treatment diabetes	Extracted insulin and effectiveness of insulin therapy in diabetes mellitus demonstrated.	[51]
1924	Harris <i>et al</i>	3	Case report	Insulinoma	1 <sup>st</sup> postulate the possibility of insulinoma in his patients	[37]
1927	Wilder <i>et al</i>	1	Case report	Insulinoma	1 <sup>st</sup> pNET syndrome (insulinoma). Extracting insulin from malignant pNET operated by WJ Mayo	[62]
1938	Whipple	Case review	Case review	Insulinoma	Diagnostic triad for insulinoma proposed	[52]
1942	Becker <i>et al</i>	2	Case report	Glucagonoma	First description of Glucagonoma in a patient with skin rash later found to have pNET	[38]
1950	Del Castillo <i>et al</i>	1	Case report	Cushing syndrome	First pNET associated with Cushing syndrome	[39]
1954	Thorson <i>et al</i>	16	Case series review	Carcinoid syndrome	First described a series of patients with small intestinal carcinoids, establishing the clinical entity "carcinoid syndrome"	[48]
1955	Zollinger <i>et al</i>	2	Case report	ZES	First description of ZES (gastrinoma)	[40]
1957	Priest <i>et al</i>	1	Case report	VIPoma	Recognition of WDHA syndrome (VIPoma) with pNET	[41]
1958	Verner <i>et al</i>	2	Case report	VIPoma	First complete description of all features WDHA from review/2 personal cases and 7 literature cases	[63]
1966	McGavran <i>et al</i>	1	Case report	Glucagonoma	Reported case of pNET with hyperglucagonemia and glucose elevation	[54]
1971,3	Wilkinson	1	Case report	Glucagonoma	Proposed term "NME" to describe rash in glucagonoma.	[55,56]
1974	Mallinson <i>et al</i>	9	Case series review	Glucagonoma	Reviewed pNET secreting glucagon and called attention to their association with necrotic migratory erythema (NME)	[57]
1977	Larsson <i>et al</i>	2	Case report	Somatostatinoma	Initial case of pNET producing somatostatin with symptoms	[42]
1977	Ganda <i>et al</i>	1	Case report	Somatostatinoma	Initial case of pNET producing somatostatin with diabetes	[43]
1978	Caplan <i>et al</i>	1	Case report	GRFoma	1st case of pNET secreting growth hormone-like substance with acromegaly	[46]
1979	Krejs <i>et al</i>	1	Case report	Somatostatinoma	Clinical features of somatostatinoma syndrome described and full endocrine characterization	[44]
1982	Guillemin <i>et al</i>	1	Biochemistry	GRFoma	Isolation of growth-hormone releasing factor (GRF) from patient with acromegaly with pNET	[45]
1982	Rivier <i>et al</i>	1	Case report	GRFoma		[64]
1982	Ruddy <i>et al</i>	1	Case report	Reninoma	First description of renin secreting pancreatic tumor causing symptoms	[31]
2004	Samyn <i>et al</i>	1	Case report	EPoma	Description of pNET secreting erythropoietin with syndrome	[30]
2004	Brignardello <i>et al</i>	1	Case report	LHoma	Description of pNET secreting luteinizing hormone with syndrome	[35]
2008	Chung <i>et al</i>	1	Case report	IGF-2oma	First report of pNET secreting IGF-2 with symptoms	[33]
2012	Roberts <i>et al</i>	1	Case report	GLP-1oma	First description of pNET secreting GLP-1 causing symptoms	[32]
2013	Rehfeld <i>et al</i>	1	Case report	CCKoma	First description of CCK secreting pNET with syndrome	[47]

CCKoma: pNET secreting cholecystokinin; EPoma: pNET secreting erythropoietin; GRFoma: pNET secreting Growth Hormone Releasing Factor; IGF-1oma/IGF-2oma: pNET secreting insulin-like growth factor 1 or 2; LHoma: pNET secreting luteinizing hormone; NET: Neuroendocrine tumor; NME: Necrolytic migratory erythema (skin rash) seen in glucagonoma cases; pNET: Pancreatic neuroendocrine tumor; Reninoma: pNET secreting renin; Somatostatinoma: pNET secreting somatostatin; VIPoma: pNET secreting vasoactive intestinal peptide; WDHA: Watery diarrhea, hypokalemia and achlorhydria which are features seen in VIPoma patients; ZES: Zollinger-Ellison syndrome due to ectopic secretion of gastrin by a gastrinoma causing acid hypersecretion.

renin causing hypertension<sup>[31]</sup>; pNETs secreting GLP-1 or GLP-2 causing hypoglycemia<sup>[32,33]</sup> and pNETs secreting luteinizing hormone causing masculinization<sup>[34,35]</sup>. Although the incidence of both carcinoid tumors and pNETs is increasing, they are still classified as rare conditions<sup>[36]</sup>. Whereas gastrinoma, insulinoma and NF-pNETs are the most frequent pNETs, they still have an incidence < 2/million per year and are thus rare diseases (less 1 in 1500), whereas the other pNET syndromes are 1/10-1/100 less frequent<sup>[11,12,26,29]</sup>. The functional syndrome seen most frequently with GI-carcinoid tumors

is the carcinoid syndrome, characterized by flushing, diarrhea, asthma and heart disease primarily due to ectopic release of serotonin, neurokinins and perhaps other biologically active peptides<sup>[29]</sup>. The carcinoid syndrome occurs in 5%-10% of patients with carcinoid tumors and thus is also present at < 3-5/million per year and hence is also a rare disease.

As can be seen in Table 1, case reports or case series, often involving < 5 cases, played a sentinel role in most GI-NET/pNET syndromes, usually providing the initial description of the functional syndrome or in

elucidation its full clinical manifestations. Specifically, case reports/series provided the initial description of insulinoma<sup>[37]</sup>, glucagonoma<sup>[38]</sup>, pNETs causing ectopic Cushing's syndrome<sup>[39]</sup>, gastrinoma causing the Zollinger-Ellison syndrome<sup>[40]</sup>, the VIPoma (WDHA) syndrome<sup>[41]</sup>, somatostatinoma and somatostatinoma syndrome<sup>[42-44]</sup>, GRFoma<sup>[45,46]</sup>, pNETs secreting renin<sup>[31]</sup>, pNETs secreting erythropoietin<sup>[30]</sup>, pNETs secreting luteinizing hormone<sup>[35]</sup>, pNET secreting IGF-2 (IGF-2oma)<sup>[33]</sup>, pNETs seeing IGF-1 (IGF-1oma)<sup>[32]</sup>, and CCKoma<sup>[47]</sup>. The initial description of the carcinoid syndrome, seen in patients with metastatic carcinoid tumors to the liver (usually ileal-jejunal-midgut tumors) was described also in a case series<sup>[48]</sup>. The sentinel role of some case reports was recognized by naming the syndrome after the initial case description such as the Verner Morrison syndrome (VIPoma-WDHA) and the Zollinger-Ellison syndrome (gastrinoma). Some of the case reports/series played other sentinel roles. These include the first description of a pNET in a report of one patient<sup>[49]</sup>; the first description of an ileal carcinoid in one case<sup>[50]</sup>; the initial use of insulin for diabetes in a case series by Banting<sup>[50]</sup> and the initial description of the clinical triad that is commonly used, even today, to suspect the diagnosis of insulinoma<sup>[26,28,52]</sup> was in a case series review, and is now referred to as Whipple's triad after this sentinel paper<sup>[53]</sup>. Some case reports/series were not the first to report a new syndrome, but played an important role in defining the spectrum of the syndrome by describing additional features of the rare pNET syndrome. This is illustrated by case reports describing the full features of the VIPoma syndrome (diarrhea, hypokalemia, achlorhydria, hypercalcemia, not associated with peptic ulcer disease or gastric hypersecretion)<sup>[11,26]</sup>, after the initial report of a nonbeta cell islet tumor (pNET) associated with large volume diarrhea causing hypokalemia<sup>[41]</sup>. Similarly additional case reports/case series after the initial description of the glucagonoma syndrome (pNET with skin rash)<sup>[38]</sup>, described the association of a pNET with hyperglycemia and hyperglucagonemia<sup>[54]</sup>, and emphasized its association with a characteristic skin rash, which was named necrolytic migratory erythema (NME)<sup>[55-57]</sup>, and which was sufficiently distinctive to become one of the main features leading to the diagnosis of glucagonomas, even at present<sup>[11,26,28,58]</sup>. Lastly, this is also the case with the somatostatinoma syndrome which was first proposed in 1977 with the description of a somatostatin secreting pNET<sup>[42]</sup>, whereas the full clinical features we generally recognize today [diabetes mellitus, cholelithiasis, steatorrhea, weight loss hypo/achlorhydria, anemia]<sup>[11,26,58]</sup>, were later described in another case report<sup>[44]</sup>. This latter finding, illustrates another important role of case reports/case series not only in rare disorders, but also in common disorders<sup>[2,3,10,19,21,59]</sup>, by reporting an uncommon feature of a common disorder or, in our case, an additional feature of a previously described, uncommon disorder.

Another conclusion that can be drawn from the findings in pNETs illustrated in Table 1 is that case reports/

series have had a prominent role in GI-NETs for longer than one century, and are still playing a prominent role. This is illustrated by the descriptions of numerous new pNET functional syndromes since 2000 (Table 1) with the most recent being a case report of a patient with a cholecystokinin secreting tumor syndrome (CCKoma)<sup>[47]</sup>. The CCKoma syndrome clinically included diarrhea, severe weight loss, advanced peptic ulcer disease, cholelithiasis, all of which can be explained by the known actions of CCK expected from the profound hyperCCK-emia this patient had (1000-fold increased)<sup>[47]</sup>. At present it remains unknown whether this is a very rare syndrome, which has long evaded description, or whether it is more frequent and might be responsible for patients presenting with ZES-like feature, but with normal serum gastrin levels<sup>[47,60,61]</sup>.

In conclusion, a review of the role of case reports/case series in the description and establishment of the GI-NET syndromes strongly support their importance in this rare group of diseases and supports the proposal that they can play a particularly important role in any rare disease<sup>[2,6,10,17,19,21-23]</sup>. The use of case reports/case series has not only provided many of the original descriptions of these rare GI-NET syndromes, they have provided other features leading to treatments as well as full characterization of aspects of the syndromes. Case reports/small series have been important throughout the last century in the elucidation of these rare syndromes and are as important today, as they were in the past.

## REFERENCES

- 1 **Vandenbroucke JP.** In defense of case reports and case series. *Ann Intern Med* 2001; **134**: 330-334 [PMID: 11182844]
- 2 **Carey JC.** The importance of case reports in advancing scientific knowledge of rare diseases. *Adv Exp Med Biol* 2010; **686**: 77-86 [PMID: 20824440 DOI: 10.1007/978-90-481-9485-8\_5]
- 3 **Mahajan RP, Hunter JM.** Volume 100: Case reports: should they be confined to the dustbin? *Br J Anaesth* 2008; **100**: 744-746 [PMID: 18483112 DOI: 10.1093/bja/aen128]
- 4 **Mason RA.** The case report—an endangered species? *Anaesthesia* 2001; **56**: 99-102 [PMID: 11167467]
- 5 **Buckley O, Torreggiani WC.** The demise of the case report. *AJR Am J Roentgenol* 2007; **189**: W54-W55 [PMID: 17646437 DOI: 10.2214/AJR.07.2203]
- 6 **Albrecht J, Werth VP, Bigby M.** The role of case reports in evidence-based practice, with suggestions for improving their reporting. *J Am Acad Dermatol* 2009; **60**: 412-418 [PMID: 19231639 DOI: 10.1016/j.jaad.2008.10.023]
- 7 **Hoffman JR.** Rethinking case reports. *West J Med* 1999; **170**: 253-254 [PMID: 10379213]
- 8 **Patsopoulos NA, Analatos AA, Ioannidis JP.** Relative citation impact of various study designs in the health sciences. *JAMA* 2005; **293**: 2362-2366 [PMID: 15900006 DOI: 10.1001/jama.293.19.2362]
- 9 **Nissen T, Wynn R.** The recent history of the clinical case report: a narrative review. *JRSM Short Rep* 2012; **3**: 87 [PMID: 23476729 DOI: 10.1258/shorts.2012.012046]
- 10 **Carey JC.** A species not extinct: publication of case reports and scientific knowledge. *Am J Med Genet A* 2006; **140A**: 801-803 [DOI: 10.1002/ajmg.a.31176]
- 11 **Metz DC, Jensen RT.** Gastrointestinal neuroendocrine



- tumors: pancreatic endocrine tumors. *Gastroenterology* 2008; **135**: 1469-1492 [PMID: 18703061 DOI: 10.1053/j.gastro.2008.05.047]
- 12 **Fraenkel M**, Kim MK, Faggiano A, Valk GD. Epidemiology of gastroenteropancreatic neuroendocrine tumours. *Best Pract Res Clin Gastroenterol* 2012; **26**: 691-703 [PMID: 23582913 DOI: 10.1016/j.bpg.2013.01.006]
- 13 **Wilkinson G**. Fare thee well-the Editor's last words. *Br J Psych* 2003; **182**: 465-466 [DOI: 10: 1192/Farewell]
- 14 **McDermott MM**, Lefevre F, Feinglass J, Reifler D, Dolan N, Potts S, Senger K. Changes in study design, gender issues, and other characteristics of clinical research published in three major medical journals from 1971 to 1991. *J Gen Intern Med* 1995; **10**: 13-18 [PMID: 7699481]
- 15 **Fletcher RH**, Fletcher SW. Clinical research in general medical journals: a 30-year perspective. *N Engl J Med* 1979; **301**: 180-183 [PMID: 377076 DOI: 10.1056/NEJM197907263010403]
- 16 **Carey JC**. Significance of case reports in the advancement of medical scientific knowledge. *Am J Med Genet A* 2006; **140**: 2131-2134 [PMID: 16964619 DOI: 10.1002/ajmg.a.31449]
- 17 **Albrecht J**, Meves A, Bigby M. Case reports and case series from Lancet had significant impact on medical literature. *J Clin Epidemiol* 2005; **58**: 1227-1232 [PMID: 16291466]
- 18 **Moses LE**. The series of consecutive cases as a device for assessing outcomes of intervention. *N Engl J Med* 1984; **311**: 705-710 [PMID: 6472357 DOI: 10.1056/NEJM198409133111104]
- 19 **Agha R**, Rosin RD. Time for a new approach to case reports. *Int J Surg* 2010; **8**: 330-332 [PMID: 20470911 DOI: 10.1016/j.ijsu.2010.05.003]
- 20 **Biggall J**, Horton R. Learning from stories--The Lancet's case reports. *Lancet* 1995; **346**: 1246 [PMID: 7475714]
- 21 **Vandenbroucke JP**. Case reports in an evidence-based world. *J R Soc Med* 1999; **92**: 159-163 [PMID: 10450190]
- 22 **Cabán-Martínez AJ**, Beltrán WF. Advancing medicine one research note at a time: the educational value in clinical case reports. *BMC Res Notes* 2012; **5**: 293 [PMID: 22697904 DOI: 10.1186/1756-0500-5-293]
- 23 **Jenicek M**. Clinical case reports and case series research in evaluating surgery. Part II. The content and form: uses of single clinical case reports and case series research in surgical specialties. *Med Sci Monit* 2008; **14**: RA149-RA162 [PMID: 18830205]
- 24 **Klimstra DS**. Pathology reporting of neuroendocrine tumors: essential elements for accurate diagnosis, classification, and staging. *Semin Oncol* 2013; **40**: 23-36 [PMID: 23391110 DOI: 10.1053/j.seminoncol.2012.11.001]
- 25 **Klöppel G**. Classification and pathology of gastroenteropancreatic neuroendocrine neoplasms. *Endocr Relat Cancer* 2011; **18** Suppl 1: S1-16 [PMID: 22005112 DOI: 10.1530/ERC-11-0013]
- 26 **Ito T**, Igarashi H, Jensen RT. Pancreatic neuroendocrine tumors: clinical features, diagnosis and medical treatment: advances. *Best Pract Res Clin Gastroenterol* 2012; **26**: 737-753 [PMID: 23582916 DOI: 10.1016/j.bpg.2012.12.003]
- 27 **Ito T**, Igarashi H, Jensen RT. Therapy of metastatic pancreatic neuroendocrine tumors (pNETs): recent insights and advances. *J Gastroenterol* 2012; **47**: 941-960 [PMID: 22886480 DOI: 10.1007/s00535-012-0642-8]
- 28 **Jensen RT**, Cadiot G, Brandi ML, de Herder WW, Katsas G, Komminoth P, Scoazec JY, Salazar R, Sauvanet A, Kianmanesh R. ENETS Consensus Guidelines for the management of patients with digestive neuroendocrine neoplasms: functional pancreatic endocrine tumor syndromes. *Neuroendocrinology* 2012; **95**: 98-119 [PMID: 22261919 DOI: 10.1159/000335591]
- 29 **Jensen RT**. Endocrine Tumors of the Gastrointestinal Tract and Pancreas. In: Longo DL, Fauci AS, Kasper DL, Hauser S, Jameson JJ, Loscalzo J, editors. *Harrison's Principles of Internal Medicine*. 18th ed. New York, NY: McGraw-Hill, 2012: 3056-3076
- 30 **Samyn I**, Fontaine C, Van Tussenbroek F, Pipeleers-Marichal M, De Grève J. Paraneoplastic syndromes in cancer: Case 1. Polycythemia as a result of ectopic erythropoietin production in metastatic pancreatic carcinoid tumor. *J Clin Oncol* 2004; **22**: 2240-2242 [PMID: 15169813 DOI: 10.1200/JCO.2004.10.031]
- 31 **Ruddy MC**, Atlas SA, Salerno FG. Hypertension associated with a renin-secreting adenocarcinoma of the pancreas. *N Engl J Med* 1982; **307**: 993-997 [PMID: 7050722 DOI: 10.1056/NEJM198210143071606]
- 32 **Roberts RE**, Zhao M, Whitelaw BC, Ramage J, Diaz-Cano S, le Roux CW, Quaglia A, Huang GC, Aylwin SJ. GLP-1 and glucagon secretion from a pancreatic neuroendocrine tumor causing diabetes and hyperinsulinemic hypoglycemia. *J Clin Endocrinol Metab* 2012; **97**: 3039-3045 [PMID: 22774207 DOI: 10.1210/jc.2011-2005]
- 33 **Chung JO**, Hong SI, Cho DH, Lee JH, Chung DJ, Chung MY. Hypoglycemia associated with the production of insulin-like growth factor II in a pancreatic islet cell tumor: a case report. *Endocr J* 2008; **55**: 607-612 [PMID: 18490836]
- 34 **Piaditis G**, Angellou A, Kontogeorgos G, Mazarakis N, Kounadi T, Kaltsas G, Vamvakidis K, Lloyd RV, Horvath E, Kovacs K. Ectopic bioactive luteinizing hormone secretion by a pancreatic endocrine tumor, manifested as luteinized granulosa-thecal cell tumor of the ovaries. *J Clin Endocrinol Metab* 2005; **90**: 2097-2103 [PMID: 15687346 DOI: 10.1210/jc.2003-032029]
- 35 **Brignardello E**, Manti R, Papotti M, Allia E, Campa D, Isolato G, Cassinis MC, Fronda G, Boccuzzi G. Ectopic secretion of LH by an endocrine pancreatic tumor. *J Endocrinol Invest* 2004; **27**: 361-365 [PMID: 15233557]
- 36 **Yao JC**, Hassan M, Phan A, Dagohoy C, Leary C, Mares JE, Abdalla EK, Fleming JB, Vauthey JN, Rashid A, Evans DB. One hundred years after "carcinoid": epidemiology of and prognostic factors for neuroendocrine tumors in 35,825 cases in the United States. *J Clin Oncol* 2008; **26**: 3063-3072 [PMID: 18565894 DOI: 10.1200/JCO.2007.15.4377]
- 37 **Harris S**. Hyperinsulinism and Dysinsulinism. *JAMA* 1924; **83**: 729-733
- 38 **Becker SW**, Rothman S. Cutaneous manifestations of internal malignant tumors. *Arch Derm Syph* 1942; **45**: 1069-1080
- 39 **Del Castillo EB**, Trucco E, Manzuoli J. [Cushing's disease and cancer of the pancreas]. *Presse Med* 1950; **58**: 783-785 [PMID: 15440663]
- 40 **Zollinger RM**, Ellison EH. Primary peptic ulcerations of the jejunum associated with islet cell tumors of the pancreas. *Ann Surg* 1955; **142**: 709-723; discussion 724-728 [PMID: 13259432]
- 41 **Priest WM**, Alexander MK. Isletcell tumour of the pancreas with peptic ulceration, diarrhoea, and hypokalaemia. *Lancet* 1957; **273**: 1145-1147 [PMID: 13492596]
- 42 **Larsson LI**, Hirsch MA, Holst JJ, Ingemansson S, Kühl C, Jensen SL, Lundqvist G, Rehfeld JF, Schwartz TW. Pancreatic somatostatinoma. Clinical features and physiological implications. *Lancet* 1977; **1**: 666-668 [PMID: 66472]
- 43 **Ganda OP**, Weir GC, Soeldner JS, Legg MA, Chick WL, Patel YC, Ebeid AM, Gabbay KH, Reichlin S. "Somatostatinoma": a somatostatin-containing tumor of the endocrine pancreas. *N Engl J Med* 1977; **296**: 963-967 [PMID: 321960 DOI: 10.1056/NEJM197704282961703]
- 44 **Krejs GJ**, Orci L, Conlon JM, Ravazzola M, Davis GR, Raskin P, Collins SM, McCarthy DM, Baetens D, Rubenstein A, Aldor TA, Unger RH. Somatostatinoma syndrome. Biochemical, morphologic and clinical features. *N Engl J Med* 1979; **301**: 285-292 [PMID: 377080 DOI: 10.1056/NEJM197908093010601]
- 45 **Guillemin R**, Brazeau P, Böhlen P, Esch F, Ling N, Wehrenberg WB. Growth hormone-releasing factor from a human pancreatic tumor that caused acromegaly. *Science* 1982; **218**: 585-587 [PMID: 6812220]

- 46 **Caplan RH**, Koob L, Abellera RM, Pagliara AS, Kovacs K, Randall RV. Cure of acromegaly by operative removal of an islet cell tumor of the pancreas. *Am J Med* 1978; **64**: 874-882 [PMID: 206142]
- 47 **Rehfeld JF**, Federspiel B, Bardram L. A neuroendocrine tumor syndrome from cholecystokinin secretion. *N Engl J Med* 2013; **368**: 1165-1166 [PMID: 23514309 DOI: 10.1056/NEJMc1215137]
- 48 **Thorson A**, Biorck G, Bjorkman G, Waldenstrom J. Malignant carcinoid of the small intestine with metastases to the liver, valvular disease of the right side of the heart (pulmonary stenosis and tricuspid regurgitation without septal defects), peripheral vasomotor symptoms, bronchoconstriction, and an unusual type of cyanosis; a clinical and pathologic syndrome. *Am Heart J* 1954; **47**: 795-817 [PMID: 13158264]
- 49 **Nichols AG**. Simple adenoma of the pancreas arising from an island of langerhans. *J Med Res* 1902; **8**: 385-395
- 50 **Ranson WB**. A case of primary carcinoma of the ileum. *Lancet* 1890; **ii**: 1020-1023
- 51 **Banting FG**, Best CH, Collip JB, Campbell WR, Fletcher AA. Pancreatic Extracts in the Treatment of Diabetes Mellitus. *Can Med Assoc J* 1922; **12**: 141-146 [PMID: 20314060]
- 52 **Whipple AO**. The surgical therapy of hyperinsulinism. *J Int Chir* 1938; **3**: 237-247
- 53 **Cryer PE**, Axelrod L, Grossman AB, Heller SR, Montori VM, Seaquist ER, Service FJ. Evaluation and management of adult hypoglycemic disorders: an Endocrine Society Clinical Practice Guideline. *J Clin Endocrinol Metab* 2009; **94**: 709-728 [PMID: 19088155 DOI: 10.1210/jc.2008-1410]
- 54 **McGavran MH**, Unger RH, Recant L, Polk HC, Kilo C, Levin ME. A glucagon-secreting alpha-cell carcinoma of the pancreas. *N Engl J Med* 1966; **274**: 1408-1413 [PMID: 4286757 DOI: 10.1056/NEJM196606232742503]
- 55 **Wilkinson DS**. Necrolytic migratory erythema with carcinoma of the pancreas. *Trans St Johns Hosp Dermatol Soc* 1973; **59**: 244-250 [PMID: 4793623]
- 56 **Wilkinson DS**. Necrolytic migratory erythema with pancreatic carcinoma. *Proc R Soc Med* 1971; **64**: 1197-1198 [PMID: 5131260]
- 57 **Mallinson CN**, Bloom SR, Warin AP, Salmon PR, Cox B. A glucagonoma syndrome. *Lancet* 1974; **2**: 1-5 [PMID: 4134714]
- 58 **Kulke MH**, Anthony LB, Bushnell DL, de Herder WW, Goldsmith SJ, Klimstra DS, Marx SJ, Pasieka JL, Pommier RF, Yao JC, Jensen RT. NANETS treatment guidelines: well-differentiated neuroendocrine tumors of the stomach and pancreas. *Pancreas* 2010; **39**: 735-752 [PMID: 20664472 DOI: 10.1097/MPA.0b013e3181ebb168]
- 59 **Juyal D**, Thaledi S, Thawani V. Writing patient case reports for publication. *Educ Health (Abingdon)* 2013; **26**: 126-129 [PMID: 24200736 DOI: 10.4103/1357-6283.120707]
- 60 **Berna MJ**, Hoffmann KM, Serrano J, Gibril F, Jensen RT. Serum gastrin in Zollinger-Ellison syndrome: I. Prospective study of fasting serum gastrin in 309 patients from the National Institutes of Health and comparison with 2229 cases from the literature. *Medicine (Baltimore)* 2006; **85**: 295-330 [PMID: 17108778 DOI: 10.1097/01.md.0000236956.74128.76]
- 61 **Jensen RT**, Niederle B, Mitry E, Ramage JK, Steinmuller T, Lewington V, Scarpa A, Sundin A, Perren A, Gross D, O'Connor JM, Pauwels S, Kloppel G. Gastrinoma (duodenal and pancreatic). *Neuroendocrinology* 2006; **84**: 173-182 [PMID: 17312377 DOI: 10.1159/000098009]
- 62 **Wilder RM**, Allan FN, Power WH, Robertson HE. Carcinoma of the islands of the pancreas: hyperinsulinism and hypoglycemia. *JAMA* 1927; **89**: 355.
- 63 **Verner JV**, Morrison AB. Islet cell tumor and a syndrome of refractory watery diarrhea and hypokalemia. *Am J Med* 1958; **25**: 374-380 [PMID: 13571250]
- 64 **Rivier J**, Spiess J, Thorner M, Vale W. Characterization of a growth hormone-releasing factor from a human pancreatic islet tumour. *Nature* 1982; **300**: 276-278 [PMID: 6292724]

**P- Reviewer:** Basu S, Morris-Stiff G, Pritchard DM, Rehman HU, Sun LC **S- Editor:** Ji FF **L- Editor:** A **E- Editor:** Lu YJ



## Evolution of endovascular mechanical thrombectomy for acute ischemic stroke

Colin J Przybylowski, Dale Ding, Robert M Starke, Christopher R Durst, R Webster Crowley, Kenneth C Liu

Colin J Przybylowski, Dale Ding, Robert M Starke, R Webster Crowley, Kenneth C Liu, Department of Neurological Surgery, University of Virginia, Charlottesville, VA 22908, United States

Christopher R Durst, Department of Radiology and Medical Imaging, University of Virginia, Charlottesville, VA 22908, United States

**Author contributions:** All authors contributed equally to this work including conception, design, and article drafting; final manuscript version approved by Liu KC.

**Correspondence to:** Kenneth C Liu, MD, Department of Neurological Surgery, University of Virginia, PO Box 800212, Charlottesville, VA 22908, United States. [kenneth.c.liu@virginia.edu](mailto:kenneth.c.liu@virginia.edu)

Telephone: +1-434-9242735 Fax: +1-434-9249656

Received: May 14, 2014 Revised: July 11, 2014

Accepted: September 17, 2014

Published online: November 16, 2014

### Abstract

Acute ischemic stroke (AIS) is a common medical problem associated with significant morbidity and mortality worldwide. A small proportion of AIS patients meet eligibility criteria for intravenous thrombolysis (IVT) with recombinant tissue plasminogen activator, and its efficacy for large vessel occlusion is poor. Therefore, an increasing number of patients with AIS are being treated with endovascular mechanical thrombectomy when IVT is ineffective or contraindicated. Rapid advancement in catheter-based and endovascular device technology has led to significant improvements in rates of cerebral reperfusion with these devices. Stentrievors and modern aspiration catheters have now surpassed earlier generation devices in the degree and rapidity of revascularization. This progress has been achieved with no concurrent increase in risk of major complications or mortality, both when used alone or in combination with IVT. The initial randomized controlled trials comparing endovascular therapy to IVT for AIS failed to show superior outcomes with endovascular treatment, but

key limitations of each trial may limit the significance of these results to current practice. While endovascular devices and operator experience continue to evolve, we are optimistic that this will be accompanied by improvements in patient outcomes. This review highlights the major endovascular devices used in current practice and the trials which have investigated their efficacy.

© 2014 Baishideng Publishing Group Inc. All rights reserved.

**Key words:** Cerebral infarction; Endovascular procedures; Intracranial hemorrhages; Stents; Stroke

**Core tip:** This review discusses the critical advancements in endovascular device technology for the treatment of acute ischemic stroke. Endovascular mechanical thrombectomy is becoming an increasingly utilized treatment approach for patients in whom intravenous thrombolysis with recombinant tissue plasminogen activator is ineffective or contraindicated. While three recent randomized controlled trials found no benefit of endovascular thrombectomy over intravenous therapy, it is important for clinicians to understand the limitations of these trials and recognize the expected key role of endovascular therapy in the future management of stroke patients.

Przybylowski CJ, Ding D, Starke RM, Durst CR, Crowley RW, Liu KC. Evolution of endovascular mechanical thrombectomy for acute ischemic stroke. *World J Clin Cases* 2014; 2(11): 614-622 Available from: URL: <http://www.wjgnet.com/2307-8960/full/v2/i11/614.htm> DOI: <http://dx.doi.org/10.12998/wjcc.v2.i11.614>

### INTRODUCTION

The annual incidence of stroke in the United States is approximately 795000<sup>[1]</sup>. Stroke is the second leading cause of lost disability-adjusted life-years in high-income

**Table 1 Summary of endovascular mechanical thrombectomy devices**

Device	Manufacturer	Mechanism
Merci retriever	Concentric Medical	Thrombus retrieved with helical snare
Penumbra system	Penumbra Inc.	Thromboaspiration
Solitaire FR	eV3 Endovascular	Thrombus incorporated into struts of deployed stent
Trevo Pro	Stryker neurovascular	Thrombus incorporated into struts of deployed stent

countries and the second most common cause of mortality worldwide<sup>[2,3]</sup>. Approximately 80% of strokes are ischemic and 20% are hemorrhagic<sup>[4]</sup>. Acute ischemic stroke (AIS) is caused by a focal interruption of cerebral blood flow, most commonly due to occlusion of a major cerebral artery by local thrombosis or embolus. The resulting ischemia leads to tissue damage through a complex pathophysiological response of excitotoxicity, perinfarction depolarization, inflammation and apoptosis<sup>[5]</sup>.

The goal of therapy for AIS is to achieve cerebral reperfusion before neurological damage becomes irreversible. The correlation between vessel recanalization and favorable neurological outcome is well-studied<sup>[6,7]</sup>, although additional factors such as stroke severity and age are also likely to have a significant impact on clinical outcome<sup>[8,9]</sup>. Currently, the only FDA-approved treatment with level 1 evidence for AIS is intravenous thrombolysis (IVT) with recombinant tissue plasminogen activator (alteplase) within three hours of symptom onset<sup>[10]</sup>. Additional trials have demonstrated that extending this time window to 4.5 h is beneficial in appropriately selected patients<sup>[11,12]</sup>. However, few patients (< 10%) meet eligibility criteria for this therapy<sup>[13-15]</sup>. Additionally, larger and more proximally-located thrombi may be relatively resistant to IVT<sup>[16-21]</sup>. Successful recanalization of large vessel occlusion (LVO) with IVT alone is infrequent, ranging from 10% in internal carotid artery (ICA) occlusions to 30% in middle cerebral artery occlusions, and IVT is associated with a risk of systemic and intracerebral hemorrhage (ICH)<sup>[22]</sup>.

These limitations have led to the exploration of alternative or complementary treatment approaches for AIS. Endovascular mechanical thrombectomy has developed over the past decade as a safe and effective intervention. Rapid advancement in catheter-based and endovascular device technology has led to an increasing number of patients with AIS being treated when IVT is ineffective or contraindicated<sup>[14]</sup>. Here, we review the evolution of endovascular mechanical thrombectomy devices for the treatment of AIS.

## ENDOVASCULAR MECHANICAL THROMBECTOMY

Endovascular treatment of AIS began with intra-arterial (IA) infusion of thrombolytic agents. Several studies investigating these therapies reported favorable rates of vessel recanalization and neurological outcomes<sup>[23-25]</sup>. Given the relatively favorable risk to benefit profiles of current mechanical thrombectomy devices, IA thrombolysis

is infrequently used in modern endovascular AIS therapy. This was followed by the implementation of balloon angioplasty and microwire techniques to mechanically disrupt thromboemboli<sup>[26,27]</sup>. Additionally, intracranial stents were shown to be effective at restoring blood flow when deployed within an occluded vessel<sup>[28,29]</sup>.

Endovascular retrieval devices were first developed to recover errant coils and other foreign bodies that had embolized within the cerebral circulation during endovascular procedures<sup>[30-32]</sup>. The development of devices to remove occlusive thromboemboli was thus a natural extension of pre-existing technology. Endovascular mechanical thrombectomy involves physical extraction of the thrombus through a catheter. Due to the anatomical limitations imposed by vascular anatomy on currently available thrombectomy catheters, thrombi in large ICA, the Circle of Willis and the first two branches of the anterior (A1 and A2), middle (M1 and M2) and posterior (P1 and P2) cerebral arteries) are the most readily accessible. Smaller branches of the cerebral circulation are often too narrow and tortuous to undergo successful mechanical thrombectomy.

Alternative treatment methods for strokes from LVO are an important development, as medical management is often unsuccessful, and these strokes are associated with high rates of morbidity and mortality<sup>[25]</sup>. The two main methods of endovascular mechanical thrombectomy for LVO include: (1) physical grasping and removal of thrombi with retrieval devices and (2) aspiration of occlusive thrombi with suction devices (Table 1).

## MERCI RETRIEVER

The Merci Retriever (Concentric Medical, Mountainview, CA) was FDA-approved in August 2004 as the first clot retriever device in the United States. This device utilizes memory shaped nitinol (nickel titanium) material to convert from a straight to helical configuration to grasp the thrombus. In this procedure<sup>[33]</sup>: (1) the retriever is advanced through the thrombus in its straight configuration; (2) two to three helical loops are deployed beyond the thrombus; (3) the device is retracted to contact the thrombus, and proximal loops are deployed within the thrombus; (4) a balloon guide catheter located in the common or internal carotid artery is inflated to control intracranial blood flow; and (5) three to five clockwise rotations are performed to fully ensnare the thrombus, and the Merci Retriever-thrombus complex and microcatheter are removed together.



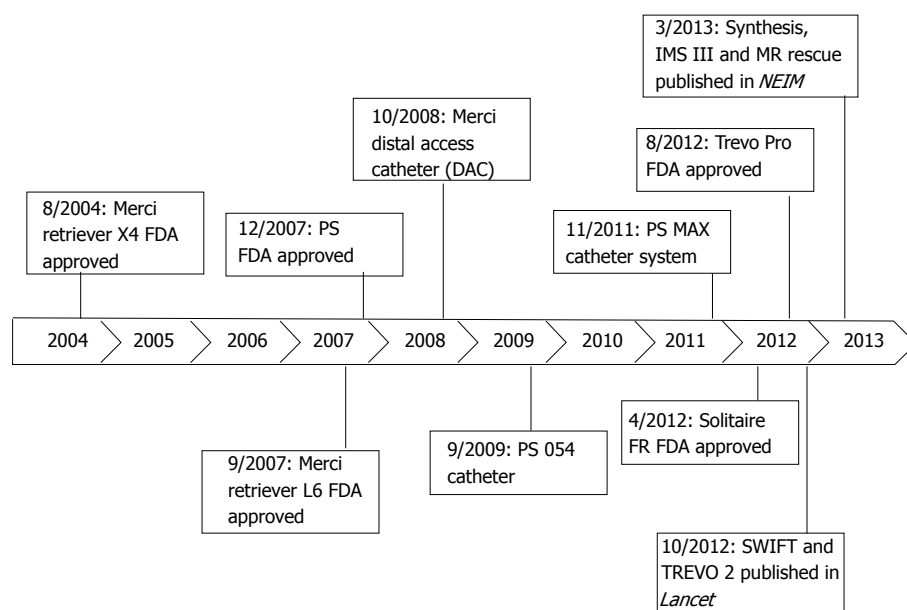


Figure 1 Timeline of FDA approval, release dates and randomized controlled trials of endovascular mechanical thrombectomy devices.

The Mechanical Embolus Removal in Cerebral Ischemia (MERCI) trial was a prospective, non-randomized, multicenter trial that first evaluated this device<sup>[34]</sup>. Recanalization, defined as Thrombolysis in Myocardial Infarction (TIMI) grade 2 or 3 flow in all treatable vessels, was achieved in 48% (68/141) of patients. Patients with recanalization had better neurological outcomes ( $P < 0.0001$ ), as determined by modified Rankin Score (mRS) of 2 or less at 90 d, and lower mortality rates ( $P = 0.01$ ) than those without recanalization, and procedure-related complication and symptomatic ICH rates were comparable to trials of IV t-PA, combined IV/intra-arterial t-PA, and intra-arterial prourokinase<sup>[10,25,35]</sup>.

Newer device generations (Figure 1) have moderately improved rates of recanalization<sup>[36]</sup>. One such advancement was the Distal Access Catheter (DAC; Concentric Medical) in 2008. The DAC has a flexible distal shaft that facilitates its navigation around the anterior genu of the ICA, beyond the origin of the ophthalmic artery<sup>[37]</sup>. This improved the navigation of the Merci Retriever through the carotid siphon with each pass, improving procedural efficiency.

## PENUMBRA SYSTEM

The Penumbra System (PS) (Penumbra Inc., Alameda, CA) was FDA-approved in December 2007 and utilizes aspiration for thrombus extraction. In this procedure<sup>[38]</sup>: (1) the PS catheter is advanced through a guide catheter to a point just proximal to the occlusion; (2) a microwire called a separator is repeatedly passed through the thrombus in order to fragment the clot; and (3) constant suction is applied to the PS catheter to aspirate the thrombus fragments.

The PS was evaluated in a prospective, multicenter study of 125 patients with National Institute of Health

Stroke Scale (NIHSS) score  $\geq 8$  who were ineligible for or refractory to IVT<sup>[38]</sup>. Recanalization (TIMI  $\geq 2$ ) was achieved in a high proportion (81.6%) of patients without significantly different complication rates than those seen in the MERCI trials. Good clinical outcome (mRS  $\leq 2$ ) was observed in 25% of patients at 30-d follow-up. More recent generations of the PS include the 054 Reperfusion catheter (2009) and the MAX Reperfusion catheter line (2011). These devices achieve greater aspiration force due to larger proximal lumens<sup>[39]</sup>. The 054 Reperfusion device was found to accomplish recanalization at a median time of 20 min<sup>[40]</sup>, significantly less than the median time of 45 min reported in the penumbra pivotal trial using previous generation technology.

## STENTRIEVER DEVICES

Stentriever utilize a retrievable stent to engage and remove the thrombus. In this procedure<sup>[41]</sup>: (1) the stentriever is advanced within a microcatheter through the thrombus until it is a few millimeters distal to the clot; (2) the stent is deployed, incorporating the thrombus into the stent struts and displacing it radially to the vascular wall; and (3) after three to five minutes, the microcatheter and stentriever are removed together under continuous proximal aspiration with a syringe. This must be performed cautiously, as at least one case of intracranial extravasation during device withdrawal has been reported<sup>[42]</sup>. It is also possible to perform a control angiogram while the stentriever is deployed, which can confirm flow restoration. However, since this may promote distal migration of thrombus fragments, the utility of performing an angiogram during stentriever deployment is controversial.

### Solitaire FR

The Solitaire FR (eV3 Endovascular, Irvine, CA) was

**Table 2 Comparison of randomized trials of endovascular thrombectomy for AIS**

Trial	Treatment arms	n	Revascularization <sup>a</sup> (%)	Good outcome <sup>bc</sup> (%)	Symptomatic ICH (%)	Mortality <sup>b</sup> (%)
SWIFT	Merci Retriever	55	67	33	11	38
	Solitaire FR	58	89	58	2	17
TREVO 2	Merci Retriever	90	60	22	2	24
	Trevo Pro	88	86	40	4	33
SYNTHESIS <sup>d</sup>	IVT	181	NR	35	6	6
	EVT	181	NR	30	6	8
IMS III	IVT	222	NR	39	6	22
	IVT + EVT	434	<sup>e</sup>	41	6	19
MR Rescue	Penumbra, IVT	34	93	26	6	21
	Penumbra, EVT	34	67	21	9	18
	Nonpenumbra, IVT	20	78	10	0	30
	Nonpenumbra, EVT	30	77	17	0	20

<sup>a</sup>Defined as TIMI or TIC1 grade  $\geq 2$ a, final revascularization rate including rescue therapies; <sup>b</sup>Assessed at 90 d unless otherwise specified; <sup>c</sup>Defined as mRS  $\leq 2$  unless otherwise specified; <sup>d</sup>This study used mRS  $\leq 1$  as the primary clinical efficacy endpoint and assessed mortality at day 7  $\pm$  2; <sup>e</sup>Reported as 65%, 81%, 70% and 77% for ICA, M1, single M2 and multiple M2 occlusions, respectively; statistically significant ( $P < 0.05$ ); SWIFT: SOLITAIRE™ with the intention for thrombectomy; TREVO 2: Thrombectomy REvascularization of Large Vessel Occlusions in Acute Ischemic Stroke; AIS: Acute ischemic stroke; IMS: Interventional Management of Stroke; IVT: Intravenous thrombolysis; ICH: Intracerebral hemorrhage; TIMI: Thrombolysis in Myocardial Infarction; TIC1: Thrombolysis in Cerebral Ischemia; mRS: Modified Rankin Score.

approved by the FDA in March 2012. Initial non-randomized case series with the Solitaire FR demonstrated high rates of recanalization (89%-96%) and improved rates of favorable clinical outcome (mRS  $\leq 2$ ; 42%-69%) compared to earlier devices<sup>[29,41,43-45]</sup>. The Solitaire FR was then directly compared to the Merci Retriever in the SOLITAIRE™ with the intention for thrombectomy (SWIFT) trial (Table 2)<sup>[46]</sup>. This was a parallel-group, non-inferiority trial of 113 patients randomized to either the Solitaire ( $n = 58$ ) or Merci ( $n = 55$ ) device. The primary outcome (TIMI  $\geq 2$ ) was more likely to be achieved in the Solitaire group than the Merci group (64% *vs* 24%;  $P < 0.0001$  non-inferiority;  $P = 0.0001$  superiority). Additionally, patients in the Solitaire group were more likely to achieve a good neurological outcome (mRS  $\leq 2$ ) at 90 d (58% *vs* 33%;  $P < 0.0001$  non-inferiority;  $P = 0.02$  superiority) and had a lower 90-d mortality rate (17% *vs* 38%;  $P = 0.0001$  non-inferiority;  $P = 0.02$  superiority) than those in the Merci group. Subsequent prospective and retrospective studies have continued to demonstrate high rates of vessel recanalization and good clinical outcomes with the Solitaire FR<sup>[47,48]</sup>.

### Trevo Pro

The Trevo Pro (Stryker Neurovascular, Kalamazoo, MI) is another retrievable stent system which was approved by the FDA in August 2012. Similar to the Solitaire FR, the Trevo Pro was found to be superior to the Merci Retriever in a head-to-head randomized study<sup>[49]</sup>. The Thrombectomy REvascularization of Large Vessel Occlusions in Acute Ischemic Stroke trial assigned patients with AIS from LVO to either the Trevo Pro ( $n = 88$ ) or Merci Retriever ( $n = 90$ ) device. Patients in the Trevo Pro group were significantly more likely to reach the primary outcome, defined as Thrombolysis in Cerebral Ischemia (TICI) grade  $\geq 2$ , (86% *vs* 60%;  $P < 0.0001$  superiority) and achieve a good 90-d neurological outcome (mRS  $\leq$

2;  $P = 0.013$ ) than those in the Merci Retriever group. No significant difference was observed in the safety profile (a composite of symptomatic ICH and procedure-related complications;  $P = 0.1826$ ) or 90-d mortality rates ( $P = 0.1845$ ) of these two devices.

A review of 13 prospective trials endorsed improved rates of vessel recanalization with the newer generation stentriever devices<sup>[50]</sup>. While early trials (mainly utilizing IA thrombolysis and the Merci Retriever) reported recanalization rates of approximately 50%, recent trials with stentriever consistently reported rates of approximately 85%. A significantly greater time from symptom onset to endovascular treatment in more recent trials was also observed. This may explain their finding that although vessel recanalization rates have significantly improved over time, functional outcomes remain relatively stagnant. Nevertheless, stentriever and large bore aspiration catheters have become the dominant endovascular devices used to treat AIS in modern practice. A recent prospective trial found no major differences in the efficacy or safety of the Solitaire FR and Trevo Pro<sup>[51]</sup>.

## COMBINED SUCTION EMBOLECTOMY AND MECHANICAL RETRIEVAL

The MAX reperfusion catheters allowed for the development of direct aspiration as an additional thrombectomy technique. Direct suction can be applied from the PS device or a syringe plunger connected to the proximal hub of the catheter. Previously, this technique was limited by the challenges of tracking an aspiration catheter through the intracranial circulation, but the improved trackability of the MAX reperfusion catheters has facilitated its development<sup>[57]</sup>. Furthermore, these catheters can still be used in combination with other endovascular devices. The ADAPT technique<sup>[52]</sup> is an increasingly utilized ap-

proach which combines modern aspiration and retrieval technology. Direct aspiration with a large bore aspiration catheter (commonly MAX reperfusion system) is first performed. If direct aspiration fails, stentriever, balloons and stents can be still be passed through the catheter. A recent retrospective series of 98 patients by Turk *et al*<sup>[53]</sup> reported revascularization (TICI  $\geq 2b$ ) in 78% of cases following direct aspiration. When stentriever were used following failed direct aspiration, this rate rose to 95%, a previously unparalleled result.

### **Penumbra 3D separator**

The Penumbra 3D Separator is the newest generation PS device currently being investigated in randomized controlled trials. It is designed to combine stentriever and direct aspiration technology into a single device. The new separator device is configured similarly to a stentriever, with an additional radial dimension to fragment the clot under continuous direct aspiration. The stent struts are designed to minimize vessel contact and thus theoretically reduce iatrogenic injury to the endothelium. An initial prospective study of 20 patients treated with the Penumbra 3D Separator demonstrated vessel recanalization (TICI  $\geq 2b$ ) and favorable neurological outcome (mRS  $\leq 2$ ) in 85% and 50% of patients, respectively<sup>[54]</sup>.

## **ENDOVASCULAR THERAPY VS IVT FOR AIS**

Due to the promising results from early pilot trials of endovascular mechanical thrombectomy for AIS<sup>[55,56]</sup>, randomized controlled trials were undertaken to evaluate the benefit of endovascular therapy compared to IVT in a more rigorous fashion.

### **IMS III**

The Interventional Management of Stroke (IMS) III trial<sup>[57]</sup> randomly assigned 656 patients who had received IVT within three hours of AIS symptom onset to receive additional endovascular therapy ( $n = 434$ ) or IVT alone ( $n = 222$ ) in a 2:1 ratio. In the endovascular group, 330 patients received treatment: IA thrombolysis alone ( $n = 160$ ), mechanical thrombectomy alone ( $n = 57$ ), IA thrombolysis plus mechanical thrombectomy ( $n = 97$ ) and combinations of multiple mechanical thrombectomy devices with or without IA thrombolysis ( $n = 16$ ). There was no significant difference between the endovascular and IVT groups for achieving a 90-d mRS  $\leq 2$  (40.8% and 38.7%, respectively; 95%CI: -6.1 to 9.1). Additional subgroup analyses showed no difference between the two groups in patients with NIHSS  $\geq 20$  (95%CI: -4.4 to 18.1) or NIHSS  $< 20$  (95%CI: -10.8 to 8.8). Similar rates of symptomatic ICH (6.2% in the endovascular group and 5.9% in the IVT group;  $P = 0.83$ ) and 90-d mortality (19.1% in the endovascular group and 21.6% in the IVT group;  $P = 0.52$ ) were observed.

Enrollment and treatment of patients in the endo-

vascular arm of this trial was not optimal. Over 20% of patients in the endovascular arm were included for analysis despite not receiving any endovascular therapy (due to lack of LVO on angiography). Notably, subgroup analysis of patients with LVO confirmed by CTA showed that endovascular therapy was associated with better functional outcomes than IVT alone ( $P = 0.01$ )<sup>[58]</sup>. The time to endovascular treatment was also significantly longer in the IMS III trial compared to the previous IMS I and II trials. These earlier trials demonstrated that there is a close association between time to reperfusion and neurological outcome, with a linear decrease in probability of good neurological outcome with time<sup>[59]</sup>. Thus, this treatment delay may have reduced the clinical benefit of endovascular therapy in this trial. Lastly, of those treated, less than 5% were treated with stentriever, either alone or in combination with other devices. This likely contributed to only 40% of patients achieving TICI grade 2b or 3 vessel recanalization<sup>[60]</sup>.

### **SYNTHESIS Expansion**

The SYNTHESIS Expansion trial<sup>[61]</sup> randomly assigned 362 patients with AIS within 4.5 h of symptom onset to either endovascular therapy ( $n = 181$ ) or IVT ( $n = 181$ ). Patients in the endovascular group who underwent treatment ( $n = 165$ ) received either IA thrombolysis ( $n = 109$ ) alone or in combination with mechanical thrombectomy ( $n = 56$ ) without any prior IVT. Survival-free disability (mRS  $\leq 1$ ) at 90 d, adjusted for key variables (age, sex, initial NIHSS grade and history of atrial fibrillation) did not significantly differ between the endovascular and IVT groups (30.4% and 34.8%, respectively;  $P = 0.16$ ). Secondary outcomes including NIHSS score  $\leq 6$ , neurological deterioration, mortality, symptomatic ICH, and recurrent AIS also did not significantly differ between groups.

Again, the protocol of this trial likely resulted in enrollment of patients who were not suitable candidates for endovascular therapy under current recommendations. No preoperative imaging was required to confirm LVO prior to randomization, and a significant portion of patients ( $> 33\%$ ) had a NIHSS  $\leq 10$ . Additionally, the majority of patients in the endovascular arm received interventions that would no longer be considered standard of care. Only 13% of patients in the endovascular arm were treated with stentriever<sup>[62]</sup>, while 60% were treated with IA thrombolysis alone without mechanical retrieval. Because vessel recanalization rates were not reported, it is unclear if these patients received optimal therapeutic effect.

### **MR Rescue**

The MR Rescue trial<sup>[63]</sup> randomized 118 patients with large vessel anterior circulation strokes to either mechanical thrombectomy ( $n = 64$ ) or IVT ( $n = 54$ ) within eight hours of symptom onset. Patient groups were also stratified based on pre-treatment imaging into favorable or non-penumbra patterns. Some studies have suggested that measuring the extent of salvageable brain tissue or ischemic penumbra on preoperative imaging may identify

patients who could preferentially benefit from endovascular therapy<sup>[64-67]</sup>. Favorable penumbral pattern was defined as a predicted infarct core of 90 mL or less and a proportion of infarct tissue within the at-risk region of 70 mL or less after pre-treatment magnetic resonance imaging or computed tomography. Results showed no significant difference in mean 90-d mRS observed among groups, both in the overall cohort ( $P = 0.99$ ) or when stratified based on penumbral pattern (favorable,  $P = 0.23$ ; non-penumbral,  $P = 0.32$ ). No differences in the rates of symptomatic ICH ( $P = 0.24$ ) or mortality ( $P = 0.75$ ) were observed between groups. These results correlate with findings from a recent study which showed that a non-perfect preoperative ASPECT score did not significantly affect functional outcome<sup>[68]</sup>.

No patients in the endovascular arm of the MR Rescue trial were treated with stentrievors. Similar to IMS III, this likely contributed to the low overall rate of recanalization. Only 27% of patients in the endovascular arm achieved recanalization of TICI grade 2b or 3<sup>[60]</sup>. Additionally, this trial may have been underpowered due to the relatively low number of patients in each group.

### Conclusions from Randomized Trials

While these trials provided valuable preliminary data for the assessment of endovascular intervention for AIS, each had significant limitations<sup>[60,62]</sup>. In SYNTHESIS and IMS III, patients with LVO were not appropriately selected based on preoperative imaging. In all three trials, due to the pace of advancement in endovascular technologies, a minority of patients were treated with the most modern endovascular devices. Stentrievors were used infrequently in all three studies, which resulted in vessel recanalization rates below current standards. There is evidence that recanalization is associated with improved functional outcomes and reduced mortality<sup>[7]</sup>. Thus, the generalizability of the results from these trials to modern endovascular stroke practice is limited, and future randomized controlled trials are still needed.

As supported by the subgroup analysis of patients with CTA-positive LVO from the IMS III trial, evidence still supports the use of endovascular mechanical thrombectomy for LVO within eight hours of symptom onset. Importantly, none of these trials raised questions about the safety of endovascular therapy. Recanalization is now possible in over 80% of cases, and for many patients, endovascular therapy is the only available treatment option. As endovascular devices and operator experience continue to evolve, improvements in patient outcomes are expected. Future trials will need to focus on proper patient selection and achieving optimal therapeutic effect (vessel recanalization) with modern endovascular devices<sup>[69]</sup>. Three ongoing clinical trials (THERAPY, SWIFT-PRIME, and POSITIVE) appear to have incorporated these key principles into their study design.

## CONCLUSION

Endovascular mechanical thrombectomy involves the

physical extraction of an occluding thromboembolus *via* grasping devices and/or direct/indirect aspiration. Over the past decade, advancements in catheter-based and endovascular device technology have led to strong improvements in rates of vessel recanalization. Initial randomized trials failed to show benefit of endovascular therapy over IVT, but limitations in study design have abated widespread acceptance of their conclusions. Future randomized trials evaluating endovascular mechanical thrombectomy for AIS will need to enroll and treat patients based off of the currently accepted standards of care.

## REFERENCES

- 1 **Go AS**, Mozaffarian D, Roger VL, Benjamin EJ, Berry JD, Borden WB, Bravata DM, Dai S, Ford ES, Fox CS, Franco S, Fullerton HJ, Gillespie C, Hailpern SM, Heit JA, Howard VJ, Huffman MD, Kissela BM, Kittner SJ, Lackland DT, Lichtman JH, Lisabeth LD, Magid D, Marcus GM, Marelli A, Matchar DB, McGuire DK, Mohler ER, Moy CS, Mussolino ME, Nichol G, Paynter NP, Schreiner PJ, Sorlie PD, Stein J, Turan TN, Virani SS, Wong ND, Woo D, Turner MB. Executive summary: heart disease and stroke statistics--2013 update: a report from the American Heart Association. *Circulation* 2013; **127**: 143-152 [PMID: 23283859 DOI: 10.1161/CIR.0b013e318282ab8f]
- 2 **Lopez AD**, Mathers CD, Ezzati M, Jamison DT, Murray CJ. Global and regional burden of disease and risk factors, 2001: systematic analysis of population health data. *Lancet* 2006; **367**: 1747-1757 [PMID: 16731270 DOI: 10.1016/S0140-6736(06)68770-9]
- 3 **Lozano R**, Naghavi M, Foreman K, Lim S, Shibuya K, Aboyans V, Abraham J, Adair T, Aggarwal R, Ahn SY, Alvarado M, Anderson HR, Anderson LM, Andrews KG, Atkinson C, Baddour LM, Barker-Collo S, Bartels DH, Bell ML, Benjamin EJ, Bennett D, Bhalla K, Bikbov B, Bin Abdulhak A, Birbeck G, Blyth F, Bolliger I, Boufous S, Bucello C, Burch M, Burney P, Carapetis J, Chen H, Chou D, Chugh SS, Coffeng LE, Colan SD, Colquhoun S, Colson KE, Condon J, Connor MD, Cooper LT, Corriere M, Cortinovis M, de Vaccaro KC, Couser W, Cowie BC, Criqui MH, Cross M, Dabhadkar KC, Dahodwala N, De Leo D, Degenhardt L, Delossantos A, Denenberg J, Des Jarlais DC, Dharmaratne SD, Dorsey ER, Driscoll T, Duber H, Ebel B, Erwin PJ, Espindola P, Ezzati M, Feigin V, Flaxman AD, Forouzanfar MH, Fowkes FG, Franklin R, Fransen M, Freeman MK, Gabriel SE, Gakidou E, Gaspari F, Gillum RF, Gonzalez-Medina D, Halasa YA, Haring D, Harrison JE, Havmoeller R, Hay RJ, Hoen B, Hotez PJ, Hoy D, Jacobsen KH, James SL, Jasrasaria R, Jayaraman S, Johns N, Karthikeyan G, Kassebaum N, Keren A, Khoo JP, Knowlton LM, Kobusingye O, Koranteng A, Krishnamurthi R, Lipnick M, Lipshultz SE, Ohno SL, Mabweijano J, MacIntyre MF, Mallinger L, March L, Marks GB, Marks R, Matsumori A, Matzopoulos R, Mayosi BM, McAnulty JH, McDermott MM, McGrath J, Mensah GA, Merriman TR, Michaud C, Miller M, Miller TR, Mock C, Mocumbi AO, Mokdad AA, Moran A, Mulholland K, Nair MN, Naldi L, Narayan KM, Nasseri K, Norman P, O'Donnell M, Omer SB, Ortblad K, Osborne R, Ozgediz D, Pahari B, Pandian JD, Rivero AP, Padilla RP, Perez-Ruiz F, Perico N, Phillips D, Pierce K, Pope CA, 3rd, Porrini E, Pourmalek F, Raju M, Ranganathan D, Rehm JT, Rein DB, Remuzzi G, Rivara FP, Roberts T, De Leon FR, Rosenfeld LC, Rushton L, Sacco RL, Salomon JA, Sampson U, Sanman E, Schwebel DC, Segui-Gomez M, Shepard DS, Singh D, Singleton J, Sliwa K, Smith E, Steer A, Taylor JA, Thomas B, Tleyjeh IM, Towbin JA, Truelsen T, Undurraga EA, Venketasubramanian N, Vijayakumar L, Vos T, Wagner GR, Wang M, Wang W, Watt



- K, Weinstock MA, Weintraub R, Wilkinson JD, Woolf AD, Wulf S, Yeh PH, Yip P, Zabetian A, Zheng ZJ, Lopez AD, Murray CJ, AlMazroa MA, Memish ZA. Global and regional mortality from 235 causes of death for 20 age groups in 1990 and 2010: A systematic analysis for the global burden of disease study 2010. *Lancet* 2012; **380**: 2095-2128 [PMID: 23245604 DOI: 10.1016/S0140-6736(12)61728-0]
- 4 Feigin VL, Lawes CM, Bennett DA, Anderson CS. Stroke epidemiology: a review of population-based studies of incidence, prevalence, and case-fatality in the late 20th century. *Lancet Neurol* 2003; **2**: 43-53 [PMID: 12849300 DOI: 10.1016/S1474-4422(03)00266-7]
- 5 Dirmagl U, Iadecola C, Moskowitz MA. Pathobiology of ischemic stroke: an integrated view. *Trends Neurosci* 1999; **22**: 391-397 [PMID: 10441299 DOI: 10.1016/S0166-2236(99)01401-0]
- 6 Kharitonova TV, Melo TP, Andersen G, Egido JA, Castillo J, Wahlgren N. Importance of cerebral artery recanalization in patients with stroke with and without neurological improvement after intravenous thrombolysis. *Stroke* 2013; **44**: 2513-2518 [PMID: 23881960 DOI: 10.1161/STROKEAHA.111.000048]
- 7 Rha JH, Saver JL. The impact of recanalization on ischemic stroke outcome: a meta-analysis. *Stroke* 2007; **38**: 967-973 [PMID: 17272772 DOI: 10.1161/01.STR.0000258112.14918.24]
- 8 Almekhlafi MA, Davalos A, Bonafe A, Chapot R, Gralla J, Pereira VM, Goyal M. Impact of Age and Baseline NIHSS Scores on Clinical Outcomes in the Mechanical Thrombectomy Using Solitaire FR in Acute Ischemic Stroke Study. *AJNR Am J Neuroradiol* 2014; **35**: 1337-1340 [PMID: 24557701 DOI: 10.3174/ajnr.A3855]
- 9 Chalouhi N, Tjoumakaris S, Starke RM, Hasan D, Sidhu N, Singhal S, Hann S, Gonzalez LF, Rosenwasser R, Jabbour P. Endovascular stroke intervention in young patients with large vessel occlusions. *Neurosurg Focus* 2014; **36**: E6 [PMID: 24380483 DOI: 10.3171/2013.9.FOCUS13398]
- 10 Tissue plasminogen activator for acute ischemic stroke. The National Institute of Neurological Disorders and Stroke rt-PA Stroke Study Group. *N Engl J Med* 1995; **333**: 1581-1587 [PMID: 7477192 DOI: 10.1056/NEJM199512143332401]
- 11 Hacke W, Kaste M, Bluhmki E, Brozman M, Dávalos A, Guidetti D, Larrue V, Lees KR, Medeghri Z, Machnig T, Schneider D, von Kummer R, Wahlgren N, Toni D. Thrombolysis with alteplase 3 to 4.5 hours after acute ischemic stroke. *N Engl J Med* 2008; **359**: 1317-1329 [PMID: 18815396 DOI: 10.1056/NEJMoa0804656]
- 12 Wahlgren N, Ahmed N, Dávalos A, Hacke W, Millán M, Muir K, Roine RO, Toni D, Lees KR. Thrombolysis with alteplase 3-4.5 h after acute ischaemic stroke (SITS-ISTR): an observational study. *Lancet* 2008; **372**: 1303-1309 [PMID: 18790527 DOI: 10.1016/S0140-6736(08)61339-2]
- 13 de Los Ríos la Rosa F, Khoury J, Kissela BM, Flaherty ML, Alwell K, Moomaw CJ, Khatri P, Adeoye O, Woo D, Ferioli S, Kleindorfer DO. Eligibility for Intravenous Recombinant Tissue-Type Plasminogen Activator Within a Population: The Effect of the European Cooperative Acute Stroke Study (ECASS) III Trial. *Stroke* 2012; **43**: 1591-1595 [PMID: 22442174 DOI: 10.1161/STROKEAHA.111.645986]
- 14 Hassan AE, Chaudhry SA, Grigoryan M, Tekle WG, Qureshi AI. National trends in utilization and outcomes of endovascular treatment of acute ischemic stroke patients in the mechanical thrombectomy era. *Stroke* 2012; **43**: 3012-3017 [PMID: 22968467 DOI: 10.1161/STROKEAHA.112.658781]
- 15 Chalouhi N, Dressler JA, Kunkel ES, Dalyai R, Jabbour P, Gonzalez LF, Starke RM, Dumont AS, Rosenwasser R, Tjoumakaris S. Intravenous tissue plasminogen activator administration in community hospitals facilitated by telestroke service. *Neurosurgery* 2013; **73**: 667-671; discussion 671-672 [PMID: 23842556 DOI: 10.1227/NEU.0000000000000073]
- 16 Riedel CH, Zimmermann P, Jensen-Kondering U, Stingle R, Deuschl G, Jansen O. The importance of size: successful recanalization by intravenous thrombolysis in acute anterior stroke depends on thrombus length. *Stroke* 2011; **42**: 1775-1777 [PMID: 21474810 DOI: 10.1161/STROKEAHA.110.609693]
- 17 Saqqur M, Uchino K, Demchuk AM, Molina CA, Garami Z, Calleja S, Akhtar N, Orouk FO, Salam A, Shuaib A, Alexandrov AV. Site of arterial occlusion identified by transcranial Doppler predicts the response to intravenous thrombolysis for stroke. *Stroke* 2007; **38**: 948-954 [PMID: 17290031 DOI: 10.1161/01.STR.0000257304.21967.ba]
- 18 Linfante I, Llinas RH, Selim M, Chaves C, Kumar S, Parker RA, Caplan LR, Schlaug G. Clinical and vascular outcome in internal carotid artery versus middle cerebral artery occlusions after intravenous tissue plasminogen activator. *Stroke* 2002; **33**: 2066-2071 [PMID: 12154264 DOI: 10.1161/01.STR.0000021001.18101.A5]
- 19 Brommer EJ, van Bockel JH. Composition and susceptibility to thrombolysis of human arterial thrombi and the influence of their age. *Blood Coagul Fibrinolysis* 1992; **3**: 717-725 [PMID: 1489893 DOI: 10.1097/00001721-199212000-00003]
- 20 Fulgham JR, Ingall TJ, Stead LG, Cloft HJ, Wijedicks EF, Flemming KD. Management of acute ischemic stroke. *Mayo Clin Proc* 2004; **79**: 1459-1469 [PMID: 15544028 DOI: 10.4065/79.11.1459]
- 21 Bhatia R, Hill MD, Shobha N, Menon B, Bal S, Kochar P, Watson T, Goyal M, Demchuk AM. Low rates of acute recanalization with intravenous recombinant tissue plasminogen activator in ischemic stroke: real-world experience and a call for action. *Stroke* 2010; **41**: 2254-2258 [PMID: 20829513 DOI: 10.1161/STROKEAHA.110.592535]
- 22 Wolpert SM, Bruckmann H, Greenlee R, Wechsler L, Pessin MS, del Zoppo GJ. Neuroradiologic evaluation of patients with acute stroke treated with recombinant tissue plasminogen activator. The rt-PA Acute Stroke Study Group. *AJNR Am J Neuroradiol* 1993; **14**: 3-13 [PMID: 8427107]
- 23 del Zoppo GJ, Higashida RT, Furlan AJ, Pessin MS, Rowley HA, Gent M. PROACT: a phase II randomized trial of recombinant pro-urokinase by direct arterial delivery in acute middle cerebral artery stroke. PROACT Investigators. *Stroke* 1998; **29**: 4-11 [PMID: 9445320 DOI: 10.1161/01.STR.29.1.4]
- 24 Ernst R, Pancioli A, Tomsick T, Kissela B, Woo D, Kanter D, Jauch E, Carrozzella J, Spilker J, Broderick J. Combined intravenous and intra-arterial recombinant tissue plasminogen activator in acute ischemic stroke. *Stroke* 2000; **31**: 2552-2557 [PMID: 11062274 DOI: 10.1161/01.STR.31.11.2552]
- 25 Furlan A, Higashida R, Wechsler L, Gent M, Rowley H, Kase C, Pessin M, Ahuja A, Callahan F, Clark WM, Silver F, Rivera F. Intra-arterial prourokinase for acute ischemic stroke. The PROACT II study: a randomized controlled trial. *JAMA* 1999; **282**: 2003-2011 [PMID: 10591382 DOI: 10.1001/jama.282.21.2003]
- 26 Ringer AJ, Qureshi AI, Fessler RD, Guterman LR, Hopkins LN. Angioplasty of intracranial occlusion resistant to thrombolysis in acute ischemic stroke. *Neurosurgery* 2001; **48**: 1282-1288; discussion 1282-1288 [PMID: 11383731]
- 27 Hayakawa M, Yamagami H, Sakai N, Matsumaru Y, Yoshimura S, Toyoda K. Endovascular treatment of acute stroke with major vessel occlusion before approval of mechanical thrombectomy devices in Japan: Japanese Registry of Neuroendovascular Therapy (JR-NET) and JR-NET 2. *Neurol Med Chir (Tokyo)* 2014; **54**: 23-31 [PMID: 24292608 DOI: 10.2176/nmc.0a2013-0155]
- 28 Levy EI, Rahman M, Khalessi AA, Beyer PT, Natarajan SK, Hartney ML, Fiorella DJ, Hopkins LN, Siddiqui AH, Mocco J. Midterm clinical and angiographic follow-up for the first Food and Drug Administration-approved prospective, Single-Arm Trial of Primary Stenting for Stroke: SARIS (Stent-Assisted Recanalization for Acute Ischemic Stroke). *Neurosurgery* 2011; **69**: 915-920; discussion 920 [PMID: 21552168 DOI: 10.1227/NEU.0b013e318222afd1]
- 29 Roth C, Papanagiotou P, Behnke S, Walter S, Haass A, Becker

- C, Fassbender K, Politi M, Körner H, Romann MS, Reith W. Stent-assisted mechanical recanalization for treatment of acute intracerebral artery occlusions. *Stroke* 2010; **41**: 2559-2567 [PMID: 20947848 DOI: 10.1161/STROKEAHA.110.592071]
- 30 **Liu KC**, Ding D, Starke RM, Geraghty SR, Jensen ME. Intraprocedural retrieval of migrated coils during endovascular aneurysm treatment with the Trevo Stentriever device. *J Clin Neurosci* 2014; **21**: 503-506 [PMID: 24332812 DOI: 10.1016/j.jocn.2013.10.012]
- 31 **Molina CA**, Saver JL. Extending reperfusion therapy for acute ischemic stroke: emerging pharmacological, mechanical, and imaging strategies. *Stroke* 2005; **36**: 2311-2320 [PMID: 16179577 DOI: 10.1161/01.STR.0000182100.65262.46]
- 32 **Ding D**, Liu KC. Management strategies for intraprocedural coil migration during endovascular treatment of intracranial aneurysms. *J Neurointerv Surg* 2014; **6**: 428-431 [PMID: 23921713 DOI: 10.1136/neurintsurg-2013-010872]
- 33 **Gobin YP**, Starkman S, Duckwiler GR, Grobelny T, Kidwell CS, Jahan R, Pile-Spellman J, Segal A, Vinuela F, Saver JL. MERCI 1: a phase I study of Mechanical Embolus Removal in Cerebral Ischemia. *Stroke* 2004; **35**: 2848-2854 [PMID: 15514171 DOI: 10.1161/01.STR.0000147718.12954.60]
- 34 **Smith WS**, Sung G, Starkman S, Saver JL, Kidwell CS, Gobin YP, Lutsep HL, Nesbit GM, Grobelny T, Rymer MM, Silverman IE, Higashida RT, Budzik RF, Marks MP. Safety and efficacy of mechanical embolectomy in acute ischemic stroke: results of the MERCI trial. *Stroke* 2005; **36**: 1432-1438 [PMID: 15961709 DOI: 10.1161/01.STR.0000171066.25248.1d]
- 35 **IMS Study Investigators**. Combined intravenous and intra-arterial recanalization for acute ischemic stroke: the Interventional Management of Stroke Study. *Stroke* 2004; **35**: 904-911 [PMID: 15017018]
- 36 **Smith WS**, Sung G, Saver J, Budzik R, Duckwiler G, Liebeskind DS, Lutsep HL, Rymer MM, Higashida RT, Starkman S, Gobin YP, Frei D, Grobelny T, Hellinger F, Huddle D, Kidwell C, Koroshetz W, Marks M, Nesbit G, Silverman IE. Mechanical thrombectomy for acute ischemic stroke: final results of the Multi MERCI trial. *Stroke* 2008; **39**: 1205-1212 [PMID: 18309168 DOI: 10.1161/STROKEAHA.107.497115]
- 37 **Spiotta AM**, Chaudry MI, Hui FK, Turner RD, Kellogg RT, Turk AS. Evolution of thrombectomy approaches and devices for acute stroke: a technical review. *J Neurointerv Surg* 2014 Jan 2; Epub ahead of print [PMID: 24385554 DOI: 10.1136/neurintsurg-2013-011022]
- 38 **Penumbra Pivotal Stroke Trial Investigators**. The penumbra pivotal stroke trial: safety and effectiveness of a new generation of mechanical devices for clot removal in intracranial large vessel occlusive disease. *Stroke* 2009; **40**: 2761-2768 [PMID: 19590057 DOI: 10.1161/STROKEAHA.108.544957]
- 39 **Simon SD**, Grey CP. Hydrodynamic comparison of the Penumbra system and commonly available syringes in forced-suction thrombectomy. *J Neurointerv Surg* 2014; **6**: 205-211 [PMID: 23531712 DOI: 10.1136/neurintsurg-2012-010638]
- 40 **Frei D**, Gerber J, Turk A, McPherson M, Heck D, Hui F, Joseph G, Jahan R, Miskolci L, Carpenter J, Grobelny T, Goddard J, Turner RD, Huddle D, Bellon R, Chaudry I. The SPEED study: initial clinical evaluation of the Penumbra novel 054 Reperfusion Catheter. *J Neurointerv Surg* 2013; **5** Suppl 1: i74-i76 [PMID: 23299104 DOI: 10.1136/neurintsurg-2012-010585]
- 41 **Castaño C**, Dorado L, Guerrero C, Millán M, Gomis M, Perez de la Ossa N, Castellanos M, García MR, Domenech S, Dávalos A. Mechanical thrombectomy with the Solitaire AB device in large artery occlusions of the anterior circulation: a pilot study. *Stroke* 2010; **41**: 1836-1840 [PMID: 20538693 DOI: 10.1161/STROKEAHA.110.584904]
- 42 **Leishangthem L**, Satti SR. Vessel perforation during withdrawal of Trevo ProVue stent retriever during mechanical thrombectomy for acute ischemic stroke. *J Neurosurg* 2014; **121**: 1-4 [PMID: 24926655 DOI: 10.3171/2014.4.JNS132187]
- 43 **Miteff F**, Faulder KC, Goh AC, Steinfort BS, Sue C, Harrington TJ. Mechanical thrombectomy with a self-expanding retrievable intracranial stent (Solitaire AB): experience in 26 patients with acute cerebral artery occlusion. *AJNR Am J Neuroradiol* 2011; **32**: 1078-1081 [PMID: 21493763 DOI: 10.3174/ajnr.A2447]
- 44 **Machi P**, Costalat V, Lobotesis K, Maldonado IL, Vendrell JF, Riquelme C, Bonafé A. Solitaire FR thrombectomy system: immediate results in 56 consecutive acute ischemic stroke patients. *J Neurointerv Surg* 2012; **4**: 62-66 [PMID: 21990438 DOI: 10.1136/jnis.2010.004051]
- 45 **Hann S**, Chalouhi N, Starke R, Gandhe A, Koltz M, Theofanis T, Jabbour P, Gonzalez LF, Rosenwasser R, Tjoumakaris S. Comparison of neurologic and radiographic outcomes with Solitaire versus Merci/Penumbra systems for acute stroke intervention. *Biomed Res Int* 2013; **2013**: 715170 [PMID: 24490169 DOI: 10.1155/2013/715170]
- 46 **Saver JL**, Jahan R, Levy EI, Jovin TG, Baxter B, Nogueira RG, Clark W, Budzik R, Zaidat OO. Solitaire flow restoration device versus the Merci Retriever in patients with acute ischaemic stroke (SWIFT): a randomised, parallel-group, non-inferiority trial. *Lancet* 2012; **380**: 1241-1249 [PMID: 22932715 DOI: 10.1016/S0140-6736(12)61384-1]
- 47 **Mokin M**, Dumont TM, Veznedaroglu E, Binning MJ, Lieberman KM, Fessler RD, To CY, Turner RD, Turk AS, Chaudry MI, Arthur AS, Fox BD, Hanel RA, Tawak RG, Kan P, Gaughen JR, Lanzino G, Lopes DK, Chen M, Moftakhar R, Billingsley JT, Ringer AJ, Snyder KV, Hopkins LN, Siddiqui AH, Levy EI. Solitaire Flow Restoration thrombectomy for acute ischemic stroke: retrospective multicenter analysis of early postmarket experience after FDA approval. *Neurosurgery* 2013; **73**: 19-25; discussion 25-26 [PMID: 23719060 DOI: 10.1227/01.neu.0000429859.96652.57]
- 48 **Pereira VM**, Gralla J, Davalos A, Bonafé A, Castaño C, Chapot R, Liebeskind DS, Nogueira RG, Arnold M, Sztajzel R, Liebig T, Goyal M, Besselmann M, Moreno A, Schroth G. Prospective, multicenter, single-arm study of mechanical thrombectomy using Solitaire Flow Restoration in acute ischemic stroke. *Stroke* 2013; **44**: 2802-2807 [PMID: 23908066 DOI: 10.1161/STROKEAHA.113.001232]
- 49 **Nogueira RG**, Lutsep HL, Gupta R, Jovin TG, Albers GW, Walker GA, Liebeskind DS, Smith WS. Trevo versus Merci retrievers for thrombectomy revascularisation of large vessel occlusions in acute ischaemic stroke (TREVO 2): a randomised trial. *Lancet* 2012; **380**: 1231-1240 [PMID: 22932714 DOI: 10.1016/S0140-6736(12)61299-9]
- 50 **Fargen KM**, Meyers PM, Khatri P, Mocco J. Improvements in recanalization with modern stroke therapy: a review of prospective ischemic stroke trials during the last two decades. *J Neurointerv Surg* 2013; **5**: 506-511 [PMID: 23042748 DOI: 10.1136/neurintsurg-2012-010541]
- 51 **Mendonça N**, Flores A, Pagola J, Rubiera M, Rodríguez-Luna D, De Miquel MA, Cardona P, Quesada H, Mora P, Alvarez-Sabín J, Molina C, Ribó M. Trevo versus solitaire a head-to-head comparison between two heavy weights of clot retrieval. *J Neuroimaging* 2014; **24**: 167-170 [PMID: 22913726 DOI: 10.1111/j.1552-6569.2012.00730.x]
- 52 **Turk AS**, Spiotta A, Frei D, Mocco J, Baxter B, Fiorella D, Siddiqui A, Mokin M, Dewan M, Woo H, Turner R, Hawk H, Miranpuri A, Chaudry I. Initial clinical experience with the ADAPT technique: a direct aspiration first pass technique for stroke thrombectomy. *J Neurointerv Surg* 2014; **6**: 231-237 [PMID: 23624315 DOI: 10.1136/neurintsurg-2013-010713]
- 53 **Turk AS**, Frei D, Fiorella D, Mocco J, Baxter B, Siddiqui A, Spiotta A, Mokin M, Dewan M, Quarfordt S, Battenhouse H, Turner R, Chaudry I. ADAPT FAST study: a direct aspiration first pass technique for acute stroke thrombectomy. *J Neurointerv Surg* 2014; **6**: 260-264 [PMID: 24569575 DOI: 10.1136/neurintsurg-2014-011125]
- 54 **Mpotsaris A**, Bussmeyer M, Weber W. Mechanical Throm-

- bectomy with the Penumbra 3D Separator and Lesional Aspiration: Technical Feasibility and Clinical Outcome. *Clin Neuroradiol* 2013; **24**: 245-250 [PMID: 23892954 DOI: 10.1007/s00062-013-0242-x]
- 55 **IMS II Trial Investigators.** The Interventional Management of Stroke (IMS) II Study. *Stroke* 2007; **38**: 2127-2135 [PMID: 17525387 DOI: 10.1161/STROKEAHA.107.483131]
- 56 **Ciccone A,** Valvassori L, Ponzio M, Ballabio E, Gasparotti R, Sessa M, Scmazzone F, Tiraboschi P, Sterzi R. Intra-arterial or intravenous thrombolysis for acute ischemic stroke? The SYNTHESIS pilot trial. *J Neurointerv Surg* 2010; **2**: 74-79 [PMID: 21990564 DOI: 10.1136/jnis.2009.001388]
- 57 **Broderick JP,** Palesch YY, Demchuk AM, Yeatts SD, Khatri P, Hill MD, Jauch EC, Jovin TG, Yan B, Silver FL, von Kummer R, Molina CA, Demaerschalk BM, Budzik R, Clark WM, Zaidat OO, Malisch TW, Goyal M, Schonewille WJ, Mazighi M, Engelter ST, Anderson C, Spilker J, Carrozzella J, Ryckborst KJ, Janis LS, Martin RH, Foster LD, Tomsick TA. Endovascular therapy after intravenous t-PA versus t-PA alone for stroke. *N Engl J Med* 2013; **368**: 893-903 [PMID: 23390923 DOI: 10.1056/NEJMoa1214300]
- 58 **Starke RM,** Komotar RJ, Connolly ES. Endovascular therapy in acute ischemic stroke. *Neurosurgery* 2013; **72**: N20-N23 [PMID: 23685516 DOI: 10.1227/01.neu.0000430740.01610.74]
- 59 **Khatri P,** Abruzzo T, Yeatts SD, Nichols C, Broderick JP, Tomsick TA. Good clinical outcome after ischemic stroke with successful revascularization is time-dependent. *Neurology* 2009; **73**: 1066-1072 [PMID: 19786699 DOI: 10.1212/WNL.0b013e3181b9c847]
- 60 **Khalessi AA,** Fargen KM, Lavine S, Mocco J. Commentary: Societal statement on recent acute stroke intervention trials: results and implications. *Neurosurgery* 2013; **73**: E375-E379 [PMID: 23632768 DOI: 10.1227/01.neu.0000430514.46473.4f]
- 61 **Ciccone A,** Valvassori L, Nichelatti M, Sgoifo A, Ponzio M, Sterzi R, Boccardi E. Endovascular treatment for acute ischemic stroke. *N Engl J Med* 2013; **368**: 904-913 [PMID: 23387822 DOI: 10.1056/NEJMoa1213701]
- 62 **Mokin M,** Khalessi AA, Mocco J, Lanzino G, Dumont TM, Hanel RA, Lopes DK, Fessler RD, Ringer AJ, Bendok BR, Veznedaroglu E, Siddiqui AH, Hopkins LN, Levy EI. Endovascular treatment of acute ischemic stroke: the end or just the beginning? *Neurosurg Focus* 2014; **36**: E5 [PMID: 24380482 DOI: 10.3171/2013.10.FOCUS13374]
- 63 **Kidwell CS,** Jahan R, Gornbein J, Alger JR, Nenov V, Ajani Z, Feng L, Meyer BC, Olson S, Schwamm LH, Yoo AJ, Marshall RS, Meyers PM, Yavagal DR, Wintermark M, Guzy J, Starkman S, Saver JL. A trial of imaging selection and endovascular treatment for ischemic stroke. *N Engl J Med* 2013; **368**: 914-923 [PMID: 23394476 DOI: 10.1056/NEJMoa1212793]
- 64 **Turk A,** Magarik JA, Chaudry I, Turner RD, Nicholas J, Holmstedt CA, Chalela J, Hays A, Lazaridis C, Jauch E, Chimowitz M, Turan T, Adams R. CT perfusion-guided patient selection for endovascular treatment of acute ischemic stroke is safe and effective. *J Neurointerv Surg* 2012; **4**: 261-265 [PMID: 21990520 DOI: 10.1136/neurintsurg-2011-010067]
- 65 **Chalouhi N,** Ghobrial G, Tjoumakaris S, Dumont AS, Gonzalez LF, Witte S, Davanzo J, Starke RM, Randazzo C, Flanders AE, Hasan D, Chitale R, Rosenwasser R, Jabbour P. CT perfusion-guided versus time-guided mechanical recanalization in acute ischemic stroke patients. *Clin Neurol Neurosurg* 2013; **115**: 2471-2475 [PMID: 24176650 DOI: 10.1016/j.clineuro.2013.09.036]
- 66 **Kan PT,** Snyder KV, Yashar P, Siddiqui AH, Hopkins LN, Levy EI. Utility of CT perfusion scanning in patient selection for acute stroke intervention: experience at University at Buffalo Neurosurgery-Millard Fillmore Gates Circle Hospital. *Neurosurg Focus* 2011; **30**: E4 [PMID: 21631228 DOI: 10.3171/2011.2.FOCUS1130]
- 67 **Turk AS,** Nyberg EM, Chaudry MI, Turner RD, Magarik JA, Nicholas JS, Holmstedt CA, Chalela JA, Hays A, Lazaridis C, Chimowitz MI, Turan TN, Adams RJ, Jauch EC. Utilization of CT perfusion patient selection for mechanical thrombectomy irrespective of time: a comparison of functional outcomes and complications. *J Neurointerv Surg* 2013; **5**: 518-522 [PMID: 22935349 DOI: 10.1136/neurintsurg-2012-010452]
- 68 **Spiotta AM,** Vargas J, Hawk H, Turner R, Chaudry MI, Battenhouse H, Turk AS. Impact of the ASPECT scores and distribution on outcome among patients undergoing thrombectomy for acute ischemic stroke. *J Neurointerv Surg* 2014; [PMID: 24916415 DOI: 10.1136/neurintsurg-2014-011195]
- 69 **Starke RM,** Komotar RJ, Connolly ES. Mechanical clot retrieval in the treatment of acute ischemic stroke. *Neurosurgery* 2013; **72**: N19-N21 [PMID: 23328660 DOI: 10.1227/01.neu.0000426217.97583.1b]

P- Reviewer: Soria F, Sobrino T S- Editor: Gong XM

L- Editor: A E- Editor: Lu YJ





## Epilepsy associated tumors: Review article

Marco Giulioni, Gianluca Marucci, Matteo Martinoni, Anna Federica Marliani, Francesco Toni, Fiorina Bartiromo, Lilia Volpi, Patrizia Riguzzi, Francesca Bisulli, Ilaria Naldi, Roberto Michelucci, Agostino Baruzzi, Paolo Tinuper, Guido Rubboli

Marco Giulioni, Matteo Martinoni, IRCCS Institute of Neurological Sciences of Bologna, Division of Neurosurgery, Bellaria Hospital, 40139 Bologna, Italy

Gianluca Marucci, Department of Biomedical and Neuromotor Sciences (DiBiNeM), Section of Pathology "M.Malpighi", Bellaria Hospital, University of Bologna, 40139 Bologna, Italy

Anna Federica Marliani, Francesco Toni, IRCCS Institute of Neurological Sciences of Bologna, Section of Neuroradiology, Bellaria Hospital, 40139 Bologna, Italy

Fiorina Bartiromo, Department of Specialistic Diagnostic and Experimental Medicine (DIMES), Section of Neuroradiology, University of Bologna, 40139 Bologna, Italy

Lilia Volpi, Patrizia Riguzzi, Roberto Michelucci, Guido Rubboli, IRCCS Institute of Neurological Sciences of Bologna, Division of Neurology, Bellaria Hospital, 40139 Bologna, Italy  
 Francesca Bisulli, Ilaria Naldi, Agostino Baruzzi, Paolo Tinuper, IRCCS Institute of Neurological Sciences of Bologna, Bellaria Hospital, 40139 Bologna, Italy

Francesca Bisulli, Agostino Baruzzi, Paolo Tinuper, Department of Biomedical and Neuromotor Sciences, University of Bologna, 40139 Bologna, Italy

Guido Rubboli, Danish Epilepsy Centre, Epilepsi hospitalet, 4293 Dianalund, Denmark

**Author contributions:** Giulioni M, Marucci G, Martinoni M drafted the article; Giulioni M, Marucci G, Martinoni M, Marliani AF, Toni F, Bartiromo F, Volpi L, Riguzzi P, Bisulli F, Naldi I, Michelucci R, Baruzzi A, Tinuper P and Rubboli G contributed to data analysis, to separate heading of the article and to revised the article.

**Correspondence to:** Marco Giulioni, MD, IRCCS Institute of Neurological Sciences, Division of Neurosurgery, Bellaria Hospital, Via Altura 1/8, 40139 Bologna, Italy. [giulioni.m@tiscali.it](mailto:giulioni.m@tiscali.it)

Telephone: +39-051-6225111 Fax: +39-051-6225347

Received: July 29, 2014 Revised: September 17, 2014

Accepted: October 1, 2014

Published online: November 16, 2014

ronal tumors are the most frequent histological type consisting of a mixture of glial and neuronal elements and most commonly arising in the temporal lobe. Cortical dysplasia or other neuronal migration abnormalities often coexist. Epilepsy associated with LEAT is generally poorly controlled by antiepileptic drugs while, on the other hand, it is high responsive to surgical treatment. However the best management strategy of tumor-related focal epilepsies remains controversial representing a contemporary issues in epilepsy surgery. Temporo-mesial LEAT have a widespread epileptic network with complex epileptogenic mechanisms. By using an epilepsy surgery oriented strategy LEAT may have an excellent seizure outcome therefore surgical treatment should be offered early, irrespective of pharmacoresistance, avoiding both the consequences of uncontrolled seizures as well as the side effects of prolonged pharmacological therapy and the rare risk of malignant transformation.

© 2014 Baishideng Publishing Group Inc. All rights reserved.

**Key words:** Epilepsy; Low grade tumors; Long-term epilepsy associated tumors; Glioneuronal tumors; Ganglioglioma; Dysembryoplastic neuroepithelial tumor; Lesionectomy; Epilepsy surgery

**Core tip:** Long-term epilepsy associated tumors (LEAT) represent a frequent cause of focal epilepsies, particularly in children and young adults. Epilepsy associated with LEAT is generally poorly controlled by antiepileptic drugs while it is extremely responsive to surgical treatment. Temporo-mesial LEAT have a widespread epileptic network and complex epileptogenic mechanisms. The best management strategy of tumor-related focal epilepsies remains controversial representing a contemporary issues in epilepsy surgery.

### Abstract

Long-term epilepsy associated tumors (LEAT) represent a well known cause of focal epilepsies. Glioneu-

Giulioni M, Marucci G, Martinoni M, Marliani AF, Toni F, Bartiromo F, Volpi L, Riguzzi P, Bisulli F, Naldi I, Michelucci R,



Baruzzi A, Tinuper P, Rubboli G. Epilepsy associated tumors: Review article. *World J Clin Cases* 2014; 2(11): 623-641 Available from: URL: <http://www.wjgnet.com/2307-8960/full/v2/i11/623.htm> DOI: <http://dx.doi.org/10.12998/wjcc.v2.i11.623>

## INTRODUCTION

Brain tumors, mostly low grade tumors, are associated with epilepsy in more than a half of cases and approximately 30% of tumor-associated epilepsy are pharmacoresistant.

Recent advances in neuroimaging and neurophysiology have allowed the recognition of subtle epilepsy-associated focal structural lesions, and have improved our understanding of the complex functional relevance of these lesions for seizure generation. Among this group of lesions the concept of long-term epilepsy associated tumors (LEAT) describes the wide group of low grade tumors in patients associated with chronic focal epilepsy<sup>[1-5]</sup>. Indeed, developmental brain lesions, in particular glioneuronal tumors (GNT), often associated with malformations of cortical development, in particular focal cortical dysplasia (FCD)<sup>[1,3,4]</sup>, are among the most common causes of pharmacologically intractable epilepsy. In the setting of epilepsy surgery a brain tumor is the second most common cause of focal epilepsy<sup>[6]</sup> and it could be encountered in approximately 30% of patients operated on for refractory focal epilepsy<sup>[5,7,8]</sup>.

Epilepsy associated-tumor is a debilitating condition, causing distress and adversely affecting the quality of life<sup>[3,5,9-17]</sup>.

Epileptic seizure incidence varies according to tumour location and histotype. Furthermore low-grade tumors often are more epileptogenic than high-grade tumours<sup>[8,10,12,13,16,18]</sup>.

Epilepsy associated with brain tumours can be divided into two groups: tumors without other symptoms (usually low-grade tumors affecting children or young patients) or tumors together with neurological deficits (more frequently high-grade tumours in middle-aged and older patients)<sup>[10]</sup>.

In the group of epilepsy associated with low grade tumors it is useful to further distinguish between the pre-eminence of oncological and epileptic logical aspects. In the group of the “diffuse low grade glioma” (LGG) the oncological aspects should prevail according to the progressive course of the neoplastic brain disease<sup>[10-12,15,16,19-22]</sup>. On the contrary in the group of LEAT, mainly represented by glioneuronal tumors (GNTs), epilepsy control should be the main goal<sup>[1,3-5,8,23-28]</sup>.

The group of LEAT, is currently enlarging not only for the recognition of new, often rare, histotypes but also for the identification of tumors having hybrid and/or mixed features<sup>[3,29-32]</sup>. The biologic behaviour of LEAT is generally benign even if some tumors could present recurrence or malignant transformation<sup>[5,33]</sup>. New tumoral entities have been recently introduced and there

is ongoing debate on improving consensus for diagnosis of LEAT between specialized centers<sup>[3,30]</sup>. While LEAT rarely coexist with hippocampal sclerosis (2%-25% of cases) they may often be associated with FCD (40%-80% of cases)<sup>[2,23,24,29,34-36]</sup>.

## LONG TERM EPILEPSY ASSOCIATED TUMORS

The histological characteristics of these tumors influence their propensity to generate seizures.

### Gangliogliomas

Gangliogliomas (GG) are the most common neoplasm causing chronic focal epileptic disorders (about 40%)<sup>[5,37-39]</sup>. GG can occur in any part of the central nervous system, although the temporal lobe is the most common location<sup>[5,33,40]</sup> followed by the frontal lobe, the optic pathway, the spinal cord, the brainstem, the cerebellum and the pineal gland.

### Dysembryoplastic neuroepithelial tumors

Dysembryoplastic neuroepithelial tumors (DNT) are grade I WHO tumors with cystic components, described by Daumas-Duport *et al.*<sup>[41]</sup> in 1988 as a typically cortical tumor affecting children and young adults with long-standing, drug-resistant epilepsy. Most frequently DNT are sited in the cortex of temporal lobe above all at the temporo-mesial site<sup>[42-46]</sup>. Rarely DNTs have been described in ectopic locations (septum pellucidum and the caudate nucleus)<sup>[47]</sup> in the pons, thalamus, basal ganglia, cerebellum, third ventricle, and brainstem. Familial occurrence of these neoplasms have been described.

### Pleomorphic Xanthoastrocytoma

Recently also pleomorphic Xanthoastrocytoma (PXA) has been considered part of this group of tumors. In fact, in addition to the astrocytic nature, there is growing evidence that PXA exhibits some histological, immunophenotypic and ultrastructural neuronal features<sup>[48,49]</sup>. Furthermore occasionally, FCD can be associated with PXA.

### Papillary glioneuronal tumor

Firstly described by Kim *et al.*<sup>[50]</sup> 1997, Papillary glioneuronal tumor (PGNT) most frequently arises in a supratentorial location with rare case showing multilobar involvement<sup>[3]</sup>. At MRI they appear as a cystic enhancing lesion with solid areas and often a mural nodule. PGNTs affect young adults.

### Pilocytic astrocytoma

Supratentorial pilocytic astrocytoma (PA) is frequently presents with chronic epilepsy. PA are included within the common histological entities encountered in series of tumor-associated epilepsy cases<sup>[3,5,30,51]</sup>.

### Diffuse astrocytoma

Diffuse astrocytomas mostly arise in the cerebral hemi-

spheres of young adults (frontal and temporal cerebral lobes) and seizures represent one of the most common symptoms. It has been described in the group of LEAT<sup>[52]</sup>. Some author stated that initial presentation with seizures could influence long-term survival<sup>[30,53]</sup>.

### **Oligodendroglioma**

Oligodendrogliomas usually arise in the cerebral hemispheres of young adults. They belong to LEAT group. Seizures represent a common presenting symptom<sup>[3,5,30]</sup>.

### **Angiocentric gliomas**

low grade cerebral tumor mostly affecting children and young adults and it is more and more frequently identified in the setting of chronic epilepsy<sup>[3]</sup>. Angiocentric gliomas (AG) have a cerebro-cortical location, often with involvement of the fronto-parietal and temporal lobe.

### **Extraventricular neurocytoma**

This rare entity, may be considered in the spectrum of GNT associated with focal epilepsy<sup>[29]</sup>.

### **LEAT with mixed tumor features**

“Hybrid” tumors constituted by mixed forms of ganglioglioma and DNT but also PXA and ganglioglioma, PXA with DNT and, PXA with an oligodendroglioma have long been recognised, representing an increasing group of tumors in epilepsy surgical series. Cases where a PA developed within a DNT, as well as PA grew in combination with a low-grade oligodendroglioma, have been noted<sup>[54,55]</sup>.

## **TUMOR SITE**

In the setting of low grade tumors associated with epilepsy, diffuse LGG (WHO grade II gliomas) are mainly found in the insular, fronto-insular, temporo-insular regions (namely paralimbic structures) representing the isomesocortical transition zone<sup>[56]</sup>.

Instead, LEAT mainly arise in the temporo-mesial structures (namely limbic lobe) in the site of allo-isocortical transition, harboring more frequently a neuronal differentiation maybe due to their proximity to the hippocampal granular layer where neurogenesis during adult life takes place<sup>[56-62]</sup>.

In our findings<sup>[8,26,28,36]</sup> according with others<sup>[62-65]</sup> in the mesial temporal lobe both the lesion and hippocampus seem to be epileptogenic even if there are no other MRI abnormality (hippocampal sclerosis) and pathological examination shows normal findings.

## **PATHOGENESIS OF TUMOR-ASSOCIATED SEIZURES**

Epileptogenesis of brain tumors depends on the histotype and location, even if the complexity of structural and molecular changes implies a multifactoriality of the pathogenesis<sup>[10,28,66,67]</sup> and may differ according to histolo-

gies (GNT *vs* diffuse low grade gliomas)<sup>[4,10,15,16,68,69]</sup>. The comprehension of the epileptogenesis in GNT is crucial to treat effectively pharmacologically intractable epilepsy (as discussed above) represents the initial, and often the only, clinical manifestation of the tumor and critically affects the patient's daily life.

LEAT are often large tumors, with a high propensity to develop seizures when located in temporal or frontal lobes<sup>[10,70]</sup>. GNT are composed of peculiar cellular components with hyperexcitable neurons, functionally integrated into excitatory circuitries, and neurochemical characteristics that can be relevant for epileptogenesis<sup>[34]</sup>. Data provided by intraslesional EEG recording have demonstrated intrinsic epileptogenicity of GG and DNT<sup>[171,72]</sup>. In addition, immunocytochemical studies showing high expression of specific glutamate receptors (GluR) subtypes suggest a hyperexcitability in the neuronal constituent of GNT<sup>[73,74]</sup>. An additional mechanism that can sustain epileptogenesis is related to an unbalance between excitation and inhibition due to a prominent expression of mGluR5 and downregulation of several gammaaminobutyric acid (GABA-A) a receptor (GABA-AR) subunits that suggest an impairment of GABAergic inhibition<sup>[75,76]</sup>. Furthermore, a disturbed ion homeostasis and transport could represent an additional potential mechanism leading to increased excitability in GNT<sup>[9,77]</sup>.

Another potential epileptogenic mechanism is related to a possible role of inflammation in the pathophysiology of human epilepsy<sup>[78]</sup>. Proinflammatory molecules have been shown in experimental models to decrease the seizure threshold<sup>[78,79]</sup> and may be involved in the generation of seizures in brain tumors, particularly in GNT<sup>[80]</sup>. Different mechanisms can cause an increment of neuronal excitability, for instance by enhancing the extracellular glutamate concentrations, as well as modifying the function of both glutamate and GABA receptors. Furthermore in GNT, particularly in GG, inflammatory changes have been showed to be associated with evidence of alterations in blood-brain barrier (BBB), with albumin extravasation and uptake in tumor astrocytes<sup>[66,81]</sup>. Interestingly, some data have shown also a prominent upregulation of the mTOR pathway, known to be a key regulator of cellular changes involved in epileptogenesis in GNT, particularly in GG<sup>[82,83]</sup>.

Several other additional mechanisms have been hypothesized to account for enhanced excitability in GG, such as for example, hypoxia and acidosis, ionic changes, and deposition of hemosiderin in the peritumoral region<sup>[10]</sup>. Enzymatic changes may also occur in peritumoral tissue, impairing neurotransmitter synthesis and storage, and contributing to tumor-associated epilepsy. Finally, association with cortical dysplasia (as discussed below) also has to be considered in the evaluation of the epileptogenicity of GG. Indeed the identification of a coexistent pathology may be clinically relevant since it has been extensively reported that the tumor itself may be electrically silent and the origin of seizures is from a pathological tissue adjacent to the tumor<sup>[42,77,84]</sup>. The implication is that excising the tumor and leaving in place the nearby abnor-

mal epileptogenic tissue, may give unsatisfactory results on the seizure outcome. Young age and long duration of illness are associated with an increased risk of secondary epileptogenesis. GNT can be intrinsically epileptogenic, even when associated with FCD<sup>[71]</sup>.

## CLINICAL AND EEG FEATURES OF FOCAL EPILEPSY ASSOCIATED WITH LEATs

### Clinical features

Focal epilepsy is the most common and often the only symptom of LEAT. Neurological deficits are relatively uncommon, varying from 0% to 15% according to different series: the neurological sparing might depend on the indolent and slow course of LEAT that might allow compensation of possible brain impairment by slowly developing plastic processes, particularly in the young age. Epilepsy can appear at any age: however, the majority of cases present with an epilepsy onset in adolescence and young adulthood. In DNET, seizures appear almost always and more than half of the patients have focal seizures with altered consciousness, with or without secondary generalization<sup>[85]</sup>. Regarding GGs, 80%-90% of patients seizures represent the only clinical symptom (mainly secondarily generalized tonic-clonic seizures)<sup>[86,87]</sup>. As already reported, the most common location of GG is the temporal lobe where they are frequently positive to CD34 glycoprotein staining. On the contrary it is not reported the association with CD34 for GG located in other sites of the brain<sup>[37,86-88]</sup>. It could be argued that this protein might represent a marker of dysplastic differentiation and that it could contribute to epileptogenesis. Seizure semiology is related to the site of tumor. In general, complex partial seizures with aura are more common in LEAT located in the temporal lobe, whereas secondary generalization is more common in epilepsies associated with extratemporal LEAT<sup>[39]</sup>. However, the extension of the tumor-related epileptogenic area may vary according to the anatomical location of the neoplasm: in fact, several data suggest that epileptogenic zone may be more widespread and complex in focal epilepsies associated to LEAT in the mesial temporal lobe in comparison to neocortical temporal lateral locations<sup>[36,40,61,65]</sup>. Occurrence of status epilepticus has been reported to be rare. Clinical parameters that differentiated patients operated on in childhood from patients operated on in adulthood were: (1) aura that was reported more often in the adult group, but it should be noted that this finding might at least partially depend on the fact that, in general, children are less able to refer their auras; and (2) mean age at seizure: probably due to the fact that developing brain has a low seizure threshold which leads to early and frequent seizures. Moreover, in pediatric age, malformations of cortical development are most often the basis of lesional epilepsy that is characterized by a high seizure frequency that can facilitate an early diagnosis and that can lead to

early evaluation for a surgical approach. No differences between the clinical features of epilepsy associated with DNET and with GG have been reported<sup>[42,89]</sup>. A favorable seizure outcome has been observed in cases with a short duration of epilepsy, only partial seizure and the lack of secondary generalization. Response of GNT-associated epilepsy to antiepileptic treatment is variable, but drug-resistance is quite common<sup>[5,39,42,90]</sup>.

Task Force of the ILAE Commission on Therapeutic Strategies defined drug resistant epilepsy as the failure of adequate trials of two tolerated, appropriately chosen and used antiepileptic drug (AEDs) schedules (whether as monotherapies or in combination) to achieve sustained seizure freedom<sup>[91]</sup>.

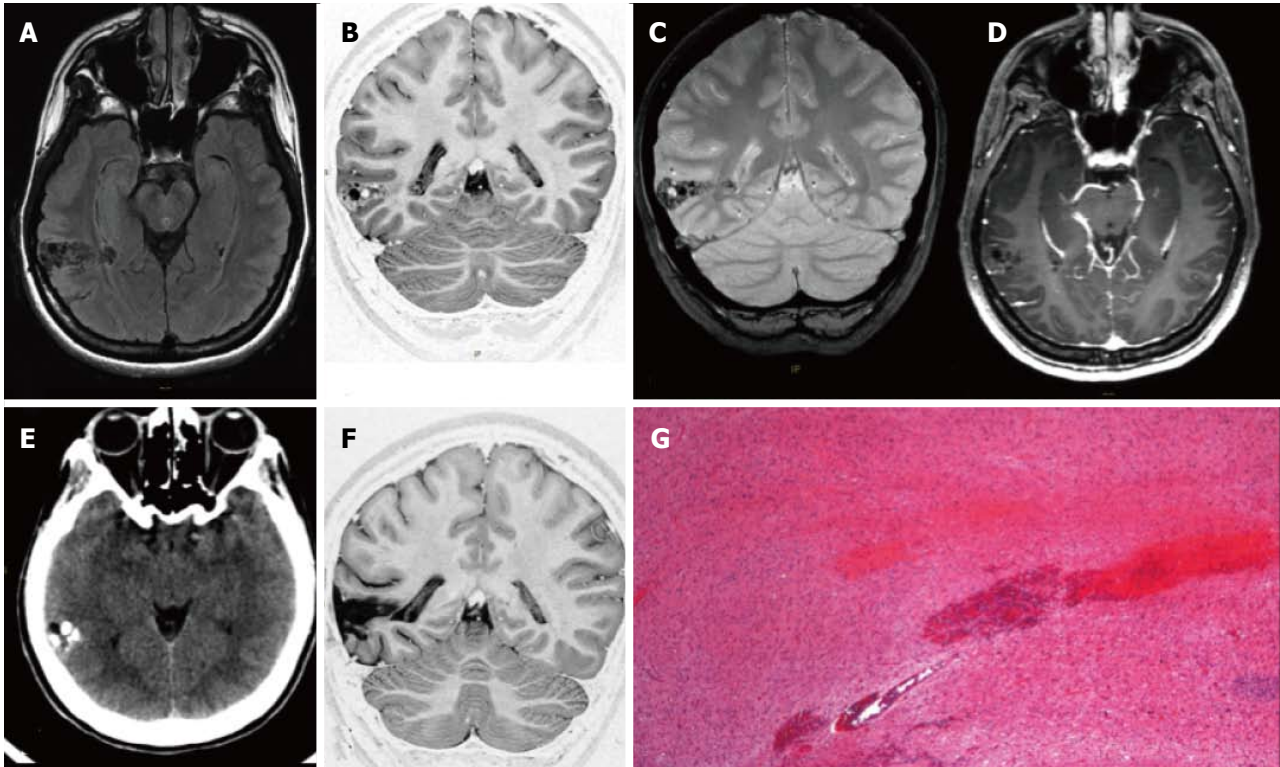
Several explanations could be at the basis for drug resistance. AEDs could be affected by the biochemical milieu of the peri-tumoral space.

Furthermore significant interactions between AEDs and other drugs (*i.e.*, chemotherapeutics) may decrease antiepileptic effectiveness, while increasing side effects interfering with the hepatic cytochrome P450 system. Furthermore AEDs resistance might result from over expression of multi-drug resistance-related proteins (MRPs) in tumors (particularly in capillary endothelial cells and astrocytes), which restrict the penetration of lipophilic substances into the pathologic tissue<sup>[10]</sup>.

### EEG features

Usually interictal EEG shows spikes and/or, sharp waves, sometimes intermixed with slow activities; in some instances normal EEG have been reported. These abnormalities, in preoperative EEG are commonly lateralized to the tumor side, less often to the correct lobe. However, Morris *et al.*<sup>[39]</sup> (1998) reported that the occurrence of interictal EEG abnormalities and ictal EEG onset in correspondence of the site of the tumor may not be predictive of seizure outcome; indeed, in some cases a post-operative poor seizure outcome has been reported in patients with EEG interictal and ictal findings perfectly concordant with tumor location. On the other hand, also patients with EEG slow or epileptiform abnormalities distant from the tumor site or with ictal EEG onset non-localized or widespread to a whole hemisphere improved regarding seizure outcome after tumor resection<sup>[39]</sup>. In temporal lobe GNT, long-term video-EEG monitoring may allow recording of seizures and identification of the epileptogenic zone; indeed, several data suggest that in mesial temporal lobe GNT a tailored resection that include, besides the tumor, the epileptogenic area as defined by the anatomic and electroclinical correlations performed on the ictal video-EEG data, provides better post-operative seizure outcome as compared to simple lesionectomy<sup>[36,45,61,92,93]</sup>. In cases of undetermined lateralization of seizure focus, invasive EEG investigations may provide useful information, although in GNT-associated focal epilepsy the main goal of intracerebral recordings is usually to map eloquent cortex in proximity of the neoplasm. Several reports focused on prediction





**Figure 1** Ganglioglioma World Health Organization grade I of the right posterior middle temporal gyrus. Axial FLAIR T2-w (A) and coronal IR T1-w (B) images show inhomogeneous cortical-subcortical mass extending within the deep white matter and reaching the ependymal layer. The tumor presents a combination of solid, cystic and calcified components. The latter is better identified on coronal T2\*-w sequence (C). Post-contrast axial T1-w image (D) shows no pathological enhancement and axial CT scan (E) confirms the calcified component. Coronal IR T1-w image (F) demonstrates lesion resection; G: Histological examination evidences a biphasic neoplastic population, with neuronal and glial elements.

of poor postoperative outcome by identifying ECoG spike discharge patterns in FCD and the persistence of seizure patterns or continuous epileptiform discharges in post-resection ECoG recordings. There are little evidences about the ECoG discharge patterns in patients with GNTs because of the small numbers of patients investigated<sup>[89,93,94]</sup>. Different disorders (LEAT and FCD) may have similar electrocorticographic abnormalities probably due to the common developmental origin. In these cases have been observed continuous spiking (more often in FCD), bursts, and recruiting discharges. When continuous spiking is found in GNT, it is likely to be due to associated dysplastic regions with a high neuronal density<sup>[45,93]</sup>. A recent study employed MEG to investigate possible differences in whole brain topology of epileptic glioma patients, comparing them to patients with non-glial lesions and healthy controls. LGG patients showed decreased network synchronizability compared to healthy controls in the theta frequency range (4-8 Hz), similar to patients with non glial lesions. Network characteristics are associated with clinical presentation (seizure frequency in LGG), and with poorer cognitive performance (both low grade and high grade glioma) suggesting that histology could partly determine differences in epileptogenesis and epileptic probably due to differences in cortical plasticity. Interestingly, it would seem that low grade glioma and non tumoral lesions have a decreased synchronizability that could predispose to a high occurrence of seizures

and cognitive decline.

## IMAGING

### Gangliogliomas and gangliocytoma

The differentiation between GG and gangliocytoma (GC) is mainly based on histology. They may have variable tumour size (2-3 cm) and a typical location at the periphery of cerebral hemispheres. There is usually little associated mass effect and peripheral vasogenic edema and superficial lesions may expand cortex and remodel bone.

The MR signal of GG is variable and inhomogeneous due to the presence of a combination of solid, cystic and calcified components<sup>[46,95]</sup> (Figures 1-4).

Calcifications can be more conspicuous as areas of hypointensity on T2\* gradient echo weighted images, or even more evident at unenhanced CT (Figure 1E).

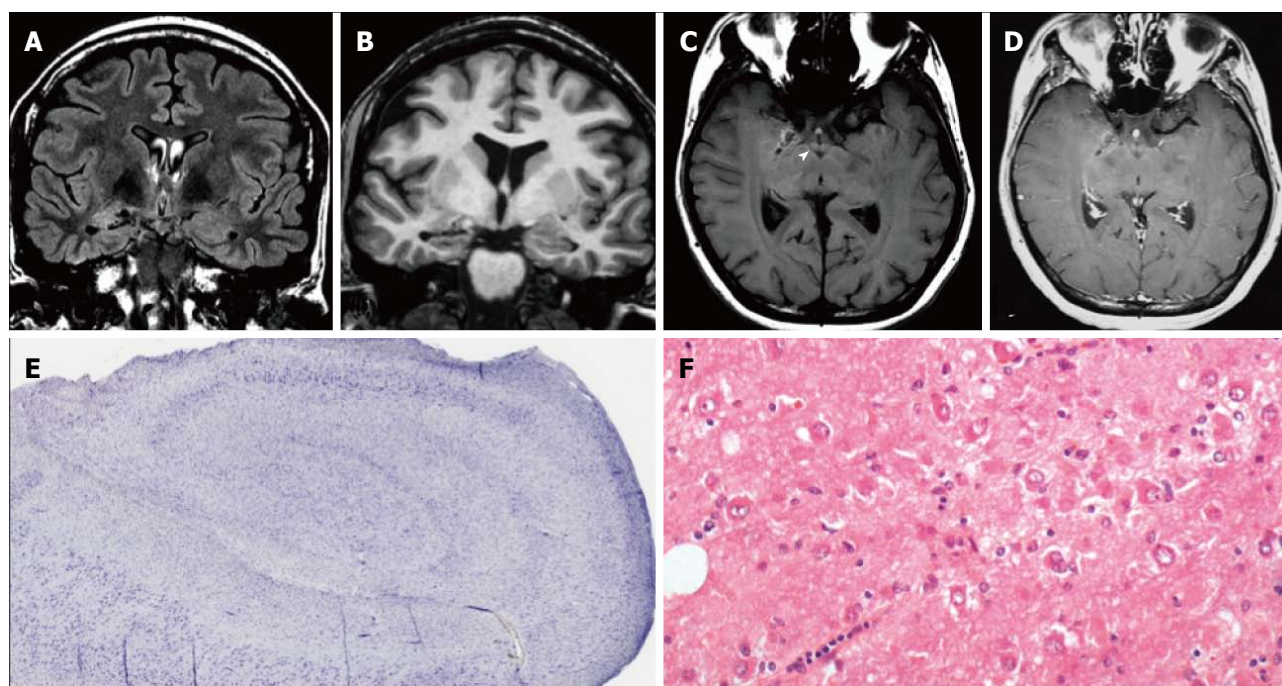
Medium contrast enhancement could be variable: nodular, intense and homogenous (Figure 3E); “ringlike” appearance (Figure 4C) but also nonenhancing (Figure 1D). Although extremely rare GG may show focal leptomeningeal involvement (Figure 4C).

### Dysembryoplastic neuroepithelial tumor

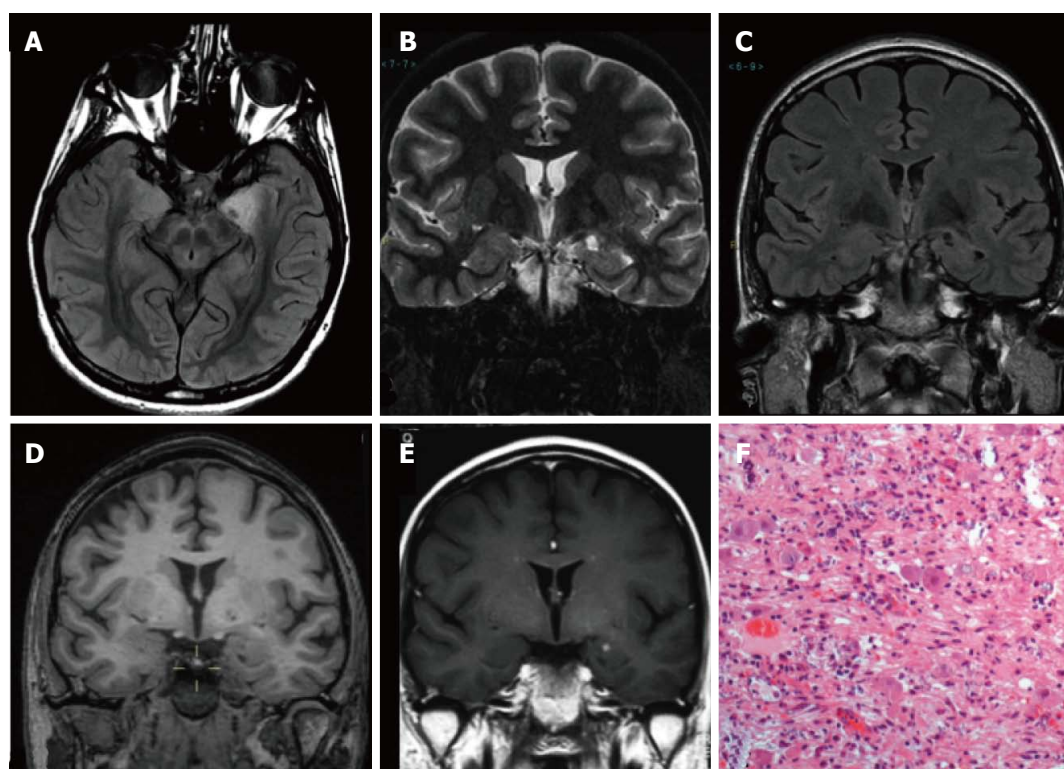
DNET are well-demarcated, wedge shaped, multinodular, “bubbly” intracortical tumors often similar to other LGG.

DNET may show a multicystic morphology more





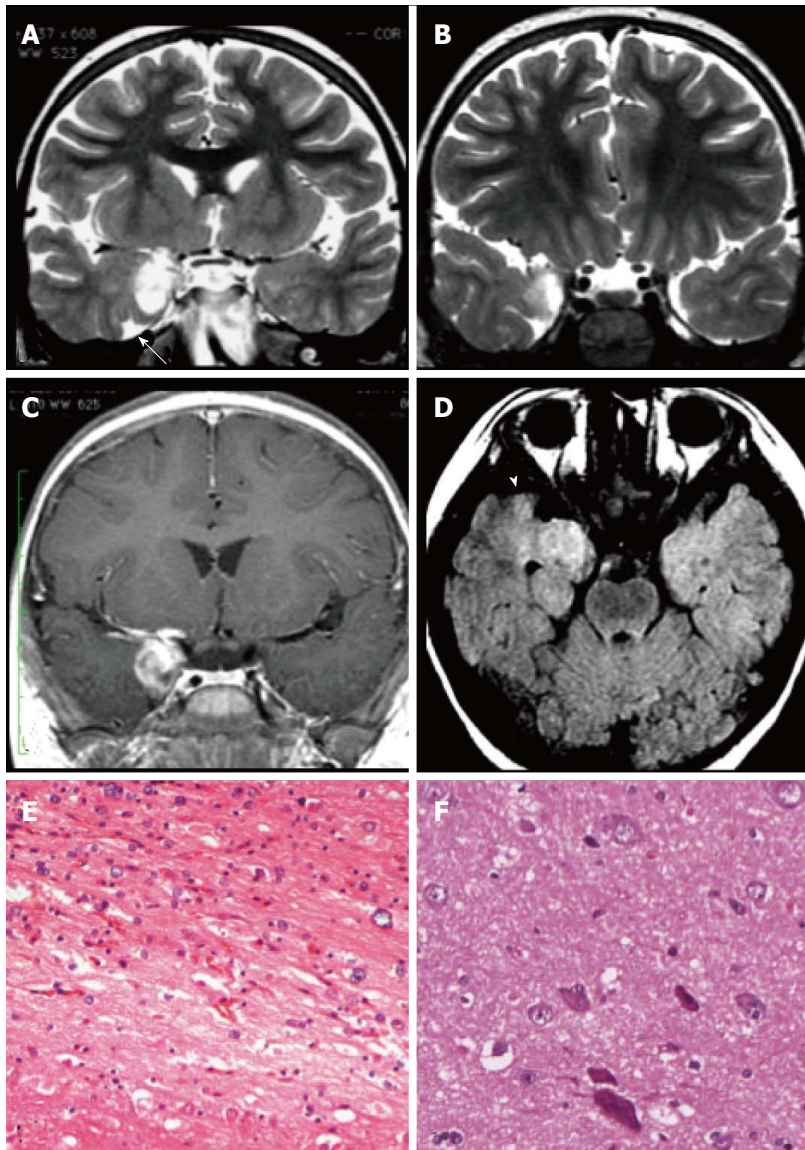
**Figure 2 Gangliocytoma and Mesial Temporal Sclerosis MTS (dual pathology).** Coronal Flair T2 (A) and T1-w images (B) demonstrate a right hippocampal atrophy with signal hyperintensity on FLAIR. The ipsilateral temporal horn is dilated. Axial T1-w pre- (C) and post-contrast injection (D) show a non-enhancing multicystic lesion with calcification near the optic tract. The right mammillary body is atrophic (arrowhead); E: Neoplastic ganglion cells exhibit disorganized clusters and show abnormal cytologic features; F: Hippocampal specimen displays ILAE hippocampal sclerosis type 1, with severe pyramidal cell loss in both CA1, CA3 and CA4 sectors.



**Figure 3 Ganglioglioma World Health Organization grade I of the left temporo-mesial cortex.** The tumor shows heterogeneous cortical-subcortical high signal on axial proton density weighted image (A). It appears partially cystic on coronal IR T1 (B) FLAIR T2 (C), T1 (D) weighted sequences. Post-contrast T1-w image displays nodular, intense and homogenous enhancement (E). Low-magnification view shows a vaguely lobulated, hypocellular vascularized neoplasia, with scattered lymphocytic infiltrates (F).

frequently than GG. Absent or very slow increase in size over time is typical of DNET, and recurrence is also

extremely rare. Contrast enhancement could be found in about 30% of cases.



**Figure 4** Ganglioglioma and associated focal cortical dysplasia IIa. Coronal FSE T2-w (A, B) demonstrate a temporo-mesial heterogeneously hyperintense lesion. Post-contrast coronal T1-w (C) shows enhancement of the tumor and adjacent leptomeninges. A signal abnormality extending from the surface of the ventricle to the pole (arrowheads in D) and adjacent anomalous sulci (arrow in A) were suspicious for FCD, subsequently histologically confirmed. Microscopy evidenced a tumor composed of ganglion cells intimately intermixed with astrocytic elements (E) and focal cortical dysplasia with dysmorphic neurons (FCD Type IIa) (F).

On CT scan the tumor appears as a cortical-subcortical hypoattenuating mass with sporadic calcifications. Scalping of the adjacent inner table of the skull may also be present. At MR imaging, DNET most commonly manifest as pseudocystic, multinodular cortical masses that are hypointense on T1-weighted images and hyperintense on T2-weighted images with minimal or without mass effect and surrounding vasogenic edema (Figures 5 and 6).

Some lesions may expand involving cortical gyri and, producing a soap bubble appearance at the cortical margin. (Figures 5 and 6).

#### **Pleomorphic Xanthoastrocytoma**

PXA classically, although not specifically, appear as cystic supratentorial mass containing a mural nodule and involving cortex and adjacent leptomeninges<sup>[96]</sup>. PXA is usually a circumscribed and slow growing lesion, that rarely recurs; size and morphology are variable.

At unenhanced CT the tumor appears as a hypo or isoattenuating mass. Calcifications are rare. On MRI T1-

WI PXA are usually hypo to isointense displaying inhomogenous, mainly iso-hyperintense, signal intensity on T2-weighted sequences. Peritumoral edema is relatively uncommon. They usually enhance after gadolinium injection (Figure 7). Leptomeninges contrast enhancement is highly characteristic<sup>[97]</sup>.

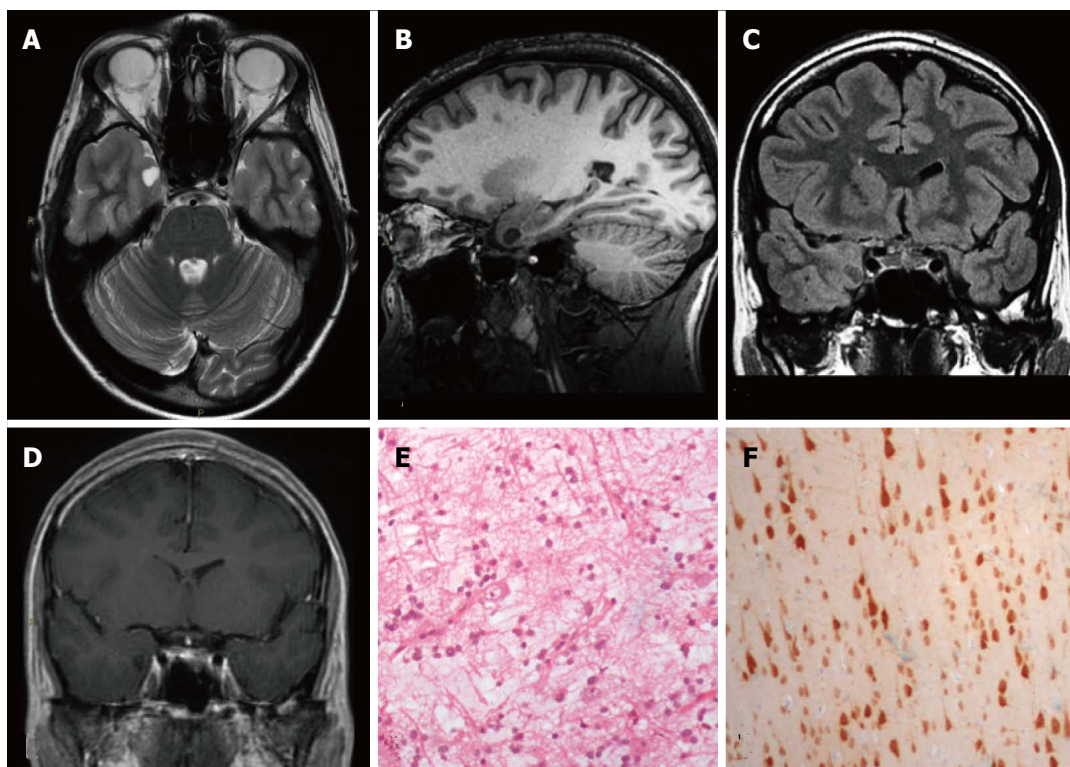
#### **Extraventricular neurocytoma**

Extraventricular neurocytoma may be difficult to differentiate from other types of low-grade tumor, such as GGs or DNET. It could be a well circumscribed, heterogeneous and variably enhancing mass. CT and MRI aspects depend on the cellularity and degree of calcification. They may have peritumoral oedema and intralesional cyst but rarely intralesional bleeding<sup>[29,98,99]</sup>.

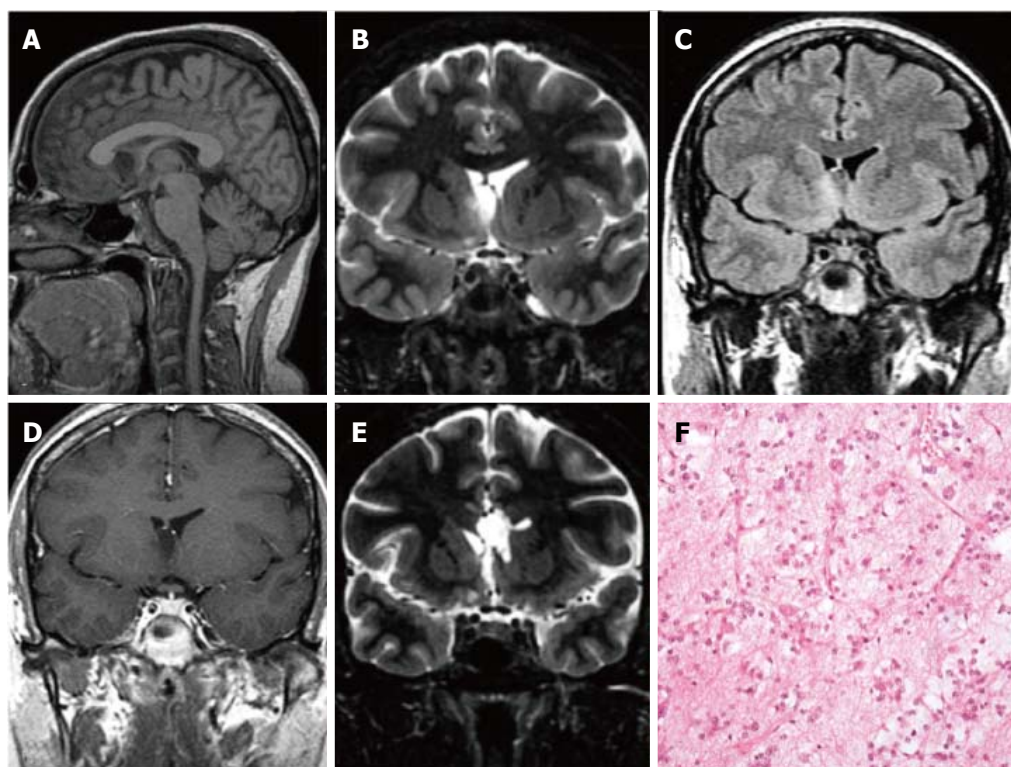
#### **Pilocytic astrocytoma**

Pilocytic astrocytomas are the most common form of glioma in childhood and most frequently manifest in the first two decades of life<sup>[100]</sup>. They may arise anywhere within the neuraxis, but among the pediatric population

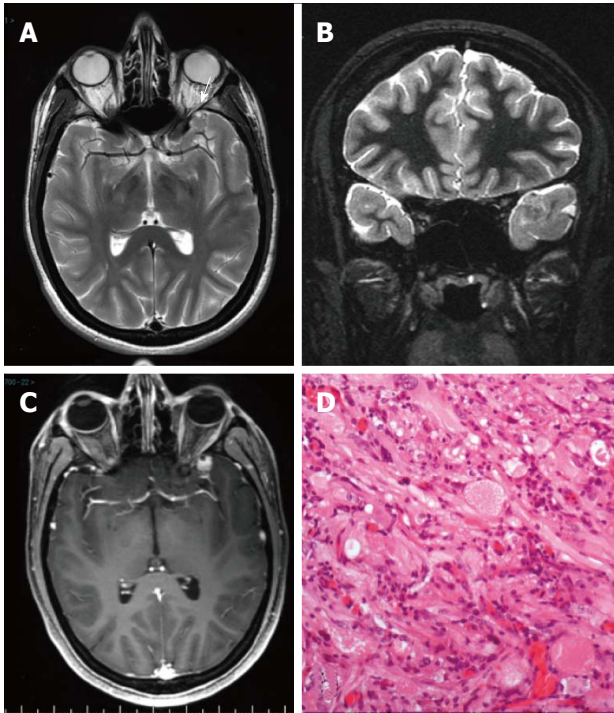




**Figure 5 DNET of the right uncus.** Axial T2-w (A) and sagittal 3D T1-w (B) reveal a cystic cortical mass well-demarcated, without perilesional oedema or mass effect. On coronal FLAIR T2-w image (C) the tumor is variably hypo- and isointense. Post-contrast axial T1-w sequence (D) shows no enhancement. Histological examination shows a tu-mor characterized by the “specific glioneuronal element”, typical of DNET, (E), while the cortex adjacent to the tumor displays cortical lamination abnormalities compatible with FCD type IIIb (F); the latter was not depicted at MR study.



**Figure 6 Extra temporal DNET.** Sagittal 3D T1 (A) coronal IR T1 (B) and FLAIR T2-w (C) demonstrate a cystic wedge-shaped lesion in the right fronto-orbital gyrus. On FLAIR T2-w the tumor is slightly hypointense with a faint hyperintense rim. On post contrast coronal T1-w images there is no enhancement uptake (D); E: Post-surgical scan on cor-onal IR T1-w; F: Microscopic study evidences the presence of floating neurons, a feature of DNET, in microcystic areas lined with oligo-like cells.



**Figure 7** Pleomorphic xanthoastrocytoma World Health Organization grade II. Axial T2 w (A) and coronal IR T1-w (B) images show temporo-polar mixed signal intensity cortical mass with a small cystic component anteriorly (arrow in A). Post-contrast coronal SE T1w (C) shows a well-delineated, peripherally located enhancing nodule. (D) Microscopically the tumor is characterized by huge cytologic atypia, a vaguely fascicular arrangement and scattered eosinophilic granular bodies.

they are more frequently found infratentorially. Optic nerves, optic chiasm and hypothalamus, basal ganglia, and thalamus represent other common localtions. Cerebral hemispheres involvement has been less frequently described<sup>[100]</sup>.

Pilocytic Astrocytomas are commonly characterized by fluid accumulation, with subsequent cyst formation and by mural nodule or a rim of tissue surrounding the cyst that enhances on post-contrast imaging. Predominantly solid mass lesions with minimal or no cyst have been described<sup>[101]</sup> (Figure 8).

Calcification may be seen in up to 25% of cases and haemorrhage has been reported. On MRI the solid portion of the neoplasm is typically isointense to hypointense on T1 weighted images and hyperintense on T2 weighted sequences to grey matter and it enhances after gadolinium chelates injection (Figure 8D). The signal intensity of the cystic portion is often not suppressed on FLAIR T2 weighted images due to its protein content.

MR spectroscopy reveals elevation in choline and reduction in NAA, with minimal elevation in lipid peak (Figure 8F). Lactate peak could be elevated, representing alteration in mitochondrial metabolism or variability in glucose uptake<sup>[102]</sup>.

### Diffuse astrocytoma

Diffuse astrocytomas are diffusely infiltrating primary brain neoplasms of astrocytic origin that are classified as

WHO grade II.

Diffuse astrocytomas are usually at unenhanced CT iso to hypoattenuating lesions. They do not enhance on post-contrast imaging. Calcifications may be present in approximately 20%; cyst formation is rare.

MRI demonstrates astrocytomas as relatively homogenous mass involving and expanding more typically cerebral hemispheres cortex and adjacent white matter. The lesions are high in water content, thus appearing as hyperintense on T2 weighted images and hypo isointense on T1 weighted sequences. They usually lack peritumoral oedema (Figure 9).

Well differentiated Astrocytomas has a variable appearance after contrast agent administration, but usually shows no significant contrast enhancement (Figure 9C). In general, contrast enhancement is not recognized as a reliable indicator of the grade of infiltrative astrocytomas. MR perfusion imaging however seems to be more informative for distinguish low- and high-grade astrocytoma and for identifying low-grade lesions that could more likely behave aggressively<sup>[103]</sup>.

On dynamic contrast enhanced T2\* weighted MR perfusion imaging study rCBV is typically less than 1.75 (Figure 9D)<sup>[104]</sup>.

MR Spectroscopy should display Cho elevation and NAA reduction. A High myo-inositol to Creatine ratio (Myo/Cre) in also present (Figure 9E)<sup>[105]</sup>.

## FOCAL CORTICAL DYSPLASIA AND LEAT

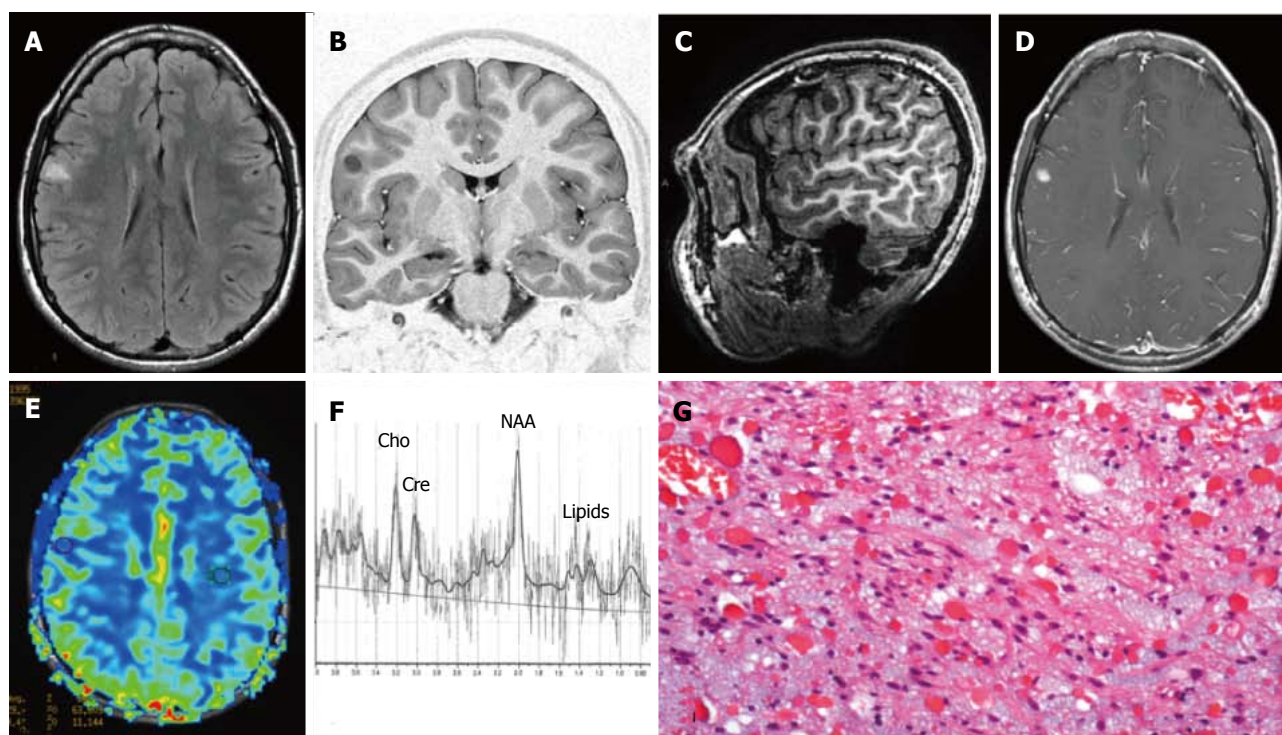
LEAT and focal cortical dysplasia FCD are common findings in drug-resistant focal epilepsies, and frequently coexist<sup>[1,6,8,24,34,36,104,106-109]</sup>.

Rarely MRI features of LEAT could be misinterpreted as FCD. Generally most important neuroradiological findings in FCD are increased cortical thickness, blurring of the cortical-white matter junction, increased signal on T2-W, a radially oriented linear or conical transmantle stripe of T2 hyperintensity, cortical thinning, and localized brain atrophy<sup>[34,110-112]</sup> (Figure 10).

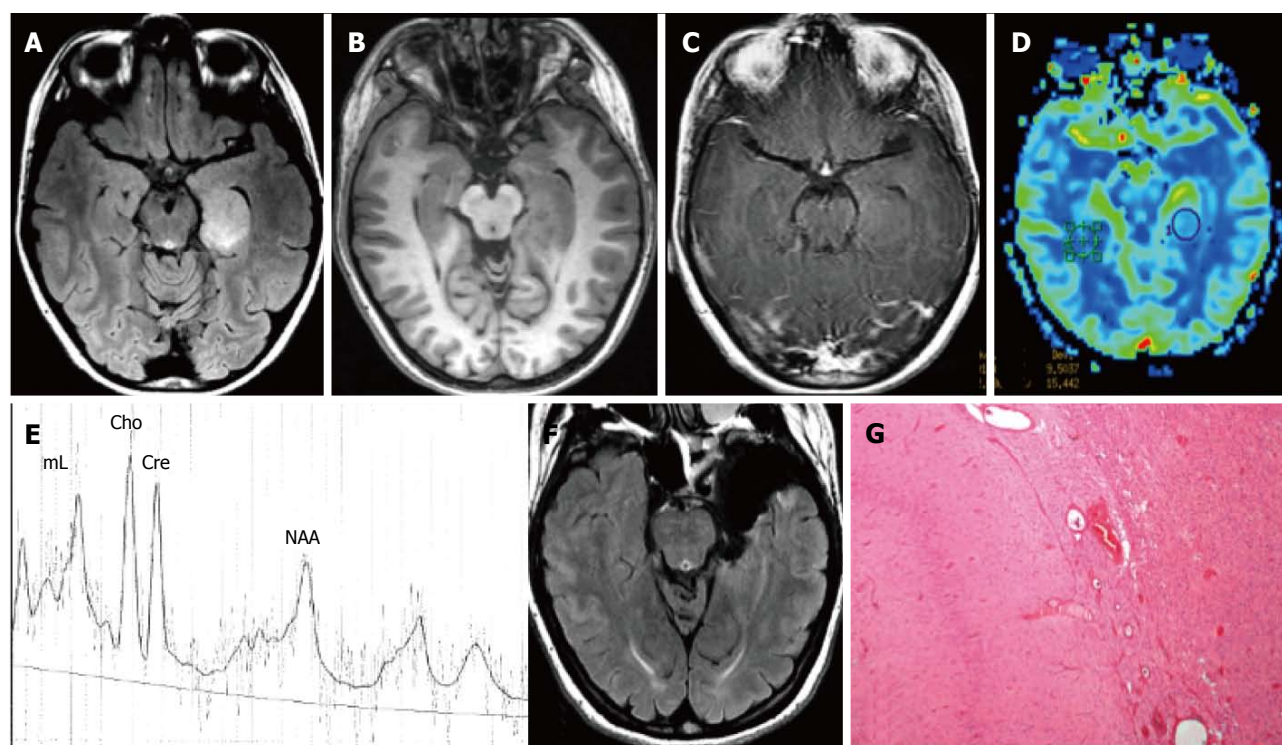
Some limitations are encountered in the correct identification of different FCD types or subtypes<sup>[111-114]</sup>. A high number of false negatives is detected with FCD type I and slightly fewer with FCD type II a (about 50% sensitivity). FCD II b is much more easily identified (about 90% sensitivity)<sup>[112,113]</sup> (Figure 10).

Association between LEAT and FCD poses further issues into its correct identification. In a limited serie of patients with LEAT, who underwent surgery at our Institution associated FCD has been correctly identified in the majority of cases<sup>[113]</sup> (Figure 4). In a few cases peritumoral edema and neoplastic infiltration both caused subcortical white matter signal alterations, determining false positives (FP) and false negatives (FN) FCD results. Indeed, the signal abnormality is able to mimic a blurring, but it could hide a FCD contiguous to the tumour (Figure 11).

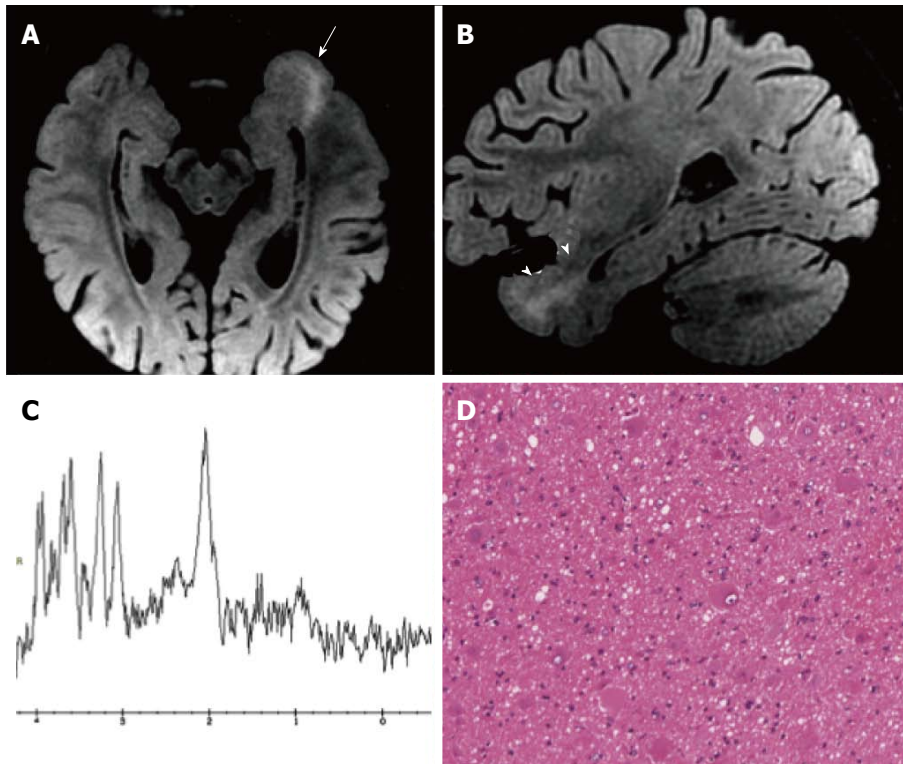




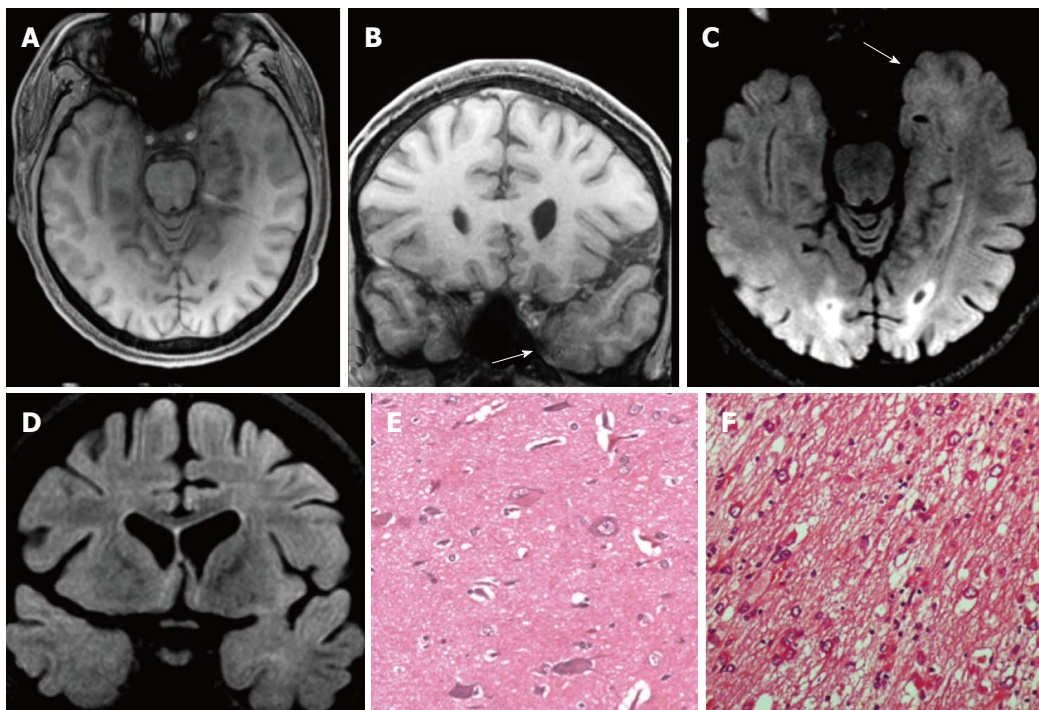
**Figure 8 Pilocytic astrocytoma World Health Organization grade I of the right frontal lobe.** Axial FLAIR T2-w (A) and coronal IR T1-w (B) images show a cortical-subcortical lesion, with cystic component, with minimal mass effect. The tumor appears well de-marcatd (C) on 3D sagittal sequence and displays nodular and homogeneous en-hancement on post-contrast axial T1-w images (D). Perfusion study doesn't show any rCBV increase within the lesion (E). MR Spectroscopy (MRS) study (F) reveals elevation in choline and reduction in NAA. (G) Histological examination shows a tumor com-posed of areas rich in myxoid material, elongated glial elements with uniform nuclei and numerous eosinophilic granular bodies.



**Figure 9 Temporo-mesial astrocytoma World Health Organization grade II.** Axial FLAIR T2-w (A) shows a left temporal hyperintense mass, involving mainly the hippocampus. The lesion is slightly hypointense on T1-w image (B) and does not demonstrate enhancement after gadolinium injection (C). Perfusion study reveals no significant rCBV increase (D). MRS study shows a faint NAA reduction, a slight Cho elevation and high ml, expression of low grade glioma (E). Postsurgical axial FLAIR T2-w (F). (G) This histological picture exhibits in the left side a portion of hippocampus and in the right side an infiltrating astrocytoma, composed of fibrillary elements with varying degree of hypercellularity.



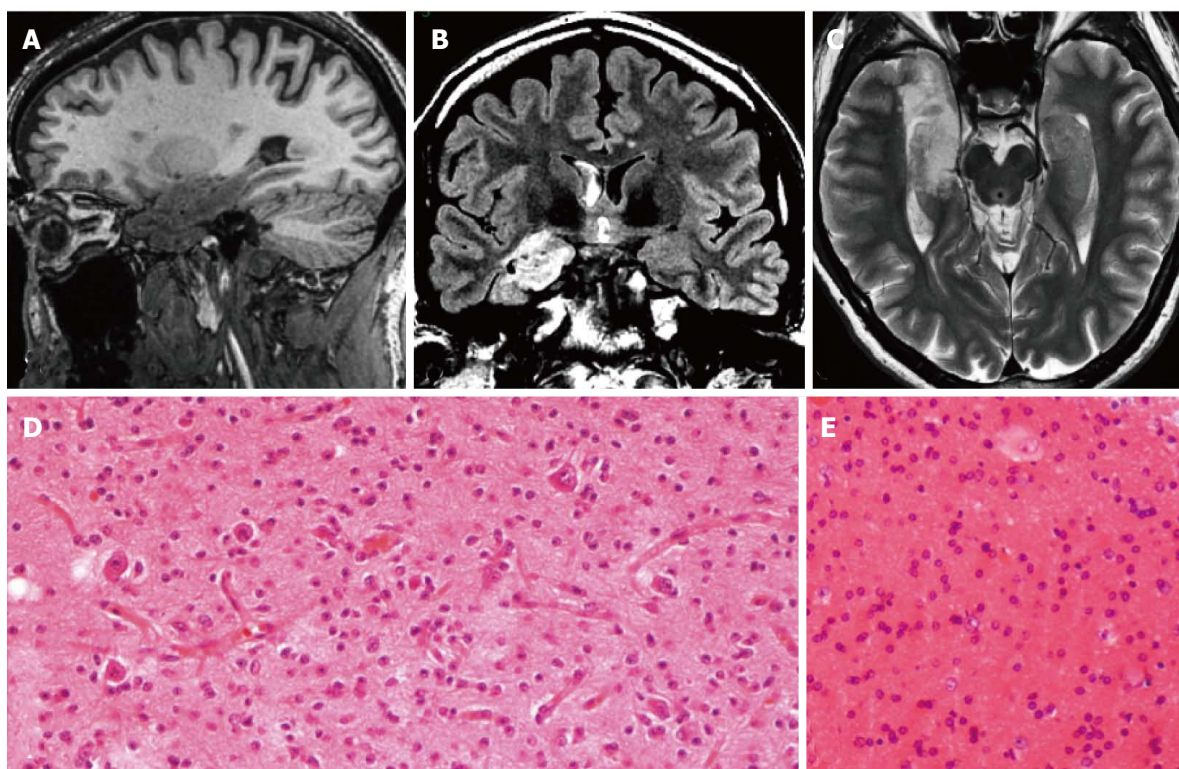
**Figure 10 Focal cortical dysplasia with balloon cells (Taylor).** Axial (A) and sagittal (B) reformatted fat-saturated 3D FLAIR images show a left temporo-mesial cortical thickening (arrow) and white matter tapering to the temporal horn of the lateral ventricle (arrowheads). MR spectroscopy shows normal metabolite concentrations (C). (D) Histology demonstrates the presence of typical balloon cells, showing large and opalescent glassy eosinophilic cytoplasm.



**Figure 11 Gangliogliomas World Health Organization grade I of the left temporo-mesial region and focal cortical dysplasia IIa subtype associated.** Axial and coronal T1-w images (A-B) show thickening of amygdala and uncus (arrow in B). Axial and coronal FLAIR T2-w images (C-D) present blurring and adjacent sub-cortical high signal abnormality compatible with a focal cortical dysplasia (FCD). Microscopy evidenced a glioneuronal tumor, with scattered binucleated ganglion cells, compatible with a gan-glioglioma (E) and dysmorphic neurons in the adjacent cortex (FCD Type IIa) (F).

These limitations were more evident when tumour size is larger (Figure 12). MRI sensibility can be reduced





**Figure 12** Gangliogliomas and focal cortical dysplasia IIa. Sagittal 3D T1-w (A), coronal FLAIR T2-w (B) and axial T2-w (C) reveal an inhomogeneous mass, involving the right hippocampus and the temporal pole. Due to the size of the tumor, the associated dysplasia is not clearly visible. Histological examination demonstrates the presence of a glioneuronal tumor with small ganglion cells in a desmoplastic stroma (D) and of dysmorphic neurons in the adjacent cortex (focal cortical dysplasia Type IIa) (E).

by an incomplete protocol too.

## MOLECULAR ASPECT OF LEAT

The following molecular markers may facilitate differential diagnosis of LEAT: (1) IDH1 and IDH2 mutations: common in low grade diffuse gliomas (70%-80%), while they are generally not present in PA and GNT<sup>[115]</sup>; (2) LOH 1p/19q: constitutes the keystone in diagnosis of oligodendrogliomas (> 70% of tumors), while it has not been detected in DNT, a useful difference in those cases in which histological aspects do not permit a conclusive diagnosis<sup>[116]</sup>; and (3) BRAF V600E mutations: frequently found in PXA, GG and PA, whereas diffuse grade II gliomas harbor only rarely these mutations<sup>[117]</sup>.

As recently observed these BRAF-mutant grade II diffuse gliomas seem to present with refractory seizures and frequently are located within the temporal lobe. It has been proposed that BRAF mutations could be strictly linked to epileptogenesis<sup>[118]</sup>.

Interestingly we found that BRAF mutations could be present in the FCD associated with LEAT, suggesting a pathogenetic role of BRAF mutations in cyto-architectural dysplasia and in the tumorigenesis of LEAT<sup>[109]</sup>.

## SURGICAL STRATEGIES FOR LEAT

Epilepsies associated to LEAT are usually unsatisfactorily

controlled by antiepileptic drugs, whereas excellent results can be achieved by surgery<sup>[4,5,26,28,42,65,92,119]</sup>. Various surgical approaches have been adopted for the radical resection of these tumors. The choice of surgical approach is also related to the goal of surgical strategy.

The surgical strategy may be directed only to oncological issues and/or to resolve epilepsy. In this last condition we must have an epilepsy surgery oriented approach.

A non-invasive presurgical study and neuropsychological assessment, may define the extension of the epileptogenic zone and may address the choice of the better surgical strategy to optimise seizure control (lesionectomy or tailored resection)<sup>[24,26,28,36,120]</sup>.

Rarely in the setting of epilepsy associated tumor may be necessary an invasive presurgical study (using subdural grid, depth electrodes, or stereo-EEG)<sup>[24,64,121-123]</sup>. LEAT are certainly the prototype of cases where epilepsy is the main problem. However, in recent years, even in cases where the main problem is oncological, it is becoming equally important trying to preserve brain functions and to best cure even epilepsy (especially when tumors involve mesiotemporal structures, the insular lobe, or the central area) in order to improve the quality of life<sup>[15,63,64,124]</sup>.

Several authors analyzed epileptological outcome according to surgical treatment in tumor-related chronic epilepsy. While some argue that lesionectomy alone is enough for good seizure control others say that the best manage-

ment should include additional resection of epileptogenic zones adjacent to the tumor<sup>[26,28,36,39,40,44,62,119,120,125,126]</sup>.

In Epilepsy-associated tumors it reaches a special meaning for the epileptogenicity and surgical strategies, the site of the lesion, *i.e.*, temporal, mesio-temporal (or limbic), temporo-lateral, paralimbic, extratemporal, eloquent areas<sup>[8,26,28,36,40,44,45,56,63,119,125,126]</sup>.

Regarding limbic and paralimbic system, the role of hippocampus in the epilepsy network is pivotal since that could play a pivotal role in epileptogenesis even without obvious neuroradiological and pathological changes (*i.e.*, hippocampal sclerosis)<sup>[26,28,36,61,64,127]</sup>.

The limbic system consists of the following elements, which are all directly or indirectly interconnected: the temporo-mesial structures (hippocampus, the parahippocampus, gyrus) and the cingulate gyrus<sup>[58,60,61,128]</sup>. The paralimbic system is composed of 3 independent anatomical parts: the orbitofrontal cortex, the temporo-polar cortex, and the insula<sup>[58,60,128]</sup>. The limbic system is connected *via* the entorhinal cortex and the uncinate fasciculus to the paralimbic system. In the setting of low-grade tumors associated with epilepsy WHO Grade II gliomas are mainly found in the paralimbic system while glioneuronal tumors are found in the limbic system (temporomesial structures)<sup>[8,57]</sup>.

LEAT are frequently associated with type I or type II a cortical dysplasia which, in contrast to focal cortical dysplasia type II b, are more difficult to identify with MRI<sup>[1,8,24,36,109,111,113]</sup>. It means that the anatomical structural lesion can be larger than what have been detected by MRI<sup>[110,113]</sup>.

For this reason the target of the surgical resection should be the epileptogenic zone defined according to neuroradiological, clinical, neurophysiological and neuropsychological findings<sup>[40,129]</sup>.

In case of LEAT located near or in eloquent area, the surgical approach is usually directed only to the anatomical structural lesion. Regarding the more frequent site of these tumors, *i.e.*, the temporal lobe, several approach have been used. The surgical strategy used in temporal lobe tumors includes lesionectomy, extended lesionectomy, tailored resection, anterior temporal lobectomy.

The majority of authors agree that lesionectomy alone provides the best seizure outcome results in LEAT located in the extratemporal and temporo-lateral site<sup>[40,42,44]</sup> while its results for temporomesial lesions are questionable<sup>[5,8,26,28,40]</sup>. Some authors suggested that the involvement of temporo-mesial regions may extend and make more complex the epileptogenic zone.

For this reason the amount of tissue removed in temporomesial surgeries is considered crucial to gain good postoperative results<sup>[5,8,60,62,63,65,125,130,131]</sup>.

One important and persistent problem are the conflicting needs of the necessary extent of resection and the avoidance of neuropsychological deficits<sup>[126,131,132]</sup>.

## SEIZURE OUTCOME

Focal epilepsy associated with LEAT and particularly

GG and DNT shows the best seizure outcome after surgery<sup>[5,18,28,36,92,95,119,132-134]</sup>. Some authors observed improvement of seizure outcome in young patients whereas others found no correlation with age at the time of surgery<sup>[4,28,38,132]</sup>.

A recent literature meta-analysis about epileptogenic gangliogliomas in adult showed that an early surgical intervention of less than 3 years from the onset of seizure is significantly associated with improved seizure control<sup>[90]</sup>.

Several studies reported that lesionectomy plus temporal tailored resection seems to offer the best results for seizure outcome<sup>[8,24,26,28,36,40]</sup>. Several authors insist that the temporal pole has a pivotal role in epileptogenesis in temporomesial epilepsy<sup>[130,135,136]</sup>.

The higher effectiveness of an extended resection beyond the LEAT might depend on the frequent association of this tumor type with other epileptogenic pathologies, such as the spectrum of cortical dysplasias that might represent the origin of a widespread epileptic network<sup>[8,24,34,36,68]</sup>.

The new class FCD Type IIIb, which includes cases with abnormal cortical layering associated with a glial or glioneuronal tumor, has been introduced by the ILAE classification<sup>[34]</sup>.

However in light of the frequent association of FCD Type II with LEAT and the immunohistochemical evidence of a common pathogenesis linking LEAT and FCD Type II<sup>[8,24,36,105]</sup>, the possibility of creating a unifying class also for this kind of FCD should be considered.

With respect to oncological behavior, LEAT are usually indolent WHO Grade I lesions, although several reports have demonstrated that gangliogliomas may potentially have an evolving course and may demonstrate malignant transformation<sup>[33,40,70]</sup>. Pleomorphic xantho-astrocytoma can carry a higher risk of early recurrence when it is characterized by numerous mitoses and/or necrosis<sup>[137-139]</sup>.

## CONCLUSION

We believe that the adjective “long-term” included in the acronym LEAT could be prospectively confusing or misleading. Nowadays patients with LEAT are operated 5 years earlier compared to mid 1990s (mean of 7.4 years *vs* 12.9 years, respectively)<sup>[1,2]</sup>.

The further increase in knowledge and a better recognition of these lesions among the scientific community (neurologists, epileptologists, neuropediatrics, neuroradiologists, epilepsy surgeons, neuropathologists) will lead to modify the present concept of “pharmacoresistance” *vs* a “tailored concept” of pharmacoresistance related to the underlying pathology submitting many more patients to an early surgical treatment<sup>[107,132,140]</sup>.

As a pathology-based approach to epilepsy surgery will be increasingly adopted<sup>[2,28,36,107,132,140,141]</sup> an early surgical treatment will become unavoidable.

In the near future this prototype of “surgically reme-



diabile cause of epilepsy” will be properly operated early, irrespective of the concept of pharmacoresistance, making the adjective “long-term” obsolete and not appropriated.

An early surgical strategy can achieve various aims, namely to obtain a definite diagnosis, to contrast epilepsy progression (including psychosocial consequences and/or adverse effects of pharmacological treatment) and even to prevent the risk, present although uncommon, of tumor growth and malignant transformation. In addition, early surgery may reduce the risk of sudden unexplained death (SUDEP) or seizure-related injuries.

Such predictable future approach will modify the clinical history of these patients, and features of epilepsy as “chronic” or “long term”, nowadays adopted in the definition of epilepsy-associated tumors, will lose sense. Neurophysiological aspects together with a proper histological and molecular characterization will become increasingly necessary for an accurate diagnosis of these epileptomas<sup>[25,34,85,142]</sup>.

Therefore, what characterizes and makes up special for this group of tumors it is not the “chronic” or “long term” epilepsy history, but their pathological-biological features (*i.e.*, sharing of immunopositivity for CD34 and of BRAF (V600E) mutation<sup>[109,143]</sup>).

## REFERENCES

- 1 **Blumcke I**, Aronica E, Urbach H, Alexopoulos A, Gonzalez-Martinez JA. A neuropathology-based approach to epilepsy surgery in brain tumors and proposal for a new terminology use for long-term epilepsy-associated brain tumors. *Acta Neuropathol* 2014; **128**: 39-54 [PMID: 24858213 DOI: 10.1007/s00401-014-1288-9]
- 2 **Blumcke I**, Russo GL, Najm I, Palmini A. Pathology-based approach to epilepsy surgery. *Acta Neuropathol* 2014; **128**: 1-3 [PMID: 24879580 DOI: 10.1007/s00401-014-1301-3]
- 3 **Thom M**, Blümcke I, Aronica E. Long-term epilepsy-associated tumors. *Brain Pathol* 2012; **22**: 350-379 [PMID: 22497610 DOI: 10.1111/j.1750-3639.2012.00582.x]
- 4 **Aronica E**, Leenstra S, van Veelen CW, van Rijen PC, Hulsebos TJ, Tersmette AC, Yankaya B, Troost D. Glioneuronal tumors and medically intractable epilepsy: a clinical study with long-term follow-up of seizure outcome after surgery. *Epilepsy Res* 2001; **43**: 179-191 [PMID: 11248530 DOI: 10.1016/S0920-1211(00)00208-4]
- 5 **Luyken C**, Blümcke I, Fimmers R, Urbach H, Elger CE, Westler OD, Schramm J. The spectrum of long-term epilepsy-associated tumors: long-term seizure and tumor outcome and neurosurgical aspects. *Epilepsia* 2003; **44**: 822-830 [PMID: 12790896 DOI: 10.1046/j.1528-1157.2003.56102.x]
- 6 **Englot DJ**, Chang EF. Rates and predictors of seizure freedom in resective epilepsy surgery: an update. *Neurosurg Rev* 2014; **37**: 389-404; discussion 404-405 [PMID: 24497269 DOI: 10.1007/s10143-014-0527-9]
- 7 **Tassi L**, Meroni A, Deleo F, Villani F, Mai R, Russo GL, Colombo N, Avanzini G, Falcone C, Brammerio M, Citterio A, Garbelli R, Spreafico R. Temporal lobe epilepsy: neuropathological and clinical correlations in 243 surgically treated patients. *Epileptic Disord* 2009; **11**: 281-292 [PMID: 19945931 DOI: 10.1684/epd.2009.0279]
- 8 **Giulioni M**, Rubboli G, Marucci G, Martinoni M, Marliani AF, Bartiromo F, Calbucci F. Focal epilepsies associated with glioneuronal tumors: review article. *Panminerva Med* 2013; **55**: 225-238 [PMID: 23676963]
- 9 **Beaumont A**, Whittle IR. The pathogenesis of tumour associated epilepsy. *Acta Neurochir (Wien)* 2000; **142**: 1-15 [PMID: 10664370 DOI: 10.1007/s007010050001]
- 10 **van Breemen MS**, Wilms EB, Vecht CJ. Epilepsy in patients with brain tumours: epidemiology, mechanisms, and management. *Lancet Neurol* 2007; **6**: 421-430 [PMID: 17434097 DOI: 10.1016/S1474-4422(07)70103-5]
- 11 **Chang EF**, Potts MB, Keles GE, Lamborn KR, Chang SM, Barbaro NM, Berger MS. Seizure characteristics and control following resection in 332 patients with low-grade gliomas. *J Neurosurg* 2008; **108**: 227-235 [PMID: 18240916 DOI: 10.3171/JNS/2008/108/2/0227]
- 12 **Sherman JH**, Moldovan K, Yeoh HK, Starke RM, Pouratian N, Shaffrey ME, Schiff D. Impact of temozolomide chemotherapy on seizure frequency in patients with low-grade gliomas. *J Neurosurg* 2011; **114**: 1617-1621 [PMID: 21235313 DOI: 10.3171/2010.12.JNS101602]
- 13 **Michelucci R**, Pasini E, Meletti S, Fallica E, Rizzi R, Florindo I, Chiari A, Monetti C, Cremonini AM, Forlivesi S, Albani F, Baruzzi A. Epilepsy in primary cerebral tumors: the characteristics of epilepsy at the onset (results from the PERNO study--Project of Emilia Romagna Region on Neuro-Oncology). *Epilepsia* 2013; **54** Suppl 7: 86-91 [PMID: 24099060 DOI: 10.1111/epi.12314]
- 14 **Maschio M**. Brain tumor-related epilepsy. *Curr Neurol Pharmacol* 2012; **10**: 124-133 [PMID: 23204982 DOI: 10.2174/157015912800604470]
- 15 **Pallud J**, Audureau E, Blonski M, Sanai N, Bauchet L, Fontaine D, Mandonnet E, Dezamis E, Psimaras D, Guyotat J, Peruzzi P, Page P, Gal B, Parraga E, Baron MH, Vlaicu M, Guillemin R, Devaux B, Duffau H, Taillandier L, Capelle L, Huberfeld G. Epileptic seizures in diffuse low-grade gliomas in adults. *Brain* 2014; **137**: 449-462 [PMID: 24374407 DOI: 10.1093/brain/awt345]
- 16 **Rudà R**, Bello L, Duffau H, Soffietti R. Seizures in low-grade gliomas: natural history, pathogenesis, and outcome after treatments. *Neuro Oncol* 2012; **14** Suppl 4: iv55-iv64 [PMID: 23095831 DOI: 10.1093/neuonc/nos199]
- 17 **Rajneesh KF**, Binder DK. Tumor-associated epilepsy. *Neurosurg Focus* 2009; **27**: E4 [PMID: 19645560 DOI: 10.3171/2009.5.FOCUS09101]
- 18 **Chang EF**, Christie C, Sullivan JE, Garcia PA, Tihan T, Gupta N, Berger MS, Barbaro NM. Seizure control outcomes after resection of dysembryoplastic neuroepithelial tumor in 50 patients. *J Neurosurg Pediatr* 2010; **5**: 123-130 [PMID: 20043747 DOI: 10.3171/2009.8.PEDS09368]
- 19 **Rudà R**, Trevisan E, Soffietti R. Epilepsy and brain tumors. *Curr Opin Oncol* 2010; **22**: 611-620 [PMID: 20706121 DOI: 10.1097/CCO.0b013e32833de99d]
- 20 **Sanai N**, Chang S, Berger MS. Low-grade gliomas in adults. *J Neurosurg* 2011; **115**: 948-965 [PMID: 22043865 DOI: 10.3171/2011.7.JNS101238]
- 21 **Duffau H**. Awake surgery for incidental WHO grade II gliomas involving eloquent areas. *Acta Neurochir (Wien)* 2012; **154**: 575-584; discussion 584 [PMID: 22139145 DOI: 10.1007/s00701-011-1216-x]
- 22 **Duffau H**, Peggy Gatignol ST, Mandonnet E, Capelle L, Taillandier L. Intraoperative subcortical stimulation mapping of language pathways in a consecutive series of 115 patients with Grade II glioma in the left dominant hemisphere. *J Neurosurg* 2008; **109**: 461-471 [PMID: 18759577 DOI: 10.3171/JNS/2008/109/9/0461]
- 23 **Aronica E**, Crino PB. Epilepsy related to developmental tumors and malformations of cortical development. *Neurotherapeutics* 2014; **11**: 251-268 [PMID: 24481729 DOI: 10.1007/s13311-013-0251-0]
- 24 **Cossu M**, Fuschillo D, Brammerio M, Galli C, Gozzo F, Pelliccia V, Casaceli G, Tassi L, Lo Russo G. Epilepsy surgery of focal cortical dysplasia-associated tumors. *Epilepsia* 2013; **54** Suppl 9: 115-122 [PMID: 24328884 DOI: 10.1111/epi.12455]

- 25 Japp A, Gielen GH, Becker AJ. Recent aspects of classification and epidemiology of epilepsy-associated tumors. *Epilepsia* 2013; **54** Suppl 9: 5-11 [PMID: 24328865 DOI: 10.1111/epi.12436]
- 26 Giulioni M, Rubboli G, Marucci G, Martinoni M, Volpi L, Michelucci R, Marliani AF, Bisulli F, Tinuper P, Castana L, Sartori I, Calbucci F. Seizure outcome of epilepsy surgery in focal epilepsies associated with temporomesial glioneuronal tumors: lesionectomy compared with tailored resection. *J Neurosurg* 2009; **111**: 1275-1282 [PMID: 19408976 DOI: 10.3171/2009.3.JNS081350]
- 27 Giulioni M. Epilepsy. *J Neurosurg* 2013; **118**: 915-917 [PMID: 23432110 DOI: 10.3171/2012.11.JNS12574]
- 28 Babini M, Giulioni M, Galassi E, Marucci G, Martinoni M, Rubboli G, Volpi L, Zucchelli M, Nicolini F, Marliani AF, Michelucci R, Calbucci F. Seizure outcome of surgical treatment of focal epilepsy associated with low-grade tumors in children. *J Neurosurg Pediatr* 2013; **11**: 214-223 [PMID: 23215740 DOI: 10.3171/2012.11.PEDS12137]
- 29 Giulioni M, Martinoni M, Rubboli G, Marucci G, Marliani AF, Battaglia S, Badaloni F, Pozzati E, Calbucci F. Temporomesial extraventricular neurocytoma and cortical dysplasia in focal temporal lobe epilepsy. *J Clin Neurosci* 2011; **18**: 147-148 [PMID: 20851605 DOI: 10.1016/j.jocn.2010.03.058]
- 30 Louis DN, Ohgaki H, Wiestler OD, Cavenee WK, Burger PC, Jouvet A, Scheithauer BW, Kleihues P. The 2007 WHO classification of tumours of the central nervous system. *Acta Neuropathol* 2007; **114**: 97-109 [PMID: 17618441]
- 31 Prayson RA. Brain tumors in adults with medically intractable epilepsy. *Am J Clin Pathol* 2011; **136**: 557-563 [PMID: 21917677 DOI: 10.1309/AJCP0RBUQAQPZOU]
- 32 Prayson RA. Tumours arising in the setting of paediatric chronic epilepsy. *Pathology* 2010; **42**: 426-431 [PMID: 20632818 DOI: 10.3109/00313025.2010.493870]
- 33 Luyken C, Blümcke I, Fimmers R, Urbach H, Wiestler OD, Schramm J. Supratentorial gangliogliomas: histopathologic grading and tumor recurrence in 184 patients with a median follow-up of 8 years. *Cancer* 2004; **101**: 146-155 [PMID: 15222000]
- 34 Blümcke I, Thom M, Aronica E, Armstrong DD, Vinters HV, Palmini A, Jacques TS, Avanzini G, Barkovich AJ, Battaglia G, Becker A, Cepeda C, Cendes F, Colombo N, Crino P, Cross JH, Delalande O, Dubeau F, Duncan J, Guerrini R, Kahane P, Mathern G, Najm I, Ozkara C, Raybaud C, Represa A, Roper SN, Salamon N, Schulze-Bonhage A, Tassi L, Vezzani A, Spreafico R. The clinicopathologic spectrum of focal cortical dysplasias: a consensus classification proposed by an ad hoc Task Force of the ILAE Diagnostic Methods Commission. *Epilepsia* 2011; **52**: 158-174 [PMID: 21219302 DOI: 10.1111/j.1528]
- 35 Bauer R, Dobesberger J, Unterhofer C, Unterberger I, Walscher G, Bauer G, Trinka E, Ortler M. Outcome of adult patients with temporal lobe tumours and medically refractory focal epilepsy. *Acta Neurochir (Wien)* 2007; **149**: 1211-1226; discussion 1211-1226; [PMID: 17940725]
- 36 Giulioni M, Marucci G, Martinoni M, Volpi L, Riguzzi P, Marliani AF, Bisulli F, Tinuper P, Tassinari CA, Michelucci R, Rubboli G. Seizure outcome in surgically treated drug-resistant mesial temporal lobe epilepsy based on the recent histopathological classifications. *J Neurosurg* 2013; **119**: 37-47 [PMID: 23641822 DOI: 10.3171/2013.3.JNS122132]
- 37 Blümcke I, Wiestler OD. Gangliogliomas: an intriguing tumor entity associated with focal epilepsies. *J Neuropathol Exp Neurol* 2002; **61**: 575-584 [PMID: 12125736]
- 38 Im SH, Chung CK, Cho BK, Lee SK. Supratentorial ganglioglioma and epilepsy: postoperative seizure outcome. *J Neurooncol* 2002; **57**: 59-66 [PMID: 12125968]
- 39 Morris HH, Matkovic Z, Estes ML, Prayson RA, Comair YG, Turnbull J, Najm I, Kotagal P, Wyllie E. Ganglioglioma and intractable epilepsy: clinical and neurophysiologic features and predictors of outcome after surgery. *Epilepsia* 1998; **39**: 307-313 [PMID: 9578050 DOI: 10.1111/j.1528-1157.1998.tb01378.x]
- 40 Giulioni M, Gardella E, Rubboli G, Roncaroli F, Zucchelli M, Bernardi B, Tassinari CA, Calbucci F. Lesionectomy in epileptogenic gangliogliomas: seizure outcome and surgical results. *J Clin Neurosci* 2006; **13**: 529-535 [PMID: 16769514]
- 41 Daumas-Duport C, Scheithauer BW, Chodkiewicz JP, Laws ER, Vedrenne C. Dysembryoplastic neuroepithelial tumor: a surgically curable tumor of young patients with intractable partial seizures. Report of thirty-nine cases. *Neurosurgery* 1988; **23**: 545-556 [PMID: 3143922]
- 42 Cataltepe O, Turanli G, Yalnizoglu D, Topçu M, Akalan N. Surgical management of temporal lobe tumor-related epilepsy in children. *J Neurosurg* 2005; **102**: 280-287 [PMID: 15881751]
- 43 Minkin K, Klein O, Mancini J, Lena G. Surgical strategies and seizure control in pediatric patients with dysembryoplastic neuroepithelial tumors: a single-institution experience. *J Neurosurg Pediatr* 2008; **1**: 206-210 [PMID: 18352764 DOI: 10.3171/PED/2008/1/3/206]
- 44 Giulioni M, Galassi E, Zucchelli M, Volpi L. Seizure outcome of lesionectomy in glioneuronal tumors associated with epilepsy in children. *J Neurosurg* 2005; **102**: 288-293 [PMID: 15881752]
- 45 Schramm J, Aliashkevich AF. Surgery for temporal medio-basal tumors: experience based on a series of 235 patients. *Neurosurgery* 2007; **60**: 285-294; discussion 294-295 [PMID: 17290179]
- 46 Adachi Y, Yagishita A. Gangliogliomas: Characteristic imaging findings and role in the temporal lobe epilepsy. *Neuroradiology* 2008; **50**: 829-834 [PMID: 18516598 DOI: 10.1007/s00234-008-0410-x]
- 47 Giulioni M, Rubboli G, Marucci G, Martinoni M, Marliani AF, Riguzzi P, Calbucci F. Focal epilepsy associated with dysembryoplastic neuroepithelial tumor in the area of the caudate nucleus. *Clin Neurol Neurosurg* 2012; **114**: 1119-1122 [PMID: 22809555 DOI: 10.1016/j.clineuro.2012.06.003]
- 48 Perry A, Giannini C, Scheithauer BW, Rojiani AM, Yachnis AT, Seo IS, Johnson PC, Kho J, Shapiro S. Composite pleomorphic xanthoastrocytoma and ganglioglioma: report of four cases and review of the literature. *Am J Surg Pathol* 1997; **21**: 763-771 [PMID: 9236832 DOI: 10.1097/00000478-199707000-00004]
- 49 Powell SZ, Yachnis AT, Rorke LB, Rojiani AM, Eskin TA. Divergent differentiation in pleomorphic xanthoastrocytoma. Evidence for a neuronal element and possible relationship to ganglion cell tumors. *Am J Surg Pathol* 1996; **20**: 80-85 [PMID: 8540612]
- 50 Kim DH, Suh YL. Pseudopapillary neurocytoma of temporal lobe with glial differentiation. *Acta Neuropathol* 1997; **94**: 187-191 [PMID: 9255395]
- 51 Korshunov A, Meyer J, Capper D, Christians A, Remke M, Witt H, Pfister S, von Deimling A, Hartmann C. Combined molecular analysis of BRAF and IDH1 distinguishes pilocytic astrocytoma from diffuse astrocytoma. *Acta Neuropathol* 2009; **118**: 401-405 [PMID: 19543740 DOI: 10.1007/s00401-009-0550-z]
- 52 Bodi I, Selway R, Bannister P, Doey L, Mullatti N, Elwes R, Honavar M. Diffuse form of dysembryoplastic neuroepithelial tumour: the histological and immunohistochemical features of a distinct entity showing transition to dysembryoplastic neuroepithelial tumour and ganglioglioma. *Neuropathol Appl Neurobiol* 2012; **38**: 411-425 [PMID: 21988102 DOI: 10.1111/j.1365-2990.2011.01225.x]
- 53 Kim YH, Nobusawa S, Mittelbronn M, Paulus W, Brokinke B, Keyvani K, Sure U, Wrede K, Nakazato Y, Tanaka Y, Vital A, Mariani L, Stawski R, Watanabe T, De Girolami U, Kleihues P, Ohgaki H. Molecular classification of low-grade diffuse gliomas. *Am J Pathol* 2010; **177**: 2708-2714 [PMID: 20851605 DOI: 10.1016/j.jocn.2010.03.058]

- 21075857 DOI: 10.2353/ajpath.2010.100680]
- 54 **Xiong J**, Ding L, Chen H, Chen H, Wang Y. Mixed glioneuronal tumor: a dysembryoplastic neuroepithelial tumor with rosette-forming glioneuronal tumor component. *Neuropathology* 2013; **33**: 431-435 [PMID: 23163721 DOI: 10.1111/neup.12000]
  - 55 **Prayson RA**, Napekoski KM. Composite ganglioglioma/dysembryoplastic neuroepithelial tumor: a clinicopathologic study of 8 cases. *Hum Pathol* 2012; **43**: 1113-1118 [PMID: 22221701]
  - 56 **Mandonnet E**, Capelle L, Duffau H. Extension of paralimbic low grade gliomas: toward an anatomical classification based on white matter invasion patterns. *J Neurooncol* 2006; **78**: 179-185 [PMID: 16739029]
  - 57 **Capizzano AA**, Kirby P, Moritani T. Limbic Tumors of the Temporal Lobe: Radiologic-Pathologic Correlation. *Clin Neuro-radiol* 2014 [PMID: 24474261 DOI: 10.1007/s00062-014-0287-5]
  - 58 **Yaşargil MG**, von Ammon K, Cavazos E, Doczi T, Reeves JD, Roth P. Tumours of the limbic and paralimbic systems. *Acta Neurochir (Wien)* 1992; **118**: 40-52 [PMID: 1414529]
  - 59 **Lövlad KO**, Schaller K. Surgical anatomy and functional connectivity of the limbic system. *Neurosurg Focus* 2009; **27**: E3 [PMID: 19645559 DOI: 10.3171/2009.5.FOCUS09103]
  - 60 **Wen HT**, Rhoton AL, de Oliveira E, Cardoso AC, Tedeschi H, Baccanelli M, Marino R. Microsurgical anatomy of the temporal lobe: part 1: mesial temporal lobe anatomy and its vascular relationships as applied to amygdalohippocampectomy. *Neurosurgery* 1999; **45**: 549-591; discussion 591-592 [PMID: 10493377]
  - 61 **Schramm J**, Aliashkevich AF. Temporal mediobasal tumors: a proposal for classification according to surgical anatomy. *Acta Neurochir (Wien)* 2008; **150**: 857-864; discussion 864 [PMID: 18726061 DOI: 10.1007/s00701-008-0013-7]
  - 62 **Schramm J**. Temporal lobe epilepsy surgery and the quest for optimal extent of resection: a review. *Epilepsia* 2008; **49**: 1296-1307 [PMID: 18410360 DOI: 10.1111/j.1528-1167.2008.01604.x]
  - 63 **Ghareeb F**, Duffau H. Intractable epilepsy in paralimbic Word Health Organization Grade II gliomas: should the hippocampus be resected when not invaded by the tumor? *J Neurosurg* 2012; **116**: 1226-1234 [PMID: 22404676 DOI: 10.3171/2012.1.JNS112120]
  - 64 **Duffau H**. Brain mapping in tumors: intraoperative or extraoperative? *Epilepsia* 2013; **54** Suppl 9: 79-83 [PMID: 24328878 DOI: 10.1111/epi.12449]
  - 65 **Clusmann H**, Schramm J, Kral T, Helmstaedter C, Ostertun B, Fimmers R, Haun D, Elger CE. Prognostic factors and outcome after different types of resection for temporal lobe epilepsy. *J Neurosurg* 2002; **97**: 1131-1141 [PMID: 12450036 DOI: 10.3171/jns.2002.97.5.1131]
  - 66 **Shamji ME**, Fric-Shamji EC, Benoit BG. Brain tumors and epilepsy: pathophysiology of peritumoral changes. *Neurosurg Rev* 2009; **32**: 275-284; discussion 284-286 [PMID: 19205766 DOI: 10.1007/s10143-009-0191-7]
  - 67 **Williamson A**, Patrylo PR, Lee S, Spencer DD. Physiology of human cortical neurons adjacent to cavernous malformations and tumors. *Epilepsia* 2003; **44**: 1413-1419 [PMID: 14636349]
  - 68 **Aronica E**, Redeker S, Boer K, Spliet WG, van Rijen PC, Gorter JA, Troost D. Inhibitory networks in epilepsy-associated gangliogliomas and in the perilesional epileptic cortex. *Epilepsy Res* 2007; **74**: 33-44 [PMID: 17267178 DOI: 10.1016/j.eplepsyres.2006.12.002]
  - 69 **You G**, Sha Z, Jiang T. The pathogenesis of tumor-related epilepsy and its implications for clinical treatment. *Seizure* 2012; **21**: 153-159 [PMID: 22300623 DOI: 10.1016/j.seizure.2011.12.016]
  - 70 **Lee MC**, Kang JY, Seol MB, Kim HS, Woo JY, Lee JS, Jung S, Kim JH, Woo YJ, Kim MK, Kim HI, Kim SU. Clinical features and epileptogenesis of dysembryoplastic neuroepithelial tumor. *Childs Nerv Syst* 2006; **22**: 1611-1618 [PMID: 16944177]
  - 71 **Barba C**, Coras R, Giordano F, Buccoliero AM, Genitori L, Blümcke I, Guerrini R. Intrinsic epileptogenicity of gangliogliomas may be independent from co-occurring focal cortical dysplasia. *Epilepsy Res* 2011; **97**: 208-213 [PMID: 21831599 DOI: 10.1016/j.eplepsyres.2011.07.004]
  - 72 **Chassoux F**, Landré E, Mellerio C, Laschet J, Devaux B, Daumas-Duport C. Dysembryoplastic neuroepithelial tumors: epileptogenicity related to histologic subtypes. *Clin Neurophysiol* 2013; **124**: 1068-1078 [PMID: 23276492 DOI: 10.1016/j.clinph.2012.11.015]
  - 73 **Wolf HK**, Birkholz T, Wellmer J, Blümcke I, Pietsch T, Wiestler OD. Neurochemical profile of glioneuronal lesions from patients with pharmacoresistant focal epilepsies. *J Neuropathol Exp Neurol* 1995; **54**: 689-697 [PMID: 7666058 DOI: 10.1097/00005072-199509000-00011]
  - 74 **Aronica E**, Yankaya B, Jansen GH, Leenstra S, van Veelen CW, Gorter JA, Troost D. Ionotropic and metabotropic glutamate receptor protein expression in glioneuronal tumours from patients with intractable epilepsy. *Neuropathol Appl Neurobiol* 2001; **27**: 223-237 [PMID: 11489142 DOI: 10.1046/j.0305-1846.2001.00314.x]
  - 75 **Samadani U**, Judkins AR, Akpalu A, Aronica E, Crino PB. Differential cellular gene expression in ganglioglioma. *Epilepsia* 2007; **48**: 646-653 [PMID: 17437409 DOI: 10.1111/j.1528-1167.2007.00925.x]
  - 76 **Fassunke J**, Majores M, Tresch A, Niehusmann P, Grote A, Schoch S, Becker AJ. Array analysis of epilepsy-associated gangliogliomas reveals expression patterns related to aberrant development of neuronal precursors. *Brain* 2008; **131**: 3034-3050 [PMID: 18819986 DOI: 10.1093/brain/awn233]
  - 77 **Becker AJ**, Blümcke I, Urbach H, Hans V, Majores M. Molecular neuropathology of epilepsy-associated glioneuronal malformations. *J Neuropathol Exp Neurol* 2006; **65**: 99-108 [PMID: 16462201 DOI: 10.1097/01.jnen.0000199570.19344.33]
  - 78 **Vezzani A**, French J, Bartfai T, Baram TZ. The role of inflammation in epilepsy. *Nat Rev Neurol* 2011; **7**: 31-40 [PMID: 21135885 DOI: 10.1038/nrneurol.2010.178]
  - 79 **Vezzani A**, Auvin S, Ravizza T, and Aronica E: Glia-neuronal interactions in ictogenesis and epileptogenesis: role of inflammatory mediators. In: Noebels JL, Avoli M, Rogawski MA, Olsen RW, Delgado-Escueta AV, editors. *Jasper's Basic Mechanisms of the Epilepsies* [Internet]. 4th ed. Bethesda (MD): National Center for Biotechnology Information (US), 2012. Available from: URL: <http://www.ncbi.nlm.nih.gov/books/NBK98146/>
  - 80 **de Groot M**, Toering ST, Boer K, Spliet WG, Heimans JJ, Aronica E, Reijneveld JC. Expression of synaptic vesicle protein 2A in epilepsy-associated brain tumors and in the peritumoral cortex. *Neuro Oncol* 2010; **12**: 265-273 [PMID: 20167814 DOI: 10.1093/neuonc/nop028]
  - 81 **Prabowo AS**, Iyer AM, Veersema TJ, Anink JJ, Schouten-van Meeteren AY, Spliet WG, van Rijen PC, Ferrier CH, Capper D, Thom M, Aronica E. BRAF V600E mutation is associated with mTOR signaling activation in glioneuronal tumors. *Brain Pathol* 2014; **24**: 52-66 [PMID: 23941441 DOI: 10.1111/bpa.12081]
  - 82 **Vezzani A**. Before epilepsy unfolds: finding the epileptogenesis switch. *Nat Med* 2012; **18**: 1626-1627 [PMID: 23135516 DOI: 10.1038/nm.2982]
  - 83 **Wong M**, Crino PB. mTOR and Epileptogenesis in Developmental Brain Malformations. In: Noebels JL, Avoli M, Rogawski MA, Olsen RW, Delgado-Escueta AV, editors. *Jasper's Basic Mechanisms of the Epilepsies* [Internet]. 4th ed. Bethesda (MD): National Center for Biotechnology Information (US), 2012. Available from: URL: <http://www.ncbi.nlm.nih.gov/books/NBK98145/>
  - 84 **Prayson RA**, Fong J, Najm I. Coexistent pathology in



- chronic epilepsy patients with neoplasms. *Mod Pathol* 2010; **23**: 1097-1103 [PMID: 20495542 DOI: 10.1038/mod-pathol.2010.94]
- 85 **Thom M**, Toma A, An S, Martinian L, Hadjivassiliou G, Ratilal B, Dean A, McEvoy A, Sisodiya SM, Brandner S. One hundred and one dysembryoplastic neuroepithelial tumors: an adult epilepsy series with immunohistochemical, molecular genetic, and clinical correlations and a review of the literature. *J Neuropathol Exp Neurol* 2011; **70**: 859-878 [PMID: 21937911 DOI: 10.1097/NEN.0b013e3182302475]
  - 86 **Compton JJ**, Laack NN, Eckel LJ, Schomas DA, Giannini C, Meyer FB. Long-term outcomes for low-grade intracranial ganglioglioma: 30-year experience from the Mayo Clinic. *J Neurosurg* 2012; **117**: 825-830 [PMID: 22957524 DOI: 10.3171/2012.7.JNS111260]
  - 87 **Southwell DG**, Garcia PA, Berger MS, Barbaro NM, Chang EF. Long-term seizure control outcomes after resection of gangliogliomas. *Neurosurgery* 2012; **70**: 1406-1413; discussion 1406-1413 [PMID: 22353798 DOI: 10.1227/NEU.0b013e3182500a4c]
  - 88 **Kerkhof M**, Vecht CJ. Seizure characteristics and prognostic factors of gliomas. *Epilepsia* 2013; **54** Suppl 9: 12-17 [PMID: 24328866 DOI: 10.1111/epi.12437]
  - 89 **Ozlen F**, Gunduz A, Asan Z, Tanriverdi T, Ozkara C, Yeni N, Yalcinkaya C, Ozyurt E, Uzan M. Dysembryoplastic neuroepithelial tumors and gangliogliomas: clinical results of 52 patients. *Acta Neurochir (Wien)* 2010; **152**: 1661-1671 [PMID: 20526635 DOI: 10.1007/s00701-010-0696-4]
  - 90 **Yang I**, Chang EF, Han SJ, Barry JJ, Fang S, Tihan T, Barbaro NM, Parsa AT. Early surgical intervention in adult patients with ganglioglioma is associated with improved clinical seizure outcomes. *J Clin Neurosci* 2011; **18**: 29-33 [PMID: 20961765 DOI: 10.1016/j.jocn.2010.05.002]
  - 91 **Kwan P**, Arzimanoglou A, Berg AT, Brodie MJ, Allen Hauser W, Mathern G, Moshé SL, Perucca E, Wiebe S, French J. Definition of drug resistant epilepsy: consensus proposal by the ad hoc Task Force of the ILAE Commission on Therapeutic Strategies. *Epilepsia* 2010; **51**: 1069-1077 [PMID: 19889013 DOI: 10.1111/j.1528-1167.2009.02397.x]
  - 92 **Clusmann H**, Kral T, Gleissner U, Sassen R, Urbach H, Blümcke I, Bogucki J, Schramm J. Analysis of different types of resection for pediatric patients with temporal lobe epilepsy. *Neurosurgery* 2004; **54**: 847-859; discussion 859-860 [PMID: 15046650 DOI: 10.1227/01.neu.0000114141.37640.37]
  - 93 **Gelinas JN**, Battison AW, Smith S, Connolly MB, Steinbok P. Electroconvulsive therapy and seizure outcomes in children with lesional epilepsy. *Childs Nerv Syst* 2011; **27**: 381-390 [PMID: 20857122 DOI: 10.1007/s00381-010-1279-7]
  - 94 **Ferrier CH**, Aronica E, Leijten FS, Spliet WG, van Huffelen AC, van Rijen PC, Binnie CD. Electroconvulsive discharge patterns in glioneuronal tumors and focal cortical dysplasia. *Epilepsia* 2006; **47**: 1477-1486 [PMID: 16981863 DOI: 10.1111/j.1528-1167.2006.00619.x]
  - 95 **Zentner J**, Wolf HK, Ostertun B, Hufnagel A, Campos MG, Solymosi L, Schramm J. Gangliogliomas: clinical, radiological, and histopathological findings in 51 patients. *J Neurol Neurosurg Psychiatry* 1994; **57**: 1497-1502 [PMID: 7798980 DOI: 10.1136/jnnp.57.12.1497]
  - 96 **Lipper MH**, Eberhard DA, Phillips CD, Vezina LG, Cail WS. Pleomorphic xanthoastrocytoma, a distinctive astroglial tumor: neuroradiologic and pathologic features. *AJNR Am J Neuroradiol* 1993; **14**: 1397-1404 [PMID: 8279337]
  - 97 **Crespo-Rodríguez AM**, Smirniotopoulos JG, Rushing EJ. MR and CT imaging of 24 pleomorphic xanthoastrocytomas (PXA) and a review of the literature. *Neuroradiology* 2007; **49**: 307-315 [PMID: 17205313 DOI: 10.1007/s00234-006-0191-z]
  - 98 **Tortori-Donati P**, Fondelli MP, Rossi A, Cama A, Brisgotti M, Pellicano G. Extraventricular neurocytoma with ganglionic differentiation associated with complex partial seizures. *AJNR Am J Neuroradiol* 1999; **20**: 724-727 [PMID: 10319989 DOI: 10.1016/j.jocn.2009.10.022]
  - 99 **Yang GF**, Wu SY, Zhang LJ, Lu GM, Tian W, Shah K. Imaging findings of extraventricular neurocytoma: report of 3 cases and review of the literature. *AJNR Am J Neuroradiol* 2009; **30**: 581-585 [PMID: 18842767 DOI: 10.3174/ajnr.A1279]
  - 100 **Koeller KK**, Rushing EJ. From the archives of the AFIP: pilocytic astrocytoma: radiologic-pathologic correlation. *Radiographics* 2004; **24**: 1693-1708 [PMID: 15537977 DOI: 10.1148/rg.246045146]
  - 101 **Pencalet P**, Maixner W, Sainte-Rose C, Lellouch-Tubiana A, Cinalli G, Zerah M, Pierre-Kahn A, Hoppe-Hirsch E, Bourgeois M, Renier D. Benign cerebellar astrocytomas in children. *J Neurosurg* 1999; **90**: 265-273 [PMID: 9950497 DOI: 10.3171/jns.1999.90.2.0265]
  - 102 **Hwang JH**, Egnaczyk GF, Ballard E, Dunn RS, Holland SK, Ball WS. Proton MR spectroscopic characteristics of pediatric pilocytic astrocytomas. *AJNR Am J Neuroradiol* 1998; **19**: 535-540 [PMID: 9541314]
  - 103 **Danchaivijitr N**, Waldman AD, Tozer DJ, Benton CE, Brasil Caseiras G, Tofts PS, Rees JH, Jäger HR. Low-grade gliomas: do changes in rCBV measurements at longitudinal perfusion-weighted MR imaging predict malignant transformation? *Radiology* 2008; **247**: 170-178 [PMID: 18372467 DOI: 10.1148/radiol.2471062089]
  - 104 **Palmini A**, Najm I, Avanzini G, Babb T, Guerrini R, Foldvary-Schaefer N, Jackson G, Lüders HO, Prayson R, Spreafico R, Vinters HV. Terminology and classification of the cortical dysplasias. *Neurology* 2004; **62**: S2-S8 [PMID: 15037671 DOI: 10.1212/01.wnl.0000114507.30388.7e]
  - 105 **Englot DJ**, Berger MS, Barbaro NM, Chang EF. Predictors of seizure freedom after resection of supratentorial low-grade gliomas. A review. *J Neurosurg* 2011; **115**: 240-244 [PMID: 21529134 DOI: 10.3171/2011.3.JNS1153]
  - 106 **Giulioni M**, Martinoni M, Marucci G. Tailored pharmacoresistance related to underlying structural lesions. *Epilepsy Behav* 2014; **36**: 22-23 [PMID: 24840751 DOI: 10.1016/j.yebeh.2014.02.032]
  - 107 **Ortiz-González XR**, Venneti S, Biegel JA, Rorke-Adams LB, Porter BE. Ganglioglioma arising from dysplastic cortex. *Epilepsia* 2011; **52**: e106-e108 [PMID: 21668439 DOI: 10.1111/j.1528-1167.2011.03124.x]
  - 108 **Castillo M**, Smith JK, Kwok L. Correlation of myo-inositol levels and grading of cerebral astrocytomas. *AJNR Am J Neuroradiol* 2000; **21**: 1645-1649 [PMID: 11039343]
  - 109 **Marucci G**, Martinoni M, Giulioni M. Relationship between focal cortical dysplasia and epilepsy-associated low-grade tumors: an immunohistochemical study. *APMIS* 2013; **121**: 22-29 [PMID: 23030838 DOI: 10.1111/j.1600-0463.2012.02938.x]
  - 110 **Urbach H**. MRI of long-term epilepsy-associated tumors. *Semin Ultrasound CT MR* 2008; **29**: 40-46 [PMID: 18383906 DOI: 10.1053/j.sult.2007.11.006]
  - 111 **Tassi L**, Colombo N, Garbelli R, Francione S, Lo Russo G, Mai R, Cardinale F, Cossu M, Ferrario A, Galli C, Bramerio M, Citterio A, Spreafico R. Focal cortical dysplasia: neuropathological subtypes, EEG, neuroimaging and surgical outcome. *Brain* 2002; **125**: 1719-1732 [PMID: 12135964 DOI: 10.1093/brain/awf175]
  - 112 **Colombo N**, Tassi L, Deleo F, Citterio A, Bramerio M, Mai R, Sartori I, Cardinale F, Lo Russo G, Spreafico R. Focal cortical dysplasia type IIa and IIb: MRI aspects in 118 cases proven by histopathology. *Neuroradiology* 2012; **54**: 1065-1077 [PMID: 22695739 DOI: 10.1007/s00234-012-1049-1]
  - 113 **Tarsi A**, Marliani AF, Bartiromo F, Giulioni M, Marucci G, Martinoni M, Volpi L, Leonardi M. MRI findings in low grade tumours associated with focal cortical dysplasia. *Neuroradiol J* 2012; **25**: 639-648 [PMID: 24029175]
  - 114 **Chamberlain WA**, Cohen ML, Gyure KA, Kleinschmidt-DeMasters BK, Perry A, Powell SZ, Qian J, Staugaitis SM, Prayson RA. Interobserver and intraobserver reproduc-



- ibility in focal cortical dysplasia (malformations of cortical development). *Epilepsia* 2009; **50**: 2593-2598 [PMID: 19817804 DOI: 10.1111/j.1528-1167.2009.02344.x]
- 115 **Bourne TD**, Schiff D. Update on molecular findings, management and outcome in low-grade gliomas. *Nat Rev Neurol* 2010; **6**: 695-701 [PMID: 21045797 DOI: 10.1038/nrneurol.2010]
  - 116 **Ray WZ**, Blackburn SL, Casavilca-Zambrano S, Barrionuevo C, Orrego JE, Heinicke H, Dowling JL, Perry A. Clinico-pathologic features of recurrent dysembryoplastic neuroepithelial tumor and rare malignant transformation: a report of 5 cases and review of the literature. *J Neurooncol* 2009; **94**: 283-292 [PMID: 19267228 DOI: 10.1007/s11060-009-9849-9]
  - 117 **Schindler G**, Capper D, Meyer J, Janzarik W, Omran H, Herold-Mende C, Schmieder K, Wesseling P, Mawrin C, Hasselblatt M, Louis DN, Korshunov A, Pfister S, Hartmann C, Paulus W, Reifenberger G, von Deimling A. Analysis of BRAF V600E mutation in 1,320 nervous system tumors reveals high mutation frequencies in pleomorphic xanthoastrocytoma, ganglioglioma and extra-cerebellar pilocytic astrocytoma. *Acta Neuropathol* 2011; **121**: 397-405 [PMID: 21274720 DOI: 10.1007/s00401-011-0802-6]
  - 118 **Chi AS**, Batchelor TT, Yang D, Dias-Santagata D, Borger DR, Ellisen LW, Iafrate AJ, Louis DN. BRAF V600E mutation identifies a subset of low-grade diffusely infiltrating gliomas in adults. *J Clin Oncol* 2013; **31**: e233-e236 [PMID: 23547069 DOI: 10.1200/JCO.2012.46.0220]
  - 119 **Zaghloul KA**, Schramm J. Surgical management of glioneuronal tumors with drug-resistant epilepsy. *Acta Neurochir (Wien)* 2011; **153**: 1551-1559 [PMID: 21603887 DOI: 10.1007/s00701-011-1050-1]
  - 120 **Cossu M**, Lo Russo G, Francione S, Mai R, Nobili L, Sartori I, Tassi L, Citterio A, Colombo N, Bramerio M, Galli C, Castana L, Cardinale F. Epilepsy surgery in children: results and predictors of outcome on seizures. *Epilepsia* 2008; **49**: 65-72 [PMID: 17645538 DOI: 10.1111/j.1528-1167.2007.01207.x]
  - 121 **Rosenow F**, Menzler K. Invasive EEG studies in tumor-related epilepsy: when are they indicated and with what kind of electrodes? *Epilepsia* 2013; **54** Suppl 9: 61-65 [PMID: 24328875 DOI: 10.1111/epi.12446]
  - 122 **Cardinale F**, Cossu M, Castana L, Casaceli G, Schiariti MP, Miserocchi A, Fuschillo D, Moscato A, Caborni C, Arnulfo G, Lo Russo G. Stereoelectroencephalography: surgical methodology, safety, and stereotactic application accuracy in 500 procedures. *Neurosurgery* 2013; **72**: 353-366; discussion 366 [PMID: 23168681 DOI: 10.1227/NEU.0b013e31827d1161]
  - 123 **Cossu M**, Cardinale F, Castana L, Citterio A, Francione S, Tassi L, Benabid AL, Lo Russo G. Stereoelectroencephalography in the presurgical evaluation of focal epilepsy: a retrospective analysis of 215 procedures. *Neurosurgery* 2005; **57**: 706-718; discussion 706-718 [PMID: 16239883 DOI: 10.1227/01.neu.0000176656.33523.1e]
  - 124 **Smits A**, Duffau H. Seizures and the natural history of World Health Organization Grade II gliomas: a review. *Neurosurgery* 2011; **68**: 1326-1333 [PMID: 21307795 DOI: 10.1227/NEU.0b013e31820c3419]
  - 125 **Peace PK**. Five year review of Küntscher nailing for femoral shaft fractures with emphasis on complications. *Acta Orthop Belg* 2002; **41**: 346-354 [PMID: 1211148 DOI: 10.1007/s00701-002-0941-6]
  - 126 **Schramm J**, Clusmann H. The surgery of epilepsy. *Neurosurgery* 2008; **62** Suppl 2: 463-481; discussion 481 [PMID: 18596456 DOI: 10.1227/01.neu.0000316250.69898.23]
  - 127 **Morioka T**, Hashiguchi K, Nagata S, Miyagi Y, Yoshida F, Shono T, Mihara F, Koga H, Sasaki T. Additional hippocampectomy in the surgical management of intractable temporal lobe epilepsy associated with glioneuronal tumor. *Neurol Res* 2007; **29**: 807-815 [PMID: 17601368 DOI: 10.1179/016164107x223566]
  - 128 **Wen HT**, Rhoton AL, de Oliveira E, Castro LH, Figueiredo EG, Teixeira MJ. Microsurgical anatomy of the temporal lobe: part 2--sylvian fissure region and its clinical application. *Neurosurgery* 2009; **65**: 1-35; discussion 36 [PMID: 19934983 DOI: 10.1227/01.NEU.0000336314.20759.85]
  - 129 **Lüders HO**, Najm I, Nair D, Widdess-Walsh P, Bingman W. The epileptogenic zone: general principles. *Epileptic Disord* 2006; **8** Suppl 2: S1-S9 [PMID: 17012067]
  - 130 **Chabardès S**, Kahane P, Minotti L, Tassi L, Grand S, Hoffmann D, Benabid AL. The temporopolar cortex plays a pivotal role in temporal lobe seizures. *Brain* 2005; **128**: 1818-1831 [PMID: 15857932 DOI: 10.1093/brain/awh512]
  - 131 **Helmstaedter C**, Roeske S, Kaaden S, Elger CE, Schramm J. Hippocampal resection length and memory outcome in selective epilepsy surgery. *J Neurol Neurosurg Psychiatry* 2011; **82**: 1375-1381 [PMID: 21653207 DOI: 10.1136/jnnp.2010.240176]
  - 132 **Ramantani G**, Kadish NE, Anastasopoulos C, Brandt A, Wagner K, Strobl K, Mayer H, Schubert-Bast S, Stathi A, Korinthenberg R, Feuerstein TJ, Mader I, van Velthoven V, Zentner J, Schulze-Bonhage A, Bast T. Epilepsy surgery for glioneuronal tumors in childhood: avoid loss of time. *Neurosurgery* 2014; **74**: 648-657; discussion 657 [PMID: 24584135 DOI: 10.1227/NEU.0000000000000327]
  - 133 **Ogiwara H**, Nordli DR, DiPatri AJ, Alden TD, Bowman RM, Tomita T. Pediatric epileptogenic gangliogliomas: seizure outcome and surgical results. *J Neurosurg Pediatr* 2010; **5**: 271-276 [PMID: 20192644 DOI: 10.3171/2009.10.PEDS09372]
  - 134 **Radhakrishnan A**, Abraham M, Radhakrishnan VV, Sarma SP, Radhakrishnan K. Medically refractory epilepsy associated with temporal lobe ganglioglioma: characteristics and postoperative outcome. *Clin Neurol Neurosurg* 2006; **108**: 648-654 [PMID: 16318902 DOI: 10.1016/j.clineuro.2005.10.014]
  - 135 **Chan CH**, Bittar RG, Davis GA, Kalnins RM, Fabinyi GC. Long-term seizure outcome following surgery for dysembryoplastic neuroepithelial tumor. *J Neurosurg* 2006; **104**: 62-69 [PMID: 16509148 DOI: 10.3171/jns.2006.104.1.62]
  - 136 **Takahashi A**, Hong SC, Seo DW, Hong SB, Lee M, Suh YL. Frequent association of cortical dysplasia in dysembryoplastic neuroepithelial tumor treated by epilepsy surgery. *Surg Neurol* 2005; **64**: 419-427 [PMID: 16253690 DOI: 10.1016/j.surneu.2005.02.005]
  - 137 **Giannini C**, Scheithauer BW, Burger PC, Brat DJ, Wollan PC, Lach B, O'Neill BP. Pleomorphic xanthoastrocytoma: what do we really know about it? *Cancer* 1999; **85**: 2033-2045 [PMID: 10223246 DOI: 10.1002/(sici)1097-0142(19990501)85:9<2033::aid-cnrcr22>3.3.co; 2-q]
  - 138 **Nakajima T**, Kumabe T, Shamoto H, Watanabe M, Suzuki H, Tominaga T. Malignant transformation of pleomorphic xanthoastrocytoma. *Acta Neurochir (Wien)* 2006; **148**: 67-71; discussion 71 [PMID: 15912255 DOI: 10.1007/s00701-005-0549-8]
  - 139 **Giannini C**, Scheithauer BW, Lopes MB, Hirose T, Kros JM, VandenBerg SR. Immunophenotype of pleomorphic xanthoastrocytoma. *Am J Surg Pathol* 2002; **26**: 479-485 [PMID: 11914626 DOI: 10.1097/0000478-200204000-00010]
  - 140 **Wirrell EC**, Wong-Kisiel LC, Nickels KC. Seizure outcome after AED failure in pediatric focal epilepsy: impact of underlying etiology. *Epilepsy Behav* 2014; **34**: 20-24 [PMID: 24681380 DOI: 10.1016/j.yebeh.2014.02.032]
  - 141 **Dahiya S**, Haydon DH, Alvarado D, Gurnett CA, Gutmann DH, Leonard JR. BRAF(V600E) mutation is a negative prognosticator in pediatric ganglioglioma. *Acta Neuropathol* 2013; **125**: 901-910 [PMID: 23609006 DOI: 10.1007/s00401-013-1120-y]
  - 142 **Duncan JS**, de Tisi J. MRI in the diagnosis and management of epileptomas. *Epilepsia* 2013; **54** Suppl 9: 40-43 [PMID: 24328871 DOI: 10.1111/epi.12442]
  - 143 **Chappé C**, Padovani L, Scavarda D, Forest F, Nanni-Metellus I, Loundou A, Mercurio S, Fina F, Lena G, Colin C, Figarella-Branger D. Dysembryoplastic neuroepithelial tu-

mors share with pleomorphic xanthoastrocytomas and gangliogliomas BRAF(V600E) mutation and expression. *Brain*

*Pathol* 2013; **23**: 574-583 [PMID: 23442159 DOI: 10.1111/bpa.12048]

**P- Reviewer:** Kakisaka Y, Spalice A, Sotelo J **S- Editor:** Ji FF  
**L- Editor:** A **E- Editor:** Lu YJ



## Pathways of fear and anxiety in dentistry: A review

Ava Elizabeth Carter, Geoff Carter, Mark Boschen, Emad AlShwaimi, Roy George

Ava Elizabeth Carter, Geoff Carter, Roy George, School of Dentistry and Oral Health Griffith University, Southport, Gold Coast, QLD 4215, Australia

Geoff Carter, School of Human Education and Resources and Oral Health Griffith University, Southport, Gold Coast, QLD 4215, Australia

Geoff Carter, Mark Boschen, School of Applied Psychology, Griffith University, Southport, Gold Coast, QLD 4215, Australia

Emad AlShwaimi, College of Dentistry, University of Dammam, Dammam 31411, Saudi Arabia

**Author contributions:** Carter AE, Carter G and George R contributed equally to the creation and design of this work; Boschen M and AlShwaimi E contributed by providing their expertise in the field of pain and anxiety and helped edit the document; George R is the senior author and completed final review prior to submission.

**Correspondence to:** Dr. Roy George, BDS, MDS (Endo), PhD (QLD), MRACDS (Endo), GCHE (QLD), Discipline Head Endodontics, School of Dentistry and Oral Health Griffith University, Parklands Drive, Southport, Gold Coast, QLD 4215, Australia. [drroygeorge@gmail.com](mailto:drroygeorge@gmail.com)

Telephone: +61-7-56780751 Fax: +61-7-56780751

Received: June 11, 2014 Revised: July 21, 2014

Accepted: September 4, 2014

Published online: November 16, 2014

© 2014 Baishideng Publishing Group Inc. All rights reserved.

**Key words:** Dentistry; Fear and anxiety; Phobia; Origin; Therapies and management

**Core tip:** (1) 5 pathways to the origin of dental fear and anxiety have been identified in this review: Cognitive Conditioning, Informative, Visual Vicarious, Verbal Threat, and Parental; (2) Development of fear and anxiety may be unique for each individual, with patients often associating fear to a combination of factors (Pathways); and (3) Management of fear and anxiety should include an understanding of the origins of dental fear.

Carter AE, Carter G, Boschen M, AlShwaimi E, George R. Pathways of fear and anxiety in dentistry: A review. *World J Clin Cases* 2014; 2(11): 642-653 Available from: URL: <http://www.wjgnet.com/2307-8960/full/v2/i11/642.htm> DOI: <http://dx.doi.org/10.12998/wjcc.v2.i11.642>

### Abstract

The aim of this article was to analyze the theories underpinning dental fear, anxiety and phobias. To be included, articles must have been published between the years of 1949 and 2013 concerning fears and phobias within dentistry and/or psychiatry. Of 200 articles originally under review, 140 were included and reviewed by the authors. Five specific pathways relating to dental fear and anxiety were identified; Cognitive Conditioning, Informative, Visual Vicarious, Verbal Threat, and Parental. Eight currently accepted management techniques across all dental disciplines for dental fear and anxiety were identified. Further research is required to identify clinical diagnosis and treatment for fears originating from different pathways.

### INTRODUCTION

Odontophobia (dental fear) is a “unique phobia with special psychosomatic components that impact on the dental health of the odontophobic persons”<sup>[1]</sup>. For some individuals, dental fear may be so great that normal life is impaired. In these instances, the individual experiences fear or anxiety that is out of proportion to the actual danger present in the situation. This often leads to avoidance behavior, and clinically significant levels of distress or impaired functioning<sup>[2]</sup>. Such avoidance behavior is well known by any dentist who has treated patients with high levels of dental fear before. In Australia, people with higher levels of dental fear tend to avoid the dentist and have irregular attendance records, usually only seeking treatment when symptomatic<sup>[3,4]</sup>. This data is consistent with other studies that noted that, although patients booked appointments, they did not keep their appointment or prematurely cancelled their appointments out of

fear<sup>[5-12]</sup>.

The incidence of dental fear and anxiety appears to be relatively consistent throughout the world, with some sub-groups reporting higher levels than others. An Australian study reported that 16.1% of individuals experienced high levels of dental fear, where adults between the ages of 40 and 64 years reported a higher incidence of dental fear, and females of any age were reportedly more afraid of the dentist than males were<sup>[4]</sup>. Of note, people from low socioeconomic status (SES) groups reported a generally higher level of dental fear than those individuals from high SES groups<sup>[4]</sup>. The reported incidence of high dental fear and anxiety was a little lower in an Icelandic study, at only 10%<sup>[11]</sup>, but slightly higher in a Singaporean population, at 17.1%<sup>[12]</sup>. A cross-cultural study of Chinese and Danish patients reported moderate to high dental fear in 30% of Chinese and 15% of Danish participants<sup>[10]</sup>. In 2009, a study of dental fear prevalence in 1959 Netherlands reported 24.3% of the participants had moderate to high dental fear<sup>[13]</sup>. Dental fear studies on German populations have reported a mean Dental Anxiety Score (DAS) of 8.6<sup>[14]</sup> and a dental phobia incidence of 11%<sup>[15]</sup>. The highest prevalence of dental fear appears to be in Japan, where a study of 3041 students and adults reported that 42.1% had high dental fear<sup>[16]</sup>.

The overall effect of dental fear and anxiety appears to be multifaceted, such that the individual not only avoids their dental appointments but also tends to have worse oral health<sup>[17]</sup>. The extent to which this is a causal relationship is unknown. An understanding of the factors underlying the etiology and maintenance of dental anxiety may assist dentists and researchers in developing interventions designed to reduce dental avoidance behaviors. In turn, this will contribute to improvements in oral health. Mehrstedt *et al.*<sup>[18]</sup> (2004) noted that dental fears were negatively linked to quality of life with respect to psychological well-being, social functioning, and vitality. This finding indicates that the link between dental fear and perceived negative quality of life is multifaceted. Some early Scandinavian studies reported on the malicious circle of dental anxiety and fear, whereby fear and avoidance lead to premature cancellation of dental appointments and further worsening of oral health conditions<sup>[2,6,19,20]</sup>. A qualitative study by Moore *et al.*<sup>[21]</sup> (2004) reported on the contributing role that embarrassment plays in dental phobia. Among other things, these researchers analyzed the social powerlessness associated with the embarrassment that arises from poor oral health. In this study, the authors concluded that patients may be so embarrassed by their poor oral health/hygiene that they avoid seeing the dentist out of fear of being reproached<sup>[1,21]</sup>. Understanding the extremely complex psychology of dental fear is essential in the prevention and treatment of dental anxiety, fear and phobias<sup>[21]</sup>.

In order to understanding the extremely complex psychology of dental fear it is essential to understanding possible pathways of dental fear and anxiety. This study identified relevant studies using Medline Database

(Medline/PubMed). The search covered the period 1900 to 2014, including only articles written in English. Search terms included “dental fear and anxiety,” “cognitive,” “informative,” “verbal threat,” “vicarious,” “parental,” and “origin of fear.” A total of 300 references were retrieved from the database search. Only articles directly relating to the management, origin of fear, and dental fear theories were evaluated to understand the pathways of fear and anxiety in dentistry. Of the three hundred retrieved references, only 137 related to fear and anxiety in dentistry, however only 10 related specifically to origins of fear and anxiety in dentistry. The aim of this review is to highlight the possible pathways of fear and anxiety in dentistry and not to analysis the actual experience of fear and anxiety.

## ETIOLOGY OF GENERAL FEAR AND ANXIETY

Processes known to contribute to the etiology of dental fear and phobia include a variety of genetic, behavioral, and cognitive factors. An individual's dental fear/phobia is likely to have been created by involving a multitude of factors.

### Genetic vulnerability

Individuals with specific phobias, including odontophobia, may have inherited genetic vulnerability factors that predispose them to anxiety in general or certain phobias specifically. While individuals with dental phobia do not directly inherit the phobia itself, genetic vulnerability factors may interact with other etiological elements that cause the phobia<sup>[22,23]</sup>. Controversy over the reliability of phylogenetic origin of fear arises in relation to a study of 173 Swedish twins, which reported that whilst “phenotypic correlations were moderate,” they were found to be counterintuitive to the electrophysical skin conductance response (SCR)<sup>[23]</sup>. In summary, it has been suggested that although genetics can predict some factors related to dental fear, it appears to be distally and not strongly related to the actual development of phobic symptom<sup>[24-26]</sup>.

### Negative affectivity/anxiety vulnerability

Negative affectivity refers to a vulnerability to experiencing negative emotional states. Negative affectivity appears to be a stable personality trait that predisposes individuals to a range of psychological disorders, including phobias<sup>[27]</sup>. The relationship between negative affectivity and dental phobia has not yet been established.

### Preparedness

Through the process of natural selection, individuals who readily acquired fear and avoidance responses to genuinely dangerous situations (*e.g.*, dangerous animals, storms, heights, small spaces, *etc.*) have passed on this tendency to their progeny<sup>[28]</sup>. As such, the human species is “prepared” to more readily acquire fear reactions to stimuli that may have posed a genuine danger to our ancestors<sup>[28,29]</sup>. Dental



phobia may be part of an evolutionarily beneficial tendency to protect the body envelope from intrusion by foreign (non-nutritional) objects.

### **Cognitive conditioning (pavlovian)**

Classical (or pavlovian) conditioning refers to the process by which a previously neutral stimulus acquires the ability to directly elicit a response through pairing this stimulus with another unconditioned stimulus (US) that elicits the same response<sup>[30-33]</sup>. For example, an individual who experiences a painful procedure (and the unconditioned response of anxiety/fear) during a dental visit may acquire a conditioned association between the dentist (the conditioned stimulus) and anxiety/fear (the conditioned response)<sup>[34-37]</sup>. Re-presentation of the conditioned stimulus (the dentist or related stimuli) is then able to elicit the conditioned response of anxiety during the patient's next dental consultation.

### **Operant conditioning**

Operant conditioning refers to a process whereby the frequency of a particular behavior ("operant") is modified through the consequences that follow the behavior. Certain behaviors may be "reinforced" (*i.e.*, increased in frequency) through their association with positive consequences ("positive reinforcement") or through the removal of negative consequences ("negative reinforcement")<sup>[30,34,35,38,39]</sup>. Alternatively, behaviors may be "punished" (*i.e.*, reduced in frequency) if they lead to negative consequences ("positive punishment") or the removal of positive consequences ("negative punishment")<sup>[38]</sup>. For phobias, the process of positive punishment (*e.g.*, pain and anxiety that occurs during a visit to the dentist) and negative reinforcement (*e.g.*, the reduction in anxiety that results when the individual avoids the dentist) are thought to be most important, and these comprise Mowrer's two-factor model of phobia acquisition and maintenance<sup>[40]</sup>.

### **Vicarious**

In addition to direct contributors to phobia acquisition, Rachman<sup>[41]</sup> (1978) proposes that individuals may also acquire phobic responses indirectly. One such pathway has been called vicarious experience or vicarious conditioning. In vicarious conditioning, the individual acquires a fear response through seeing the fearful experience of others. In dental phobia, for example, a child who observes a fear response of a parent attending the dentist may learn indirectly that the situation poses a significant threat.

### **Verbal threat**

Rachman<sup>[36]</sup> (1977) proposed a second indirect pathway to phobia acquisition referred to as "verbal transmission". In this process, the individual acquires a fear or phobia through learning about the dangerousness of a situation from others without observing it directly<sup>[36]</sup>. In dental phobia, for example, an individual may hear stories from others about traumatic or painful experiences that

they have had during dental treatment, which may lead to a learned fear of dental procedures<sup>[42]</sup>.

### **Cognitive content**

There are a range of cognitions that have been identified as important in the acquisition and maintenance of anxiety disorders, including specific phobias. These include a set of ideas about the probability (*e.g.*, "If I go to the dentist it will definitely be painful") and severity (*e.g.*, "If I go to the dentist the pain will be excruciating") of negative outcomes<sup>[43]</sup>. Additionally, individuals may hold beliefs about their inability to cope in the face of an aversive outcome (*e.g.*, "If I am in pain at the dentist, it will be unbearable")<sup>[44]</sup>.

### **Cognitive biases**

In addition to the content of cognition, phobias are associated with biases in the process of cognition<sup>[43]</sup>. For example, individuals with anxiety disorders such as phobias are known to have memory biases in which memories of threat-consistent experiences and information are more readily retrieved<sup>[45]</sup>. Although the link between cognitive bias and dental fear and anxiety is plausible, no research has yet been done to confirm this.

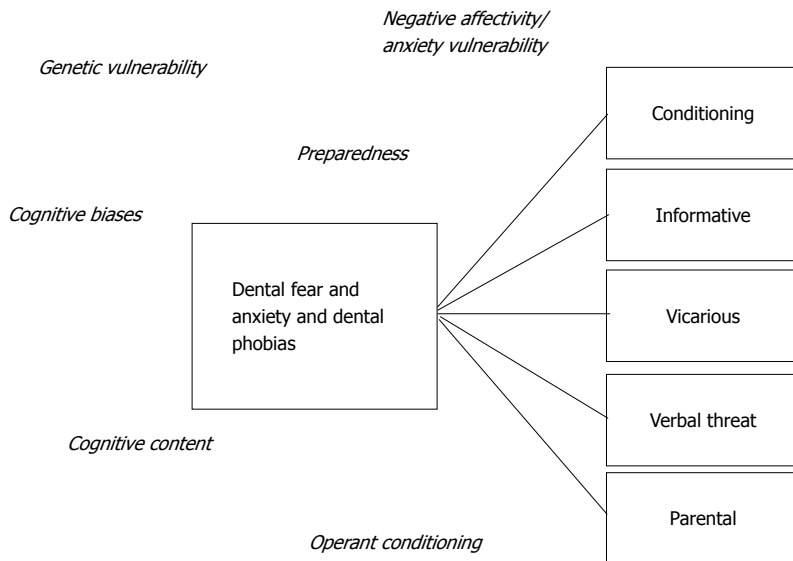
---

## **CURRENT KNOWLEDGE OF DENTAL FEAR: WHAT WE KNOW RIGHT NOW**

---

Current literature on dental fear is limited relative to other fields. Specifically, most of our understanding surrounding dental fear is based on results from two meta-analyses; one of which focuses on adults, while the other on children and adolescents.

In a meta-analysis of 32 articles on dental behavior management problems, Klingberg *et al.*<sup>[46]</sup> (2007) reported that children and adolescents were expected to experience mild fear and anxiety. This fear and anxiety only becomes a concern if it is "disproportionate to the actual threat and daily functioning becomes impaired", a definition very similar to the DSM-IV. However, this research also noted that the third criterion for dental phobia (recognition that the fear is unreasonable or excessive) does not always apply to children. This is a reasonable argument, as coping with pain and anxiety requires a high level of cognitive function and self-control that a young child might not have yet developed. However, one must attempt to separate general fearfulness (an anxiety-related personality trait) from a specific fear because both are capable of presenting as an acute fear reaction (*e.g.*, screaming at the sight of a drill). This distinction can be difficult to make if the parent-child relationship is synergistically inflating the dental fear. Research demonstrates that the dental fear of a child who is 8 years or younger is significantly related to the dental fear of the parent<sup>[47]</sup>. However, in children older than 8, the relationship is less clear. In addition, it was noted that girls presented as more anxious and harder to manage than boys, sup-



**Figure 1** Pathways of fear in dentistry with background influences.

porting the current accepted relationship between anxiety disorders and gender in children and adolescents<sup>[48]</sup>. However, particular fears changed as the child grew older, such that one-year-old had separation anxiety but primary school children had more social anxieties, demonstrating a positive development of metacognition. Also, younger children were more likely to have more fears of higher intensity. However, there is inconclusive evidence regarding the origin of fear among children and adolescents due to the gap in the literature examining this cohort. In their review, Klingberg *et al* (2007) did, however, agree on 3 distinct, yet commonly occurring causes for dental fear in children (not including neuropsychiatric disorders): (1) Some children's past "negative experiences with dental care" was the origin of their dental behavior management problems; (2) Other children were "genetically prone to react with fear...to threatening situations"; and (3) Other children still reacted to frustrating demands (*e.g.*, sitting still) with anger<sup>[46]</sup>.

The first represents direct trauma from treatment<sup>[36]</sup>, while the second and third are officially undefined at present and require further investigation. It must be noted that parental dental fear has an effect on the child's dental fear<sup>[47,49]</sup>. Making it an important part of the conceptualization of an individual's dental phobia.

With regard to adults, it is generally accepted that the patient developed fear either due to personal trauma from a dental treatment or because of some form of psychological disorder or constitutional vulnerability. Yet, few studies analyze the actual pathway or origin of fear adults experience with regard to dental fear. However, it is possible that some of these origins may apply directly to dental fear<sup>[50]</sup> (Figure 1). Originally Watson *et al*<sup>[33]</sup> (1920) and Rachman<sup>[41]</sup> (1978) purported that specific fears were condition-based, vicarious, or based on information learning. Between the 1920s and 1970s, these theories dominated the discipline of fear and anxiety management and diagnosis. In 1970, Seligman proposed that mankind is prepared by evolution to associate certain situations

(previously encountered by ancestors) with particular outcomes, and thus the mind reacts to these situations by instigating fear (See Figure 1: Preparedness framework)<sup>[51]</sup>. In 2001, Mineka *et al*<sup>[28,52]</sup> suggested that the amygdala and hippocampus were responsible creating generalized fear responses. Analogous to this and supporting Seligman's theory, Poulton *et al*<sup>[53,54]</sup> (2002) posited that evolutionarily associated fears can manifest without a stimulus. Among these theories, the associative and non-associative theories are the most distinctive. Menzies *et al*<sup>[55,56]</sup> (1993a) first described the associative theory in relation to water phobia, where fears occur in response to a bad experience (CS), while non-associative fears are innate (US). In addition, Muris *et al*<sup>[57]</sup> posited that parental modeling contributes to the fearfulness found in children. Here, the trait anxiety was related to that of both parents (Mother:  $r = 0.34$ ,  $P < 0.05$ , Father:  $r = 0.31$ ,  $P < 0.05$ ), but the act of being fearful was only related to mother's fearfulness ( $r = 0.56$ ,  $P < 0.001$ )<sup>[57]</sup>. Klingberg *et al*<sup>[58]</sup> also supported the notion of maternal dental fear impacting the development of dental fear in children.

Of these theories, there are 5 pathways that are thought to specifically relate to dental fear and anxiety: Cognitive Conditioning, Vicarious, Verbal Threat, Informative, and Parental (Figure 1). These five pathways are discussed further in this article but it is important to note that a single or a combination of background factors disused in the etiology of general fear and anxiety may affect these pathways.

### Conditioning pathway

Conditioning is a process where the participant learns through personal experience that the event or stimulus heralds a detrimental outcome<sup>[50,59]</sup>. Pioneers in early conditioning research Watson *et al*<sup>[60]</sup> (1917) who theorized that in infancy there are limited emotional reaction patterns (*e.g.*, fear, rage, love) and that there must be some stimuli which are associated with these. Watson *et al*<sup>[33]</sup> (1920) then performed experimental work on an infant,

analyzing directly conditioned emotional responses. Their results showed that the non-fear-inducing stimuli elicited a fearful emotional response when the fear-inducing and non-fear-inducing stimuli were shown together, and when the non-fear-inducing stimuli was shown on its own later<sup>[33]</sup>. In 1927, Pavlov<sup>[32]</sup> published his seminal paper on “Conditioned Reflexes,” which perhaps represents the first in-depth and detailed experiment on the development of conditioning. Pavlov<sup>[32]</sup> identified that animals can learn to associate a conditioned stimuli with a new non-conditioned stimuli so that the non-conditioned stimuli causes a conditioned response. Here, the animals (dogs) began to associate food and salivating with the sound of a bell. Thus, anytime the bell sounded, the dogs salivated<sup>[32]</sup>. In a similar attempt to replicate physiological responses during fear, Rachman<sup>[41]</sup> (1978) then successfully demonstrated that physiological responses, such as sweating and increased heart rate, occur when individuals experience fear. Such responses are evident in odontophobic patients, where heart rate, breathing, and sweating all increase due to fear associated with dental environments and dental stimuli<sup>[19,61-63]</sup>. In addition, many individuals report painful past experiences being the cause for their subsequent dental fear<sup>[44,64-66]</sup>. Researchers<sup>[67]</sup> have indeed found a “strong direct relationship between severity of trauma-related symptomatology and severity of dental anxiety where the shared variance was 38%”<sup>[67]</sup>. Thus, it can be proposed that the majority of dental fears are reactions to stressful experiences that provoke anxiety in the individual<sup>[36,68-70]</sup>. In summary, the conditioning pathway appears to be the most commonly utilized pathway by patients.

### Informative pathway

The informative pathway is another indirect pathway for fear acquisition, which does not require the presence of an unconditioned stimulus. As far back as 1977, Rachman discussed the relevance of the informative pathway in so much as child-rearing involved information giving<sup>[36]</sup>. Rachman<sup>[36]</sup> noted that the instructional process of child rearing may lead to biases for commonly encountered fears. Such a dynamic could help explain childhood dental anxiety, where children learn to fear the dental environment from dental phobic elders, negative connotations advertised by media (*e.g.*, television, movies), and friends with personal negative experiences.

### Vicarious pathway

The vicarious pathway is an indirect pathway for fear acquisition that does not require the presence of an unconditioned stimulus. It has been acknowledged in the literature that people with extreme dental fear avoid the dentist<sup>[3,4,17,33,71-78]</sup>. In a recent Australian study using Armfield’s Index of Dental Anxiety and Fear (IDAF), it was found that participants who indicated extreme dental fear were marginally more likely not to undertake an oral examination, here females exhibited significantly higher dental fear than males<sup>[4,71]</sup>. Whether this fear is purely

conditioned or vicarious is not yet fully understood<sup>[76]</sup>. Conceivably, one of the most renowned contributions to the theory of “vicarious conditioning in phobia acquisition”<sup>[50]</sup> was by a pair of researchers<sup>[38,52,79]</sup> whose experiments provided convincing evidence that fear can be learned vicariously<sup>[36,69,80]</sup>. By utilizing this vicarious pathway, it is plausible to suggest that vicarious learning could be contributing to pediatric fears, whereby expressions of fear by elders at the dentist in front of children leads to fear acquisition in the children<sup>[81,82]</sup>.

### Verbal threat pathway

The verbal threat pathway presents another indirect pathway for fear acquisition that does not require the presence of an unconditioned stimulus. To explain the origin of a fear that is not seen or experienced, it is essential to understand the “emotion” of fear. Research<sup>[83]</sup> has suggested that emotions arise because of three factors: verbal cognition, behavior changes, and physiological states. This “emotion” is known as the “tripartite,” and appears to govern onset and origin of fears generated by the verbal threat pathway<sup>[83-87]</sup>. Many articles examining the effects that “word of mouth” information has upon children and acquisition of fear<sup>[81,82,84-86,88-97]</sup> note that children become fearful of a stimulus or situation when they hear or read that it may be dangerous. To control for bias, all studies were done on medically healthy children, aged 6-13 years. The majority of participants (88.9%) demonstrated that self-reported fears increase as children were given violent/dangerous/threatening information about a particular stimulus, irrespective of its actual threat<sup>[85,86,92-94]</sup>. Simultaneously, it has been found that giving positive information results in a decrease in children’s self-reported fear<sup>[89,91]</sup>. Similar research on children ages 7-9 years found that when given verbal information about a “monster,” “children’s fear-beliefs changed. However, these fear-beliefs only changed when information came from an adult”<sup>[96]</sup>. In short, one interpretation of the verbal threat pathway is that fear is induced when an authority figure threatens an individual with a painful experience. In the case of dental fear, painful and/or negative experiences are linked to dental visits. Although perhaps within strict psychological terminology the informative and verbal threat pathways are similar. Within odontophobia the two pathways differ in that the verbal threat pathway occurs when a “visit to the dentist” is literally used as a form of punishment for bad behavior. This does not occur in the informative pathway.

### Parental pathway

The parental modeling pathway presents another indirect pathway for fear acquisition that does not require an US. The concept of parental modeling is supported by research<sup>[69]</sup> demonstrating that in a sample of 40 children between the ages of 9 and 12 years, children’s fear was positively related to their mother’s dental fear. Specifically, mothers who expressed heightened levels of fear in front of their children were more likely to have fearful children.

Conversely, mothers who did not frequently express fear had less fearful children<sup>[69]</sup>. These findings are consistent with another study showing that most adults attributed the origin of their fears to informative and vicarious factors occurring in childhood (56% and 39%, respectively) more so than to cognitive model events (37%)<sup>[84]</sup>. Given that the majority of heightened levels of fear in some children was a consequence of an amalgamation of different learning dynamics<sup>[69]</sup>, it has been suggested that “fear is more likely to develop as a result of synergistic effects of various sources or origins”<sup>[56]</sup>. However, one must note that any relationship between parent and child fears may also be due to the informative or vicarious pathways because they are all linked in some way. Again, strict psychological terminology may not necessarily differentiate between the parental and vicarious pathways. However within odontophobia individuals utilizing the parental pathway had their sole influence of odontophobia from their parents’ expression of fear, whereas the vicarious pathway is multifaceted. Further investigation is needed to identify criteria for each pathway’s application.

## MEASUREMENT INSTRUMENTS AND DIAGNOSTIC CATEGORIES OF DENTAL FEAR AND ANXIETY

### *Measures of dental anxiety (Pre-1990)*

The first widely accepted questionnaire for assessing dental fear was the Phobic Origins Questionnaire (POQ). Out of the 10 items, the first 9 required the participant to make a binary Yes/No response<sup>[98,99]</sup>. Following the POQ, a 16-item self-report questionnaire referred to as the Origins Questionnaire (OQ)<sup>[56,100]</sup> became popular. This measure also examined individuals’ history in relation to their phobia<sup>[55,56]</sup>. However, as several studies have indicated<sup>[56,101-103]</sup>, the POQ is inherently biased towards conditioning models. It was found that the POQ indicated conditioning was the primary origin for fear 56%-78% of the time, while the vicarious pathway accounted for 17%-42%<sup>[104]</sup>. Additionally, given that the control group for this research<sup>[99]</sup> consisted of only analogue cases of mild and low level fear by different researchers<sup>[77,105-107]</sup>, it cannot be confirmed that this research represents the general populations’ origins of fear. Numerous other researchers have criticized the POQ, noting that the authors wrongly systematized frightening stimuli to relate to the cognitive model origin, even though no unconditioned stimulus was described by participants<sup>[55,56,108,109]</sup>. Consequently, the construct validity and convergent validity of the POQ was found to be very poor<sup>[55,56,100,101,103,110,111]</sup>.

### *Measures of dental anxiety (Post 1990)*

As dental fear can be difficult to define and measure effectively<sup>[103,109]</sup>, research began to create a more practical, reliable, and theoretically efficacious dental fear measurement. Research found that the Index of Dental Anxiety and Fear (IDAF-4C+), developed by Jason Armfield pre-

sented strong statistically significant correlations with previous measures of dental fear (Corah’s DAS, 1969). Armfield’s reasoning for creating a new dental fear scale was due to problems with existing scales such as Kleinknecht’s Dental Fear Survey (DFS, 1973), Stouthard’s Dental Anxiety Inventory Short-Form (DAI-S, 1993), the Modified Dental Anxiety Scale (MDAS, 1995), and the Hierarchical Anxiety Questionnaire (HAQ, 1999). Problems associated with these measures were that they were too long, measured fear-related stimuli rather than fear itself, and had poor construct validity<sup>[71,77,112,113]</sup>.

Consisting of 3 modules, each with 8 items, the IDAF-4C+ analyzes emotional, behavioral, physiological, and cognitive responses related to dental fear<sup>[66,113]</sup>. Each module uses a Likert scale ranging from 1-5, where 1 represents “strongly disagree” and 5 represents “strongly agree.” Utilizing an exploratory analysis, “all items showed good internal consistency (Cronbach’s alpha = 0.94) and test-retest reliability at 4 mo review ( $r = 0.82$ )”<sup>[71,114]</sup>. With regard to phobia diagnoses, positive results were found with regard to the convergent and predictive validity of the IDAF-4C+ when compared to Corah’s DAS,  $\eta^2 = 0.154$  and  $0.060$ , respectively<sup>[71]</sup>.

### *Diagnostic categories of dental fear*

Individuals who are classified as “dentally anxious,” tend not to have qualities that can be catalogued. As such, they differ in their origin of fear, specific fear stimulus, age of onset, as well as the bodily reactions and psychological reactions that manifest in response to fear-related stimuli. The etiology of dental fear is wide-ranging and can be attributed to personal traumatic experiences (conditioning)<sup>[38]</sup>, threats of dental visits as punishment (verbal threat pathway)<sup>[86,93]</sup>, and fear through observing pain in loved ones and others (vicarious pathway) to name a few<sup>[50,99,115,116]</sup>. Moreover, at times, dental fear has been shown to be part of a larger “set” of fears such as arachnophobia and claustrophobia, and fears of mutilation and suffocation. Consequently, there has been debate on whether dental anxiety is a “simple” CS, or a component of a “set” of fears and mood or anxiety disorders<sup>[117]</sup>. Previous and well documented research has described these two variations of dental fear as exogenous and endogenous<sup>[118]</sup>.

A group of researchers, well known for their clinical experience, developed a richer, more detailed classification system for dental fear. Their system, known as the Seattle System, mirrored the origin and the main stimuli of fear surrounding dental anxiety and phobias<sup>[116]</sup>. Essentially, the Seattle System can be used to classify individuals with respect to the severity of the psychological phobia relative to dentistry and the dentist as a person, based on a range of mean scores that represent different levels of dental fear. These mean scores have been applied to a number of questionnaires [*i.e.*, DAS, Fear Survey Schedule II (FSSII), Spielberger Trait Anxiety Index (STA), Anxiety Sensitivity Index (ASI), Emotional Control Questionnaire (ECQ), General Health Question-



naire (GHQ), Fear of Pain Scale (FPS), and Mutilation Questionnaire (MQ)]. The Seattle System consists of four diagnostic elements: (1) simple CS of specific dental stimuli; (2) anxiety about somatic reactions during dental treatment; (3) patients with a generalized anxiety state and multi-phobic symptoms; and (4) distrust of dental personnel<sup>[116,119]</sup>. Despite the fact that the classification was originally designed for pragmatic academic purposes, it has shown to hold some evidence of psychologically valid identifications of dental anxiety subtypes<sup>[119]</sup>. Of note is the qualitative evaluation component of the Seattle System, which consists of in-depth interviews that give a more thorough understanding of the true multi-phobic nature that dental fear can present with<sup>[119]</sup>. Indeed, subjects with type 4 Seattle fear were further split into 3 subgroups, which met the criteria for distinct uniqueness, internal consistency, and distinct response to treatment type as proposed by earlier researchers<sup>[120]</sup>.

Roughly comparable results were reported three years later utilizing the DSM-III-TR criteria for simple dental phobia (code 300.29-Specific phobia)<sup>[121]</sup>. However, although the results did not support the theory that the Seattle System corresponds to the DSM-III-TR, as proposed three years earlier<sup>[119]</sup>, the researchers proposed that dentally anxious subjects should be calibrated for fear using a distinct method that differs from that for psychiatric mood and personality disorders<sup>[121]</sup>. Then, just before the turn of the century, newly published research brought to light some intriguing facts regarding the Seattle System<sup>[119]</sup>. Here, it was proposed that the Seattle System was valid from a psychological perspective in addition to being a well-rounded tool for clinical diagnosis (Table 1). Accordingly, they discovered that some participants in the older age brackets were of type 3 fear (Seattle System), indicating that those with simple phobias are able to recover in time, while those individuals with more complex multiphasic conditions may require psychological treatment<sup>[119]</sup>.

## CURRENT MANAGEMENT TECHNIQUES FOR DENTAL FEAR AND ANXIETY (CBT)

With regard to treatment of dental fear and anxiety, there are a number of possible avenues to explore with patients, including pre-treatment anxiety questionnaires, cognitive behavioral therapy (CBT), relaxation therapy, computer-assisted relaxation learning (CARL), hypnotherapy (HT), group therapy (GT), individual systematic desensitization (ISD), pharmacological, flooding (implosion), and swallowing relaxation. These forms of treatment are essentially a form of counter conditioning to reverse the fear into a state of acceptance and calm.

### Pre-treatment anxiety questionnaires

To date, only one study exists as to general dentists' use of pre-treatment anxiety questionnaires to assess patient anxiety before treatment. A study of United Kingdom dentists reported that only 20% of the dentists surveyed

used adult anxiety questionnaires, and only 17% formally assessed children's levels of fear and anxiety<sup>[122]</sup>. Interestingly the study reported that when treating adults, male dentist used pre-treatment fear surveys more often than female dentist ( $P < 0.05$ )<sup>[122]</sup>. The authors believe that these pre-treatment surveys can help enhance patient care; however it would be interesting to evaluate the current utilization rate of these anxiety surveys and methods to encourage this practice.

### Individual systematic desensitization and group therapy

Individual systematic desensitization (ISD) is a behavioral therapy whereby individuals are gradually exposed or incrementally exposed to fearful stimuli. In this process, the individual must first identify and accept the fear-related stimulus; second, the individual must learn to employ a relaxation or coping technique; and finally, the individual must utilize the learned relaxation or coping strategy to react and overcome the fearful stimulus. In 2002, Moore *et al.*<sup>[123]</sup> compared GT and ISD (as well as HT) and found that after 3 years, 65.5% of patients' with ISD and 69.6% with GT maintained dental appointments (although these results were not significant). In this work, the ISD was a combination of muscle relaxation therapy and video reel exposures (looped) of threatening dental situations and instruments with intermittent tension awareness training and breath control lessons. GT involved groups of patients meeting for seven 2-h sessions led by a dentist, dental assistant, and successful former patient. Video desensitization reels were also played and a final demonstration of injection and drilling was performed at the last session. Unfortunately, Moore *et al.*<sup>[123]</sup> (2002) did not identify the origin of fear for the participants. Thus, the current results cannot be extrapolated to the pathways and further research is needed.

### Flooding/implosion

Flooding is a form of desensitization for treating phobias when the patient has a directly conditioned origin of fear (Origin 2). In flooding therapy, the patient is subjected to repeated exposure of fear-inducing stimuli until they no longer show a fear response, causing termination of the CR<sup>[124]</sup>. Implosion is used for either indirect conditioned or non-conditioned origins of fear (Origins 1 and 3) that may be imagined. However, the technique of flooding has not been examined in the literature since Mathews *et al.*<sup>[125]</sup> in 1977. In this work, Mathews *et al.*<sup>[126]</sup> report that among subjects who attended 2 or more flooding sessions, 48% successfully completed dental treatment 2 mo later. No further investigations appear to have been performed on this technique; this might be due to the highly anxiety-inducing nature of the treatment.

### Cognitive behavioral therapy

Cognitive behavioral therapy (CBT) is a psychotherapeutic approach to address dysfunctional emotions and negative behaviors and cognitions using a series of goal-oriented sessions. Davies *et al.*<sup>[126]</sup> (2011) found that of 21

**Table 1** Seattle system diagnostic criteria for dental phobia

Fear type	Diagnostic Item	Classification of fear
Type 1	Fear of dental procedures	Simple conditioned phobia
Type 2	Fear of fainting, panic attack, heart attack	Fear of catastrophe
Type 3	Nervous person in general	Generalized anxiety
Type 4	Distrust of dentists	Fear of dentists
Subclass a		→High fear of dental procedures
Subclass b		→Generally anxious
Subclass c		→Fearful of dental catastrophes

patients offered CBT to overcome their dental fear as opposed to using sedation, 90% continued to be able to attend dental appointments without sedation ten years later. Current research appears to support CBT and relaxation therapy for treatment of directly conditioned fears (Origin 2)<sup>[127,128]</sup>.

### Relaxation therapy

Relaxation therapy is a diverse set of practices aimed at eliciting a relaxation response, including a reduction in overall physical arousal symptoms. The phobic individual implements a particular mental relaxation technique (*e.g.*, slow breathing, counting, relaxation swallowing) to reduce stress. ten Berge *et al.*<sup>[129]</sup> (2001) reported that parents play a more secondary role in treatment of child dental fear and anxiety. Results seem to suggest that CBT is more effective but should be combined with parental guidance in treatment of pediatric dental fear. Extrapolating this data, a combination of CBT and relaxation guidance may provide effective treatment of parental modeling dental fears (Origin 1).

### Computer-assisted relaxation learning

A recent development in the treatment of dental fear, computer-assisted relaxation learning (CARL) is a self-paced treatment for dental phobic individuals for treating needle phobia. The program begins by introducing its purpose, followed by activities and videos on how to cope with their fear. The program is based on the theory of systematic desensitization and in a recent study in 2013, researchers compared CARL to information pamphlets (control) in a block randomized study<sup>[130]</sup>. The authors reported that CARL significantly reduced self-reported general and injection-specific dental anxiety ( $P < 0.001$ )<sup>[131]</sup>. After the intervention, twice as many CARL participants (35.3%) *vs* controls (17.6%) were comfortable enough to receive an injection though not significant (12 of 34)<sup>[131]</sup>. Participants' origins of fear were not assessed, thus it cannot currently be determined which pathways were involved, and further research is required. However, as CARL is self-paced, it may perhaps aid in treating patients who wish to learn to cope without therapists, thereby improving access to oral health care.

### Hypnotherapy

Perhaps one of the least understood treatments for dental fear is hypnotherapy (HT). HT attempts to create a state

of unconscious change, whereby the individual forms new responses, attitudes, and behaviors to previously feared stimuli. Few studies have analyzed the clinical effectiveness of hypnotherapy. In 1995, research reported that when compared to psychophysiological therapies such as CBT, HT did not significantly reduce dental fear<sup>[132]</sup>. Researchers purported that this was because some people were put off by the concept of hypnotherapy and were not fully receptive to the therapy<sup>[132]</sup>. Some years later, Moore *et al.*<sup>[123]</sup> (2002) found that although 54.5% of HT patients were able to maintain regular dental appointments, at 3 years post treatment, there was no difference between the HT, GT, or ISD groups.

### Pharmacological

The use of nitrous oxide (NO) and benzodiazepines in dentistry has long been employed to reduce anxiety. NO has often been compared to the effectiveness of CBT and relaxation therapies. For example, Willumsen *et al.*<sup>[133]</sup> (2001) reported no significant differences between NO and CBT or applied relaxation therapy. They suggested that in the short term, either treatment was effective. Interestingly the study reported a 95% of participants attended rate a year later, with the greatest reduction in dental fear observed in the relaxation therapy group<sup>[130]</sup>. While all groups reported normal levels of dental fear (as per Corah's DAS) one year later<sup>[130]</sup>, analysis of benzodiazepines when combined with ISD did not reduce overall therapy time and was not advantageous for treating injection phobia<sup>[134]</sup>. The studies did note that the results might have been skewed by the fact that each participant's dental fear might have different origins. Thus, research is required to determine whether certain origins of fear and pathways are more receptive to pharmacological agents than others are.

## CONCLUSION

The present article has highlighted the possible types of dental fear, their origins in dentistry and current knowledge on management of patient with fear and anxiety. There is, however, a lack of knowledge of the effects of demographics, causal factors, ethnicity, and treatment modalities relative to the origin and pathways of fear in dentistry. Understanding the origin of a patient's fears and anxiety could help enhance patient management and care.

## REFERENCES

- 1 **Moore R**, Birn H. [Phenomenon of dental fear]. *Tandlaege-bladet* 1990; **94**: 34-41 [PMID: 2377962]
- 2 **Moore R**, Brødsgaard I. Differential diagnosis of odontophobic patients using the DSM-IV. *Eur J Oral Sci* 1995; **103**: 121-126 [PMID: 7767707]
- 3 **Armfield JM**, Stewart JF, Spencer AJ. The vicious cycle of dental fear: exploring the interplay between oral health, service utilization and dental fear. *BMC Oral Health* 2007; **7**: 1 [PMID: 17222356 DOI: 10.1186/1472-6831-7-1]
- 4 **Armfield JM**, Spencer AJ, Stewart JF. Dental fear in Australia: who's afraid of the dentist? *Aust Dent J* 2006; **51**: 78-85 [PMID: 16669482]
- 5 **Gross PR**. Is pain sensitivity associated with dental avoidance? *Behav Res Ther* 1992; **30**: 7-13 [PMID: 1540116]
- 6 **Berggren U**, Meynert G. Dental fear and avoidance: causes, symptoms, and consequences. *J Am Dent Assoc* 1984; **109**: 247-251 [PMID: 6590605]
- 7 **Australian Research Centre for Population Oral Health**. The avoidance and delaying of dental visits in Australia. Australia: University of Adelaide, 2012: 1-5 [DOI: 10.1111/j.1834-7819.2012.01697.x]
- 8 **Pohjola V**, Mattila AK, Joukamaa M, Lahti S. Anxiety and depressive disorders and dental fear among adults in Finland. *Eur J Oral Sci* 2011; **119**: 55-60 [PMID: 21244512 DOI: 10.1111/j.1600-0722.2010.00795.x]
- 9 **Mellor AC**. Dental anxiety and attendance in the north-west of England. *J Dent* 1992; **20**: 207-210 [PMID: 1430509 DOI: 10.1016/0300-5712(92)90077-P]
- 10 **Schwarz E**, Birn H. Dental anxiety in Danish and Chinese adults--a cross-cultural perspective. *Soc Sci Med* 1995; **41**: 123-130 [PMID: 7667665]
- 11 **Ragnarsson E**. Dental fear and anxiety in an adult Icelandic population. *Acta Odontol Scand* 1998; **56**: 100-104 [PMID: 9669461]
- 12 **Chellappah NK**, Vignehsa H, Milgrom P, Lam LG. Prevalence of dental anxiety and fear in children in Singapore. *Community Dent Oral Epidemiol* 1990; **18**: 269-271 [PMID: 2249413]
- 13 **Oosterink FM**, de Jongh A, Hoogstraten J. Prevalence of dental fear and phobia relative to other fear and phobia subtypes. *Eur J Oral Sci* 2009; **117**: 135-143 [PMID: 19320722 DOI: 10.1111/j.1600-0722.2008.00602.x]
- 14 **Kunzelmann KH**, Dünninger P. Dental fear and pain: effect on patient's perception of the dentist. *Community Dent Oral Epidemiol* 1990; **18**: 264-266 [PMID: 2249411]
- 15 **Enkling N**, Marwinski G, Jöhren P. Dental anxiety in a representative sample of residents of a large German city. *Clin Oral Investig* 2006; **10**: 84-91 [PMID: 16477408]
- 16 **Weinstein P**, Shimono T, Domoto P, Wohlers K, Matsumura S, Ohmura M, Uchida H, Omachi K. Dental fear in Japan: Okayama Prefecture school study of adolescents and adults. *Anesth Prog* 1992; **39**: 215-220 [PMID: 8250343]
- 17 **Aartman IH**, de Jongh A, Makkes PC, Hoogstraten J. Dental anxiety reduction and dental attendance after treatment in a dental fear clinic: a follow-up study. *Community Dent Oral Epidemiol* 2000; **28**: 435-442 [PMID: 11106016]
- 18 **Mehrstedt M**, Tönnies S, Eisentraut I. Dental fears, health status, and quality of life. *Anesth Prog* 2004; **51**: 90-94 [PMID: 15497298]
- 19 **Moore R**, Brødsgaard I, Birn H. Manifestations, acquisition and diagnostic categories of dental fear in a self-referred population. *Behav Res Ther* 1991; **29**: 51-60 [PMID: 2012589]
- 20 **Berggren U**, Carlsson SG, Gustafsson JE, Hakeberg M. Factor analysis and reduction of a Fear Survey Schedule among dental phobic patients. *Eur J Oral Sci* 1995; **103**: 331-338 [PMID: 8521126]
- 21 **Moore R**, Brødsgaard I, Rosenberg N. The contribution of embarrassment to phobic dental anxiety: a qualitative research study. *BMC Psychiatry* 2004; **4**: 10 [PMID: 15096278 DOI: 10.1186/1471-244X-4-10]
- 22 **Gregory AM**, Eley TC. Genetic influences on anxiety in children: what we've learned and where we're heading. *Clin Child Fam Psychol Rev* 2007; **10**: 199-212 [PMID: 17503180]
- 23 **Hettema JM**, Annas P, Neale MC, Fredrikson M, Kendler KS. The genetic covariation between fear conditioning and self-report fears. *Biol Psychiatry* 2008; **63**: 587-593 [PMID: 17698042]
- 24 **Fyer AJ**, Mannuzza S, Chapman TF, Martin LY, Klein DF. Specificity in familial aggregation of phobic disorders. *Arch Gen Psychiatry* 1995; **52**: 564-573 [PMID: 7598633]
- 25 **Rose RJ**, Miller JZ, Pogue-Geile MF, Cardwell GF. Twin-family studies of common fears and phobias. *Prog Clin Biol Res* 1981; **69** Pt B: 169-174 [PMID: 7199159]
- 26 **Skre I**, Onstad S, Torgersen S, Philos DR, Lygren S, Kringlen E. The heritability of common phobic fear: a twin study of a clinical sample. *J Anxiety Disord* 2000; **14**: 549-562 [PMID: 11918091 DOI: 10.1016/S0887-6185(00)00049-9]
- 27 **Kressin NR**, Spiro A, Skinner KM. Negative affectivity and health-related quality of life. *Med Care* 2000; **38**: 858-867 [PMID: 10929997]
- 28 **Mineka S**, Ohman A. Phobias and preparedness: the selective, automatic, and encapsulated nature of fear. *Biol Psychiatry* 2002; **52**: 927-937 [PMID: 12437934]
- 29 **Seligman MEP**. Phobias and Preparedness. *Behav Ther* 1971; **2**: 307-320 [DOI: 10.1016/S0005-7894(71)80064-3]
- 30 **Wolpe J**. The dichotomy between classically conditioned and cognitively learned anxiety. *J Behav Ther Exp Psychiatry* 1981; **12**: 35-42 [PMID: 7251880]
- 31 **Hosoba T**, Iwanaga M, Seiwa H. The effect of UCS inflation and deflation procedures on 'fear' conditioning. *Behav Res Ther* 2001; **39**: 465-475 [PMID: 11280344 DOI: 10.1016/0146-6402(92)90010-L]
- 32 **Kryukov VI**. Towards a unified model of pavlovian conditioning: short review of trace conditioning models. *Cogn Neurodyn* 2012; **6**: 377-398 [PMID: 24082960]
- 33 **Watson JB**, Rayner R. Conditioned Emotional Reactions. *J Exp Psychol* 1920; **3**: 1-14
- 34 **Mineka S**, Keir R. The effects of flooding on reducing snake fear in rhesus monkeys: 6-month follow-up and further flooding. *Behav Res Ther* 1983; **21**: 527-535 [PMID: 6360128 DOI: 10.1037/0021-843X.95.4.307]
- 35 **Hugdahl K**. Direction of changes in the cardiac component in a Pavlovian conditioning paradigm with variations in CS- and UCS-contents. *Biol Psychol* 1979; **9**: 91-102 [PMID: 540114]
- 36 **Rachman S**. The conditioning theory of fear-acquisition: a critical examination. *Behav Res Ther* 1977; **15**: 375-387 [PMID: 612338 DOI: 10.1016/0005-7967(77)90041-9]
- 37 **Merckelbach H**, Arntz A, de Jong P. Conditioning experiences in spider phobics. *Behav Res Ther* 1991; **29**: 333-335 [PMID: 1679628]
- 38 **Cook M**, Mineka S. Observational conditioning of fear to fear-relevant versus fear-irrelevant stimuli in rhesus monkeys. *J Abnorm Psychol* 1989; **98**: 448-459 [PMID: 2592680]
- 39 **Wolpe J**, Lande SD, McNally RJ, Schotte D. Differentiation between classically conditioned and cognitively based neurotic fears: two pilot studies. *J Behav Ther Exp Psychiatry* 1985; **16**: 287-293 [PMID: 4086650]
- 40 **Mowrer OH**. Learning theory and the symbolic processes. London: UK, 1960. Available from: URL: <http://www.abebooks.co.uk/Learning-Theory-Symbolic-Process-Mowrer-OH/857643055/bd>
- 41 **Rachman S**. Fear and Courage. San Francisco: Freeman, 1978. Available from: URL: <http://trove.nla.gov.au/work/11583705?selectedversion=NBD1120715>
- 42 **Askew C**, Field AP. The vicarious learning pathway to fear 40 years on. *Clin Psychol Rev* 2008; **28**: 1249-1265 [PMID: 18614263 DOI: 10.1016/j.cpr.2008.05.003]



- 43 **Carrillo-Díaz M**, Crego A, Armfield J, Romero M. The moderating role of dental expectancies on the relationship between cognitive vulnerability and dental fear in children and adolescents. *Community Dent Oral Epidemiol* 2013; **41**: 269-278 [PMID: 23005253 DOI: 10.1111/cdoe.12009]
- 44 **Carrillo-Díaz M**, Crego A, Armfield JM, Romero-Maroto M. Treatment experience, frequency of dental visits, and children's dental fear: a cognitive approach. *Eur J Oral Sci* 2012; **120**: 75-81 [PMID: 22288924 DOI: 10.1111/j.1600-0722.2011.00921.x]
- 45 **Waters AM**, Wharton TA, Zimmer-Gembeck MJ, Craske MG. Threat-based cognitive biases in anxious children: comparison with non-anxious children before and after cognitive behavioural treatment. *Behav Res Ther* 2008; **46**: 358-374 [PMID: 18304519 DOI: 10.1016/j.brat.2008.01.002]
- 46 **Klingberg G**, Broberg AG. Dental fear/anxiety and dental behaviour management problems in children and adolescents: a review of prevalence and concomitant psychological factors. *Int J Paediatr Dent* 2007; **17**: 391-406 [PMID: 17935593]
- 47 **Themessl-Huber M**, Freeman R, Humphris G, MacGillivray S, Terzi N. Empirical evidence of the relationship between parental and child dental fear: a structured review and meta-analysis. *Int J Paediatr Dent* 2010; **20**: 83-101 [PMID: 20384823 DOI: 10.1111/j.1365-263X.2009.00998.x]
- 48 **Pine DS**, Klein RG. Anxiety Disorders. In: Rutter's Child and Adolescent Psychiatry, Rutter M, editor. Oxford UK: Blackwell Publishing Ltd, 2009
- 49 **ten Berge M**, Veerkamp JS, Hoogstraten J, Prins PJ. Childhood dental fear in relation to parental child-rearing attitudes. *Psychol Rep* 2003; **92**: 43-50 [PMID: 12674255]
- 50 **Coelho MC**, Purkis H. The Origins of Specific Phobias: Influential Theories and current Perspectives. *RGP* 2009; **13**: 335-348 [DOI: 10.1037/a0017759]
- 51 **Seligman MEP**. On the generality of the laws of learning. *Psychological Review* 1970; **77**: 406-418 [DOI: 10.1037/h0029790]
- 52 **Mineka S**, Ohman A. Born to fear: non-associative vs associative factors in the etiology of phobias. *Behav Res Ther* 2002; **40**: 173-184 [PMID: 11814181]
- 53 **Poulton R**, Menzies RG. Fears born and bred: toward a more inclusive theory of fear acquisition. *Behav Res Ther* 2002; **40**: 197-208 [PMID: 11814183]
- 54 **Poulton R**, Menzies RG. Non-associative fear acquisition: a review of the evidence from retrospective and longitudinal research. *Behav Res Ther* 2002; **40**: 127-149 [PMID: 11814178]
- 55 **Menzies RG**, Clarke JC. The etiology of childhood water phobia. *Behav Res Ther* 1993; **31**: 499-501 [PMID: 8333825]
- 56 **Menzies RG**, Clarke JC. The etiology of fear of heights and its relationship to severity and individual response patterns. *Behav Res Ther* 1993; **31**: 355-365 [PMID: 8512537]
- 57 **Muris P**, Steerneman P, Merckelbach H, Meesters C. The role of parental fearfulness and modeling in children's fear. *Behav Res Ther* 1996; **34**: 265-268 [PMID: 8881095]
- 58 **Klingberg G**, Berggren U, Carlsson SG, Noren JG. Child dental fear: cause-related factors and clinical effects. *Eur J Oral Sci* 1995; **103**: 405-412 [PMID: 8747678]
- 59 **Brush RF**, Overmier BJ. Affect conditioning and cognition: Essays on the determinants of behavior. Hillsdale (NJ): Lawrence Erlbaum Associates, 1985
- 60 **Morgan JB**, Watson JB. Emotional reactions and psychological experimentation. By John B. Watson and J. J. B. Morgan, 1917. *Am J Psychol* 1917; **100**: 510-537 [PMID: 3322055]
- 61 **Carter A**. Development of a Dental Fear Questionnaire: the role of Ethnicity in Endodontic Fear and Anxiety. Gold Coast (Australia): Doctoral Dissertation, School of Dentistry and Oral Health, Griffith University, 2012
- 62 **Ost LG**, Hugdahl K. Acquisition of blood and dental phobia and anxiety response patterns in clinical patients. *Behav Res Ther* 1985; **23**: 27-34 [PMID: 3985914 DOI: 10.1016/0005-7967(85)90139-1]
- 63 **Kudo T**, Mishima R, Yamamura K, Mostafaezur R, Zakir HM, Kurose M, Yamada Y. Difference in physiological responses to sound stimulation in subjects with and without fear of dental treatments. *Odontology* 2008; **96**: 44-49 [PMID: 18661204 DOI: 10.1007/s10266-008-0086-z]
- 64 **Watkins CA**, Logan HL, Kirchner HL. Anticipated and experienced pain associated with endodontic therapy. *J Am Dent Assoc* 2002; **133**: 45-54 [PMID: 11811742]
- 65 **van Wijk AJ**, Hoogstraten J. Experience with dental pain and fear of dental pain. *J Dent Res* 2005; **84**: 947-950 [PMID: 16183796]
- 66 **Armfield JM**. Towards a better understanding of dental anxiety and fear: cognitions vs. experiences. *Eur J Oral Sci* 2010; **118**: 259-264 [PMID: 20572859]
- 67 **De Jongh A**, van der Burg J, van Overmeir M, Aartman I, van Zuuren FJ. Trauma-related sequelae in individuals with a high level of dental anxiety. Does this interfere with treatment outcome? *Behav Res Ther* 2002; **40**: 1017-1029 [PMID: 12296487]
- 68 **Hakeberg M**, Berggren U. Dimensions of the Dental Fear Survey among patients with dental phobia. *Acta Odontol Scand* 1997; **55**: 314-318 [PMID: 9370030]
- 69 **Ollendick TH**, King NJ. Origins of childhood fears: an evaluation of Rachman's theory of fear acquisition. *Behav Res Ther* 1991; **29**: 117-123 [PMID: 2021373]
- 70 **Stabholz A**, Peretz B. Dental anxiety among patients prior to different dental treatments. *Int Dent J* 1999; **49**: 90-94 [PMID: 10858738]
- 71 **Armfield JM**. Development and psychometric evaluation of the Index of Dental Anxiety and Fear (IDAF-4C+). *Psychol Assess* 2010; **22**: 279-287 [PMID: 20528055 DOI: 10.1037/a0018678]
- 72 **Berggren U**. General and specific fears in referred and self-referred adult patients with extreme dental anxiety. *Behav Res Ther* 1992; **30**: 395-401 [PMID: 1616474]
- 73 **Domoto PK**, Weinstein P, Melnick S, Ohmura M, Uchida H, Ohmachi K, Hori M, Okazaki Y, Shimamoto T, Matsumura S. Results of a dental fear survey in Japan: implications for dental public health in Asia. *Community Dent Oral Epidemiol* 1988; **16**: 199-201 [PMID: 3165743]
- 74 **Locker D**, Liddell A, Dempster L, Shapiro D. Age of onset of dental anxiety. *J Dent Res* 1999; **78**: 790-796 [PMID: 10096455]
- 75 **Armfield JM**, Slade GD, Spencer AJ. Are people with dental fear under-represented in oral epidemiological surveys? *Soc Psychiatry Psychiatr Epidemiol* 2009; **44**: 495-500 [PMID: 18974907 DOI: 10.1007/s00127-008-0454-6]
- 76 **Armfield JM**, Slade GD, Spencer AJ. Cognitive vulnerability and dental fear. *BMC Oral Health* 2008; **8**: 2 [PMID: 18218075 DOI: 10.1186/1472-6831-8-2]
- 77 **Kleinknecht RA**, Thorndike RM, McGlynn FD, Harkavy J. Factor analysis of the dental fear survey with cross-validation. *J Am Dent Assoc* 1984; **108**: 59-61 [PMID: 6582116]
- 78 **Lindsay SJ**, Wege P, Yates J. Expectations of sensations, discomfort and fear in dental treatment. *Behav Res Ther* 1984; **22**: 99-108 [PMID: 6712560]
- 79 **Cook M**, Mineka S. Selective associations in the observational conditioning of fear in rhesus monkeys. *J Exp Psychol Anim Behav Process* 1990; **16**: 372-389 [PMID: 2230660]
- 80 **Smith TA**, Heaton LJ. Fear of dental care: are we making any progress? *J Am Dent Assoc* 2003; **134**: 1101-1108 [PMID: 12956352]
- 81 **Field AP**. Watch out for the beast: fear information and attentional bias in children. *J Clin Child Adolesc Psychol* 2006; **35**: 431-439 [PMID: 16836480]
- 82 **Field AP**, Cartwright-Hatton S, Reynolds S, Creswell C. Future directions for child anxiety theory and treatment. *Cognition and Emotion* 2008; **22**: 385-394 [DOI: 10.1080/02699930701842270]
- 83 **Lang**. The cognitive psychopathology of emotion: Fear and



- anxiety, in *Anxiety and the anxiety disorders*. In: Tuma A, Maser J, editors. Hillsdale (NJ): Lawrence Erlbaum Associates, 1985: 131-170
- 84 **Field AP**, Ball JE, Kawycz NJ, Moore H. Parent-child relations and the verbal information pathway to fear in children: Two preliminary experiments. *Behavioural and Cognitive Psychotherapy* 2007; **35**: 473-486 [DOI: 10.1017/S1352465807003736]
  - 85 **Field A**, Lawson J. The verbal information pathway to fear and subsequent causal learning in children. *Cognition and Emotion* 2008; **22**: 459-479 [DOI: 10.1080/02699930801886532]
  - 86 **Field AP**, Lawson J, Banerjee R. The verbal threat information pathway to fear in children: the longitudinal effects on fear cognitions and the immediate effects on avoidance behavior. *J Abnorm Psychol* 2008; **117**: 214-224 [PMID: 18266499 DOI: 10.1037/0021-843X.117.1.214]
  - 87 **Muris P**, Field AP. The role of verbal threat information in the development of childhood fear. "Beware the Jabberwock!". *Clin Child Fam Psychol Rev* 2010; **13**: 129-150 [PMID: 20198423 DOI: 10.1007/s10567-010-0064-1]
  - 88 **Adelaide TUO**. Dr Jason Armfield, Senior Research Fellow. Available from: URL: <http://www.arcpoh.adelaide.edu.au/people/html/jason.html> [retrieved 11/09/13]
  - 89 **Field AP**, Graham D. Anxiety disorders in children and adolescents: research, assessment and intervention. In: conditioning models of childhood anxiety. Silverman WK, Trefers PA, editors. Cambridge (UK): Cambridge University Press, 2001: 187-211
  - 90 **Field AP**, Hamilton SJ, Knowles KA, Plews EL. Fear information and social phobic beliefs in children: a prospective paradigm and preliminary results. *Behav Res Ther* 2003; **41**: 113-123 [PMID: 12488124]
  - 91 **Field AP**, Lawson J. Fear information and the development of fears during childhood: effects on implicit fear responses and behavioural avoidance. *Behav Res Ther* 2003; **41**: 1277-1293 [PMID: 14527528]
  - 92 **Field A**, Lester KJ. Learning of information processing biases in anxious children and adolescents. In: Information processing biases and anxiety: A developmental perspective. Hadwin J, Field A, editors. Chichester (UK): Wiley and Sons Ltd, 2010 [DOI: 10.1002/9780470661468]
  - 93 **Van Kraaij C**, Breukink E, Rollemans HS, Siezen RJ, Demel RA, De Kruijff B, Kuipers OP. Influence of charge differences in the C-terminal part of nisin on antimicrobial activity and signaling capacity. *Eur J Biochem* 1997; **247**: 114-120 [PMID: 9249016]
  - 94 **Field AP**, Schorah H. The verbal information pathway to fear and heart rate changes in children. *J Child Psychol Psychiatry* 2007; **48**: 1088-1093 [PMID: 17995484]
  - 95 **Field AP**, Storcken-Coulson H. The interaction of pathways to fear in childhood anxiety: a preliminary study. *Behav Res Ther* 2007; **45**: 3051-3059 [PMID: 17935694]
  - 96 **Field AP**, Argyris NG, Knowles KA. Who's afraid of the big bad wolf: a prospective paradigm to test Rachman's indirect pathways in children. *Behav Res Ther* 2001; **39**: 1259-1276 [PMID: 11686263]
  - 97 **Field A**, Lester K, Cartwright-Hatton S. Cognitive-behavioral processes in the intergenerational transmission of fear to children. Annual congress of the association for the advancement of behavior and cognitive therapy, 2008
  - 98 **Antony MM**, Orsillo SM, Roemer L. Practitioners guide to empirically based measures of anxiety. 1st ed. New York (USA): Springer, 2001
  - 99 **Ost LG**, Hugdahl K. Acquisition of phobias and anxiety response patterns in clinical patients. *Behav Res Ther* 1981; **19**: 439-447 [DOI: 10.1016/0005-7967(81)90134-0]
  - 100 **Kirkby KC**, Menzies RG, Daniels BA, Smith KL. Aetiology of spider phobia: classificatory differences between two origins instruments. *Behav Res Ther* 1995; **33**: 955-958 [PMID: 7487855 DOI: 10.1016/0005-7967(95)00010-U]
  - 101 **Menzies RG**, Clarke JC. Retrospective studies of the origins of phobias: A review. *Anxiety, Stress and Coping: An International Journal* 1994; **7**: 305-318 [DOI: 10.1080/10615809408249354]
  - 102 **McNeil DW**, Rainwater AJ. Development of the Fear of Pain Questionnaire--III. *J Behav Med* 1998; **21**: 389-410 [PMID: 9789168]
  - 103 **Menzies RG**, Kirkby K, Harris LM. The convergent validity of the Phobia Origins Questionnaire (POQ): a review of the evidence. *Behav Res Ther* 1998; **36**: 1081-1089 [PMID: 9737060]
  - 104 **Merckelbach H**, van Hout W, van den Hout MA, Mersch PP. Psychophysiological and subjective reactions of social phobics and normals to facial stimuli. *Behav Res Ther* 1989; **27**: 289-294 [PMID: 2730510]
  - 105 **Fazio AF**. Implosive therapy with semiclinical phobias. *J Abnorm Psychol* 1972; **80**: 183-188 [PMID: 5077184]
  - 106 **Kleinknecht RD**. The origins and remission of fear in a group of tarantula enthusiasts. *Behav Res Ther* 1982; **20**: 437-443 [DOI: 10.1016/0005-7967(82)90065-1]
  - 107 **Rimm DC**, Janda LH, Lancaster DW, Nahl M, Dittmar K. An exploratory investigation of the origin and maintenance of phobias. *Behav Res Ther* 1977; **15**: 231-238 [PMID: 597092]
  - 108 **Marks IM**. Fears phobias and rituals: Panic, anxiety and their disorders. New York: Oxford University Press, 1987
  - 109 **Mattick R**. Nature and treatment of social phobia: Unpublished Doctoral Dissertation. Sydney: University of New South Wales, 1987
  - 110 **Menzies RG**. The origins of specific phobias in a mixed clinical sample: Classificatory differences between two origins instruments. *J ANXIETY DISORD* 1996; **10**: 347-354 [DOI: 10.1016/0887-6185(96)00015-1]
  - 111 **Withers RD**, Deane FP. Origins of common fears: effects on severity, anxiety responses and memories of onset. *Behav Res Ther* 1995; **33**: 903-915 [PMID: 7487850]
  - 112 **Schuurs AH**, Hoogstraten J. Appraisal of dental anxiety and fear questionnaires: a review. *Community Dent Oral Epidemiol* 1993; **21**: 329-339 [PMID: 8306609]
  - 113 **Armfield JM**. How do we measure dental fear and what are we measuring anyway? *Oral Health Prev Dent* 2010; **8**: 107-115 [PMID: 20589243]
  - 114 **Armfield JM**. Australian population norms for the Index of Dental Anxiety and Fear (IDAF-4C). *Aust Dent J* 2011; **56**: 16-22 [PMID: 21332736]
  - 115 **Milgrom P**, Fiset L, Melnick S, Weinstein P. The prevalence and practice management consequences of dental fear in a major US city. *J Am Dent Assoc* 1988; **116**: 641-647 [PMID: 3164029]
  - 116 **Milgrom P**. Treating Fearful Dental Patients: A Patient Management Handbook. Reston (Va): Reston Pub. Co, 1985
  - 117 **McNeil DW**, Berryman ML. Components of dental fear in adults? *Behav Res Ther* 1989; **27**: 233-236 [PMID: 2730504]
  - 118 **Weiner AA**, Sheehan DV. Etiology of dental anxiety: psychological trauma or CNS chemical imbalance? *Gen Dent* 1990; **38**: 39-43 [PMID: 2376317]
  - 119 **Locker D**, Liddell A, Shapiro D. Diagnostic categories of dental anxiety: a population-based study. *Behav Res Ther* 1999; **37**: 25-37 [PMID: 9922555]
  - 120 **Sheehan DV**, Sheehan KH. The classification of phobic disorders. *Int J Psychiatry Med* 1983; **12**: 243-266 [PMID: 7166458 DOI: 10.1192/bjp.116.533.377]
  - 121 **Roy-Byrne PP**, Milgrom P, Khoon-Mei T, Weinstein P, Katon W. Psychopathology and psychiatric diagnosis in subjects with dental phobia. *JAD* 1994; **8**: 19-31 [DOI: 10.1016/0887-6185(94)90020-5]
  - 122 **Dailey YM**, Humphris GM, Lennon MA. The use of dental anxiety questionnaires: a survey of a group of UK dental practitioners. *Br Dent J* 2001; **190**: 450-453 [PMID: 11352394]
  - 123 **Moore R**, Brødsgaard I, Abrahamsen R. A 3-year comparison of dental anxiety treatment outcomes: hypnosis, group

- therapy and individual desensitization vs. no specialist treatment. *Eur J Oral Sci* 2002; **110**: 287-295 [PMID: 12206590]
- 124 **American Psychological Association.** APA Dictionary of Psychology. USA: APA, 2006
  - 125 **Mathews A,** Rezin V. Treatment of dental fears by imaginal flooding and rehearsal of coping behaviour. *Behav Res Ther* 1977; **15**: 321-328 [PMID: 907605 DOI: 10.1016/0005-7967(77)90063-8]
  - 126 **Davies JG,** Wilson KI, Clements AL. A joint approach to treating dental phobia: a re-evaluation of a collaboration between community dental services and specialist psychotherapy services ten years on. *Br Dent J* 2011; **211**: 159-162 [PMID: 21869789 DOI: 10.1038/sj.bdj.2011.674.]
  - 127 **Lundgren J,** Carlsson SG, Berggren U. Relaxation versus cognitive therapies for dental fear--a psychophysiological approach. *Health Psychol* 2006; **25**: 267-273 [PMID: 16719597]
  - 128 **Berggren U,** Hakeberg M, Carlsson SG. Relaxation vs. cognitively oriented therapies for dental fear. *J Dent Res* 2000; **79**: 1645-1651 [PMID: 11023258]
  - 129 **ten Berge M,** Veerkamp JS, Hoogstraten J, Prins PJ. Parental beliefs on the origins of child dental fear in The Netherlands. *ASDC J Dent Child* 2001; **68**: 51-54, 12 [PMID: 11324408]
  - 130 **Willumsen T,** Vassend O, Hoffart A. One-year follow-up of patients treated for dental fear: effects of cognitive therapy, applied relaxation, and nitrous oxide sedation. *Acta Odontol Scand* 2001; **59**: 335-340 [PMID: 11831481]
  - 131 **Heaton LJ,** Leroux BG, Ruff PA, Coldwell SE. Computerized dental injection fear treatment: a randomized clinical trial. *J Dent Res* 2013; **92**: 37S-42S [PMID: 23690352 DOI: 10.1177/0022034513484330]
  - 132 **Stivala F,** Bonina F, Iacona G, Cordopatri F, Mazzone G. [Effects of lymphocyte stimulation in vitro of alkaline salts of some aroyl-hydrazino-carbodithioic acids and 1,3,4-oxadiazole derivatives: preliminary research]. *Boll Soc Ital Biol Sper* 1978; **54**: 1264-1270 [PMID: 747677]
  - 133 **Willumsen T,** Vassend O, Hoffart A. A comparison of cognitive therapy, applied relaxation, and nitrous oxide sedation in the treatment of dental fear. *Acta Odontol Scand* 2001; **59**: 290-296 [PMID: 11680648]
  - 134 **Coldwell SE,** Wilhelm FH, Milgrom P, Prall CW, Getz T, Spadafora A, Chiu IY, Leroux BG, Ramsay DS. Combining alprazolam with systematic desensitization therapy for dental injection phobia. *J Anxiety Disord* 2007; **21**: 871-887 [PMID: 17320345]

P- Reviewer: Lopez-Jornet P, Oji C S- Editor: Ji FF  
L- Editor: A E- Editor: Lu YJ



## Squamous cell carcinoma of the scrotum: A look beyond the chimneystacks

Ritva Vyas, Homayoun Zargar, Rossella Di Trollo, Giuseppe Di Lorenzo, Riccardo Autorino

Ritva Vyas, Department of Dermatology, University Hospitals Case Medical Center, Cleveland, OH 44106, United States

Homayoun Zargar, Glickman Urological and Kidney Institute, Cleveland Clinic, Cleveland, OH 44195, United States

Rossella Di Trollo, Unit of Medical Oncology and Innovative Therapy, National Cancer Institute "Fondazione Giovanni Pascale", 80100 Napoli, Italy

Giuseppe Di Lorenzo, Genitourinary Cancer Section and Rare-Cancer Center, Medical Oncology Division, University Federico II, 80100 Napoli, Italy

Riccardo Autorino, Urology Institute, University Hospitals Case Medical Center, Cleveland, OH 44106, United States

Riccardo Autorino, Urology Unit, Second University of Naples, 80100 Naples, Italy

Author contributions: All authors contributed to this paper.

Correspondence to: Riccardo Autorino, MD, PhD, FEBU, Urology Institute, University Hospitals Case Medical Center, 11100 Euclid Avenue, Cleveland, OH 44106, United States. [ricautor@gmail.com](mailto:ricautor@gmail.com)

Telephone: +1-440-5168700 Fax: +1-216-2015276

Received: June 11, 2014 Revised: August 23, 2014

Accepted: September 16, 2014

Published online: November 16, 2014

**Key words:** Squamous cell carcinoma; Genital cancer; Scrotal cancer

**Core tip:** Scrotal squamous cell carcinoma (SCC) although rare, represents one of the most common forms of scrotal malignancy. The epidemiology of SCC has changed over time and iatrogenic conditions (psoralens and ultraviolet A radiation, immunosuppression, *etc.*) and human papilloma virus infection play a significant role as associated conditions. Surgery is the cornerstone of treatment and primary excision with a risk stratified approach for staging and treatment of regional lymph node is advisable. Sentinel lymph node biopsy can mitigate the morbidities of unwarranted inguinal lymph node dissection in selected cases. For locally advanced and metastatic disease palliative chemotherapy is advocated. Targeted therapies might hold promise for management of advanced SCC.

Vyas R, Zargar H, Trollo RD, Lorenzo GD, Autorino R. Squamous cell carcinoma of the scrotum: A look beyond the chimneystacks. *World J Clin Cases* 2014; 2(11): 654-660 Available from: URL: <http://www.wjgnet.com/2307-8960/full/v2/i11/654.htm> DOI: <http://dx.doi.org/10.12998/wjcc.v2.i11.654>

### Abstract

Despite the low incidence, squamous cell carcinoma (SCC) remains the most common scrotal malignancy with a propensity for recurrence and metastasis. In recent years there has been a significant change in the epidemiology of scrotal SCC. Surgery is the mainstay of treatment for resectable disease. Sentinel lymph node dissection adapted from experience with penile SCC can reduce the morbidity of routine lymph node dissection. Emerging treatments for advanced and metastatic SCC are at the cusp of significantly changing management of this disease. We have performed a comprehensive review of scrotal SCC with a focus on these topics.

© 2014 Baishideng Publishing Group Inc. All rights reserved.

### INTRODUCTION

Squamous cell carcinoma (SCC) is the most common scrotal malignancy<sup>[1,2]</sup>. Despite awareness and removal of occupational carcinogens over the last century, after initial reduction in incidence, scrotal SCC has maintained a steady incidence rate. Due to significant associated morbidity and mortality it remains an important urogenital malignancy for the urologist. Our aim was to review recent published literature on scrotal SCC and highlight changing epidemiology as well as emerging therapies.

## HISTORICAL BACKGROUND

The earliest accounts of scrotal SCC date back to the Persian nomads who used to transport pots of burning coal between their legs to keep warm as they travelled<sup>[3]</sup>. The first clinical descriptions of cases occurring were by Bassius and Treyling in the mid 1700s, with Treyling describing a case in a Cavalryman<sup>[4]</sup>. Sir Percival Potts in 1775 was the first to link the chronic lodgment of soot in the rugal folds of the scrotum occurring in chimney sweeps to development of scrotal SCC<sup>[5-7]</sup>. It hence became known as the first described occupational disease. The active carcinogen discovered later was 3,4-benzpyrene. Occupational scrotal SCC was also later described in association with other occupations with chronic carcinogen exposure including cotton mule spinners, paraffin and tar workers, creosote workers, shale oil workers, lathe workers, pitch workers and machine tool setters and operators<sup>[4,8-12]</sup>. More recently it has been described in car mechanics, car and airplane manufacture, gas workers, engineers, steel manufacture and aluminum workers<sup>[11,13-15]</sup>. The majority of occupationally related scrotal SCC can be attributed to exposure to carcinogenic polycyclic aromatic hydrocarbons<sup>[10]</sup>.

## EPIDEMIOLOGY

In order to assess recent trends in the epidemiology of scrotal SCC, we examined all clinical studies published on scrotal SCC since the year 2000.

There were six case series published including two Surveillance Epidemiology, and End Results (SEER) based analyses, one Netherlands Cancer Registry (NCR) based analysis, one prospective multi-institutional study and two retrospective studies<sup>[1,2,16-19]</sup>.

Studies in the mid-to-late 1900s reported that scrotal SCC accounting for the majority (80%-100%) of all scrotal malignancies but in more recent reports it only accounts for one-third of all scrotal malignancies<sup>[1,2,16,20,21]</sup>. However scrotal SCC still remains the most common scrotal malignancy<sup>[1,2,16]</sup>. Other scrotal malignancies include extramammary Paget's disease (EMPD), sarcoma, basal cell carcinoma, melanoma, Bowen's disease (SCCIS) and adnexal skin tumors. Median age at diagnosis ranges from 52-57 years<sup>[1,18,19]</sup>. Most cases occur in Caucasian men followed by Black and Asian men and other ethnicities.

Verhoeven *et al*<sup>[1]</sup> reported the age-standardized 5-year incidence rate of all histologic types of scrotal cancer in the Netherlands and this varied between 0.9 and 1.8 per 1000000 male person-years from 1986 to 2006 with no statistically significant change over time<sup>[1]</sup>. Age-standardized incidence rate of scrotal SCC varied between 0.34 and 0.44 per 1000000 male person-years from 1986 to 2006. Over a similar time period Wright *et al*<sup>[2]</sup> reported on the age-adjusted incidence rate of scrotal cancer in the United states which increased from 0.49 per 1000000 persons in 1973 to 0.95 per 1000000 persons in 2002. While

specific incidence rate of scrotal SCC was not provided they did report no change in incidence rates by histologic type<sup>[2]</sup>. The incidence reported from the Connecticut Tumor registry data from 1935 to 1979 showed stable incidence rates of all scrotal malignancies and epithelial scrotal malignancies<sup>[22]</sup>. It has been speculated that the reason for this sustained incidence despite occupation carcinogen avoidance has been the emergence of new risk factors such as phototherapy for the treatment of skin diseases and human papilloma virus (HPV).

Johnson *et al*<sup>[16]</sup> reported on the largest SEER series of scrotal squamous cell carcinoma with 269 patients focusing on histologic subtypes. They categorized scrotal SCC, melanoma and adnexal skin tumors as high-risk scrotal cancer and scrotal basal cell carcinoma, EMPD and sarcoma as low-risk based on median overall survival of 118 mo for the high-risk group and 166 mo for the low-risk group<sup>[16]</sup>. Survival for scrotal SCC was 115 mo (range 97-133), which was the second lowest with lowest being adnexal skin tumors with median overall survival of 114 mo<sup>[16]</sup>. Wright *et al*<sup>[2]</sup> reported statistically significant worse survival for those with SCC than for those with other histologic types. SCC comprised 35% of all scrotal tumors in whites compared to 69% in blacks<sup>[2]</sup>. Dutch researchers reported 77% 5-year survival for scrotal SCC<sup>[1]</sup>.

In early 1990s, Goldolf *et al*<sup>[23]</sup> reported that the incidence of scrotal SCC despite increase in the rates of UV exposure through sunbeds and sunlamps has not changed. However psoralens and ultraviolet A radiation (PUVA) used for the treatment of psoriasis and other inflammatory skin diseases has been implicated with the development of scrotal SCC<sup>[24,25]</sup>. In 1990 Stern reported on a prospective 12.3 year study in 892 men who had undergone ultraviolet radiation as part of their psoriasis treatment, out of which 14 developed genital tumors including 5 patients who developed 9 invasive scrotal SCC and one scrotal SCC in situ (SCCIS)<sup>[26]</sup>. They found that patients with high dose PUVA had 286 times the risk of the general population to develop invasive genital SCC, low dose PUVA had 16.3 times the risk and high dose UVB was associated with 4.6 times elevation of the risk<sup>[26]</sup>. Authors recommended genital protection for men undergoing UV radiation for treatment of skin diseases.

Increasing incidence of oropharyngeal SCC has been attributed to increasing prevalence of oral mucosal HPV<sup>[27,28]</sup>. HPV viral oncoproteins E5, E6 and E7 have an important role in carcinogenesis with p53 tumor suppressor gene and Rb oncogene being the major targets<sup>[29]</sup>. HPV infection in scrotal SCC has only been reported in a few case reports or small series<sup>[18,30-33]</sup>. Andrews *et al*<sup>[32]</sup> reported a total of 6 (42.9%) out of 14 cases were associated with HPV.

Matoso *et al*<sup>[18]</sup> reported on 29 patients with scrotal SCC and found high-risk HPV in 7 cases (24.1%) assessed by *in-situ* hybridization. These authors also reported p16 positivity and elevated Ki67 in HPV positive scrotal SCC. These cases were also more likely to display a basaloid or



**Table 1 Risk factors associated with scrotal squamous cell carcinoma**

Occupations
Chimney sweepers, tar and paraffin workers, occupations with exposure to mineral and cutting oils, printing, metal working, car and aeroplane manufacture, car mechanics, commercial printing, aluminum worker, shale oil workers, pitch workers, engineering, steel production, cavalrymen
Carcinogenic metals
Arsenic, nickel, chromium
Chronic mechanical irritation
Chronic inflammatory states
Chronic lymphedema, infective and surgical scars
Lifestyle
Poor personal hygiene, smoking
Viruses
HPV
Ionizing Radiation
Iatrogenic
Coal tar, PUVA, radiotherapy, nitrogen mustard, Fowler's solution
Immunosuppression
Acquired and inherited immunodeficiency, post transplant immunosuppression

HPV: Human papilloma virus; PUVA: Psoralens and ultraviolet A radiation.

warty morphology. They suggested p16 stain to be used for screening for HPV infection with addition of Ki67 in cases with equivocal p16. If indeed the true proportion of HPV associated scrotal SCC lies between 24%-42% as in these small series, it has important implications for preventive therapy with the availability of HPV vaccines.

Chronic mechanical irritation has been associated with scrotal SCC. Long-term rubber urinal use<sup>[34]</sup>, topical nitrogen mustard<sup>[35]</sup> and coal tar<sup>[36]</sup> have been reported to be associated with scrotal SCC. Initially scrotal SCC was thought to be uncommon among non-Caucasian ethnicities however subsequent reports in Africans, African Americans and other ethnicities including Chinese refuted this hypothesis<sup>[37,38]</sup>.

Both preceding and subsequent increased malignancy risk has been described in patients with scrotal SCC<sup>[39]</sup>. Verhoeven reported 18% of patients with scrotal malignancy developed one or more tumors after the scrotal tumor with lung cancer, skin SCC and second scrotal tumor being the most common second malignancy<sup>[1]</sup>.

## DIAGNOSIS

The most common presentation of scrotal SCC is of an erythematous scrotal nodule or plaque<sup>[40]</sup>. Ulceration and pruritus often accompany the lesion. It occurs most commonly in the left scrotum, lower and anterior areas<sup>[40,41]</sup>. It can uncommonly present as abscess or ulcer<sup>[42]</sup>. The main differential diagnoses are extramammary Paget's disease, verrucous carcinoma and bowenoid papulosis<sup>[43-46]</sup>. Pigmented scrotal SCC and scrotal SCCIS have been rarely reported<sup>[38,47]</sup>. Multiple scrotal SCCs in the same patient have often been described<sup>[26,48]</sup>. Table 1 lists the risk factors that have been associated with scrotal SCC.

**Table 2 Lowe's staging of scrotal squamous cell carcinoma**

A1	Disease localized to scrotum
A2	Locally extensive disease involving adjacent structures (penis, perineum, testis or cord, and pubic bone) by continuity but without evident metastasis
B	Superficial lymph node metastasis, resectable
C	Pelvic lymph node metastasis or any unresectable metastasis
D	Distant metastasis beyond regional nodes

## STAGING

In 1983, Lowe modified the initial staging system proposed by Ray and Whitmore and this staging system is still in use as outlined in Table 2<sup>[49]</sup>.

The American Joint committee on Cancer (AJCC), TNM classification for scrotal SCC is similar to TNM classification for SCC in other locations (with the exception of Eyelid, Vulva and Penis) and is shown in Table 3.

For staging, clinical examination including the assessment of extension and depth of the scrotal lesion and examination of inguinal lymph nodes is mandatory. Plain chest X-ray for evaluation of the lungs is recommended. MRI scan and ultrasonography can be used for assessing the depth of the lesion and evidence of involvement of underlying structures where this is suspected. For inguinal lymph node imaging CT scan can detect enlarged inguinal and pelvic lymph nodes but is unable to identify small metastatic deposits in normal sized nodes. For nodal disease ultrasound and fine needle biopsy of suspicious lymph nodes similar to penile cancer might be of diagnostic value<sup>[50]</sup>. Similarly with improvement in sensitivity and specificity profile, 18F-FDG PET/CT might have a role in further staging of inguinal lymph nodes in patients with scrotal SCC<sup>[51]</sup>. For high-risk cases sentinel lymph node biopsy at the time of excision of primary lesion similar to penile cancer has been advocated<sup>[52]</sup>.

## MANAGEMENT

Few case series have been reported since 2000 (Table 4).

### Primary tumour

Wide local excision of the lesion with a negative margin is the goal for the treatment of primary tumor. A surgical margin of 2-3 cm has been advocated by some authors<sup>[53]</sup>, however the available guidelines for the management of cutaneous SCC recommend a 4mm radial margin for small (< 2 cm) lesions with well define edges and a radial margin of 6mm for larger lesions with poor defined edges and risk of subcutaneous extension<sup>[54]</sup>. Based on evidence from penile SCC, for < T2 disease a margin of  $\geq 3$  mm is considered safe where for  $\geq$  T2 disease a surgical margin of 5-10 mm is considered appropriate<sup>[55]</sup>. Given the redundancy and laxity of scrotal skin primary scrotal closure is usually possible, but after large tumor resection primary closure might not be achievable. The defect can be reconstructed with simple closure, flap,

**Table 3 TNM staging system for squamous cell carcinoma**

Stage	Primary tumour	Regional lymph nodes	Distant metastasis
Stage 0	Tis = carcinoma in situ	N0 = no regional lymph node involvement	M0
Stage I	T1 = tumour 2 cm or less	N0	M0
Stage II	T2 = tumour > 2 cm but < 5 cm T3 = tumour > 5 cm	N0 N0	M0 M0
Stage III	T4 = Invasion of deeper extradermal structures	N0	M0
Stage IV	Any T Any T	N1 = regional lymph node spread. Any N	M0 M1 = distant metastasis.

**Table 4 Case series with epidemiology, management and outcomes of scrotal squamous cell carcinoma published after 2000**

Ref.	n	Design	Cohort characteristics	Summary
Stern <i>et al</i> <sup>[17]</sup> , 2002	17	Prospective multi-institutional cohort study	892 men first treated with PUVA	Dose-dependent increase in the risk of genital tumors in men treated with PUVA
Seabra <i>et al</i> <sup>[19]</sup> , 2007	6	Retrospective single institution	Age: 52 (31-89) Race: Ca: 2; Bl: 2; Oth: 1; Unknown: 1 Staging: LC: 4, RL: 1, DD: 1	4/6 WLE; 1/6 WLE + SLNB; 1/6 was unresectable: 1 developed LN metastasis and was treated with chemo/radiation Patient with unresectable disease and was treated with chemotherapy and subsequently died
Wright <i>et al</i> <sup>[2]</sup> , 2008	151	SEER (1973-2002)	Age: 68 <sup>2</sup> Race: Ca 117 (77.5); Bl 24 (15.9); Oth 10 (6.6)	SCC had the worse survival compared to other histological subtypes
Verhoeven <i>et al</i> <sup>[11]</sup> , 2010	53	NCR (1989-2006)	Age: 56.5 Staging: Stg 0: 1 (1.9), Stg 1: 22 (41.5), Stg 2: 18 (34), Stg 3: 2 (3.8), Stg 4: 0, Unk: 10 (18.9)	SCC had the worse survival compared to other histological subtypes: 1 yr relative survival 93% 3 yr relative survival 80% 5 yr relative survival 77%
Johnson <i>et al</i> <sup>[16]</sup> , 2013	269	SEER (1973-2006)	Age: 65.4 <sup>2</sup> ± 14.9 Race: Ca 206 (76.6%), Bl 43 (16.0%), As 12 (4.5%), Hi 18 (6.7%), Oth 8 (3.0%) Staging: LC 205 (76.2%), RL 54 (20.1%), DD 10 (3.7%)	The median OS for patients with SCC was 115 (95%CI: 97-133) mo
Matoso <i>et al</i> <sup>[18]</sup> , 2014	29	Retrospective multi-institutional	Age: 55 (30-74) Race: Ca 19 (65.5%), Bl 10 (34.5%) Follow up: 37 mo	25/29 WLE; 1/29 WLE + LND; 3/29 imiquimod post WLE: 13 (45%) with <sup>1</sup> margins required re-excision1 3/29 local recurrence: 2 WLE; 1 WLE/RT 3 /29 with lymphadenopathy lost to follow-up

<sup>1</sup>Positive; <sup>2</sup>Mean. As: Asian; Bl: Black; Ca: Caucasians; DD: Distant disease; Hi: Hispanics; LC: Local disease; NCR: Netherlands Cancer Registry; OS: Overall survival; Oth: Other; PUVA: Psoralens and ultraviolet A radiation; RL: Regional lymph node; SCC: Squamous cell carcinoma; SEER: Surveillance, Epidemiology and end results; SLNB: Sentinel lymph node biopsy; Stg: Stage; WLE: Wide local excision.

split thickness skin graft, mesh grafts or myocutaneous grafts. Hemiscrotoectomy is required for more advanced disease. Contralateral testicular transposition is an option if preservation of testis is preferable<sup>[56]</sup>.

For patients with significant co-morbidities in whom surgical management is not suitable less invasive treatments such as CO2 laser for invasive SCC and 5-fluorouracil, photodynamic therapy or imiquimod for SCCIS may be considered<sup>[57,58]</sup>. Imiquimod has also been used as adjuvant to surgery post-excision<sup>[18]</sup>. Superficial small SCC and SCCIS are also amenable to mohs micrographic surgery which offers full evaluation of the surgical margins at the time of surgery and skin-sparing surgery with good functional and aesthetic outcomes<sup>[59,60]</sup>.

### Inguinal lymph node

Morley observed early on in the 20<sup>th</sup> century that the raphe of the scrotum does not provide a physical barrier to

scrotal lymphatic drainage and the scrotum has bilateral inguinal drainage<sup>[61]</sup>. This observation forms the basis for bilateral inguinal assessment when treating patients with scrotal SCC. Data from early series suggest that similar to penile cancer only half of the patients with inguinal lymphadenopathy at the time of diagnosis, harbor metastatic disease at inguinal lymph node dissection (ILND) questioning the need for routine ILND in patients with inguinal adenopathy<sup>[62]</sup>. The authors advocated a period of follow-up (2-3 mo) after excision of primary lesion and ipsilateral ilioinguinal dissection if patient developed biopsy proven evidence of metastasis, and to defer contralateral node dissection until clinical verification of metastasis is evident.

The more contemporary algorithm for treatment of inguinal lymph node in patients with scrotal SCC has many similarities to patients with penile cancer<sup>[63]</sup>. A risk based approach to minimize morbidity associated with

ILND advocates the use of inguinal sentinel lymph node biopsy<sup>[49]</sup>, with subsequent complete ILND in cases where sentinel lymph node biopsy is positive<sup>[64]</sup>. Due to rarity of this condition data from large case series are lacking and the current recommendations are largely based on experts' opinions and extrapolation of data from series with penile SCCs.

### Locally advanced and metastatic disease

Adjuvant chemotherapy has been utilized in advanced stage and metastatic disease. Systemic chemotherapy is also indicated for inoperable scrotal SCC. Combination chemotherapy with methotrexate, bleomycin and cisplatin has been reported in inoperable or metastatic SCC of male genital tract with response rate of 72%, however median response duration was only 6 mo and only 14% achieved complete response<sup>[65]</sup>. Bleomycin has been utilized in the neoadjuvant setting. Adjuvant radiation has been shown to not change outcomes<sup>[32]</sup>.

## EMERGING THERAPIES

The era of targeted molecular and immunotherapies holds promise for management of advanced squamous cell carcinoma. Cetuximab an anti-epidermal growth factor receptor (EGFR) monoclonal antibody is an approved agent for treatment of head and neck SCC<sup>[66]</sup>. Emerging therapies for head and neck SCC include EGFR tyrosine kinase inhibitors, vascular endothelial growth factor receptor (VEGFR) inhibitors, insulin-like growth factor receptor (IGF-1R) inhibitors and inhibitors of the PI3K/AKT/mTOR pathway may have a role in the treatment of patients with scrotal SCC in future<sup>[67]</sup>. Unfortunately currently data on the efficacy of such therapies for patients with scrotal SCC is lacking.

Recently Lavens *et al*<sup>[68]</sup> showed increased EGFR expression in penile SCC. Carthon *et al*<sup>[69]</sup> evaluated EGFR targeted therapy in patients with advanced penile or scrotal cancer in a retrospective case series of twenty-four patients. Only one of twenty-four patients had scrotal SCC. This patient developed metastases to right groin with disease progression despite paclitaxel, ifosfamide, and cisplatin (TIP) chemotherapy. The addition of EGFR targeted therapy lead to reduction in tumor burden and allowed resection of residual disease. He was reported to be disease free 38 mo post EGFR therapy.

Further studies need to focus on establishing EGFR status in scrotal SCC tissue before prospective evaluation of benefits of EGFR targeted therapies. Due to low incidence of scrotal SCC, multi-institutional collaboration would be a more feasible approach. Further genomic and molecular characterization of scrotal SCC would be important in identifying key pathways and developing therapeutic targets.

## CONCLUSION

Scrotal SCC is a rare clinical entity that represents one of

the most common forms of scrotal malignancy. Although historically considered as an occupational disease, its epidemiology has changed in recent years and iatrogenic conditions (PUVA, Immunosuppression, *etc.*) and HPV infection play a significant role as associating conditions. Surgery is the cornerstone of the treatment algorithm for scrotal SCC. Excision of the primary lesion and a risk stratified approach for staging and treatment of regional lymph nodes is advisable. For patients with high-risk disease and negative clinical lymph nodes, sentinel lymph node biopsy can mitigate the morbidities of unwarranted ILND. For locally advanced and metastatic disease palliative chemotherapy is advocated. Future endeavors with focus on targeted therapies might hold promise for management of advanced squamous cell carcinoma. Given the rarity of this condition, multi-institutional trials in conjunction with trials for the treatment of penile SCC are likely to provide us with further knowledge in this field.

## REFERENCES

- 1 Verhoeven RH, Louwman WJ, Koldewijn EL, Demeyere TB, Coebergh JW. Scrotal cancer: incidence, survival and second primary tumours in the Netherlands since 1989. *Br J Cancer* 2010; **103**: 1462-1466 [PMID: 20877361 DOI: 10.1038/sj.bjc.6605914]
- 2 Wright JL, Morgan TM, Lin DW. Primary scrotal cancer: disease characteristics and increasing incidence. *Urology* 2008; **72**: 1139-1143 [PMID: 18799208 DOI: 10.1016/j.urology.2008.06.043]
- 3 Graves RC, Flo S. Carcinoma of the scrotum. *J Urol* 1940; **43**: 309-332
- 4 Waterhouse JA. Subsequent malignancy in environmental scrotal cancers. *Proc R Soc Med* 1977; **70**: 111-112 [PMID: 558614]
- 5 Kipling MD, Waldron HA. Percivall Pott and cancer scroti. *Br J Ind Med* 1975; **32**: 244-246 [PMID: 1098690]
- 6 Doll R. Part III: 7th Walter Hubert lecture. Pott and the prospects for prevention. *Br J Cancer* 1975; **32**: 263-272 [PMID: 764848 DOI: 10.1038/bjc.1975.212]
- 7 Jackson R. Early clinical descriptions of skin cancer. *Can Med Assoc J* 1973; **109**: 906-908 [PMID: 4584333]
- 8 Hodgson GA, Whiteley HJ. Personal susceptibility to pitch. *Br J Ind Med* 1970; **27**: 160-166 [PMID: 4246788]
- 9 Lee WR, McCann JK. Mule spinners' cancer and the wool industry. *Br J Ind Med* 1967; **24**: 148-151 [PMID: 6071507]
- 10 Kipling MD. Oil and cancer. *Ann R Coll Surg Engl* 1974; **55**: 71-79 [PMID: 4858528]
- 11 Fay HT. Risk factors in scrotal epithelioma. *J R Soc Med* 1978; **71**: 741-747 [PMID: 712728]
- 12 Henry SA. Occupational cutaneous cancer attributable to certain chemicals in industry. *Br Med Bull* 1947; **4**: 389-401 [PMID: 20240897]
- 13 Angulo JC, López JL, Flores N. Squamous cell carcinoma of the scrotum in an aluminium worker. *Postgrad Med J* 1993; **69**: 960-961 [PMID: 8121880 DOI: 10.1136/pgmj.69.818.960-a]
- 14 Doll R, Vessey MP, Beasley RW, Buckley AR, Fear EC, Fisher RE, Gammon EJ, Gunn W, Hughes GO, Lee K, Norman-Smith B. Mortality of gasworkers - final report of a prospective study. *Br J Ind Med* 1972; **29**: 394-406 [PMID: 15625750]
- 15 Cruickshank CN, Squire JR. Skin cancer in the engineering industry from the use of mineral oil. *Br J Ind Med* 1950; **7**: 1-11 [PMID: 15403146]
- 16 Johnson TV, Hsiao W, Delman KA, Canter DJ, Master VA.

- Scrotal cancer survival is influenced by histology: a SEER study. *World J Urol* 2013; **31**: 585-590 [PMID: 22418823 DOI: 10.1007/s00345-012-0834-0]
- 17 **Stern RS**, Bagheri S, Nichols K. The persistent risk of genital tumors among men treated with psoralen plus ultraviolet A (PUVA) for psoriasis. *J Am Acad Dermatol* 2002; **47**: 33-39 [PMID: 12077578]
  - 18 **Matoso A**, Ross HM, Chen S, Allbritton J, Epstein JL. Squamous neoplasia of the scrotum: a series of 29 cases. *Am J Surg Pathol* 2014; **38**: 973-981 [PMID: 24618607]
  - 19 **Seabra D**, Fava G, Faria E, Sacheto T, Hidalgo G. Scrotal neoplasia: would truck drivers be at greater risk? *Int Braz J Urol* 2007; **33**: 515-519; discussion 520 [PMID: 17767756]
  - 20 **Kickham CJ**, Dufresne M. An assessment of carcinoma of the scrotum. *J Urol* 1967; **98**: 108-110 [PMID: 6067877]
  - 21 **Parys BT**, Hutton JL. Fifteen-year experience of carcinoma of the scrotum. *Br J Urol* 1991; **68**: 414-417 [PMID: 1933164 DOI: 10.1111/j.1464-410X.1991.tb15363.x]
  - 22 **Roush GC**, Schymura MJ, Flannery JT. Secular and age distribution of scrotal cancer in Connecticut and a review of United States literature. *Cancer* 1984; **54**: 596-601 [PMID: 6733690 DOI: 10.1002/1097-0142(19840801)54:3<596::AID-CNCR2820540335>3.0.CO;2-J]
  - 23 **Goldoft MJ**, Weiss NS. Incidence of male genital skin tumors: lack of increase in the United States. *Cancer Causes Control* 1992; **3**: 91-93 [PMID: 1536920]
  - 24 **Loughlin KR**. Psoriasis: association with 2 rare cutaneous urological malignancies. *J Urol* 1997; **157**: 622-623 [PMID: 8996374 DOI: 10.1016/S0022-5347(01)65222-4]
  - 25 **Taniguchi S**, Furukawa M, Kutsuna H, Sowa J, Ishii M. Squamous cell carcinoma of the scrotum. *Dermatology* 1996; **193**: 253-254 [PMID: 8944352 DOI: 10.1159/000246258]
  - 26 **Stern RS**. Genital tumors among men with psoriasis exposed to psoralens and ultraviolet A radiation (PUVA) and ultraviolet B radiation. The Photochemotherapy Follow-up Study. *N Engl J Med* 1990; **322**: 1093-1097 [PMID: 2320078 DOI: 10.1056/NEJM199004193221601]
  - 27 **Shaw R**, Robinson M. The increasing clinical relevance of human papillomavirus type 16 (HPV-16) infection in oropharyngeal cancer. *Br J Oral Maxillofac Surg* 2011; **49**: 423-429 [PMID: 20727631 DOI: 10.1016/j.bjoms.2010.06.023]
  - 28 **Panwar A**, Batra R, Lydiatt WM, Ganti AK. Human papilloma virus positive oropharyngeal squamous cell carcinoma: a growing epidemic. *Cancer Treat Rev* 2014; **40**: 215-219 [PMID: 24080155 DOI: 10.1016/j.ctrv.2013.09.006]
  - 29 **Mighty KK**, Laimins LA. The role of human papillomaviruses in oncogenesis. *Recent Results Cancer Res* 2014; **193**: 135-148 [PMID: 24008297 DOI: 10.1007/978-3-642-38965-8\_8]
  - 30 **Orihuela E**, Tyring SK, Pow-Sang M, Dozier S, Cirelli R, Arany I, Rady P, Sanchez R. Development of human papillomavirus type 16 associated squamous cell carcinoma of the scrotum in a patient with Darier's disease treated with systemic isotretinoin. *J Urol* 1995; **153**: 1940-1943 [PMID: 7752363 DOI: 10.1097/00005392-199506000-00064]
  - 31 **Güran S**, Pak I. Cumulation of TP53 mutations and p16INK4A/p15INK4B homozygous deletions in human papilloma virus type 16 positive scrotal cancer. *Cancer Genet Cytogenet* 1999; **109**: 108-113 [PMID: 10087941 DOI: 10.1016/S0165-4608(98)00155-1]
  - 32 **Andrews PE**, Farrow GM, Oesterling JE. Squamous cell carcinoma of the scrotum: long-term followup of 14 patients. *J Urol* 1991; **146**: 1299-1304 [PMID: 1942281]
  - 33 **Burner GC**, True LD, Krieger JN. Squamous cell carcinoma of the scrotum associated with human papillomaviruses. *J Urol* 1993; **149**: 374-377 [PMID: 8381191]
  - 34 **Grundy D**, Jones AC, Powley PH. Carcinoma of the scrotum associated with rubber urinals. Case report. *Paraplegia* 1993; **31**: 616-617 [PMID: 8247605 DOI: 10.1038/sc.1993.98]
  - 35 **Lee LA**, Fritz KA, Golitz L, Fritz TJ, Weston WL. Second cutaneous malignancies in patients with mycosis fungoides treated with topical nitrogen mustard. *J Am Acad Dermatol* 1982; **7**: 590-598 [PMID: 7142467 DOI: 10.1016/S0190-9622(82)70138-0]
  - 36 **Moy LS**, Chalet M, Lowe NJ. Scrotal squamous cell carcinoma in a psoriatic patient treated with coal tar. *J Am Acad Dermatol* 1986; **14**: 518-519 [PMID: 3958269 DOI: 10.1016/S0190-9622(86)80436-4]
  - 37 **Oluwasanmi JO**, Williams AO, Alli AF. Superficial cancer in Nigeria. *Br J Cancer* 1969; **23**: 714-728 [PMID: 5367332 DOI: 10.1038/bjc.1969.88]
  - 38 **Wagner RF**, Grande DJ. Solitary pigmented Bowen's disease of the scrotum. *J Dermatol Surg Oncol* 1986; **12**: 1114-1115 [PMID: 3760318 DOI: 10.1111/j.1524-4725.1986.tb02091.x]
  - 39 **Gerber WL**. Scrotal malignancies: the University of Iowa experience and a review of the literature. *Urology* 1985; **26**: 337-342 [PMID: 2996197 DOI: 10.1016/0090-4295(85)90179-7]
  - 40 **McDonald MW**. Carcinoma of scrotum. *Urology* 1982; **19**: 269-274 [PMID: 7064253 DOI: 10.1016/0090-4295(82)90497-6]
  - 41 **Southam AH**, Wilson SR. Cancer of the scrotum: The Etiology, Clinical Features, and Treatment of the Disease. *Br Med J* 1922; **2**: 971-970.1 [PMID: 20770922]
  - 42 **Huen KH**, Nourparvar P, Decaro JJ, Walsh MD, Issa MM, Ritenour CW. Scrotal abscess as initial presentation of squamous cell carcinoma. *Case Rep Urol* 2013; **2013**: 807346 [PMID: 24102031]
  - 43 **Du X**, Yin X, Zhou N, Zhang G, Shi H, Cao S. Extramammary Paget's disease mimicking acantholytic squamous cell carcinoma in situ: a case report. *J Cutan Pathol* 2010; **37**: 683-686 [PMID: 19615013 DOI: 10.1111/j.1600-0560.2009.01336.x]
  - 44 **Miyakawa T**, Togawa Y, Matushima H, Nakamura H, Kamada N, Momota Y, Tochigi N, Nikaido T, Shinkai H, Utani A. Squamous metaplasia of Paget's disease. *Clin Exp Dermatol* 2004; **29**: 71-73 [PMID: 14723727 DOI: 10.1111/j.1365-2230.2004.01425.x]
  - 45 **Criton S**, Aravindan KP. Bowenoid papulosis turning to squamous cell carcinoma. *Indian J Dermatol Venereol Leprol* 1998; **64**: 37-39 [PMID: 20921709]
  - 46 **Quinn AM**, Sienko A, Basrawala Z, Campbell SC. Extramammary Paget disease of the scrotum with features of Bowen disease. *Arch Pathol Lab Med* 2004; **128**: 84-86 [PMID: 14692806]
  - 47 **Matsumoto M**, Sonobe H, Takeuchi T, Furihata M, Iwata J, Ikeda M, Ohtsuki Y. Pigmented squamous cell carcinoma of the scrotum associated with a lentigo. *Br J Dermatol* 1999; **141**: 132-136 [PMID: 10417529 DOI: 10.1046/j.1365-2133.1999.02934.x]
  - 48 **Yamaoka H**, Ikoma N, Kato M, Akasaka E, Tamiya S, Matsuyama T, Ozawa A, Fukunaga Y. Multiple Bowen's disease in a patient with a history of possible arsenic exposure: a case report. *Tokai J Exp Clin Med* 2011; **36**: 53-57 [PMID: 21769774]
  - 49 **Lowe FC**. Squamous cell carcinoma of the scrotum. *J Urol* 1983; **130**: 423-427 [PMID: 6350613]
  - 50 **Djajadiningrat RS**, Teertstra HJ, van Werkhoven E, van Boven HH, Horenblas S. Ultrasound examination and fine needle aspiration cytology-useful for followup of the regional nodes in penile cancer? *J Urol* 2014; **191**: 652-655 [PMID: 23994372 DOI: 10.1016/j.juro.2013.08.046]
  - 51 **Rosevear HM**, Williams H, Collins M, Lightfoot AJ, Coleman T, Brown JA. Utility of <sup>18</sup>F-FDG PET/CT in identifying penile squamous cell carcinoma metastatic lymph nodes. *Urol Oncol* 2012; **30**: 723-726 [PMID: 21396850 DOI: 10.1016/j.urolonc.2010.09.015]
  - 52 **Greene TD**, Abrahams HM, Moran ME. Dynamic lymphoscintigraphy for staging scrotal carcinoma. *J Urol* 2001; **165**: 536-537 [PMID: 11176424 DOI: 10.1097/00005392-200102000-00054]
  - 53 **Azike JE**. A review of the history, epidemiology and treatment of squamous cell carcinoma of the scrotum. *Rare Tumors* 2009; **1**: e17 [PMID: 21139888]
  - 54 **Motley R**, Kersey P, Lawrence C; British Association of Der-



- matologists; British Association of Plastic Surgeons. Multi-professional guidelines for the management of the patient with primary cutaneous squamous cell carcinoma. *Br J Plast Surg* 2003; **56**: 85-91 [PMID: 12791348]
- 55 **Minhas S**, Kayes O, Hegarty P, Kumar P, Freeman A, Ralph D. What surgical resection margins are required to achieve oncological control in men with primary penile cancer? *BJU Int* 2005; **96**: 1040-1043 [PMID: 16225525 DOI: 10.1111/j.1464-410X.2005.05769.x]
- 56 **Arango O**, Bielsa O, Lorente JA, De Leon E, Mas AG. Hemiscrotoectomy with contralateral testicular transposition for scrotal cancer. *J Urol* 2002; **168**: 1406-1407 [PMID: 12352404 DOI: 10.1097/00005392-200210010-00024]
- 57 **Rosemberg SK**. Lasers and squamous cell carcinoma of external genitalia. *Urology* 1986; **27**: 430-433 [PMID: 3705277 DOI: 10.1016/0090-4295(86)90408-5]
- 58 **Bath-Hextall FJ**, Matin RN, Wilkinson D, Leonardi-Bee J. Interventions for cutaneous Bowen's disease. *Cochrane Database Syst Rev* 2013; **6**: CD007281 [PMID: 23794286]
- 59 **Wells MJ**, Taylor RS. Mohs micrographic surgery for penoscrotal malignancy. *Urol Clin North Am* 2010; **37**: 403-409 [PMID: 20674695 DOI: 10.1016/j.ucl.2010.04.012]
- 60 **Brown MD**, Zachary CB, Grekin RC, Swanson NA. Genital tumors: their management by micrographic surgery. *J Am Acad Dermatol* 1988; **18**: 115-122 [PMID: 3346395 DOI: 10.1016/S0190-9622(88)70017-1]
- 61 **Morely J**. The lymphatics of the scrotum. *Lancet* 1911; **1**: 1545-1547 [DOI: 10.1016/S0140-6736(00)40413-7]
- 62 **Ray B**, Whitmore WF. Experience with carcinoma of the scrotum. *J Urol* 1977; **117**: 741-745 [PMID: 559784]
- 63 **Pizzocaro G**, Algaba F, Horenblas S, Solsona E, Tana S, Van Der Poel H, Watkin NA. EAU penile cancer guidelines 2009. *Eur Urol* 2010; **57**: 1002-1012 [PMID: 20163910 DOI: 10.1016/j.eururo.2010.01.039]
- 64 **Lowe FC**. Squamous-cell carcinoma of the scrotum. *Urol Clin North Am* 1992; **19**: 397-405 [PMID: 1574830]
- 65 **Dexeus FH**, Logothetis CJ, Sella A, Amato R, Kilbourn R, Fitz K, Striegel A. Combination chemotherapy with methotrexate, bleomycin and cisplatin for advanced squamous cell carcinoma of the male genital tract. *J Urol* 1991; **146**: 1284-1287 [PMID: 1719241]
- 66 **Cohen RB**. Current challenges and clinical investigations of epidermal growth factor receptor (EGFR)- and ErbB family-targeted agents in the treatment of head and neck squamous cell carcinoma (HNSCC). *Cancer Treat Rev* 2014; **40**: 567-577 [PMID: 24216225 DOI: 10.1016/j.ctrv.2013.10.002]
- 67 **Dorsey K**, Agulnik M. Promising new molecular targeted therapies in head and neck cancer. *Drugs* 2013; **73**: 315-325 [PMID: 23440867 DOI: 10.1007/s40265-013-0025-3]
- 68 **Lavens N**, Gupta R, Wood LA. EGFR overexpression in squamous cell carcinoma of the penis. *Curr Oncol* 2010; **17**: 4-6 [PMID: 20179797]
- 69 **Carthon BC**, Ng CS, Pettaway CA, Pagliaro LC. Epidermal growth factor receptor-targeted therapy in locally advanced or metastatic squamous cell carcinoma of the penis. *BJU Int* 2014; **113**: 871-877 [PMID: 24053151 DOI: 10.1111/bju.12450]

P- Reviewer: Fernandez-Pello S S- Editor: Ji FF L- Editor: A  
E- Editor: Lu YJ



## Olfactory dysfunction in dementia

Jorge Alves, Agavni Petrosyan, Rosana Magalhães

Jorge Alves, Rosana Magalhães, Cognitive Rehabilitation Center, 4710-228 Braga, Portugal

Agavni Petrosyan, Department of Cognitive Sciences, University of California at Irvine, Irvine, CA 92717, United States

**Author contributions:** Alves J conceptualized the present work; Alves J and Magalhães R performed article search and data acquisition, and drafted the initial version of the manuscript; Petrosyan A contributed to data acquisition and further revisions of the paper; all authors read and approved the final version of the manuscript before submission.

**Correspondence to:** Jorge Alves, PhD, Cognitive Rehabilitation Center, Av. Central, 33, 3, S4, 4710-228 Braga, Portugal. [jorge.alves@neuropsicologia.pt](mailto:jorge.alves@neuropsicologia.pt)

Telephone: +351-25-3095648

Received: June 6, 2014

Revised: July 31, 2014

Accepted: September 6, 2014

Published online: November 16, 2014

**Key words:** Dementia; Aging; Olfaction; Olfactory dysfunction

**Core tip:** Olfactory dysfunction is often present as a symptom of a neurodegenerative disease. The potential clinical value (prodromal/pre-diagnostic, diagnostic, intervention target) of olfactory dysfunction still remains to be fully established. Standardized and easy to use tools are available and can be implemented to improve the definite differential profiles, through its widespread integration in clinical practice and research.

Alves J, Petrosyan A, Magalhães R. Olfactory dysfunction in dementia. *World J Clin Cases* 2014; 2(11): 661-667 Available from: URL: <http://www.wjgnet.com/2307-8960/full/v2/i11/661.htm> DOI: <http://dx.doi.org/10.12998/wjcc.v2.i11.661>

### Abstract

The natural aging process brings about some inevitable consequences, such as olfactory dysfunction, which is also frequently linked to numerous neurodegenerative disorders. Many age-related dementia, such as Alzheimer's disease, Vascular dementia, Parkinson's disease, and Frontotemporal Dementia often display olfactory dysfunction. Despite the overwhelming evidence of above mentioned facts, the symptomatic relevance and potential clinical and pre-clinical value of olfactory dysfunction remains overlooked by many clinicians and public alike. Olfactory dysfunction has strong practical implications on daily activities and, although not as prominent as in other mammals, olfaction is still an evolutionarily relevant sense involved in human survival (*e.g.*, smelling gas; bad food). In this work, we provide a brief review of current research related to the olfactory dysfunction profiles in different types of dementia. Additionally, we present a compilation of accessible, easy to use olfaction assessment tools; and highlight future directions in terms of improving clinical diagnosis in patient care and research.

© 2014 Baishideng Publishing Group Inc. All rights reserved.

### INTRODUCTION

Although olfaction is a topic of scientific interest for both public and many professionals<sup>[1]</sup>, awareness concerning olfactory dysfunction, both in healthy aging and dementia, remains limited even when considering the widespread prevalence of age-related olfactory decline. For example, half of the elderly population between 65 and 80 years of age have evident olfactory dysfunction<sup>[2-4]</sup>.

Moreover, olfactory dysfunction has been acknowledged as a symptom present in dementias, such as Alzheimer's disease, vascular dementia, Parkinson and Frontotemporal Dementia (FTD)<sup>[5]</sup>.

Indeed, olfactory dysfunction has a considerable prevalence in dementia, with estimated numbers as high as 100% in Alzheimer's disease (AD)<sup>[6]</sup>, 90% in Parkinson's disease (PD)<sup>[7]</sup>; 96% in the frontal variant of FTD<sup>[8]</sup> and 15% in Vascular dementia (VD)<sup>[6]</sup>.

In the next sections we will briefly review the main types of dementia in which olfactory dysfunction is present.

## RESEARCH

The present study is a selective narrative review. The selected articles consisted of literature/articles previously known by the authors, complemented with a search on PubMed/MEDLINE focusing on olfactory dysfunction with the following search terms: olfaction (and related expressions - olfactory), Alzheimer's disease, vascular dementia, Parkinson's disease, frontotemporal dementia, Lewy body dementia, and dysfunction/impairment/deficit. Relevant articles were selected through abstract inspection. Both, reviews and clinical studies were included.

## OLFACTION IN HEALTHY AGING

### *Olfactory loss associated with normal aging*

Olfactory dysfunction has a considerable prevalence with recent estimates pointing to 3.8% in adults between 21 and 84 years of age, increasing prevalence with age (from 0.6% in those < 35 years to 13.9% among those ≥ 65 years), with higher prevalence in men<sup>[9]</sup>. Factors involved in age-related olfactory dysfunction include changes in non-olfactory elements of the nose (*e.g.*, airflow patterns and mucous composition), olfactory neuroepithelium, olfactory bulb, central brain regions involved in olfactory processing, and neurochemical changes in the brain (for a detailed review see Doty and Kamath<sup>[10]</sup>).

Measured with University of Pennsylvania Smell Identification Test UPSIT, Djordjevic<sup>[11]</sup> and Morgan<sup>[12]</sup> refer values of approximately 33-35 as a normal olfactory performance. Doty *et al.*<sup>[2]</sup> also provide a prototypical progression of olfactory decline during normal aging. They report median UPSIT values of normal olfactory performance around 37, with olfactory decline starting in the 60 s, reaching around 34 in the 70 s, and 26 in the 80 s. Lower values than those of the observed normative scores would imply a loss of olfactory abilities (for further details please see Doty *et al.*<sup>[2]</sup> or Doty and Kamath<sup>[10]</sup>). For a systematic review on normative and pathological values of olfactory performance in dementia please refer to Sun *et al.*<sup>[13]</sup>.

Besides the normal age-related olfactory decrements, sensory and central processing impairments in the components of olfaction, are observed in number of neurodegenerative conditions<sup>[14]</sup>. These impairments might influence appetite in people with dementia and lead to dietary restrictions with negative implications on nutrition and overall health<sup>[15]</sup>.

It is important to note, however, that the performance in olfactory assessment tasks might also be influenced by the assessment method as well as other brain functions such as memory. For example, Larson *et al.*<sup>[16]</sup> suggest that age-related difficulties in the activation of odor knowledge (*i.e.*, odor names) might contribute to the observed age differences.

## OLFACTION IN DEMENTIA

### *Alzheimer's disease*

Alzheimer's disease is characterized by neuropathological

changes, such as neurofibrillary tangles, neuritic plaques and atrophy, leading to progressively marked deficits in memory (amnesic presentation) and/or other domains such as language and visuospatial capacities (non-amnesic presentations)<sup>[17]</sup>. Olfactory bulbs are considered to be involved from the early stages of the disease and related to the neuropathological changes<sup>[18-20]</sup>. Indeed, there is evidence for considerable olfactory tau pathology in post-mortem confirmed AD, with tau pathology correlating with dementia severity<sup>[21]</sup>. Moreover, similar pathologic changes have been reported in the brain and olfactory mucosa of AD patients<sup>[14]</sup>.

As expected due to the aforementioned lesional pattern, olfactory dysfunction, namely odor identification, is also a widely acknowledged, feature of Alzheimer's<sup>[22]</sup> with patients showing overt deficits in odor identification<sup>[22,23]</sup>.

Olfactory dysfunction may even be present during the amnesic mild cognitive impairment (MCI) stage of Alzheimer's disease, mainly as an odor discrimination and identification difficulty and less of an odor detection deficit<sup>[24]</sup>. While cognitive and sensory characteristics associated with visuospatial, language and immediate memory skills are interconnected with olfactory discrimination, olfactory identification in itself is more related to delayed memory processing<sup>[24]</sup>.

Although evidence is still limited, differential profiles between AD and other dementias have been observed which are evidently due to the underlying neurological decline characteristic of each dementia type. For example, smell identification seems to be more impaired in AD than in VD<sup>[23]</sup>, however Gray *et al.*<sup>[25]</sup> found impairment similarities. In the same way, AD and PD patients show equivalent levels of hyposmia (assessed through odor identification)<sup>[26]</sup>. On the other hand, there is evidence of more olfactory impairment in mild Dementia with Lewy Bodies (DLB) than in MCI or AD<sup>[27]</sup>.

However, whether the available olfactory screening tests are well adjusted and specifically tailored for each of these dementias is still unclear.

### *Vascular dementia*

Vascular dementia (VD) is characterized by cognitive decline, typically in a stepwise manner, compatible with dementia related to cerebrovascular disease<sup>[28]</sup>.

VD is considered the second main cause of dementia<sup>[29]</sup> and is the topic of a considerable amount of research concerning its characterization and etiopathology. Research on olfactory dysfunction in VD is comparatively scarce. However, it has been found that VD patients score below normative performance in olfactory tests<sup>[25]</sup>. Nonetheless, when comparing VD and AD, there are mixed findings with Gray *et al.*<sup>[25]</sup> reporting a similar degree of olfactory impairment between AD and VD while Duff *et al.*<sup>[6]</sup> state lower performance in AD patients.

Interestingly, preliminary data, on people with history of stroke, identified them having within normal or slightly below normal olfactory performance<sup>[30]</sup>.

From the aforementioned data it seems plausible to

hypothesize that the presence or absence, the range/extent and type of olfactory deficit might depend on the location and extension of vascular pathology.

### **Parkinson disease and other synucleinopathies**

Parkinson's disease belongs to a group of neurological conditions named movement disorders, which occur due to a loss of nigrostriatal dopaminergic neurons in certain circuits of the brain<sup>[31]</sup>.

Diagnosis usually occurs after the fifth decade of life typically with a slow progression of disease which is based on neurological examination and the patient's clinical history<sup>[31]</sup>. Feature symptoms include tremor, trembling of hands, legs, jaw, and face; stiffness of the limbs and trunk; bradykinesia of movements; and postural instability, resulting in impaired balance and coordination. As expected, these symptoms interfere with several daily living activities<sup>[31]</sup>.

Researchers have recently directed their attention towards olfactory dysfunction in PD, as it is a prominent symptom, occurring in about 80%-90% of PD patients<sup>[32]</sup>. Moreover, olfactory dysfunction is usually prodromal to motor symptoms by several years<sup>[33,34]</sup>. Olfactory dysfunction also occurs alongside non-motor symptoms, such as in autonomic<sup>[35]</sup> (cardiovascular changes) and REM-sleep Behavior Disorders<sup>[36]</sup> (RBD), both during and at the pre-motor phases of PD.

Therefore, authors argue that deficits in the sense of smell may be used to assess the risk of developing PD in apparent asymptomatic patients<sup>[37]</sup>.

In a population-based prospective study (longitudinal Honolulu-Asia Aging Study; HAAS), authors have demonstrated that odor identification deficits may precede the development of clinical PD in men by at least 4 years<sup>[34]</sup>.

The fact that olfactory deficits appear even before confirmed PD diagnosis<sup>[38]</sup>, while motor signs appear afterwards and gradually worsen, might explain the lack of relationship found between olfactory deficits and PD severity or disease duration<sup>[39]</sup>.

Unsurprisingly, olfactory testing is quite sensitive and specific in distinguishing PD from other movement disorders<sup>[33,37,40]</sup>. In particular, considering that hyposmia is relatively rare in atypical Parkinson syndromes or in essential tremor, olfactory dysfunction presents added value due to its discriminatory power to differentiate neurodegenerative diseases<sup>[33]</sup>. Several tests are currently being used<sup>[10,41]</sup>, some of them purposely adapted and implemented for assisting in Parkinson's Disease diagnosis, presenting appropriate sensitivity and specificity indices<sup>[42]</sup>.

Decreased odor identification in PD patients has been associated with older age, greater smoking habits, more coffee intake and lower performance in cognition tests<sup>[34]</sup>. Additionally, hyposmia was also found to be predictive of dementia installation in PD patients within 3 years of assessment<sup>[43]</sup>. Furthermore, patients with severe hyposmia at baseline, display more prominent cognitive decline in the follow-up assessment.

More recently, Lee *et al*<sup>[44]</sup> divided non-demented PD participants into three groups according to their performance in an olfactory test (Cross-Cultural Smell Identification; CCSI<sup>[45]</sup>): PD-H (high score), PD-M (middle score) and PD-L (low score group). They further noted that the clinical dementia rating score was lower in the PD-H patients than in the PD-M or PD-L patients<sup>[44]</sup>. Moreover, the PD-L patients performance in the verbal memory tests was noted to be worse than that of the PD-H patients<sup>[44]</sup>, which is in consonance with previous findings<sup>[34,43]</sup>.

In terms of the neuropathological findings in olfactory bulb, depositions of  $\alpha$ -Syn have been found in Lewy Body Diseases<sup>[33]</sup>, with additional lesions extending to the olfactory epithelium as well as to the olfactory cortex and other olfactory-related structures<sup>[33,46]</sup>. Indeed, MRI studies confirmed that PD patients present greater Gray Matter (GM) loss in brain regions subserving primary and secondary olfactory processing, namely, bilateral piriform cortex (PC) and bilateral orbitofrontal cortex (OFC), when compared to controls (*e.g.*, Lee *et al*<sup>[47]</sup>). Additionally, right PC and left OFC volumes were correlated with the performance in olfactory tests (reduced performance correlated with lower GM volumes)<sup>[47]</sup>.

These results foster the hypothesis that olfactory dysfunction is related with extranigral cortical involvement, which is consistent with the fact that the olfactory function does not improve with dopaminergic treatments<sup>[41]</sup>. Hence, other neurotransmitter systems are being considered to be involved in olfactory dysfunction (*e.g.*, cholinergic<sup>[48,49]</sup>).

Importantly, differences between studies may also be explained by the tested components such as odor threshold, discrimination and identification. Each of these olfactory components can be related to atrophy in different brain structures<sup>[47]</sup> therefore possibly contributing to the diverse smell deficits.

Finally, Takeda *et al*<sup>[41]</sup> highlight some considerations: there is actually no established standard odorants for the olfactory testing; environmental conditions such as humidity may interfere in olfactory stimulation; and sniffing (the act by one inhales air to be able to smell) may be impaired in PD patients due to motor deficits<sup>[41]</sup>.

Since olfactory dysfunction is an evident feature of PD, which can be detected in early stages of the disease, to improve diagnostic precision, stronger efforts should be made to include olfactory assessment in the routine neurological examinations<sup>[41]</sup>.

### **Frontotemporal dementia**

Frontotemporal dementia is a clinical syndrome associated with shrinking/degeneration of the frontal and anterior temporal lobes of the brain<sup>[50]</sup>, sometimes called frontotemporal lobar degeneration<sup>[51]</sup>. FTD was formerly known as Pick's disease<sup>[50]</sup>, however, currently, FTD groups several neurological designations such as Pick's disease, primary progressive aphasia and semantic dementia<sup>[50,52]</sup>.

FTD accounts for up to 10% to 20% of presenile



dementia cases and its onset tends to occur between the ages of 45 and 65 years<sup>[52,53]</sup>. The main feature in FTD is a marked change in the behavior, usually characterized by either impulsive, disinhibited or apathetic behaviors; accompanied by inappropriate social interaction, lack of social skills, lack of empathy, distractibility and compulsive behavior. Regarding language disturbances, patients may present difficulties in producing or understanding speech<sup>[50,52]</sup>.

Concerning other cognitive abilities, such as spatial skills and memory, they tend to remain intact. For a careful characterization of this clinical syndrome, core features and cognitive changes in FTD, refer to the works of Snowden *et al.*<sup>[52]</sup> and Neary *et al.*<sup>[51]</sup>.

Regarding its neuropathology, FTD is mostly characterized by cortical loss of pyramidal cells, and spongiform degeneration. In fewer cases, neuron swellings or inclusions are observed, that is, accumulation of tau proteins in neurons, visible as silver-staining aggregations (Pick bodies)<sup>[50,52]</sup>.

Despite being less frequent than in Parkinson's Disease, olfactory dysfunction has been reported in FTD as well<sup>[54]</sup>. Considering the neuroanatomy of the olfactory system (involving parahippocampal gyrus and entorhinal area) and the existing compromise of the temporal cortex in FTD, olfactory dysfunction should be expected as well. One of the first studies comparing several dementia types, concluded that, when compared with AD and Semantic Dementia (SD) FTD patients do present olfactory impairment but at a lesser degree<sup>[54]</sup>. Namely, FTD patients demonstrate preserved odor discrimination abilities, whereas impairment surfaced in tasks of odor naming and odor-picture matching<sup>[54]</sup>. Additionally, the authors found a correlation between odor identification performance and measures of executive functioning<sup>[54]</sup>.

In the same line of findings, McLaughlin and Westervelt<sup>[55]</sup> compared groups of FTD, AD patients and controls in an odor identification test (BSIT). The authors found that the FTD performed significantly worse than the controls, but very similar to the AD group<sup>[55]</sup>. Additionally, a tendency towards correlation between FTD severity and olfactory identification ability was observed.

In another study<sup>[8]</sup> patients with the frontal variant of FTD presented olfactory recognition deficits. The authors highlight the need to assess olfactory function in FTD patients more often, since initially these patients are commonly misdiagnosed as having depressive disorder. Considering the fact that depressive patients are expected to have better olfactory function, olfactory testing could be used to distinguish depression in elderly from a FTD diagnosis<sup>[8]</sup>.

When comparing variants of FTD in an odor identification test, Omar *et al.*<sup>[56]</sup> did not find differences between the subgroups, even when compared in a flavor identification task. Interestingly, these authors also found that the odor identification performance paralleled the flavor identification and both performances were correlated in

clinical groups<sup>[56]</sup>.

## CONCLUSION

### General conclusions and future directions

In the present review, in hopes of providing a primer of the topic, we summarized the main findings regarding olfactory dysfunction in aging and the main types of dementia (please refer to Table 1 for a summary of main findings in different dementias).

While there is still no solid olfactory profile for each type of dementia, olfactory assessment might prove to be a valuable tool in assisting diagnosis, as a biomarker for disease progression and a surrogate marker for disease-modifying drug efficacy<sup>[33,57]</sup>. Easy to use tests/assessments (Table 2 for an exemplifying list of standardized tests) are available and can be easily implemented from a practice-research integrative perspective, leading into an improved evidence-based profiling. However, a clear definition of the evaluated component (identification, recognition, retrieval, choice) must be regarded carefully since the discrepancies in the results reported throughout this work might have the contribution of confounding variables such as memory and naming difficulties.

Regarding these procedural issues, computerized odor systems might provide a more accurate disposal of odorants and determination of potential differential olfactory thresholds in early stages of different types of dementia. Although, functional neuroimaging studies, concerning the present topic, are scarce, if implemented more often they may assist in the clarification of the existence of different *in vivo* neural signatures related to differential olfactory impairments (*e.g.*, naming identification, confrontation identification, retrieval).

In the context of neuroimaging, despite the costs associated with sophisticated olfactometer apparatus, simpler alternatives, such as odorant saturated cotton can be implemented as well (although with less reliability). Also, semi-automatic olfactometers/odor dispensers for imaging setting can be built on a rather reasonable budget<sup>[58]</sup>.

Although olfactory symptoms are a feature of dementia, which is regarded as such with a relative consensus, diagnostic guidelines seldom highlight its role or presence as a supportive feature. In this regard, screening pocket olfactory tests could be recommended in healthcare and diagnostic guidelines as a supportive test for improving differential diagnosis through fast data collection and prior screening for the purposes of a more extensive olfactory assessment. Although one may argue that these tests are not exempt of costs, there are alternatives, such as the Smell Diskettes, which can be reused for several months.

The use of olfactory baseline measurements, similar to the neuropsychological baseline assessments used in some countries, should be implemented worldwide. However, as in neuropsychological assessments, baseline olfactory results are seldom available.

As noted recently, olfactory assessments could also be included in other routine sensory assessments, such as in

**Table 1 Table of main findings (comparing findings in different dementias)**

Type of dementia	Profile/main findings	Differences between dementias (extent/degree/severity of impairment)
Alzheimer	Odor identification deficit, is a widely acknowledged feature of Alzheimer's	Mixed findings: AD > VD <sup>[6,23]</sup> ; AD = VD <sup>[25]</sup>
VD	Olfactory performance below normative scores; Unclear differential profile with other dementias	AD = PD <sup>[26]</sup> ; mild DLB > MCI/AD <sup>[27]</sup> FTD < AD <sup>[54]</sup>
PD	Decreased odor identification, which may precede the development of clinical PD	FTD = AD <sup>[55]</sup>
FTD	FTD patients demonstrate preserved odor discrimination abilities, Impairments in odor naming and odor-picture	Legend: > more impaired; < less impaired; = similar

AD: Alzheimer's disease; VD: Vascular dementia; PD: Parkinson's disease; FTD: Frontotemporal dementia; DLB: Dementia with Lewy bodies; MCI: Mild cognitive impairment.

**Table 2 Easy to use common olfaction tests**

Test name	Internet address
Smell Identification Test (UPSIT) <sup>[60]</sup>	<a href="http://sensonics.com/smell-products/smell-identification-test-international-versions-available.html">http://sensonics.com/smell-products/smell-identification-test-international-versions-available.html</a>
Brief Smell Identification Test <sup>1</sup> - also known as the Cross-Cultural Smell Identification Test <sup>[61]</sup>	<a href="http://sensonics.com/smell-products/brief-smell-identification-test.html">http://sensonics.com/smell-products/brief-smell-identification-test.html</a>
Pocket Smell Test <sup>[62]</sup>	<a href="http://sensonics.com/smell-products/pocket-smell-test.html">http://sensonics.com/smell-products/pocket-smell-test.html</a>
Smell Diskettes <sup>[63]</sup>	<a href="http://www.smelldiskettes.com/">http://www.smelldiskettes.com/</a>
Screening 12 Test (Sniffin' Sticks) <sup>[64]</sup>	<a href="http://www.usneurologicals.com/index.php?app=ecom&amp;ns=prodshow&amp;ref=ST_SniffinSticks">http://www.usneurologicals.com/index.php?app=ecom&amp;ns=prodshow&amp;ref=ST_SniffinSticks</a>

<sup>1</sup>Test available in multiple languages.

eye or hearing tests<sup>[59]</sup>. Routine olfactory tests, assessing several olfaction components<sup>[54]</sup>, could assist not only in the detection and the discovery of causes for olfactory dysfunctions, but also aid longitudinal studies aiming to understand olfaction, and more immediately in the detection of common causes of olfactory dysfunctions, such as airway disorders and viral or bacterial infections.

In order to improve and generalize these baseline assessment practices, it is important to increase awareness of its clinical and research relevance not only among the researchers, but also among the physicians and the psychologists. Concerted informative action for generating awareness among governmental and legislative health bodies should be implemented by researchers and clinicians in all the fields of olfactory dysfunction. The absence of baseline assessments will continue to minimize accuracy in studies and clinical practices, since comparisons of patient values exclusively to group results, and not to individual levels of olfactory functioning, will only yield approximate results.

In sum, we hope that the potential of utilizing the olfactory dysfunction for diagnosis and perhaps even as intervention outcome, together with an awareness of available inexpensive and easy to implement assessment tools, can lead to its wider clinical use (integrated with research efforts). The latter mentioned proposal may very well improve dementia diagnosis and allow an establishment of differential profiles. Implementation of olfactory tests in standard neuropsychological screening and diagnostic batteries, from preclinical and early stages of dementia, will clarify if olfactory dysfunction holds any potential

for aiding research progress in the field of dementia<sup>[13,24]</sup>.

## REFERENCES

- 1 **Chu S**, Downes JJ. Odour-evoked autobiographical memories: psychological investigations of proustian phenomena. *Chem Senses* 2000; **25**: 111-116 [PMID: 10668001]
- 2 **Doty RL**, Shaman P, Applebaum SL, Giberson R, Sikorski L, Rosenberg L. Smell identification ability: changes with age. *Science* 1984; **226**: 1441-1443 [PMID: 6505700]
- 3 **Duffy VB**, Backstrand JR, Ferris AM. Olfactory dysfunction and related nutritional risk in free-living, elderly women. *J Am Diet Assoc* 1995; **95**: 879-884; quiz 885-886 [PMID: 7636078 DOI: 10.1016/S0002-8223(95)00244-8]
- 4 **Murphy C**, Schubert CR, Cruickshanks KJ, Klein BE, Klein R, Nondahl DM. Prevalence of olfactory impairment in older adults. *JAMA* 2002; **288**: 2307-2312 [PMID: 12425708]
- 5 **Barresi M**, Ciurleo R, Giacoppo S, Foti Cuzzola V, Celi D, Bramanti P, Marino S. Evaluation of olfactory dysfunction in neurodegenerative diseases. *J Neurol Sci* 2012; **323**: 16-24 [PMID: 23010543 DOI: 10.1016/j.jns.2012.08.028]
- 6 **Duff K**, McCaffrey RJ, Solomon GS. The Pocket Smell Test: successfully discriminating probable Alzheimer's dementia from vascular dementia and major depression. *J Neuropsychiatry Clin Neurosci* 2002; **14**: 197-201 [PMID: 11983795]
- 7 **Doty RL**. Olfactory dysfunction in Parkinson disease. *Nat Rev Neurol* 2012; **8**: 329-339 [PMID: 22584158 DOI: 10.1038/nnrneurol.2012.80]
- 8 **Pardini M**, Huey ED, Cavanagh AL, Grafman J. Olfactory function in corticobasal syndrome and frontotemporal dementia. *Arch Neurol* 2009; **66**: 92-96 [PMID: 19139305 DOI: 10.1001/archneurol.2008.521]
- 9 **Schubert CR**, Cruickshanks KJ, Fischer ME, Huang GH, Klein BE, Klein R, Pankow JS, Nondahl DM. Olfactory impairment in an adult population: the Beaver Dam Offspring Study. *Chem Senses* 2012; **37**: 325-334 [PMID: 22045704 DOI:

- 10.1093/chemse/bjr102]
- 10 **Doty RL**, Kamath V. The influences of age on olfaction: a review. *Front Psychol* 2014; **5**: 20 [PMID: 24570664 DOI: 10.3389/fpsyg.2014.00020]
- 11 **Djordjevic J**, Jones-Gotman M, De Sousa K, Chertkow H. Olfaction in patients with mild cognitive impairment and Alzheimer's disease. *Neurobiol Aging* 2008; **29**: 693-706 [PMID: 17207898 DOI: 10.1016/j.neurobiolaging.2006.11.014]
- 12 **Morgan CD**, Murphy C. Olfactory event-related potentials in Alzheimer's disease. *J Int Neuropsychol Soc* 2002; **8**: 753-763 [PMID: 12240739]
- 13 **Sun GH**, Raji CA, Maceachern MP, Burke JF. Olfactory identification testing as a predictor of the development of Alzheimer's dementia: a systematic review. *Laryngoscope* 2012; **122**: 1455-1462 [PMID: 22552846 DOI: 10.1002/lary.23365]
- 14 **Yamagishi M**, Ishizuka Y, Seki K. Pathology of olfactory mucosa in patients with Alzheimer's disease. *Ann Otol Rhinol Laryngol* 1994; **103**: 421-427 [PMID: 8203807]
- 15 **Aliani M**, Udenigwe CC, Girgih AT, Pownall TL, Bugera JL, Eskin MN. Aroma and taste perceptions with Alzheimer disease and stroke. *Crit Rev Food Sci Nutr* 2013; **53**: 760-769 [PMID: 23638935 DOI: 10.1080/10408398.2011.559557]
- 16 **Larsson M**, Oberg C, Bäckman L. Recollective experience in odor recognition: influences of adult age and familiarity. *Psychol Res* 2006; **70**: 68-75 [PMID: 15480757 DOI: 10.1007/s00426-004-0190-9]
- 17 **McKhann GM**, Knopman DS, Chertkow H, Hyman BT, Jack CR, Kawas CH, Klunk WE, Koroshetz WJ, Manly JJ, Mayeux R, Mohs RC, Morris JC, Rossor MN, Scheltens P, Carrillo MC, Thies B, Weintraub S, Phelps CH. The diagnosis of dementia due to Alzheimer's disease: recommendations from the National Institute on Aging-Alzheimer's Association workgroups on diagnostic guidelines for Alzheimer's disease. *Alzheimers Dement* 2011; **7**: 263-269 [PMID: 21514250 DOI: 10.1016/j.jalz.2011.03.005]
- 18 **Kovács T**, Cairns NJ, Lantos PL. Olfactory centres in Alzheimer's disease: olfactory bulb is involved in early Braak's stages. *Neuroreport* 2001; **12**: 285-288 [PMID: 11209936]
- 19 **Esiri MM**, Wilcock GK. The olfactory bulbs in Alzheimer's disease. *J Neurol Neurosurg Psychiatry* 1984; **47**: 56-60 [PMID: 6693914]
- 20 **Wesson DW**, Levy E, Nixon RA, Wilson DA. Olfactory dysfunction correlates with amyloid-beta burden in an Alzheimer's disease mouse model. *J Neurosci* 2010; **30**: 505-514 [PMID: 20071513 DOI: 10.1523/JNEUROSCI.4622-09.2010]
- 21 **Attems J**, Jellinger KA. Olfactory tau pathology in Alzheimer disease and mild cognitive impairment. *Clin Neuropathol* 2006; **25**: 265-271 [PMID: 17140156]
- 22 **Rezek DL**. Olfactory deficits as a neurologic sign in dementia of the Alzheimer type. *Arch Neurol* 1987; **44**: 1030-1032 [PMID: 3632374]
- 23 **Motomura N**, Tomota Y. Olfactory dysfunction in dementia of Alzheimer's type and vascular dementia. *Psychogeriatrics* 2006; **6**: 19-20 [DOI: 10.1111/j.1479-8301.2006.00119.x]
- 24 **Fusetti M**, Fioretti AB, Silvagni F, Simaskou M, Sucapane P, Necozione S, Eibenstein A. Smell and preclinical Alzheimer disease: study of 29 patients with amnesic mild cognitive impairment. *J Otolaryngol Head Neck Surg* 2010; **39**: 175-181 [PMID: 20211105]
- 25 **Gray AJ**, Staples V, Murren K, Dhariwal A, Bentham P. Olfactory identification is impaired in clinic-based patients with vascular dementia and senile dementia of Alzheimer type. *Int J Geriatr Psychiatry* 2001; **16**: 513-517 [PMID: 11376468]
- 26 **Chou KL**, Bohnen NI. Performance on an Alzheimer-selective odor identification test in patients with Parkinson's disease and its relationship with cerebral dopamine transporter activity. *Parkinsonism Relat Disord* 2009; **15**: 640-643 [PMID: 19329351 DOI: 10.1016/j.parkreldis.2009.03.004]
- 27 **Williams SS**, Williams J, Combrinck M, Christie S, Smith AD, McShane R. Olfactory impairment is more marked in patients with mild dementia with Lewy bodies than those with mild Alzheimer disease. *J Neurol Neurosurg Psychiatry* 2009; **80**: 667-670 [PMID: 19448090 DOI: 10.1136/jnnp.2008.155895]
- 28 **Wiederkehr S**, Simard M, Fortin C, van Reekum R. Validity of the clinical diagnostic criteria for vascular dementia: a critical review. Part II. *J Neuropsychiatry Clin Neurosci* 2008; **20**: 162-177 [PMID: 18451187 DOI: 10.1176/appi.neuropsych.20.2.162]
- 29 **Albert MS**, DeKosky ST, Dickson D, Dubois B, Feldman HH, Fox NC, Gamst A, Holtzman DM, Jagust WJ, Petersen RC, Snyder PJ, Carrillo MC, Thies B, Phelps CH. The diagnosis of mild cognitive impairment due to Alzheimer's disease: recommendations from the National Institute on Aging-Alzheimer's Association workgroups on diagnostic guidelines for Alzheimer's disease. *Alzheimers Dement* 2011; **7**: 270-279 [PMID: 21514249 DOI: 10.1016/j.jalz.2011.03.008]
- 30 **Cecchini MP**, Bojanowski V, Bodechtel U, Hummel T, Hähner A. Olfactory function in patients with ischemic stroke: a pilot study. *Eur Arch Otorhinolaryngol* 2012; **269**: 1149-1153 [PMID: 22042242 DOI: 10.1007/s00405-011-1819-0]
- 31 **Hall WC**. Movement and Its Central Control. In: Purves D, Augustine GJ, Fitzpatrick D, Hall WC, Lamantia AS, McNamara JO, Williams SM, editors. *Neuroscience*. 3rd ed. Sunderland, MA, USA: Sinauer Associates Inc., 2004
- 32 **Hawkes CH**, Shephard BC, Daniel SE. Is Parkinson's disease a primary olfactory disorder? *QJM* 1999; **92**: 473-480 [PMID: 10627864]
- 33 **Attems J**, Walker L, Jellinger KA. Olfactory bulb involvement in neurodegenerative diseases. *Acta Neuropathol* 2014; **127**: 459-475 [PMID: 24554308 DOI: 10.1007/s00401-014-1261-7]
- 34 **Ross GW**, Petrovitch H, Abbott RD, Tanner CM, Popper J, Masaki K, Launer L, White LR. Association of olfactory dysfunction with risk for future Parkinson's disease. *Ann Neurol* 2008; **63**: 167-173 [PMID: 18067173 DOI: 10.1002/ana.21291]
- 35 **Mizutani Y**, Nakamura T, Okada A, Suzuki J, Watanabe H, Hirayama M, Sobue G. Hyposmia and cardiovascular dysautonomia correlatively appear in early-stage Parkinson's disease. *Parkinsonism Relat Disord* 2014; **20**: 520-524 [PMID: 24637128 DOI: 10.1016/j.parkreldis.2014.02.010]
- 36 **Slow EJ**, Postuma RB, Lang AE. Implications of nocturnal symptoms towards the early diagnosis of Parkinson's disease. *J Neural Transm* 2014; **121** Suppl 1: 49-57 [PMID: 24500032 DOI: 10.1007/s00702-014-1168-4]
- 37 **Haehner A**, Hummel T, Reichmann H. A clinical approach towards smell loss in Parkinson's disease. *J Parkinsons Dis* 2014; **4**: 189-195 [PMID: 24322062 DOI: 10.3233/JPD-130278]
- 38 **Müller A**, Reichmann H, Livermore A, Hummel T. Olfactory function in idiopathic Parkinson's disease (IPD): results from cross-sectional studies in IPD patients and long-term follow-up of de-novo IPD patients. *J Neural Transm* 2002; **109**: 805-811 [PMID: 12111470 DOI: 10.1007/s007020200067]
- 39 **Doty RL**, Deems DA, Stellar S. Olfactory dysfunction in parkinsonism: a general deficit unrelated to neurologic signs, disease stage, or disease duration. *Neurology* 1988; **38**: 1237-1244 [PMID: 3399075]
- 40 **Duda JE**. Olfactory system pathology as a model of Lewy neurodegenerative disease. *J Neurol Sci* 2010; **289**: 49-54 [PMID: 19783257 DOI: 10.1016/j.jns.2009.08.042]
- 41 **Takeda A**, Saito N, Baba T, Kikuchi A, Sugeno N, Kobayashi M, Hasegawa T, Itoyama Y. Functional imaging studies of hyposmia in Parkinson's disease. *J Neurol Sci* 2010; **289**: 36-39 [PMID: 19720385 DOI: 10.1016/j.jns.2009.08.041]
- 42 **Antsov E**, Silveira-Moriyama L, Kilk S, Kadastik-Eerme L, Toomsoo T, Lees A, Taba P. Adapting the Sniffin' Sticks olfactory test to diagnose Parkinson's disease in Estonia. *Parkinsonism Relat Disord* 2014; **20**: 830-833 [PMID: 24792992 DOI: 10.1016/j.parkreldis.2014.04.012]
- 43 **Baba T**, Kikuchi A, Hirayama K, Nishio Y, Hosokai Y, Kanno S, Hasegawa T, Sugeno N, Konno M, Suzuki K,

- Takahashi S, Fukuda H, Aoki M, Itoyama Y, Mori E, Takeda A. Severe olfactory dysfunction is a prodromal symptom of dementia associated with Parkinson's disease: a 3 year longitudinal study. *Brain* 2012; **135**: 161-169 [PMID: 22287381 DOI: 10.1093/brain/awr321]
- 44 Lee JE, Cho KH, Ham JH, Song SK, Sohn YH, Lee PH. Olfactory performance acts as a cognitive reserve in non-demented patients with Parkinson's disease. *Parkinsonism Relat Disord* 2014; **20**: 186-191 [PMID: 24262869 DOI: 10.1016/j.parkreldis.2013.10.024]
  - 45 Double KL, Rowe DB, Hayes M, Chan DK, Blackie J, Corbett A, Joffe R, Fung VS, Morris J, Halliday GM. Identifying the pattern of olfactory deficits in Parkinson disease using the brief smell identification test. *Arch Neurol* 2003; **60**: 545-549 [PMID: 12707068 DOI: 10.1001/archneur.60.4.545]
  - 46 Braak H, Del Tredici K, Rüb U, de Vos RA, Jansen Steur EN, Braak E. Staging of brain pathology related to sporadic Parkinson's disease. *Neurobiol Aging* 2003; **24**: 197-211 [PMID: 12498954]
  - 47 Lee EY, Eslinger PJ, Du G, Kong L, Lewis MM, Huang X. Olfactory-related cortical atrophy is associated with olfactory dysfunction in Parkinson's disease. *Mov Disord* 2014; **29**: 1205-1208 [PMID: 24482154 DOI: 10.1002/mds.25829]
  - 48 Müller ML, Bohnen NI. Cholinergic dysfunction in Parkinson's disease. *Curr Neurol Neurosci Rep* 2013; **13**: 377 [PMID: 23943367 DOI: 10.1007/s11910-013-0377-9]
  - 49 Bohnen NI, Müller ML, Kotagal V, Koeppe RA, Kilbourn MA, Albin RL, Frey KA. Olfactory dysfunction, central cholinergic integrity and cognitive impairment in Parkinson's disease. *Brain* 2010; **133**: 1747-1754 [PMID: 20413575 DOI: 10.1093/brain/awq079]
  - 50 NINDS. NINDS Frontotemporal Dementia Information Page [Internet] 2014. Available from: URL: <http://www.ninds.nih.gov/disorders/picks/picks.htm>
  - 51 Neary D, Snowden J, Mann D. Frontotemporal dementia. *Lancet Neurol* 2005; **4**: 771-780 [PMID: 16239184 DOI: 10.1016/S1474-4422(05)70223-4]
  - 52 Snowden JS, Neary D, Mann DM. Frontotemporal dementia. *Br J Psychiatry* 2002; **180**: 140-143 [PMID: 11823324]
  - 53 Manji H, Wills A, Kitchen N, Dorward N, Connelly S, Mehta A. Oxford Handbook of Neurology. Oxford: Oxford University Press. *Physiotherapy* 2009; **95**: 326 [DOI: 10.1016/j.physio.2007.10.003]
  - 54 Luzzi S, Snowden JS, Neary D, Coccia M, Provinciali L, Lambon Ralph MA. Distinct patterns of olfactory impairment in Alzheimer's disease, semantic dementia, frontotemporal dementia, and corticobasal degeneration. *Neuropsychologia* 2007; **45**: 1823-1831 [PMID: 17270222 DOI: 10.1016/j.neuropsychologia.2006.12.008]
  - 55 McLaughlin NC, Westervelt HJ. Odor identification deficits in frontotemporal dementia: a preliminary study. *Arch Clin Neuropsychol* 2008; **23**: 119-123 [PMID: 17875380 DOI: 10.1016/j.acn.2007.07.008]
  - 56 Omar R, Mahoney CJ, Buckley AH, Warren JD. Flavour identification in frontotemporal lobar degeneration. *J Neurol Neurosurg Psychiatry* 2013; **84**: 88-93 [PMID: 23138765 DOI: 10.1136/jnnp-2012-303853]
  - 57 Takeda A, Baba T, Kikuchi A, Hasegawa T, Sugeno N, Konno M, Miura E, Mori E. Olfactory dysfunction and dementia in Parkinson's disease. *J Parkinsons Dis* 2014; **4**: 181-187 [PMID: 24625830 DOI: 10.3233/JPD-130277]
  - 58 Vigouroux M, Bertrand B, Farget V, Plailly J, Royet JP. A stimulation method using odors suitable for PET and fMRI studies with recording of physiological and behavioral signals. *J Neurosci Methods* 2005; **142**: 35-44 [PMID: 15652615 DOI: 10.1016/j.jneumeth.2004.07.010]
  - 59 Fox M. Worried You May Be Developing Alzheimer's? Check Your Eyes. NBCNews [Internet]. 2014 July 12. Available from: URL: <http://www.nbcnews.com/health/aging/worried-you-may-be-developing-alzheimers-check-your-eyes-n153226>
  - 60 Doty RL, Shaman P, Dann M. Development of the University of Pennsylvania Smell Identification Test: a standardized microencapsulated test of olfactory function. *Physiol Behav* 1984; **32**: 489-502 [PMID: 6463130]
  - 61 Doty RL, Marcus A, Lee WW. Development of the 12-item Cross-Cultural Smell Identification Test (CC-SIT). *Laryngoscope* 1996; **106**: 353-356 [PMID: 8614203]
  - 62 Solomon GS, Petrie WM, Hart JR, Brackin HB. Olfactory dysfunction discriminates Alzheimer's dementia from major depression. *J Neuropsychiatry Clin Neurosci* 1998; **10**: 64-67 [PMID: 9547468]
  - 63 Briner HR, Simmen D. Smell diskettes as screening test of olfaction. *Rhinology* 1999; **37**: 145-148 [PMID: 10670026]
  - 64 Hummel T, Sekinger B, Wolf SR, Pauli E, Kobal G. 'Sniffin' sticks': olfactory performance assessed by the combined testing of odor identification, odor discrimination and olfactory threshold. *Chem Senses* 1997; **22**: 39-52 [PMID: 9056084]

P- Reviewer: Altamura C, Carter WG S- Editor: Ji FF

L- Editor: A E- Editor: Lu YJ





## Promising new treatment targets in patients with fibrosing lung disorders

Martina Sterclova, Martina Vasakova

Martina Sterclova, Martina Vasakova, Department of Respiratory Medicine, Thomayer Hospital and 1<sup>st</sup> Medical Faculty of Charles University, Prague 14000, Czech Republic

Author contributions: Sterclova M wrote the paper; Vasakova M critically revised the paper.

Supported by IGA Grant G 1207 (Internal Grant Agency of the Czech Ministry of Health)

Correspondence to: Martina Sterclova, MD, PhD, Department of Respiratory Medicine, Thomayer Hospital and 1<sup>st</sup> Medical Faculty of Charles University, Videnska 800, Prague 14000, Czech Republic. [martinasafankova@seznam.cz](mailto:martinasafankova@seznam.cz)

Telephone: +420-261-082163 Fax: +420-261-082206

Received: May 20, 2014 Revised: July 21, 2014

Accepted: September 6, 2014

Published online: November 16, 2014

### Abstract

The processes of lung fibrogenesis and fibrotic healing are common to a number of conditions with different etiologies. The lungs are the only affected organ in some cases, whereas in others, several organ systems are involved. Therapeutic options can be discussed from various perspectives. In this review, we address the localization of therapeutic targets with regard to cell compartments, including secreted ligands, cell surface, plasma membrane-cytosol interplay, cytosol and nucleus. Complex approach using stem cell therapy is also discussed. As the prognosis of patients with these disorders remains grim, treatment combinations targeting different molecules within the cell should sometimes be considered. It is reasonable to assume that blocking specific pathways will more likely lead to disease stabilization, while stem cell-based treatments could potentially restore lung architecture. Gene therapy could be a candidate for preventive care in families with proven specific gene polymorphisms and documented familial lung fibrosis. Chronobiology, that takes into account effect of circadian rhythm on cell biology, has demonstrated that timed drug administration can improve treatment outcomes. However, the specific

recommendations for optimal approaches are still under debate. A multifaceted approach to interstitial lung disorders, including cooperation between those doing basic research and clinical doctors as well as tailoring research and treatment strategies toward (until now) unmet medical needs, could improve our understanding of the diseases and, above all, provide benefits for our patients.

© 2014 Baishideng Publishing Group Inc. All rights reserved.

**Key words:** Interstitial lung disease; Treatment; Idiopathic pulmonary fibrosis; Connective tissue disease; Cell compartments; Signaling molecules; Signal transducers; Transcription factors

**Core tip:** Novel treatment targets in patients with fibrosing interstitial lung diseases are summarized. Targets are listed according to defined cell compartments. Ongoing clinical studies focusing on some of the promising targets provide insight into current progress in lung fibrosis research.

Sterclova M, Vasakova M. Promising new treatment targets in patients with fibrosing lung disorders. *World J Clin Cases* 2014; 2(11): 668-675 Available from: URL: <http://www.wjgnet.com/2307-8960/full/v2/i11/668.htm> DOI: <http://dx.doi.org/10.12998/wjcc.v2.i11.668>

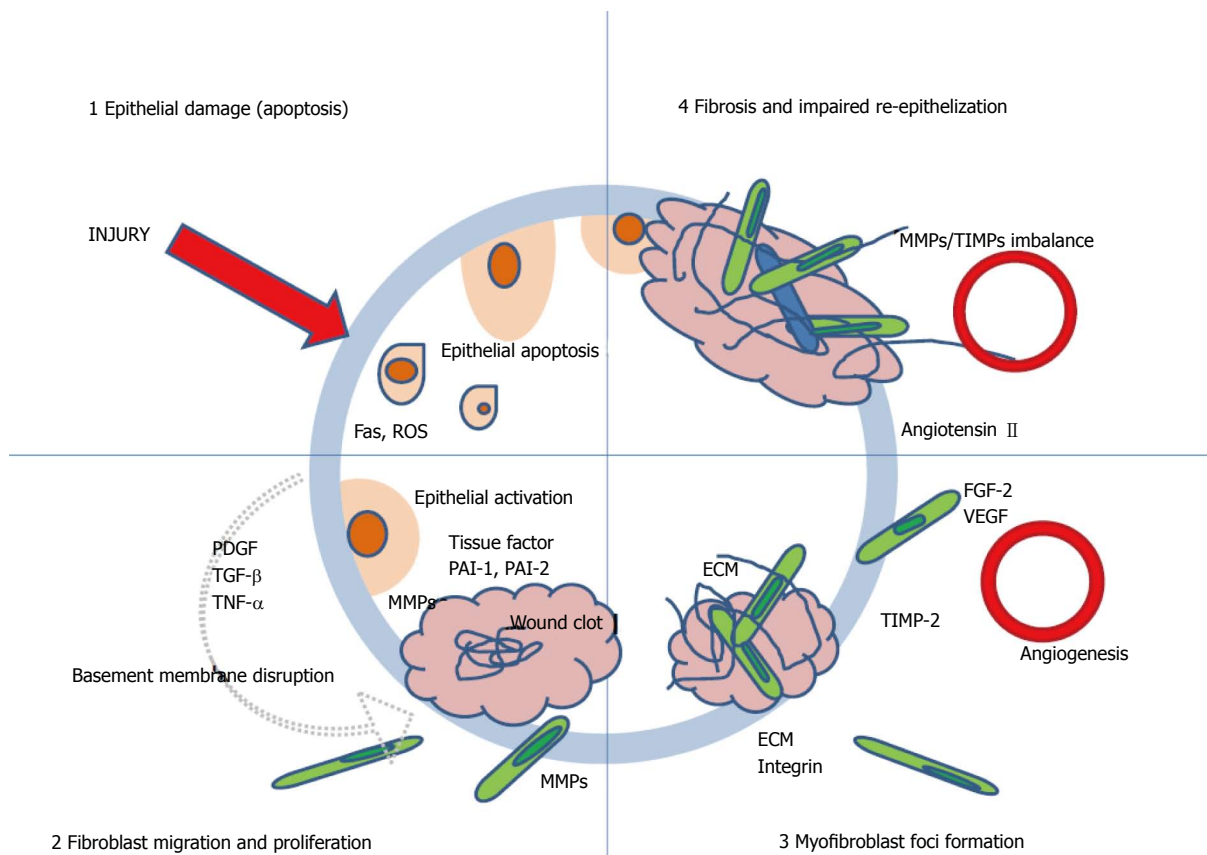
### INTRODUCTION

The processes of lung fibrogenesis and fibrotic healing are common to a number of conditions with different etiologies. The lungs are the only affected organ in some cases, whereas in others, several organ systems are involved. There are several similar features that can be observed in adult patients with fibrosing lung disorders: *e.g.*, a history of exposure to inhaled antigens (organic or

**Table 1 Interstitial lung diseases with a fibro-proliferative pattern, radiologic/histologic phenotypes and new treatment modalities**

Etiology	Radiologic/histopathologic phenotype	New treatment modalities studied
Lung-specific involvement		
Inhalation of organic antigens ( <i>e.g.</i> , EAA)	NSIP, UIP, OP, DIP, AIP	No
Inhalation of inorganic materials ( <i>e.g.</i> , asbestosis)	NSIP, UIP, OP, DIP, AIP	No
Drug and radiation toxicity	NSIP, UIP, OP, DIP, AIP	No
Idiopathic pulmonary fibrosis	UIP $\pm$ NSIP	Yes
Idiopathic nonspecific interstitial pneumonia	NSIP $\pm$ UIP	No
Systemic involvement		
ILDs associated with connective tissue diseases	NSIP, UIP, OP, DIP, AIP	Yes
Sarcoidosis and other granulomatoses	NSIP, UIP, OP, DIP, AIP	Yes

EAA: Extrinsic allergic alveolitis; IPF: Idiopathic pulmonary fibrosis; NSIP: Nonspecific interstitial pneumonia; ILD: Interstitial lung disease; UIP: Usual interstitial pneumonia; OP: Organizing pneumonia; DIP: Desquamative interstitial pneumonia; AIP: Acute interstitial pneumonia.



**Figure 1 Suggested pathogenesis of idiopathic pulmonary fibrosis.** ROS: Reactive oxygen species; PDGF: Platelet-derived growth factor; TGF-β: Transforming growth factor beta; TNF-α: Tumor necrosis factor alpha; MMPs: Matrix metalloproteases; PAI: Platelet activator inhibitor; ECM: Extracellular matrix; TIMP: Tissue inhibitor of metalloproteases; FGF: Fibroblast growth factor; VEGF: Vascular endothelial growth factor.

inorganic compounds, smoking), respiratory infections (viral), extra-esophageal reflux, impaired coagulation cascade, signs of immune system disorders with detectable autoantibodies, and genetic susceptibility<sup>[1-5]</sup>. In some patients, both fibrosis and inflammation may be observed; in contrast, in the pathogenesis of idiopathic pulmonary fibrosis (IPF), inflammation plays a relatively minor role<sup>[6]</sup>.

The spectrum of interstitial lung diseases with a fibro-proliferative pattern of healing is summarized in Table 1.

Until recently, most treatment options in patients with interstitial lung disorders have focused on inflamma-

tion and lung fibrosis, relying on anti-inflammatory and immunosuppressive agents<sup>[7]</sup>. However, these strategies have been found to be effective only in specific groups of patients (patients with connective tissue-associated ILD, history of inhalation of organic antigens, drug- and radiation-induced ILD, sarcoidosis or other granulomatoses). In IPF patients, as documented in the Panther study, these treatments not only failed, but they seemed to negatively impact the mortality and morbidity outcomes of patients<sup>[8]</sup>.

Figure 1 depicts the hypothesized mechanism underlying the pathogenesis of IPF. Repeated micro-injuries to

**Table 2 Potential treatment targets in patients with fibrosing lung disease, according to target location**

Target	Potential molecular target
Signals from other cells	Cytokines, survival factors, chemokines, hormones, transmitters, growth factors, extracellular
Autocrine signals	matrix compounds, Wnt, Hedgehog, death factor
Cell surface	Cytokine receptors, receptor tyrosine kinase, G protein-coupled receptors, integrins, Frizzled, Patched, Fas receptor, ion channels
Plasma membrane-cytosol interface	Kinases
	miRNAs
Cytosol signal transducers	Apoptosis-related proteins
Nucleus	Transcription factors
	Epigenetic modifiers

miRNA: Micro-ribonucleic acid.

**Table 3 Ongoing clinical studies in idiopathic pulmonary fibrosis patients**

Target	Potential molecular target	Ongoing clinical study
Signals from other cells	Interleukin 13	Lebrikizumab NCT01872689
Autocrine signals	Connective tissue growth factor	Tralokinumab NCT02036580
		FG-3019 NCT01890265
Cell surface	Lysophosphatidic acid receptor	Lysophosphatidic acid receptor antagonist-NCT01766817
	Lysyl oxidase LOXL2	Simtuzumab NCT01769196
	CD20	Rituximab NCT01969409
	Androgen receptor	Nandrolone decanoate NCT02055456
Plasma membrane-cytosol interface	Phosphoinositol kinase PI3K	Phosphoinositol kinase PI3K inhibitor NCT01725139
Cytosol signal transducers	Avβ6 integrin	STX-100 NCT01371305
Nucleus		None
Stem cells		Autologous adipose-derived adult stem cells NCT02135380
		Autologous mesenchymal bone marrow-derived stem cells NCT01919827
		Allogenic human mesenchymal stem cells NCT02013700

the alveolar epithelium seem to play a key role in the initiation of the disease. Fibroblasts are attracted to the site of injury, proliferate and eventually form fibroblast foci with exaggerated extracellular matrix production<sup>[9]</sup>. Some of the epithelial type II alveolar cells may undergo trans-differentiation into fibroblasts and become activated<sup>[10]</sup>. Developmentally active programs, including Sonic hedgehog (Shh), Notch and Wnt-related MMTV integration site (Wnt), were found to be repeated in IPF<sup>[11,12]</sup>. However, unlike in “normal” development, these pathways seem to be dysregulated, resulting in an overactive development phenotype<sup>[13]</sup>.

These clinical observations as well as new insights into the pathogenesis of fibrosing lung diseases have led to a vigorous search for alternative treatments. Potential targets for the treatment of fibrosing ILD are listed in Table 2. Table 3 presents ongoing clinical studies in IPF patients.

## SECRETED LIGANDS (SIGNALS FROM OTHER CELLS, AUTOCRINE SIGNALS)

Cytokines, chemokines, growth factors and their receptors have been widely investigated in patients with various fibrosing lung diseases. These molecules play a role in inflammation, fibrogenesis and angiogenesis, and most of them have been found to be somehow involved in

the pathogenesis of fibrosing lung disorders<sup>[14]</sup>. Although *in vitro* studies and experiments using mouse models have provided promising results suggesting that blocking certain chemokines or cytokines could prevent the progression of lung fibrosis, results from clinical studies have not been convincing. For instance, although tumor necrosis factor alpha (TNF-alpha) inhibitors were found to be useful in the management of connective tissue diseases (CTDs) and sarcoidosis, they were demonstrated to have no benefit in patients with marked lung fibro-proliferation, such as in IPF patients<sup>[15,16]</sup>. Moreover, in patients with pulmonary involvement due to CTDs, the role of TNF-alpha inhibitors has yet to be established<sup>[17]</sup>. Other agents, such as interleukin-13 (IL-13) inhibitors, chemokine (C-C motif) ligand 2 inhibitors, connective tissue growth factor (CTGF) inhibitors, transforming growth factor (TGF) inhibitors and (beta 1 isoform) lysyl oxidase-like (LOXL) 2 inhibitors, are currently the subject of clinical studies<sup>[18]</sup>. TGF beta is considered an important mediator of fibrotic processes. It plays a role in wound healing, extracellular matrix production and angiogenesis. However, it is also involved in inflammatory responses and can exhibit both pro-inflammatory and anti-inflammatory properties. TGF beta also plays an ambiguous role in oncogenesis: it can inhibit the growth of some tumor cells while enhancing migration and growth in others<sup>[19]</sup>. As the fibrogenic properties of TGF beta

have been known and extensively studied, an anti-TGF beta antibody (fresolimumab) has already been tested in IPF patients. Current strategies are directed mostly at downstream mediators, which are thought to have fewer harmful effects on tissue homeostasis<sup>[20]</sup>.

Oxidative stress is considered to be a key mediator in IPF pathogenesis. It is not known whether this is due to the overproduction of reactive oxygen species (ROS) or to the diminished scavenger capacity of various cells<sup>[21]</sup>. NADPH oxidase (NOX) is one of the ROS-generating enzyme systems expressed by alveolar epithelial cells, endothelial cells, macrophages, neutrophils, mesenchymal cells and smooth muscle cells. Several isoforms of NOX have been characterized, with NOX-1, NOX-2 and NOX-4 appearing to be the most relevant in IPF pathogenesis. Specific NOX inhibitors may prove to be effective drug targets in IPF<sup>[22]</sup>.

## CELL SURFACE

Pirfenidone was found to inhibit the synthesis of TGF beta and TNF alpha, even though the underlying mechanism has yet to be elucidated. Compared to placebo, pirfenidone delays the progression of IPF and mortality, and it is currently the only registered molecule for IPF treatment in some countries<sup>[23]</sup>.

Lung fibrosis with distortion of vessel architecture is accompanied by enhanced coagulation. The primary function of the coagulation cascade is to promote hemostasis and limit blood loss in response to tissue injury. However, coagulation also plays a pivotal role in inflammatory and tissue repair responses, including lung fibrosis<sup>[24]</sup>. Hyperplastic alveolar epithelium in patients with fibro-proliferative lung disorders might be an important source of several coagulation-promoting factors. There have been several studies on the potential therapeutic role of warfarin, but these resulted in a strong recommendation against the use of warfarin in IPF treatment. Further studies have shown that other components of the coagulation cascade can be targeted. Proteinase-activated receptor 1 (PAR-1) is a major high-affinity receptor for thrombin and its activation leads to a number of pro-fibrotic events, including the proliferation of fibroblasts and their differentiation into myofibroblasts<sup>[25]</sup>. PAR-1 has been suggested as a major player in endothelial-epithelial barrier disruption. Atopaxar and vorapaxar inhibit PAR-1 and may represent possible options in IPF treatment<sup>[26]</sup>.

Given that fibroblast proliferation and extracellular matrix production are the hallmark of fibrotic lung diseases, huge efforts have been made to investigate fibroblast biology and signaling<sup>[27]</sup>. Lung fibroblasts derived from IPF patients have enhanced motility compared to their normal counterparts. This hypermotile phenotype of fibroblasts is thought to be driven by ligation of urokinase with its receptor (uPAR), which leads to the formation of unique lipid raft platforms. Blocking fibroblast migration *via* uPAR represents one possible future treatment option for IPF patients<sup>[28]</sup>.

Another therapeutic approach may involve blocking signaling mechanisms in cells that are common to multiple pathways. The pro-fibrotic effect of TGF beta 1 and basic fibroblast growth factor (FGF) was found to be dependent on a  $\text{Ca}^{2+}$ -activated  $\text{K}^{+}$  channel ( $\text{K}_{\text{Ca}3.1}$ ). Inhibiting this channel can block the function of pro-fibrotic human lung myofibroblasts. This makes the  $\text{K}_{\text{Ca}3.1}$  channel an attractive pharmacological target, particularly as it appears to play only a minor role in normal physiology<sup>[29]</sup>. So far, inhibitors of this channel have been used in humans with sickle cell disease with few side effects.

## PLASMA MEMBRANE-CYTOSOL INTERPLAY

Tyrosine kinase (TK) inhibition also attenuates downstream signaling in cells and might be useful if a mutation in the gene coding for tyrosine kinase leads to uncontrolled activation of the cell, manifested as unregulated cell cycle or protein production. Several authors have suggested that similar features and pathogenic pathways might play a key role in idiopathic pulmonary fibrosis and lung cancer<sup>[30]</sup>. In both diseases, epigenetic and genetic changes result in altered responses to regulatory signals, abnormal expression of microRNAs and activation of specific signaling pathways, which raises suspicion that a similar treatment approach could be useful. Inhibitors of TKs or TK-dependent signal transduction pathways might be very helpful in controlling the growth of cancer cells<sup>[31]</sup>. Although studies with imatinib mesylate in IPF patients showed a lack of efficacy, this compound is not the only inhibitor of TK signal transduction that has been tested. Nintedanib is a triple inhibitor of TK receptors (platelet-derived growth factor, vascular endothelial growth factor, and fibroblast growth factor receptors) and is just one of the new drugs that may improve the prognosis of IPF patients<sup>[32]</sup>. Recently published data show that nintedanib reduces lung function decline and slows the progression of IPF<sup>[33]</sup>.

Another member of the protein kinase family is a group of serine-threonine kinases. Rho-kinase (ROCK) is a member of this group and is involved in the regulation of cell movement and shape and plays a role in the function of the tumor suppressor gene PTEN and the mechanism of apoptosis<sup>[34]</sup>. The rho-kinase inhibitor fasudil has potential as a new treatment in systemic scleroderma patients. Additionally, this molecule was found to inhibit lung fibrosis in the bleomycin mouse model and has been suggested as a possible treatment for IPF patients<sup>[35]</sup>.

As mentioned above, pathological remodeling of the extracellular matrix by fibroblasts plays a role in IPF pathogenesis. Parker *et al.*<sup>[36]</sup> noted that expansion of fibrotic lesions after the initial insult leading to fibrogenesis is likely driven by a positive feedback loop between fibroblasts and the extracellular matrix. An interesting option for blocking this loop could be miR-29, which is a potent negative regulator of extracellular matrix genes. Gener-



ally, miRNAs are a type of non-coding, small-sized, evolutionarily preserved RNA and they act as repressors of gene expression at the post-transcriptional level. Other miRNAs that may play a role in IPF and may represent treatment opportunities include miR-21, miR-155 and miR-200<sup>[37]</sup>.

## NUCLEUS

Novel treatment targets are not just limited to the cell surface or cytoplasm; some potential treatments also target the nucleus. Transcription factors are proteins necessary for the transcription of DNA into mRNA. There are specific transcription factors involved in development, response to environmental stimuli, cell cycle control and response to intercellular signals. Immediate-early response transcription factor (Egr-1) takes part in mitogenesis and differentiation. It is thought to be a tumor suppressor gene. Egr-1 has been found to play a role in the fibrotic process, in addition to oncogenesis. It can regulate the expression of extracellular matrix components, matrix remodeling enzymes and fibrogenic cytokines, and drive myofibroblast differentiation<sup>[38,39]</sup>. Although several drugs have been found to have potent inhibitory activity against Egr-1 induction or activity (*e.g.*, mycophenolate mofetil, cyclosporine, imatinib mesylate), clinical studies have only supported their potential use in a subset of patients (ILD associated with CTD)<sup>[40]</sup>. Although mycophenolate mofetil, cyclosporine or imatinib mesylate may be useful in patients with autoimmune disorders that also affect the lung, they are not routinely recommended for IPF patients. The role of simvastatin and rosiglitazone still needs to be established<sup>[41,42]</sup>.

Gene therapy has been suggested as a potential treatment option in numerous respiratory diseases. Gene preparations can be administered to target organs by intravenous, intramuscular or intra-tumor injections. One possible noninvasive delivery strategy includes intranasal administration<sup>[43]</sup>. Effective introduction to the lungs is thought to be possible because of the large absorption area of the mucous membrane and high perfusion. Most research in this area is concentrated on monogenic diseases and lung cancer, with few data on IPF thus far. Gene therapy has been combined with conventional treatment in cancer models and seems to offer interesting treatment possibilities in cases with a known genetic cause - especially for familial lung fibrosis due to short telomere syndrome or MUC5B (gene for mucin) gene polymorphisms<sup>[44-46]</sup>.

## TISSUE REPAIR- POTENTIAL FOR STEM CELLS

Stem cells represent a more complex treatment approach than specific molecular targeted therapy. Stem cells were expected to be the ultimate strategy for restoring diseased lungs, including structural repair (engraftment of cells) and immunomodulation. Endogenous lung progenitors,

endothelial stem cells, induced pluripotent cells, mesenchymal stem cells and epithelial stem cells have all been proposed as prospective treatments, especially for IPF patients<sup>[47,48]</sup>. Intravenous and intratracheal administration of epithelial type II alveolar cells is now being tested in humans. Mesenchymal stem cells (MSCs) were found to be immunosuppressive, they have low immunogenicity and they home to sites of injury after systemic administration. However, MSCs appear to be more efficient in resolving diseases with high inflammatory activity and are less able to preserve organ function or restore cell rearrangements in patients with chronic disease. It has been suggested that systematically administered bone marrow MSCs can differentiate into type II epithelial cells and suppress the expression of proinflammatory and profibrotic genes<sup>[49,50]</sup>. However, ongoing studies in IPF patients were designed as safety studies and their results are still somewhat controversial. The therapeutic potential of bone marrow MSCs may be further enhanced by using a cell-based gene delivery approach.

## CHRONOBIOLOGY

Although circadian rhythms have proved to be strong regulators of many tissue-specific genes, the data concerning lung fibrosis patients are limited. A study by Pekovic-Vaughan suggests that susceptibility to oxidative stress lung injury may vary during the day, because the activity of redox-sensitive transcription factor Nrf2 correlates with the circadian rhythm<sup>[51]</sup>. Not only does Nrf2 enhance oxidative stress, it also points toward a new site for lung fibrosis research<sup>[52]</sup>. Chronobiology has demonstrated that timed drug administration can improve treatment outcomes.

## NON-IPF DISORDERS

In patients with non-IPF fibrosing interstitial lung disorders that continue to progress despite conventional immunosuppression, the anti-CD20 monoclonal antibody rituximab has been tested and appears to be an effective therapeutic intervention, regardless of the final diagnosis<sup>[53]</sup>. However, the data on the optimal treatment strategy in CTD-related fibrosing lung disease are still limited. In patients with systemic lupus erythematosus (SLE), belimumab (IgG1 lambda monoclonal antibody binding circulating B-lymphocyte stimulator) may be an attractive alternative to rituximab. The anti-interferon antibody sifalimumab is being studied in SLE patients and may represent a new treatment option for other autoimmune disorders<sup>[54]</sup>. Whether it could also be beneficial in patients with associated interstitial lung disease is still unknown.

Pulmonary involvement in systemic sclerosis (SSc) patients is common and it is considered to a major cause of death in SSc patients. The pathogenesis of SSc is characterized by significant accumulation of inflammatory cells in the lung parenchyma, even in patients with an otherwise usual interstitial pneumonia (UIP) pattern

of interstitial lung fibrosis. There is an ongoing debate regarding the optimal immunosuppressive agents for SSc ILD patients, especially concerning newer agents such as mycophenolate or rituximab. According to some authors, cyclophosphamide should not be routinely replaced by mycophenolate in SSc ILD subjects<sup>[55]</sup>. Several studies have indicated that rituximab can be useful, but it should be further investigated<sup>[56]</sup>. Pirfenidone, STX-100 and fasudil represent interesting possible treatment options in SSc ILD patients.

## CONCLUSION

Despite recent advances and deeper insight into the pathogenesis of fibrosing lung disorders, we are still unable to successfully treat our patients. Several points need to be addressed, and several intriguing questions need to be answered: (1) How do we define effective treatment? Should effective treatment be defined in terms of disease stabilization and prevention of further decline in lung function? Should we define effective treatment as an improvement in patient quality of life, without necessarily extending it? Should the optimal definition of “effective treatment” include restoration of the lung parenchyma and resolution of both fibrosis and inflammation (if any is present)? It is reasonable to assume that blocking specific pathways will more likely lead to disease stabilization, while stem cell-based treatments could potentially restore lung architecture. Gene therapy could be a candidate for preventive care in families with proven specific gene polymorphisms and documented familial lung fibrosis; (2) Radiological and histopathological patterns of usual interstitial pneumonia (UIP) may be observed in patients with fibrosing lung disease of known cause, such as CTDs, drug-induced lung fibrosis or in patients with a history of exposure to inorganic/organic inhalation antigens. Can any of the above-mentioned therapeutic approaches also be used in non-IPF patients with a radiographic/histopathologic UIP pattern? (3) Should a combination of drugs and therapeutic approaches be used instead of monotherapy? and (4) Similarities between IPF and lung cancer were listed above. What should we learn from the oncological approach? Should we use different treatment strategies according to the stage of the disease and the individual genetic background of patients? If so, what should the staging of lung fibrosis be based on?

We believe that a multifaceted approach to IPF, including cooperation between those doing basic research and clinical doctors as well as tailoring research and treatment strategies toward (until now) unmet medical needs, could improve our understanding of the disease and, above all, provide benefits for our patients.

## REFERENCES

- 1 Molyneaux PL, Maher TM. The role of infection in the pathogenesis of idiopathic pulmonary fibrosis. *Eur Respir Rev* 2013; **22**: 376-381 [PMID: 23997064 DOI: 10.1183/09059180.00000713]
- 2 Cottin V. Significance of connective tissue diseases features in pulmonary fibrosis. *Eur Respir Rev* 2013; **22**: 273-280 [PMID: 23997055 DOI: 10.1183/09059180.00003013]
- 3 Kropski JA, Lawson WE, Young LR, Blackwell TS. Genetic studies provide clues on the pathogenesis of idiopathic pulmonary fibrosis. *Dis Model Mech* 2013; **6**: 9-17 [PMID: 23268535 DOI: 10.1242/dmm.010736]
- 4 Chambers RC. Procoagulant signalling mechanisms in lung inflammation and fibrosis: novel opportunities for pharmacological intervention? *Br J Pharmacol* 2008; **153** Suppl 1: S367-S378 [PMID: 18223674 DOI: 10.1038/sj.bjp.0707603]
- 5 Lee JS, Collard HR, Raghu G, Sweet MP, Hays SR, Campos GM, Golden JA, King TE. Does chronic microaspiration cause idiopathic pulmonary fibrosis? *Am J Med* 2010; **123**: 304-311 [PMID: 20362747 DOI: 10.1016/j.amjmed.2009.07.033]
- 6 Willems S, Verleden SE, Vanaudenaerde BM, Wynants M, Doms C, Yserbyt J, Somers J, Verbeken EK, Verleden GM, Wuyts WA. Multiplex protein profiling of bronchoalveolar lavage in idiopathic pulmonary fibrosis and hypersensitivity pneumonitis. *Ann Thorac Med* 2013; **8**: 38-45 [PMID: 23440593 DOI: 10.4103/1817-1737.105718]
- 7 Behr J, Richeldi L. Recommendations on treatment for IPF. *Respir Res* 2013; **14** Suppl 1: S6 [PMID: 23734936 DOI: 10.1186/1465-9921-14-S1-S6]
- 8 Wells AU, Behr J, Costabel U, Cottin V, Poletti V. Triple therapy in idiopathic pulmonary fibrosis: an alarming press release. *Eur Respir J* 2012; **39**: 805-806 [PMID: 22467722 DOI: 10.1183/09031936.00009112]
- 9 Camelo A, Dunmore R, Sleeman MA, Clarke DL. The epithelium in idiopathic pulmonary fibrosis: breaking the barrier. *Front Pharmacol* 2014; **4**: 173 [PMID: 24454287 DOI: 10.3389/fphar.2013.00173]
- 10 Günther A, Korfei M, Mahavadi P, von der Beck D, Ruppert C, Markart P. Unravelling the progressive pathophysiology of idiopathic pulmonary fibrosis. *Eur Respir Rev* 2012; **21**: 152-160 [PMID: 22654088 DOI: 10.1183/09059180.00001012]
- 11 Königshoff M, Balsara N, Pfaff EM, Kramer M, Chrobak I, Seeger W, Eickelberg O. Functional Wnt signaling is increased in idiopathic pulmonary fibrosis. *PLoS One* 2008; **3**: e2142 [PMID: 18478089 DOI: 10.1371/journal.pone.0002142]
- 12 Bolaños AL, Milla CM, Lira JC, Ramírez R, Checa M, Barrera L, García-Alvarez J, Carbajal V, Becerril C, Gaxiola M, Pardo A, Selman M. Role of Sonic Hedgehog in idiopathic pulmonary fibrosis. *Am J Physiol Lung Cell Mol Physiol* 2012; **303**: L978-L990 [PMID: 230223967 DOI: 10.1152/ajplung.00184.2012]
- 13 Duffield JS, Lupher M, Thannickal VJ, Wynn TA. Host responses in tissue repair and fibrosis. *Annu Rev Pathol* 2013; **8**: 241-276 [PMID: 23092186 DOI: 10.1146/annurev-pathol-020712-163930]
- 14 Wynn TA. Integrating mechanisms of pulmonary fibrosis. *J Exp Med* 2011; **208**: 1339-1350 [PMID: 21727191 DOI: 10.1084/jem.20110551]
- 15 Korsten P, Mirsaeidi M, Sweiss NJ. Nonsteroidal therapy of sarcoidosis. *Curr Opin Pulm Med* 2013; **19**: 516-523 [PMID: 23884295 DOI: 10.1097/MCP.0b013e3283642ad0]
- 16 Rao V, Bowman S. Latest advances in connective tissue disorders. *Ther Adv Musculoskelet Dis* 2013; **5**: 234-249 [PMID: 23904866 DOI: 10.1177/1759720X13480280]
- 17 Raghu G, Brown KK, Costabel U, Cottin V, du Bois RM, Lasky JA, Thomeer M, Utz JP, Khandker RK, McDermott L, Fatenejad S. Treatment of idiopathic pulmonary fibrosis with etanercept: an exploratory, placebo-controlled trial. *Am J Respir Crit Care Med* 2008; **178**: 948-955 [PMID: 18669816 DOI: 10.1164/rccm.200709-1446OC]
- 18 Antoniou KM, Margaritopoulos GA, Siafakas NM. Pharmacological treatment of idiopathic pulmonary fibrosis: from the past to the future. *Eur Respir Rev* 2013; **22**: 281-291 [PMID: 23997056 DOI: 10.1183/09059180.00002113]
- 19 Lee CM, Park JW, Cho WK, Zhou Y, Han B, Yoon PO, Chae

- J, Elias JA, Lee CG. Modifiers of TGF- $\beta$ 1 effector function as novel therapeutic targets of pulmonary fibrosis. *Korean J Intern Med* 2014; **29**: 281-290 [PMID: 24851060 DOI: 10.3904/kjim.2014.29.3.281]
- 20 **Katsumoto TR**, Violette SM, Sheppard D. Blocking TGF $\beta$  via Inhibition of the  $\alpha$ v $\beta$ 6 Integrin: A Possible Therapy for Systemic Sclerosis Interstitial Lung Disease. *Int J Rheumatol* 2011; **2011**: 208219 [PMID: 22013449 DOI: 10.1155/2011/208219]
  - 21 **Hecker L**, Cheng J, Thannickal VJ. Targeting NOX enzymes in pulmonary fibrosis. *Cell Mol Life Sci* 2012; **69**: 2365-2371 [PMID: 22618245 DOI: 10.1007/s00018-012-1012-7]
  - 22 **Kliment CR**, Oury TD. Oxidative stress, extracellular matrix targets, and idiopathic pulmonary fibrosis. *Free Radic Biol Med* 2010; **49**: 707-717 [PMID: 20452419 DOI: 10.1016/j.freeradbiomed.2010.04.036]
  - 23 **King TE**, Bradford WZ, Castro-Bernardini S, Fagan EA, Glaspole I, Glassberg MK, Gorina E, Hopkins PM, Kardatzke D, Lancaster L, Lederer DJ, Nathan SD, Pereira CA, Sahn SA, Sussman R, Swigris JJ, Noble PW. A phase 3 trial of pirfenidone in patients with idiopathic pulmonary fibrosis. *N Engl J Med* 2014; **370**: 2083-2092 [PMID: 24836312 DOI: 10.1056/NEJMoa1402582]
  - 24 **Noth I**, Anstrom KJ, Calvert SB, de Andrade J, Flaherty KR, Glazer C, Kaner RJ, Olman MA; Idiopathic Pulmonary Fibrosis Clinical Research Network (IPFnet). A placebo-controlled randomized trial of warfarin in idiopathic pulmonary fibrosis. *Am J Respir Crit Care Med* 2012; **186**: 88-95 [PMID: 22561965 DOI: 10.1164/rccm.201202-0314OC]
  - 25 **Mercer PF**, Johns RH, Scotton CJ, Krupiczkoj MA, Königshoff M, Howell DC, McNulty RJ, Das A, Thorley AJ, Tetley TD, Eickelberg O, Chambers RC. Pulmonary epithelium is a prominent source of proteinase-activated receptor-1-inducible CCL2 in pulmonary fibrosis. *Am J Respir Crit Care Med* 2009; **179**: 414-425 [PMID: 19060230 DOI: 10.1164/rccm.200712-1827OC]
  - 26 **Chatterjee S**, Sharma A, Mukherjee D. PAR-1 antagonists: current state of evidence. *J Thromb Thrombolysis* 2013; **35**: 1-9 [PMID: 22644721 DOI: 10.1007/s11239-012-0752-4]
  - 27 **Habiel DM**, Hogaboam C. Heterogeneity in fibroblast proliferation and survival in idiopathic pulmonary fibrosis. *Front Pharmacol* 2014; **5**: 2 [PMID: 24478703 DOI: 10.3389/fphar.2014.00002]
  - 28 **Grove LM**, Southern BD, Jin TH, White KE, Paruchuri S, Harel E, Wei Y, Rahaman SO, Gladson CL, Ding Q, Craik CS, Chapman HA, Olman MA. Urokinase-type plasminogen activator receptor (uPAR) ligation induces a raft-localized integrin signaling switch that mediates the hypermotile phenotype of fibrotic fibroblasts. *J Biol Chem* 2014; **289**: 12791-12804 [PMID: 24644284 DOI: 10.1074/jbc.M113.498576]
  - 29 **Roach KM**, Duffy SM, Coward W, Feghali-Bostwick C, Wulff H, Bradding P. The K<sup>+</sup> channel KCa3.1 as a novel target for idiopathic pulmonary fibrosis. *PLoS One* 2013; **8**: e85244 [PMID: 24392001 DOI: 10.1371/journal.pone.0085244]
  - 30 **Vancheri C**. Common pathways in idiopathic pulmonary fibrosis and cancer. *Eur Respir Rev* 2013; **22**: 265-272 [PMID: 23997054 DOI: 10.1183/09059180.00003613]
  - 31 **Daniels CE**, Lasky JA, Limper AH, Mieras K, Gabor E, Schroeder DR; Imatinib-IPF Study Investigators. Imatinib treatment for idiopathic pulmonary fibrosis: Randomized placebo-controlled trial results. *Am J Respir Crit Care Med* 2010; **181**: 604-610 [PMID: 20007927 DOI: 10.1164/rccm.200906-0964OC]
  - 32 **Antoniou SA**. Nintedanib (BIBF 1120) for IPF: A tomorrow therapy? *Multidiscip Respir Med* 2012; **7**: 41 [PMID: 23146151 DOI: 10.1186/2049-6958-7-41]
  - 33 **Richeldi L**, du Bois RM, Raghu G, Azuma A, Brown KK, Costabel U, Cottin V, Flaherty KR, Hansell DM, Inoue Y, Kim DS, Kolb M, Nicholson AG, Noble PW, Selman M, Taniguchi H, Brun M, Le Maulf F, Girard M, Stowasser S, Schlenker-Herceg R, Disse B, Collard HR; INPULSIS Trial Investigators. Efficacy and safety of nintedanib in idiopathic pulmonary fibrosis. *N Engl J Med* 2014; **370**: 2071-2082 [PMID: 24836310 DOI: 10.1056/NEJMoa1402584]
  - 34 **Sheppard D**. ROCKing pulmonary fibrosis. *J Clin Invest* 2013; **123**: 1005-1006 [PMID: 23434586 DOI: 10.1172/JCI68417]
  - 35 **Jiang C**, Huang H, Liu J, Wang Y, Lu Z, Xu Z, Fasudil, a rho-kinase inhibitor, attenuates bleomycin-induced pulmonary fibrosis in mice. *Int J Mol Sci* 2012; **13**: 8293-8307 [PMID: 22942703 DOI: 10.3390/ijms13078293]
  - 36 **Parker MW**, Rossi D, Peterson M, Smith K, Sikström K, White ES, Connett JE, Henke CA, Larsson O, Bitterman PB. Fibrotic extracellular matrix activates a profibrotic positive feedback loop. *J Clin Invest* 2014; **124**: 1622-1635 [PMID: 24590289 DOI: 10.1172/JCI71386]
  - 37 **Angulo M**, Lecuona E, Sznajder JI. Role of MicroRNAs in lung disease. *Arch Bronconeumol* 2012; **48**: 325-330 [PMID: 22607962 DOI: 10.1016/j.arbr.2012.06.015]
  - 38 **Bhattacharyya S**, Wu M, Fang F, Tourtellotte W, Feghali-Bostwick C, Varga J. Early growth response transcription factors: key mediators of fibrosis and novel targets for anti-fibrotic therapy. *Matrix Biol* 2011; **30**: 235-242 [PMID: 21511034 DOI: 10.1016/j.matbio.2011.03.005]
  - 39 **Bhattacharyya S**, Fang F, Tourtellotte W, Varga J. Egr-1: new conductor for the tissue repair orchestra directs harmony (regeneration) or cacophony (fibrosis). *J Pathol* 2013; **229**: 286-297 [PMID: 23132749 DOI: 10.1002/path.4131]
  - 40 **Maher TM**. Immunosuppression for connective tissue disease-related pulmonary disease. *Semin Respir Crit Care Med* 2014; **35**: 265-273 [PMID: 24668541 DOI: 10.1055/s-0034-1371531]
  - 41 **Tzouveleakis A**, Bouros E, Oikonomou A, Ntoliou P, Zacharis G, Kolios G, Bouros D. Effect and safety of mycophenolate mofetil in idiopathic pulmonary fibrosis. *Pulm Med* 2011; **2011**: 849035 [PMID: 22135741 DOI: 10.1155/2011/849035]
  - 42 **Raghu G**, Collard HR, Egan JJ, Martinez FJ, Behr J, Brown KK, Colby TV, Cordier JF, Flaherty KR, Lasky JA, Lynch DA, Ryu JH, Swigris JJ, Wells AU, Ancochea J, Bouros D, Carvalho C, Costabel U, Ebina M, Hansell DM, Johkoh T, Kim DS, King TE, Kondoh Y, Myers J, Müller NL, Nicholson AG, Richeldi L, Selman M, Dudden RF, Griss BS, Protzko SL, Schünemann HJ. An official ATS/ERS/JRS/ALAT statement: idiopathic pulmonary fibrosis: evidence-based guidelines for diagnosis and management. *Am J Respir Crit Care Med* 2011; **183**: 788-824 [PMID: 21471066 DOI: 10.1164/rccm.2009-040GL]
  - 43 **Podolska K**, Stachurska A, Hajdukiewicz K, Malecki M. Gene therapy prospects--intranasal delivery of therapeutic genes. *Adv Clin Exp Med* 2012; **21**: 525-534 [PMID: 23240459]
  - 44 **Liu T**, Ullenbruch M, Young Choi Y, Yu H, Ding L, Xaubet A, Pereda J, Feghali-Bostwick CA, Bitterman PB, Henke CA, Pardo A, Selman M, Phan SH. Telomerase and telomere length in pulmonary fibrosis. *Am J Respir Cell Mol Biol* 2013; **49**: 260-268 [PMID: 23526226 DOI: 10.1165/rcmb.2012-0514OC]
  - 45 **Wei R**, Li C, Zhang M, Jones-Hall YL, Myers JL, Noth I, Liu W. Association between MUC5B and TERT polymorphisms and different interstitial lung disease phenotypes. *Transl Res* 2014; **163**: 494-502 [PMID: 24434656 DOI: 10.1016/j.trsl.2013.12.006]
  - 46 **Borie R**, Kannengiesser C, Crestani B. Familial forms of nonspecific interstitial pneumonia/idiopathic pulmonary fibrosis: clinical course and genetic background. *Curr Opin Pulm Med* 2012; **18**: 455-461 [PMID: 22781209 DOI: 10.1097/MCP.0b013e328356b15c]
  - 47 **Mora AL**, Rojas M. Adult stem cells for chronic lung diseases. *Respirology* 2013; **18**: 1041-1046 [PMID: 23648014 DOI: 10.1111/resp.12112]
  - 48 **McNulty K**, Janes SM. Stem cells and pulmonary fibrosis: cause or cure? *Proc Am Thorac Soc* 2012; **9**: 164-171 [PMID: 22802292 DOI: 10.1513/pats.201201-010AW]
  - 49 **Fehrenbach H**. Alveolar epithelial type II cells from embryonic

- stem cells: knights in shining armour? *Eur Respir J* 2012; **39**: 240-241 [PMID: 22298611 DOI: 10.1183/09031936.00162111]
- 50 **Weiss DJ**, Bertonecello I, Borok Z, Kim C, Panoskaltsis-Mortari A, Reynolds S, Rojas M, Stripp B, Warburton D, Prockop DJ. Stem cells and cell therapies in lung biology and lung diseases. *Proc Am Thorac Soc* 2011; **8**: 223-272 [PMID: 21653527 DOI: 10.1513/pats.201012-071DW]
- 51 **Pekovic-Vaughan V**, Gibbs J, Yoshitane H, Yang N, Pathirana D, Guo B, Sagami A, Taguchi K, Bechtold D, Loudon A, Yamamoto M, Chan J, van der Horst GT, Fukada Y, Meng QJ. The circadian clock regulates rhythmic activation of the NRF2/glutathione-mediated antioxidant defense pathway to modulate pulmonary fibrosis. *Genes Dev* 2014; **28**: 548-560 [PMID: 24637114 DOI: 10.1101/gad.237081.113]
- 52 **Zucker SN**, Fink EE, Bagati A, Mannava S, Bianchi-Smiraglia A, Bogner PN, Wawrzyniak JA, Foley C, Leonova KI, Grimm MJ, Moparthy K, Ionov Y, Wang J, Liu S, Sexton S, Kandel ES, Bakin AV, Zhang Y, Kaminski N, Segal BH, Nikiforov MA. Nrf2 amplifies oxidative stress via induction of Klf9. *Mol Cell* 2014; **53**: 916-928 [PMID: 24613345 DOI: 10.1016/j.molcel.2014.01.033]
- 53 **Keir GJ**, Maher TM, Ming D, Abdullah R, de Lauretis A, Wickremasinghe M, Nicholson AG, Hansell DM, Wells AU, Renzoni EA. Rituximab in severe, treatment-refractory interstitial lung disease. *Respirology* 2014; **19**: 353-359 [PMID: 24286447 DOI: 10.1111/resp.12214]
- 54 **Vij R**, Strek ME. Diagnosis and treatment of connective tissue disease-associated interstitial lung disease. *Chest* 2013; **143**: 814-824 [PMID: 23460159 DOI: 10.1378/chest.12-0741]
- 55 **Panopoulos ST**, Bournia VK, Trakada G, Giavri I, Kostopoulos C, Sfrikakis PP. Mycophenolate versus cyclophosphamide for progressive interstitial lung disease associated with systemic sclerosis: a 2-year case control study. *Lung* 2013; **191**: 483-489 [PMID: 23925736 DOI: 10.1007/s00408-013-9499-8]
- 56 **Wells AU**, Margaritopoulos GA, Antoniou KM, Denton C. Interstitial lung disease in systemic sclerosis. *Semin Respir Crit Care Med* 2014; **35**: 213-221 [PMID: 24668536 DOI: 10.1055/s-0034-1371541]

**P-Reviewer:** Araujo A, Daoussis D, Hattori N, Koyama N

**S-Editor:** Song XX **L-Editor:** A **E-Editor:** Lu YJ





## Recurrent anterior shoulder instability: Review of the literature and current concepts

Hakan Sofu, Sarper Gürsu, Nizamettin Koçkara, Ali Öner, Ahmet Issin, Yalkın Çamurcu

Hakan Sofu, Nizamettin Koçkara, Ahmet Issin, Department of Orthopedics and Traumatology, Erzincan University Faculty of Medicine, 24030 Erzincan, Turkey

Sarper Gürsu, Yalkın Çamurcu, Department of Orthopedics and Traumatology, Baltalimanı Bone and Joint Diseases Hospital, 34470 Istanbul, Turkey

Ali Öner, Department of Orthopedics and Traumatology, Mengücekgazi Education and Research Hospital, 24030 Erzincan, Turkey

**Author contributions:** All authors have contributed to this paper starting from decision of preparing the article to the final submission in the aspects of design, literature search, intellectual concept, writing, editing, and the final approval of the version to be published.

**Correspondence to:** Hakan Sofu, MD, Department of Orthopedics and Traumatology, Erzincan University Faculty of Medicine, 24030 Erzincan, Turkey. [hakansofu@yahoo.com](mailto:hakansofu@yahoo.com)

Telephone: +90-531-3657646 Fax: +90-446-2122200

Received: June 1, 2014 Revised: July 6, 2014

Accepted: September 4, 2014

Published online: November 16, 2014

the procedure that allows observation of the joint surfaces, provides the anatomical repair, maintains range of motion, and also can be applied with low rates of complications and recurrence. Although various surgical techniques have been described, a consensus does not exist and thus, orthopedic surgeons should follow and try to improve the current evidence-based treatment modalities for the patients.

© 2014 Baishideng Publishing Group Inc. All rights reserved.

**Key words:** Recurrent instability; Glenohumeral joint; Dislocation; Shoulder; Review

**Core tip:** Recurrent anterior instability of the shoulder is a complex disorder which mainly affects younger population, and generally requires surgical intervention to restore joint stability. Although many authors published good to excellent clinical results regarding various techniques described in the literature, a consensus on the ideal treatment modality has not been established yet. In this review article, we present an overview of recurrent anterior instability of the glenohumeral joint and discuss the treatment options with current concepts.

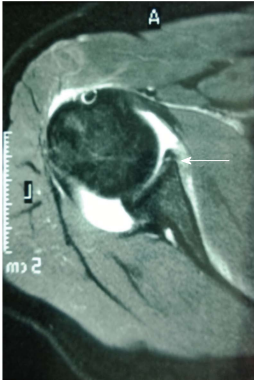
### Abstract

The purpose of this review article is to discuss the clinical spectrum of recurrent traumatic anterior shoulder instability with the current concepts and controversies at the scientific level. Because of increasing participation of people from any age group of the population in sports activities, health care professionals dealing with the care of trauma patients must have a thorough understanding of the anatomy, patho-physiology, risk factors, and management of anterior shoulder instability. The risk factors for recurrent shoulder dislocation are young age, participation in high demand contact sports activities, presence of Hill-Sachs or osseous Bankart lesion, previous history of ipsilateral traumatic dislocation, ipsilateral rotator cuff or deltoid muscle insufficiency, and underlying ligamentous laxity. Achieving the best result for any particular patient depends on

Sofu H, Gürsu S, Koçkara N, Öner A, Issin A, Çamurcu Y. Recurrent anterior shoulder instability: Review of the literature and current concepts. *World J Clin Cases* 2014; 2(11): 676-682 Available from: URL: <http://www.wjgnet.com/2307-8960/full/v2/i11/676.htm> DOI: <http://dx.doi.org/10.12998/wjcc.v2.i11.676>

### INTRODUCTION

Anterior glenohumeral dislocation during sports activities or social life is one of the most commonly seen pathologies in the clinical practice of orthopedic traumatology. The prevalence of anterior glenohumeral instability has been reported as 2%<sup>[1]</sup>. The glenohumeral joint has been



**Figure 1** The Bankart lesion on magnetic resonance imaging.

reported as the most commonly dislocated synovial joint of the human body<sup>[2]</sup>. Forced abduction and external rotation of the shoulder can cause anterior dislocation resulting in instability<sup>[3]</sup>. Participation in athletics can place exceptional demands on the musculoskeletal system, especially the shoulders of the ones who perform overhead activities<sup>[4]</sup>. Shoulder instability most commonly affects people who are in their late teens to mid-thirties<sup>[5]</sup>. A major problem following a primary traumatic anterior shoulder dislocation is the high risk of recurrence among young patients<sup>[6]</sup>. Rhee *et al.*<sup>[7]</sup> mentioned that these injuries occur at a younger age, with higher rates of recurrence, and with shorter intervals between initial injury and recurrent instability events among athletes. Because of increasing participation of people from any age group of the population in sports activities, health care professionals dealing with the care of trauma patients must have a thorough understanding of the anatomy, patho-physiology, risk factors, and management of anterior shoulder instability. Degenerative arthropathy in the shoulder joint is generally the final result of chronic instability<sup>[8]</sup>. The purpose of this review article is to discuss the clinical spectrum of recurrent traumatic anterior shoulder instability with the current concepts and controversies at the scientific level.

## FUNCTIONAL ANATOMY

Shoulder joint is a complex anatomical and biomechanical structure which functions in a manner that several stabilizers play role in a special harmony in different stages of motion. Stability of the shoulder is established by the glenohumeral articulation, labrum, glenohumeral ligaments, rotator cuff, and deltoid muscle. The contact surface of the humeral head with the glenoid is about 30%, which means that the joint has a limited osseous constraint so that the primary stability is due to other soft tissue components rather than the osseous contact<sup>[9]</sup>. This allows a very large range of motion but in turn, a predisposition to subluxation or dislocation as well. The anterior labrum plays a key role in anteroposterior stability as it deepens the glenoid cavity up to 50%<sup>[10]</sup>. Therefore, injuries causing detachment of the labrum from its original

anatomic location can cause recurrent anterior instability. A Bankart lesion, which is defined as the antero-inferior detachment of the glenoid labrum, was demonstrated in 87% to 100% of first-time dislocations<sup>[11-13]</sup> (Figure 1).

The superior, middle and inferior glenohumeral ligaments unite to form a soft tissue complex which functions as a static stabilizer for the joint. Each component of this ligamentous structure has its unique contribution to joint stability during different stages of motion. The coracohumeral ligament also functions synergistically with the superior glenohumeral ligament in resisting inferior translation of an adducted shoulder joint<sup>[14]</sup>. The middle and inferior glenohumeral ligaments provide anterior stability in different degrees of shoulder abduction and external rotation. The antero-inferior portion is the weakest part of the glenohumeral ligament complex in an abducted and externally rotated shoulder.

The deltoid muscle and the rotator cuff are named as the primary dynamic stabilizers which are active during shoulder motion in all axes<sup>[9]</sup>. The pathologies affecting the deltoid muscle and the rotator cuff not only cause decrease in range of motion of the shoulder joint but also disturbance of the biomechanical stability. Muscle weakness and/or imbalance of the dynamic stabilizers have been reported as leading to recurrent anterior shoulder instability<sup>[15-20]</sup>.

## CLINICAL EVALUATION

A detailed history and a careful physical examination of the patient are the primary steps of the clinical assessment. Mechanism of the first incident, time period from the first dislocation to recurrent instability, activities leading to recurrence or apprehension, number of dislocations, and history of reducibility without emergency visit should be noted for each patient. Schrupf *et al.*<sup>[14]</sup> mentioned the importance of distinguishing traumatic subluxation or dislocation and multidirectional instability, as the pathophysiologies and the treatment approaches of them were far different.

Physical examination is crucial in understanding the mechanism of recurrent dislocations. Comparative evaluation of both shoulders should be performed. Any visible deformity and/or muscle atrophy with respect to contralateral shoulder, or any scar tissue related to past trauma or surgery are important and simply recognizable just by a careful inspection. Active and passive range of motion in all planes should be measured and noted for both shoulders in every patient. Generalized ligamentous laxity should be kept in mind and checked in every patient. Axillary nerve examination should always be considered as critically important during clinical assessment. Apprehension and relocation tests as provocative examination are the fundamentals of clinical evaluation of any patient with a medical history of recurrent instability (Figure 2). Anterior apprehension test is performed with the shoulder in 90 degrees of abduction and the elbow in 90 degrees of flexion, with forced external rota-

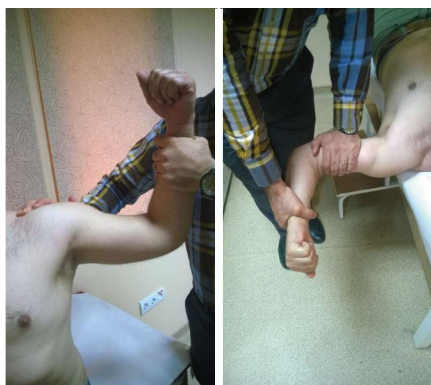

Figure 2 Apprehension and relocation tests.

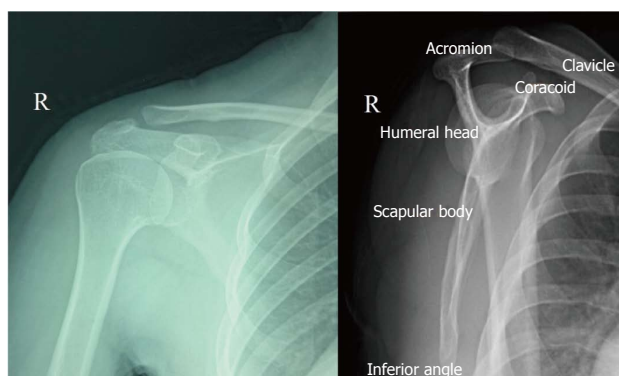


Figure 3 Anteroposterior shoulder view and scapular Y view radiographs.

tion applied to the extremity as anterior stress is applied to the humerus. Relocation test is performed while the patient is supine and the shoulder in 90 degrees of abduction and external rotation. Anterior stress is applied to the humerus in various degrees of abduction. When the pain or apprehension occurs, posterior-directed force is applied to relocate the humeral head. If the release of posteriorly directed stress used to relocate the humeral head produces a feeling of apprehension or subluxation, it indicates anterior instability. Laxity specific to lesions of inferior glenohumeral ligament can be distinguished by performing the hyperabduction test (Gagey's sign)<sup>[21]</sup>.

Anteroposterior, axillary lateral and scapular Y-view images are the primary routine radiographic evaluation tools in patients with recurrent instability (Figure 3). Different specific radiographic imaging techniques including apical oblique view, West point axillary view or Stryker notch view can also be valuable to detect particular pathologies related to patient's complaint. West point axillary view is used to evaluate for a glenoid rim fracture, whereas Stryker notch view is for Hill-Sachs lesion. However, a three-dimensional computed tomography is gold-standard technique to detect osseous pathologies as well as quantifying the degree of bone loss<sup>[22]</sup>. Magnetic resonance imaging (MRI) is a very useful tool in detecting soft tissue pathologies. Gadolinium-enhanced MRI is a minimally invasive and effective radiographic method to diagnose any capsular or labral damage pre-operatively.

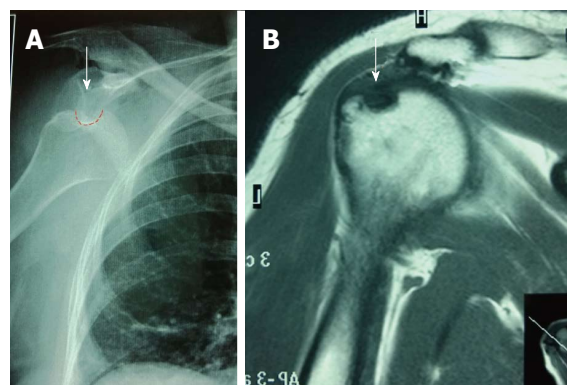


Figure 4 Engaging Hill-Sachs lesion leading to recurrent anterior instability (A) and Hill-Sachs lesion on magnetic resonance imaging (B).

## RISK FACTORS FOR RECURRENT INSTABILITY

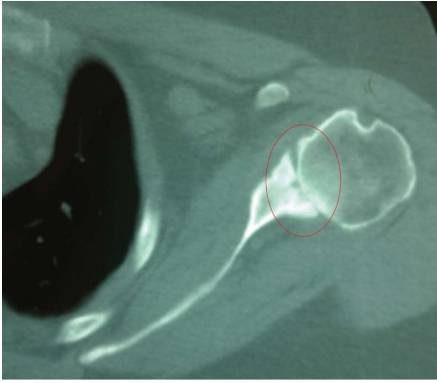
Many different risk factors for recurrent anterior shoulder dislocation such as young age, participation in high demand contact sports activities, previous history of ipsilateral traumatic dislocation, presence of Hill-Sachs or osseous Bankart lesion, ipsilateral rotator cuff or deltoid muscle insufficiency, and underlying ligamentous laxity have been described<sup>[1,23-30]</sup>. Ramsey *et al*<sup>[31]</sup> reported that traumatic anterior instability of the shoulder is associated with a high rate of recurrence in young patients. Marans *et al*<sup>[32]</sup> reported 100% redislocation rate in twenty-one skeletally immature patients who were treated with a sling.

According to Porcellini *et al*<sup>[33]</sup>, age at the time of the first dislocation, male sex, and the time from the first dislocation until surgery were significant risk factors for recurrence. However, in a prospective multicenter clinical study with twenty-five years of follow-up no significant differences with respect to gender could be demonstrated<sup>[34]</sup>. According to the results of a Level-I prospective cohort study subjects with a prior history of glenohumeral joint instability were approximately five times more likely to experience a subsequent instability event, regardless of direction<sup>[35]</sup>. Although glenoid bone loss is more common, engaging Hill-Sachs lesions can also be a cause of recurrent instability<sup>[36]</sup> (Figure 4). A Hill-Sachs lesion, which is defined as an osseous defect resulting from forceful impaction on the posterolateral side of the humeral head during anterior dislocation, was demonstrated as high as 90% to 100% of the patients with shoulder instability<sup>[11-13]</sup>. Hovelius *et al*<sup>[34]</sup> reported that immobilization was not found to be associated with the risk of redislocation.

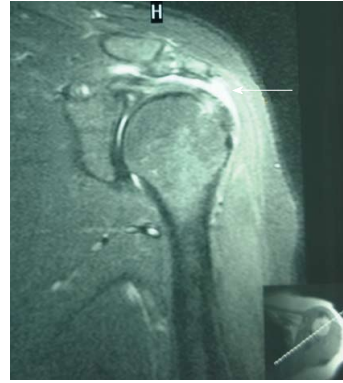## TREATMENT

Recurrent anterior shoulder instability resulted from an initial traumatic dislocation can be as serious as preventing an athlete from returning to sports. Without proper treatment, chronic instability generally results in a degen-





**Figure 5** Degenerative arthritis secondary to chronic instability.



**Figure 6** Rotator-cuff tear in a patient with recurrent anterior instability.

erative arthropathy in the shoulder joint (Figure 5). The common surgical interventions address the labral tears as well as the capsular laxity which are generally the basic underlying pathologies. Surgical repair of any accompanying rotator cuff tear should also be included in the treatment process (Figure 6). Although many different surgical techniques have been described to treat traumatic recurrent anterior instability of the shoulder, the best method still remains controversial. A successful clinical outcome basically requires an accurate surgical technique applied *via* adequate exposure. The main objective of the treatment should be considered as the most anatomical repair of the well defined pathological condition leading to recurrent instability. Achieving the best result for any particular patient depends on the procedure which allows observation of the joint surfaces, provides the anatomical repair, maintains range of motion, and also can be applied with low rates of complications and recurrence.

Open and arthroscopic procedures are treatment options in patients with traumatic recurrent anterior instability of the shoulder which is unresponsive to conservative measures. The arthroscopic treatment of glenohumeral instability requires that a level of expertise be achieved and retained<sup>[31]</sup>. Although open stabilization was reported as more effective than arthroscopic stabilization in the aspect of post-operative recurrence rates in 1990s, clinical outcomes have become similar in time. Technological improvements in arthroscopic instrumentation as well as the development of the innovative surgical techniques as a result of the cumulative experience with improved understanding of the factors leading failure in such patients have played the key role<sup>[24,33,37-43]</sup>. In their prospective randomized study, Fabbriani *et al*<sup>[41]</sup> reported equal results between arthroscopic and open surgical repair of Bankart lesion in the aspect of recurrence. According to the results of another recent prospective randomized clinical trial comparing open and arthroscopic techniques, the difference in quality of life between the patients in the two groups was neither significant nor clinically important at two years follow-up; however significantly lower risk of recurrence was obtained in patients for whom open repair was preferred<sup>[5]</sup>. Surgical treatment of athletes participating in contact sports is still controversial.

Rhee *et al*<sup>[44]</sup> compared the results of arthroscopic and open stabilization in young contact athletes and reported recurrent instability as 25% in the arthroscopic group and 13% in the open stabilization group. Some authors mentioned that athletic activity plays a greater role in post-operative recurrence than the surgical method used for stabilization<sup>[39,45]</sup>.

Bone loss either on the glenoid or the humeral head may cause or complicate recurrent shoulder dislocations. Recurrent episodes of anterior instability of the shoulder joint may cause Hill-Sachs or osseous Bankart lesion get larger which leads further instability<sup>[46,47]</sup>. Therefore, isolated Bankart repair is generally not sufficient as the surgical management of the patients with osseous lesions. In their study which evaluates the morphology of the glenoid cavity in patients with recurrent anterior instability of the shoulder, Sugaya *et al*<sup>[48]</sup> concluded that 10% of subjects did not have osseous pathology, 40% had bony erosion, and 50% had an osseous Bankart lesion. If bone loss is greater than 25% of the glenoid surface, surgical treatment should include a bony reconstruction procedure<sup>[49]</sup>. Ideal technique for the surgical management of bony defects on the glenoid rim is controversial. Reduction and fixation of the displaced glenoid rim fracture, transfer of the coracoid process to the anterior glenoid, and reconstruction by using autograft or allograft bone block are the methods to restore the normal width and depth of the glenoid cavity. Basically, all of the various surgical interventions aim to restore more anatomic glenoid morphology to prevent recurrent instability. Park *et al*<sup>[50]</sup> reported that following successful fixation of the glenoid fracture in its anatomic position, fragments unite and survive without resorption at one year. When the bone loss is greater than 25% of the glenoid surface with a missing fragment, transfer of the coracoid process to the anterior glenoid rim as a structural block is the best approach. Bristow, Latarjet, or Trillat procedures are effective, most widely known and used techniques of coracoid transfer into the glenoid lesion. Latarjet procedure, which was first described in 1954, is the transfer of the coracoid process through the subscapularis tendon to provide an osseous block during joint motion. Bristow procedure is the technique in which the terminal 1 cm



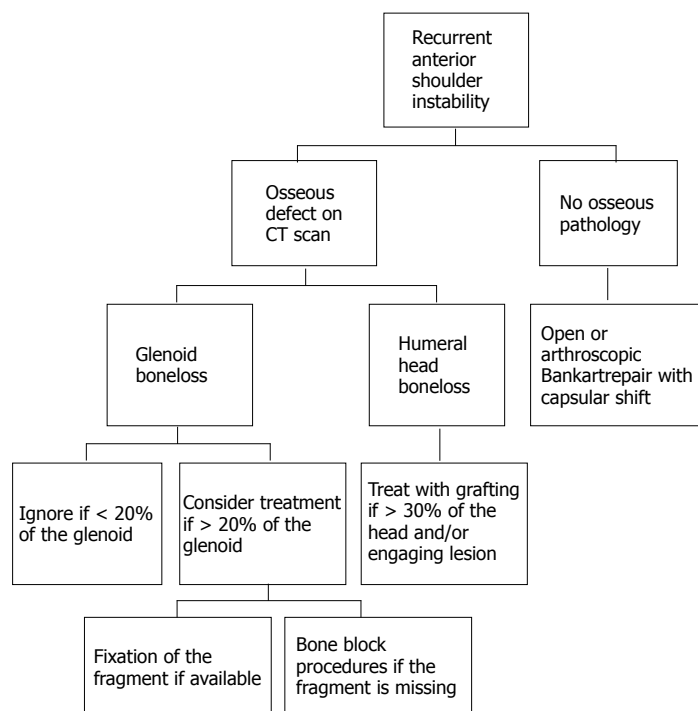


Figure 7 Treatment algorithm that we follow in our clinical practice.

of the coracoid is transferred together with the conjoint tendon onto the neck of the scapula through a horizontal slit in the subscapularis muscle. In Trillat procedure, the coracoid is osteotomized following an arthrotomy, then it is displaced and fixed with a coracoscapular screw. Burkhart *et al*<sup>[51]</sup> reported that no recurrent instability was detected at a mean follow-up of 4.9 years following coracoid transfer performed in forty-seven patients. The Latarjet procedure, also as a revision to manage recurrence of anterior shoulder instability after previous operative repair associated with defects of the anterior glenoid rim and an intact subscapularis muscle, was reported as satisfactorily restoring glenohumeral stability<sup>[52]</sup>. Warner *et al*<sup>[53]</sup> and Scheibel *et al*<sup>[54]</sup> evaluated recurrence of the anterior instability following anterior glenoid augmentation by using iliac crest bone autograft and they reported no evidence of recurrent instability in their series.

Burkhart *et al*<sup>[24]</sup> used the term “engaging Hill-Sachs lesion” to describe a compression fracture on the posterosuperior aspect of the humeral head which drops over the glenoid rim in external rotation of an abducted shoulder and is associated with recurrent instability. Tenodesis of the infraspinatus into the lesion which is also called “remplissage” and bone grafting of the defect are the surgical interventions described to address the osseous defect on the humeral head. Boileau *et al*<sup>[55]</sup> reported that arthroscopic Hill-Sachs remplissage procedure in combination with Bankart repair in the treatment of patients with a large bony defect on the humeral head was an effective method. The authors also concluded that 98% of the patients had a stable shoulder joint at the latest follow-up with approximately 10 degrees of restriction in external rotation which did not significantly affect return to sports activity. An *in-vitro* study evaluating biomechanical effects of remplissage showed that

in specimens with a 30% Hill-Sachs lesion it prevented engagement of the lesion<sup>[56]</sup>. Bone grafting can also be applied as another treatment option for defects of the humeral head. Osteoarticular plugs and osteoarticular humeral head allograft are the options for large diameter lesions<sup>[36,57]</sup>. Collapse or resorption of the graft should be kept in mind as an important risk factor which may lead to failure in such cases.

There are various techniques addressing different pathologies of both the soft tissues and bones which generally unite to form a complex disease process. Therefore, when dealing with the clinical management of recurrent anterior instability of the shoulder joint, one should always carefully analyze the patient-specific pathologies and consider treatment options according to the needs of every particular case. In this regard, a guideline is generally needed. Figure 7 demonstrates the algorithm that we use in the management of patients with recurrent anterior instability of the shoulder joint.

## CONCLUSION

Anterior shoulder instability is among the most commonly seen disorders in traumatology, which typically affects the younger age population with high rates of recurrence. Recurrent anterior instability of the shoulder is a complex disease which may include both soft tissue and osseous pathologies. Primary clinical approach should be the combination of a careful medical history, a detailed physical examination, and appropriate imaging studies to recognize changes leading to recurrence. Although various surgical techniques have been described, a consensus does not exist and thus, surgeons should select the most effective procedure to restore joint stability in a patient-specific manner.

## REFERENCES

- 1 **Hovelius L**, Augustini BG, Fredin H, Johansson O, Norlin R, Thorling J. Primary anterior dislocation of the shoulder in young patients. A ten-year prospective study. *J Bone Joint Surg Am* 1996; **78**: 1677-1684 [PMID: 8934481]
- 2 **Dodson CC**, Cordasco FA. Anterior glenohumeral joint dislocations. *Orthop Clin North Am* 2008; **39**: 507-518, vii [PMID: 18803980 DOI: 10.1016/j.ocl.2008.06.001]
- 3 **Kaplan LD**, Flanigan DC, Norwig J, Jost P, Bradley J. Prevalence and variance of shoulder injuries in elite collegiate football players. *Am J Sports Med* 2005; **33**: 1142-1146 [PMID: 16002483]
- 4 **Taylor DC**, Krasinski KL. Adolescent shoulder injuries: consensus and controversies. *J Bone Joint Surg Am* 2009; **91**: 462-473 [PMID: 19181993]
- 5 **Mohtadi NG**, Chan DS, Hollinshead RM, Boorman RS, Hiemstra LA, Lo IK, Hannaford HN, Fredine J, Sasyniuk TM, Paolucci EO. A randomized clinical trial comparing open and arthroscopic stabilization for recurrent traumatic anterior shoulder instability: two-year follow-up with disease-specific quality-of-life outcomes. *J Bone Joint Surg Am* 2014; **96**: 353-360 [PMID: 24599195 DOI: 10.2106/JBJS.L.01656]
- 6 **Liavaag S**, Brox JL, Pripp AH, Enger M, Soldal LA, Svenningsen S. Immobilization in external rotation after primary shoulder dislocation did not reduce the risk of recurrence: a randomized controlled trial. *J Bone Joint Surg Am* 2011; **93**: 897-904 [PMID: 21498489 DOI: 10.2106/JBJS.J.00416]
- 7 **Rhee YG**, Cho NS, Cho SH. Traumatic anterior dislocation of the shoulder: factors affecting the progress of the traumatic anterior dislocation. *Clin Orthop Surg* 2009; **1**: 188-193 [PMID: 19956475 DOI: 10.4055/cios.2009.1.4.188]
- 8 **Hovelius L**, Saeboe M. Neer Award 2008: Arthropathy after primary anterior shoulder dislocation--223 shoulders prospectively followed up for twenty-five years. *J Shoulder Elbow Surg* 2009; **18**: 339-347 [PMID: 19254851 DOI: 10.1016/j.jse.2008.11.004]
- 9 **Bigliani LU**, Kelkar R, Flatow EL, Pollock RG, Mow VC. Glenohumeral stability. Biomechanical properties of passive and active stabilizers. *Clin Orthop Relat Res* 1996; **330**: 13-30 [PMID: 8804270]
- 10 **Howell SM**, Galinat BJ. The glenoid-labral socket. A constrained articular surface. *Clin Orthop Relat Res* 1989; **243**: 122-125 [PMID: 2721051]
- 11 **Taylor DC**, Arciero RA. Pathologic changes associated with shoulder dislocations. Arthroscopic and physical examination findings in first-time, traumatic anterior dislocations. *Am J Sports Med* 1997; **25**: 306-311 [PMID: 9167808]
- 12 **Baker CL**, Uribe JW, Whitman C. Arthroscopic evaluation of acute initial anterior shoulder dislocations. *Am J Sports Med* 1990; **18**: 25-28 [PMID: 2301687]
- 13 **Norlin R**. Intraarticular pathology in acute, first-time anterior shoulder dislocation: an arthroscopic study. *Arthroscopy* 1993; **9**: 546-549 [PMID: 7818617]
- 14 **Schrumpf MA**, Maak TG, Delos D, Jones KJ, Dines DM, Walch G, Dines JS. The management of anterior glenohumeral instability with and without bone loss: AAOS exhibit selection. *J Bone Joint Surg Am* 2014; **96**: e12 [PMID: 24430421 DOI: 10.2106/JBJS.L.01377]
- 15 **Levine WN**, Flatow EL. The pathophysiology of shoulder instability. *Am J Sports Med* 2000; **28**: 910-917 [PMID: 11101119]
- 16 **Myers JB**, Lephart SM. The role of the sensorimotor system in the athletic shoulder. *J Athl Train* 2000; **35**: 351-363 [PMID: 16558648]
- 17 **Rupp S**, Berninger K, Hopf T. Shoulder problems in high level swimmers--impingement, anterior instability, muscular imbalance? *Int J Sports Med* 1995; **16**: 557-562 [PMID: 8776212]
- 18 **Forthomme B**, Willems S, Hurlet S, Berger JP, Houben G, Croisier J-L. Shoulder isokinetic profile after Latarjet's technique. *Isokinet Exerc Sci* 2005; **13**: 71-76
- 19 **Tsai L**, Wredmark T, Johansson C, Gibo K, Engström B, Törnqvist H. Shoulder function in patients with unoperated anterior shoulder instability. *Am J Sports Med* 1991; **19**: 469-473 [PMID: 1962711]
- 20 **Ellenbecker TS**, Davies GJ. The application of isokinetics in testing and rehabilitation of the shoulder complex. *J Athl Train* 2000; **35**: 338-350 [PMID: 16558647]
- 21 **Gagey OJ**, Gagey N. The hyperabduction test. *J Bone Joint Surg Br* 2001; **83**: 69-74 [PMID: 11245541]
- 22 **Saito H**, Itoi E, Sugaya H, Minagawa H, Yamamoto N, Tuoheti Y. Location of the glenoid defect in shoulders with recurrent anterior dislocation. *Am J Sports Med* 2005; **33**: 889-893 [PMID: 15827355]
- 23 **Arciero RA**, Wheeler JH, Ryan JB, McBride JT. Arthroscopic Bankart repair versus nonoperative treatment for acute, initial anterior shoulder dislocations. *Am J Sports Med* 1994; **22**: 589-594 [PMID: 7810780]
- 24 **Burkhart SS**, De Beer JF. Traumatic glenohumeral bone defects and their relationship to failure of arthroscopic Bankart repairs: significance of the inverted-pear glenoid and the humeral engaging Hill-Sachs lesion. *Arthroscopy* 2000; **16**: 677-694 [PMID: 11027751]
- 25 **Robinson CM**, Kelly M, Wakefield AE. Redislocation of the shoulder during the first six weeks after a primary anterior dislocation: risk factors and results of treatment. *J Bone Joint Surg Am* 2002; **84-A**: 1552-1559 [PMID: 12208911]
- 26 **Hawkins RH**, Hawkins RJ. Failed anterior reconstruction for shoulder instability. *J Bone Joint Surg Br* 1985; **67**: 709-714 [PMID: 4055865]
- 27 **Pagnani MJ**, Dome DC. Surgical treatment of traumatic anterior shoulder instability in american football players. *J Bone Joint Surg Am* 2002; **84-A**: 711-715 [PMID: 12004010]
- 28 **Bacilla P**, Field LD, Savoie FH. Arthroscopic Bankart repair in a high demand patient population. *Arthroscopy* 1997; **13**: 51-60 [PMID: 9043604]
- 29 **Zaffagnini S**, Marcheggiani Muccioli GM, Giordano G, Bonanzinga T, Grassi A, Nitri M, Bruni D, Ravazzolo G, Marcacci M. Long-term outcomes after repair of recurrent post-traumatic anterior shoulder instability: comparison of arthroscopic transglenoid suture and open Bankart reconstruction. *Knee Surg Sports Traumatol Arthrosc* 2012; **20**: 816-821 [PMID: 21932077 DOI: 10.1007/s00167-011-1674-y]
- 30 **O'Neill DB**. Arthroscopic Bankart repair of anterior detachments of the glenoid labrum. A prospective study. *J Bone Joint Surg Am* 1999; **81**: 1357-1366 [PMID: 10535586]
- 31 **Ramsey ML**, Getz CL, Parsons BO. What's new in shoulder and elbow surgery. *J Bone Joint Surg Am* 2010; **92**: 1047-1061 [PMID: 20360533 DOI: 10.2106/JBJS.J.00072]
- 32 **Marans HJ**, Angel KR, Schemitsch EH, Wedge JH. The fate of traumatic anterior dislocation of the shoulder in children. *J Bone Joint Surg Am* 1992; **74**: 1242-1244 [PMID: 1400553]
- 33 **Porcellini G**, Campi F, Pegreff F, Castagna A, Paladini P. Predisposing factors for recurrent shoulder dislocation after arthroscopic treatment. *J Bone Joint Surg Am* 2009; **91**: 2537-2542 [PMID: 19884424 DOI: 10.2106/JBJS.H.01126]
- 34 **Hovelius L**, Olofsson A, Sandström B, Augustini BG, Krantz L, Fredin H, Tillander B, Skoglund U, Salomonsson B, Nowak J, Sannerby U. Nonoperative treatment of primary anterior shoulder dislocation in patients forty years of age and younger. a prospective twenty-five-year follow-up. *J Bone Joint Surg Am* 2008; **90**: 945-952 [PMID: 18451384 DOI: 10.2106/JBJS.G.00070]
- 35 **Cameron KL**, Mountcastle SB, Nelson BJ, DeBerardino TM, Duffey ML, Svoboda SJ, Owens BD. After radiation for DCIS, no increase in cardiovascular mortality, morbidity. *Oncology (Williston Park)* 2013; **27**: 1044 [PMID: 24367867 DOI: 10.2106/JBJS.L.00252]

- 36 **Miniaci A**, Gish MW. Management of anterior glenohumeral instability associated with large Hill-Sachs defects. *Tech Shoulder Elbow Surg* 2004; **5**: 170-175
- 37 **Guanche CA**, Quick DC, Sodergren KM, Buss DD. Arthroscopic versus open reconstruction of the shoulder in patients with isolated Bankart lesions. *Am J Sports Med* 1996; **24**: 144-148 [PMID: 8775110]
- 38 **Geiger DF**, Hurley JA, Tovey JA, Rao JP. Results of arthroscopic versus open Bankart suture repair. *Clin Orthop Relat Res* 1997; **337**: 111-117 [PMID: 9137182]
- 39 **Cole BJ**, L'Insalata J, Irrgang J, Warner JJ. Comparison of arthroscopic and open anterior shoulder stabilization. A two to six-year follow-up study. *J Bone Joint Surg Am* 2000; **82-A**: 1108-1114 [PMID: 10954100]
- 40 **Kim SH**, Ha KI, Kim SH. Bankart repair in traumatic anterior shoulder instability: open versus arthroscopic technique. *Arthroscopy* 2002; **18**: 755-763 [PMID: 12209434]
- 41 **Fabbriciani C**, Milano G, Demontis A, Fadda S, Ziranu F, Mulas PD. Arthroscopic versus open treatment of Bankart lesion of the shoulder: a prospective randomized study. *Arthroscopy* 2004; **20**: 456-462 [PMID: 15122134]
- 42 **Tjoumakaris FP**, Abboud JA, Hasan SA, Ramsey ML, Williams GR. Arthroscopic and open Bankart repairs provide similar outcomes. *Clin Orthop Relat Res* 2006; **446**: 227-232 [PMID: 16467628]
- 43 **Lenters TR**, Franta AK, Wolf FM, Leopold SS, Matsen FA. Arthroscopic compared with open repairs for recurrent anterior shoulder instability. A systematic review and meta-analysis of the literature. *J Bone Joint Surg Am* 2007; **89**: 244-254 [PMID: 17272436]
- 44 **Rhee YG**, Ha JH, Cho NS. Anterior shoulder stabilization in collision athletes: arthroscopic versus open Bankart repair. *Am J Sports Med* 2006; **34**: 979-985 [PMID: 16436537]
- 45 **Owens BD**, DeBerardino TM, Nelson BJ, Thurman J, Cameron KL, Taylor DC, Uhorchak JM, Arciero RA. Long-term follow-up of acute arthroscopic Bankart repair for initial anterior shoulder dislocations in young athletes. *Am J Sports Med* 2009; **37**: 669-673 [PMID: 19218560 DOI: 10.1177/0363546508328416]
- 46 **Cetik O**, Uslu M, Ozsar BK. The relationship between Hill-Sachs lesion and recurrent anterior shoulder dislocation. *Acta Orthop Belg* 2007; **73**: 175-178 [PMID: 17515227]
- 47 **Kralinger FS**, Golser K, Wischatta R, Wambacher M, Sperner G. Predicting recurrence after primary anterior shoulder dislocation. *Am J Sports Med* 2002; **30**: 116-120 [PMID: 11799007]
- 48 **Sugaya H**, Moriishi J, Dohi M, Kon Y, Tsuchiya A. Glenoid rim morphology in recurrent anterior glenohumeral instability. *J Bone Joint Surg Am* 2003; **85-A**: 878-884 [PMID: 12728039]
- 49 **Mologne TS**, Provencher MT, Menzel KA, Vachon TA, Dewing CB. Arthroscopic stabilization in patients with an inverted pear glenoid: results in patients with bone loss of the anterior glenoid. *Am J Sports Med* 2007; **35**: 1276-1283 [PMID: 17387219]
- 50 **Park JY**, Lee SJ, Lhee SH, Lee SH. Follow-up computed tomography arthrographic evaluation of bony Bankart lesions after arthroscopic repair. *Arthroscopy* 2012; **28**: 465-473 [PMID: 22265046 DOI: 10.1016/j.arthro.2011.09.008]
- 51 **Burkhart SS**, De Beer JF, Barth JR, Cresswell T, Roberts C, Richards DP. Results of modified Latarjet reconstruction in patients with anteroinferior instability and significant bone loss. *Arthroscopy* 2007; **23**: 1033-1041 [PMID: 17916467]
- 52 **Schmid SL**, Farshad M, Catanzaro S, Gerber C. The Latarjet procedure for the treatment of recurrence of anterior instability of the shoulder after operative repair: a retrospective case series of forty-nine consecutive patients. *J Bone Joint Surg Am* 2012; **94**: e75 [PMID: 22637215 DOI: 10.2106/JBJS.K.00380]
- 53 **Warner JJ**, Gill TJ, O'hollerhan JD, Pathare N, Millett PJ. Anatomical glenoid reconstruction for recurrent anterior glenohumeral instability with glenoid deficiency using an autogenous tricortical iliac crest bone graft. *Am J Sports Med* 2006; **34**: 205-212 [PMID: 16303879]
- 54 **Scheibel M**, Nikulka C, Dick A, Schroeder RJ, Gerber Popp A, Haas NP. Autogenous bone grafting for chronic antero-inferior glenoid defects via a complete subscapularis tenotomy approach. *Arch Orthop Trauma Surg* 2008; **128**: 1317-1325 [PMID: 18196255 DOI: 10.1007/s00402-007-0560-z]
- 55 **Boileau P**, O'Shea K, Vargas P, Pinedo M, Old J, Zumstein M. Anatomical and functional results after arthroscopic Hill-Sachs remplissage. *J Bone Joint Surg Am* 2012; **94**: 618-626 [PMID: 22488618 DOI: 10.2106/JBJS.K.00101]
- 56 **Elkinson I**, Giles JW, Faber KJ, Boons HW, Ferreira LM, Johnson JA, Athwal GS. The effect of the remplissage procedure on shoulder stability and range of motion: an in vitro biomechanical assessment. *J Bone Joint Surg Am* 2012; **94**: 1003-1012 [PMID: 22637206 DOI: 10.2106/JBJS.J.01956]
- 57 **DiPaola MJ**, Jazrawi LM, Rokito AS, Kwon YW, Patel L, Pahk B, Zuckerman JD. Management of humeral and glenoid bone loss--associated with glenohumeral instability. *Bull NYU Hosp Jt Dis* 2010; **68**: 245-250 [PMID: 21162700]

P- Reviewer: Ertem K, Swanik C S- Editor: Ji FF L- Editor: A  
E- Editor: Lu YJ



## Evaluation of anatomical considerations in the posterior maxillae for sinus augmentation

Ji-Eun Lee, Seong-Ho Jin, Youngkyung Ko, Jun-Beom Park

Ji-Eun Lee, Seong-Ho Jin, Youngkyung Ko, Jun-Beom Park, Department of Periodontics, College of Medicine, The Catholic University of Korea, Seoul 137-701, South Korea

**Author contributions:** Lee JE and Ko Y contributed to the conception, critical assessment of the relevant literature, providing intellectual content of critical importance to the work and final approval of version to be submitted; Jin SH contributed to the critical assessment of the relevant literature, providing intellectual content of critical importance to the work and final approval of version to be submitted; Park JB contributed to the conception, critical assessment of the relevant literature, revising the article, providing intellectual content of critical importance to the work and final approval of version to be submitted.

**Supported by** Basic Science Research Program through the National Research Foundation of Korea (NRF) funded by the Ministry of Science, ICT and Future Planning, No. NRF-2014R1A1A1003106

**Correspondence to:** Jun-Beom Park, DDS, MSD, PhD, Department of Periodontics, College of Medicine, The Catholic University of Korea, 222 Banpo-daero, Seocho-gu, Seoul 137-701, South Korea. [jbassoonis@yahoo.co.kr](mailto:jbassoonis@yahoo.co.kr)

Telephone: +82-2-22586290 Fax: +82-2-5372374

Received: April 8, 2014 Revised: July 15, 2014

Accepted: September 6, 2014

Published online: November 16, 2014

the structures of the maxillary sinus during sinus augmentation. These anatomical findings can help in complications and potential injuries of the maxillary sinus procedures. It can be suggested that pre-operative evaluation is helpful for diagnosis and treatment planning and minimizing complication during the surgery.

© 2014 Baishideng Publishing Group Inc. All rights reserved.

**Key words:** Anatomy; Intraoperative complications; Sinus floor augmentation

**Core tip:** The edentulous posterior maxilla is considered a clinical challenge during dental implant treatment. Sinus augmentation and bone augmentation are used to overcome these problems. Maxillary sinus septa have been related to increased risk of perforation of the membrane during sinus augmentation. The lateral window design may be modified by the making of two windows or one w-shape window if the septum is lower. The branches of the maxillary artery should be taken into consideration to avoid bleeding complications. It can be suggested that pre-operative evaluation is helpful for diagnosis and treatment planning and minimizing complication during the surgery.

### Abstract

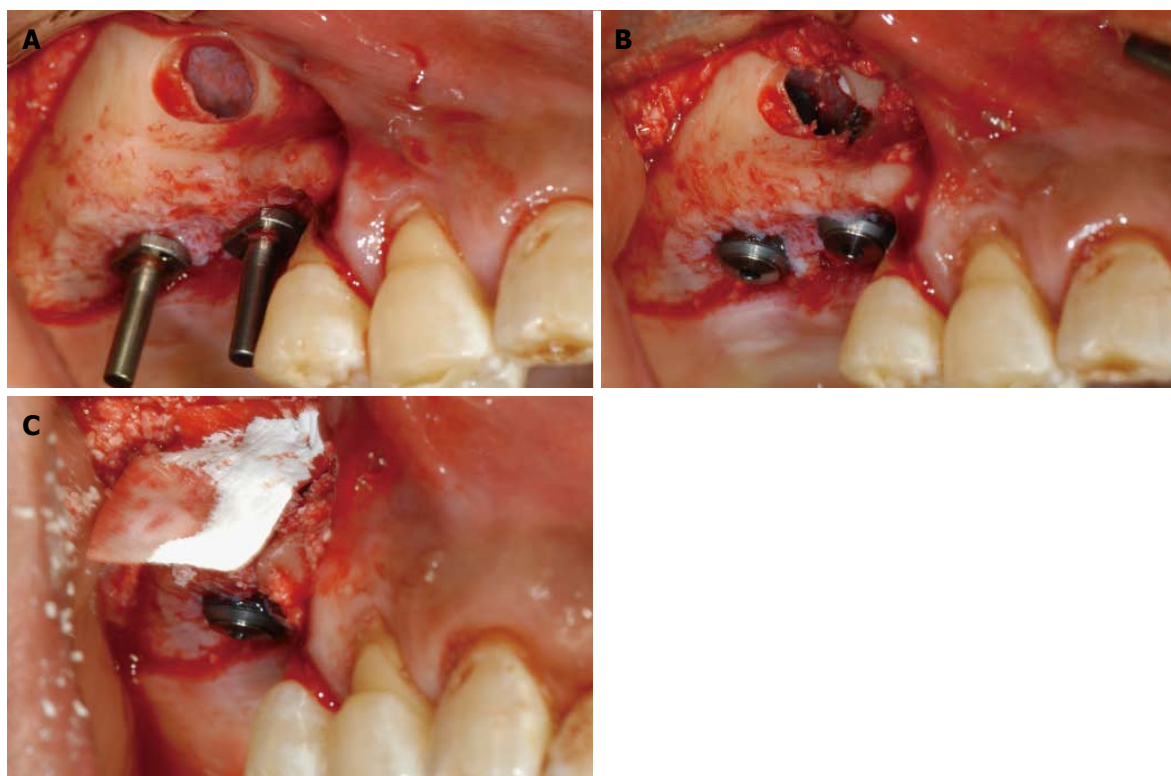
The edentulous posterior maxilla is considered a clinical challenge during dental implant treatment for many dental practitioners. This is because its insufficient bone quality, deficient alveolar ridge, spiny ridges, undercuts, and sinus pneumatization are often encountered after tooth loss. To overcome these problems, several approaches have been developed and are currently used, including sinus augmentation and bone augmentation. Today, two main procedures of sinus floor elevation for dental implant placement are in use: a two-stage technique using the lateral window approach, and a one-stage technique using a lateral or a crestal approach. In this study, we deal with the anatomic relations of

Lee JE, Jin SH, Ko Y, Park JB. Evaluation of anatomical considerations in the posterior maxillae for sinus augmentation. *World J Clin Cases* 2014; 2(11): 683-688 Available from: URL: <http://www.wjgnet.com/2307-8960/full/v2/i11/683.htm> DOI: <http://dx.doi.org/10.12998/wjcc.v2.i11.683>

### INTRODUCTION

For many dental practitioners, the edentulous posterior maxilla is considered a clinical challenge during dental implant treatment<sup>[1]</sup>. This is because its insufficient bone quality, deficient alveolar ridge, spiny ridges, undercuts,





**Figure 1 Buccal and clinical view.** A: Buccal view after elevation of sinus membrane; B: Buccal view after installation of dental implants; C: Clinical view after application of graft material.

and sinus pneumatization are often encountered after tooth loss. Several approaches have been developed and are currently used to overcome these problems, two of them being sinus augmentation and bone augmentation<sup>[2,3]</sup>. Elevation of the maxillary sinus floor was first published by Boyne *et al*<sup>[4]</sup> in 1980. After these reports, several techniques were reported for successful sinus floor elevation, including crestal and transalveolar approaches<sup>[5,6]</sup>. A crestal approach uses the osteotome technique introduced by Summers in 1994<sup>[5]</sup>. Today, dental practitioners use two main procedures of sinus floor elevation for dental implant placement: a two-stage technique using the lateral window approach, and a one-stage technique using a lateral or a crestal approach (Figure 1)<sup>[7]</sup>.

In this report, we have reviewed anatomical consideration in the posterior maxillae for sinus augmentation, to ensure predictable sinus graft surgery and help decide surgical technique with minimum complication. Pre-operative evaluation seems necessary for implant surgery to succeed without complication.

## ANATOMY OF MAXILLARY SINUS

Before performing sinus augmentation surgery, it is crucial to understand the anatomy of maxillary sinus. The function of the maxillary sinus is not yet well known. Theories on its physiologic function include: (1) weight reduction to maintain equipoise of the head; (2) protection of intracranial structures; (3) thermal insulation of vital parts; (4) humidification and warming of inhaled air;

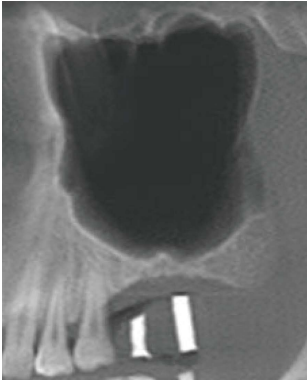
(5) secretion of mucus to moisten the nasal cavity; (6) secretion of mucus to moisten the nasal cavity; (7) increasing the area for olfaction; and (8) imparting resonance to the voice<sup>[8]</sup>.

The maxillary sinus is the largest and most constant of the paranasal sinuses. After birth, it undergoes two periods of rapid growth, first between birth and 3 years since, and then between ages 7 and 18 years<sup>[9]</sup>. The maxillary sinus has a pyramidal shape, with an anterior wall corresponding to the facial surface of the maxilla. Its posterior bony wall separates it from the pterygomaxillary fossa medially and from the infratemporal fossa laterally. Its medial wall is the lateral nasal wall and separates the sinus from the nasal cavity and communicates with the nasal cavity *via* the ostium semilunaris to the hiatus semilunaris (middle meatus)<sup>[10]</sup>. The ostium of the maxillary sinus is high up on the medial wall and on average is 2.4 mm in diameter<sup>[10]</sup>.

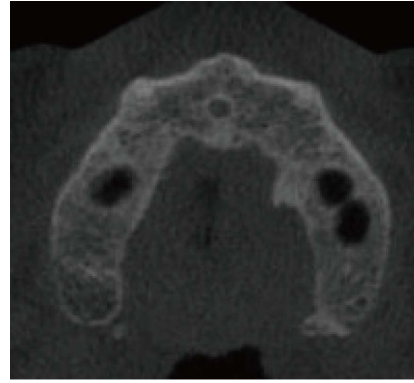
The Maxillary sinus floor consists of the alveolar process of the maxilla. The sinus floor is usually convex, with its lowest point around the first and second upper molars<sup>[11]</sup>. As aging occurs, the sinus floor tends to resorb and form dehiscences around the roots<sup>[12]</sup>. The root ends may jut into the cavity, covered only by the Schneiderian membrane and a small bone cortex flap<sup>[13]</sup>.

## SINUS PNEUMATIZATION AND RESIDUAL BONE RESORPTION

Maxillary sinus pneumatization is a physiologic process



**Figure 2** Panoramic view from cone beam computed tomography showing septum.



**Figure 3** Axial view from cone beam computed tomography with septum on left maxillary sinus.

that occurs in all paranasal sinuses during the growth period, causing them to increase in volume<sup>[14]</sup>. The reasons for sinus pneumatization are poorly understood, but factors that cause this process include heredity, the pneumatization drive of the nose's mucous membrane, craniofacial configuration, density of the bone, growth hormones, sinus air pressure, sinus surgery, and posterior tooth extraction<sup>[15]</sup>. According to a radiographic study, pneumatization was more significant after extraction of teeth enveloped by a superiorly curving sinus floor, extraction of several adjacent posterior teeth, and extraction of second molars as opposed to first molars<sup>[15]</sup>.

Residual ridge resorption following tooth extraction is unavoidable process in posterior maxillary area. Extensive ridge resorption is one of the many problems for implant-prosthetic treatment in the posterior maxillae. Although resorption rate is subject to individual variability and almost resorption occurs in 6 mo after extraction, the alveolar ridge resorption persists for subsequent years to decades<sup>[16,17]</sup>.

Available alveolar bone may be compromised in the in the posterior maxillae may be compromised because of sinus pneumatization and/or residual ridge resorption after tooth loss. The average height of the available bone in the edentulous maxilla was classified into three classes<sup>[14]</sup>. Class 1 had a residual bone height of 10 mm, usually found in edentulism of no more than 5 years' standing. Class 2 had a residual bone height of 5-10 mm, usually found in edentulism of 5-10 years. Class 3 indicated a bone height of 0-5 mm, usually found in edentulism of more than 10 years. A previous report has recommended that sinus augmentation be performed in classes 2 and 3. If the implant with 10 mm length is planned, sinus augmentation should be considered in Classes 2 and 3.

## SEPTA OF THE MAXILLARY SINUS

Maxillary sinus septa are barriers of cortical bone that divide the maxillary sinus into multiple compartments, known as recesses. Diagnosis of septa presence by computed tomography is important for planning maxillary sinus elevation surgery and later separating the sinus

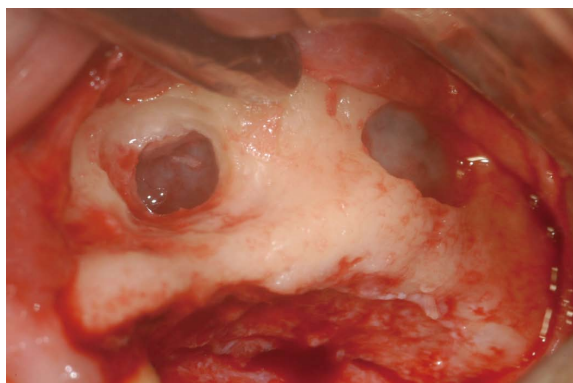
membrane from the septa (Figures 2 and 3)<sup>[18]</sup>. Septa have become increasingly important in maxillary sinus anatomy as surgical technique has developed. The cause of antral septa has been described previously<sup>[19]</sup>. Congenital septa are thought to have evolved during the growth of the middle part of the face, and the other, secondary septa are reported to be arisen from irregular pneumatization of the sinus floor after tooth extraction. Other reports classify septa as primary septa if they are located above the maxillary tooth and as other septa if they are located above an edentulous ridge, since septa may be either primary or secondary, or a combination of both types<sup>[20,21]</sup>.

A previous report has showed that septa are significantly higher in the atrophic sinus than in the dentate maxillae, and septa are more commonly located in the molar regions than in the premolar and retromolar areas<sup>[22]</sup>. Prevalence of sinus septa is between 20% and 35%<sup>[19,23]</sup>, and the mean height of septa is 7.5 mm<sup>[22]</sup>. Diagnosis using two-dimensional panoramic radiographs yields incorrect results in 29% of cases, and it has been suggested that three-dimensional computed tomography may be used to avoid complications during sinus augmentation<sup>[22]</sup>.

The septum has been related to increased risk of perforation of the membrane during sinus augmentation<sup>[24,25]</sup>. The lateral window design may be modified by the making of two windows or one w-shape window if the septum is lower (Figure 4). Septa may be cut with a chisel and be removed so that the graft can be placed without interruption<sup>[20]</sup>.

## VASCULAR SYSTEM OF THE MAXILLARY SINUS

The blood supply of the maxillary sinus is derived from three arteries: the infra-orbital artery, the posterior lateral nasal artery, and the posterior superior alveolar artery<sup>[26,27]</sup>. Among these arteries, the posterior superior alveolar artery and the infra-orbital artery supply the buccal part of the maxillary sinus, and they also supply local oral mucosa as well as the mucous membrane in a double



**Figure 4** Buccal view showing lateral window design having two windows.

arterial circle<sup>[28]</sup>. The posterior superior alveolar artery enters the pterygopalatine fossa, and divides into one extraosseous and one intraosseous branch, which enter the maxillary tuberosity<sup>[29]</sup>. To prevent damage to the extraosseous anastomosis, it is crucial to analyze its height from the cortical bone, its diameter, and the course of the artery. The anastomosis forms a concave arch at the first molar, and that is the lowest point of the bony canal's arch course, and the mean distance between the bone crest and the canal is 19 mm<sup>[26,30]</sup>. An intraosseous vascular canal at the lateral antral wall has been found in over 50% of cases<sup>[28]</sup>. To avoid bleeding complications, the branches of the maxillary artery should be taken into consideration.

## SCHNEIDERIAN MEMBRANE

The Schneiderian membrane lines the inner walls of the sinus, which is represented by ciliated columnar cells, goblet cells, and basal cells resting on the basement membrane<sup>[10]</sup>. The membrane's thickness varies but is generally 0.3-0.8 mm in unfixed, fresh cadavers without sinusitis<sup>[31]</sup>. A study with cone beam computed tomography has showed that individuals vary greatly in the thickness of their Schneiderian membranes, from 0.16 to 34.61 mm, and the highest mean values have been found in the mid-sagittal aspect<sup>[32]</sup>. Other local or systemic factors that influence the thickness of the Schneiderian membrane are described in previous reports. Gingival thickness and sex are reported to be related to the Schneiderian membrane's thickness: the membrane is thicker in patients with thick gingival biotype and thinner in female subjects<sup>[32-34]</sup>. Higher Schneiderian membrane thickness has been noted next to restored teeth and periodontal and endodontic lesions. Especially in molar regions with periodontal destruction, the Schneiderian membrane has thickened, particularly when there are small bone layers above the root tips or periapical lesions. In addition, inflammation or allergic phenomena, as well as smoking, are correlated with increased mucosal thickness<sup>[35]</sup>.

It has been shown that the Schneiderian membrane swells significantly, by 6.7 mm, after sinus augmenta-

tion, and that this swelling disappears three weeks later<sup>[36]</sup>. In one report, patients' computed tomographic scans have been compared before bone grafting and 4 to 6 mo after bone grafting<sup>[37]</sup>. Sinus membrane thickness differs significantly before (0.8-1.2 mm) and after (1.5-1.3 mm) augmentation surgery, with a mean increase of 0.8-1.6 mm (maximum: 4.4 mm), and only 28% of augmented sinuses do not show membrane thickening. Other reports, however, show no significant change in the membrane thickness between computed tomographic scans taken before operation and an average of 8.9 mo after operation<sup>[38]</sup>. This discrepancy may be explained by the study design: the latter study excluded bilateral sinus augmentations and had higher membrane thickness before operation, with a higher history of periodontitis (75.7 %).

Which types of mucosal thickening require therapy is still unknown, but historically 2 mm is considered a reliable threshold for pathological mucosal swelling<sup>[39]</sup>. Since the most frequent surgical complication occurring during sinus augmentation is perforation of the Schneiderian membrane (10%-56%)<sup>[40]</sup>, it is crucial to check the Schneiderian membrane status by cone beam computed tomography or with an endoscope, and to eliminate sinusitis and other potential pathological conditions before any surgery. A previous study shows that 38.2% of presumably reversible ear, nose, and throat contraindications have been detected and resolved before sinus augmentation, and the same study suggests that a careful multitasking preoperative management, including an ear, nose, and throat assessment with fiberoptic endoscopy and a radiological evaluation extended to the ostiomeatal complex, may be very useful in candidates for sinus augmentation<sup>[41]</sup>.

## CONCLUSION

In this report, we have dealt with the anatomic relations of the structures of the maxillary sinus during sinus augmentation. These anatomical findings can help with complications and potential injuries in procedures involving the maxillary sinus. It can be suggested that preoperative evaluation is helpful for diagnosis and treatment planning, as well as for minimizing complications during surgery.

## REFERENCES

- 1 Jivraj S, Chee W, Corrado P. Treatment planning of the edentulous maxilla. *Br Dent J* 2006; **201**: 261-279; quiz 304 [PMID: 16960607 DOI: 10.1038/sj.bdj.4813952]
- 2 Khojasteh A, Sadr SJ, Saboury A, Shidfar S. Onlay bone augmentation and bilateral open sinus lifting with simultaneous implant placement in a cherubic patient. *J Craniofac Surg* 2014; **25**: e193-e196 [PMID: 24621770 DOI: 10.1097/SCS.0000000000000433]
- 3 Cha JK, Park JC, Jung UW, Kim CS, Cho KS, Choi SH. Case series of maxillary sinus augmentation with biphasic calcium phosphate: a clinical and radiographic study. *J Periodontal Implant Sci* 2011; **41**: 98-104 [PMID: 21556261 DOI:



- 10.5051/jpis.2011.41.2.98]
- 4 **Boyne PJ**, James RA. Grafting of the maxillary sinus floor with autogenous marrow and bone. *J Oral Surg* 1980; **38**: 613-616 [PMID: 6993637]
- 5 **Summers RB**. A new concept in maxillary implant surgery: the osteotome technique. *Compendium* 1994; **15**: 152, 154-156, 158 passim; quiz 162 [PMID: 8055503]
- 6 **Tatum OH**, Lebowitz MS, Tatum CA, Borgner RA. Sinus augmentation. Rationale, development, long-term results. *N Y State Dent J* 1993; **59**: 43-48 [PMID: 8510868]
- 7 **Pjetursson BE**, Tan WC, Zwahlen M, Lang NP. A systematic review of the success of sinus floor elevation and survival of implants inserted in combination with sinus floor elevation. *J Clin Periodontol* 2008; **35**: 216-240 [PMID: 18724852 DOI: 10.1111/j.1600-051X.2008.01272.x]
- 8 **Blanton PL**, Biggs NL. Eighteen hundred years of controversy: the paranasal sinuses. *Am J Anat* 1969; **124**: 135-147 [PMID: 4886838 DOI: 10.1002/aja.1001240202.]
- 9 **Zoukaa B**, Sargi RRC. Surgical Anatomy of the Paranasal Sinuses. Berlin, Heidelberg: Springer, 2007: 17-26
- 10 **Bell GW**, Joshi BB, Macleod RI. Maxillary sinus disease: diagnosis and treatment. *Br Dent J* 2011; **210**: 113-118 [PMID: 21311531 DOI: 10.1038/sj.bdj.2011.47]
- 11 **Woo I**, Le BT. Maxillary sinus floor elevation: review of anatomy and two techniques. *Implant Dent* 2004; **13**: 28-32 [PMID: 15017301 DOI: 10.1097/01.id.0000116369.66716.12]
- 12 **Testori T**. Maxillary sinus surgery: Anatomy and advanced diagnostic imaging. *J Imp Reconst Dent* 2011; **3**: 18-25
- 13 **Testori T**. Maxillary sinus surgery: Anatomy and advanced diagnostic imaging. *J PROSTHODONT* 2011; **2**
- 14 **Nimigean V**, Nimigean VR, Măru N, Sălăvăstru DI, Bădiță D, Tuculină MJ. The maxillary sinus floor in the oral implantology. *Rom J Morphol Embryol* 2008; **49**: 485-489 [PMID: 19050796]
- 15 **Sharan A**, Madjar D. Maxillary sinus pneumatization following extractions: a radiographic study. *Int J Oral Maxillofac Implants* 2008; **23**: 48-56 [PMID: 18416412]
- 16 **Tallgren A**. The continuing reduction of the residual alveolar ridges in complete denture wearers: A mixed-longitudinal study covering 25 years (Reprinted from *J Prosthet Dent* vol 27, pg 120-32, 1972). *J Prosthet Dent* 2003; **89**: 427-435 [DOI: 10.1016/S0022-3913(03)00158-6]
- 17 **Jackson RA**, Ralph WJ. Continuing changes in the contour of the maxillary residual alveolar ridge. *J Oral Rehabil* 1980; **7**: 245-248 [PMID: 6931200 DOI: 10.1111/j.1365-2842.1980.tb00441.x]
- 18 **Solopov VN**, Lunichkina IV. [Mucociliary transport in chronic bronchitis]. *Sov Med* 1987; **2012**: 3-6 [PMID: 3423929 DOI: 10.1155/2012/365809]
- 19 **Krennmair G**, Ulm CW, Lugmayr H, Solar P. The incidence, location, and height of maxillary sinus septa in the edentulous and dentate maxilla. *INT J ORAL MAX SURG* 1999; **57**: 667-671; discussion 671-662
- 20 **Maestre-Ferrín L**, Galán-Gil S, Rubio-Serrano M, Peñarocha-Diogo M, Peñarocha-Oltra D. Maxillary sinus septa: a systematic review. *Med Oral Patol Oral Cir Bucal* 2010; **15**: e383-e386 [PMID: 19767706 DOI: 10.4317/medoral.15.e383]
- 21 **Velásquez-Plata D**, Hovey LR, Peach CC, Alder ME. Maxillary sinus septa: a 3-dimensional computerized tomographic scan analysis. *Int J Oral Maxillofac Implants* 2002; **17**: 854-860 [PMID: 12507246]
- 22 **Pommer B**, Ulm C, Lorenzoni M, Palmer R, Watzek G, Zechner W. Prevalence, location and morphology of maxillary sinus septa: systematic review and meta-analysis. *J Clin Periodontol* 2012; **39**: 769-773 [PMID: 22624862 DOI: 10.1111/j.1600-051X.2012.01897.x]
- 23 **Wen SC**, Chan HL, Wang HL. Classification and management of antral septa for maxillary sinus augmentation. *Int J Periodontics Restorative Dent* 2013; **33**: 509-517 [PMID: 23820711 DOI: 10.11607/prd.1609]
- 24 **Ardekian L**, Oved-Peleg E, Mactei EE, Peled M. The clinical significance of sinus membrane perforation during augmentation of the maxillary sinus. *J Oral Maxillofac Surg* 2006; **64**: 277-282 [PMID: 16413901 DOI: 10.1016/j.joms.2005.10.031]
- 25 **Becker ST**, Terheyden H, Steinriede A, Behrens E, Springer I, Wiltfang J. Prospective observation of 41 perforations of the Schneiderian membrane during sinus floor elevation. *Clin Oral Implants Res* 2008; **19**: 1285-1289 [PMID: 19040444 DOI: 10.1111/j.1600-0501.2008.01612.x]
- 26 **Solar P**, Geyerhofer U, Traxler H, Windisch A, Ulm C, Watzek G. Blood supply to the maxillary sinus relevant to sinus floor elevation procedures. *Clin Oral Implants Res* 1999; **10**: 34-44 [DOI: 10.1034/j.1600-0501.1999.100105.x]
- 27 **Rosano G**, Taschieri S, Gaudy JF, Weinstein T, Del Fabbro M. Maxillary sinus vascular anatomy and its relation to sinus lift surgery. *Clin Oral Implants Res* 2011; **22**: 711-715 [PMID: 21143535 DOI: 10.1111/j.1600-0501.2010.02045.x]
- 28 **Traxler H**, Windisch A, Geyerhofer U, Surd R, Solar P, Firsbas W. Arterial blood supply of the maxillary sinus. *Clin Anat* 1999; **12**: 417-421 [PMID: 10545857 DOI: 10.1002/(sici)1098-2353(1999)12:6<417::aid-ca3>3.0.co;2-w]
- 29 **Flanagan D**. Arterial supply of maxillary sinus and potential for bleeding complication during lateral approach sinus elevation. *Implant Dent* 2005; **14**: 336-338 [PMID: 16361882]
- 30 **Mardinger O**, Abba M, Hirshberg A, Schwartz-Arad D. Prevalence, diameter and course of the maxillary intraosseous vascular canal with relation to sinus augmentation procedure: a radiographic study. *Int J Oral Maxillofac Surg* 2007; **36**: 735-738 [PMID: 17629462 DOI: 10.1016/j.jiom.2007.05.005]
- 31 **Tos M**, Mogensen C. Mucus production in chronic maxillary sinusitis. A quantitative histopathological study. *Acta Otolaryngol* 1984; **97**: 151-159 [PMID: 6689823 DOI: 10.3109/00016488409130975]
- 32 **Janner SF**, Caversaccio MD, Dubach P, Sendi P, Buser D, Bornstein MM. Characteristics and dimensions of the Schneiderian membrane: a radiographic analysis using cone beam computed tomography in patients referred for dental implant surgery in the posterior maxilla. *Clin Oral Implants Res* 2011; **22**: 1446-1453 [DOI: 10.1111/j.1600-0501.2010.02140.x]
- 33 **Aimetti M**, Massei G, Morra M, Cardesi E, Romano F. Correlation between gingival phenotype and Schneiderian membrane thickness. *Int J Oral Maxillofac Implants* 2008; **23**: 1128-1132 [PMID: 19216284]
- 34 **Vallo J**, Suominen-Taipale L, Huuonen S, Soikkonen K, Norblad A. Prevalence of mucosal abnormalities of the maxillary sinus and their relationship to dental disease in panoramic radiography: results from the Health 2000 Health Examination Survey. *Oral surgery, oral medicine, oral pathology, oral radiology, and endodontics* 2010; **109**: e80-87 [DOI: 10.1016/j.tripleo.2009.10.031]
- 35 **Dagassan-Berndt DC**, Zitzmann NU, Lambrecht JT, Weiger R, Walter C. Is the Schneiderian membrane thickness affected by periodontal disease? A cone beam computed tomography-based extended case series. *J Int Acad Periodontol* 2013; **15**: 75-82 [PMID: 24079099]
- 36 **Quirynen M**, Lefever D, Hellings P, Jacobs R. Transient swelling of the Schneiderian membrane after transversal sinus augmentation: a pilot study. *Clin Oral Implants Res* 2014; **25**: 36-41 [PMID: 23106796 DOI: 10.1111/clr.12056]
- 37 **Pommer B**, Dvorak G, Jesch P, Palmer RM, Watzek G, Gahleitner A. Effect of maxillary sinus floor augmentation on sinus membrane thickness in computed tomography. *J Periodontol* 2012; **83**: 551-556 [PMID: 22060048 DOI: 10.1902/jop.2011.110345]
- 38 **Anduze-Acher G**, Brochery B, Felizardo R, Valentini P, Katsahian S, Bouchard P. Change in sinus membrane dimension following sinus floor elevation: a retrospective cohort study. *Clin Oral Implants Res* 2013; **24**: 1123-1129 [DOI: 10.1111/j.1600-0501.2012.02520.x]



- 39 **Cagici CA**, Yilmazer C, Hurcan C, Ozer C, Ozer F. Appropriate interslice gap for screening coronal paranasal sinus tomography for mucosal thickening. *EUR ARCH OTO-RHINO-L* 2009; **266**: 519-525 [DOI: 10.1007/s00405-008-0786-6]
- 40 **Bornstein MM**, Chappuis V, von Arx T, Buser D. Performance of dental implants after staged sinus floor elevation procedures: 5-year results of a prospective study in partially edentulous patients. *Clin Oral Implants Res* 2008; **19**: 1034-1043 [PMID: 18828820 DOI: 10.1111/j.1600-0501.2008.01573.x]
- 41 **Torretta S**, Mantovani M, Testori T, Cappadona M, Pignataro L. Importance of ENT assessment in stratifying candidates for sinus floor elevation: a prospective clinical study. *Clin Oral Implants Res* 2013; **24** Suppl A100: 57-62 [PMID: 22107048 DOI: 10.1111/j.1600-0501.2011.02371.x]

**P- Reviewer:** Park JB, Schwartz-Arad D **S- Editor:** Ji FF  
**L- Editor:** A **E- Editor:** Lu YJ



## Value of temporary stents for the management of perivaterian perforation during endoscopic retrograde cholangiopancreatography

Sang Min Lee, Kwang Bum Cho

Sang Min Lee, Kwang Bum Cho, Department of Internal Medicine and Institute for Medical Science, Keimyung University School of Medicine, Daegu 700-712, South Korea  
Author contributions: Lee SM and Cho KB contributed to this paper.

Supported by The research promoting grant from the Keimyung University Dongsan Medical Center in 2004

Correspondence to: Kwang Bum Cho, MD, PhD, Department of Internal Medicine and Institute for Medical Science, Keimyung University School of Medicine, 194 Dongsan-dong, Jung-gu, Daegu 700-712, South Korea. [chokb@dsmc.or.kr](mailto:chokb@dsmc.or.kr)  
Telephone: +82-53-2507088 Fax: +82-53-2507442

Received: July 28, 2014 Revised: August 25, 2014

Accepted: September 16, 2014

Published online: November 16, 2014

**Core tip:** Although the evidence supporting the use of fully covered self-expandable metallic stent in perivaterian perforations is still insufficient, the clinical outcomes were encouraging.

Lee SM, Cho KB. Value of temporary stents for the management of perivaterian perforation during endoscopic retrograde cholangiopancreatography. *World J Clin Cases* 2014; 2(11): 689-697 Available from: URL: <http://www.wjgnet.com/2307-8960/full/v2/i11/689.htm> DOI: <http://dx.doi.org/10.12998/wjcc.v2.i11.689>

### Abstract

Endoscopic retrograde cholangiopancreatography (ERCP) has become the mainstay of treatment in hepato-pancreato-biliary disease. However, ERCP requires a high level of technical skills and experience in therapeutic endoscopy, there is always a risk of complications. Especially, the perforation *per se* affects the patient adversely, and the clinical course may lead to a poor prognosis, even with appropriate management. The treatments for ERCP-related perforation are diverse, depending on the location and mechanism of the bowel perforation and the time of diagnosis. Thus, we reviewed the appropriate surgical and non-surgical management options for therapeutic ERCP-related perforations, especially, evaluating metallic stenting as a treatment modality in perivaterian perforation.

© 2014 Baishideng Publishing Group Inc. All rights reserved.

**Key words:** Endoscopic retrograde cholangiopancreatography; Perforation; Self-expandable metallic stent; Duodenum; Perivaterian

### INTRODUCTION

Endoscopic retrograde cholangiopancreatography (ERCP) has become the mainstay of treatment in hepato-pancreato-biliary disease since its introduction in 1968<sup>[1]</sup>. In the past, ERCP had been used as a *diagnostic* tool in choledocholithiasis presenting with jaundice, dilated common bile duct, acute pancreatitis, and cholangitis, but recently ERCP combined with sphincterotomy and stone removal has become a valuable *therapeutic* procedure<sup>[2]</sup>.

Because ERCP requires a high level of technical skills and experience in therapeutic endoscopy, there is always a risk of complications, such as bleeding, perforation, pancreatitis, and cholangitis. Indeed, complication rates range from 5.4% to 11.2%<sup>[3-11]</sup>, among which the rate of perforation, a potentially fatal complication, is 0.3%-1.0%<sup>[3,12,13]</sup>, and the rate of mortality in perforated patients is high (8%-23%)<sup>[3,12-14]</sup>. Moreover, perforation *per se* affects the patient adversely, and the clinical course may lead to a poor prognosis, even with appropriate management. Delayed diagnosis and management can further affect clinical outcomes adversely<sup>[15,16]</sup>.

The treatments for ERCP-related perforation are diverse, depending on the location and mechanism of the

**Table 1** Classification of endoscopic retrograde cholangiopancreatography-related perforations

Ref.	Type
Stapfer <i>et al</i> <sup>[18]</sup>	Type I, duodenal perforation of medial or lateral wall Type II, perivaterian perforation Type III, perforation of distal bile duct Type IV, retroperitoneal air alone
Howard <i>et al</i> <sup>[17]</sup>	Group I, guidewire perforation Group II, periampullary retroperitoneal perforation Group III, duodenal perforation remote from the ampulla

bowel perforation and the time of diagnosis<sup>[17,18]</sup>. Previously, most ERCP-related perforations, regardless of the above factors, were managed using surgery, and the mortality rate with such surgery was generally high. However, after the introduction of treatment strategies according to the type of perforation, nonsurgical management, such as radiologic interventions using percutaneous transhepatic biliary drainage (PTBD) and endoscopic management using endoscopic nasobiliary drainage (ENBD), endoscopic retrograde biliary drainage (ERBD), endoclips, and fibrin glue, have been developed. Consequently, treatment outcomes have improved greatly over time<sup>[12,15-24]</sup>.

Now, nonsurgical techniques are being used in suitable select patients more than often than surgery. Among the various nonsurgical options, several recent studies have reported that fully covered self-expandable metallic stents (SEMSs) could be used in ERCP-related perforation, especially in periampullary perforations<sup>[25-28]</sup>. Thus, we reviewed the appropriate surgical and non-surgical management options for therapeutic ERCP-related perforations, especially, evaluating metallic stenting as a treatment modality in perivaterian perforation.

## CLASSIFICATION OF ERCP-RELATED PERFORATION

The treatment modality in ERCP-related perforations is associated with the type of the perforation (Table 1). Stapfer *et al*<sup>[18]</sup> classified perforations into four types according to anatomical location and severity. Type I duodenal injuries are perforations of the lateral or medial wall, caused by the endoscope itself. Type II duodenal injuries are perforations of the medial wall. These are perivaterian or periampullary perforations, and most occur during endoscopic sphincterotomies. Type III duodenal injuries are perforations of the distal bile duct, typically due to wire or basket instrumentation. Type IV duodenal injuries are diminutive retroperitoneal perforations due to excessive use of compressed air to retain a patent bowel lumen.

Similar to Stapfer's classification, Howard *et al*<sup>[17]</sup> reported three types of ERCP-related perforations in accordance with the mechanism of injury. Group I perforations are guidewire perforations of the duct, group II perforations

are periampullary perforations, and group III perforations are duodenal perforations remote from the ampulla.

Regarding incidence by type of perforation, generally, periampullary perforations caused by endoscopic sphincterotomies are most common, 15%-55%<sup>[12,17-19]</sup>. Polydorou *et al*<sup>[23]</sup> reported incidences using a modified classification of ERCP-related perforation. Type I, and type II injuries are identical with Stapfer's type I and II injuries, but type III injuries are ductal or duodenal perforations caused by endoscopic instruments, but not guidewires, and type IV injuries are guidewire perforations with the presence of retroperitoneal air on X-ray examination. They showed incidences of 68% for type II, 16% for type I, 11% for type III, and 4% for type IV perforations. Another study showed that guidewire-related perforations were most common (32%)<sup>[19]</sup>. Moreover, 15% were sphincterotomy-related perforations, 11% occurred during passage of the endoscope, and 9% occurred due to stent migration. Morgan *et al*<sup>[22]</sup> reported that 12 of 24 cases of ERCP-related perforations were related to sphincterotomy, and the other 12 cases were perforations remote from the papilla. Although the incidence of ERCP-related perforations varied slightly among the previous studies, sphincterotomy-related perforations tend to be most common, followed by guidewire-related perforations and free wall perforations.

## RISK FACTORS FOR ERCP-RELATED PERFORATIONS

Several studies have reported risk factors for ERCP-related perforations. Overall risk factors, regardless of the type of ERCP-related perforation, include old age and a longer ERCP procedure time. Enns *et al*<sup>[12]</sup> demonstrated that patients older than 65 years had a greater risk of ERCP-related perforation. Longer procedure times are often accompanied by repeated cannulation or more invasive methods to achieve "good" results. Thus, there tends to also be a greater risk of perforation. Additionally, ERCP-related perforation may be increased when performed by a trainee endoscopist. However, experts in the therapeutic ERCP field operate frequently and especially with severe and difficult cases; thus, there is always a risk of perforation during the procedure regardless of the surgeon's experience.

Risk factors for Stapfer's type I perforation are abnormal anatomical structures, such as gastrojejunostomy, pancreaticoduodenectomy, duodenal diverticulum or stricture, and situs inversus<sup>[22,29-31]</sup>. With anatomical features that differ from those of normal situations, it may be difficult to penetrate the bowel lumen using a side-viewing endoscope, increasing the risk of perforation by the endoscope itself.

Risk factors for Stapfer's type II, III, and IV perforations are similar and overlapping. They include sphincter of Oddi dysfunction, precut sphincterotomy, and a dilated common bile duct on abdominal imaging<sup>[12]</sup>. Precut sphincterotomy has been reported as a known risk factor

for pancreatitis<sup>[6,7,32]</sup>. However, several studies have demonstrated that precut sphincterotomy also increases the risk of perforation compared with a conventional sphincterotomy. In fact, the risk of perforation increases if the incision for the sphincterotomy is outside of the usually recommended sector (11 to 1 o'clock position)<sup>[6,33-35]</sup>. A previous report demonstrated that 7 of 13 sphincterotomy-related perforations were associated with precutting<sup>[12]</sup>. Since a dilated common bile duct is associated with distal common bile duct stricture, the risk of perforation may be related to the deep manipulation needed to achieve a deep cannulation. Additionally, an ampullectomy can increase the risk of perforations. Alfieri *et al*<sup>[15]</sup> reported that ampullectomy had been performed in 7 of 30 (23%) cases of ERCP-related perforations.

## CLINICAL MANIFESTATIONS AND DIAGNOSIS

Patients with ERCP-related perforations may complain mainly of epigastric pain and tenderness, but obviously these complaints are very nonspecific. Other symptoms and signs include fever, tachycardia, leukocytosis, and mildly elevated serum amylase levels. Several studies have reported rare complications after ERCP, such as pneumomediastinum, pneumothorax, and gas in the portal system<sup>[36-42]</sup>, whereas patients with retroperitoneal air present on abdominal imaging, after an endoscopic sphincterotomy, can be asymptomatic clinically. Generally, the patients did not require intervention but only conservative management. Genzlinger *et al*<sup>[43]</sup> showed that asymptomatic patients with retroperitoneal air evident on a computed tomography (CT) scan did not require surgical intervention. As the range is diverse, from asymptomatic to severe signs of peritonitis, to suspect and recognize the possibility of perforation early, during and after ERCP is most important. For early detection of perforation, it is necessary to check the patient's condition immediately after ERCP. If the patient complains severe abdominal pain, abdominal X-ray and CT are good methods to identify ERCP-related perforation. If retroperitoneal air is visible during the procedure, abdominal X-ray and CT are also useful.

ERCP-related perforation can sometimes be diagnosed readily by imaging if suspected. Typically, an abdominal X-ray may show retroperitoneal air around the right kidney. Suspected perforation may not be confirmed by an abdominal X-ray, but a contrast CT scan or upper gastrointestinal oral contrast evaluation should be helpful. However, this could be delayed unless the physician suspects a perforation. Furthermore, if the patient has elevated serum amylase levels and complaints of epigastric pain, it is difficult to distinguish between perforation and pancreatitis. Gottlieb *et al*<sup>[44]</sup> reported that post-ERCP pancreatitis can be excluded if their values of amylase and lipase 2 h after ERCP are below 276 U/L and 1000 U/L, respectively. Another study demonstrated that post-ERCP pancreatitis cases showed serum amylase levels

greater than five-fold the normal level<sup>[45]</sup>. Thus, laboratory findings, especially serum amylase and lipase levels, may be important clues for differentiating perforation from pancreatitis.

Although a physical examination is frequently useful in suspected patients, not all perforated patients show signs of acute peritonitis<sup>[43]</sup>. Bell *et al*<sup>[46]</sup> demonstrated positive physical findings in 75% of the included patients, but no specific finding of perforations. Thus, it is important to consider not only a physical examination and laboratory findings but also abdominal imaging, such as abdominal X-ray and abdominal CT scans, for an accurate diagnosis.

## TREATMENT OF ERCP-RELATED PERFORATION

Traditionally, ERCP-related perforation has been managed surgically. The objectives of such surgical management include control of infection and inflammation (drainage of the retroperitoneal/intraperitoneal fluid and air and drainage of the biliary system) and closure of the perforation, with or without bypass<sup>[2]</sup>. However, the recent trend has been towards a selective approach according to the type of perforation and, more recently, according to the overall status of the patient, considering issues such as age, vital signs, peritoneal signs, comorbidities, and CT images.

Duodenal free wall perforations (Stapfer type I or Howard Group III) tend to be larger and located remotely from the ampulla and to cause substantial collections in the peritoneal or retroperitoneal space. Thus, these perforations should be subjected to prompt surgical intervention. One study reported three of four cases of type I perforation that underwent surgery immediately<sup>[12]</sup>. One case had abnormal anatomy, a gastrojejunostomy, and the others cases had duodenal diverticulum and stricture. All three patients were suspected and diagnosed immediately; there was no mortality. The one patient without surgical management had severe comorbidities, thus receiving only conservative management but died 2 d later. Polydorou *et al*<sup>[23]</sup> reported that 83% (6/7) of Stapfer's type I perforation cases underwent surgery. Three patients with type I perforation showed abnormal anatomy due to Billroth II gastrectomies. Among the patients who underwent surgery, two died as a result of respiratory insufficiency and aspiration pneumonia. One patient with a type I perforation, caused by rupture of the diverticulum, was managed conservatively. The patient had no fever or signs of peritonitis but only complained of mild abdominal pain.

In the studies mentioned above, in general most of the type I perforations were treated using surgery due to the large size of the perforation. Recently, some studies have introduced endoscopic management using simple metallic endoclips or an endoloop with multiple endoclips and fibrin glue for free wall duodenal perforations<sup>[28,34,47-50]</sup>. In addition, an over-the-scope-clip, used



**Table 2 Treatment of periampullary perforations (Stapfer's type II perforations)**

Ref.	Patients (n)	Patients according to treatment method, n (%)	Treatment method	Mortality n (%)
Alfieri <i>et al</i> <sup>[15]</sup>	15	6 (40.0)	Conservative management + ENBD ± PTBD	0 (0.0)
		9 (60.0)	Surgery	1 (11.1)
Wu <i>et al</i> <sup>[16]</sup>	11	6 (54.5)	Conservative management	0 (0.0)
		5 (45.5)	Surgery	4 (80.0)
Kim <i>et al</i> <sup>[58]</sup>	5	2 (40.0)	Conservative management	0 (0.0)
		3 (60.0)	Surgery	0 (0.0)
Enns <i>et al</i> <sup>[12]</sup>	13	11 (84.6)	Conservative management ± biliary drainage (PTBD, ERBD)	0 (0.0)
		2 (13.4)	Surgery	0 (0.0)
Polydorou <i>et al</i> <sup>[23]</sup>	30	24 (80.0)	Conservative management ± biliary drainage (PTBD, ERBD)	0 (0.0)
		6 (20.0)	Surgery	0 (0.0)
Stapfer <i>et al</i> <sup>[18]</sup>	6	3 (50.0)	Conservative management	0 (0.0)
		3 (50.0)	Surgery	0 (0.0)
Howard <i>et al</i> <sup>[17]</sup>	22	18 (81.8)	Conservative management ± biliary drainage (ENBD, ERBD)	0 (0.0)
		4 (18.2)	Surgery	1 (25)
Morgan <i>et al</i> <sup>[22]</sup>	12	12 (100.0)	Conservative management	0 (0.0)
		0 (0.0)	Surgery	0 (0.0)
Kim <i>et al</i> <sup>[59]</sup>	9	8 (88.8)	Conservative management ± ENBD	0 (0.0)
		1 (11.2)	Surgery	0 (0.0)

Conservative management: intravenous antibiotics, fluids, pain control, nil-by-mouth, close monitoring, and nasogastric drainage. ENBD: Endoscopic naso-biliary drainage; PTBD: Percutaneous transhepatic biliary drainage; ERBD: Endoscopic retrograde biliary drainage.

primarily in gastrointestinal bleeding or perforation, could be considered for use in post-ERCP perforations<sup>[51,52]</sup>.

Distal bile duct injuries (Stapfer type III or Howard Group I), caused by penetration of the guidewire through the bile duct during cannulation in a narrow or obstructed duct, tend to be smaller than duodenal free wall perforations. Commonly, these perforations tend to become obstructed spontaneously, and these patients can be 'cured' by conservative management with intravenous antibiotics, hydration, pain control, or nil-by-mouth<sup>[12,17,18,53]</sup>. However, since some patients have ongoing bile leakage, endoscopic management to prevent bile leakage to the retroperitoneum may be necessary. To prevent such leakage, ENBD or ERBD together with insertion of a plastic or metallic stent can be used. If endoscopic management is not possible, PTBD can be performed.

Diminutive duodenal perforation (Stapfer type IV) is not a true perforation; generally, it can be treated sufficiently with conservative management alone. In fact, Genzlinger *et al*<sup>[43]</sup> reported that retroperitoneal air alone, with no abnormal clinical signs or symptoms, does not require surgical intervention. However, regardless of the type of perforation, patients with retained stones or unalleviated biliary obstruction should undergo surgery<sup>[18]</sup>.

Perivaterian perforations (Stapfer type II or Howard group II) occurring after endoscopic sphincterotomy are controversial issues in the treatment field presently because of variation in clinical outcomes<sup>[14,18,34,41,53-57]</sup>. Surgical intervention is not an issue but is an abstruse problem, because it seems that conservative management alone, including biliary drainage, may aggravate or fail to cure the perforation. Several studies have demonstrated that conservative management with or without biliary drainage was successful in peri-ampullary perforation pa-

tients<sup>[18,53-55]</sup>.

Wu *et al*<sup>[16]</sup> reported that 55% (6/11) of patients with type II perforations were treated with conservative management with or without biliary drainage. In all patients, clinical signs and symptoms improved rapidly. However, 80% (4/5) of the patients who underwent surgery died, due to delayed diagnosis and operation as well as sepsis. The surgical indications for those patients were large retroperitoneal fluid collections, liver abscess on abdominal CT scan, and severe abdominal pain. Enns *et al*<sup>[12]</sup> demonstrated that 46% (6/13) of patients with type II perforations were treated using conservative management with or without nasogastric suction. In 38% (5/13) of the patients, biliary drainage (stent insertion with three, PTBD with two) was performed. The mortality rate was zero in patients managed conservatively and with biliary drainage. Alfieri *et al*<sup>[15]</sup> showed that 40% (6/15) of patients with type II perforations were treated successfully by conservative management with biliary drainage (PTBD or nasobiliary drainage).

The rates of nonsurgical management *vs* surgical intervention in peri-ampullary perforation vary widely (Table 2)<sup>[12,15-18,22,23,58,59]</sup>. Thus, the appropriate choice of treatment modality for peri-ampullary perforation remains an important issue. Most surgical indications in peri-ampullary perforations include hemodynamic instability, signs of peritonitis, continuing leakage, septic conditions, and a perforation of large size. One author also suggested that patients with a large amount of fluid collection in the peritoneum or retroperitoneum on abdominal CT should be treated aggressively<sup>[12]</sup>, because the possibility of continuing leakage is high. If there is no surgical indication, the essential aspects of nonsurgical management consist of diversion of duodenal, biliary, and pancreatic drainage<sup>[21]</sup>. A nasogastric or nasoduodenal tube for duodenal

**Table 3** Temporary self-expandable metallic stent used for peri-ampullary perforations

Ref.	Age/sex	ERCP indication	Abdominal CT scan	Stent indication	Type of stent/duration (d)
Vezakis <i>et al</i> <sup>[28]</sup>	61/F	Stones or sphincter of Oddi dysfunction	Retroperitoneal air	Duodenal fistula, Continuing leakage	Partially covered SEMS/14
Jeon <i>et al</i> <sup>[26]</sup>	82/F	Stones	Retroperitoneal air and fluid	Continuing leakage	Fully covered SEMS/28
Canena <i>et al</i> <sup>[25]</sup>	55/F	Stones	Retroperitoneal air and fluid	Perforation	Fully covered SEMS/21
	29/F	Stones	Retroperitoneal air and fluid	Perforation	Fully covered SEMS/30
	31/M	Stones	Retroperitoneal air and fluid	Perforation	Fully covered SEMS/30
	76/F	Stones	Retroperitoneal air and fluid	Perforation	Fully covered SEMS/29
Park <i>et al</i> <sup>[27]</sup>	61/F	Biliary tree dilatation	Retroperitoneal air and fluid	Perforation	Fully covered SEMS/10
Unpublished	46/M	Stones	Retroperitoneal air	Perforation	Fully covered SEMS/ spontaneously fell out

CT: Computed tomography; SEMS: Self-expandable metallic stent; ERCP: Endoscopic retrograde cholangiopancreatography.

decompression can be used. ENBD or ERBD can be used in internal biliary drainage to prevent leakage of bile juice into the perforation site. For external biliary drainage, PTBD is used as well.

However, some conditions, such as severe common bile duct dilatation or a large perforation hole, may reduce the diversion of biliary drainage using ENBD or ERBD<sup>[27]</sup>. Thus, several studies have reported that fully covered self-expandable metallic stents (SEMS) can be useful in biliary stenting for perivaterian perforations<sup>[25-28]</sup>.

Initially, most periampullary perforation patients receive conservative management with or without biliary drainage, according to most previous studies. If conservative management failed and a delayed operation was then performed, the subsequent clinical course was found to be poor in some studies<sup>[15,16]</sup>. Thus, there is a need to treat using active conservative management. Taking advantage of biliary drainage by ENBD, ERBD, use of plastic or metallic stents, PTBD, duodenal drainage *via* a nasogastric or nasoduodenal tube, pancreatic drainage, and inflammation control are essential. "Conservative management" indicating only intravenous antibiotics, hydration, pain control, and nil-by-mouth is inadequate. Indeed, it is important to combine methods to prevent bile leakage into the perforation site.

## ARE FULLY COVERED SEMS IN ERCP-RELATED PERFORATIONS VALUABLE?

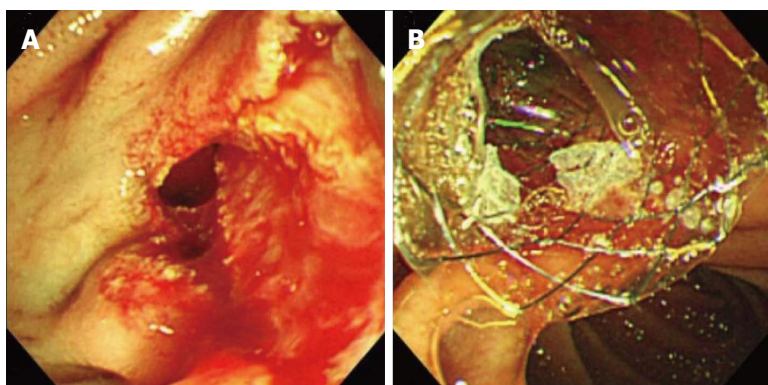
As mentioned above, it is important to divert biliary drainage to prevent leakage of bile juice into the peritoneum in a peri-ampullary perforation. For such diversion, fully covered SEMS occlude the perforation site by radial force, and the perforation site can heal quickly. That is, recovery of the epithelium in the injury site, stent-associated reepithelialization, is achieved. A similar procedure has been performed previously in esophageal perforations. Siersema *et al*<sup>[60,61]</sup> reported that a fully covered SEMS was useful in nonmalignant and traumatic esophageal perforations; however, in general fully covered SEMS have been used for malignant perforations or fistulas for palliative management. A fully covered SEMS enabled the sealing of an esophageal perforation and prevented mediastinal

infection.

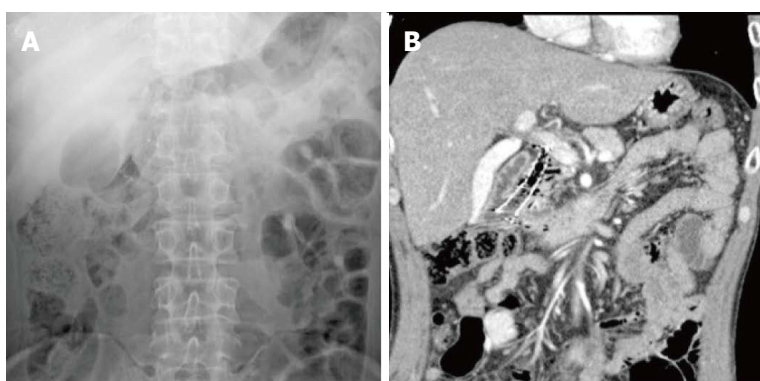
Some case series have reported the use of SEMS in ERCP-related perforations (Table 3)<sup>[25-28]</sup>. Vezakis *et al*<sup>[28]</sup> reported a case of a persistent high-volume duodenal fistula, caused during an endoscopic sphincterotomy, that was treated successfully using a partially covered SEMS. Jeon *et al*<sup>[26]</sup> also reported the use of a fully covered SEMS in a sphincterotomy-related duodenal perforation. Although this patient had retroperitoneal fluid collections and peritonitis, she was not considered a candidate for surgery. She was treated with multiple plastic stents for internal biliary drainage and with PTBD for external biliary drainage due to her poor medical condition and old age (82 years). However, because of persistent percutaneous catheter drainage (> 150 mL/d) and contrast leakage from a distal common bile duct on tubogram, a fully covered SEMS was inserted after removing the previous plastic stents. She then recovered completely, and the fully covered SEMS was removed 1 mo later.

Park *et al*<sup>[27]</sup> also considered duodenal perforation after endoscopic sphincterotomy, similar to the above two studies. Their case was a 61-year-old female complaining of right upper quadrant pain. Biliary duct dilatation had been detected on an abdominal CT scan, and therefore ERCP with sphincterotomy was performed. The day after ERCP, she developed severe abdominal pain, fever, and leukocytosis according to laboratory findings. An abdominal CT showed retroperitoneal air and fluid collection, and the diagnosis was peri-ampullary perforation. A fully covered SEMS (5-cm-long, 10 mm in diameter) was inserted immediately after identifying the perforation, and the patient recovered completely. The retroperitoneal fluid collection seen on the abdominal CT scan resolved. The stent was then removed 10 d after insertion.

In another previously unpublished case, a 46-year-old male was referred to the hospital for right quadrant abdominal pain. He had previously undergone a Billroth I operation for gastric ulcer perforation. Because the patient developed abnormal liver functioning and gallbladder stones on abdominal CT scan, ERCP was performed to identify the biliary duct stone. However, after endoscopic sphincterotomy, a peri-ampullary perforation was detected, and a fully covered SEMS was placed immediately during the ERCP (Figures 1 and 2). After stent-



**Figure 1** Insertion of fully covered self-expandable metallic stent for the management of periampullary perforation immediately after endoscopic sphincterotomy. A: A peri-ampullary perforation was seen after endoscopic sphincterotomy; B: A fully covered self-expandable metallic stent (5-cm-long, 10 mm in diameter) inserted into the common bile duct to prevent bile entering the perforation site can be seen at the ampulla of Vater.



**Figure 2** Deployed fully covered self-expandable metallic stent on (A) abdominal X-ray and (B) abdominal computed tomography scan.

ing, the patient was stable and was discharged without complications. Although he underwent endoscopy for removal of the stent on day 28 after insertion, the stent had already fallen out spontaneously.

Because fully covered SEMS are available in large diameters, they can be used in a dilated common bile duct without stent migration. They are capable of maintaining long-term patency of the lumen, in contrast to plastic stents. Also, in comparison with uncovered SEMS, fully covered SEMS have several benefits. Uncovered SEMS tend to embed readily in the duct, making it difficult to remove the stent<sup>[62-64]</sup>. Thus, it is inappropriate to use them for benign conditions, such as strictures, obstructions, and traumatic perforations. The fully covered SEMS overcomes these disadvantage, and can be removed readily<sup>[64-66]</sup>.

However, the optimal duration of stenting has not been established. Bakken *et al.*<sup>[67]</sup> reported that the mean duration of stent placement was 67 (range, 0-279) d for benign strictures and 59 (range, 1-601) d for leaks, fistulas, and perforations. Another study showed that the mean duration was 37 (range, 4-84) d for benign conditions<sup>[68]</sup>. While discrepancies exist among studies, the time until stent removal is approximately 2 mo for benign esophageal conditions. Several studies have reported stenting durations in peri-ampullary perforations ranging from 10 to 30 d<sup>[25-28]</sup>. Moreover, because the treatment outcome did not seem to depend on the duration of stenting, and the stent was removed according to the status of the patient, a stent should be removed when the patient shows improved perforation-related symptoms, signs, and imaging results, such as simple abdominal X-rays and abdomi-

nal CT scans, even after 1 wk of stenting.

Although several studies have demonstrated good outcomes using temporary fully covered SEMS in ERCP-related perforations, clinically, the situation has not been clarified entirely. Because treatment failure after non-surgical treatment, including the insertion of plastic stents and fully covered SEMS, can cause high mortality and morbidity, close attention must be paid to the decision on treatment modality. A decision taking into consideration the surgery time, while performed non-surgical treatment, is also important. Unrelieved abdominal pain, continued leakage on abdominal CT scans, or hemodynamic instability despite non-surgical management are considerations relevant to surgical intervention. Thus, frequent physical examinations and serial follow-up using abdominal CT scans are helpful in checking for adverse events or treatment failure. However, a patient's condition, such as cardiopulmonary comorbidity, hemodynamic instability, and old age, is also highly relevant to postoperative mortality. If a patient with peri-ampullary perforation has an inoperable condition due to high postoperative risks, a fully covered SEMS can be attempted for palliative treatment<sup>[26]</sup>. First, it is better to use a fully covered SEMS, especially for a major leakage and large perforation, because ENBD and ERBD may not prevent bile flow into the perforation site completely. Although it is essential to select cases according to their condition, optimal conservative management using a fully covered SEMS may be a good treatment option.

In conclusion, early diagnosis of ERCP-related duodenal perforation is important, and according to the type of perforation, its treatment varies from conservative



management to surgical intervention. Although conservative management is the mainstay for all types of perforations, except type I perforations, the most appropriate treatment modality should be established by performing a comprehensive evaluation of the patient. In particular, a fully covered SEMS for perivaterian perforations was used in selected cases, and the clinical outcomes were encouraging. However, the evidence supporting the use of fully covered SEMS in perivaterian perforations is still insufficient, and further studies are required.

## REFERENCES

- 1 **McCune WS**, Shorb PE, Moscovitz H. Endoscopic cannulation of the ampulla of Vater: a preliminary report. *Ann Surg* 1968; **167**: 752-756 [PMID: 5646296]
- 2 **Lai CH**, Lau WY. Management of endoscopic retrograde cholangiopancreatography-related perforation. *Surgeon* 2008; **6**: 45-48 [PMID: 18318088]
- 3 **Christensen M**, Matzen P, Schulze S, Rosenberg J. Complications of ERCP: a prospective study. *Gastrointest Endosc* 2004; **60**: 721-731 [PMID: 15557948]
- 4 **Coppola R**, Riccioni ME, Ciletti S, Cosentino L, Coco C, Magistrelli P, Picciocchi A. Analysis of complications of endoscopic sphincterotomy for biliary stones in a consecutive series of 546 patients. *Surg Endosc* 1997; **11**: 129-132 [PMID: 9069143]
- 5 **Halme L**, Doepel M, von Numers H, Edgren J, Ahonen J. Complications of diagnostic and therapeutic ERCP. *Ann Chir Gynaecol* 1999; **88**: 127-131 [PMID: 10392249]
- 6 **Loperfido S**, Angelini G, Benedetti G, Chilovi F, Costan F, De Berardinis F, De Bernardin M, Ederle A, Fina P, Fratton A. Major early complications from diagnostic and therapeutic ERCP: a prospective multicenter study. *Gastrointest Endosc* 1998; **48**: 1-10 [PMID: 9684657]
- 7 **Masci E**, Toti G, Mariani A, Curioni S, Lomazzi A, Dinelli M, Minoli G, Crosta C, Comin U, Fertitta A, Prada A, Passoni GR, Testoni PA. Complications of diagnostic and therapeutic ERCP: a prospective multicenter study. *Am J Gastroenterol* 2001; **96**: 417-423 [PMID: 11232684 DOI: 10.1111/j.1572-0241.2001.03594.x]
- 8 **Vaira D**, D'Anna L, Ainley C, Dowsett J, Williams S, Bailie J, Cairns S, Croker J, Salmon P, Cotton P. Endoscopic sphincterotomy in 1000 consecutive patients. *Lancet* 1989; **2**: 431-434 [PMID: 2569609]
- 9 **Vandervoort J**, Soetikno RM, Tham TC, Wong RC, Ferreri AP, Montes H, Roston AD, Slivka A, Lichtenstein DR, Ruyman FW, Van Dam J, Hughes M, Carr-Locke DL. Risk factors for complications after performance of ERCP. *Gastrointest Endosc* 2002; **56**: 652-656 [PMID: 12397271 DOI: 10.1067/mge.2002.129086]
- 10 **Zinsser E**, Hoffmann A, Will U, Koppe P, Bossekert H. Success and complication rates of diagnostic and therapeutic endoscopic retrograde cholangiopancreatography--a prospective study. *Z Gastroenterol* 1999; **37**: 707-713 [PMID: 10494605]
- 11 **Zissin R**, Shapiro-Feinberg M, Oscadchy A, Pomeranz I, Leichtmann G, Novis B. Retroperitoneal perforation during endoscopic sphincterotomy: imaging findings. *Abdom Imaging* 2000; **25**: 279-282 [PMID: 10823451]
- 12 **Enns R**, Eloubeidi MA, Mergener K, Jowell PS, Branch MS, Pappas TM, Baillie J. ERCP-related perforations: risk factors and management. *Endoscopy* 2002; **34**: 293-298 [PMID: 11932784 DOI: 10.1055/s-2002-23650]
- 13 **Pungpapong S**, Kongkam P, Rerknimitr R, Kullavanijaya P. Experience on endoscopic retrograde cholangiopancreatography at tertiary referral center in Thailand: risks and complications. *J Med Assoc Thai* 2005; **88**: 238-246 [PMID: 15962677]
- 14 **Booth FV**, Doerr RJ, Khalafi RS, Luchette FA, Flint LM. Surgical management of complications of endoscopic sphincterotomy with precut papillotomy. *Am J Surg* 1990; **159**: 132-135; discussion 132-135 [PMID: 2294790]
- 15 **Alfieri S**, Rosa F, Cina C, Tortorelli AP, Tringali A, Perri V, Bellantone C, Costamagna G, Doglietto GB. Management of duodeno-pancreato-biliary perforations after ERCP: outcomes from an Italian tertiary referral center. *Surg Endosc* 2013; **27**: 2005-2012 [PMID: 23299135 DOI: 10.1007/s00464-012-2702-9]
- 16 **Wu HM**, Dixon E, May GR, Sutherland FR. Management of perforation after endoscopic retrograde cholangiopancreatography (ERCP): a population-based review. *HPB (Oxford)* 2006; **8**: 393-399 [PMID: 18333093 DOI: 10.1080/13651820600700617]
- 17 **Howard TJ**, Tan T, Lehman GA, Sherman S, Madura JA, Fogel E, Swack ML, Kopecky KK. Classification and management of perforations complicating endoscopic sphincterotomy. *Surgery* 1999; **126**: 658-663; discussion 664-665 [PMID: 10520912]
- 18 **Stapfer M**, Selby RR, Stain SC, Katkhouda N, Parekh D, Jabbour N, Garry D. Management of duodenal perforation after endoscopic retrograde cholangiopancreatography and sphincterotomy. *Ann Surg* 2000; **232**: 191-198 [PMID: 10903596]
- 19 **Fatima J**, Baron TH, Topazian MD, Houghton SG, Iqbal CW, Ott BJ, Farley DR, Farnell MB, Sarr MG. Pancreaticobiliary and duodenal perforations after perampullary endoscopic procedures: diagnosis and management. *Arch Surg* 2007; **142**: 448-454; discussion 454-455 [PMID: 17515486 DOI: 10.1001/archsurg.142.5.448]
- 20 **Lee TH**, Bang BW, Jeong JI, Kim HG, Jeong S, Park SM, Lee DH, Park SH, Kim SJ. Primary endoscopic approximation suture under cap-assisted endoscopy of an ERCP-induced duodenal perforation. *World J Gastroenterol* 2010; **16**: 2305-2310 [PMID: 20458771]
- 21 **Lee TH**, Han JH, Park SH. Endoscopic treatments of endoscopic retrograde cholangiopancreatography-related duodenal perforations. *Clin Endosc* 2013; **46**: 522-528 [PMID: 24143315 DOI: 10.5946/ce.2013.46.5.522]
- 22 **Morgan KA**, Fontenot BB, Ruddy JM, Mickey S, Adams DB. Endoscopic retrograde cholangiopancreatography gut perforations: when to wait! When to operate! *Am Surg* 2009; **75**: 477-483; discussion 483-484 [PMID: 19545095]
- 23 **Polydorou A**, Vezakis A, Fragulidis G, Katsarelis D, Vagianos C, Polymeneas G. A tailored approach to the management of perforations following endoscopic retrograde cholangiopancreatography and sphincterotomy. *J Gastrointest Surg* 2011; **15**: 2211-2217 [PMID: 22005896 DOI: 10.1007/s11605-011-1723-3]
- 24 **Sebastian S**, Byrne AT, Torreggiani WC, Buckley M. Endoscopic closure of iatrogenic duodenal perforation during endoscopic ultrasound. *Endoscopy* 2004; **36**: 245 [PMID: 14986227 DOI: 10.1055/s-2004-814257]
- 25 **Canena J**, Liberato M, Horta D, Romão C, Coutinho A. Short-term stenting using fully covered self-expandable metal stents for treatment of refractory biliary leaks, postsphincterotomy bleeding, and perforations. *Surg Endosc* 2013; **27**: 313-324 [PMID: 22806507 DOI: 10.1007/s00464-012-2368-3]
- 26 **Jeon HJ**, Han JH, Park S, Yoon S, Chae H, Yoon S. Endoscopic sphincterotomy-related perforation in the common bile duct successfully treated by placement of a covered metal stent. *Endoscopy* 2011; **43** Suppl 2 UCTN: E295-E296 [PMID: 21915834 DOI: 10.1055/s-0030-1256464]
- 27 **Park WY**, Cho KB, Kim ES, Park KS. A case of ampullary perforation treated with a temporally covered metal stent. *Clin Endosc* 2012; **45**: 177-180 [PMID: 22866262 DOI: 10.5946/ce.2012.45.2.177]
- 28 **Vezakis A**, Fragulidis G, Nastos C, Yiallourou A, Poly-



- dorou A, Voros D. Closure of a persistent sphincterotomy-related duodenal perforation by placement of a covered self-expandable metallic biliary stent. *World J Gastroenterol* 2011; **17**: 4539-4541 [PMID: 22110286 DOI: 10.3748/wjg.v17.i40.4539]
- 29 **Faylona JM**, Qadir A, Chan AC, Lau JY, Chung SC. Small-bowel perforations related to endoscopic retrograde cholangiopancreatography (ERCP) in patients with Billroth II gastrectomy. *Endoscopy* 1999; **31**: 546-549 [PMID: 10533739 DOI: 10.1055/s-1999-61]
- 30 **Lin LF**, Siauw CP, Ho KS, Tung JC. ERCP in post-Billroth II gastrectomy patients: emphasis on technique. *Am J Gastroenterol* 1999; **94**: 144-148 [PMID: 9934745 DOI: 10.1111/j.1572-0241.1999.00785.x]
- 31 **Wilkinson ML**, Engelman JL, Hanson PJ. Intestinal perforation after ERCP in Billroth II partial gastrectomy. *Gastrointest Endosc* 1994; **40**: 389-390 [PMID: 8056259]
- 32 **Freeman ML**. Complications of endoscopic biliary sphincterotomy: a review. *Endoscopy* 1997; **29**: 288-297 [PMID: 9255535 DOI: 10.1055/s-2007-1004193]
- 33 **Boender J**, Nix GA, de Ridder MA, van Blankenstein M, Schütte HE, Dees J, Wilson JH. Endoscopic papillotomy for common bile duct stones: factors influencing the complication rate. *Endoscopy* 1994; **26**: 209-216 [PMID: 8026367 DOI: 10.1055/s-2007-1008945]
- 34 **Cotton PB**, Lehman G, Vennes J, Geenen JE, Russell RC, Meyers WC, Liguory C, Nickl N. Endoscopic sphincterotomy complications and their management: an attempt at consensus. *Gastrointest Endosc* 1991; **37**: 383-393 [PMID: 2070995]
- 35 **Trap R**, Adamsen S, Hart-Hansen O, Henriksen M. Severe and fatal complications after diagnostic and therapeutic ERCP: a prospective series of claims to insurance covering public hospitals. *Endoscopy* 1999; **31**: 125-130 [PMID: 10223360 DOI: 10.1055/s-1999-13659]
- 36 **Alexiou K**, Sakellariadis T, Sikalias N, Karanikas I, Economou N, Antsaklis G. Subcutaneous emphysema, pneumomediastinum and pneumoperitoneum after unsuccessful ERCP: a case report. *Cases J* 2009; **2**: 120 [PMID: 19192290 DOI: 10.1186/1757-1626-2-120]
- 37 **Ciaccia D**, Branch MS, Baillie J. Pneumomediastinum after endoscopic sphincterotomy. *Am J Gastroenterol* 1995; **90**: 475-477 [PMID: 7872289]
- 38 **Colemont LJ**, Pelckmans PA, Moorkens GH, Van Maercke YM. Unilateral periorbital emphysema: an unusual complication of endoscopic papillotomy. *Gastrointest Endosc* 1988; **34**: 473-475 [PMID: 3234686]
- 39 **Merine D**, Fishman EK. Uncomplicated portal venous gas associated with duodenal perforation following ERCP: CT features. *J Comput Assist Tomogr* 1989; **13**: 138-139 [PMID: 2910933]
- 40 **Savides T**, Sherman S, Kadell B, Cryer H, Derezin M. Bilateral pneumothoraces and subcutaneous emphysema after endoscopic sphincterotomy. *Gastrointest Endosc* 1993; **39**: 814-817 [PMID: 8293908]
- 41 **Scarlett PY**, Falk GL. The management of perforation of the duodenum following endoscopic sphincterotomy: a proposal for selective therapy. *Aust N Z J Surg* 1994; **64**: 843-846 [PMID: 7980259]
- 42 **Tam F**, Prindiville T, Wolfe B. Subcutaneous emphysema as a complication of endoscopic sphincterotomy of the ampulla of Vater. *Gastrointest Endosc* 1989; **35**: 447-449 [PMID: 2551769]
- 43 **Genzlinger JL**, McPhee MS, Fisher JK, Jacob KM, Helzberg JH. Significance of retroperitoneal air after endoscopic retrograde cholangiopancreatography with sphincterotomy. *Am J Gastroenterol* 1999; **94**: 1267-1270 [PMID: 10235205 DOI: 10.1111/j.1572-0241.1999.00996.x]
- 44 **Gottlieb K**, Sherman S, Pezzi J, Esber E, Lehman GA. Early recognition of post-ERCP pancreatitis by clinical assessment and serum pancreatic enzymes. *Am J Gastroenterol* 1996; **91**: 1553-1557 [PMID: 8759660]
- 45 **Testoni PA**, Bagnolo F. Pain at 24 hours associated with amylase levels greater than 5 times the upper normal limit as the most reliable indicator of post-ERCP pancreatitis. *Gastrointest Endosc* 2001; **53**: 33-39 [PMID: 11154486 DOI: 10.1067/mge.2001.111390]
- 46 **Bell RC**, Van Stiegmann G, Goff J, Reveille M, Norton L, Pearlman NW. Decision for surgical management of perforation following endoscopic sphincterotomy. *Am Surg* 1991; **57**: 237-240 [PMID: 2053743]
- 47 **Marano BJ**, Bonanno CA. Metallic biliary endoprosthesis causing duodenal perforation and acute upper gastrointestinal bleeding. *Gastrointest Endosc* 1994; **40**: 257-258 [PMID: 8013842]
- 48 **Matsuda T**, Fujii T, Emura F, Kozu T, Saito Y, Ikematsu H, Saito D. Complete closure of a large defect after EMR of a lateral spreading colorectal tumor when using a two-channel colonoscope. *Gastrointest Endosc* 2004; **60**: 836-838 [PMID: 15557972]
- 49 **Mutignani M**, Iacopini F, Dokas S, Larghi A, Familiari P, Tringali A, Costamagna G. Successful endoscopic closure of a lateral duodenal perforation at ERCP with fibrin glue. *Gastrointest Endosc* 2006; **63**: 725-727 [PMID: 16564890 DOI: 10.1016/j.gie.2005.11.028]
- 50 **Nakagawa Y**, Nagai T, Soma W, Okawara H, Nakashima H, Tasaki T, Hisamatu A, Hashinaga M, Murakami K, Fujioka T. Endoscopic closure of a large ERCP-related lateral duodenal perforation by using endoloops and endoclips. *Gastrointest Endosc* 2010; **72**: 216-217 [PMID: 20304402 DOI: 10.1016/j.gie.2009.10.040]
- 51 **Buffoli F**, Grassia R, Iiritano E, Bianchi G, Dizioli P, Staiano T. Endoscopic "retroperitoneal fatpexy" of a large ERCP-related jejunal perforation by using a new over-the-scope clip device in Billroth II anatomy (with video). *Gastrointest Endosc* 2012; **75**: 1115-1117 [PMID: 21820111 DOI: 10.1016/j.gie.2011.05.029]
- 52 **Doğan ÜB**, Keskin MB, Söker G, Akın MS, Yalaki S. Endoscopic closure of an endoscope-related duodenal perforation using the over-the-scope clip. *Turk J Gastroenterol* 2013; **24**: 436-440 [PMID: 24557968]
- 53 **Martin DF**, Tweedle DE. Retroperitoneal perforation during ERCP and endoscopic sphincterotomy: causes, clinical features and management. *Endoscopy* 1990; **22**: 174-175 [PMID: 2209500 DOI: 10.1055/s-2007-1012833]
- 54 **Chung RS**, Sivak MV, Ferguson DR. Surgical decisions in the management of duodenal perforation complicating endoscopic sphincterotomy. *Am J Surg* 1993; **165**: 700-703 [PMID: 8506969]
- 55 **Ciostek P**, Bielska H, Myrcha P, Jarosz O, Milewski J, Noszczyk W. [Surgical tactics in treatment of duodenal injuries after endoscopic sphincterotomy]. *Wiad Lek* 1997; **50** Suppl 1 Pt 2: 421-424 [PMID: 9424916]
- 56 **Neri V**, Ambrosi A, Fersini A, Valentino TP. Duodenal perforation in course of endoscopic retrograde cholangiopancreatography-endoscopic sphincterotomy. Therapeutic considerations. *Ann Ital Chir* 2006; **77**: 161-164 [PMID: 17147091]
- 57 **Sarr MG**, Fishman EK, Milligan FD, Siegelman SS, Cameron JL. Pancreatitis or duodenal perforation after peri-Vaterian therapeutic endoscopic procedures: diagnosis, differentiation, and management. *Surgery* 1986; **100**: 461-466 [PMID: 3738765]
- 58 **Kim BS**, Kim IG, Ryu BY, Kim JH, Yoo KS, Baik GH, Kim JB, Jeon JY. Management of endoscopic retrograde cholangiopancreatography-related perforations. *J Korean Surg Soc* 2011; **81**: 195-204 [PMID: 22066121 DOI: 10.4174/jkss.2011.81.3.195]
- 59 **Kim JH**, Yoo BM, Kim JH, Kim MW, Kim WH. Management of ERCP-related perforations: outcomes of single institution in Korea. *J Gastrointest Surg* 2009; **13**: 728-734 [PMID:

- 19130154 DOI: 10.1007/s11605-008-0786-2]
- 60 **Siersema PD**, Schrauwen SL, van Blankenstein M, Steyerberg EW, van der Gaast A, Tilanus HW, Dees J. Self-expanding metal stents for complicated and recurrent esophagogastric cancer. *Gastrointest Endosc* 2001; **54**: 579-586 [PMID: 11677473]
- 61 **Siersema PD**, Homs MY, Haringsma J, Tilanus HW, Kuipers EJ. Use of large-diameter metallic stents to seal traumatic nonmalignant perforations of the esophagus. *Gastrointest Endosc* 2003; **58**: 356-361 [PMID: 14528208]
- 62 **Baron TH**. Covered self-expandable metal stents for benign biliary tract diseases. *Curr Opin Gastroenterol* 2011; **27**: 262-267 [PMID: 21248636 DOI: 10.1097/MOG.0b013e3283438a26]
- 63 **Dumonceau JM**, Devière J, Delhaye M, Baize M, Cremer M. Plastic and metal stents for postoperative benign bile duct strictures: the best and the worst. *Gastrointest Endosc* 1998; **47**: 8-17 [PMID: 9468417]
- 64 **García-Cano J**, Taberna-Arana L, Jimeno-Ayllón C, Martínez-Fernández R, Serrano-Sánchez L, Reyes-Guevara AK, Viñuelas-Chicano M, Gómez-Ruiz CJ, Morillas-Ariño MJ, Pérez-García JL, Pérez-Vigara G, Pérez-Sola A. Use of fully covered self-expanding metal stents for the management of benign biliary conditions. *Rev Esp Enferm Dig* 2010; **102**: 526-532 [PMID: 20883068]
- 65 **Mahajan A**, Ho H, Sauer B, Phillips MS, Shami VM, Ellen K, Rehan M, Schmitt TM, Kahaleh M. Temporary placement of fully covered self-expandable metal stents in benign biliary strictures: midterm evaluation (with video). *Gastrointest Endosc* 2009; **70**: 303-309 [PMID: 19523620 DOI: 10.1016/j.gie.2008.11.029]
- 66 **Wang AY**, Ellen K, Berg CL, Schmitt TM, Kahaleh M. Fully covered self-expandable metallic stents in the management of complex biliary leaks: preliminary data - a case series. *Endoscopy* 2009; **41**: 781-786 [PMID: 19693751 DOI: 10.1055/s-0029-1215050]
- 67 **Bakken JC**, Wong Kee Song LM, de Groen PC, Baron TH. Use of a fully covered self-expandable metal stent for the treatment of benign esophageal diseases. *Gastrointest Endosc* 2010; **72**: 712-720 [PMID: 20883848 DOI: 10.1016/j.gie.2010.06.028]
- 68 **Senousy BE**, Gupte AR, Draganov PV, Forsmark CE, Wagh MS. Fully covered Alimaxx esophageal metal stents in the endoscopic treatment of benign esophageal diseases. *Dig Dis Sci* 2010; **55**: 3399-3403 [PMID: 20859687 DOI: 10.1007/s10620-010-1415-y]

**P- Reviewer:** ElGeidie AAR, Murata A **S- Editor:** Ji FF  
**L- Editor:** A **E- Editor:** Lu YJ



## Simultaneous *vs* staged treatment of urolithiasis in patients undergoing radical prostatectomy

Boyd R Viers, Matthew K Tollefson, David E Patterson, Matthew T Gettman, Amy E Krambeck

Boyd R Viers, Matthew K Tollefson, David E Patterson, Matthew T Gettman, Amy E Krambeck, Mayo Clinic Department of Urology, Rochester, MN 55902, United States

**Author contributions:** Viers BR contributed to the study design, data acquisition and analysis and manuscript drafting; Tollefson MK, Patterson DE and Gettman MT assisted with data acquisition, manuscript review and revisions; Krambeck AE assisted with study design, data interpretation, drafting, review and revisions of manuscript and resided as the senior author for this manuscript.

**Correspondence to:** Amy E Krambeck, MD, Mayo Clinic Department of Urology, 200 1<sup>st</sup> SW, Rochester, MN 55902, United States. [krambeck.amy@mayo.edu](mailto:krambeck.amy@mayo.edu)

Telephone: +1-507-2849983 Fax: +1-507-2844951

Received: June 24, 2014 Revised: September 17, 2014

Accepted: October 1, 2014

Published online: November 16, 2014

### Abstract

**AIM:** To assess the outcomes of men treated for urolithiasis at the time of radical prostatectomy.

**METHODS:** From 1991 to 2010, 22 patients were retrospectively identified who were treated simultaneously ( $n = 10$ ) at radical prostatectomy, or ( $n = 12$ ) within 120 d prior to prostatectomy, for urolithiasis. Clinical characteristics were reviewed including: type of prostatectomy and stone surgery, location and amount of stone burden, perioperative change in hemoglobin and creatinine, stent frequency, total hospital d, stone-free rates, additional stone procedures and complications. Long-term functional outcomes including stress urinary incontinence and bladder neck contracture were reported. Differences between cohorts (simultaneous *vs* staged treatment) were assessed.

**RESULTS:** Among men undergoing radical prostatectomy, primary stone procedures included 12 ureteroscopy, 6 shock wave lithotripsy, 2 open nephrolithotomy

and 2 percutaneous nephrolithotomy. In staged shock wave lithotripsy there were 4 complications and 3 additional procedures *vs* 1 ( $P = 0.5$ ) and 0 ( $P = 0.2$ ) in the simultaneous cohort. Meanwhile in staged ureteroscopy there were 5 complications and 1 additional procedure *vs* 1 ( $P = 0.2$ ) and 1 ( $P = 0.9$ ) in the simultaneous cohort. Additional procedures for residual stones was greater among patients with asymptomatic upper tract calculi 3 (60%) relative to patients with symptomatic stones 2 (13%;  $P = 0.02$ ). Likewise, patients with proximal or multiple calculi had a greater total hospital days 5.5 *vs* 4.1 ( $P = 0.04$ ), additional procedures 6 *vs* 0 ( $P = 0.04$ ) and lower stone-free rates 39% *vs* 89% ( $P = 0.02$ ) relative to men with distal stones. Finally, there was no difference in the incidence of bladder neck contracture ( $P = 0.4$ ) or stress urinary incontinence ( $P = 0.7$ ) between cohorts.

**CONCLUSION:** Ureteroscopic treatment of symptomatic distal urolithiasis at radical prostatectomy appears to be safe and efficacious with a low rate of adverse postoperative outcomes.

© 2014 Baishideng Publishing Group Inc. All rights reserved.

**Key words:** Urolithiasis; Kidney stone; Prostate cancer; Radical prostatectomy

**Core tip:** Prostate cancer and urolithiasis can present simultaneously. An acute stone event in the immediate perioperative radical prostatectomy period poses unique management issues. Herein, we describe our experience with the simultaneous treatment of urolithiasis at the time of prostatectomy. We concluded that simultaneous ureteroscopy among symptomatic men with distal ureteral calculi appears to be safe and efficacious. Whereas, in asymptomatic men, or those with proximal/multiple calculi, one should consider treatment in a staged fashion secondary to an increased risk of additional procedures and lower stone-free rates.

Viers BR, Tollefson MK, Patterson DE, Gettman MT, Krambeck AE. Simultaneous vs staged treatment of urolithiasis in patients undergoing radical prostatectomy. *World J Clin Cases* 2014; 2(11): 698-704 Available from: URL: <http://www.wjg-net.com/2307-8960/full/v2/i11/698.htm> DOI: <http://dx.doi.org/10.12998/wjcc.v2.i11.698>

## INTRODUCTION

The incidence of urolithiasis and associated healthcare costs continues to rise<sup>[1-5]</sup>. Specifically, the prevalence of stone disease in the male population ages 50 to 74 years old has increased from 13% from 1988-1994 to 19% in 2007-2010<sup>[2]</sup>, representing a roughly equivalent to 40% relative increase in stone disease<sup>[6]</sup>. A similar increase in the incidence of prostate cancer has also been observed due to prostate-specific antigen (PSA) screening<sup>[7-11]</sup>. Currently, it is estimated that greater than 240000 patients are diagnosed with prostate cancer annually in the United States<sup>[8,9]</sup>. As such, a significant number of male patients diagnosed with prostate cancer may harbor urolithiasis.

As part of prostate cancer evaluation a subset of high-risk men undergo cross-sectional imaging to evaluate for metastatic disease<sup>[12-15]</sup>. If urinary stone disease is discovered, these patients pose a complex management dilemma given that 44% of asymptomatic patients with urolithiasis will develop symptoms within 1.3 years<sup>[16-19]</sup>. An acute stone event within the immediate post radical prostatectomy period poses a unique concern; specifically, instrumentation of the fresh vesicourethral anastomosis has the potential for anastomotic injury with resultant long-term urinary incontinence<sup>[20,21]</sup> and/or bladder neck contracture<sup>[22,23]</sup>. Historically, at our institution, such cases have been temporized with a nephrostomy tube and delayed definitive stone management until after the vesicourethral anastomosis matures (approximately 120 d).

To date, the safety and feasibility of synchronous treatment of urinary stone disease at radical prostatectomy is unknown. The goal of this study is to assess outcomes of patients with upper tract stone disease treated at the time of prostatectomy compared to those treated in the preoperative period.

## MATERIALS AND METHODS

We retrospectively reviewed all male patients who underwent radical prostatectomy from 1991 to 2010. A total of 22 patients were identified who underwent radical retropubic prostatectomy (RRP) or robotic-assisted radical prostatectomy (RARP) treated simultaneously, or within 120 d preoperatively, for urolithiasis. We evaluated clinical characteristics including type of prostatectomy and stone surgery, location and amount of stone burden, perioperative change in hemoglobin and creatinine, stent frequency, total hospital days, stone-free rates, additional stone procedures and postoperative complications including: steinstrasse, intraoperative bleeding requiring

transfusion, acute kidney injury<sup>[24]</sup>, and urosepsis. The total length of hospital stay included both stone and radical prostatectomy procedure. Urinary incontinence was defined as bothersome leakage with straining or need for pad. Bladder neck contracture was identified during post-prostatectomy cystoscopy for obstructive voiding symptoms.

The urinary stone procedure was determined by the operating surgeon based on stone location, timing and type of radical prostatectomy. Simultaneous primary stone intervention was defined as occurring under the same anesthetic as the radical prostatectomy. Staged stone treatments were those within the 120 d before prostatectomy. Maximum stone diameter, location and total burden were determined by preoperative abdominal radiography or computerized tomography. Urolithiasis follow-up included metabolic evaluation, urinalysis with culture and kidney, ureter, and bladder (KUB) X-ray with renal ultrasound between 6-12 wk following stone treatment. Additional cross-sectional imaging, or KUB X-ray with tomograms, was obtained based upon patient symptomology and at the discretion of the treating provider. Stone-free status, after the primary stone procedure was defined as no residual fragments. Post-operative prostate cancer surveillance included physical examinations and serum PSA measurement quarterly for 2 years, semiannually for an additional 2 years and annually thereafter.

Statistical analysis was performed with Student's *t*-test or Wilcoxon Rank Sum for continuous data and Chi-Square or Fisher's Exact test for categorical outcome analysis using JMP software (SAS Institute Inc., Cary, North Carolina), with a *P* value < 0.05 considered statistically significant.

## RESULTS

A total of 29 stone procedures were performed in 19 (86%) men undergoing RRP and 3 (14%) RARP at a median age of 65 years [Interquartile range (IQR) 62-69] (Table 1). Mean follow-up in the simultaneous cohort was 48.5 mo *vs* 45.7 mo in staged patients. In the staged cohort stones were treated prior to radical prostatectomy at a median 31 d (IQR 21-55). A prior history of urolithiasis was present in 16 (73%) men overall. At the time of stone surgery 17 (77%) men presented with one or more symptoms of flank pain, hematuria, urinary tract infection, pyelonephritis or acute renal failure. Ureteral stent was placed in 20 of 21 patients (95%) and nephrostomy tube only in 1 patient. In the simultaneous cohort, ureteral stent was removed at the time of urethral catheter removal 14 d post-prostatectomy with stent string secured to urinary catheter in 4 (40%), *via* clinic cystoscopy 21 d after procedure in 3 (30%), at the time of subsequent stone procedure in 1 (10%) or other method in 2 (20%). In staged patients, ureteral stents were all removed prior to radical prostatectomy or at the time of RRP. Follow-up imaging to determine stone-free status was obtained



**Table 1 Patient demographics *n* (%)**

	Simultaneous ( <i>n</i> = 10)	Staged ( <i>n</i> = 12)	<i>P</i> -value
Age (yr), median (IQR)	68 (60-71)	63 (62-67)	0.4 <sup>1</sup>
Stone size (mm), mean ± SD	8.0 ± 3.8	9.9 ± 5.3	0.3 <sup>1</sup>
Location			
Renal	2 (20)	2 (17)	0.8 <sup>2</sup>
Proximal	2 (20)	2 (17)	0.8 <sup>2</sup>
Multiple	1 (10)	4 (33)	0.2 <sup>2</sup>
Distal	5 (50)	4 (33)	0.4 <sup>2</sup>
Procedure ( <i>n</i> = 29)	11	18	
Open	2 (18)	0 (0)	-
Rigid URS	5 (46)	5 (28)	-
Flexible URS	2 (18)	4 (22)	-
SWL	2 (18)	4 (22)	-
PCNL	0 (0)	5 (28)	-
RARP	1 (10)	2 (17)	-
RRP	9 (90)	10 (83)	-
Patient symptomatic	7 (70)	10 (83)	0.5 <sup>3</sup>
History of stones	9 (90)	7 (58)	0.1 <sup>3</sup>

<sup>1</sup>Student's *t*-test; <sup>2</sup>Fisher's Exact; <sup>3</sup>χ<sup>2</sup>. IQR: Interquartile range; SD: Standard deviation; SWL: Shock wave lithotripsy; URS: Ureteroscopy; PCNL: Percutaneous nephrolithotomy; RARP: Robot assisted radical prostatectomy; RRP: Radical retropubic prostatectomy.

in all patients. Mean stone diameter was 9.1 mm (range 4-20 mm) with no difference in stone size or location between groups. After the initial stone procedure, 6 (60%) simultaneous and 7 (58%) staged were stone-free (*P* = 0.9) with no difference in stone size between stone-free patients and those with residual calculi (mean 8.3 mm *vs* 10.2 mm; *P* = 0.3).

Postoperative complications were noted in 5 (42%) staged and 3 (30%) simultaneous patients (*P* = 0.6), for a total of 7 and 3 complications (*P* = 0.3) (Table 2). In the simultaneous cohort, bleeding requiring transfusion occurred during radical prostatectomy in 2 (20%) and postoperative urosepsis in 1 (10%). In the staged cohort, there were 7 complications in 5 (42%) patients including 2 (17%) steinstrasse, 4 (33%) bleeding events during and 1 (8%) acute kidney injury after radical prostatectomy. Overall, bladder neck contracture occurred in 3 (14%) patients of whom all required bladder neck dilation. Stress urinary incontinence persisted in 7 (39%), with 1 (4.5%) requiring artificial urinary sphincter and 6 (27%) utilizing ≤ 1 pad with activity.

We then performed a subgroup analysis of simultaneous *vs* staged ureteroscopy (URS) and shock wave lithotripsy (SWL) and found no significant difference in outcomes between groups including: perioperative complications, bladder neck contracture, urinary incontinence, stone-free rates or number of additional procedures (Tables 3 and 4). Among patients undergoing simultaneous URS there were no stone related complications or bladder neck contractures; furthermore only 1 (17%) patient required an additional procedure. In those undergoing SWL, 4 (67%) patients experienced significant complications and 3 (50%) required additional procedures.

**Table 2 Simultaneous *vs* staged urinary stone treatment at time of prostatectomy *n* (%)**

	Simultaneous ( <i>n</i> = 10)	Staged ( <i>n</i> = 12)	<i>P</i> -value
Patient complications	3 (30)	5 (42)	0.6 <sup>1</sup>
Steinstrasse	0 (0)	2 (17)	0.2 <sup>1</sup>
Bleeding <sup>2</sup>	2 (20)	4 (33)	0.5 <sup>1</sup>
AKI	0 (0)	1 (8)	0.4 <sup>1</sup>
Urosepsis	1 (10)	0 (0)	0.3 <sup>1</sup>
BNC	2 (20)	1 (8)	0.4 <sup>1</sup>
Urinary incontinence	2 (33)	5 (42)	0.7 <sup>1</sup>
Change in Cr (mg/dL), mean ± SD	0.04 ± 0.2	-0.2 ± 0.5	0.1 <sup>3</sup>
change in Hb (g/dL), mean ± SD	3.9 ± 1.4	4.7 ± 1.6	0.2 <sup>3</sup>
Hospital (d), mean ± SD	4.5 ± 3.8	5.5 ± 2.8	0.5 <sup>3</sup>
Stone free	6 (60)	7 (58)	0.9 <sup>4</sup>
Multiple procedures	1 (10)	4 (33)	0.2 <sup>4</sup>
Avg. # stone procedures, mean ± SD	1.1 ± 0.3	1.4 ± 0.7	0.2 <sup>3</sup>

<sup>1</sup>Fisher's Exact; <sup>2</sup>Occurred at the time of prostatectomy; <sup>3</sup>Student's *t*-test; <sup>4</sup>χ<sup>2</sup>. BNC: Bladder neck contracture; AKI: Acute kidney injury; Cr: Creatinine; Hb: Hemoglobin; SD: Standard deviation.

When stratified by symptomology, 5 (23%) were asymptomatic and 17 (77%) had stone related symptoms; of which, multiple procedures were required in 3 (60%) *vs* 2 (12%; *P* = 0.02) respectively with no difference in adverse events or length of hospitalization. When stone location was analyzed, 9 (41%) patients had distal ureteral calculi and 13 (59%) had proximal or multiple stones. Relative to patients with multiple or proximal stones, patients with distal calculi had a significantly shorter hospital stay (mean 4.1 *vs* 5.5 d; *P* = 0.040) and need for subsequent procedures (mean 1.0 procedures/patient; *P* = 0.03). Moreover, in proximal or multiple stones, 5 (36%) patients required 6 additional procedures (mean 1.46 procedures/patient; *P* = 0.050) with a stone-free rate following the initial procedure of 5 (39%) *vs* 8 (89%) for distal ureteral calculi (*P* = 0.02). Finally, there was no difference in complications among those with distal stones compared to proximal or multiple stones [3 (33%) *vs* 5 (38%); *P* = 0.8].

## DISCUSSION

We evaluate the feasibility, safety and efficacy of simultaneous prostate cancer and urinary stone disease treatment. The potential advantages of this approach include the minimization of perioperative complications associated with urolithiasis and the need for additional procedures. We found no significant difference in treatment outcomes among simultaneous or staged patients; including those men undergoing URS. Meanwhile, men with multiple or proximal stones were at increased risk for additional procedures, longer hospitalization and lower stone-free rates relative to those with distal stones. Similarly, asymptomatic patients were more likely to require additional procedures. Finally, men undergoing SWL had a high rate of stone related complications and retreatment making this a poor option for a simultaneous

**Table 3 Simultaneous *vs* staged ureteroscopic stone treatment at time of prostatectomy *n* (%)**

	Simultaneous ( <i>n</i> = 6)	Staged ( <i>n</i> = 7)	<i>P</i> -value
Age (yr), median (IQR)	70 (65-71)	63 (61-68)	0.06 <sup>1</sup>
Patient complications	1 (17)	3 (43)	0.3 <sup>2</sup>
Steinstrasse	0 (0)	0 (0)	-
Bleeding <sup>3</sup>	1 (17)	3 (43)	0.3 <sup>2</sup>
AKI	0 (0)	1 (14)	0.3 <sup>2</sup>
BNC	0 (0)	1 (14)	0.3 <sup>2</sup>
Urinary Incontinence	2 (40)	3 (43)	0.9 <sup>2</sup>
Change in Cr (mg/dL), mean $\pm$ SD	0.04 $\pm$ 0.1	-0.4 $\pm$ 0.5	0.1 <sup>4</sup>
Change in Hb (g/dL), mean $\pm$ SD	4.1 $\pm$ 1.8	5.1 $\pm$ 0.9	0.2 <sup>4</sup>
Hospital (d), mean $\pm$ SD	2.8 $\pm$ 2.1	5.5 $\pm$ 3.5	0.1 <sup>4</sup>
Multiple procedures	1 (17)	1 (14)	0.9 <sup>4</sup>
Avg. # stone procedures, mean $\pm$ SD	1.2 $\pm$ 0.4	1.1 $\pm$ 0.4	0.9 <sup>4</sup>
Stone free	4 (67)	6 (86)	0.4 <sup>4</sup>
Stone size (mm), mean $\pm$ SD	5.8 $\pm$ 1.7	6.9 $\pm$ 2.3	0.3 <sup>4</sup>

<sup>1</sup>Student's *t*-test; <sup>2</sup>Fisher's Exact; <sup>3</sup>Occurred at the time of prostatectomy; <sup>4</sup> $\chi^2$ . BNC: Bladder neck contracture; AKI: Acute kidney injury; Cr: Creatinine; Hb: Hemoglobin; SD: Standard deviation.

treatment approach. As such, given its low rate of complications, and need for secondary procedures, we conclude that there is a potential role for the simultaneous use of URS to treat symptomatic distal ureteral stones at the time of RP.

With a high incidence of prostate cancer<sup>[7-9]</sup> and urolithiasis in the aging male population<sup>[2]</sup>, a significant proportion of these men may present with urinary stone disease discovered during cancer staging and treatment. In general, asymptomatic urolithiasis has an 8% prevalence with approximately 20% developing a symptomatic stone event within 1.3 years<sup>[16]</sup>; and, up to 26% may require surgical intervention<sup>[18]</sup>. However, the appropriate management of the asymptomatic patient that is incidentally found to have stone disease prior to radical prostatectomy remains unknown. Furthermore, for the symptomatic patient that presents a trial of passage may be a reasonable option. However, in those patients who fail medical expulsion therapy<sup>[25,26]</sup>, elect for surgical management<sup>[27]</sup>, or have high-risk prostate cancer the timing of urinary stone treatment becomes paramount.

Meanwhile, the risk of injury to the vesicourethral anastomosis with instrumentation is likely greatest in the immediate postoperative period. Unfortunately, little work has been done to assess the true risk to radical prostatectomy patients undergoing instrumentation for urinary stone treatment in the perioperative period. Gibbons *et al*<sup>[28]</sup> evaluated the feasibility of retrograde endoscopy in the post-prostatectomy patient. They observed no complications or adverse effect on urinary continence in 21 patients with a mean interval between radical prostatectomy and retrograde endoscopy of 24 mo<sup>[28]</sup>. Although reassuring, their series may not reflect the true long-term risk due to a short follow-up and significant time between prostatectomy and endoscopy. Herein, we found no significant difference between groups with 14%

**Table 4 Simultaneous *vs* staged SWL at time of prostatectomy *n* (%)**

	Simultaneous ( <i>n</i> = 2)	Staged ( <i>n</i> = 4)	<i>P</i> -value
Age (yr), median (IQR)	55 (53-57)	63 (62-65)	0.1 <sup>1</sup>
Patient complications	1 (50)	3 (75)	0.5 <sup>2</sup>
Steinstrasse	0 (0)	2 (50)	0.2 <sup>2</sup>
Bleeding <sup>3</sup>	0 (0)	2 (50)	0.2 <sup>2</sup>
AKI	0 (0)	0 (0)	-
Urosepsis	1 (50)	0 (0)	0.1 <sup>2</sup>
BNC	0 (0)	0 (0)	-
Urinary incontinence	-	1 (25)	-
Change in Cr (mg/dL), mean $\pm$ SD	0.15 $\pm$ 0.4	-0.3 $\pm$ 0.3	0.4 <sup>1</sup>
Change in Hb (g/dL), mean $\pm$ SD	3.9 $\pm$ 0.8	5.1 $\pm$ 1.7	0.5 <sup>1</sup>
Hospital (d), mean $\pm$ SD	4.0 $\pm$ 1.4	4.8 $\pm$ 1.5	0.6 <sup>1</sup>
Multiple procedures	0	3 (75)	0.08 <sup>2</sup>
Avg. # stone procedures, mean $\pm$ SD	1.0 (0.0)	2.0 (0.8)	0.2 <sup>1</sup>
Stone free	2 (100)	1 (25)	0.08 <sup>2</sup>
Stone size (mm), mean $\pm$ SD	12.5 $\pm$ 6.4	10.4 $\pm$ 1.3	1.0 <sup>1</sup>

<sup>1</sup>Wilcoxon Rank Sum; <sup>2</sup>Fisher's Exact; <sup>3</sup>Occurred at the time of prostatectomy. BNC: Bladder neck contracture; AKI: Acute kidney injury; Cr: Creatinine; Hb: Hemoglobin.

developing bladder neck contracture and 39% having mild to moderate urinary incontinence at last follow-up. Currently, depending on method of evaluation, 60%-93% of patients will regain urinary continence by 12 mo<sup>[20]</sup> and 2%-18% develop bladder neck contracture<sup>[22]</sup>, which is not considerably different from our cohort.

In our series complications occurred in 42% *vs* 30% and additional stone procedures in 33% *vs* 10% of staged and simultaneous patients, respectively. We included complications secondary to the stone procedure (urosepsis and steinstrasse) and radical prostatectomy (bleeding). Thus, our increased rate of overall complications is not typically observed with traditional stone procedures. Furthermore, after subgroup analysis of patients undergoing URS and SWL, there remained no significant difference in outcomes. However, in SWL, 50% of staged patients developed steinstrasse and 75% required subsequent procedures which may place a patient at undue risk following prostatectomy. Salem *et al*<sup>[29]</sup> prospectively evaluated over 3000 patients undergoing SWL and noted a retreatment rate of 37% and steinstrasse in 24% of patients. Our increased retreatment rate reflects an attempt to render all patients stone-free following SWL and limit acute stone events following radical prostatectomy. As such, given the high rate of secondary procedures we feel that SWL should only be performed in a staged setting.

Multiple studies have established the importance of stone size, location and number in predicting stone-free rates<sup>[30-35]</sup>. Rippel *et al*<sup>[30]</sup> evaluated patients with CT imaging 30 to 90 d post-operatively. On univariate analysis 49% patients with multiple and 50% with intrarenal calculi had residual stone fragments greater than 2 mm. In our study, only stone location was significantly associated with a risk of retreatment as 38% of patients with proxi-

mal or multiple stones required additional procedures. Meanwhile our stone-free rate, although not significantly different between simultaneous and staged patients, was lower in patients with multiple or upper tract stones ( $P = 0.02$ ) with no difference based on stone burden ( $P = 0.3$ ).

Interestingly, patient symptomology was significantly associated with an increased risk of subsequent procedures as 60% of asymptomatic patients required additional stone treatment. We hypothesize that urinary obstruction over time allows for passive dilation of the collecting system thus increasing compliance and allowing ease of stone passage and instrumentation. Frequently, in our experience, the treatment of asymptomatic patients in a single-stage setting can be difficult often requiring multiple procedures and leading to increased complications. Keeley *et al.*<sup>[36]</sup> prospectively evaluated patients undergoing SWL treatment of small ( $< 15$  mm) asymptomatic renal calculi and found a stone-free rate of only 28% at 2.2 years. Despite evidence suggesting that a patient's symptomatology may be a predictor of treatment outcomes; this question has yet to be previously addressed among patients undergoing URS.

Certain limitations of our study exist. We acknowledge that the small patient population, and its retrospective nature, may limit any definitive clinical recommendations for a change of practice. Furthermore, we do not know the incidence of symptomatic progression of urinary stone disease following RP in those men who undergo expectant management preoperatively. Despite these limitations, this study attempts to address the safety, feasibility and utility of performing simultaneous stone treatment at the time of radical prostatectomy. We demonstrate no difference in outcomes which may suggest a role for simultaneous stone removal, specifically URS, in appropriately selected patients. Further prospective trials are needed to identify eligible patients, risk factors for significant short and long-term complications and cost-analysis of a single-stage procedure.

The current study demonstrates that simultaneous treatment of symptomatic distal urolithiasis with URS at the time of radical prostatectomy is safe and efficacious. Meanwhile, given the high rate of residual stone fragments and re-instrumentation following SWL, we recommend it be performed in a staged fashion. Finally, in asymptomatic patients, or those with multiple or upper tract stones, one should consider a staged approach due to the increased risk of additional procedures and reduced stone-free rates.

## COMMENTS

### Background

The prevalence of urinary stone disease in the male population ages 50 to 74 years old has increased from 13% from 1988-1994 to 19% in 2007-2010, representing a roughly equivalent to 40% relative increase in stone disease. A similar increase in the incidence of prostate cancer has also been observed due to PSA screening. As such, a significant number of male patients diagnosed with prostate cancer may harbor urolithiasis. If urinary stone disease is discovered, these patients pose a complex management dilemma given that 44% of asymptomatic patients with urolithiasis will develop symptoms within 1.3 years. An

acute stone event within the immediate post radical prostatectomy period poses a unique concern; specifically, instrumentation of the fresh vesicourethral anastomosis has the potential for anastomotic injury with resultant long-term urinary incontinence and/or bladder neck contracture.

### Research frontiers

Ongoing research in the field of urinary stone disease is attempting to identify modifiable patient risk factors to prevent future stone events. Moreover, among men undergoing radical prostatectomy for prostate cancer, significant research efforts are ongoing, including investigation of minimally invasive techniques and minimizing post prostatectomy complications such as urinary incontinence and bladder neck contracture; which can be disabling.

### Innovations and breakthroughs

To the best of our knowledge, this is the first study to investigate the safety and efficacy of synchronous upper tract urinary stone treatment at the time of radical prostatectomy. One previous study has evaluated the association between upper tract endoscopy following radical prostatectomy and stress urinary incontinence. They found no difference in outcomes among men underwent ureteroscopy at a mean 24 mo following prostatectomy.

### Applications

With a high incidence of prostate cancer and urolithiasis in the aging male population, a significant proportion of these men may present with urinary stone disease discovered during cancer staging and treatment. In general, asymptomatic urolithiasis has an 8% prevalence with approximately 20% developing a symptomatic stone event within 1.3 years; and, up to 26% requiring surgical intervention. Meanwhile, the risk of injury to the vesicourethral anastomosis with instrumentation in the setting of an acute stone event is likely greatest in the immediate postoperative period. As such, the appropriate management and timing of treatment in these men is of paramount significance. The potential advantages of a synchronous approach include the minimization of perioperative complications associated with urolithiasis and the need for additional procedures. The current study demonstrates that simultaneous treatment of symptomatic distal urolithiasis with ureteroscopy at the time of radical prostatectomy is safe and efficacious. Meanwhile, we noted a high rate of residual stone fragments and re-instrumentation following shock wave lithotripsy and as such recommend it be performed in a staged fashion. Finally, in asymptomatic patients, or those with multiple or upper tract stones, one should consider a staged approach due to the increased risk of additional procedures and reduced stone-free rates.

### Terminology

Radical prostatectomy is the surgical removal of the prostate gland for the treatment of prostate cancer. Ureteroscopy is a minimally invasive endoscopic procedure to diagnose and treat upper urinary tract disorders. Shock Wave Lithotripsy is a technique for fragmenting a kidney stone with a shock wave that is produced outside the body. Steinstrasse is a complication of shock wave lithotripsy for urinary tract calculi in which stone fragments obstruct the renal unit. Percutaneous Nephrolithotomy is a technique for treating upper tract urinary stone disease by which percutaneous access into the renal unit is obtain. Stone Free refers to no residual stone fragments following stone treatment.

### Peer review

The present study by Amy E Krambeck is investigated the differences in perioperative and long-term outcomes of patients, which treated for urolithiasis at the time of radical prostatectomy (simultaneous) in the preoperative period (staged). The results showed that the simultaneous ureteroscopic treatment of symptomatic urolithiasis appeared to be safe and efficacious with radical prostatectomy. In general, the work was interesting, except several issues to be addressed to increase the quality of the present work.

## REFERENCES

- 1 Johnson CM, Wilson DM, O'Fallon WM, Malek RS, Kurland LT. Renal stone epidemiology: a 25-year study in Rochester, Minnesota. *Kidney Int* 1979; **16**: 624-631 [PMID: 548606 DOI: 10.1038/ki.1979.173]
- 2 Stamatelou KK, Francis ME, Jones CA, Nyberg LM, Curhan GC. Time trends in reported prevalence of kidney stones in the United States: 1976-1994. *Kidney Int* 2003; **63**: 1817-1823 [PMID: 12675858 DOI: 10.1046/j.1523-1755.2003.00917.x]
- 3 Pearle MS, Calhoun EA, Curhan GC. Urologic diseases in America project: urolithiasis. *J Urol* 2005; **173**: 848-857 [PMID: 15881111 DOI: 10.1093/ajph/95.5.848]



- 15711292 DOI: 10.1097/01.ju.0000152082.14384.d7]
- 4 **Eaton SH**, Cashy J, Pearl JA, Stein DM, Perry K, Nadler RB. Admission rates and costs associated with emergency presentation of urolithiasis: analysis of the Nationwide Emergency Department Sample 2006-2009. *J Endourol* 2013; **27**: 1535-1538 [PMID: 24251430 DOI: 10.1089/end.2013.0205]
- 5 **Ghani KR**, Roghmann F, Sammon JD, Trudeau V, Sukumar S, Rahbar H, Kumar R, Karakiewicz PI, Peabody JO, Menon M, Sun M, Trinh QD. Emergency department visits in the United States for upper urinary tract stones: trends in hospitalization and charges. *J Urol* 2014; **191**: 90-96 [PMID: 23933053 DOI: 10.1016/j.juro.2013.07.098]
- 6 **Scales CD**, Smith AC, Hanley JM, Saigal CS. Prevalence of kidney stones in the United States. *Eur Urol* 2012; **62**: 160-165 [PMID: 22498635 DOI: 10.1016/j.eururo.2012.03.052]
- 7 **Quinn M**, Babb P. Patterns and trends in prostate cancer incidence, survival, prevalence and mortality. Part II: individual countries. *BJU Int* 2002; **90**: 174-184 [PMID: 12081759 DOI: 10.1046/j.1464-410X.2002.02823.x]
- 8 **Hayat MJ**, Howlader N, Reichman ME, Edwards BK. Cancer statistics, trends, and multiple primary cancer analyses from the Surveillance, Epidemiology, and End Results (SEER) Program. *Oncologist* 2007; **12**: 20-37 [PMID: 17227898 DOI: 10.1634/theoncologist.12-1-20]
- 9 **Siegel R**, DeSantis C, Virgo K, Stein K, Mariotto A, Smith T, Cooper D, Gansler T, Lerro C, Fedewa S, Lin C, Leach C, Cannady RS, Cho H, Scoppa S, Hachey M, Kirch R, Jemal A, Ward E. Cancer treatment and survivorship statistics. *CA Cancer J Clin* 2012; **62**: 220-241 [PMID: 22700443 DOI: 10.3322/caac.21149]
- 10 **Gulati R**, Tsodikov A, Etzioni R, Hunter-Merrill RA, Gore JL, Mariotto AB, Cooperberg MR. Expected population impacts of discontinued prostate-specific antigen screening. *Cancer* 2014; Epub ahead of print [PMID: 25065910 DOI: 10.1002/cncr.28932]
- 11 **Etzioni R**, Gulati R, Falcon S, Penson DF. Impact of PSA screening on the incidence of advanced stage prostate cancer in the United States: a surveillance modeling approach. *Med Decis Making* 2008; **28**: 323-331 [PMID: 18319508 DOI: 10.1177/0272989X07312719]
- 12 **Lavery HJ**, Brajtford JS, Levinson AW, Nabizada-Pace F, Polard ME, Samadi DB. Unnecessary imaging for the staging of low-risk prostate cancer is common. *Urology* 2011; **77**: 274-278 [PMID: 20932557 DOI: 10.1016/j.urol.2010.07.491]
- 13 **Choi WW**, Williams SB, Gu X, Lipsitz SR, Nguyen PL, Hu JC. Overuse of imaging for staging low risk prostate cancer. *J Urol* 2011; **185**: 1645-1649 [PMID: 21419444 DOI: 10.1016/j.juro.2010.12.033]
- 14 **Porten SP**, Smith A, Odisho AY, Litwin MS, Saigal CS, Carroll PR, Cooperberg MR. Updated trends in imaging use in men diagnosed with prostate cancer. *Prostate Cancer Prostatic Dis* 2014; **17**: 246-251 [PMID: 24819235 DOI: 10.1038/pcan.2014.19]
- 15 **Thompson I**, Thrasher JB, Aus G, Burnett AL, Canby-Hagino ED, Cookson MS, D'Amico AV, Dmochowski RR, Eton DT, Forman JD, Goldenberg SL, Hernandez J, Higano CS, Kraus SR, Moul JW, Tangen CM. Guideline for the management of clinically localized prostate cancer: 2007 update. *J Urol* 2007; **177**: 2106-2131 [PMID: 17509297 DOI: 10.1016/j.juro.2007.03.003]
- 16 **Boyce CJ**, Pickhardt PJ, Lawrence EM, Kim DH, Bruce RJ. Prevalence of urolithiasis in asymptomatic adults: objective determination using low dose noncontrast computerized tomography. *J Urol* 2010; **183**: 1017-1021 [PMID: 20092842 DOI: 10.1016/j.juro.2009.11.047]
- 17 **Glowacki LS**, Beecroft ML, Cook RJ, Pahl D, Churchill DN. The natural history of asymptomatic urolithiasis. *J Urol* 1992; **147**: 319-321 [PMID: 1732583]
- 18 **Burgher A**, Beman M, Holtzman JL, Monga M. Progression of nephrolithiasis: long-term outcomes with observation of asymptomatic calculi. *J Endourol* 2004; **18**: 534-539 [PMID: 15333216 DOI: 10.1089/end.2004.18.534]
- 19 **Kang HW**, Lee SK, Kim WT, Kim YJ, Yun SJ, Lee SC, Kim WJ. Natural history of asymptomatic renal stones and prediction of stone related events. *J Urol* 2013; **189**: 1740-1746 [PMID: 23201376 DOI: 10.1016/j.juro.2012.11.113]
- 20 **Ficarra V**, Novara G, Rosen RC, Artibani W, Carroll PR, Costello A, Menon M, Montorsi F, Patel VR, Stolzenburg JU, Van der Poel H, Wilson TG, Zattoni F, Motttrie A. Systematic review and meta-analysis of studies reporting urinary continence recovery after robot-assisted radical prostatectomy. *Eur Urol* 2012; **62**: 405-417 [PMID: 22749852 DOI: 10.1016/j.eururo.2012.05.045]
- 21 **Potosky AL**, Davis WW, Hoffman RM, Stanford JL, Stephenson RA, Penson DF, Harlan LC. Five-year outcomes after prostatectomy or radiotherapy for prostate cancer: the prostate cancer outcomes study. *J Natl Cancer Inst* 2004; **96**: 1358-1367 [PMID: 15367568 DOI: 10.1093/jnci/djh259]
- 22 **Breyer BN**, Davis CB, Cowan JE, Kane CJ, Carroll PR. Incidence of bladder neck contracture after robot-assisted laparoscopic and open radical prostatectomy. *BJU Int* 2010; **106**: 1734-1738 [PMID: 20438567 DOI: 10.1111/j.1464-410X.2010.09333.x]
- 23 **Brede C**, Angermeier K, Wood H. Continence outcomes after treatment of recalcitrant postprostatectomy bladder neck contracture and review of the literature. *Urology* 2014; **83**: 648-652 [PMID: 24365088 DOI: 10.1016/j.urol.2013.10.042]
- 24 **Mehta RL**, Kellum JA, Shah SV, Molitoris BA, Ronco C, Warnock DG, Levin A. Acute Kidney Injury Network: report of an initiative to improve outcomes in acute kidney injury. *Crit Care* 2007; **11**: R31 [PMID: 17331245 DOI: 10.1186/cc5713]
- 25 **Hollingsworth JM**, Rogers MA, Kaufman SR, Bradford TJ, Saint S, Wei JT, Hollenbeck BK. Medical therapy to facilitate urinary stone passage: a meta-analysis. *Lancet* 2006; **368**: 1171-1179 [PMID: 17011944 DOI: 10.1016/S0140-6736(06)69474-9]
- 26 **Preminger GM**, Tiselius HG, Assimos DG, Alken P, Buck C, Gallucci M, Knoll T, Lingeman JE, Nakada SY, Pearle MS, Sarica K, Türk C, Wolf JS. 2007 guideline for the management of ureteral calculi. *J Urol* 2007; **178**: 2418-2434 [PMID: 17993340 DOI: 10.1016/j.juro.2007.09.107]
- 27 **Sarkissian C**, Noble M, Li J, Monga M. Patient decision making for asymptomatic renal calculi: balancing benefit and risk. *Urology* 2013; **81**: 236-240 [PMID: 23374767 DOI: 10.1016/j.urol.2012.10.032]
- 28 **Gibbons EP**, Ricchiuti D, Nelson J, Averch T. Feasibility and outcome of retrograde endoscopy in a post-prostatectomy population. *J Endourol* 2007; **21**: 189-191 [PMID: 17338620]
- 29 **Salem S**, Mehra A, Zartab H, Shahdadi N, Pourmand G. Complications and outcomes following extracorporeal shock wave lithotripsy: a prospective study of 3241 patients. *Urol Res* 2010; **38**: 135-142 [PMID: 20016885 DOI: 10.1007/s00240-009-0247-8]
- 30 **Rippel CA**, Nikkel L, Lin YK, Danawala Z, Olorunnisomo V, Youssef RF, Pearle MS, Lotan Y, Raman JD. Residual fragments following ureteroscopic lithotripsy: incidence and predictors on postoperative computerized tomography. *J Urol* 2012; **188**: 2246-2251 [PMID: 23083650 DOI: 10.1016/j.juro.2012.08.040]
- 31 **Resorlu B**, Unsal A, Gulec H, Oztuna D. A new scoring system for predicting stone-free rate after retrograde intrarenal surgery: the "resorlu-unsal stone score". *Urology* 2012; **80**: 512-518 [PMID: 22840867 DOI: 10.1016/j.urol.2012.02.072]
- 32 **Khalil MM**. Which is more important in predicting the outcome of extracorporeal shockwave lithotripsy of solitary renal stones: stone location or stone burden? *J Endourol* 2012; **26**: 535-539 [PMID: 22050487 DOI: 10.1089/end.2011.0314]
- 33 **Labadie K**, Okhunov Z, Akhavein A, Moreira D, Moreno-



- Palacios J, Del Junco M, Okeke Z, Bird V, Smith AD, Landman J. Evaluation and Comparison of Urolithiasis Scoring Systems in Percutaneous Kidney Stone Surgery. *J Urol* 2014; Epub ahead of print [PMID: 25088952 DOI: 10.1016/j.juro.2014.07.104]
- 34 **Molina WR**, Kim FJ, Spendlove J, Pompeo AS, Sillau S, Sehrt DE. The S.T.O.N.E. Score: a new assessment tool to predict stone free rates in ureteroscopy from pre-operative radiological features. *Int Braz J Urol* 2014; **40**: 23-29 [PMID: 24642147 DOI: 10.1590/S1677-5538.IBJU.2014.01.04]
- 35 **Kanao K**, Nakashima J, Nakagawa K, Asakura H, Miyajima A, Oya M, Ohigashi T, Murai M. Preoperative nomograms for predicting stone-free rate after extracorporeal shock wave lithotripsy. *J Urol* 2006; **176**: 1453-1456; discussion 1456-1457 [PMID: 16952658 DOI: 10.1016/j.juro.2006.06.089]
- 36 **Keeley FX**, Tilling K, Elves A, Menezes P, Wills M, Rao N, Feneley R. Preliminary results of a randomized controlled trial of prophylactic shock wave lithotripsy for small asymptomatic renal calyceal stones. *BJU Int* 2001; **87**: 1-8 [PMID: 11121982 DOI: 10.1046/j.1464-410x.2001.00781.x]

**P-Reviewer:** Cosmi E, Schiavina R, Wang SK **S-Editor:** Tian YL  
**L-Editor:** A **E-Editor:** Lu YJ



## Adjuvant chemotherapy and acute toxicity in hypofractionated radiotherapy for early breast cancer

Vassilis Kouloulis, Anna Zygogianni, Efrosini Kypraiou, John Georgakopoulos, Zoi Thrapsanioti, Ivelina Beli, Eftychia Mosa, Amanta Psyrris, Christos Antypas, Christina Armbilia, Maria Tolia, Kalliopi Platoni, Christos Papadimitriou, Nikolaos Arkadopoulos, Costas Gennatas, George Zografos, George Kyrgias, Maria Dilvoi, George Patatoucas, Nikolaos Kelekis, John Kouvaris

Vassilis Kouloulis, Efrosini Kypraiou, John Georgakopoulos, Zoi Thrapsanioti, Ivelina Beli, Eftychia Mosa, Maria Tolia, Kalliopi Platoni, Maria Dilvoi, George Patatoucas, Nikolaos Kelekis, 2<sup>nd</sup> Department of Radiology, Radiotherapy Unit, Attikon University Hospital, 12462 Athens, Greece

Vassilis Kouloulis, Anna Zygogianni, Christos Antypas, Christina Armbilia, Costas Gennatas, John Kouvaris, 1<sup>st</sup> Department of Radiology, Radiotherapy Unit, Aretaieion University Hospital, 12462 Athens, Greece

Anna Zygogianni, George Kyrgias, Radiotherapy Department, Larisa University Hospital, 12462 Athens, Greece

Amanta Psyrris, Medical Oncology Unit, Attikon University Hospital, 12462 Athens, Greece

Christos Papadimitriou, Department of Clinical Therapeutics, Alexandra Hospital, 12462 Athens, Greece

Nikolaos Arkadopoulos, 4<sup>th</sup> Surgical Clinic, Attikon University Hospital, 12462 Athens, Greece

George Zografos, 1<sup>st</sup> Propaedeutic Surgical Clinic, Medical School, Ippokration Hospital, 12462 Athens, Greece

Author contributions: All authors contributed in this paper.

Correspondence to: Zoi Thrapsanioti, MSc, Medical Physicist, 2<sup>nd</sup> Department of Radiology, Radiotherapy Unit, Attikon University Hospital, Radiotherapy, Rimini 1, XAIDARI, 12462 Athens, Greece. [zoi313@gmail.com](mailto:zoi313@gmail.com)

Telephone: +30-694-4186670 Fax: +30-210-5326418

Received: April 29, 2014 Revised: September 23, 2014

Accepted: October 14, 2014

Published online: November 16, 2014

3-D conformal radiotherapy with a total physical dose of 50.54 Gy or 53.2 Gy in 19 or 20 fractions according to stage, over 23-24 d. The last three to four fractions were delivered as a sequential tumor boost. All patients were monitored for acute skin toxicity according to the European Organization for Research and Treatment of Cancer/Radiation Therapy Oncology Group criteria. The maximum monitored value was taken as the final grading score. Multivariate analysis was performed for the contribution of age, chemotherapy and 19 vs 20 fractions to the radiation acute skin toxicity.

**RESULTS:** The acute radiation induced skin toxicity was as following: grade I 27.6%, grade II 7.8% and grade III 2.6%. No significant correlation was noted between toxicity grading and chemotherapy ( $P = 0.154$ ,  $\chi^2$  test). The mean values of acute toxicity score in terms of chemotherapy or not, were 0.64 and 0.46 respectively ( $P = 0.109$ , Mann Whitney test). No significant correlation was also noted between acute skin toxicity and radiotherapy fractions ( $P = 0.47$ ,  $\chi^2$  test). According to univariate analysis, only chemotherapy contributed significantly to the development of acute skin toxicity but with a critical value of  $P = 0.05$ . However, in multivariate analysis, chemotherapy lost its statistical significance. None of the patients during the 2-years of follow-up presented any locoregional relapse.

**CONCLUSION:** There is no clear evidence that chemotherapy has an impact to acute skin toxicity after an HFRT schedule. A randomized trial is needed for definite conclusions.

© 2014 Baishideng Publishing Group Inc. All rights reserved.

**Key words:** Hypofractionated radiotherapy; Breast cancer

### Abstract

**AIM:** To evaluate the effect of chemotherapy to the acute toxicity of a hypofractionated radiotherapy (HFRT) schedule for breast cancer.

**METHODS:** We retrospectively analyzed 116 breast cancer patients with T1, 2N0Mx. The patients received

cer; Acute toxicity; Chemotherapy; Retrospective analysis

**Core tip:** The adjuvant radiotherapy for early breast cancer after lumpectomy is an established treatment. Hypofractionation is an attractive approach and the trend nowadays towards new techniques involving hypofractionation is huge, mainly due to the long waiting lists, patients' desire for fast treatment, better planning of radiotherapy with computed tomography-based target definition and better dose homogeneity assured by 3D conformal planning. The aim of the current study is to evaluate the potential effect of previous chemotherapy to the acute skin toxicity and the local control followed for 2 years in patients with breast cancer, treated with hypofractionated radiotherapy regimen.

Kouloulis V, Zygianni A, Kypraiou E, Georgakopoulos J, Thrapsanioti Z, Beli I, Mosa E, Psyrri A, Antypas C, Armibia C, Tolia M, Platoni K, Papadimitriou C, Arkadopoulos N, Gennatas C, Zografos G, Kyrgias G, Dilvoi M, Patatoucas G, Kelekis N, Kouvaris J. Adjuvant chemotherapy and acute toxicity in hypofractionated radiotherapy for early breast cancer. *World J Clin Cases* 2014; 2(11): 705-710 Available from: URL: <http://www.wjgnet.com/2307-8960/full/v2/i11/705.htm> DOI: <http://dx.doi.org/10.12998/wjcc.v2.i11.705>

## INTRODUCTION

The adjuvant radiotherapy (RT) for early breast cancer after lumpectomy is an established treatment. The most widely used schedule for whole breast irradiation is 50 Gy in 25 fractions (conventional), while randomized trials comparing conventional radiotherapy schedules to different hypofractionation, have shown equivalent results<sup>[1]</sup>. A lot of shorter (accelerated hypofractionated) RT schedules have been already used in clinical practice<sup>[2-6]</sup>. Hypofractionation is an attractive approach and the trend nowadays towards new techniques involving hypofractionation is huge, mainly due to the long waiting lists, patients' desire for fast treatment, better planning of radiotherapy with computed tomography (CT)-based target definition and better dose homogeneity assured by 3D conformal planning.

However it is quite difficult to compare the treatment outcome due to the variation of clinical parameters, such as patient selection, chemo/hormonotherapy, differences in breast size, radiation dosimetry and RT techniques<sup>[2-6]</sup>.

The aim of the current paper is to evaluate the potential effect of previous chemotherapy to the acute skin toxicity and to the local control followed for 2 years in breast cancer patients irradiated with this hypofractionated regimen.

## MATERIALS AND METHODS

One hundred sixteen patients were retrospectively selected, between May 2004 and December 2010. Patients

**Table 1 Patients' characteristics**

Age median (range)	58.5 (35-86)
T1	81
T2	35
Chemotherapy	
Yes	83
No	33

characteristics are shown in details in Table 1. All patients received radiotherapy with a total prescription dose of 50.54 Gy or 53.2 Gy by 2.66 Gy per fraction, in 19 or 20 fractions, over 23-24 d. The decision of giving either 19 or 20 fractions was made in terms of stage (T1, 2) or in case maxima in dose distributions more than 108%. The last three to four fractions were delivered as a sequential tumor boost. The patients were irradiated either at the Radiotherapy unit of the 1<sup>st</sup> Department of Radiology in ATTIKON University Hospital or at the Radiotherapy Unit of the 2<sup>nd</sup> Department of Radiology in Aretaicion University Hospital<sup>[7,8]</sup>. However, the follow-up was realized in several departments either in Athens or Larisa.

Inclusion criteria in this study were breast cancer patients with stage I - II invasive carcinoma after conservative surgery and axillary lymph node dissection. Any adjuvant chemotherapy had to be completed before the start of RT.

The exclusion criteria were: mastectomy, presence of Paget's disease, presence of autoimmune conditions, previous thoracic neoplasia (cancer, sarcoma, lymphoma), previous breast cancer operated with bad cosmesis, diagnosis of previous or concomitant malignancies or skin disease, breast size in craniocaudal dimension more than 20 cm (or alternatively less than 2500 mL) and presence of psychiatric or addictive disorders<sup>[7]</sup>.

All patients were monitored for acute skin toxicity according to the European Organization for Research and Treatment of Cancer/Radiation Therapy Oncology Group (EORTC/RTOG) criteria, during radiotherapy schedule once per week and one month thereafter<sup>[9]</sup>. The maximum monitored value was taken as the final grading score. The primary outcome measure was radiation induced acute skin toxicity. The secondary end point was the local recurrence free survival. Clinical and laboratory tests suggested recurrent disease were investigated, while the criterion for local disease recurrence was recurrent tumor within the treated irradiated field. Hormonal therapy, if prescribed according to indications, was administered after the completion of radiotherapy.

### Simulation and treatment planning

Patients underwent standard CT simulation in the supine position. The ipsilateral breast and tumor bed with surgical clips were contoured for the delineation of Clinical Target Volumes (CTV), while contralateral breast, left and right lung and heart were contoured as organs at risk (OARs)<sup>[10]</sup>. When surgical clips were not present, preoperative mammography and ultrasound data were used for

**Table 2** Incidence of acute skin toxicity in terms of previous chemotherapy or not

		EORTC/ROG radiation induced acute skin toxicity grade				Total
		0	1	2	3	
Chemotherapy	No	56/83 (67.5%)	18/83 (21.7%)	7/83 (8.4%)	2/83 (2.4%)	83
	Yes	16/33 (48.5%)	14/33 (42.4%)	2/33 (6.0%)	1/33 (3.0%)	33
Total		72/116 (62.1%)	32/116 (27.6%)	9/116 (7.8%)	3/116 (2.6%)	116

No significant correlation was noted (Pearson  $\chi^2 P = 0.15$ ). EORTC/ROG: Organization for Research and Treatment of Cancer/Radiation Therapy.

tumor bed definition. The planning target volume of the tumor bed (PTV<sub>t</sub>) was a 1-2 cm expansion around the clinical target volume (CTV). The ipsilateral breast volume was the planning target volume (PTV<sub>B</sub>), excluding the chest wall and 0.5 cm from the skin<sup>[10]</sup>.

### Radiobiological issue

We used linear-quadratic (LQ) model in order to assess the equivalent of hypofractionation schedules to the Normalised Total Dose (NTD) if delivered in conventional scheme of 2 Gy per fraction<sup>[11-16]</sup>:

$$NTD = D_{new} [(d_{new} + \alpha/\beta)/(2 + \alpha/\beta)]$$

where D<sub>new</sub> and d<sub>new</sub> are the total dose and dose per fraction for the hypofractionated schedule, respectively. Normalized Total Dose - NTD has been calculated and tabulated for both breast ( $\alpha/\beta = 4$  Gy) and acute reacting tissues ( $\alpha/\beta = 10$  Gy)<sup>[11-16]</sup>. When considering that  $\alpha/\beta = 4$ , the NTD was 56.10 Gy and 59.05 Gy for 19 and 20 fractions, respectively. When considering that  $\alpha/\beta = 10$ , the NTD was 53.3 Gy and 56.13 Gy for 19 and 20 fractions, respectively.

We used the QUANTEC trial for the dose constrains, as described below, concerning NTD values for an  $\alpha/\beta = 3$  (late reacting tissues)<sup>[17,18]</sup>: (1) Ipsilateral lung: < 15% of lung should receive less than 30% of prescribed dose; (2) Heart (left sided breast): Volume of heart getting 5% of dose (V5) should be less than 40%; (3) Heart (right sided breast): < 5% of heart should receive less than 5% of the prescribed dose; (4) Contralateral breast: should receive less than < 3% of prescribed dose to any point; and (5) Contralateral lung: < 15% of lung should receive less than 5% of prescribed dose.

### Systemic therapy

Patients with axillary nodal metastases received adjuvant systemic treatment. Concerning the premenopausal women, two schedules were used: 62 patients received 4 cycles of epirubicin and endoxan every 2 wk, 3 wk break and then 4 cycles taxotere every 3 wk; 54 patients received 6 cycles of cyclophosphamide, methotrexate, and 5-fluorouracil (CMF) chemotherapy *iv* every 21 d. Postmenopausal patients received also tamoxifen 20 mg daily for 5 years, after the completion of radiotherapy. All patients received irradiation in a time post chemotherapy ranged 25-45 d.

### Statistical analysis

The comparison of mean value of toxicity score between patients undergone adjuvant chemotherapy *vs* no che-

motherapy was done with the Mann Whitney non-parametric test. The correlation of the incidence of toxicity grading with either the administration of chemotherapy or the prescribed schedule of 19 *vs* 20 radiotherapy fractions was performed with the  $\chi^2$  test. The impact of age, chemotherapy and total dose to the radiation induced acute skin toxicity was performed with the logistic linear regression analysis in two steps: first all variables were entered in the equation as a univariate analysis; second only variables with a statistical significance were entered in a multivariate model. The significance level was set at 0.05. All the analysis was performed using the SPSS ver. 10 software (IL, United States).

## RESULTS

Thirty three patients underwent a radiotherapy schedule of 19 fractions while 83 underwent schedule of 20 fractions. Overall, acute radiation induced skin toxicity, according to European Organization for Research and Treatment of Cancer/Radiation Therapy Oncology Group criteria, was as following: grade I 27.6%, grade II 7.8% and grade III 2.6%. The acute radiation induced toxicity score in details is shown in Table 2. No treatment interruption was occurred since no skin toxicity more than grade 3 was noted. No significant correlation was noted between toxicity grading and chemotherapy ( $P = 0.154$ ,  $\chi^2$  test). The mean values of acute toxicity score in terms of chemotherapy or not, were 0.64 and 0.46 respectively (Figure 1). No significant difference was noted ( $P = 109$ , Mann Whitney test). No significant correlation was also noted between acute skin toxicity and radiotherapy fractions ( $P = 0.47$ ,  $\chi^2$  test). The logistic regression analysis performed in two steps is shown in Table 3. According to univariate analysis, only chemotherapy contributed significantly to the development of acute skin toxicity but with a critical value of 0.05. However, in multivariate analysis chemotherapy lost its statistical significance.

None of the patients during the 2-years of follow-up presented with any locoregional relapse. The acute radiation skin toxicity decreased rapidly after the completion of radiotherapy. Three months post irradiation, 107 out of 116 (92.2%) patients presented grade 0 of skin toxicity, while 9 out of 116 (7.7%) presented only grade I acute skin toxicity.

## DISCUSSION

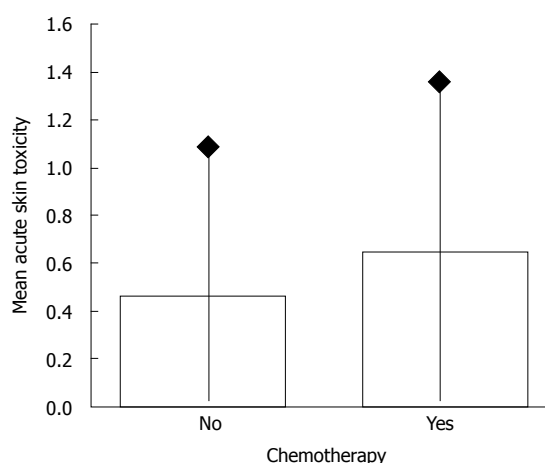
The linear quadratic (LQ) is a well established model that



**Table 3** Logistic regression analysis performed for analyzing the contribution of age, chemotherapy and radiotherapy fractions (19 vs 20) to the development of acute radiation induced skin toxicity

	Univariate analysis			Multivariate analysis		
	P	RR	95%CI	P	RR	95%CI
Age	0.31	-	-	0.41	-	-
Chemotherapy	0.05	2.35	1.01-5.52	0.057	-	-
19 vs 20 fractions	0.55	-	-	0.66	-	-

The univariate model chi-square with 3 degrees of freedom was 4.97 ( $P = 0.17$ ). None of the variables entered to the multivariate model. RR: Risk ratio.



**Figure 1** Mean acute skin toxicity score for patients undergone chemotherapy or not ( $P = 0.109$ , Mann Whitney test).

provides assessments of equivalent doses to both tumor and normal tissues<sup>[11-17]</sup>.

Biological factors related to proliferation (overall time and delayed after irradiation), and the effect of dose per fraction, are basic knowledge necessary for the planning of new irradiation schedules which are effective in practice<sup>[11-16]</sup>.

In our institution we have already reported on the efficacy of the certain hypofractionated schedule for breast cancer<sup>[7,8]</sup>. Moreover we have made a thorough dosimetric analysis for the dose deposited at the contralateral breast<sup>[19]</sup>. However, this is the first study according to our knowledge, evaluating the impact of adjuvant chemotherapy to the skin toxicity for a hypofractionated irradiation schedule for breast cancer. In univariate analysis the parameter of chemotherapy seems to have a significant impact to the radiation induced skin toxicity with a critical value of 0.05. However, in multivariate analysis chemotherapy lost its statistical significance. Thus eventually neither chemotherapy, nor the age and the total dose seemed to have any impact to acute skin toxicity.

Sanguineti *et al.*<sup>[20]</sup> investigated whether chemotherapy administered at earlier or concomitant with radiotherapy, has an impact either to the RT duration or to the hematological profile. The RT schedule was consisted of 50 Gy in five weeks. The investigators concluded that there is no correlation in terms of toxicity between chemotherapy dose-density and dose-intensity of RT. However,

the concomitant administration of chemotherapy and RT decreases the ability of prescribing a full irradiation scheme. The only toxicity observed was in white blood cells (WBC). The toxicity on late responding tissues with the combination of hypofractionation and chemotherapy was not investigated. In terms of multivariate analysis, no significant correlation was assessed between skin toxicity and weekly dose rate, while the analysis of potential factors associated with skin toxicity was not a subject of this study<sup>[20]</sup>.

According to current literature concerning clinical guidelines and randomized trials, Hypofractionated RT in breast cancer patients offers equivalent outcome to the standard conventional schedule, in terms of tumor control and normal tissue damage<sup>[21-24]</sup>. In clinical practice the most commonly used schedule of 2.66 Gy in 16 fractions is equivalent to 50 in 2.0 Gy fractions, when the  $\alpha/\beta$  value is equal to 3Gy. Any potential loss of therapeutic ratio (2.9 Gy loss of anti-tumor dose) would be compensating with the shorted treatment time due to reduced tumor repopulation and either adjuvant or neo-adjuvant chemotherapy<sup>[21]</sup>.

One of the trials, published in 2002 by Whelan *et al.*<sup>[23]</sup>, compared a schedule of 42.5 Gy in 16 fractions over 22 d (accelerated arm 266 Gy/fraction) with conventional breast irradiation consisted of 50 Gy in 25 fractions over 35 d (2 Gy/fraction). No boost was added. The randomized women had invasive breast cancer, free resection margins, uninvolved axillary lymph nodes. After 69 mo (more than 5 years) follow up the randomized trial determined that the accelerated arm was as effective as the conventional arm concerning the two outcomes- local control and cosmetic results. As it was obvious in the long term results, published in 2010, the local recurrence rate at 10 years was 7.5% in the conventional group as compared with 7.4% in the accelerated group<sup>[24]</sup>. The survival rate at 10 years was equivalent in both arms by means of 84.4% in the conventional group vs 84.6% in the accelerated group, while cosmetic outcomes were also similar concerning a rate of 4% or less grade 3 radiation induced toxicity<sup>[24]</sup>.

The 5 year results of two big randomized trials - the United Kingdom Standardisation of Breast Radiotherapy (START) Trial A and START Trial B have been also reported<sup>[25,26]</sup>. START Trial A<sup>[25]</sup> compared each of two schedules of hypofractionation 41.6 Gy or 39 Gy in 13 fractions of 3.2 Gy or 3.0 Gy over 5 wk with conven-

tional whole-breast irradiation and START Trial B<sup>[26]</sup> compared 40 Gy in 15 fractions of 2.67 Gy over 3 wk with conventional irradiation 50 Gy in 25 fractions of 2 Gy. The interpretations of the results from the two trials were that the hypofractionation schedules offered similar rates of tumour control and normal tissue damage as the international standard fractionation schedule of 50 Gy in 25 fractions. The endpoints of both studies at term of tumor relapse, late normal tissue effects, and quality of life were at least as favorable as the standard schedule. Boost irradiation was according to protocol guidelines in both START trials, while adjuvant chemotherapy was used more widely than in Whelan *et al* trial<sup>[23]</sup>, while up to nowadays follow-up, no significant increase in toxicity has been reported. Zygogianni *et al*<sup>[8]</sup> in a previous study, at the end of RT reported 24.1% of grade I and 9.3% of grade II acute skin toxicity, while 66.7% of the patients showed no radiation induced skin morbidity. In this study the results are equivalent with 27.6% and 7.8% of grade I and II skin toxicity, respectively.

Dorn *et al*<sup>[27]</sup> studied the skin toxicity in large breasts by an hypofractionated schedule of 42.56 Gy in 2.66 Gy per fraction. Of the 80 treated patients with large breasts, the maximum acute skin toxicity was mild erythema or hyperpigmentation in 70.0%, dry desquamation in 21.25% and focal moist desquamation in 8.75%. Maximum acute toxicity occurred after the completion of radiation in 31.9% of patients. Breast volume was the only patient-related factor significantly associated with moist desquamation on multivariable analysis ( $P = 0.01$ ). Patients with breast volume > 2500 mL showed focal moist desquamation in 27.2% of cases *vs* 6.34% in patients with breast volume < 2500 mL ( $P = 0.03$ ). In our case, according to eligibility criteria, all patients had a breast volume less than 2500 mL.

In another study referring to 44 patients with primary stage breast cancer after adjuvant chemotherapy and hypofractionated RT, Zygogianni *et al*<sup>[28]</sup> reported a significantly acute skin toxicity when the intermediate time between chemotherapy and RT was less than 20 d ( $P < 0.05$ ). All patients in this study received irradiation 25 d at the minimum after chemotherapy.

Although, all the above mentioned trials studied skin toxicity according to the hypofractionated schedule, none of them explored the impact of chemotherapy on acute skin morbidity. According to our results, the hypofractionated radiotherapy for breast cancer is safe in terms of mild toxicity, independently with the sequential chemotherapy, if administered. Our acute toxicity is in accordance with the reported values in all previous published studies. Obviously, the maximum grade of skin toxicity was noted during the whole breast irradiation and not during the boost radiotherapy. On the other hand, it seems that chemotherapy might not be a major factor affecting the radiation induced morbidity. However, due to the retrospective nature of our study, it is difficult to extract safe conclusions, while a randomized prospective study is needed to answer the question: has chemotherapy a definite impact to radiation induced morbidity

if a hypofractionated schedule is used? Consequently, the question is still open.

## ACKNOWLEDGMENTS

We want to thank the following technologists: Nazos J, Aivalioti A, Tsioumas J, Bakouras G, Darakis G, Dempegioti A, Vergetidou M, Proiskas C and Christogiannis N.

## COMMENTS

### Background

The Hypofractionated irradiation for breast cancer patients has been involved in the routine clinical practice for several years. However, the impact of previous chemotherapy to radiation induced toxicity has not been studied thoroughly.

### Research frontiers

No clear evidence that chemotherapy has an impact to radiation induced skin toxicity has been noted.

### Innovations and breakthroughs

This is a retrospective study documenting the absence of clear impact of previous chemotherapy to Hypofractionated radiotherapy for breast cancer.

### Applications

Clinicians that decide to use hypofractionated irradiation for breast cancer may prescribe this schedule independently to previous chemotherapy.

### Terminology

Hypofractionated: irradiation schedule with more than 200 cGy per fraction.

### Peer review

In this study, the authors evaluated the impact of chemotherapy to the acute toxicity of a hypofractionated irradiation schedule for breast cancer. Delivering postoperative radiotherapy in a shorter time could effectively be much more convenient for patients and several clinical randomized trials have shown that hypofractionated adjuvant radiotherapy in breast cancer offers similar rates of tumour control and normal tissue damage as the standard schedule.

## REFERENCES

- Owen JR, Ashton A, Bliss JM, Homewood J, Harper C, Hanson J, Haviland J, Bentzen SM, Yarnold JR. Effect of radiotherapy fraction size on tumour control in patients with early-stage breast cancer after local tumour excision: long-term results of a randomised trial. *Lancet Oncol* 2006; **7**: 467-471 [PMID: 16750496 DOI: 10.1016/S1470-2045(06)70699-4]
- Holloway CL, Panet-Raymond V, Olivetto I. Hypofractionation should be the new 'standard' for radiation therapy after breast conserving surgery. *Breast* 2010; **19**: 163-167 [PMID: 20511064 DOI: 10.1016/j.breast.2010.03.002]
- Khan A, Haffty BG. Hypofractionation in adjuvant breast radiotherapy. *Breast* 2010; **19**: 168-171 [PMID: 20511065 DOI: 10.1016/j.breast.2010.03.004]
- Shelley W, Brundage M, Hayter C, Paszat L, Zhou S, Mackillop W. A shorter fractionation schedule for post-lumpectomy breast cancer patients. *Int J Radiat Oncol Biol Phys* 2000; **47**: 1219-1228 [PMID: 10889375 DOI: 10.1016/S0360-3016(00)00567-8]
- Yarnold J, Bloomfield D, LeVay J. Prospective randomized trial testing 5.7 Gy and 6.0 Gy fractions of whole breast radiotherapy in women with early breast cancer (FAST) trial. *Clin Oncol* 2004; **16**: S30
- Martin S, Mannino M, Rostom A, Tait D, Donovan E, Eagle S, Haviland J, Yarnold J. Acute toxicity and 2-year adverse effects of 30 Gy in five fractions over 15 days to whole breast after local excision of early breast cancer. *Clin Oncol (R Coll Radiol)* 2008; **20**: 502-505 [PMID: 18556186 DOI: 10.1016/j.clon.2008.04.020]
- Zygogianni AG, Kouvaris JR, Kouloulis V, Armpilia C, Antypas C, Vlachos L. Hypofractionated accelerated irradiation for stage I-II breast carcinoma: a phase II study.

- Breast J* 2010; **16**: 337-338 [PMID: 20565472 DOI: 10.1111/j.1524-4741.2010.00913.x]
- 8 **Zygianni AG**, Kouloulis V, Armpilia C, Balafouta M, Antypas C, Kouvaris JR. The potential role of hypofractionated accelerated radiotherapy to cosmesis for stage I-II breast carcinoma: a prospective study. *J BUON* 2011; **16**: 58-63 [PMID: 21674851]
- 9 **Cox JD**, Stetz J, Pajak TF. Toxicity criteria of the Radiation Therapy Oncology Group (RTOG) and the European Organization for Research and Treatment of Cancer (EORTC) *Int J Radiat Oncol Biol Phys* 1995; **31**: 1341-1346 [PMID: 7713792 DOI: 10.1016/0360-3016(95)00060-C]
- 10 International Commission on Radiation Units and Measurements (ICRU) - Report 62. Prescribing, recording, and reporting photon beam therapy (Supplement to ICRU Report 50). Bethesda, MD: ICRU, 1999. Available from: URL: <http://www.icru.org/home/reports/prescribing-recording-and-reporting-photon-beam-therapy-report-62>
- 11 **Fowler JF**. The linear-quadratic formula and progress in fractionated radiotherapy. *Br J Radiol* 1989; **62**: 679-694 [PMID: 2670032]
- 12 **Fowler JF**, Tomé WA, Fenwick JD, Mehta MP. A challenge to traditional radiation oncology. *Int J Radiat Oncol Biol Phys* 2004; **60**: 1241-1256 [PMID: 15519797 DOI: 10.1016/j.ijrobp.2004.07.691]
- 13 **Barendsen GW**. Dose fractionation, dose rate and iso-effect relationships for normal tissue responses. *Int J Radiat Oncol Biol Phys* 1982; **8**: 1981-1997 [PMID: 6759484 DOI: 10.1016/0360-3016(82)90459-X]
- 14 **Dale RG**. The application of the linear-quadratic dose-effect equation to fractionated and protracted radiotherapy. *Br J Radiol* 1985; **58**: 515-528 [PMID: 4063711]
- 15 **Thames HD**. An 'incomplete-repair' model for survival after fractionated and continuous irradiations. *Int J Radiat Biol Relat Stud Phys Chem Med* 1985; **47**: 319-339 [PMID: 3872284]
- 16 **Thames HD**, Bentzen SM, Turesson I, Overgaard M, Van den Bogaert W. Time-dose factors in radiotherapy: a review of the human data. *Radiother Oncol* 1990; **19**: 219-235 [PMID: 2281152]
- 17 **Bentzen SM**, Constine LS, Deasy JO, Eisbruch A, Jackson A, Marks LB, Ten Haken RK, Yorke ED. Quantitative Analyses of Normal Tissue Effects in the Clinic (QUANTEC): an introduction to the scientific issues. *Int J Radiat Oncol Biol Phys* 2010; **76**: S3-S9 [PMID: 20171515 DOI: 10.1016/j.ijrobp.2009.09.040]
- 18 **Marks LB**, Yorke ED, Jackson A, Ten Haken RK, Constine LS, Eisbruch A, Bentzen SM, Nam J, Deasy JO. Use of normal tissue complication probability models in the clinic. *Int J Radiat Oncol Biol Phys* 2010; **76**: S10-S19 [PMID: 20171502 DOI: 10.1016/j.ijrobp.2009.07.1754]
- 19 **Tolia M**, Platoni K, Foteineas A, Kalogeridi MA, Zygianni A, Tsoukalas N, Caimi M, Margari N, Dilvoi M, Pantelakos P, Kouvaris J, Kouloulis V. Assessment of contralateral mammary gland dose in the treatment of breast cancer using accelerated hypofractionated radiotherapy. *World J Radiol* 2011; **3**: 233-240 [PMID: 22013502 DOI: 10.4329/wjr.v3.i9.233]
- 20 **Sanguineti G**, Del Mastro L, Guenzi M, Ricci P, Cavallari M, Canavese G, Stevani I, Venturini M. Impact of chemotherapy dose-density on radiotherapy dose-intensity after breast conserving surgery. *Ann Oncol* 2001; **12**: 373-378 [PMID: 11332151]
- 21 **Yarnold J**, Ashton A, Bliss J, Homewood J, Harper C, Hanson J, Haviland J, Bentzen S, Owen R. Fractionation sensitivity and dose response of late adverse effects in the breast after radiotherapy for early breast cancer: long-term results of a randomised trial. *Radiother Oncol* 2005; **75**: 9-17 [PMID: 15878095 DOI: 10.1016/j.radonc.2005.01.005]
- 22 **Whelan TJ**, Kim DH, Sussman J. Clinical experience using hypofractionated radiation schedules in breast cancer. *Semin Radiat Oncol* 2008; **18**: 257-264 [PMID: 18725113 DOI: 10.1016/j.semradonc.2008.04.008]
- 23 **Whelan T**, MacKenzie R, Julian J, Levine M, Shelley W, Grimard L, Lada B, Lukka H, Perera F, Fyles A, Laukkanen E, Gulavita S, Benk V, Szechtman B. Randomized trial of breast irradiation schedules after lumpectomy for women with lymph node-negative breast cancer. *J Natl Cancer Inst* 2002; **94**: 1143-1150 [PMID: 12165639 DOI: 10.1093/jnci/94.15.1143]
- 24 **Whelan TJ**, Pignol JP, Levine MN, Julian JA, MacKenzie R, Parpia S, Shelley W, Grimard L, Bowen J, Lukka H, Perera F, Fyles A, Schneider K, Gulavita S, Freeman C. Long-term results of hypofractionated radiation therapy for breast cancer. *N Engl J Med* 2010; **362**: 513-520 [PMID: 20147717 DOI: 10.1056/NEJMoa0906260]
- 25 **Bentzen SM**, Agrawal RK, Aird EG, Barrett JM, Barrett-Lee PJ, Bliss JM, Brown J, Dewar JA, Dobbs HJ, Haviland JS, Hoskin PJ, Hopwood P, Lawton PA, Magee BJ, Mills J, Morgan DA, Owen JR, Simmons S, Sumo G, Sydenham MA, Venables K, Yarnold JR. The UK Standardisation of Breast Radiotherapy (START) Trial A of radiotherapy hypofractionation for treatment of early breast cancer: a randomised trial. *Lancet Oncol* 2008; **9**: 331-341 [PMID: 18356109 DOI: 10.1016/S1470-2045(08)70077-9]
- 26 **Bentzen SM**, Agrawal RK, Aird EG, Barrett JM, Barrett-Lee PJ, Bentzen SM, Bliss JM, Brown J, Dewar JA, Dobbs HJ, Haviland JS, Hoskin PJ, Hopwood P, Lawton PA, Magee BJ, Mills J, Morgan DA, Owen JR, Simmons S, Sumo G, Sydenham MA, Venables K, Yarnold JR. The UK Standardisation of Breast Radiotherapy (START) Trial B of radiotherapy hypofractionation for treatment of early breast cancer: a randomised trial. *Lancet* 2008; **371**: 1098-1107 [PMID: 18355913 DOI: 10.1016/S0140-6736(08)60348-7]
- 27 **Dorn PL**, Corbin KS, Al-Hallaq H, Hasan Y, Chmura SJ. Feasibility and acute toxicity of hypofractionated radiation in large-breasted patients. *Int J Radiat Oncol Biol Phys* 2012; **83**: 79-83 [PMID: 22035661 DOI: 10.1016/j.ijrobp.2011.05.074]
- 28 **Zygianni A**, Kouloulis V, Antypas C, Armpilia C, Kyrgias G, Kouvaris J. The impact of intermediate time between chemotherapy and hypofractionated radiotherapy to the radiation induced skin toxicity for breast adjuvant treatment. *Breast J* 2014; **20**: 74-78 [PMID: 24237451 DOI: 10.1111/tbj.12206]

**P- Reviewer:** Arcangeli S, Gehmert S **S- Editor:** Ji FF  
**L- Editor:** A **E- Editor:** Lu YJ



## Concomitant achondroplasia and Chiari II malformation: A double-hit at the cervicomedullary junction

Al-Wala Awad, Kyrieckos A Aleck, Ratan D Bhardwaj

Al-Wala Awad, College of Medicine-Phoenix, University of Arizona, Phoenix, AZ 85004, United States

Kyrieckos A Aleck, Division of Genetics and Metabolism, Phoenix Children's Hospital, Phoenix, AZ 85016, United States

Ratan D Bhardwaj, Division of Neurological Surgery, Barrow Neurological Institute at Phoenix Children's Hospital, Phoenix, AZ 85016, United States

Author contributions: All the authors solely contributed to this paper.

Correspondence to: Al-Wala Awad, BS, College of Medicine-Phoenix, University of Arizona, 550 E. Van Buren St, Phoenix, AZ 85004, United States. [wala.awad@gmail.com](mailto:wala.awad@gmail.com)

Telephone: +1-480-2921480

Received: April 26, 2014 Revised: July 28, 2014

Accepted: September 4, 2014

Published online: November 16, 2014

drocephalus. Chiari decompression may not always be necessary, however, diligent and acute follow-up is important to monitor for signs of impending hydrocephalus. If cerebral spinal fluid diversion is required, remember that shunt failure is common in the pediatric age group and also requires close follow-up.

Awad AW, Aleck KA, Bhardwaj RD. Concomitant achondroplasia and Chiari II malformation: A double-hit at the cervicomedullary junction. *World J Clin Cases* 2014; 2(11): 711-716 Available from: URL: <http://www.wjgnet.com/2307-8960/full/v2/i11/711.htm> DOI: <http://dx.doi.org/10.12998/wjcc.v2.i11.711>

### Abstract

We report the first case of a neonate with concurrent Chiari II malformation and achondroplasia. Although rare, both these conditions contribute to several deleterious anatomical changes at the cervicomedullary junction and thus predispose to acute hydrocephalus. Although our patient was initially asymptomatic, hydrocephalus ensued several weeks after birth and required cerebral spinal fluid diversion. We discuss the potential links between the two conditions, the pathophysiology, and the important clinical implications for the management of the increased risk of hydrocephalus.

© 2014 Baishideng Publishing Group Inc. All rights reserved.

**Key words:** Achondroplasia; Chiari II malformation; Hydrocephalus; Shunt failure; Cervicomedullary junction; Cerebral spinal fluid diversion

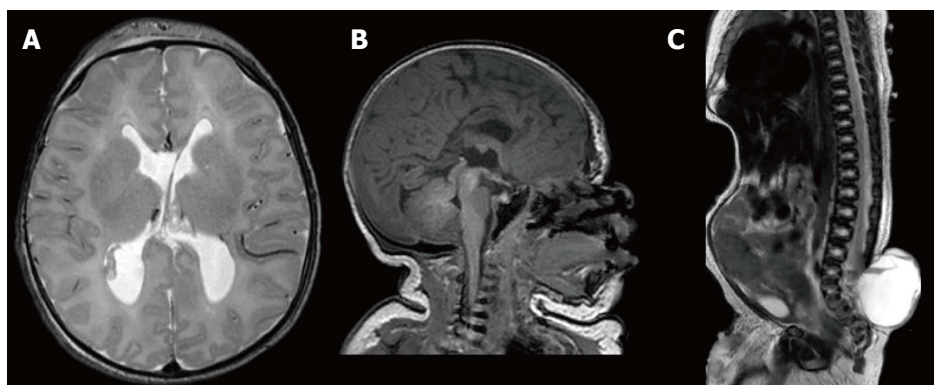
**Core tip:** Achondroplasia and Chiari II malformations can induce similar anatomical changes at the cervicomedullary junction which increase the risk of acute hy-

### INTRODUCTION

Achondroplasia is the most common cause of dwarfism, occurring at a frequency of 1 and 26000 live births<sup>[1]</sup>. Mutations of the *FGFR3* gene, which encodes a tyrosine kinase receptor that is differentially expressed during various stages of development, are responsible for the characteristic short-stature and macrocephaly<sup>[2,3]</sup>. The condition follows an autosomal dominant inheritance pattern with complete penetrance, however 80%-90% of cases are due to sporadic mutation<sup>[1,4]</sup>. The *FGFR3* gene has been mapped to chromosome 4p16.3, and is part of a larger family of fibroblast growth factor receptor genes which play important roles in skeletal development<sup>[2,3]</sup>.

The Chiari II malformation (CM II) is a well characterized congenital malformation of the central nervous system. Although the exact mechanism is still disputed, the condition is defined by a small posterior fossa and caudal displacement of the brainstem and cerebellum through the foramen magnum<sup>[5]</sup>. In addition, all cases of CM II are associated with a myelomeningocele<sup>[5]</sup> which can be further complicated by hydrocephalus, syringomyelia, heterotopias, and agenesis of the corpus callosum are only some of the commonly reported sequelae<sup>[5-7]</sup>.





**Figure 1** Pre-operative magnetic resonance imaging of the patient to evaluate and screen for anatomical abnormalities. A: Axial T2 MRI of the head at birth demonstrating no signs of hydrocephalus; B: Sagittal T1 MRI of the head and neck at birth with evidence of a tight cervicomedullary junction, a small posterior fossa, and hypoplastic corpus callosum and cerebellar vermis; C: Sagittal T2 MRI of the spine at birth demonstrating a large 7 cm × 7 cm sacral myelomeningocele with evidence of tethering. MRI: Magnetic resonance imaging.

In our literature review we found two case reports of patients with both achondroplasia and Chiari I malformations<sup>[8,9]</sup>, however to our knowledge there are no published case reports of concomitant achondroplasia and CM II. Here we report the first such case in a neonate, and discuss the potential links between the two conditions, the pathophysiology, and the management of the increased risk of hydrocephalous.

## CASE REPORT

### History of present illness

A 1 d old male born after 39-3/7 wk of gestation to a 39-year-old gravid 1, para 0 women presented after delivery for surgical correction of a sacral mass. During pregnancy, an elevated AFP was noted and ultrasound findings demonstrated enlarged ventricles, large for gestational age status, and a sacral myelomeningocele. The infant was delivered *via* cesarean section with no complications; at birth, 1 and 5 min APGARs were 8 and 9 respectively. The child's cranium appeared relatively macrocephalic and measured in the 75<sup>th</sup> percentile with a short cranial base and mild frontal bossing. A 7 cm × 7 cm sacral myelomeningocele was noted and no cerebral spinal fluid (CSF) leak was evident. The extremities showed shortening of the femurs and humeri with relatively long fibulae and a trident confirmation of the hands. The patient had a short stature with an upper-lower segment ratio of 1.9 (normal 1.6 to 1.7), these exam findings initiated a genetic and skeletal survey for achondroplasia. The remainder of the physical and neurological exam were normal.

### Imaging studies

An axial T-2 magnetic resonance image (MRI) of the head showed no signs of hydrocephalus (Figure 1A). There was no evidence of a tonsillar herniation, however, a tight cervicomedullary junction was noted on the sagittal T-1 MRI of the head (Figure 1B), and the lateral and third ventricles were slightly enlarged. The corpus

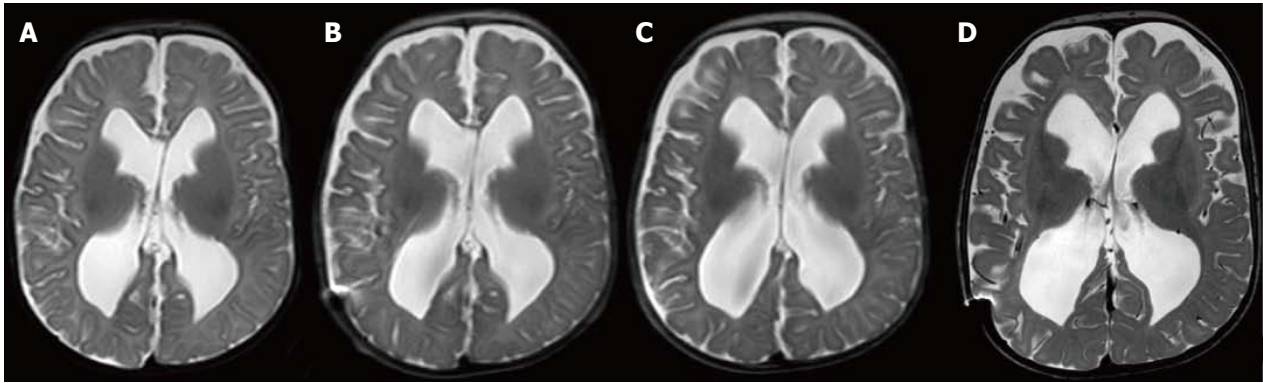
callosum and cerebral vermis were noted to be hypoplastic and a small posterior fossa with frontal bossing were evident. A sagittal T-2 MRI of the spine (Figure 1C) demonstrated a well circumscribed hyperintense sacral mass protruding dorsally, with a loss of posterior spinal elements distal to L3. There was some evidence of cauda equina involvement and tethering of the cord.

### Operative course

The patient's radiographic and physical exam findings were consistent with a CM II. The patient was taken to the operating room on the same day of presentation to undergo repair of the myelomeningocele. A typical elliptical incision was made adjacent to the defect with midline extension caudal and rostral to the dome. The myelomeningocele was delicately dissected away from the dome skin and the surrounding fascial and dural layers. The termination of the placode was detethered from the dome skin, and the dorsal and ventral nerve roots were mobilized laterally. The lateral edges of the placode were approximated and sutured to form a closed cavity. The dura was then closed and no signs of CSF leak were evident after valsalva. Finally, the fascial layers and skin were re-approximated; some trimming of the excess skin was necessary. The operation was completed without complications and the patient's recovery was monitored in the neonatal intensive care unit.

### Post-operative course

A genetic evaluation for achondroplasia was positive for a mutation of the *FGFR3* gene on chromosome 4 showed a glycine to arginine substitution mutation at the 380<sup>th</sup> amino acid residue confirming a diagnosis of achondroplasia. It was not immediately clear if the CM II was related to the patients' concomitant achondroplasia. The patient was monitored post-operatively for 6 d. During that period the fontanelles remained soft and there were no signs of increased intracranial pressure (ICP). The patients' family was counseled on the symptoms of hydrocephalous and the patient was discharged home with



**Figure 2** T-2 weighted magnetic resonance imaging demonstrating shunt failure and progression of hydrocephalous over the course of 4 mo of treatment. A: Pre-shunting axial T-2 weighted MRI ordered after patient had increased head circumference and suture splaying demonstrating ventriculomegaly; B, C: Subtle increase in ventricular size at 2 wk (B) and 6 wk post-shunting (C); D: At 4 mo post-operative shunting with significant increase in ventriculomegaly and extra axial fluid spacing. MRI: Magnetic resonance imaging.

instructions to follow up in 2 wk.

### Progressive hydrocephalus

In the subsequent weeks, the patient had bi-weekly clinical and ultrasound exams which were normal. At 8 wk however, the patients head circumference was in the 97<sup>th</sup> percentile, the anterior fontanelle was full and pulsatile with signs of sagittal suture splaying, but the patient had no signs of respiratory distress. A T2 MRI (Figure 2A) showed evidence of ventriculomegaly with increased extra-axial spacing. Given the physical exam and radiographic findings we placed a ventriculoperitoneal (VP) shunt in the right lateral ventricle without incident.

After discharge the patient was monitored with serial MRIs (Figure 2B, C) which demonstrated subtle but continued ventriculomegaly. During this time the patient was asymptomatic and had normal exam findings.

### Shunt failure

Four months following shunt placement, the patient was found to have an enlarged head circumference that measured above the 95<sup>th</sup> percentile. The patient was reported to be less active than usual and the anterior fontanelle was full but soft. A T-2 MRI demonstrated the VP shunt catheter was no longer in the lateral ventricle; subsequently, the lateral and third ventricle had enlarged (Figure 2D) and there was evidence of encroachment of the cerebellar tonsils into the spinal canal. The patient required shut revision, which was completed without complications. At the time of the shunt revision, somatosensory evoked potentials were within normal limits and Chiari decompression was not carried out.

The patient is now 10 mo old and we continue to monitor his head circumference which has stabilized since shunt revision.

## DISCUSSION

### Genetic associations

Embryogenesis is a complex physiologic phenomenon

that is subject to a wide range of exogenous and endogenous forces that can have significant impact on developmental outcomes. At times, these changes are so gross they can be detected in-utero as in the case of a CM II, in which a myelomeningocele is evident in pre-partum ultrasound. Conversely, in conditions like achondroplasia, developmental changes become apparent shortly after birth. Although the exact mechanism by which these effects take place are not entirely delineated, understanding them is crucial to the development of preventive and therapeutic strategies.

As in our case, almost all cases of achondroplasia are due to a substitution mutation of the 380<sup>th</sup> amino acid Gly for an Arg residue, which resides in the trans-membrane domain of the receptor protein<sup>[2,3]</sup>. Gene expression studies in mice have shown elevated levels of mRNA encoding the FGFR3 protein in the rudimentary cartilage of all premature bone during organogenesis<sup>[10]</sup>. The effects of achondroplasia on the developing calvarium can produce signs and symptoms similar to those seen in CM II. In addition to the characteristic macrocephalic changes commonly seen, changes in the shape and size of the foramen magnum, cervical stenosis, cervicomedullary compression and upward herniation of the brainstem are common<sup>[8,11]</sup>.

Although there are several proposed hypotheses describing the pathogenesis of CM II, the exact mechanism remains elusive. Animal models have demonstrated that open neural tube defects (NTD) are causative in the case of CM II. NTD that were surgically created in mouse, rat, and sheep models replicate the hindbrain herniation through the foramen magnum that is stereotypical of CM II<sup>[12-14]</sup>. This finding has two important implications; firstly it lends considerable evidence to the widely accepted “unified theory” of CM II<sup>[6]</sup>. This theory alleges the loss of CSF through the open caudal NTD causes a subsequent drop in ICP. This loss of pressure at a critical point during fetal development results in poor cranial vault expansion culminating into a small posterior fossa. The unexpectedly narrowed posterior fossa leads

to the caudal displacement of the brainstem and cerebellum through the foramen magnum<sup>[6]</sup>. Secondly, the causal relationship of NTD and CM II has valuable corollaries for prevention. Folic acid supplementation has been found to reduce the incidence of NTD by 70%<sup>[15]</sup>. The incidence of CM II has not been well studied to determine whether the expected decrease exists following the increased use of folic acid supplementation.

Due to the association of folic acid and NTD, there has been considerable research evaluating the role of enzymes and transport proteins involved in its metabolism, namely MTRR, MTHFD1 and FOLR1-2<sup>[16]</sup>. However, these genes appear to have little relation to those of achondroplasia and make up only a small portion of candidate genes. The genetic causes of NTD appear to be far more complex and varied than originally anticipated; over 200 gene mutations in mice are known to cause NTD<sup>[17]</sup>. Similarly in humans, NTD defects arise in the setting of multiple syndromes (Pallister-Hall, Walker-Warburg and Fanconi anemia among others) and chromosomal abnormalities including Trisomies 13 and 18<sup>[18-20]</sup>. Of the wide range of potential gene candidates we focused on reports of mutations involving chromosome 4, where the *FGFR3* gene is located. In a small series of 5 autopsy reports of fetuses with Wolf-Hirschhorn syndrome due to partial mutations (deletion/substitution) of the short arm of chromosome 4, three patients had sacral dimples, while 2 had partial or complete agenesis of the corpus callosum, all patients exhibited growth retardation, and had consistent craniofacial abnormalities including frontal bossing<sup>[21]</sup>. Furthermore, reports of achondroplasia and other spinal dysraphisms exist including tethered cords and lipomas indicating the range of phenotypes that ensue from genetic mutations in this region<sup>[22,23]</sup>.

Familial studies of Chiari malformations are limited mainly to Chiari I malformations, as such, the genetics of CM II are not as well characterized. Animal models have suggested possible gene candidates. The Splootch mouse model for example can produce NTD and the hindbrain herniation characteristic of the CM II<sup>[6]</sup>. The genetic mutation responsible for this phenotype in mouse models was mapped to the human *Pax-3* gene on chromosome 1, encodes transcription factors which play various roles in embryogenesis<sup>[24,25]</sup>. Further studies in humans however, demonstrated that mutations in *Pax-3* generate distinct features not commonly seen in CM II, namely deafness and abnormal pigmentation which were later characterized into a distinct Waardenburg Syndrome<sup>[25,26]</sup>.

### Clinical management

Given our patients' concurrent conditions, the concern for hydrocephalus was high. Brainstem herniation as a result of hydrocephalus in both CM II and achondroplasia can be acutely progressive, and greatly increases the risk of apneic spells and acute respiratory failure<sup>[1,11,27]</sup>. At the time of presentation we believed the degree of cervicomedullary constriction present did not warrant surgical Chiari decompression, as a result the patient underwent

myelomeningocele repair with acute follow-up. Although our patient ultimately required CSF diversion, there were no overt signs of respiratory distress, spasticity, or dysphagia which would warrant a surgical Chiari decompression. In a large series of 148 patients with CM II, only 14% of patients required surgical decompression<sup>[7]</sup>. Treating the obstructive hydrocephalus by shunting is a more common method that is associated with fewer risks. In a series of 71 cases of CM II, 64 (90%) patients had hydrocephalus, 89% of which required VP shunting<sup>[28]</sup>. As in our case, shunt placement necessitates close follow-up and thorough patient education. Unfortunately, our patient experienced shunt failure due to tip migration, a risk associated with this treatment. A large series of 1015 patients who underwent VP shunting reported a failure rate of 46.3%, in the pediatric group however, failure rates were reported to be 79.2%, the majority of which occurred in the first 6 mo<sup>[29]</sup>. Importantly, in patients with spinal dysraphisms, as in our case, failure rates were 84.8%<sup>[29]</sup>. At last follow up (10 mo) the patient was symptom free with signs of improved CSF outflow. Due to the compounding effects of both underlying conditions on the potential hydrocephalus we continue to monitor the patient with routine monthly follow-up.

In conclusion, both achondroplasia and the CM II are relatively common as independent conditions; however, they very rarely occur concomitantly. Importantly, the CM II is a consequence of NTDs which appear to have multifocal genetic and environmental etiologies. Although the genes involved in achondroplasia appear to be distinct from those of the CM II, due to the complexity of embryologic development, there may be key interactions between the downstream pathways which may account for some of the similar anatomic changes seen at the cervicomedullary junction. As such the management of the potential hydrocephalus that may arise within patients with this unique predisposition requires acute and diligent follow up and patient education.

## COMMENTS

### Case characteristics

A newborn boy presented with macrocephaly, short limbs, and a sacral mass.

### Clinical diagnosis

Concurrent achondroplasia and Chiari II malformation.

### Differential diagnosis

Myelomeningocele has a unique gross presentation however a sacrococcygeal teratoma should be considered and the two conditions can be easily differentiated using magnetic resonance imaging. The differential of a newborn with macrocephaly is quite large and includes congenital infections, obstructive hydrocephalus, metabolic conditions (Canavan's disease, Alexander's disease, etc.), and osteogenesis imperfecta are only a few to consider.

### Laboratory diagnosis

A genetic test indicated a missense mutation of the *FGFR3* gene on chromosome 4 confirming a diagnosis of Achondroplasia.

### Imaging diagnosis

MRI of the head and spinal column confirmed a diagnosis of Chiari II malformation.

### Treatment

Surgical myelomeningocele repair and ventriculoperitoneal shunting due to



hydrocephalous is a standard treatment.

### Related reports

This is the first reported case of both a Chiari II malformation and achondroplasia in the same patient. Cases of concurrent Chiari I malformation and achondroplasia have been reported in references 7 and 8.

### Term explanation

Spina bifida is an incomplete closure of the spine during embryogenesis. A myelomeningocele is a form of spina bifida that includes a herniation of the spinal meninges through the spinal defect.

### Experiences and lessons

Shunt failure is more common in pediatric patients with spinal dysraphisms, generally occurring within the first 6 mo.

### Peer review

The manuscript of Awad *et al* describes a neonate case with concomitant achondroplasia and Chiari II malformation. According to a literature review performed by the authors this is the first case report of a patient with this combination. This is definitely an interesting case that is thoroughly documented. Everything seems to be very well described.

## REFERENCES

- 1 Oberklaid F, Danks DM, Jensen F, Stace L, Rosshandler S. Achondroplasia and hypochondroplasia. Comments on frequency, mutation rate, and radiological features in skull and spine. *J Med Genet* 1979; **16**: 140-146 [PMID: 458831 DOI: 10.1136/jmg.16.2.140]
- 2 Shiang R, Thompson LM, Zhu YZ, Church DM, Fielder TJ, Bocian M, Winokur ST, Wasmuth JJ. Mutations in the transmembrane domain of FGFR3 cause the most common genetic form of dwarfism, achondroplasia. *Cell* 1994; **78**: 335-342 [PMID: 7913883 DOI: 10.1016/0092-8674(94)90302-6]
- 3 Vajo Z, Francomano CA, Wilkin DJ. The molecular and genetic basis of fibroblast growth factor receptor 3 disorders: the achondroplasia family of skeletal dysplasias, Muenke craniosynostosis, and Crouzon syndrome with acanthosis nigricans. *Endocr Rev* 2000; **21**: 23-39 [PMID: 10696568 DOI: 10.1210/edrv.21.1.0387]
- 4 Murdoch JL, Walker BA, Hall JG, Abbey H, Smith KK, McKusick VA. Achondroplasia--a genetic and statistical survey. *Ann Hum Genet* 1970; **33**: 227-244 [PMID: 5504223 DOI: 10.1111/j.1469-1809.1970.tb01648.x]
- 5 Stevenson KL. Chiari Type II malformation: past, present, and future. *Neurosurg Focus* 2004; **16**: E5 [PMID: 15209488 DOI: 10.3171/foc.2004.16.2.6]
- 6 McLone DG, Knepper PA. The cause of Chiari II malformation: a unified theory. *Pediatr Neurosci* 1989; **15**: 1-12 [PMID: 2699756 DOI: 10.1159/000120432]
- 7 Messing-Jünger M, Röhrig A. Primary and secondary management of the Chiari II malformation in children with myelomeningocele. *Childs Nerv Syst* 2013; **29**: 1553-1562 [PMID: 24013325 DOI: 10.1007/s00381-013-2134-4]
- 8 Thomas IT, Frias JL, Williams JL, Friedman WA. Magnetic resonance imaging in the assessment of medullary compression in achondroplasia. *Am J Dis Child* 1988; **142**: 989-992 [PMID: 3046333 DOI: 10.1001/archpedi.1988.02150090087031]
- 9 Nakai T, Asato R, Miki Y, Tanaka F, Matsumoto S, Konishi J. A case of achondroplasia with downward displacement of the brain stem. *Neuroradiology* 1995; **37**: 293-294 [PMID: 7666963 DOI: 10.1007/BF00588337]
- 10 Peters K, Ornitz D, Werner S, Williams L. Unique expression pattern of the FGF receptor 3 gene during mouse organogenesis. *Dev Biol* 1993; **155**: 423-430 [PMID: 8432397 DOI: 10.1006/dbio.1993.1040]
- 11 Ruiz-Garcia M, Tovar-Baudin A, Del Castillo-Ruiz V, Rodriguez HP, Collado MA, Mora TM, Rueda-Franco F, Gonzalez-Astiazaran A. Early detection of neurological manifestations in achondroplasia. *Childs Nerv Syst* 1997; **13**: 208-213 [PMID: 9202856 DOI: 10.1007/s003819770001]
- 12 Inagaki T, Schoenwolf GC, Walker ML. Experimental model: change in the posterior fossa with surgically induced spina bifida aperta in mouse. *Pediatr Neurosurg* 1997; **26**: 185-189 [PMID: 9436828 DOI: 10.1159/000121188]
- 13 Paek BW, Farmer DL, Wilkinson CC, Albanese CT, Peacock W, Harrison MR, Jennings RW. Hindbrain herniation develops in surgically created myelomeningocele but is absent after repair in fetal lambs. *Am J Obstet Gynecol* 2000; **183**: 1119-1123 [PMID: 11084552 DOI: 10.1067/mob.2000.108867]
- 14 Weber Guimarães Barreto M, Ferro MM, Guimarães Bitencourt D, Violin Pereira LA, Barini R, Sbragia L. Arnold-Chiari in a fetal rat model of dysraphism. *Fetal Diagn Ther* 2005; **20**: 437-441 [PMID: 16113568 DOI: 10.1159/000086827]
- 15 Prevention of neural tube defects: results of the Medical Research Council Vitamin Study. MRC Vitamin Study Research Group. *Lancet* 1991; **338**: 131-137 [PMID: 1677062 DOI: 10.1016/0140-6736(91)90133-A]
- 16 Greene ND, Stanier P, Copp AJ. Genetics of human neural tube defects. *Hum Mol Genet* 2009; **18**: R113-R129 [PMID: 19808787 DOI: 10.1093/hmg/ddp347]
- 17 Harris MJ, Juriloff DM. Mouse mutants with neural tube closure defects and their role in understanding human neural tube defects. *Birth Defects Res A Clin Mol Teratol* 2007; **79**: 187-210 [PMID: 17177317 DOI: 10.1002/bdra.20333]
- 18 Goetzinger KR, Stamilio DM, Dicke JM, Macones GA, Odibo AO. Evaluating the incidence and likelihood ratios for chromosomal abnormalities in fetuses with common central nervous system malformations. *Am J Obstet Gynecol* 2008; **199**: 285.e1-285.e6 [PMID: 18771985 DOI: 10.1016/j.ajog.2008.06.100]
- 19 Detrait ER, George TM, Etchevers HC, Gilbert JR, Veke-mans M, Speer MC. Human neural tube defects: developmental biology, epidemiology, and genetics. *Neurotoxicol Teratol* 2005; **27**: 515-524 [PMID: 15939212 DOI: 10.1016/j.ntt.2004.12.007]
- 20 Chen CP. Syndromes, disorders and maternal risk factors associated with neural tube defects (V). *Taiwan J Obstet Gynecol* 2008; **47**: 259-266 [PMID: 18935987 DOI: 10.1016/S1028-4559(08)60122-9]
- 21 Tachdjian G, Fondacci C, Tapia S, Hutten Y, Blot P, Nessmann C. The Wolf-Hirschhorn syndrome in fetuses. *Clin Genet* 1992; **42**: 281-287 [PMID: 1493641 DOI: 10.1111/j.1399-0004.1992.tb03257.x]
- 22 Phadke RV, Phadke SR, Chakravarti AL. Spinal dysraphism in achondroplasia. *Pediatr Neurosurg* 1990; **16**: 32-4; discussion 34 [PMID: 2133408 DOI: 10.1159/000120500]
- 23 Archibeck MJ, Smith JT, Carroll KL, Davitt JS, Stevens PM. Surgical release of tethered spinal cord: survivorship analysis and orthopedic outcome. *J Pediatr Orthop* 1997; **17**: 773-776 [PMID: 9591981 DOI: 10.1097/00004694-199711000-00014]
- 24 Barber TD, Barber MC, Cloutier TE, Friedman TB. PAX3 gene structure, alternative splicing and evolution. *Gene* 1999; **237**: 311-319 [PMID: 10521655 DOI: 10.1016/S0378-1119(99)00339-X]
- 25 Chalepakis G, Goulding M, Read A, Strachan T, Gruss P. Molecular basis of splotch and Waardenburg Pax-3 mutations. *Proc Natl Acad Sci USA* 1994; **91**: 3685-3689 [PMID: 7909605]
- 26 Tassabehji M, Newton VE, Leverton K, Turnbull K, Seemanova E, Kunze J, Sperling K, Strachan T, Read AP. PAX3 gene structure and mutations: close analogies between Waardenburg syndrome and the Splotch mouse. *Hum Mol Genet* 1994; **3**: 1069-1074 [PMID: 7981674 DOI: 10.1093/hmg/3.7.1069]
- 27 Aryanpur J, Hurko O, Francomano C, Wang H, Carson B. Craniocervical decompression for cervicomedullary compression in pediatric patients with achondroplasia. *J Neurosurg* 1990; **73**: 375-382 [PMID: 2384775 DOI: 10.3171/jns.1990.73.3.0375]
- 28 Elgamal EA. Natural history of hydrocephalus in children with spinal open neural tube defect. *Surg Neurol Int* 2012; **3**: 112 [PMID: 23087828 DOI: 10.4103/2152-7806.101801]



- 29 **Reddy GK**, Bollam P, Caldito G. Long-term outcomes of ventriculoperitoneal shunt surgery in patients with hy-

drocephalus. *World Neurosurg* 2014; **81**: 404-410 [PMID: 23380280 DOI: 10.1016/j.wneu.2013.01.096]

**P- Reviewer:** Zaucke F **S- Editor:** Song XX **L- Editor:** A  
**E- Editor:** Lu YJ



## Bevacizumab maintenance in metastatic colorectal cancer: How long?

Alfonso De Stefano, Roberto Moretto, Chiara Alessandra Cella, Francesco Jacopo Romano, Lucia Raimondo, Giovanni Fiore, Francesca Di Pietro, Stefano Pepe, Sabino De Placido, Chiara Carlomagno

Alfonso De Stefano, Roberto Moretto, Chiara Alessandra Cella, Francesco Jacopo Romano, Lucia Raimondo, Giovanni Fiore, Francesca Di Pietro, Sabino De Placido, Chiara Carlomagno, Department of Clinical Medicine and Surgery, School of Medicine, University of Naples "Federico II", 80131 Napoli, Italy

Stefano Pepe, Department of Medicine, School of Medicine and Pharmacology, University of Salerno, 84081 Baronissi (SA), Italy

**Author contributions:** De Stefano A drafted the manuscript, collected the figures, and approved the final version of the manuscript; Moretto R, Cella CA, Romano FJ, Raimondo L, Fiore G, Di Pietro F, Pepe S, De Placido S revised the manuscript and approved the final version of the manuscript; Carlomagno C worked on data interpretation, revised the manuscript, and approved the final version of the manuscript.

**Correspondence to:** Alfonso De Stefano, MD, PhD, Department of Clinical Medicine and Surgery, University of Naples "Federico II", Via Sergio Pansini, 5, 80131 Napoli, Italy. [alfonso.destefano@unina.it](mailto:alfonso.destefano@unina.it)

Telephone: +39-08-17464984 Fax: +39-08-12203147

Received: April 2, 2014 Revised: July 30, 2014

Accepted: September 6, 2014

Published online: November 16, 2014

remains free from relapse. Adverse effects were minimal and easily controlled.

© 2014 Baishideng Publishing Group Inc. All rights reserved.

**Key words:** Metastatic colorectal cancer; Bevacizumab; Maintenance

**Core tip:** A colorectal cancer patient with lung metastases received bevacizumab combined with chemotherapy for six months, and then bevacizumab monotherapy as maintenance treatment for more than three years. The patient achieved a complete response without evidence of side effects. He remains relapse free 58 mo after diagnosis.

De Stefano A, Moretto R, Cella CA, Romano FJ, Raimondo L, Fiore G, Di Pietro F, Pepe S, De Placido S, Carlomagno C. Bevacizumab maintenance in metastatic colorectal cancer: How long? *World J Clin Cases* 2014; 2(11): 717-723 Available from: URL: <http://www.wjgnet.com/2307-8960/full/v2/i11/717.htm> DOI: <http://dx.doi.org/10.12998/wjcc.v2.i11.717>

### Abstract

The management of patients with non-progressive metastatic colorectal cancer after six months of treatment has not yet been codified. The most relevant concerns are the effectiveness of maintenance *vs* discontinuation, and the tolerability of prolonged treatment. Here we report the case of a 72-year-old man affected by colorectal cancer with lung metastases who achieved a complete response after receiving capecitabine, oxaliplatin and bevacizumab for six months, and bevacizumab alone for six months. Bevacizumab was continued as maintenance regimen for more than three years. It was discontinued because of an arthroplasty. Fifty-eight months after beginning first-line treatment, the patient

### INTRODUCTION

The management of metastatic colorectal cancer (mCRC) has evolved over the past decade<sup>[1]</sup>. Patients receiving irinotecan<sup>[2]</sup>, oxaliplatin<sup>[3]</sup> and fluorouracil achieve the best outcome (median survival, approximately 21 mo), regardless of treatment sequence<sup>[4]</sup>. Adding biological drugs such as anti-vascular endothelial growth factor (VEGF) or anti-epidermal growth factor receptor (EGFR) monoclonal antibodies to chemotherapy improved survival further<sup>[5]</sup>. The anti-VEGF monoclonal antibody bevacizumab significantly prolonged survival when added to first-line<sup>[6]</sup> or second-line chemotherapy<sup>[7]</sup>. Recent clinical

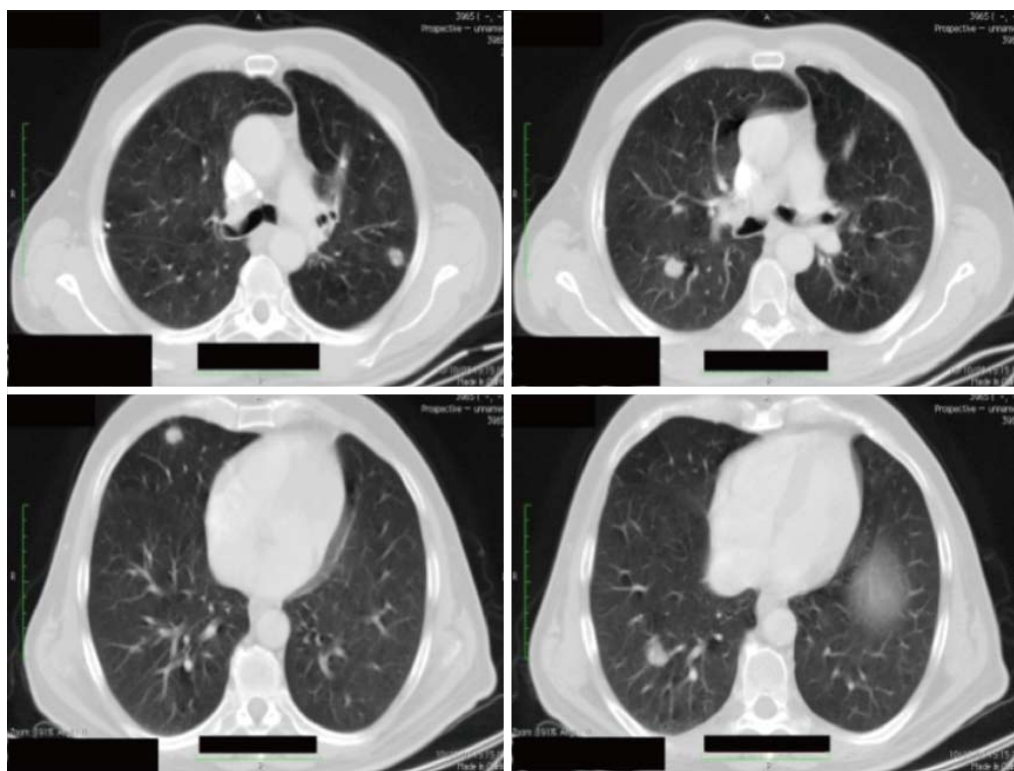


Figure 1 Thorax computed tomography-scan before starting chemotherapy (October 2008).

trials showed a clinical benefit in patients receiving bevacizumab even beyond progression<sup>[8,9]</sup>.

Although often used in clinical practice, maintenance therapy in non-progressive patients after four-six months of chemotherapy  $\pm$  biological drugs is not yet codified in terms of duration (indefinitely until disease progression?) and type of drugs (same chemotherapy regimen, simplified chemotherapy, targeted drug alone?). The most relevant concerns are the effectiveness of maintenance *vs* discontinuation, and the tolerability of such prolonged treatment.

Here, we report the case of a 72-year-old man affected by mCRC who obtained a complete response after treatment with capecitabine, oxaliplatin and bevacizumab for six months, followed by bevacizumab alone for a further six months. He then continued with bevacizumab as maintenance treatment for the following three years with no evidence of disease relapse or toxicity.

## CASE REPORT

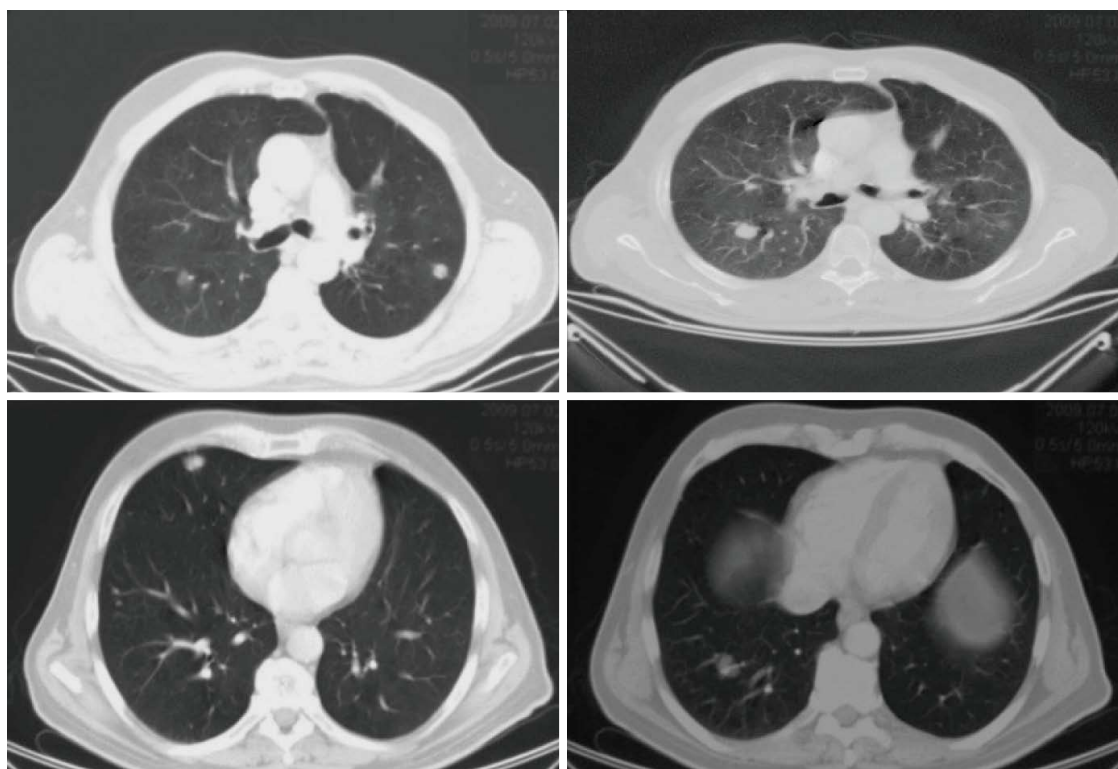
In October 2008, a 72-year-old man underwent left hemicolectomy for an obstructing mass located at the sigmoid-rectal junction. The pathological diagnosis was an undifferentiated (G3) adenocarcinoma, invading through the muscularis mucosae up to the peri-colic fat tissue (pT3); 12 nodes were isolated, all of which were metastatic (pN2). Radiological staging by contrast enhanced CT-scan showed several lung lesions (4 measurable) up to 20 mm in diameter (Figure 1). No liver metastases were detected. KRAS mutational status showed a mutation in

codon 12 of exon 2.

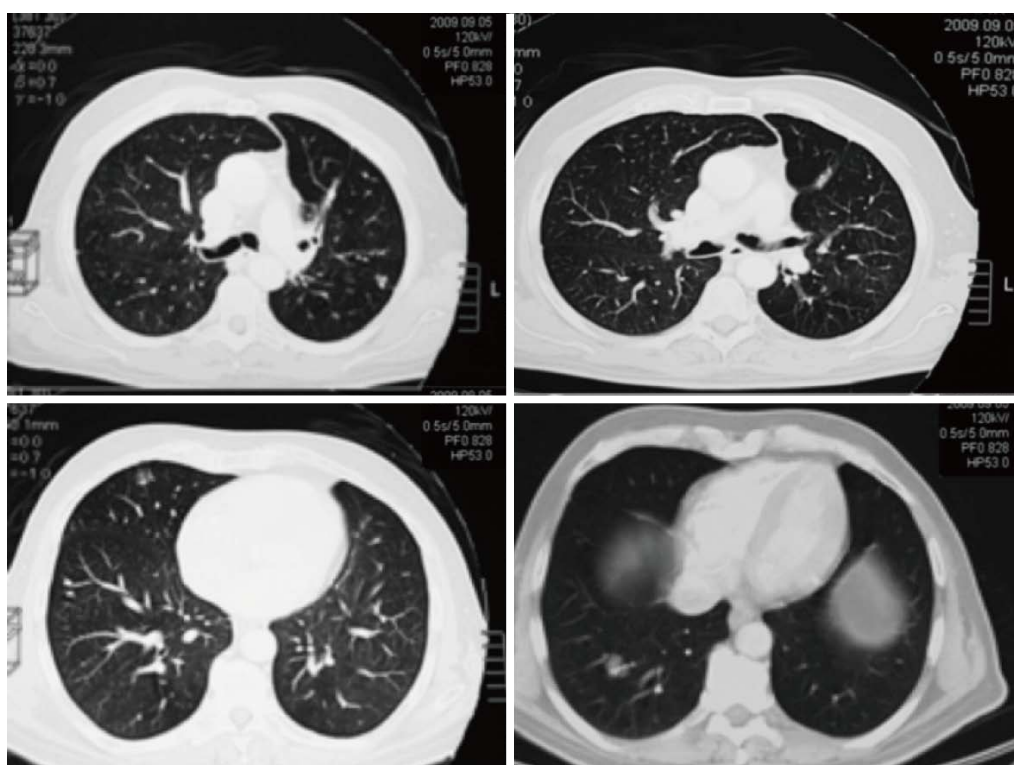
The patient was referred to the Division of Medical Oncology of the University of Naples “Federico II” in November 2008 to begin first-line chemotherapy. He was in good condition (ECOG performance status = 1), and was only taking an ACE-inhibitor for arterial hypertension. Serum tumor markers exceeded the upper normal level: CA19.9 was 54 U/L (normal values < 37 U/L), and CEA 23.3 ng/mL (normal values < 5 ng/mL).

He began chemotherapy with the XELOX + bevacizumab schedule (capecitabine 1000 mg/m<sup>2</sup> twice daily, days 1-14; oxaliplatin 130 mg/m<sup>2</sup>, and bevacizumab 7.5 mg/kg day 1, every 21 d). The work-up consisted of blood cell count and hematology before each cycle, and CT-scan every three months (or four cycles). Arterial blood pressure was measured before and after bevacizumab administration on day 1 and, thereafter, once daily with an electronic sphygmomanometer. The worse adverse events were: grade 1 peripheral neuropathy, grade 2 arterial hypertension, grade 1 hand-foot syndrome and grade 2 thrombocytopenia. Due to the worsening of arterial hypertension after the first treatment cycle, a diuretic and a calcium channel blocker were added to the anti-hypertensive treatment, which resulted in good blood pressure control. Bevacizumab administration remained unchanged, and blood pressure was well controlled.

Re-staging performed by whole-body CT scan after the fourth and the eighth (Figure 2) cycle of treatment showed a stable disease according to RECIST criteria. Thus, after completing eight courses (six months), capecitabine and oxaliplatin were discontinued and main-



**Figure 2** Thorax computed tomography-scan after 8 cycles of treatment. Note stabilization of the disease according to RECIST criteria (June 2009).

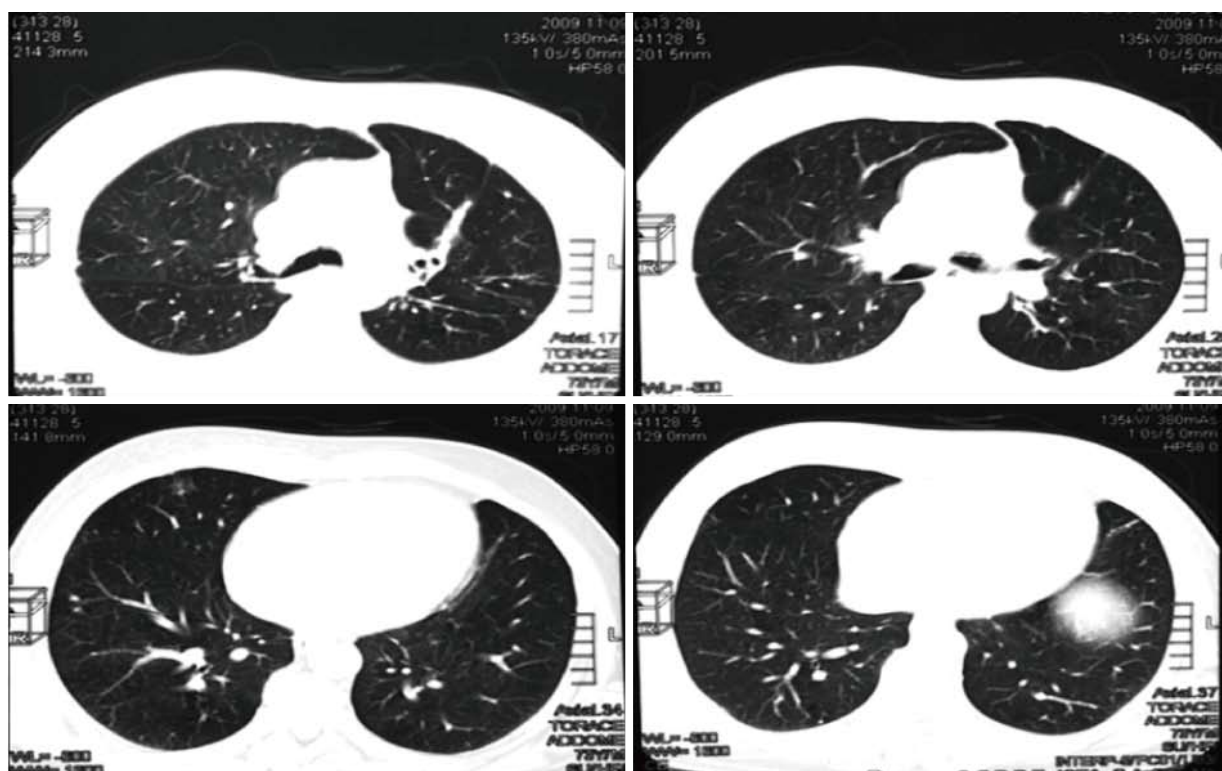


**Figure 3** Thorax computed tomography-scan after two months of maintenance treatment. Note a partial regression of disease according to RECIST criteria (September 2009).

tenance with bevacizumab alone (7.5 mg/kg every 21 d) was started. During the maintenance period, re-staging by whole-body CT scan was scheduled every three months.

In September 2009, the CT scan showed a significant reduction of the maximum diameter of the four measurable lung metastases (Figure 3), which were no longer





**Figure 4** Thorax computed tomography-scan after 4 mo of maintenance treatment. The disease has completely regressed according to RECIST criteria (November 2009).

detected after a further 3 mo of treatment (November 2009) (Figure 4).

The patient continued with bevacizumab for the following 44 mo, remaining free from metastases (Figure 5), and without reporting any adverse event. Serum marker levels mirrored the outcome of the lung metastases throughout treatment and follow-up (Figure 6). In January 2013, bevacizumab was discontinued to enable the patient to undergo hip arthroplasty because of right coxarthrosis. Currently (June 2014), 68 mo after diagnosis, the patient has a good ECOG performance status with no evidence of metastatic disease (Figure 7). He attends follow-up controls every three months.

## DISCUSSION

Here we report the case of a 72-year-old man with multiple lung metastases from a colon adenocarcinoma who achieved a complete radiological response after 12 mo of treatment: six with chemotherapy plus bevacizumab and six with bevacizumab alone. Bevacizumab alone was continued as maintenance therapy with bevacizumab alone for 44 mo, and patient experienced only a few side effects that were easily managed, and he enjoyed a good quality of life throughout the entire course of treatment.

Bevacizumab in combination with fluoropyrimidine-based chemotherapy is indicated for the treatment of patients with metastatic carcinoma of the colon or rectum, and it is recommended that treatment be continued until disease progression or unacceptable toxicity. However,

when used as monotherapy, bevacizumab is not known to induce tumor regression or disappearance<sup>[7]</sup>.

Saltz *et al.*<sup>[10]</sup> reported that the addition of bevacizumab to an oxaliplatin-based regimen in the first-line setting significantly prolonged median progression-free survival (9.4 mo *vs* 8.0 mo;  $P = 0.0023$ ), but did not significantly improve overall survival or the response rate<sup>[10]</sup>. However, many patients discontinued bevacizumab combined with chemotherapy for reasons other than progression or toxicity. A pre-defined analysis of on-treatment patients showed a much higher magnitude of benefit in progression-free survival for treatment until progression (HR = 0.63) than pre-progression discontinuation (HR = 0.83), which suggests that it is important to continue bevacizumab to maximize the benefit of its addition to chemotherapy<sup>[10]</sup>.

The role of maintenance therapy in mCRC is still controversial. The most recent ESMO consensus guidelines suggest that treatment discontinuation or maintenance are feasible options after 4–6 mo of full-dose first-line therapy<sup>[11]</sup>. Two randomized trials—MACRO<sup>[12]</sup>, and DREAM<sup>[13]</sup>—support the role of maintenance with bevacizumab alone<sup>[12]</sup> or with erlotinib<sup>[13]</sup>.

However, the magnitude of the benefit of maintenance therapy over the discontinuation approach has been addressed in 3 clinical trials, comparing maintenance with complete treatment discontinuation. The CAIRO 3 trial after a 4 mo' period of treatment (CAP-OX plus bevacizumab regimen) randomized not progressive patients to maintenance with capecitabine plus bevacizumab or

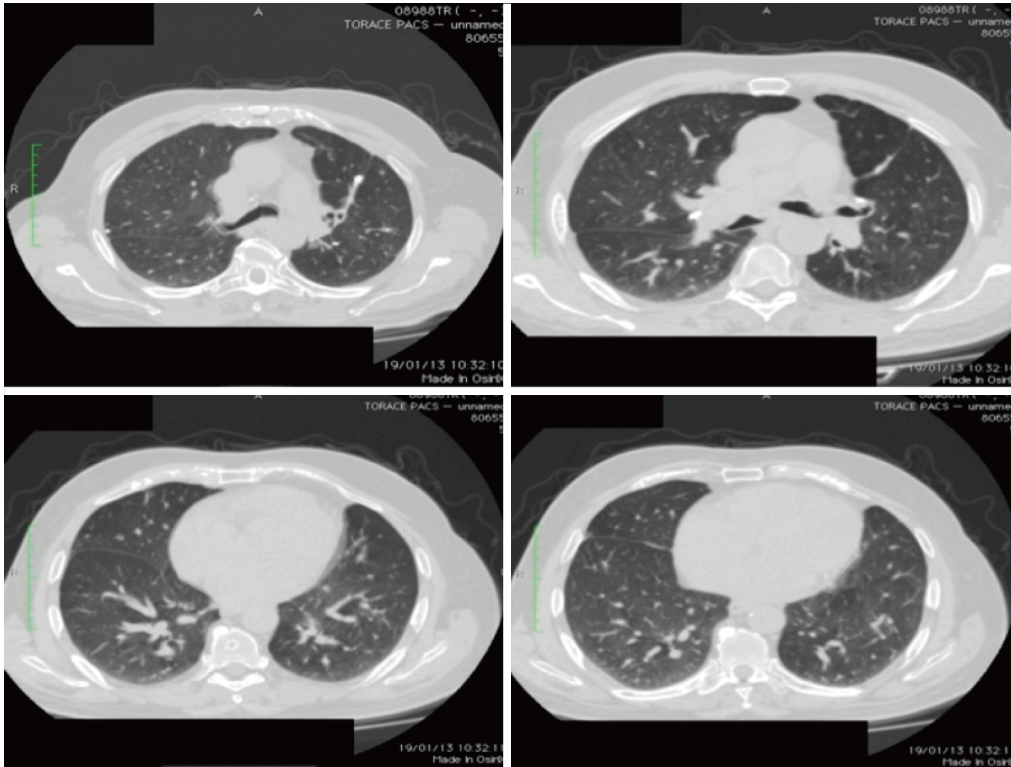


Figure 5 Thorax computed tomography-scan showing the complete response after discontinuing bevacizumab (January 2013).

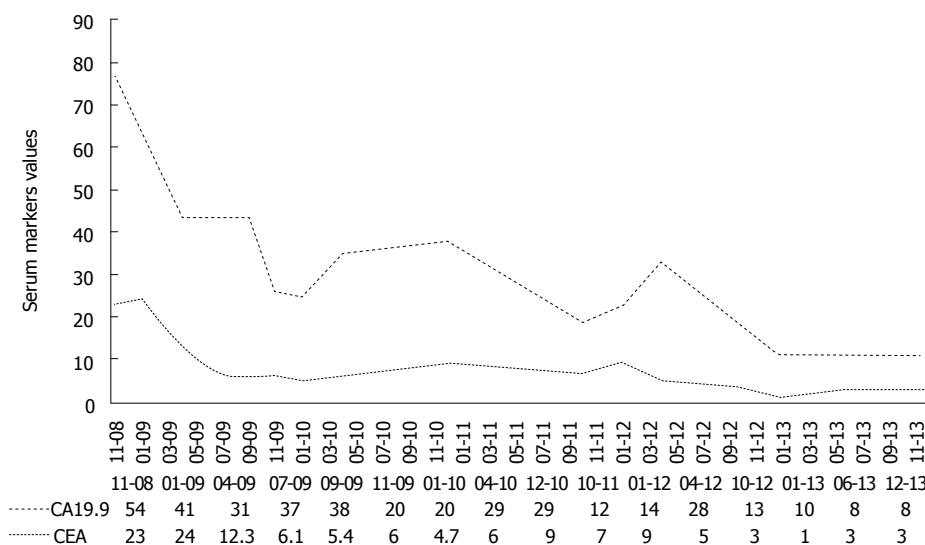


Figure 6 CEA (ng/mL) and CA19.9 (U/mL) serum levels throughout the treatment and follow-up period.

no further therapy. First and second progression-free survival times and time to second progression were improved in the maintenance arm.

The SAKK (41/06) trial was designed to demonstrate the non-inferiority of complete discontinuation of treatment as compared to maintenance with bevacizumab after 4-6 mo of chemotherapy plus bevacizumab. The non-inferiority was not statistically demonstrated, suggesting that maintenance with bevacizumab might be considered an appropriate option.

At ASCO 2014 the results of AIO0207 were pre-

sented. After 24 wk of induction therapy with fluoropyrimidines, oxaliplatin and bevacizumab, maintenance with fluoropyrimidines plus bevacizumab was compared with bevacizumab alone or with complete discontinuation. Maintenance treatment with fluoropyrimidines and bevacizumab prolongs progression free survival and time to failure of strategy with respect to complete discontinuation.

When we decided the maintenance strategy for our patient, there was no information available about the role of fluoropyrimidines in this condition, therefore only be-

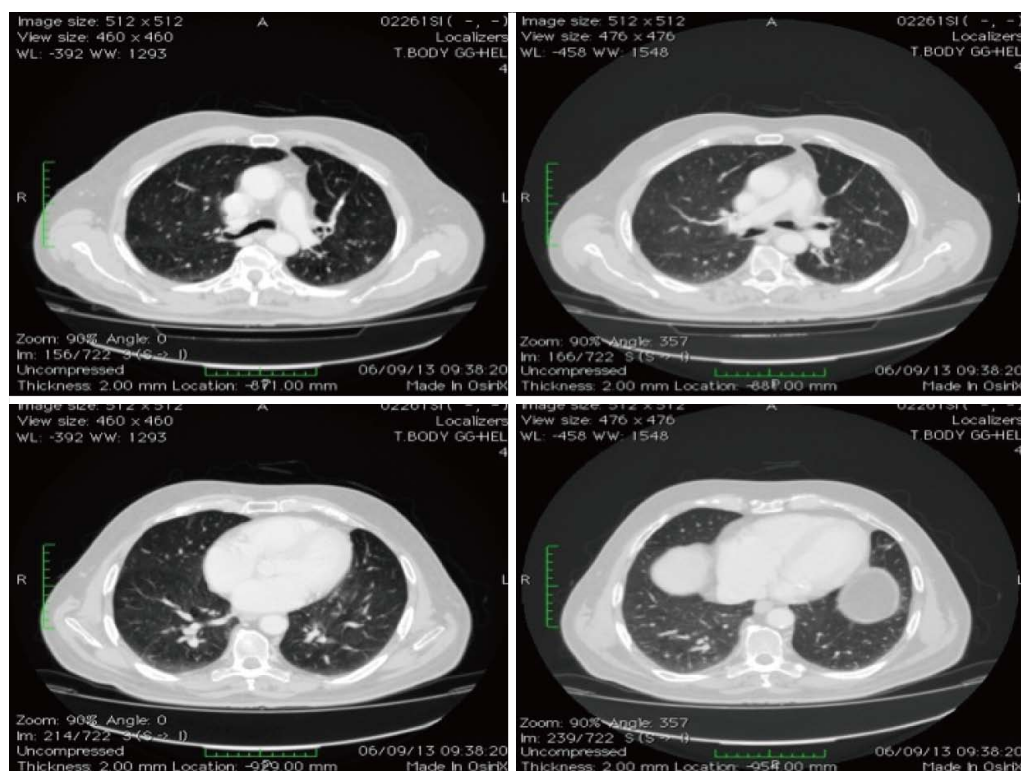


Figure 7 Thorax computed tomography-scan, showing the response at 60 mo since diagnosis (September 2013).

vacizumab was continued. Of note, our patient achieved a complete response after 12 mo of treatment and a very long progression-free survival, which supports continuing bevacizumab after stopping chemotherapy.

Another issue we were able to address is the tolerability of very long treatment with bevacizumab. Our patient was 72-year-old when metastatic disease was diagnosed, and was affected by arterial hypertension. Bleeding, hypertension and venous thromboembolic events are the most frequent side effects of bevacizumab recorded, also in a randomized clinical study<sup>[14]</sup>. Although hypertension was much more frequent in patients treated with bevacizumab than in controls, only arterial thromboembolic events were significantly higher in the bevacizumab-treated patients aged  $\geq 70$  years (6.7% *vs* 3.2% in the control group)<sup>[14]</sup>. It is noteworthy that patients enrolled in clinical trials are selected for their very good conditions, and with very limited comorbidities. However, similar results were in that BRITe observational study, where only a modest increase of arterial thromboembolic events was observed in elderly patients: unadjusted rate per 100 patients-years was 1.4 for patients  $< 75$  years old, 4.0 for patients aged 75–80, and 4.8 for older patients)<sup>[15]</sup>. Moreover, in the BRITe study, the median time to occurrence of bleeding and arterial thromboembolic events was about 5 mo and the risk of cardiovascular side effects did not increase with the duration of bevacizumab treatment<sup>[15]</sup>.

The AVEX trial<sup>[16]</sup> was the first phase III trial to prospectively evaluate the use of bevacizumab in elderly patients ( $\geq 70$ -year-old) affected by mCRC. Bleeding (25.4%), arterial hypertension (19.4%), venous throm-

boembolic (11.9%) and arterial thromboembolic events (4.5%) were the most common all-grade adverse events in the cohort of 140 patients receiving bevacizumab<sup>[16]</sup>.

In our patient, arterial hypertension worsened after the first administration of bevacizumab, and was successfully managed with anti-hypertensive therapy, without discontinuing bevacizumab.

In conclusion, our report, although based on a single patient, supports the feasibility and, possibly, the benefit of continuing bevacizumab as maintenance treatment for a very long period. Moreover, the case reported here suggests that this regimen can be administered even in elderly patients provided they are fit. Indeed, they can have the same benefits as adult subjects, possibly without a significant increase in toxicity.

## ACKNOWLEDGMENTS

We thank Jean Ann Gilder (Scientific Communication srl, Naples, Italy) for editing the text.

## COMMENTS

### Case characteristics

The case reports the clinical case of a colorectal cancer patient presenting with lung metastases.

### Clinical diagnosis

He underwent first line chemotherapy with capecitabine, oxaliplatin and bevacizumab as induction treatment for six months, after which he continued receiving bevacizumab monotherapy for more than three years.

### Treatment

He achieved a complete response and is currently free from relapse.



## Experiences and lessons

The long progression-free survival time and the absence of side effects indicates that bevacizumab-based maintenance treatment is beneficial in mCRC patients. However, although some studies reported a benefit of maintenance therapy in PFS or TTF, the definite role of maintenance on survival and the best maintenance regimen might be further investigated in properly designed clinical trials.

## Peer review

It is a very interested topic for physicians of multiple specialties such as Internal Medicine, Oncology, Surgery, Family Medicine. The manuscript is very well written.

## REFERENCES

- 1 Siegel R, Naishadham D, Jemal A. Cancer statistics, 2013. *CA Cancer J Clin* 2013; **63**: 11-30 [PMID: 23335087 DOI: 10.3322/caac.21166]
- 2 Saltz LB, Cox JV, Blanke C, Rosen LS, Fehrenbacher L, Moore MJ, Maroun JA, Ackland SP, Locker PK, Pirotta N, Elfring GL, Miller LL. Irinotecan plus fluorouracil and leucovorin for metastatic colorectal cancer. Irinotecan Study Group. *N Engl J Med* 2000; **343**: 905-914 [PMID: 11006366 DOI: 10.1056/NEJM200009283431302]
- 3 de Gramont A, Figer A, Seymour M, Homerin M, Hmissi A, Cassidy J, Boni C, Cortes-Funes H, Cervantes A, Freyer G, Papamichael D, Le Bail N, Louvet C, Hendler D, de Braud F, Wilson C, Morvan F, Bonetti A. Leucovorin and fluorouracil with or without oxaliplatin as first-line treatment in advanced colorectal cancer. *J Clin Oncol* 2000; **18**: 2938-2947 [PMID: 10944126]
- 4 Grothey A, Sargent D, Goldberg RM, Schmoll HJ. Survival of patients with advanced colorectal cancer improves with the availability of fluorouracil-leucovorin, irinotecan, and oxaliplatin in the course of treatment. *J Clin Oncol* 2004; **22**: 1209-1214 [PMID: 15051767 DOI: 10.1200/JCO.2004.11.037]
- 5 Gallagher DJ, Kemeny N. Metastatic colorectal cancer: from improved survival to potential cure. *Oncology* 2010; **78**: 237-248 [PMID: 20523084 DOI: 10.1159/000315730]
- 6 Hurwitz H, Fehrenbacher L, Novotny W, Cartwright T, Hainsworth J, Heim W, Berlin J, Baron A, Griffing S, Holmgren E, Ferrara N, Fyfe G, Rogers B, Ross R, Kabbinavar F. Bevacizumab plus irinotecan, fluorouracil, and leucovorin for metastatic colorectal cancer. *N Engl J Med* 2004; **350**: 2335-2342 [PMID: 15175435 DOI: 10.1056/NEJMoa032691]
- 7 Giantonio BJ, Catalano PJ, Meropol NJ, O'Dwyer PJ, Mitchell EP, Alberts SR, Schwartz MA, Benson AB. Bevacizumab in combination with oxaliplatin, fluorouracil, and leucovorin (FOLFOX4) for previously treated metastatic colorectal cancer: results from the Eastern Cooperative Oncology Group Study E3200. *J Clin Oncol* 2007; **25**: 1539-1544 [PMID: 17442997 DOI: 10.1200/JCO.2006.09.6305]
- 8 Bennouna J, Sastre J, Arnold D, Österlund P, Greil R, Van Cutsem E, von Moos R, Viéitez JM, Bouché O, Borg C, Steffens CC, Alonso-Orduña V, Schlichting C, Reyes-Rivera I, Bendahmane B, André T, Kubicka S. Continuation of bevacizumab after first progression in metastatic colorectal cancer (ML18147): a randomised phase 3 trial. *Lancet Oncol* 2013; **14**: 29-37 [PMID: 23168366 DOI: 10.1016/S1470-2045(12)70477-1]
- 9 Masi G, Loupakakis F, Salvatore L, Cremolini C, Fornaro L, Schirripa M, Fea E, Granetto C, Antonuzzo L, Gionmonni E, Allegrini G, Cupini S, Boni C, Banzi M, Chiara S, Sonaglio C, Valsuani C, Bonetti A, Boni L, Falcone A. A randomized phase III study evaluating the continuation of bevacizumab (bv) beyond progression in metastatic colorectal cancer (mCRC) patients (pts) who received bv as part of first-line treatment: results of the BEBYP trial by the Gruppo Oncologico Nord Ovest (GONO). *Ann Oncol* 2012; **23** (suppl 9): 9
- 10 Saltz LB, Clarke S, Díaz-Rubio E, Scheithauer W, Figer A, Wong R, Koski S, Lichinitser M, Yang TS, Rivera F, Couture F, Sirzén F, Cassidy J. Bevacizumab in combination with oxaliplatin-based chemotherapy as first-line therapy in metastatic colorectal cancer: a randomized phase III study. *J Clin Oncol* 2008; **26**: 2013-2019 [PMID: 18421054 DOI: 10.1200/JCO.2007.14.9930]
- 11 Schmoll HJ, Van Cutsem E, Stein A, Valentini V, Glimelius B, Haustermans K, Nordlinger B, van de Velde CJ, Balmana J, Regula J, Nagtegaal ID, Beets-Tan RG, Arnold D, Ciardiello F, Hoff P, Kerr D, Köhne CH, Labianca R, Price T, Scheithauer W, Sobrero A, Tabernero J, Aderka D, Barroso S, Bodoky G, Douillard JY, El Ghazaly H, Gallardo J, Garin A, Glynn-Jones R, Jordan K, Meshcheryakov A, Papamichail D, Pfeiffer P, Souglakos I, Turhal S, Cervantes A. ESMO Consensus Guidelines for management of patients with colon and rectal cancer: A personalized approach to clinical decision making. *Ann Oncol* 2012; **23**: 2479-2516 [PMID: 23012255 DOI: 10.1093/annonc/mds236]
- 12 Díaz-Rubio E, Gómez-España A, Massutí B, Sastre J, Abad A, Valladares M, Rivera F, Safont MJ, Martínez de Prado P, Gallén M, González E, Marcuello E, Benavides M, Fernández-Martos C, Losa F, Escudero P, Arrivi A, Cervantes A, Dueñas R, López-Ladrón A, Lacasta A, Llanos M, Tabernero JM, Antón A, Aranda E. First-line XELOX plus bevacizumab followed by XELOX plus bevacizumab or single-agent bevacizumab as maintenance therapy in patients with metastatic colorectal cancer: the phase III MACRO TTD study. *Oncologist* 2012; **17**: 15-25 [PMID: 22234633 DOI: 10.1634/theoncologist.2011-0249]
- 13 Tournigand C, Samson B, Scheithauer W, Lledo G, Viret F, Andre T, Ramée JF, Tubiana-Mathieu N, Dauba J, Dupuis O, Rinaldi Y, Mabro M, Aucoin N, Khalil A, Latreille J, Louvet C, Brusquant D, Bonnetain F, Chibaudel B, De Gramont A. Bevacizumab (Bev) with or without erlotinib as maintenance therapy, following induction first-line chemotherapy plus Bev, in patients (pts) with metastatic colorectal cancer (mCRC): Efficacy and safety results of the International GERCOR DREAM phase III trial. *J Clin Oncol* 2012; **30** suppl (4): 3500
- 14 Cassidy J, Saltz LB, Giantonio BJ, Kabbinavar FF, Hurwitz H, Rohr UP. Effect of bevacizumab in older patients with metastatic colorectal cancer: pooled analysis of four randomized studies. *J Cancer Res Clin Oncol* 2010; **136**: 737-743 [PMID: 19904559 DOI: 10.1007/s00432-009-0712-3]
- 15 Kozloff MF, Berlin J, Flynn PJ, Kabbinavar F, Ashby M, Dong W, Sing AP, Grothey A. Clinical outcomes in elderly patients with metastatic colorectal cancer receiving bevacizumab and chemotherapy: results from the BRiTE observational cohort study. *Oncology* 2010; **78**: 329-339 [PMID: 20733336 DOI: 10.1159/000320222]
- 16 Cunningham D, Lang I, Lorusso V, Ocvirk J, Shin D, Jonker D, Osborne S, Andre N, Waterkamp D, Saunders M. Bevacizumab (bev) in combination with capecitabine (cape) for the first-line treatment of elderly patients with metastatic colorectal cancer (mCRC): Results of a randomized international phase III trial (AVEX). *J Clin Oncol* 2013; **30** suppl: 3502

P- Reviewer: Casadesus D, Herszenyi L, Lu F, Nishida T

S- Editor: Ji FF L- Editor: A E- Editor: Lu YJ





## Acute abdomen in pregnancy due to isolated Fallopian tube torsion: The laparoscopic treatment of a rare case

Zacharoula Sidiropoulou, António Setúbal

Zacharoula Sidiropoulou, General Surgery Department, Hospital São Francisco Xavier-CHLO, 1449-005 Lisbon, Portugal  
António Setúbal, Gynecology and Obstetrics Department, Hospital da Luz, 1500-650 Lisbon, Portugal

Author contributions: The authors have reviewed the paper and consent fully to its publication.

Correspondence to: Dr. Zacharoula Sidiropoulou, MD, MSc, General Surgery Department, Hospital São Francisco Xavier-CHLO, Estrada do Forte do Alto do Duque, 1449-005 Lisbon, Portugal. [zachsmd@gmail.com](mailto:zachsmd@gmail.com)

Received: April 3, 2014 Revised: June 27, 2014

Accepted: October 1, 2014

Published online: November 16, 2014

estimated 1 per 1.5 million women to have isolated Fallopian tube torsion in Denmark. And since 1933 only 25 cases of Fallopian tube torsion in pregnant women were described.

Sidiropoulou Z, Setúbal A. Acute abdomen in pregnancy due to isolated Fallopian tube torsion: The laparoscopic treatment of a rare case. *World J Clin Cases* 2014; 2(11): 724-727 Available from: URL: <http://www.wjgnet.com/2307-8960/full/v2/i11/724.htm> DOI: <http://dx.doi.org/10.12998/wjcc.v2.i11.724>

### Abstract

In the last years, operative laparoscopy became a standard approach in gynaecology and general surgery. Even in pregnancy its use is becoming more widely accepted. In fact, it offers advantages similar to those in no pregnant women, associated with good maternal and fetal outcomes. Around 0.2% of pregnant women require abdominal surgery. The most common indications of laparoscopy in pregnancy are cholelithiasis complications, appendicitis, persistent ovarian cyst and adnexal torsion. Authors describe a very rare case of acute abdomen due to isolated Fallopian tube torsion in a 24<sup>th</sup> weeks pregnant woman, managed by laparoscopic salpingectomy.

© 2014 Baishideng Publishing Group Inc. All rights reserved.

**Key words:** Fallopian tube torsion; Acute abdomen; Pregnancy; Laparoscopy

**Core tip:** Authors describe a very rare case of acute abdomen due to isolated Fallopian tube torsion in a 24<sup>th</sup> weeks pregnant woman, managed by laparoscopic salpingectomy. In all literature the most recent estimation for its incidence dates from 1970, when Hansen

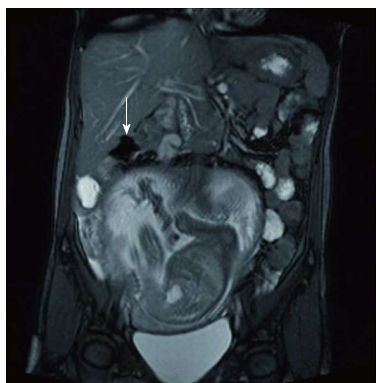
### INTRODUCTION

The Fallopian tube torsion is a rare cause of acute abdomen and even more rare during pregnancy. In 1933, Regad<sup>[1]</sup> reported 201 cases of tubal torsion, 12% of these occurred in pregnant women ( $n = 24$ ). Since 1933 until 2013 only 25 cases were described.

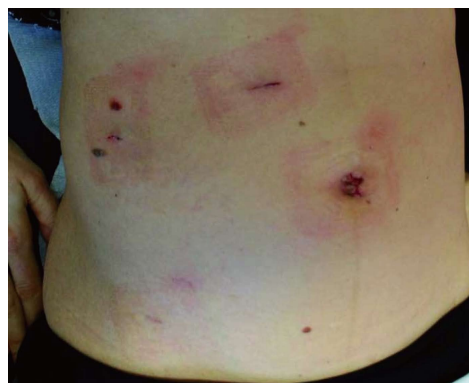The etiology is uncertain, but some authors described factors that could be implicated in the occurrence of Fallopian tube torsion. Some of them are intrinsic of the tube like congenital anomalies or acquired pathology (hydrosalpinx, hematosalpinx, neoplasm, surgery) or autonomic dysfunction and abnormal peristalsis; and other are extrinsic like adhesions, pregnancy, mechanical factors, movement or trauma to the pelvic organs or pelvic congestion<sup>[2,3]</sup>.

Since the Fallopian tube torsion is a rare condition and sporadic cases are reported, its real incidence is unknown, and it seems that it is more frequent in the reproductive age, which is understandable because almost all risk factors are not frequent before menarche or during menopause<sup>[3]</sup>.

The clinical characteristics, the laboratory or the imaging studies are not specific, so the diagnosis is difficult. The acute abdominal pain at the lower quadrants is the most common symptom, with sensitive painful palpa-



**Figure 1** Cystic structure on the right adnexa (magnetic resonance imaging image).



**Figure 2** The abdominal sites of the auxiliary trocars.

tion of the same abdominal area. As the clinical and the complementary study are not specific, the definitive diagnosis can be made by laparoscopy. The authors think that, at the present time, laparoscopy in the setting of experienced and dedicated teams should be the standard approach for this situation, even in pregnant women.

We described a case of a 24 wk pregnancy with a right Fallopian tube torsion which was managed by laparoscopic salpingectomy.

## CASE REPORT

A 36-year-old healthy primigravida, with an uneventful pregnancy until the 24<sup>th</sup> week of pregnancy. At this time she complained of a persistent right flank abdominal pain with a sudden increase. Physical examination revealed abdominal enlargement compatible with pregnancy age and a painful right mid abdominal quadrant palpation, with tenderness and without palpable masses.

The ultrasound study revealed a single, life fetus, with a biometry compatible to a 24 wk pregnancy, with normal amniotic fluid volume and with a normal placenta with no signs of abruption; and in the right lower area it showed a cystic structure measuring 4 cm × 3 cm in diameter, probably with an adnexial origin. The MRI confirmed the cystic image, without any other pathology (Figure 1). Because pain persists, laboratory findings were unspecific and physical examination then was a persisting pain with poor tenderness and peritoneal reaction (acute abdominal pain), two diagnoses were made - acute appendicitis and adnexal torsion.

A diagnostic laparoscopy was then performed. Because the uterus extends 5 cm above the umbilicus, this fact limits the abdomen first entrance, so a direct entrance in the umbilicus could accidentally damage the uterus. Alternative Palmer point or the 9<sup>th</sup> intercostal space is also dangerous because the big pregnant uterus push all the abdominal viscera up. The surgery that we described was an emergent situation, the bowel was not prepared, the viscera distortion was bigger. So the decision was to perform the open technique with the Hasson trocar. The problem was identified by the diagnostic laparoscopy

and then the auxiliary trocars were placed under direct vision and according to the best ergonomic approach for the salpingectomy (Figure 2). We decided to perform a salpingectomy because of the gangrenous aspect of the tube as consequence of its pedicle torsion (Figure 3), without any macroscopic changes of the appendix. The specimen was extracted with a laparoscopic bag. The patient was discharged on the second day after surgery without any complains or surgical and obstetric complication. The reason for two days of hospital stay was based on the diagnosis in a 24<sup>th</sup> week pregnant woman and immediate control of fetal well-being.

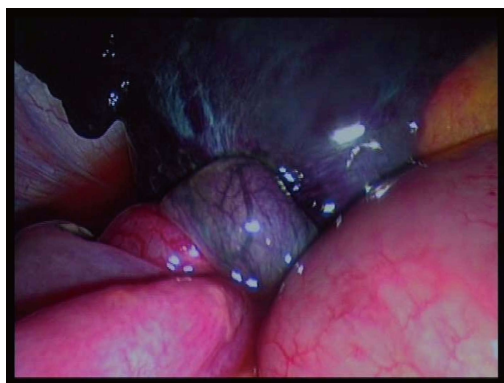
The histopathologic examination of the specimen showed a necrotic tube, secondary of a paraovarian cyst torsion. She delivered a healthy, 3350 g, baby at the 40<sup>th</sup> week of pregnancy by an instrumental vacuum vaginal delivery because of a progressive distocia at the 2<sup>nd</sup> stage. No maternal or fetal complications occurred at the peripartum period.

## DISCUSSION

Isolated torsion of Fallopian tube is a very uncommon condition, even more rare in pregnant women. In all literature the most recent estimation for its incidence dates from 1970, when Hansen<sup>[4]</sup> estimated 1 per 1.5 million women to have isolated Fallopian tube torsion in Denmark. And since 1933 only 25 cases of Fallopian tube torsion in pregnant women were described<sup>[2,5,6]</sup>. Since this is a very rare situation, probably the series published underestimate the real incidence of this pathology.

Other aspect hard to describe is its etiology. Its real cause is uncertain and it can happen in healthy tubes, but some risk factors were described as possible causes. This factors were divided in two types: internal or intrinsic like congenital anomalies (excessive length of tube or spiral course), acquired pathology (hydrosalpinx, hematosalpinx, neoplasm, surgery) or autonomic dysfunction and abnormal peristalsis; and external or extrinsic factors such as changes in neighboring organs (neoplasm, adhesions, pregnancy), mechanical factors, movement or trauma to the pelvic organs or pelvic congestion<sup>[2,3,7]</sup>.

Although the clinical characteristics are not exclusive



**Figure 3** The pedicle torsion of the right Fallopian tube.

of the Fallopian tube torsion, the most common symptom is the lower abdominal pain, generally with a sudden onset and accompanied by nausea, vomiting or urinary urgency<sup>[2,3]</sup>. Physical findings include abdominal tenderness, with or without peritoneal signs and an inconstant palpable mass<sup>[2,3]</sup>.

All this clinical signs and symptoms are common with other medical conditions and give the physician a differential diagnosis problem, which includes ovarian torsion, acute appendicitis, ectopic pregnancy, acute salpingitis, tuboovarian abscess, ruptured ovarian cyst, degenerated leiomyoma, urolithiasis, intestinal obstruction or perforation<sup>[7-9]</sup>. Laboratory values are nonspecific and do not help in the differential diagnosis<sup>[7,9]</sup>. The sonographic findings of isolated Fallopian tube torsion are not pathognomonic and are quite variable<sup>[9]</sup>, especially in second and third trimesters of pregnancy, where the adnexas are more difficult to visualize. But the finding of a high impedance or absence of flow in a tubular structure, especially in a patient with a history of tubal ligation, can be indicative of the diagnosis<sup>[10,11]</sup>.

Pre-operative diagnosis of tubal torsion is very difficult and as its management is surgical the diagnostic laparoscopy is the tool for the definitive diagnosis and treatment<sup>[3]</sup>, even in advanced pregnancies, like the case described.

Until now, there are no prospective and randomized studies that compared laparoscopic procedures with laparotomy during pregnancy. Retrospective studies published, show that laparoscopy in pregnancy appears safe and can be performed without a considerable increment in maternal and fetal complications. Mathevet *et al*<sup>[12]</sup> published the results of 48 laparoscopic procedures for management of adnexal masses in pregnancy (17 cases were performed during the first trimester, 27 cases in the second trimester and 4 in the third trimester). Except one fetal loss 4 d after surgery, no complications were observed during the intra and post-operative periods and obstetrical outcomes were. So the authors concluded that laparoscopic management of adnexal masses in pregnancy is a safe and effective procedure, performed by an experienced team. Similar conclusions were made by Lenglet *et al*<sup>[13]</sup> in a series of 26 pregnant patients who

underwent the laparoscopic surgery of ovarian cysts.

Despite the limited data, it seems that laparoscopic surgery in pregnancy, in experienced hands, is a technique acceptable with some advantages, including early return of bowel function, early ambulation, short hospital stay, rapid return to normal activity, low rate of wound infection and hernia and less pain after the procedure<sup>[14,15]</sup>. Another advantage of laparoscopy is the lesser manipulation of the uterus which leads to less uterine contractions, so less spontaneous abortion, preterm labor and premature delivery<sup>[14]</sup>. However laparoscopy during pregnancy should be performed with caution and some precautions should be taken like: routinely intraoperative fetal monitoring, attention with patient position (for example, the lateral decubitus position should be preferred to prevent inferior vena cava compression), the Hasson trocar open technique seems to be safer to prevent inadvertent puncture of the uterus (but no studies showed a real advantage under the Veress technique), intra-abdominal pressure should be kept less than 15 mmHg, maternal end-tidal volume CO<sub>2</sub> should be monitored and kept within the normal range, depending on the height of the uterus the secondary trocars should be inserted under direct vision and their position decided according to the uterus size and the position of the abnormal findings. The administration of prophylactic tocolytics is not necessary; it can be given if there is evidence of uterine contractions<sup>[14,16]</sup>.

In conclusion, isolated Fallopian tube torsion should be considered as a possible diagnosis of acute abdominal pain in pregnancy. The diagnostic laparoscopy is the gold standard for its definitive diagnosis and allows the tube torsion resolution with a minimal invasive technique, even in pregnant women.

## COMMENTS

### Case characteristics

Acute abdomen in pregnancy, diagnostic challenges.

### Clinical diagnosis

Abdominal enlargement compatible with pregnancy age and a painful right mid abdominal quadrant palpation, with tenderness and without palpable masses.

### Differential diagnosis

Laboratory and image exams, high clinical suspicion.

### Imaging diagnosis

Ultrasonography in first approach, magnetic resonance imaging confirmation.

### Pathological diagnosis

Histology validates the findings.

### Treatment

Laparoscopy, diagnostic and treatment.

### Experiences and lessons

Laparoscopy in experienced hands might be the gold standard approach in acute abdomen in pregnant woman.

### Peer review

In this case report, the authors highlighted the useful of laparoscopic approach for emergent abdominal surgery in pregnant women. Their assertion is acceptable and the manuscript is well written.

## REFERENCES

- 1 Regad J. Etude anatomo-pathologique de la torsion des trompes uterines. *Gynecol Obstet* 1933; **27**: 519-35

- 2 **Origoni M**, Cavoretto P, Conti E, Ferrari A. Isolated tubal torsion in pregnancy. *Eur J Obstet Gynecol Reprod Biol* 2009; **146**: 116-120 [PMID: 19493607 DOI: 10.1016/j.ejogrb.2009.05.002]
- 3 **Krissi H**, Shalev J, Bar-Hava I, Langer R, Herman A, Kaplan B. Fallopian tube torsion: laparoscopic evaluation and treatment of a rare gynecological entity. *J Am Board Fam Pract* 2001; **14**: 274-277 [PMID: 11458970]
- 4 **Hansen OH**. Isolated torsion of the Fallopian tube. *Acta Obstet Gynecol Scand* 1970; **49**: 3-6 [PMID: 5519474 DOI: 10.3109/00016347009157506]
- 5 **Işçi H**, Güdücü N, Gönenç G, Başgul AY. Isolated tubal torsion in pregnancy--a rare case. *Clin Exp Obstet Gynecol* 2011; **38**: 272-273 [PMID: 21995163]
- 6 **Duncan RP**, Shah MM. Laparoscopic salpingectomy for isolated fallopian tube torsion in the third trimester. *Case Rep Obstet Gynecol* 2012; **2012**: 239352 [PMID: 23024868]
- 7 **Antoniu N**, Varras M, Akkrivis C, Kitsiou E, Stefanaki S, Salamalekis E. Isolated torsion of the fallopian tube: a case report and review of the literature. *Clin Exp Obstet Gynecol* 2004; **31**: 235-238 [PMID: 15491073]
- 8 **Yalcin OT**, Hassa H, Zeytinoglu S, Isiksoy S. Isolated torsion of fallopian tube during pregnancy; report of two cases. *Eur J Obstet Gynecol Reprod Biol* 1997; **74**: 179-182 [PMID: 9306114 DOI: 10.1016/S0301-2115(97)00117-6]
- 9 **Batukan C**, Ozgun MT, Turkyilmaz C, Tayyar M. Isolated torsion of the fallopian tube during pregnancy: a case report. *J Reprod Med* 2007; **52**: 745-747 [PMID: 17879840]
- 10 **Baumgartel PB**, Fleischer AC, Cullinan JA, Bluth RF. Color Doppler sonography of tubal torsion. *Ultrasound Obstet Gynecol* 1996; **7**: 367-370 [PMID: 8774106 DOI: 10.1046/j.1469-0705.1996.07050367.x]
- 11 **Elchalal U**, Caspi B, Schachter M, Borenstein R. Isolated tubal torsion: clinical and ultrasonographic correlation. *J Ultrasound Med* 1993; **12**: 115-117 [PMID: 8468737]
- 12 **Mathevet P**, Nessah K, Dargent D, Mellier G. Laparoscopic management of adnexal masses in pregnancy: a case series. *Eur J Obstet Gynecol Reprod Biol* 2003; **108**: 217-222 [PMID: 12781415 DOI: 10.1016/S0301-2115(02)00374-3]
- 13 **Lenglet Y**, Roman H, Rabishong B, Bourdel N, Bonnin M, Bolandard F, Duband P, Pouly JL, Mage G, Canis M. [Laparoscopic management of ovarian cysts during pregnancy]. *Gynecol Obstet Fertil* 2006; **34**: 101-106 [PMID: 16442326 DOI: 10.1016/j.gyobfe.2005.11.008]
- 14 **Al-Fozan H**, Tulandi T. Safety and risks of laparoscopy in pregnancy. *Curr Opin Obstet Gynecol* 2002; **14**: 375-379 [PMID: 12151826 DOI: 10.1097/00001703-200208000-00003]
- 15 **Fatum M**, Rojansky N. Laparoscopic surgery during pregnancy. *Obstet Gynecol Surv* 2001; **56**: 50-59 [PMID: 11140864 DOI: 10.1097/00006254-200101000-00025]
- 16 **Kilpatrick CC**, Orejuela FJ. Management of the acute abdomen in pregnancy: a review. *Curr Opin Obstet Gynecol* 2008; **20**: 534-539 [PMID: 18989127 DOI: 10.1097/GCO.0b013e328317c735]

**P- Reviewer:** Agresta F, Noguera J, Yokoyama N

**S- Editor:** Song XX **L- Editor:** A **E- Editor:** Lu YJ





## Rare etiology of mechanical intestinal obstruction: Abdominal cocoon syndrome

Yener Uzunoglu, Fatih Altintoprak, Omer Yalkin, Yasemin Gunduz, Guner Cakmak, Orhan V Ozkan, Fehmi Celebi

Yener Uzunoglu, Omer Yalkin, Guner Cakmak, Department of General Surgery, Sakarya University Research and Educational Hospital, 54100 Sakarya, Turkey

Fatih Altintoprak, Orhan V Ozkan, Fehmi Celebi, Department of General Surgery, Faculty of Medicine, Sakarya University, 54100 Sakarya, Turkey

Yasemin Gunduz, Department of Radiology, Faculty of Medicine, Sakarya University, 54100 Sakarya, Turkey

**Author contributions:** Uzunoglu Y and Altintoprak F contributed to study design; Uzunoglu Y, Yalkin O and Gunduz Y contributed to data collection; Celebi F, Cakmak G and Altintoprak F contributed to data analysis; Uzunoglu Y and Ozkan OV contributed to writing.

**Correspondence to:** Orhan V Ozkan, Associate Professor of General Surgery, Department of General Surgery, Faculty of Medicine, Sakarya University, Adnan Menderes Caddesi, Saglik Sokak No: 193, 54100 Sakarya, Turkey. [veliorhan@hotmail.com](mailto:veliorhan@hotmail.com)

Telephone: +90-532-3417440 Fax: +90-264-2552106

Received: May 6, 2014 Revised: July 7, 2014

Accepted: August 27, 2014

Published online: November 16, 2014

### Abstract

Abdominal cocoon syndrome is a rare cause of intestinal obstruction with unknown etiology. Diagnosis of this syndrome, which can be summarized as the small intestine being surrounded by a fibrous capsule not containing the mesothelium, is difficult in the preoperative period. A 47-year-old male patient was referred to the emergency department with complaints of abdominal pain, nausea, and vomiting for two days. The abdominal computed tomography examination detected dilated small intestinal loops containing air-fluid levels clustered in the left upper quadrant of the abdomen and surrounded by a thick, saclike, contrast-enhanced membrane. During exploratory surgery, a capsular structure was identified in the upper left quadrant with a regular surface that was solid-fibrous in nature. Ab-

dominal cocoon syndrome is a rarely seen condition, for which the preoperative diagnosis is difficult. The combination of physical examination and radiological signs, and the knowledge of "recurrent characteristics of the complaints" that can be learned by a careful history, may be helpful in diagnosis.

© 2014 Baishideng Publishing Group Inc. All rights reserved.

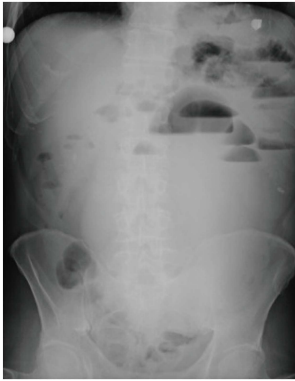**Key words:** Intestinal obstruction; Abdominal cocoon syndrome; Preoperatively diagnosis; Adult patient

**Core tip:** Abdominal "cocoon" is an extremely rare cause of small bowel obstruction. It should be thought of as a rare cause of small bowel obstruction. Its diagnosis is rarely made preoperatively. It has been reported mainly in young adolescent women. But in this adult patient, the small bowel is encased in a fibrous sac called an abdominal cocoon. The clinical manifestations of abdominal "cocoon" are non-specific. The combination of physical examination and radiological signs, and the knowledge of "recurrent characteristics of the complaints" which can be learned by a careful history, may be helpful in diagnosis. Surgery remains the main stay of treatment with satisfactory outcome.

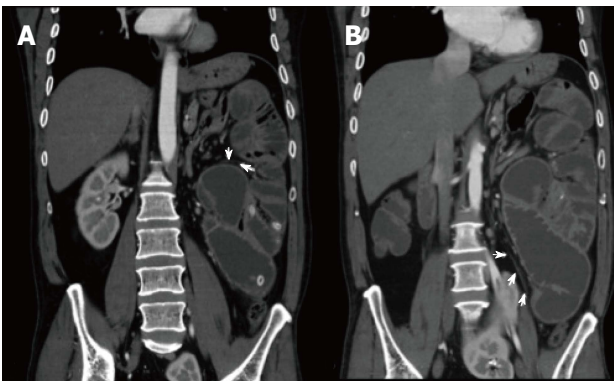
Uzunoglu Y, Altintoprak F, Yalkin O, Gunduz Y, Cakmak G, Ozkan OV, Celebi F. Rare etiology of mechanical intestinal obstruction: Abdominal cocoon syndrome. *World J Clin Cases* 2014; 2(11): 728-731 Available from: URL: <http://www.wjgnet.com/2307-8960/full/v2/i11/728.htm> DOI: <http://dx.doi.org/10.12998/wjcc.v2.i11.728>

### INTRODUCTION

Abdominal cocoon syndrome, which was first defined in 1978<sup>[1]</sup>, is relatively rare, with descriptions in the literature



**Figure 1** Abdominal radiography, multiple air-fluid levels are seen, which was more prominent in the left upper quadrant.

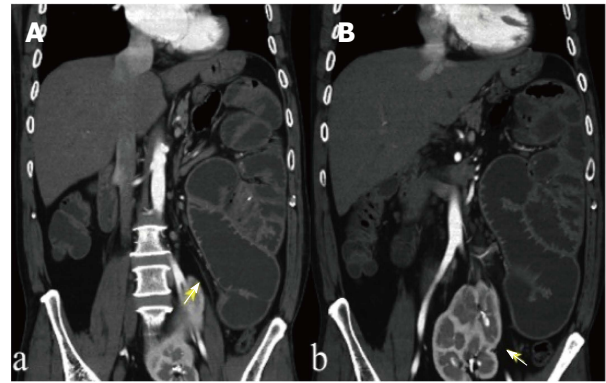


**Figure 2** Abdominal computerized tomography - coronal section; dilated small intestinal loops containing air-fluid levels clustered in the left upper quadrant of the abdomen and surrounded by a thick, saclike, contrast-enhanced membrane in the sections close to the root of mesentery (white arrows). A: Superior; B: Inferior.

limited to case reports. In this syndrome, a portion or all of the small intestine is surrounded with a fibrocollagenous membrane not containing the mesothelium. As it is rarely seen, and its clinical findings nonspecific, it is generally diagnosed during surgery<sup>[2]</sup>. However, it can be characterized by the membrane surrounding the small intestine with contrast-enhanced abdominal computerized tomography (CT) during the preoperative period. Surgical treatment that releases the small intestine by cutting away the adhesions after excision of the membrane is the basic intervention in these cases. This article presents a case with abdominal cocoon syndrome diagnosed, following recurrent complaints, with abdominal CT during the preoperative period and surgically treated.

## CASE REPORT

A 47-year-old male patient was referred to the emergency department with complaints of abdominal pain, nausea, and vomiting for two days. The detailed medical history of the patient, who did not have a known chronic systemic disease or a previous history of any abdominal procedures, revealed similar complaints dating back several years that recurred at certain time intervals and had been

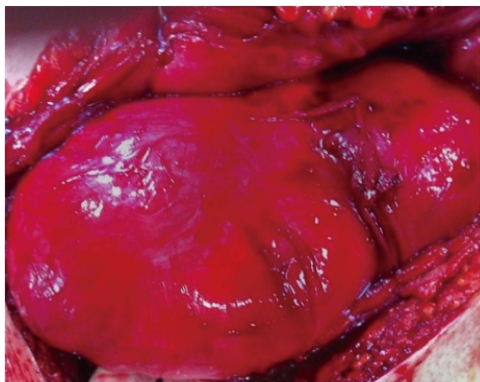

**Figure 3** Abdominal computerized tomography - coronal section; dilated small intestinal loops containing air-fluid levels clustered in the left upper quadrant of the abdomen and surrounded by a thick, saclike, contrast-enhanced membrane (A) (arrow). The left kidney was also located ectopically at the midline in the abdomen at the level of the pelvis (B) (arrow).

treated. Upon physical examination, there was asymmetrical distension and general tenderness, especially prominent in upper regions of the abdomen, with heightened intestinal sounds. The laboratory examinations were normal, except for leukocytosis ( $14.300 \text{ mm}^3$ ). Multiple air-fluid levels were detected on abdominal radiography, which was more prominent in the left upper quadrant (Figure 1). The abdominal CT examination detected dilated small intestinal loops containing air-fluid levels clustered in the left upper quadrant of the abdomen and surrounded by a thick, saclike, contrast-enhanced membrane. The left kidney was also located ectopically at the midline in the abdomen at the level of the pelvis (Figures 2 and 3). During exploratory surgery, widespread adhesions with the peritoneum and small intestine could not be seen. Upon further exploration, a capsular structure was identified in the upper left quadrant with a regular surface that was solid-fibrous in nature. Only 20 cm of the jejunal and ileal segments in the proximal and distal portions of the small intestine were intra-abdominally localized. The remaining small intestinal segments were inside this structure and the greater omentum was hypoplastic (Figure 4). When the capsule was opened, the small intestinal segments inside the capsule were dilated due to obstruction but otherwise normal in structure. The obstruction was caused by fibrous bands of irregular thickness inside the capsule. The operation was completed after total excision of the capsule and removal of the adhesions. The patient manifested clinical signs of ileus on postoperative day 3 due to the adhesions. He was medically treated with nasogastric decompression and parenteral nutrition and discharged on postoperative day 12 without any problems. Upon histopathological examination, a nonspecific inflammatory reaction in conjunction with fibrous connective tissue proliferation was found. On the third month of his follow-up, the patient did not report any problems.

## DISCUSSION

Abdominal cocoon syndrome is a rare cause of acute or



**Figure 4** Intraoperative findings; small intestine could not be seen, a capsular structure was identified in the upper left quadrant with a regular surface that was solid-fibrous in nature.

subacute intestinal obstruction, and its' classified as primary (idiopathic) and secondary. Although the etiology is not precisely known, conditions that result in chronic asymptomatic peritonitis (such as: the use of practalol, peritoneal dialysis, endometriosis, and abdominal tuberculosis) are risk factors. Moreover, accompanied by some diseases (systemic lupus erythematosus, familial Mediterranean fever, infections of the Fallopian tubes, retrograde menstruation) have also been reported<sup>[3-6]</sup>. In a two-case series reported by Yeniy *et al*<sup>[7]</sup>, the greater omentum was absent, suggesting that genetic factors may also play a role in the etiology. Our case reports the role of genetic factors since our patient developed chronic peritonitis without having any of the known risk factors, the greater omentum was hypoplastic, and there was a locational abnormality in the left kidney.

The clinical presentation of abdominal cocoon syndrome is generally acute or subacute intestinal obstruction. There is an increase in intestinal sounds and abdominal distension on physical examination. However, abdominal distension may be asymmetrical, as the small intestine is surrounded by a membrane and not mobile<sup>[8]</sup>. Common complaints during patient history include the recurrence of nonspecific symptoms such as nausea and vomiting that spontaneously recover or respond to medical therapy. Chronic constipation, anorexia, weight loss, and intra-abdominal masses rarely present in these patients<sup>[9]</sup>. In the current case, there were signs of intestinal obstruction associated with asymmetrical distension during the physical examination of the abdomen.

As it is rarely seen and the clinical symptoms are nonspecific, diagnosis in the preoperative period is difficult. Clusters of intestinal loops and a surrounding membrane in contrast-enhanced abdominal CT, especially multislice CT, are diagnostic<sup>[10]</sup>. An abdominal CT that is performed during the preoperative period provides both diagnosis and differential diagnosis, and determines the associated congenital changes, such as the midline location of the left kidney in our case. This prevents undesirable complications during surgery. However, in spite of all opportunities, preoperative diagnosis is difficult and requires

advanced radiological experience. In a retrospective study of twenty-four cases, it was reported that only 16% of the cases could be preoperatively diagnosed<sup>[11]</sup>.

There is a consensus that surgical treatment is ideal in these patients. The recommended procedure excises the membrane and unbinds the adhesions between intestinal segments<sup>[7,10]</sup>. However, this process requires great care, due to the general possibility of secondary damage, as there are extensive adhesions between the membrane and between the intestinal segments. Bowel perforation, enterocutaneous fistula or sepsis occurring as a result of secondary damage, are among the complications that can be encountered during the postoperative period<sup>[3]</sup>. The recurrence of the cocoon in the postoperative period is rare but the most probable complication is the obstruction of small intestine due to adhesions. The current case revealed clinical signs of ileus during postoperative day 3 that responded to medical therapy.

In conclusion, abdominal cocoon syndrome is a rarely seen condition, for which the preoperative diagnosis is difficult. The combination of physical examination and radiological signs, and the knowledge of "recurrent characteristics of the complaints" which can be learned by a careful history, may be helpful in diagnosis. It should be remembered that medical treatment will not be beneficial and definitive treatment requires careful surgical excision during the early stages of the disease.

## COMMENTS

### Case characteristics

Patient was referred to the emergency department with complaints of abdominal pain, nausea, and vomiting for two days.

### Clinical diagnosis

Upon physical examination, there was asymmetrical distension and general tenderness, especially prominent in upper regions of the abdomen, with heightened intestinal sounds.

### Differential diagnosis

The abdominal computerized tomography examination detected dilated small intestinal loops containing air-fluid levels clustered in the left upper quadrant of the abdomen and surrounded by a thick, saclike, contrast-enhanced membrane.

### Laboratory diagnosis

During exploratory surgery, widespread adhesions with the peritoneum and small intestine could not be seen.

### Imaging diagnosis

Please summarize imaging methods and major findings in one sentence.

### Pathological diagnosis

When the capsule was opened, the small intestinal segments inside the capsule were dilated due to obstruction but otherwise normal in structure.

### Treatment

The operation was completed after total excision of the capsule and removal of the adhesions.

### Term explanation

Early diagnosis is important.

### Experiences and lessons

It should be remembered that medical treatment will not be beneficial and definitive treatment requires careful surgical excision during the early stages of the disease.

### Peer review

The case report and the discussion are well-written.

## REFERENCES

- 1 **Foo KT**, Ng KC, Rauff A, Foong WC, Sinniah R. Unusual small intestinal obstruction in adolescent girls: the abdominal cocoon. *Br J Surg* 1978; **65**: 427-430 [PMID: 656764]
- 2 **Hur J**, Kim KW, Park MS, Yu JS. Abdominal cocoon: pre-operative diagnostic clues from radiologic imaging with pathologic correlation. *AJR Am J Roentgenol* 2004; **182**: 639-641 [PMID: 14975962]
- 3 **Meshikhes AW**, Bojal S. A rare cause of small bowel obstruction: Abdominal cocoon. *Int J Surg Case Rep* 2012; **3**: 272-274 [PMID: 22522743 DOI: 10.1016/j.ijscr.2012.03.016]
- 4 **Akbulut S**, Yagmur Y, Babur M. Coexistence of abdominal cocoon, intestinal perforation and incarcerated Meckel's diverticulum in an inguinal hernia: A troublesome condition. *World J Gastrointest Surg* 2014; **6**: 51-54 [PMID: 24672651 DOI: 10.4240/wjgs.v6.i3.51]
- 5 **Li N**, Zhu W, Li Y, Gong J, Gu L, Li M, Cao L, Li J. Surgical treatment and perioperative management of idiopathic abdominal cocoon: single-center review of 65 cases. *World J Surg* 2014; **38**: 1860-1867 [PMID: 24519587 DOI: 10.1007/s00268-014-2458-6]
- 6 **Singh B**, Gupta S. Abdominal cocoon: a case series. *Int J Surg* 2013; **11**: 325-328 [PMID: 23459185 DOI: 10.1016/j.ijssu.2013.02.011]
- 7 **Yeniay L**, Karaca CA, Çalışkan C, Fırat O, Ersin SM, Akgün E. Abdominal cocoon syndrome as a rare cause of mechanical bowel obstruction: report of two cases. *Ulus Travma Acil Cerrahi Derg* 2011; **17**: 557-560 [PMID: 22290011 DOI: 10.5505/tjtes.2011.39018]
- 8 **Naidoo K**, Mewa Kinoo S, Singh B. Small Bowel Injury in Peritoneal Encapsulation following Penetrating Abdominal Trauma. *Case Rep Surg* 2013; **2013**: 379464 [PMID: 23533912 DOI: 10.1155/2013/379464]
- 9 **Kayastha K**, Mirza B. Abdominal cocoon simulating acute appendicitis. *APSP J Case Rep* 2012; **3**: 8 [PMID: 22953302]
- 10 **Hu D**, Wang R, Xiong T, Zhang HW. Successful delivery after IVF-ET in an abdominal cocoon patient: case report and literature review. *Int J Clin Exp Pathol* 2013; **6**: 994-997 [PMID: 23638238]
- 11 **Wei B**, Wei HB, Guo WP, Zheng ZH, Huang Y, Hu BG, Huang JL. Diagnosis and treatment of abdominal cocoon: a report of 24 cases. *Am J Surg* 2009; **198**: 348-353 [PMID: 19217609 DOI: 10.1016/j.amjsurg.2008.07.054]

**P- Reviewer:** Hedgire SS, Prasad KK, Paraskevas KI

**S- Editor:** Ji FF **L- Editor:** A **E- Editor:** Lu YJ





# World Journal of *Clinical Cases*

*World J Clin Cases* 2014 December 16; 2(12): 732-942



## Contents

Monthly Volume 2 Number 12 December 16, 2014

### REVIEW

- 732 Adenoid cystic carcinoma of breast: Recent advances  
*Miyai K, Schwartz MR, Divatia MK, Anton RC, Park YW, Ayala AG, Ro JY*
- 742 Drug-targeting methodologies with applications: A review  
*Kleinstreuer C, Feng Y, Childress E*
- 757 Relational coordination and healthcare management in lung cancer  
*Romero JAV, Señaris JDL, Heredero CDP, Nuijten M*
- 769 New targeted therapies for breast cancer: A focus on tumor microenvironmental signals and chemoresistant breast cancers  
*Nwabo Kamdje AH, Seke Etet PF, Vecchio L, Tagne RS, Mbo Amvene J, Muller JM, Krampera M, Lukong KE*
- 787 Antimicrobial resistance in *Acinetobacter baumannii*: From bench to bedside  
*Lin MF, Lan CY*

### MINIREVIEWS

- 815 Follicular contact dermatitis revisited: A review emphasizing neomycin-associated follicular contact dermatitis  
*Cohen PR*
- 822 Prognostic factors in periodontal therapy and their association with treatment outcomes  
*Ioannou AL, Kotsakis GA, Hinrichs JE*
- 828 Sleep disordered breathing in interstitial lung disease: A review  
*Troy LK, Corte TJ*
- 835 Role of MGMT as biomarker in colorectal cancer  
*Inno A, Fanetti G, Di Bartolomeo M, Gori S, Maggi C, Cirillo M, Iacovelli R, Nichetti F, Martinetti A, de Braud F, Bossi I, Pietrantonio F*
- 840 Acute necrotizing pancreatitis: Surgical indications and technical procedures  
*Aranda-Narváez JM, González-Sánchez AJ, Montiel-Casado MC, Titos-García A, Santoyo-Santoyo J*
- 846 Large bowel injuries during gynecological laparoscopy  
*Ülker K, Anuk T, Bozkurt M, Karasu Y*

- 852 Aetiology of idiopathic granulomatous mastitis

*Altintoprak F, Kivilcim T, Ozkan OV*

- 859 Role of immunotherapy in the treatment of allergic asthma

*Yukselen A, Kendirli SG*

- 866 Precancerous lesions of oral mucosa

*Yardimci G, Kutlubay Z, Engin B, Tuzun Y*

- 873 Eosinophilic chronic rhinosinusitis in East Asians

*Wang ET, Zheng Y, Liu PF, Guo LJ*

- RETROSPECTIVE STUDY** 883 Spectrum of magnetic resonance imaging findings in congenital lumbar spinal stenosis

*Soldatos T, Chalian M, Thawait S, Belzberg AJ, Eng J, Carrino JA, Chhabra A*

- PROSPECTIVE STUDY** 888 Appendiceal Crohn's disease clinically presenting as acute appendicitis

*Han H, Kim H, Rehman A, Jang SM, Paik SS*

- SYSTEMATIC REVIEW** 893 Tranexamic acid for the management of uterine fibroid tumors: A systematic review of the current evidence

*Peitsidis P, Koukoulomati A*

- CASE REPORT** 899 Reconstruction using a pedicled upper arm fillet flap after excision of a malignant peripheral nerve sheath tumor: A case report

*Singla P, Kachare SD, Fitzgerald TL, Zeri RS, Haque E*

- 903 Cecal bascule herniation into the lesser sac

*Makarawo T, Macedo FI, Jacobs MJ*

- 907 Tentorial dural arteriovenous fistula presenting as myelopathy: Case series and review of literature

*Gross R, Ali R, Kole M, Dorbeistein C, Jayaraman MV, Khan M*

- 912 Relapsing polychondritis with p-ANCA associated vasculitis: Which triggers the other?

*File I, Trinn C, Mátyus Z, Ujhelyi L, Balla J, Mátyus J*

- 918 Gastric trichobezoar associated with perforated peptic ulcer and *Candida glabrata* infection  
*Morales Losada H, Huenchullán Catalán C, Arriagada Demetrio R, Espinoza Rivas M, Castagnoli Parraguez N, Alanis Alvarez M*
- 924 Rare entity: Ectopic liver tissue in the wall of the gallbladder - A case report  
*Arslan Y, Altintoprak F, Serin KR, Kivilcim T, Yalkin O, Ozkan OV, Celebi F*
- 927 Rare multiple fistulas with large saccular aneurysms originating from left anterior descending artery and left main coronary artery  
*Emre E, Aktas M, Sahin T, Ural E, Ural D*
- 930 Case of cannabinoid hyperemesis syndrome with long-term follow-up  
*Cha JM, Kozarek RA, Lin OS*
- 934 Scalp block for brain abscess drainage in a patient with uncorrected tetralogy of Fallot  
*Sethi S, Kapil S*
- 938 Complete oral rehabilitation in a case with severe dental fluorosis  
*Joshi N, Palaskar J, Joshi M, Kathariya R*



## Contents

*World Journal of Clinical Cases*  
Volume 2 Number 12 December 16, 2014

**APPENDIX** I-V Instructions to authors

### ABOUT COVER

Editorial Board Member of *World Journal of Clinical Cases*, Flavia Mariana Valente, PhD, Associate Professor, Department of Physiotherapy and Cardiology, Master's Degree in Health Sciences, Paulista University, Faculty of Medicine of Sao Jose do Rio Preto, 15025-900 Sao Jose do Rio Preto, Brazil

### AIM AND SCOPE

*World Journal of Clinical Cases* (*World J Clin Cases*, *WJCC*, online ISSN 2307-8960, DOI: 10.12998) is a peer-reviewed open access academic journal that aims to guide clinical practice and improve diagnostic and therapeutic skills of clinicians.

The primary task of *WJCC* is to rapidly publish high-quality Autobiography, Case Report, Clinical Case Conference (Clinicopathological Conference), Clinical Management, Diagnostic Advances, Editorial, Field of Vision, Frontier, Medical Ethics, Original Articles, Clinical Practice, Meta-Analysis, Minireviews, Review, Therapeutics Advances, and Topic Highlight, in the fields of allergy, anesthesiology, cardiac medicine, clinical genetics, clinical neurology, critical care, dentistry, dermatology, emergency medicine, endocrinology, family medicine, gastroenterology and hepatology, geriatrics and gerontology, hematology, immunology, infectious diseases, internal medicine, obstetrics and gynecology, oncology, ophthalmology, orthopedics, otolaryngology, pathology, pediatrics, peripheral vascular disease, psychiatry, radiology, rehabilitation, respiratory medicine, rheumatology, surgery, toxicology, transplantation, and urology and nephrology.

### INDEXING/ABSTRACTING

*World Journal of Clinical Cases* is now indexed in PubMed Central, PubMed, Digital Object Identifier.

**FLYLEAF** I-V Editorial Board

### EDITORS FOR THIS ISSUE

Responsible Assistant Editor: *Xiang Li*  
Responsible Electronic Editor: *Huan-Liang Wu*  
Proofing Editor-in-Chief: *Lian-Sheng Ma*

Responsible Science Editor: *Yue-Li Tian*  
Proofing Editorial Office Director: *Xiu-Xia Song*

#### NAME OF JOURNAL

*World Journal of Clinical Cases*

#### ISSN

ISSN 2307-8960 (online)

#### LAUNCH DATE

April 16, 2013

#### FREQUENCY

Monthly

#### EDITORS-IN-CHIEF

**Giuseppe Di Lorenzo, MD, PhD, Professor**, Genitourinary Cancer Section and Rare-Cancer Center, University Federico II of Napoli, Via Sergio Pansini, 5 Ed. 1, 80131, Naples, Italy

**Jan Jacques Michiels, MD, PhD, Professor**, Primary Care, Medical Diagnostic Center Rijnmond Rotterdam, Bloodcoagulation, Internal and Vascular Medicine, Erasmus University Medical Center, Rotterdam, Goodheart Institute and Foundation, Erasmus Tower, Veenmos 13, 3069 AT, Erasmus City, Rotterdam, The Netherlands

**Sandro Vento, MD**, Department of Internal Medicine, University of Botswana, Private Bag 00713, Gaborone,

Botswana

**Shuhei Yoshida, MD, PhD**, Division of Gastroenterology, Beth Israel Deaconess Medical Center, Dana 509, Harvard Medical School, 330 Brookline Ave, Boston, MA 02215, United States

#### EDITORIAL OFFICE

Jin-Lei Wang, Director  
Xiu-Xia Song, Vice Director  
*World Journal of Clinical Cases*  
Room 903, Building D, Ocean International Center, No. 62 Dongsihuan Zhonglu, Chaoyang District, Beijing 100025, China  
Telephone: +86-10-85381891  
Fax: +86-10-85381893  
E-mail: [editorialoffice@wjgnet.com](mailto:editorialoffice@wjgnet.com)  
Help Desk: <http://www.wjgnet.com/csp/helpdesk.aspx>  
<http://www.wjgnet.com>

#### PUBLISHER

Baishideng Publishing Group Inc  
8226 Regency Drive,  
Pleasanton, CA 94588, USA  
Telephone: +1-925-223-8242  
Fax: +1-925-223-8243  
E-mail: [bpgoffice@wjgnet.com](mailto:bpgoffice@wjgnet.com)  
Help Desk: <http://www.wjgnet.com/csp/helpdesk.aspx>

<http://www.wjgnet.com>

#### PUBLICATION DATE

December 16, 2014

#### COPYRIGHT

© 2014 Baishideng Publishing Group Inc. Articles published by this Open Access journal are distributed under the terms of the Creative Commons Attribution Non-commercial License, which permits use, distribution, and reproduction in any medium, provided the original work is properly cited, the use is non commercial and is otherwise in compliance with the license.

#### SPECIAL STATEMENT

All articles published in journals owned by the Baishideng Publishing Group (BPG) represent the views and opinions of their authors, and not the views, opinions or policies of the BPG, except where otherwise explicitly indicated.

#### INSTRUCTIONS TO AUTHORS

Full instructions are available online at [http://www.wjgnet.com/2307-8960/g\\_info\\_20100722180909.htm](http://www.wjgnet.com/2307-8960/g_info_20100722180909.htm)

#### ONLINE SUBMISSION

<http://www.wjgnet.com/csp/>

## Adenoid cystic carcinoma of breast: Recent advances

Kosuke Miyai, Mary R Schwartz, Mukul K Divatia, Rose C Anton, Yong Wook Park, Alberto G Ayala, Jae Y Ro

Kosuke Miyai, Mary R Schwartz, Mukul K Divatia, Rose C Anton, Alberto G Ayala, Jae Y Ro, Department of Pathology and Genomic Medicine, Houston Methodist Hospital, Weill Medical College of Cornell University, Houston, TX 77030, United States

Kosuke Miyai, Department of Basic Pathology, National Defense Medical College, Saitama 359-0042, Japan

Yong Wook Park, Department of Pathology, Hanyang University, Guri Hospital, 153 Gyeongchun-ro, Guri, Gyeonggi-do 471-701, South Korea

Author contributions: All the authors contributed to this work. Correspondence to: Jae Y Ro, MD, PhD, Department of Pathology and Genomic Medicine, Houston Methodist Hospital, Weill Medical College of Cornell University, 6565 Fannin Street, Suite M227, Houston, TX 77030, United States. [jaero@houstonmethodist.org](mailto:jaero@houstonmethodist.org)

Telephone: +1-713-4412263 Fax: +1-713-7931603

Received: July 3, 2014 Revised: September 3, 2014

Accepted: September 18, 2014

Published online: December 16, 2014

© 2014 Baishideng Publishing Group Inc. All rights reserved.

**Key words:** Adenoid cystic carcinoma; Breast; Triple-negative and basal-like phenotype; Histology; Molecular genetic features

**Core tip:** Adenoid cystic carcinoma (ACC) of the breast is a rare, special subtype of breast cancer characterized by the presence of luminal and basaloid cells arranged in specific growth patterns. Although ACCs display a triple-negative, basal-like phenotype, these tumors are usually low-grade and exhibit an indolent clinical behavior. Many discoveries regarding the molecular genetic features of the ACC, including a specific chromosomal translocation t(6;9) that results in a *MYB-NFIB* fusion gene, have been made in recent years. This review provides our experience with ACCs, as well as an overview of its clinical, histopathological, and molecular genetic features.

### Abstract

Adenoid cystic carcinoma (ACC) of the breast is a rare special subtype of breast cancer characterized by the presence of a dual cell population of luminal and basaloid cells arranged in specific growth patterns. Most breast cancers with triple-negative, basal-like breast features (*i.e.*, tumors that are devoid of estrogen receptor, progesterone receptor, and human epidermal growth factor receptor 2 expression, and express basal cell markers) are generally high-grade tumors with an aggressive clinical course. Conversely, while ACCs also display a triple-negative, basal-like phenotype, they are usually low-grade and exhibit an indolent clinical behavior. Many discoveries regarding the molecular and genetic features of the ACC, including a specific chromosomal translocation t(6;9) that results in a *MYB-NFIB* fusion gene, have been made in recent years. This comprehensive review provides our experience with ACC of the breast, as well as an overview of clinical, histopathological, and molecular genetic features.

Miyai K, Schwartz MR, Divatia MK, Anton RC, Park YW, Ayala AG, Ro JY. Adenoid cystic carcinoma of breast: Recent advances. *World J Clin Cases* 2014; 2(12): 732-741 Available from: URL: <http://www.wjgnet.com/2307-8960/full/v2/i12/732.htm> DOI: <http://dx.doi.org/10.12998/wjcc.v2.i12.732>

### INTRODUCTION

Invasive breast carcinoma comprises a heterogeneous group of tumors with various clinical, morphologic, and molecular genetic features<sup>[1,2]</sup>. According to the 2012 World Health Organization classification, invasive ductal carcinoma of no special type (NST) is the most common histologic type, accounting for up to 75% of all invasive breast carcinomas<sup>[3]</sup>. The remainder of the invasive cancers represent at least 18 different special and rare histomorphologic subtypes, including adenoid cystic carcinoma (ACC), a salivary gland-type of breast carcinoma<sup>[3]</sup>.

A characteristic histologic pattern of ACC of the breast includes both epithelial and myoepithelial compo-

**Table 1** Clinical characteristics of adenoid cystic carcinoma of the breast in recently reported cohorts

Ref.	No. of patients'		Pathologic T1 or T2	Lymph node involvement	Distant metastasis	Survival
	Cases	Age (yr)				
Kulkarni <i>et al</i> <sup>[14]</sup>	933	60 (median)	Not reported	5.1%	Not reported	88% (5 yr)
Coates <i>et al</i> <sup>[15]</sup>	376	62 (mean)	90%	6.1%	1.1% (site not specified)	90% (10 yr)
Ghabach <i>et al</i> <sup>[11]</sup>	338	63 (mean)	95%	1.7%	< 1% (site not specified)	94.9% (10 yr)
Thompson <i>et al</i> <sup>[16]</sup>	244	62 (median)	92%	4.9%	2.9% (site not specified)	94.9% (10 yr)
Khanfir <i>et al</i> <sup>[17]</sup>	61	59 (median)	88%	0%	6.5% (bone, liver, lung)	94% (5 yr)
Defaud-Hénon <i>et al</i> <sup>[18]</sup>	30	61 (median)	95%	0%	10% (bone, liver, lung)	Not calculated
Vranic <i>et al</i> <sup>[19]</sup>	21	60.8 (mean)	85%	0%	20% (bone, kidney, lung)	90% (5 yr)

nents and resembles a well-known tumor of the salivary gland origin known by the same name. However, patients diagnosed with ACC of the breast have a better prognosis than those who are diagnosed with ACC of the salivary gland<sup>[4-6]</sup>. ACC of the breast belongs to the basal-like subgroup of breast cancers<sup>[7-9]</sup>. Based on extensive molecular and genetic profiling studies, basal-like tumors are most often hormone receptor [estrogen receptor (ER) and progesterone receptor (PR)] negative, do not express human epidermal growth factor receptor 2 (Her2), but express one or more basal/myoepithelial cell markers [*e.g.*, cytokeratins (CKs) 5, 5/6, 14 and 17]<sup>[10]</sup>. Unlike other triple-negative breast cancers that are associated with poor prognosis, ACC has an overall excellent prognosis<sup>[11]</sup>. Because of these distinct clinicopathologic features that set it apart from the other triple-negative breast cancers, an understanding of ACC of the breast is essential for surgical pathologists, breast surgeons, and oncologists. This review will focus on ACC of the breast and will outline important updates in its epidemiology, clinical features, histomorphologic/immunohistochemical characteristics, molecular genetic features, and prognosis/treatment. In addition, we will address our team's experience with this clinical entity.

## EPIDEMIOLOGY

ACC is an uncommon subtype of invasive breast carcinoma and accounts for less than 0.1% of all primary carcinomas of the breast<sup>[3,12,13]</sup>. Recently, several independent studies based on large patient cohorts have provided more insight into its epidemiology and clinical characteristics<sup>[11,14-20]</sup>. This information, in the recent studies published in 2010 and after, is summarized in Table 1. The reported age distribution for patients diagnosed with ACC of the breast ranges from 38 to 81 years (with a median age of 60 years; Table 1) and is similar to that seen in other invasive breast cancer cases<sup>[3]</sup>. Moreover, a previous case series of 338 patients with ACC of the breast conducted over a 30-year period identified its age-adjusted incidence ratio (AAIR) to be 0.92 per 1 million person-years. The AAIR remained constant during the 30-year period and was 39%, lower in African-Americans than in Caucasian-Americans<sup>[11]</sup>. Most cases are in females, but occasional cases have been reported in male patients<sup>[21,22]</sup>.

## CLINICAL FEATURES

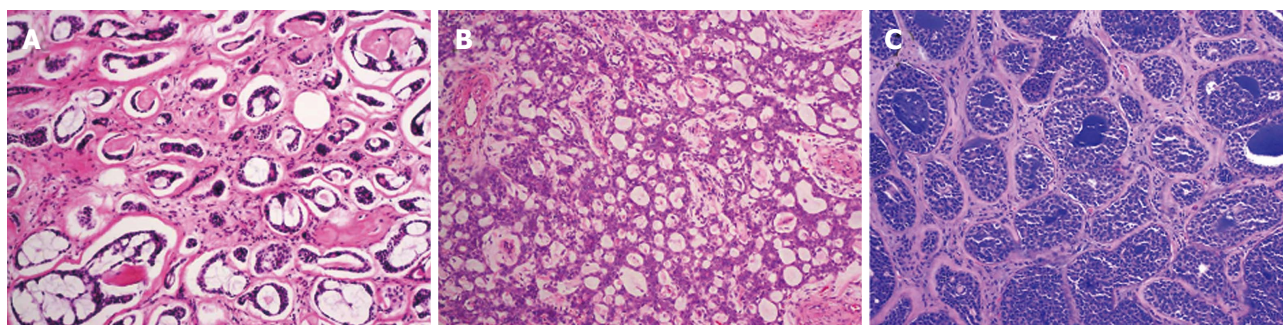
ACC of the breast affects the left and right breasts equally and tumors arise irrespective of the breast quadrants. However, in about 50 percent of patients, lesions are found in subareolar region<sup>[23]</sup>. Pain or tenderness described in the minority of cases has not been correlated with histologically-confirmed perineural invasion<sup>[24]</sup>. Mammographically, these tumors may appear as asymmetric densities or irregular masses. Sonographically, they appear as well-defined, irregular, heterogeneous, or hypoechoic masses. Nonetheless, the radiographic findings are non-specific and can be misdiagnosed as benign lesions<sup>[13,25]</sup>. Subsequently, it could be challenging for a radiologist to make the correct diagnosis of carcinoma without histologic confirmation<sup>[25]</sup>. Lastly, although most patients present with a solitary tumor, a few cases of multifocal ACC of the breast have also been reported<sup>[26,27]</sup>.

## HISTOMORPHOLOGIC/IMMUNOHISTOCHEMICAL CHARACTERISTICS

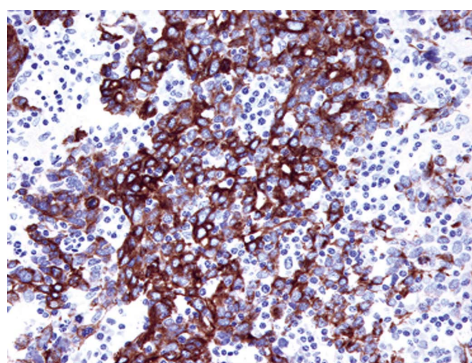
The mean size of ACC is 3.0 cm (range, 0.7 to 12.0 cm)<sup>[28]</sup>. Most cases are macroscopically well-circumscribed. Occasionally, pink, tan, or gray microcysts are evident<sup>[28]</sup>. ACC usually presents as a localized disease of pathologic T1 or T2 (Table 1).

The histology of ACC of the breast is similar to that of their salivary gland counterparts. A variety of microscopic patterns detected in the ACC of the salivary glands may also be present in the ACC of the breast. A tumor typically consists of a dual-cell population of luminal and myoepithelial-basal cells which may be arranged in one or more of three architectural patterns: tubular-trabecular, cribriform, and solid-basaloid (Figure 1)<sup>[3]</sup>. There are two types of structures lined by these two different types of cells: true glandular spaces and pseudolumina. Luminal cells, characterized by round nuclei and eosinophilic cytoplasm, surround true gland lumina containing periodic acid-Schiff-positive neutral mucin. Immunohistochemically, the luminal cells are positive for CK7, CK8/18, epithelial membrane antigen, and CD117 (c-Kit)<sup>[2,29-31]</sup>. On the other hand, the myoepithelial-basal cells exhibit central oval nuclei and scant cytoplasm, and form pseudolumina, which result from intraluminal invaginations of





**Figure 1 Adenoid cystic carcinoma of the breast.** Adenoid cystic carcinomas predominantly showing tubular-trabecular (A), cribriform (B), and solid-basaloid patterns (C). Original magnification  $\times 100$ .



**Figure 2 Immunoreactivity of cytokeratin 5/6 in solid pattern of adenoid cystic carcinoma of the breast.** The tumor cells are immunoreactive for cytokeratin 5/6, indicating myoepithelial-basal cell origin of tumor cells. Original magnification  $\times 200$ .

the stroma. The myoepithelial-basal cells are immunoreactive for basal cytokeratins (CK5, CK5/6, CK14, CK17) (Figure 2), myoepithelial markers (p63, actin, calponin, S-100 protein), vimentin, and epidermal growth factor receptor (EGFR)<sup>[2,29-32]</sup>. Kasami *et al.*<sup>[33]</sup> reported that the polarity of the different types of cells could be demonstrated by immunohistochemistry: myoepithelial-basal cells usually express laminin, fibronectin, basal lamina related proteins, and type IV collagen, whereas the luminal cells express proteins related to cell polarization and epithelial differentiation, including fodrin, E-cadherin, and  $\beta$ -catenin. The authors suggest that this preserved cell polarity and segregated cell differentiation could explain the lack of metastatic capacity observed in this tumor type. Other reports describe areas of squamous differentiation and even rare sebaceous differentiation in ACC of the breast<sup>[34,35]</sup>.

In a way akin to the ACC of the salivary gland, ACCs of the breast are graded according to the proportion of solid growth: tumors with either cribriform or tubular-trabecular pattern and without solid elements are considered grade I, tumors with  $\leq 30\%$  of solid growth are classified as grade II, and tumors having more than 30% solid growth are designated grade III<sup>[4,36]</sup>. Ro *et al.*<sup>[4]</sup> reported that tumors with a solid pattern (grade II and III) had a tendency to be larger than those without a solid pattern (grade I), and that grade II and III tumors were more

**Table 2 Review of data reported on the expression of prognostic and predictive markers of breast adenoid cystic carcinoma (%)**

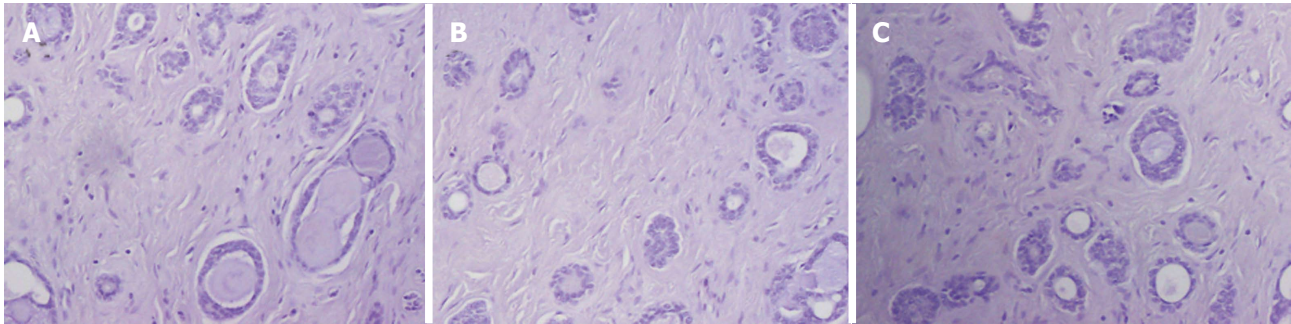
Ref.	No. of cases	Percentage of cases showing positivity		
		ER	PR	Her2
Kulkarni <i>et al.</i> <sup>[14]</sup>	933	15	13	NA
Ghabach <i>et al.</i> <sup>[11]</sup>	338	12	2	NA
Arpino <i>et al.</i> <sup>[5]</sup>	28	46	36	NA
Mastropasqua <i>et al.</i> <sup>[36]</sup>	20	15	10	0
Azouley <i>et al.</i> <sup>[41]</sup>	18	0	0	0
Crisi <i>et al.</i> <sup>[42]</sup>	6	0	0	0
Weigelt <i>et al.</i> <sup>[43]</sup>	4	0	0	0

ER: Estrogen receptor; Her2: Human epidermal growth factor receptor 2; NA: Not available; PR: Progesterone receptor.

likely to develop recurrences. In their series, three patients who developed metastatic ACC had grade II or III lesions. Furthermore, Shin *et al.*<sup>[37]</sup> reported 9 cases of the solid (basaloid) variant of breast ACC in which the tumor cells tended to be larger, with hyperchromatic nuclei showing moderate to marked atypia, pleomorphism, and increased mitotic activity. This solid variant of ACC was associated with an aggressive clinical course. However, it is important to note that the histological grade defined by this system did not correlate with disease outcomes observed in two other studies<sup>[34,38]</sup>. The most recent American Joint Committee on Cancer staging manual (7<sup>th</sup> edition) recommends that Nottingham histologic grading be provided uniformly for all breast carcinomas<sup>[39]</sup>. Based on this grading scheme, most ACCs would belong to the histologic grade 1 (3 - 1 + 1) or histologic grade 2 (3 + 2 + 1).

Phenotypically, both luminal and myoepithelial-basaloid cells in ACC of the breast are generally negative for ER, PR, and Her2 proteins (Table 2 and Figure 3)<sup>[11,14,40-43]</sup>. The immunohistochemical profile of ACC of the breast fits well within that of triple-negative breast cancers with basal-like features. In one study, ER and PR expression was detected in 46% and 36% of ACC cases, respectively<sup>[5]</sup>. Although this cohort was one of the larger series of ACCs reported to date ( $n = 28$ ), the cases were collected from different institutions and did not undergo a central review of the diagnosis. Consequently, it cannot be ruled out that a substantial number of these cases were actually invasive cribriform carcinomas with ER and PR immunoreactivity. In addition, it should be noted that





**Figure 3** Immunohistochemical findings in adenoid cystic carcinoma of the breast. A: Estrogen receptor; B: Progesterone receptor; C: Human epidermal growth factor receptor 2. All these markers are negative in a case of adenoid cystic carcinoma of the breast. Original magnification  $\times 100$ .

**Table 3** Houston Methodist experience of adenoid cystic carcinoma of the breast (2004 to 2010)

Case No.	Age (yr)	Laterality	Tumor size (cm)	Perineural invasion	Lymph node metastasis	Distant metastasis	TMN stage (AJCC)	Follow-up (mo)
1	61	Left	1.6	-	pN0	-	I A	14
2	83	Right	3.0	-	pN0	Lungs, multiple	IV	85
3	51	Right	2.2	-	cN0	-	II A	12
4	57	Left	4.5	+	cN0	-	II A	65
5	48	Left	2.0	-	cN0	-	II A	90

AJCC: American Joint Committee on Cancer.

in the latter study, dextran-coated charcoal assay was used to assess expression for ER and PR instead of the now more widely used immunohistochemistry. Since normal breast lobules and ducts are often entrapped within the tumor tissues, it may lead to false positive results of the dextran-coated charcoal assay.

There have been several case reports suggesting an association between ACC of the breast and various benign lesions including microglandular adenosis, tubular adenosis, adenomyoepithelioma, and fibroadenoma<sup>[44-48]</sup>. Acs *et al*<sup>[44]</sup> suggested that ACC of the breast may develop in a background of and in continuity with microglandular adenosis. Following this hypothesis, their group described a morphological spectrum of lesions with a trend of progression, encompassing microglandular adenosis, “atypical microglandular adenosis” (also described as “ACC in situ”), and invasive ACC<sup>[44]</sup>. Da Silva *et al*<sup>[45]</sup> reported a morphological characterization of tubular adenosis arising concurrently with ACC in the breast, although the comparative genomic hybridization (CGH) analysis performed on these two lesions failed to provide evidence of molecular evolution from tubular adenosis to ACC. Importantly, breast that harbors an ACC can rarely also contain other types of carcinoma, as was shown in a case where the ACC of the breast coexisted with an invasive ductal carcinoma of NST<sup>[49,50]</sup>.

ACC of the breast that exhibits a cribriform/tubular pattern should be distinguished from invasive cribriform/tubular carcinoma or a benign condition termed collagenous spherulosis<sup>[51,52]</sup>. This is especially important when a pathologist is provided with tiny tissue specimens obtained by core needle biopsies<sup>[36]</sup>. Invasive cribriform/tubular carcinomas are characterized by the hyper-proliferation of a single type of neoplastic cells (*i.e.*, luminal

cell) only, in contrast to the dual cell types observed in ACC. Moreover, cribriform/tubular carcinomas are generally immunoreactive for ER and PR, whereas ACCs are negative for both<sup>[53]</sup>. In addition, limited evidence exists of c-Kit and/or p63 immunoreactivity in ACCs of the breast (positive for both), compared to the invasive cribriform/tubular carcinomas which are negative for both markers<sup>[40]</sup>. In collagenous spherulosis, collagenous spherules are irregular, mostly observed at the periphery of the lesions, and no mucosubstance is detected within lumina. Immunohistochemically, ACCs are c-Kit (+), calponin (-), and smooth muscle myosin (-), whereas collagenous spherulosis lesions are c-Kit (-), calponin (+), and smooth muscle myosin (+), which may help to differentiate between these two types of lesions<sup>[54]</sup>. The differential diagnosis of the solid (basaloid) variant of ACC includes small cell carcinoma (neuroendocrine carcinoma), solid papillary carcinoma, metaplastic carcinoma, and malignant lymphoma<sup>[37]</sup>. Although an extensive and careful search for a more typical cribriform pattern of ACC should be performed, immunohistochemistry can also be helpful to distinguish these tumors from ACC.

## MOLECULAR GENETIC FEATURES

Microarray-based gene expression profiling studies have been performed in common types of breast cancer, such as the invasive ductal and lobular carcinomas<sup>[7-9]</sup>. However, most of these studies did not focus on special types of breast cancer, and consequently, there is only limited transcriptomic data on the ACC features. A recent molecular subtype analysis using a single sample predictor (*i.e.*, centroid) performed on 4 ACCs revealed that two of the samples were classified as basal-like, while the other two

were shown to exhibit the normal breast-like phenotype. Based on this divergence in the results, they could be an artifact of sample representation, perhaps caused by the contamination with normal tissues<sup>[55]</sup>. In fact, molecular subtype assignment following hierarchical clustering showed that all four ACCs consistently displayed a basal-like phenotype, and all of them clustered with one of the five subgroups of the triple-negative breast cancers. In another study that utilized the immunohistochemical staining analysis and microarray-based gene expression profiling for a series of 113 tumors that belonged to 11 special histologic types of breast cancer (including 4 ACCs), Weigelt *et al.*<sup>[43]</sup> reported that the ACC, medullary carcinoma, and metaplastic carcinoma were highly similar in their immunohistochemical and gene expression profile. However, ACCs did not intermingle with medullary and metaplastic carcinomas in the hierarchical clustering, but formed a separate group. Another study, an array-based CGH analysis of 59 breast cancers that belonged to 10 special histologic special types established that while medullary and metaplastic carcinomas displayed complex genomes, ACCs consistently exhibited simpler patterns of gene copy number aberrations<sup>[56]</sup>. In line with these results, a recent CGH analysis study revealed that ACC of the breast manifested significantly lower frequencies of genetic instability and lower copy number alterations than the histologic grade-matched basal-like and invasive ductal carcinomas of NST<sup>[29]</sup>. At the genomic level, ACC is substantially different from the other basal-like breast cancers. Studies show that it rarely harbors genomic aberrations associated with basal-like invasive ductal carcinomas of NST, such as gains of 1q, 6p, 8q, and 10p, and losses of 4p, 5q, and 10q<sup>[29,57,58]</sup>. Furthermore, aneuploidy is reported in fewer than 10% of cases with ACC of the breast<sup>[5]</sup>. Together, these findings illustrate the heterogeneity of triple-negative, basal-like breast cancers. Although the majority of these tumors are high grade cancers with high levels of genetic instability and an aggressive clinical course (*e.g.*, grade 3 invasive ductal carcinoma of NST, medullary carcinoma, and metaplastic carcinoma), there is also a subgroup of low grade tumors with low frequencies of genetic instability and an indolent clinical behavior (*e.g.*, ACC and secretory carcinoma)<sup>[10,41,43,59-61]</sup>. Thus, we emphasize that based solely on molecular subtyping and without proper histologic classification, ACCs, which have an indolent clinical behavior, would be classified as triple-negative, clinically aggressive tumors. Therefore, information regarding the histologic type of triple-negative breast cancers should be included in histopathology reports and taken into account for clinical decision-making.

Although studies using next-generation sequencing (NGS) for whole exome or microRNA expression profiling for ACC of the salivary gland have been recently reported<sup>[62-65]</sup>, there have been few studies using NGS for ACC of the breast. In one study utilizing microRNA expression profiling for two cases each of ACC of the salivary gland and breast, Kiss *et al.*<sup>[65]</sup> reported that the let-7b was overexpressed in ACC of the salivary gland, while

decreased in ACC of the breast. In addition, the miR-24 was decreased in salivary gland-derived but overexpressed in breast-derived adenoid cystic carcinomas.

Similar to ACCs of the salivary gland, ACCs of the breast are characterized by the t(6;9) (q22-23; p23-24) chromosomal translocation, which generates fusion transcripts involving the oncogene *MYB* and the transcription factor gene *NFIB*. Several previous studies reported that this chromosomal translocation is present in over 90% of ACC cases and is a key ACC oncogenic mechanism<sup>[29,66,67]</sup>. The myeloblastoma (*MYB*)- nuclear factor I/B (*NFIB*) fusion protein retains the DNA-binding and transactivation domains of a wild-type *MYB*, and is therefore expected to activate *MYB* target genes<sup>[29,66]</sup>. *MYB* is a leucine zipper transcription factor that plays an important role in the control of cell proliferation, apoptosis, and differentiation<sup>[68,69]</sup>, while its target genes include *BCL2* and *GRP78/BIP*, which are essential for cell survival<sup>[70]</sup>. *MYB* is a direct target of EG signaling and is highly expressed not only in ACCs, but also in cell lines of ER-positive breast cancers<sup>[71,72]</sup>. Recently, one study reported that 67% (8/12 cases) of dermal cylindroma displayed the t(6;9) and *MYB-NFIB* fusion transcripts and that the composition of these chimeric transcripts was identical to that seen in ACC<sup>[73]</sup>.

Approximately 7% of breast cancer cases are related to hereditary conditions and caused by mutations in the *BRCA1* and *BRCA2* genes<sup>[3]</sup>. Although medullary and metaplastic breast carcinomas, with which ACC shares immunohistochemical and molecular findings, show a frequent promotor methylation of *BRCA1* gene, ACC of the breast usually retains normal *BRCA1* gene function<sup>[2,29]</sup>. To our knowledge, *BRCA2* gene status has not been investigated in ACCs of the breast.

ACCs of the breast typically do not express the full-length ER- $\alpha$  (ER- $\alpha$ 66) and PR<sup>[11,14,39-42]</sup>. However, several studies have shown that the ACC, apocrine carcinoma, and triple-negative breast cancer of NST exhibited a frequent membranous/cytoplasmic immunoreactivity for ER- $\alpha$ 36, a novel ER- $\alpha$ 66 splice variant implicated in membrane-initiated estrogen signaling<sup>[74-76]</sup>. In the experimental cell models of breast cancer, ER- $\alpha$ 36 was shown to transduce the membrane-initiated steroid signaling cascade, and served as a dominant-negative modulator of ER- $\alpha$ 66 mediated transcription activity<sup>[75]</sup>. In addition, ER- $\alpha$ 36 was reported to be related to non-genomic ER activities, in which activation of the mitogen-activated protein kinase (MAPK/ERK) signaling pathway plays a major role<sup>[75]</sup>. The MAPK/ERK signaling pathway is activated in response to antiestrogens (*e.g.*, tamoxifen), indicating a subset of ER- $\alpha$ 66 (-)/ER- $\alpha$ 36 (+) breast carcinomas might still respond to antiestrogen based therapy<sup>[74,75]</sup>. Finally, ER- $\alpha$ 36 protein closely interacts with EGFR protein, which is commonly expressed in ACC and triple-negative breast cancers<sup>[75]</sup>. Some investigators have reported that ACCs of the breast frequently overexpress EGFR protein in the absence of underlying EGFR gene alterations<sup>[19,29]</sup>.

Cancer stem cells have been reported to be associ-

ated with tumor initiation, progression, survival, and resistance to therapy<sup>[77]</sup>. However, the cancer stem cell field is still fairly controversial and stem cell markers have not been fully elucidated. In the majority of studies, breast cancer cells with a CD44 (+)/CD24 (-) phenotype have been proposed to have tumor-initiating properties with stem cell-like features<sup>[78]</sup>, and Defaud-Hénon *et al*<sup>[18]</sup> recently reported that a characteristic CD44 (+)/CD24 (-) phenotype is commonly observed in the ACC of the breast. On the other hand, frequent overexpression of c-Kit and EGFR proteins was observed in undifferentiated carcinomas with stem cell-like features<sup>[79]</sup>. Although several studies illustrated that a consistent c-Kit protein expression was detected in most ACCs<sup>[29,40-43]</sup>, underlying *KIT* gene alterations, such as gene mutations, have not been previously detected<sup>[80]</sup>. Finally, SOX10 transcription factor appears to support stem-like properties in normal tissues and cancer cells<sup>[81]</sup>. Recently, Ivanov *et al*<sup>[82]</sup> described SOX10 as a novel diagnostic marker for ACCs of the salivary gland and breast basal-like carcinomas, indicating that SOX10 expression might be worth examining in ACCs of the breast.

Although triple-negative NST breast cancers usually have high proliferative activity, ACC of the breast exhibits a low proliferation rate using standard Ki-67 labeling index<sup>[29,83]</sup>. Interestingly, their typical proliferation rate is even lower than that of low-grade conventional breast carcinomas<sup>[84]</sup>. Mastropasqua *et al*<sup>[40]</sup> suggested that proliferative indices showed greater values in high-grade ACCs when compared to low-grade lesions. However, another study reported that the proliferative activity is not associated with the outcome of ACC patients with ACC<sup>[38]</sup>. In addition to low Ki-67 labeling index, ACCs of the breast, including high-grade solid-basaloid lesions, also show low p53 protein expression<sup>[29,39,83]</sup>. Trendell-Smith *et al*<sup>[53]</sup> described a slightly higher p53 protein expression in ACC than that in invasive cribriform carcinoma.

Finally there are several recent studies that identified potential breast ACC biomarkers. Insulin-like growth factor-II mRNA-binding protein 3 (IMP3) is an oncofetal protein and a component of the insulin-like growth factor-II pathway. Studies indicate that it could serve as a biomarker for basal-like breast carcinomas<sup>[84-87]</sup>, and a recent report showed that the IMP3 is commonly overexpressed in ACCs of the breast<sup>[88]</sup>. In another report, the molecular genetic analysis of a primary ACC of the breast and its renal metastasis revealed *PTEN* and *PIK3CA* gene mutations<sup>[89]</sup>.

## PROGNOSIS AND TREATMENT

A striking feature of ACC of the breast, which is in stark contrast with other triple-negative, basal-like breast cancers and the ACC of the salivary gland, is its excellent prognosis. As shown in Table 1, the 10-year survival rate is 90%-100%, and lymph node metastasis is rare, as well as distant metastases, which affect mainly visceral organs<sup>[11,14-19,90]</sup>. Based on its indolent clinical course and

favorable outcome, ACC of the breast is generally cured by breast-conserving surgery, such as wide excision or quadrantectomy with or without radiotherapy<sup>[11,17,91]</sup>. Mastectomy is recommended for invasive lesions when a cosmetically satisfactory excision is not possible, especially when the tumor has a high-grade pattern<sup>[4,36,92]</sup>. A recent study of a large patient cohort reported a considerable benefit of adjuvant radiotherapy on overall and disease-specific survival in patients with ACC<sup>[15]</sup>. Moreover, because a high rate of positive surgical margins has been detected following breast conserving surgery, adjuvant radiotherapy may be beneficial<sup>[93]</sup>. Furthermore, while some clinicians recommend systemic adjuvant chemotherapy for patients with high-grade lesions or axillary lymph node/distant metastasis<sup>[36]</sup>, its role in breast ACC patients remains controversial.

When patients with ACC demonstrate local recurrence or distant metastases, a prolonged and indolent clinical course is still likely<sup>[94-97]</sup>. However, long-term follow-up is recommended, since their long clinical course carries a risk of secondary malignancies<sup>[98,99]</sup>, and the risk of distant metastases increases with time<sup>[100]</sup>.

As treatment of cancer enters a new stage with the development of targeted therapies, the common *MYB-NFIB* fusion gene may provide new therapeutic avenues for the management of advanced ACC of the breast. Consequently, further functional studies investigating the biological consequences of the *MYB* gene of function due to the *MYB-NFIB* fusion are needed. Gene silencing experiments are also necessary to demonstrate that *MYB* expression is required for the survival of cancer cells with genetically activated *MYB*. Finally, the functional role of the ER- $\alpha$ 36 variant in ACC merits further research as experimental evidence in triple-negative breast cancer cell lines suggests that breast cancer cells with ER- $\alpha$ 66 (-)/ER- $\alpha$ 36 (+) phenotype might still be responsive to antiestrogens<sup>[72,73]</sup>.

## HOUSTON METHODIST EXPERIENCE OF ACC OF THE BREAST

A search of the electronic data base at Houston Methodist Hospital from 2004 to 2010 yielded five cases of ACC of the breast. The clinicopathologic and follow-up status of these five patients are summarized in Table 3. The five female patients ranged from 48 to 76 years in age, with a mean age of 60 years. All tumors had distinct morphologic features of classic ACC: histologic grade 1 with cribriform, trabecular or glandular architectural patterns, and basement membrane deposition. No cases of grade II and III tumors were identified. Perineural invasion was identified in one case. Lymphovascular invasion was not seen in any of the cases. An associated adenomyoepithelioma was observed in one case. All patients received lumpectomy and two of these patients had axillary lymph node dissections, with no nodal metastasis found. No patients received adjuvant chemotherapy or radiotherapy. Pulmonary metastasis developed in one case (case 2)



seven years after the initial diagnosis. All of the tumors, including the pulmonary metastatic lesion in case 2, were ER/PR negative and did not express Her2. No synchronous/metachronous in-situ carcinoma, invasive ductal/lobular carcinoma, or microglandular adenosis was reported in any of the cases. Four patients without metastasis were alive and showed no evidence of disease for an average (follow-up) of 45.3 mo (range 12-90 mo). The last patient (case 2) who was diagnosed with pulmonary metastasis is alive with disease at 85 mo (one month after metastasis was detected).

## CONCLUSION

The correct classification of the histological special types of breast cancer is not just an academic exercise, as it has both prognostic and predictive implications. Although the majority of triple-negative, basal-like breast carcinomas are high-grade tumors, ACC is a subgroup of low-grade tumors with an indolent clinical behavior that also displays a triple-negative, basal-like phenotype. Because of its low incidence, there have been only few comprehensive studies of ACC of the breast, which is one of the major limitations of this review. However, this review of recent updates, including certain molecular genetic features in breast ACC, herein will hopefully serve as a prognostic and treatment guide for surgical pathologists, breast surgeons, and oncologists, and lead to the development of more specific, personalized therapies for this rare tumor subtype.

## REFERENCES

- 1 **Schnitt SJ**, Collins LC. Biopsy interpretation of the breast. Philadelphia: Lippincott Williams & Wilkins, 2009
- 2 **Badve S**, Dabbs DJ, Schnitt SJ, Baehner FL, Decker T, Eusebi V, Fox SB, Ichihara S, Jacquemier J, Lakhani SR, Palacios J, Rakha EA, Richardson AL, Schmitt FC, Tan PH, Tse GM, Weigelt B, Ellis IO, Reis-Filho JS. Basal-like and triple-negative breast cancers: a critical review with an emphasis on the implications for pathologists and oncologists. *Mod Pathol* 2011; **24**: 157-167 [PMID: 21076464 DOI: 10.1038/modpathol.2010.200]
- 3 **Lakhani SR**, Ellis LO, Schnitt SJ, Tan PH, van de Vijver MJ. World Health Organization Classification of tumours of the breast, 4th ed. Lyon: IARC Press, 2012
- 4 **Ro JY**, Silva EG, Gallager HS. Adenoid cystic carcinoma of the breast. *Hum Pathol* 1987; **18**: 1276-1281 [PMID: 2824330 DOI: 10.1016/S0046-8177(87)80413-6]
- 5 **Arpino G**, Clark GM, Mohsin S, Bardou VJ, Elledge RM. Adenoid cystic carcinoma of the breast: molecular markers, treatment, and clinical outcome. *Cancer* 2002; **94**: 2119-2127 [PMID: 12001107 DOI: 10.1002/cncr.10455]
- 6 **Wells CA**, Nicoll S, Ferguson DJ. Adenoid cystic carcinoma of the breast: a case with axillary lymph node metastasis. *Histopathology* 1986; **10**: 415-424 [PMID: 3011635 DOI: 10.1111/j.1365-2559.1986.tb02494.x]
- 7 **Perou CM**, Sørlie T, Eisen MB, van de Rijn M, Jeffrey SS, Rees CA, Pollack JR, Ross DT, Johnsen H, Akslen LA, Fluge O, Pergamenschikov A, Williams C, Zhu SX, Lønning PE, Børresen-Dale AL, Brown PO, Botstein D. Molecular portraits of human breast tumours. *Nature* 2000; **406**: 747-752 [PMID: 10963602 DOI: 10.1038/35021093]
- 8 **Sørlie T**, Perou CM, Tibshirani R, Aas T, Geisler S, Johnsen H, Hastie T, Eisen MB, van de Rijn M, Jeffrey SS, Thorsen T, Quist H, Matese JC, Brown PO, Botstein D, Lønning PE, Børresen-Dale AL. Gene expression patterns of breast carcinomas distinguish tumor subclasses with clinical implications. *Proc Natl Acad Sci USA* 2001; **98**: 10869-10874 [PMID: 11553815 DOI: 10.1073/pnas.191367098]
- 9 **Sørlie T**, Tibshirani R, Parker J, Hastie T, Marron JS, Nobel A, Deng S, Johnsen H, Pesich R, Geisler S, Demeter J, Perou CM, Lønning PE, Brown PO, Børresen-Dale AL, Botstein D. Repeated observation of breast tumor subtypes in independent gene expression data sets. *Proc Natl Acad Sci USA* 2003; **100**: 8418-8423 [PMID: 12829800 DOI: 10.1073/pnas.0932692100]
- 10 **Rakha EA**, Elsheikh SE, Aleskandarany MA, Habashi HO, Green AR, Powe DG, El-Sayed ME, Benhasouna A, Brunet JS, Akslen LA, Evans AJ, Blamey R, Reis-Filho JS, Foulkes WD, Ellis IO. Triple-negative breast cancer: distinguishing between basal and nonbasal subtypes. *Clin Cancer Res* 2009; **15**: 2302-2310 [PMID: 19318481 DOI: 10.1158/1078-0432.CCR-08-2132]
- 11 **Ghabach B**, Anderson WF, Curtis RE, Huycke MM, Lavigne JA, Doros GM. Adenoid cystic carcinoma of the breast in the United States (1977 to 2006): a population-based cohort study. *Breast Cancer Res* 2010; **12**: R54 [PMID: 20653964 DOI: 10.1186/bcr2613]
- 12 **Rosen PP**. Adenoid cystic carcinoma of the breast. A morphologically heterogeneous neoplasm. *Pathol Annu* 1989; **24** Pt 2: 237-254 [PMID: 2549491]
- 13 **Glazebrook KN**, Reynolds C, Smith RL, Gimenez EI, Boughey JC. Adenoid cystic carcinoma of the breast. *AJR Am J Roentgenol* 2010; **194**: 1391-1396 [PMID: 20410430 DOI: 10.2214/AJR.09.3545]
- 14 **Kulkarni N**, Pezzi CM, Greif JM, Suzanne Klimberg V, Bailey L, Korourian S, Zuraek M. Rare breast cancer: 933 adenoid cystic carcinomas from the National Cancer Data Base. *Ann Surg Oncol* 2013; **20**: 2236-2241 [PMID: 23456318 DOI: 10.1245/s10434-013-2911-z]
- 15 **Coates JM**, Martinez SR, Bold RJ, Chen SL. Adjuvant radiation therapy is associated with improved survival for adenoid cystic carcinoma of the breast. *J Surg Oncol* 2010; **102**: 342-347 [PMID: 20589709 DOI: 10.1002/jso.21638]
- 16 **Thompson K**, Grabowski J, Saltzstein SL, Sadler GR, Blair SL. Adenoid cystic breast carcinoma: is axillary staging necessary in all cases? Results from the California Cancer Registry. *Breast J* 2011; **17**: 485-489 [PMID: 21790841 DOI: 10.1111/j.1524-4741.2011.01117.x]
- 17 **Khanfir K**, Kallel A, Villette S, Belkacemi Y, Vautravers C, Nguyen T, Miller R, Li YX, Taghian AG, Boersma L, Poortmans P, Goldberg H, Veas H, Senkus E, Igdem S, Ozsahin M, Jeanneret Sozzi W. Management of adenoid cystic carcinoma of the breast: a Rare Cancer Network study. *Int J Radiat Oncol Biol Phys* 2012; **82**: 2118-2124 [PMID: 21570212 DOI: 10.1016/j.ijrobp.2010.12.008]
- 18 **Defaud-Hénon F**, Tunon-de-Lara C, Fournier M, Marty M, Velasco V, de Mascarel I, MacGrogan G. Adenoid cystic carcinoma of the breast: clinical, histological and immunohistochemical characterization. *Ann Pathol* 2010; **30**: 7-16 [PMID: 20223349 DOI: 10.1016/j.annpat.2010.01.003]
- 19 **Vranic S**, Frkovic-Grazio S, Lamovec J, Serdarevic F, Gurjeva O, Palazzo J, Bilalovic N, Lee LM, Gatalica Z. Adenoid cystic carcinomas of the breast have low Topo IIa expression but frequently overexpress EGFR protein without EGFR gene amplification. *Hum Pathol* 2010; **41**: 1617-1623 [PMID: 20688355 DOI: 10.1016/j.humpath.2010.04.013]
- 20 **Kim M**, Lee DW, Im J, Suh KJ, Keam B, Moon HG, Im SA, Han W, Park IA, Noh DY. Adenoid cystic carcinoma of the breast: a case series of six patients and literature review. *Cancer Res Treat* 2014; **46**: 93-97 [PMID: 24520228 DOI: 10.4143/crt.2014.46.1.93]
- 21 **Miliauskas JR**, Leong AS. Adenoid cystic carcinoma in a juvenile male breast. *Pathology* 1991; **23**: 298-301 [PMID: 1664513]



- 22 **Yoo SJ**, Lee DS, Oh HS, Kim HJ, Kim MH, Ahn YC, Kang GH, Eom DW, Cha CH, Ahn HJ. Male breast adenoid cystic carcinoma. *Case Rep Oncol* 2013; **6**: 514-519 [PMID: 24403896 DOI: 10.1159/000356062]
- 23 **Azzopardi JG**. Problems in breast pathology. London: Saunders Company, 1979
- 24 **McClenathan JH**, de la Roza G. Adenoid cystic breast cancer. *Am J Surg* 2002; **183**: 646-649 [PMID: 12095593 DOI: 10.1016/S0002-9610(02)00858-9]
- 25 **Sheen-Chen SM**, Eng HL, Chen WJ, Cheng YF, Ko SF. Adenoid cystic carcinoma of the breast: truly uncommon or easily overlooked? *Anticancer Res* 2005; **25**: 455-458 [PMID: 15816611]
- 26 **Alis H**, Yigitbas H, Kapan S, Kalayci M, Kilic G, Aygun E. Multifocal adenoid cystic carcinoma of the breast: an unusual presentation. *Can J Surg* 2008; **51**: E36-E37 [PMID: 18377738]
- 27 **Franceschini G**, Terribile D, Scafetta I, Magno S, Fabbri C, Chiesa F, Di Leone A, Moschella F, Scaldaferrì A, Fragoni S, Vellone V, Mulè A, Masetti R. Conservative treatment of a rare case of multifocal adenoid cystic carcinoma of the breast: case report and literature review. *Med Sci Monit* 2010; **16**: CS33-CS39 [PMID: 20190690]
- 28 **Tavassoli FA**, Eusebi V. Carcinomas of low-grade malignancy. Adenoid cystic carcinoma. In: Tavassoli FA, Eusebi V. Tumors of the mammary gland. AFIP atlas of tumor pathology. 4th series; fasc. 10. Washington, D.C, USA: American Registry of Pathology in collaboration with the Armed Forces Institute of Pathology, 2009: 183-187
- 29 **Wetterskog D**, Lopez-Garcia MA, Lambros MB, A'Hern R, Geyer FC, Milanezi F, Cabral MC, Natrajan R, Gauthier A, Shiu KK, Orr N, Shousha S, Gatalica Z, Mackay A, Palacios J, Reis-Filho JS, Weigelt B. Adenoid cystic carcinomas constitute a genomically distinct subgroup of triple-negative and basal-like breast cancers. *J Pathol* 2012; **226**: 84-96 [PMID: 22015727 DOI: 10.1002/path.2974]
- 30 **Marchiò C**, Weigelt B, Reis-Filho JS. Adenoid cystic carcinomas of the breast and salivary glands (or 'The strange case of Dr Jekyll and Mr Hyde' of exocrine gland carcinomas). *J Clin Pathol* 2010; **63**: 220-228 [PMID: 20203221 DOI: 10.1136/jcp.2009.073908]
- 31 **Franzese C**, Zei G, Masoni T, Cecchini S, Monteleone E, Livi L, Biti G. Adenoid cystic carcinoma of the breast. The double face of an exocrine gland carcinoma. *Strahlenther Onkol* 2013; **189**: 1049-1050 [PMID: 24158637 DOI: 10.1007/s00066-013-0461-8]
- 32 **Reyes C**, Jorda M, Gomez-Fernández C. Salivary gland-like tumors of the breast express basal-type immunohistochemical markers. *Appl Immunohistochem Mol Morphol* 2013; **21**: 283-286 [PMID: 22935826 DOI: 10.1097/PAL.0b013e31826a277e]
- 33 **Kasami M**, Olson SJ, Simpson JF, Page DL. Maintenance of polarity and a dual cell population in adenoid cystic carcinoma of the breast: an immunohistochemical study. *Histopathology* 1998; **32**: 232-238 [PMID: 9568508 DOI: 10.1046/j.1365-2559.1998.00383.x]
- 34 **Lamovec J**, Us-Krasovec M, Zidar A, Kljun A. Adenoid cystic carcinoma of the breast: a histologic, cytologic, and immunohistochemical study. *Semin Diagn Pathol* 1989; **6**: 153-164 [PMID: 2474845]
- 35 **Tavassoli FA**, Norris HJ. Mammary adenoid cystic carcinoma with sebaceous differentiation. A morphologic study of the cell types. *Arch Pathol Lab Med* 1986; **110**: 1045-1053 [PMID: 3022669]
- 36 **Rosen PP**. Adenoid cystic carcinoma. In: Rosen PP. Rosen's breast pathology, third edition. Philadelphia: Lippincott Williams & Wilkins, 2009: 590-604
- 37 **Shin SJ**, Rosen PP. Solid variant of mammary adenoid cystic carcinoma with basaloid features: a study of nine cases. *Am J Surg Pathol* 2002; **26**: 413-420 [PMID: 11914618 DOI: 10.1097/0000478-200204000-00002]
- 38 **Kleer CG**, Oberman HA. Adenoid cystic carcinoma of the breast: value of histologic grading and proliferative activity. *Am J Surg Pathol* 1998; **22**: 569-575 [PMID: 9591727 DOI: 10.1097/0000478-199805000-00008]
- 39 **Edge SB**, Byrd DR. AJCC cancer staging manual. 7th ed. Berlin: Springer, 2010
- 40 **Mastropasqua MG**, Maiorano E, Pruneri G, Orvieto E, Mazzarol G, Vento AR, Viale G. Immunoreactivity for c-kit and p63 as an adjunct in the diagnosis of adenoid cystic carcinoma of the breast. *Mod Pathol* 2005; **18**: 1277-1282 [PMID: 15846389 DOI: 10.1038/modpathol.3800423]
- 41 **Azoulay S**, Laé M, Fréneaux P, Merle S, Al Ghuzlan A, Chnecker C, Rosty C, Klijanienko J, Sigal-Zafrani B, Salmon R, Fourquet A, Sastre-Garau X, Vincent-Salomon A. KIT is highly expressed in adenoid cystic carcinoma of the breast, a basal-like carcinoma associated with a favorable outcome. *Mod Pathol* 2005; **18**: 1623-1631 [PMID: 16258515]
- 42 **Crisi GM**, Marconi SA, Makari-Judson G, Goulart RA. Expression of c-kit in adenoid cystic carcinoma of the breast. *Am J Clin Pathol* 2005; **124**: 733-739 [PMID: 16203286 DOI: 10.1309/61MVENEK5EJ7J7KGF]
- 43 **Weigelt B**, Horlings HM, Kreike B, Hayes MM, Hauptmann M, Wessels LF, de Jong D, Van de Vijver MJ, Van't Veer LJ, Peterse JL. Refinement of breast cancer classification by molecular characterization of histological special types. *J Pathol* 2008; **216**: 141-150 [PMID: 18720457 DOI: 10.1002/path.2407]
- 44 **Acs G**, Simpson JF, Bleiweiss JJ, Hugh J, Reynolds C, Olson S, Page DL. Microglandular adenosis with transition into adenoid cystic carcinoma of the breast. *Am J Surg Pathol* 2003; **27**: 1052-1060 [PMID: 12883237]
- 45 **Da Silva L**, Buck L, Simpson PT, Reid L, McCallum N, Madigan BJ, Lakhani SR. Molecular and morphological analysis of adenoid cystic carcinoma of the breast with synchronous tubular adenosis. *Virchows Arch* 2009; **454**: 107-114 [PMID: 19031084 DOI: 10.1007/s00428-008-0700-z]
- 46 **Van Dorpe J**, De Pauw A, Moerman P. Adenoid cystic carcinoma arising in an adenomyoepithelioma of the breast. *Virchows Arch* 1998; **432**: 119-122 [PMID: 9504855 DOI: 10.1007/s004280050144]
- 47 **Canyilmaz E**, Uslu GH, Memiş Y, Bahat Z, Yildiz K, Yoney A. Adenoid cystic carcinoma of the breast: A case report and literature review. *Oncol Lett* 2014; **7**: 1599-1601 [PMID: 24765184]
- 48 **Blanco M**, Egozi L, Lubin D, Poppiti R. Adenoid cystic carcinoma arising in a fibroadenoma. *Ann Diagn Pathol* 2005; **9**: 157-159 [PMID: 15944959 DOI: 10.1016/j.anndiagpath.2005.02.008]
- 49 **Righi A**, Lenzi M, Morandi L, Flamminio F, De Biase D, Farnedi A, Foschini MP. Adenoid cystic carcinoma of the breast associated with invasive duct carcinoma: a case report. *Int J Surg Pathol* 2011; **19**: 230-234 [PMID: 19233861 DOI: 10.1177/1066896909332321]
- 50 **Kontos M**, Karles D, Petrou A, Alexandrou PT. Adenoid cystic carcinoma intermingled with ductal carcinoma of the breast: a case report and review of the literature. *J Med Case Rep* 2011; **5**: 437 [PMID: 21896177 DOI: 10.1186/1752-1947-5-437]
- 51 **Resetskova E**, Albarracín C, Sneige N. Collagenous spherulosis of breast: morphologic study of 59 cases and review of the literature. *Am J Surg Pathol* 2006; **30**: 20-27 [PMID: 16330938 DOI: 10.1097/01.pas.0000179237.91515.81]
- 52 **Ogata K**, Sakamoto G, Sakurai T. Adenoid cystic carcinoma with collagenous spherulosis-like structures in the breast: report of a case. *Pathol Int* 2004; **54**: 332-336 [PMID: 15086837 DOI: 10.1111/j.1440-1827.2004.01627.x]
- 53 **Trendell-Smith NJ**, Peston D, Shousha S. Adenoid cystic carcinoma of the breast: a tumour commonly devoid of oestrogen receptors and related proteins. *Histopathology* 1999; **35**: 241-248 [PMID: 10469216 DOI: 10.1046/j.1365-2559.1999.00722.x]
- 54 **Rabban JT**, Swain RS, Zaloudek CJ, Chase DR, Chen YY. Immunophenotypic overlap between adenoid cystic carcinoma and ductal carcinoma in situ of the breast.

- noma and collagenous spherulosis of the breast: potential diagnostic pitfalls using myoepithelial markers. *Mod Pathol* 2006; **19**: 1351-1357 [PMID: 16810311 DOI: 10.1038/modpathol.3800658]
- 55 **Kreike B**, van Kouwenhove M, Horlings H, Weigelt B, Peterse H, Bartelink H, van de Vijver MJ. Gene expression profiling and histopathological characterization of triple-negative/basal-like breast carcinomas. *Breast Cancer Res* 2007; **9**: R65 [PMID: 17910759 DOI: 10.1186/bcr1771]
- 56 **Horlings HM**, Weigelt B, Anderson EM, Lambros MB, Mackay A, Natrajan R, Ng CK, Geyer FC, van de Vijver MJ, Reis-Filho JS. Genomic profiling of histological special types of breast cancer. *Breast Cancer Res Treat* 2013; **142**: 257-269 [PMID: 24162157 DOI: 10.1007/s10549-013-2740-6]
- 57 **Natrajan R**, Lambros MB, Rodríguez-Pinilla SM, Moreno-Bueno G, Tan DS, Marchió C, Vatcheva R, Rayter S, Mahler-Araujo B, Fulford LG, Hungermann D, Mackay A, Grigoriadis A, Fenwick K, Tamber N, Hardisson D, Tutt A, Palacios J, Lord CJ, Buerger H, Ashworth A, Reis-Filho JS. Tiling path genomic profiling of grade 3 invasive ductal breast cancers. *Clin Cancer Res* 2009; **15**: 2711-2722 [PMID: 19318498 DOI: 10.1158/1078-0432.CCR-08-1878]
- 58 **Natrajan R**, Lambros MB, Geyer FC, Marchio C, Tan DS, Vatcheva R, Shiu KK, Hungermann D, Rodríguez-Pinilla SM, Palacios J, Ashworth A, Buerger H, Reis-Filho JS. Loss of 16q in high grade breast cancer is associated with estrogen receptor status: Evidence for progression in tumors with a luminal phenotype? *Genes Chromosomes Cancer* 2009; **48**: 351-365 [PMID: 19156836 DOI: 10.1002/gcc.20646]
- 59 **Reis-Filho JS**, Milanezi F, Steele D, Savage K, Simpson PT, Nesland JM, Pereira EM, Lakhani SR, Schmitt FC. Metaplastic breast carcinomas are basal-like tumours. *Histopathology* 2006; **49**: 10-21 [PMID: 16842242 DOI: 10.1111/j.1365-2559.2006.02467.x]
- 60 **Laé M**, Fréneaux P, Sastre-Garau X, Chouchane O, Sigal-Zafarani B, Vincent-Salomon A. Secretory breast carcinomas with ETV6-NTRK3 fusion gene belong to the basal-like carcinoma spectrum. *Mod Pathol* 2009; **22**: 291-298 [PMID: 19011601 DOI: 10.1038/modpathol.2008.184]
- 61 **Weigelt B**, Kreike B, Reis-Filho JS. Metaplastic breast carcinomas are basal-like breast cancers: a genomic profiling analysis. *Breast Cancer Res Treat* 2009; **117**: 273-280 [PMID: 18815879 DOI: 10.1007/s10549-008-0197-9]
- 62 **Ross JS**, Wang K, Rand JV, Sheehan CE, Jennings TA, Al-Rohil RN, Otto GA, Curran JC, Palmer G, Downing SR, Yelensky R, Lipson D, Balasubramanian S, Garcia L, Mahoney K, Ali SM, Miller VA, Stephens PJ. Comprehensive genomic profiling of relapsed and metastatic adenoid cystic carcinomas by next-generation sequencing reveals potential new routes to targeted therapies. *Am J Surg Pathol* 2014; **38**: 235-238 [PMID: 24418857 DOI: 10.1097/PAS.0000000000000102]
- 63 **Stephens PJ**, Davies HR, Mitani Y, Van Loo P, Shlien A, Tarpey PS, Papaemmanuil E, Cheverton A, Bignell GR, Butler AP, Gamble J, Gamble S, Hardy C, Hinton J, Jia M, Jayakumar A, Jones D, Latimer C, McLaren S, McBride DJ, Menzies A, Mudie L, Maddison M, Raine K, Nik-Zainal S, O'Meara S, Teague JW, Varela I, Wedge DC, Whitmore I, Lippman SM, McDermott U, Stratton MR, Campbell PJ, El-Naggar AK, Futreal PA. Whole exome sequencing of adenoid cystic carcinoma. *J Clin Invest* 2013; **123**: 2965-2968 [PMID: 23778141]
- 64 **Cho WC**. MicroRNAs: potential biomarkers for cancer diagnosis, prognosis and targets for therapy. *Int J Biochem Cell Biol* 2010; **42**: 1273-1281 [PMID: 20026422 DOI: 10.1016/j.biocel.2009.12.014]
- 65 **Kiss O**, Tóké AM, Spisák S, Szilágyi A, Lippai N, Szász AM, Kulka J. MicroRNA-profiling in breast- and salivary gland-derived adenoid cystic carcinomas. *Orv Hetil* 2013; **154**: 963-968 [PMID: 23774803 DOI: 10.1556/OH.2013.29643]
- 66 **Brill LB**, Kanner WA, Fehr A, Andrén Y, Moskaluk CA, Löning T, Stenman G, Frierson HF. Analysis of MYB expression and MYB-NFIB gene fusions in adenoid cystic carcinoma and other salivary neoplasms. *Mod Pathol* 2011; **24**: 1169-1176 [PMID: 21572406 DOI: 10.1038/modpathol.2011.86]
- 67 **Persson M**, Andrén Y, Mark J, Horlings HM, Persson F, Stenman G. Recurrent fusion of MYB and NFIB transcription factor genes in carcinomas of the breast and head and neck. *Proc Natl Acad Sci USA* 2009; **106**: 18740-18744 [PMID: 19841262 DOI: 10.1073/pnas.0909114106]
- 68 **Stenman G**, Andersson MK, Andrén Y. New tricks from an old oncogene: gene fusion and copy number alterations of MYB in human cancer. *Cell Cycle* 2010; **9**: 2986-2995 [PMID: 20647765 DOI: 10.4161/cc.9.15.12515]
- 69 **Ramsay RG**, Gonda TJ. MYB function in normal and cancer cells. *Nat Rev Cancer* 2008; **8**: 523-534 [PMID: 18574464 DOI: 10.1038/nrc2439]
- 70 **Miao RY**, Drabsch Y, Cross RS, Cheasley D, Carpinteri S, Pereira L, Malaterre J, Gonda TJ, Anderson RL, Ramsay RG. MYB is essential for mammary tumorigenesis. *Cancer Res* 2011; **71**: 7029-7037 [PMID: 21948968 DOI: 10.1158/0008-5472.CAN-11-1015]
- 71 **Gonda TJ**, Leo P, Ramsay RG. Estrogen and MYB in breast cancer: potential for new therapies. *Expert Opin Biol Ther* 2008; **8**: 713-717 [PMID: 18476782 DOI: 10.1517/14712598.8.6.713]
- 72 **Nicolau M**, Levine AJ, Carlsson G. Topology based data analysis identifies a subgroup of breast cancers with a unique mutational profile and excellent survival. *Proc Natl Acad Sci USA* 2011; **108**: 7265-7270 [PMID: 21482760 DOI: 10.1073/pnas.1102826108]
- 73 **Fehr A**, Kovács A, Löning T, Frierson H, van den Oord J, Stenman G. The MYB-NFIB gene fusion-a novel genetic link between adenoid cystic carcinoma and dermal cylindroma. *J Pathol* 2011; **224**: 322-327 [PMID: 21618541 DOI: 10.1002/path.2909]
- 74 **Vranic S**, Gatalica Z, Deng H, Frkovic-Grazio S, Lee LM, Gurjeva O, Wang ZY. ER-α36, a novel isoform of ER-α66, is commonly over-expressed in apocrine and adenoid cystic carcinomas of the breast. *J Clin Pathol* 2011; **64**: 54-57 [PMID: 21045236 DOI: 10.1136/jcp.2010.082776]
- 75 **Wang Z**, Zhang X, Shen P, Loggie BW, Chang Y, Deuel TF. A variant of estrogen receptor-α, hER-α36: transduction of estrogen- and antiestrogen-dependent membrane-initiated mitogenic signaling. *Proc Natl Acad Sci USA* 2006; **103**: 9063-9068 [PMID: 16754886 DOI: 10.1073/pnas.0603339103]
- 76 **Zhang XT**, Kang LG, Ding L, Vranic S, Gatalica Z, Wang ZY. A positive feedback loop of ER-α36/EGFR promotes malignant growth of ER-negative breast cancer cells. *Oncogene* 2011; **30**: 770-780 [PMID: 20935677 DOI: 10.1038/onc.2010.458]
- 77 **Weinberg RA**. The biology of cancer. New York, USA: Garland Science, Taylor & Francis Group, LLC, 2007
- 78 **Honeth G**, Bendahl PO, Ringnér M, Saal LH, Gruvberger-Saal SK, Lövgren K, Grabau D, Fernö M, Borg A, Hegardt C. The CD44+/CD24- phenotype is enriched in basal-like breast tumors. *Breast Cancer Res* 2008; **10**: R53 [PMID: 18559090 DOI: 10.1186/bcr2108]
- 79 **Tsuda H**, Tani Y, Weisenberger J, Kitada S, Hasegawa T, Murata T, Tamai S, Hirohashi S, Matsubara O, Natori T. Frequent KIT and epidermal growth factor receptor overexpressions in undifferentiated-type breast carcinomas with 'stem-cell-like' features. *Cancer Sci* 2005; **96**: 333-339 [PMID: 15958055]
- 80 **Wetterskog D**, Wilkerson PM, Rodrigues DN, Lambros MB, Fritchie K, Andersson MK, Natrajan R, Gauthier A, Di Palma S, Shousha S, Gatalica Z, Töpfer C, Vukovic V, A'Hern R, Weigelt B, Vincent-Salomon A, Stenman G, Rubin BP, Reis-Filho JS. Mutation profiling of adenoid cystic carcinomas from multiple anatomical sites identifies mutations in the RAS pathway, but no KIT mutations. *Histopathology* 2013; **62**:

- 543-550 [PMID: 23398044 DOI: 10.1111/his.12050]
- 81 **Ivanov SV**, Panaccione A, Brown B, Guo Y, Moskaluk CA, Wick MJ, Brown JL, Ivanova AV, Issaeva N, El-Naggar AK, Yarbrough WG. TrkC signaling is activated in adenoid cystic carcinoma and requires NT-3 to stimulate invasive behavior. *Oncogene* 2013; **32**: 3698-3710 [PMID: 23027130 DOI: 10.1038/onc.2012.377]
  - 82 **Ivanov SV**, Panaccione A, Nonaka D, Prasad ML, Boyd KL, Brown B, Guo Y, Sewell A, Yarbrough WG. Diagnostic SOX10 gene signatures in salivary adenoid cystic and breast basal-like carcinomas. *Br J Cancer* 2013; **109**: 444-451 [PMID: 23799842 DOI: 10.1038/bjc.2013.326]
  - 83 **Pastolero G**, Hanna W, Zbieranowski I, Kahn HJ. Proliferative activity and p53 expression in adenoid cystic carcinoma of the breast. *Mod Pathol* 1996; **9**: 215-219 [PMID: 8685217]
  - 84 **Lerma E**, Peiro G, Ramón T, Fernandez S, Martinez D, Pons C, Muñoz F, Sabate JM, Alonso C, Ojeda B, Prat J, Barnadas A. Immunohistochemical heterogeneity of breast carcinomas negative for estrogen receptors, progesterone receptors and Her2/neu (basal-like breast carcinomas). *Mod Pathol* 2007; **20**: 1200-1207 [PMID: 17885672 DOI: 10.1038/modpathol.3800961]
  - 85 **Nielsen J**, Christiansen J, Lykke-Andersen J, Johnsen AH, Wewer UM, Nielsen FC. A family of insulin-like growth factor II mRNA-binding proteins represses translation in late development. *Mol Cell Biol* 1999; **19**: 1262-1270 [PMID: 9891060]
  - 86 **Walter O**, Prasad M, Lu S, Quinlan RM, Edmiston KL, Khan A. IMP3 is a novel biomarker for triple negative invasive mammary carcinoma associated with a more aggressive phenotype. *Hum Pathol* 2009; **40**: 1528-1533 [PMID: 19695680 DOI: 10.1016/j.humpath.2009.05.005]
  - 87 **Sidoni A**, Cartaginosa F. IMP3 expression in triple-negative breast carcinoma. *Hum Pathol* 2010; **41**: 1355-1356; author reply 1356-1357 [PMID: 20708461 DOI: 10.1016/j.humpath.2010.05.004]
  - 88 **Vranic S**, Gurjeva O, Frkovic-Grazio S, Palazzo J, Tawfik O, Gatalica Z. IMP3, a proposed novel basal phenotype marker, is commonly overexpressed in adenoid cystic carcinomas but not in apocrine carcinomas of the breast. *Appl Immunohistochem Mol Morphol* 2011; **19**: 413-416 [PMID: 21436679 DOI: 10.1097/PAI.0b013e3182143399]
  - 89 **Vranic S**, Bilalovic N, Lee LM, Kruslin B, Lilleberg SL, Gatalica Z. PIK3CA and PTEN mutations in adenoid cystic carcinoma of the breast metastatic to kidney. *Hum Pathol* 2007; **38**: 1425-1431 [PMID: 17669465 DOI: 10.1016/j.humpath.2007.03.021]
  - 90 **Silva I**, Tome V, Oliveira J. Adenoid cystic carcinoma of the breast with cerebral metastasis: a clinical novelty. *BMJ Case Rep* 2011; **2011**: [PMID: 22679170 DOI: 10.1136/bcr.08.2011.4692]
  - 91 **Xue Y**, Liu X, Poplack S, Memoli VA. Adenoid cystic carcinoma of the breast in reduction mammoplasty. *Breast J* 2012; **18**: 611-613 [PMID: 23078292 DOI: 10.1111/tbj.12029]
  - 92 **Youk JH**, Kim MJ, Kim EK, Lee JY, Oh KK, Park BW. Recurrence of adenoid cystic carcinoma in the breast after lumpectomy and adjuvant therapy. *J Ultrasound Med* 2006; **25**: 921-924 [PMID: 16798905]
  - 93 **Hodgson NC**, Lytwyn A, Bacopulos S, Elavathil L. Adenoid cystic breast carcinoma: high rates of margin positivity after breast conserving surgery. *Am J Clin Oncol* 2010; **33**: 28-31 [PMID: 19730354 DOI: 10.1097/COC.0b013e31819f8fc8]
  - 94 **Wilson WB**, Spell JP. Adenoid cystic carcinoma of breast: a case with recurrence and regional metastasis. *Ann Surg* 1967; **166**: 861-864 [PMID: 6057095 DOI: 10.1097/0000658-19671100-00021]
  - 95 **Herzberg AJ**, Bossen EH, Walther PJ. Adenoid cystic carcinoma of the breast metastatic to the kidney. A clinically symptomatic lesion requiring surgical management. *Cancer* 1991; **68**: 1015-1020 [PMID: 1655210]
  - 96 **Koller M**, Ram Z, Findler G, Lipshitz M. Brain metastasis: a rare manifestation of adenoid cystic carcinoma of the breast. *Surg Neurol* 1986; **26**: 470-472 [PMID: 3020724 DOI: 10.1016/0090-3019(86)90260-0]
  - 97 **Lim SK**, Kovi J, Warner OG. Adenoid cystic carcinoma of breast with metastasis: a case report and review of the literature. *J Natl Med Assoc* 1979; **71**: 329-330 [PMID: 220431]
  - 98 **Millar BA**, Kerba M, Youngson B, Lockwood GA, Liu FF. The potential role of breast conservation surgery and adjuvant breast radiation for adenoid cystic carcinoma of the breast. *Breast Cancer Res Treat* 2004; **87**: 225-232 [PMID: 15528965 DOI: 10.1007/s10549-004-8693-z]
  - 99 **Page DL**. Adenoid cystic carcinoma of breast, a special histopathologic type with excellent prognosis. *Breast Cancer Res Treat* 2005; **93**: 189-190 [PMID: 16142443 DOI: 10.1007/s10549-005-5198-3]
  - 100 **Sinn HP**, Lehnert T, Otto HF. Adenoid cystic cancer of the breast. Case report and meta-analysis of the literature. *Chirurg* 1993; **64**: 198-202 [PMID: 8387001]

P- Reviewer: Cho W S- Editor: Gong XM L- Editor: A  
E- Editor: Wu HL





## Drug-targeting methodologies with applications: A review

Clement Kleinstreuer, Yu Feng, Emily Childress

Clement Kleinstreuer, Yu Feng, Department of Mechanical and Aerospace Engineering, North Carolina State University, Raleigh, NC 27695, United States

Emily Childress, Department of Biomedical Engineering, Mercer University, Macon, GA 31207, United States

**Author contributions:** Feng Y and Childress E conducted the literature reviews, and drafted and formatted Section 2 and Section 3, respectively; Kleinstreuer C designed and revised the manuscript and finalized the submitted version.

**Supported by** National Science Foundation, No. NSF-CBET 1232988 and ANSYS Inc. (Canonsburg, PA)

**Correspondence to:** Clement Kleinstreuer, PhD, Professor, Department of Mechanical and Aerospace Engineering, North Carolina State University, Raleigh, NC 27695, United States. [ck@ncsu.edu](mailto:ck@ncsu.edu)

Telephone: +1-919-5155261 Fax: +1-919-5157968

Received: May 28, 2014 Revised: September 16, 2014

Accepted: October 14, 2014

Published online: December 16, 2014

### Abstract

Targeted drug delivery to solid tumors is a very active research area, focusing mainly on improved drug formulation and associated best delivery methods/devices. Drug-targeting has the potential to greatly improve drug-delivery efficacy, reduce side effects, and lower the treatment costs. However, the vast majority of drug-targeting studies assume that the drug-particles are already at the target site or at least in its direct vicinity. In this review, drug-delivery methodologies, drug types and drug-delivery devices are discussed with examples in two major application areas: (1) inhaled drug-aerosol delivery into human lung-airways; and (2) intravascular drug-delivery for solid tumor targeting. The major problem addressed is how to deliver efficiently the drug-particles from the entry/infusion point to the target site. So far, most experimental results are based on animal studies. Concerning pulmonary drug delivery, the focus is on the pros and cons of three inhaler types, *i.e.*, pressurized metered dose inhaler, dry powder inhaler and nebulizer, in addition to drug-aerosol formulations. Computational fluid-particle dynamics techniques and the underlying methodology for a smart inhaler system are discussed as well.

Concerning intravascular drug-delivery for solid tumor targeting, passive and active targeting are reviewed as well as direct drug-targeting, using optimal delivery of radioactive microspheres to liver tumors as an example. The review concludes with suggestions for future work, considering both pulmonary drug targeting and direct drug delivery to solid tumors in the vascular system.

© 2014 Baishideng Publishing Group Inc. All rights reserved.

**Key words:** Targeted drug delivery; Pulmonary system; Vascular system; Types of drugs and delivery devices; Computational analysis and experimental evidence; Future work

**Core tip:** Targeted drug delivery to diseased areas or solid tumors has the great potential to significantly improve treatment efficacy, minimize side-effects, and reduce health-care cost. The major problem addressed is how to deliver efficiently the drug-particles from the entry/infusion point to the target site. Past and present developments in drug formulation and associated drug-delivery devices are discussed. Examples of optimal drug delivery to pulmonary target sites as well as targeting solid tumors in the vascular system are reviewed.

Kleinstreuer C, Feng Y, Childress E. Drug-targeting methodologies with applications: A review. *World J Clin Cases* 2014; 2(12): 742-756 Available from: URL: <http://www.wjgnet.com/2307-8960/full/v2/i12/742.htm> DOI: <http://dx.doi.org/10.12998/wjcc.v2.i12.742>

### INTRODUCTION

In light of the high cost of medicine and potentially devastating side-effects of drug treatment, targeted drug delivery is of great clinical significance. Thus, targeted drug delivery to solid tumors is a very active research area, focusing mainly on improved drug formulation and associated best delivery methods/devices. Drug-targeting has



the potential to greatly improve drug-delivery efficacy, reduce side effects, and lower treatment costs. However, the vast majority of drug-targeting studies assume that the drug-particles are already at the target site or at least in its direct vicinity.

In this review, drug-delivery methodologies, drug types and drug-delivery devices are discussed with examples in two major application areas: (1) inhaled drug-aerosol delivery into human lung-airways; and (2) intravascular drug-delivery for solid tumor targeting. The major problem addressed is how to deliver efficiently the drug-particles from the entry/infusion point to the target site. So far, most experimental results are based on animal studies.

Concerning pulmonary drug delivery, the focus is on the advantages and disadvantages of the three inhaler types, *i.e.*, pressurized metered dose, dry powder and nebulizer, in addition to drug-aerosol formulations. Computational fluid-particle dynamics techniques and the underlying methodology for a smart inhaler system (SIS) are discussed as well.

Concerning intravascular drug-delivery for solid tumor targeting, passive and active targeting are reviewed as well as direct drug-targeting, using optimal delivery of radioactive microspheres to liver tumors as an example.

The review concludes with future work for both pulmonary drug targeting and direct drug delivery to solid tumors in the vascular system.

## PULMONARY DRUG-TARGETING METHODOLOGIES

Targeted drug delivery and controlled release are current challenges in pulmonary drug delivery. Three popular drug delivery ways are per oral (pill swallowing), intravenous (drug injection through the vein), and inhalation (breathing into the human lung).

Pulmonary drug delivery therapies, ranging from the treatment of asthma and chronic obstructive pulmonary diseases (COPD) to lung tumors and systemic diseases, have gained great interest in recent years. Advantages of pulmonary drug delivery, when compared with conventional medical treatments include, improvements in efficiency because of the large surface area of the lung (*i.e.*, 100 m<sup>2</sup>) and the thin epithelial layer thickness (0.2 to 0.7 μm)<sup>[1]</sup>, reduction of systemic drug levels with a decrease in adverse effects, and higher degree of convenience<sup>[2-4]</sup>. Specifically, as the drug aerosol directly travels to the designated target area, a much lower dose can be used to produce a therapeutic response with negligible side effects<sup>[5]</sup>.

Pulmonary drug delivery therapies are widely used to treat inflammation, asthma, COPD and cystic fibrosis (CF) as well as diabetes and other systemic diseases. For proper treatment the aerodynamic diameters of drug particles/droplets are recommended to be in the range of  $0.4 < d_p < 7 \mu\text{m}$ <sup>[6,7]</sup>. However, due to the sophisticated pharmaceutical aerosol formulations and the complex

anatomy and physiology of human lung airways, the optimization of pulmonary drug delivery (*e.g.*, drug-targeting delivery in lung airways) is challenging. The major research concern in pulmonary drug delivery is on the utilization of physical or chemical mechanisms, novel particles or drug carriers, and new drug-delivery device developments with improved performance.

In this section, three major classes of pulmonary drug delivery systems, *i.e.*, pressurized metered-dose inhaler (pMDI), dry powder inhaler (DPI) and nebulizer, are introduced and discussed, focusing on their delivery mechanisms, efficacies, and challenges for future developments. Furthermore, this section is also devoted to the foundation of lung-aerosol dynamics, *i.e.*, the transport and deposition of particulate drug carriers, which include the parameters affecting drug aerosol transport and deposition characteristics. It will be followed by a description of state-of-the-art methodologies for the realization of optimal pulmonary drug delivery.

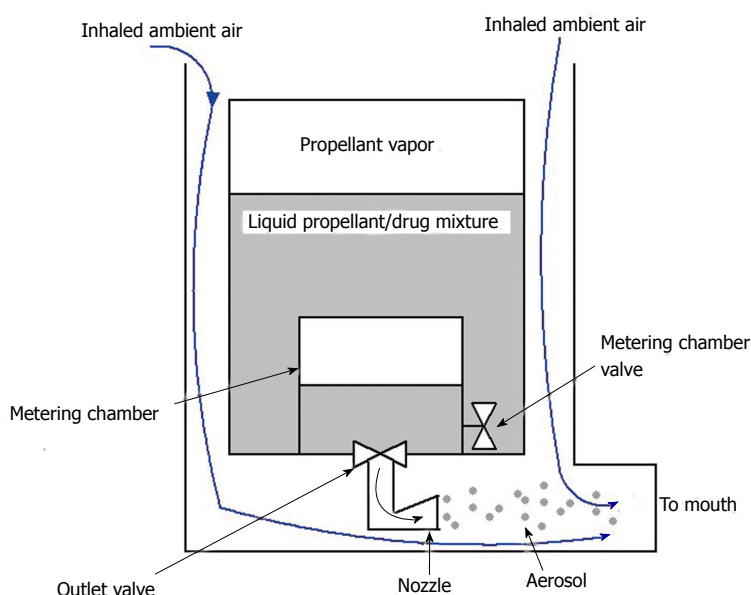
### Inhalers and drug-aerosol transport

**Type of inhalers:** There is a rich history of the development of pulmonary drug delivery therapy<sup>[8]</sup>. Pulmonary drug delivery devices or inhalers are classified into three major types: pMDIs, DPI and nebulizers<sup>[3]</sup>.

pMDIs are devices in which the mixture of drugs and propellants is stored in a canister from which accurate amounts can be released when the device is actuated by human power<sup>[3]</sup>. Thus, pMDIs provide a fast and cost-efficient solution to deliver pulmonary drug aerosols<sup>[9]</sup>. A pMDI expels the drug aerosol driven by propellants, such as chlorofluorocarbons (CFC) which, however, is being phased out due to environmental concerns. More recently, hydro fluoroalkanes propel the medicine through a nozzle at high velocities ( $> 30 \text{ m/s}$ )<sup>[10]</sup>. The typical structure of a pMDI is shown in Figure 1, including canister, metering valve, actuator, and propellant. Detailed functions of each part were presented by Newman<sup>[11]</sup>.

The advantages of pMDIs are: good portability, accurate dosage control, large capacity of medical doses at low cost<sup>[12]</sup>. Disadvantages of pMDIs include: highly dependent on the coordination of the patient's inhalation<sup>[3,13]</sup>, limited to certain drugs that are physically and chemically inert in the mixture with the propellant, and not efficient to treat deeper lung conditions due to the strong impaction in the upper respiratory system induced by the high jet velocity<sup>[5]</sup>. For example, only approximately 10%-20% of the medications emitted from CFC-pMDIs are able to enter and deposit in the lung, while the rest deposits in the oropharynx<sup>[14]</sup>. Additionally, the deposition of the content of drug formulation inside the canister can result in an incorrect dose of medication delivery ([en.wikipedia.org/wiki/Metered-dose\\_Inhaler](http://en.wikipedia.org/wiki/Metered-dose_Inhaler)).

To replace CFC and find a new propellant, hydrofluoroalkane was introduced<sup>[12]</sup> and approved. To resolve the synchronization problem between device actuation and patient's inhalation, breath-actuated MDIs were developed; for example, the Maxair Autohaler<sup>[15]</sup>. The devices actuate early during inspiration at an inspiratory flow rate



**Figure 1** Typical structure of pressurized metered-dose inhaler<sup>[23]</sup>. (Reprinted with permission from Ref.<sup>[23]</sup>).

of 30 L/min and are well accepted by patients<sup>[12,16]</sup>. It is announced that using breath-actuated inhalers might improve asthma control and reduce overall cost of asthma therapy compared with conventional pMDIs<sup>[12,17]</sup>.

Furthermore, to improve efficacy of drug delivery and avoid synchronization difficulties between patient's inhalation and pMDI actuation, spacer devices have been introduced as an alternative method. The basic design of a spacer contains 3 parts: the open tube, the reservoir/holding chamber, and the reverse flow design in which the pMDI is fired in the direction away from the patient. A one-way valve is used to create a holding chamber after pMDI actuation. Holding chambers serve as particle size filter and produce a fine aerosol because of the stronger inertial impaction of drug-aerosol particles with larger size and particle evaporation of propellant within the chamber. Studies indicated that using a larger-volume (> 750 mL) holding chamber (also called spacer) can provide higher fine-particle doses than a pMDI alone<sup>[18]</sup>. However, spacers may decrease the portability of pMDIs.

DPIs are an alternative to pMDIs, delivering pulmonary drugs into the respiratory system in the form of dry solid particles<sup>[3]</sup>. The dispersion of a dry powder aerosol is conducted from a static powder bed. When the patient takes a breath, air is introduced into the powder bed which creates turbulent flow and leads to fluidization of a static powder blend, entering the patient's airways. DPIs contain medicine in a variety of types, *e.g.*, single-dose capsule-based designs, multi-dose units containing the drug in bulk, and multi-dose units containing individual blister packages<sup>[19,20]</sup>. DPIs can also be divided into two types in terms of its drive force, *i.e.*, a passive DPI dependent on patients' inhalation and an active DPI dependent on external forces<sup>[21,22]</sup>. Active DPIs have become a preferred method to uniformly distribute drugs independent of the inspiration flow. A typical structure of a unit-dose DPI is shown in Figure 2.

DPIs are small, portable and easy to use. Several advantages were discussed by Sahane *et al.*<sup>[3]</sup>. For example,

there is no need for coordination of actuation and inhalation, because the patient's inspiratory force de-aggregates the powder and generates the aerosol. Furthermore, DPIs are able to deliver higher drug payloads to the airways<sup>[20]</sup>.

However, there are several disadvantages of DPIs. For example, if the therapeutic dose of a drug is high, the patient needs to manually reload several individual units per dose, as delivery is limited to a capsule-based or blister-based unit<sup>[19]</sup>. Also, DPI medications must be stored in a dry place at a temperature of not more than 25 °C and humidity between 40%-50% in sealed packages ([en.wikipedia.org/wiki/Dry\\_Powder\\_Inhaler](http://en.wikipedia.org/wiki/Dry_Powder_Inhaler)). Specifically, exposing the powder in a high-humidity environment destroy the medication dispersion ability of the device, implying that the efficacy of a DPI depends mainly on the flow properties of the powder suspension.

Nebulizers are breathing devices that generate droplets in small scales from a liquid in solution/suspension<sup>[12]</sup>, which are used to treat lung diseases. The inhaled drug is in the form of mist aerosols. Nebulizers are often used in situations in which a conventional inhaler is ineffective. In simple targeting cases, nebulizers may limit side effects of certain medication, say, steroids, by delivering the drug directly to the desired site. Several conventional designs of nebulizers are shown in Figure 3.

Atomizers (or jet nebulizers)<sup>[23]</sup> are the most common ones (Figure 3A). They use compressed gas, or a compressor, to generate high-velocity air streams through a tight opening and across the fluid medication suspension to create particulate/droplet aerosols. The fluid is split up by the airstream and divided into droplets inside the nebulizing chamber. The primary advantage of jet nebulizers is the low operational expense. However, there is always the lack of portability because of the need of compressed gas<sup>[12]</sup>.

Ultrasonic wave nebulizers generate aerosols *via* the vibration of a piezoelectric crystal at a high frequency (> 1 MHz) through the drug liquid (Figure 3B). Contrasted

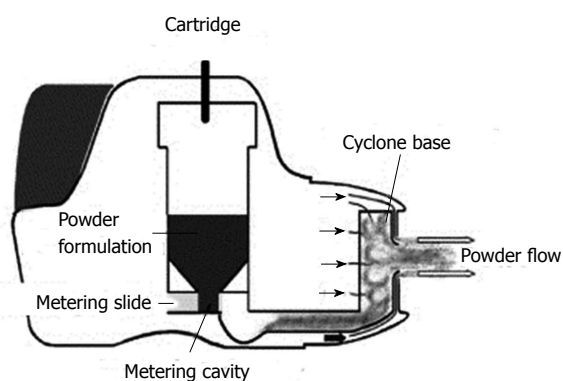


Figure 2 Typical structure of unit-dose dry powder inhaler.

with jet nebulizers, ultrasonic nebulizers work with lower noise and provide faster delivery of pharmaceuticals; although due to the complimentary heat generated during the operation, there are several medication restrictions for the ultrasonic wave nebulizers. With both types of nebulizers, the patient inhales vapor through a mouthpiece or face mask. Electronic nebulizers form a subcategory of ultrasonic nebulizers.

Based on the vibrating mesh technology (VMT), smaller portable devices have been developed as advanced nebulizers, *i.e.*, vibrating mesh nebulizers<sup>[24]</sup>. With the VMT, a mesh/membrane with multiple apertures vibrates at the top of the liquid reservoir (Figure 3C), generating drug aerosols consisting of small-scale droplets. Vibrating mesh nebulizers are claimed to have higher output efficiency, minimal residual volume, and high percentage of fine particulate drugs in the emitting stream<sup>[24]</sup>.

Another type of new-generation nebulizers is called human-powered nebulizers which are breath-enhanced<sup>[25]</sup>. Their improved designs avoid exhaled loss and apparatus loss of aerosols. Ambient air is entrained through a one-way valve along with the power gas during inspiration, while during exhalation the one-way plastic flapper valve is closed.

As part of the developments of human-powered nebulizers, a dosimetric nebulizer is defined as one that releases aerosols only during inhalation, being the most efficient nebulizer generating aerosols. Comparisons of different types of nebulizers are presented in Table 1<sup>[12]</sup>. A variety of nebulizer products on the market are summarized in Table 2.

In addition to the three major classes of inhalers, new types of inhalers were designed in order to improve the efficacy. "Soft mist inhaler" is another type of drug delivery device<sup>[5,26]</sup>. It was developed in order to overcome the limitations of traditional inhaler devices and to meet the need for a convenient propellant-free inhaler<sup>[5]</sup>. For example, the Respimat® Soft Mist™ inhaler (SMI) utilizes the mechanical force from a spring instead of a fluid-gas propellant to produce a drug aerosol which is suitable for inhalation. The spring system inside the inhaler can guarantee that the aerosol is produced by a reliable and reproducible energy source. Thus, dosage and size distribution of the drug aerosols are insensitive to the

Table 1 Comparisons of conventional categories of nebulizers

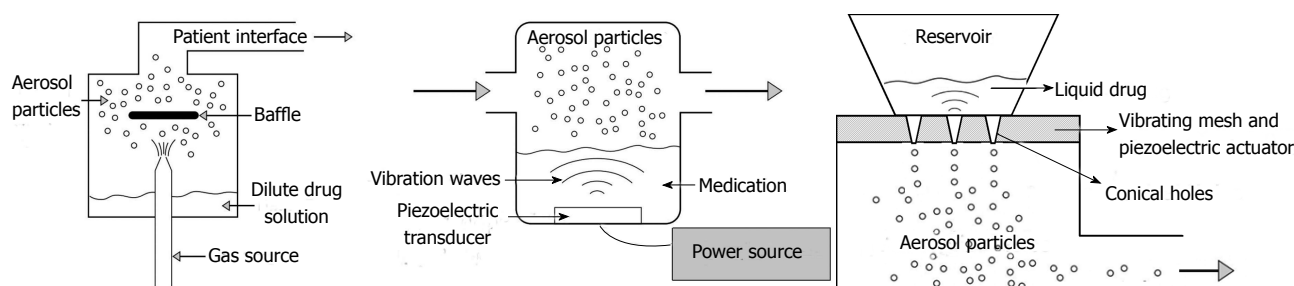
	Jet	Ultrasonic	Vibrating mesh
Features			
Power source	Compressed gas or electrical mains	Electrical mains	Batteries or electrical mains
Portability	Restricted	Restricted	Portable
Treatment time	Long	Intermediate	Short
Output rate	Low	Higher	Highest
Residual volume	0.8-2.0 mL	Variable but low	< 0.2 mL
Environmental contamination			
Continuous use	High	High	High
Breath-activated	Low	Low	Low
Performance variability	High	Intermediate	Low
Formulation characteristics			
Temperature	Decreases	Increases	Minimum change
Concentration	Increases	Variables	Minimum change
Suspensions	Low efficiency	Poor efficiency	Variable efficiency
Denaturation	Possible	Probable	Possible
Cleaning	Required, after single use	Required, after multiple use	Required, after single use
Cost	Very low	High	High

inspiratory characteristics of the patient. Medicine delivered by the SMI is stored in a collapsible bag in a sealed plastic container inside the cartridge. With each actuation, the correct dose is drawn from the reservoir and the flexible bag contracts, which is launched by the spring<sup>[27]</sup>. A recent papers<sup>[28]</sup> also claimed that SMI can avoid the coordination difficulty between inhalation and actuation. Also, the emitted stream velocity of the aerosol is much slower than that of a pMDI. Theoretically, with the SMI aerosol transport to deeper lung airways is easier due to lower inertial impaction in the upper respiratory system, so that the resulting deposition fraction can reach 40% for adults<sup>[19]</sup>. However, besides the advantages of SMI, such a device is relatively expensive. Other SMI designs include AERx, and AERx Essence platform (Aradigm, Hayward, California)<sup>[29]</sup>.

MDIs and DPIs are both portable and fast delivering devices for low medication dosages. Another characteristics of both device types is that the aerosol generator and the medication are not detachable. In contrast, nebulizers are able to deliver high medication dosages, and a single device can be used with different drugs<sup>[30]</sup>.

Compared to pMDIs and DPIs, another advantage of using nebulizers for drug inhalation is that no special inhalation techniques are required<sup>[12]</sup>. However, due to the need of compressed gas or a compressor to operate, conventional nebulizers are generally not portable. Additionally, the drug-delivery efficacy and treatment time using conventional nebulizers are much lower and longer than those for pMDIs and DPIs<sup>[31]</sup>. However, presently there appears to be a tendency among physicians to prefer to prescribe a pMDI rather than a jet nebulizer which produces more noise and is less portability.

Comparative efficacy of different pulmonary drug delivery devices has been performed by different research groups. Chou *et al*<sup>[32]</sup> concluded that MDIs can give a



**Figure 3** Typical structures of different nebulizer categories. (Reprinted with permission from Ref.<sup>[117]</sup>. A: Atomizer (jet nebulizer); B: Ultrasonic wave nebulizer; C: Vibrating mesh nebulizer.

**Table 2** Advantages and disadvantages of different nebulizer products

Product name	Type	Pros	Cons
PARI Vios®	Jet nebulizer	Low operational cost, robust in structure, effective in nebulizing suspensions	Relatively bigger in size and heavier in weight; more noisy
Omron MicroAir®	Electronic nebulizer	Does not heat the medicine, quiet and fast drug delivery	Comparatively expensive; replaced much more frequently
Omron NE-U17®, Beurer Nebulizer IH30®	Ultrasonic nebulizer	Silent and portable	
Omron NE-U22V®, Pari E-Flow®	Vibrating mesh nebulizer	Higher output efficiency, minimal residual volume, and High percentage of particles in the emission, small in size	Less efficient in nebulizing aerosols
Pari LCD®	Breathe-enhanced nebulizers	Higher output efficiency avoiding apparatus loss and exhaled loss	N/A
AeroEclipse®	Dosimetric nebulizer	Higher output efficiency avoiding apparatus loss and exhaled loss	N/A

faster and more economical approach to deliver bronchodilator drug aerosols for asthma treatment in elder children and adults. A similar conclusion was reported by Batra *et al.*<sup>[33]</sup> for the aerosolized salbutamol in an acute exacerbation of asthma in children. Delgado *et al.*<sup>[9]</sup> investigated nebulizers *vs* MDI with spacers for bronchodilator therapy to treat wheezing in children aged 2 to 24 mo. They drew the conclusion that although younger patients are often unable to coordinate inspiration with activation of the MDI, thereby limiting the effective amount of drug inhaled, MDI with spacers may be as efficacious as nebulizers for the emergency department treatment of wheezing in children aged two years or younger. Dhuper *et al.*<sup>[34]</sup> claimed that using a MDI with a spacer may result in a marked reduction in time and effort, thereby saving the total cost for treatment compared with conventional nebulizers.

While the optimization of treatment using MDIs requires coordination between inspiration and actuation, which is difficult to achieve by patients<sup>[13]</sup>, most DPIs generate and deliver drug aerosols depending on subject-specific inhalation efforts. Indeed, the dose delivered by DPIs is more related to the inspiratory flow rate than by the device<sup>[35]</sup>. Specifically, MDIs are able to generate more consistent aerosol sizes across a range of inspiratory flow rates. In contrast, the aerosol-size distributions produced by DPIs are reported to be highly dependent on the inhalation patterns, with some being showing more sensitive than others<sup>[36]</sup>.

Not surprising, all drug delivery devices have advantages and limitations. Device selection must consider portability, convenience level for users, therapeutic efficacy

as well as low cost and high safety<sup>[12]</sup>. As mentioned, the therapeutic efficacy is determined by many factors, *i.e.*, the kind of medication used, the aerosol's physical and chemical properties, as well as the patient's inhalation patterns and the physiology of their respiratory systems<sup>[30]</sup>.

The efficacy enhancement of drug delivery devices can be achieved through two major strategies: (1) improved drug formulation; and (2) improved device structure design. The primary goal is to control the agglomeration of drug aerosols inside devices to reduce drug residues in the device, thereby enhancing the efficacy.

**Drug formulation:** The physical and chemical properties (*e.g.*, particle size distribution, shape, surface charge, hygroscopicity, *etc.*) of drug-particles are most important. Usually, drug formulations, including drug-carrier selections, are able to lower inhaler retention and improve transport, the proportion of drugs that reach the desired lung site, and the stability of the drug *in vivo*. Sufficiently strong attractions between carrier and drug must be guaranteed for maintaining the stability of the medication mixture. However, the attractions between carrier and drug must also be sufficiently weak so that the release of the medication from the carrier will not be impeded inside the human respiratory system<sup>[3]</sup>. Sahane *et al.*<sup>[3]</sup> also discussed the formulation of drugs for DPIs. For example, DPIs are formulated using four types of formulation strategies: Carrier Free, Drug Carrier, Drug Additive, Drug Carrier Additive. Specifically, therapeutic dry powders for inhalation are often composed of fine drug particles and inert coarse carrier particles such as lactose<sup>[37]</sup>.



Sufficient detachment of the drug from its carrier must be guaranteed to improve the delivery efficiency. Improved formulation should reduce the particle-particle interacting forces which are the major cause of the agglomeration between drugs and carriers. Furthermore, adding preservatives and mixing it with other drugs will also influence device output and aerosol characteristics in a good way<sup>[38]</sup>. Formulations for pMDIs are also necessary. For example, mast cell stabilizers such as cromoglicate or nedocromil are used to extend the duration of the device<sup>[11]</sup>. In the recent decade, non-hygroscopic mannitol exhibits particularly great promise as an attractive carrier in DPI systems to replace lactose<sup>[37,39]</sup>. Additionally, it is necessary to minimize the adhesion intensity between the drug particle and the inner wall of the inhalers by using surface treatment to reduce inhaler retention and enhance the drug delivery efficacy<sup>[40]</sup>.

**Device structure:** Device structures can have a strong impact on the velocity field inside the device, thereby influencing the drug suspension characteristics. For example, the design of the actuator plays an important role in the delivered spray characteristics generated by pMDIs<sup>[11]</sup>. Specifically, the design variables of the actuator are expansion chamber size and shape, nozzle diameter, nozzle path length, mouthpiece length and shape, breath-actuation, spray velocity modification, and spacer attachment<sup>[19,41]</sup>. For nebulizers, the chamber design using a one-way valve is important to decrease aerosol waste during exhalation<sup>[27]</sup>. Also, the mouthpiece design is essential to lower the percentage of drugs remaining in the device. For example, increasing the cross-sectional area of the mouthpiece section will decrease the emitting velocity of the drug aerosol thereby lowering the extent of drug deposition in the oral cavity due to the inertial impaction effect<sup>[42]</sup>. Other factors related to structure which will influence the device performance are flow path design and manufacturing design<sup>[7]</sup>.

The patient's inhalation behavior, in light of the correct utilization of a drug delivery device, is likewise essential for successful therapy. Specifically, it needs to be guaranteed that a patient can easily use the device correctly and properly thereby optimizing the therapeutic efficacy<sup>[27]</sup>. Therefore, the ideal design of drug delivery devices should include the following characteristics<sup>[11,22]</sup>: (1) attractive in appearance, easy to use, and easy to carry; (2) accurate and uniform delivery of medication over a variety of patient's inhalation intensities; (3) reliable qualitative drug delivery control throughout the life of the inhaler; and (4) low cost with high efficacy.

Traditionally, the biotechnology and pharmaceutical industries preferred jet nebulizers for novel medication development, considering their capabilities to deliver higher doses of drugs and the lower research and development expenses than other types of devices<sup>[19]</sup>. However, recently many companies have recognized the long time duration at each treatment experienced by patients. Therefore, to handle that issue they have been starting preclinical development with novel devices based on more efficient and advanced drug delivery technologies.

In the previous two decades, a few innovative inhaler designs have been developed, providing more efficient drug aerosol delivery<sup>[12]</sup>. New designs and new improvements were presented in several papers<sup>[11,12,19,20,43-46]</sup>. For example, the improvement of pMDIs is mainly focusing on providing more precise targeting, dose metering, and easy actuation. Related new products are listed by Dolovich *et al.*<sup>[12]</sup>. For new designs of the major three classes of inhalers, Zhang *et al.*<sup>[20]</sup> proposed novel active and multi-dose dry powder inhalers which are able to utilize the compressed air to deliver a small quantity of extra fine particles with high delivery efficacy. A new design for a nebulizer with flow meter function was proposed by Addington *et al.*<sup>[46]</sup>. By changing DPI device structure and drug formulation, Behara *et al.*<sup>[47]</sup> proposed a design option of a DPI which controls the aerosol diameters and increases the emitted drug dose.

**Drug-aerosol dynamics:** Liquid and solid micro/nano-particulate matter (*i.e.*, solid particles and droplets) and vapors are generated by drug delivery devices for therapeutic purposes. The objective of targeting is to guide and deliver drugs from their releasing position to expected deposition regions in the human respiratory system to optimize the medical effectiveness<sup>[48]</sup>. The fluid-particle dynamics during drug-aerosol transport, deposition, absorption, and clearance are essential for guiding the optimization technique of drug delivery. Specifically, "targeting" can be categorized into three levels<sup>[1]</sup>: (1) delivery to a specific lung region, *i.e.*, central or peripheral, right or left; (2) delivery to the site of disease; and (3) delivery to distinct cell types with biological barrier transport, *e.g.*, epithelial cells, or cells of the lung associated lymphatic tissue. Traditional targeting activities can be also grouped into passive and active targeting<sup>[49]</sup>.

As discussed in the previous sections, great progress has been made in drug aerosol formulation for better drug-aerosol delivery efficiency, as well as controlling drug aerosol transport before deposition in lung airways. However, it is also necessary to understand the absorption and systemic transport of drug aerosols after the deposition at the air-blood barriers, which has been rarely investigated. In this section, underlying principles for drug-aerosol transport and deposition in human respiratory systems are discussed to provide valuable insight into certain aspects for optimal pulmonary drug-targeting.

Physical and chemical factors which can affect the transport and deposition of drug-aerosols include: initial particle size, shape, density, concentration, as well as release position and velocity; furthermore, the drug-aerosol formulation (*i.e.*, hygroscopicity, charge and surfactant) as well as the geometric characteristics of the patient-specific respiratory system are important<sup>[6,41,48]</sup>.

The underlying principles to describe the complex and coupled fluid-aerosol dynamics inside the human respiratory systems are the physical conservation laws, using the Eulerian or Lagrangian modeling approach. Specifically, the Eulerian approach can be employed to calculate continuity, momentum and energy equations

for the continuous airflow phase, while both Eulerian and Lagrange approaches can be used for the discrete drug aerosol phases<sup>[6,48]</sup>. Supplementary equations may be necessary for the description of complex mechanisms, *e.g.*, evaporation or condensation of aerosol droplets<sup>[50]</sup>, magnetic-force driven drug-targeting delivery<sup>[51]</sup>, rotational motion of non-spherical particles<sup>[52]</sup>, *etc.* Several computational fluid-particle dynamics (CF-PD) models are available for the calculation of air-drug mixture dynamics<sup>[53]</sup>, such as the discrete phase model (DPM), two-fluid model, mixture model, dense dispersed phase model (DDPM), and the discrete element method (DEM).

The deposition mechanisms of aerosol particles or droplets - impaction, sedimentation, diffusion and combinations in the respiratory tract - have been extensively discussed<sup>[6,48,54]</sup>. Specifically, for microparticles, the deposition may occur due to: (1) secondary airflow (laminar or turbulent) induced wall impaction; (2) inertial wall impaction; (3) gravity induced sedimentation; (4) particle-particle interaction induced wall impaction; and/or (5) diffusion. For nanoparticles, diffusion, caused by Brownian motion, may become most significant.

Other than treating local diseases in the respiratory system, pulmonary drug delivery is also promising for systemic drug delivery which is intended to utilize the alveolar region to swiftly absorb drug aerosols. However, the processes that take place after an aerosol particle has landed on the pulmonary epithelial surfaces, *i.e.*, the dissolution, absorption, mucociliary clearance, and systemic translocation, still lack information<sup>[55]</sup>. Using complex pharmacokinetic modeling will be helpful in understanding the absorption process through the lung epithelium, including paracellular transport and transcellular transport. Considering numerical modeling of this process, mass transfer advection-diffusion equations can be employed with proper boundary conditions<sup>[56]</sup>. Furthermore, systemic drug transport can be modeled using multi-compartment mass transfer models for drug-aerosol migration into the mucus-tissue-blood system<sup>[57,58]</sup>. Factors affecting drug absorption are physiochemical properties of drug aerosol particles (*e.g.*, hydrophobicity), co-administration conditions, lung pathophysiology, *etc.*<sup>[55]</sup>.

With decreasing computational limitations and the advancements in commercial CFD software development, more realistic numerical models are becoming available for the simulation of dense particle suspensions as well as droplets with heat and mass transfer. Those models can be used for the design of drug delivery devices<sup>[59]</sup>. Although experiments can provide some information about the airflow field of the drug delivery device<sup>[60]</sup>, using CFD-techniques provide more detailed information when compared to experiments. Specifically, computer simulation models require initial and boundary conditions as well as the geometry of the flow domain of the device. Once fully validated, they are cost-effective tools to analyze factors influencing the performance of drug delivery devices, *e.g.*, turbulence in the inhaler, spray momentum and inlet jet effects, as well as best possible geometric de-

sign and operation.

Originally, CFD was only utilized for airflow field analysis of the drug inhalers<sup>[61,62]</sup>. With the development of numerical multiphase flow methods, simulation techniques were used for the design and analysis. For example, Kleinstreuer *et al.*<sup>[63]</sup> numerically investigated the transport and deposition of drug droplet aerosols from a pMDI into a model of the human respiratory system. The parametric analyses with different propellants, nozzle diameters, and releasing positions were presented. Based on the numerical results, they found that using a smaller nozzle provides a better atomization effect and finer droplets with more uniform dispersion.

Recently, based on the numerical model established by Worth Longest *et al.*<sup>[64,65]</sup>, Longest *et al.*<sup>[13]</sup> investigated different aerosol deposition in human lung airways between a specific MDI and DPI. Fluent 12.0 with user-defined functions (UDFs) was employed for the Euler-Lagrange numerical simulations. They claimed that for the specific inhaler models they investigated, MDI is able to deliver significantly more drugs to the tracheobronchial region when compare to DPI. It is worth mentioning that they did not consider any particle-particle interaction effects. Jiang *et al.*<sup>[66]</sup> investigated the design impact on a commercial DPI using the LRN  $\kappa$ - $\omega$  model in ANSYS Fluent 6.2.16. However, they did not simulate powder transport and subsequent deposition by using any multiphase flow model. Based on CFD analysis, Longest *et al.*<sup>[67]</sup> evaluated associations between aerodynamic parameters and DPI performance for a carrier-free formulation, forming micron/submicron-scale drug aerosols. Factors which may influence the dispersion of aerosol particles were discussed.

With the development of computational fluid dynamics-discrete element method (CFD-DEM), the discrete element method is a robust and computational economic model to simulate the highly dynamic process (*i.e.*, particle-particle interaction) for dense powder dispersions in inhalers<sup>[68]</sup>. Inhaler developments based on CFD-DEM simulations have been focused on pharmaceutical agglomerate break-up in DPIs<sup>[59]</sup>. For example, Tong *et al.*<sup>[68,69]</sup> recently employed ANSYS Fluent with in-house UDFs, describing powder dispersion in a commercial Aerolizer® Inhaler model. They also investigated the factors influencing the performance of the inhaler based on their numerical simulation results. They found that at low flow velocities, agglomerates consisting of particulate matters with smaller diameters were more difficult to disperse. They also claimed that the dispersion efficiency is proportional to the ratio of the particle impact energy and particle-particle cohesion energy.

In summary, it is promising to use CFD-DEM or DDPM-DEM for the simulation of dense drug-powder suspensions in pMDIs and DPIs, because of the DEM capability of taking into account the particle-particle contact interaction as well as the computational economy aspect. CF-PD models can also provide guidance for drug delivery and hence enhancing methodology developments which are discussed in Section 2.2. For a recent review see Ruzzycki *et al.*<sup>[70]</sup>.

**Design and strategies for direct drug-targeting**

Existing drug aerosol delivery devices, including those that attempt to target specific areas in the lung, exhibit poor efficiencies (*e.g.*, from 5% to 20%). Efforts are being made to improve direct drug delivery through the pulmonary route. The goal is to provide high doses of drugs to lung tumor tissue *via* inhalation, resulting in treatment efficiencies and low adverse side effects.

**Smart inhaler system methodology:** Kleinstreuer *et al.*<sup>[63]</sup> analyzed computationally the performance of pMDIs with and without spacers and compared their deposition efficiencies with that of a smart inhaler system (US Patent 7900625 issued 03/08/2011) based on a new optimal targeting methodology<sup>[71]</sup>. A novel smart inhaler system (SIS), which achieves up to 85% drug-aerosol deposition efficiency, is being prototyped and experimentally tested. The SIS is a device for directed aerosol delivery to predetermined lung sites, facilitated by an adaptive nozzle and a mechanism for inhalation waveform modulation. The aerosol particles are released through a nozzle which incorporates lightweight, multifunctional shape memory materials that allows to move the nozzle's optimal radial position based on subject-specific numerical data. The SIS is promising to notably improve the aerosol delivery efficiency to specific locations through pulmonary routes, thereby reducing unwanted deposition in healthy lung airways.

**Enhanced deeper lung delivery of nano- and micro-pharmaceutical aerosols *via* condensational growth:**

Drug aerosol losses occur because of high deposition in the nasal passages or in the oral cavity due to impaction. To enhance drug-aerosol delivery into deeper lung airways, enhanced condensational growth (ECG) and excipient enhanced growth (EEG) methods have been proposed and validated by experiments *in vitro*<sup>[13,72-74]</sup>. Based on the fact that the larger mass mean aerodynamic diameter of drug aerosols indicates strong impacting, deposition of particles before entering the trachea as well as most submicron particles inhaled will be exhaled without depositing in the lung airways. Thus one can utilize the high relative humidity of the ambient air or inside the human respiratory system to control the trajectories and depositing sites of the particles in human pulmonary routes, relying on different condensational growth rates of such sub-micron aerosols of different formulations. Specifically, submicron particles are emitted from the inhalers which are able to initially penetrate through the oral or nasal cavity, thereby reducing the deposition before entering the trachea. With the condensation effect, those particles will grow in size and most of them will deposit in deeper lung airways. For ECG, the sub-micron aerosols are inhaled with highly humidified air at a temperature higher than that of the human body. The droplets will grow due to the condensation of surrounding water vapors when they enter the human respiratory system<sup>[72]</sup>. For EEG, hygroscopic excipients are formulated with the drug and the formulated drug aerosol will absorb water inside the human respiratory system. Although these

methods result in higher pulmonary deposition, they are not able to provide location-specific delivery (see Level 2).

**Magnetic nanoparticles for site-specific pulmonary drug delivery:**

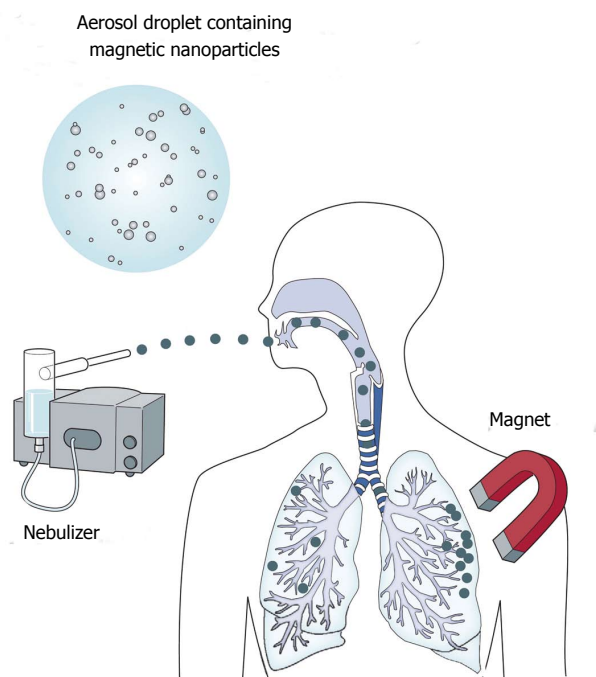
Another active targeting strategy is magnetic targeting, which can be realized by combining magnetic nanoparticles (*i.e.*,  $\gamma$ -Fe<sub>2</sub>O<sub>3</sub> and Fe<sub>3</sub>O<sub>4</sub>) with micron particles or droplets<sup>[51,75-79]</sup>. These types of particles are also called magnetic nano-in-microparticles (NIMs). An external magnetic field will be enforced to guide drug aerosols to specific regions of the lung (Figure 4), thereby reducing undesired side effects, *e.g.*, mitigating deposition on healthy lung tissues. To succeed in direct drug delivery, those magnetic nanoparticles should have characteristics such as mono-dispersity, superparamagnetism, stability and biocompatibility<sup>[80]</sup>.

However, further translation of magnetic nanoparticles may cause potential health problems and need further clinical investigations. The long-term effects of magnetic nanoparticles need to be studied as well<sup>[77]</sup>. For example, concerns associated with long-term tissue damage, toxicity, carcinogenesis, immunogenicity, and inflammation need to be investigated to improve the production of magnetic nanoparticles<sup>[81]</sup>.

**Shape engineering for novel drug carriers:** For pulmonary drug delivery, the deposition pattern and clearance from deposition sites are two key parameters for a proper design of drug-delivery carriers<sup>[82]</sup>. For example the particle shape of drug carriers has a profound impact on optimizing performance of drug delivery. Compared to spherical particles, numerical studies have shown that fiber-like particles are more likely to reach the deeper lung airways<sup>[52,83]</sup>. Also, fiber-like carriers have better internalization abilities than spherical particles for drug delivery<sup>[84]</sup>. This finding demonstrates that when targeting drugs into deeper lung airways, fiber-like drug carriers may perform more efficiently than spherical ones. A recent study demonstrated that using elongated fine mannitol particles enhance the aerosolization performance of inhalable drugs which may improve the efficiency of drug delivery from the devices<sup>[37,85]</sup>. It is promising to explore the shape as an important parameter for improved drug delivery performance.

**Multifunctional Nanoparticles:** Today, the size of drug aerosol particles can be reduced from tens of micrometers to tens of nanometers (*i.e.*, less than 100 nm in size), which is a significant technological and medical breakthrough. Drug-delivery systems for nanoparticles have been developed which can potentially enhance the efficacy and reduce side effects for a wide range of drugs. Due to the small inertia of nanoparticles, they can avoid impacting the oral cavity when being inhaled, and hence they are transported deeper into human lung airways. Those nanoparticles with diameters around 50 nm have been reported to be most efficiently internalized by cells<sup>[86]</sup>. The design of multifunctional nanoparticles for treatment of pulmonary diseases (*i.e.*, lung cancer) is also





**Figure 4 Targeted deliveries of magnetic aerosol particles.** (Reprinted from Ref.<sup>[12]</sup>, with permission from Elsevier).

a promising methodology. Additional functionality such as image contrast enhancement can be realized by adding other constituents into multifunctional nanoparticles, thereby assisting better drug-targeting control. Multifunctional nanoparticles can be designed for detecting infected cells, and delivering drugs specifically to those cells, and leaving healthy organs and lung cells unaffected<sup>[87]</sup>. Multifunctional nanoparticles can also deliver multiple therapeutic agents in a single formulation<sup>[49]</sup>. A multifunctional nanoparticle consists of a surface coating, imaging agent for detection, and therapeutic drugs. The aims of multifunctional nanoparticles are<sup>[49]</sup>: (1) enable specific targeting and aid in uptake realized by surface modification; (2) avoid fast endothelial system clearance *via* surface coating technology<sup>[88]</sup>, and thereby extending circulation time and enhance uptake; and (3) load higher concentrations of multiple remedial agents that can override multidrug resistance and result in therapeutic effects.

However, more work is needed to understand the fate of nanoparticles after inhalation, including interactions with biological cells and nano-toxicity. Also, in a recent review article, Cheng *et al.*<sup>[89]</sup> discussed the costs and regulatory hurdles for using multifunctional nanoparticles *vs* their potential benefits.

## INTRAVASCULAR DRUG-TARGETING METHODOLOGIES FOR SOLID TUMORS

In addition to drug-targeting in the pulmonary system, much focus has been placed on treating unresectable tumors *via* intravascular therapies. These therapies involve either systemic or local, intra-arterial delivery of therapeutic agents such as chemotherapeutic drugs, multi-

functional nanoparticles (NPs), radioactive microspheres, or embolic agents. While micron-sized agents must be delivered locally due to their embolic potential, this local drug administration is also beneficial for delivering higher therapeutic concentrations to cancer cells.

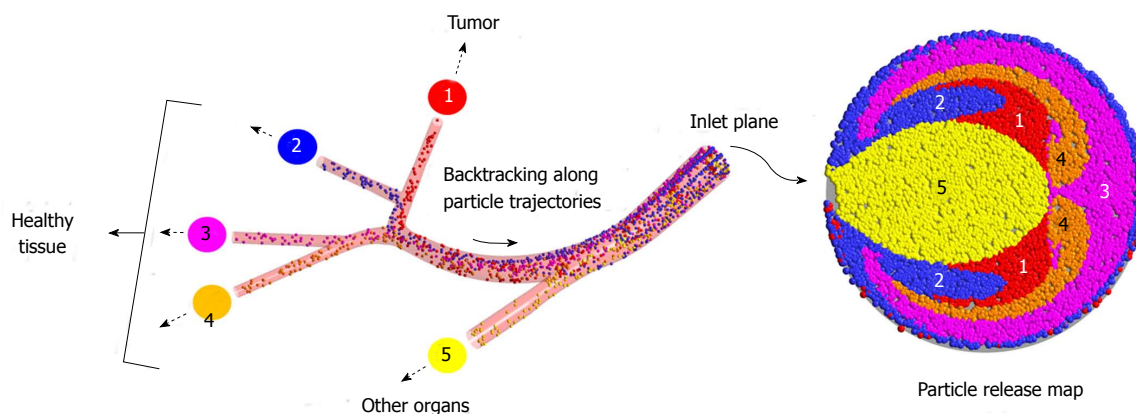
Intra-arterial delivery is often achieved using a locally placed drug-infusion catheter. However, due to the often tortuous and small size of the complex arterial systems leading to tumors, it is difficult or impossible to manually position this catheter directly in tumor-supplying arteries. As a result, therapeutic agents can still deposit in healthy tissue and/or travel to other organs. Thus, techniques are needed to better target predetermined cancer sites from upstream. Some existing methods include passive and active targeting for multifunctional nanoparticles as well as magnetic drug targeting. As will be discussed in the next sections, the shortcomings of these methods are that the nanoparticles must be very close to the tumor for passive and active targeting to be effective, and the magnetic particles must be near the body's surface and in slow blood-flow systems for magnetic drug targeting to be successful. As a result, a direct drug-targeting strategy has been proposed which uses knowledge of the patient-specific, local blood flow field to precisely position a smart micro-catheter radially and deliver the therapeutic agents to the tumor directly. Current research is focused on developing and testing such a device.

### Passive and active targeting

Being less than 1  $\mu\text{m}$  in at least one dimension, multifunctional nanoparticles can more readily extravasate through tumor vessels and attach to cancer cells with the help of passive and active targeting. Specifically, passive targeting takes advantage of the leaky walls and poor lymphatic drainage of many tumor vessels. This allows NPs to more readily enter the tumor interstitium and linger for extended periods (*i.e.*, the enhanced permeability and retention effect)<sup>[90-100]</sup>. Active targeting can then enhance tumor accumulation through ligand-receptor binding which is achieved by incorporating ligands on the drug's surface to selectively attach to over-expressed antigens or receptors on tumor cells<sup>[101,102]</sup>. This targeting can also enhance therapeutic efficacy through receptor-mediated endocytosis.

The limitation of these passive/active-targeting events is that the NPs must come in close proximity to the tumors for both strategies to be effective. Thus, the NPs' size, shape, surface properties, and targeting ligands have been modified in attempts to lengthen their circulation time and increase site specific accumulation<sup>[91,103-105]</sup>. For example, drug-loaded nanoparticles are often coated with polyethylene glycol to minimize the attraction of proteins which trigger immunogenic responses leading to system clearance. However, while such characteristics are beneficial for prolonging the NPs circulation time, they can also be detrimental once the NPs are near the tumor cells due to their resistance to endocytosis. Thus, the possibility of dynamically altering these characteristics *in vivo* is currently being investigated<sup>[106]</sup>. Such functionality has





**Figure 5** Illustration of the direct tumor-targeting methodology. (Reprinted from Ref. <sup>[115]</sup>, with permission from Springer).

been achieved by taking advantage of the different pH, temperature, and enzyme levels in and around tumors. Despite these efforts, NPs still face filtration by non-target organs or clearance by the immune system before reaching the tumor<sup>[91,103-105,107]</sup>.

### Magnetic drug targeting

Magnetic drug targeting is one technique for increasing NP accumulation at solid tumors. In this method, drugs are bound to magnetic nanoparticles, and an external magnetic field is applied to attract the particles to a target site. Several studies have demonstrated the feasibility of this approach through computational and animal studies, and a few have demonstrated this targeting in human trials. Recently, studies have focused on obtaining a better understanding of the parameters which affect magnetic targeting success. For example, Kayal *et al.*<sup>[108]</sup> experimentally and computationally analyzed the effects of the flow, magnet, nanoparticle properties, and injection site on deposition efficiency. As expected, they found that the efficiency was lower for increased flow rates, lower magnetic field strength, and smaller NPs. These, and other studies, demonstrate that the current applications are limited due to restrictions on the particle size and magnetic field strength. Specifically, this technique is only applicable when the tumor is located near the body surface and the flow rate is small. To overcome this, implant-assisted magnetic drug targeting has been proposed in which a magnetic implant is inserted near the target site to increase the magnetic field gradient in deep tissue<sup>[109]</sup>. However, this technique is still not likely to resolve the downstream tumor-targeting problem because it may not be feasible to place these implants as near to the tumor as necessary.

### Direct drug-targeting

As an alternative to the current strategies, a novel direct tumor-targeting methodology has been proposed. In this technique, the catheter position (*i.e.*, radial position in the arterial particle-injection plane), infusion speed, and injection timing are precisely controlled so that the injected drug-loaded particles are carried by the blood flow directly to the target site<sup>[110]</sup>. While previous work has

demonstrated that the particle infusion speed should be relatively equal to the surrounding blood flow<sup>[111,112]</sup>, the remaining conditions are determined by computational simulations which mimic the targeted arterial system. Specifically, a vast amount of particles are infused over the selected injection position of the truncated arterial system, and their transport is modeled through the system. By backtracking along the particle trajectories (as indicated in Figure 5), a patient-specific particle release map (PRM) can be generated, which visually links particle injection regions with associated exit branches, some potentially connected to tumors. Such PRMs can then be used to determine radial micro-catheter positions to achieve optimal targeting. For example, in the scenario given in Figure 5, the catheter should be placed in the red zone (zone 1) of the PRM while avoiding the remaining zones. By generating multiple PRMs at subsequent intervals throughout the cardiac cycle, the best injection interval can also be determined<sup>[113]</sup>.

### The computational medical management program:

The Computational Medical Management Program has been proposed to implement this targeting methodology into clinical practice. As illustrated in Figure 6, there are three basic stages in this program: (1) the patient evaluation stage; (2) the computer modeling stage; and (3) the clinical implementation stage.

As in current intra-arterial procedures, the patient evaluation stage includes classification of the tumor and determination of the best treatment route. In the proposed procedure, the patient's geometry and flow conditions are also collected in this stage. In the next stage, computational case studies are run in the truncated geometry to determine the best injection region and interval for targeting as well as the appropriate time to terminate injection. In the final stage, optimal catheter positioning and injection is achieved using the proposed Smart Micro-Catheter (SMC) and Medicine Supply Apparatus (MSA). As in current procedures, success of the treatment is then evaluated.

**SMC system for optimal drug-delivery:** As introduced in the previous section, a SMC and MSA have been

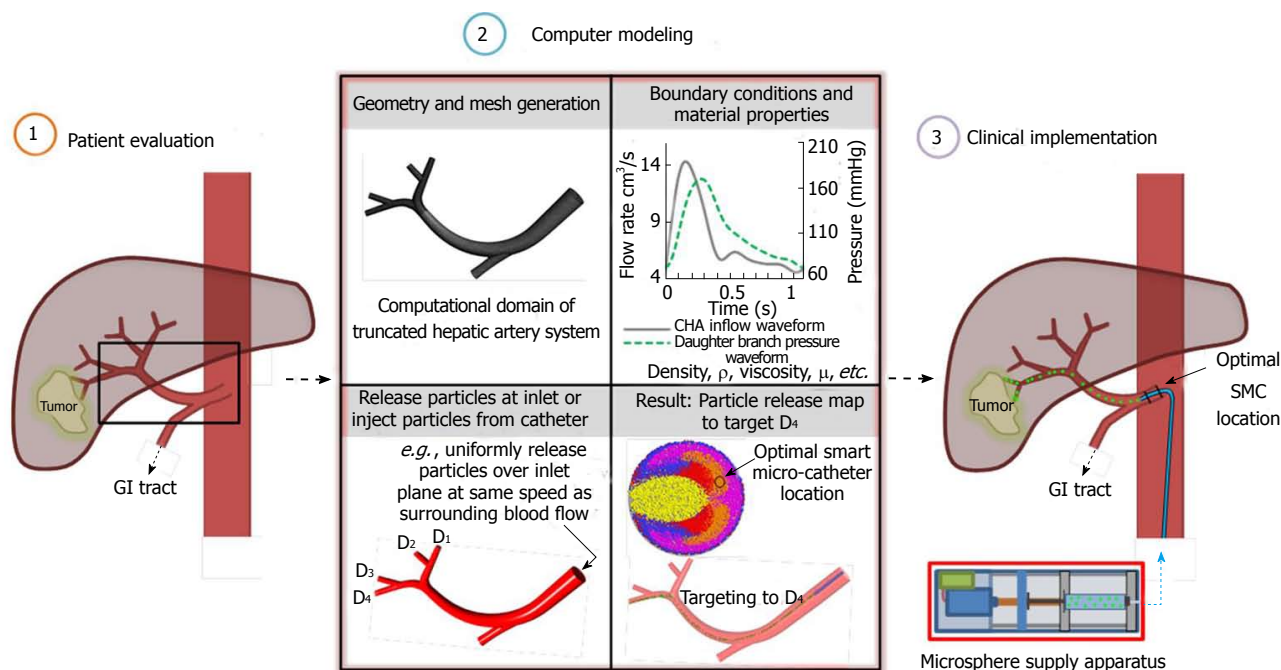


Figure 6 Computational medical management program. SMC: Smart micro-catheter.

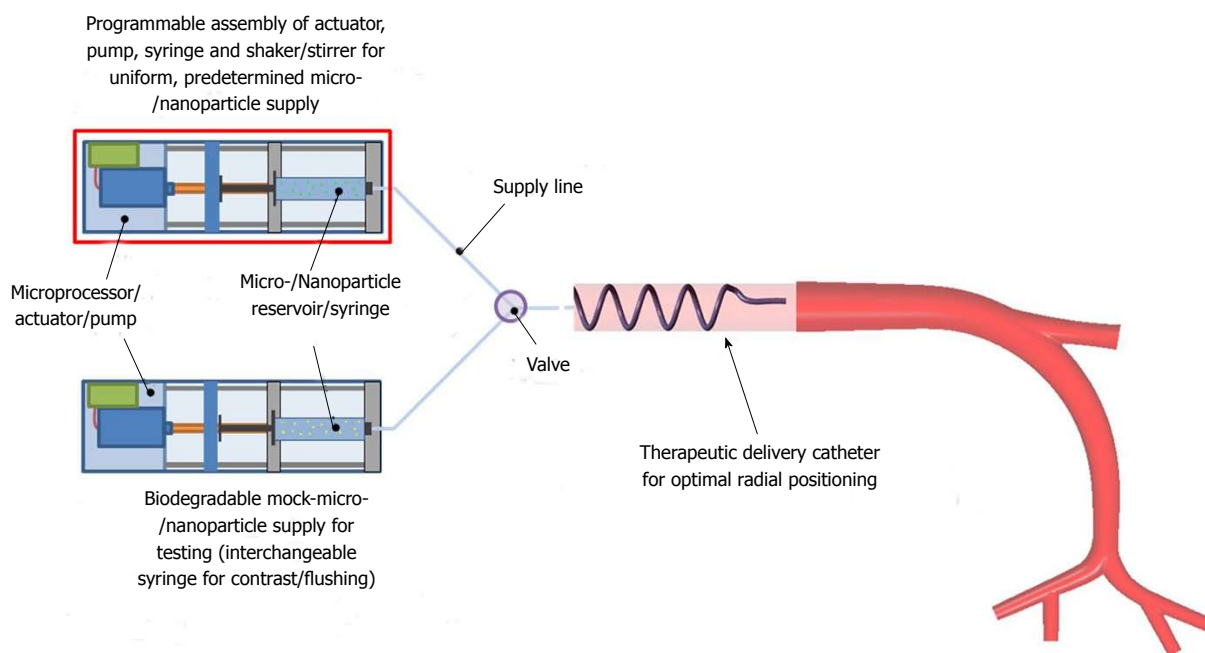


Figure 7 Proposed components of the medicine supply apparatus. (Reprinted from Ref.<sup>[118]</sup> with permission from Elsevier).

proposed to achieve direct tumor-targeting. The main objective of the SMC is to provide precise intra-arterial positioning of the particle injection stream, while the main objective of the MSA is to supply the particle stream to the SMC at the appropriate interval and speed for targeting. Figure 7 illustrates sample concepts for each device.

**Experimental and computational studies:** As an initial validation of this direct tumor-targeting strategy, Richards *et al.*<sup>[114]</sup> performed experimental studies in a scaled-up,

rigid hepatic artery system with steady Newtonian-fluid flow. Using the generated particle release map from the corresponding computational simulation, it was demonstrated that specific downstream arteries could be targeted by precisely positioning the particle injection region upstream. While additional computational studies have demonstrated the feasibility of this technique under more realistic conditions such as transient pulsatile flow, a patient-specific geometry, and flexible arterial walls<sup>[111-113,115]</sup>, future experimental studies will need to verify these findings.

## CONCLUSION

In this review article, we compared and discussed different drug-delivery devices and drug-targeting methodologies using pulmonary or intravascular routes, as well as related computational fluid dynamics techniques and applications. Drug-targeting has the potential to greatly enhance drug-delivery efficacy, reduce side effects, and lower treatment cost. However, the vast majority of drug-targeting studies assume that the drug-particles are already at the target site or at least in its direct vicinity.

In this review, drug-delivery methodologies, drug types and drug-delivery devices are discussed with examples in two major application areas: (1) inhaled drug-aerosol delivery into human lung-airways; and (2) intravascular drug-delivery for solid tumor targeting. The major problem addressed is how to deliver efficiently the drug-particles from the entry/infusion point to the target site. Experimental results so far are based on simple laboratory studies and restrictive animal tests. Concerning computational fluid-particle dynamics, further advancements in software and hardware are needed to develop faster, more realistic and accurate computer simulation models.

### Pulmonary drug targeting

As mentioned, the selection of drug delivery device and drug aerosol formulation has a critical influence on pulmonary drug-targeting efficiency. To further optimize the pulmonary drug-delivery process and provide more effective therapy, the focus should be on the following aspects: (1) control the aerosol generation process<sup>[119]</sup>; (2) control the aerosol deposition patterns in lung airways; and (3) control the aerosol transport after penetrating the air-blood barriers. Specifically, due to the scarcity of air-blood barrier transport of drug aerosols *via* the lung route, it is of interest that to know to what extent drug-aerosols can be absorbed or cleared. That will affect the systemic drug delivery effectiveness, including modulation of solubility in the airway-surface layers and the permeability across the epithelial barrier to improve pulmonary bio-availability of the active pharmaceutical ingredients. It should also control the clearance process to prolong the action of the active pharmaceutical ingredients.

### Solid-tumor targeting

It is evident that the micron- or nano-drugs have to be delivered directly from the infusion point to the pre-determined tumor site to guarantee high treatment efficiency, minimal side-effects, and low cost. Such a direct drug delivery equates to optimal tumor targeting. Concerning the promising smart micro-catheter system, *i.e.*, a combined and synchronized SMC and MSA assembly, SMC-device miniaturization and system testing in the lab and clinical environment are ongoing and planned projects.

## REFERENCES

- 1 Ruge CA, Kirch J, Lehr CM. Pulmonary drug delivery: from generating aerosols to overcoming biological barriers-therapeutic possibilities and technological challenges. *Lancet Respir Med* 2013; **1**: 402-413 [PMID: 24429205]
- 2 Kunda NK, Somavarapu S, Gordon SB, Hutcheon GA, Saleem IY. Nanocarriers targeting dendritic cells for pulmonary vaccine delivery. *Pharm Res* 2013; **30**: 325-341 [PMID: 23054093 DOI: 10.1007/s11095-012-0891-5]
- 3 Sahane S, Nikhar A, Bhaskaran S, Mundhada D. Dry powder inhaler: An advance technique for pulmonary drug delivery system. *IJPCS* 2012; **1**: 1027-1034. Available from: URL: <http://www.ijpcsonline.com/files/63-209A.pdf>
- 4 Sandhya P, Fatima A, Afreen G, Afreen A. A review on drug targeting to respiratory system. *IJPCS* 2013; **1**: 277-291. Available from: URL: <http://www.ijpronline.com/15.pdf>
- 5 Dalby R, Spallek M, Voshaar T. A review of the development of Respimat Soft Mist Inhaler. *Int J Pharm* 2004; **283**: 1-9 [PMID: 15363496 DOI: 10.1016/j.ijpharm.2004.06.018]
- 6 Kleinstreuer C. Biofluid dynamics: Principles and selected applications. Florida: CRC Press, 2006
- 7 Sumbly B, Slater A, Atkins PJ, Prime D. Review of dry powder inhalers. *Adv Drug Deliv Rev* 1997; **26**: 51-58 [PMID: 10837532 DOI: 10.1016/S0169-409X(97)00510-3]
- 8 Sanders M. Inhalation therapy: an historical review. *Prim Care Respir J* 2007; **16**: 71-81 [PMID: 17356785 DOI: 10.3132/pcrj.2007.00017]
- 9 Delgado A, Chou KJ, Silver EJ, Crain EF. Nebulizers vs metered-dose inhalers with spacers for bronchodilator therapy to treat wheezing in children aged 2 to 24 months in a pediatric emergency department. *Arch Pediatr Adolesc Med* 2003; **157**: 76-80 [PMID: 12517199 DOI: 10.1001/archpedi.157.1.76]
- 10 Gangurde H, Chordiya M, Baste N, Tamizharasi S, Upasani C. Approaches and devices used in pulmonary drug delivery system: a review. *AJPRHC* 2012; **4**: 11-27. Available from: URL: <http://www.ajprhc.in/index.php/ajprhc/article/download/18/17>
- 11 Newman SP. Principles of metered-dose inhaler design. *Respir Care* 2005; **50**: 1177-1190 [PMID: 16122401]
- 12 Dolovich MB, Dhand R. Aerosol drug delivery: developments in device design and clinical use. *Lancet* 2011; **377**: 1032-1045 [PMID: 21036392 DOI: 10.1016/S0140-6736(10)60926-9]
- 13 Longest PW, Tian G, Walenga RL, Hindle M. Comparing MDI and DPI aerosol deposition using in vitro experiments and a new stochastic individual path (SIP) model of the conducting airways. *Pharm Res* 2012; **29**: 1670-1688 [PMID: 22290350 DOI: 10.1007/s11095-012-0691-y]
- 14 Newman SP, Pavia D, Morén F, Sheahan NF, Clarke SW. Deposition of pressurised aerosols in the human respiratory tract. *Thorax* 1981; **36**: 52-55 [PMID: 7292382 DOI: 10.1136/thx.36.1.52]
- 15 Silverman R, Sellers J, Greene S, Flaster E, Colice G. Comparison of the Maxair Autohaler to wet nebulizer in patients with acute asthma. *Chest* 1998; **114**: 766-770 [PMID: 9743164 DOI: 10.1378/chest.114.3.766]
- 16 Lenney J, Innes JA, Crompton GK. Inappropriate inhaler use: assessment of use and patient preference of seven inhalation devices. *EDICI. Respir Med* 2000; **94**: 496-500 [PMID: 10868714 DOI: 10.1053/rmed.1999.0767]
- 17 Price D, Thomas M, Mitchell G, Niziol C, Featherstone R. Improvement of asthma control with a breath-actuated pressurised metered dose inhaler (BAI): a prescribing claims study of 5556 patients using a traditional pressurised metered dose inhaler (MDI) or a breath-actuated device. *Respir Med* 2003; **97**: 12-19 [PMID: 12556005 DOI: 10.1053/rmed.2002.1426]
- 18 Barry PW, O'Callaghan C. Inhalational drug delivery from seven different spacer devices. *Thorax* 1996; **51**: 835-840 [PMID: 8795674 DOI: 10.1136/thx.51.8.835]
- 19 Kesser KC, Geller DE. New aerosol delivery devices for cystic fibrosis. *Respir Care* 2009; **54**: 754-767; discussion 767-768 [PMID: 19467162]
- 20 Zhang X, Ma Y, Zhang L, Zhu J, Jin F. The development of a novel dry powder inhaler. *Int J Pharm* 2012; **431**: 45-52 [PMID: 22429205]



- 22543053 DOI: 10.1016/j.ijpharm.2012.04.019]
- 21 **Islam N**, Gladki E. Dry powder inhalers (DPIs)—a review of device reliability and innovation. *Int J Pharm* 2008; **360**: 1-11 [PMID: 18583072 DOI: 10.1016/j.ijpharm.2008.04.044]
- 22 **Newman SP**, Busse WW. Evolution of dry powder inhaler design, formulation, and performance. *Respir Med* 2002; **96**: 293-304 [PMID: 12113378 DOI: 10.1053/rmed.2001.1276]
- 23 **Finlay WH**. The mechanics of inhaled pharmaceutical aerosols: an introduction. Pittsburgh: Academic Press, 2001
- 24 **Waldrep JC**, Berlinski A, Dhand R. Comparative analysis of methods to measure aerosols generated by a vibrating mesh nebulizer. *J Aerosol Med* 2007; **20**: 310-319 [PMID: 17894537 DOI: 10.1089/jam.2007.0538]
- 25 **Rau JL**. The inhalation of drugs: advantages and problems. *Respir Care* 2005; **50**: 367-382 [PMID: 15737247]
- 26 **Hochrainer D**, Hölz H, Kreher C, Scaffidi L, Spallek M, Wachtel H. Comparison of the aerosol velocity and spray duration of Respimat Soft Mist inhaler and pressurized metered dose inhalers. *J Aerosol Med* 2005; **18**: 273-282 [PMID: 16181002 DOI: 10.1089/jam.2005.18.273]
- 27 **Hess DR**. Aerosol delivery devices in the treatment of asthma. *Respir Care* 2008; **53**: 699-723; discussion 723-725 [PMID: 18501026]
- 28 **Anderson P**. Use of Respimat Soft Mist inhaler in COPD patients. *Int J Chron Obstruct Pulmon Dis* 2006; **1**: 251-259 [PMID: 18046862 DOI: 10.2147/copd.2006.1.3.251]
- 29 **Geller DE**. New liquid aerosol generation devices: systems that force pressurized liquids through nozzles. *Respir Care* 2002; **47**: 1392-1404; discussion 1404-1405 [PMID: 12467498]
- 30 **Vecellio L**. The mesh nebuliser: A recent technical innovation for aerosol delivery. *Breathe* 2006; **2**: 253-260
- 31 **Amani A**, Amini MA, Ali HS, York P. Alternatives to conventional suspensions for pulmonary drug delivery by nebulisers: a review. *J Pharm Sci* 2011; **100**: 4563-4570 [PMID: 21671227 DOI: 10.1002/jps.22665]
- 32 **Chou KJ**, Cunningham SJ, Crain EF. Metered-dose inhalers with spacers vs nebulizers for pediatric asthma. *Arch Pediatr Adolesc Med* 1995; **149**: 201-205 [PMID: 7849885 DOI: 10.1001/archpedi.1995.02170140083015]
- 33 **Batra V**, Sethi GR, Sachdev HP. Comparative efficacy of jet nebulizer and metered dose inhaler with spacer device in the treatment of acute asthma. *Indian Pediatr* 1997; **34**: 497-503 [PMID: 9357205]
- 34 **Dhuper S**, Chandra A, Ahmed A, Bista S, Moghekar A, Verma R, Chong C, Shim C, Cohen H, Choksi S. Efficacy and cost comparisons of bronchodilator administration between metered dose inhalers with disposable spacers and nebulizers for acute asthma treatment. *J Emerg Med* 2011; **40**: 247-255 [PMID: 19081697 DOI: 10.1016/j.jemermed.2008.06.029]
- 35 **Tarsin WY**, Pearson SB, Assi KH, Chrystyn H. Emitted dose estimates from Seretide Diskus and Symbicort Turbuhaler following inhalation by severe asthmatics. *Int J Pharm* 2006; **316**: 131-137 [PMID: 16584855 DOI: 10.1016/j.ijpharm.2006.02.040]
- 36 **Smith IJ**, Bell J, Bowman N, Everard M, Stein S, Weers JG. Inhaler devices: what remains to be done? *J Aerosol Med Pulm Drug Deliv* 2010; **23** Suppl 2: S25-S37 [PMID: 21133798 DOI: 10.1089/jamp.2010.0853]
- 37 **Nokhodchi A**, Larhrib H. Overcoming the undesirable properties of dry-powder inhalers with novel engineered mannitol particles. *Ther Deliv* 2013; **4**: 879-882 [PMID: 23919464 DOI: 10.4155/TDE.13.64]
- 38 **Berlinski A**, Waldrep JC. Four hours of continuous albuterol nebulization. *Chest* 1998; **114**: 847-853 [PMID: 9743177 DOI: 10.1378/chest.114.3.847]
- 39 **D'Addio SM**, Prud'homme RK. Controlling drug nanoparticle formation by rapid precipitation. *Adv Drug Deliv Rev* 2011; **63**: 417-426 [PMID: 21565233 DOI: 10.1016/j.addr.2011.04.005]
- 40 **Heng D**, Lee SH, Ng WK, Chan HK, Kwek JW, Tan RB. Novel alternatives to reduce powder retention in the dry powder inhaler during aerosolization. *Int J Pharm* 2013; **452**: 194-200 [PMID: 23680726 DOI: 10.1016/j.ijpharm.2013.05.006]
- 41 **Smutney CC**, Grant M, Kinsey PS. Device factors affecting pulmonary delivery of dry powders. *Ther Deliv* 2013; **4**: 939-949 [PMID: 23919473 DOI: 10.4155/tde.13.77]
- 42 **Friebel C**, Steckel H, Müller BW. Rational design of a dry powder inhaler: device design and optimisation. *J Pharm Pharmacol* 2012; **64**: 1303-1315 [PMID: 22881442 DOI: 10.1111/j.2042-7158.2012.01525.x]
- 43 **Kakade PP**, Versteeg HK, Hargrave GK, Genova P, Williams Iii RC, Deaton D. Design optimization of a novel pMDI actuator for systemic drug delivery. *J Aerosol Med* 2007; **20**: 460-474 [PMID: 18158718 DOI: 10.1089/jam.2007.0595]
- 44 **Watts AB**, McConville JT, Williams RO. Current therapies and technological advances in aqueous aerosol drug delivery. *Drug Dev Ind Pharm* 2008; **34**: 913-922 [PMID: 18663654 DOI: 10.1080/03639040802144211]
- 45 **Chrystyn H**, Niederlaender C. The Genuair® inhaler: a novel, multidose dry powder inhaler. *Int J Clin Pract* 2012; **66**: 309-317 [PMID: 22340451 DOI: 10.1111/j.1742-1241.2011.02832.x]
- 46 **Addington WR**, Miller SP, Phelipa MM, Stephens RE. Nebulizer having flow meter function. United States patent US 8333190 B2. 2012 Dec 18
- 47 **Behara SR**, Farkas DR, Hindle M, Longest PW. Development of a high efficiency dry powder inhaler: effects of capsule chamber design and inhaler surface modifications. *Pharm Res* 2014; **31**: 360-372 [PMID: 23949304 DOI: 10.1007/s11095-013-1165-6]
- 48 **Kleinstreuer C**, Zhang Z, Li Z, Roberts WL, Rojas C. A new methodology for targeting drug-aerosols in the human respiratory system. *Int J Heat Mass Transfer* 2008; **51**: 5578-5589 [DOI: 10.1016/j.jheheatmasstransfer.2008.04.052]
- 49 **Dawar S**, Singh N, Kanwar RK, Kennedy RL, Veedu RN, Zhou SF, Krishnakumar S, Hazra S, Sasidharan S, Duan W, Kanwar JR. Multifunctional and multitargeted nanoparticles for drug delivery to overcome barriers of drug resistance in human cancers. *Drug Discov Today* 2013; **18**: 1292-1300 [PMID: 24055842 DOI: 10.1016/j.drudis.2013.09.009]
- 50 **Zhang Z**, Kleinstreuer C, Hyun S. Size-change and deposition of conventional and composite cigarette smoke particles during inhalation in a subject-specific airway model. *J Aerosol Sci* 2012; **46**: 34-52 [DOI: 10.1016/j.jaerosci.2011.12.002]
- 51 **Babincova M**, Babinec P. Magnetic drug delivery and targeting: principles and applications. *Biomed Pap Med Fac Univ Palacky Olomouc Czech Repub* 2009; **153**: 243-250 [PMID: 20208962 DOI: 10.5507/bp.2009.042]
- 52 **Feng Y**, Kleinstreuer C. Analysis of non-spherical particle transport in complex internal shear flows. *Physics of Fluids* 2013; **25**: 091904 [DOI: 10.1063/1.4821812]
- 53 **Feng Y**, Kleinstreuer C. Micron-particle transport, interactions and deposition in triple lung-airway bifurcations using a novel modeling approach. *J Aerosol Sci* 2014; **71**: 1-15 [DOI: 10.1016/j.jaerosci.2014.01.003]
- 54 **Tu J**, Inthavong K, Ahmadi G. Computational Fluid and Particle Dynamics (CFPD): An Introduction. In: Computational Fluid and Particle Dynamics in the Human Respiratory System. Germany: Springer, 2013
- 55 **Ibrahim M**, Garcia-Contreras L. Mechanisms of absorption and elimination of drugs administered by inhalation. *Ther Deliv* 2013; **4**: 1027-1045 [PMID: 23919477 DOI: 10.4155/tde.13.67]
- 56 **Zhang Z**, Kleinstreuer C, Feng Y. Vapor deposition during cigarette smoke inhalation in a subject-specific human airway model. *J Aerosol Sci* 2012; **53**: 40-60 [DOI: 10.1016/j.jaerosci.2012.05.008]
- 57 **Kolanjiyil AV**, Kleinstreuer C. Nanoparticle mass transfer from lung airways to systemic regions--Part I: Whole-lung aerosol dynamics. *J Biomech Eng* 2013; **135**: 121003 [PMID: 24008503 DOI: 10.1115/1.4025332]
- 58 **Kolanjiyil AV**, Kleinstreuer C. Nanoparticle mass transfer from lung airways to systemic regions--Part II: Multi-compartmental modeling. *J Biomech Eng* 2013; **135**: 121004 [PMID:



- 24008585 DOI: 10.1115/1.4025333]
- 59 **Wong W**, Fletcher DF, Traini D, Chan HK, Young PM. The use of computational approaches in inhaler development. *Adv Drug Deliv Rev* 2012; **64**: 312-322 [PMID: 22063020 DOI: 10.1016/j.addr.2011.10.004]
  - 60 **Crosland BM**, Johnson MR, Matida EA. Characterization of the spray velocities from a pressurized metered-dose inhaler. *J Aerosol Med Pulm Drug Deliv* 2009; **22**: 85-97 [PMID: 18956946 DOI: 10.1089/jamp.2008.0687]
  - 61 **Versteeg H**, Hargrave G, Harrington L, Shrubb I, Hodson D. The use of computational fluid dynamics (CFD) to predict pMDI air flows and aerosol plume formation. In: *Respiratory Drug Delivery*. 2000: 7(1)
  - 62 **Shakkeed T**, Katoshevski D, Broday DM, Amirav I. Numerical simulation of air flow and medical-aerosol distribution in an innovative nebulizer hood. *J Aerosol Med* 2005; **18**: 207-217 [PMID: 15966775 DOI: 10.1089/jam.2005.18.207]
  - 63 **Kleinstreuer C**, Shi H, Zhang Z. Computational analyses of a pressurized metered dose inhaler and a new drug-aerosol targeting methodology. *J Aerosol Med* 2007; **20**: 294-309 [PMID: 17894536 DOI: 10.1089/jam.2006.0617]
  - 64 **Worth Longest P**, Hindle M, Das Choudhuri S. Effects of generation time on spray aerosol transport and deposition in models of the mouth-throat geometry. *J Aerosol Med Pulm Drug Deliv* 2009; **22**: 67-83 [PMID: 18956949 DOI: 10.1089/jamp.2008.0692]
  - 65 **Worth Longest P**, Hindle M. Evaluation of the Respimat Soft Mist Inhaler using a concurrent CFD and in vitro approach. *J Aerosol Med Pulm Drug Deliv* 2009; **22**: 99-112 [PMID: 18956950 DOI: 10.1089/jamp.2008.0708]
  - 66 **Jiang L**, Tang Y, Zhang H, Lu X, Chen X, Zhu J. Importance of powder residence time for the aerosol delivery performance of a commercial dry powder inhaler Aerolizer®. *J Aerosol Med Pulm Drug Deliv* 2012; **25**: 265-279 [PMID: 22280548 DOI: 10.1089/jamp.2011.0908]
  - 67 **Longest PW**, Son YJ, Holbrook L, Hindle M. Aerodynamic factors responsible for the deaggregation of carrier-free drug powders to form micrometer and submicrometer aerosols. *Pharm Res* 2013; **30**: 1608-1627 [PMID: 23471640 DOI: 10.1007/s11095-013-1001-z]
  - 68 **Tong Z**, Zheng B, Yang R, Yu A, Chan H. CFD-DEM investigation of the dispersion mechanisms in commercial dry powder inhalers. *Powder Technol* 2013; **240**: 19-24 [DOI: 10.1016/j.powtec.2012.07.012]
  - 69 **Tong Z**, Yang R, Chu K, Yu A, Adi S, Chan H. Numerical study of the effects of particle size and polydispersity on the agglomerate dispersion in a cyclonic flow. *Chem Eng J* 2010; **164**: 432-441 [DOI: 10.1016/j.cej.2009.11.027]
  - 70 **Ruzycski CA**, Javaheri E, Finlay WH. The use of computational fluid dynamics in inhaler design. *Expert Opin Drug Deliv* 2013; **10**: 307-323 [PMID: 23289401 DOI: 10.1517/17425247.2013.753053]
  - 71 **Kleinstreuer C**, Seelecke S. Inhaler system for targeted maximum drug-aerosol delivery. United States patent US 7900625 B2. 2011 May 8
  - 72 **Hindle M**, Longest PW. Condensational growth of combination drug-excipient submicrometer particles for targeted high-efficiency pulmonary delivery: evaluation of formulation and delivery device. *J Pharm Pharmacol* 2012; **64**: 1254-1263 [PMID: 22881438 DOI: 10.1111/j.2042-7158.2012.01476.x]
  - 73 **Hindle M**, Longest PW. Evaluation of enhanced condensational growth (ECG) for controlled respiratory drug delivery in a mouth-throat and upper tracheobronchial model. *Pharm Res* 2010; **27**: 1800-1811 [PMID: 20454837 DOI: 10.1007/s11095-010-0165-z]
  - 74 **Longest PW**, Hindle M. Numerical Model to Characterize the Size Increase of Combination Drug and Hygroscopic Excipient Nanoparticle Aerosols. *Aerosol Sci Technol* 2011; **45**: 884-899 [PMID: 21804683 DOI: 10.1080/02786826.2011.566592]
  - 75 **Dames P**, Gleich B, Flemmer A, Hajek K, Seidl N, Wiekhorst F, Eberbeck D, Bittmann I, Bergemann C, Weyh T, Trahms L, Rosenecker J, Rudolph C. Targeted delivery of magnetic aerosol droplets to the lung. *Nat Nanotechnol* 2007; **2**: 495-499 [PMID: 18654347 DOI: 10.1038/nnano.2007.217]
  - 76 **Plank C**. Nanomagnetosols: magnetism opens up new perspectives for targeted aerosol delivery to the lung. *Trends Biotechnol* 2008; **26**: 59-63 [PMID: 18191261 DOI: 10.1016/j.tibtech.2007.11.001]
  - 77 **Yang HW**, Hua MY, Liu HL, Huang CY, Wei KC. Potential of magnetic nanoparticles for targeted drug delivery. *Nanotechnol Sci Appl* 2012; **5**: 73-86 [PMID: 24198498 DOI: 10.2147/NSA.S35506]
  - 78 **McBride AA**, Price DN, Lamoureux LR, Elmaoued AA, Vargas JM, Adolphi NL, Muttli P. Preparation and characterization of novel magnetic nano-in-microparticles for site-specific pulmonary drug delivery. *Mol Pharm* 2013; **10**: 3574-3581 [PMID: 23964796 DOI: 10.1021/mp3007264]
  - 79 **Tewes F**, Ehrhardt C, Healy AM. Superparamagnetic iron oxide nanoparticles (SPIONs)-loaded Trojan microparticles for targeted aerosol delivery to the lung. *Eur J Pharm Biopharm* 2014; **86**: 98-104 [PMID: 24055690 DOI: 10.1016/j.ejpb.2013.09.004]
  - 80 **Arruebo M**. Drug delivery from structured porous inorganic materials. *Wiley Interdiscip Rev Nanomed Nanobiotechnol* 2012; **4**: 16-30 [PMID: 21374827 DOI: 10.1002/wnan.132]
  - 81 **Kim JW**, Xi J, Si XA. Dynamic growth and deposition of hygroscopic aerosols in the nasal airway of a 5-year-old child. *Int J Numer Method Biomed Eng* 2013; **29**: 17-39 [PMID: 23293067]
  - 82 **Mitragotri S**. In drug delivery, shape does matter. *Pharm Res* 2009; **26**: 232-234 [PMID: 18923811 DOI: 10.1007/s11095-008-9740-y]
  - 83 **Sturm R**, Hofmann W. A theoretical approach to the deposition and clearance of fibers with variable size in the human respiratory tract. *J Hazard Mater* 2009; **170**: 210-218 [PMID: 19477590 DOI: 10.1016/j.jhazmat.2009.04.107]
  - 84 **Gratton SE**, Ropp PA, Pohlhaus PD, Luft JC, Madden VJ, Napier ME, DeSimone JM. The effect of particle design on cellular internalization pathways. *Proc Natl Acad Sci USA* 2008; **105**: 11613-11618 [PMID: 18697944 DOI: 10.1073/pnas.0801763105]
  - 85 **Kaialy W**, Nokhodchi A. Engineered mannitol ternary additives improve dispersion of lactose-salbutamol sulphate dry powder inhalations. *AAPS J* 2013; **15**: 728-743 [PMID: 23591748 DOI: 10.1208/s12248-013-9476-4]
  - 86 **Mansour HM**. Advances in targeted lung nanomedicine as inhalable multifunctional microparticles & nanoparticles for pulmonary disease treatment and prevention. International Conference and Exhibition on Nanotechnology & nanomedicine. USA: Omaha Marriott, 2012: 12-14
  - 87 **Taratula O**, Kuzmov A, Shah M, Garbuzenko OB, Minko T. Nanostructured lipid carriers as multifunctional nanomedicine platform for pulmonary co-delivery of anticancer drugs and siRNA. *J Control Release* 2013; **171**: 349-357 [PMID: 23648833 DOI: 10.1016/j.jconrel.2013.04.018]
  - 88 **Wei Y**, Zhao L. Passive lung-targeted drug delivery systems via intravenous administration. *Pharm Dev Technol* 2014; **19**: 129-136 [PMID: 23336716 DOI: 10.3109/10837450.2012.757782]
  - 89 **Cheng Z**, Al Zaki A, Hui JZ, Muzykantor VR, Tsourkas A. Multifunctional nanoparticles: cost versus benefit of adding targeting and imaging capabilities. *Science* 2012; **338**: 903-910 [PMID: 23161990 DOI: 10.1126/science]
  - 90 **Jang SH**, Wientjes MG, Lu D, Au JL. Drug delivery and transport to solid tumors. *Pharm Res* 2003; **20**: 1337-1350 [PMID: 14567626]
  - 91 **Cho K**, Wang X, Nie S, Chen ZG, Shin DM. Therapeutic nanoparticles for drug delivery in cancer. *Clin Cancer Res* 2008; **14**: 1310-1316 [PMID: 18316549 DOI: 10.1158/1078-0432.CCR-07-1441]
  - 92 **Yuan F**, Leunig M, Huang SK, Berk DA, Papahadjopoulos D, Jain RK. Microvascular permeability and interstitial pen-

- etration of sterically stabilized (stealth) liposomes in a human tumor xenograft. *Cancer Res* 1994; **54**: 3352-3356 [PMID: 8012948]
- 93 **Hobbs SK**, Monsky WL, Yuan F, Roberts WG, Griffith L, Torchilin VP, Jain RK. Regulation of transport pathways in tumor vessels: role of tumor type and microenvironment. *Proc Natl Acad Sci USA* 1998; **95**: 4607-4612 [PMID: 9539785 DOI: 10.1073/pnas.95.8.4607]
  - 94 **Yuan F**, Salehi HA, Boucher Y, Vasthare US, Tuma RF, Jain RK. Vascular permeability and microcirculation of gliomas and mammary carcinomas transplanted in rat and mouse cranial windows. *Cancer Res* 1994; **54**: 4564-4568 [PMID: 8062241]
  - 95 **Yuan F**, Dellian M, Fukumura D, Leunig M, Berk DA, Torchilin VP, Jain RK. Vascular permeability in a human tumor xenograft: molecular size dependence and cutoff size. *Cancer Res* 1995; **55**: 3752-3756 [PMID: 7641188]
  - 96 **Bundgaard M**. Transport pathways in capillaries--in search of pores. *Annu Rev Physiol* 1980; **42**: 325-336 [PMID: 6996584 DOI: 10.1146/annurev.ph.42.030180.001545]
  - 97 **Maeda H**. The enhanced permeability and retention (EPR) effect in tumor vasculature: the key role of tumor-selective macromolecular drug targeting. *Adv Enzyme Regul* 2001; **41**: 189-207 [PMID: 11384745 DOI: 10.1016/S0065-2571(00)00013-3]
  - 98 **Maeda H**, Wu J, Sawa T, Matsumura Y, Hori K. Tumor vascular permeability and the EPR effect in macromolecular therapeutics: a review. *J Control Release* 2000; **65**: 271-284 [PMID: 10699287 DOI: 10.1016/S0168-3659(99)00248-5]
  - 99 **Maeda H**. Tumor-selective delivery of macromolecular drugs via the EPR effect: background and future prospects. *Bioconjug Chem* 2010; **21**: 797-802 [PMID: 20397686 DOI: 10.1021/bc100070g]
  - 100 **Muggia FM**. Doxorubicin-polymer conjugates: further demonstration of the concept of enhanced permeability and retention. *Clin Cancer Res* 1999; **5**: 7-8 [PMID: 9918196]
  - 101 **Kamaly N**, Xiao Z, Valencia PM, Radovic-Moreno AF, Farokhzad OC. Targeted polymeric therapeutic nanoparticles: design, development and clinical translation. *Chem Soc Rev* 2012; **41**: 2971-3010 [PMID: 22388185 DOI: 10.1039/c2cs15344k]
  - 102 **Peer D**, Karp JM, Hong S, Farokhzad OC, Margalit R, Langer R. Nanocarriers as an emerging platform for cancer therapy. *Nat Nanotechnol* 2007; **2**: 751-760 [PMID: 18654426 DOI: 10.1038/nnano.2007.387]
  - 103 **De Jong WH**, Borm PJ. Drug delivery and nanoparticles: applications and hazards. *Int J Nanomedicine* 2008; **3**: 133-149 [PMID: 18686775 DOI: 10.2147/IJN.S596]
  - 104 **Nie S**. Understanding and overcoming major barriers in cancer nanomedicine. *Nanomedicine (Lond)* 2010; **5**: 523-528 [PMID: 20528447 DOI: 10.2217/nnm.10.23]
  - 105 **Blanco E**, Kessinger CW, Sumer BD, Gao J. Multifunctional micellar nanomedicine for cancer therapy. *Exp Biol Med* (Maywood) 2009; **234**: 123-131 [PMID: 19064945 DOI: 10.3181/0808-MR-250]
  - 106 **Yoo JW**, Doshi N, Mitragotri S. Adaptive micro and nanoparticles: temporal control over carrier properties to facilitate drug delivery. *Adv Drug Deliv Rev* 2011; **63**: 1247-1256 [PMID: 21605607 DOI: 10.1016/j.addr.2011.05.004]
  - 107 **Mornet S**, Vasseur S, Grasset F, Duguet E. Magnetic nanoparticle design for medical diagnosis and therapy. *J Mater Chem* 2004; **14**: 2161-2175 [DOI: 10.1039/B402025A]
  - 108 **Kayal S**, Bandyopadhyay D, Mandal TK, Ramanujan RV. The flow of magnetic nanoparticles in magnetic drug targeting. *RSC Advances* 2011; **1**: 238-246 [DOI: 10.1039/C1RA00023C]
  - 109 **Cregg P**, Murphy K, Mardinoglu A. Inclusion of interactions in mathematical modelling of implant assisted magnetic drug targeting. *Appl Math Model* 2012; **36**: 1-34 [DOI: 10.1016/j.apm.2011.05.036]
  - 110 **Kleinstreuer C**. Methods and devices for targeted injection of microspheres. United States patent US 20120190976 A1. 2010 Jul 26
  - 111 **Kleinstreuer C**, Basciano CA, Childress EM, Kennedy AS. A new catheter for tumor targeting with radioactive microspheres in representative hepatic artery systems. Part I: impact of catheter presence on local blood flow and microsphere delivery. *J Biomech Eng* 2012; **134**: 051004 [PMID: 22757492 DOI: 10.1115/1.4006684]
  - 112 **Basciano CA**. Computational particle-hemodynamics analysis applied to an abdominal aortic aneurysm with thrombus and microsphere-targeting of liver tumors (2010). Available from: URL: <http://www.lib.ncsu.edu/resolver/1840.16/7113>
  - 113 **Childress EM**, Kleinstreuer C, Kennedy AS. A new catheter for tumor-targeting with radioactive microspheres in representative hepatic artery systems--part II: solid tumor-targeting in a patient-inspired hepatic artery system. *J Biomech Eng* 2012; **134**: 051005 [PMID: 22757493 DOI: 10.1115/1.4006685]
  - 114 **Richards AL**, Kleinstreuer C, Kennedy AS, Childress E, Buckner GD. Experimental microsphere targeting in a representative hepatic artery system. *IEEE Trans Biomed Eng* 2012; **59**: 198-204 [PMID: 21965193 DOI: 10.1109/TBME.2011.2170195]
  - 115 **Childress EM**, Kleinstreuer C. Impact of fluid-structure interaction on direct tumor-targeting in a representative hepatic artery system. *Ann Biomed Eng* 2014; **42**: 461-474 [PMID: 24048712 DOI: 10.1007/s10439-013-0910-7]
  - 116 **Niven R**. Prospects and challenges: inhalation delivery systems. *Ther Deliv* 2013; **4**: 519-522 [PMID: 23647267 DOI: 10.4155/tde.13.18]
  - 117 **Muchão FP**, Filho LV. Advances in inhalation therapy in pediatrics. *J Pediatr (Rio J)* 2010; **86**: 367-376 [PMID: 20938588 DOI: 10.2223/JPED.2024]
  - 118 **Kleinstreuer C**, Childress EM, Kennedy AS. Targeted Drug Delivery: Multifunctional Nanoparticles and Direct Micro-drug Delivery to Tumors In: Becker S, Kuznetsov, A. Transport in Biological Media. San Diego: Academic Press, 2012: 392-414

P- Reviewer: Aggarwal D S- Editor: Ji FF L- Editor: A  
E- Editor: Wu HL



## Relational coordination and healthcare management in lung cancer

José Antonio Vinagre Romero, Juan Del Llano Señarís, Carmen De Pablos Heredero, Mark Nuijten

José Antonio Vinagre Romero, Clinical Management, Business Organization, Entrepreneurship, Health Administration, Business Organization, Universidad Rey Juan Carlos, Respiratory Unit at La Paz University Hospital, 28046 Madrid, Spain

Juan Del Llano Señarís, Community Health, Gaspar Casal Foundation, Universidad Pompeu Fabra-CRES, 28006 Madrid, Spain

Carmen De Pablos Heredero, Economics, Rey Juan Carlos University, School of Social Sciences, Doctoral Program in Business Organization and Entrepreneurship, 28032 Madrid, Spain

Mark Nuijten, Rotterdam School of Management, Erasmus University, University of Maastricht and the University of Groningen, 3062 PA, Rotterdam, The Netherlands

**Author contributions:** All authors contributed to this paper.

**Correspondence to:** José Antonio Vinagre Romero, RN, MSc in Clinical Management, MSc in Business Organization, MSc in Entrepreneurship, Master of Health Administration, PhD Candidate in Business Organization, Universidad Rey Juan Carlos, Respiratory Unit at La Paz University Hospital, Paseo de la Castellana 261, 28046 Madrid,

Spain. [joseantonio.vinagre@salud.madrid.org](mailto:joseantonio.vinagre@salud.madrid.org)

Telephone: +34-61-6860921

Received: August 12, 2014 Revised: October 22, 2014

Accepted: October 31, 2014

Published online: December 16, 2014

### Abstract

In the current socio-economic scenario characterized by a growing shortage of resources and progressive budget constraints, the need to better coordinate processes in health institutions appears as a relevant aspect to ensure the future sustainability of system. In this sense, Relational Coordination (RC) provides a valuable opportunity for the reconfiguration of clinical guidelines concerning isolated single-level considerations. In this research the RC model has been applied to explain best results in the process of diagnosing and offering clinical treatments for lung cancer. Lung cancer presents the higher rates of tumor's mortality worldwide. Through unstructured and informal interviews with clinicians at both levels (Primary/Specialist Care), a diagnosis of the situation in relation to joint management of lung cancer is provided. Solutions of continuity in terms of coordi-

nation are explained due to the observation of lack of effective knowledge transfer between the two levels. It is this disconnection which justifies the introduction of a modified model of RC for the study and implementation of transfer relations between the knowledge holders, in order to structure consolidated and cooperative evidence-based models that lead to a substantial shortening in the response times with a marked outcomes improvement. To our knowledge, the application of this model to a Public Health problem bringing together both levels of care, hasn't been made till now.

© 2014 Baishideng Publishing Group Inc. All rights reserved.

**Key words:** Relational Coordination; Lung cancer; Clinical pathway; Dialogic practices; High performance work systems; Healthcare performance

**Core tip:** Innovative managerial frameworks have to be put into practice when treating severe diseases. Relational Coordination makes possible to enhance inter-level knowledge networks to obtain better outcomes from the perspective of the National Health System and the patients. Through systematic revision, it has been checked that only in the fields of Endocrinology and Psychiatry have these frameworks been applied. This model tries to establish a coordinative solution within the field of Oncology, implementing the Theory of Relational Coordination as a tool to get optimal results in lung cancer.

Romero JAV, Señarís JDL, Heredero CDP, Nuijten M. Relational coordination and healthcare management in lung cancer. *World J Clin Cases* 2014; 2(12): 757-768 Available from: URL: <http://www.wjgnet.com/2307-8960/full/v2/i12/757.htm> DOI: <http://dx.doi.org/10.12998/wjcc.v2.i12.757>

### INTRODUCTION

In the current schemes of complex pathologies manage-



ment, collaborative scenarios are required in order to get to an integral coordination of health problems *via* multi-level strategies<sup>[1-3]</sup>. This statement acquires higher importance once we consider some concrete disease processes that, due to their increasing incidence and associated costs from both the patient's and the National Health System's (NHS) perspective, constitute core objectives for specific interventions that may reduce time to take accurate decisions headed to resolute, chronify or minimize the pain caused by the disorder. Coordination networks building and optimization of multi-level tacit knowledge transfer, would provide cost containment per patient stay to the NHS and to the social welfare system, contributing this way, to increase Quality Adjusted Life Years decreasing, as well, Disability Adjusted Life Years.

The objective of this study is to apply the Relational Coordination (RC) Model<sup>[4-6]</sup> to a determined health problem in order to implement the appropriate treatment trajectories based on continual permutation of actions<sup>[7]</sup> that return positive outcomes on the indicators formerly mentioned. Although, as far as we know, this model has proven very good results in hospitals, nothing has been performed using this model to check out the effectiveness of coordination strategies between levels of care, when considering the design of common pathways to treat successfully neoplasia as a serious Public Health concern.

To enforce this objective, lung cancer has been selected as an example of great relevance disorder. This is due to: its really important Disease Load<sup>[8,9]</sup>, high treatment cost<sup>[10,11]</sup>, social coverage of disabilities, side-effects on productivity<sup>[12]</sup>, assistance discontinuity between Primary (PC) and Specialized Care (SC)<sup>[13]</sup> and lack of common recognized procedures and pathways between them and within every isolated level.

This study is focused on comparing actual circuits that patients from PC follow until they get to their reference hospital (in this study we consider a high complexity one, Beveridge typology within a National Health System, with its made-to-measure design of Lung Cancer Clinical Pathway), with our proposal of modified, multilevel RC model applied to clinical trajectories that permit assistance continuity.

As a consequence, it is absolutely necessary to build a clinical alert system triggered by proven suspicion of neoplasia. This needs to be in accordance with the next healthcare level (SC) to, under the premise of evidence-based clinical practices, develop quick completion check-lists that enable immediate<sup>[14]</sup> transference of patients to the adequate level, using information technologies as preferred communication channel<sup>[15,16]</sup>.

With respect to inter-level coordination, we can highlight that this is not a clinical routine. As scientific literature points out, this cooperative strategy is put into practice by medical specialties not or discretely related to Oncology, such as Endocrinology o Psychiatry. Actually, we find no evidence of cooperative inter-level strategies being carried out in the field of Oncology<sup>[17]</sup>. Difficulties in structuring these kinds of practices lie on the basis of knowledge transfer<sup>[18,19]</sup> in organizations characterized by the dominance of its tacit component<sup>[20,21]</sup> that rarely

show High-Performance Work Systems (HPWS) practices<sup>[22]</sup>. Furthermore, organizational designs for effective and efficient management of oncologic diseases have to be both adaptative and dynamic<sup>[23]</sup> to be aligned with the state-of-the-art advances recognized in gold standards.

To this respect, RC appears as a high-traceable bi-directional tool to provide excellence in neoplastic lung disease treatment. The model theorized by Gittell<sup>[5]</sup> offers a global coordinative vision of the organizational process, helping to figure out inefficiencies that can be corrected by initializing and implementing cooperative practices and, as a result, proactive organizational designs that tend to rationalize use of resources. Additionally, it contributes to establish optimal relational dimensions for potential efficiencies of scale and scope depending on the attributes of relational and intellectual capital within the organization<sup>[24-27]</sup>.

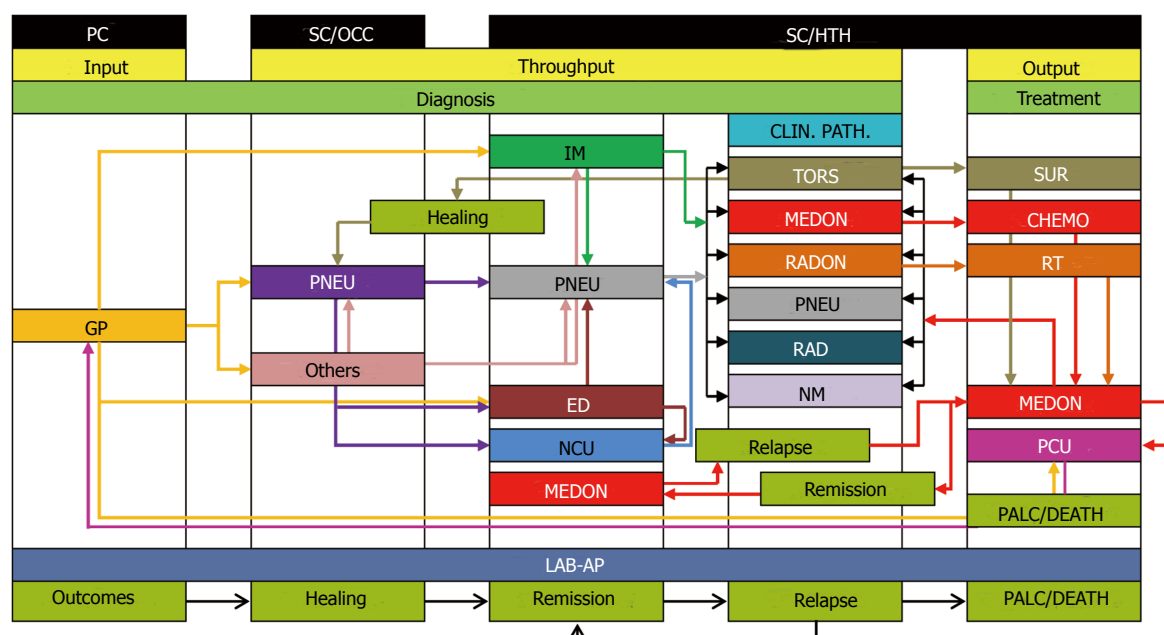
A noteworthy aspect of the suitability of the model of choice is supported by the complement that offers for the integration of related scientific approaches within the field of Business Organization, such as Operational Management. This will allow the development of further studies to refine reengineering process *via* supply-chain, thus contributing to the optimization of both the intermediate (surrogate-end-points) and the final results observed in patients (outcomes), and in the income mediated by Risk Adjustment Systems<sup>[28]</sup> used in health financing. Thus, if the inefficiencies inherent in the coordination process of the disease are debugged, additional financial returns (based on capitation criteria related to the number of processes) could be achieved (even from the health organization's perspective with regard to cost-efficiency). Another feature that makes Gittell's<sup>[5]</sup> model ideal for our purpose, is that it previously develops a series of tables analyzing HPWS practices, correlating its absence or presence with RC and, consequently, with final outcomes. Thus, the same model before being implemented, allows a diagnosis of the situation in terms of the practices mentioned. Once conclusions resulting from field work have been extracted, the implementation of the model can lead to the development of the absent figures, resulting in a multidirectional dynamic feedback identifiable with the continuous improvement cycle<sup>[29]</sup>.

Moreover, and in a methodological approach, given the intangible nature of the concepts that promote operational developments in the organization as well as their interaction and mutual influence, the model enables the application of multivariate analysis techniques focused on structural equations. This has the potential to provide greater rigor and validity when checking the assumptions in a context of real research.

In addition, *via* RC valuable information it would be possible to extend the network (regarding the possibility of generating "Value Networks"<sup>[30]</sup> in the process) to other stakeholders such as pharmaceuticals and health technology companies, and even to managerial superstructures committed on public health concerns.

Incorporating the principles of Business Organization to the clinical setting is absolutely essential to promote





**Figure 1 Inter-level process map.** Source: Authors' own elaboration. PC: Primary Care; SC/OCC: Specialist Care/Outpatient Care Center; SC/HTH: Specialist Care/High-Tech Hospital; GP: General Practitioner; PNEU: Pneumology; IM: Internal Medicine; ED: Emergency Department; NCU: Neoplasia Consulting Unit; MEDON: Medical Oncology; TORS: Thoracic Surgery; RADON: Radiation Oncology; RAD: Radiology; NM: Nuclear Medicine; SUR: Surgery; CHEMO: Chemotherapy; RT: Radiotherapy; PCU: Palliative Care Unit; LAB-AP: Clinical Laboratory and Anatomical Pathology Services; PALC/DEATH: Palliative Care/Death.

the reduction of redundant, iterative processes in traditionally knowledge intensive organizations. These have ignored their role as business managers of a huge amount of resources, in interest of a pretended clinical excellence oriented to complex phenomenology and high media impact in terms of prestige, influence and fund raising, but with little residual value in the generation of efficiencies of scale and scope, given the peculiarities involved in tertiary healthcare.

Given the above, the model postulated by Gittel<sup>[4,5]</sup> having been tested previously<sup>[6]</sup> in these types of organizations, is an excellent reference for the detailed study of the relationships involved in designing healthcare procedures between the different levels. It provides the basic tools for understanding and constructing a single treatment line that does not register any undesirable delays attributable to gaps in knowledge and other factors, including relational. The model also facilitates the continuous review of the adequacy of the approaches proposed and its comparison with reference standards in relation to screening, extension study, staging, treatment, monitoring and rehabilitation of lung neoplasia.

## INTER-LEVEL PROCESS MAP AND LUNG CANCER CLINICAL PATHWAY IN A HIGH-TECH HOSPITAL OF A NATIONAL HEALTH SYSTEM

Before accessing the clinical pathway itself, there are many routes to be made by patients in their journey between the two levels of care. This route identifies itself

with the diagnosis and treatment of the disease, and represents the transition between access to primary and secondary healthcare (Figure 1). For operational reasons, it excludes access to tertiary level (rehabilitation).

To carry out the process map, unstructured interviews during the months of March, April and May 2012 have been developed with Pneumologists and General Practitioners (GP), as key agents in the user's address to the specific resources for diagnosis and treatment.

The patient's contact with the system starts at the level of PC in the Health Center, where the person requests for consultation to GP due to a series of signs and/or symptoms which may be more or less related to tumors. At this point, a series of basic tests as conventional radiology and blood analytics are required. It is here, where they may be starting to produce the first delayed diagnosis attributable to the transfer of knowledge not based on evidence, since these blood tests not always include non-specific tumor markers, but indicators of malignancy. Furthermore, in many cases, treatment is initiated based on empirical diagnosis of pneumonia, since the neoplastic process can be masked or not being clearly visible by conventional radiology.

From this first GP visit, a second one is requested for reevaluation of improvement and/or worsening of the patient. Also in this second visit, imaging and laboratory results are delivered. This time period can vary from one week to fifteen days (period in which the empirical treatment of antibiotic action produces noticeable changes in the patient's condition and laboratory data). At the persistence of symptoms or onset of signs clearly suggestive of clinical suspicion, inter-consultation part is issued to

the specialty of Pneumology (SC) based at an Outpatient Care Center (OCC). This will lead to an additional delay, although it may be attenuated in case of emergency.

While the above, it should be noted that this path is followed if the clinical manifestations clearly compromise the patient's respiratory status. However, there are not always reliable evidences of pathology as they may be semi-hidden or produce "*a priori*" events unrelated to the disease. This can lead to other specialties not specifically connected with the process, due to the absence of effective knowledge transfer between levels.

Consider, for example, the case in which the disease is indirectly manifested through referred pain in locations as knee or scapula, with inconclusive imaging tests and non-specific tumor markers requested either. In this case, when a person with referred pain consults GP and also has a history of degenerative joint disease, the first inclination is based on the therapeutic application of trauma imaging at the involved location. If this do not show alterations, to an extension diagnosis, the patient maybe referred to other specialties, *via* interconsultation, at the level of OCC, as may be Rheumatology or Traumatology (again, we would have another delay in the issuance of a firm diagnosis). To this must be added, the additional delay in the appointment date for new consultations, delays in the completion of tests that are to be applied in these services and the appointment date for review. Note, that the pain reported by the patient could be produced as a result of neurological compression due to tumor growth.

Once the presence of specific pathology related to other specialties different to Oncology is ruled out, and for a possible occurrence of respiratory and/or systemic signs, the patient may be referred back to the GP (who will likely refer the patient to another specialist in the short-term, as for example an Internal Medicine practitioner at the hospital level) or Pneumologist at OCC level.

It is vitally important to consider that these successive accumulated delays entail delayed diagnosis and may incur progression of the disease from an early stage potentially curable, to an irreversible stage where only palliative measures can be adopted.

Special mention deserves the situation in which the patient attends a first GP consultation when the disease is in an advanced stage. In this case, the GP may take two decisions: one would be immediate referral to the reference hospital emergency department. The other one would be derivation, equally immediate and avoiding waiting list, to Pneumology at OCC.

The tours in both situations are as follow. In the case of referring the patient to the high-tech hospital emergency department considered for the study, the user would be admitted in the lower course of time. Alternatively, the physician at SC may order scheduled or urgent admission according to his criteria, and even *via* emergency if the clinic is accused and limiting.

Returning to the circuit in which the disease is not clearly delimited, and placing the patient back to Pneumology at OCC, application of tumor markers and more

specific diagnostic imaging tests with their corresponding waiting times will be issued. This will finally lead to a first diagnosis of neoplastic disease, although in many cases progress is relentless, having passed the tipping point between curability and elongation of survival.

Once the diagnosis has been confirmed (after issuance of radiological and pathological opinion), the Pneumologist at OCC (based on clinical signs) will apply for patient admission at the Respiratory Unit at the reference hospital or at the Neoplasia consulting Unit (staffed by Pneumologists), also located at the hospital but belonging to the outpatient section (OCC/HTH), who predictably will speed his admission to the Respiratory Unit.

It has to be taken into consideration that, as reflected in Figure 1, in cases of nonspecific symptoms the GP or the specialist physician from other disciplines different to Pneumology, can request patient admission at an Internal Medicine Unit. Once there, and after confirming diagnosis, the patient will be placed in charge of the service consulted (Pneumology) or included directly in the clinical pathway in order to be admitted to the Respiratory Unit.

As it has been explained, to reach this clinical decision, the circuits followed by patients are often redundant and inefficient incurring incremental health expenditure and associated loss of productivity, with the aggravating factor of disease progression, which dramatically affects the effective resolution of the process due to a probability increasing of metastatic dissemination. The next step is the inclusion of the patient in the clinical pathway itself.

The Clinical Pathway Commission is a multidisciplinary board delegated by the Chief Medical Officer of the hospital, whose mission is to take collective decisions about the individualized treatment for each patient given the specific types of lung neoplasia presented. It consists of various clinical services such as Thoracic Surgery, Oncology, Radiation Oncology, Pneumology, Radiology and Nuclear Medicine, and meets in session once a week to discern treatment strategies addressing cases that present criteria for inclusion.

Previously, and once the patient has already been admitted in hospital, sequential examinations to limit the spread of the disease and rule out metastasis are conducted.

Once all results are available, which will generate a new lengthening of waiting times due to internal procedures, they are presented in clinical session to elucidate what the best combination of medical and surgical options is. In this regard, it is noteworthy to point out several strategies that, in turn, generate new decisional and time-restricted flows around the patient.

First, and once the kind of broncho-pulmonary neoplastic lesion is typified, in case that the option of surgery is the one chosen, the patient is transferred to Thoracic Surgery (which acts only in relation to the surgical process) being the customer the Respiratory Unit. Upon resolution of this action, the patient can follow two routes

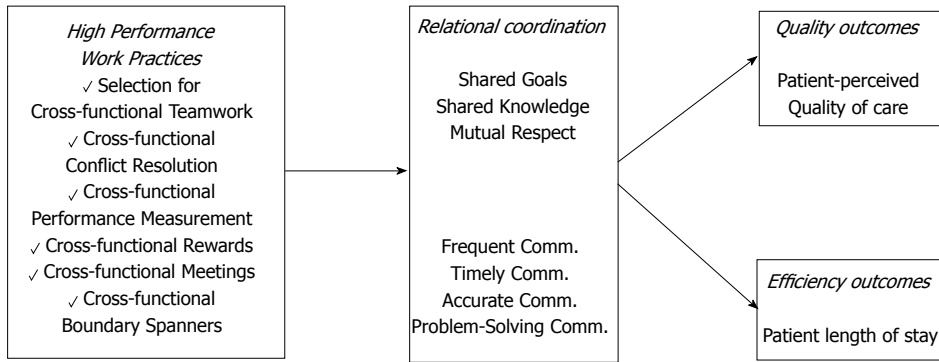


Figure 2 Relational coordination model. Gittell<sup>[4]</sup> (2009).

depending on the characteristics of the disease. If the lesion was curable with just surgery, if it is in a nearly stage, the subject is again brought back to the customer service where periodic reassessments continue on an OCC basis. If clinical pathway was structured in a combined plan of several therapeutic strategies, the patient will be assigned to Medical Oncology and submitted to treatment schemes consisting of chemotherapy and/or radiotherapy (if appropriate), acting as coadjutor service, Radiation Oncology.

Following this, we have to clarify the types and purposes of cancer treatments and their relationship with Thoracic Surgery, as well as with the alternative circuits of patients arising as a result. These treatments can be neoadjuvant or adjuvant. If a neoadjuvant treatment is preferred, the patient will be referred to Medical Oncology from Pneumology, where after receiving the appropriate treatments, will be referred to Thoracic Surgery, and once its performance has concluded, he will be returned to Medical Oncology where the patient will ultimately be assigned. If the *adjuvant* treatment option was considered, the bypass sequence would start from Pneumology to Thoracic Surgery and from the latter to Oncology, where, likewise, the patient would stay finally allocated.

In the case (very common) that Radiation Oncology intervenes, the customer service would be Medical Oncology, and the role of Radiotherapy would be the imposition of costs derived from treatment processes to the original customer.

While all of the above, it is another distinct possibility in case the lesion is unresectable. In this situation, the Commission may choose the administration of chemotherapy and/or radiotherapy to ensure the stabilization of the process. In this sense, the patient is finally moved to Medical Oncology where clinical decisions and treatments are provided, appearing again the interactions described above for the Radiation Oncology department.

After running all the steps above, the circuit would continue in different ways to transfer responsibilities between services and even between levels, depending on the clinical outcome. Thus, we would obtain the following sequences: (1) healing: The patient would return to Pneumology at the OCC level for regular checkups; (2) remission: If partial or complete remission, the patient

would be discharged and would attend appointed check-ups at Oncology Day Hospital (OCC/HTH); (3) relapse: In this case, the patient re-enters in charge of Medical Oncology, without his case again be subjected to clinical pathway for application of second-and subsequent lines; and (4) palliative Care/Death: For unsolvable progression of the disease, the patient is transferred from Medical Oncology to Palliative Care Unit (PCU), where treatment is merely symptomatic. Nevertheless, depending on the patient's general condition and in respect of his decision making capacity (if this was preserved or had been previously stated), the patient can be treated at home through a collaborative partnership between PCU (SC) and GP.

Restructuring of patient inter-and intra-level flows is absolutely needed. It requires corporate collaborative systems providing knowledge to one medical act. Therefore, the role of the RC model acquires great relevance as it acts as mediator and promotor of joint strategies aimed at improving results, from both, the patient's and the NHS' viewpoint.

## RELATIONAL COORDINATION MODEL

Based on previous studies grounded in mutual adjustment<sup>[31-35]</sup> and coordination approaches based on relationships<sup>[14,36-40]</sup> in corporate environments of high/low interdependence/uncertainty, Gittell develops her model (Figure 2) as a contribution to the study of relational dynamics.

In this sense, Gittell<sup>[5]</sup> defines her model as a mutually reinforcing process of interaction between communication and relationships carried out for the purpose of task integration. She also states that her theory differs from others due to the proposition of three specific relational dimensions that are necessary for effective coordination.

While many other recent theories emphasize the importance of shared knowledge, RC argues that while this is necessary, is not sufficient. Accordingly, to achieve effective coordination, the members must also be connected through the possession of shared goals and mutual respect.

As mentioned in the previous section, role-based coordination has an advantage over coordination based on

personal ties. While the former may require more investment for being implemented, role-based coordination fosters a role exchange that encourages corporate flexibility to adapt to changing environments within a high uncertainty and interdependence frame over time.

The model is structured around two types of dimensions: Communication and Relationship.

Within the dimensions of communication, we find:

(1) frequent communication: Frequent communication helps to establish relationships among roles through the closeness generated as a result of repeated interaction<sup>[5]</sup>; (2) timely communication: Delays in communication may have negative implications for organizational performance. Hence, the importance of timely communication, and at the right time, for successful development of organizational tasks<sup>[41]</sup>; (3) accurate communication: Accurate communication, regarding the content of relevant information, plays a critical role in the effectiveness of group tasks performance<sup>[42]</sup>; and (4) problem-Solving communication: Effective coordination requires that those involved in the task, engage in communication to solve the problems that appear in a group performance characterized by high interdependence (rather than blame others involved or evading the responsibilities). This can lead to negative consequences that singularly affect performance<sup>[29]</sup>.

Within relational dimensions in Gittell's model we find: (1) shared goals: This aspect plays a key role on the coordination of highly interdependent tasks<sup>[43,44]</sup>. Using a set of shared goals regarding the work process, involved individuals develop ties that allow them to reach conclusions that are compatible with the different ways of thinking and acting as new information is available<sup>[5]</sup>; and (2) shared knowledge: While Dougherty<sup>[45]</sup> points out that communication among those involved in the various tasks that constitute a process is not always effective because of different social backgrounds, training and/or experience, Gittell<sup>[5]</sup> states that when members know how their tasks are related to other members within the same process, it creates a dynamic in which everyone knows the impact that each change will reflect on each task and each role; and (3) mutual respect: Respect for the competence of others involved in the process, provides a powerful tie that will be implemented in a comprehensive way across the whole process generating, as a result, an effective coordination<sup>[5]</sup>.

Through this design, it follows that the RC model turns into a model of intensive coordination in communication and relationships, particularly useful to achieve higher levels of performance under high levels of interdependence among tasks, uncertainty and time constraints. So, it is an example of process improvement that allows a work group department or organization, raise their production possibility frontier to more favorable positions while achieving higher efficiency and quality<sup>[5]</sup>.

It is, therefore, to achieve work processes improvement through improving the quality of labor relations

among the actors that play different roles in these processes, thus leading to a higher quality of communication. Through this procedure, it is intended to reduce errors delays and redundancies observable among tasks interdependences within the critical organizational processes.

Model measurement is done through validated surveys to participants in a given process, on the activities of communication and relationships with others involved in the same process, with whom relations of interdependence are kept for achieving the same common objective. Related to the above, the first step would be the selection of a work process that serves a population of interest. Then, the roles or functional groups embroiled in the development of the focal process must be identified. The third step would consist on identifying which of those groups could be accessed by the researcher in order to develop matrices (symmetric/asymmetric) of RC links.

Once the previous steps have been run, likert-type survey would be delivered to the participants consisting of seven questions: four on communication and three concerning relations between different process roles. In order to reduce possible bias attributable to socially desirable responses, RC's survey asks participants about behaviors of other roles, except for organizational behavior feature represented by the frequency of communication. In addition, questions are referenced to habitual patterns of behavior, rather than be directed towards identifying specific events, that are part of the current patterns in the time of evaluation. Thus, avoiding erroneous response patterns based on retrospective response biases.

The characteristics of the model applied to the investigation of coordination practices in the management of interdependent processes, allow multi-functionality in analytical and exploratory orientation, presenting four complementary and inclusive perspectives that give great versatility in building research designs. Thus, the model can be used with the next main purposes: (1) analysis of the effect of RC on organizational performance: Determination of the impact of the model on improving the quality and efficiency of a given process characterized by high levels of interdependence, uncertainty and time constraints; (2) analysis of predictive factors of RC: Determination of the effects of organizational practices to use on the model; (3) analysis of the mediating effect of RC: Determination of the influence of the model on existing organizational practices and their impact on results; and (4) analysis of the moderating effect on RC: Determination of the influence of a/some given factor/s on the effect of the model on organizational performance measurement.

Next, we describe the proposed model for this paper based on RC modified at its core by adding two features of organizational behavior that are interrelated. Also, we introduce two moderating factors to analyze the mediating effect of it and its impact on organizational performance, taking as a critical process multilevel management of health institutions in relation to lung cancer.



To increase consistency and operational development in the future, a comparison with institutional practices currently applied (particularly single level clinical pathways) is made.

## **APPLICATION OF A MODIFIED, DOUBLE-MODERATED MODEL OF RELATIONAL COORDINATION IN PERFORMANCE MEASUREMENT OF LUNG CANCER MULTI-LEVEL TREATMENT TRAJECTORY VS ISOLATED, SINGLE-LEVEL CLINICAL PATHWAYS**

As it has been previously described, the main objective of this paper is the proposal of a modified, double-moderated model of RC (Figure 3), to investigate the degree of development of the theory proposed by Gittel<sup>[5]</sup> and the impact of its implementation on HPWS practices and outcomes obtained by the institution. In reference to the above, the greatest achievement of this study is supported by theoretically increased times of disease-free survival (DFS) as a consequence of optimal-efficient redesign of coordination strategies between levels involved in diagnosis and treatment. In addition, the potential gains highlighted would imply healthcare costs containment that would return positive savings on other important health problems, being possible to achieve true clinically-oriented corporate strategies.

First, and as a previous step for defining the implications of the proposed model on performance, we need to identify HPWS practices currently observable at health organization level (Table 1) and at the level of diagnosis and treatment of broncho-pulmonary carcinoma (Table 2) for both care providers (PC/SC).

As seen on Table 1, HPWS practices in the health care organization have a wide variability and segmentation that result in continuity of care disconnection. Furthermore, the absence of inter-level operational relations in critical aspects emphasizes the fact pointed out, generating a discontinuity of the care process that could lead to very significant increases in transaction costs, as well as duplication of health expenditure and intangible consumption.

This situation is much more serious when looking at data provided in Figure 2, referred to the specific coordination process of the pathology. In this case, it highlights the virtual absence of joint strategies for the management of the disease. In light of this information, the existence of redundant and iterative processes (that create delays in the effective application of therapeutic measures associated with consequent costs due to disabilities and/or productivity losses), gets verified.

The comparison of data shown in Tables 1 and 2 has been made through unstructured interviews with senior doctors at a health center, which has as reference hospital the one mentioned throughout this work, and that is very

representative due to the volume of population served (approximately 22000 health cards).

It justifies the introduction of a modified model of RC for the study and implementation of transfer relations among knowledge holders, in order to structure consolidated, evidence-based cooperative models that would lead to a substantial shortening of response times with a marked improvement in outcomes.

The sequential development of our model is based on the examination of the organizational behavior considered by Gittel, using the methodology annexed to the theoretical approach<sup>[5]</sup>. Then, it will be complemented by a combination of studies of other authors in the field of management, which postulate the study of trust relationships<sup>[21,46]</sup> and dialogic practices<sup>[14]</sup> as effective methods of organizational coordination.

These are especially relevant for high-uncertainty processes requiring quick and adaptive replies.

Related to the above, trust is a predictor and a consequence of interpersonal relationships<sup>[21]</sup>. In this sense, a higher degree of trust acts as a stimulating factor for communication accessibility, promotes greater effort from those involved in a task and reduces conflict in work teams, fostering better results in performance<sup>[47,48]</sup>. It could be inferred that it acts as an enhancer of RC.

Moreover, dialogic practices tested in high-uncertainty hospital services<sup>[14]</sup> appear as coordinative solutions (from a point of view focused on process trajectories<sup>[7]</sup>), by which cooperative guidelines are structured (Figure 4). This fact is particularly important, given the high variability inherent to the process of diagnosis and treatment, and the consequences of a not entirely optimal assembly of tasks committed with the successful resolution within a framework of time-coordinated action.

Related to approaches focused on trajectories<sup>[7]</sup>, these are described as goal achievement oriented sequences of action that emphasize contingencies and interactions among those involved in, differing from routines in that the latter merely emphasizes a sequence of steps that can't be extrapolated to work situations characterized by novelty, unpredictability and changing environments in relation to tasks, actors and resources<sup>[14]</sup>.

So, it is about measuring the degree of trust that the different professionals at both levels have in dialogic practices, following the methodology used by Dietz and Hartog<sup>[46]</sup> (Figure 5). This evaluation methodology would be applied to the PC level on the SC level and *vice-versa*.

In a structured way, it would be done a pre-test evaluation of the RC status (for a given level of trust in dialogic practices) at an early stage at both levels, applied to the target health problem. These data would be correlated with the evidence about HPWS developments.

Subsequently, a series of actions would be designed to strengthen relational ties between the two levels. For example, formal assistance on regular basis of one PC-GP to the meetings of the Clinical Pathway Commission (SC), with the aim of promoting the practices mentioned as of excellence, can be suggested. As a consequence,

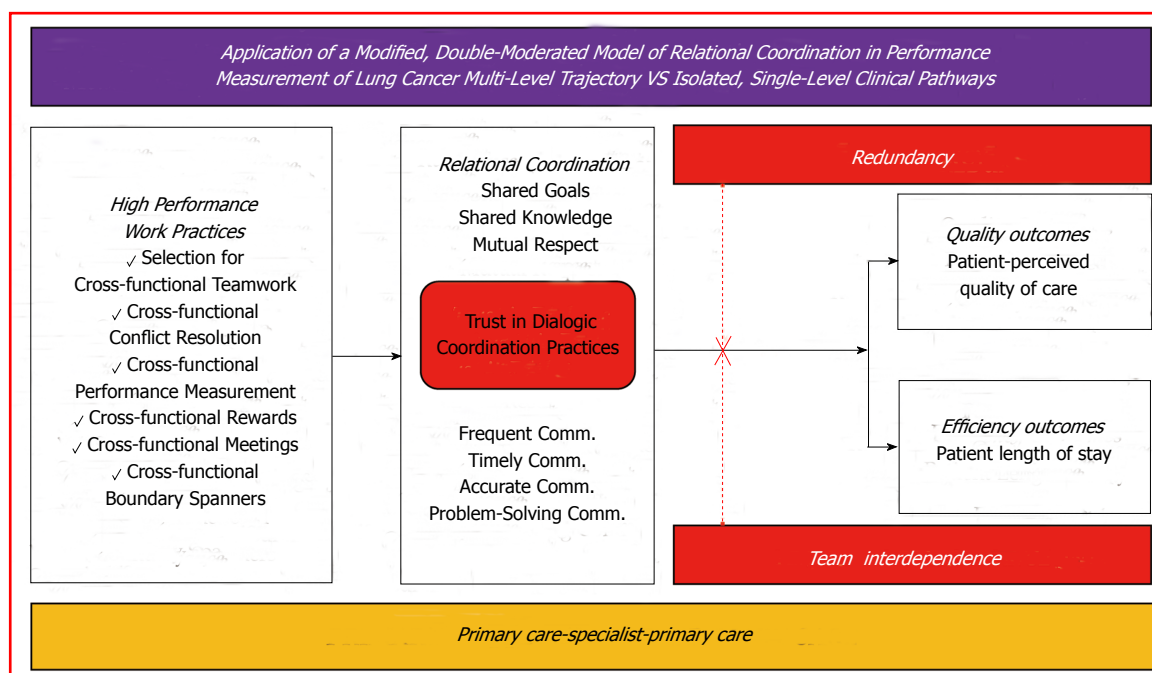


Figure 3 Modified, double-moderated model of relational coordination. Source: Authors' own elaboration.

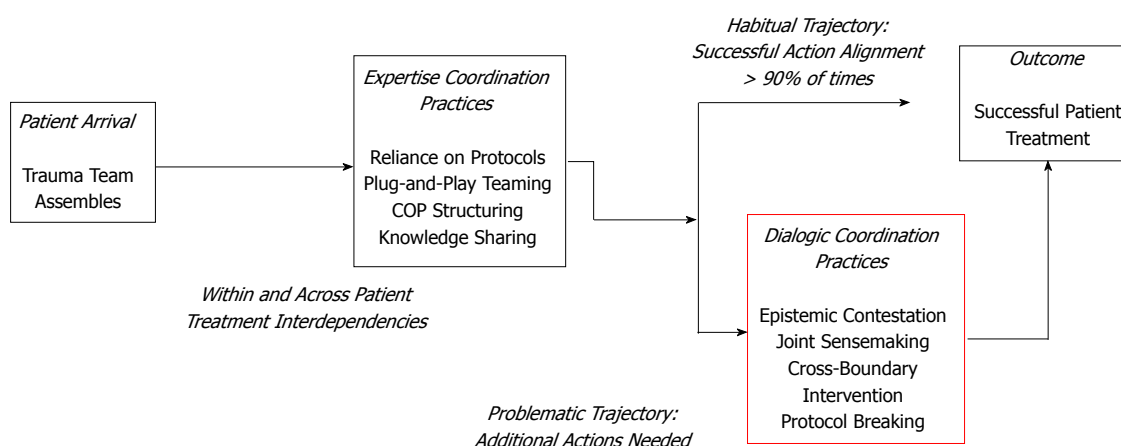


Figure 4 Coordination-focused model of trauma patient treatment. Faraj *et al.*<sup>[14]</sup> (2006).

the development of inter-level HPWS practices would be promoted, development that could materialize in creating joint Clinical Practice Guidelines which would contribute to early detection of lung cancer.

Furthermore, to streamline the circuit followed by the patient, direct referring to specific knowledge resources located on SC is intended, always ensuring the traceability of the patient's health status *via* widespread use of shared databases.

In this sense, it is about promoting the representativeness of the Continuity of Care Coordinator (see Table 1) in bidirectional management of patients affected.

Secondly, the interdependence of tasks generated under the prism pointed by Van de Ven *et al.*<sup>[35]</sup> would be considered in terms of work flows at the team level. Participating GP's would be enrolled in a training program of High-Fidelity Clinical Simulation following a method-

ology of Objective Structured Clinical Examination<sup>[49-51]</sup> that would be taught by specialist physicians specifically trained in this type of methodology. Once these actions have been carried out, a new post-test measure of the degree of trust in RC and dialogic practices would be done at the same time that HPWS practices are re-evaluated.

From this point on, it is necessary to evaluate (retrospectively/prospectively) the time passed since the first contact with the system takes place until the patient receives the first therapeutic action for treatment, prior to and after the implementation of measures aimed at encouraging the development of RC and dialogic practices. Also, as a control measure that would reinforce the theoretical assumptions (raised by some a priori confirmatory hypotheses for the model proposed vs. single level clinical pathways), TNM staging category (at the time of diagnosis confirmation) and estimation of DFS would be

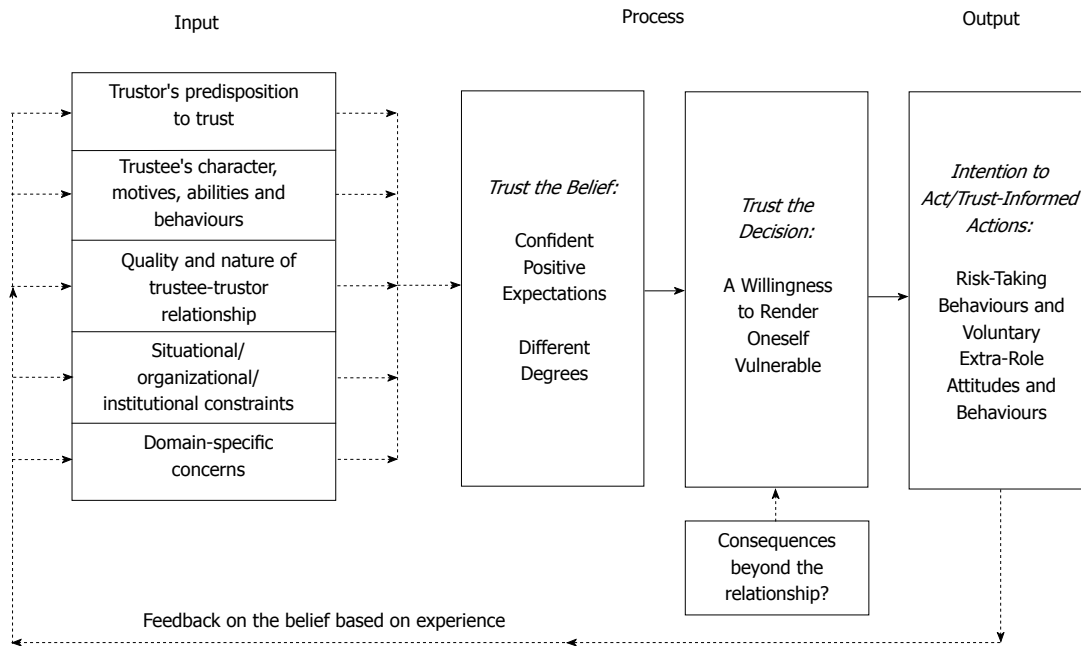
Figure 5 Depiction of the trust process. Dietz *et al.*<sup>[46]</sup> 2006.

Table 1 High-Performance Work Systems Practices-Health Care Organization

HPWS Practices	Level		
	PC	SC	Inter-level
Selection for Cross-Functional Teamwork	Health Plans	Clinical Pathway Commission Hospital Commissions	Non-existent
Cross-Functional Conflict Resolution	Managing Director at Primary Care Center	Hospital Board of Managers	Deputy Medical Care Continuity (Since October 2010)
Cross-Functional Performance Measurement	Primary Care Center	Clinical Units	Non-existent
Cross-Functional Rewards	Professional Categories at Primary Care Center (Pre-established at 100% Objective Compliance)	Professional Categories at Clinical Units (Pre-established at 100% Objective Compliance)	Non-existent
Cross-Functional Meetings	Primary Care Center	Hospital Board of Managers, Hospital Technical Commissions, Medical Services Commissions	Health Area Managing Board
Cross-Functional Boundary Spanners	Managing Director at Primary Care Center	Hospital General Manager	Deputy Medical Care Continuity (Since October 2010)

Source: Authors' own elaboration. HPWS: High-Performance Work Systems; PC: Primary Care; SC: Specialized Care.

Table 2 High-Performance Work Systems Practices-Lung Cancer Diagnosis and Treatment

HPWS Practices	Level		
	PC	SC	Inter-level
Selection for Cross-Functional Teamwork	Non-existent	Clinical Pathway Commission	Only at Palliative Care Level
Cross-Functional Conflict Resolution	Non-existent	Clinical Pathway Commission/Chief Medical Officer	Non-existent
Cross-Functional Performance Measurement	Non-existent	Clinical Pathway Commission (No. of patients included in the clinical pathway)	Non-existent
Cross-Functional Rewards	Non-existent	Non-existent	Non-existent
Cross-Functional Meetings	Non-existent	Clinical Pathway Commission	Non-existent
Cross-Functional Boundary Spanners	Non-existent	Clinical Pathway Commission	Non-existent

Source: Authors' own elaboration. HPWS: High-Performance Work Systems; PC: Primary Care; SC: Specialized Care.

done. In closing, costs related to hospital stays savings (as a result of early detection) would be calculated.

The proposed model goes from an exploratory qualitative design to (after an inductive process) an explana-

tory type, which generates synergies in the use of scarce resources through coordinative economies of scope.

## CONCLUSION

In the current socio-economic scenario characterized by a growing shortage of resources and progressive budget constraints, coordinated process management in health institutions appears as a relevant need to ensure the sustainability of the medium/long term.

The fact that a health system is strategic for a country (particularly if this system is public and universal), together with the sheer volume of resources associated with healthcare provision, makes mandatory to impose a rational logic in the clinical management of public health concerns. This logic has to be even more intense, when it comes to diseases on the rise and rate of disability and/or mortality as the one we are considering in this paper.

In this sense, RC provides a valuable opportunity for the reconfiguration of clinical guidelines concerning isolated single-level considerations, to turn them into cooperative inter-level ones.

Through unstructured and informal interviews with clinicians at both levels (Primary/Specialist Care), diagnosis of the situation in relation to joint management of lung cancer is made, noting that solutions of continuity (in terms of coordination) are observed due to the lack of effective knowledge transfer between the two levels as a result of RC practices absence<sup>[52]</sup>.

Is in this way, where it is theoretically inferred that delays secondary to ineffective coordination would be attenuated if launching and implementation of cooperative schemes (including relational trust in dialogic practices) had been run. In turn, these strategies would result in the generation of “*ad hoc*” Clinical Practice Guidelines (equivalent to HPWS in other corporate environments), which would strengthen the mission of RC. In this regard, it is worth highlighting the flexibility provided by Gittel’s theory<sup>[5]</sup>. It allows adaptation and modeling of its precepts to the organizational conditions of actual practice, providing a specific management architecture for knowledge intensive organizations that remains under heavy pressure on casuistic, uncertainty and technological changes.

The model proposed in this research, advocates a regularization and training of new skills and relational attitudes arising from the collaboration between the two levels of care involved. This consideration is particularly relevant if we return to the defining characteristics of health systems in which advances in the state of the art occur constantly and must be properly transferred.

The operational implications of the suggested theoretical alternative pursue a dual purpose on results. So on the one hand, facilitating diagnosis in early stages of broncho-pulmonary carcinoma, allows more cost-efficient measures, which will return a decrease in rates of morbidity and mortality and a significant reduction in opportunity costs from the patient’s point of view. This would be translated into tangible gains in DFS and the

appearance of negative costs obtained from savings in productivity loss avoiding and containment of hospital stays per process.

On the other hand, the second approach is characterized by the impact on health spending of Medical Care Variation. Because physicians are resource allocators, this scheme of coordination is intended to reduce duplication in diagnostic tests and clinical times. Here appears again the concept of opportunity cost, but in this case, from the point of view of the NHS. If the process is clearly predefined, there would be a bidirectional action sequence that would lead up to a regulated and bottom-up asset allocation from an optimum-efficiency criteria based on clinical excellence and non-repetitive processes. The savings generated by this approach can, in turn, be reinvested in the process itself or moved to other singular processes of great clinical significance.

The research model is, therefore, to efficiently redirect health expenditure incurred by the disease through proactive inter-level and inter-professional coordinative solutions, achieving, this way, improvements in quality of life and survival of patients affected.

It should be noted that the health organization is not to stay longer away from the improvement proposals dropped from the corporate world, because it is in itself a great company if we pay attention to budget, employability and management processes underlying their daily operation.

In this sense, this document is made taking into account the feasibility and methodological orientations arising from the healthcare business world and academia, providing a new strategic vision of the organization of clinical processes in high complexity health corporations.

## REFERENCES

- 1 **Canino G**, McQuaid EL, Rand CS. Addressing asthma health disparities: a multilevel challenge. *J Allergy Clin Immunol* 2009; **123**: 1209-1217; quiz 1218-1219 [PMID: 19447484 DOI: 10.1016/j.jaci.2009.02.043]
- 2 **McMahon T**, Gallagher RM, Little D. Psychiatry--family practice liaison: a collaborative approach to clinical training. *Gen Hosp Psychiatry* 1983; **5**: 1-6 [PMID: 6840541 DOI: 10.1016/0163-8343(83)90036-1]
- 3 **Wagner EH**, Glasgow RE, Davis C, Bonomi AE, Provost L, McCulloch D, Carver P, Sixta C. Quality improvement in chronic illness care: a collaborative approach. *Jt Comm J Qual Improv* 2001; **27**: 63-80 [PMID: 11221012]
- 4 **Gittel JH**. High performance healthcare: using the power of relationships to achieve quality, efficiency and resilience. New York, NY: Mc Graw-Hill, 2009
- 5 **Gittel JH**. Relational coordination: guidelines for theory, measurement and analysis (Internet) 2010 (accessed 2013 May 23). Available from: URL: [http://rcrc.brandeis.edu/downloads/Relational\\_Coordination\\_Guidelines\\_8-25-11.pdf](http://rcrc.brandeis.edu/downloads/Relational_Coordination_Guidelines_8-25-11.pdf)
- 6 **Gittel JH**. Coordinating mechanisms in care provider groups: relational coordination as a mediator and input uncertainty as a moderator of performance effects. *Manage Sci* 2002; **48**: 1408-1426 [DOI: 10.1287/mnsc.48.11.1408.268]
- 7 **Strauss AL**. Continual permutations of action. Hawthorne, NY: Aldyne de Gruyter, 1993



- 8 **Globocan**, (IARC). Section of Cancer Information (Internet). World Health Organization 2008 (accessed 2013 May 23). Available from: URL: <http://www.who.int/>
- 9 **Murray CJ**, Lopez AD. Alternative projections of mortality and disability by cause 1990-2020: Global Burden of Disease Study. *Lancet* 1997; **349**: 1498-1504 [PMID: 9167458 DOI: 10.1016/S0140-6736(96)07492-2]
- 10 **Warren JL**, Yabroff KR, Meekins A, Topor M, Lamont EB, Brown ML. Evaluation of trends in the cost of initial cancer treatment. *J Natl Cancer Inst* 2008; **100**: 888-897 [PMID: 18544740 DOI: 10.1093/jnci/djn175]
- 11 **Yabroff KR**, Lamont EB, Mariotto A, Warren JL, Topor M, Meekins A, Brown ML. Cost of care for elderly cancer patients in the United States. *J Natl Cancer Inst* 2008; **100**: 630-641 [PMID: 18445825 DOI: 10.1093/jnci/djn103]
- 12 **Bradley CJ**, Yabroff KR, Dahman B, Feuer EJ, Mariotto A, Brown ML. Productivity costs of cancer mortality in the United States: 2000-2020. *J Natl Cancer Inst* 2008; **100**: 1763-1770 [PMID: 19066273 DOI: 10.1093/jnci/djn384]
- 13 **Safran DG**, Miller W, Beckman H. Organizational dimensions of relationship-centered care. Theory, evidence, and practice. *J Gen Intern Med* 2006; **21** Suppl 1: S9-S15 [PMID: 16405711 DOI: 10.1111/j.1525-1497.2006.00303.x]
- 14 **Faraj S**, Xiao Y. Coordination in fast-response organizations. *Manage Sci* 2006; **52**: 1155-1169 [DOI: 10.1287/mnsc.1060.0526]
- 15 **Davidow WH**, Malone MS. The virtual corporation: structuring and revitalizing the corporation for the 21<sup>st</sup> century. New York, NY: Harper Collins, 1992
- 16 **Porter ME**, Millar VE. How information gives you competitive advantage. *Harvard Bus Rev* 1985; **63**: 149-160 [DOI: 10.1225/85415]
- 17 **Foy R**, Hempel S, Rubenstein L, Suttorp M, Seelig M, Shanman R, Shekelle PG. Meta-analysis: effect of interactive communication between collaborating primary care physicians and specialists. *Ann Intern Med* 2010; **152**: 247-258 [PMID: 20157139 DOI: 10.7326/0003-4819-152-4-201002160-00010]
- 18 **Grant RM**. Toward a knowledge-based theory of the firm. *Strategic Manage J* 1996; **17**: 109-122 [DOI: 10.1002/smj.4250171110]
- 19 **Nonaka I**, Takeuchi H. The knowledge-creating company. New York, NY: Oxford University Press, 1995
- 20 **Davenport TH**, Thomas RJ, Cantrell S. The mysterious art and science of knowledge-worker performance. *Mit Sloan Manage Rev* 2002; **44**: 23-30 [DOI: 10.1225/SMR089]
- 21 **Hopp WJ**, Irvani SMR, Liu F. Managing white-collar work: an operations-oriented survey. *Prod Oper Manag* 2009; **18**: 1-32 [DOI: 10.1111/j.1937-5956.2009.01002.x]
- 22 **Becker BE**, Huselid MA. Strategic human resources management: where do we go from here? *J Manage* 2006; **32**: 898-925 [DOI: 10.1177/0149206306293668]
- 23 **Teece DJ**, Pisano G, Shuen A. Dynamic capabilities and strategic management. *Strategic Manage J* 1997; **18**: 509-533 [DOI: 10.1002/(SICI)1097-0266(199708)18:7<509::AID-SMJ882>3.0.CO;2-Z]
- 24 **Bontis N**. Intellectual capital: an exploratory analysis that develops measures and models. *Manage Decis* 1998; **36**: 63-76 [DOI: 10.1108/00251749810204142]
- 25 **Grant RM**. The resource-based theory of competitive advantage: implications for strategy formulation. *Calif Manage Rev* 1991; **33**: 114-135 [DOI: 10.2307/41166664]
- 26 **Hatch NW**, Dyer JH. Human capital and learning as a source of sustainable competitive advantage. *Strategic Manage J* 2004; **25**: 1155-1178 [DOI: 10.1002/smj.421]
- 27 **Wernerfelt B**. A resource-based view of the firm. *Strategic Manage J* 1984; **5**: 171-180 [DOI: 10.1002/smj.4250050207]
- 28 **Peiró S**. Métodos de medición de casuística y ajuste de severidad y riesgos. In: Gimeno JA, Repullo JR, Rubio S, dir. Manuales de dirección médica y gestión clínica: gestión clínica desarrollo e instrumentos. Madrid: Ed. Díaz de Santos, 2006:145-200
- 29 **Deming WE**. Out of the crisis. Cambridge, MA: MIT Press, 1986
- 30 **Vanhaverbeke W**, Cloodt M. "Open innovation in value networks". In: Chesbrough H, Vanhaverbeke W, West J, eds. Open innovation: researching a new paradigm. Oxford: Oxford University Press, 2006: 258-281
- 31 **Argote L**. Input uncertainty and organizational coordination in hospital emergency units. *Adm Sci Q* 1982; **27**: 420-434 [PMID: 10256878 DOI: 10.2307/2392320]
- 32 **Kogut B**, Zander U. What firms do? Coordination, identity and learning. *Organ Sci* 1996; **7**: 502-518 [DOI: 10.1287/orsc.7.5.502]
- 33 **Thompson JD**. Organizations in action: social science bases of administrative theory. New York, NY: McGraw-Hill, 1967
- 34 **Tushman M**, Nadler D. Information processing as an integrating concept in organizational design. *Acad Manage Rev* 1978; **3**: 613-624 [DOI: 10.5465/AMR.1978.4305791]
- 35 **Van de Ven AH**, Delbecq AL, Koenig R. Determinants of coordination modes within organizations. *Am Sociol Rev* 1976; **41**: 322-328 [DOI: 10.2307/2094477]
- 36 **Heckscher C**, Adler P. The firm as collaborative community: reconstructing trust in the knowledge economy. Oxford: Oxford University Press, 2007
- 37 **Heckscher C**, Rubinstein SA, Flynn L, Erhardt N, Boniface M. Collaboration and the quality of health care delivery. Working Paper (Internet) 2009 (accessed 2013 May 23). Available from: URL: <http://www.lera.uiuc.edu/IndustryCouncils/healthcare/Heckscher-CollaborationQualityHealthcareDelivery.pdf>
- 38 **Liang DW**, Moreland R, Argote L. Group versus individual training and group performance: the mediating role of group transactive memory. *Pers Soc Psychol Bull* 1995; **21**: 384-393 [DOI: 10.1177/0146167295214009]
- 39 **Quinn R**, Dutton JE. Coordination as energy-in-conversation. *Acad Manage Rev* 2005; **30**: 36-57 [DOI: 10.5465/AMR.2005.15281422]
- 40 **Weick KE**. The collapse of sense-making in organizations: the mann gulch disaster. *Admin Sci Quart* 1993; **38**: 628-652 [DOI: 10.2307/2393339]
- 41 **Waller MJ**. The timing of adaptive group responses to non-routine events. *Acad Manage J* 1999; **42**: 127-137 [DOI: 10.2307/257088]
- 42 **O'Reilly CA**, Roberts K. Task group structure, communication and effectiveness in three organizations. *J Appl Psychol* 1977; **62**: 674-681 [DOI: 10.1037/0021-9010.62.6.674]
- 43 **Saavedra R**, Earley PC, Van Dyne L. Complex interdependence in task-performing groups. *J Appl Psychol* 1993; **78**: 61-72 [DOI: 10.1037/0021-9010.78.1.61]
- 44 **Wageman R**. Interdependence and group effectiveness. *Admin Sci Quart* 1995; **40**: 145-180 [DOI: 10.2307/2393703]
- 45 **Dougherty D**. Interpretive barriers to successful product innovation in large firms. *Organ Sci* 1992; **3**: 179-202 [DOI: 10.1287/orsc.3.2.179]
- 46 **Dietz G**, Hartog DND. Measuring trust inside organizations. *Pers Rev* 2006; **35**: 557-588 [DOI: 10.1108/00483480610682299]
- 47 **Dirks KT**. The effects of interpersonal trust on work group performance. *J Appl Psychol* 1999; **84**: 445-455 [PMID: 10380424 DOI: 10.1037/0021-9010.84.3.445]
- 48 **Porter T**, Lilly B. The effects of conflict, trust and task commitment on project team performance. *Int J Confl Manage* 1996; **7**: 361-376 [DOI: 10.1108/eb022787]
- 49 **Epstein RM**, Hundert EM. Defining and assessing professional competence. *JAMA* 2002; **287**: 226-235 [PMID: 11779266 DOI: 10.1001/jama.287.2.226]
- 50 **Epstein RM**. Assessment in medical education. *N Engl J Med*

- 2007; **356**: 387-396 [PMID: 17251535 DOI: 10.1056/NEJM-ra054784]
- 51 **Wass V**, Van der Vleuten C, Shatzer J, Jones R. Assessment of clinical competence. *Lancet* 2001; **357**: 945-949 [PMID: 11289364 DOI: 10.1016/S0140-6736(00)04221-5]
- 52 **Pisano GP**. Knowledge, integration and the locus of learning: an empirical analysis of process development. *Strategic Manage J* 1994; **15**: 85-100 [DOI: 10.1002/smj.4250150907]
- P- Reviewer:** Kawai H, Sugawara I, Wang HY    **S- Editor:** Ji FF  
**L- Editor:** A    **E- Editor:** Wu HL



## New targeted therapies for breast cancer: A focus on tumor microenvironmental signals and chemoresistant breast cancers

Armel Hervé Nwabo Kamdje, Paul Faustin Seke Etet, Lorella Vecchio, Richard Simo Tagne, Jeremie Mbo Amvene, Jean-Marc Muller, Mauro Krampera, Kiven Erique Lukong

Armel Hervé Nwabo Kamdje, Richard Simo Tagne, Jeremie Mbo Amvene, Department of Biomedical Sciences, Faculty of Sciences, University of Ngaoundéré, PO Box 454, Ngaoundéré, Cameroon

Paul Faustin Seke Etet, Lorella Vecchio, Department of Basic Health Sciences, College of Applied Medical Sciences, Qassim University, Buraydah 52571, Saudi Arabia

Jean-Marc Muller, Université de Poitiers, Faculté des Sciences, Pôle Biologie-Santé Bât B36, 1, rue Georges Bonnet-BP633, 86022 Poitiers cedex, France

Mauro Krampera, Department of Medicine, Section of Hematology, Stem Cell Research Laboratory, University of Verona, 37129 Verona, Italy

Kiven Erique Lukong, Department of Biochemistry, College of Medicine, University of Saskatchewan, Saskatoon S7N 5E5, Canada

Author contributions: All authors contributed to this paper.

Correspondence to: Armel Hervé Nwabo Kamdje, PhD, Department of Biomedical Sciences, Faculty of Sciences, University of Ngaoundere, PO Box 454, Ngaoundere, Cameroon. [armel.nwabo@gmail.com](mailto:armel.nwabo@gmail.com)

Telephone: +237-90-190421 Fax: +237-22-251747

Received: May 30, 2014 Revised: July 12, 2014

Accepted: September 23, 2014

Published online: December 16, 2014

recently entered clinical trials in mono- and combination therapy in metastatic and chemo-resistant breast cancers. Anticancer epigenetic drugs, mainly histone deacetylase inhibitors and DNA methyltransferase inhibitors, also entered clinical trials. Because of the complexity and heterogeneity of breast cancer, the future in therapy lies in the application of individualized tailored regimens. Emerging therapeutic targets and the implications for personalized-based therapy development in breast cancer are herein discussed.

© 2014 Baishideng Publishing Group Inc. All rights reserved.

**Key words:** Breast cancer; Microenvironment; Signaling molecule; Targeted therapy; Chemoresistance

**Core tip:** Emerging therapeutic targets may overcome chemoresistance in breast cancer.

Nwabo Kamdje AH, Seke Etet PF, Vecchio L, Tagne RS, Mbo Amvene J, Muller JM, Krampera M, Lukong KE. New targeted therapies for breast cancer: A focus on tumor microenvironmental signals and chemoresistant breast cancers. *World J Clin Cases* 2014; 2(12): 769-786 Available from: URL: <http://www.wjgnet.com/2307-8960/full/v2/i12/769.htm> DOI: <http://dx.doi.org/10.12998/wjcc.v2.i12.769>

### Abstract

Breast cancer is the most frequent female malignancy worldwide. Current strategies in breast cancer therapy, including classical chemotherapy, hormone therapy, and targeted therapies, are usually associated with chemoresistance and serious adverse effects. Advances in our understanding of changes affecting the interactome in advanced and chemoresistant breast tumors have provided novel therapeutic targets, including, cyclin dependent kinases, mammalian target of rapamycin, Notch, Wnt and Shh. Inhibitors of these molecules

### INTRODUCTION

The incidence of breast cancer, the most common cancer in women and the second cause of cancer death in women worldwide<sup>[1,2]</sup>, is currently growing<sup>[3,4]</sup>. Cancers are diseases characterized by aberrant microenvironment and intrinsic signaling causing a continuous proliferation of affected cells ("cancer cells"). Clinical features and

prognosis of cancers vary tremendously according to the tissue and organs they originate from and affect. Breast cancer may start in milk ducts, and can be invasive [invasive ductal carcinoma (IDC)] or not (ductal carcinoma *in situ*). IDC would represent up to 80% of cases<sup>[5,6]</sup>. Breast cancer may also start in the lobules, with invasive features (invasive lobular carcinoma) or not (lobular carcinoma *in situ*). In metastatic breast cancer malignant cells originating from breast primary tumors invade other tissues and organs of the body, resulting in a systemic disease. As disease early detection is associated with better prognosis, screening campaigns involving healthy female subjects are performed worldwide. Notably, mammography, which requires the use of low-dose X-rays to capture images inside the breast, is the current gold standard screening for detection of breast cancer asymptomatic cases<sup>[7,8]</sup>. However, although the technique requires X-rays, the benefits of the earlier detection of breast cancer outweigh the risk of radiation exposure, which can be associated with the development of breast cancer in previously healthy women is present<sup>[9,10]</sup>. New approaches for early detection have been proposed, and may also contribute to reducing breast cancer mortality (for review see<sup>[11,12]</sup>).

Three major therapeutic approaches are used today to treat or control breast cancer: surgical removal of primary tumors, irradiation of cancer cells to stop their growth, and anticancer drugs, which kill cancer cells or inhibit their proliferation. Notably, oncoplastic surgery, a technique combining classical lumpectomy (or partial mastectomy) and plastic surgery techniques have revolutionized breast-conserving surgery for removal of lumps and malignant masses. However, surgery or radiotherapy still requires chemotherapy to eradicate remaining malignant cells and impede relapses. Anticancer drugs are based on three therapeutic approaches: (1) the classical chemotherapy, where cancer cell proliferation is stopped by the indiscriminate targeting of rapid cell divisions in the body; (2) hormone therapy, devised to stop cancer cell growth by targeting the receptors and downstream signaling molecules of hormones pivotal for the proliferation of these cells; and (3) the emerging and promising targeted therapy, where signaling pathways deregulated in primary breast tumors are specifically targeted. Breast cancer treatment is still challenging, as drugs in use are expensive, have serious undesired effects<sup>[13-15]</sup>, and drug resistance is common, particularly in metastatic cases<sup>[16,17]</sup>, underlying the need for new targeted therapies. Interestingly, recent advances in the understanding of breast cancer biology have highlighted the tumor microenvironment as a major player in breast carcinogenesis and have provided new avenues for targeted therapy.

The present review summarizes and discusses the current understanding of changes affecting breast microenvironment during breast tumorigenesis, with a particular emphasis on signaling pathways currently targeted for therapy and emerging therapeutic targets. Personalized-based targeting implementation is also discussed.

## TUMOR MICROENVIRONMENT IS PIVOTAL FROM BREAST CANCER INITIATION TO METASTASIS

Numerous stromal cell types are found in the extracellular matrix of the breast stroma, including endothelial cells, fibroblasts, adipocytes, and resident immune cells<sup>[18]</sup>. In addition to these cell types, cancer-affected microenvironment contains malignant cells termed as cancer-associated fibroblasts (CAFs), which are the most numerous cell type, and infiltrating macrophages termed as tumor-associated macrophages (TAMs).

### Cancer-associated fibroblasts

CAFs were reported to play key roles in malignant cell proliferation and tumor maintenance<sup>[18,19]</sup>. An *in vivo* study involving xenograft of MDA-MB-231 breast cells in SCID mice revealed that CAFs induce p53-dependent antimitogenic responses in normal stromal fibroblast<sup>[20]</sup>, at least partly through Notch-dependent mechanisms<sup>[21]</sup>. In another study, CAFs expressed vascular endothelial growth factor in presence of hypoxia inducible factor 1  $\alpha$ /G-protein estrogen receptor (HIF-1 $\alpha$ /GPER) signaling, suggesting a role for these cells in hypoxia-dependent tumor angiogenesis<sup>[22]</sup>. Under the same conditions, CAFs were shown to express Notch molecules<sup>[23]</sup>, which promotes cancer cell survival, proliferation<sup>[24,25]</sup>, as well as angiogenesis<sup>[26]</sup>. In addition, Luga *et al.*<sup>[27]</sup> showed that CAFs release exosomes, which stimulate invasiveness and malignant cell metastasis *via* a Wnt11-dependent mechanism. On the same hand, CAFs induced phenotypical changes in adipocytes resulting in the generation of fibroblast-like cells [adipocyte-derived fibroblasts (ADF)], which in turn increased migratory abilities of metastatic cells by releasing high levels of collagen I and fibronectin<sup>[28]</sup>. Notably, CAF-induced ADF phenotype generation was mediated by reactivation of the oncogenic Wnt/ $\beta$ -catenin pathway in the latter cells in response to Wnt3a produced by the cancer cells, suggesting CAFs and ADFs as potential therapeutic targets in metastatic breast cancer. Furthermore, CAFs may promote breast cancer initiation and progression to metastasis *via* tumor- $\alpha\beta 1$  integrin signaling<sup>[29]</sup> and fibroblast growth factor signaling<sup>[30]</sup>, as well as malignancy orchestration and tumor stroma reprogramming through activation of heat shock factor 1<sup>[31]</sup>, a transcriptional regulator.

Interestingly, Capparelli *et al.*<sup>[32,33]</sup> have hypothesized that senescent fibroblasts may promote tumor growth through an autophagy-dependent mechanism termed as “autophagy-senescence transition”. In order to test such hypothesis, these authors introduced autophagy genes such as *bnip3*, *ctsb* or *ATG16L1* in immortalized human fibroblasts that resulted in the induction of a constitutive autophagic phenotype (characterized by mitophagy, aerobic glycolysis, L-lactate and ketone body production) with senescence features associated with increased  $\beta$ -galactosidase activity, increased level of cyclin depen-



dent kinase inhibitor (CDKI) p21, and cellular hypertrophy. Interestingly, “autophagic-senescent” fibroblasts were able to induce tumor growth and metastasis independently of angiogenesis, with stronger effects (up to 11-fold) in autophagic fibroblasts producing large amounts of ketone bodies. These observations were confirmed *in vivo*, as the lysosomal enzyme and biomarker of senescence,  $\beta$ -galactosidase, was also found in human breast cancer stroma. A recent *in vivo* study revealed the ability of CAF autophagy and senescence to promote tumor growth and metastasis increasing the rate of glycolysis and enhancing the generation of mitochondrial fuels including bodies<sup>[33]</sup> in a compartment-specific fashion, thus supporting the role of CAFs to metabolically regulate tumorigenesis. In this study, the injection of the antidiabetic molecule along with peroxisome proliferator-activated receptor gamma (PPAR $\gamma$ ), known to stimulate glycolysis and pro-autophagy, into stromal cells enhanced the growth of co-injected breast cancer cells by 60%, whereas PPAR $\gamma$  injection in cancer cells reduced the growth of breast cancer cells by 40%<sup>[34]</sup>.

### Tumor-associated macrophages

TAMs infiltration into neoplastic tissues is an important negative prognostic factor<sup>[35,36]</sup>, and a hallmark of triple negative breast cancer<sup>[37]</sup>, a chemoresistant subtype of breast cancer<sup>[38,39]</sup>. Overall, emerging evidence suggests that TAMs are major player in anticancer drug resistance in breast cancer. For instance, Yamashina *et al.*<sup>[40]</sup> recently reported that cancer stem-like cells originating from chemoresistant tumor promote macrophage colony-stimulating factor production *via* an interferon regulatory factor 5-dependent mechanism, and transform recruited CD14(+) monocytes in tumorigenic M2-macrophages (immunoregulatory), probably through CXCR3 downregulation<sup>[41]</sup>. Interestingly, the differentiation inducer dimethyl sulfoxide exerted antitumor effects in a mouse breast cancer model (4T1) possibly by inducing M1-phenotype in TAMs<sup>[42]</sup>.

Furthermore, TAMs may promote carcinogenesis and metastasis *via* Wnt signaling, which mediates the angiogenic switch and metastatic processes in breast cancer<sup>[43,44]</sup>. Notably, TAMs release high levels of the Wnt family ligand Wnt7b<sup>[45]</sup>, and cancer stem-like cells may trigger the metastatic effect of TAMs through enhancement of the  $\beta$ -catenin pathway *via* vitamin D receptor suppression by tumor necrosis factor alpha<sup>[46]</sup>. In addition, *in vivo* and *in vitro* studies supported a pivotal role for Wnt 5a signaling in TAMs-induced metastasis<sup>[47,48]</sup>, and a strong correlation was found between Wnt5a expression in malignant cells and the number of CD163(+) M2-macrophages<sup>[49]</sup>. In a relatively recent study investigating the potential of the phosphodiesterase type 5 inhibitor (vasodilator) drug dipyridamole in xenograft mice, anticancer effects were mediated at least partly by decreasing  $\beta$ -catenin cytosolic levels<sup>[50]</sup>. Altogether, these findings implicated TAMs as a key links between chemoresistance and tumorigenic activities of cancer stem-like cells, and thus, positioning TAMs as potential therapeutic targets

for breast cancer. Figure 1 shows the main signaling pathways currently in use for targeted breast cancer therapy, as well as some possible new targets.

## NOTCH SIGNALING

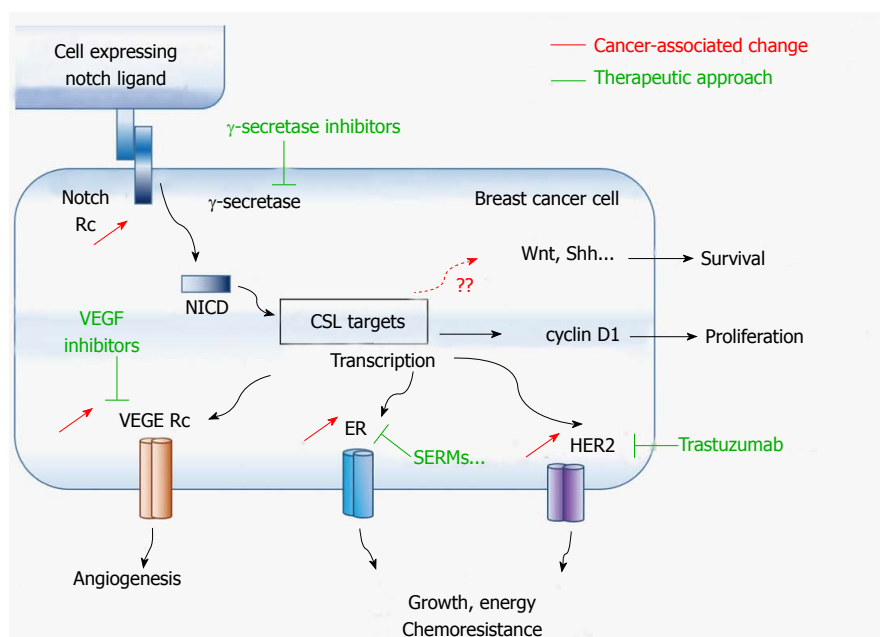
### Notch family of molecules

The Notch family of membrane bound receptors and ligands regulate several cell processes including cell invasion, survival and apoptosis, *via* the Notch signaling pathway. The pathway comprises four receptors (Notch1 through Notch4) and five Notch ligands (Delta-like 1, 3, and 4, and Jagged1 and 2). Notch ligands include an extracellular domain containing multiple epidermal growth factor (EGF)-like repeats and an extracellular DSL where ligand binding occurs, and an intracellular domain with a PDZ-binding motif at C-terminal domain<sup>[51,52]</sup>. Notch receptors are also made of an extracellular and an intracellular domain covalently linked. Notch receptor extracellular domain also contains EGF-like repeats (26-29 depending on the Notch receptor), whereas Notch intracellular domain (NICD) presents with LIN12/Notch-related repeats preventing ligand-independent signaling, cysteine residues, and a C-terminal transactivation domain containing a PEST sequence with proteolytic activity.

Notch ligands are expressed on the plasma membrane of one cell and interact with Notch receptors on the plasma membrane of a neighboring cell, initiating the cleavage of the receptor by proteases [ADAM (a disintegrin and metalloprotease) and  $\gamma$ -secretase] that culminates in the release of the NICD<sup>[53]</sup>. Released NICD translocate to the nucleus and forms a transcriptional activator complex with C-promoter binding factor 1/Suppressor of Hairless and Lag-1 (CSL) transcription factor. Together with cofactors like mastermind-like protein, NICD-CSL complex induces the transcription of cell fate key target genes such as *vegfr3* and, *notch1* that regulate angiogenesis and apoptosis, *p21* that regulates the cell cycle, as well as transcription factor genes such as the basic helix-loop-helix and hairy/enhancer of split/-related (*hes* and *hey*)<sup>[54,55]</sup> (Figure 1).

### Notch signaling as a therapeutic target

As already mentioned (section 2), Notch signaling is used by CAFs to promote cancer cell survival and proliferation. Early reports revealed that upregulation of Notch signaling suffices to transform normal breast epithelial cells in malignant cells *in vitro*, and that high levels of NICD are present in breast primary tumors<sup>[56-59]</sup>. Notch carcinogenic effects are mediated *via* the silencing proapoptotic signaling pathways and growth-inhibitory molecules like TGF- $\beta$ <sup>[58]</sup>. Notch-induced TGF- $\beta$  silencing also promotes bone metastasis<sup>[60,61]</sup>. In addition, Notch signaling, which is required for physiological angiogenesis, may also be a key player in neoangiogenesis<sup>[62]</sup>. A Notch 3 addition of the lymphovascular embolus was reported in a xenograft model of inflammatory breast carcinoma, a subtype of breast cancer whose hallmark is



**Figure 1 Notch signaling in breast cancer.** In Notch-driven breast cancers, tumor cells and neighboring cells express Notch ligand and receptors. In presence of ADAM/TACE and  $\gamma$ -secretase enzymatic complex, Notch ligand-receptor interactions result in the release of Notch intracellular domain (NICD), which translocate to cell nucleus and activate CSL transcription factor. Target genes include signaling molecules involve in cancer cell survival, proliferation, angiogenesis, growth, energy metabolism, and chemoresistance. Inhibitors of many of these signaling molecules have been developed and are in use in various cancers, including g-secretase inhibitors, vascular endothelial growth factor inhibitors, estrogen signaling inhibitors, and HER2 inhibitors. ER: Estrogen receptor; HER2: Epidermal growth factor receptor 2; ADAM/TACE: A disintegrin and metalloprotease/tumor necrosis factor- $\alpha$  converting enzyme; CSL: CBF1/Suppressor of Hairless/LAG-1.

lymphovascular invasion<sup>[63]</sup>.

*In vitro* studies in estrogen receptor (ER)-negative breast cancer cells (MDA-MB-231) performed by Lee *et al.*<sup>[64]</sup> revealed that Notch signaling up-regulates the transcription of the apoptosis inhibitor survivin. In another study, these authors showed that Notch-1-survivin functional gene signature is common in basal breast cancer<sup>[65]</sup>. In addition, crosstalk between Notch and signaling pathways involved in cell growth were reported as well, including the estrogen receptor<sup>[66]</sup>, human epidermal growth factor receptor 2 (HER2)<sup>[67]</sup>, and the metabolic signaling pathways phosphatidylinositol 3-kinase (PI3K)/ protein kinase B (Akt)/mammalian target of rapamycin (mTOR)<sup>[68,69]</sup> and MAP kinase/ERK<sup>[70,71]</sup>. Interestingly combined targeting of Notch and EGFR signaling suppressed chemoresistance in a basal-like breast cancer *in vivo* model<sup>[72]</sup>, suggesting that co-targeting of Notch and associated pathways may represent a new avenue for overcoming chemoresistance (Figure 1).

Tumor initiating cells of tumors overexpressing HER2/neu also express high levels of Notch molecules, whose signaling is known to enhance HER2 expression<sup>[73]</sup>. Chemoresistance to HER2+ breast cancers to trastuzumab, a monoclonal antibody against HER2, is associated with the overexpression of Notch-1 and its ligand Jagged-1<sup>[74,75]</sup>. Similarly, cancer stem-like cells also achieve resistance against chemotherapy and radiotherapy *via* Notch signaling<sup>[76]</sup>, and targeting of this signaling pathway reduces the stem-like population<sup>[77]</sup>. The  $\gamma$ -secretase inhibitor MRK-003 induced long-term recurrence-free survival in a transgenic mouse model of HER2+ breast cancer<sup>[78]</sup>. Similarly, co-targeting of Notch and HER2

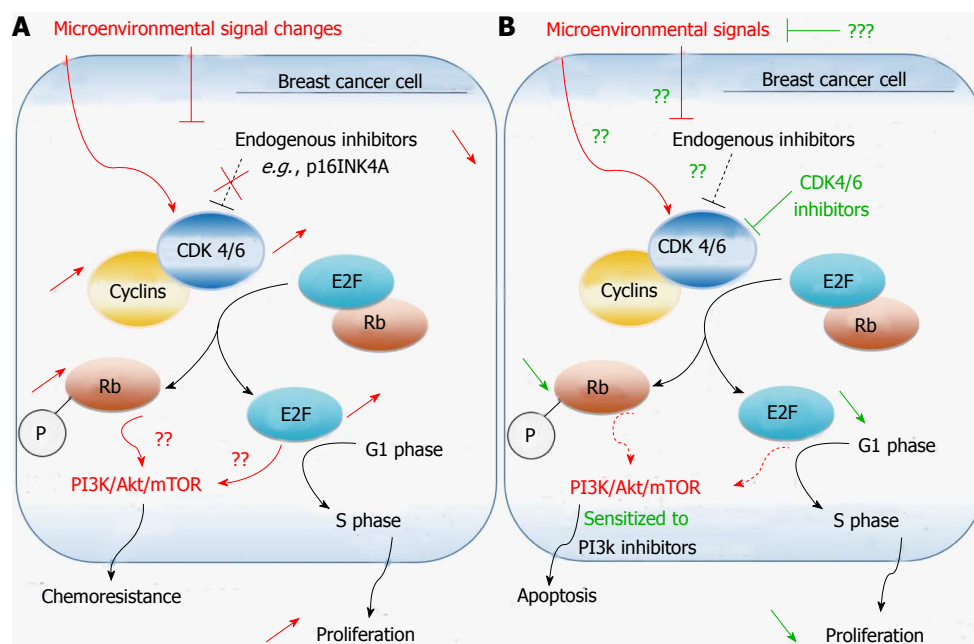
signaling pathways prevented breast tumor recurrence in orthotopic breast tumor xenograft using trastuzumab-resistant BT474 cells<sup>[79]</sup>.

Platelet-derived growth factor-D, another marker of breast cancer poor prognosis, may increase breast tumor aggressiveness by activating Notch and NF- $\kappa$ B signaling pathways<sup>[80]</sup>. Furthermore, Notch-1 and Notch-4, established bio-markers of the chemoresistant breast cancer subtype<sup>[81]</sup>, were reported as novel transcriptional targets in triple negative breast cancer<sup>[82,83]</sup>. Jagged1/Notch4 signaling was shown to induce epithelial-to-mesenchymal transition<sup>[84]</sup>. Notch signaling was also reported as a mechanism of resistance to PI3K inhibitors<sup>[85]</sup> and hormone therapy<sup>[86]</sup>.

### Clinical evaluation of Notch signaling targeting

Notch signaling inhibitors have a promising clinical efficacy as they abrogate HER2-Notch axis of chemoresistance. Notch silencing by  $\gamma$ -secretase inhibitors (GSIs) inhibited the proliferation of breast cancer cells partly by causing cell cycle arrest and apoptosis<sup>[76]</sup>, and by sensitizing chemoresistant breast cancer cells to the BH3 mimetic ABT-737<sup>[87]</sup>. Notably, GSIs induce toxicity to breast cancer both *in vitro* and *in vivo* models, however mechanisms of such cytotoxicity are complex and may involve proteasome inhibition and downregulation of Bax and Bcl-2<sup>[88,89]</sup>.

Following encouraging pre-clinical studies<sup>[83,90,91]</sup>, the oral gamma secretase inhibitor R04929097 recently entered phase- I trial in patients with advanced solid tumors. Early reports of combination therapies with the kinase inhibitor temsirolimus<sup>[92]</sup>, the antimetabolites of the



**Figure 2** CDK4/6 signaling in breast cancer. A: Cyclin dependent kinases (CDK) 4/6 signaling is overexpressed in breast cancer. Such overexpression, which results from the silencing of CDK endogenous inhibitors, participate directly to cancer cell proliferation by triggering G1-S transition, and indirectly to chemoresistance via a PI3K/Akt/mTOR-dependent mechanism; B: CDK4/6 inhibitors sensitize chemoresistant cells to PI3K inhibitors and various other anticancer agents. PI3K: Phosphatidylinositol 3-kinase.

pyrimidine analog family gemcitabine (PHL-078/CTEP 8575)<sup>[93]</sup> or cediranib (PJC-004/NCI 8503) revealed that the combinations were safe and promising in breast, tracheal, and pancreas cancer patients. However, anemia, diarrhea, fatigue, hypertension, neutropenia, and nausea were observed, among other side effects. GSI reported side effects seem to be mediated primarily through proteasome inhibition<sup>[88,94]</sup>. Thus, CSL inhibition, which was reported to mediate a more effective inhibition of Notch-dependent carcinogenic processes than GSIs<sup>[95]</sup>, may represent a less toxic approach for Notch signaling targeting.

Another GSI, PF-03084014, also presented promising results in breast xenograft models<sup>[96]</sup>, with gastrointestinal toxicity easily abrogated by glucocorticoids<sup>[97]</sup>. Other promising pre-clinical observations included a synergistic effect with the antimitotic drug docetaxel in breast cancer<sup>[98]</sup>, colorectal cancer<sup>[99]</sup>, and metastatic pancreatic cancer<sup>[100]</sup> models. Antiangiogenic effects were also reported in combinations with the tyrosine kinase inhibitor sunitinib in solid tumors<sup>[101]</sup>, whereas in chronic lymphocytic leukemia cells combinations with the nucleoside metabolic inhibitor fludarabine inhibited angiogenesis as well as migration and invasion of Notch 1-mutated cancer cells<sup>[102,103]</sup>. PF-03084014 therefore appears as an appealing GSI for both solid and blood cancers and may be a good targeted-therapy drug in breast cancer.

## CDK

### CDKs, cyclins and CDKI

Cyclins, CDK inhibitors (CDKIs, *e.g.*, p16INK4, p15INK4B, p18INK4C, p21WAF1/CIP1<sup>[104,105]</sup>) and CDKs are the three key classes of regulatory molecules that deter-

mine cell cycle progression through the G0-G1-S-G2 and M phases<sup>[106,107]</sup>. Numerous CDKs are found in eukaryotic cells, of which some are pivotal cell cycle regulators, such as CDK1/2/4/6 (Figure 2). CDKs (catalytic subunits, heterodimeric serine/threonine kinase class) associate with cyclins (regulatory subunits) to form an active catalytic complex favoring G1/S cell-cycle progression in mitosis. For instance, CDK1/A2 or CDK1/B1 complexes trigger mitosis in mammalian cells by phosphorylating downstream cell cycle regulatory proteins<sup>[108]</sup>. Other CDKs are involved in the regulation of cellular transcription, such as CDK7-11<sup>[107,109]</sup>. A recent proteomic analysis of the CDK family in human cells has identified a CDK5 complex as a key regulator of non-neural cell growth and migration factor<sup>[110]</sup>.

### CDK involvement in breast cancer

Early and emerging evidence suggests that cyclin D1 promotes breast tumorigenesis<sup>[111,112]</sup>. CDK1 activity was recently reported as a powerful predictor of taxane chemosensitivity, indicating a role for CDK1 in breast tumorigenesis<sup>[111]</sup>. Notably, taxanes are the drug class most used for breast cancer pre-operative chemotherapy; they induce apoptosis in malignant cells by stopping their replication<sup>[113,114]</sup>. Moreover, studies investigating genes that are synthetically lethal in Myc-dependent cancer identified numerous CDKs as Myc synthetic-lethal genes<sup>[115-117]</sup>. Interestingly, in one of such studies CDK1, but not CDK2 or CDK4/6 was selectively lethal to Myc-dependent breast cancer cells<sup>[117]</sup>. This observation indicates that targeting CDK1 may induce apoptosis in Myc-dependent cancers, where Myc drives cancer cell growth and cycle progression<sup>[118]</sup>. Increases in activities and levels of other CDK complexes were also reported in breast cancer

primary tumors and experimental models, including CDK4/6 and cyclin E/CDK2 complexes<sup>[119-121]</sup>. The occurrence of cyclin E/CDK2 proteolytic cleavage products associates with poor clinical outcome in breast cancer patients and increases tumorigenicity in experimental models at least partly by promoting stem-like properties of tumor cells<sup>[120]</sup>. Transcriptional regulator CDK8 targeting was also recently reported to inhibit both the proliferation and the migration of breast cancer cells<sup>[122]</sup>. In addition, *BRC42* gene, whose aberrant activating mutations associate with familial breast cancer<sup>[123,124]</sup>, was reported to induce genomic stability in malignant cells through a CDK-dependent mechanism<sup>[125]</sup>.

A link between the cell cycle and steroid hormone metabolism involving CDK4/6 was recently uncovered in breast cancer primary tumor cells<sup>[126]</sup>. In this study, malignant cells appeared to control the activity of steroid metabolic enzymes, *i.e.*, the expression of steroid hormone receptors (including ER), by alteration of CDK4/6-levels (overexpression of CDK4 and decrease of its homolog CDK6). Such mechanism may play a pivotal role in the carcinogenesis and chemoresistance of steroid hormone-dependent cancers. In another recent study the newly synthesized compound KU004 that had a potent anticancer effect by targeting HER2 induced a decrease in CDK4 expression<sup>[127]</sup>. On the same hand, CDK 4/6 inhibitors sensitized *PIK3CA* mutant breast cancer to PI3K inhibitors in a xenograft study<sup>[128]</sup> (Figure 2), further suggesting a role for CDK4/6 imbalance in breast tumorigenesis.

### CDK inhibitors

CDK4/6 inhibitors are more efficient and less toxic anti-neoplastic agents than molecules targeting other CDKs<sup>[129]</sup>. The selective cyclin D kinase 4/6 inhibitor palbociclib (PD-0332991) is currently entering phase III trial for ER+ breast cancer patients, following encouraging results in progression free survival in phase II trials<sup>[130]</sup>. Using the bioluminescence imaging technology, an early study in xenograft models displaying metastatic progression revealed powerful antimetastatic effects, comparable to avastin, and docetaxel effects<sup>[131]</sup>. In addition, palbociclib, preferentially inhibited the proliferation of luminal ER+ breast cancer cell lines *in vitro*<sup>[132]</sup>, suppressed malignant cell proliferation in approximately 85% of cases irrespective of ER+/- or HER2+/- statuses<sup>[133]</sup>. Furthermore, palbociclib induced growth arrest in hormone-resistant MCF-7 breast cancer cells by a mechanism consistent with cellular senescence<sup>[134]</sup>. This observation is not surprising considering the functional link between tumor microenvironment carcinogenic activity, ageing, and autophagy discussed above (section 2.1), and indicate that the drug may also affect metabolic processes in CAFs and stem-like tumor cells<sup>[133,134]</sup>.

Chemoresistance to CDK4/6 inhibitors has been reported<sup>[133,135]</sup>. Analyses of primary tumor cells of cases resistant to CDK4/6 inhibitors showed that these cells lack the tumor suppressor retinoblastoma protein (RB)<sup>[133]</sup>,

which is necessary for CDK4/6 control of the cell cycle restriction point<sup>[135]</sup>. Interestingly, RB-deficient chemoresistant breast cancers, such as RB-deficient triple negative breast cancers, are more sensitive to the metabolic inhibitor of the folate analog family methotrexate and to the anthracycline topoisomerase inhibitor doxorubicin compared to RB+ cell lines<sup>[136]</sup>, indicating that combination therapy may improve CDK4/6 inhibitor response in resistant cases. However, a report by Roberts and colleagues cautioned against the use of these agents in combination with DNA-damaging drugs (*e.g.*, doxorubicin, carboplatin), considering the potential genotoxic side effects<sup>[129]</sup>. The dangers that may result from such combination also emerged in other pre-clinical studies<sup>[137,138]</sup>.

The CDKI dinaciclib (MK-7965), which selectively binds to the ATP site of CDKs and acts as a protein-protein inhibitor of bromodomains<sup>[139,140]</sup>, also displayed encouraging anticancer properties in pre-clinical studies in human cancer models<sup>[141,142]</sup>. The drug recently entered phase III in leukemia<sup>[139]</sup> and phase II trial in solid cancers. The drug is well tolerated in monotherapy, but revealed an antitumor activity whose efficacy was not superior to the nucleoside metabolic inhibitor capecitabine in a phase II trial in advanced breast cancer patients<sup>[143]</sup>. Comparable observations were reported in non-small cell lung cancer where the drug was compared with the protein kinase inhibitor erlotinib<sup>[144]</sup>. Similar combination therapy studies in progress for breast cancer<sup>[143,144]</sup> may provide alternative strategies for breast cancer therapy.

## OTHER EMERGING THERAPEUTIC TARGETS

### Wnt signaling

A number of reports have suggested that Wnt signaling pathway, which is normally involved in embryonic induction and cell fate<sup>[145,146]</sup>, is aberrantly activated in blood cancers<sup>[147-149]</sup> and solid cancers, such as head and neck, lung, gastrointestinal, and breast cancer<sup>[27,150-155]</sup>. Wnt5a and Wnt11 are major players in macrophage-induced malignant invasion in metastatic breast cancer<sup>[27,151]</sup>, and several breast tumors constitutively release-inducible Wnt ligands<sup>[156]</sup>. In addition, the naturally occurring pentacyclic triterpenoid ursolic acid, which is known to exert anti-tumor activity in various solid cancers including breast cancer, may act through inhibition of canonical (Wnt/ $\beta$ -catenin) signaling<sup>[150]</sup>. Similarly, the natural plant polyphenol rottlerin was reported to inhibit Wnt/ $\beta$ -catenin signaling in cancer cells by promoting the degradation of Wnt co-receptor LRP6 (low density lipoprotein receptor-related protein 6)<sup>[157]</sup>. Such inhibition resulted in cell death in various cancer cell lines, including MDA-MB-231 and T-47D breast cancer cells. Salinomycin, another novel LRP6 inhibitor, induced comparable effects in breast and prostate cancer cell lines, by inhibiting both Wnt/ $\beta$ -catenin and PI3K/Akt/mTOR signaling<sup>[158]</sup>.

The development of specific Wnt inhibitors is in



progress. Recently, a specific inhibitor of Porcupine (PORCN, an O-acyltransferase required for the secretion of Wnt ligands<sup>[159]</sup>) termed as LGK974 was developed. LGK974 displayed potent anticancer properties in *in vitro* and *in vivo* models of breast cancer and pancreatic adenocarcinoma mediated by reduction of the transcriptional expression of Wnt target genes<sup>[147,160]</sup>. However, another recent report revealed that Wnt signaling molecules are differentially expressed in breast cancer clinical subtypes and in cancer stem-like cells, indicating that the development of more specific Wnt-targeted therapies in breast cancer may be necessary<sup>[161]</sup>. Wnt signaling was also reported a major role in malignant cell acquired resistance to classical chemotherapy, including resistance to tamoxifen<sup>[162]</sup>, and in chemoresistant cells from triple negative breast cancer patients<sup>[163]</sup>, suggesting the potential of Wnt inhibitor combination therapies.

### Shh signaling

Early studies have suggested that Sonic Hedgehog (Shh) overexpression, mediated by both NF- $\kappa$ B up-regulation and *shh* promoter hypomethylation in breast cancer<sup>[164]</sup>, is a critical event in the development of various solid cancers<sup>[165-167]</sup>. For instance, Shh signaling was reported to promote the survival of cancer epithelial cells, but not their normal counterparts<sup>[168]</sup>. Targeting of Shh transcription activator Gli1 enhanced apoptosis and attenuated migration in inflammatory breast cancer cells<sup>[169]</sup>. In addition, Shh non-classical activation was reported as a multidrug resistance enhancer, including resistance to Smo inhibitors<sup>[170]</sup>, suggesting that targeting these pathways specifically may abrogate the associated chemoresistance.

Smo inhibitor anticancer drug cyclopamine, which inhibits Shh signaling by antagonizing its downstream target Smo, is metabolically stable and is currently investigated for the treatment of various cancers<sup>[171-173]</sup>. The chemotherapy drug paclitaxel used in combination with cyclopamine was shown to antagonize chemoresistant breast cancer cells both *in vivo* and *in vitro*<sup>[174]</sup>, suggesting Shh signaling as a candidate for targeted therapy in chemoresistant cancer cells. Similarly, cyclopamine also sensitized chemoresistant tumor cells to taxane drugs in ovarian cancer<sup>[175]</sup>, another hormone-related cancer. Not surprisingly, Shh targeting was reported as a therapeutic option in endocrine-resistant breast cancer due to its ability to sensitize PI3K/AKT signaling-induced tamoxifen chemoresistant malignant cells<sup>[176]</sup>.

Notably, ER- $\alpha$  physiologically regulates non-canonical Shh signaling in the mammary gland, and is essential for mammary gland morphogenesis at puberty<sup>[177,178]</sup>. However, Gli1 expression also enhances migration and invasion of malignant cells in ER $\alpha$ -negative and triple negative breast cancers, where it represents a predictor of poor prognosis<sup>[179]</sup>. These observations indicate that Shh signaling involvement in breast cancer cells is complex and therefore targeting Shh in chemoresistant cancer therapy can also compromise its normal physiological function.

## FUTURE DIRECTIONS:

### PERSONALIZED-BASED THERAPY AND EPIGENETIC TARGETS

#### Personalized-based therapy

The major challenges in breast cancer treatment include resistance to chemotherapy, hormone therapy and even targeted therapy (Table 1), which underline the need for developing novel targeted therapies. Although the main molecular events driving cancer involve the activation of proto-oncogenes or the inactivation of tumor suppressors, deregulation of various signaling intermediates and metabolic factors have been well documented<sup>[72,77,82,83,149,161]</sup>. The events triggering cancer development affect proto-oncogenes such as Notch, Wnt, and Shh, which are the developmental genes driving embryonic induction and organogenesis during fetal life. These genes, whose expression is normally transcriptionally reduced or silenced in most adult tissues (except stem-like cells) by regulator molecules, are aberrantly overexpressed in cancer cells, conferring them stem-like properties<sup>[72,77,82,83,149,161]</sup>.

Concomitantly, neoplastic tissue growth is fuelled by the upregulation and overexpression of receptors such as HER2, ER and, IGF-1R<sup>[70,71,180]</sup>, the upregulation and/or activation of signaling molecules associated with cell proliferation<sup>[111,112]</sup>, cell migration<sup>[181,182]</sup>, oxidative stress, hypoxia and neoangiogenesis<sup>[22,26]</sup>, all which are characteristic of tumor microenvironment. Thus, the complete characterization of all these tumor promoting events will pave the way for the development more efficient and less toxic anticancer drugs. Computational causal network models aimed at improving the current understanding of signaling molecule interactions in breast cancer, which will allow the determination of specific subsets of patients susceptible to a given therapeutic approach, are currently in development<sup>[156,183]</sup>. Although the complexity of such networks makes this effort challenging, nonetheless, the development of such tool would allow implementation of a highly efficient personalized-based therapy in breast cancer.

#### Epigenetic changes drive tumorigenesis

Epigenetics describes heritable alterations in gene expression patterns that do not alter the primary DNA sequence, but play critical roles in normal differentiation and development. Epigenetic alterations include modifications such as DNA methylation, histone modifications and nucleosome remodeling. The plasticity and reversibility of epigenetic events enable a better control of the dynamism of cellular processes. However, deregulation of the normal epigenetic patterns can lead to aberrant expression of cell growth regulatory genes that can culminate in cancer. Epigenetic factors affect gene expression both pre- and post-transcriptionally and probably account for the high inter-individual variability in clinical course and treatment outcome of both blood and solid cancers<sup>[184,185]</sup>. There is ample evidence linking

**Table 1** Current therapeutics for breast cancer

Drug	Trade name	Class	Anticancer mechanism
Classical chemotherapy			
Methotrexate	Abitrexate®, Mexate®, Folex®	Antimetabolites, folate analogs	Folate receptor competitive antagonist <sup>[218]</sup>
5-fluorouracil	Adrucil®, Efudex®, Fluoroplex®, prodrug capecitabine/Xeloda®	Antimetabolite, pyrimidine analogs	Inhibition of the phosphatase and tensin homolog thymidylate synthase <sup>[219]</sup>
Gemcitabine hydrochloride	Gemzar®	Anthracycline	Deoxyribonuclease inhibitor <sup>[220]</sup>
Doxorubicin hydrochloride	Adriamycin®		
Epirubicin hydrochloride	Ellence®		
Pamidronate disodium	Aredia®		
Cyclophosphamide	Clafen®, Cytoxan®, Neosar®	Nitrogen-containing bisphosphonate	Inhibition of farnesyl pyrophosphate synthase activity <sup>[221]</sup>
		Nitrogen mustard alkylating agent	Inhibition of DNA replication by interacting with the alkyl group of DNA guanine base <sup>[222]</sup>
Paclitaxel	Abraxane® Taxol®	Taxanes	Microtubule Inhibitors <sup>[223,224]</sup>
Docetaxel	Docetad®, Taxotere®		
Ixabepilone	Ixemptra®	Epothilone B analog	
Targeted therapy			
Everolimus	Afinitor®	mTOR inhibitor	Silencing of PI3K/ Akt/ mTOR signaling <sup>[225]</sup>
Trastuzumab	Herceptin®	HER2 inhibitor	Anti-HER2 monoclonal antibodies <sup>[226,227]</sup>
Pertuzumab	Perjeta®	Antibody-drug conjugate Dual tyrosine kinase inhibitor	HER2 inhibitor and cytotoxic agent <sup>[228]</sup> EGFR/HER2 inhibitor <sup>[229]</sup>
Ado-Trastuzumab Emtansine	Kadcyla®		
Lapatinib ditosylate	Tykerb®		
Hormone therapy			
Toremifene	Fareston®	Selective ER modulator ER antagonists	Silence ER signaling <sup>[230,231]</sup>
Fulvestrant	Faslodex®		
Tamoxifen citrate	Nolvadex®	Aromatase inhibitors	Inhibit estrogen synthesis <sup>[232-234]</sup>
Anastrozole	Arimidex®		
Exemestane	Aromasin®		
Letrozole	Femara®	GnRH agonist Progesterone derivative	Progestational and antigonadotropic effects <sup>[235]</sup>
Goserelin acetate	Zoladex®		
Megestrol acetate	Megace®		

PI3K: Phosphatidylinositol 3-kinase; Akt: Protein kinase B; HER: Epidermal growth factor receptor 2.

the etiology of breast to abnormal genetic and epigenetic events<sup>[180,186,187]</sup>. Cancer-specific DNA methylation changes and well as dysregulation of histone modification have been characterized as contributors to breast cancer development. Progress in our understanding of epigenetics mechanisms in breast cancer have led to the identification of novel therapeutic targets. Recent therapeutic strategies involving the use of epigenetic agents alone or in combination with chemotherapy and/or endocrine therapy are showing promising results in breast cancer patients including chemoresistant cases<sup>[186,188]</sup>.

The technological breakthrough of “omics era” has allowed the development of high-throughput sequencing technology allowing both global and comprehensive investigations of the interactome, the epigenome, and the transcriptome (*i.e.*, active signaling pathways, cascades of pre- and post-translational changes affecting specific genes, and changes in gene expression)<sup>[189-191]</sup> at individual level. Epigenetic alterations in cancer constitute appealing therapeutic targets due to their pivotal roles in disease initiation, progression, and chemoresistance, and to their reversibility. For instance, chemoresistance to the ER antagonist fulvestrant is mediated by epigenetic modulation (more specifically hSWI/SNF-mediated chromatin remodeling) of GPER and CDK6 expression<sup>[192]</sup>, suggesting that adjuvant therapy targeting SWI/SNF activity may induce apoptosis in resistant cancer cells. SWI/SNF

tumor-dependency has also been reported in other solid cancers and in leukemias<sup>[193,194]</sup>.

**Epigenetic targets in breast cancer:** histone deacetylation and DNA hypermethylation

Studies have shown that the transcriptional expression of various signaling molecules associated with breast cancer and other cancers may result from selective epigenetic silencing of regulator genes mediated by histone deacetylation and gene promoter (DNA) hypermethylation<sup>[195-197]</sup>, among other potential epigenetic mechanisms<sup>[186,198]</sup>. For instance, the reduction in ER expression observed in various chemoresistant breast tumors may be mediated by epigenetic silencing (*e.g.*, *erbB1* silencing)<sup>[199]</sup>; and some histone deacetylases (HDACs) such as HDAC3/8 were reported to play pivotal regulatory roles in the proliferation of normal and MDA-MB-231 cells<sup>[200]</sup>.

Data from numerous pre-clinical *in vivo* and *in vitro* studies support the potential of DNA methylation status targeting in breast cancer. Both the HDAC inhibitor (HDACI) trichostatin A and the DNA methyltransferase (DNMT) inhibitor (DNMTI) deoxycytidine (5-aza-2'-deoxycytidine) induced apoptosis in various breast cancer cell lines<sup>[201-205]</sup>. The HDACI Romidepsin (FK-288) eliminated both primary and metastatic tumors in combination with Paclitaxel in the Mary-X pre-clinical model of inflammatory breast cancer<sup>[206]</sup>. The green tea-derived

anticancer molecule epigallocatechin-3-gallate suppressed invasiveness in MDA-MB-231 and MCF-7 breast cancer cells by silencing matrix metalloproteinase 2 (MMP2) and MMP-9 and inducing TIMP-3 through increased activities of the enhancer of zeste homolog 2 and HDACs<sup>[207]</sup>. Suberoylanilide hydroxamic acid, another naturally occurring HDACI, restored radiosensitivity and suppressed breast cancer lung metastasis *in vitro* and *in vivo*<sup>[208]</sup>.

The HDACI Vorinostat sensitized mesenchymal-like triple-negative breast cancer cell lines to hormone therapy by reactivating ER $\alpha$ <sup>[209]</sup> and PI3K/Akt/mTOR signaling sensitivity<sup>[210]</sup>, corroborating the role of epigenetic alterations in chemoresistance development in breast tumors. Furthermore, the HDACI abexinostat induced cancer-like stem cells differentiation in 16 breast cancer cell lines<sup>[211]</sup>. Because of these interesting observations, the HDACIs belinostat, panobinostat, and vorinostat, previously used only in blood cancers, have entered phase I and II clinical trials in solid tumors, such as lung, prostate, gastrointestinal, ovarian and breast cancer, where they are showing encouraging results (for review see<sup>[212]</sup>). Various DNMTI are also showing encouraging responses in metastatic and chemoresistant breast cancers in monotherapy and in combination therapies in phase I and II trials<sup>[213-217]</sup>.

## CONCLUSION

Targeted therapies are associated with reduced adverse effects and better outcome. Tumor microenvironment cells such as cancer-associated fibroblasts and tumor-associated macrophages undergo aberrant genetic and epigenetic changes that trigger the overexpression of signaling molecules promoting neoplasia and neoplastic tissue survival. Many therapeutic targets have emerged. They include Notch, CDKs, mTOR, Wnt, and Shh, whose inhibitors are showing promising results in ongoing clinical trials, both in monotherapy and in combination therapy. Similarly, epigenetic drugs are also showing encouraging results in breast cancer, particularly in advanced and chemoresistant cases. New technological advances will enable the identification of precise alterations affecting the interactome, transcriptome, and the epigenome, leading to the design of more specific tailored therapies. Such therapeutic approach may also be beneficial in the treatment of chemoresistant breast cancers.

## REFERENCES

- 1 **Azim HA**, Ibrahim AS. Breast cancer in Egypt, China and Chinese: statistics and beyond. *J Thorac Dis* 2014; **6**: 864-866 [PMID: 25093081 DOI: 10.3978/j.issn.2072-1439.2014.06.38]
- 2 **Youlden DR**, Cramb SM, Yip CH, Baade PD. Incidence and mortality of female breast cancer in the Asia-Pacific region. *Cancer Biol Med* 2014; **11**: 101-115 [PMID: 25009752 DOI: 10.7497/j.issn.2095-3941.2014.02.005]
- 3 **Villarreal-Garza C**, Aguila C, Magallanes-Hoyos MC, Mohar A, Bargalló E, Meneses A, Cazap E, Gomez H, López-Carrillo L, Chávarri-Guerra Y, Murillo R, Barrios C. Breast cancer in young women in Latin America: an unmet, growing burden. *Oncologist* 2013; **18**: 1298-1306 [PMID: 24277771 DOI: 10.1634/theoncologist.2013-0321]
- 4 **de Azambuja E**, Ameye L, Paesmans M, Zielinski CC, Piccart-Gebhart M, Preusser M. The landscape of medical oncology in Europe by 2020. *Ann Oncol* 2014; **25**: 525-528 [PMID: 24425791 DOI: 10.1093/annonc/mdt559]
- 5 **Zengel B**, Yazarbas U, Duran A, Uslu A, Elyatkin N, Demirkiran MA, Cengiz F, Simsek C, Postacı H, Vardar E, Durusoy R. Comparison of the clinicopathological features of invasive ductal, invasive lobular, and mixed (invasive ductal + invasive lobular) carcinoma of the breast. *Breast Cancer* 2013 Aug 8; Epub ahead of print [PMID: 23925582 DOI: 10.1007/s12282-013-0489-8]
- 6 **Arps DP**, Jorns JM, Zhao L, Bensenhaver J, Kleer CG, Pang JC. Re-Excision Rates of Invasive Ductal Carcinoma with Lobular Features Compared with Invasive Ductal Carcinomas and Invasive Lobular Carcinomas of the Breast. *Ann Surg Oncol* 2014; Epub ahead of print [PMID: 24980090 DOI: 10.1245/s10434-014-3871-7]
- 7 **Al-Foheidi M**, Al-Mansour MM, Ibrahim EM. Breast cancer screening: review of benefits and harms, and recommendations for developing and low-income countries. *Med Oncol* 2013; **30**: 471 [PMID: 23420062 DOI: 10.1007/s12032-013-0471-5]
- 8 **Onega T**, Weaver D, Geller B, Oster N, Tosteson AN, Carney PA, Nelson H, Allison KH, O'Malley FP, Schnitt SJ, Elmore JG. Digitized whole slides for breast pathology interpretation: current practices and perceptions. *J Digit Imaging* 2014; **27**: 642-648 [PMID: 24682769]
- 9 **Suzuki A**, Ishida T, Ohuchi N. Controversies in breast cancer screening for women aged 40-49 years. *Jpn J Clin Oncol* 2014; **44**: 613-618 [PMID: 24821976 DOI: 10.1093/jjco/hyu054]
- 10 **Paci E**, Broeders M, Hofvind S, Puliti D, Duffy SW. European breast cancer service screening outcomes: a first balance sheet of the benefits and harms. *Cancer Epidemiol Biomarkers Prev* 2014; **23**: 1159-1163 [PMID: 24991022 DOI: 10.1158/1055-9965.EPI-13-0320]
- 11 **Plescia M**, White MC. The National Prevention Strategy and breast cancer screening: scientific evidence for public health action. *Am J Public Health* 2013; **103**: 1545-1548 [PMID: 23865665 DOI: 10.2105/AJPH.2013.301305]
- 12 **Nishikawa RM**, Gur D. CADE for early detection of breast cancer-current status and why we need to continue to explore new approaches. *Acad Radiol* 2014; **21**: 1320-1321 [PMID: 25086951 DOI: 10.1016/j.acra.2014.05.018]
- 13 **Stockler MR**, Harvey VJ, Francis PA, Byrne MJ, Ackland SP, Fitzharris B, Van Hazel G, Wilcken NR, Grimison PS, Nowak AK, Gainford MC, Fong A, Paksec L, Sourjina T, Zannino D, Gebbski V, Simes RJ, Forbes JF, Coates AS. Capecitabine versus classical cyclophosphamide, methotrexate, and fluorouracil as first-line chemotherapy for advanced breast cancer. *J Clin Oncol* 2011; **29**: 4498-4504 [PMID: 22025143 DOI: 10.1200/JCO.2010.33.9101]
- 14 **Dadla A**, Tannenbaum S, Yates B, Holle L. Delayed hypersensitivity reaction related to the use of pegfilgrastim. *J Oncol Pharm Pract* 2014 Jul 3; Epub ahead of print [PMID: 24993705]
- 15 **Karczmarek-Borowska B**, Drzymala M, Golon K. Hepatotoxicity of acetaminophen in a patient treated with capecitabine due to breast cancer. *Pol Merkur Lekarski* 2014; **36**: 348-351 [PMID: 24964515]
- 16 **Hurvitz S**, Guerin A, Brammer M, Guardino E, Zhou ZY, Latremouille Viau D, Wu EQ, Lalla D. Investigation of adverse-event-related costs for patients with metastatic breast cancer in a real-world setting. *Oncologist* 2014; **19**: 901-908 [PMID: 25085897]
- 17 **Hansen RN**, Ramsey SD, Lalla D, Masaquel A, Kamath T, Brammer M, Hurvitz SA, Sullivan SD. Identification and cost of adverse events in metastatic breast cancer in taxane and capecitabine based regimens. *Springerplus* 2014; **3**: 259 [PMID: 24993705]



- 24926422 DOI: 10.1186/2193-1801-3-259]
- 18 **Mao Y**, Keller ET, Garfield DH, Shen K, Wang J. Stromal cells in tumor microenvironment and breast cancer. *Cancer Metastasis Rev* 2013; **32**: 303-315 [PMID: 23114846 DOI: 10.1007/s10555-012-9415-3]
- 19 **Vivacqua A**, Romeo E, De Marco P, De Francesco EM, Abonante S, Maggiolini M. GPER mediates the Egr-1 expression induced by 17 $\beta$ -estradiol and 4-hydroxitamoxifen in breast and endometrial cancer cells. *Breast Cancer Res Treat* 2012; **133**: 1025-1035 [PMID: 22147081 DOI: 10.1007/s10549-011-1901-8]
- 20 **Farmaki E**, Chatzistamou I, Bourlis P, Santoukou E, Trimis G, Papavassiliou AG, Kiaris H. Selection of p53-Deficient Stromal Cells in the Tumor Microenvironment. *Genes Cancer* 2012; **3**: 592-598 [PMID: 23486847 DOI: 10.1177/1947601912474002]
- 21 **Tao L**, Roberts AL, Dunphy KA, Bigelow C, Yan H, Jerry DJ. Repression of mammary stem/progenitor cells by p53 is mediated by Notch and separable from apoptotic activity. *Stem Cells* 2011; **29**: 119-127 [PMID: 21280161 DOI: 10.1002/stem.552]
- 22 **De Francesco EM**, Lappano R, Santolla MF, Marsico S, Caruso A, Maggiolini M. HIF-1 $\alpha$ /GPER signaling mediates the expression of VEGF induced by hypoxia in breast cancer associated fibroblasts (CAFs). *Breast Cancer Res* 2013; **15**: R64 [PMID: 23947803 DOI: 10.1186/bcr3458]
- 23 **Pupo M**, Pisano A, Abonante S, Maggiolini M, Musti AM. GPER activates Notch signaling in breast cancer cells and cancer-associated fibroblasts (CAFs). *Int J Biochem Cell Biol* 2014; **46**: 56-67 [PMID: 24275097 DOI: 10.1016/j.biocel.2013.11.011]
- 24 **Nwabo Kamdje AH**, Mosna F, Bifari F, Lisi V, Bassi G, Malpeli G, Ricciardi M, Perbellini O, Scupoli MT, Pizzolo G, Krampera M. Notch-3 and Notch-4 signaling rescue from apoptosis human B-ALL cells in contact with human bone marrow-derived mesenchymal stromal cells. *Blood* 2011; **118**: 380-389 [PMID: 21602525 DOI: 10.1182/blood-2010-12-326694]
- 25 **Nwabo Kamdje AH**, Bassi G, Pacelli L, Malpeli G, Amati E, Nichele I, Pizzolo G, Krampera M. Role of stromal cell-mediated Notch signaling in CLL resistance to chemotherapy. *Blood Cancer J* 2012; **2**: e73 [PMID: 22829975 DOI: 10.1038/bcj.2012.17]
- 26 **Guo S**, Gonzalez-Perez RR. Notch, IL-1 and leptin crosstalk outcome (NILCO) is critical for leptin-induced proliferation, migration and VEGF/VEGFR-2 expression in breast cancer. *PLoS One* 2011; **6**: e21467 [PMID: 21731759]
- 27 **Luga V**, Wrana JL. Tumor-stroma interaction: Revealing fibroblast-secreted exosomes as potent regulators of Wnt-planar cell polarity signaling in cancer metastasis. *Cancer Res* 2013; **73**: 6843-6847 [PMID: 24265274 DOI: 10.1158/0008-5472.CAN-13-1791]
- 28 **Bochet L**, Lehuédé C, Dauvillier S, Wang YY, Dirat B, Laurent V, Dray C, Guét R, Maridonneau-Parini I, Le Goudec S, Couderc B, Escourrou G, Valet P, Muller C. Adipocyte-derived fibroblasts promote tumor progression and contribute to the desmoplastic reaction in breast cancer. *Cancer Res* 2013; **73**: 5657-5668 [PMID: 23903958 DOI: 10.1158/0008-5472.CAN-13-0530]
- 29 **Ota D**, Kanayama M, Matsui Y, Ito K, Maeda N, Kutomi G, Hirata K, Torigoe T, Sato N, Takaoka A, Chambers AF, Morimoto J, Ueda T. Tumor- $\alpha\beta 1$  integrin-mediated signaling induces breast cancer growth and lymphatic metastasis via the recruitment of cancer-associated fibroblasts. *J Mol Med (Berl)* 2014 Aug 8; Epub ahead of print [PMID: 25099519 DOI: 10.1007/s00109-014-1183-9]
- 30 **Ishikawa M**, Inoue T, Shirai T, Takamatsu K, Kunihiro S, Ishii H, Nishikata T. Simultaneous expression of cancer stem cell-like properties and cancer-associated fibroblast-like properties in a primary culture of breast cancer cells. *Cancers (Basel)* 2014; **6**: 1570-1578 [PMID: 25089665 DOI: 10.3390/cancers6031570]
- 31 **Scherz-Shouval R**, Santagata S, Mendillo ML, Sholl LM, Ben-Aharon I, Beck AH, Dias-Santagata D, Koeva M, Stemmer SM, Whitesell L, Lindquist S. The reprogramming of tumor stroma by HSF1 is a potent enabler of malignancy. *Cell* 2014; **158**: 564-578 [PMID: 25083868 DOI: 10.1016/j.cell.2014.05.045]
- 32 **Capparelli C**, Guido C, Whitaker-Menezes D, Bonuccelli G, Balliet R, Pestell TG, Goldberg AF, Pestell RG, Howell A, Sneddon S, Birbe R, Tsigos A, Martinez-Outschoorn U, Sotgia F, Lisanti MP. Autophagy and senescence in cancer-associated fibroblasts metabolically supports tumor growth and metastasis via glycolysis and ketone production. *Cell Cycle* 2012; **11**: 2285-2302 [PMID: 22684298 DOI: 10.4161/cc.20718]
- 33 **Capparelli C**, Chiavarina B, Whitaker-Menezes D, Pestell TG, Pestell RG, Hulit J, Andò S, Howell A, Martinez-Outschoorn UE, Sotgia F, Lisanti MP. CDK inhibitors (p16/p19/p21) induce senescence and autophagy in cancer-associated fibroblasts, "fueling" tumor growth via paracrine interactions, without an increase in neo-angiogenesis. *Cell Cycle* 2012; **11**: 3599-3610 [PMID: 22935696 DOI: 10.4161/cc.21884]
- 34 **Avena P**, Anselmo W, Whitaker-Menezes D, Wang C, Pestell RG, Lamb RS, Hulit J, Casaburi I, Andò S, Martinez-Outschoorn UE, Lisanti MP, Sotgia F. Compartment-specific activation of PPAR $\gamma$  governs breast cancer tumor growth, via metabolic reprogramming and symbiosis. *Cell Cycle* 2013; **12**: 1360-1370 [PMID: 23574724 DOI: 10.4161/cc.24289]
- 35 **Tymoszyk P**, Evens H, Marzola V, Wachowicz K, Wasmer MH, Datta S, Müller-Holzner E, Fiegl H, Böck G, van Rooijen N, Theurl I, Doppler W. In situ proliferation contributes to accumulation of tumor-associated macrophages in spontaneous mammary tumors. *Eur J Immunol* 2014; **44**: 2247-2262 [PMID: 24796276 DOI: 10.1002/eji.201344304]
- 36 **Xuan QJ**, Wang JX, Nanding A, Wang ZP, Liu H, Lian X, Zhang QY. Tumor-associated macrophages are correlated with tamoxifen resistance in the postmenopausal breast cancer patients. *Pathol Oncol Res* 2014; **20**: 619-624 [PMID: 24414992 DOI: 10.1007/s12253-013-9740-z]
- 37 **Chaturvedi P**, Gilkes DM, Takano N, Semenza GL. Hypoxia-inducible factor-dependent signaling between triple-negative breast cancer cells and mesenchymal stem cells promotes macrophage recruitment. *Proc Natl Acad Sci USA* 2014; **111**: E2120-E2129 [PMID: 24799675 DOI: 10.1073/pnas.1406655111]
- 38 **Liu H**, Wang Y, Li X, Zhang YJ, Li J, Zheng YQ, Liu M, Song X, Li XR. Expression and regulatory function of miRNA-182 in triple-negative breast cancer cells through its targeting of profilin 1. *Tumour Biol* 2013; **34**: 1713-1722 [PMID: 23430586 DOI: 10.1007/s13277-013-0708-0]
- 39 **Ouyang M**, Li Y, Ye S, Ma J, Lu L, Lv W, Chang G, Li X, Li Q, Wang S, Wang W. MicroRNA profiling implies new markers of chemoresistance of triple-negative breast cancer. *PLoS One* 2014; **9**: e96228 [PMID: 24788655 DOI: 10.1371/journal.pone.0096228]
- 40 **Yamashina T**, Baghdadi M, Yoneda A, Kinoshita I, Suzu S, Dosaka-Akita H, Jinushi M. Cancer stem-like cells derived from chemoresistant tumors have a unique capacity to prime tumorigenic myeloid cells. *Cancer Res* 2014; **74**: 2698-2709 [PMID: 24638980 DOI: 10.1158/0008-5472.CAN-13-2169]
- 41 **Oghumu S**, Varikuti S, Terrazas C, Kotov D, Nasser MW, Powell CA, Ganju RK, Satoskar AR. CXCR3 deficiency enhances tumor progression by promoting macrophage M2 polarization in a murine breast cancer model. *Immunology* 2014; **143**: 109-119 [PMID: 24679047 DOI: 10.1111/imm.12293]
- 42 **Deng R**, Wang SM, Yin T, Ye TH, Shen GB, Li L, Zhao JY, Sang YX, Duan XG, Wei YQ. Dimethyl Sulfoxide Suppresses Mouse 4T1 Breast Cancer Growth by Modulating Tumor-Associated Macrophage Differentiation. *J Breast Cancer* 2014; **17**: 25-32 [PMID: 24744794 DOI: 10.4048/jbc.2014.17.1.25]
- 43 **Milovanovic T**, Planutis K, Nguyen A, Marsh JL, Lin F, Hope C, Holcombe RF. Expression of Wnt genes and frizzled 1 and 2 receptors in normal breast epithelium and infiltrat-



- ing breast carcinoma. *Int J Oncol* 2004; **25**: 1337-1342 [PMID: 15492823 DOI: 10.3892/ijo.25.5.1337]
- 44 **Benhaj K**, Akcali KC, Ozturk M. Redundant expression of canonical Wnt ligands in human breast cancer cell lines. *Oncol Rep* 2006; **15**: 701-707 [PMID: 16465433 DOI: 10.3892/or.15.3.701]
  - 45 **Yeo EJ**, Cassetta L, Qian BZ, Lewkowich I, Li JF, Stefater JA, Smith AN, Wiechmann LS, Wang Y, Pollard JW, Lang RA. Myeloid WNT7b mediates the angiogenic switch and metastasis in breast cancer. *Cancer Res* 2014; **74**: 2962-2973 [PMID: 24638982 DOI: 10.1158/0008-5472.CAN-13-2421]
  - 46 **Zhang Y**, Guo Q, Zhang Z, Bai N, Liu Z, Xiong M, Wei Y, Xiang R, Tan X. VDR status arbitrates the prometastatic effects of tumor-associated macrophages. *Mol Cancer Res* 2014; **12**: 1181-1191 [PMID: 24821711 DOI: 10.1158/1541-7786.MCR-14-0036]
  - 47 **Pukrop T**, Klemm F, Hagemann T, Gradl D, Schulz M, Siemes S, Trümper L, Binder C. Wnt 5a signaling is critical for macrophage-induced invasion of breast cancer cell lines. *Proc Natl Acad Sci USA* 2006; **103**: 5454-5459 [PMID: 16569699 DOI: 10.1073/pnas.0509703103]
  - 48 **Ojalvo LS**, Whittaker CA, Condeelis JS, Pollard JW. Gene expression analysis of macrophages that facilitate tumor invasion supports a role for Wnt-signaling in mediating their activity in primary mammary tumors. *J Immunol* 2010; **184**: 702-712 [PMID: 20018620]
  - 49 **Bergenfels C**, Medrek C, Ekström E, Jirstrom K, Janols H, Wullt M, Bredberg A, Leandersson K. Wnt5a induces a tolerogenic phenotype of macrophages in sepsis and breast cancer patients. *J Immunol* 2012; **188**: 5448-5458 [PMID: 22547701 DOI: 10.4049/jimmunol.1103378]
  - 50 **Spano D**, Marshall JC, Marino N, De Martino D, Romano A, Scoppettuolo MN, Bello AM, Di Dato V, Navas L, De Vita G, Medaglia C, Steeg PS, Zollo M. Dipyridamole prevents triple-negative breast-cancer progression. *Clin Exp Metastasis* 2013; **30**: 47-68 [PMID: 22760522 DOI: 10.1007/s10585-012-9506-0]
  - 51 **Lai EC**. Notch signaling: control of cell communication and cell fate. *Development* 2004; **131**: 965-973 [PMID: 14973298 DOI: 10.1242/dev.01074]
  - 52 **Pintar A**, De Biasio A, Popovic M, Ivanova N, Pongor S. The intracellular region of Notch ligands: does the tail make the difference? *Biol Direct* 2007; **2**: 19 [PMID: 17623096 DOI: 10.1186/1745-6150-2-19]
  - 53 **Zhang P**, Ostrander JH, Faivre EJ, Olsen A, Fitzsimmons D, Lange CA. Regulated association of protein kinase B/Akt with breast tumor kinase. *J Biol Chem* 2005; **280**: 1982-1991 [PMID: 15539407 DOI: 10.1074/jbc.M412038200]
  - 54 **Wu L**, Sun T, Kobayashi K, Gao P, Griffin JD. Identification of a family of mastermind-like transcriptional coactivators for mammalian notch receptors. *Mol Cell Biol* 2002; **22**: 7688-7700 [PMID: 12370315 DOI: 10.1128/MCB.22.21.7688-7700.2002]
  - 55 **Weng AP**, Millholland JM, Yashiro-Ohtani Y, Arcangeli ML, Lau A, Wai C, Del Bianco C, Rodriguez CG, Sai H, Tobias J, Li Y, Wolfe MS, Shachaf C, Felsner D, Blacklow SC, Pear WS, Aster JC. c-Myc is an important direct target of Notch1 in T-cell acute lymphoblastic leukemia/lymphoma. *Genes Dev* 2006; **20**: 2096-2109 [PMID: 16847353 DOI: 10.1101/gad.1450406]
  - 56 **Sun Y**, Lowther W, Kato K, Bianco C, Kenney N, Strizzi L, Raafat D, Hirota M, Khan NI, Bargo S, Jones B, Salomon D, Callahan R. Notch4 intracellular domain binding to Smad3 and inhibition of the TGF-beta signaling. *Oncogene* 2005; **24**: 5365-5374 [PMID: 16007227 DOI: 10.1038/sj.onc.1208528]
  - 57 **Stylianou S**, Clarke RB, Brennan K. Aberrant activation of notch signaling in human breast cancer. *Cancer Res* 2006; **66**: 1517-1525 [PMID: 16452208 DOI: 10.1158/0008-5472.CAN-05-3054]
  - 58 **Liu Z**, Teng L, Bailey SK, Frost AR, Bland KI, LoBuglio AF, Ruppert JM, Lobo-Ruppert SM. Epithelial transformation by KLF4 requires Notch1 but not canonical Notch1 signaling. *Cancer Biol Ther* 2009; **8**: 1840-1851 [PMID: 19717984]
  - 59 **Brabletz S**, Bajdak K, Meidhof S, Burk U, Niedermann G, Firat E, Wellner U, Dimmler A, Faller G, Schubert J, Brabletz T. The ZEB1/miR-200 feedback loop controls Notch signalling in cancer cells. *EMBO J* 2011; **30**: 770-782 [PMID: 21224848 DOI: 10.1038/emboj.2010.349]
  - 60 **Sethi N**, Dai X, Winter CG, Kang Y. Tumor-derived JAGGED1 promotes osteolytic bone metastasis of breast cancer by engaging notch signaling in bone cells. *Cancer Cell* 2011; **19**: 192-205 [PMID: 21295524 DOI: 10.1016/j.ccr.2010.12.022]
  - 61 **Xing F**, Okuda H, Watabe M, Kobayashi A, Pai SK, Liu W, Pandey PR, Fukuda K, Hirota S, Sugai T, Wakabayashi G, Koeda K, Kashiwaba M, Suzuki K, Chiba T, Endo M, Mo YY, Watabe K. Hypoxia-induced Jagged2 promotes breast cancer metastasis and self-renewal of cancer stem-like cells. *Oncogene* 2011; **30**: 4075-4086 [PMID: 21499308 DOI: 10.1038/onc.2011.122]
  - 62 **Shi W**, Harris AL. Notch signaling in breast cancer and tumor angiogenesis: cross-talk and therapeutic potentials. *J Mammary Gland Biol Neoplasia* 2006; **11**: 41-52 [PMID: 16947085 DOI: 10.1007/s10911-006-9011-7]
  - 63 **Xiao Y**, Ye Y, Zou X, Jones S, Yearsley K, Shetuni B, Tellez J, Barsky SH. The lymphovascular embolus of inflammatory breast cancer exhibits a Notch 3 addiction. *Oncogene* 2011; **30**: 287-300 [PMID: 20838375 DOI: 10.1038/onc.2010.405]
  - 64 **Lee CW**, Raskett CM, Prudovsky I, Altieri DC. Molecular dependence of estrogen receptor-negative breast cancer on a notch-survivin signaling axis. *Cancer Res* 2008; **68**: 5273-5281 [PMID: 18593928 DOI: 10.1158/0008-5472.CAN-07-6673]
  - 65 **Lee CW**, Simin K, Liu Q, Plescia J, Guha M, Khan A, Hsieh CC, Altieri DC. A functional Notch-survivin gene signature in basal breast cancer. *Breast Cancer Res* 2008; **10**: R97 [PMID: 19025652 DOI: 10.1186/bcr2200]
  - 66 **Rizzo P**, Miao H, D'Souza G, Osipo C, Song LL, Yun J, Zhao H, Mascarenhas J, Wyatt D, Antico G, Hao L, Yao K, Rajan P, Hicks C, Siziopikou K, Selvaggi S, Bashir A, Bhandari D, Marchese A, Lendahl U, Qin JZ, Tonetti DA, Albain K, Nickoloff BJ, Miele L. Cross-talk between notch and the estrogen receptor in breast cancer suggests novel therapeutic approaches. *Cancer Res* 2008; **68**: 5226-5235 [PMID: 18593923 DOI: 10.1158/0008-5472.CAN-07-5744]
  - 67 **Dai J**, Ma D, Zang S, Guo D, Qu X, Ye J, Ji C. Cross-talk between Notch and EGFR signaling in human breast cancer cells. *Cancer Invest* 2009; **27**: 533-540 [PMID: 19219656 DOI: 10.1080/07357900802563036]
  - 68 **Mungamuri SK**, Yang X, Thor AD, Somasundaram K. Survival signaling by Notch1: mammalian target of rapamycin (mTOR)-dependent inhibition of p53. *Cancer Res* 2006; **66**: 4715-4724 [PMID: 16651424 DOI: 10.1158/0008-5472.CAN-05-3830]
  - 69 **Efferson CL**, Winkelmann CT, Ware C, Sullivan T, Giampaoli S, Tammam J, Patel S, Mesiti G, Reilly JF, Gibson RE, Buser C, Yeatman T, Coppola D, Winter C, Clark EA, Draetta GF, Strack PR, Majumder PK. Downregulation of Notch pathway by a gamma-secretase inhibitor attenuates AKT/mammalian target of rapamycin signaling and glucose uptake in an ERBB2 transgenic breast cancer model. *Cancer Res* 2010; **70**: 2476-2484 [PMID: 20197467 DOI: 10.1158/0008-5472.CAN-09-3114]
  - 70 **Sridhar SS**, Hedley D, Siu LL. Raf kinase as a target for anticancer therapeutics. *Mol Cancer Ther* 2005; **4**: 677-685 [PMID: 15827342 DOI: 10.1158/1535-7163.MCT-04-0297]
  - 71 **Mittal S**, Subramanyam D, Dey D, Kumar RV, Rangarajan A. Cooperation of Notch and Ras/MAPK signaling pathways in human breast carcinogenesis. *Mol Cancer* 2009; **8**: 128 [PMID: 20030805 DOI: 10.1186/1476-4598-8-128]
  - 72 **Dong Y**, Li A, Wang J, Weber JD, Michel LS. Synthetic lethality through combined Notch-epidermal growth factor receptor pathway inhibition in basal-like breast can-

- cer. *Cancer Res* 2010; **70**: 5465-5474 [PMID: 20570903 DOI: 10.1158/0008-5472.CAN-10-0173]
- 73 **Magnifico A**, Albano L, Campaner S, Delia D, Castiglioni F, Gasparini P, Sozzi G, Fontanella E, Menard S, Tagliabue E. Tumor-initiating cells of HER2-positive carcinoma cell lines express the highest oncoprotein levels and are sensitive to trastuzumab. *Clin Cancer Res* 2009; **15**: 2010-2021 [PMID: 19276287 DOI: 10.1158/1078-0432.CCR-08-1327]
- 74 **Dickson BC**, Mulligan AM, Zhang H, Lockwood G, O'Malley FP, Egan SE, Reedijk M. High-level JAG1 mRNA and protein predict poor outcome in breast cancer. *Mod Pathol* 2007; **20**: 685-693 [PMID: 17507991 DOI: 10.1038/modpathol.3800785]
- 75 **Osipo C**, Patel P, Rizzo P, Clementz AG, Hao L, Golde TE, Miele L. ErbB-2 inhibition activates Notch-1 and sensitizes breast cancer cells to a gamma-secretase inhibitor. *Oncogene* 2008; **27**: 5019-5032 [PMID: 18469855 DOI: 10.1038/onc.2008.149]
- 76 **Zang S**, Ji Ch, Qu X, Dong X, Ma D, Ye J, Ma R, Dai J, Guo D. A study on Notch signaling in human breast cancer. *Neoplasma* 2007; **54**: 304-310 [PMID: 17822320 DOI: 10.1186/1471-2407-13-307]
- 77 **Grudzien P**, Lo S, Albain KS, Robinson P, Rajan P, Strack PR, Golde TE, Miele L, Foreman KE. Inhibition of Notch signaling reduces the stem-like population of breast cancer cells and prevents mammosphere formation. *Anticancer Res* 2010; **30**: 3853-3867 [PMID: 21036696]
- 78 **Kondratyev M**, Kreso A, Hallett RM, Girgis-Gabardo A, Barcelon ME, Ilieva D, Ware C, Majumder PK, Hassell JA. Gamma-secretase inhibitors target tumor-initiating cells in a mouse model of ERBB2 breast cancer. *Oncogene* 2012; **31**: 93-103 [PMID: 21666715 DOI: 10.1038/onc.2011.212]
- 79 **Pandya K**, Meeke K, Clementz AG, Rogowski A, Roberts J, Miele L, Albain KS, Osipo C. Targeting both Notch and ErbB-2 signalling pathways is required for prevention of ErbB-2-positive breast tumour recurrence. *Br J Cancer* 2011; **105**: 796-806 [PMID: 21847123 DOI: 10.1038/bjc.2011.321]
- 80 **Ahmad A**, Wang Z, Kong D, Ali R, Ali S, Banerjee S, Sarkar FH. Platelet-derived growth factor-D contributes to aggressiveness of breast cancer cells by up-regulating Notch and NF- $\kappa$ B signaling pathways. *Breast Cancer Res Treat* 2011; **126**: 15-25 [PMID: 20379844 DOI: 10.1007/s10549-010-0883-2]
- 81 **Speiser J**, Foreman K, Drinka E, Godellas C, Perez C, Salhadar A, Erşahin Ç, Rajan P. Notch-1 and Notch-4 biomarker expression in triple-negative breast cancer. *Int J Surg Pathol* 2012; **20**: 139-145 [PMID: 22084425 DOI: 10.1177/1066896911427035]
- 82 **Clementz AG**, Rogowski A, Pandya K, Miele L, Osipo C. NOTCH-1 and NOTCH-4 are novel gene targets of PEA3 in breast cancer: novel therapeutic implications. *Breast Cancer Res* 2011; **13**: R63 [PMID: 21679465 DOI: 10.1186/bcr2900]
- 83 **Azzam DJ**, Zhao D, Sun J, Minn AJ, Ranganathan P, Drews-Elger K, Han X, Picon-Ruiz M, Gilbert CA, Wander SA, Capobianco AJ, El-Ashry D, Slingerland JM. Triple negative breast cancer initiating cell subsets differ in functional and molecular characteristics and in  $\gamma$ -secretase inhibitor drug responses. *EMBO Mol Med* 2013; **5**: 1502-1522 [PMID: 23982961 DOI: 10.1002/emmm.201302558]
- 84 **Leong KG**, Niessen K, Kulic I, Raouf A, Eaves C, Pollet I, Karsan A. Jagged1-mediated Notch activation induces epithelial-to-mesenchymal transition through Slug-induced repression of E-cadherin. *J Exp Med* 2007; **204**: 2935-2948 [PMID: 17984306]
- 85 **Muellner MK**, Uras IZ, Gapp BV, Kerzendorfer C, Smida M, Lechtermann H, Craig-Mueller N, Colinge J, Duernberger G, Nijman SM. A chemical-genetic screen reveals a mechanism of resistance to PI3K inhibitors in cancer. *Nat Chem Biol* 2011; **7**: 787-793 [PMID: 21946274 DOI: 10.1038/nchembio.695]
- 86 **Haughian JM**, Pinto MP, Harrell JC, Bliesner BS, Joensuu KM, Dye WW, Sartorius CA, Tan AC, Heikkilä P, Perou CM, Horwitz KB. Maintenance of hormone responsiveness in luminal breast cancers by suppression of Notch. *Proc Natl Acad Sci USA* 2012; **109**: 2742-2747 [PMID: 21969591 DOI: 10.1073/pnas.1106509108]
- 87 **Séveno C**, Loussouarn D, Bréchet S, Campone M, Juin P, Barillé-Nion S.  $\gamma$ -Secretase inhibition promotes cell death, Noxa upregulation, and sensitization to BH3 mimetic ABT-737 in human breast cancer cells. *Breast Cancer Res* 2012; **14**: R96 [PMID: 22703841]
- 88 **Han J**, Ma I, Hendzel MJ, Allalunis-Turner J. The cytotoxicity of gamma-secretase inhibitor I to breast cancer cells is mediated by proteasome inhibition, not by gamma-secretase inhibition. *Breast Cancer Res* 2009; **11**: R57 [PMID: 19660128 DOI: 10.1186/bcr2347]
- 89 **Rasul S**, Balasubramanian R, Filipović A, Slade MJ, Yagüe E, Coombes RC. Inhibition of gamma-secretase induces G2/M arrest and triggers apoptosis in breast cancer cells. *Br J Cancer* 2009; **100**: 1879-1888 [PMID: 19513078 DOI: 10.1038/sj.bjc.6605034]
- 90 **Luistro L**, He W, Smith M, Packman K, Vilenchik M, Carvajal D, Roberts J, Cai J, Berkofsky-Fessler W, Hilton H, Linn M, Flohr A, Jakob-Røtne R, Jacobsen H, Glenn K, Heimbrook D, Boylan JF. Preclinical profile of a potent gamma-secretase inhibitor targeting notch signaling with in vivo efficacy and pharmacodynamic properties. *Cancer Res* 2009; **69**: 7672-7680 [PMID: 19773430 DOI: 10.1158/0008-5472.CAN-09-1843]
- 91 **Debeb BG**, Cohen EN, Boley K, Freiter EM, Li L, Robertson FM, Reuben JM, Cristofanilli M, Buchholz TA, Woodward WA. Pre-clinical studies of Notch signaling inhibitor RO4929097 in inflammatory breast cancer cells. *Breast Cancer Res Treat* 2012; **134**: 495-510 [PMID: 22547109 DOI: 10.1007/s10549-012-2075-8]
- 92 **Diaz-Padilla I**, Hirte H, Oza AM, Clarke BA, Cohen B, Reedjik M, Zhang T, Kamel-Reid S, Ivy SP, Hotte SJ, Razak AA, Chen EX, Brana I, Wizemann M, Wang L, Siu LL, Bedard PL. A phase Ib combination study of RO4929097, a gamma-secretase inhibitor, and temsirolimus in patients with advanced solid tumors. *Invest New Drugs* 2013; **31**: 1182-1191 [PMID: 23860641 DOI: 10.1007/s10637-013-0001-5]
- 93 **Richter S**, Bedard PL, Chen EX, Clarke BA, Tran B, Hotte SJ, Stathis A, Hirte HW, Razak AR, Reedijk M, Chen Z, Cohen B, Zhang WJ, Wang L, Ivy SP, Moore MJ, Oza AM, Siu LL, McWhirter E. A phase I study of the oral gamma secretase inhibitor R04929097 in combination with gemcitabine in patients with advanced solid tumors (PHL-078/CTEP 8575). *Invest New Drugs* 2014; **32**: 243-249 [PMID: 23645447 DOI: 10.1007/s10637-013-9965-4]
- 94 **Han J**, Shen Q. Targeting  $\gamma$ -secretase in breast cancer. *Breast Cancer* (Dove Med Press) 2012; **4**: 83-90 [PMID: 24367196 DOI: 10.2147/BCTT.S26437]
- 95 **Yong T**, Sun A, Henry MD, Meyers S, Davis JN. Down regulation of CSL activity inhibits cell proliferation in prostate and breast cancer cells. *J Cell Biochem* 2011; **112**: 2340-2351 [PMID: 21520243 DOI: 10.1002/jcb.23157]
- 96 **Zhang CC**, Pavlicek A, Zhang Q, Lira ME, Painter CL, Yan Z, Zheng X, Lee NV, Ozeck M, Qiu M, Zong Q, Lappin PB, Wong A, Rejto PA, Smeal T, Christensen JG. Biomarker and pharmacologic evaluation of the  $\gamma$ -secretase inhibitor PF-03084014 in breast cancer models. *Clin Cancer Res* 2012; **18**: 5008-5019 [PMID: 22806875 DOI: 10.1158/1078-0432.CCR-12-1379]
- 97 **Wei P**, Walls M, Qiu M, Ding R, Denlinger RH, Wong A, Tsaparikos K, Jani JP, Hosea N, Sands M, Randolph S, Smeal T. Evaluation of selective gamma-secretase inhibitor PF-03084014 for its antitumor efficacy and gastrointestinal safety to guide optimal clinical trial design. *Mol Cancer Ther* 2010; **9**: 1618-1628 [PMID: 20530712 DOI: 10.1158/1535-7163.MCT-10-0034]
- 98 **Zhang CC**, Yan Z, Zong Q, Fang DD, Painter C, Zhang Q, Chen E, Lira ME, John-Baptiste A, Christensen JG. Syner-

- gistic effect of the  $\gamma$ -secretase inhibitor PF-03084014 and docetaxel in breast cancer models. *Stem Cells Transl Med* 2013; **2**: 233-242 [PMID: 23408105 DOI: 10.5966/sctm.2012-0096]
- 99 **Arcaroli JJ**, Quackenbush KS, Purkey A, Powell RW, Pitts TM, Bagby S, Tan AC, Cross B, McPhillips K, Song EK, Tai WM, Winn RA, Bikkavilli K, Vanscoyk M, Eckhardt SG, Messersmith WA. Tumours with elevated levels of the Notch and Wnt pathways exhibit efficacy to PF-03084014, a  $\gamma$ -secretase inhibitor, in a preclinical colorectal explant model. *Br J Cancer* 2013; **109**: 667-675 [PMID: 23868008 DOI: 10.1038/bjc.2013.361]
- 100 **Yabuuchi S**, Pai SG, Campbell NR, de Wilde RF, De Oliveira E, Korangath P, Streppel MM, Rasheed ZA, Hidalgo M, Maitra A, Rajeshkumar NV. Notch signaling pathway targeted therapy suppresses tumor progression and metastatic spread in pancreatic cancer. *Cancer Lett* 2013; **335**: 41-51 [PMID: 23402814 DOI: 10.1016/j.canlet.2013.01.054]
- 101 **Zhang CC**, Yan Z, Giddabasappa A, Lappin PB, Painter CL, Zhang Q, Li G, Goodman J, Simmons B, Pascual B, Lee J, Levkoff T, Nichols T, Xie Z. Comparison of dynamic contrast-enhanced MR, ultrasound and optical imaging modalities to evaluate the antiangiogenic effect of PF-03084014 and sunitinib. *Cancer Med* 2014; **3**: 462-471 [PMID: 24573979 DOI: 10.1002/cam4.215]
- 102 **López-Guerra M**, Xargay-Torrent S, Rosich L, Montraveta A, Roldán J, Matas-Céspedes A, Villamor N, Aymerich M, López-Otín C, Pérez-Galán P, Roué G, Campo E, Colomer D. The  $\gamma$ -secretase inhibitor PF-03084014 combined with fludarabine antagonizes migration, invasion and angiogenesis in NOTCH1-mutated CLL cells. *Leukemia* 2014 Apr 30; Epub ahead of print [PMID: 24781018 DOI: 10.1038/leu.2014.143]
- 103 **Carol H**, Maris JM, Kang MH, Reynolds CP, Kolb EA, Gorlick R, Keir ST, Wu J, Kurmasheva RT, Houghton PJ, Smith MA, Lock RB, Lyalin D. Initial testing (stage 1) of the notch inhibitor PF-03084014, by the pediatric preclinical testing program. *Pediatr Blood Cancer* 2014; **61**: 1493-1496 [PMID: 24664981 DOI: 10.1002/pbc.25026]
- 104 **Musgrove EA**, Lilischkis R, Cornish AL, Lee CS, Setlur V, Seshadri R, Sutherland RL. Expression of the cyclin-dependent kinase inhibitors p16INK4, p15INK4B and p21WAF1/CIP1 in human breast cancer. *Int J Cancer* 1995; **63**: 584-591 [PMID: 7591270]
- 105 **Zariwala M**, Liu E, Xiong Y. Mutational analysis of the p16 family cyclin-dependent kinase inhibitors p15INK4b and p18INK4c in tumor-derived cell lines and primary tumors. *Oncogene* 1996; **12**: 451-455 [PMID: 8570224]
- 106 **Nurse PM**. Nobel Lecture. Cyclin dependent kinases and cell cycle control. *Biosci Rep* 2002; **22**: 487-499 [PMID: 12635846]
- 107 **Malumbres M**. Cyclins and related kinases in cancer cells. *J BUON* 2007; **12** Suppl 1: S45-S52 [PMID: 17935277]
- 108 **Satyanarayana A**, Kaldis P. Mammalian cell-cycle regulation: several Cdk, numerous cyclins and diverse compensatory mechanisms. *Oncogene* 2009; **28**: 2925-2939 [PMID: 19561645 DOI: 10.1038/ncr.2009.170]
- 109 **Kuwajima M**, Kumano G, Nishida H. Regulation of the number of cell division rounds by tissue-specific transcription factors and Cdk inhibitor during ascidian embryogenesis. *PLoS One* 2014; **9**: e90188 [PMID: 24608898 DOI: 10.1371/journal.pone.0090188]
- 110 **Xu S**, Li X, Gong Z, Wang W, Li Y, Nair BC, Piao H, Yang K, Wu G, Chen J. Proteomic Analysis of the Human Cyclin-dependent Kinase Family Reveals a Novel CDK5 Complex Involved in Cell Growth and Migration. *Mol Cell Proteomics* 2014; **13**: 2986-3000 [PMID: 25096995 DOI: 10.1074/mcp.M113.036699]
- 111 **Torikoshi Y**, Gohda K, Davis ML, Symmans WF, Pusztai L, Kazansky A, Nakayama S, Yoshida T, Matsushima T, Hortobagyi GN, Ishihara H, Kim SJ, Noguchi S, Ueno NT. Novel functional assay for spindle-assembly checkpoint by cyclin-dependent kinase activity to predict taxane chemosensitivity in breast tumor patient. *J Cancer* 2013; **4**: 697-702 [PMID: 24312139]
- 112 **Casimiro MC**, Velasco-Velázquez M, Aguirre-Alvarado C, Pestell RG. Overview of cyclins D1 function in cancer and the CDK inhibitor landscape: past and present. *Expert Opin Investig Drugs* 2014; **23**: 295-304 [PMID: 24387133 DOI: 10.1517/13543784.2014.867017]
- 113 **Jinno H**, Matsuda S, Hayashida T, Takahashi M, Hirose S, Ikeda T, Kitagawa Y. Differential pathological response to preoperative chemotherapy across breast cancer intrinsic subtypes. *Chemotherapy* 2012; **58**: 364-370 [PMID: 23207824 DOI: 10.1159/000343663]
- 114 **Yamaguchi T**, Mukai H. Ki-67 index guided selection of pre-operative chemotherapy for HER2-positive breast cancer: a randomized phase II trial. *Jpn J Clin Oncol* 2012; **42**: 1211-1214 [PMID: 23129778 DOI: 10.1093/jjco/hys161]
- 115 **Toyoshima M**, Howie HL, Imakura M, Walsh RM, Annis JE, Chang AN, Frazier J, Chau BN, Loboda A, Linsley PS, Cleary MA, Park JR, Grandori C. Functional genomics identifies therapeutic targets for MYC-driven cancer. *Proc Natl Acad Sci USA* 2012; **109**: 9545-9550 [PMID: 22623531 DOI: 10.1073/pnas.112119109]
- 116 **Kessler JD**, Kahle KT, Sun T, Meerbrey KL, Schlabach MR, Schmitt EM, Skinner SO, Xu Q, Li MZ, Hartman ZC, Rao M, Yu P, Dominguez-Vidana R, Liang AC, Solimini NL, Bernardi RJ, Yu B, Hsu T, Golding I, Luo J, Osborne CK, Creighton CJ, Hilsenbeck SG, Schiff R, Shaw CA, Elledge SJ, Westbrook TF. A SUMOylation-dependent transcriptional subprogram is required for Myc-driven tumorigenesis. *Science* 2012; **335**: 348-353 [PMID: 22157079 DOI: 10.1126/science.1212728]
- 117 **Kang J**, Sergio CM, Sutherland RL, Musgrove EA. Targeting cyclin-dependent kinase 1 (CDK1) but not CDK4/6 or CDK2 is selectively lethal to MYC-dependent human breast cancer cells. *BMC Cancer* 2014; **14**: 32 [PMID: 24444383 DOI: 10.1186/1471-2407-14-32]
- 118 **Cunningham JT**, Pourdehnad M, Stumpf CR, Ruggero D. Investigating Myc-dependent translational regulation in normal and cancer cells. *Methods Mol Biol* 2013; **1012**: 201-212 [PMID: 24006066 DOI: 10.1007/978-1-62703-429-6\_13]
- 119 **Said TK**, Medina D. Cell cyclins and cyclin-dependent kinase activities in mouse mammary tumor development. *Carcinogenesis* 1995; **16**: 823-830 [PMID: 7728962 DOI: 10.1093/carcin/16.4.823]
- 120 **Duong MT**, Akli S, Macalou S, Biernacka A, Debeb BG, Yi M, Hunt KK, Keyomarsi K. Hbo1 is a cyclin E/CDK2 substrate that enriches breast cancer stem-like cells. *Cancer Res* 2013; **73**: 5556-5568 [PMID: 23955388 DOI: 10.1158/0008-5472.CAN-13-0013]
- 121 **Rath SL**, Senapati S. Why are the truncated cyclin Es more effective CDK2 activators than the full-length isoforms? *Biochemistry* 2014; **53**: 4612-4624 [PMID: 24947816 DOI: 10.1021/bi5004052]
- 122 **Li XY**, Luo QF, Wei CK, Li DF, Fang L. siRNA-mediated silencing of CDK8 inhibits proliferation and growth in breast cancer cells. *Int J Clin Exp Pathol* 2014; **7**: 92-100 [PMID: 24427329]
- 123 **Pisanò M**, Mezzolla V, Galante MM, Alemanno G, Manca C, Lorusso V, Malvasi A, Tinelli A. A new mutation of BRCA2 gene in an Italian healthy woman with familial breast cancer history. *Fam Cancer* 2011; **10**: 65-71 [PMID: 20878484 DOI: 10.1007/s10689-010-9389-7]
- 124 **Pruss D**, Morris B, Hughes E, Eggington JM, Esterling L, Robinson BS, van Kan A, Fernandes PH, Roa BB, Gutin A, Wenstrup RJ, Bowles KR. Development and validation of a new algorithm for the reclassification of genetic variants identified in the BRCA1 and BRCA2 genes. *Breast Cancer Res Treat* 2014; **147**: 119-132 [PMID: 25085752 DOI: 10.1007/s10549-014-3065-9]
- 125 **Yata K**, Bleuyard JY, Nakato R, Ralf C, Katou Y, Schwab RA, Niedzwiedz W, Shirahige K, Esashi F. BRCA2 coordi-



- nates the activities of cell-cycle kinases to promote genome stability. *Cell Rep* 2014; **7**: 1547-1559 [PMID: 24835992 DOI: 10.1016/j.celrep.2014.04.023]
- 126 **Jia Y**, Domenico J, Swasey C, Wang M, Gelfand EW, Lucas JJ. Modulated expression of genes encoding estrogen metabolizing enzymes by G1-phase cyclin-dependent kinases 6 and 4 in human breast cancer cells. *PLoS One* 2014; **9**: e97448 [PMID: 24848372 DOI: 10.1371/journal.pone.0097448]
  - 127 **Fu J**, Tian C, Xing M, Wang X, Guo H, Sun L, Sun L, Jiang Z, Zhang L. KU004 induces G1 cell cycle arrest in human breast cancer SKBR-3 cells by modulating PI3K/Akt pathway. *Biomed Pharmacother* 2014; **68**: 625-630 [PMID: 24996960 DOI: 10.1016/j.biopha.2014.05.006]
  - 128 **Vora SR**, Juric D, Kim N, Mino-Kenudson M, Huynh T, Costa C, Lockerman EL, Pollack SF, Liu M, Li X, Lehar J, Wiesmann M, Wartmann M, Chen Y, Cao ZA, Pinzon-Ortiz M, Kim S, Schlegel R, Huang A, Engelman JA. CDK 4/6 inhibitors sensitize PIK3CA mutant breast cancer to PI3K inhibitors. *Cancer Cell* 2014; **26**: 136-149 [PMID: 25002028 DOI: 10.1016/j.ccr.2014.05.02]
  - 129 **Roberts PJ**, Bisi JE, Strum JC, Combest AJ, Darr DB, Usary JE, Zamboni WC, Wong KK, Perou CM, Sharpless NE. Multiple roles of cyclin-dependent kinase 4/6 inhibitors in cancer therapy. *J Natl Cancer Inst* 2012; **104**: 476-487 [PMID: 22302033 DOI: 10.1093/jnci/djs002]
  - 130 **Akin S**, Babacan T, Sarici F, Altundag K. A novel targeted therapy in breast cancer: cyclin dependent kinase inhibitors. *J BUON* 2014; **19**: 42-46 [PMID: 24659641]
  - 131 **Zhang C**, Yan Z, Arango ME, Painter CL, Anderes K. Advancing bioluminescence imaging technology for the evaluation of anticancer agents in the MDA-MB-435-HAL-Luc mammary fat pad and subrenal capsule tumor models. *Clin Cancer Res* 2009; **15**: 238-246 [PMID: 19118051]
  - 132 **Finn RS**, Dering J, Conklin D, Kalous O, Cohen DJ, Desai AJ, Ginther C, Atefi M, Chen I, Fowst C, Los G, Slamon DJ. PD 0332991, a selective cyclin D kinase 4/6 inhibitor, preferentially inhibits proliferation of luminal estrogen receptor-positive human breast cancer cell lines in vitro. *Breast Cancer Res* 2009; **11**: R77 [PMID: 19874578 DOI: 10.1158/1078-0432.CCR-08-0897]
  - 133 **Dean JL**, McClendon AK, Hickey TE, Butler LM, Tilley WD, Witkiewicz AK, Knudsen ES. Therapeutic response to CDK4/6 inhibition in breast cancer defined by ex vivo analyses of human tumors. *Cell Cycle* 2012; **11**: 2756-2761 [PMID: 22767154 DOI: 10.4161/cc.21195]
  - 134 **Lange CA**, Yee D. Killing the second messenger: targeting loss of cell cycle control in endocrine-resistant breast cancer. *Endocr Relat Cancer* 2011; **18**: C19-C24 [PMID: 21613412 DOI: 10.1530/ERC-11-0112]
  - 135 **Rocca A**, Farolfi A, Bravaccini S, Schirone A, Amadori D. Palbociclib (PD 0332991) : targeting the cell cycle machinery in breast cancer. *Expert Opin Pharmacother* 2014; **15**: 407-420 [PMID: 24369047 DOI: 10.1517/14656566.2014.870555]
  - 136 **Robinson TJ**, Liu JC, Vizeacoumar F, Sun T, Maclean N, Egan SE, Schimmer AD, Datti A, Zacksenhaus E. RB1 status in triple negative breast cancer cells dictates response to radiation treatment and selective therapeutic drugs. *PLoS One* 2013; **8**: e78641 [PMID: 24265703 DOI: 10.1371/journal.pone.0078641]
  - 137 **McClendon AK**, Dean JL, Rivadeneira DB, Yu JE, Reed CA, Gao E, Farber JL, Force T, Koch WJ, Knudsen ES. CDK4/6 inhibition antagonizes the cytotoxic response to anthracycline therapy. *Cell Cycle* 2012; **11**: 2747-2755 [PMID: 22751436 DOI: 10.4161/cc.21127]
  - 138 **DiRocco DP**, Bisi J, Roberts P, Strum J, Wong KK, Sharpless N, Humphreys BD. CDK4/6 inhibition induces epithelial cell cycle arrest and ameliorates acute kidney injury. *Am J Physiol Renal Physiol* 2014; **306**: F379-F388 [PMID: 24338822 DOI: 10.1152/ajprenal.00475.2013]
  - 139 **Martin MP**, Olesen SH, Georg GI, Schönbrunn E. Cyclin-dependent kinase inhibitor dinaciclib interacts with the acetyl-lysine recognition site of bromodomains. *ACS Chem Biol* 2013; **8**: 2360-2365 [PMID: 24007471 DOI: 10.1021/cb4003283]
  - 140 **Nguyen TK**, Grant S. Dinaciclib (SCH727965) inhibits the unfolded protein response through a CDK1- and 5-dependent mechanism. *Mol Cancer Ther* 2014; **13**: 662-674 [PMID: 24362465 DOI: 10.1158/1535-7163.MCT-13-0714]
  - 141 **Paruch K**, Dwyer MP, Alvarez C, Brown C, Chan TY, Doll RJ, Keertikar K, Knutson C, McKittrick B, Rivera J, Rossman R, Tucker G, Fischmann T, Hruza A, Madison V, Nomeir AA, Wang Y, Kirschmeier P, Lees E, Parry D, Sgambellone N, Seghezzi W, Schultz L, Shanahan F, Wiswell D, Xu X, Zhou Q, James RA, Paradkar VM, Park H, Rokosz LR, Stauffer TM, Guzi TJ. Discovery of Dinaciclib (SCH 727965): A Potent and Selective Inhibitor of Cyclin-Dependent Kinases. *ACS Med Chem Lett* 2010; **1**: 204-208 [PMID: 24900195 DOI: 10.1021/ml100051d]
  - 142 **Parry D**, Guzi T, Shanahan F, Davis N, Prabhavalkar D, Wiswell D, Seghezzi W, Paruch K, Dwyer MP, Doll R, Nomeir A, Windsor W, Fischmann T, Wang Y, Oft M, Chen T, Kirschmeier P, Lees EM. Dinaciclib (SCH 727965), a novel and potent cyclin-dependent kinase inhibitor. *Mol Cancer Ther* 2010; **9**: 2344-2353 [PMID: 20663931 DOI: 10.1158/1535-7163.MCT-10-0324]
  - 143 **Mita MM**, Joy AA, Mita A, Sankhala K, Jou YM, Zhang D, Statkevich P, Zhu Y, Yao SL, Small K, Bannerji R, Shapiro CL. Randomized phase II trial of the cyclin-dependent kinase inhibitor dinaciclib (MK-7965) versus capecitabine in patients with advanced breast cancer. *Clin Breast Cancer* 2014; **14**: 169-176 [PMID: 24393852 DOI: 10.1016/j.clbc.2013.10.016]
  - 144 **Stephenson JJ**, Nemunaitis J, Joy AA, Martin JC, Jou YM, Zhang D, Statkevich P, Yao SL, Zhu Y, Zhou H, Small K, Bannerji R, Edelman MJ. Randomized phase 2 study of the cyclin-dependent kinase inhibitor dinaciclib (MK-7965) versus erlotinib in patients with non-small cell lung cancer. *Lung Cancer* 2014; **83**: 219-223 [PMID: 24388167 DOI: 10.1016/j.lungcan.2013.11.020]
  - 145 **Logan CY**, Nusse R. The Wnt signaling pathway in development and disease. *Annu Rev Cell Dev Biol* 2004; **20**: 781-810 [PMID: 15473860]
  - 146 **Asai N**, Ohkawara B, Ito M, Masuda A, Ishiguro N, Ohno K. LRP4 induces extracellular matrix productions and facilitates chondrocyte differentiation. *Biochem Biophys Res Commun* 2014; **451**: 302-307 [PMID: 25091481 DOI: 10.1016/j.bbrc.2014.07.125]
  - 147 **Liu J**, Pan S, Hsieh MH, Ng N, Sun F, Wang T, Kasibhatla S, Schuller AG, Li AG, Cheng D, Li J, Tompkins C, Pferdekamper A, Steffy A, Cheng J, Kowal C, Phung V, Guo G, Wang Y, Graham MP, Flynn S, Brenner JC, Li C, Villarroel MC, Schultz PG, Wu X, McNamara P, Sellers WR, Petruzzelli L, Boral AL, Seidel HM, McLaughlin ME, Che J, Carey TE, Vanasse G, Harris JL. Targeting Wnt-driven cancer through the inhibition of Porcupine by LGK974. *Proc Natl Acad Sci USA* 2013; **110**: 20224-20229 [PMID: 24277854 DOI: 10.1073/pnas.1314239110]
  - 148 **Lento W**, Congdon K, Voermans C, Kritzik M, Reya T. Wnt signaling in normal and malignant hematopoiesis. *Cold Spring Harb Perspect Biol* 2013; **5**: pii: a008011 [PMID: 23378582 DOI: 10.1101/cshperspect.a008011]
  - 149 **Seke Etet PE**, Vecchio L, Bogne Kamga P, Nchiwan Nukemine E, Krampera M, Nwabo Kamdje AH. Normal hematopoiesis and hematologic malignancies: role of canonical Wnt signaling pathway and stromal microenvironment. *Biochim Biophys Acta* 2013; **1835**: 1-10 [PMID: 22982245 DOI: 10.1016/j.bbcan.2012.08.002]
  - 150 **Park JH**, Kwon HY, Sohn EJ, Kim KA, Kim B, Jeong SJ, Song JH, Joo JS, Kim SH. Inhibition of Wnt/ $\beta$ -catenin signaling mediates ursolic acid-induced apoptosis in PC-3 prostate cancer cells. *Pharmacol Rep* 2013; **65**: 1366-1374 [PMID: 24399733]



- 151 **Menck K**, Klemm F, Gross JC, Pukrop T, Wenzel D, Binder C. Induction and transport of Wnt 5a during macrophage-induced malignant invasion is mediated by two types of extracellular vesicles. *Oncotarget* 2013; **4**: 2057-2066 [PMID: 24185202]
- 152 **Tumova L**, Pombinho AR, Vojtechova M, Stancikova J, Gradl D, Krausova M, Sloncova E, Horazna M, Kriz V, Machonova O, Jindrich J, Zdrahal Z, Bartunek P, Korinek V. Monensin inhibits canonical Wnt signaling in human colorectal cancer cells and suppresses tumor growth in multiple intestinal neoplasia mice. *Mol Cancer Ther* 2014; **13**: 812-822 [PMID: 24552772 DOI: 10.1158/1535-7163.MCT-13-0625]
- 153 **Kim JT**, Liu C, Zaytseva YY, Weiss HL, Townsend CM Jr, Evers BM. Neurotensin, a novel target of Wnt/ $\beta$ -catenin pathway, promotes growth of neuroendocrine tumor cells. *Int J Cancer* 2014 Aug 5; Epub ahead of print [PMID: 25098665 DOI: 10.1002/ijc.29123]
- 154 **Yu DH**, Zhang X, Wang H, Zhang L, Chen H, Hu M, Dong Z, Zhu G, Qian Z, Fan J, Su X, Xu Y, Zheng L, Dong H, Yin X, Ji Q, Ji J. The essential role of TNK gene amplification in gastric cancer growth. *Oncogenesis* 2014; **2**: e89 [PMID: 24566388 DOI: 10.1038/oncsis.2014.2]
- 155 **Many AM**, Brown AM. Both canonical and non-canonical Wnt signaling independently promote stem cell growth in mammospheres. *PLoS One* 2014; **9**: e101800 [PMID: 25019931 DOI: 10.1371/journal.pone.0101800]
- 156 **Klinke DJ**. Induction of Wnt-inducible signaling protein-1 correlates with invasive breast cancer oncogenesis and reduced type 1 cell-mediated cytotoxic immunity: a retrospective study. *PLoS Comput Biol* 2014; **10**: e1003409 [PMID: 24426833 DOI: 10.1371/journal.pcbi.1003409]
- 157 **Lu W**, Li Y. Salinomycin suppresses LRP6 expression and inhibits both Wnt/ $\beta$ -catenin and mTORC1 signaling in breast and prostate cancer cells. *J Cell Biochem* 2014; **115**: 1799-1807 [PMID: 24905570 DOI: 10.1002/jcb.24850]
- 158 **Lu W**, Lin C, Li Y. Rottlerin induces Wnt co-receptor LRP6 degradation and suppresses both Wnt/ $\beta$ -catenin and mTORC1 signaling in prostate and breast cancer cells. *Cell Signal* 2014; **26**: 1303-1309 [PMID: 24607787 DOI: 10.1016/j.cellsig.2014.02.018]
- 159 **Proffitt KD**, Madan B, Ke Z, Pendharkar V, Ding L, Lee MA, Hannoush RN, Virshup DM. Pharmacological inhibition of the Wnt acyltransferase PORCN prevents growth of WNT-driven mammary cancer. *Cancer Res* 2013; **73**: 502-507 [PMID: 23188502 DOI: 10.1158/0008-5472.CAN-12-2258]
- 160 **Jiang X**, Hao HX, Gowney JD, Woolfenden S, Bottiglio C, Ng N, Lu B, Hsieh MH, Bagdasarjan L, Meyer R, Smith TR, Avello M, Charlat O, Xie Y, Porter JA, Pan S, Liu J, McLaughlin ME, Cong F. Inactivating mutations of RNF43 confer Wnt dependency in pancreatic ductal adenocarcinoma. *Proc Natl Acad Sci USA* 2013; **110**: 12649-12654 [PMID: 23847203 DOI: 10.1073/pnas.1307218110]
- 161 **Lamb R**, Ablett MP, Spence K, Landberg G, Sims AH, Clarke RB. Wnt pathway activity in breast cancer sub-types and stem-like cells. *PLoS One* 2013; **8**: e67811 [PMID: 23861811 DOI: 10.1371/journal.pone.0067811]
- 162 **Loh YN**, Heddditch EL, Baker LA, Jary E, Ward RL, Ford CE. The Wnt signalling pathway is upregulated in an in vitro model of acquired tamoxifen resistant breast cancer. *BMC Cancer* 2013; **13**: 174 [PMID: 23547709 DOI: 10.1186/1471-2407-13-174]
- 163 **Yin S**, Xu L, Bonfil RD, Banerjee S, Sarkar FH, Sethi S, Reddy KB. Tumor-initiating cells and FZD8 play a major role in drug resistance in triple-negative breast cancer. *Mol Cancer Ther* 2013; **12**: 491-498 [PMID: 23445611 DOI: 10.1158/1535-7163.MCT-12-1090]
- 164 **Cui W**, Wang LH, Wen YY, Song M, Li BL, Chen XL, Xu M, An SX, Zhao J, Lu YY, Mi XY, Wang EH. Expression and regulation mechanisms of Sonic Hedgehog in breast cancer. *Cancer Sci* 2010; **101**: 927-933 [PMID: 20180807 DOI: 10.1111/j.1349-7006.2010.01495.x]
- 165 **Kasperczyk H**, Baumann B, Debatin KM, Fulda S. Characterization of sonic hedgehog as a novel NF-kappaB target gene that promotes NF-kappaB-mediated apoptosis resistance and tumor growth in vivo. *FASEB J* 2009; **23**: 21-33 [PMID: 18772349 DOI: 10.1096/fj.08-111096]
- 166 **Wang TP**, Hsu SH, Feng HC, Huang RF. Folate deprivation enhances invasiveness of human colon cancer cells mediated by activation of sonic hedgehog signaling through promoter hypomethylation and cross action with transcription nuclear factor-kappa B pathway. *Carcinogenesis* 2012; **33**: 1158-1168 [PMID: 22461522 DOI: 10.1093/carcin/bgs138]
- 167 **Singh AP**, Arora S, Bhardwaj A, Srivastava SK, Kadakia MP, Wang B, Grizzle WE, Owen LB, Singh S. CXCL12/CXCR4 protein signaling axis induces sonic hedgehog expression in pancreatic cancer cells via extracellular regulated kinase- and Akt kinase-mediated activation of nuclear factor  $\kappa$ B: implications for bidirectional tumor-stromal interactions. *J Biol Chem* 2012; **287**: 39115-39124 [PMID: 22995914 DOI: 10.1074/jbc.M112.409581]
- 168 **Mukherjee S**, Frolova N, Sadlonova A, Novak Z, Steg A, Page GP, Welch DR, Lobo-Ruppert SM, Ruppert JM, Johnson MR, Frost AR. Hedgehog signaling and response to cyclopamine differ in epithelial and stromal cells in benign breast and breast cancer. *Cancer Biol Ther* 2006; **5**: 674-683 [PMID: 16855373]
- 169 **Thomas ZI**, Gibson W, Sexton JZ, Aird KM, Ingram SM, Aldrich A, Lysterly HK, Devi GR, Williams KP. Targeting GLI1 expression in human inflammatory breast cancer cells enhances apoptosis and attenuates migration. *Br J Cancer* 2011; **104**: 1575-1586 [PMID: 21505458 DOI: 10.1038/bjc.2011.133]
- 170 **Das S**, Samant RS, Shevde LA. Nonclassical activation of Hedgehog signaling enhances multidrug resistance and makes cancer cells refractory to Smoothened-targeting Hedgehog inhibition. *J Biol Chem* 2013; **288**: 11824-11833 [PMID: 23508962 DOI: 10.1074/jbc.M112.432302]
- 171 **Bai R**, Zhao H, Zhang X, DU S. Characterization of sonic hedgehog inhibition in gastric carcinoma cells. *Oncol Lett* 2014; **7**: 1381-1384 [PMID: 24765141]
- 172 **Heiden KB**, Williamson AJ, Doscas ME, Ye J, Wang Y, Liu D, Xing M, Prinz RA, Xu X. The sonic hedgehog signaling pathway maintains the cancer stem cell self-renewal of anaplastic thyroid cancer by inducing snail expression. *J Clin Endocrinol Metab* 2014; **99**: E2178-E2187 [PMID: 25078145]
- 173 **Balbous A**, Renoux B, Cortes U, Milin S, Guilloteau K, Legigan T, Rivet P, Boissonnade O, Martin S, Tripianna C, Wager M, Bensadoun RJ, Papot S, Karayan-Tapon L. Selective release of a cyclopamine glucuronide prodrug toward stem-like cancer cell inhibition in glioblastoma. *Mol Cancer Ther* 2014; **13**: 2159-2169 [PMID: 25053823]
- 174 **Chai F**, Zhou J, Chen C, Xie S, Chen X, Su P, Shi J. The Hedgehog inhibitor cyclopamine antagonizes chemoresistance of breast cancer cells. *Onco Targets Ther* 2013; **6**: 1643-1647 [PMID: 24250231 DOI: 10.2147/OTT.S51914]
- 175 **Steg AD**, Katre AA, Bevis KS, Ziebarth A, Dobbin ZC, Shah MM, Alvarez RD, Landen CN. Smoothened antagonists reverse taxane resistance in ovarian cancer. *Mol Cancer Ther* 2012; **11**: 1587-1597 [PMID: 22553355 DOI: 10.1158/1535-7163.MCT-11-105]
- 176 **Ramaswamy B**, Lu Y, Teng KY, Nuovo G, Li X, Shapiro CL, Majumder S. Hedgehog signaling is a novel therapeutic target in tamoxifen-resistant breast cancer aberrantly activated by PI3K/AKT pathway. *Cancer Res* 2012; **72**: 5048-5059 [PMID: 22875023 DOI: 10.1158/0008-5472.CAN-12-1248]
- 177 **Moraes RC**, Zhang X, Harrington N, Fung JY, Wu MF, Hilsenbeck SG, Allred DC, Lewis MT. Constitutive activation of smoothened (SMO) in mammary glands of transgenic mice leads to increased proliferation, altered differentiation and ductal dysplasia. *Development* 2007; **134**: 1231-1242 [PMID: 17287253 DOI: 10.1242/dev.02797]

- 178 **Okolowsky N**, Furth PA, Hamel PA. Oestrogen receptor- $\alpha$  regulates non-canonical Hedgehog-signalling in the mammary gland. *Dev Biol* 2014; **391**: 219-229 [PMID: 24769368 DOI: 10.1016/j.ydbio.2014.04.007]
- 179 **Kwon YJ**, Hurst DR, Steg AD, Yuan K, Vaidya KS, Welch DR, Frost AR. Gli1 enhances migration and invasion via up-regulation of MMP-11 and promotes metastasis in ER $\alpha$  negative breast cancer cell lines. *Clin Exp Metastasis* 2011; **28**: 437-449 [PMID: 21442356 DOI: 10.1007/s10585-011-9382-z]
- 180 **Djiogue S**, Nwabo Kamdje AH, Vecchio L, Kipanyula MJ, Farahna M, Aldebasi Y, Seke Etet PF. Insulin resistance and cancer: the role of insulin and IGFs. *Endocr Relat Cancer* 2013; **20**: R1-R17 [PMID: 23207292 DOI: 10.1530/ERC-12-0324]
- 181 **Zhou L**, Guo X, Jing BA, Zhao L. CD44 is involved in CXCL-12 induced acute myeloid leukemia HL-60 cell polarity. *Biocell* 2010; **34**: 91-94 [PMID: 20925198]
- 182 **Razis E**, Kalogeras KT, Kotoula V, Eleftheraki AG, Nikitas N, Kronenwett R, Timotheadou E, Christodoulou C, Pectasides D, Gogas H, Wirtz RM, Makatsoris T, Bafaloukos D, Aravantinos G, Televantou D, Pavlidis N, Fountzilas G. Improved outcome of high-risk early HER2 positive breast cancer with high CXCL13-CXCR5 messenger RNA expression. *Clin Breast Cancer* 2012; **12**: 183-193 [PMID: 22607768 DOI: 10.1016/j.clbc.2012.03.006]
- 183 **Jaeger S**, Min J, Nigsch F, Camargo M, Hutz J, Cornett A, Cleaver S, Buckler A, Jenkins JL. Causal Network Models for Predicting Compound Targets and Driving Pathways in Cancer. *J Biomol Screen* 2014; **19**: 791-802 [PMID: 24518063 DOI: 10.1177/1087057114522690]
- 184 **Konkel MK**, Batzer MA. A mobile threat to genome stability: The impact of non-LTR retrotransposons upon the human genome. *Semin Cancer Biol* 2010; **20**: 211-221 [PMID: 20307669 DOI: 10.1016/j.semcancer.2010.03.001]
- 185 **Kipanyula MJ**, Seke Etet PF, Vecchio L, Farahna M, Nuke-nine EN, Nwabo Kamdje AH. Signaling pathways bridging microbial-triggered inflammation and cancer. *Cell Signal* 2013; **25**: 403-416 [PMID: 23123499 DOI: 10.1016/j.cellsig.2012.10.014]
- 186 **Vecchio L**, Seke Etet PF, Kipanyula MJ, Krampera M, Nwabo Kamdje AH. Importance of epigenetic changes in cancer etiology, pathogenesis, clinical profiling, and treatment: what can be learned from hematologic malignancies? *Biochim Biophys Acta* 2013; **1836**: 90-104 [PMID: 23603458 DOI: 10.1016/j.bbcan.2013.04.001]
- 187 **Flanagan JM**, Wilhelm-Benartzi CS, Metcalf M, Kaye SB, Brown R. Association of somatic DNA methylation variability with progression-free survival and toxicity in ovarian cancer patients. *Ann Oncol* 2013; **24**: 2813-2818 [PMID: 24114859 DOI: 10.1093/annonc/mdt370]
- 188 **Muntané J**, De la Rosa AJ, Docoabo F, García-Carbonero R, Padillo FJ. Targeting tyrosine kinase receptors in hepatocellular carcinoma. *Curr Cancer Drug Targets* 2013; **13**: 300-312 [PMID: 23016985 DOI: 10.2174/15680096113139990075]
- 189 **Huang SS**, Clarke DC, Gosline SJ, Labadorf A, Chouinard CR, Gordon W, Lauffenburger DA, Fraenkel E. Linking proteomic and transcriptional data through the interactome and epigenome reveals a map of oncogene-induced signaling. *PLoS Comput Biol* 2013; **9**: e1002887 [PMID: 23408876 DOI: 10.1371/journal.pcbi.1002887]
- 190 **Zazzu V**, Regierer B, Kühn A, Sudbrak R, Lehrach H. IT Future of Medicine: from molecular analysis to clinical diagnosis and improved treatment. *N Biotechnol* 2013; **30**: 362-365 [PMID: 23165094 DOI: 10.1016/j.nbt.2012.11.002]
- 191 **Daniels M**, Goh F, Wright CM, Sriram KB, Relan V, Clarke BE, Duhig EE, Bowman RV, Yang IA, Fong KM. Whole genome sequencing for lung cancer. *J Thorac Dis* 2012; **4**: 155-163 [PMID: 22833821 DOI: 10.3978/j.issn.2072-1439.2012.02.01]
- 192 **Giesrigl B**, Schmidt WM, Kalipciyan M, Jeitler M, Bilban M, Gollinger M, Krieger S, Jäger W, Mader RM, Krupitza G. Fulvestrant induces resistance by modulating GPER and CDK6 expression: implication of methyltransferases, deacetylases and the hSWI/SNF chromatin remodelling complex. *Br J Cancer* 2013; **109**: 2751-2762 [PMID: 24169358 DOI: 10.1038/bjc.2013.583]
- 193 **Hohmann AF**, Vakoc CR. A rationale to target the SWI/SNF complex for cancer therapy. *Trends Genet* 2014; **30**: 356-363 [PMID: 24932742 DOI: 10.1016/j.tig.2014.05.001]
- 194 **Kimura A**, Arakawa N, Hirano H. Mass Spectrometric Analysis of the Phosphorylation Levels of the SWI/SNF Chromatin Remodeling/Tumor Suppressor Proteins ARID1A and Brg1 in Ovarian Clear Cell Adenocarcinoma Cell Lines. *J Proteome Res* 2014; **13**: 4959-4969 [PMID: 25083560 DOI: 10.1021/pr500470h]
- 195 **Brglez V**, Pucer A, Pungerčar J, Lambeau G, Petan T. Secreted phospholipases A<sub>2</sub> are differentially expressed and epigenetically silenced in human breast cancer cells. *Biochem Biophys Res Commun* 2014; **445**: 230-235 [PMID: 24508801 DOI: 10.1016/j.bbrc.2014.01.182]
- 196 **Al-Rayyan N**, Litchfield LM, Ivanova MM, Radde BN, Cheng A, Elbedewy A, Klinge CM. 5-Aza-2-deoxycytidine and trichostatin A increase COUP-TFII expression in antiestrogen-resistant breast cancer cell lines. *Cancer Lett* 2014; **347**: 139-150 [PMID: 24513177 DOI: 10.1016/j.canlet.2014.02.001]
- 197 **Wilson-Edell KA**, Yevtushenko MA, Rothschild DE, Rogers AN, Benz CC. mTORC1/C2 and pan-HDAC inhibitors synergistically impair breast cancer growth by convergent AKT and polysome inhibiting mechanisms. *Breast Cancer Res Treat* 2014; **144**: 287-298 [PMID: 24562770 DOI: 10.1007/s10549-014-2877-y]
- 198 **Nickel A**, Stadler SC. Role of epigenetic mechanisms in epithelial-to-mesenchymal transition of breast cancer cells. *Transl Res* 2014 Apr 12; Epub ahead of print [PMID: 24768944 DOI: 10.1016/j.trsl.2014.04.001]
- 199 **Al-Nakhle H**, Smith L, Bell SM, Burns PA, Cummings M, Hanby AM, Lane S, Parker MD, Hughes TA, Speirs V. Regulation of estrogen receptor  $\beta$ 1 expression in breast cancer by epigenetic modification of the 5' regulatory region. *Int J Oncol* 2013; **43**: 2039-2045 [PMID: 24068253 DOI: 10.3892/ijo.2013.2112]
- 200 **Mohapatra DK**, Reddy DS, Ramaiah MJ, Ghosh S, Pothula V, Lunavath S, Thomas S, Valli SN, Bhadra MP, Yadav JS. Rugulactone derivatives act as inhibitors of NF- $\kappa$ B activation and modulates the transcription of NF- $\kappa$ B dependent genes in MDA-MB-231 cells. *Bioorg Med Chem Lett* 2014; **24**: 1389-1396 [PMID: 24508135 DOI: 10.1016/j.bmcl.2014.01.030]
- 201 **Liao XH**, Li YQ, Wang N, Zheng L, Xing WJ, Zhao DW, Yan TB, Wang Y, Liu LY, Sun XG, Hu P, Zhou H, Zhang TC. Re-expression and epigenetic modification of maspin induced apoptosis in MCF-7 cells mediated by myocardin. *Cell Signal* 2014; **26**: 1335-1346 [PMID: 24607789 DOI: 10.1016/j.cellsig.2014.03.001]
- 202 **Sun S**, Han Y, Liu J, Fang Y, Tian Y, Zhou J, Ma D, Wu P. Trichostatin A targets the mitochondrial respiratory chain, increasing mitochondrial reactive oxygen species production to trigger apoptosis in human breast cancer cells. *PLoS One* 2014; **9**: e91610 [PMID: 24626188 DOI: 10.1371/journal.pone.0091610]
- 203 **Cody JJ**, Markert JM, Hurst DR. Histone deacetylase inhibitors improve the replication of oncolytic herpes simplex virus in breast cancer cells. *PLoS One* 2014; **9**: e92919 [PMID: 24651853 DOI: 10.1371/journal.pone.0092919]
- 204 **Pellon-Maison M**, Montanaro MA, Lacunza E, Garcia-Fabiani MB, Soler-Gerino MC, Cattaneo ER, Quiroga IY, Abba MC, Coleman RA, Gonzalez-Baro MR. Glycerol-3-phosphate acyltransferase-2 behaves as a cancer testis gene and promotes growth and tumorigenicity of the breast cancer MDA-MB-231 cell line. *PLoS One* 2014; **9**: e100896 [PMID: 24967918 DOI: 10.1371/journal.pone.0100896]
- 205 **Katz TA**, Vasilatos SN, Harrington E, Oesterreich S, Da-

- vidson NE, Huang Y. Inhibition of histone demethylase, LSD2 (KDM1B), attenuates DNA methylation and increases sensitivity to DNMT inhibitor-induced apoptosis in breast cancer cells. *Breast Cancer Res Treat* 2014; **146**: 99-108 [PMID: 24924415 DOI: 10.1007/s10549-014-3012-9]
- 206 **Robertson FM**, Chu K, Boley KM, Ye Z, Liu H, Wright MC, Moraes R, Zhang X, Green TL, Barsky SH, Heise C, Cristofanilli M. The class I HDAC inhibitor Romidepsin targets inflammatory breast cancer tumor emboli and synergizes with paclitaxel to inhibit metastasis. *J Exp Ther Oncol* 2013; **10**: 219-233 [PMID: 24416998]
- 207 **Deb G**, Thakur VS, Limaye AM, Gupta S. Epigenetic induction of tissue inhibitor of matrix metalloproteinase-3 by green tea polyphenols in breast cancer cells. *Mol Carcinog* 2014 Jan 31; Epub ahead of print [PMID: 24481780 DOI: 10.1002/mc.22121]
- 208 **Chiu HW**, Yeh YL, Wang YC, Huang WJ, Chen YA, Chiou YS, Ho SY, Lin P, Wang YJ. Suberoylanilide hydroxamic acid, an inhibitor of histone deacetylase, enhances radiosensitivity and suppresses lung metastasis in breast cancer in vitro and in vivo. *PLoS One* 2013; **8**: e76340 [PMID: 24130769 DOI: 10.1371/journal.pone.0076340]
- 209 **Stark K**, Burger A, Wu J, Shelton P, Polin L, Li J. Reactivation of estrogen receptor  $\alpha$  by vorinostat sensitizes mesenchymal-like triple-negative breast cancer to aminoflavone, a ligand of the aryl hydrocarbon receptor. *PLoS One* 2013; **8**: e74525 [PMID: 24058584 DOI: 10.1371/journal.pone.0074525]
- 210 **Tuval-Kochen L**, Paglin S, Keshet G, Lerenthal Y, Nakar C, Golani T, Toren A, Yahalom J, Pfeffer R, Lawrence Y. Eukaryotic initiation factor 2 $\alpha$ -a downstream effector of mammalian target of rapamycin--modulates DNA repair and cancer response to treatment. *PLoS One* 2013; **8**: e77260 [PMID: 24204783 DOI: 10.1371/journal.pone.0077260]
- 211 **Salvador MA**, Wicinski J, Cabaud O, Toiron Y, Finetti P, Josselin E, Lelievre H, Kraus-Berthier L, Depil S, Bertucci F, Collette Y, Birnbaum D, Charafe-Jauffret E, Ginestier C. The histone deacetylase inhibitor abexinostat induces cancer stem cells differentiation in breast cancer with low Xist expression. *Clin Cancer Res* 2013; **19**: 6520-6531 [PMID: 24141629 DOI: 10.1158/1078-0432.CCR-13-0877]
- 212 **Grassadonia A**, Cioffi P, Simiele F, Iezzi L, Zilli M, Natoli C. Role of Hydroxamate-Based Histone Deacetylase Inhibitors (Hb-HDACIs) in the Treatment of Solid Malignancies. *Cancers (Basel)* 2013; **5**: 919-942 [PMID: 24202327 DOI: 10.3390/cancers5030919]
- 213 **Martin M**, Bonnetterre J, Geyer CE, Ito Y, Ro J, Lang I, Kim SB, Germa C, Vermette J, Wang K, Wang K, Awada A. A phase two randomised trial of neratinib monotherapy versus lapatinib plus capecitabine combination therapy in patients with HER2+ advanced breast cancer. *Eur J Cancer* 2013; **49**: 3763-3772 [PMID: 23953056 DOI: 10.1016/j.ejca.2013.07.142]
- 214 **Curigliano G**, Pivot X, Cortés J, Elias A, Cesari R, Khosravan R, Collier M, Huang X, Cataruzolo PE, Kern KA, Goldhirsch A. Randomized phase II study of sunitinib versus standard of care for patients with previously treated advanced triple-negative breast cancer. *Breast* 2013; **22**: 650-656 [PMID: 23958375 DOI: 10.1016/j.breast.2013.07.037]
- 215 **Earl HM**, Vallier AL, Hiller L, Fenwick N, Young J, Iddawela M, Abraham J, Hughes-Davies L, Gounaris I, McAdam K, Houston S, Hickish T, Skene A, Chan S, Dean S, Ritchie D, Laing R, Harries M, Gallagher C, Wishart G, Dunn J, Provenzano E, Caldas C. Effects of the addition of gemcitabine, and paclitaxel-first sequencing, in neoadjuvant sequential epirubicin, cyclophosphamide, and paclitaxel for women with high-risk early breast cancer (Neo-tAnGo): an open-label, 2x2 factorial randomised phase 3 trial. *Lancet Oncol* 2014; **15**: 201-212 [PMID: 24360787 DOI: 10.1016/S1470-2045]
- 216 **Wang J**, Song P, Schrieber S, Liu Q, Xu Q, Blumenthal G, Amiri Kordestani L, Cortazar P, Ibrahim A, Justice R, Wang Y, Tang S, Booth B, Mehrotra N, Rahman A. Exposure-response relationship of T-DM1: insight into dose optimization for patients with HER2-positive metastatic breast cancer. *Clin Pharmacol Ther* 2014; **95**: 558-564 [PMID: 24488143 DOI: 10.1038/clpt.2014.24]
- 217 **Kashiwaba M**, Inaba T, Komatsu H, Ishida K, Kawagishi R, Matsui Y, Uesugi N, Sugai T, Wakabayashi G. A phase I study of capecitabine combined with CPT-11 in metastatic breast cancer pretreated with anthracyclines and taxanes. *Oncology* 2014; **86**: 206-211 [PMID: 24820348 DOI: 10.1159/000358596]
- 218 **Reddy JA**, Allagadda VM, Leamon CP. Targeting therapeutic and imaging agents to folate receptor positive tumors. *Curr Pharm Biotechnol* 2005; **6**: 131-150 [PMID: 15853692 DOI: 10.2174/1389201053642376]
- 219 **Harrap KR**, Jackman AL, Newell DR, Taylor GA, Hughes LR, Calvert AH. Thymidylate synthase: a target for anticancer drug design. *Adv Enzyme Regul* 1989; **29**: 161-179 [PMID: 2633608 DOI: 10.1016/0065-2571]
- 220 **Kolarevic A**, Yancheva D, Kocic G, Smelcerovic A. Deoxyribonuclease inhibitors. *Eur J Med Chem* 2014 Jul 15; Epub ahead of print [PMID: 25042005 DOI: 10.1016/j.ejmech.2014.07.040]
- 221 **Benzaïd I**, Mönkkönen H, Bonnelye E, Mönkkönen J, Clézardin P. In vivo phosphoantigen levels in bisphosphonate-treated human breast tumors trigger V $\gamma$ 9V $\delta$ 2 T-cell antitumor cytotoxicity through ICAM-1 engagement. *Clin Cancer Res* 2012; **18**: 6249-6259 [PMID: 23032740 DOI: 10.1158/1078-0432.CCR-12-0918]
- 222 **Kollmannsberger C**, Mross K, Jakob A, Kanz L, Bokemeyer C. Topotecan - A novel topoisomerase I inhibitor: pharmacology and clinical experience. *Oncology* 1999; **56**: 1-12 [PMID: 9885371 DOI: 10.1159/000011923]
- 223 **Kumar N**. Taxol-induced polymerization of purified tubulin. Mechanism of action. *J Biol Chem* 1981; **256**: 10435-10441 [PMID: 6116707]
- 224 **Nicolaou KC**, Winssinger N, Pastor J, Ninkovic S, Sarabia F, He Y, Vourloumis D, Yang Z, Li T, Giannakakou P, Hamel E. Synthesis of epothilones A and B in solid and solution phase. *Nature* 1997; **387**: 268-272 [PMID: 9153390]
- 225 **Schuurman HJ**, Cottens S, Fuchs S, Joergensen J, Meerloo T, Sedrani R, Tanner M, Zenke G, Schuler W. SDZ RAD, a new rapamycin derivative: synergism with cyclosporine. *Transplantation* 1997; **64**: 32-35 [PMID: 9233697 DOI: 10.1097/00007890-199707150-00007]
- 226 **McNeil C**. Herceptin raises its sights beyond advanced breast cancer. *J Natl Cancer Inst* 1998; **90**: 882-883 [PMID: 9637135 DOI: 10.1093/jnci/90.12.882]
- 227 **Sabatier R**, Gonçalves A. Pertuzumab (Perjeta®) approval in HER2-positive metastatic breast cancers. *Bull Cancer* 2014; **101**: 765-771 [PMID: 25091659]
- 228 **Corrigan PA**, Cicci TA, Auten JJ, Lowe DK. Ado-trastuzumab emtansine: a HER2-positive targeted antibody-drug conjugate. *Ann Pharmacother* 2014; **48**: 1484-1493 [PMID: 25082874 DOI: 10.1177/1060028014545354]
- 229 **Xia W**, Mullin RJ, Keith BR, Liu LH, Ma H, Rusnak DW, Owens G, Alligood KJ, Spector NL. Anti-tumor activity of GW572016: a dual tyrosine kinase inhibitor blocks EGF activation of EGFR/erbB2 and downstream Erk1/2 and AKT pathways. *Oncogene* 2002; **21**: 6255-6263 [PMID: 12214266 DOI: 10.1038/sj.onc.1205794]
- 230 **Kangas L**, Nieminen AL, Cantell K. Additive and synergistic effects of a novel antiestrogen, toremifene (Fc-1157a), and human interferons on estrogen responsive MCF-7 cells in vitro. *Med Biol* 1985; **63**: 187-190 [PMID: 2419713]
- 231 **Wakeling AE**, Dukes M, Bowler J. A potent specific pure antiestrogen with clinical potential. *Cancer Res* 1991; **51**: 3867-3873 [PMID: 1855205]
- 232 **Nicholson RI**, Walker KJ, Maynard PV. Anti-tumour potential of a new luteinizing hormone releasing hormone analogue, ICI 118630. *Eur J Cancer* 1980; **Suppl 1**: 295-299 [PMID: 6459236]
- 233 **Plourde PV**, Dyrhoff M, Dukes M. Arimidex: a potent and

- selective fourth-generation aromatase inhibitor. *Breast Cancer Res Treat* 1994; **30**: 103-111 [PMID: 7949201 DOI: 10.1007/BF00682745]
- 234 **Giudici D**, Ornati G, Briatico G, Buzzetti F, Lombardi P, di Salle E. 6-Methylenandrosta-1,4-diene-3,17-dione (FCE 24304): a new irreversible aromatase inhibitor. *J Steroid Biochem* 1988; **30**: 391-394 [PMID: 3386266 DOI: 10.1016/0022-4731]
- 235 **Ansfield FJ**, Davis HL, Ellerby RA, Ramirez G. A clinical trial of megestrol acetate in advanced breast cancer. *Cancer* 1974; **33**: 907-910 [PMID: 4819220 DOI: 10.1002/1097-0142]

**P- Reviewer:** Peng Y   **S- Editor:** Ji FF   **L- Editor:** A  
**E- Editor:** Wu HL





## Antimicrobial resistance in *Acinetobacter baumannii*: From bench to bedside

Ming-Feng Lin, Chung-Yu Lan

Ming-Feng Lin, Chung-Yu Lan, Institute of Molecular and Cellular Biology, National Tsing Hua University, Hsin-Chu 31064, Taiwan

Ming-Feng Lin, Department of Medicine, National Taiwan University Hospital Chu-Tung Branch, Hsin-Chu 31064, Taiwan

Author contributions: Lin MF and Lan CY contributed to this paper; both authors read and approved the final version of the manuscript before submission.

Correspondence to: Ming-Feng Lin, MD, Chief of Department of Medicine, National Taiwan University Hospital Chu-Tung Branch, No. 52, Chih Shan Road, Chutung Town, Hsin-Chu 31064, Taiwan. [c9977@ms27.hinet.net](mailto:c9977@ms27.hinet.net)

Telephone: +886-35-943248 Fax: +886-35-308630

Received: July 26, 2014 Revised: August 25, 2014

Accepted: October 23, 2014

Published online: December 16, 2014

### Abstract

*Acinetobacter baumannii* (*A. baumannii*) is undoubtedly one of the most successful pathogens in the modern healthcare system. With invasive procedures, antibiotic use and immunocompromised hosts increasing in recent years, *A. baumannii* has become endemic in hospitals due to its versatile genetic machinery, which allows it to quickly evolve resistance factors, and to its remarkable ability to tolerate harsh environments. Infections and outbreaks caused by multidrug-resistant *A. baumannii* (MDRAB) are prevalent and have been reported worldwide over the past twenty or more years. To address this problem effectively, knowledge of species identification, typing methods, clinical manifestations, risk factors, and virulence factors is essential. The global epidemiology of MDRAB is monitored by persistent surveillance programs. Because few effective antibiotics are available, clinicians often face serious challenges when treating patients with MDRAB. Therefore, a deep understanding of the resistance mechanisms used by MDRAB can shed light on two possible strategies to combat the dissemination of antimicrobial resistance: stringent infection control and

antibiotic treatments, of which colistin-based combination therapy is the mainstream strategy. However, due to the current unsatisfying therapeutic outcomes, there is a great need to develop and evaluate the efficacy of new antibiotics and to understand the role of other potential alternatives, such as antimicrobial peptides, in the treatment of MDRAB infections.

© 2014 Baishideng Publishing Group Inc. All rights reserved.

**Key words:** *Acinetobacter baumannii*; Antibiotic resistance; Epidemiology; Genomics; Infection control

**Core tip:** With the current rapid increase in the numbers of studies on *Acinetobacter baumannii* (*A. baumannii*), the complexity of the entire picture regarding how this superbug copes with its environment and influences human beings is gradually being understood. By conducting a thorough review of this topic, this paper aims to present the relevant literature regarding the antimicrobial resistance of *A. baumannii* and the currently available treatment options for *A. baumannii* infections to highlight possible future research directions.

Lin MF, Lan CY. Antimicrobial resistance in *Acinetobacter baumannii*: From bench to bedside. *World J Clin Cases* 2014; 2(12): 787-814 Available from: URL: <http://www.wjgnet.com/2307-8960/full/v2/i12/787.htm> DOI: <http://dx.doi.org/10.12998/wjcc.v2.i12.787>

### INTRODUCTION

#### *Species identification and current taxonomy*

*Acinetobacter spp.* are glucose-non-fermentative, non-motile, non-fastidious, catalase-positive, oxidase-negative, aerobic Gram-negative coccobacilli<sup>[1]</sup>. Since 1986, the taxonomy of the genus *Acinetobacter* has been modified several times. Currently, the original single species clas-

sification of *Acinetobacter calcoaceticus* (*A. calcoaceticus*) has been abandoned, and at least 34 genomic species can be distinguished within the genus *Acinetobacter*, 23 of which have been assigned species names<sup>[2]</sup>. The challenge in the taxonomy of *Acinetobacter* is due to the clusters of closely related species that are difficult to distinguish using phenotypic traits and chemotaxonomic methods. The *A. calcoaceticus*-*Acinetobacter baumannii* (*A. baumannii*) complex, comprising *A. calcoaceticus*, *A. baumannii*, and the genomic species 3 and 13TU, is the most well-known example<sup>[3]</sup>. Because the antibiotic susceptibilities and clinical relevance of the different genomic species are significantly different<sup>[4-7]</sup>, genomic methods for *Acinetobacter* species identification are necessary. A number of genomic fingerprinting methods have been proposed, including pulsed-field gel electrophoresis (PFGE); ribotyping; polymerase chain reaction (PCR)-based fingerprinting techniques, such as random amplified polymorphic DNA analysis; repetitive extragenic palindromic sequence-based PCR (rep-PCR); amplified ribosomal DNA restriction analysis; RNA spacer fingerprinting; and amplified fragment length polymorphism analysis<sup>[8]</sup>. In addition, new methods, such as 16S-23S ribosomal intergenic spacer, 16S rRNA gene, *rpoB* gene and *gyrB* gene sequence analyses, have been developed for *Acinetobacter* species identification<sup>[9,10]</sup>.

### Common typing methods in outbreak investigations

Of all of the *Acinetobacter* species, *A. baumannii* is the most important member associated with infections in clinical practice and causes most of the reported outbreaks. In addition to chart review and statistical epidemiology, some DNA fingerprinting methods are valuable in outbreak investigations and strain discrimination. Rep-PCR, PFGE, and multilocus sequence typing (MLST) have all been used in previous studies. Rep-PCR has been proven to be a useful and expedient method for the epidemiological characterization of *A. baumannii* nosocomial outbreaks<sup>[11]</sup>. Rep-PCR has also been used as a tool for determining species lineages of *A. baumannii* in a hospital<sup>[12]</sup> and for differentiating pan-European, multi-resistant *A. baumannii* clone III from clones I and II<sup>[13]</sup>. Despite the inter-laboratory variability of rep-PCR, this method has the advantage of being faster to perform than PFGE and MLST. The intra-laboratory clustering of *A. baumannii* has been shown to be well conserved<sup>[14]</sup> and to correlate well with PFGE<sup>[15]</sup> or MLST results<sup>[16]</sup>, demonstrating the robustness of rep-PCR. We have found one rep-PCR major cluster (84%) of *A. baumannii* carrying a class I integron that spread among four regional hospitals in northern Taiwan<sup>[17]</sup>. However, PFGE is still considered the gold standard for typing outbreak-related isolates of *A. baumannii*<sup>[18-21]</sup>, whereas MLST provides a high level of resolution and is an excellent tool for studying the population structure and long-term epidemiology of *A. baumannii*<sup>[22]</sup>. Recently, the *A. baumannii* MLST database (<http://pubmlst.org/abaumannii/>) was developed for the BIGSdb genomics platform<sup>[23]</sup> to assist the broader community in elucidating the structure and function of this

microorganism.

### Clinical manifestations

*A. baumannii*, named after Paul Baumann, is ubiquitous in soil and water<sup>[24]</sup>. Previously, *A. baumannii* was regarded as a low-virulence commensal bacterium. However, it has become a successful pathogen<sup>[25]</sup> and has emerged as a major cause of healthcare-associated infections, most of which have occurred in critically ill patients in the intensive care unit (ICU) setting<sup>[26]</sup>. In recent decades, infections caused by *A. baumannii* have also occurred outside the ICU or in trauma patients after natural disasters, and they have even affected patients with co-morbidities in the community<sup>[27]</sup>. Reports of community-acquired *Acinetobacter* infections have increased over the past decade<sup>[28]</sup>. Several different types of infections, including pneumonia, urinary tract infections, bacteremia, wound infections and even meningitis, are caused by this organism<sup>[29]</sup>. These infections often occur in older patients, many of whom have chronic underlying diseases and have previously received antimicrobial treatment<sup>[30,31]</sup>. The mortality of patients with *A. baumannii* infections in hospitals and in the ICU has ranged from 7.8% to 23% and from 10% to 43%, respectively<sup>[32]</sup>.

### Risk factors

In recent years, many studies have reported the risk factors for acquiring *A. baumannii* infections and have particularly focused on those caused by multidrug-resistant strains. The acquisition of MDRA is related to multiple factors, including environmental contamination and contact with transiently colonized healthcare providers<sup>[33]</sup>. The independent risk factors for the acquisition of imipenem-resistant *A. baumannii* (IRAB) include a hospital size of > 500 beds, previous antimicrobial treatment, a urinary catheter, surgery<sup>[34]</sup>, previous ICU stay, and prior exposure to imipenem or third-generation cephalosporins<sup>[35]</sup>. The only significant independent risk factor for the appearance of imipenem-resistant multidrug-resistant *A. baumannii* (MDRA) in patients formerly infected with imipenem-susceptible MDRA is imipenem or meropenem exposure<sup>[36]</sup>. For extensively drug-resistant *A. baumannii* (XDRA) infections, the prior use of imipenem, meropenem, piperacillin/tazobactam or fourth-generation cephalosporins and > 30 d of being bedridden have been found to be independent risk factors<sup>[37]</sup>. A systematic review concluded that the acquisition and spread of *A. baumannii* appeared to be related to a large number of variables, the most important of which were deficiencies in the implementation of infection control guidelines and the use of broad-spectrum antibiotics<sup>[38]</sup>.

The risk factors that are associated with *A. baumannii* bacteremia are immunosuppression, unscheduled hospital admission, respiratory failure at ICU admission, previous antimicrobial therapy, previous sepsis in the ICU, and the invasive procedures index<sup>[39]</sup>. Resistance to carbapenems, mechanical ventilation, and the presence of malignancy have also been found to be associated with high mortality rates in patients with *A. baumannii* bacteremia<sup>[40]</sup>.

Regarding ventilator-associated pneumonia caused by *A. baumannii*, the risk factors include neurosurgery, adult respiratory distress syndrome, head trauma, and large-volume pulmonary aspiration<sup>[41]</sup>. Because various studies showed certain differences in the risk factors of acquiring drug-resistant *A. baumannii* bacteremia or pneumonia<sup>[42-46]</sup>, a separate investigation should be performed in each hospital setting to limit the spread of this pathogen<sup>[38]</sup>.

### Virulence factors

Previously, *A. baumannii* was regarded as a low-grade pathogen; however, it contains virulence factors that enhance its bacterial toxicity and pathogenicity. A combined approach of genomic and phenotypic analyses led to the identification of several virulence factors, including extracellular components with hemolytic, phospholipase, protease and iron-chelating activities, biofilm formation, surface motility, and stress resistance<sup>[47]</sup>. The biofilm formation of *A. baumannii* facilitates its attachment to abiotic and biotic surfaces<sup>[48]</sup>, including those of medical devices and host tissues. The initiation and maturation of biofilms are related to pilus assembly and the production of the biofilm-associated protein (Bap), which is regulated by the two-component system BfmRS<sup>[49]</sup>. The Bap protein plays a role in adhesion to human epithelial cells<sup>[50]</sup>, and the inhibition of this protein can prevent *A. baumannii* infection<sup>[51]</sup>. In fact, in a multicenter cohort study, all catheter-related urinary or blood stream infections due to *A. baumannii* were caused by biofilm-forming strains<sup>[52]</sup>. A 2D proteomic analysis of pellicle-forming *A. baumannii* isolates showed that overexpression of CarO, which is an OprD-homolog, siderophore iron uptake, and pili systems are involved in the development of biofilms<sup>[53]</sup>.

Iron uptake systems are essential to the survival and pathogenicity of bacteria, especially in the low-iron environment of the human host. *A. baumannii* grown under iron-limited conditions undergo major transcriptional changes of not only many iron acquisition-related genes but also of genes involved in motility<sup>[54]</sup>. *A. baumannii* is well-equipped with metal homeostatic systems that are required for the colonization of a diverse array of tissues<sup>[55]</sup>. Genome investigations have revealed wide distributions of endogenous siderophores in clinical *A. baumannii* isolates, arguing for their role in pathogenic capabilities<sup>[47]</sup>. The zinc acquisition system has also been found in *A. baumannii*, which is required for efficient zinc uptake *in vitro* and full pathogenesis *in vivo*<sup>[56]</sup>.

*A. baumannii* adheres to human bronchial epithelial cells *in vitro*, and its prevalent European clone II has a relatively high capacity for adhering to these cells<sup>[57]</sup>. Additionally, the K1 capsular polysaccharide has been shown to prevent *A. baumannii* from being phagocytized by macrophages, to optimize its growth in human ascites fluid and serum, and to enhance its survival in a rat soft tissue infection model<sup>[58]</sup>. Moreover, several proteins have been implicated as possible virulence factors in *A. baumannii*. Omp38 induces the apoptosis of host cells<sup>[59]</sup>, the absence of the RecA protein decreases survival in

response to both heat shock and desiccation<sup>[60]</sup>, and the inactivation of phospholipase D diminishes *A. baumannii* pathogenesis<sup>[61]</sup>. Importantly, the outer membrane protein A of *A. baumannii* (AbOmpA) is the most abundant surface protein that has been associated with the apoptosis of epithelial cells through mitochondrial targeting<sup>[62]</sup>. AbOmpA is also the major nonspecific channel in *A. baumannii* and appears to be essential for this organism's high levels of intrinsic resistance to a number of antibiotics<sup>[63]</sup>. *A. baumannii* can rapidly develop resistance to polymyxin antibiotics through the loss of the lipid A component of lipopolysaccharide<sup>[64]</sup>, which subsequently alters the expression of critical transport and biosynthesis systems associated with modulating the composition and structure of the bacterial surface<sup>[65]</sup>.

## GLOBAL EPIDEMIOLOGY

Two key factors contributing to the significant and ubiquitous dissemination of *A. baumannii* in hospitals are the extent of its antimicrobial resistance and its environmental resilience<sup>[66]</sup>. The extent of antimicrobial resistance is more severe in *A. baumannii* isolates from patients in Asian and European ICUs than from patients in American ICUs<sup>[27]</sup>, and significant increases in antimicrobial resistance were noted worldwide from 2004 to 2009. The highest resistance rates in 2009 were for ceftriaxone (83.6%), piperacillin-tazobactam (82.0%), and ceftazidime (80.3%) in the Middle East. Increases in resistance were noted for all antimicrobials in isolates collected from the Asia-Pacific Rim, ranging from a 19.1% increase in ceftazidime resistance to a 38.9% increase in levofloxacin resistance. Resistance also increased significantly in Africa (including piperacillin-tazobactam, ceftriaxone, cefepime, amikacin, meropenem, and levofloxacin resistance) and Europe (including piperacillin-tazobactam, ceftriaxone, ceftazidime, levofloxacin, amikacin, minocycline, meropenem, and cefepime resistance)<sup>[67]</sup>.

The first MDRAB isolate resistant to almost all available antibiotics in Taiwan was discovered in 1998<sup>[68]</sup>. Since then, many MDRAB outbreaks have been reported in Taiwan<sup>[69-72]</sup>. A Taiwanese surveillance report of antimicrobial resistance in 2000 found that 73% of *A. baumannii* isolates collected from 21 medical centers and regional hospitals were ceftazidime-resistant<sup>[73]</sup>. Another study conducted during the same year at five major teaching hospitals in Taiwan showed that as many as 22% of *A. baumannii* isolates were not susceptible to imipenem<sup>[74]</sup>. In 2012, the Taiwan Surveillance of Antimicrobial Resistance program showed that the prevalence of the IRAB complex increased from 3.4% in 2002 to 58.7% in 2010 and that of the XDRAB complex increased from 1.3% in 2002 to 41.0% in 2010<sup>[75]</sup>. In addition, the proportion of healthcare-associated infections caused by carbapenem-resistant *A. baumannii* (CRAB) significantly increased, compared to infections by all *A. baumannii*, from 14% in 2003 to 46% in 2008 in Taiwan<sup>[76]</sup>. The local spread of MDRAB has been demonstrated in five proximal hospitals in northern Taiwan, with resistance determinants



distributed widely in clonal and non-clonal isolates<sup>[77]</sup>.

In addition to its prevalence in Taiwan, MDRAB is also prevalent in hospitals in many areas of the world, including Korea<sup>[78]</sup>, Belgium<sup>[79]</sup>, Italy<sup>[80]</sup>, Iraq<sup>[81]</sup>, Israel<sup>[82]</sup>, Greece<sup>[83]</sup> and America<sup>[84]</sup>. Furthermore, a one-year study demonstrated that three clones of MDRAB had spread in hospitals in Brazil<sup>[85]</sup>. In a single institution in Queensland, Australia, sequence type 92 (ST92) was the dominant sequence type and was present for 9 years<sup>[86]</sup>. Additionally, clonal dissemination among three hospitals located in two different cities has been documented in China, indicating the epidemic potential of MDRAB<sup>[87]</sup>. Both inter-institutional and intra-institutional transmission of a strain of *A. baumannii* is possible<sup>[15]</sup>. Several multidrug-resistant clones can coexist endemically in one hospital for several years<sup>[31,88]</sup>, and the same clones often spread on a small scale within a short period of time<sup>[31]</sup> or can be detected during an outbreak by a close survey of epidemic sources<sup>[88]</sup>. Furthermore, such outbreaks can occur across national boundaries. For example, Wybo *et al*<sup>[89]</sup> reported a MDRAB nosocomial infection involving approximately 20 patients in a university hospital in Belgium that was the result of a transfer of two patients from Greece.

In addition to the increasing importance of MDRAB in nosocomial infections, the increasing reports of outbreaks caused by CRAB in recent years have become another frightening reality. The imipenem resistance rate of *A. baumannii* from a worldwide collection between 2005 and 2009 reached resistance rates of greater than 50%<sup>[90]</sup>. In Brooklyn, New York, citywide surveillance revealed that about 2 of every 3 isolates were resistant to carbapenem antibiotics<sup>[91]</sup>. One predominant strain type of CRAB has established predominance after being introduced in a university hospital in Chicago in 2005<sup>[21]</sup>. In addition, molecular epidemiological investigations of sequential outbreaks of *A. baumannii* in an ICU showed the emergence of carbapenem resistance in Italy from 1999 to 2002<sup>[19]</sup>. The clonal spread of imipenem-resistant *Acinetobacter* spp. accompanied by the wide dissemination of the OXA-23 carbapenemase has been noted in China<sup>[92]</sup>. The first CRAB outbreak was reported in America in 1991, followed by global CRAB dissemination<sup>[93]</sup>. Most outbreaks caused by CRAB have occurred in ICU settings<sup>[29,94]</sup> throughout many countries. An outbreak caused by pandrug-resistant *A. baumannii* (PDRAB) was also reported in a pediatric ICU in a Taiwanese hospital<sup>[95]</sup>.

## COMPARATIVE GENOMICS

In recent years, whole-genome sequencing and comparative genomics have been performed to elucidate the genetic basis of *A. baumannii* resistance, especially regarding the extent of variability and the acquisition and transfer of resistance determinants among different strains. The *A. baumannii* strain AYE, an endemic strain in France, exhibits an 86-kb resistance island in which 45 resistance genes are clustered<sup>[96]</sup>. Sequence similarities and phylogenetic analyses confirm that most of the resistance genes

found in the *A. baumannii* AYE strain have been acquired from bacteria of the genera *Pseudomonas*, *Salmonella*, or *Escherichia*. Using pyrosequencing and transposon mutagenesis, the assembled genome of *A. baumannii* ATCC 17978 has been shown to consist of 3976746 base pairs (bp) and 3830 open reading frames (ORFs), a significant fraction (17.2%) of which are located in 28 putative alien islands<sup>[97]</sup>. A remarkable number of the islands contain genes implicated in virulence. *A. baumannii* ACICU has a single chromosome of 3904116 bp and two plasmids, pACICU1 and pACICU2, of 28279 and 64366 bp, respectively<sup>[98]</sup>. As many as 36 putative alien islands (pAs), 15 of which encode genes related to drug resistance, have been detected in the ACICU genome. One investigation involving MDRAB strains from hospitals of 10 European countries showed that AbaR3 is the original structure from which the AbaRs, the genomic islands containing many resistance genes, have been derived in European clone I, thus providing the strains of this lineage with a selective advantage<sup>[99]</sup>. All of these findings indicate that the genome of *A. baumannii* has acquired a large amount of foreign DNA, which has an important role in pathogenesis and antimicrobial resistance.

Currently, the whole-genome sequencing of the widely spread MDRAB strain MDR-ZJ06<sup>[100]</sup>, an MDR-TJ<sup>[101]</sup> strain in China; and two other multidrug-resistant strains (TCDC-AB0715, harboring both *bla*<sub>OXA-23</sub> and *bla*<sub>OXA-66</sub><sup>[102]</sup>, and TYTH-1<sup>[103]</sup> from Taiwan) has been completed. A comparative genomics analysis has revealed a common strain lineage between the Taiwanese strains (TYTH-1 and TCDCAB0715) and the Chinese strains (MDR-TJ and MDR-ZJ06)<sup>[104]</sup>. Phylogenetic studies and GC profiles showed that the genome of TYTH-1 was the closest to the genome of MDR-ZJ06, which implies that the dissemination of *bla*<sub>OXA-23</sub>-carrying CRAB in Taiwan may have been mediated by the transfer of people between Taiwan and China.

Adams *et al*<sup>[105]</sup> found that the entire multidrug-resistance phenotype of *A. baumannii* can be explained by the acquisition of discrete resistance determinants distributed throughout the genome. A comparison of closely related multidrug-resistant and drug-susceptible isolates suggests that drug efflux may contribute less to the resistance to certain classes of antibiotics than inactivation of enzymes. A resistance island with a variable composition of resistance determinants interspersed with transposons, integrons, and other mobile genetic elements is a significant contributor to the multidrug-resistant phenotype. A whole-genome sequencing analysis of six closely related clinical isolates of *A. baumannii*, including four from one hospital, revealed an extensive divergence of the resistance genotype that correlated with the observed differences in antimicrobial susceptibility<sup>[106]</sup>. Resistance genes associated with insertion sequences, plasmids, and a chromosomal resistance gene island all showed certain degrees of variability. The dynamic resistance gene pool suggests the rapid evolution of drug resistance in *A. baumannii*. The whole-genome sequencing of three dominant *A. baumannii* strains in an outbreak concluded that



much of their diversification was mediated by homologous recombination across 20% of their genomes<sup>[107]</sup>. The differences in genomic contents among different *Acinetobacter* spp. are partly shaped by their distinct ecological niches<sup>[108]</sup>. This notion is further supported by the variable presence of some genes encoding transcription factors and transporters among clinical isolates and their environmental *Acinetobacter* spp.<sup>[105]</sup>.

## RESISTANCE MECHANISMS

### Overview

Currently, certain strains of *A. baumannii* is highly resistant to most antibiotics available in clinical practice. A number of resistance mechanisms to many classes of antibiotics are known to exist in *A. baumannii*, including  $\beta$ -lactamases, multidrug efflux pumps, aminoglycoside-modifying enzymes, permeability defects, and the alteration of target sites<sup>[109-111]</sup>. Most of these resistance mechanisms can target different classes of antibiotics. However, several different mechanisms can work together to contribute to the resistance to a single class of antibiotics. For example, the resistance mechanisms in CRAB are diverse<sup>[112]</sup>. In addition to  $\beta$ -lactamases with carbapenem-hydrolyzing activity as a major carbapenem resistance mechanism, which include carbapenem-hydrolyzing class D  $\beta$ -lactamases (CHDLs) and metallo- $\beta$ -lactamases (MBLs), porins such as CarO<sup>[66]</sup> and penicillin-binding protein modifications might also be involved in carbapenem resistance<sup>[113]</sup>. The spread of multidrug-resistance determinants in *A. baumannii* is mostly through plasmid conjugation, transposon acquisition or integron mobilization to gain clusters of genes encoding resistance to several antibiotic families<sup>[110]</sup>. Furthermore, the functional insertion sequences are important in amplifying antimicrobial resistance and gene plasticity<sup>[114-118]</sup>. Table 1 shows the various antimicrobial resistance mechanisms of *A. baumannii*. The details are further discussed below.

### $\beta$ -lactamase

Inactivation of  $\beta$ -lactams constitutes an important part of multidrug resistance in *A. baumannii*, especially for  $\beta$ -lactam antibiotic resistance. All four Ambler classes of  $\beta$ -lactamases (*i.e.*, classes A, B, C and D) can be identified in this organism<sup>[66]</sup>. Although a wide range of class A  $\beta$ -lactamases, including those of temoneira (TEM)<sup>[119-121]</sup>, sulfhydryl variable (SHV)<sup>[122]</sup>, cefotaxime hydrolyzing capabilities (CTX-M)<sup>[123,124]</sup>, guiana extended-spectrum (GES)<sup>[115,125]</sup>, self-transferable plasmid from *E. coli* (SCO)<sup>[126]</sup>, *Pseudomonas* extended resistant (PER)<sup>[127-130]</sup>, vietnam extended-spectrum  $\beta$ -lactamase (VEB)<sup>[96,131-133]</sup>, carbenicillin hydrolyzing  $\beta$ -lactamase (CARB)<sup>[134,135]</sup> and *K. pneumoniae* carbapenemase (KPC)<sup>[136]</sup>, have been reported in *A. baumannii* (Table 1), they are generally regarded to play a minor role in its resistance phenotype, especially in carbapenem resistance. Some of these enzymes are narrow-spectrum  $\beta$ -lactamases, *e.g.*, TEM-1<sup>[119-121]</sup>, SCO-1<sup>[126]</sup> and CARB-4<sup>[135]</sup>; however, a number of these enzymes are still responsible for the hydrolysis of

extended-spectrum  $\beta$ -lactams (ESBL). PER-1 was the first ESBL enzyme identified in *A. baumannii*<sup>[137]</sup>, whereas TEM-92 and CARB-10 were the first reported TEM-type<sup>[120]</sup> and CARB-type<sup>[134]</sup> ESBLs, respectively. Later, the chromosomally encoded ESBLs SHV-5<sup>[122]</sup>, PER-2<sup>[132]</sup> and PER-7<sup>[129,130]</sup> were also described. *A. baumannii* strains carrying the extended spectrum VEB-1 enzyme were first reported in an outbreak in France<sup>[131]</sup>. GES-11, an integron-associated GES variant, can even confer reduced susceptibility to carbapenems<sup>[115,125]</sup>. In addition, CTX-M enzymes are transmitted by integrons or plasmids, indicating the potential dissemination in outbreaks between different strains<sup>[123,124]</sup>. Finally, KPC-10 was the first KPC  $\beta$ -lactamase to be identified<sup>[136]</sup>.

Class B  $\beta$ -lactamases can confer resistance to the majority of  $\beta$ -lactams because of their broad range, potent carbapenemase activity and resistance to inhibitors<sup>[138]</sup>. Although MBLs are not the predominant carbapenemases in *A. baumannii*, verona integron-encoded metallo- $\beta$ -lactamase (VIM), imipenemase (IMP) and seoul imipenemase (SIM) MBLs have been found contribute to the high-level resistance to carbapenems. The first VIM enzyme was described by Yum in 2002<sup>[139]</sup>. Thereafter, several other VIM variants, including VIM-1<sup>[140-142]</sup>, VIM-3<sup>[143]</sup>, VIM-4<sup>[141,142]</sup>, and VIM-11<sup>[143]</sup>, were identified in *A. baumannii*. IMP enzymes have also been reported in several Gram-negative bacteria worldwide, including *A. baumannii*. At least nine variants of IMP enzymes have been identified in *A. baumannii*: IMP-1<sup>[144]</sup>, IMP-2<sup>[145]</sup>, IMP-4<sup>[146,147]</sup>, IMP-5<sup>[148]</sup>, IMP-6<sup>[149]</sup>, IMP-8<sup>[143]</sup>, IMP-11<sup>[150]</sup>, IMP-19<sup>[150]</sup> and IMP-24<sup>[143]</sup>. SIM-1 is the only SIM enzyme that has been reported in *A. baumannii*<sup>[151]</sup>. More recently, NDM (new Delhi metallo- $\beta$ -lactamase)-1<sup>[152-154]</sup> and NDM-2<sup>[155]</sup> were observed in *A. baumannii*. *bla*<sub>NDM-1</sub> is integrated in the chromosome within a new transposon structure with two copies of the insertion sequence *ISA*-*ba*125 in one clinical strain of *A. baumannii*. Such variability of the genetic environment of *bla*<sub>NDM-1</sub> likely facilitates its rapid dissemination<sup>[153]</sup>.

The nucleotide sequence of the chromosomal cephalosporinase gene, which encodes an AmpC  $\beta$ -lactamase, in *A. baumannii* was first characterized in a clinical isolate from Spain in 2000<sup>[156]</sup>. Different isolates of *A. baumannii* have been shown to have almost identical AmpC sequences (no more than two amino-acid substitutions)<sup>[157]</sup>. A phylogenetic analysis showed that *Acinetobacter ampC* genes are descended from a common ancestor and are more closely related to each other than the *ampC* genes found in other species of bacteria<sup>[158]</sup>. The class C chromosomal  $\beta$ -lactamase AmpC in *A. baumannii* has a typical cephalosporinase substrate profile<sup>[156]</sup>. The presence of AmpC  $\beta$ -lactamase plays an important role in  $\beta$ -lactam resistance in *A. baumannii*, and in fact, a high percentage of drug-resistant *A. baumannii* possess *bla*<sub>ampC</sub><sup>[119]</sup>. In a study of 23 MDRA clinical isolates from five proximal hospitals in Taiwan, all isolates had AmpC-type *bla*<sup>[77]</sup>. The presence of an insertion sequence with a strong promoter upstream of *ampC* in *A. baumannii* clinical isolates has the potential to overexpress AmpC, resulting in high-

**Table 1** Antimicrobial resistance mechanisms in *Acinetobacter baumannii*

Resistance mechanism	Class/family	Protein	Ref.
β-lactamases	Class A	TEM-1	[105,119,121]
		TEM-92	[120]
		SHV-5	[122]
		CTX-M-2	[123]
		CTX-M-15	[124]
		GES-11	[115,125]
		GES-12	[115]
		GES-14	[115]
		SCO-1	[126]
		PER-1	[127,128]
		PER-2	[132]
		PER-7	[129,130]
		VEB-1	[96,105,131-133]
		CARB-4	[135]
		CARB-10	[134]
		KPC-10	[136]
	Class B	VIM-1	[140-142]
		VIM-2	[139,143]
		VIM-3	[143]
		VIM-4	[141,142]
		VIM-11	[143]
		IMP-1	[144]
		IMP-2	[145]
		IMP-4	[146,147]
		IMP-5	[148]
		IMP-6	[149]
		IMP-8	[143]
		IMP-11	[150]
		IMP-19	[150]
		IMP-24	[143]
		SIM-1	[151]
		NDM-1	[152-154]
		NDM-2	[155]
		AmpC	[156-160]
	Class C		
	Class D		
	Narrow-spectrum	OXA-3	[163]
		OXA-20	[164]
		OXA-10	[387]
	CHDLs	OXA-23	[66,92,105,147,167-183]
		OXA-133	[185]
		OXA-24	[197,201,204]
		OXA-40	[188,200, 202,203]
		OXA-72	[92,205,206]
		OXA-25, OXA-26, OXA-27	[198]
		OXA-51	[105,187-190]
		OXA64, OXA-65, OXA-66, OXA-68, OXA-70, OXA-71	[191]
		OXA-69, OXA-75, OXA-76, OXA-77	[186]
		OXA-79, OXA80, OXA-104, OXA106~OXA-112	[194]
	OXA-51 group	OXA-82, OXA-83, OXA-84	[192,194]
		OXA-86, OXA-87	[193]

		OXA-88, OXA-91, OXA-93, OXA-94, OXA-95, OXA-96	[147]
		OXA-92	[195]
		OXA-113	[122]
	OXA-58 group	OXA-58	[116,118,207,210,211, 215,219]
		OXA-96	[147]
		OXA-97	[220]
	Novel groups	OXA-143	[196]
		OXA-182	[221]
		OXA-235	[222]
Efflux pumps	RND	AdeABC	[235,238]
		AdeFGH	[243]
		AdelJK	[244]
	MFS	TetA	[248]
		CmlA	[225]
		MdfA	[233]
		CraA	[249]
		AmvA	[250]
	MATE	AbeM	[251]
	SMR	AbeS	[252]
AME	AAC	AAC3 (aacC1, aacC2)	[256]
		AAC (6') ( <i>aacA4</i> )	[17,253,257-259,261]
	ANT	ANT (2'') ( <i>aadB</i> )	[256]
		ANT (3'') ( <i>aadA1</i> )	[17,253,261]
	APH	APH (3') ( <i>aphA1</i> )	[255]
		APH (3'')	[253]
Permeability defects		CarO	[263-267]
		47-kDa OMP	[91]
		44-kDa OMP	[91]
		37-kDa OMP	[91]
		33-36-kDa OMP	[269]
		22-33-kDa OMP	[268]
		43-kDa OMP	[271]
		Lipopolysaccharide	[64]
		OmpA	[274]
Alteration of target sites	Change of PBP	PBP2	[276]
	DNA gyrase	GyrA/ParC	[237]
	Ribosomal	TetM	[280]
	protection		
	Dihydrofolate reductase	Dfr or Dhfr	[17,281]
		FolA	[281]
	16S rRNA methylation	ArmA	[253,258,282-286]

TEM: Temoneira; SHV: Sulfhydryl variable; CTX-M: Cefotaxime hydrolyzing capabilities; GES: Guiana extended-spectrum; SCO: Self-transferable plasmid from *E. coli*; PER: *Pseudomonas* extended resistant; VEB: Vietnam extended-spectrum β-lactamase; CARB: Carbenicillin hydrolyzing β-lactamase; KPC: *K. pneumoniae* carbapenemase; VIM: Verona integron-encoded metallo-β-lactamase; IMP: Imipenemase; SIM: Seoul imipenemase; NDM: New Delhi metallo-β-lactamase; AmpC: Ampicillin class C β-lactamase; CHDL: Carbapenem-hydrolyzing class D β-lactamase; OXA: Oxacillinase; RND: Resistance-nodulation-division; MFS: Major facilitator superfamily; MATE: Multidrug and toxic compound extrusion; SMR: Small multidrug resistance; Ade: *A. baumannii* multidrug-resistant efflux pump; TetA: Tetracycline resistant *Acinetobacter*; CmlA: Chloramphenicol resistance *Acinetobacter*; MdfA: Multidrug facilitator; CraA: Chloramphenicol resistance *Acinetobacter*; AmvA: *A. baumannii* Methyl Viologen and antimicrobial resistance protein; AbeM: *A. baumannii* efflux pump of MATE family; AbeS: *A. baumannii* efflux pump of SMR family; AME: Aminoglycoside-modifying enzyme; AAC: Aminoglycoside acetyltransferases; ANT: Aminoglycoside adenylyltransferases; APH: Aminoglycoside phosphotransferases; CarO: Carbapenem-associated outer membrane protein; OMP: Outer membrane protein; PBP: Penicillin binding protein; GyrA/ParC: DNA Gyrase/partitioning of the nucleoid partition; Dhfr: Dihydrofolate reductase; FolA: Folate; ArmA: Armillaria mellea.

level ceftazidime resistance<sup>[159,160]</sup>. IS*Aba1*-like sequences have been identified immediately upstream of the *bla<sub>ampC</sub>* gene in ceftazidime-resistant *A. baumannii* isolates but have been shown to be absent in ceftazidime-susceptible *A. baumannii* isolates<sup>[157]</sup>.

Class D  $\beta$ -lactamases were designated OXAs in reference to their preferred substrate oxacillin<sup>[161]</sup>. Some OXAs are also able to hydrolyze extended-spectrum cephalosporins, and some can even inactivate carbapenems by acting as carbapenemases<sup>[66]</sup>. At least 121 different variants of class D  $\beta$ -lactamases have been identified at the protein level, and in contrast to other class D  $\beta$ -lactamases, 45 of these variants exhibit carbapenem-hydrolyzing activities<sup>[162]</sup>. The *bla<sub>oxa</sub>* genes can be located either on a chromosome or a plasmid and can sometimes be found in integrons<sup>[163,164]</sup>. Among the four classes of  $\beta$ -lactamases, MBLs and CHDLs are the two main groups of carbapenemases in *A. baumannii*, the latter of which is responsible for the most common type of carbapenem resistance *via* enzymatic degradation<sup>[165]</sup>. Currently, nine major subgroups of OXA carbapenemases have been identified based on amino acid homologies<sup>[166]</sup>. Four subgroups of OXA with carbapenemase activity, including the OXA-23, OXA-40/24, OXA-51 and OXA-58 clusters, are prevalent in *A. baumannii*<sup>[162,166]</sup>.

New OXA-type carbapenemases have been frequently discovered since the first clinical isolate of *A. baumannii* with OXA-23 was characterized<sup>[66]</sup>. The *bla<sub>oxa-23</sub>* carbapenemase gene has also been disseminated worldwide<sup>[167]</sup>. The countries that have reported *A. baumannii* with OXA-23 carbapenemase include France<sup>[168-170]</sup>, Germany<sup>[171]</sup>, Bulgaria<sup>[172]</sup>, Romania<sup>[173]</sup>, the United States<sup>[105]</sup>, Colombia<sup>[174]</sup>, Brazil<sup>[175]</sup>, Australia<sup>[176]</sup>, Taiwan<sup>[177,178]</sup>, China<sup>[92,179]</sup>, Korea<sup>[180]</sup>, Singapore<sup>[147,181]</sup>, Italy<sup>[182]</sup> and Spain<sup>[183]</sup>. *A. radioresistens* has been proposed as a silent source of *bla<sub>oxa-23</sub>* for *A. baumannii*<sup>[184]</sup>, and a novel variant, named *bla<sub>oxa-133</sub>*, has been reported by the Asia-Pacific SENTRY surveillance program<sup>[185]</sup>.

OXA-51/69-like  $\beta$ -lactamases are intrinsic chromosomal enzymes in *A. baumannii*<sup>[166,186]</sup> that emerged as a new subgroup of carbapenemases in MDRAB in 2004<sup>[187]</sup> and that show increased carbapenemase activity when IS*Aba1* is upstream of the promoter region<sup>[188,189]</sup>. However, drug export by an efflux pump might be more important in some clinical isolates<sup>[190]</sup>. A comparative genomics study by Adams *et al.*<sup>[105]</sup> showed that the studied *A. baumannii* strains, including wild-type strains and clinical isolates of MDRAB, all possessed genes belonging to the OXA-51 group. The recently identified OXA-51 group of  $\beta$ -lactamases comprises a novel cluster among the OXA-type carbapenemases, and the cluster includes many variant oxacillinases that have been reported in several studies, including those by Heriter in 2005<sup>[186]</sup>, Brown in 2005<sup>[191]</sup>, Turton in 2006<sup>[192]</sup>, Vahaboglu in 2006<sup>[193]</sup>, Koh in 2007<sup>[147]</sup>, Evans in 2007<sup>[194]</sup>, Naas in 2007<sup>[122]</sup>, Tsakris in 2007<sup>[195]</sup> and Higgins in 2009<sup>[196]</sup>. The CHDLs that have been found are listed in Table 1.

The OXA-40/OXA-24 CHDL group is made up of OXA-25, OXA-26, OXA-40, and OXA-72 (an original

sequencing error occurred in sequencing OXA-24; it is now known as OXA-40)<sup>[166]</sup>. These enzymes only differ by a few amino acid substitutions. OXA-40/OXA-24 was originally identified as chromosomally encoded in a carbapenem-resistant *A. baumannii* isolate recovered from Spain<sup>[197]</sup>. OXA-25, OXA-26, and OXA-27 were later characterized to be associated with carbapenem resistance in clinical isolates of *A. baumannii* from Spain, Belgium and Singapore<sup>[198]</sup>. Thereafter, the OXA-40/OXA-24 gene in *A. baumannii* was reported in several areas<sup>[199]</sup>, including Spain<sup>[188,200,201]</sup>, Portugal<sup>[202]</sup> and the United States<sup>[203]</sup>. The plasmid-mediated *bla<sub>oxa-24</sub>* gene was noted in the isolates from an outbreak in Spain<sup>[204]</sup>. Additionally, OXA-72 has been identified in *A. baumannii* isolates from Taiwan<sup>[205]</sup>, China<sup>[92]</sup> and Croatia<sup>[206]</sup>.

OXA-58 was first identified from an isolate of MDRAB in France<sup>[207]</sup>. The *bla<sub>oxa-58</sub>* gene was found to be plasmid borne. Many OXA-58-producing *A. baumannii* isolates were reported worldwide in subsequent years, including isolates in Europe<sup>[208-211]</sup>, Argentina<sup>[208]</sup>, Kuwait<sup>[208]</sup>, the United Kingdom<sup>[208]</sup>, Australia<sup>[212]</sup>, Taiwan<sup>[116]</sup>, the United States<sup>[213,214]</sup> and China<sup>[215]</sup>. A number of outbreaks have also been reported in many countries, including Italy<sup>[216]</sup>, Belgium<sup>[79]</sup>, France<sup>[217]</sup>, Turkey<sup>[193]</sup>, Greece<sup>[218,219]</sup>, and the United States<sup>[214]</sup>. OXA58 can lead to high-level carbapenem resistance in *A. baumannii* *via* the upstream IS1008 insertion<sup>[116]</sup> or the presence of the IS*Aba25*-IS*Aba3*-like hybrid promoter<sup>[118]</sup>. OXA-97 is a point mutation variant of OXA-58 that shares the same hydrolytic properties and has been recently identified in *A. baumannii* isolates from Tunisia<sup>[220]</sup>. Another point mutation derivative is OXA-96, which was identified in *A. baumannii* from Singapore<sup>[147]</sup>.

In 2009, a novel CHDL, OXA-143, was identified that shares 88% amino acid identity with OXA-40, 63% identity with OXA-23, and 52% identity with OXA-58<sup>[196]</sup>. Another novel oxacillinase, OXA-182, was identified in imipenem-nonsusceptible *Acinetobacter* isolates in Korea<sup>[221]</sup> and showed 93% identity with OXA-143 and 89% identity with OXA-40 based on amino acid sequence alignment. OXA-235, and the amino acid variants OXA-236 and OXA-237, were identified from *A. baumannii* isolates from the United States and Mexico<sup>[222]</sup>. The deduced amino acid sequences shared an 85% identity with OXA-134, 54 to 57% identities with the acquired OXA-23, OXA-24, OXA-58, and OXA-143, and a 56% identity with the intrinsic OXA-51. Thus, OXA-235, OXA-236 and OXA-237 represent a novel subclass of OXAs. The expression of OXA-235 in *A. baumannii* leads to reduced carbapenem susceptibility, while the cephalosporin minimal inhibition concentrations (MICs) are unaffected.

### Multidrug efflux pumps

While multidrug-resistant efflux pumps have been shown to have roles in bacterial pathogenicity<sup>[223]</sup>, the contribution of efflux pumps to bacterial multidrug resistance is often reported<sup>[224,225]</sup>. Efflux-based mechanisms are responsible for resistance against many different classes of antibiotics, including tigecycline resistance<sup>[226,227]</sup> or imipenem resistance<sup>[190]</sup> in *A. baumannii*. Furthermore, the



linear relationship between the log-transformed expression values of the AdeABC efflux pump genes and the log-transformed MIC values is statistically significant, indicating that overexpression of the AdeABC efflux pump is a prevalent mechanism for decreased susceptibility to tigecycline<sup>[228]</sup>. The importance of efflux pumps in multidrug resistance in *A. baumannii* is supported by the fact that the presence of efflux pump inhibitors, such as 1-(1-naphthylmethyl)-piperazine<sup>[229,230]</sup>, phenyl-arginine- $\beta$ -naphthylamide<sup>[231,232]</sup>, or carbonyl cyanide 3-chlorophenyl-hydrazone<sup>[232]</sup>, can reverse the resistance pattern.

Four categories of efflux pumps, including the resistance-nodulation-division (RND) superfamily, the major facilitator superfamily (MFS), the multidrug and toxic compound extrusion (MATE) family and the small multidrug resistance (SMR) family transporters, have been reported to be related to antimicrobial resistance in *A. baumannii*<sup>[233,234]</sup>. Of these different pumps, the RND and MFS transporters are mentioned most often. AdeABC, a RND-type efflux pump with a three-component structure, is not only associated with aminoglycoside resistance<sup>[235]</sup> but is also associated with decreasing susceptibility to several antimicrobials, including tigecycline<sup>[226]</sup>. Differences in the expression of *adeABC* were shown to contribute to both inter- and intra-clone variation in tigecycline MICs in a study of *A. baumannii* epidemic clones<sup>[236]</sup>. Both the increase in tigecycline resistance during therapy<sup>[236]</sup> and the decrease in susceptibility to non-fluoroquinolone antibiotics during an outbreak<sup>[237]</sup> are mediated by the up-regulation of AdeABC in *A. baumannii*. The AdeABC pump in wild *A. baumannii* is cryptic due to stringent control by the AdeRS two-component system<sup>[238]</sup>. Point mutations in AdeS and AdeR or a truncation of AdeS due to an IS*Aba1* insertion may be related to the overexpression of AdeABC, which leads to multidrug resistance<sup>[238,239]</sup>. However, the existence of tigecycline-nonsusceptible and *adeB*-overexpressing *A. baumannii* clinical isolates without known *adeRS* mutations<sup>[240]</sup> and the low expression of *adeABC* in a clinical strain of *A. baumannii* with the IS*Aba1* insertion in the *adeRS* operon<sup>[239]</sup> suggest that the regulation of *adeABC* gene expression is complex. Additionally, the cell density-dependent expression of *adeB* suggests the presence of global regulatory mechanisms for the expression of this gene in *A. baumannii*<sup>[241]</sup>. BaeSR, which functions as an envelope stress response system to external stimuli, is proposed to influence the transcription of *adeAB* and thus tigecycline susceptibility in *A. baumannii* by functioning as a regulator of global transcription<sup>[242]</sup>.

In addition to the AdeABC efflux pump, the inactivation of other RND-type efflux pumps, including AdeFGH<sup>[243]</sup> and AdeIJK<sup>[232,244,245]</sup>, demonstrates their contribution to multidrug resistance in *A. baumannii*. The AdeABC and AdeIJK efflux systems can contribute synergistically to tigecycline resistance<sup>[244]</sup>. An open reading frame encoding a LysR-type transcriptional regulator, named *adeL*, is located upstream of the *adeFGH* operon and is responsible for the overexpression of AdeFGH<sup>[243]</sup>, whereas the expression of AdeIJK in *Acinetobacter bau-*

*mannii* is regulated by AdeN, a TetR-Type regulator<sup>[246]</sup>. Although the RND efflux pump AdeDE was initially identified in *Acinetobacter* genomic group 3<sup>[247]</sup>, *adeE* was later found to coexist with *adeB* in some clinical isolates of *A. baumannii*<sup>[245]</sup>.

A number of MFS efflux pumps, including TetA<sup>[248]</sup>, CmlA<sup>[225]</sup>, MdfA<sup>[233]</sup>, CraA<sup>[249]</sup> and AmvA<sup>[250]</sup>, that mediate resistance to different types of antibiotics in *A. baumannii* have been characterized. AbeM, a H-coupled pump that belongs to the MATE family<sup>[251]</sup>, was reported to be present in the clinical isolates of *A. baumannii* in several studies<sup>[77,232,245]</sup> and to confer resistance to fluoroquinolones or imipenem in *A. baumannii*. *A. baumannii* with a mutant AbeS SMR pump exhibits erythromycin and chloramphenicol resistance<sup>[252]</sup>.

### Aminoglycoside-modifying enzymes

Aminoglycoside-modifying enzymes (AMEs) are the principal mode of resistance to aminoglycosides. This resistance is primarily mediated by three classes of enzymes, including acetyltransferases, adenylyltransferases and phosphotransferases, that typically reside on transposable elements; these enzymes chemically modify aminoglycosides<sup>[253]</sup>. The coding genes for these enzymes can be transferred among different bacterial types through plasmids, transposons, integrons, and natural transformation or transduction<sup>[254]</sup>. A phenotypic analysis of aminoglycoside resistance profiles indicated that many isolates could produce a combination of aminoglycoside-modifying enzymes<sup>[255,256]</sup>. The co-carrying of four AME genes, including a novel AME gene *aac(6')-Ib*, was reported in a PDRAB strain from China<sup>[257]</sup>. The identification of MDRAB isolates harboring genes for the *bla*<sub>OXA-23</sub>-like genes, AME (*aac(6')-Ib*) and the 16S rRNA methylase (*armA*) implicates AMEs in multidrug resistance<sup>[258]</sup>.

Different types of AMEs have been reported in *A. baumannii*. Amikacin resistance has been reported to be associated with a gene encoding APH(3')-VI phosphotransferase<sup>[255]</sup>. Furthermore, AME *aac(6')-Iad* plays an important role in amikacin resistance in *Acinetobacter spp.* in Japan<sup>[259]</sup>. Of the 106 MDRAB isolates identified in one study, 95% possessed at least one type of AME, including *aacA4*, *aacC1*, *aacC2*, *aadB*, *aadA1*, *aphA1* and *aphA6*<sup>[256]</sup>. In another study in Greece, all of the collected *A. baumannii* strains contained AMEs, which were either *aac(6')-Ib* or *aac(6')-Ib*<sup>[260]</sup>. Class I integrons containing the gene cassettes *aacA4-catB8-aadA1*, *dhfrXII-orfF-aadA2*, or *aacC1-orfP-orfP-orfQ-aadA1* have been proposed to be associated with the horizontal transfer of diversified aminoglycoside-resistant genes among clinical isolates of *A. baumannii*<sup>[17,256,261]</sup>.

### Permeability defects

Porins, which perform multiple functions in membranes, are proteins that can form channels to allow the transport of molecules across lipid bilayer membranes<sup>[233]</sup>. These outer membrane proteins not only influence the virulence of *A. baumannii*, e.g., through Omp38-induced epithelial cell apoptosis<sup>[59]</sup>, biofilm formation related to OmpA<sup>[262]</sup>,



OmpA-dependent host cell death<sup>[263]</sup>, and attenuated virulence by the decreased expression of genes encoding CarO- and OprD-like proteins<sup>[263]</sup>, but also play a significant role in the mechanisms of resistance. For example, the loss of a 29 kDa outer-membrane protein, which was later shown to be CarO, contributes to imipenem resistance<sup>[263-267]</sup>. Several other studies have also identified a number of OMPs involved in the carbapenem resistance of *A. baumannii*. A reduction in the expression of two porins of 22 and 33 kDa was involved in the carbapenem resistance of *A. baumannii* strains in an outbreak in Spain<sup>[268]</sup>. In one study, CRAB isolates found in New York had reduced expression of the 47-, 44-, and 37-kDa outer-membrane proteins<sup>[91]</sup>, while in other studies, a 33- to 36-kDa OMP was also shown to be associated with carbapenem resistance in *A. baumannii*<sup>[269,270]</sup>. A 43-kDa OMP, belonging to the OprD family, has been identified as a basic amino acid and imipenem porin through electrophoresis and MALDI-MS analyses<sup>[271]</sup>.

In the presence of OXA carbapenemases, including OXA-51-like or OXA-23-like enzymes, the loss of the 29-kDa outer-membrane protein is associated with a higher imipenem MIC in *A. baumannii*<sup>[272,273]</sup>. Moreover, a novel insertion sequence, IS*Aba10*, inserted into IS*Aba1* adjacent to the *bla*<sub>OXA-23</sub> gene, can disrupt the outer-membrane protein gene *carO* in *A. baumannii*<sup>[180]</sup>. The loss of lipopolysaccharide (LPS) from the outer membrane, resulting in a decrease in membrane integrity, occurred in a colistin-resistant clinical isolate of *A. baumannii* in Australia<sup>[64]</sup>. Disruption of the *ompA* gene can lead to decreases in the MICs of chloramphenicol, aztreonam, and nalidixic acid<sup>[274]</sup>.

### Alteration of target sites

Changes in penicillin-binding proteins (PBPs), mutations of DNA gyrase, ribosomal protection by the TetM protein and the involvement of dihydrofolate reductase in trimethoprim resistance all occur *via* mechanisms that alter the target sites for antibiotics<sup>[275]</sup>. Imipenem resistance has been associated with the overexpression of certain PBPs with a low affinity for imipenem in the absence of other known resistance mechanisms<sup>[276]</sup>. While an insertion sequence disrupting the gene encoding PBP6b has been identified in an endemic carbapenem-resistant clone, its role must be further evaluated<sup>[277]</sup>. Furthermore, mutations in DNA gyrase gene *gyrA* and *parC*, which encode topoisomerase IV, have been reported in an *A. baumannii* outbreak investigation<sup>[237]</sup>. The *gyrA* mutation at Ser-83 was shown to be associated with quinolone resistance in epidemiologically unrelated isolates of *A. baumannii*<sup>[278]</sup>. While *tetA* and *tetB* genes are well recognized for their role in tetracycline resistance in *A. baumannii* through efflux pumps<sup>[225,279]</sup>, *tetM* is proposed to be another resistance mechanism that acts through ribosomal protection<sup>[280]</sup>. Trimethoprim resistance through dihydrofolate reductase in *A. baumannii* is similar to that of other bacteria. Plasmids containing *folA* genes and integrons harboring *dhfr* or *dhfr* genes in *A. baumannii* have been found<sup>[117,279,281]</sup>. Recently, the coexistence of the 16S rRNA

methylase *armA* gene and genes encoding OXA carbapenemases were reported in many countries, including China<sup>[282]</sup>, South Korea<sup>[253,283]</sup>, India<sup>[284]</sup>, Italy<sup>[285]</sup>, Japan<sup>[286]</sup>, and Yemen<sup>[258]</sup>, indicating the contribution of the *armA* gene to the multidrug resistance of MDRAB.

### Roles of integrons

The horizontal transfer of resistance genes is a successful mechanism for the transmission and dissemination of multiple drug resistance determinants among bacterial pathogens<sup>[287]</sup>. Integrons, which are located on either bacterial chromosomes or plasmids, are assembly platforms that incorporate exogenous ORFs by site-specific recombination and convert them to functional genes by ensuring their correct expression<sup>[288]</sup>. Integrons share common features: a gene encoding an integrase, a specific recombination site that is recognized by the integrase and into which the cassettes are inserted, and a promoter that directs the transcription of the cassette-encoded genes. Currently, there are four classes of integrons, and class 1 integrons are the most common in bacteria<sup>[289]</sup>.

The role of integrons in the development of multidrug resistance relies on their unique capacity to cluster and express drug resistance genes<sup>[287]</sup>. Many studies regarding integrons harboring different types of resistance genes have been reported worldwide in recent decades. Class I integrons were detected in 52.8% of *A. baumannii* strains in the Nanjing area of China in 2007<sup>[290]</sup>, whereas an epidemic, class 1 integron-carrying MDRAB clone was found to be widespread in Taiwan in the same year<sup>[291]</sup>. Four different integron structures were detected in 84% of all collected isolates of *A. baumannii* in a Spanish study<sup>[255]</sup>. However, while no clear antibiogram differences could be associated with the presence or absence of integron structures in the Spanish study, other reports have suggested that integrons play a major role in multidrug resistance in *A. baumannii*<sup>[261,291,292]</sup>. Additionally, epidemic strains of *A. baumannii* have been found to contain significantly more integrons than non-epidemic strains<sup>[293]</sup>. Therefore, integrons are regarded as useful markers for epidemic strains of *A. baumannii*, and their typing can provide valuable information for epidemiological studies<sup>[294,295]</sup>.

A study performed in Italy found that 44% of the epidemiologically unrelated *A. baumannii* isolates collected over an 11-year period were integron-positive<sup>[296]</sup>. Most integron-positive strains carried the same array of cassettes, despite their notable genetic diversity that was identified through a ribotyping analysis, implying that horizontal transfer of the entire integron structure or an ancient acquisition occurred. Additionally, while the same integron can be present in unrelated strains<sup>[17]</sup>, related strains can also have different integrons<sup>[297]</sup>.

Although different relationships exist among different classes of antibiotics and integrons<sup>[298,299]</sup>, most studies have emphasized the association of integrons with cassette genes and aminoglycoside resistance<sup>[261]</sup>. The diversity of the genes encoding AMEs and their association with class 1 integrons was observed in a study involving

three pan-European clones of *A. baumannii*<sup>[256]</sup>. Six different class 1 integron variable regions were detected in 74% of the collected strains. Furthermore, Huang *et al*<sup>[291]</sup> collected 283 MDRAB isolates from three medical centers in Taiwan from 1996 to 2004 and found seven types of gene cassettes, most of which contained AMEs, including *aacA4*, *aacC1*, *aac(6)-II*, *aadA1*, *aadA2*, *aadA4* and *aadDA1*.

Variable CHDL genes, including *bla<sub>OXA-3</sub>*<sup>[292]</sup>, *bla<sub>OXA-10</sub>*<sup>[96,290]</sup>, *bla<sub>OXA-20</sub>*<sup>[19,292,296]</sup>, *bla<sub>OXA-21</sub>*<sup>[297]</sup>, and *bla<sub>OXA-37</sub>*, have been reported in integrons<sup>[164,297]</sup>. Integron-associated imipenem resistance in *A. baumannii* has also been documented<sup>[300]</sup>. Genes encoding carbapenemases, such as MBLs *bla<sub>VIM</sub>*, *bla<sub>IMP</sub>* and *bla<sub>SIM</sub>*, have been found in integrons. *bla<sub>VIM-1</sub>*-carrying integrons<sup>[140]</sup> and *bla<sub>VIM-2</sub>*-carrying integrons<sup>[139]</sup> have been noted in Greece and Korea, respectively. In Taiwan, integron-mediated gene spreading has been demonstrated hospitals<sup>[301]</sup>, especially in a unit with high antibiotic selective pressure<sup>[302]</sup>. *bla<sub>VIM-11</sub>*-carrying integrons have also been identified in MDRAB isolates, and this MBL gene has been postulated to spread among *Pseudomonas aeruginosa* and *A. baumannii* strains<sup>[143,291]</sup>. Other reported MBLs include *bla<sub>IMP-1</sub>*<sup>[303]</sup>, *bla<sub>IMP-2</sub>*<sup>[145]</sup>, *bla<sub>IMP-4</sub>*<sup>[146,147]</sup>, *bla<sub>IMP-5</sub>*<sup>[148]</sup>, *bla<sub>IMP-8</sub>*<sup>[291]</sup> and *bla<sub>SIM-1</sub>*<sup>[151]</sup>. The genes for chloramphenicol resistance in the integrons of *A. baumannii* are *catB2*<sup>[135]</sup>, *catB3*<sup>[146,147,151]</sup> and *catB8*<sup>[294,304]</sup>.

## CLINICAL IMPACT OF ANTIMICROBIAL RESISTANCE

The clinical impact of *A. baumannii* infections has been a matter of debate<sup>[2]</sup>. A high mortality rate in immunocompromised hosts with *A. baumannii* infections had been attributed to the patients' underlying diseases rather than to the infections. One Spanish study concluded that there were no differences in mortality among patients with ventilator-associated pneumonia (VAP) caused by imipenem-resistant or imipenem-susceptible *A. baumannii* or by other pathogens<sup>[305]</sup>. However, other related studies suggest that *A. baumannii* infection itself has a profound influence on high mortality or prolonged length of stay (LOS)<sup>[306]</sup>. Falagas suggested that the mortality attributed to *A. baumannii* infections should no longer be a controversial issue<sup>[307]</sup> based on six relevant case-control studies<sup>[308-313]</sup>.

Several previous surveillance<sup>[314-317]</sup> studies have demonstrated that increasing antimicrobial resistance, especially multidrug resistance, has become a major issue in *A. baumannii* strains in recent years. Whether multidrug resistance is a risk factor for high mortality in *A. baumannii* infections has been a controversial issue. A few studies suggested that MDRAB-related pneumonia or bacteremia is a signal of disease severity and is not related to prolonged LOS or increased mortality<sup>[318,319]</sup>, but more recent studies have shown that MDRAB infections lead to higher mortality. The acquisition of MDRAB was shown to be an independent risk factor for mortality in a burn center in Singapore<sup>[320]</sup>. A multicenter retrospective study in Taiwan

also showed that patients with CRAB infections have a higher mortality rate than those with carbapenem-susceptible *A. baumannii* infections<sup>[321]</sup>, which is consistent with the results of several previous studies<sup>[309-311,313,322]</sup>. The high impact of imipenem resistance on the mortality rate of patients with *Acinetobacter* bacteremia is chiefly attributable to discordant antimicrobial therapy<sup>[311]</sup>. Moreover, patients with MDRAB infections have increased hospital and ICU LOS compared to patients with susceptible *A. baumannii* infections and uninfected patients<sup>[308]</sup>. A mini review of this issue indicated that blood stream infections and nosocomial ICU infections caused by carbapenem-resistant *Acinetobacter* spp. are associated with increased rates of mortality, whereas other types of infections have not clearly been shown to be associated with higher mortality rates but are associated with increased LOSs and hospital costs<sup>[323]</sup>.

## STRATEGIES TO COMBAT THE DISSEMINATION OF ANTIMICROBIAL RESISTANCE

The development of new antibiotics against MDRAB and the implementation of infection control measures are regarded as two methods to aid in controlling the increasing problem of *A. baumannii* infections<sup>[307]</sup>. When GlaxoSmithKline shared the challenges and difficulties in screening for new classes of antimicrobial agents over a 7-year period, the authors concluded that the pipeline of novel-mechanism antibacterials is still empty and will remain so for a considerable period<sup>[324]</sup>. Therefore, the importance of following the Association of Professionals in Infection Control and Epidemiology's (APIC) 2010 guide to the elimination of MDRAB transmission in health care settings cannot be overemphasized<sup>[325]</sup>. This guide includes MDRAB risk assessment and infection surveillance, strict adherence to hand hygiene protocols, implementation of standard and transmission-based precautions, environmental decontamination, outbreak recognition and control, and antibiotic stewardship.

Gastrointestinal or skin colonization of *A. baumannii* develops soon after the pathogen is first isolated from a clinical site<sup>[326]</sup>. The finding of multidrug-resistant colonized strains compared with susceptible clinical strains without apparent relation to antibiotic use implies that a new onset of MDRAB colonization may not be identified without surveillance. Additionally, the increasing occurrence of multidrug-resistant strains among seriously ill patients emphasizes the importance of continued surveillance as a critical component of any program aimed at preventing and controlling antimicrobial resistance<sup>[315]</sup>. Environmental contamination, airborne transmission, patient transfer, and cross-contamination are regarded as key factors in causing *A. baumannii* epidemics<sup>[327]</sup>, and clonal expansion has been shown to play a major role in the increase of MDRAB in hospitals<sup>[328]</sup>. Therefore, barrier infection control measures are necessary to prevent the nosocomial spread of MDRAB<sup>[326]</sup>. One outbreak

**Table 2** Antimicrobial treatment for MDRAB infections

Regimen	Pathogen	Diseases	Outcome <sup>1</sup>	Comparator	Ref.
CST + RIF	XDRAB	HAP VAP BSI cIAI	The same in CR (mortality) Better in MR	CST	[367]
CST + RIF	CRAB	VAP	The same in CR + MR	CST	[366]
CST + IPM	XDRAB	BSI	Better in CR (mortality) + MR	CST	[369]
CST + SAM					
CST + others					
CST + SUL	MDRAB	VAP	The same in CR + MR	CST	[341]
TGC based	MDRAB	Pneumonia	Higher mortality	CST based	[349]
TGC based	MDRAB	HAIs	The same in mortality <sup>2</sup> Better in MR	IPM + SAM	[352]
CT	MDRAB	Infections	The same in mortality	MT	[374]

<sup>1</sup>"The same" means no significant difference between comparator groups, and "Better" means a significant difference exists between comparator groups;

<sup>2</sup>Has a statistically significant favorable outcome. MDRAB: Multidrug-resistant *A. baumannii*; CST: Colistin; IPM: Imipenem; RIF: Rifampicin; SUL: Sulbactam; SAM: Ampicillin/sulbactam; TGC: Tigecycline; HAP: Hospital-associated pneumonia; VAP: Ventilator-associated pneumonia; BSI: Blood stream infection; cIAI: Complicated intra-abdominal infection; HAIs: Healthcare-associated infections; CR: Clinical response; MR: Microbiological response; CT: Combination therapy; MT: Monotherapy.

reported in an ICU in a Greek hospital ceased after the implementation of hygienic measures, complete cleaning and complete disinfection in the ICU<sup>[329]</sup>. However, cross-infection with *A. baumannii* among patients still occurred, despite the implementation of stringent infection control measures, in a previously reported outbreak; thus, temporary closure of the surgical ward for disinfection was necessary to control the outbreak<sup>[330]</sup>.

Environmental contamination plays an important role in the transmission of MDRAB. One outbreak investigation found that the affected patients had a higher risk of harboring *A. baumannii* after blood transfusion, hydrotherapy or extended use of a respirator, which was possible through the contamination of healthcare personnel and the environment. Another *A. baumannii* outbreak investigation in a surgical ICU at a teaching hospital in Taiwan showed extensive amounts of environmental contamination, including the contamination of bed rails, bedside tables, sinks, ventilator and infusion pump surfaces, and water for nasogastric feeding and ventilator rinsing. Hence, intensified infection prevention control (IPC) measures are needed to terminate an outbreak. The IPC measures include: (1) implementation of enhanced contact isolation precautions; (2) active surveillance cultures; (3) daily environmental cleaning with detergents and phenolic agents; (4) an up-to-date education program for all healthcare workers; and (5) delivery of real-time feedback to healthcare workers regarding IPC compliance<sup>[331]</sup>, which has minimized the spread of colistin-resistant *A. baumannii*. Furthermore, the infection control bundle resulted in a significant reduction in the incidence of nosocomial *A. baumannii* in one burn unit and prevented further outbreaks of this organism, with an 88.8% decrease during the intervention period<sup>[332]</sup>.

Imipenem has been proven to be a strong inducer of multidrug resistance in *A. baumannii*<sup>[333]</sup>. Many *A. baumannii* isolates exhibit imipenem resistance, which is strongly associated with the prior use of carbapenems<sup>[334]</sup>. Because of the high mortality rate associated with *A. bauman-*

*nii* infection, strategies to slow down the emergence of MDRAB in clinical practice by optimizing antimicrobial therapy are necessary. Therefore, antimicrobial stewardship is mandatory in an infection prevention program to prevent the emergence and transmission of MDRAB in health care facilities<sup>[325]</sup>.

## ANTIMICROBIAL THERAPY

Carbapenems, including imipenem or meropenem, have been regarded as effective antimicrobial agents to treat *A. baumannii* infections<sup>[314,335]</sup>. With many studies reporting increasingly high rates of CRAB in clinical isolates<sup>[75,76,90]</sup>, other classes of antibiotics or combination therapies are urgently needed. Because the choices of antimicrobial treatment for MDRAB are severely limited by resistance, there are only a few effective options available, including polymyxins and tigecyclines<sup>[336]</sup>. Furthermore, the appearance of PDRAB, which is resistant to all available antibiotics, including polymyxin, implies that more efforts should be devoted to investigating the treatment options for this superbug<sup>[27]</sup>. Combination therapies with imipenem/sulbactam, colistin/rifampicin, colistin/sulbactam, colistin/tigecycline, colistin/imipenem or meropenem and colistin/teicoplanin have been studied and proposed as possible choices. The recently published reports on the treatment of MDRAB are summarized in Table 2.

### Sulbactam

While ampicillin/sulbactam has been shown to be effective in treating blood stream infections caused by MDRAB<sup>[337]</sup>, a later meta-analysis revealed that sulbactam-based therapy is not superior to other therapeutic approaches, including colistin, cephalosporins, antipseudomonas penicillins, fluoroquinolones, minocycline/doxycycline, aminoglycosides, tigecycline, polymyxin, imipenem/cilastatin, and combination therapies<sup>[338]</sup>. Although sulbactam-based therapy failed to prove its superiority to other regimens for the treatment of *A. baumannii* in-



fections, a case of skin and soft tissue infection caused by CRAB that was treated successfully with ampicillin/sulbactam and meropenem combination<sup>[339]</sup> raises the possibility of ampicillin/sulbactam as a component of combination therapy against CRAB. The combination of ampicillin/sulbactam with a carbapenem for treating MDRAB bacteremia has been shown to be associated with a better outcome<sup>[340]</sup>, but such beneficial effects were not observed for MDRAB VAP<sup>[341]</sup>.

### Tigecycline-based therapy

In 2004, tigecycline was reported to have a good *in vitro* bacteriostatic effect against *A. baumannii*, including strains resistant to imipenem<sup>[342]</sup>. Another *in vitro* study using a time-kill assay demonstrated the potential role of tigecycline in the treatment of *A. baumannii* and proposed that doxycycline could be a suitable and cost-effective option in some instances<sup>[343]</sup>. Tigecycline efficacy was shown to correlate well with the free concentration-time curve of MIC in a murine *Acinetobacter* spp. model<sup>[344]</sup>. Additionally, several cases affiliated with severe infections by MDRAB were successfully treated with tigecycline in terms of their clinical and microbiological outcomes<sup>[345]</sup>.

With its increasing use, the limitations and adverse aspects of tigecycline in treating MDRAB infections have begun to be realized. Tigecycline was less effective than imipenem in the treatment of pneumonia caused by non-IRAB strains in a murine pneumonia model<sup>[346]</sup>. In a study consisting of 34 patients with MDRAB infections, the mortality rate reached up to 41%. The authors found that the correlation of clinical and microbiological outcomes was poor and concluded that tigecycline had excellent *in vitro* activity against MDRAB, but its clinical efficacy was still uncertain<sup>[346]</sup>. One of the possible causes for the discrepancy of treatment outcomes may be variable tigecycline MICs. MIC determination for tigecycline before treatment, with the broth dilution method being favored<sup>[347]</sup>, might increase clinical success<sup>[345]</sup>. *A. baumannii* isolates with tigecycline MICs of  $\geq 2$  mg/L were associated with higher mortality rates; thus, treatment with  $\beta$ -lactams or carbapenems instead of with tigecycline is preferred<sup>[348]</sup>. This notion was further supported in a matched cohort study in Taiwan that dealt with the effectiveness of tigecycline-based versus colistin-based therapy for the treatment of pneumonia caused by MDRAB<sup>[349]</sup>. The excess mortality rate of 16.7% in the tigecycline-based group compared with the colistin-based group was mostly attributed to subjects with MIC  $> 2$   $\mu$ g/mL.

In a meta-analysis of the efficacy and safety of tigecycline, clinical failure, superinfection and adverse events were more frequent with the use of tigecycline<sup>[350]</sup>. The authors suggested that physicians should avoid tigecycline monotherapy for the treatment of severe infections caused by MDRAB and that they should use it as a last-resort antibiotic. There was no antagonism found when tigecycline was used with other antimicrobials possessing activities against Gram-negative bacteria<sup>[351]</sup>. However, tigecycline-based therapy for MDRAB infections is not satisfactory. In a study of 266 patients with healthcare-

associated MDRAB infections, the mortality rate was not significantly different between those receiving tigecycline-based therapy and those receiving non-tigecycline therapy<sup>[352]</sup>.

While tigecycline has an expanded spectrum of antibacterial activity and a synergic effect with some classes of antibiotics, such as amikacin<sup>[353]</sup>, earlier studies have shown that tigecycline resistance in *A. baumannii* has emerged<sup>[354]</sup> and is associated with multidrug efflux systems, especially overexpression of the *adeABC* pump<sup>[226,227]</sup>. The increased expression of the *adeABC* operon can be found in clinical isolates of *A. baumannii* post-tigecycline therapy<sup>[236,355]</sup>. High resistance rates and high MICs of tigecycline in multiple clones of MDRAB were noted in a medical center in Israel<sup>[356]</sup>. This phenomenon led to concern regarding the use of tigecycline as one of the few treatment choices for infections caused by MDRAB.

### Colistin-based therapy

Colistin has been described as a last resort for the treatment of MDRAB<sup>[357]</sup>, and this drug is often used in combination therapy. In a report on the clonal spread of MDRAB in eastern Taiwan, antibiotic susceptibility testing showed that 10.4%, 47.8% and 45.5% of MDRAB isolates were resistant to colistin, rifampicin, and tigecycline, respectively, implying that colistin was the only effective antimicrobial agent in that area for treating MDRAB<sup>[358]</sup>. In addition to its intravenous injection for MDRAB infections, colistin can be given *via* intraventricular and intrathecal routes for meningitis<sup>[359]</sup> and *via* nebulization for pneumonia<sup>[360,361]</sup>.

Unfortunately, colistin-resistant *A. baumannii* strains have been reported all over the world<sup>[357]</sup> and are attributed to the loss of lipopolysaccharide<sup>[64]</sup> or/and phosphoethanolamine modification of lipid A mediated by the PmrAB two-component system<sup>[362,363]</sup>. Because colistin monotherapy is unable to curb the appearance of resistance, colistin-based combination therapy might be the optimal antimicrobial strategy. Colistin combined with different classes of antibiotics, including tigecycline, cefoperazone/sulbactam or piperacillin/tazobactam, revealed synergistic effects in some CRAB strains<sup>[364]</sup>. Time-kill assays have also shown that colistin/meropenem, colistin/rifampicin, and colistin/minocycline are synergistic *in vitro* against XDRAB strains<sup>[365]</sup>. The beneficial effects of colistin and rifampicin combination for patients with VAP caused by CRAB have been documented in terms of clinical and microbiological outcomes<sup>[366]</sup>. However, another multi-center, randomized clinical trial concluded that 30-d mortality was not reduced by the addition of rifampicin to colistin in serious XDRAB infections<sup>[367]</sup>. Additionally, such a regimen might be hindered by a high level of rifampicin resistance in *A. baumannii*<sup>[368]</sup>. Treatment with combination therapy, including colistin/carbapenem and colistin/sulbactam, for XDRAB blood stream infections led to higher microbiological eradication and lower mortality rates in comparison with the colistin monotherapy group<sup>[369]</sup>. The combination therapy



of colistin and tigecycline has also been proposed as a reasonable treatment of choice for XDRAB pneumonia, especially in the first 48 h, in a rat lung model<sup>[370]</sup>. Interestingly, a significant synergy has been observed for the combination of colistin and teicoplanin against MDRAB *in vitro*<sup>[371]</sup>. Telavancin, a similar lipoglycopeptide of teicoplanin, has been shown to be efficacious *in vivo* when used in colistin combination therapy in a *Galleria mellonella* model of *A. baumannii* infection<sup>[372]</sup>.

### Other antimicrobial therapies

Doripenem, a novel broad-spectrum carbapenem, has displayed *in vitro* synergistic activity with tigecycline, colistin and amikacin against MDRAB strains with doripenem resistance<sup>[373]</sup>. One recent prospective, observational Spanish study did not support an association of combination therapy with reduced mortality in MDRAB infections<sup>[374]</sup>. Overall, the choice of combination therapy should take several key factors into consideration, including the antimicrobial resistance phenotype, resistance mechanisms, and MIC<sup>[375]</sup>.

## FUTURE PERSPECTIVES

One of the difficulties encountered in understanding the antimicrobial resistance mechanisms of *A. baumannii* lies in the complexity of the involved genes. A DNA microarray, the Check-MDR CT102 microarray, has proven useful in detecting TEM, SHV and CTX-M extended-spectrum  $\beta$ -lactamases and KPC, OXA-48, VIM, IMP, and NDM-1 carbapenemases in some *Enterobacteriaceae* and glucose non-fermentative bacteria, including *A. baumannii*, with 100% sensitivity and specificity for most of the tested genes<sup>[376]</sup>. The detection of plasmid-mediated cephalosporinases, including CMY-2-like, DHA, FOX, ACC-1, ACT/MIR and CMY-1-like/MOX, was also possible using this assay, suggesting that this DNA array is a powerful high-throughput tool for most common resistance gene identifications and provides a platform for epidemiological or infection-control studies<sup>[377]</sup>.

Bacteria develop resistance to new classes of antibiotics very quickly, and bacteria may even be resistant to new classes of antibiotics before they are introduced to clinical use<sup>[378]</sup>. Hence, antimicrobial peptides (AMPs) may be another option due to the rare appearance of resistance to AMPs in addition to their antimicrobial and anti-inflammatory effects<sup>[379]</sup>. AMPs are an important component of host defenses against invading pathogens<sup>[380]</sup>. They are small, cationic and amphipathic peptides of variable length, sequence and structure. Thus far, more than 750 different AMPs have been identified in various organisms ranging from plants to animals, including humans, most of which exhibit broad-spectrum activity against a wide range of microorganisms by disrupting the plasma membrane and causing cell lysis. Three classes of AMPs, including defensins, cathelicidins, and histatins, have been found in humans<sup>[379]</sup>. The cathelicidin family is currently limited to a single gene, CAMP. LL-37, which begins with

two leucine residues and consists of 37 amino acids, was the first mature peptide isolated from CAMP gene products<sup>[381]</sup>.

While only a few studies regarding the use of AMPs in *A. baumannii* have been reported, AMPs might be a potential therapeutic alternative to antibiotics. This hypothesis is supported by the conclusion reached from a study of an LPS-deficient, colistin-resistant *A. baumannii* strain, which showed reduced viability even at a low concentration of LL-37<sup>[382]</sup>. The human antimicrobial peptide LL-37 and its fragments KS-30 and KR-20 have been shown to have significant antimicrobial activity against clinical isolates of MDRAB, of which the KS-30 fragment exhibits the highest bactericidal ability<sup>[383]</sup>. Moreover, the prevention of biofilm formation *in vitro* by LL-37, KS-30 and KR-20 adds significance to their efficacy. We predict that AMPs, specifically LL-37, will be promising targets in future research on therapeutics against MDRAB infections.

Because marketing a new antimicrobial is extremely difficult and because bacteria quickly adapt to so-called magic bullets, understanding the interplay between a pathogen such as *A. baumannii* and its hosts may provide another possible solution in the war against bacteria. The microbes that exist in the human body are collectively known as the human microbiota, and this remarkably complex and poorly understood group of communities has an enormous impact on humans<sup>[384]</sup>. The Human Microbiome Project, funded by the National Institutes of Health, aims to develop tools and databases for the research community to study the role of these microbes in human health and disease. One of the tasks the NIH has set itself is to develop a catalog of the microbial genome sequences of reference strains<sup>[385]</sup>. For example, the microbiome diversity in the bronchial tracts of patients with chronic obstructive pulmonary disease has been documented<sup>[386]</sup>. More advances in understanding the pathogenesis of *A. baumannii* using the databases of the Human Microbiome Project can be anticipated.

In conclusion, we hope that this review will aid in understanding the relevant studies regarding the antimicrobial resistance of *A. baumannii* as well as the currently available treatment options for the infections that this pathogen cause, thereby leading to new strategies to combat *A. baumannii*.

## REFERENCES

- 1 Van Looveren M, Goossens H. Antimicrobial resistance of *Acinetobacter* spp. in Europe. *Clin Microbiol Infect* 2004; **10**: 684-704 [PMID: 15301671 DOI: 10.1111/j.1469-0691.2004.00942.x]
- 2 Visca P, Seifert H, Towner KJ. *Acinetobacter* infection--an emerging threat to human health. *IUBMB Life* 2011; **63**: 1048-1054 [PMID: 22006724 DOI: 10.1002/iub.534]
- 3 Gerner-Smidt P, Tjernberg I, Ursing J. Reliability of phenotypic tests for identification of *Acinetobacter* species. *J Clin Microbiol* 1991; **29**: 277-282 [PMID: 2007635]
- 4 Bergogne-Bérézin E, Towner KJ. *Acinetobacter* spp. as nosocomial pathogens: microbiological, clinical, and epidemiological features. *Clin Microbiol Rev* 1996; **9**: 148-165 [PMID: 8964033]

- 5 **Dijkshoorn L**, Aucken H, Gerner-Smidt P, Janssen P, Kaufmann ME, Garaizar J, Ursing J, Pitt TL. Comparison of outbreak and nonoutbreak *Acinetobacter baumannii* strains by genotypic and phenotypic methods. *J Clin Microbiol* 1996; **34**: 1519-1525 [PMID: 8735109]
- 6 **Houang ET**, Chu YW, Chu KY, Ng KC, Leung CM, Cheng AF. Significance of genomic DNA group delineation in comparative studies of antimicrobial susceptibility of *Acinetobacter* spp. *Antimicrob Agents Chemother* 2003; **47**: 1472-1475 [PMID: 12654697 DOI: 10.1128/aac.47.4.1472-1475.2003]
- 7 **Lee JH**, Choi CH, Kang HY, Lee JY, Kim J, Lee YC, Seol SY, Cho DT, Kim KW, Song do Y, Lee JC. Differences in phenotypic and genotypic traits against antimicrobial agents between *Acinetobacter baumannii* and *Acinetobacter* genomic species 13TU. *J Antimicrob Chemother* 2007; **59**: 633-639 [PMID: 17339277 DOI: 10.1093/jac/dkm007]
- 8 **Koелеman JG**, Stoof J, Biesmans DJ, Savelkoul PH, Vandenbroucke-Grauls CM. Comparison of amplified ribosomal DNA restriction analysis, random amplified polymorphic DNA analysis, and amplified fragment length polymorphism fingerprinting for identification of *Acinetobacter* genomic species and typing of *Acinetobacter baumannii*. *J Clin Microbiol* 1998; **36**: 2522-2529 [PMID: 9705386]
- 9 **Chang HC**, Wei YF, Dijkshoorn L, Vaneechoutte M, Tang CT, Chang TC. Species-level identification of isolates of the *Acinetobacter calcoaceticus*-*Acinetobacter baumannii* complex by sequence analysis of the 16S-23S rRNA gene spacer region. *J Clin Microbiol* 2005; **43**: 1632-1639 [PMID: 15814977 DOI: 10.1128/JCM.43.4.1632-1639.2005]
- 10 **La Scola B**, Gundi VA, Khamis A, Raoult D. Sequencing of the *rpoB* gene and flanking spacers for molecular identification of *Acinetobacter* species. *J Clin Microbiol* 2006; **44**: 827-832 [PMID: 16517861 DOI: 10.1128/JCM.44.3.827-832.2006]
- 11 **Bou G**, Cerveró G, Domínguez MA, Quereda C, Martínez-Beltrán J. PCR-based DNA fingerprinting (REP-PCR, AP-PCR) and pulsed-field gel electrophoresis characterization of a nosocomial outbreak caused by imipenem- and meropenem-resistant *Acinetobacter baumannii*. *Clin Microbiol Infect* 2000; **6**: 635-643 [PMID: 11284921]
- 12 **Misbah S**, AbuBakar S, Hassan H, Hanifah YA, Yusof MY. Antibiotic susceptibility and REP-PCR fingerprints of *Acinetobacter* spp. isolated from a hospital ten years apart. *J Hosp Infect* 2004; **58**: 254-261 [PMID: 15564001 DOI: 10.1016/j.jhin.2004.07.007]
- 13 **Huys G**, Cnockaert M, Nemec A, Dijkshoorn L, Brisse S, Vaneechoutte M, Swings J. Repetitive-DNA-element PCR fingerprinting and antibiotic resistance of pan-European multi-resistant *Acinetobacter baumannii* clone III strains. *J Med Microbiol* 2005; **54**: 851-856 [PMID: 16091436 DOI: 10.1099/jmm.0.45986-0]
- 14 **Higgins PG**, Hujer AM, Hujer KM, Bonomo RA, Seifert H. Interlaboratory reproducibility of DiversiLab rep-PCR typing and clustering of *Acinetobacter baumannii* isolates. *J Med Microbiol* 2012; **61**: 137-141 [PMID: 21903821 DOI: 10.1099/jmm.0.036046-0]
- 15 **Saeed S**, Fakih MG, Riederer K, Shah AR, Khatib R. Inter-institutional and intrainstitutional transmission of a strain of *Acinetobacter baumannii* detected by molecular analysis: comparison of pulsed-field gel electrophoresis and repetitive sequence-based polymerase chain reaction. *Infect Control Hosp Epidemiol* 2006; **27**: 981-983 [PMID: 16941328 DOI: 10.1086/507286]
- 16 **Higgins PG**, Janssen K, Fresen MM, Wisplinghoff H, Seifert H. Molecular epidemiology of *Acinetobacter baumannii* bloodstream isolates obtained in the United States from 1995 to 2004 using rep-PCR and multilocus sequence typing. *J Clin Microbiol* 2012; **50**: 3493-3500 [PMID: 22895032 DOI: 10.1128/JCM.01759-12]
- 17 **Lin MF**, Liou ML, Tu CC, Yeh HW, Lan CY. Molecular epidemiology of integron-associated antimicrobial gene cassettes in the clinical isolates of *Acinetobacter baumannii* from northern Taiwan. *Ann Lab Med* 2013; **33**: 242-247 [PMID: 23826559 DOI: 10.3343/alm.2013.33.4.242]
- 18 **Seifert H**, Dolzani L, Bressan R, van der Reijden T, van Strijen B, Stefanik D, Heersma H, Dijkshoorn L. Standardization and interlaboratory reproducibility assessment of pulsed-field gel electrophoresis-generated fingerprints of *Acinetobacter baumannii*. *J Clin Microbiol* 2005; **43**: 4328-4335 [PMID: 16145073 DOI: 10.1128/JCM.43.9.4328-4335.2005]
- 19 **Zarrilli R**, Crispino M, Bagattini M, Barretta E, Di Popolo A, Triassi M, Villari P. Molecular epidemiology of sequential outbreaks of *Acinetobacter baumannii* in an intensive care unit shows the emergence of carbapenem resistance. *J Clin Microbiol* 2004; **42**: 946-953 [PMID: 15004037 DOI: 10.1128/jcm.42.3.946-953.2004]
- 20 **Towner KJ**, Levi K, Vlassiadi M. Genetic diversity of carbapenem-resistant isolates of *Acinetobacter baumannii* in Europe. *Clin Microbiol Infect* 2008; **14**: 161-167 [PMID: 18093236]
- 21 **Qi C**, Malczynski M, Parker M, Scheetz MH. Characterization of genetic diversity of carbapenem-resistant *Acinetobacter baumannii* clinical strains collected from 2004 to 2007. *J Clin Microbiol* 2008; **46**: 1106-1109 [PMID: 18216212 DOI: 10.1128/JCM.01877-07]
- 22 **Bartual SG**, Seifert H, Hippler C, Luzon MA, Wisplinghoff H, Rodríguez-Valera F. Development of a multilocus sequence typing scheme for characterization of clinical isolates of *Acinetobacter baumannii*. *J Clin Microbiol* 2005; **43**: 4382-4390 [PMID: 16145081 DOI: 10.1128/JCM.43.9.4382-4390.2005]
- 23 **Jolley KA**, Maiden MC. BIGSdb: Scalable analysis of bacterial genome variation at the population level. *BMC Bioinformatics* 2010; **11**: 595 [PMID: 21143983 DOI: 10.1186/1471-2105-11-595]
- 24 **Baumann P**. Isolation of *Acinetobacter* from soil and water. *J Bacteriol* 1968; **96**: 39-42 [PMID: 4874313]
- 25 **Peleg AY**, Seifert H, Paterson DL. *Acinetobacter baumannii*: emergence of a successful pathogen. *Clin Microbiol Rev* 2008; **21**: 538-582 [PMID: 18625687 DOI: 10.1128/CMR.00058-07]
- 26 **Fournier PE**, Richet H. The epidemiology and control of *Acinetobacter baumannii* in health care facilities. *Clin Infect Dis* 2006; **42**: 692-699 [PMID: 16447117 DOI: 10.1086/500202]
- 27 **Falagas ME**, Karveli EA. The changing global epidemiology of *Acinetobacter baumannii* infections: a development with major public health implications. *Clin Microbiol Infect* 2007; **13**: 117-119 [PMID: 17328722 DOI: 10.1111/j.1469-0691.2006.01596.x]
- 28 **Dijkshoorn L**, Nemec A, Seifert H. An increasing threat in hospitals: multidrug-resistant *Acinetobacter baumannii*. *Nat Rev Microbiol* 2007; **5**: 939-951 [PMID: 18007677 DOI: 10.1038/nrmicro1789]
- 29 **Maragakis LL**, Perl TM. *Acinetobacter baumannii*: epidemiology, antimicrobial resistance, and treatment options. *Clin Infect Dis* 2008; **46**: 1254-1263 [PMID: 18444865 DOI: 10.1086/529198]
- 30 **Rodríguez-Baño J**, Cisneros JM, Fernández-Cuenca F, Ribera A, Vila J, Pascual A, Martínez-Martínez L, Bou G, Pachón J. Clinical features and epidemiology of *Acinetobacter baumannii* colonization and infection in Spanish hospitals. *Infect Control Hosp Epidemiol* 2004; **25**: 819-824 [PMID: 15518022]
- 31 **Lin MF**, Yang CM, Lin CH, Huang ML, Tu CC, Liou ML. Clinical features and molecular epidemiology of multidrug-resistant *Acinetobacter calcoaceticus*-*A. baumannii* complex in a regional teaching hospital in Taiwan. *Am J Infect Control* 2009; **37**: e1-e3 [PMID: 19576662 DOI: 10.1016/j.ajic.2009.03.008]
- 32 **Falagas ME**, Bliziotis IA, Siempos II. Attributable mortality of *Acinetobacter baumannii* infections in critically ill patients: a systematic review of matched cohort and case-control studies. *Crit Care* 2006; **10**: R48 [PMID: 16563184]
- 33 **Simor AE**, Lee M, Vearncombe M, Jones-Paul L, Barry C, Gomez M, Fish JS, Cartotto RC, Palmer R, Louie M. An out-

- break due to multiresistant *Acinetobacter baumannii* in a burn unit: risk factors for acquisition and management. *Infect Control Hosp Epidemiol* 2002; **23**: 261-267 [PMID: 12026151]
- 34 **Cisneros JM**, Rodríguez-Baño J, Fernández-Cuenca F, Ribera A, Vila J, Pascual A, Martínez-Martínez L, Bou G, Pachón J. Risk-factors for the acquisition of imipenem-resistant *Acinetobacter baumannii* in Spain: a nationwide study. *Clin Microbiol Infect* 2005; **11**: 874-879 [PMID: 16216101 DOI: 10.1111/j.1469-0691.2005.01256.x]
  - 35 **Lee SO**, Kim NJ, Choi SH, Hyong Kim T, Chung JW, Woo JH, Ryu J, Kim YS. Risk factors for acquisition of imipenem-resistant *Acinetobacter baumannii*: a case-control study. *Antimicrob Agents Chemother* 2004; **48**: 224-228 [PMID: 14693543 DOI: 10.1128/aac.48.1.224-228.2004]
  - 36 **Ye JJ**, Huang CT, Shie SS, Huang PY, Su LH, Chiu CH, Leu HS, Chiang PC. Multidrug resistant *Acinetobacter baumannii*: risk factors for appearance of imipenem resistant strains on patients formerly with susceptible strains. *PLoS One* 2010; **5**: e9947 [PMID: 20369056 DOI: 10.1371/journal.pone.0009947]
  - 37 **Chan MC**, Chiu SK, Hsueh PR, Wang NC, Wang CC, Fang CT. Risk factors for healthcare-associated extensively drug-resistant *Acinetobacter baumannii* infections: a case-control study. *PLoS One* 2014; **9**: e85973 [PMID: 24465819 DOI: 10.1371/journal.pone.0085973]
  - 38 **Falagas ME**, Kopterides P. Risk factors for the isolation of multi-drug-resistant *Acinetobacter baumannii* and *Pseudomonas aeruginosa*: a systematic review of the literature. *J Hosp Infect* 2006; **64**: 7-15 [PMID: 16822583 DOI: 10.1016/j.jhin.2006.04.015]
  - 39 **García-Garmendia JL**, Ortiz-Leyba C, Garnacho-Montero J, Jiménez-Jiménez FJ, Pérez-Paredes C, Barrero-Almodóvar AE, Gili-Miner M. Risk factors for *Acinetobacter baumannii* nosocomial bacteremia in critically ill patients: a cohort study. *Clin Infect Dis* 2001; **33**: 939-946 [PMID: 11528563]
  - 40 **Park SY**, Choo JW, Kwon SH, Yu SN, Lee EJ, Kim TH, Choo EJ, Jeon MH. Risk Factors for Mortality in Patients with *Acinetobacter baumannii* Bacteremia. *Infect Chemother* 2013; **45**: 325-330 [PMID: 24396634 DOI: 10.3947/ic.2013.45.3.325]
  - 41 **Baraibar J**, Correa H, Mariscal D, Gallego M, Vallés J, Rello J. Risk factors for infection by *Acinetobacter baumannii* in intubated patients with nosocomial pneumonia. *Chest* 1997; **112**: 1050-1054 [PMID: 9377916]
  - 42 **Huang ST**, Chiang MC, Kuo SC, Lee YT, Chiang TH, Yang SP, Ti-Yin TL, Fung CP. Risk factors and clinical outcomes of patients with carbapenem-resistant *Acinetobacter baumannii* bacteremia. *J Microbiol Immunol Infect* 2012; **45**: 356-362 [PMID: 22575430 DOI: 10.1016/j.jmii.2011.12.009]
  - 43 **Jung JY**, Park MS, Kim SE, Park BH, Son JY, Kim EY, Lim JE, Lee SK, Lee SH, Lee KJ, Kang YA, Kim SK, Chang J, Kim YS. Risk factors for multi-drug resistant *Acinetobacter baumannii* bacteremia in patients with colonization in the intensive care unit. *BMC Infect Dis* 2010; **10**: 228 [PMID: 20670453 DOI: 10.1186/1471-2334-10-228]
  - 44 **Ng TM**, Teng CB, Lye DC, Apisarnthanarak A. A multicenter case-control study for risk factors and outcomes of extensively drug-resistant *Acinetobacter baumannii* bacteremia. *Infect Control Hosp Epidemiol* 2014; **35**: 49-55 [PMID: 24334798 DOI: 10.1086/674387]
  - 45 **Zheng YL**, Wan YF, Zhou LY, Ye ML, Liu S, Xu CQ, He YQ, Chen JH. Risk factors and mortality of patients with nosocomial carbapenem-resistant *Acinetobacter baumannii* pneumonia. *Am J Infect Control* 2013; **41**: e59-e63 [PMID: 23523521 DOI: 10.1016/j.ajic.2013.01.006]
  - 46 **Özgür ES**, Horasan ES, Karaca K, Ersöz G, Naycı Atış S, Kaya A. Ventilator-associated pneumonia due to extensive drug-resistant *Acinetobacter baumannii*: risk factors, clinical features, and outcomes. *Am J Infect Control* 2014; **42**: 206-208 [PMID: 24485378 DOI: 10.1016/j.ajic.2013.09.003]
  - 47 **Antunes LC**, Imperi F, Carattoli A, Visca P. Deciphering the multifactorial nature of *Acinetobacter baumannii* pathogenicity. *PLoS One* 2011; **6**: e22674 [PMID: 21829642 DOI: 10.1371/journal.pone.0022674]
  - 48 **Gaddy JA**, Actis LA. Regulation of *Acinetobacter baumannii* biofilm formation. *Future Microbiol* 2009; **4**: 273-278 [PMID: 19327114 DOI: 10.2217/fmb.09.5]
  - 49 **Tomaras AP**, Flagler MJ, Dorsey CW, Gaddy JA, Actis LA. Characterization of a two-component regulatory system from *Acinetobacter baumannii* that controls biofilm formation and cellular morphology. *Microbiology* 2008; **154**: 3398-3409 [PMID: 18957593 DOI: 10.1099/mic.0.2008/019471-0]
  - 50 **Brossard KA**, Campagnari AA. The *Acinetobacter baumannii* biofilm-associated protein plays a role in adherence to human epithelial cells. *Infect Immun* 2012; **80**: 228-233 [PMID: 22083703 DOI: 10.1128/IAI.05913-11]
  - 51 **Fattahian Y**, Rasooli I, Mousavi Gargari SL, Rahbar MR, Darvish Alipour A, Amani J. Protection against *Acinetobacter baumannii* infection via its functional deprivation of biofilm associated protein (Bap). *Microb Pathog* 2011; **51**: 402-406 [PMID: 21946278 DOI: 10.1016/j.micpath.2011.09.004]
  - 52 **Rodríguez-Baño J**, Martí S, Soto S, Fernández-Cuenca F, Cisneros JM, Pachón J, Pascual A, Martínez-Martínez L, McQuary C, Actis LA, Vila J. Biofilm formation in *Acinetobacter baumannii*: associated features and clinical implications. *Clin Microbiol Infect* 2008; **14**: 276-278 [PMID: 18190568 DOI: 10.1111/j.1469-0691.2007.01916.x]
  - 53 **Marti S**, Nait Chabane Y, Alexandre S, Coquet L, Vila J, Jouenne T, Dé E. Growth of *Acinetobacter baumannii* in pellicle enhanced the expression of potential virulence factors. *PLoS One* 2011; **6**: e26030 [PMID: 22046254 DOI: 10.1371/journal.pone.0026030]
  - 54 **Eijkelkamp BA**, Hassan KA, Paulsen IT, Brown MH. Investigation of the human pathogen *Acinetobacter baumannii* under iron limiting conditions. *BMC Genomics* 2011; **12**: 126 [PMID: 21342532 DOI: 10.1186/1471-2164-12-126]
  - 55 **Mortensen BL**, Skaar EP. The contribution of nutrient metal acquisition and metabolism to *Acinetobacter baumannii* survival within the host. *Front Cell Infect Microbiol* 2013; **3**: 95 [PMID: 24377089 DOI: 10.3389/fcimb.2013.00095]
  - 56 **Hood MI**, Mortensen BL, Moore JL, Zhang Y, Kehl-Fie TE, Sugitani N, Chazin WJ, Caprioli RM, Skaar EP. Identification of an *Acinetobacter baumannii* zinc acquisition system that facilitates resistance to calprotectin-mediated zinc sequestration. *PLoS Pathog* 2012; **8**: e1003068 [PMID: 23236280 DOI: 10.1371/journal.ppat.1003068]
  - 57 **Lee JC**, Koerten H, van den Broek P, Beekhuizen H, Wolterbeek R, van den Barselaar M, van der Reijden T, van der Meer J, van de Gevel J, Dijkshoorn L. Adherence of *Acinetobacter baumannii* strains to human bronchial epithelial cells. *Res Microbiol* 2006; **157**: 360-366 [PMID: 16326077 DOI: 10.1016/j.resmic.2005.09.011]
  - 58 **Russo TA**, Luke NR, Beanan JM, Olson R, Sauberman SL, MacDonald U, Schultz LW, Umland TC, Campagnari AA. The K1 capsular polysaccharide of *Acinetobacter baumannii* strain 307-0294 is a major virulence factor. *Infect Immun* 2010; **78**: 3993-4000 [PMID: 20643860 DOI: 10.1128/IAI.00366-10]
  - 59 **Choi CH**, Lee EY, Lee YC, Park TI, Kim HJ, Hyun SH, Kim SA, Lee SK, Lee JC. Outer membrane protein 38 of *Acinetobacter baumannii* localizes to the mitochondria and induces apoptosis of epithelial cells. *Cell Microbiol* 2005; **7**: 1127-1138 [PMID: 16008580 DOI: 10.1111/j.1462-5822.2005.00538.x]
  - 60 **Aranda J**, Bardina C, Beceiro A, Rumbo S, Cabral MP, Barbé J, Bou G. *Acinetobacter baumannii* RecA protein in repair of DNA damage, antimicrobial resistance, general stress response, and virulence. *J Bacteriol* 2011; **193**: 3740-3747 [PMID: 21642465 DOI: 10.1128/JB.00389-11]
  - 61 **Jacobs AC**, Hood I, Boyd KL, Olson PD, Morrison JM, Carson S, Sayood K, Iwen PC, Skaar EP, Dunman PM. Inactivation of phospholipase D diminishes *Acinetobacter baumannii* pathogenesis. *Infect Immun* 2010; **78**: 1952-1962 [PMID: 20369056 DOI: 10.1371/journal.pone.0009947]



- 20194595 DOI: 10.1128/IAI.00889-09]
- 62 **Choi CH**, Hyun SH, Lee JY, Lee JS, Lee YS, Kim SA, Chae JP, Yoo SM, Lee JC. *Acinetobacter baumannii* outer membrane protein A targets the nucleus and induces cytotoxicity. *Cell Microbiol* 2008; **10**: 309-319 [PMID: 17760880 DOI: 10.1111/j.1462-5822.2007.01041.x]
- 63 **Sugawara E**, Nikaido H. OmpA is the principal nonspecific slow porin of *Acinetobacter baumannii*. *J Bacteriol* 2012; **194**: 4089-4096 [PMID: 22636785 DOI: 10.1128/JB.00435-12]
- 64 **Moffatt JH**, Harper M, Harrison P, Hale JD, Vinogradov E, Seemann T, Henry R, Crane B, St Michael F, Cox AD, Adler B, Nation RL, Li J, Boyce JD. Colistin resistance in *Acinetobacter baumannii* is mediated by complete loss of lipopolysaccharide production. *Antimicrob Agents Chemother* 2010; **54**: 4971-4977 [PMID: 20855724 DOI: 10.1128/AAC.00834-10]
- 65 **Henry R**, Vithanage N, Harrison P, Seemann T, Coutts S, Moffatt JH, Nation RL, Li J, Harper M, Adler B, Boyce JD. Colistin-resistant, lipopolysaccharide-deficient *Acinetobacter baumannii* responds to lipopolysaccharide loss through increased expression of genes involved in the synthesis and transport of lipoproteins, phospholipids, and poly- $\beta$ -1,6-N-acetylglucosamine. *Antimicrob Agents Chemother* 2012; **56**: 59-69 [PMID: 22024825 DOI: 10.1128/AAC.05191-11]
- 66 **Perez F**, Hujer AM, Hujer KM, Decker BK, Rather PN, Bonomo RA. Global challenge of multidrug-resistant *Acinetobacter baumannii*. *Antimicrob Agents Chemother* 2007; **51**: 3471-3484 [PMID: 17646423 DOI: 10.1128/AAC.01464-06]
- 67 **Morfin-Otero R**, Dowzicky MJ. Changes in MIC within a global collection of *Acinetobacter baumannii* collected as part of the Tigecycline Evaluation and Surveillance Trial, 2004 to 2009. *Clin Ther* 2012; **34**: 101-112 [PMID: 22177546 DOI: 10.1016/j.clinthera.2011.11.028]
- 68 **Hsueh PR**, Teng LJ, Chen CY, Chen WH, Yu CJ, Ho SW, Luh KT. Pandrug-resistant *Acinetobacter baumannii* causing nosocomial infections in a university hospital, Taiwan. *Emerg Infect Dis* 2002; **8**: 827-832 [PMID: 12141969 DOI: 10.3201/eid0805.020014]
- 69 **Wang SH**, Sheng WH, Chang YY, Wang LH, Lin HC, Chen ML, Pan HJ, Ko WJ, Chang SC, Lin FY. Healthcare-associated outbreak due to pan-drug resistant *Acinetobacter baumannii* in a surgical intensive care unit. *J Hosp Infect* 2003; **53**: 97-102 [PMID: 12586567]
- 70 **Chang PY**, Hsueh PR, Wu PS, Chan PC, Yang TT, Lu CY, Chang LY, Chen JM, Lee PI, Lee CY, Huang LM. Multidrug-resistant *Acinetobacter baumannii* isolates in pediatric patients of a university hospital in Taiwan. *J Microbiol Immunol Infect* 2007; **40**: 406-410 [PMID: 17932600]
- 71 **Chang HL**, Tang CH, Hsu YM, Wan L, Chang YF, Lin CT, Tseng YR, Lin YJ, Sheu JJ, Lin CW, Chang YC, Ho MW, Lin CD, Ho CM, Lai CH. Nosocomial outbreak of infection with multidrug-resistant *Acinetobacter baumannii* in a medical center in Taiwan. *Infect Control Hosp Epidemiol* 2009; **30**: 34-38 [PMID: 19049437 DOI: 10.1086/592704]
- 72 **Lee YT**, Fung CP, Wang FD, Chen CP, Chen TL, Cho WL. Outbreak of imipenem-resistant *Acinetobacter calcoaceticus*-*Acinetobacter baumannii* complex harboring different carbapenemase gene-associated genetic structures in an intensive care unit. *J Microbiol Immunol Infect* 2012; **45**: 43-51 [PMID: 22169123 DOI: 10.1016/j.jmii.2011.09.020]
- 73 **Lauderdale TL**, Clifford McDonald L, Shiao YR, Chen PC, Wang HY, Lai JF, Ho M. The status of antimicrobial resistance in Taiwan among gram-negative pathogens: the Taiwan surveillance of antimicrobial resistance (TSAR) program, 2000. *Diagn Microbiol Infect Dis* 2004; **48**: 211-219 [PMID: 15023432 DOI: 10.1016/j.diagmicrobio.2003.10.005]
- 74 **Hsueh PR**, Liu YC, Yang D, Yan JJ, Wu TL, Huang WK, Wu JJ, Ko WC, Leu HS, Yu CR, Luh KT. Multicenter surveillance of antimicrobial resistance of major bacterial pathogens in intensive care units in 2000 in Taiwan. *Microb Drug Resist* 2001; **7**: 373-382 [PMID: 11822777]
- 75 **Kuo SC**, Chang SC, Wang HY, Lai JF, Chen PC, Shiao YR, Huang IW, Lauderdale TL. Emergence of extensively drug-resistant *Acinetobacter baumannii* complex over 10 years: nationwide data from the Taiwan Surveillance of Antimicrobial Resistance (TSAR) program. *BMC Infect Dis* 2012; **12**: 200 [PMID: 22929085 DOI: 10.1186/1471-2334-12-200]
- 76 **Su CH**, Wang JT, Hsiung CA, Chien LJ, Chi CL, Yu HT, Chang FY, Chang SC. Increase of carbapenem-resistant *Acinetobacter baumannii* infection in acute care hospitals in Taiwan: association with hospital antimicrobial usage. *PLoS One* 2012; **7**: e37788 [PMID: 22629456 DOI: 10.1371/journal.pone.0037788]
- 77 **Lin MF**, Chang KC, Lan CY, Chou J, Kuo JW, Chang CK, Liou ML. Molecular epidemiology and antimicrobial resistance determinants of multidrug-resistant *Acinetobacter baumannii* in five proximal hospitals in Taiwan. *Jpn J Infect Dis* 2011; **64**: 222-227 [PMID: 21617307]
- 78 **Jeong SH**, Bae IK, Park KO, An YJ, Sohn SG, Jang SJ, Sung KH, Yang KS, Lee K, Young D, Lee SH. Outbreaks of imipenem-resistant *Acinetobacter baumannii* producing carbapenemases in Korea. *J Microbiol* 2006; **44**: 423-431 [PMID: 16953178]
- 79 **Bogaerts P**, Naas T, Wybo I, Bauraing C, Soetens O, Piérard D, Nordmann P, Glupczynski Y. Outbreak of infection by carbapenem-resistant *Acinetobacter baumannii* producing the carbapenemase OXA-58 in Belgium. *J Clin Microbiol* 2006; **44**: 4189-4192 [PMID: 16957031 DOI: 10.1128/JCM.00796-06]
- 80 **Zarrilli R**, Casillo R, Di Popolo A, Tripodi MF, Bagattini M, Cuccurullo S, Crivaro V, Ragone E, Mattei A, Galdieri N, Triassi M, Utili R. Molecular epidemiology of a clonal outbreak of multidrug-resistant *Acinetobacter baumannii* in a university hospital in Italy. *Clin Microbiol Infect* 2007; **13**: 481-489 [PMID: 17430339]
- 81 **Scott P**, Deye G, Srinivasan A, Murray C, Moran K, Hulten E, Fishbain J, Craft D, Riddell S, Lindler L, Mancuso J, Milstrey E, Bautista CT, Patel J, Ewell A, Hamilton T, Gaddy C, Tenney M, Christopher G, Petersen K, Endy T, Petruccielli B. An outbreak of multidrug-resistant *Acinetobacter baumannii*-calcoaceticus complex infection in the US military health care system associated with military operations in Iraq. *Clin Infect Dis* 2007; **44**: 1577-1584 [PMID: 17516401 DOI: 10.1086/518170]
- 82 **Marchaim D**, Navon-Venezia S, Leavitt A, Chmelnitsky I, Schwaber MJ, Carmeli Y. Molecular and epidemiologic study of polyclonal outbreaks of multidrug-resistant *Acinetobacter baumannii* infection in an Israeli hospital. *Infect Control Hosp Epidemiol* 2007; **28**: 945-950 [PMID: 17620242 DOI: 10.1086/518970]
- 83 **Markogiannakis A**, Fildisis G, Tsiplakou S, Ikonomidis A, Koutsoukou A, Pournaras S, Manolis EN, Baltopoulos G, Tsakris A. Cross-transmission of multidrug-resistant *Acinetobacter baumannii* clonal strains causing episodes of sepsis in a trauma intensive care unit. *Infect Control Hosp Epidemiol* 2008; **29**: 410-417 [PMID: 18419362 DOI: 10.1086/533545]
- 84 **Shelburne SA**, Singh KV, White AC, Byrne L, Carmer A, Austin C, Graviss E, Stager C, Murray BE, Atmar RL. Sequential outbreaks of infections by distinct *Acinetobacter baumannii* strains in a public teaching hospital in Houston, Texas. *J Clin Microbiol* 2008; **46**: 198-205 [PMID: 18003801 DOI: 10.1128/JCM.01459-07]
- 85 **Martins AF**, Kuchenbecker RS, Pilger KO, Pagano M, Barth AL. High endemic levels of multidrug-resistant *Acinetobacter baumannii* among hospitals in southern Brazil. *Am J Infect Control* 2012; **40**: 108-112 [PMID: 21784555 DOI: 10.1016/j.ajic.2011.03.010]
- 86 **Runnegar N**, Sidjabat H, Goh HM, Nimmo GR, Schembri MA, Paterson DL. Molecular epidemiology of multidrug-resistant *Acinetobacter baumannii* in a single institution over a 10-year period. *J Clin Microbiol* 2010; **48**: 4051-4056 [PMID: 20739495 DOI: 10.1128/JCM.01208-10]



- 87 **Yan ZQ**, Shen DX, Cao JR, Chen R, Wei X, Liu LP, Xu XL. Susceptibility patterns and molecular epidemiology of multidrug-resistant *Acinetobacter baumannii* strains from three military hospitals in China. *Int J Antimicrob Agents* 2010; **35**: 269-273 [PMID: 20036519 DOI: 10.1016/j.ijantimicag.2009.10.016]
- 88 **Fillaux J**, Dubouix A, Conil JM, Laguerre J, Marty N. Retrospective analysis of multidrug-resistant *Acinetobacter baumannii* strains isolated during a 4-year period in a university hospital. *Infect Control Hosp Epidemiol* 2006; **27**: 647-653 [PMID: 16807836 DOI: 10.1086/507082]
- 89 **Wybo I**, Blommaert L, De Beer T, Soetens O, De Regt J, Lator P, Piérard D, Lauwers S. Outbreak of multidrug-resistant *Acinetobacter baumannii* in a Belgian university hospital after transfer of patients from Greece. *J Hosp Infect* 2007; **67**: 374-380 [PMID: 18023922 DOI: 10.1016/j.jhin.2007.09.012]
- 90 **Mendes RE**, Farrell DJ, Sader HS, Jones RN. Comprehensive assessment of tigecycline activity tested against a worldwide collection of *Acinetobacter* spp. (2005-2009). *Diagn Microbiol Infect Dis* 2010; **68**: 307-311 [PMID: 20955916 DOI: 10.1016/j.diagmicrobio.2010.07.003]
- 91 **Quale J**, Bratu S, Landman D, Heddurshetti R. Molecular epidemiology and mechanisms of carbapenem resistance in *Acinetobacter baumannii* endemic in New York City. *Clin Infect Dis* 2003; **37**: 214-220 [PMID: 12856214 DOI: 10.1086/375821]
- 92 **Wang H**, Guo P, Sun H, Wang H, Yang Q, Chen M, Xu Y, Zhu Y. Molecular epidemiology of clinical isolates of carbapenem-resistant *Acinetobacter* spp. from Chinese hospitals. *Antimicrob Agents Chemother* 2007; **51**: 4022-4028 [PMID: 17846127 DOI: 10.1128/AAC.01259-06]
- 93 **Afzal-Shah M**, Livermore DM. Worldwide emergence of carbapenem-resistant *Acinetobacter* spp. *J Antimicrob Chemother* 1998; **41**: 576-577 [PMID: 9630416]
- 94 **Young LS**, Sabel AL, Price CS. Epidemiologic, clinical, and economic evaluation of an outbreak of clonal multidrug-resistant *Acinetobacter baumannii* infection in a surgical intensive care unit. *Infect Control Hosp Epidemiol* 2007; **28**: 1247-1254 [PMID: 17926275 DOI: 10.1086/521660]
- 95 **Chan PC**, Huang LM, Lin HC, Chang LY, Chen ML, Lu CY, Lee PI, Chen JM, Lee CY, Pan HJ, Wang JT, Chang SC, Chen YC. Control of an outbreak of pandrug-resistant *Acinetobacter baumannii* colonization and infection in a neonatal intensive care unit. *Infect Control Hosp Epidemiol* 2007; **28**: 423-429 [PMID: 17385148 DOI: 10.1086/513120]
- 96 **Fournier PE**, Vallenet D, Barbe V, Audic S, Ogata H, Poirel L, Richet H, Robert C, Mangenot S, Abergel C, Nordmann P, Weissenbach J, Raoult D, Claverie JM. Comparative genomics of multidrug resistance in *Acinetobacter baumannii*. *PLoS Genet* 2006; **2**: e7 [PMID: 16415984 DOI: 10.1371/journal.pgen.0020007]
- 97 **Smith MG**, Gianoulis TA, Pukatzki S, Mekalanos JJ, Ornston LN, Gerstein M, Snyder M. New insights into *Acinetobacter baumannii* pathogenesis revealed by high-density pyrosequencing and transposon mutagenesis. *Genes Dev* 2007; **21**: 601-614 [PMID: 17344419 DOI: 10.1101/gad.1510307]
- 98 **Iacono M**, Villa L, Fortini D, Bordoni R, Imperi F, Bonnal RJ, Sicheritz-Ponten T, De Bellis G, Visca P, Cassone A, Carattoli A. Whole-genome pyrosequencing of an epidemic multidrug-resistant *Acinetobacter baumannii* strain belonging to the European clone II group. *Antimicrob Agents Chemother* 2008; **52**: 2616-2625 [PMID: 18411315 DOI: 10.1128/AAC.01643-07]
- 99 **Krizova L**, Dijkshoorn L, Nemec A. Diversity and evolution of AbaR genomic resistance islands in *Acinetobacter baumannii* strains of European clone I. *Antimicrob Agents Chemother* 2011; **55**: 3201-3206 [PMID: 21537009 DOI: 10.1128/AAC.00221-11]
- 100 **Zhou H**, Zhang T, Yu D, Pi B, Yang Q, Zhou J, Hu S, Yu Y. Genomic analysis of the multidrug-resistant *Acinetobacter baumannii* strain MDR-ZJ06 widely spread in China. *Antimicrob Agents Chemother* 2011; **55**: 4506-4512 [PMID: 21788470 DOI: 10.1128/AAC.01134-10]
- 101 **Gao F**, Wang Y, Liu YJ, Wu XM, Lv X, Gan YR, Song SD, Huang H. Genome sequence of *Acinetobacter baumannii* MDR-TJ. *J Bacteriol* 2011; **193**: 2365-2366 [PMID: 21398552 DOI: 10.1128/JB.00226-11]
- 102 **Chen CC**, Lin YC, Sheng WH, Chen YC, Chang SC, Hsia KC, Liao MH, Li SY. Genome sequence of a dominant, multidrug-resistant *Acinetobacter baumannii* strain, TCDC-AB0715. *J Bacteriol* 2011; **193**: 2361-2362 [PMID: 21398540 DOI: 10.1128/JB.00244-11]
- 103 **Liou ML**, Liu CC, Lu CW, Hsieh MF, Chang KC, Kuo HY, Lee CC, Chang CT, Yang CY, Tang CY. Genome sequence of *Acinetobacter baumannii* TYTH-1. *J Bacteriol* 2012; **194**: 6974 [PMID: 23209228 DOI: 10.1128/JB.01860-12]
- 104 **Liu CC**, Tang CY, Kuo HY, Lu CW, Chang KC, Liou ML. The origin of *Acinetobacter baumannii* TYTH-1: a comparative genomics study. *Int J Antimicrob Agents* 2013; **41**: 318-324 [PMID: 23402702 DOI: 10.1016/j.ijantimicag.2012.12.010]
- 105 **Adams MD**, Goglin K, Molyneaux N, Hujer KM, Lavender H, Jamison JJ, MacDonald IJ, Martin KM, Russo T, Campagnari AA, Hujer AM, Bonomo RA, Gill SR. Comparative genome sequence analysis of multidrug-resistant *Acinetobacter baumannii*. *J Bacteriol* 2008; **190**: 8053-8064 [PMID: 18931120 DOI: 10.1128/JB.00834-08]
- 106 **Adams MD**, Chan ER, Molyneaux ND, Bonomo RA. Genomewide analysis of divergence of antibiotic resistance determinants in closely related isolates of *Acinetobacter baumannii*. *Antimicrob Agents Chemother* 2010; **54**: 3569-3577 [PMID: 20530228 DOI: 10.1128/AAC.00057-10]
- 107 **Snitkin ES**, Zelazny AM, Montero CI, Stock F, Mijares L, Murray PR, Segre JA. Genome-wide recombination drives diversification of epidemic strains of *Acinetobacter baumannii*. *Proc Natl Acad Sci USA* 2011; **108**: 13758-13763 [PMID: 21825119 DOI: 10.1073/pnas.1104404108]
- 108 **Vallenet D**, Nordmann P, Barbe V, Poirel L, Mangenot S, Bataille E, Dossat C, Gas S, Kreimeyer A, Lenoble P, Oztas S, Poulain J, Segurens B, Robert C, Abergel C, Claverie JM, Raoult D, Médigue C, Weissenbach J, Cruveiller S. Comparative analysis of *Acinetobacter*: three genomes for three lifestyles. *PLoS One* 2008; **3**: e1805 [PMID: 18350144 DOI: 10.1371/journal.pone.0001805]
- 109 **Gordon NC**, Wareham DW. Multidrug-resistant *Acinetobacter baumannii*: mechanisms of virulence and resistance. *Int J Antimicrob Agents* 2010; **35**: 219-226 [PMID: 20047818 DOI: 10.1016/j.ijantimicag.2009.10.024]
- 110 **Esterly J**, Richardson CL, Eltoukhy NS, Qi C, Scheetz MH. Genetic Mechanisms of Antimicrobial Resistance of *Acinetobacter baumannii* (February). *Ann Pharmacother* 2011 Feb 8; Epub ahead of print [PMID: 21304033 DOI: 10.1345/aph.1P084]
- 111 **Roca I**, Espinal P, Vila-Farrés X, Vila J. The *Acinetobacter baumannii* Oxymoron: Commensal Hospital Dweller Turned Pan-Drug-Resistant Menace. *Front Microbiol* 2012; **3**: 148 [PMID: 22536199 DOI: 10.3389/fmicb.2012.00148]
- 112 **Kim YJ**, Kim SI, Kim YR, Hong KW, Wie SH, Park YJ, Jeong H, Kang MW. Carbapenem-resistant *Acinetobacter baumannii*: diversity of resistant mechanisms and risk factors for infection. *Epidemiol Infect* 2012; **140**: 137-145 [PMID: 21554783 DOI: 10.1017/S0950268811000744]
- 113 **Poirel L**, Nordmann P. Carbapenem resistance in *Acinetobacter baumannii*: mechanisms and epidemiology. *Clin Microbiol Infect* 2006; **12**: 826-836 [PMID: 16882287 DOI: 10.1111/j.1469-0691.2006.01456.x]
- 114 **Turton JF**, Ward ME, Woodford N, Kaufmann ME, Pike R, Livermore DM, Pitt TL. The role of ISAbal in expression of OXA carbapenemase genes in *Acinetobacter baumannii*. *FEMS Microbiol Lett* 2006; **258**: 72-77 [PMID: 16630258 DOI: 10.1111/j.1574-6968.2006.00195.x]
- 115 **Bogaerts P**, Naas T, El Garch F, Cuzon G, Deplano A, Delaire

- T, Huang TD, Lissioir B, Nordmann P, Glupczynski Y. GES extended-spectrum  $\beta$ -lactamases in *Acinetobacter baumannii* isolates in Belgium. *Antimicrob Agents Chemother* 2010; **54**: 4872-4878 [PMID: 20805394 DOI: 10.1128/AAC.00871-10]
- 116 **Chen TL**, Wu RC, Shiao MF, Fung CP, Cho WL. Acquisition of a plasmid-borne blaOXA-58 gene with an upstream IS1008 insertion conferring a high level of carbapenem resistance to *Acinetobacter baumannii*. *Antimicrob Agents Chemother* 2008; **52**: 2573-2580 [PMID: 18443121 DOI: 10.1128/AAC.00393-08]
- 117 **Mugnier PD**, Poirel L, Nordmann P. Functional analysis of insertion sequence ISAbal, responsible for genomic plasticity of *Acinetobacter baumannii*. *J Bacteriol* 2009; **191**: 2414-2418 [PMID: 19136598 DOI: 10.1128/JB.01258-08]
- 118 **Ravasi P**, Limansky AS, Rodriguez RE, Viale AM, Mussi MA. ISAb825, a functional insertion sequence modulating genomic plasticity and bla(OXA-58) expression in *Acinetobacter baumannii*. *Antimicrob Agents Chemother* 2011; **55**: 917-920 [PMID: 21098239 DOI: 10.1128/AAC.00491-10]
- 119 **Chen CH**, Young TG, Huang CC. Predictive biomarkers for drug-resistant *Acinetobacter baumannii* isolates with bla(TEM-1), AmpC-type bla and integrase 1 genotypes. *J Microbiol Immunol Infect* 2006; **39**: 372-379 [PMID: 17066198]
- 120 **Endimiani A**, Luzzaro F, Migliavacca R, Mantengoli E, Hujer AM, Hujer KM, Pagani L, Bonomo RA, Rossolini GM, Toniolo A. Spread in an Italian hospital of a clonal *Acinetobacter baumannii* strain producing the TEM-92 extended-spectrum beta-lactamase. *Antimicrob Agents Chemother* 2007; **51**: 2211-2214 [PMID: 17404005 DOI: 10.1128/AAC.01139-06]
- 121 **Krizova L**, Poirel L, Nordmann P, Nemec A. TEM-1  $\beta$ -lactamase as a source of resistance to sulbactam in clinical strains of *Acinetobacter baumannii*. *J Antimicrob Chemother* 2013; **68**: 2786-2791 [PMID: 23838947 DOI: 10.1093/jac/dkt275]
- 122 **Naas T**, Namdari F, Réglie-Poupert H, Poyart C, Nordmann P. Panresistant extended-spectrum beta-lactamase SHV-5-producing *Acinetobacter baumannii* from New York City. *J Antimicrob Chemother* 2007; **60**: 1174-1176 [PMID: 17881631 DOI: 10.1093/jac/dkm366]
- 123 **Nagano N**, Nagano Y, Cordevant C, Shibata N, Arakawa Y. Nosocomial transmission of CTX-M-2 beta-lactamase-producing *Acinetobacter baumannii* in a neurosurgery ward. *J Clin Microbiol* 2004; **42**: 3978-3984 [PMID: 15364979 DOI: 10.1128/JCM.42.9.3978-3984.2004]
- 124 **Pottron A**, Munoz-Price LS, Nordmann P, Cleary T, Poirel L. Genetic features of CTX-M-15-producing *Acinetobacter baumannii* from Haiti. *Antimicrob Agents Chemother* 2011; **55**: 5946-5948 [PMID: 21930877 DOI: 10.1128/AAC.05124-11]
- 125 **Moubareck C**, Brémont S, Conroy MC, Courvalin P, Lambert T. GES-11, a novel integron-associated GES variant in *Acinetobacter baumannii*. *Antimicrob Agents Chemother* 2009; **53**: 3579-3581 [PMID: 19451292 DOI: 10.1128/AAC.00072-09]
- 126 **Poirel L**, Corvec S, Rapoport M, Mugnier P, Petroni A, Pasteran F, Faccone D, Galas M, Drugeon H, Cattoir V, Nordmann P. Identification of the novel narrow-spectrum beta-lactamase SCO-1 in *Acinetobacter* spp. from Argentina. *Antimicrob Agents Chemother* 2007; **51**: 2179-2184 [PMID: 17420213 DOI: 10.1128/AAC.01600-06]
- 127 **Jeong SH**, Bae IK, Kwon SB, Lee K, Yong D, Woo GJ, Lee JH, Jung HI, Jang SJ, Sung KH, Lee SH. Investigation of a nosocomial outbreak of *Acinetobacter baumannii* producing PER-1 extended-spectrum beta-lactamase in an intensive care unit. *J Hosp Infect* 2005; **59**: 242-248 [PMID: 15694982 DOI: 10.1016/j.jhin.2004.09.025]
- 128 **Poirel L**, Cabanne L, Vahaboglu H, Nordmann P. Genetic environment and expression of the extended-spectrum beta-lactamase blaPER-1 gene in gram-negative bacteria. *Antimicrob Agents Chemother* 2005; **49**: 1708-1713 [PMID: 15855485 DOI: 10.1128/AAC.49.5.1708-1713.2005]
- 129 **Bonnin RA**, Potron A, Poirel L, Lecuyer H, Neri R, Nordmann P. PER-7, an extended-spectrum beta-lactamase with increased activity toward broad-spectrum cephalosporins in *Acinetobacter baumannii*. *Antimicrob Agents Chemother* 2011; **55**: 2424-2427 [PMID: 21383087 DOI: 10.1128/AAC.01795-10]
- 130 **Opazo A**, Sonnevend A, Lopes B, Hamouda A, Ghazawi A, Pal T, Amyes SG. Plasmid-encoded PER-7  $\beta$ -lactamase responsible for ceftazidime resistance in *Acinetobacter baumannii* isolated in the United Arab Emirates. *J Antimicrob Chemother* 2012; **67**: 1619-1622 [PMID: 22419799 DOI: 10.1093/jac/dks087]
- 131 **Naas T**, Coignard B, Carbonne A, Blanckaert K, Bajolet O, Bernet C, Verdeil X, Astagneau P, Desenclos JC, Nordmann P. VEB-1 Extended-spectrum beta-lactamase-producing *Acinetobacter baumannii*, France. *Emerg Infect Dis* 2006; **12**: 1214-1222 [PMID: 16965700]
- 132 **Pasterán F**, Rapoport M, Petroni A, Faccone D, Corso A, Galas M, Vázquez M, Procopio A, Tokumoto M, Cagnoni V. Emergence of PER-2 and VEB-1a in *Acinetobacter baumannii* Strains in the Americas. *Antimicrob Agents Chemother* 2006; **50**: 3222-3224 [PMID: 16940137 DOI: 10.1128/AAC.00284-06]
- 133 **Poirel L**, Mugnier PD, Toleman MA, Walsh TR, Rapoport MJ, Petroni A, Nordmann P. ISCR2, another vehicle for bla(VEB) gene acquisition. *Antimicrob Agents Chemother* 2009; **53**: 4940-4943 [PMID: 19704129 DOI: 10.1128/AAC.00414-09]
- 134 **Pottron A**, Poirel L, Croizé J, Chantepedrix V, Nordmann P. Genetic and biochemical characterization of the first extended-spectrum CARB-type beta-lactamase, RTG-4, from *Acinetobacter baumannii*. *Antimicrob Agents Chemother* 2009; **53**: 3010-3016 [PMID: 19380596 DOI: 10.1128/AAC.01164-08]
- 135 **Ramírez MS**, Piñeiro S, Centrón D. Novel insights about class 2 integrons from experimental and genomic epidemiology. *Antimicrob Agents Chemother* 2010; **54**: 699-706 [PMID: 19917745 DOI: 10.1128/AAC.01392-08]
- 136 **Robledo IE**, Aquino EE, Santé MI, Santana JL, Otero DM, León CF, Vázquez GJ. Detection of KPC in *Acinetobacter* spp. in Puerto Rico. *Antimicrob Agents Chemother* 2010; **54**: 1354-1357 [PMID: 20038618 DOI: 10.1128/AAC.00899-09]
- 137 **Vahaboglu H**, Öztürk R, Aygün G, Coşkun F, Yaman A, Kaygusuz A, Leblebicioğlu H, Balık I, Aydın K, Ötkün M. Widespread detection of PER-1-type extended-spectrum beta-lactamases among nosocomial *Acinetobacter* and *Pseudomonas aeruginosa* isolates in Turkey: a nationwide multicenter study. *Antimicrob Agents Chemother* 1997; **41**: 2265-2269 [PMID: 9333059]
- 138 **Cornaglia G**, Giamarellou H, Rossolini GM. Metallo- $\beta$ -lactamases: a last frontier for  $\beta$ -lactams? *Lancet Infect Dis* 2011; **11**: 381-393 [PMID: 21530894 DOI: 10.1016/S1473-3099(11)70056-1]
- 139 **Yum JH**, Yi K, Lee H, Yong D, Lee K, Kim JM, Rossolini GM, Chong Y. Molecular characterization of metallo-beta-lactamase-producing *Acinetobacter baumannii* and *Acinetobacter genomospecies* 3 from Korea: identification of two new integrons carrying the bla(VIM-2) gene cassettes. *J Antimicrob Chemother* 2002; **49**: 837-840 [PMID: 12003980 DOI: 10.1093/jac/dkf043]
- 140 **Tsakris A**, Ikonomidis A, Pournaras S, Tzouveleakis LS, Sofianou D, Legakis NJ, Maniatis AN. VIM-1 metallo-beta-lactamase in *Acinetobacter baumannii*. *Emerg Infect Dis* 2006; **12**: 981-983 [PMID: 16707056]
- 141 **Tsakris A**, Ikonomidis A, Poulou A, Spanakis N, Vrizas D, Diomidous M, Pournaras S, Markou F. Clusters of imipenem-resistant *Acinetobacter baumannii* clones producing different carbapenemases in an intensive care unit. *Clin Microbiol Infect* 2008; **14**: 588-594 [PMID: 18397334 DOI: 10.1111/j.1469-0691.2008.01996.x]
- 142 **Papa A**, Koulourida V, Souliou E. Molecular epidemiology of carbapenem-resistant *Acinetobacter baumannii* in a newly established Greek hospital. *Microb Drug Resist* 2009; **15**: 257-260 [PMID: 19857131 DOI: 10.1089/mdr.2009.0060]
- 143 **Lee MF**, Peng CF, Hsu HJ, Chen YH. Molecular characterization of the metallo-beta-lactamase genes in imipenem-resistant Gram-negative bacteria from a university hospital in southern Taiwan. *Int J Antimicrob Agents* 2008; **32**: 475-480

- [PMID: 18804966 DOI: 10.1016/j.ijantimicag.2008.07.009]
- 144 **Tognim MC**, Gales AC, Penteado AP, Silbert S, Sader HS. Dissemination of IMP-1 metallo-  $\beta$ -lactamase-producing *Acinetobacter* species in a Brazilian teaching hospital. *Infect Control Hosp Epidemiol* 2006; **27**: 742-747 [PMID: 16807851]
  - 145 **Riccio ML**, Franceschini N, Boschi L, Caravelli B, Cornaglia G, Fontana R, Amicosante G, Rossolini GM. Characterization of the metallo- $\beta$ -lactamase determinant of *Acinetobacter baumannii* AC-54/97 reveals the existence of bla(IMP) allelic variants carried by gene cassettes of different phylogeny. *Antimicrob Agents Chemother* 2000; **44**: 1229-1235 [PMID: 10770756 DOI: 10.1128/aac.44.5.1229-1235.2000]
  - 146 **Chu YW**, Afzal-Shah M, Houang ET, Palepou MI, Lyon DJ, Woodford N, Livermore DM. IMP-4, a novel metallo- $\beta$ -lactamase from nosocomial *Acinetobacter* spp. collected in Hong Kong between 1994 and 1998. *Antimicrob Agents Chemother* 2001; **45**: 710-714 [PMID: 11181348 DOI: 10.1128/AAC.45.3.710-714.2001]
  - 147 **Koh TH**, Sng LH, Wang GC, Hsu LY, Zhao Y. IMP-4 and OXA  $\beta$ -lactamases in *Acinetobacter baumannii* from Singapore. *J Antimicrob Chemother* 2007; **59**: 627-632 [PMID: 17284537 DOI: 10.1093/jac/dkl544]
  - 148 **Da Silva GJ**, Correia M, Vital C, Ribeiro G, Sousa JC, Leitão R, Peixe L, Duarte A. Molecular characterization of bla(IMP-5), a new integron-borne metallo- $\beta$ -lactamase gene from an *Acinetobacter baumannii* nosocomial isolate in Portugal. *FEMS Microbiol Lett* 2002; **215**: 33-39 [PMID: 12393197]
  - 149 **Gales AC**, Tognim MC, Reis AO, Jones RN, Sader HS. Emergence of an IMP-like metallo-enzyme in an *Acinetobacter baumannii* clinical strain from a Brazilian teaching hospital. *Diagn Microbiol Infect Dis* 2003; **45**: 77-79 [PMID: 12573555 DOI: 10.1016/S0732-8893(02)00500-X]
  - 150 **Yamamoto M**, Nagao M, Matsumura Y, Matsushima A, Ito Y, Takakura S, Ichiyama S. Interspecies dissemination of a novel class 1 integron carrying blaIMP-19 among *Acinetobacter* species in Japan. *J Antimicrob Chemother* 2011; **66**: 2480-2483 [PMID: 21862476 DOI: 10.1093/jac/dkr336]
  - 151 **Lee K**, Yum JH, Yong D, Lee HM, Kim HD, Docquier JD, Rossolini GM, Chong Y. Novel acquired metallo- $\beta$ -lactamase gene, bla(SIM-1), in a class 1 integron from *Acinetobacter baumannii* clinical isolates from Korea. *Antimicrob Agents Chemother* 2005; **49**: 4485-4491 [PMID: 16251286 DOI: 10.1128/AAC.49.11.4485-4491.2005]
  - 152 **Chen Y**, Zhou Z, Jiang Y, Yu Y. Emergence of NDM-1-producing *Acinetobacter baumannii* in China. *J Antimicrob Chemother* 2011; **66**: 1255-1259 [PMID: 21398294 DOI: 10.1093/jac/dkr082]
  - 153 **Pfeifer Y**, Wilharm G, Zander E, Wichelhaus TA, Göttig S, Hunfeld KP, Seifert H, Witte W, Higgins PG. Molecular characterization of blaNDM-1 in an *Acinetobacter baumannii* strain isolated in Germany in 2007. *J Antimicrob Chemother* 2011; **66**: 1998-2001 [PMID: 21693460 DOI: 10.1093/jac/dkr256]
  - 154 **Bonnin RA**, Poirel L, Naas T, Pirs M, Seme K, Schrenzel J, Nordmann P. Dissemination of New Delhi metallo- $\beta$ -lactamase-1-producing *Acinetobacter baumannii* in Europe. *Clin Microbiol Infect* 2012; **18**: E362-E365 [PMID: 22738206 DOI: 10.1111/j.1469-0691.2012.03928.x]
  - 155 **Espinal P**, Fugazza G, López Y, Kasma M, Lerman Y, Malhotra-Kumar S, Goossens H, Carmeli Y, Vila J. Dissemination of an NDM-2-producing *Acinetobacter baumannii* clone in an Israeli rehabilitation center. *Antimicrob Agents Chemother* 2011; **55**: 5396-5398 [PMID: 21825296 DOI: 10.1128/AAC.00679-11]
  - 156 **Bou G**, Martínez-Beltrán J. Cloning, nucleotide sequencing, and analysis of the gene encoding an AmpC  $\beta$ -lactamase in *Acinetobacter baumannii*. *Antimicrob Agents Chemother* 2000; **44**: 428-432 [PMID: 10639377]
  - 157 **Héritier C**, Poirel L, Nordmann P. Cephalosporinase overexpression resulting from insertion of ISAbal in *Acinetobacter baumannii*. *Clin Microbiol Infect* 2006; **12**: 123-130 [PMID: 16441449 DOI: 10.1111/j.1469-0691.2005.01320.x]
  - 158 **Hujer KM**, Hamza NS, Hujer AM, Perez F, Helfand MS, Bethel CR, Thomson JM, Anderson VE, Barlow M, Rice LB, Tenover FC, Bonomo RA. Identification of a new allelic variant of the *Acinetobacter baumannii* cephalosporinase, ADC-7  $\beta$ -lactamase: defining a unique family of class C enzymes. *Antimicrob Agents Chemother* 2005; **49**: 2941-2948 [PMID: 15980372 DOI: 10.1128/AAC.49.7.2941-2948.2005]
  - 159 **Segal H**, Nelson EC, Elisha BG. Genetic environment and transcription of ampC in an *Acinetobacter baumannii* clinical isolate. *Antimicrob Agents Chemother* 2004; **48**: 612-614 [PMID: 14742218 DOI: 10.1128/aac.48.2.612-614.2004]
  - 160 **Corvec S**, Caroff N, Espaze E, Giraudeau C, Drugeon H, Reynaud A. AmpC cephalosporinase hyperproduction in *Acinetobacter baumannii* clinical strains. *J Antimicrob Chemother* 2003; **52**: 629-635 [PMID: 12951337 DOI: 10.1093/jac/dkg407]
  - 161 **Bush K**, Jacoby GA, Medeiros AA. A functional classification scheme for  $\beta$ -lactamases and its correlation with molecular structure. *Antimicrob Agents Chemother* 1995; **39**: 1211-1233 [PMID: 7574506 DOI: 10.1128/aac.39.6.1211]
  - 162 **Walther-Rasmussen J**, Høiby N. OXA-type carbapenemases. *J Antimicrob Chemother* 2006; **57**: 373-383 [PMID: 16446375 DOI: 10.1093/jac/dki482]
  - 163 **Vila J**, Navia M, Ruiz J, Casals C. Cloning and nucleotide sequence analysis of a gene encoding an OXA-derived  $\beta$ -lactamase in *Acinetobacter baumannii*. *Antimicrob Agents Chemother* 1997; **41**: 2757-2759 [PMID: 9420053]
  - 164 **Navia MM**, Ruiz J, Vila J. Characterization of an integron carrying a new class D  $\beta$ -lactamase (OXA-37) in *Acinetobacter baumannii*. *Microb Drug Resist* 2002; **8**: 261-265 [PMID: 12523622]
  - 165 **Zarrilli R**, Giannouli M, Tomasone F, Triassi M, Tsakris A. Carbapenem resistance in *Acinetobacter baumannii*: the molecular epidemic features of an emerging problem in health care facilities. *J Infect Dev Ctries* 2009; **3**: 335-341 [PMID: 19759502]
  - 166 **Poirel L**, Naas T, Nordmann P. Diversity, epidemiology, and genetics of class D  $\beta$ -lactamases. *Antimicrob Agents Chemother* 2010; **54**: 24-38 [PMID: 19721065 DOI: 10.1128/AAC.01512-08]
  - 167 **Mugnier PD**, Poirel L, Naas T, Nordmann P. Worldwide dissemination of the blaOXA-23 carbapenemase gene of *Acinetobacter baumannii*. *Emerg Infect Dis* 2010; **16**: 35-40 [PMID: 20031040 DOI: 10.3201/eid1601.090852]
  - 168 **Héritier C**, Poirel L, Lambert T, Nordmann P. Contribution of acquired carbapenem-hydrolyzing oxacillinases to carbapenem resistance in *Acinetobacter baumannii*. *Antimicrob Agents Chemother* 2005; **49**: 3198-3202 [PMID: 16048925 DOI: 10.1128/AAC.49.8.3198-3202.2005]
  - 169 **Naas T**, Levy M, Hirschauer C, Marchandin H, Nordmann P. Outbreak of carbapenem-resistant *Acinetobacter baumannii* producing the carbapenemase OXA-23 in a tertiary care hospital of Papeete, French Polynesia. *J Clin Microbiol* 2005; **43**: 4826-4829 [PMID: 16145150 DOI: 10.1128/JCM.43.9.4826-4829.2005]
  - 170 **Corvec S**, Poirel L, Naas T, Drugeon H, Nordmann P. Genetics and expression of the carbapenem-hydrolyzing oxacillinase gene blaOXA-23 in *Acinetobacter baumannii*. *Antimicrob Agents Chemother* 2007; **51**: 1530-1533 [PMID: 17220422 DOI: 10.1128/AAC.01132-06]
  - 171 **Kohlenberg A**, Brümmer S, Higgins PG, Sohr D, Piening BC, de Grahl C, Halle E, Rüden H, Seifert H. Outbreak of carbapenem-resistant *Acinetobacter baumannii* carrying the carbapenemase OXA-23 in a German university medical centre. *J Med Microbiol* 2009; **58**: 1499-1507 [PMID: 19589905 DOI: 10.1099/jmm.0.012302-0]



- 172 **Stoeva T**, Higgins PG, Bojkova K, Seifert H. Clonal spread of carbapenem-resistant OXA-23-positive *Acinetobacter baumannii* in a Bulgarian university hospital. *Clin Microbiol Infect* 2008; **14**: 723-727 [PMID: 18558947 DOI: 10.1111/j.1469-0691.2008.02018.x]
- 173 **Bonnin RA**, Poirel L, Licker M, Nordmann P. Genetic diversity of carbapenem-hydrolysing  $\beta$ -lactamases in *Acinetobacter baumannii* from Romanian hospitals. *Clin Microbiol Infect* 2011; **17**: 1524-1528 [PMID: 21883667 DOI: 10.1111/j.1469-0691.2011.03622.x]
- 174 **Beenken SW**, Karsenty G, Raycroft L, Lozano G. An intron binding protein is required for transformation ability of p53. *Nucleic Acids Res* 1991; **19**: 4747-4752 [PMID: 1891364 DOI: 10.1128/AAC.00226-07]
- 175 **Chagas TP**, Carvalho KR, de Oliveira Santos IC, Carvalho-Assef AP, Asensi MD. Characterization of carbapenem-resistant *Acinetobacter baumannii* in Brazil (2008-2011): countrywide spread of OXA-23-producing clones (CC15 and CC79). *Diagn Microbiol Infect Dis* 2014; **79**: 468-472 [PMID: 24880823 DOI: 10.1016/j.diagmicrobio.2014.03.006]
- 176 **Valenzuela JK**, Thomas L, Partridge SR, van der Reijden T, Dijkshoorn L, Iredell J. Horizontal gene transfer in a polyclonal outbreak of carbapenem-resistant *Acinetobacter baumannii*. *J Clin Microbiol* 2007; **45**: 453-460 [PMID: 17108068 DOI: 10.1128/JCM.01971-06]
- 177 **Kuo HY**, Yang CM, Lin MF, Cheng WL, Tien N, Liou ML. Distribution of blaOXA-23-carrying imipenem-resistant *Acinetobacter* spp. in 3 hospitals in Taiwan. *Diagn Microbiol Infect Dis* 2010; **66**: 195-199 [PMID: 19836186 DOI: 10.1016/j.diagmicrobio.2009.09.013]
- 178 **Lin MF**, Kuo HY, Yeh HW, Yang CM, Sung CH, Tu CC, Huang ML, Liou ML. Emergence and dissemination of blaOXA-23-carrying imipenem-resistant *Acinetobacter* sp in a regional hospital in Taiwan. *J Microbiol Immunol Infect* 2011; **44**: 39-44 [PMID: 21531351 DOI: 10.1016/j.jmii.2011.01.008]
- 179 **Li Y**, Guo Q, Wang P, Zhu D, Ye X, Wu S, Wang M. Clonal dissemination of extensively drug-resistant *Acinetobacter baumannii* producing an OXA-23  $\beta$ -lactamase at a teaching hospital in Shanghai, China. *J Microbiol Immunol Infect* 2014 May 23; Epub ahead of print [PMID: 24863499 DOI: 10.1016/j.jmii.2014.04.005]
- 180 **Lee Y**, Kim CK, Lee H, Jeong SH, Yong D, Lee K. A novel insertion sequence, ISAbal10, inserted into ISAbal1 adjacent to the bla(OXA-23) gene and disrupting the outer membrane protein gene carO in *Acinetobacter baumannii*. *Antimicrob Agents Chemother* 2011; **55**: 361-363 [PMID: 20937784 DOI: 10.1128/AAC.01672-09]
- 181 **Koh TH**, Tan TT, Khoo CT, Ng SY, Tan TY, Hsu LY, Ooi EE, Van Der Reijden TJ, Dijkshoorn L. *Acinetobacter calcoaceticus*-*Acinetobacter baumannii* complex species in clinical specimens in Singapore. *Epidemiol Infect* 2012; **140**: 535-538 [PMID: 21733253 DOI: 10.1017/S0950268811001129]
- 182 **Principe L**, Piazza A, Giani T, Bracco S, Caltagirone MS, Arena F, Nucleo E, Tammara F, Rossolini GM, Pagani L, Luzzaro F. Epidemic diffusion of OXA-23-producing *Acinetobacter baumannii* isolates in Italy: results of the first cross-sectional countrywide survey. *J Clin Microbiol* 2014; **52**: 3004-3010 [PMID: 24920776 DOI: 10.1128/JCM.00291-14]
- 183 **Mosqueda N**, Espinal P, Cosgaya C, Viota S, Plasencia V, Alvarez-Lerma F, Montero M, Gómez J, Horcajada JP, Vila J, Roca I. Globally expanding carbapenemase finally appears in Spain: nosocomial outbreak of *Acinetobacter baumannii* producing plasmid-encoded OXA-23 in Barcelona, Spain. *Antimicrob Agents Chemother* 2013; **57**: 5155-5157 [PMID: 23877694 DOI: 10.1128/AAC.01486-13]
- 184 **Poirel L**, Figueiredo S, Cattoir V, Carattoli A, Nordmann P. *Acinetobacter radioresistens* as a silent source of carbapenem resistance for *Acinetobacter* spp. *Antimicrob Agents Chemother* 2008; **52**: 1252-1256 [PMID: 18195058 DOI: 10.1128/AAC.01304-07]
- 185 **Mendes RE**, Bell JM, Turnidge JD, Castanheira M, Jones RN. Emergence and widespread dissemination of OXA-23, -24/40 and -58 carbapenemases among *Acinetobacter* spp. in Asia-Pacific nations: report from the SENTRY Surveillance Program. *J Antimicrob Chemother* 2009; **63**: 55-59 [PMID: 18957398 DOI: 10.1093/jac/dkn434]
- 186 **Héritier C**, Poirel L, Fournier PE, Claverie JM, Raoult D, Nordmann P. Characterization of the naturally occurring oxacillinase of *Acinetobacter baumannii*. *Antimicrob Agents Chemother* 2005; **49**: 4174-4179 [PMID: 16189095 DOI: 10.1128/AAC.49.10.4174-4179.2005]
- 187 **Brown S**, Young HK, Amyes SG. Characterisation of OXA-51, a novel class D carbapenemase found in genetically unrelated clinical strains of *Acinetobacter baumannii* from Argentina. *Clin Microbiol Infect* 2005; **11**: 15-23 [PMID: 15649299]
- 188 **Ruiz M**, Marti S, Fernandez-Cuenca F, Pascual A, Vila J. High prevalence of carbapenem-hydrolysing oxacillinases in epidemiologically related and unrelated *Acinetobacter baumannii* clinical isolates in Spain. *Clin Microbiol Infect* 2007; **13**: 1192-1198 [PMID: 17850347]
- 189 **Chen TL**, Lee YT, Kuo SC, Hsueh PR, Chang FY, Siu LK, Ko WC, Fung CP. Emergence and Distribution of Plasmids Bearing the blaOXA-51-like gene with an upstream ISAbal1 in carbapenem-resistant *Acinetobacter baumannii* isolates in Taiwan. *Antimicrob Agents Chemother* 2010; **54**: 4575-4581 [PMID: 20713680 DOI: 10.1128/AAC.00764-10]
- 190 **Hu WS**, Yao SM, Fung CP, Hsieh YP, Liu CP, Lin JF. An OXA-66/OXA-51-like carbapenemase and possibly an efflux pump are associated with resistance to imipenem in *Acinetobacter baumannii*. *Antimicrob Agents Chemother* 2007; **51**: 3844-3852 [PMID: 17724156 DOI: 10.1128/AAC.01512-06]
- 191 **Brown S**, Amyes SG. The sequences of seven class D beta-lactamases isolated from carbapenem-resistant *Acinetobacter baumannii* from four continents. *Clin Microbiol Infect* 2005; **11**: 326-329 [PMID: 15760431 DOI: 10.1111/j.1469-0691.2005.01096.x]
- 192 **Pitt TL**, Woodford N, Glover J, Yarde S, Kaufmann ME, Turt TL. Identification of *Acinetobacter baumannii* by detection of the blaOXA-51-like carbapenemase gene intrinsic to this species. *J Clin Microbiol* 2006; **44**: 2974-2976 [PMID: 16891520 DOI: 10.1128/JCM.01021-06]
- 193 **Vahaboglu H**, Budak F, Kasap M, Gacar G, Torol S, Karadenizli A, Kolayli F, Eroglu C. High prevalence of OXA-51-type class D beta-lactamases among ceftazidime-resistant clinical isolates of *Acinetobacter* spp.: co-existence with OXA-58 in multiple centres. *J Antimicrob Chemother* 2006; **58**: 537-542 [PMID: 16816400 DOI: 10.1093/jac/dkl273]
- 194 **Evans BA**, Brown S, Hamouda A, Findlay J, Amyes SG. Eleven novel OXA-51-like enzymes from clinical isolates of *Acinetobacter baumannii*. *Clin Microbiol Infect* 2007; **13**: 1137-1138 [PMID: 17850339 DOI: 10.1111/j.1469-0691.2007.01828.x]
- 195 **Tsakris A**, Ikonomidis A, Spanakis N, Pournaras S, Bethimouti K. Identification of a novel bla(OXA-51) variant, bla(OXA-92), from a clinical isolate of *Acinetobacter baumannii*. *Clin Microbiol Infect* 2007; **13**: 348-349 [PMID: 17391399 DOI: 10.1111/j.1469-0691.2006.01598.x]
- 196 **Higgins PG**, Poirel L, Lehmann M, Nordmann P, Seifert H. OXA-143, a novel carbapenem-hydrolyzing class D beta-lactamase in *Acinetobacter baumannii*. *Antimicrob Agents Chemother* 2009; **53**: 5035-5038 [PMID: 19770279 DOI: 10.1128/AAC.00856-09]
- 197 **Bou G**, Oliver A, Martínez-Beltrán J. OXA-24, a novel class D beta-lactamase with carbapenemase activity in an *Acinetobacter baumannii* clinical strain. *Antimicrob Agents Chemother* 2000; **44**: 1556-1561 [PMID: 10817708]
- 198 **Afzal-Shah M**, Woodford N, Livermore DM. Characterization of OXA-25, OXA-26, and OXA-27, molecular class D



- beta-lactamases associated with carbapenem resistance in clinical isolates of *Acinetobacter baumannii*. *Antimicrob Agents Chemother* 2001; **45**: 583-588 [PMID: 11158758 DOI: 10.1128/AAC.45.2.583-588.2001]
- 199 **Brown S**, Amyes S. OXA (beta)-lactamases in *Acinetobacter*: the story so far. *J Antimicrob Chemother* 2006; **57**: 1-3 [PMID: 16332731 DOI: 10.1093/jac/dki425]
  - 200 **Héritier C**, Poirel L, Aubert D, Nordmann P. Genetic and functional analysis of the chromosome-encoded carbapenem-hydrolyzing oxacillinase OXA-40 of *Acinetobacter baumannii*. *Antimicrob Agents Chemother* 2003; **47**: 268-273 [PMID: 12499201 DOI: 10.1128/aac.47.1.268-273.2003]
  - 201 **Acosta J**, Merino M, Viedma E, Poza M, Sanz F, Otero JR, Chaves F, Bou G. Multidrug-resistant *Acinetobacter baumannii* Harboring OXA-24 carbapenemase, Spain. *Emerg Infect Dis* 2011; **17**: 1064-1067 [PMID: 21749771 DOI: 10.3201/eid1706.091866]
  - 202 **Quinteira S**, Grosso F, Ramos H, Peixe L. Molecular epidemiology of imipenem-resistant *Acinetobacter haemolyticus* and *Acinetobacter baumannii* isolates carrying plasmid-mediated OXA-40 from a Portuguese hospital. *Antimicrob Agents Chemother* 2007; **51**: 3465-3466 [PMID: 17606684 DOI: 10.1128/AAC.00267-07]
  - 203 **Lolans K**, Rice TW, Munoz-Price LS, Quinn JP. Multicity outbreak of carbapenem-resistant *Acinetobacter baumannii* isolates producing the carbapenemase OXA-40. *Antimicrob Agents Chemother* 2006; **50**: 2941-2945 [PMID: 16940085 DOI: 10.1128/AAC.00116-06]
  - 204 **Merino M**, Acosta J, Poza M, Sanz F, Beceiro A, Chaves F, Bou G. OXA-24 carbapenemase gene flanked by XerC/XerD-like recombination sites in different plasmids from different *Acinetobacter* species isolated during a nosocomial outbreak. *Antimicrob Agents Chemother* 2010; **54**: 2724-2727 [PMID: 20385865 DOI: 10.1128/AAC.01674-09]
  - 205 **Lu PL**, Doumith M, Livermore DM, Chen TP, Woodford N. Diversity of carbapenem resistance mechanisms in *Acinetobacter baumannii* from a Taiwan hospital: spread of plasmid-borne OXA-72 carbapenemase. *J Antimicrob Chemother* 2009; **63**: 641-647 [PMID: 19182237 DOI: 10.1093/jac/dkn553]
  - 206 **Goic-Barisic I**, Townner KJ, Kovacic A, Sisko-Kraljevic K, Tonkic M, Novak A, Punda-Polic V. Outbreak in Croatia caused by a new carbapenem-resistant clone of *Acinetobacter baumannii* producing OXA-72 carbapenemase. *J Hosp Infect* 2011; **77**: 368-369 [PMID: 21316806 DOI: 10.1016/j.jhin.2010.12.003]
  - 207 **Poirel L**, Marqué S, Héritier C, Segonds C, Chabanon G, Nordmann P. OXA-58, a novel class D {beta}-lactamase involved in resistance to carbapenems in *Acinetobacter baumannii*. *Antimicrob Agents Chemother* 2005; **49**: 202-208 [PMID: 15616297 DOI: 10.1128/AAC.49.1.202-208.2005]
  - 208 **Coelho J**, Woodford N, Afzal-Shah M, Livermore D. Occurrence of OXA-58-like carbapenemases in *Acinetobacter* spp. collected over 10 years in three continents. *Antimicrob Agents Chemother* 2006; **50**: 756-758 [PMID: 16436738 DOI: 10.1128/AAC.50.2.756-758.2006]
  - 209 **Marqué S**, Poirel L, Héritier C, Brisse S, Blasco MD, Filip R, Coman G, Naas T, Nordmann P. Regional occurrence of plasmid-mediated carbapenem-hydrolyzing oxacillinase OXA-58 in *Acinetobacter* spp. in Europe. *J Clin Microbiol* 2005; **43**: 4885-4888 [PMID: 16145167 DOI: 10.1128/JCM.43.9.4885-4888.2005]
  - 210 **Gogou V**, Pournaras S, Giannouli M, Voulgari E, Piperaki ET, Zarrilli R, Tsakris A. Evolution of multidrug-resistant *Acinetobacter baumannii* clonal lineages: a 10 year study in Greece (2000-09). *J Antimicrob Chemother* 2011; **66**: 2767-2772 [PMID: 21933784 DOI: 10.1093/jac/dkr390]
  - 211 **Donnarumma F**, Sergi S, Indorato C, Mastromei G, Monnanni R, Nicoletti P, Pecile P, Cecconi D, Mannino R, Bencini S, Fanci R, Bosi A, Casalone E. Molecular characterization of *Acinetobacter* isolates collected in intensive care units of six hospitals in Florence, Italy, during a 3-year surveillance program: a population structure analysis. *J Clin Microbiol* 2010; **48**: 1297-1304 [PMID: 20181903 DOI: 10.1128/JCM.01916-09]
  - 212 **Peleg AY**, Franklin C, Walters LJ, Bell JM, Spelman DW. OXA-58 and IMP-4 carbapenem-hydrolyzing beta-lactamases in an *Acinetobacter junii* blood culture isolate from Australia. *Antimicrob Agents Chemother* 2006; **50**: 399-400 [PMID: 16377723 DOI: 10.1128/AAC.50.1.399-400.2006]
  - 213 **Castanheira M**, Wanger A, Kruzel M, Deshpande LM, Jones RN. Emergence and clonal dissemination of OXA-24- and OXA-58-producing *Acinetobacter baumannii* strains in Houston, Texas: report from the SENTRY Antimicrobial Surveillance Program. *J Clin Microbiol* 2008; **46**: 3179-3180 [PMID: 18768660 DOI: 10.1128/JCM.00988-08]
  - 214 **Hujer KM**, Hujer AM, Hulten EA, Bajaksouzian S, Adams JM, Donskey CJ, Ecker DJ, Massire C, Eshoo MW, Sampath R, Thomson JM, Rather PN, Craft DW, Fishbain JT, Ewell AJ, Jacobs MR, Paterson DL, Bonomo RA. Analysis of antibiotic resistance genes in multidrug-resistant *Acinetobacter* sp. isolates from military and civilian patients treated at the Walter Reed Army Medical Center. *Antimicrob Agents Chemother* 2006; **50**: 4114-4123 [PMID: 17000742 DOI: 10.1128/AAC.00778-06]
  - 215 **Fu Y**, Jiang J, Zhou H, Jiang Y, Fu Y, Yu Y, Zhou J. Characterization of a novel plasmid type and various genetic contexts of bla OXA-58 in *Acinetobacter* spp. from multiple cities in China. *PLoS One* 2014; **9**: e84680 [PMID: 24400107 DOI: 10.1371/journal.pone.0084680]
  - 216 **Bertini A**, Giordano A, Varesi P, Villa L, Mancini C, Carattoli A. First report of the carbapenem-hydrolyzing oxacillinase OXA-58 in *Acinetobacter baumannii* isolates in Italy. *Antimicrob Agents Chemother* 2006; **50**: 2268-2269 [PMID: 16723603 DOI: 10.1128/AAC.00166-06]
  - 217 **Héritier C**, Dubouix A, Poirel L, Marty N, Nordmann P. A nosocomial outbreak of *Acinetobacter baumannii* isolates expressing the carbapenem-hydrolyzing oxacillinase OXA-58. *J Antimicrob Chemother* 2005; **55**: 115-118 [PMID: 15590718 DOI: 10.1093/jac/dkh500]
  - 218 **Poirel L**, Nordmann P. Genetic structures at the origin of acquisition and expression of the carbapenem-hydrolyzing oxacillinase gene blaOXA-58 in *Acinetobacter baumannii*. *Antimicrob Agents Chemother* 2006; **50**: 1442-1448 [PMID: 16569863 DOI: 10.1128/AAC.50.4.1442-1448.2006]
  - 219 **Pournaras S**, Markogiannakis A, Ikonomidis A, Kondyli L, Bethimouti K, Maniatis AN, Legakis NJ, Tsakris A. Outbreak of multiple clones of imipenem-resistant *Acinetobacter baumannii* isolates expressing OXA-58 carbapenemase in an intensive care unit. *J Antimicrob Chemother* 2006; **57**: 557-561 [PMID: 16431857 DOI: 10.1093/jac/dkl004]
  - 220 **Poirel L**, Mansour W, Bouallegue O, Nordmann P. Carbapenem-resistant *Acinetobacter baumannii* isolates from Tunisia producing the OXA-58-like carbapenem-hydrolyzing oxacillinase OXA-97. *Antimicrob Agents Chemother* 2008; **52**: 1613-1617 [PMID: 18299404 DOI: 10.1128/AAC.00978-07]
  - 221 **Kim CK**, Lee Y, Lee H, Woo GJ, Song W, Kim MN, Lee WG, Jeong SH, Lee K, Chong Y. Prevalence and diversity of carbapenemases among imipenem-nonsusceptible *Acinetobacter* isolates in Korea: emergence of a novel OXA-182. *Diagn Microbiol Infect Dis* 2010; **68**: 432-438 [PMID: 20884158 DOI: 10.1016/j.diagmicrobio.2010.07.014]
  - 222 **Higgins PG**, Pérez-Llarena FJ, Zander E, Fernández A, Bou G, Seifert H. OXA-235, a novel class D  $\beta$ -lactamase involved in resistance to carbapenems in *Acinetobacter baumannii*. *Antimicrob Agents Chemother* 2013; **57**: 2121-2126 [PMID: 23439638 DOI: 10.1128/AAC.02413-12]
  - 223 **Piddock LJ**. Multidrug-resistance efflux pumps - not just for resistance. *Nat Rev Microbiol* 2006; **4**: 629-636 [PMID: 16845433 DOI: 10.1038/nrmicro1464]

- 224 Hooper DC. Efflux pumps and nosocomial antibiotic resistance: a primer for hospital epidemiologists. *Clin Infect Dis* 2005; **40**: 1811-1817 [PMID: 15909271 DOI: 10.1086/430381]
- 225 Coyne S, Courvalin P, Périchon B. Efflux-mediated antibiotic resistance in *Acinetobacter* spp. *Antimicrob Agents Chemother* 2011; **55**: 947-953 [PMID: 21173183 DOI: 10.1128/AAC.01388-10]
- 226 Ruzin A, Keeney D, Bradford PA. AdeABC multidrug efflux pump is associated with decreased susceptibility to tigecycline in *Acinetobacter calcoaceticus*-*Acinetobacter baumannii* complex. *J Antimicrob Chemother* 2007; **59**: 1001-1004 [PMID: 17363424 DOI: 10.1093/jac/dkm058]
- 227 Peleg AY, Adams J, Paterson DL. Tigecycline Efflux as a Mechanism for Nonsusceptibility in *Acinetobacter baumannii*. *Antimicrob Agents Chemother* 2007; **51**: 2065-2069 [PMID: 17420217 DOI: 10.1128/AAC.01198-06]
- 228 Ruzin A, Immermann FW, Bradford PA. RT-PCR and statistical analyses of adeABC expression in clinical isolates of *Acinetobacter calcoaceticus*-*Acinetobacter baumannii* complex. *Microb Drug Resist* 2010; **16**: 87-89 [PMID: 20438348 DOI: 10.1089/mdr.2009.0131]
- 229 Pannek S, Higgins PG, Steinke P, Jonas D, Akova M, Bohnert JA, Seifert H, Kern WV. Multidrug efflux inhibition in *Acinetobacter baumannii*: comparison between 1-(1-naphthylmethyl)-piperazine and phenyl-arginine-beta-naphthylamide. *J Antimicrob Chemother* 2006; **57**: 970-974 [PMID: 16531429 DOI: 10.1093/jac/dkl081]
- 230 Coban AY, Guney AK, Tanriverdi Cayci Y, Durupinar B. Effect of 1-(1-Naphthylmethyl)-piperazine, an efflux pump inhibitor, on antimicrobial drug susceptibilities of clinical *Acinetobacter baumannii* isolates. *Curr Microbiol* 2011; **62**: 508-511 [PMID: 20717673 DOI: 10.1007/s00284-010-9736-9]
- 231 Cortez-Cordova J, Kumar A. Activity of the efflux pump inhibitor phenylalanine-arginine  $\beta$ -naphthylamide against the AdeFGH pump of *Acinetobacter baumannii*. *Int J Antimicrob Agents* 2011; **37**: 420-424 [PMID: 21377839 DOI: 10.1016/j.ijantimicag.2011.01.006]
- 232 Deng M, Zhu MH, Li JJ, Bi S, Sheng ZK, Hu FS, Zhang JJ, Chen W, Xue XW, Sheng JF, Li LJ. Molecular epidemiology and mechanisms of tigecycline resistance in clinical isolates of *Acinetobacter baumannii* from a Chinese university hospital. *Antimicrob Agents Chemother* 2014; **58**: 297-303 [PMID: 24165187 DOI: 10.1128/AAC.01727-13]
- 233 Vila J, Martí S, Sánchez-Céspedes J. Porins, efflux pumps and multidrug resistance in *Acinetobacter baumannii*. *J Antimicrob Chemother* 2007; **59**: 1210-1215 [PMID: 17324960 DOI: 10.1093/jac/dkl509]
- 234 Wieczorek P, Sacha P, Hauschild T, Zórawski M, Krawczyk M, Tryniszewska E. Multidrug resistant *Acinetobacter baumannii*--the role of AdeABC (RND family) efflux pump in resistance to antibiotics. *Folia Histochem Cytobiol* 2008; **46**: 257-267 [PMID: 19056528 DOI: 10.2478/v10042-008-0056-x]
- 235 Magnet S, Courvalin P, Lambert T. Resistance-nodulation-cell division-type efflux pump involved in aminoglycoside resistance in *Acinetobacter baumannii* strain BM4454. *Antimicrob Agents Chemother* 2001; **45**: 3375-3380 [PMID: 11709311 DOI: 10.1128/AAC.45.12.3375-3380.2001]
- 236 Hornsey M, Ellington MJ, Doumith M, Thomas CP, Gordon NC, Wareham DW, Quinn J, Lolans K, Livermore DM, Woodford N. AdeABC-mediated efflux and tigecycline MICs for epidemic clones of *Acinetobacter baumannii*. *J Antimicrob Chemother* 2010; **65**: 1589-1593 [PMID: 20554571 DOI: 10.1093/jac/dkq218]
- 237 Higgins PG, Wisplinghoff H, Stefanik D, Seifert H. Selection of topoisomerase mutations and overexpression of adeB mRNA transcripts during an outbreak of *Acinetobacter baumannii*. *J Antimicrob Chemother* 2004; **54**: 821-823 [PMID: 15355942 DOI: 10.1093/jac/dkh427]
- 238 Marchand I, Damier-Piolle L, Courvalin P, Lambert T. Expression of the RND-type efflux pump AdeABC in *Acinetobacter baumannii* is regulated by the AdeRS two-component system. *Antimicrob Agents Chemother* 2004; **48**: 3298-3304 [PMID: 15328088 DOI: 10.1128/AAC.48.9.3298-3304.2004]
- 239 Sun JR, Perng CL, Chan MC, Morita Y, Lin JC, Su CM, Wang WY, Chang TY, Chiueh TS. A truncated AdeS kinase protein generated by ISAbal insertion correlates with tigecycline resistance in *Acinetobacter baumannii*. *PLoS One* 2012; **7**: e49534 [PMID: 23166700 DOI: 10.1371/journal.pone.0049534]
- 240 Sun JR, Chan MC, Chang TY, Wang WY, Chiueh TS. Overexpression of the adeB gene in clinical isolates of tigecycline-nonsusceptible *Acinetobacter baumannii* without insertion mutations in adeRS. *Antimicrob Agents Chemother* 2010; **54**: 4934-4938 [PMID: 20696871 DOI: 10.1128/AAC.00414-10]
- 241 Fernando D, Kumar A. Growth phase-dependent expression of RND efflux pump- and outer membrane porin-encoding genes in *Acinetobacter baumannii* ATCC 19606. *J Antimicrob Chemother* 2012; **67**: 569-572 [PMID: 22146875 DOI: 10.1093/jac/dkr519]
- 242 Lin MF, Lin YY, Yeh HW, Lan CY. Role of the BaeSR two-component system in the regulation of *Acinetobacter baumannii* adeAB genes and its correlation with tigecycline susceptibility. *BMC Microbiol* 2014; **14**: 119 [PMID: 24885279 DOI: 10.1186/1471-2180-14-119]
- 243 Coyne S, Rosenfeld N, Lambert T, Courvalin P, Périchon B. Overexpression of resistance-nodulation-cell division pump AdeFGH confers multidrug resistance in *Acinetobacter baumannii*. *Antimicrob Agents Chemother* 2010; **54**: 4389-4393 [PMID: 20696879 DOI: 10.1128/AAC.00155-10]
- 244 Damier-Piolle L, Magnet S, Brémont S, Lambert T, Courvalin P. AdeIJK, a resistance-nodulation-cell division pump effluxing multiple antibiotics in *Acinetobacter baumannii*. *Antimicrob Agents Chemother* 2008; **52**: 557-562 [PMID: 18086852 DOI: 10.1128/AAC.00732-07]
- 245 Hou PF, Chen XY, Yan GF, Wang YP, Ying CM. Study of the correlation of imipenem resistance with efflux pumps AdeABC, AdeIJK, AdeDE and AbeM in clinical isolates of *Acinetobacter baumannii*. *Chemotherapy* 2012; **58**: 152-158 [PMID: 22614896 DOI: 10.1159/000335599]
- 246 Rosenfeld N, Bouchier C, Courvalin P, Périchon B. Expression of the resistance-nodulation-cell division pump AdeIJK in *Acinetobacter baumannii* is regulated by AdeN, a TetR-type regulator. *Antimicrob Agents Chemother* 2012; **56**: 2504-2510 [PMID: 22371895 DOI: 10.1128/AAC.06422-11]
- 247 Chau SL, Chu YW, Houang ET. Novel resistance-nodulation-cell division efflux system AdeDE in *Acinetobacter* genomic DNA group 3. *Antimicrob Agents Chemother* 2004; **48**: 4054-4055 [PMID: 15388479 DOI: 10.1128/AAC.48.10.4054-4055.2004]
- 248 Ribera A, Roca I, Ruiz J, Gibert I, Vila J. Partial characterization of a transposon containing the tet(A) determinant in a clinical isolate of *Acinetobacter baumannii*. *J Antimicrob Chemother* 2003; **52**: 477-480 [PMID: 12888597 DOI: 10.1093/jac/dkg344]
- 249 Roca I, Martí S, Espinal P, Martínez P, Gibert I, Vila J. CraA, a major facilitator superfamily efflux pump associated with chloramphenicol resistance in *Acinetobacter baumannii*. *Antimicrob Agents Chemother* 2009; **53**: 4013-4014 [PMID: 19581458 DOI: 10.1128/AAC.00584-09]
- 250 Rajamohan G, Srinivasan VB, Gebreyes WA. Molecular and functional characterization of a novel efflux pump, AmvA, mediating antimicrobial and disinfectant resistance in *Acinetobacter baumannii*. *J Antimicrob Chemother* 2010; **65**: 1919-1925 [PMID: 20573661 DOI: 10.1093/jac/dkq195]
- 251 Su XZ, Chen J, Mizushima T, Kuroda T, Tsuchiya T. AbeM, an H<sup>+</sup>-coupled *Acinetobacter baumannii* multidrug efflux pump belonging to the MATE family of transporters. *Antimicrob Agents Chemother* 2005; **49**: 4362-4364 [PMID: 16189122 DOI: 10.1128/AAC.49.10.4362-4364.2005]

- 252 **Srinivasan VB**, Rajamohan G, Gebreyes WA. Role of AbeS, a novel efflux pump of the SMR family of transporters, in resistance to antimicrobial agents in *Acinetobacter baumannii*. *Antimicrob Agents Chemother* 2009; **53**: 5312-5316 [PMID: 19770280 DOI: 10.1128/AAC.00748-09]
- 253 **Cho YJ**, Moon DC, Jin JS, Choi CH, Lee YC, Lee JC. Genetic basis of resistance to aminoglycosides in *Acinetobacter* spp. and spread of armA in *Acinetobacter baumannii* sequence group 1 in Korean hospitals. *Diagn Microbiol Infect Dis* 2009; **64**: 185-190 [PMID: 19361944 DOI: 10.1016/j.diagmicrobio.2009.02.010]
- 254 **Ramirez MS**, Tolmasky ME. Aminoglycoside modifying enzymes. *Drug Resist Updat* 2010; **13**: 151-171 [PMID: 20833577 DOI: 10.1016/j.drug.2010.08.003]
- 255 **Gallejo L**, Townner KJ. Carriage of class 1 integrons and antibiotic resistance in clinical isolates of *Acinetobacter baumannii* from northern Spain. *J Med Microbiol* 2001; **50**: 71-77 [PMID: 11192508]
- 256 **Nemec A**, Dolzani L, Brisse S, van den Broek P, Dijkshoorn L. Diversity of aminoglycoside-resistance genes and their association with class 1 integrons among strains of pan-European *Acinetobacter baumannii* clones. *J Med Microbiol* 2004; **53**: 1233-1240 [PMID: 15585503 DOI: 10.1099/jmm.0.45716-0]
- 257 **Zhu J**, Wang C, Wu J, Jiang R, Mi Z, Huang Z. A novel aminoglycoside-modifying enzyme gene aac(6')-Ib in a pandrug-resistant *Acinetobacter baumannii* strain. *J Hosp Infect* 2009; **73**: 184-185 [PMID: 19703723 DOI: 10.1016/j.jhin.2009.06.026]
- 258 **Bakour S**, Alsharapy SA, Touati A, Rolain JM. Characterization of *Acinetobacter baumannii* Clinical Isolates Carrying blaOXA-23 Carbapenemase and 16S rRNA Methylase armA genes in Yemen. *Microb Drug Resist* 2014 Jun 5; Epub ahead of print [PMID: 24901296 DOI: 10.1089/mdr.2014.0018]
- 259 **Doi Y**, Wachino J, Yamane K, Shibata N, Yagi T, Shibayama K, Kato H, Arakawa Y. Spread of novel aminoglycoside resistance gene aac(6')-Iad among *Acinetobacter* clinical isolates in Japan. *Antimicrob Agents Chemother* 2004; **48**: 2075-2080 [PMID: 15155202 DOI: 10.1128/AAC.48.6.2075-2080.2004]
- 260 **Ploy MC**, Giamarellou H, Bourlioux P, Courvalin P, Lambert T. Detection of aac(6')-I genes in amikacin-resistant *Acinetobacter* spp. by PCR. *Antimicrob Agents Chemother* 1994; **38**: 2925-2928 [PMID: 7695286 DOI: 10.1128/aac.38.12.2925]
- 261 **Lin MF**, Chang KC, Yang CY, Yang CM, Xiao CC, Kuo HY, Liou ML. Role of integrons in antimicrobial susceptibility patterns of *Acinetobacter baumannii*. *Jpn J Infect Dis* 2010; **63**: 440-443 [PMID: 21099097]
- 262 **Gaddy JA**, Tomaras AP, Actis LA. The *Acinetobacter baumannii* 19606 OmpA protein plays a role in biofilm formation on abiotic surfaces and in the interaction of this pathogen with eukaryotic cells. *Infect Immun* 2009; **77**: 3150-3160 [PMID: 19470746 DOI: 10.1128/IAI.00096-09]
- 263 **Jin JS**, Kwon SO, Moon DC, Gurung M, Lee JH, Kim SI, Lee JC. *Acinetobacter baumannii* secretes cytotoxic outer membrane protein A via outer membrane vesicles. *PLoS One* 2011; **6**: e17027 [PMID: 21386968 DOI: 10.1371/journal.pone.0017027]
- 264 **Siroy A**, Molle V, Lemaître-Guillier C, Vallenet D, Pestel-Caron M, Cozzzone AJ, Jouenne T, Dé E. Channel formation by CarO, the carbapenem resistance-associated outer membrane protein of *Acinetobacter baumannii*. *Antimicrob Agents Chemother* 2005; **49**: 4876-4883 [PMID: 16304148 DOI: 10.1128/AAC.49.12.4876-4883.2005]
- 265 **Mussi MA**, Limansky AS, Viale AM. Acquisition of resistance to carbapenems in multidrug-resistant clinical strains of *Acinetobacter baumannii*: natural insertional inactivation of a gene encoding a member of a novel family of beta-barrel outer membrane proteins. *Antimicrob Agents Chemother* 2005; **49**: 1432-1440 [PMID: 15793123 DOI: 10.1128/AAC.49.4.1432-1440.2005]
- 266 **Mussi MA**, Relling VM, Limansky AS, Viale AM. CarO, an *Acinetobacter baumannii* outer membrane protein involved in carbapenem resistance, is essential for L-ornithine uptake. *FEBS Lett* 2007; **581**: 5573-5578 [PMID: 17997983 DOI: 10.1016/j.febslet.2007.10.063]
- 267 **Catel-Ferreira M**, Coadou G, Molle V, Mugnier P, Nordmann P, Siroy A, Jouenne T, Dé E. Structure-function relationships of CarO, the carbapenem resistance-associated outer membrane protein of *Acinetobacter baumannii*. *J Antimicrob Chemother* 2011; **66**: 2053-2056 [PMID: 21705362 DOI: 10.1093/jac/dkr267]
- 268 **Bou G**, Cerveró G, Domínguez MA, Quereda C, Martínez-Beltrán J. Characterization of a nosocomial outbreak caused by a multiresistant *Acinetobacter baumannii* strain with a carbapenem-hydrolyzing enzyme: high-level carbapenem resistance in *A. baumannii* is not due solely to the presence of beta-lactamases. *J Clin Microbiol* 2000; **38**: 3299-3305 [PMID: 10970374]
- 269 **del Mar Tomás M**, Beceiro A, Pérez A, Velasco D, Moure R, Villanueva R, Martínez-Beltrán J, Bou G. Cloning and functional analysis of the gene encoding the 33- to 36-kilodalton outer membrane protein associated with carbapenem resistance in *Acinetobacter baumannii*. *Antimicrob Agents Chemother* 2005; **49**: 5172-5175 [PMID: 16304197 DOI: 10.1128/AAC.49.12.5172-5175.2005]
- 270 **Hood MI**, Jacobs AC, Sayood K, Dunman PM, Skaar EP. *Acinetobacter baumannii* increases tolerance to antibiotics in response to monovalent cations. *Antimicrob Agents Chemother* 2010; **54**: 1029-1041 [PMID: 20028819 DOI: 10.1128/AAC.00963-09]
- 271 **Dupont M**, Pagès JM, Lafitte D, Siroy A, Bollet C. Identification of an OprD homologue in *Acinetobacter baumannii*. *J Proteome Res* 2005; **4**: 2386-2390 [PMID: 16335991]
- 272 **Jeong HW**, Cheong HJ, Kim WJ, Kim MJ, Song KJ, Song JW, Kim HS, Roh KH. Loss of the 29-kilodalton outer membrane protein in the presence of OXA-51-like enzymes in *Acinetobacter baumannii* is associated with decreased imipenem susceptibility. *Microb Drug Resist* 2009; **15**: 151-158 [PMID: 19728771 DOI: 10.1089/mdr.2009.0828]
- 273 **Fonseca EL**, Scheidegger E, Freitas FS, Cipriano R, Vicente AC. Carbapenem-resistant *Acinetobacter baumannii* from Brazil: role of carO alleles expression and blaOXA-23 gene. *BMC Microbiol* 2013; **13**: 245 [PMID: 24195496 DOI: 10.1186/1471-2180-13-245]
- 274 **Smani Y**, Fàbrega A, Roca I, Sánchez-Encinales V, Vila J, Pachón J. Role of OmpA in the multidrug resistance phenotype of *Acinetobacter baumannii*. *Antimicrob Agents Chemother* 2014; **58**: 1806-1808 [PMID: 24379205 DOI: 10.1128/AAC.02101-13]
- 275 **Lambert PA**. Bacterial resistance to antibiotics: modified target sites. *Adv Drug Deliv Rev* 2005; **57**: 1471-1485 [PMID: 15964098 DOI: 10.1016/j.addr.2005.04.003]
- 276 **Gehrlein M**, Leying H, Cullmann W, Wendt S, Opferkuch W. Imipenem resistance in *Acinetobacter baumannii* is due to altered penicillin-binding proteins. *Chemotherapy* 1991; **37**: 405-412 [PMID: 1760939]
- 277 **Cayó R**, Rodríguez MC, Espinal P, Fernández-Cuenca F, Ocampo-Sosa AA, Pascual A, Ayala JA, Vila J, Martínez-Martínez L. Analysis of genes encoding penicillin-binding proteins in clinical isolates of *Acinetobacter baumannii*. *Antimicrob Agents Chemother* 2011; **55**: 5907-5913 [PMID: 21947403 DOI: 10.1128/AAC.00459-11]
- 278 **Vila J**, Ruiz J, Goñi P, Marcos A, Jimenez de Anta T. Mutation in the gyrA gene of quinolone-resistant clinical isolates of *Acinetobacter baumannii*. *Antimicrob Agents Chemother* 1995; **39**: 1201-1203 [PMID: 7625818 DOI: 10.1128/aac.39.5.1201]
- 279 **Taitt CR**, Leski TA, Stockelman MG, Craft DW, Zurawski DV, Kirkup BC, Vora GJ. Antimicrobial resistance determinants in *Acinetobacter baumannii* isolates taken from mili-



- tary treatment facilities. *Antimicrob Agents Chemother* 2014; **58**: 767-781 [PMID: 24247131 DOI: 10.1128/aac.01897-13]
- 280 **Ribera A**, Ruiz J, Vila J. Presence of the Tet M determinant in a clinical isolate of *Acinetobacter baumannii*. *Antimicrob Agents Chemother* 2003; **47**: 2310-2312 [PMID: 12821485 DOI: 10.1128/aac.47.7.2310-2312.2003]
- 281 **Mak JK**, Kim MJ, Pham J, Tapsall J, White PA. Antibiotic resistance determinants in nosocomial strains of multidrug-resistant *Acinetobacter baumannii*. *J Antimicrob Chemother* 2009; **63**: 47-54 [PMID: 18988680 DOI: 10.1093/jac/dkn454]
- 282 **Yu YS**, Zhou H, Yang Q, Chen YG, Li LJ. Widespread occurrence of aminoglycoside resistance due to ArmA methylase in imipenem-resistant *Acinetobacter baumannii* isolates in China. *J Antimicrob Chemother* 2007; **60**: 454-455 [PMID: 17561497 DOI: 10.1093/jac/dkm208]
- 283 **Hong SB**, Shin KS, Ha J, Han K. Co-existence of blaOXA-23 and armA in multidrug-resistant *Acinetobacter baumannii* isolated from a hospital in South Korea. *J Med Microbiol* 2013; **62**: 836-844 [PMID: 23518656 DOI: 10.1099/jmm.0.055384-0]
- 284 **Karthikeyan K**, Thirunarayan MA, Krishnan P. Coexistence of blaOXA-23 with blaNDM-1 and armA in clinical isolates of *Acinetobacter baumannii* from India. *J Antimicrob Chemother* 2010; **65**: 2253-2254 [PMID: 20650909 DOI: 10.1093/jac/dkq273]
- 285 **Brigante G**, Migliavacca R, Bramati S, Motta E, Nucleo E, Manenti M, Migliorino G, Pagani L, Luzzaro F, Viganò FE. Emergence and spread of a multidrug-resistant *Acinetobacter baumannii* clone producing both the carbapenemase OXA-23 and the 16S rRNA methylase ArmA. *J Med Microbiol* 2012; **61**: 653-661 [PMID: 22282459 DOI: 10.1099/jmm.0.040980-0]
- 286 **Tada T**, Miyoshi-Akiyama T, Shimada K, Shimojima M, Kirikae T. Dissemination of 16S rRNA methylase ArmA-producing *acinetobacter baumannii* and emergence of OXA-72 carbapenemase coproducers in Japan. *Antimicrob Agents Chemother* 2014; **58**: 2916-2920 [PMID: 24550340 DOI: 10.1128/aac.01212-13]
- 287 **Carattoli A**. Importance of integrons in the diffusion of resistance. *Vet Res* 2001; **32**: 243-259 [PMID: 11432416]
- 288 **Mazel D**. Integrons: agents of bacterial evolution. *Nat Rev Microbiol* 2006; **4**: 608-620 [PMID: 16845431 DOI: 10.1038/nrmicro1462]
- 289 **Hall RM**, Collis CM, Kim MJ, Partridge SR, Recchia GD, Stokes HW. Mobile gene cassettes and integrons in evolution. *Ann N Y Acad Sci* 1999; **870**: 68-80 [PMID: 10415474]
- 290 **Gu B**, Tong M, Zhao W, Liu G, Ning M, Pan S, Zhao W. Prevalence and characterization of class I integrons among *Pseudomonas aeruginosa* and *Acinetobacter baumannii* isolates from patients in Nanjing, China. *J Clin Microbiol* 2007; **45**: 241-243 [PMID: 17122024 DOI: 10.1128/JCM.01318-06]
- 291 **Huang LY**, Chen TL, Lu PL, Tsai CA, Cho WL, Chang FY, Hung CP, Siu LK. Dissemination of multidrug-resistant, class 1 integron-carrying *Acinetobacter baumannii* isolates in Taiwan. *Clin Microbiol Infect* 2008; **14**: 1010-1019 [PMID: 19040472 DOI: 10.1111/j.1469-0691.2008.02077.x]
- 292 **Ploy MC**, Denis F, Courvalin P, Lambert T. Molecular characterization of integrons in *Acinetobacter baumannii*: description of a hybrid class 2 integron. *Antimicrob Agents Chemother* 2000; **44**: 2684-2688 [PMID: 10991844]
- 293 **Koeleman JG**, Stoof J, Van Der Bijl MW, Vandenbroucke-Grauls CM, Savelkoul PH. Identification of epidemic strains of *Acinetobacter baumannii* by integrase gene PCR. *J Clin Microbiol* 2001; **39**: 8-13 [PMID: 11136740 DOI: 10.1128/JCM.39.1.8-13.2001]
- 294 **Turton JF**, Kaufmann ME, Glover J, Coelho JM, Warner M, Pike R, Pitt TL. Detection and typing of integrons in epidemic strains of *Acinetobacter baumannii* found in the United Kingdom. *J Clin Microbiol* 2005; **43**: 3074-3082 [PMID: 16000417 DOI: 10.1128/JCM.43.7.3074-3082.2005]
- 295 **Gaur A**, Prakash P, Anupurba S, Mohapatra TM. Possible role of integrase gene polymerase chain reaction as an epidemiological marker: study of multidrug-resistant *Acinetobacter baumannii* isolated from nosocomial infections. *Int J Antimicrob Agents* 2007; **29**: 446-450 [PMID: 17270402 DOI: 10.1016/j.ijantimicag.2006.11.014]
- 296 **Gombac F**, Riccio ML, Rossolini GM, Lagatolla C, Tonin E, Monti-Bragadin C, Lavenia A, Dolzani L. Molecular characterization of integrons in epidemiologically unrelated clinical isolates of *Acinetobacter baumannii* from Italian hospitals reveals a limited diversity of gene cassette arrays. *Antimicrob Agents Chemother* 2002; **46**: 3665-3668 [PMID: 12384388 DOI: 10.1128/aac.46.11.3665-3668.2002]
- 297 **Ruiz J**, Navia MM, Casals C, Sierra JM, Jiménez De Anta MT, Vila J. Integron-mediated antibiotic multiresistance in *Acinetobacter baumannii* clinical isolates from Spain. *Clin Microbiol Infect* 2003; **9**: 907-911 [PMID: 14616677]
- 298 **Martínez-Freije P**, Fluit AC, Schmitz FJ, Grek VS, Verhoef J, Jones ME. Class I integrons in Gram-negative isolates from different European hospitals and association with decreased susceptibility to multiple antibiotic compounds. *J Antimicrob Chemother* 1998; **42**: 689-696 [PMID: 10052890]
- 299 **Yang CM**, Lin MF, Lin CH, Huang YT, Hsu CT, Liou ML. Characterization of antimicrobial resistance patterns and integrons in human fecal *Escherichia coli* in Taiwan. *Jpn J Infect Dis* 2009; **62**: 177-181 [PMID: 19468175]
- 300 **Liu SY**, Lin JY, Chu C, Su LH, Lin TY, Chiu CH. Integron-associated imipenem resistance in *Acinetobacter baumannii* isolated from a regional hospital in Taiwan. *Int J Antimicrob Agents* 2006; **27**: 81-84 [PMID: 16359845 DOI: 10.1016/j.ijantimicag.2005.09.010]
- 301 **Chen YS**, Lin HH, Wu CH, Hsiao YS, Hsu NS, Chen YL. Colonization of a medical center in Southern Taiwan by epidemic strains of carbapenem- and multidrug-resistant *Acinetobacter baumannii* and the genetic organization of their integrons. *Jpn J Infect Dis* 2009; **62**: 155-157 [PMID: 19305060]
- 302 **Wu TL**, Ma L, Chang JC, Su LH, Chu C, Leu HS, Siu LK. Variable resistance patterns of integron-associated multidrug-resistant *Acinetobacter baumannii* isolates in a surgical intensive care unit. *Microb Drug Resist* 2004; **10**: 292-299 [PMID: 15650373]
- 303 **Mendes RE**, Castanheira M, Toleman MA, Sader HS, Jones RN, Walsh TR. Characterization of an integron carrying blaIMP-1 and a new aminoglycoside resistance gene, aac(6')-31, and its dissemination among genetically unrelated clinical isolates in a Brazilian hospital. *Antimicrob Agents Chemother* 2007; **51**: 2611-2614 [PMID: 17470660 DOI: 10.1128/AAC.00838-06]
- 304 **Xu X**, Kong F, Cheng X, Yan B, Du X, Gai J, Ai H, Shi L, Iredell J. Integron gene cassettes in *Acinetobacter* spp. strains from South China. *Int J Antimicrob Agents* 2008; **32**: 441-445 [PMID: 18757181 DOI: 10.1016/j.ijantimicag.2008.05.014]
- 305 **Garnacho-Montero J**, Ortiz-Leyba C, Fernández-Hinojosa E, Aldabó-Pallás T, Cayuela A, Marquez-Vácaro JA, García-Curiel A, Jiménez-Jiménez FJ. *Acinetobacter baumannii* ventilator-associated pneumonia: epidemiological and clinical findings. *Intensive Care Med* 2005; **31**: 649-655 [PMID: 15785929 DOI: 10.1007/s00134-005-2598-0]
- 306 **Lortholary O**, Fagon JY, Hoi AB, Slama MA, Pierre J, Giral P, Rosenzweig R, Gutmann L, Safar M, Acar J. Nosocomial acquisition of multiresistant *Acinetobacter baumannii*: risk factors and prognosis. *Clin Infect Dis* 1995; **20**: 790-796 [PMID: 7795075]
- 307 **Falagas ME**, Rafailidis PI. Attributable mortality of *Acinetobacter baumannii*: no longer a controversial issue. *Crit Care* 2007; **11**: 134 [PMID: 17543135 DOI: 10.1186/cc5911]
- 308 **Sunenshine RH**, Wright MO, Maragakis LL, Harris AD, Song X, Hebden J, Cosgrove SE, Anderson A, Carnell J, Jernigan DB, Kleinbaum DG, Perl TM, Standiford HC, Srinivasan



- A. Multidrug-resistant *Acinetobacter* infection mortality rate and length of hospitalization. *Emerg Infect Dis* 2007; **13**: 97-103 [PMID: 17370521 DOI: 10.3201/eid1301.060716]
- 309 **Grupper M**, Sprecher H, Mashiach T, Finkelstein R. Attributable mortality of nosocomial *Acinetobacter* bacteremia. *Infect Control Hosp Epidemiol* 2007; **28**: 293-298 [PMID: 17326019]
- 310 **Playford EG**, Craig JC, Iredell JR. Carbapenem-resistant *Acinetobacter baumannii* in intensive care unit patients: risk factors for acquisition, infection and their consequences. *J Hosp Infect* 2007; **65**: 204-211 [PMID: 17254667 DOI: 10.1016/j.jhin.2006.11.010]
- 311 **Kwon KT**, Oh WS, Song JH, Chang HH, Jung SI, Kim SW, Ryu SY, Heo ST, Jung DS, Rhee JY, Shin SY, Ko KS, Peck KR, Lee NY. Impact of imipenem resistance on mortality in patients with *Acinetobacter* bacteraemia. *J Antimicrob Chemother* 2007; **59**: 525-530 [PMID: 17213265 DOI: 10.1093/jac/dkl499]
- 312 **Robenshtok E**, Paul M, Leibovici L, Fraser A, Pitlik S, Ostfeld I, Samra Z, Perez S, Lev B, Weinberger M. The significance of *Acinetobacter baumannii* bacteraemia compared with *Klebsiella pneumoniae* bacteraemia: risk factors and outcomes. *J Hosp Infect* 2006; **64**: 282-287 [PMID: 16930770 DOI: 10.1016/j.jhin.2006.06.025]
- 313 **Falagas ME**, Kasiakou SK, Rafailidis PI, Zouglikis G, Morfou P. Comparison of mortality of patients with *Acinetobacter baumannii* bacteraemia receiving appropriate and inappropriate empirical therapy. *J Antimicrob Chemother* 2006; **57**: 1251-1254 [PMID: 16627593 DOI: 10.1093/jac/dkl130]
- 314 **Turner PJ**, Greenhalgh JM. The activity of meropenem and comparators against *Acinetobacter* strains isolated from European hospitals, 1997-2000. *Clin Microbiol Infect* 2003; **9**: 563-567 [PMID: 12848736]
- 315 **Unal S**, Garcia-Rodriguez JA. Activity of meropenem and comparators against *Pseudomonas aeruginosa* and *Acinetobacter* spp. isolated in the MYSTIC Program, 2002-2004. *Diagn Microbiol Infect Dis* 2005; **53**: 265-271 [PMID: 16360550 DOI: 10.1016/j.diagmicrobio.2005.10.002]
- 316 **Tognim MC**, Andrade SS, Silbert S, Gales AC, Jones RN, Sader HS. Resistance trends of *Acinetobacter* spp. in Latin America and characterization of international dissemination of multi-drug resistant strains: five-year report of the SENTRY Antimicrobial Surveillance Program. *Int J Infect Dis* 2004; **8**: 284-291 [PMID: 15325597 DOI: 10.1016/j.ijid.2003.11.009]
- 317 **Landman D**, Bratu S, Kochar S, Panwar M, Trehan M, Doymaz M, Quale J. Evolution of antimicrobial resistance among *Pseudomonas aeruginosa*, *Acinetobacter baumannii* and *Klebsiella pneumoniae* in Brooklyn, NY. *J Antimicrob Chemother* 2007; **60**: 78-82 [PMID: 17490999 DOI: 10.1093/jac/dkm129]
- 318 **Mai MH**, Tsai HC, Lee SS, Wang YH, Chen YS, Wann SR, Liu YC. Multidrug-resistant *Acinetobacter baumannii* in ventilator-associated pneumonia at a medical center in southern Taiwan. *J Microbiol Immunol Infect* 2007; **40**: 401-405 [PMID: 17932599]
- 319 **Chopra T**, Marchaim D, Awali RA, Krishna A, Johnson P, Tansek R, Chaudary K, Lephart P, Slim J, Hothi J, Ahmed H, Pogue JM, Zhao JJ, Kaye KS. Epidemiology of bloodstream infections caused by *Acinetobacter baumannii* and impact of drug resistance to both carbapenems and ampicillin-sulbactam on clinical outcomes. *Antimicrob Agents Chemother* 2013; **57**: 6270-6275 [PMID: 24100492 DOI: 10.1128/AAC.01520-13]
- 320 **Wong TH**, Tan BH, Ling ML, Song C. Multi-resistant *Acinetobacter baumannii* on a burns unit--clinical risk factors and prognosis. *Burns* 2002; **28**: 349-357 [PMID: 12052373]
- 321 **Sheng WH**, Liao CH, Lauderdale TL, Ko WC, Chen YS, Liu JW, Lau YJ, Wang LH, Liu KS, Tsai TY, Lin SY, Hsu MS, Hsu LY, Chang SC. A multicenter study of risk factors and outcome of hospitalized patients with infections due to carbapenem-resistant *Acinetobacter baumannii*. *Int J Infect Dis* 2010; **14**: e764-e769 [PMID: 20646946 DOI: 10.1016/j.ijid.2010.02.2254]
- 322 **Gkrania-Klotsas E**, Hershov RC. Colonization or infection with multidrug-resistant *Acinetobacter baumannii* may be an independent risk factor for increased mortality. *Clin Infect Dis* 2006; **43**: 1224-1225 [PMID: 17029151]
- 323 **Giske CG**, Monnet DL, Cars O, Carmeli Y. Clinical and economic impact of common multidrug-resistant gram-negative bacilli. *Antimicrob Agents Chemother* 2008; **52**: 813-821 [PMID: 18070961 DOI: 10.1128/AAC.01169-07]
- 324 **Payne DJ**, Gwynn MN, Holmes DJ, Pompliano DL. Drugs for bad bugs: confronting the challenges of antibacterial discovery. *Nat Rev Drug Discov* 2007; **6**: 29-40 [PMID: 17159923 DOI: 10.1038/nrd2201]
- 325 **Rebmann T**, Rosenbaum PA. Preventing the transmission of multidrug-resistant *Acinetobacter baumannii*: an executive summary of the Association for Professionals in infection control and epidemiology's elimination guide. *Am J Infect Control* 2011; **39**: 439-441 [PMID: 21420758 DOI: 10.1016/j.ajic.2010.08.015]
- 326 **Dy ME**, Nord JA, LaBombardi VJ, Kislak JW. The emergence of resistant strains of *Acinetobacter baumannii*: clinical and infection control implications. *Infect Control Hosp Epidemiol* 1999; **20**: 565-567 [PMID: 10466561 DOI: 10.1086/501673]
- 327 **Akalin H**, Ozakin C, Gedikoglu S. Epidemiology of *Acinetobacter baumannii* in a university hospital in Turkey. *Infect Control Hosp Epidemiol* 2006; **27**: 404-408 [PMID: 16622820 DOI: 10.1086/503349]
- 328 **Ho PL**, Ho AY, Chow KH, Lai EL, Ching P, Seto WH. Epidemiology and clonality of multidrug-resistant *Acinetobacter baumannii* from a healthcare region in Hong Kong. *J Hosp Infect* 2010; **74**: 358-364 [PMID: 20153548 DOI: 10.1016/j.jhin.2009.10.015]
- 329 **Kraniotaki E**, Manganelli R, Platsouka E, Grossato A, Paniara O, Palù G. Molecular investigation of an outbreak of multidrug-resistant *Acinetobacter baumannii*, with characterisation of class 1 integrons. *Int J Antimicrob Agents* 2006; **28**: 193-199 [PMID: 16904293 DOI: 10.1016/j.ijantimicag.2006.04.016]
- 330 **Koeleman JG**, Parlevliet GA, Dijkshoorn L, Savelkoul PH, Vandembroucke-Grauls CM. Nosocomial outbreak of multi-resistant *Acinetobacter baumannii* on a surgical ward: epidemiology and risk factors for acquisition. *J Hosp Infect* 1997; **37**: 113-123 [PMID: 9364260]
- 331 **Gandra S**, Braykov N, Laxminarayan R. East North Central region has the highest prevalence of vancomycin-resistant *Enterococcus faecalis* in the United States. *Infect Control Hosp Epidemiol* 2013; **34**: 443-445 [PMID: 23466924 DOI: 10.1086/669872]
- 332 **Barbut F**, Yezli S, Mimoun M, Pham J, Chaouat M, Otter JA. Reducing the spread of *Acinetobacter baumannii* and methicillin-resistant *Staphylococcus aureus* on a burns unit through the intervention of an infection control bundle. *Burns* 2013; **39**: 395-403 [PMID: 22884127 DOI: 10.1016/j.burns.2012.07.007]
- 333 **Kuo HY**, Chang KC, Kuo JW, Yueh HW, Liou ML. Imipenem: a potent inducer of multidrug resistance in *Acinetobacter baumannii*. *Int J Antimicrob Agents* 2012; **39**: 33-38 [PMID: 21996406 DOI: 10.1016/j.ijantimicag.2011.08.016]
- 334 **Lautenbach E**, Synnestvedt M, Weiner MG, Bilker WB, Vo L, Schein J, Kim M. Epidemiology and impact of imipenem resistance in *Acinetobacter baumannii*. *Infect Control Hosp Epidemiol* 2009; **30**: 1186-1192 [PMID: 19860563 DOI: 10.1086/648450]
- 335 **Cisneros JM**, Rodríguez-Baño J. Nosocomial bacteremia due to *Acinetobacter baumannii*: epidemiology, clinical features and treatment. *Clin Microbiol Infect* 2002; **8**: 687-693 [PMID: 12445005]
- 336 **Gordon NC**, Wareham DW. A review of clinical and microbiological outcomes following treatment of infections

- involving multidrug-resistant *Acinetobacter baumannii* with tigecycline. *J Antimicrob Chemother* 2009; **63**: 775-780 [PMID: 19158109 DOI: 10.1093/jac/dkn555]
- 337 **Smolyakov R**, Borer A, Riesenberger K, Schlaeffer F, Alkan M, Porath A, Rimar D, Almog Y, Gilad J. Nosocomial multidrug resistant *Acinetobacter baumannii* bloodstream infection: risk factors and outcome with ampicillin-sulbactam treatment. *J Hosp Infect* 2003; **54**: 32-38 [PMID: 12767844 DOI: 10.1016/s0195-6701(03)00046-x]
- 338 **Chu H**, Zhao L, Wang M, Liu Y, Gui T, Zhang J. Sulbactam-based therapy for *Acinetobacter baumannii* infection: a systematic review and meta-analysis. *Braz J Infect Dis* 2013; **17**: 389-394 [PMID: 23602463 DOI: 10.1016/j.bjid.2012.10.029]
- 339 **Hiraki Y**, Yoshida M, Masuda Y, Inoue D, Tsuji Y, Kamimura H, Karube Y, Takaki K, Kawano F. Successful treatment of skin and soft tissue infection due to carbapenem-resistant *Acinetobacter baumannii* by ampicillin-sulbactam and meropenem combination therapy. *Int J Infect Dis* 2013; **17**: e1234-e1236 [PMID: 23791858 DOI: 10.1016/j.ijid.2013.05.002]
- 340 **Kuo LC**, Lai CC, Liao CH, Hsu CK, Chang YL, Chang CY, Hsueh PR. Multidrug-resistant *Acinetobacter baumannii* bacteraemia: clinical features, antimicrobial therapy and outcome. *Clin Microbiol Infect* 2007; **13**: 196-198 [PMID: 17328733 DOI: 10.1111/j.1469-0691.2006.01601.x]
- 341 **Kalin G**, Alp E, Akin A, Coskun R, Doganay M. Comparison of colistin and colistin/sulbactam for the treatment of multidrug resistant *Acinetobacter baumannii* ventilator-associated pneumonia. *Infection* 2014; **42**: 37-42 [PMID: 23828559 DOI: 10.1007/s15010-013-0495-y]
- 342 **Pachón-Ibáñez ME**, Jiménez-Mejías ME, Pichardo C, Llanos AC, Pachón J. Activity of tigecycline (GAR-936) against *Acinetobacter baumannii* strains, including those resistant to imipenem. *Antimicrob Agents Chemother* 2004; **48**: 4479-4481 [PMID: 15504889 DOI: 10.1128/AAC.48.11.4479-4481.2004]
- 343 **Bantar C**, Schell C, Posse G, Limansky A, Ballerini V, Mobilia L. Comparative time-kill study of doxycycline, tigecycline, sulbactam, and imipenem against several clones of *Acinetobacter baumannii*. *Diagn Microbiol Infect Dis* 2008; **61**: 309-314 [PMID: 18375084 DOI: 10.1016/j.diagmicrobio.2008.02.014]
- 344 **Koomanachai P**, Kim A, Nicolau DP. Pharmacodynamic evaluation of tigecycline against *Acinetobacter baumannii* in a murine pneumonia model. *J Antimicrob Chemother* 2009; **63**: 982-987 [PMID: 19279050 DOI: 10.1093/jac/dkp056]
- 345 **Anthony KB**, Fishman NO, Linkin DR, Gasink LB, Edelstein PH, Lautenbach E. Clinical and microbiological outcomes of serious infections with multidrug-resistant gram-negative organisms treated with tigecycline. *Clin Infect Dis* 2008; **46**: 567-570 [PMID: 18199038 DOI: 10.1086/526775]
- 346 **Pichardo C**, Pachón-Ibáñez ME, Docobo-Pérez F, López-Rojas R, Jiménez-Mejías ME, García-Curiel A, Pachón J. Efficacy of tigecycline vs. imipenem in the treatment of experimental *Acinetobacter baumannii* murine pneumonia. *Eur J Clin Microbiol Infect Dis* 2010; **29**: 527-531 [PMID: 20182760 DOI: 10.1007/s10096-010-0890-6]
- 347 **Liao CH**, Kung HC, Hsu GJ, Lu PL, Liu YC, Chen CM, Lee CM, Sun W, Jang TN, Chiang PC, Cheng YJ, Lin HC, Shi ZY, Wang LS, Chuang YC, Tsao SM, Lu CT, Liu JW, Huang CH, Hsueh PR. In-vitro activity of tigecycline against clinical isolates of *Acinetobacter baumannii* in Taiwan determined by the broth microdilution and disk diffusion methods. *Int J Antimicrob Agents* 2008; **32** Suppl 3: S192-S196 [PMID: 19013354 DOI: 10.1016/s0924-8579(08)70027-x]
- 348 **Curcio D**, Fernández F. Tigecycline for *Acinetobacter baumannii* infection: other considerations. *Clin Infect Dis* 2008; **46**: 1797-1798; author reply 1798-1799 [PMID: 18462123 DOI: 10.1086/588051]
- 349 **Chuang YC**, Cheng CY, Sheng WH, Sun HY, Wang JT, Chen YC, Chang SC. Effectiveness of tigecycline-based versus colistin- based therapy for treatment of pneumonia caused by multidrug-resistant *Acinetobacter baumannii* in a critical setting: a matched cohort analysis. *BMC Infect Dis* 2014; **14**: 102 [PMID: 24564226 DOI: 10.1186/1471-2334-14-102]
- 350 **Yahav D**, Lador A, Paul M, Leibovici L. Efficacy and safety of tigecycline: a systematic review and meta-analysis. *J Antimicrob Chemother* 2011; **66**: 1963-1971 [PMID: 21685488 DOI: 10.1093/jac/dkr242]
- 351 **Scheetz MH**, Qi C, Warren JR, Postelnick MJ, Zembower T, Obias A, Noskin GA. In vitro activities of various antimicrobials alone and in combination with tigecycline against carbapenem-intermediate or -resistant *Acinetobacter baumannii*. *Antimicrob Agents Chemother* 2007; **51**: 1621-1626 [PMID: 17307973 DOI: 10.1128/AAC.01099-06]
- 352 **Lee YT**, Tsao SM, Hsueh PR. Clinical outcomes of tigecycline alone or in combination with other antimicrobial agents for the treatment of patients with healthcare-associated multidrug-resistant *Acinetobacter baumannii* infections. *Eur J Clin Microbiol Infect Dis* 2013; **32**: 1211-1220 [PMID: 23553594 DOI: 10.1007/s10096-013-1870-4]
- 353 **Moland ES**, Craft DW, Hong SG, Kim SY, Hachmeister L, Sayed SD, Thomson KS. In vitro activity of tigecycline against multidrug-resistant *Acinetobacter baumannii* and selection of tigecycline-amikacin synergy. *Antimicrob Agents Chemother* 2008; **52**: 2940-2942 [PMID: 18519722 DOI: 10.1128/AAC.01581-07]
- 354 **Liu JW**, Wang LS, Cheng YJ, Hsu GJ, Lu PL, Liu YC, Chen CM, Lee CM, Sun W, Jang TN, Chiang PC, Chuang YC, Lin HC, Shi ZY, Kung HC, Huang CH, Tsao SM, Lu CT, Liao CH, Hsueh PR. In-vitro activity of tigecycline against clinical isolates of *Acinetobacter baumannii* in Taiwan. *Int J Antimicrob Agents* 2008; **32** Suppl 3: S188-S191 [PMID: 19013353 DOI: 10.1016/s0924-8579(08)70026-8]
- 355 **Hornsey M**, Loman N, Wareham DW, Ellington MJ, Pallen MJ, Turton JF, Underwood A, Gaulton T, Thomas CP, Doumith M, Livermore DM, Woodford N. Whole-genome comparison of two *Acinetobacter baumannii* isolates from a single patient, where resistance developed during tigecycline therapy. *J Antimicrob Chemother* 2011; **66**: 1499-1503 [PMID: 21565804 DOI: 10.1093/jac/dkr168]
- 356 **Navon-Venezia S**, Leavitt A, Carmeli Y. High tigecycline resistance in multidrug-resistant *Acinetobacter baumannii*. *J Antimicrob Chemother* 2007; **59**: 772-774 [PMID: 17353223 DOI: 10.1093/jac/dkm018]
- 357 **Cai Y**, Chai D, Wang R, Liang B, Bai N. Colistin resistance of *Acinetobacter baumannii*: clinical reports, mechanisms and antimicrobial strategies. *J Antimicrob Chemother* 2012; **67**: 1607-1615 [PMID: 22441575 DOI: 10.1093/jac/dks084]
- 358 **Chang KC**, Lin MF, Lin NT, Wu WJ, Kuo HY, Lin TY, Yang TL, Chen YC, Liou ML. Clonal spread of multidrug-resistant *Acinetobacter baumannii* in eastern Taiwan. *J Microbiol Immunol Infect* 2012; **45**: 37-42 [PMID: 22154678 DOI: 10.1016/j.jjmi.2011.09.019]
- 359 **Karaïskos I**, Galani L, Baziaka F, Giamarellou H. Intraventricular and intrathecal colistin as the last therapeutic resort for the treatment of multidrug-resistant and extensively drug-resistant *Acinetobacter baumannii* ventriculitis and meningitis: a literature review. *Int J Antimicrob Agents* 2013; **41**: 499-508 [PMID: 23507414 DOI: 10.1016/j.ijantimicag.2013.02.006]
- 360 **Lu Q**, Luo R, Bodin L, Yang J, Zahr N, Aubry A, Golmard JL, Rouby JJ. Efficacy of high-dose nebulized colistin in ventilator-associated pneumonia caused by multidrug-resistant *Pseudomonas aeruginosa* and *Acinetobacter baumannii*. *Anesthesiology* 2012; **117**: 1335-1347 [PMID: 23132092 DOI: 10.1097/ALN.0b013e31827515de]
- 361 **Lin CC**, Liu TC, Kuo CF, Liu CP, Lee CM. Aerosolized colistin for the treatment of multidrug-resistant *Acinetobacter baumannii* pneumonia: experience in a tertiary care hospital in northern Taiwan. *J Microbiol Immunol Infect* 2010; **43**: 323-331

- [PMID: 20688293 DOI: 10.1016/S1684-1182(10)60050-3]
- 362 **Adams MD**, Nickel GC, Bajaksouzian S, Lavender H, Murthy AR, Jacobs MR, Bonomo RA. Resistance to colistin in *Acinetobacter baumannii* associated with mutations in the PmrAB two-component system. *Antimicrob Agents Chemother* 2009; **53**: 3628-3634 [PMID: 19528270 DOI: 10.1128/AAC.00284-09]
  - 363 **Beceiro A**, Llobet E, Aranda J, Bengoechea JA, Doumith M, Hornsey M, Dhanji H, Chart H, Bou G, Livermore DM, Woodford N. Phosphoethanolamine modification of lipid A in colistin-resistant variants of *Acinetobacter baumannii* mediated by the pmrAB two-component regulatory system. *Antimicrob Agents Chemother* 2011; **55**: 3370-3379 [PMID: 21576434 DOI: 10.1128/AAC.00079-11]
  - 364 **Karaoglan I**, Zer Y, Bosnak VK, Mete AO, Namiduru M. In vitro synergistic activity of colistin with tigecycline or  $\beta$ -lactam antibiotic/ $\beta$ -lactamase inhibitor combinations against carbapenem-resistant *Acinetobacter baumannii*. *J Int Med Res* 2013; **41**: 1830-1837 [PMID: 24265334 DOI: 10.1177/0300060513496172]
  - 365 **Liang W**, Liu XF, Huang J, Zhu DM, Li J, Zhang J. Activities of colistin- and minocycline-based combinations against extensive drug resistant *Acinetobacter baumannii* isolates from intensive care unit patients. *BMC Infect Dis* 2011; **11**: 109 [PMID: 21521536 DOI: 10.1186/1471-2334-11-109.]
  - 366 **Aydemir H**, Akduman D, Piskin N, Comert F, Horuz E, Terzi A, Kokturk F, Ornek T, Celebi G. Colistin vs. the combination of colistin and rifampicin for the treatment of carbapenem-resistant *Acinetobacter baumannii* ventilator-associated pneumonia. *Epidemiol Infect* 2013; **141**: 1214-1222 [PMID: 22954403 DOI: 10.1017/S095026881200194X]
  - 367 **Durante-Mangoni E**, Signoriello G, Andini R, Mattei A, De Cristoforo M, Murino P, Bassetti M, Malacarne P, Petrosillo N, Galdieri N, Mocavero P, Corcione A, Viscoli C, Zarrilli R, Gallo C, Utili R. Colistin and rifampicin compared with colistin alone for the treatment of serious infections due to extensively drug-resistant *Acinetobacter baumannii*: a multicenter, randomized clinical trial. *Clin Infect Dis* 2013; **57**: 349-358 [PMID: 23616495 DOI: 10.1093/cid/cit253]
  - 368 **Giannouli M**, Di Popolo A, Durante-Mangoni E, Bernardo M, Cuccurullo S, Amato G, Tripodi MF, Triassi M, Utili R, Zarrilli R. Molecular epidemiology and mechanisms of rifampicin resistance in *Acinetobacter baumannii* isolates from Italy. *Int J Antimicrob Agents* 2012; **39**: 58-63 [PMID: 22055530 DOI: 10.1016/j.jantimicag.2011.09.016]
  - 369 **Batirel A**, Balkan II, Karabay O, Agalar C, Akalin S, Alici O, Alp E, Altay FA, Altin N, Arslan F, Aslan T, Bekiroglu N, Cesur S, Celik AD, Dogan M, Durdu B, Duygu F, Engin A, Engin DO, Gonen I, Guclu E, Guven T, Hatipoglu CA, Hosoglu S, Karahocagil MK, Kilic AU, Ormen B, Ozdemir D, Ozer S, Oztoprak N, Sezak N, Turhan V, Turker N, Yilmaz H. Comparison of colistin-carbapenem, colistin-sulbactam, and colistin plus other antibacterial agents for the treatment of extremely drug-resistant *Acinetobacter baumannii* bloodstream infections. *Eur J Clin Microbiol Infect Dis* 2014; **33**: 1311-1322 [PMID: 24532009 DOI: 10.1007/s10096-014-2070-6]
  - 370 **Mutlu Yilmaz E**, Sunbul M, Aksoy A, Yilmaz H, Guney AK, Guven T. Efficacy of tigecycline/colistin combination in a pneumonia model caused by extensively drug-resistant *Acinetobacter baumannii*. *Int J Antimicrob Agents* 2012; **40**: 332-336 [PMID: 22831842 DOI: 10.1016/j.jantimicag.2012.06.003]
  - 371 **Wareham DW**, Gordon NC, Hornsey M. In vitro activity of teicoplanin combined with colistin versus multidrug-resistant strains of *Acinetobacter baumannii*. *J Antimicrob Chemother* 2011; **66**: 1047-1051 [PMID: 21393131 DOI: 10.1093/jac/dkr069]
  - 372 **Hornsey M**, Phee L, Longshaw C, Wareham DW. In vivo efficacy of telavancin/colistin combination therapy in a *Galleria mellonella* model of *Acinetobacter baumannii* infection. *Int J Antimicrob Agents* 2013; **41**: 285-287 [PMID: 23312607 DOI: 10.1016/j.jantimicag.2012.11.013]
  - 373 **Principe L**, Capone A, Mazzarelli A, D'Arezzo S, Bordini E, Di Caro A, Petrosillo N. In vitro activity of doripenem in combination with various antimicrobials against multidrug-resistant *Acinetobacter baumannii*: possible options for the treatment of complicated infection. *Microb Drug Resist* 2013; **19**: 407-414 [PMID: 23659601 DOI: 10.1089/mdr.2012.0250]
  - 374 **López-Cortés LE**, Cisneros JM, Fernández-Cuenca F, Bou G, Tomás M, Garnacho-Montero J, Pascual A, Martínez-Martínez L, Vila J, Pachón J, Rodríguez Baño J. Monotherapy versus combination therapy for sepsis due to multidrug-resistant *Acinetobacter baumannii*: analysis of a multicentre prospective cohort. *J Antimicrob Chemother* 2014; **69**: 3119-3126 [PMID: 24970742 DOI: 10.1093/jac/dku233]
  - 375 **Zavascki AP**, Carvalhaes CG, Picão RC, Gales AC. Multidrug-resistant *Pseudomonas aeruginosa* and *Acinetobacter baumannii*: resistance mechanisms and implications for therapy. *Expert Rev Anti Infect Ther* 2010; **8**: 71-93 [PMID: 20014903]
  - 376 **Naas T**, Cuzon G, Bogaerts P, Glupczynski Y, Nordmann P. Evaluation of a DNA microarray (Check-MDR CT102) for rapid detection of TEM, SHV, and CTX-M extended-spectrum  $\beta$ -lactamases and of KPC, OXA-48, VIM, IMP, and NDM-1 carbapenemases. *J Clin Microbiol* 2011; **49**: 1608-1613 [PMID: 21325547 DOI: 10.1128/JCM.02607-10]
  - 377 **Cuzon G**, Naas T, Bogaerts P, Glupczynski Y, Nordmann P. Evaluation of a DNA microarray for the rapid detection of extended-spectrum  $\beta$ -lactamases (TEM, SHV and CTX-M), plasmid-mediated cephalosporinases (CMY-2-like, DHA, FOX, ACC-1, ACT/MIR and CMY-1-like/MOX) and carbapenemases (KPC, OXA-48, VIM, IMP and NDM). *J Antimicrob Chemother* 2012; **67**: 1865-1869 [PMID: 22604450 DOI: 10.1093/jac/dks156]
  - 378 **Luh KT**, Hsueh PR, Teng LJ, Pan HJ, Chen YC, Lu JJ, Wu JJ, Ho SW. Quinupristin-dalfopristin resistance among gram-positive bacteria in Taiwan. *Antimicrob Agents Chemother* 2000; **44**: 3374-3380 [PMID: 11083643 DOI: 10.1128/aac.44.12.3374-3380.2000]
  - 379 **Bals R**. Epithelial antimicrobial peptides in host defense against infection. *Respir Res* 2000; **1**: 141-150 [PMID: 11667978]
  - 380 **Reddy KV**, Yedery RD, Aranha C. Antimicrobial peptides: premises and promises. *Int J Antimicrob Agents* 2004; **24**: 536-547 [PMID: 15555874 DOI: 10.1016/j.jantimicag.2004.09.005]
  - 381 **Izadpanah A**, Gallo RL. Antimicrobial peptides. *J Am Acad Dermatol* 2005; **52**: 381-390; quiz 391-392 [PMID: 15761415 DOI: 10.1016/j.jaad.2004.08.026]
  - 382 **Moffatt JH**, Harper M, Mansell A, Crane B, Fitzsimons TC, Nation RL, Li J, Adler B, Boyce JD. Lipopolysaccharide-deficient *Acinetobacter baumannii* shows altered signaling through host Toll-like receptors and increased susceptibility to the host antimicrobial peptide LL-37. *Infect Immun* 2013; **81**: 684-689 [PMID: 23250952 DOI: 10.1128/IAI.01362-12]
  - 383 **Feng X**, Sambanthamoorthy K, Palys T, Paranavitana C. The human antimicrobial peptide LL-37 and its fragments possess both antimicrobial and antibiofilm activities against multidrug-resistant *Acinetobacter baumannii*. *Peptides* 2013; **49**: 131-137 [PMID: 24071034 DOI: 10.1016/j.peptides.2013.09.007]
  - 384 **Weinstock GM**. Genomic approaches to studying the human microbiota. *Nature* 2012; **489**: 250-256 [PMID: 22972298]
  - 385 **Proctor LM**. The Human Microbiome Project in 2011 and beyond. *Cell Host Microbe* 2011; **10**: 287-291 [PMID: 22018227 DOI: 10.1016/j.chom.2011.10.001]
  - 386 **Cabrera-Rubio R**, García-Núñez M, Setó L, Antó JM, Moya A, Monsó E, Mira A. Microbiome diversity in the bronchial tracts of patients with chronic obstructive pulmonary dis-

ease. *J Clin Microbiol* 2012; **50**: 3562-3568 [PMID: 22915614 DOI: 10.1128/JCM.00767-12]

- 387 **Giannouli M**, Tomasone F, Agodi A, Vahaboglu H, Daoud Z, Triassi M, Tsakris A, Zarrilli R. Molecular epidemiology

of carbapenem-resistant *Acinetobacter baumannii* strains in intensive care units of multiple Mediterranean hospitals. *J Antimicrob Chemother* 2009; **63**: 828-830 [PMID: 19223304 DOI: 10.1093/jac/dkp032]

**P- Reviewer:** Ergin MA, Landry DL **S- Editor:** Tian YL  
**L- Editor:** A **E- Editor:** Wu HL





## Follicular contact dermatitis revisited: A review emphasizing neomycin-associated follicular contact dermatitis

Philip R Cohen

Philip R Cohen, Division of Dermatology, University of California San Diego, San Diego, CA 92131-3643, United States  
Author contributions: Cohen PR solely contributed to this paper.

Correspondence to: Philip R Cohen, MD, Division of Dermatology, University of California San Diego, 10991 Twinleaf Court, San Diego, CA 92131-3643, United States. [mitehead@gmail.com](mailto:mitehead@gmail.com)  
Telephone: +1-858-6578322

Received: June 9, 2014 Revised: September 19, 2014

Accepted: September 23, 2014

Published online: December 16, 2014

### Abstract

Follicular contact dermatitis clinically presents as individual papules that include a central hair follicle. Pathologic features involve the follicle and the surrounding dermis: spongiosis and vesicle formation of the follicular epithelium associated with perifollicular and perivascular lymphocytic inflammation. Using the PubMed database, an extensive literature search was performed on follicular contact dermatitis and neomycin. Relevant papers were reviewed and the clinical and pathologic features, the associated chemicals (including a more detailed description of neomycin), the hypothesized pathogenesis, and the management of follicular contact dermatitis were described. Several agents—either as allergens or irritants—have been reported to elicit follicular contact dermatitis. Several hypotheses have been suggested for the selective involvement of the follicles in follicular contact dermatitis: patient allergenicity, characteristics of the agent, vehicle containing the agent, application of the agent, and external factors. The differential diagnosis of follicular contact dermatitis includes not only recurrent infundibulofolliculitis, but also drug eruption, mite infestation, viral infection, and dermatoses that affect hair follicles. The primary therapeutic intervention for follicular contact dermatitis is withdrawal of the causative agent; treatment with a topical corticosteroid preparation may also

promote resolution of the dermatitis. In conclusion, follicular contact dermatitis may be secondary to allergens or irritants; topical antibiotics, including neomycin, may cause this condition. Several factors may account for the selective involvement of the hair follicle in this condition. Treatment of the dermatitis requires withdrawal of the associated topical agent; in addition, topical corticosteroids may be helpful to promote resolution of lesions.

© 2014 Baishideng Publishing Group Inc. All rights reserved.

**Key words:** Allergic; Contact; Dermatitis; Follicular; Irritant; Neomycin; Papular

**Core tip:** Follicular contact dermatitis can be elicited by several agents and clinically presents as individual papules that include a central hair follicle. Pathologic features involve the follicle and the surrounding dermis. Hypotheses for the selective involvement of the follicles include patient allergenicity, characteristics of the agent, vehicle containing the agent, application of the agent, and external factors. The differential diagnosis includes dermatoses that affect hair follicles, drug eruption, infundibulofolliculitis, mite infestation and viral infection. Treatment with a topical corticosteroid preparation and/or withdrawal of the causative agent are therapeutic interventions for follicular contact dermatitis.

Cohen PR. Follicular contact dermatitis revisited: A review emphasizing neomycin-associated follicular contact dermatitis. *World J Clin Cases* 2014; 2(12): 815-821 Available from: URL: <http://www.wjgnet.com/2307-8960/full/v2/i12/815.htm> DOI: <http://dx.doi.org/10.12998/wjcc.v2.i12.815>

### INTRODUCTION

Contact dermatitis can be either allergic or irritant in eti-

ology. Follicular contact dermatitis is a variant of contact dermatitis that has been observed in individuals secondary to incidental exposure or patch testing to the eliciting agent. The allergens and irritants that have previously been reported to cause follicular contact dermatitis are summarized and neomycin-associated follicular contact dermatitis is emphasized.

## CLINICAL MORPHOLOGY AND SYMPTOMS OF FOLLICULAR CONTACT DERMATITIS

Follicular contact dermatitis is usually characterized by individual papules that include a central hair follicle. However, prominent hairs within the papules may not be readily visible when the lesions surround vellus hairs<sup>[1]</sup>. The papular lesions are frequently pruritic and occasionally painful or burning. The individual lesions have also been described as poral<sup>[2,3]</sup> or acneiform<sup>[1]</sup>. In addition, the clinical spectrum of follicular contact dermatitis also includes follicular-based pustules<sup>[3]</sup>.

## PATHOLOGY OF FOLLICULAR CONTACT DERMATITIS

Microscopic examination of the perifollicular papule is similar, regardless of the eliciting contactant. The pathologic changes involve the follicle and the surrounding dermis. There is often spongiosis and vesicle formation of the follicular epithelium or the eccrine sweat ducts or both. In the dermis, predominantly lymphocytic inflammation is noted around the periadnexal vessels, the follicle and/or the eccrine pore. Importantly, the epithelium adjacent to the follicle or pore is normal in appearance<sup>[1-12]</sup>.

## ALLERGIC CONTACT DERMATITIS AND TOPICAL ANTIBIOTICS

Allergic contact dermatitis to topical antibiotics is a relatively common phenomenon. The North American Contact Dermatitis Group reported that among patients referred for patch testing, during 1985 to 2004, the prevalence of allergic contact dermatitis to neomycin ranged from 7.2 to 13.1 percent<sup>[13]</sup>.

Allergic contact dermatitis to topical antibiotics is most commonly observed in certain at-risk populations. These include patients with chronic eczematous dermatoses (such as atopy and stasis dermatitis), chronic otitis externa, chronic venous insufficiency, and post operative or post traumatic wounds. In addition, an occupational risk to develop allergic contact dermatitis to antibiotics occurs more frequently in those individuals who handle them regularly, such as farmers, health care workers, pharmaceutical employees, and veterinary surgeons<sup>[13]</sup>.

## CHEMICALS CAPABLE OF ELICITING FOLLICULAR CONTACT DERMATITIS

Several chemicals, including topical antibiotics, have been described in either individual reports or larger studies to elicit follicular contact dermatitis. The agents associated with the development of follicular contact dermatitis can be allergens (Table 1)<sup>[1-10,14-21]</sup> or irritants (Table 2)<sup>[4,5,11,22-28]</sup>. Several metals have been associated with follicular patch test reactions: chromium, cobalt, copper, fluoride, and nickel<sup>[3,29]</sup>. Allergic and non-allergic development of follicular contact dermatitis has also been observed following exposure to tocopheryl linoleate, a vitamin E derivative<sup>[4,5]</sup>.

### Neomycin-associated follicular contact dermatitis

**Neomycin-drug characteristics:** Neomycin is produced by the growth of *Streptomyces fradiae*. It is an aminoglycoside antibiotic. Its efficacy as an antimicrobial is based upon the drug's ability to irreversibly bind to the 30S ribosomal RNA subunits and inhibit bacterial protein synthesis<sup>[13,30-32]</sup>.

Neomycin can be used as a topical antibiotic and has activity against many aerobic Gram-negative organisms (except *Pseudomonas aeruginosa*). It is also effective against some aerobic Gram-positive bacteria including *Staphylococci*. However it is not effective against *Streptococci*<sup>[13,30-32]</sup>.

Neomycin is usually formulated commercially as 20% neomycin sulfate in a petrolatum vehicle. However, it is often combined with other topical antibiotics such as bacitracin zinc and polymyxin B sulfate. This is done to expand the antimicrobial coverage<sup>[13,30-32]</sup>.

**Neomycin-clinical presentation:** The woman in Figures 1-4 developed follicular contact dermatitis to an antibiotic ointment that contained neomycin sulfate in combination with bacitracin zinc and polymyxin B sulfate. Indeed, individual hair follicles were observed in the center of the papular lesions (Figure 4). Allergic contact dermatitis has been reported to all three components of this antibiotic<sup>[33-35]</sup>. However, follicular contact dermatitis has only been described in association with neomycin.

**Neomycin-prior observations:** Allergic contact dermatitis to neomycin was initially reported in 1952<sup>[36]</sup>. Six years later, in 1958, Epstein<sup>[9]</sup> described contact dermatitis to neomycin as "...an aggravation or "irritation" of a pre-existing dermatitis..." and not the obvious picture of an acute contact dermatitis. He considered it to represent a dermal contact sensitivity reaction<sup>[9]</sup>. The lesions elicited by patch testing clinically presented as papules and histologically demonstrated an intact epidermis with pathologic changes in the dermis<sup>[9]</sup>.

Subsequently, Jillson *et al*<sup>[7]</sup> reported contact dermatitis to neomycin in 10 patients with atopic dermatitis. One of the patients, a 50-year-old woman had an eczematous dermatitis of her left flexor arm for which prior treatment with neomycin ointment had irritated the dermati-

**Table 1 Agents associated with allergic follicular contact dermatitis**

Agent	Comment	Ref.
Ammonium fluoride	A farm helper who sprayed trees with chemical and had an exudative dermatitis and a postal employee with right foot and bilateral popliteal dermatitis; patch test showed folliculoporal reaction	[2]
Chromium trioxide	A shoe-shiner with severe hand dermatitis, a plasterer who worked with cement (after a cast had been applied to his hand to treat a fracture), and an electrician with chronic dermatitis flared when he drilled through aluminum coated with zinc chromate primer; all had a folliculoporal patch testing reaction	[2]
Cobalt chloride	103 follicular patch test reactions in 853 heavy metal workers that were tested	[3]
Colored permanent pressing sheets chemical	Sheets were 50% cotton and 50% polyester; widely disseminated erythematous follicular keratotic papules; primarily on hairy areas with a predominance on legs and forearms. Several washings of sheets did not prevent dermatitis; it persisted up to 8 wk after sheets removed	[10]
Copper sulfate	110 patients patch tested; 8 of 69 who reacted had follicular or poral (folliculoporal) reactions	[2]
Cosmetic creams	5 young women in a 3 mo period; at sites where cream applied following bathing or before sun exposure: extensor limbs (with well developed vellus hairs) were greatly affected	[1]
Dander (human)	Patch test reactions to dander histologically showed eczematous changes in the upper parts of hair follicles and clinically consisted of erythema and papules; they were positive in 120 of 181 atopic patients, 2 of 28 allergic contact dermatitis patients, and 1 of 31 normal controls	[14]
Formaldehyde	A postal employee with right foot and bilateral popliteal dermatitis; patch test showed folliculoporal reaction 2 women developed textile contact dermatitis to a new long sleeved shirt and new pajamas; a hair usually pierced the center of the papular lesions Positive patch test reactions frequently showed a follicular pattern; in some patients, only bright red follicular papules set in a background of normal appearing skin	[2,8,15]
Homomenthyl salicylate	Sunscreening chemical in a suntan lotion; 2 women with follicular dermatitis. One of the woman developed consort allergic contact dermatitis from contact with her boy friend who used the lotion; she was originally misdiagnosed as having recurrent disseminated infundibulofolliculitis	[6]
Methyl glucose sesquistearate	Follicular dermatitis developed to both a lotion and facial cream that contained this chemical	[16]
Neomycin	Repeat topical application on abdomen (current report) and patch test reaction (woman with atopy and left arm dermatitis that flared after applying neomycin ointment)	[7,9]
Nickel sulfate	A farm helper who sprayed trees with chemical and had an exudative dermatitis; patch test showed folliculoporal reaction 29 follicular patch test reactions in 853 heavy metal workers that were tested Female production line worker with dermatitis of hands, chest and face after exposed to metals and cutting fluids and patch test positive to nickel; she developed follicular contact dermatitis in her pubic area 2 d after shaving with a metal razor blade	[2,17,18]
Paraphenylenediamine	An atopic woman with recurrent episodes of follicular-based pruritic papules on her face, chest and back beginning 3 wk after starting daily oral hydrochlorothiazide; she had a similar dermatitis after contact with "black hair dye" and positive patch test reaction to paraphenylenediamine (which cross reacts with her new oral antihypertensive)	[19]
Polyoxyethylene laurylether	An emulsifier (and an addition of lauryl alcohol and ethylene oxide) used in cosmetics. A woman developed pruritic follicular facial papules after starting to use new cosmetics; both a use test and a patch test for polyoxyethylene laurylether showed a follicular papular reaction	[20]
Potassium dichromate	61 follicular patch test reactions in 853 heavy metal workers that were tested	[3]
Selenium salts	In glass industry, 4 employees exposed to barium and sodium selenite suffered from dermatitis and/or conjunctivitis; 2 of the patients developed follicular allergic contact dermatitis with papulo-follicular lesions. Patch testing with sodium selenite confirmed the diagnosis	[21]
Sodium tungstate	3 follicular patch test reactions in 853 heavy metal workers that were tested; heavy metal contains about 90% tungsten carbide	[3,18]
Tocopheryl linoleate	Vitamin E derivative added to base formulation of a cosmetic line in Switzerland; 905 patients with papular and follicular dermatitis. Positive patch test reactions to cosmetics and vitamin E linoleate	[4,5]

tis<sup>[7]</sup>. Patch testing to neomycin ointment "...was characterized by multiple small (papules of) eczematous areas rather than a confluent eczematous plaque<sup>[7]</sup>".

The patient in Figures 1-4 developed allergic contact dermatitis to neomycin. Her initial lesions were perifollicular papules. Some of these subsequently developed into confluent plaques.

## PATHOGENESIS OF FOLLICULAR CONTACT DERMATITIS

Several hypotheses have been suggested for the selective involvement of the follicles in follicular contact dermatitis in contrast to the diffuse clinical changes more fre-

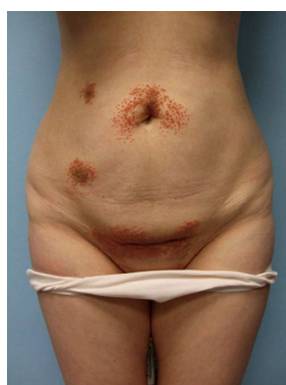quently observed in allergic or irritant contact dermatitis. These include direct penetration of the stratum corneum by the agent *via* the pilosebaceous apparatus, hapten conjugation of the agent to a substance only present in the infundibular region, or both<sup>[6]</sup>. Other factors may also influence the development of follicular contact dermatitis.

### Patient allergenicity

Previously individuals with atopy were considered less likely to be susceptible to allergic contact dermatitis. However, several subsequent studies have demonstrated that atopic patients not only develop contact dermatitis to metals<sup>[37]</sup>, but also more commonly develop follicular contact dermatitis<sup>[38,39]</sup>. Hence, the patient's diathesis to allergens may influence whether they develop follicular

**Table 2** Agents associated with irritant follicular contact dermatitis

Agent	Comment	Ref.
Beetle toxin	Pederin toxin released as a defensive mechanism from the rove (staphylinid) beetle in hot tropical and moderate climate regions typically limited to uncovered body areas	[22,23]
Bis-hydroxyethyl-tallow amine	Antistatic agent used to impregnate plastic tote boxes; outbreak of the hand or arms of 48.3% (14 of 29) of employees of the incoming inspections department of a microelectronic plant. The chemical provoked both follicular and nonfollicular irritant dermatitis; it was also a potential skin sensitizer	[24]
Coal-tar products	Hand dermatitis presenting with follicular papules and pustules at the site of exposure to coal-tar oils, creosote, pitch	[25]
Croton oil	Occupational source for irritant pustular and follicular irritant contact hand dermatitis	[25]
Debromoaplysiatoxin	Occurs after swimming in water contaminated by sea algae ( <i>Lyngbya majuscula</i> Gomont); the alga cause a seaweed dermatitis in persons swimming off the coast of Oahu, Hawaii. Topical application of the toxin produces an irritant pustular folliculitis	[26]
Fluorine	Antirust solution containing 20% ammonium bifluoride diluted in water; acute irritant contact dermatitis in an atopic child. Rusted buckles of the right shoe cleaned with solution; 12 h later, the 19-mo-old boy developed an erythematous pustular dermatitis on the areas of the treated buckles	[27]
Greases	Occupational source for irritant pustular and follicular irritant contact hand dermatitis	[25]
Naphthalenes	Occupational source for irritant pustular and follicular irritant contact hand dermatitis	[25]
Petroleum	Hand dermatitis presenting with follicular papules and pustules at the site of exposure to petroleum derivatives: crude oil and fractions, cutting oils; lesions develop at the contact site to oil-soaked and tar-soaked clothes	[25]
Propylene glycol	It is used as a solvent, a plasticizer, a component of household products, a food additive and an ingredient in cosmetics and pharmaceutical preparations. 45138 patients patch tested; only 1044 (2.4%) patients with actual allergic contact dermatitis and 43 (0.10%) patients with non-allergic follicular reactions	[28]
Tri-phenyl-tin-fluoride	It is a bioactive organo-tin compound used as agricultural fungicides, general biocides, bactericides, herbicides, insecticides and antifoulant in boat paints (ship bottom coatings); it is moderately toxic to the skin. The patient's forearm accidentally contacted an empty drum that was still contaminated with the chemical; within 2 d he developed multiple follicular keratosis-like red papules evenly distributed over the affected area	[11]
Tocopheryl linoleate	Vitamin E derivative added to base formulation of a cosmetic line in Switzerland; 905 patients with papular and follicular dermatitis. In a few patients, the skin reaction appeared after a few applications on discontinuous days or more rarely after a single application suggesting an irritation reaction	[4,5]



**Figure 1** Neomycin-associated follicular contact dermatitis presenting as follicular papules on the right abdomen, in and around the umbilicus, and the suprapubic region. The patient is a 59-year-old Asian woman who presented with itchy lesions at the sites of prior incisions on her lower abdomen. Her past medical history was significant for stage I, T2N0M0 adenocarcinoma of the sigmoid colon. Her tumor was successfully managed by a laparoscopic anterior resection of the sigmoid colon.

contact dermatitis<sup>[17]</sup>.

### Characteristics of the agent

Heavier molecules are less easily capable of penetrating the epidermis as compared to lighter molecules. Hence, it can be hypothesized that the heavier molecules exhibit a preference for entering the dermis through the pilosebaceous units of hair follicles. For example, cobalt demonstrates an increased number and severity of contact dermatitis reactions at follicles<sup>[3]</sup>. Neomycin, is a larger

molecule than cobalt; therefore, the size of neomycin may account for the observed follicular contact dermatitis to this agent (Figures 1-4).

The concentration of the agent can also influence a predilection for follicular contact dermatitis. Not only cobalt, but also tungstate shows an increase in follicular reactions at higher concentrations<sup>[3,18]</sup>.

### Vehicle containing the agent

Lipophilic irritant agents absorb through the pilosebaceous apparatus<sup>[40]</sup>. However, water-soluble substances penetrate more easily into and around hair follicles<sup>[3]</sup>. Yet, in patch test reactions to metals, follicular contact dermatitis is more common when the testing vehicle is petrolatum as compared to water<sup>[3]</sup>.

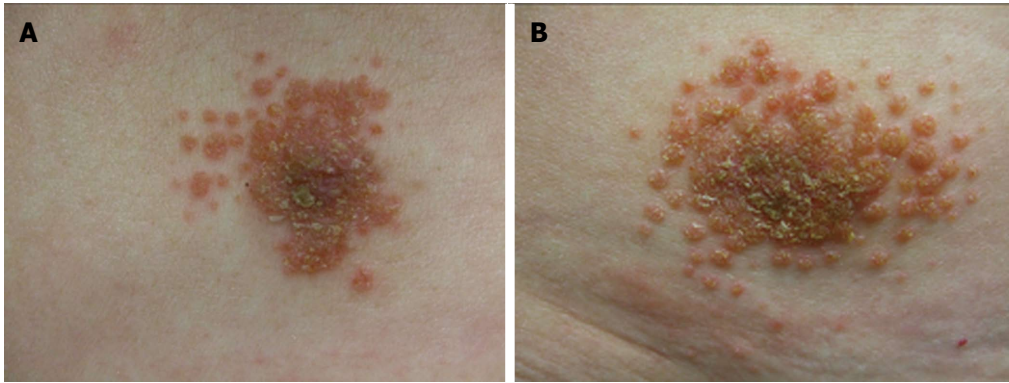
### Application of the agent

Not only in patch testing, but also in clinical use features regarding the application of the agent can potentially influence the occurrence and severity of follicular contact dermatitis<sup>[41,42]</sup>. It is reasonable to hypothesize that repeated application and occlusion of the agent may allow for greater contact with larger areas of epithelium instead of only the follicles, resulting in a more confluent dermatitis. Therefore, follicular reactions are less likely to occur when the agent is applied more frequently or is occluded.

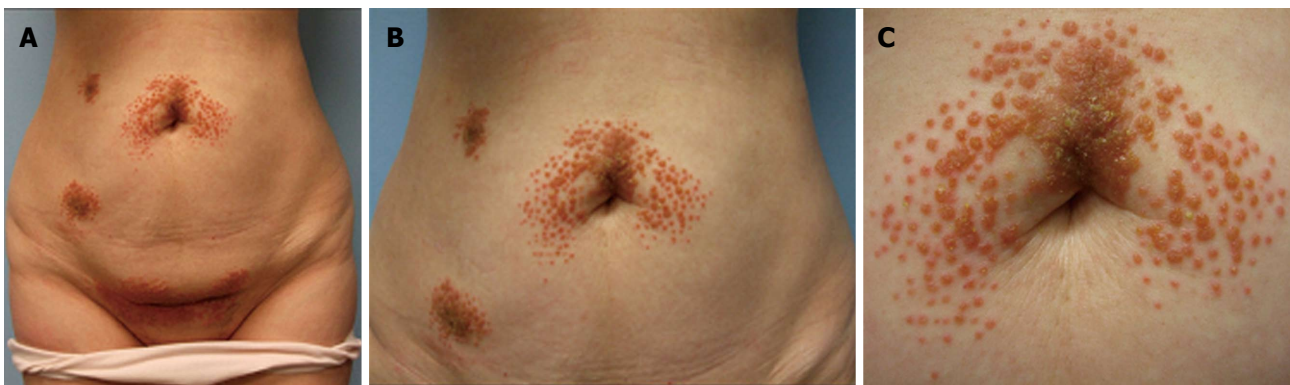### External factors

Follicular contact dermatitis to heavy metals was increased in individuals with hyperkeratosis of their hair follicles;

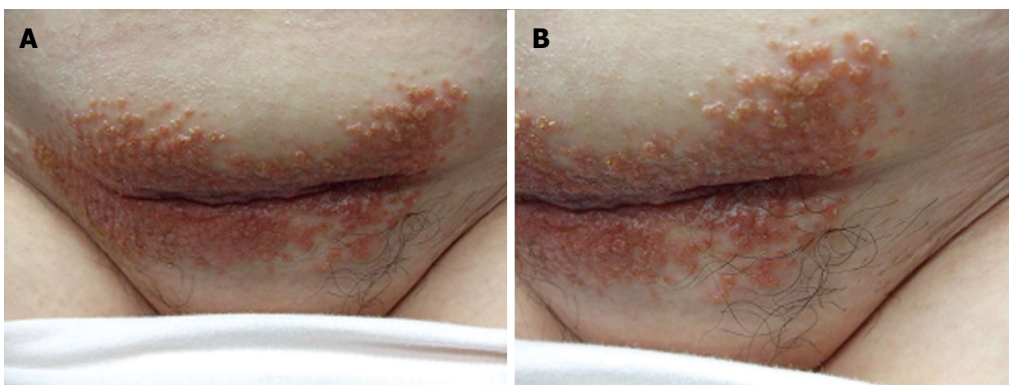




**Figure 2** Closer view of neomycin-associated follicular contact dermatitis on the right mid abdomen (A) and right lower abdomen (B). The woman noted, one month postoperatively, that there was still some drainage from her surgical wounds. She was instructed to daily clean the sites and apply an antibiotic ointment that contained neomycin sulfate, polymyxin B zinc, and bacitracin zinc (Neosporin ointment). She began to develop small individual lesions at the sites of antibiotic ointment application after 6 wk of daily topical treatment; however, she continued to treat the incision sites for another 4 wk as the individual lesions enlarged and some become confluent-before seeking medical attention.



**Figure 3** Cutaneous examination of her abdomen and suprapubic region (A) showed individual and confluent red-brown pruritic papules where she had been applying the antibiotic ointment to prior incision sites: right mid abdomen, right lower abdomen, umbilicus and periumbilical area (B, distant view and C, closer view) and suprapubic region.



**Figure 4** Distant (A) and closer (B) inspection, particularly of the lesion in her suprapubic area, showed individual hair follicles in the center of the papules. The topical antibiotic was discontinued and flucanide 0.05% cream was applied twice daily; all of the lesions resolved within 2 wk with residual post inflammatory hyperpigmentation at the sites.

however, it was not associated with either the presence of acne or sweating<sup>[3]</sup>. In contrast, not only sweating, but also pressure and friction contributed to the development of follicular contact dermatitis caused by a chemical in colored permanent pressing sheets<sup>[10]</sup>. These external factors enhanced the penetration of the allergen into the follicles of the patients who developed dermatitis<sup>[10]</sup>.

## DIFFERENTIAL DIAGNOSIS OF FOLLICULAR CONTACT DERMATITIS

Conditions to be considered in the differential diagnosis of follicular contact dermatitis are listed in Table 3<sup>[6,10]</sup>. Some of the patients with follicular contact dermatitis were initially considered to have disseminated recurrent

**Table 3 Clinical differential diagnosis of follicular contact dermatitis**

Drug eruption
Fiberglass dermatitis
Food allergy
Hyperkeratosis follicularis et follicularis in cutem penetrans (Kyle's disease)
Infundibulofolliculitis
Keratosis follicularis (Darier's disease)
Keratosis pilaris
Perforating folliculitis
Pityriasis rubra pilaris
Scabies
Viral exanthema

infundibular folliculitis—even though they were Caucasian<sup>[6,10]</sup>. In contrast to follicular contact dermatitis which was characterized by severe itching or areas of erythema and oozing or both in some of the patients, infundibular folliculitis is typically observed in black patients as mild to moderately pruritic or burning, flesh colored, widely distributed, non-inflammatory follicular papules; the papules are typically refractory to treatment and the recurrent episodes persist for weeks to months before spontaneously resolving<sup>[43,44]</sup>.

An individual in whom infundibulofolliculitis was suspected presented with recurrent 2-mm erythematous follicular papules. She was a 24-year-old nurse whose skin eruption partially improved with topical corticosteroids and resolved when her boyfriend moved to another city. However, it recurred when he returned and they went to the beach. Subsequently, the diagnosis of consort follicular contact dermatitis to the homomenthyl salicylate in her boy friend's Coppertone sunscreen lotion was considered and confirmed by positive patch testing to the lotion; additional patch testing to each component of the lotion was only positive for homomenthyl salicylate<sup>[6]</sup>.

The other patients had been exposed to a chemical used in colored permanent-pressed sheets<sup>[10]</sup>. Not only the distribution and duration of the follicular contact dermatitis, but also the histopathology of the chemical-associated lesions were similar to those observed in individuals with infundibulofolliculitis. However several features permitted the patients with follicular contact dermatitis to be differentiated from those with infundibulofolliculitis: severe itching (as compared to mild or moderate pruritus), the presence of erythematous and even oozing areas (as compared to noninflammatory lesions) and a white patient population (as compared to occurring in African American individuals)<sup>[10]</sup>.

## MANAGEMENT OF FOLLICULAR CONTACT DERMATITIS

The primary management of follicular contact dermatitis is withdrawal of the causative agent. The skin lesions for many of the affected individuals either resolved spontaneously or following treatment with a topical corticosteroid preparation. However, in some of the patients

lesions either persisted or recurred even after elimination of the inducing chemical or repetitive washing of the eliciting item from the source of exposure; specifically, follicular contact dermatitis persisted up to 8 wk after exposure to chemical in colored permanent-pressed sheets had been eliminated and new lesions would appear even after the sheets had been washed 3 or 4 times<sup>[10]</sup>.

## CONCLUSION

Follicular contact dermatitis clinically presents as individual papules that include a central hair follicle. Pathologic features involve the follicle and the surrounding dermis: spongiosis and vesicle formation of the follicular epithelium associated with perifollicular and perivascular lymphocytic inflammation. Several chemicals, including topical antibiotics, can elicit follicular contact dermatitis—either as allergens or irritants. Neomycin-associated follicular contact dermatitis was initially reported in 1952. Subsequently, follicular contact dermatitis in additional patients treated with neomycin was observed and the diagnosis was confirmed by patch testing with the agent. Several hypotheses have been suggested for the selective involvement of the follicles in follicular contact dermatitis: patient allergenicity, characteristics of the agent, vehicle containing the agent, application of the agent, and external factors. The differential diagnosis of follicular contact dermatitis includes not only recurrent infundibulofolliculitis, but also drug eruption, mite infestation, viral infection, and dermatoses that affect hair follicles. Withdrawal of the causative agent is the primary therapeutic intervention for follicular contact dermatitis. In addition, treatment with a topical corticosteroid preparation may promote resolution of the dermatitis.

## REFERENCES

- 1 Mitchell JC. Follicular contact dermatitis from cosmetic creams. *Can Med Assoc J* 1980; **123**: 972 [PMID: 7448673]
- 2 Becker SW, O'BRIEN MP. Value of patch tests in dermatology; special study of follicular reactions. *AMA Arch Derm* 1959; **79**: 569-577 [PMID: 13636448 DOI: 10.1001/archderm.1959.01560170067010]
- 3 Fischer T, Rystedt I. False-positive, follicular and irritant patch test reactions to metal salts. *Contact Dermatitis* 1985; **12**: 93-98 [PMID: 3157537 DOI: 10.1111/j.1600-0536.1985.tb01060.x]
- 4 Perrenoud D. Papular and follicular contact dermatitis: irritation and/or allergy? Swiss Contact Dermatitis Research Group. *Curr Probl Dermatol* 1995; **23**: 9-17 [PMID: 9035932]
- 5 Perrenoud D, Homberger HP, Auderset PC, Emmenegger R, Frenk E, Saurat JH, Hauser C. An epidemic outbreak of papular and follicular contact dermatitis to tocopheryl linoleate in cosmetics. Swiss Contact Dermatitis Research Group. *Dermatology* 1994; **189**: 225-233 [PMID: 7949472 DOI: 10.1159/000246843]
- 6 Rietschel RL, Lewis CW. Contact dermatitis to homomenthyl salicylate. *Arch Dermatol* 1978; **114**: 442-443 [PMID: 629582 DOI: 10.1001/archderm.1978.01640150078023]
- 7 Jillson OF, Curwen WL, Alexander BR. Problems of contact dermatitis in the atopic individual, with reference to neomycin and ragweed oil sensitivity. *Ann Allergy* 1959; **17**: 215-223 [PMID: 13650423]
- 8 Uehara M. Follicular contact dermatitis due to formalde-

- hyde. *Dermatologica* 1978; **156**: 48-54 [PMID: 145383 DOI: 10.1159/000250896]
- 9 **Epstein S**. Dermal contact dermatitis from neomycin; observations on forty cases. *Ann Allergy* 1958; **16**: 268-280 [PMID: 13545700]
  - 10 **Panaccio F**, Montgomery DC, Adam JE. Follicular contact dermatitis due to coloured permanent-pressed sheets. *Can Med Assoc J* 1973; **109**: 23-26 [PMID: 4268628]
  - 11 **Andersen KE**, Petri M. Occupational irritant contact folliculitis associated with triphenyl tin fluoride (TPTF) exposure. *Contact Dermatitis* 1982; **8**: 173-177 [PMID: 6212184 DOI: 10.1111/j.1600-0536.1982.tb04178.x]
  - 12 **Vestergaard L**, Clemmensen OJ, Sørensen FB, Andersen KE. Histological distinction between early allergic and irritant patch test reactions: follicular spongiosis may be characteristic of early allergic contact dermatitis. *Contact Dermatitis* 1999; **41**: 207-210 [PMID: 10515099 DOI: 10.1111/j.1600-0536.1999.tb06131.x]
  - 13 **Gehrig KA**, Warshaw EM. Allergic contact dermatitis to topical antibiotics: Epidemiology, responsible allergens, and management. *J Am Acad Dermatol* 2008; **58**: 1-21 [PMID: 18158924 DOI: 10.1016/j.jaad.2007.07.050]
  - 14 **Uehara M**, Ofuji S. Patch test reactions to human dander in atopic dermatitis. *Arch Dermatol* 1976; **112**: 951-954 [PMID: 938073 DOI: 10.1001/archderm.1976.01630310013002]
  - 15 **Epstein E**, Maibach HI. Formaldehyde allergy. Incidence and patch test problems. *Arch Dermatol* 1966; **94**: 186-190 [PMID: 5916470 DOI: 10.1001/archderm.1966.01600260078009]
  - 16 **Dooms-Goossens A**, Vandekerckhove M, Verschave H, Degre H. Cosmetic dermatitis due to methyl glucose sesquiterate. *Contact Dermatitis* 1984; **10**: 312-313 [PMID: 6734194 DOI: 10.1111/j.1600-0536.1984.tb00153.x]
  - 17 **Kanerva L**, Estlander T. Occupational allergic contact dermatitis associated with curious public nickel dermatitis from minimal exposure. *Contact Dermatitis* 1995; **32**: 309-310 [PMID: 7634792 DOI: 10.1111/j.1600-0536.1995.tb00792.x]
  - 18 **Rystedt I**, Fischer T, Lagerholm B. Patch testing with sodium tungstate. *Contact Dermatitis* 1983; **9**: 69-73 [PMID: 6839742]
  - 19 **Jacob SE**, Zapolanski T, Chayavichitsilp P. Sensitivity to para-phenylenediamine and intolerance to hydrochlorothiazide. *Dermatitis* 2008; **19**: E44-E45 [PMID: 19134428]
  - 20 **Kimura M**, Kawada A. Follicular contact dermatitis due to polyoxyethylene lauryl ether. *J Am Acad Dermatol* 2000; **42**: 879-880 [PMID: 10767693 DOI: 10.1016/S0190-9622(00)90260-3]
  - 21 **Richter G**, Heidebach U, Heidenbluth I. Allergic contact eczemas caused by selenite. *Derm Beruf Umwelt* 1987; **35**: 162-164 [PMID: 2961548]
  - 22 **Sendur N**, Savk E, Karaman G. Paederus dermatitis: a report of 46 cases in Aydin, Turkey. *Dermatology* 1999; **199**: 353-355 [PMID: 10640849]
  - 23 **Dursteler BB**, Nyquist RA. Outbreak of rove beetle (Staphylinid) pustular contact dermatitis in Pakistan among deployed U.S. personnel. *Mil Med* 2004; **169**: 57-60 [PMID: 14964503]
  - 24 **Bennett DE**, Mathias CG, Susten AS, Fannick NL, Smith AB. Dermatitis from plastic tote boxes impregnated with an anti-static agent. *J Occup Med* 1988; **30**: 252-255 [PMID: 2966239]
  - 25 **Bauer A**. Hand dermatitis: uncommon presentations. *Clin Dermatol* 2005; **23**: 465-469 [PMID: 16179180]
  - 26 **Solomon AE**, Stoughton RB. Dermatitis from purified sea algae toxin (debromoaplysiatoxin). *Arch Dermatol* 1978; **114**: 1333-1335 [PMID: 686747]
  - 27 **Stéciuk A**, Domp Martin A, Saussey J, Louvet S, Leroy D. Pustular contact dermatitis from fluorine in an antirust solution. *Contact Dermatitis* 1997; **36**: 276-277 [PMID: 9197975]
  - 28 **Lessmann H**, Schnuch A, Geier J, Uter W. Skin-sensitizing and irritant properties of propylene glycol. *Contact Dermatitis* 2005; **53**: 247-259 [PMID: 16283903]
  - 29 **Epstein S**. Contact dermatitis due to nickel and chromate; observations on dermal delayed (tuberculin-type) sensitivity. *AMA Arch Derm* 1956; **73**: 236-255 [PMID: 13291894]
  - 30 **Spann CT**, Taylor SC, Weinberg JM. Topical antimicrobial agents in dermatology. *Dis Mon* 2004; **50**: 407-421 [PMID: 15280871]
  - 31 **Kaye ET**. Topical antibacterial agents. *Infect Dis Clin North Am* 2000; **14**: 321-339 [PMID: 10829258]
  - 32 **Larsen WG**. Topical neomycin. *Arch Dermatol* 1968; **97**: 202-203 [PMID: 4865737]
  - 33 **Held JL**, Kalb RE, Ruszkowski AM, DeLeo V. Allergic contact dermatitis from bacitracin. *J Am Acad Dermatol* 1987; **17**: 592-594 [PMID: 3668004]
  - 34 **Jiaravuthisan MM**, DeKoven JG. Contact dermatitis to polymyxin B. *Contact Dermatitis* 2008; **59**: 314-316 [PMID: 18976383]
  - 35 **Grandinetti PJ**, Fowler JF. Simultaneous contact allergy to neomycin, bacitracin, and polymyxin. *J Am Acad Dermatol* 1990; **23**: 646-647 [PMID: 2172331]
  - 36 **Patrick J**, Panzer JD, Derbes VJ. Neomycin sensitivity in the normal (nonatopic) individual. *Arch Dermatol* 1970; **102**: 532-535 [PMID: 5474117]
  - 37 **Cohen PR**, Cardullo AC, Ruszkowski AM, DeLeo VA. Allergic contact dermatitis to nickel in children with atopic dermatitis. *Ann Allergy* 1990; **65**: 73-79 [PMID: 2195923]
  - 38 **Wahlberg JE**, Maibach HI. Sterile cutaneous pustules: a manifestation of primary irritancy? Identification of contact pustulogens. *J Invest Dermatol* 1981; **76**: 381-383 [PMID: 6453167]
  - 39 **Epstein S**. Neomycin sensitivity and atopy. *Dermatologica* 1965; **130**: 280-286 [PMID: 14331058]
  - 40 **Lyle WH**. Lesions of the skin in process workers caused by contact with butyl tin compounds. *Br J Ind Med* 1958; **15**: 193-196 [PMID: 13596538]
  - 41 **Scheuplein RJ**. Mechanism of percutaneous adsorption. I. Routes of penetration and the influence of solubility. *J Invest Dermatol* 1965; **45**: 334-346 [PMID: 5847304]
  - 42 **Scheuplein RJ**. Mechanism of percutaneous absorption. II. Transient diffusion and the relative importance of various routes of skin penetration. *J Invest Dermatol* 1967; **48**: 79-88 [PMID: 6018244]
  - 43 **Hitch JM**, Lund HZ. Disseminate and recurrent infundibulofolliculitis: report of a case. *Arch Dermatol* 1968; **97**: 432-435 [PMID: 5643238]
  - 44 **Hitch JM**, Lund HZ. Disseminate and recurrent infundibulofolliculitis. *Arch Dermatol* 1972; **105**: 580-583 [PMID: 5017270]

P- Reviewer: Chen GS, Sun JQ S- Editor: Song XX  
L- Editor: A E- Editor: Wu HL





## Prognostic factors in periodontal therapy and their association with treatment outcomes

Andreas L Ioannou, Georgios A Kotsakis, James E Hinrichs

Andreas L Ioannou, Georgios A Kotsakis, James E Hinrichs, Advanced Education in Periodontology, Division of Periodontology, University of Minnesota, Minnesota, MN 55455, United States

Author contributions: All authors contributed to this paper.  
Correspondence to: Georgios A Kotsakis, DDS, Dental Fellow, Advanced Education Program in Periodontology, University of Minnesota, 515 Delaware Street SE, Minneapolis, MN 55455, United States. [kotsa001@umn.edu](mailto:kotsa001@umn.edu)  
Telephone: +1-612-6255166

Received: June 13, 2014 Revised: August 22, 2014

Accepted: October 14, 2014

Published online: December 16, 2014

advancements on this topic have been made in the periodontal literature during the last decade. Current evidence shows that except for good prognosis, the assignment of overall prognosis remains rather dicey. The major focus of future studies should be to construct simplified prognostic models with high predictability that will increase the confidence of Dentists and Periodontists when assigning teeth prognosis.

Ioannou AL, Kotsakis GA, Hinrichs JE. Prognostic factors in periodontal therapy and their association with treatment outcomes. *World J Clin Cases* 2014; 2(12): 822-827 Available from: URL: <http://www.wjgnet.com/2307-8960/full/v2/i12/822.htm>  
DOI: <http://dx.doi.org/10.12998/wjcc.v2.i12.822>

### Abstract

During the incipient steps of periodontal treatment, clinicians are usually asked to predict the prognosis of teeth with compromised periodontium. The aim of this literature review was to investigate the association between periodontal Prognosis, Tooth Loss and risk indicators, such as smoking and genetics. Results showed that the definition of good prognosis has much higher predictability than the one for questionable prognosis. Several risk indicators for periodontal prognosis and tooth loss are discussed as well as different definitions of questionable prognosis and their success in predicting tooth loss. In conclusion, the major focus of future studies should be to construct simplified prognostic models with high predictability that will increase the confidence of dentists and periodontists when assigning teeth prognosis.

© 2014 Baishideng Publishing Group Inc. All rights reserved.

**Key words:** Periodontal prognosis; Tooth loss; Risk indicators; Periodontitis

**Core tip:** During the incipient steps of periodontal treatment, clinicians are usually asked to predict the prognosis of teeth with compromised periodontium. Little

### INTRODUCTION

During the incipient phases of periodontal treatment, clinicians are usually asked to predict the prognosis of teeth with compromised periodontium<sup>[1]</sup>. To address this difficult and challenging task, Periodontists have introduced the term “questionable” prognosis. In essence, this term means that a tooth may or may not respond well to treatment and many factors such as patient/host susceptibility, age, location of the tooth and degree of bone loss among others must be weighted to better determine its prognosis.

Scientific attempts to identify risk indicators for tooth loss that can help clarify and better define this term have been reported in the literature. Usually retrospective and cross-sectional studies are employed as these types of investigations allow for access to a large pool of data for analysis without the cost, or the ethical limitations that pertain to interventional studies<sup>[2]</sup>. The drawback is that it is uncertain whether an observational study can verify the causal role of a true risk factor, yet observational studies are valuable in identifying risk indicators<sup>[2]</sup>.

The aim of this critical review was to investigate the



association between periodontal Prognosis, Tooth Loss and risk indicators. This review paper will discuss how specific risk indicators affect periodontal prognosis and how accurate initial periodontal prognosis can be.

## CRITICAL REVIEW

### ***Inceptive definition of questionable prognosis***

Hirschfeld *et al*<sup>[3]</sup> (1978) presented data of a cross-sectional study that included 600 patients with at least 15 years and up to 50 years of follow-up. This patient cohort was described by the authors as consisting of well-motivated middle-class patients that attended frequent (4-6 mo intervals) recalls.

The authors allocated the patients in three groups based on their response to treatment: well maintained (83.2%), downhill (12.6%), or extreme downhill (4.2%).

In the well-maintained group a mean of 0.68 teeth per patient were lost during the follow-up. The number of teeth lost in the downhill and extreme downhill groups were 5.7 and 13.3 per patient, respectively.

In regards to risk indicators for post-treatment tooth loss, residual mobility was insignificant. The authors' definition of questionable prognosis (furcation involvement, deep non-eradicable pocket, extensive bone loss and/or at least grade 2 mobility with active inflammation) was accurate in depicting clinical reality for the well-maintained group. In this group 80% of the teeth lost had been initially assigned a questionable prognosis. That percentage dropped to approximately 50% in the remaining groups. Almost all of the teeth with questionable prognosis were lost in the extreme downhill group. The authors concluded that tooth loss patterns were case-related and they noted a bilaterally symmetrical pattern. They found a predictable order of likelihood of tooth loss according to position in the arch. Mandibular cuspids and first bicuspid responded most favorable to treatment and maintenance, while maxillary second and first molars and mandibular second and first molars were more susceptible to loss. In this study the characteristics of the extreme downhill group were not identified, so the question of how to predict which patients will lose more teeth remains unanswered.

In a similar study McLeod *et al*<sup>[4]</sup> (1997) investigated the effectiveness of periodontal treatment in a cohort of patients with moderate to advanced periodontitis that were treated over a period of 29 years. Tooth loss was set as the primary outcome of treatment. The authors utilized the categorization to well-maintained (0-3 teeth lost), downhill (4-9 teeth lost) and extreme downhill (10-23 teeth lost) groups as suggested by Hirschfeld *et al*<sup>[3]</sup> (1978). The authors defined moderate disease as 4-7 mm of CAL loss and severe as greater than 7 mm of loss. It should be expected that this patient pool would be assigned a diagnosis of severe periodontitis based on contemporary definitions. All patients were treated by means of SRP followed by surgical treatment if indicated and were put on frequent (3-6 mo) recalls. Again, the definition of questionable prognosis was based on Hirschfeld's definition<sup>[3]</sup>. A total

of 2889 teeth were nested in the 114 patients included in this study. After a mean of 12.5 years post-treatment, 220 teeth were lost during maintenance. In agreement with the results of Hirschfeld *et al*<sup>[3]</sup> (1978), the authors noted a bilateral pattern of tooth loss. They also noted that maxillary and mandibular molars and maxillary first premolars had a higher incidence of extractions. The distribution of patients in the well-maintained, downhill and extreme downhill groups was 84.2%, 13.2% and 2.6%, respectively. Those findings are in remarkable agreement with results from the study of Hirschfeld *et al*<sup>[3]</sup> (1978). There was a higher rate of tooth loss in teeth with furcation involvement especially in the downhill groups. In regards to questionable prognosis accuracy, 529 teeth were initially assigned to this prognosis group. Sixty-eight of those teeth were lost (12.9%), while the remaining 152 teeth that were lost had not been assigned a questionable prognosis. Therefore, the negative predictive value of that definition of questionable prognosis is brought to question.

This study was novel in attempting to correlate the Hirschfeld *et al*<sup>[3]</sup> (1978) classification of response to periodontal treatment with the AAP-accepted terminology for periodontal disease. According to the authors: "Nine of the 18 patients in the downhill and extreme-downhill groups had periodontal disease that would be classified as systemic-disease-associated or early-onset periodontitis, and the remaining patients would be classified as having refractory periodontitis". This statement is valuable as it provides an explanation for the response to treatment and maintenance, but does not yield information on how to predict which patients will have a downhill response.

McFall *et al*<sup>[5]</sup> (1982), replicated the study of Hirschfeld *et al*<sup>[3]</sup> (1978) in a faculty-practice based patient population ( $n = 100$ ) that was followed up for at least 15 years. There results were in complete agreement with the previous studies. As in previous studies, maxillary 2<sup>nd</sup> molars were the most frequently lost teeth and mandibular cuspids and bicuspid were the less frequently lost ones. The definition of questionable prognosis that was utilized in this study predicted only 48.7% of the tooth loss in all groups. From the teeth that were initially assigned questionable prognosis, 62.3% were lost during the follow-up.

A question can be raised as to what benefit, other than a rough estimation of the percentage of poor responders, there is in categorizing patients in groups based on the outcome of treatment. Categorizing patients in a group prior to initiation of treatment, based on specific risk indicators and assessing the accuracy in predicting which patients will exhibit downhill response seems more reasonable.

Chace *et al*<sup>[6]</sup> (1993) performed a cross-sectional study that specifically aimed to address the fate of teeth that were assigned a questionable prognosis. The authors' definition of questionable prognosis slightly differed from the previous definitions, as it required that the teeth simultaneously exhibited pocket depth greater than 6 mm, mobility greater than 0.5 mm in buccal-lingual direction, poor

root-crown ratio and at least class II furcation involvement. In this study 166 patients, lending 455 questionable teeth to the study, were followed up over up to 40 years. A total of 55 teeth were lost (12%), with an average survival period of 8.8 years. Half of the teeth were bilaterally symmetrical and as in the previous studies most frequently lost teeth mostly groups were maxillary second molars, first molars, first bicuspid, or mandibular molars<sup>[3-5]</sup>. Even though the accuracy of the assignment of "questionable prognosis" could not be investigated with this study design, results of this study showed that teeth with significant loss of periodontal tissues could be functionally maintained. Yet, factors such as esthetics and patient satisfaction were not discussed.

In another study, Wilson *et al.*<sup>[7]</sup> (1987) focused in investigating the effect of patient compliance on tooth loss. One hundred and sixty-two patients were followed up for at least 5 years and were categorized as "compliant", or "erratic". Results showed that completely compliant patients lost no teeth during the follow-up. Twenty-two patients in the erratic group lost a total 60 teeth, for an average of 0.06/patient/year in that group. The authors claimed a higher percentage of teeth with questionable to poor prognosis being lost, in comparison to teeth that were assigned good or fair prognosis, albeit no statistical test was performed.

## AN EVIDENCED-BASED ATTEMPT TO DEFINE PROGNOSIS: THE "MCGUIRE AND NUNN" STUDIES

In 1991 McGuire<sup>[1]</sup> evaluated the outcome of treatment in 100 patients that were followed up for a mean of 7 years following active treatment. All patients received standard of care non-surgical treatment and all of them received surgical treatment in areas with residual pockets. Patients underwent a stringent maintenance schedule with the first maintenance appointment scheduled at 1 mo post-surgery and at 1-3 mo intervals thereafter. Each tooth was assigned to one of the following five prognosis gradients: good, fair, poor, questionable, and hopeless. The author re-assigned prognosis to each tooth based on the clinical situation at 5 and 8 years post-active treatment. Results showed that the average prognosis of the teeth studied at each interval changed very little from initial to 5 to 8 years.

A 2.1% tooth loss (51/2484) was noted for the study population. The teeth with good prognosis remained relatively stable, while teeth in the fair and poor categories frequently improved. The questionable category generally got better, but a significant number of teeth were lost and teeth in the hopeless category were generally lost. Findings of interest were that prognosis was more accurate for single rooted teeth than multi-rooted, and that 3<sup>rd</sup> molars and mandibular molars tended to perform worse than expected. The author discussed that the criteria for assigning prognosis in this study were less lenient in downgrading a tooth to questionable prognosis in com-

parison to the criteria of Hirschfeld *et al.*<sup>[3]</sup> (1978).

In the second part of this study the authors attempted to investigate the accuracy of a statistical model that would consider several explanatory variables such as, furcation involvement, pocket depth, percentage of bone loss, mobility, crown to root ratio and root proximity, based on the data published previously<sup>[8]</sup>. The model was very accurate in predicting prognosis (approximately 80%), especially in non-molar teeth. When scrutinizing the results, the authors found that the accuracy of the model was significantly compromised when teeth with good prognosis were excluded from the analysis (< 50%). The clinical repercussion of those findings is debatable. It may not be as crucial to determine if a tooth that was assigned questionable prognosis may move to fair, or vice versa. On the contrary it is very valuable the ability to foresee which teeth will shift from the fair, or questionable gradient to hopeless. That question was addressed in the third part of this study that was published later the same year<sup>[9]</sup>.

In the third part of the study the authors extended the follow-up to 16 years. This extended observation time increased the number of teeth lost to 131 of the 2509 initially present. The average survival time for teeth that were lost was approximately 5 years post treatment. In this publication a true endpoint<sup>[10]</sup> was chosen, tooth loss.

Results showed that both the sensitivity and specificity of the suggested prognosis classification increased when tooth loss was considered as the endpoint.

When questionable and hopeless prognoses were grouped together they were relatively accurate in predicting future tooth loss. The authors also constructed a proportional hazard model that identified initial probing depth, initial furcation involvement, initial mobility, initial percent bone loss, parafunctional habits with no biteguard, and smoking risk indicators for tooth loss.

## CONTEMPORARY VIEWS ON PERIODONTAL PROGNOSIS

New data and studies have initiated a shift in the consideration of risk indicators for periodontal prognosis. A vastly increasing number of new studies are now focusing on risk indicators involving host susceptibility rather than local factors<sup>[11,12]</sup>. The genetic and host components of periodontal disease and their association with periodontal prognosis are magnetizing the interest of clinicians. The pathophysiologic cascade underlining this relationship has not been clearly elucidated. Yet, there are clear indications of this association. Fardal *et al.*<sup>[13]</sup> (2004) investigated risk factors associated with tooth loss due to periodontal reasons during maintenance phase of treatment in a hundred patients in a Norwegian specialist periodontal practice. This study examined how initial prognosis related to actual outcome as measured by a true point, namely periodontal tooth loss. The patients included in this practice-based study, had comprehensive periodontal treatment and were followed for 9-11 years

during maintenance care. The authors identified that only 36 (1.5%) of the 2436 teeth present at baseline were subsequently lost due to periodontal disease. The majority 27 (75%) of the teeth lost due to periodontal disease had been assigned an uncertain, poor or hopeless initial prognosis. Fardal *et al*<sup>[13]</sup> found that tooth loss was significantly associated with older age (> 60 years), male gender and smoking, but was not significantly associated with oral health status and family history, and that compliance with maintenance following active periodontal treatment was associated with low levels of tooth loss. Notably, even though the majority of teeth lost due periodontal disease had been initially assigned an uncertain, poor or hopeless prognosis, 9 of the teeth lost (25%) had been assigned a good prognosis at baseline. This indicates that it is not always possible to identify all teeth that are at risk of being lost during the progression of periodontitis. From the interpretation of results of Fardal *et al*<sup>[13]</sup> (2004) it is evident that risk indicators related with host and genetic components are more predictive of tooth loss, rather than those associated with clinical parameters and local factors. Age and gender were significantly associated with tooth loss in contrast with oral health status, indicating a strong association between tooth loss and the genetic-host component of periodontal disease<sup>[13]</sup>.

A common finding in earlier studies on tooth survival following active treatment and maintenance has shown that furcation involvement is a risk indicator for future tooth loss<sup>[1,3,5]</sup> and makes assignment of accurate prognosis very challenging<sup>[9]</sup>. Svärdröm *et al*<sup>[14]</sup> (2000) evaluated 1313 molars in 222 patients in order to analyze the outcome of non-regenerative treatment. They found that from the 899 molars that were deemed maintainable, only 21 (3.5%) were extracted within a 10-year follow-up period. All molars in this group were treated with scaling and root planning followed by modified Widman flap surgery, if indicated. The authors concluded that molar teeth treated with non-resective, non-regenerative approaches have a good long-term prognosis if a frequent recall schedule is followed.

The potential prognostic value of clinical, genetic, and radiographic variables in predicting tooth loss in periodontal patients was assessed in a 10-year retrospective analysis<sup>[15]</sup>. Sixty periodontal patients were treated according to the standard of care and were placed at 3-4 mo maintenance schedules. In addition to standard clinical and radiographic examination, the patient underwent interleukin-1 genotype assessment. The distance of the bottom of the bony defect to the root apex as well as molar teeth were significant predictors of tooth loss. On the contrary deep intrabony defects had a protective effect. Interleukin-1 test was not efficient as a predictor of tooth prognosis.

Faggion *et al*<sup>[16]</sup> (2007) also attempted to identify risk indicators to construct a prognostic model. In agreement with the previous studies, teeth with multiple roots were identified as a significant factor. The authors also identified diabetes mellitus, reduced bone levels at baseline, non-vital pulp and tooth mobility as risk indicators for

future tooth loss.

A simplification of the McGuire<sup>[1]</sup> (1991) classification of periodontal prognosis was proposed by Checchi *et al*<sup>[17]</sup> (2002). This simplified classification includes three prognosis gradients: good, questionable, and hopeless. The authors elected to define prognosis based on residual bone levels and/or furcation involvement. Teeth with more than 75% per cent bone loss were assigned “hopeless” prognosis and teeth that had between 50% to 75% bone loss, or furcation involvement were assigned “questionable” prognosis. If a tooth exhibited both characteristics it was downgraded. Results showed that 0.07% of teeth with good prognosis were lost, 3.63% were lost from the questionable prognosis category and 11.34% were lost from the hopeless prognosis subgroup. While previous prognosis classifications were shown to be accurate for the “good” and “hopeless” prognosis, this simplified approach performed very well for “good” and “questionable” prognosis, but seemed to have been pessimistic in assigning “hopeless” prognosis.

Most of the studies mentioned in this review evaluated the prognosis of teeth that had undergone periodontal treatment and went into a maintenance phase. Neely *et al*<sup>[18]</sup> (2001) looked into risk indicators for tooth loss in an untreated cohort of 154 Sri Lankan tea laborers. This patient cohort had no access to periodontal treatment and represented a population sample of untreated periodontal disease. Results were very interesting as they showed that plaque index and smoking were not associated with mean attachment loss. Age, gingival index, calculus index and time were associated with attachment loss over 20 years of follow-up.

The same group of researchers published a follow-up paper that evaluated a true endpoint (tooth loss) instead of a surrogate endpoint (attachment loss)<sup>[19]</sup>.

Results were striking as they significantly differed from results of the previous study. In this second part, none of the individual risk indicators had a significant impact on tooth loss. Tooth loss was associated with increasing attachment loss in the presence of use of betel nut. Interestingly, betel nut (a nut containing substances with vasoconstricting properties) was found to be a poor predictor of increase in attachment loss in the first part of the study. These findings point out that even though attachment loss is a well-established surrogate for tooth loss in the treatment of periodontitis, studies that utilize surrogate endpoints should always be reviewed with that limitation in mind<sup>[20]</sup>.

### Other risk indicators for tooth loss

Several studies have investigated the effect of single risk indicators, or risk factors, depending on the definition, on tooth loss. Such ones are furcation involvement<sup>[21]</sup>, retained “hopeless” teeth<sup>[22]</sup>, residual deep pockets<sup>[23]</sup> and maintenance schedule frequency<sup>[24]</sup>.

Axelsson *et al*<sup>[24]</sup> (1981) assessed the efficacy of a stringent maintenance schedule in patients that had undergone surgical periodontal therapy. All patients were treated with modified widman flap surgery in all four



quadrants. One third of the initial group of 90 patients was referred back to their general dentists for maintenance, while the remaining two thirds underwent a stringent maintenance schedule that included professional debridement once every two months for the first two years post-operatively and once every three months thereafter. Results showed that there was a significant difference in pocket depth maintenance and maintenance of attachment levels around treated teeth between the “recall” and “non-recall” groups. It should be noted that patients in the stringent maintenance group received subgingival scaling at their bimonthly, or trimonthly visits, when indicated. Results on tooth maintenance in each group were not at all that impressive. No significant difference was noted in the number of teeth lost between the two groups. No teeth were lost in the “recall” group and only few teeth were lost in the “non-recall” group. Numerical results were not published. The authors concluded that stringent maintenance is of paramount importance as it can prevent future attachment loss. One could argue that the authors overemphasized results of this study. It is more reasonable to evaluate a true endpoint, such as tooth loss as being more significant over a surrogate, such as attachment loss<sup>[10]</sup>. On the other hand the sample size on the non-recall group was smaller and as a result the study might have not been powered enough to identify a difference in the incidence of tooth loss, as this is a rare event.

Furcation involvement is another risk indicator that has been highlighted in several studies. Waerhaug<sup>[21]</sup> (1980) investigated the anatomy and pathophysiology of furcation defects and concluded that if clinicians are aware of specific considerations when treating molar teeth with furcation defects, then their prognosis may be improved.

Interesting findings were that there is significantly increased attachment loss in the furcation area in comparison to the outer surfaces of the root and that the absence of bleeding on probing of the marginal gingiva is not associated with absence of inflammation, or progression of disease in the furcation area.

In a different study, researchers attempted to evaluate the retention of “hopeless” teeth as an indicator for future progression of disease in neighboring sites<sup>[22]</sup>. In order to define “hopeless” the authors employed a combination of risk indicators such as at least 75% of bone loss, class 3 furcation defect, residual 8mm pocket depth, or repeated periodontal abscesses. Results showed no significant effect of the hopeless teeth on the “adjacent” surfaces of the neighboring teeth in comparison to the “non-adjacent” ones. Pocket depth post-treatment averaged at approximately 3.5 mm around the teeth that were in the vicinity of retained “hopeless” teeth, which indicates that even though no significant increase in surrogate markers for progression of disease was noted, many of the teeth had residual pockets greater than 3 mm. The authors concluded that retained “hopeless” teeth do not affect the periodontium of neighboring teeth as long as patients undergo frequent maintenance.

The influence of residual pockets in the prognosis of

teeth has also been a matter of interest. Matulienė *et al.*<sup>[23]</sup> (2008) followed 172 patients with residual pockets after the active phase of treatment for 3-27 years. Progression of disease was defined as at least 3 mm of proximal attachment loss in at least two teeth. During the maintenance phase of treatment the percentage of pocket depths that were less than 5 mm did not change significantly. On the other hand, the percentage of pockets that had an initial depth of at least 5 mm increased from 2.9% to 4.3%. Increased pocket depth was found to be strongly associated with tooth loss in multilevel logistic regression analysis. During the follow-up 1.7 teeth were lost per patient. Residual pockets of at least 6 mm that were left untreated were a significant factor for tooth loss. During the maintenance phase, 43% of all cases were identified as progressing cases based on the definition mentioned above. The authors concluded that residual pockets with depth greater or equal to 6 mm represent incomplete periodontal treatment and are a risk indicator for tooth loss.

## CONCLUSION

Even though this topic has been extensively discussed in the literature a solid definition of questionable prognosis has not been yet established. The importance of assigning an accurate prognosis for teeth prior to initiation of treatment cannot be emphasized enough. Not only it sets the foundation of trust between the therapist and the patient but also prevents legal implications from arising after the treatment process.

The major focus of future studies should be to construct simplified prognostic models with high predictability that will increase the confidence of dentists and periodontists when assigning teeth prognosis.

## REFERENCES

- 1 **McGuire MK.** Prognosis versus actual outcome: a long-term survey of 100 treated periodontal patients under maintenance care. *J Periodontol* 1991; **62**: 51-58 [PMID: 2002432 DOI: 10.1902/jop.1991.62.1.51]
- 2 **Hulley SB.** Designing Clinical Research. Pennsylvania: Lippincott Williams & Wilkins, 2007 [DOI: 10.1097/OPX.0b013e3181b2fb29]
- 3 **Hirschfeld L, Wasserman B.** A long-term survey of tooth loss in 600 treated periodontal patients. *J Periodontol* 1978; **49**: 225-237 [PMID: 277674 DOI: 10.1902/jop.1978.49.5.225]
- 4 **McLeod DE, Lainson PA, Spivey JD.** The effectiveness of periodontal treatment as measured by tooth loss. *J Am Dent Assoc* 1997; **128**: 316-324 [PMID: 9066216 DOI: 10.14219/jada.archive.1997.0195]
- 5 **McFall WT.** Tooth loss in 100 treated patients with periodontal disease. A long-term study. *J Periodontol* 1982; **53**: 539-549 [PMID: 6957591 DOI: 10.1902/jop.1982.53.9.539]
- 6 **Chace R, Low SB.** Survival characteristics of periodontally-involved teeth: a 40-year study. *J Periodontol* 1993; **64**: 701-705 [PMID: 8410607 DOI: 10.1902/jop.1993.64.8.701]
- 7 **Wilson TG, Glover ME, Malik AK, Schoen JA, Dorsett D.** Tooth loss in maintenance patients in a private periodontal practice. *J Periodontol* 1987; **58**: 231-235 [PMID: 3295181 DOI: 10.1902/jop.1987.58.4.231]
- 8 **McGuire MK, Nunn ME.** Prognosis versus actual outcome.



- II. The effectiveness of clinical parameters in developing an accurate prognosis. *J Periodontol* 1996; **67**: 658-665 [PMID: 8832476 DOI: 10.1902/jop.1996.67.7.658]
- 9 **McGuire MK**, Nunn ME. Prognosis versus actual outcome. III. The effectiveness of clinical parameters in accurately predicting tooth survival. *J Periodontol* 1996; **67**: 666-674 [PMID: 8832477 DOI: 10.1902/jop.1996.67.7.666]
  - 10 **Greenstein G**. The use of surrogate variables to reflect long-term tooth survivability. *J Periodontol* 2005; **76**: 1398-1402 [PMID: 16101375 DOI: 10.1902/jop.2005.76.8.1398]
  - 11 **Volzing K**, Biliouris K, Kaznessis YN. proTeOn and proTeOff, new protein devices that inducibly activate bacterial gene expression. *ACS Chem Biol* 2011; **6**: 1107-1116 [PMID: 21819083 DOI: 10.1021/cb200168y]
  - 12 **Miao D**, Godovikova V, Qian X, Seshadrinathan S, Kapila YL, Fenno JC. Treponema denticola upregulates MMP-2 activation in periodontal ligament cells: interplay between epigenetics and periodontal infection. *Arch Oral Biol* 2014; **59**: 1056-1064 [PMID: 24973519 DOI: 10.1016/j.archoralbio.2014.06.003]
  - 13 **Fardal Ø**, Johannessen AC, Linden GJ. Tooth loss during maintenance following periodontal treatment in a periodontal practice in Norway. *J Clin Periodontol* 2004; **31**: 550-555 [PMID: 15191591 DOI: 10.1111/j.1600-051X.2004.00519.x]
  - 14 **Svårdström G**, Wennström JL. Periodontal treatment decisions for molars: an analysis of influencing factors and long-term outcome. *J Periodontol* 2000; **71**: 579-585 [PMID: 10807122 DOI: 10.1902/jop.2000.71.4.579]
  - 15 **Muzzi L**, Nieri M, Cattabriga M, Rotundo R, Cairo F, Pini Prato GP. The potential prognostic value of some periodontal factors for tooth loss: a retrospective multilevel analysis on periodontal patients treated and maintained over 10 years. *J Periodontol* 2006; **77**: 2084-2089 [PMID: 17209795 DOI: 10.1902/jop.2006.050227]
  - 16 **Faggion CM**, Petersilka G, Lange DE, Gerss J, Flemmig TF. Prognostic model for tooth survival in patients treated for periodontitis. *J Clin Periodontol* 2007; **34**: 226-231 [PMID: 17257157 DOI: 10.1111/j.1600-051X.2006.01045.x]
  - 17 **Checchi L**, Montevercchi M, Gatto MR, Trombelli L. Retrospective study of tooth loss in 92 treated periodontal patients. *J Clin Periodontol* 2002; **29**: 651-656 [PMID: 12354091 DOI: 10.1034/j.1600-051X.2002.290710.x]
  - 18 **Neely AL**, Holford TR, Löe H, Anerud A, Boysen H. The natural history of periodontal disease in man. Risk factors for progression of attachment loss in individuals receiving no oral health care. *J Periodontol* 2001; **72**: 1006-1015 [PMID: 11525431 DOI: 10.1902/jop.2001.72.8.1006]
  - 19 **Neely AL**, Holford TR, Löe H, Anerud A, Boysen H. The natural history of periodontal disease in humans: risk factors for tooth loss in caries-free subjects receiving no oral health care. *J Clin Periodontol* 2005; **32**: 984-993 [PMID: 16104963 DOI: 10.1111/j.1600-051X.2005.00797.x]
  - 20 **Kotsakis GA**, Kher, U. A critical review of periodontal prognosis and tooth loss. *J Dental Res Rev* 2014; **1**: 32-36 [DOI: 10.4103/2348-3172.126164]
  - 21 **Waerhaug J**. The furcation problem. Etiology, pathogenesis, diagnosis, therapy and prognosis. *J Clin Periodontol* 1980; **7**: 73-95 [PMID: 6929794 DOI: 10.1111/j.1600-051X.1980.tb01951.x]
  - 22 **Wojcik MS**, DeVore CH, Beck FM, Horton JE. Retained "hopeless" teeth: lack of effect periodontally-treated teeth have on the proximal periodontium of adjacent teeth 8-years later. *J Periodontol* 1992; **63**: 663-666 [PMID: 1507046 DOI: 10.1902/jop.1992.63.8.663]
  - 23 **Matuliene G**, Pjetursson BE, Salvi GE, Schmidlin K, Brägger U, Zwahlen M, Lang NP. Influence of residual pockets on progression of periodontitis and tooth loss: results after 11 years of maintenance. *J Clin Periodontol* 2008; **35**: 685-695 [PMID: 18549447 DOI: 10.1111/j.1600-051X.2008.01245.x]
  - 24 **Axelsson P**, Lindhe J. The significance of maintenance care in the treatment of periodontal disease. *J Clin Periodontol* 1981; **8**: 281-294 [PMID: 6947992 DOI: 10.1111/j.1600-051X.1981.tb02039.x]

**P- Reviewer:** Arabaci T, Bartold PM, Shimauchi H

**S- Editor:** Ji FF **L- Editor:** A **E- Editor:** Wu HL



## Sleep disordered breathing in interstitial lung disease: A review

Lauren K Troy, Tamera J Corte

Lauren K Troy, Tamera J Corte, Department of Respiratory Medicine, Royal Prince Alfred Hospital, Camperdown, Sydney NSW 2050, Australia

Lauren K Troy, Tamera J Corte, Sydney Medical School, University of Sydney, Sydney NSW 2006, Australia

Author contributions: Troy LK and Corte TJ were involved in manuscript preparation and writing.

Supported by An Australian Postgraduate Award through the University of Sydney (Troy LK is supported)

Correspondence to: Dr. Tamera J Corte, Department of Respiratory and Sleep Medicine, Royal Prince Alfred Hospital, Missenden Road, Camperdown, Sydney NSW2050, Australia. [tameracorte@mac.com](mailto:tameracorte@mac.com)

Telephone: +61-2-95156120 Fax: +61-2-95158196

Received: July 28, 2014 Revised: September 25, 2014

Accepted: October 14, 2014

Published online: December 16, 2014

**Key words:** Sleep disordered breathing; Interstitial lung disease; Pulmonary fibrosis; Nocturnal hypoxia; Obstructive sleep apnoea

**Core tip:** This article reviews the literature on sleep disordered breathing in interstitial lung disease, seeking to define the important contributing factors and sequelae. The key concepts that are explored include the contribution of nocturnal hypoxaemia to the development of pulmonary hypertension, and the mechanisms behind the observed high prevalence of obstructive sleep apnoea in interstitial lung disease patients.

Troy LK, Corte TJ. Sleep disordered breathing in interstitial lung disease: A review. *World J Clin Cases* 2014; 2(12): 828-834 Available from: URL: <http://www.wjgnet.com/2307-8960/full/v2/i12/828.htm> DOI: <http://dx.doi.org/10.12998/wjcc.v2.i12.828>

### Abstract

Patients with interstitial lung disease commonly exhibit abnormal sleep architecture and increased sleep fragmentation on polysomnography. Fatigue is a frequent complaint, and it is likely that poor sleep quality is a significant contributor. A number of studies have shown that sleep disordered breathing is prevalent in this population, particularly in the idiopathic pulmonary fibrosis subgroup. The factors that predispose these patients to obstructive sleep apnoea are not well understood, however it is believed that reduced caudal traction on the upper airway can enhance collapsibility. Ventilatory control system instability may also be an important factor, particularly in those with increased chemo-responsiveness, and in hypoxic conditions. Transient, repetitive nocturnal oxygen desaturation is frequently observed in interstitial lung disease, both with and without associated obstructive apnoeas. There is increasing evidence that sleep-desaturation is associated with increased mortality, and may be important in the pathogenesis of pulmonary hypertension in this population.

### INTRODUCTION

The interstitial lung diseases (ILD) are a heterogeneous group of disorders characterized by varying degrees of fibrosis and inflammation of lung parenchyma. Sufferers exhibit lung restriction and exercise intolerance, often developing progressive hypoxia over time. Independent of the presence of daytime hypoxia, many individuals with ILD are observed to desaturate during sleep, with or without associated apnoea.

There is mounting evidence that nocturnal hypoxia and sleep-disordered breathing (SDB) may contribute to adverse outcomes. Aside from resulting in poor sleep quality and daytime fatigue, transient repetitive desaturation and associated sympathetic nervous system activation may play a role in the development of pulmonary hypertension and contribute to increased mortality<sup>[1-3]</sup>.

Existing evidence on aspects of sleep physiology and pathophysiology in ILD will be considered within this review.

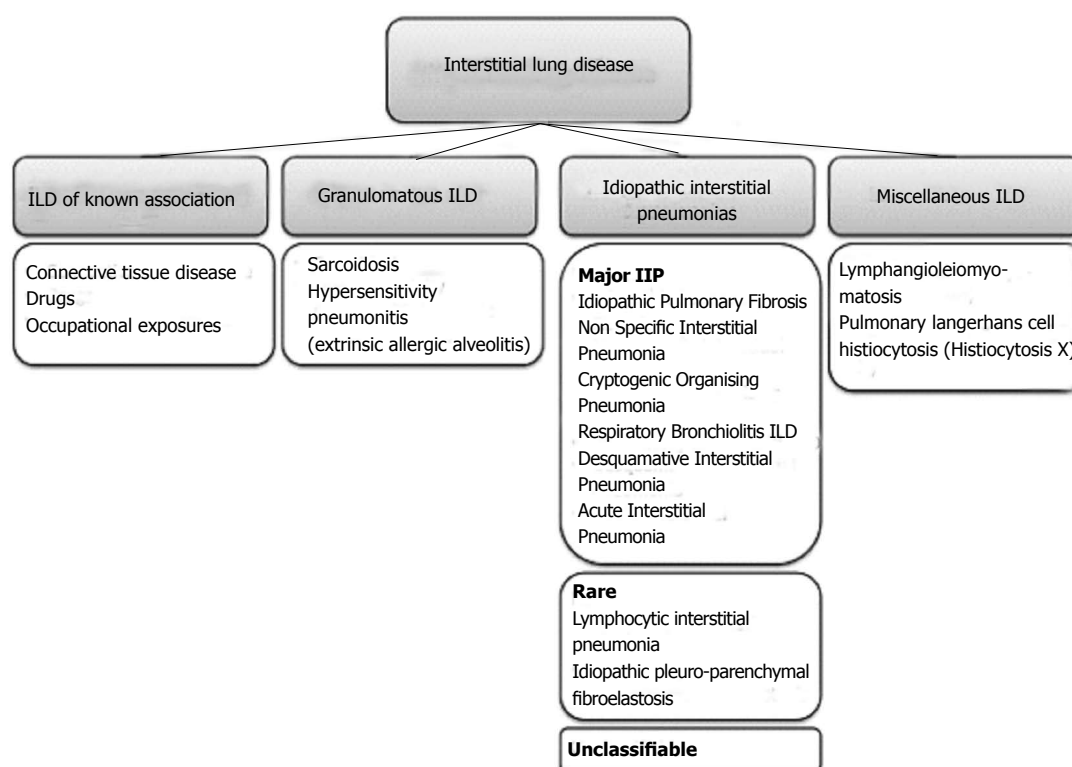


Figure 1 Classification scheme of interstitial lung disease (Adapted from<sup>[4,5]</sup>). ILD: Interstitial lung disease; IIP: Idiopathic interstitial pneumonia.

## POPULATION AT RISK

There are estimates of more than two hundred known causes of ILD, leading to restrictive physiology, dyspnoea and often a pervasive cough. These diseases can be divided into broad subcategories: (1) those with known aetiology such as the pneumoconioses, drug-related ILD, and connective tissue disease-associated ILD; (2) the granulomatous diseases such as sarcoidosis and chronic hypersensitivity pneumonitis; (3) the idiopathic interstitial pneumonias such as idiopathic pulmonary fibrosis (IPF), non-specific interstitial pneumonia, cryptogenic organizing pneumonia (COP); and (4) a miscellaneous group including pulmonary Langerhans cell histiocytosis<sup>[4,5]</sup>. A classification scheme is depicted in Figure 1.

Many of these diseases evolve from an initial inflammatory process involving the lung interstitium with varying inclusion of the lung vasculature and airways. Over time, inflammation may give way to advancing fibrosis, especially in cases where diagnosis and treatment are delayed and inflammation persists unabated. In contrast, IPF is a distinct entity, in which inflammation does not appear to play an important role in the pathogenesis of fibrosis, which often progresses rapidly and relentlessly.

Irrespective of underlying aetiology, advancing fibrosis often leads to worsening gas exchange across a thickened collagen-dense interstitium, and respiratory failure may eventually ensue. Hypoxic vasoconstriction, endothelial remodelling and vascular obliteration all contribute to the development of pulmonary hypertension, a poor prognostic feature when present in ILD patients<sup>[6,7]</sup>.

## SLEEP CHARACTERISTICS IN ILD

### Breathing pattern during sleep

During wakefulness, ILD patients are known to have a rapid, shallow breathing pattern both at rest and with exercise<sup>[8,9]</sup>. This is thought to be due to increased intrinsic elastic loading of respiratory muscles and stimulation of peripheral mechanoreceptors<sup>[8,10]</sup>. Even in the face of severely impaired gas exchange, this respiratory pattern allows ILD patients to maintain ventilation and daytime eucapnia until very advanced stages of disease. During sleep, some investigators have found respiratory frequency,  $f$  to be no different to that when awake<sup>[11-14]</sup>. Others have shown that  $f$  falls, but with an attendant increase in tidal volume, so that overall, the increased minute ventilation is preserved during sleep<sup>[15]</sup>.

### Sleep architecture and sleep quality

Not surprisingly, sleep quality is comparatively poorer than that of the normal population. Nocturnal cough, medications, breathing difficulties, hypoxia and obstructive apneas have all been implicated in disrupting sleep in this population. Perez-Padilla *et al*<sup>[14]</sup> in 1985, compared 11 ILD patients with age- and sex-matched controls. They reported decreased amounts of rapid eye movement (REM) sleep as well as significant sleep fragmentation in the patient group<sup>[14]</sup>. Further prospective studies, with particular focus on IPF confirm these findings, and also report increased stage 1 and 2 sleep, reduced slow wave sleep and poorer overall sleep efficiency<sup>[13,15-20]</sup>. Sleep characteristics in ILD subjects are shown in Table 1.

**Table 1** Sleep characteristics in interstitial lung disease

Sleep characteristic	Abnormality	Patient group	Ref.
Respiratory rate	Decreased	ILD	[15]
	Unchanged	ILD, IPF	[11-14]
Stage 1/2 sleep	Increased	ILD	[14]
		IPF	[19,20]
REM sleep	Reduced	ILD	[11,14,15,25]
		Scleroderma	[26]
Slow wave sleep	Reduced	IPF	[2,19,20]
		ILD	[13]
Arousal index	Increased	ILD	[17,25]
		IPF	[12,14,15]
Sleep efficiency	Reduced	ILD	[2,19,20]
		IPF	[25]
		IPF	[13,19,20]

ILD: Interstitial lung disease; IPF: Idiopathic pulmonary fibrosis; REM: Rapid eye movement.

### Daytime symptoms and quality of life

The symptoms of sleepiness and fatigue often co-exist in ILD patients. Common causative factors include systemic inflammation, treatment side effects, age and comorbidities. Depression and disease-related stressors also affect many. In addition, sleep fragmentation appears to be a substantial contributor, as demonstrated in studies using numerous sleep and health-related quality of life (QoL) questionnaires in ILD subjects. Fatigue is frequently reported, impacting on wellbeing and daytime function<sup>[13,21,22]</sup>. The Epworth Sleepiness Scale (ESS), and Pittsburgh Sleep Quality Index (PSQI) scores are higher in unselected ILD patients than in normal controls, indicating poorer quality sleep<sup>[22-24]</sup>. However, in ILD cohorts with polysomnography, the ESS and other tools do not reliably predict severity of sleep-disordered breathing<sup>[2,19,25]</sup>. The PSQI does appear to correlate with health-related QoL indices, particularly physical function and vitality, highlighting the pervasive influence of sleep fragmentation<sup>[22]</sup>. Nocturnal hypoxia in ILD patients is also independently associated with a reduction in energy levels, as well as physical and social functioning, as assessed by a variety of QoL instruments<sup>[13,21]</sup>.

### Non-respiratory disturbances to sleep

Increased periodic limb movements and restless legs syndrome (RLS) have been documented in IPF and scleroderma patients<sup>[17,26]</sup>. A self-reported study in IPF patients and normal controls, however, did not find any difference in the incidence of RLS<sup>[27]</sup>. Gastro-oesophageal reflux disease may also play a role in sleep disruption, particularly in high-risk groups including scleroderma patients<sup>[26]</sup>.

## OBSTRUCTIVE SLEEP APNOEA IN ILD

Increasing attention has been focused on the prevalence of obstructive sleep apnoea (OSA) in ILD, with much of the cross-sectional data coming from studies in IPF patients. Three prospective studies showed the incidence of OSA in IPF subjects to markedly exceed that reported in healthy age-matched populations, with estimates between

59% and 90%<sup>[2,19,20]</sup>. This increased risk however, does not appear to be unique to IPF, with studies of mixed ILD populations (and in particular sarcoidosis and scleroderma subgroups) demonstrating similar findings<sup>[18,25,28]</sup>. These results are summarized in Table 2.

### Association between degree of OSA and severity of lung disease

Although retrospective analyses of ILD subjects suggest an association between the degree of lung restriction and the risk and severity of sleep disordered breathing, this has not been demonstrated in larger, prospective studies<sup>[2,17,19,20,25,29]</sup>. The only correlation between measured lung volumes and PSG parameters, reported by Mermigkis *et al.*<sup>[20]</sup>, was in total lung capacity and REM sleep apnoea hypopnoea index (AHI). Kolilekas *et al.*<sup>[2]</sup> found an association between overall AHI and peak VO<sub>2</sub> on exercise testing, but this may simply reflect poorer daytime function and more deconditioning in those with more fragmented sleep.

### Hypotheses for why SDB is increased in patients with ILD

In the general OSA literature, recent attention has been turned towards the inherent characteristics that predispose individuals to sleep disordered breathing. The two key components believed to underscore the pathogenesis of OSA are increased upper airway collapsibility and enhanced ventilatory control system instability<sup>[30]</sup>. It is useful to consider these processes in the ILD population.

**Upper airway collapsibility:** It is generally believed that restrictive lung disease leads to increased upper airway collapsibility through reduced caudal traction on these structures<sup>[31,32]</sup>. The inability to demonstrate a relationship between lung function parameters and AHI seems to refute this theory. One limitation with all reported data, however, is the assessment of lung function in the upright position only. There may be more robust associations between supine measurements and SDB, but this is yet to be investigated in ILD subjects. Increased body mass index (BMI) is associated with deposition of adipose tissue around upper airway structures, enhancing collapsibility. BMI correlates with AHI in some, but not all studies of ILD subjects, suggesting that other mechanisms are important<sup>[2,18-20,25]</sup>.

**Ventilatory control system instability:** In sleep, any rise in arterial CO<sub>2</sub> (such as occurs with an apnoea) will stimulate carotid and medullary chemoreceptors, resulting in a central respiratory motor output response<sup>[33]</sup>. The direct activation of respiratory pump muscles and upper airway dilator muscles (*e.g.*, genioglossus) restores upper airway patency, and is often accompanied by an arousal. Some individuals with heightened chemo-responsiveness may overshoot the eucapnic range, by overventilating in response to apnoea-induced hypercapnia. The ensuing hypocapnia will then cause a further apnoea, sometimes leading to a cyclical pattern of repetitive apnoeas as the ventilatory system continues to attempt to achieve ho-



**Table 2** Prevalence of obstructive sleep apnoea in interstitial lung disease populations *n* (%)

Ref.	Population	Prevalence of OSA	M/F	Age (mean)	BMI (mean)	Comment
Aydoğdu <i>et al</i> <sup>[18]</sup> , 2006	ILD	24 (65)				Abstract only
Mermigkis <i>et al</i> <sup>[17]</sup> , 2007	IPF	11 (61)	12/6	68.1	33.2	Retrospective study; subjects with symptoms of SDB
Lancaster <i>et al</i> <sup>[19]</sup> , 2009	IPF	44 (88)	34/16	65.7	32.2	Prospective study of unselected patients; 16 subjects used oxygen during PSG
Mermigkis <i>et al</i> <sup>[20]</sup> , 2010	IPF	20 (59)	21/13	65.0	27.3	Prospective study of subjects with newly diagnosed IPF
Kolilekas <i>et al</i> <sup>[21]</sup> , 2013	IPF	28 (90)	24/7	68.0	28.7	Increased AHI associated with decreased survival, after exclusion of those prescribed CPAP
Pihtili <i>et al</i> <sup>[25]</sup> , 2013	ILD	34 (68)	14/36	53.9	25.9	Prospective study; excluded obese subjects (BMI ≥ 30)
	IPF	14 (82)				
	Sarcoidosis	10 (67)				
	Scleroderma	10 (56)				

OSA: Obstructive sleep apnoea; BMI: Body mass index; ILD: Interstitial lung disease; IPF: Idiopathic pulmonary fibrosis; SDB: Sleep disordered breathing; PSG: Polysomnography; AHI: Apnoea hypopnoea index; CPAP: Continuous positive airway pressure.

meostasis. This ventilatory system instability is believed to be an important contributing factor in many with OSA<sup>[34]</sup>.

Intermittent hypoxia enhances chemo-responsiveness, and is likely to exacerbate ventilatory instability in susceptible individuals<sup>[35]</sup>. This may at least partly explain the frequent observation in some ILD patients, where repetitive apnoeas are unmasked during REM sleep when hypoxia is most pronounced<sup>[20]</sup>.

## NOCTURNAL OXYGEN DESATURATION IN ILD

Nocturnal hypoxia is common in ILD, both with and without concomitant OSA. The relative importance of this has been debated, with some early studies concluding that desaturation was minimal, having little clinical impact in ILD<sup>[15,16,36]</sup>. Other observational studies found that ILD patients experience transient or sustained hypoxia repetitively throughout sleep, leading to a substantial cumulative period of time with SpO<sub>2</sub> below 90%<sup>[11-14,18,21]</sup>. More recently, sleep-desaturation has been found to be an independent predictor of poorer prognosis<sup>[1,2]</sup>.

Whilst obstructive events will undoubtedly be the cause for a proportion of the transient desaturations, there are many other pathophysiologic contributions. Perez-Padilla *et al*<sup>[14]</sup>, did not observe OSA in any of their subjects, but transient desaturation was a frequent occurrence amounting to an average of nearly 50% of total sleep time with SpO<sub>2</sub> below 90%. Further studies found the degree of desaturation that subjects experienced during sleep was independent from oxygen desaturation during moderate and maximal exercise<sup>[2,11,16]</sup>.

There are a number of reasons why ILD patients might be more vulnerable to desaturation during sleep than normal subjects, and indeed than sufferers of OSA with normal lungs. Firstly, many patients will be on the steep portion of the oxygen-haemoglobin dissociation curve, whereby small changes in arterial oxygen tension lead to large decrements in saturation. In support of this is the observation of greater degrees of sleep desaturation in those with lower awake resting PaO<sub>2</sub> and

SaO<sub>2</sub><sup>[16,21,36,37]</sup>. Hypoxia may also occur due to worsening ventilation/perfusion inhomogeneity, and also alveolar hypoventilation, particularly during REM sleep<sup>[3]</sup>. Findley *et al*<sup>[38]</sup> studied the effect of lung volume on apnoea-related desaturation in normal subjects lying supine. Apnoeas were initiated at a range of lung volumes between total lung capacity and residual volume. The most severe desaturations occurred with apnoeas at the lower volumes, presumably because of the greater relative impact of dependent airway closure. This is a further mechanism of sleep-related hypoxia that may be extrapolated to individuals with lung restriction from ILD and concomitant sleep apnoea.

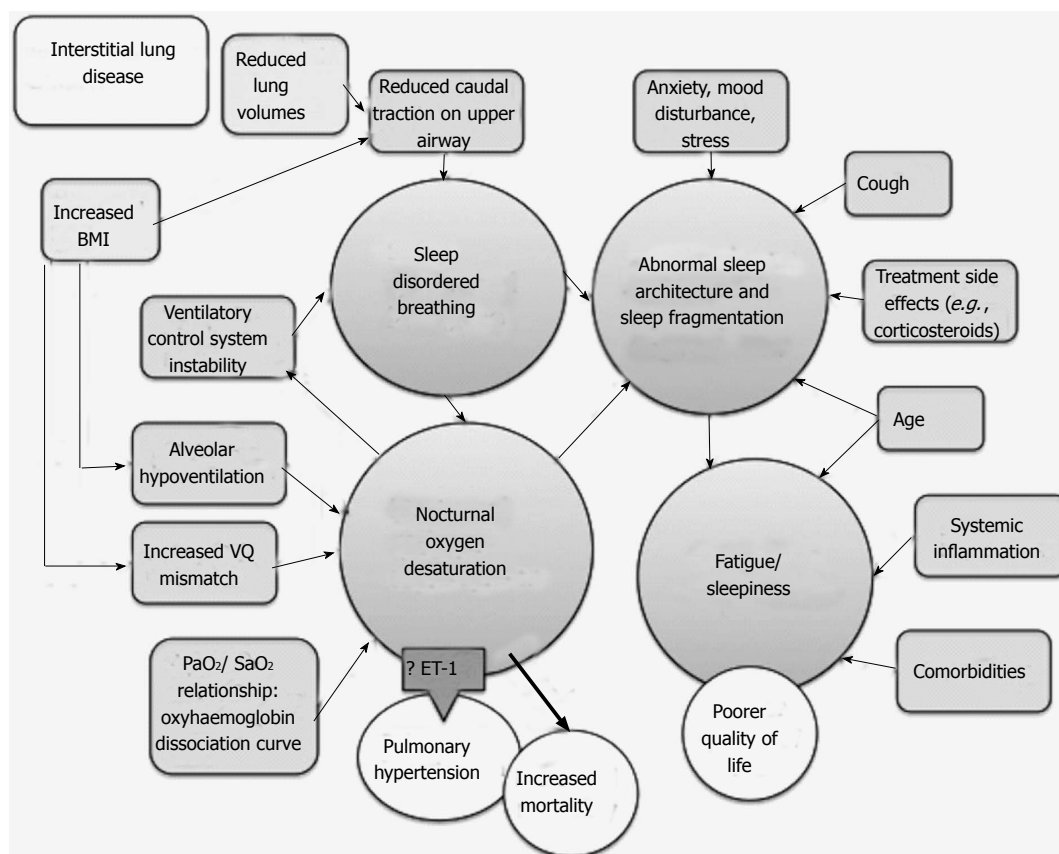
### Predicting nocturnal desaturation in ILD patients

As might be expected, daytime hypoxia has been identified as a predictor of night-time desaturation in a number of studies<sup>[16,21,36,37]</sup>. Severity of lung restriction and degree of desaturation with exercise, on the other hand, do not correlate well with nocturnal hypoxia<sup>[1,16,21,37,39]</sup>. Respiratory drive during wakefulness, (measured as the change in ventilation in response to changes in PaCO<sub>2</sub>), shows a tight negative correlation with the degree of desaturation in both REM and NREM sleep in ILD patients<sup>[37]</sup>, suggesting the innate chemo-responsiveness of the individual will also influence susceptibility to hypoxia. It is possible also that repeated severe episodes of nocturnal desaturation will eventually blunt this responsiveness, further perpetuating the problem as the disease advances.

### Oxygen supplementation during sleep

Although there is widespread practice to provide supplemental oxygen for chronic lung disease patients with significant sleep desaturation, there is very little supportive evidence. In the COPD literature, the survival benefit derived from continuous oxygen therapy has not been demonstrated with overnight supplementation in those with nocturnal hypoxia only<sup>[40-42]</sup>. There is some suggestion that pulmonary haemodynamics may be improved in COPD patients with long-term nocturnal oxygen<sup>[43]</sup>.

Only two studies have looked at the acute use of noc-



**Figure 2** Mechanisms of sleep-related pathology in interstitial lung disease. BMI: Body mass index; VQ: Ventilation-perfusion; ET-1: Endothelin-1.

turnal oxygen in ILD. By eliminating sleep-hypoxia with supplemental oxygen, Shea and co-workers were able to demonstrate a fall in both  $f$  and minute ventilation compared with awake values, approximating those of normal controls<sup>[44]</sup>. Vazquez studied ILD subjects at 2240 m above sea-level, breathing air or oxygen on two separate nights<sup>[45]</sup>. Not surprisingly, all were hypoxic at rest (mean  $\text{PaO}_2$  51 mmHg). With the addition of low-flow oxygen during sleep, heart rate and  $f$  were reduced and oxygenation improved. Sleep architecture, efficiency and arousal index were not significantly altered. To date, there have been no studies to address whether sleep quality or haemodynamics may improve with long-term use in ILD.

## NOCTURNAL DESATURATION AND PULMONARY HYPERTENSION

The link between intermittent desaturation and increased pulmonary arterial pressure was hypothesised nearly forty years ago<sup>[46,47]</sup>. Cross-sectional data in ILD subjects confirms the association between severity of nocturnal desaturation and the presence of pulmonary hypertension on echocardiography and right heart catheterisation<sup>[1,39,48]</sup>. Furthermore, prolonged exposure to transient, repetitive hypoxia in both animals and humans leads to measurable changes in pulmonary haemodynamics<sup>[49]</sup>. Tatsumi and colleagues studied subjects with both obstructive and restrictive lung diseases, comparing those with significant

nocturnal oxygen desaturation (NOD) to those without NOD, but matched for other disease variables<sup>[3]</sup>. Daytime, supine pulmonary arterial pressures (PAP) and pulmonary vascular resistances (PVR) were significantly higher in the NOD group. Under hypoxic conditions, these differences became more marked. Hyperoxia, on the other hand, improved PVR and PAP, but not to the normal range seen in the non-NOD patients. This experimental data suggests that the effects may last well beyond the acute period, due to permanent structural changes in the vasculature.

### Biomarkers in pulmonary hypertension

Serum Endothelin-1 (ET-1), a vasoactive peptide believed to be important in the pathogenesis of pulmonary hypertension, has been measured in ILD patients during sleep, in a novel study by Trakada and colleagues<sup>[50]</sup>. During wakefulness, ET-1 was significantly higher in those with elevated pulmonary pressures. During sleep, ET-1 rose acutely in all patients during episodes of desaturation below 90%, and correlated with simultaneously measured  $\text{PaO}_2$  concentrations and pulmonary arterial pressures. This very interesting research highlights a putative mechanistic pathway in the evolution of pulmonary vascular disease in ILD patients.

In summary, there is increasing evidence that nocturnal desaturation is not a benign phenomenon in ILD patients. In a large proportion, NOD occurs transiently and repeatedly throughout sleep, both with and without associated apnoeas. This may promote development of

pulmonary hypertension, and is independently associated with higher mortality. Mechanisms of SDB and NOD are illustrated in Figure 2.

## CONCLUSION

A small but growing body of literature suggests that SDB and NOD are common in patients with IPF and other ILD. There is still much to learn regarding the true impact that these have on the natural history of disease. A large area of uncertainty remains in whether targeted treatment (*e.g.*, positive pressure ventilation, oxygen or other novel therapies) will offer any quality of life or mortality benefits.

## REFERENCES

- 1 **Corte TJ**, Wort SJ, Talbot S, Macdonald PM, Hansel DM, Polkey M, Renzoni E, Maher TM, Nicholson AG, Wells AU. Elevated nocturnal desaturation index predicts mortality in interstitial lung disease. *Sarcoidosis Vasc Diffuse Lung Dis* 2012; **29**: 41-50 [PMID: 23311122]
- 2 **Kolilekas L**, Manali E, Vlami KA, Lyberopoulos P, Triantafyllidou C, Kagouridis K, Baou K, Gyftopoulos S, Vougas KN, Karakatsani A, Alchanatis M, Papiris S. Sleep oxygen desaturation predicts survival in idiopathic pulmonary fibrosis. *J Clin Sleep Med* 2013; **9**: 593-601 [PMID: 23772193 DOI: 10.5664/jcsm.2758]
- 3 **Fletcher EC**, Luckett RA, Miller T, Costarongos C, Kutka N, Fletcher JG. Pulmonary vascular hemodynamics in chronic lung disease patients with and without oxyhemoglobin desaturation during sleep. *Chest* 1989; **95**: 757-764 [PMID: 2924605]
- 4 **American Thoracic Society**, European Respiratory Society. American Thoracic Society/European Respiratory Society International Multidisciplinary Consensus Classification of the Idiopathic Interstitial Pneumonias. This joint statement of the American Thoracic Society (ATS), and the European Respiratory Society (ERS) was adopted by the ATS board of directors, June 2001 and by the ERS Executive Committee, June 2001. *Am J Respir Crit Care Med* 2002; **165**: 277-304 [PMID: 11790668 DOI: 10.1164/ajrccm.165.2.ats01]
- 5 **Travis WD**, Costabel U, Hansell DM, King TE, Lynch DA, Nicholson AG, Ryerson CJ, Ryu JH, Selman M, Wells AU, Behr J, Bouros D, Brown KK, Colby TV, Collard HR, Cordeiro CR, Cottin V, Crestani B, Drent M, Dudden RF, Egan J, Flaherty K, Hogaboam C, Inoue Y, Johkoh T, Kim DS, Kitaichi M, Loyd J, Martinez FJ, Myers J, Protzko S, Raghu G, Richeldi L, Sverzellati N, Swigris J, Valeyre D. An official American Thoracic Society/European Respiratory Society statement: Update of the international multidisciplinary classification of the idiopathic interstitial pneumonias. *Am J Respir Crit Care Med* 2013; **188**: 733-748 [PMID: 24032382 DOI: 10.1164/rccm.201308-1483ST]
- 6 **Shlobin OA**, Nathan SD. Pulmonary hypertension secondary to interstitial lung disease. *Expert Rev Respir Med* 2011; **5**: 179-189 [PMID: 21510729 DOI: 10.1586/ers.11.11]
- 7 **Nadrous HF**, Pellikka PA, Krowka MJ, Swanson KL, Chawwalit N, Decker PA, Ryu JH. Pulmonary hypertension in patients with idiopathic pulmonary fibrosis. *Chest* 2005; **128**: 2393-2399 [PMID: 16236900 DOI: 10.1378/chest.128.4.2393]
- 8 **Javaheri S**, Sicilian L. Lung function, breathing pattern, and gas exchange in interstitial lung disease. *Thorax* 1992; **47**: 93-97 [PMID: 1549829]
- 9 **O'Donnell DE**, Chau LK, Webb KA. Qualitative aspects of exertional dyspnea in patients with interstitial lung disease. *J Appl Physiol* (1985) 1998; **84**: 2000-2009 [PMID: 9609795]
- 10 **Kornbluth RS**, Turino GM. Respiratory control in diffuse interstitial lung disease and diseases of the pulmonary vasculature. *Clin Chest Med* 1980; **1**: 91-102 [PMID: 6793291]
- 11 **Bye PT**, Issa F, Berthon-Jones M, Sullivan CE. Studies of oxygenation during sleep in patients with interstitial lung disease. *Am Rev Respir Dis* 1984; **129**: 27-32 [PMID: 6703484]
- 12 **Hira HS**, Sharma RK. Study of oxygen saturation, breathing pattern and arrhythmias in patients of interstitial lung disease during sleep. *Indian J Chest Dis Allied Sci* 1997; **39**: 157-162 [PMID: 9357149]
- 13 **Mermigkis C**, Stagaki E, Amfilochiou A, Polychronopoulos V, Korkonikitas P, Mermigkis D, Bregou M, Kouris N, Bouros D. Sleep quality and associated daytime consequences in patients with idiopathic pulmonary fibrosis. *Med Princ Pract* 2009; **18**: 10-15 [PMID: 19060484 DOI: 10.1159/000163039]
- 14 **Perez-Padilla R**, West P, Lertzman M, Kryger MH. Breathing during sleep in patients with interstitial lung disease. *Am Rev Respir Dis* 1985; **132**: 224-229 [PMID: 2411177]
- 15 **McNicholas WT**, Coffey M, Fitzgerald MX. Ventilation and gas exchange during sleep in patients with interstitial lung disease. *Thorax* 1986; **41**: 777-782 [PMID: 3787507]
- 16 **Midgren B**, Hansson L, Eriksson L, Airikkala P, Elmqvist D. Oxygen desaturation during sleep and exercise in patients with interstitial lung disease. *Thorax* 1987; **42**: 353-356 [PMID: 3660289]
- 17 **Mermigkis C**, Chapman J, Golish J, Mermigkis D, Budur K, Kopanakis A, Polychronopoulos V, Burgess R, Foldvary-Schaefer N. Sleep-related breathing disorders in patients with idiopathic pulmonary fibrosis. *Lung* 2007; **185**: 173-178 [PMID: 17436039 DOI: 10.1007/s00408-007-9004-3]
- 18 **Aydoğdu M**, Ciftçi B, Firat Güven S, Ulukavak Ciftçi T, Erdoğan Y. [Assessment of sleep with polysomnography in patients with interstitial lung disease]. *Tuberk Toraks* 2006; **54**: 213-221 [PMID: 17001537]
- 19 **Lancaster LH**, Mason WR, Parnell JA, Rice TW, Loyd JE, Milstone AP, Collard HR, Malow BA. Obstructive sleep apnea is common in idiopathic pulmonary fibrosis. *Chest* 2009; **136**: 772-778 [PMID: 19567497 DOI: 10.1378/chest.08-2776]
- 20 **Mermigkis C**, Stagaki E, Tryfon S, Schiza S, Amfilochiou A, Polychronopoulos V, Panagou P, Galanis N, Kallianos A, Mermigkis D, Kopanakis A, Varouchakis G, Kapsimalis F, Bouros D. How common is sleep-disordered breathing in patients with idiopathic pulmonary fibrosis? *Sleep Breath* 2010; **14**: 387-390 [PMID: 20232261 DOI: 10.1007/s11325-010-0336-5]
- 21 **Clark M**, Cooper B, Singh S, Cooper M, Carr A, Hubbard R. A survey of nocturnal hypoxaemia and health related quality of life in patients with cryptogenic fibrosing alveolitis. *Thorax* 2001; **56**: 482-486 [PMID: 11359966]
- 22 **Krishnan V**, McCormack MC, Mathai SC, Agarwal S, Richardson B, Horton MR, Polito AJ, Collop NA, Danoff SK. Sleep quality and health-related quality of life in idiopathic pulmonary fibrosis. *Chest* 2008; **134**: 693-698 [PMID: 18625669 DOI: 10.1378/chest.08-0173]
- 23 **Johns MW**. A new method for measuring daytime sleepiness: the Epworth sleepiness scale. *Sleep* 1991; **14**: 540-545 [PMID: 1798888]
- 24 **Buysse DJ**, Reynolds CF, Monk TH, Berman SR, Kupfer DJ. The Pittsburgh Sleep Quality Index: a new instrument for psychiatric practice and research. *Psychiatry Res* 1989; **28**: 193-213 [PMID: 2748771]
- 25 **Pihtili A**, Bingol Z, Kiyan E, Cuhadaroglu C, Issever H, Gulbaran Z. Obstructive sleep apnea is common in patients with interstitial lung disease. *Sleep Breath* 2013; **17**: 1281-1288 [PMID: 23563999 DOI: 10.1007/s11325-013-0834-3]
- 26 **Prado GF**, Allen RP, Trevisani VM, Toscano VG, Earley CJ. Sleep disruption in systemic sclerosis (scleroderma) patients: clinical and polysomnographic findings. *Sleep Med* 2002; **3**: 341-345 [PMID: 14592197]
- 27 **Puthalapattu S**, Roman-Rodriguez J, Perez RL, Bhadriraju S, Ioachimescu OC. Sleep apnea and other sleep disorders: sur-



- vey in individuals with idiopathic pulmonary fibrosis (IPF). *J Sleep Disorders Ther* 2013; **2**: 1-4
- 28 **Turner GA**, Lower EE, Corser BC, Gunther KL, Baughman RP. Sleep apnea in sarcoidosis. *Sarcoidosis Vasc Diffuse Lung Dis* 1997; **14**: 61-64 [PMID: 9186990]
  - 29 **Patterson KC**, Huang F, Oldham JM, Bhardwaj N, Hogarth DK, Mokhlesi B. Excessive daytime sleepiness and obstructive sleep apnea in patients with sarcoidosis. *Chest* 2013; **143**: 1562-1568 [PMID: 23258454 DOI: 10.1378/chest.12-1524]
  - 30 **Dempsey JA**, Xie A, Patz DS, Wang D. Physiology in medicine: obstructive sleep apnea pathogenesis and treatment-considerations beyond airway anatomy. *J Appl Physiol* (1985) 2014; **116**: 3-12 [PMID: 24201709 DOI: 10.1152/jappphysiol.01054.2013]
  - 31 **Bradley TD**, Brown IG, Grossman RF, Zamel N, Martinez D, Phillipson EA, Hoffstein V. Pharyngeal size in snorers, nonsnorers, and patients with obstructive sleep apnea. *N Engl J Med* 1986; **315**: 1327-1331 [PMID: 3773955 DOI: 10.1056/NEJM198611203152105]
  - 32 **Kairaitis K**, Byth K, Parikh R, Stavrinou R, Wheatley JR, Amis TC. Tracheal traction effects on upper airway patency in rabbits: the role of tissue pressure. *Sleep* 2007; **30**: 179-186 [PMID: 17326543]
  - 33 **Nakayama H**, Smith CA, Rodman JR, Skatrud JB, Dempsey JA. Carotid body denervation eliminates apnea in response to transient hypocapnia. *J Appl Physiol* (1985) 2003; **94**: 155-164 [PMID: 12391082 DOI: 10.1152/jappphysiol.00722.2002]
  - 34 **Younes M**. Role of respiratory control mechanisms in the pathogenesis of obstructive sleep disorders. *J Appl Physiol* (1985) 2008; **105**: 1389-1405 [PMID: 18787092 DOI: 10.1152/jappphysiol.90408.2008]
  - 35 **Marcus NJ**, Li YL, Bird CE, Schultz HD, Morgan BJ. Chronic intermittent hypoxia augments chemoreflex control of sympathetic activity: role of the angiotensin II type 1 receptor. *Respir Physiol Neurobiol* 2010; **171**: 36-45 [PMID: 20153844 DOI: 10.1016/j.resp.2010.02.003]
  - 36 **Midgren B**. Oxygen desaturation during sleep as a function of the underlying respiratory disease. *Am Rev Respir Dis* 1990; **141**: 43-46 [PMID: 2297185 DOI: 10.1164/ajrcm/141.1.43]
  - 37 **Tatsumi K**, Kimura H, Kunitomo F, Kuriyama T, Honda Y. Arterial oxygen desaturation during sleep in interstitial pulmonary disease. Correlation with chemical control of breathing during wakefulness. *Chest* 1989; **95**: 962-967 [PMID: 2707087]
  - 38 **Findley LJ**, Ries AL, Tisi GM, Wagner PD. Hypoxemia during apnea in normal subjects: mechanisms and impact of lung volume. *J Appl Physiol Respir Environ Exerc Physiol* 1983; **55**: 1777-1783 [PMID: 6662768]
  - 39 **Miyahara Y**, Miyahara Y, Naito T, Ikeda S. Monitoring of nocturnal oxygen desaturation using pulse oximeter and apnomonitor in patients with chronic pulmonary disease. *Respiration* 1995; **62**: 348-352 [PMID: 8552867]
  - 40 Long term domiciliary oxygen therapy in chronic hypoxic cor pulmonale complicating chronic bronchitis and emphysema. Report of the Medical Research Council Working Party. *Lancet* 1981; **1**: 681-686 [PMID: 6110912]
  - 41 Continuous or nocturnal oxygen therapy in hypoxemic chronic obstructive lung disease: a clinical trial. Nocturnal Oxygen Therapy Trial Group. *Ann Intern Med* 1980; **93**: 391-398 [PMID: 6776858]
  - 42 **Chaouat A**, Weitzenblum E, Kessler R, Charpentier C, Enrhart M, Schott R, Levi-Valensi P, Zielinski J, Delaunoy L, Cornudella R, Moutinho dos Santos J. A randomized trial of nocturnal oxygen therapy in chronic obstructive pulmonary disease patients. *Eur Respir J* 1999; **14**: 1002-1008 [PMID: 10596681]
  - 43 **Fletcher EC**, Luckett RA, Goodnight-White S, Miller CC, Qian W, Costaragos-Galarza C. A double-blind trial of nocturnal supplemental oxygen for sleep desaturation in patients with chronic obstructive pulmonary disease and a daytime PaO<sub>2</sub> above 60 mm Hg. *Am Rev Respir Dis* 1992; **145**: 1070-1076 [PMID: 1586049]
  - 44 **Shea SA**, Winning AJ, McKenzie E, Guz A. Does the abnormal pattern of breathing in patients with interstitial lung disease persist in deep, non-rapid eye movement sleep? *Am Rev Respir Dis* 1989; **139**: 653-658 [PMID: 2923365]
  - 45 **Vázquez JC**, Pérez-Padilla R. Effect of oxygen on sleep and breathing in patients with interstitial lung disease at moderate altitude. *Respiration* 2001; **68**: 584-589 [PMID: 11786712]
  - 46 **Unger M**, Atkins M, Briscoe WA, King TK. Potentiation of pulmonary vasoconstrictor response with repeated intermittent hypoxia. *J Appl Physiol Respir Environ Exerc Physiol* 1977; **43**: 662-667 [PMID: 908680]
  - 47 **Tilkian AG**, Guilleminault C, Schroeder JS, Lehrman KL, Simmons FB, Dement WC. Hemodynamics in sleep-induced apnea. Studies during wakefulness and sleep. *Ann Intern Med* 1976; **85**: 714-719 [PMID: 999107]
  - 48 **Pitsiou G**, Bagalas V, Boutou A, Stanopoulos I, Argyropoulou-Pataka P. Should we routinely screen patients with idiopathic pulmonary fibrosis for nocturnal hypoxemia? *Sleep Breath* 2013; **17**: 447-448 [PMID: 22562264 DOI: 10.1007/s11325-012-0716-0]
  - 49 **Nattie EE**, Bartlett D, Johnson K. Pulmonary hypertension and right ventricular hypertrophy caused by intermittent hypoxia and hypercapnia in the rat. *Am Rev Respir Dis* 1978; **118**: 653-658 [PMID: 152077]
  - 50 **Trakada G**, Nikolaou E, Pouli A, Tsiamita M, Spiropoulos K. Endothelin-1 levels in interstitial lung disease patients during sleep. *Sleep Breath* 2003; **7**: 111-118 [PMID: 14569522 DOI: 10.1007/s11325-003-0111-y]

**P- Reviewer:** Resch B, Turner AM **S- Editor:** Ji FF  
**L- Editor:** A **E- Editor:** Wu HL





## Role of MGMT as biomarker in colorectal cancer

Alessandro Inno, Giuseppe Fanetti, Maria Di Bartolomeo, Stefania Gori, Claudia Maggi, Massimo Cirillo, Roberto Iacovelli, Federico Nichetti, Antonia Martinetti, Filippo de Braud, Ilaria Bossi, Filippo Pietrantonio

Alessandro Inno, Stefania Gori, Massimo Cirillo, Medical Oncology Department, Ospedale Sacro Cuore Don Calabria, Negrar, 37100 Verona, Italy

Giuseppe Fanetti, Radiotherapy Unit, European Institute of Oncology, 20100 Milan, Italy

Maria Di Bartolomeo, Claudia Maggi, Roberto Iacovelli, Federico Nichetti, Antonia Martinetti, Filippo de Braud, Ilaria Bossi, Filippo Pietrantonio, Medical Oncology Department, Fondazione IRCCS Istituto Nazionale dei Tumori, 20100 Milan, Italy

**Author contributions:** All authors gave substantial contributions to conception and design, acquisition of data, analysis and interpretation of data; drafting the article or revising it critically for important intellectual content; final approval of the version to be published.

**Correspondence to:** Filippo Pietrantonio, MD, Medical Oncology Department, Fondazione IRCCS Istituto Nazionale dei Tumori, Via Venezian, 20100 Milan, Italy. [filippo.pietrantonio@istitutotumori.mi.it](mailto:filippo.pietrantonio@istitutotumori.mi.it)

Telephone: +39-2-23903807 Fax: +39-2-23902149

Received: July 23, 2014 Revised: September 1, 2014

Accepted: October 14, 2014

Published online: December 16, 2014

includes investigation of synergic combinations with other agents such as fluoropyrimidines and research for additional biomarkers, in order to better define the role of temozolomide in the treatment of individual patients.

© 2014 Baishideng Publishing Group Inc. All rights reserved.

**Key words:** Colorectal cancer; O<sup>6</sup>-methylguanine DNA methyltransferase; Temozolomide; Dacarbazine; Biomarker

**Core tip:** O<sup>6</sup>-methylguanine DNA methyltransferase (MGMT) methylation is involved in colorectal carcinogenesis and represents a predictive biomarker for alkylating agents in metastatic colorectal cancer. In fact, patients with chemorefractory metastatic colorectal cancer with *MGMT* methylation derived promising response from treatment with dacarbazine or temozolomide, and ongoing research is investigating the efficacy of temozolomide in combination with other chemotherapy drugs for *MGMT*-methylated colorectal cancer. Future challenges include the combination with biologic drugs and the research for additional biomarkers.

### Abstract

O<sup>6</sup>-methylguanine DNA methyltransferase (MGMT) gene promoter methylation plays an important role in colorectal carcinogenesis, occurring in about 30%-40% of metastatic colorectal cancer. Its prognostic role has not been defined yet, but loss of expression of *MGMT*, which is secondary to gene promoter methylation, results in an interesting high response to alkylating agents such as dacarbazine and temozolomide. In a phase 2 study on heavily pre-treated patients with *MGMT* methylated metastatic colorectal cancer, temozolomide achieved about 30% of disease control rate. Activating mutations of *RAS* or *BRAF* genes as well as mismatch repair deficiency may represent mechanisms of resistance to alkylating agents, but a dose-dense schedule of temozolomide may potentially restore sensitivity in *RAS*-mutant patients. Further development of temozolomide in *MGMT* methylated colorectal cancer

Inno A, Fanetti G, Di Bartolomeo M, Gori S, Maggi C, Cirillo M, Iacovelli R, Nichetti F, Martinetti A, de Braud F, Bossi I, Pietrantonio F. Role of MGMT as biomarker in colorectal cancer. *World J Clin Cases* 2014; 2(12): 835-839 Available from: URL: <http://www.wjgnet.com/2307-8960/full/v2/i12/835.htm> DOI: <http://dx.doi.org/10.12998/wjcc.v2.i12.835>

### ROLE OF MGMT IN THE DEVELOPMENT OF COLORECTAL CANCER

Colorectal carcinogenesis is a complex, multistep and still not completely understood process including both genetic and epigenetic alterations. DNA damage certainly plays a central role in cancer development and progression, especially when the DNA repair machinery is not

efficient.

O<sup>6</sup>-methylguanine DNA methyltransferase (MGMT) is a DNA repair enzyme codified by the *MGMT* gene at locus 10q26<sup>[1]</sup>. MGMT removes alkyl groups from the O<sup>6</sup>-position of the guanine acting itself as an acceptor, and such reaction leads to an irreversible inactivation of the enzyme<sup>[2]</sup>. *MGMT* transcription is regulated by epigenetic mechanisms. Methylation of the CpG dinucleotides in the promoter region of *MGMT* results in gene silencing, MGMT loss of expression and inability to remove alkyl groups from methylated guanine, with a consequent alteration of the normal DNA structure<sup>[3]</sup>.

While protecting normal cell from carcinogens, MGMT activity also protects tumor cells from lethal effects of chemotherapy with alkylating agents such as dacarbazine (DTIC) or temozolomide (TMZ), widely used for the treatment of melanoma and glioblastoma. In glioblastoma, in fact, *MGMT* methylation has been identified as a relevant prognostic factor and as an independent predictive factor of benefit from TMZ<sup>[4,5]</sup>. For melanoma, the predictive and prognostic role of *MGMT* methylation status is controversial, but patients with MGMT-methylated melanoma treated with DTIC seem to be at higher risk of treatment-related adverse events<sup>[6]</sup>.

*MGMT* promoter methylation is a frequent and relevant event in colorectal cancerogenesis, with a low expression of MGMT secondary to gene silencing observed in 27 to 40% of metastatic chemorefractory colorectal cancer (mCRC)<sup>[7]</sup>. However, MGMT loss has been also demonstrated in normal colorectal tissue, suggesting that *MGMT* silencing is only one of several steps needed for the accumulation of DNA damage and cell transformation. MGMT loss has been defined as a “field defect”, since it is neither necessary nor sufficient to cancer progression - *i.e.*, in a multistep process, it represents only one of the earlier passages leading to carcinogenesis. In fact, a second level of defense against DNA damage is represented by the mismatch repair (MMR) system which leads cell to apoptosis in presence of serious genomic alterations<sup>[8]</sup>. Loss of MGMT expression is more frequent in CRC with microsatellite instability, suggesting that methylated *MGMT* select cellular clones with MMR deficient status<sup>[9]</sup>.

However, MGMT loss also plays a role in microsatellite-stable CRC through a mechanism of chromosomal instability<sup>[10]</sup>. During DNA transcription, methylated guanine is wrongly recognized as adenine causing C:G to A:T transition mutations. MGMT may prevent guanine to adenine transition in *ras*-family genes, while the loss of MGMT activity may increase the likelihood of *RAS* and *TP53* mutations. In fact, *MGMT* methylation was found in 71% of mCRC with *KRAS* G>A mutations, whereas it was present only in 32% of tumors with non-G>A *KRAS* mutations and in 35% of tumors with wild-type *KRAS*<sup>[11,12]</sup>. In *KRAS*-mutant tumors, *MGMT* promoter methylation occurs before *KRAS* mutations and it represents an early event in the adenoma-carcinoma sequence. Therefore, there should be a high concordance of *MGMT* methylation status between primary tumor and

distant metastases.

Despite its defined position in the pathogenesis of CRC, the prognostic role of *MGMT* is still controversial. Few studies directed to investigate the prognostic role of *MGMT* methylation have been published with different results. In a series of 116 patients, a reduction of recurrence rate after adjuvant therapy has been reported in *MGMT* methylated patients<sup>[13]</sup>. Shima *et al*<sup>[14]</sup> analyzed a group of 855 patients with CRC showing no prognostic value of MGMT loss or gene promoter hypermethylation. No benefit from 5-fluorouracil (5-FU)- or oxaliplatin-based regimens was reported in presence of *MGMT* promoter methylation or *MGMT* loss<sup>[15]</sup>.

## ACTIVITY OF ALKYLATING AGENTS IN MGMT-METHYLATED COLORECTAL CANCER

DTIC and its oral derivative TMZ exert their cytotoxic effects through methylation of DNA at the N3 position of adenine and at the N7 and O6 positions of guanine. Although N7-methyl-guanine and N3-methyl-adenine represent the majority of adducts, cytotoxicity of DTIC and TMZ seems to be mainly due to DNA methylation at the O6-position of guanine, which leads to DNA double strand breaks and subsequent inhibition of DNA replication and apoptosis. As the cytotoxic effect of TMZ is mediated primarily through methylation of O6-guanine, the predominant mechanism of tumor resistance to DTIC and TMZ is *MGMT* expression.

TMZ showed *in vitro* activity against several human malignancies, including colorectal cancer<sup>[16]</sup>. In a phase 1 study on solid tumors comparing a novel schedule for TMZ given twice a day for more than 5 consecutive days with the standard schedule of a daily administration for 5 consecutive days, the drug activity was quite disappointing with only 1 out of 12 mCRC patients responding to treatment<sup>[17]</sup>. However, patients enrolled in the trial were not molecularly selected according to the *MGMT* methylation status.

In a pilot study, 66 patients with refractory metastatic cancer were treated according to the molecular tumor profiling, and TMZ was effective in 2 cases of advanced CRC exhibiting loss of *MGMT* expression<sup>[18]</sup>. Consistently with these data, Schacham-Schmueli and colleagues described 2 patients with mCRC and a low expression of MGMT who were treated with TMZ achieving an impressive clinical response<sup>[19]</sup>. To explore the hypothesis that in mCRC the activity of TMZ is confined to tumors with low levels of *MGMT*, a phase II trial combined the alkylating drug with lomeguatrib, a nontoxic low-molecular weight pseudosubstrate which inactivates MGMT<sup>[20]</sup>. Unfortunately, the study was terminated early for futility, after 19 instead of the 30 patient initially planned had been recruited. The main reason why no objective response was observed, as the same authors stated, may be related to the low doses of TMZ and lomeguatrib used in the trial.

**Table 1 Phase 2 clinical trials with alkylating agents in metastatic chemorefractory colorectal cancer**

Ref.	Schedule	<i>n</i> ( <i>MGMT</i> -m)	RR ( <i>MGMT</i> -m)	DCR ( <i>MGMT</i> -m)	PFS mo ( <i>MGMT</i> -m)	OS mo ( <i>MGMT</i> -m)
Amatu <i>et al</i> <sup>[21]</sup>	DTIC 250 mg/m <sup>2</sup> per day, d 1-4 q21d	68 (26)	3% (8%)	12% (44%)	1.7 (NR) <sup>1</sup>	NR
Hochhauser <i>et al</i> <sup>[22]</sup>	TMZ 150 mg/m <sup>2</sup> per day 7 d on/7 d off	37 <sup>2</sup> (37)	3% (3%)	44% (445)	NR	NR
Pietrantonio <i>et al</i> <sup>[23]</sup>	TMZ 150 mg/m <sup>2</sup> per day d 1-5, q28d	32 <sup>3</sup> (32)	12% (12%)	31% (31%)	1.8 (1.8)	8.4 (8.4)
Pietrantonio <i>et al</i> <sup>[26]</sup>	TMZ 75 mg/m <sup>2</sup> per day, d 1-21 q28d	21 <sup>4</sup> (21)	24% (24%)	30% (30%)	2.2 (2.2)	NR

<sup>1</sup>Median PFS for *MGMT*-m patients was not reported, but hazard ratio for progression between methylated and non-methylated patients was 0.66 (95%CI: 0.40-1.10), *P* = 0.0982; <sup>2</sup>The study enrolled 86 patients with *MGMT*-m metastatic CRC (MCrc), esophageal, head and neck and non small cell lung cancer; this table reports data of patients with mCRC only; <sup>3</sup>Only *MGMT*-m patients were enrolled in the study; <sup>4</sup>Preliminary results. DTIC: Dacarbazine; TMZ: Temozolomide; RR: Response rate; DCR: Disease control rate; PFS: Progression-free survival; OS: Overall survival; *MGMT*-m: *MGMT*-methylated; NR: Not reported.

Amatu *et al*<sup>[21]</sup> evaluated the activity of dacarbazine in 68 heavily pretreated mCRC patients. The response rate was only 3% with 2 partial responses, but a preplanned analysis based on *MGMT* methylation status in the individual tumors showed that objective responses only occurred in patients with *MGMT* methylated cancer. In the *MGMT*-methylated group, a significantly higher disease control rate (44% *vs* 6%, *P* = 0.012) and a trend toward longer progression-free survival (PFS) were also observed (Table 1). These results provided the proof-of-concept that dacarbazine, and consequently its derivative TMZ, are effective only in patients with mCRC harboring methylation in the *MGMT* gene promoter.

Patients with advanced aerodigestive tract and colorectal cancers and methylation of *MGMT* gene promoter were treated by Hochhauser *et al*<sup>[22]</sup> with TMZ given at 150 mg/m<sup>2</sup> per day on a 7-day-on/7-day-off schedule. A low response rate (3%) was reported in patients with mCRC (Table 1), suggesting that *MGMT* methylation may be not the only factor determining response to TMZ. Particularly, cell death induced by TMZ also depends on the integrity of MMR pathways. In this study, all the patients with objective response were MMR-proficient, and most MMR-deficient patients experienced a disease progression, but data were limited to drive definitive conclusions about the correlation between MMR status and response to TMZ.

A phase 2 study run by our research group at the National Cancer Institute of Milan enrolled 32 patients with *MGMT*-methylated mCRC who progressed after all the approved standard therapies including fluoropyrimidines, oxaliplatin, irinotecan and, if *KRAS* wild-type, also cetuximab or panitumumab<sup>[23]</sup>. All the patients received TMZ at the standard dose of 150 mg/m<sup>2</sup> per day for 5 consecutive days every 28 d until disease progression or unacceptable toxicity. This was the first trial of TMZ given to mCRC patients selected for *MGMT* methylation status. The study met its primary end-point of promising activity, with 4 (12%) partial responses and 6 (19%) disease stabilizations; median PFS and overall survival (OS) were 1.8 and 8.4 mo, respectively (Table 1). TMZ was well tolerated, with severe thromocytopenia occur-

ring in only 1 patient and no other grade 3-4 toxicities observed. Dose reduction was necessary in 3 patients, and no patients underwent early discontinuation due to adverse events. The study also explored potential predictive biomarkers, showing that none of the patients with mCRC harboring a mutation in the mitogen-activated protein kinases (MAPK), either *RAS* or *BRAF*, achieved a response. Conversely, four of nine patients with *RAS* and *BRAF* wild-type tumors had an objective response (0% *vs* 44%, *P* = 0.004). These results confirmed what was already shown for glioblastoma, namely that MAPK signaling may enhance *MGMT* activity and drive cellular resistance to TMZ<sup>[24]</sup>. Interestingly, none of the patients included in this trial were MMR-deficient, and this might explain the clinically meaningful response rate observed in this study.

Other trials are currently ongoing, with the aim to shed more light on the role of TMZ as single agent and investigate predictive biomarkers in patients with *MGMT* methylated CRC (Eudract n. 2012-003338-17; 2012-002766-13).

## FUTURE CHALLENGES

It was previously shown that a dose-dense TMZ regimen results in prolonged depletion of *MGMT* in blood mononuclear cells and possibly in the tumor<sup>[25]</sup>. This schedule of administration may have enhanced activity due to higher cumulative dose and might be able to restore treatment sensitivity in *RAS* mutant tumors. Preliminary results from a mono-institutional, phase II, open label, single arm study with dose-dense TMZ were recently presented by our group<sup>[26]</sup>. Patients with chemorefractory disease were treated with TMZ at a dose of 75 mg/m<sup>2</sup> given daily for 21 consecutive days of a 4-week cycle, up to 6 cycles or until disease progression or unacceptable toxicity. Seventeen out of 21 patients were evaluable for RECIST response. Tumor response, which was the primary endpoint of the study, was 24%. Interestingly, all patients with tumor response had a mutation of either *KRAS* (3 patients) or *BRAF* (1 patient). These preliminary data confirmed the encouraging activity of



TMZ in molecularly selected patients with *MGMT* methylation-positive, chemorefractory mCRC (Table 1). The good safety profile of dose-dense TMZ, as well as the response rate obtained in the *RAS* mutant population, are promising and warrant further prospective randomized confirmation.

There is a strong rationale for combining TMZ with fluoropyrimidines, based on preclinical data in slow-growing carcinoid cell line. It was found that TMZ and 5-FU have synergistic activity in a schedule-dependent manner in which 5-FU exposure preceded TMZ by 5–7 d with maximal synergism at 9 d. When the two agents were delivered concomitantly or if TMZ preceded 5-FU, *in vitro* cytotoxicity was additive but not synergistic. From these translational studies, researchers from the Columbia university formulated the CAPTEM regimen using TMZ for 5 d at 150–200 mg/m<sup>2</sup> per day refracted in a BID dosing on days 10–14 and capecitabine 750 mg/m<sup>2</sup> BID on days 1–14 of a 28-d-cycle<sup>[27]</sup>. The TMZ was given twice-a-day instead of the standard daily dosing because the first dose binds *MGMT*, thus allowing the second dose to methylate guanines in presence of a decreased repair activity of *MGMT*<sup>[17,28]</sup>. Given the potential synergy of CAPTEM combination in mCRC, we planned a randomized phase II study of second-line CAPTEM *vs* FOLFIRI after failure of prior first-line oxaliplatin-based treatment in patients with advanced, *MGMT* methylated, *RAS* mutated CRC (Eudract n 2014-002417-36). The primary objective of the study is to demonstrate the superiority of CAPTEM over standard FOLFIRI in terms of PFS; secondary endpoints are response rate, safety, quality of life, OS, with an exploratory biomarkers sub-study.

In conclusion, there is growing evidence that *MGMT* methylation status may serve as a predictive biomarker of response to TMZ in mCRC. TMZ is a promising agent for the treatment of *MGMT*-methylated mCRC, and the future research should establish the best schedule of TMZ and should also investigate how to integrate TMZ with the current available therapeutic options for mCRC, whether as single agent in chemorefractory patients or in combination with other active drugs in first or second line. The combination of TMZ with fluoropyrimidines is based on a strong rationale and is currently being investigated, but also the combination of TMZ with irinotecan<sup>[29]</sup> has been proven to be feasible and it may deserve evaluation in mCRC. TMZ-containing chemotherapy may also provide an interesting backbone for the addition of biologic agents. However, the identification of additional biomarkers is a priority for future research, in order to select individual patients who may benefit the most from alkylating agents.

## REFERENCES

- 1 Natarajan AT, Vermeulen S, Darroudi F, Valentine MB, Brent TP, Mitra S, Tano K. Chromosomal localization of human O6-methylguanine-DNA methyltransferase (*MGMT*) gene by in situ hybridization. *Mutagenesis* 1992; **7**: 83-85 [PMID: 1635460 DOI: 10.1093/mutage/7.1.83]
- 2 Pegg AE. Mammalian O6-alkylguanine-DNA alkyltransferase: regulation and importance in response to alkylating carcinogenic and therapeutic agents. *Cancer Res* 1990; **50**: 6119-6129 [PMID: 2205376]
- 3 Gerson SL. *MGMT*: its role in cancer aetiology and cancer therapeutics. *Nat Rev Cancer* 2004; **4**: 296-307 [PMID: 15057289 DOI: 10.1038/nrc1319]
- 4 Hegi ME, Diserens AC, Gorlia T, Hamou MF, de Tribolet N, Weller M, Kros JM, Hainfellner JA, Mason W, Mariani L, Bromberg JE, Hau P, Mirimanoff RO, Cairncross JG, Janzer RC, Stupp R. *MGMT* gene silencing and benefit from temozolomide in glioblastoma. *N Engl J Med* 2005; **352**: 997-1003 [PMID: 15758010 DOI: 10.1056/NEJMoa043331]
- 5 Reifenberger G, Hentschel B, Felsberg J, Schackert G, Simon M, Schnell O, Westphal M, Wick W, Pietsch T, Loeffler M, Weller M. Predictive impact of *MGMT* promoter methylation in glioblastoma of the elderly. *Int J Cancer* 2012; **131**: 1342-1350 [PMID: 22139906 DOI: 10.1002/ijc.27385]
- 6 Hassel JC, Sucker A, Edler L, Kurzen H, Moll I, Stresemann C, Spieth K, Mauch C, Rass K, Dummer R, Schadendorf D. *MGMT* gene promoter methylation correlates with tolerance of temozolomide treatment in melanoma but not with clinical outcome. *Br J Cancer* 2010; **103**: 820-826 [PMID: 20736948 DOI: 10.1038/sj.bjc.6605796]
- 7 Esteller M, Herman JG. Generating mutations but providing chemosensitivity: the role of O6-methylguanine DNA methyltransferase in human cancer. *Oncogene* 2004; **23**: 1-8 [PMID: 14712205 DOI: 10.1038/sj.onc.1207316]
- 8 Allan JM, Travis LB. Mechanisms of therapy-related carcinogenesis. *Nat Rev Cancer* 2005; **5**: 943-955 [PMID: 16294218 DOI: 10.1038/nrc1749]
- 9 Svrcek M, Buhard O, Colas C, Coulet F, Dumont S, Massaadoudi I, Lamri A, Hamelin R, Cosnes J, Oliveira C, Seruca R, Gaub MP, Legrain M, Collura A, Lascols O, Tired E, Fléjou JF, Duval A. Methylation tolerance due to an O6-methylguanine DNA methyltransferase (*MGMT*) field defect in the colonic mucosa: an initiating step in the development of mismatch repair-deficient colorectal cancers. *Gut* 2010; **59**: 1516-1526 [PMID: 20947886 DOI: 10.1136/gut.2009.194787]
- 10 Shen L, Kondo Y, Rosner GL, Xiao L, Hernandez NS, Vilaythong J, Houlihan PS, Krouse RS, Prasad AR, Einspahr JG, Buckmeier J, Alberts DS, Hamilton SR, Issa JP. *MGMT* promoter methylation and field defect in sporadic colorectal cancer. *J Natl Cancer Inst* 2005; **97**: 1330-1338 [PMID: 16174854 DOI: 10.1093/jnci/dji275]
- 11 Esteller M, Risques RA, Toyota M, Capella G, Moreno V, Peinado MA, Baylin SB, Herman JG. Promoter hypermethylation of the DNA repair gene O(6)-methylguanine-DNA methyltransferase is associated with the presence of G: C to A: T transition mutations in p53 in human colorectal tumorigenesis. *Cancer Res* 2001; **61**: 4689-4692 [PMID: 11406538]
- 12 Esteller M, Toyota M, Sanchez-Cespedes M, Capella G, Peinado MA, Watkins DN, Issa JP, Sidransky D, Baylin SB, Herman JG. Inactivation of the DNA repair gene O6-methylguanine-DNA methyltransferase by promoter hypermethylation is associated with G to A mutations in K-ras in colorectal tumorigenesis. *Cancer Res* 2000; **60**: 2368-2371 [PMID: 10811111]
- 13 Nagasaka T, Sharp GB, Notohara K, Kambara T, Sasamoto H, Isozaki H, MacPhee DG, Jass JR, Tanaka N, Matsubara N. Hypermethylation of O6-methylguanine-DNA methyltransferase promoter may predict nonrecurrence after chemotherapy in colorectal cancer cases. *Clin Cancer Res* 2003; **9**: 5306-5312 [PMID: 14614014]
- 14 Shima K, Morikawa T, Baba Y, Noshio K, Suzuki M, Yamachi M, Hayashi M, Giovannucci E, Fuchs CS, Ogino S. *MGMT* promoter methylation, loss of expression and prognosis in 855 colorectal cancers. *Cancer Causes Control* 2011; **22**: 301-309 [PMID: 21140203 DOI: 10.1007/s10552-010-9698-z]
- 15 Kim JC, Choi JS, Roh SA, Cho DH, Kim TW, Kim YS. Promoter methylation of specific genes is associated with the phenotype and progression of colorectal adenocarcinomas. *Ann Surg Oncol* 2010; **17**: 1767-1776 [PMID: 20077021 DOI: 10.1245/s10434-010-1767-7]



- 10.1245/s10434-009-0901-y]
- 16 **Raymond E**, Izbicka E, Soda H, Gerson SL, Dugan M, Von Hoff DD. Activity of temozolomide against human tumor colony-forming units. *Clin Cancer Res* 1997; **3**: 1769-1774 [PMID: 9815562]
  - 17 **Spiro TP**, Liu L, Majka S, Haaga J, Willson JK, Gerson SL. Temozolomide: the effect of once- and twice-a-day dosing on tumor tissue levels of the DNA repair protein O(6)-alkylguanine-DNA-alkyltransferase. *Clin Cancer Res* 2001; **7**: 2309-2317 [PMID: 11489806]
  - 18 **Von Hoff DD**, Stephenson JJ, Rosen P, Loesch DM, Borad MJ, Anthony S, Jameson G, Brown S, Cantafio N, Richards DA, Fitch TR, Wasserman E, Fernandez C, Green S, Sutherland W, Bittner M, Alarcon A, Mallery D, Penny R. Pilot study using molecular profiling of patients' tumors to find potential targets and select treatments for their refractory cancers. *J Clin Oncol* 2010; **28**: 4877-4883 [PMID: 20921468 DOI: 10.1200/JCO.2009.26.5983]
  - 19 **Shacham-Shmueli E**, Beny A, Geva R, Blachar A, Figer A, Aderka D. Response to temozolomide in patients with metastatic colorectal cancer with loss of MGMT expression: a new approach in the era of personalized medicine? *J Clin Oncol* 2011; **29**: e262-e265 [PMID: 21220612 DOI: 10.1200/JCO.2010.32.0242]
  - 20 **Khan OA**, Ranson M, Michael M, Olver I, Levitt NC, Mortimer P, Watson AJ, Margison GP, Midgley R, Middleton MR. A phase II trial of lomeguatrib and temozolomide in metastatic colorectal cancer. *Br J Cancer* 2008; **98**: 1614-1618 [PMID: 18475294 DOI: 10.1038/sj.bjc.6604366]
  - 21 **Amatu A**, Sartore-Bianchi A, Moutinho C, Belotti A, Ben-cardino K, Chirico G, Cassingena A, Rusconi F, Esposito A, Nichelatti M, Esteller M, Siena S. Promoter CpG island hypermethylation of the DNA repair enzyme MGMT predicts clinical response to dacarbazine in a phase II study for metastatic colorectal cancer. *Clin Cancer Res* 2013; **19**: 2265-2272 [PMID: 23422094 DOI: 10.1158/1078-0432.CCR-12-3518]
  - 22 **Hochhauser D**, Glynne-Jones R, Potter V, Grávalos C, Doyle TJ, Pathiraja K, Zhang Q, Zhang L, Sausville EA. A phase II study of temozolomide in patients with advanced aerodigestive tract and colorectal cancers and methylation of the O6-methylguanine-DNA methyltransferase promoter. *Mol Cancer Ther* 2013; **12**: 809-818 [PMID: 23443801 DOI: 10.1158/1535-7163.MCT-12-0710]
  - 23 **Pietrantonio F**, Perrone F, de Braud F, Castano A, Maggi C, Bossi I, Gevorgyan A, Biondani P, Pacifici M, Busico A, Gariboldi M, Festinese F, Tamborini E, Di Bartolomeo M. Activity of temozolomide in patients with advanced chemorefractory colorectal cancer and MGMT promoter methylation. *Ann Oncol* 2014; **25**: 404-408 [PMID: 24379162 DOI: 10.1093/annonc/mdt547]
  - 24 **Sato A**, Sunayama J, Matsuda K, Seino S, Suzuki K, Watanabe E, Tachibana K, Tomiyama A, Kayama T, Kitanaka C. MEK-ERK signaling dictates DNA-repair gene MGMT expression and temozolomide resistance of stem-like glioblastoma cells via the MDM2-p53 axis. *Stem Cells* 2011; **29**: 1942-1951 [PMID: 21957016 DOI: 10.1002/stem.753]
  - 25 **Tolcher AW**, Gerson SL, Denis L, Geyer C, Hammond LA, Patnaik A, Goetz AD, Schwartz G, Edwards T, Reyderman L, Statkevich P, Cutler DL, Rowinsky EK. Marked inactivation of O6-alkylguanine-DNA alkyltransferase activity with protracted temozolomide schedules. *Br J Cancer* 2003; **88**: 1004-1011 [PMID: 12671695]
  - 26 **Pietrantonio F**, de Braud F, Maggi C, Milione M, Iacovelli R, Castano A, Perrone F, Bossi I, Ricchini F, Pusceddu S, Leone G, Dominoni F, Saibene G, Di Bartolomeo M. Dose-dense temozolomide (TMZ) in patients with advanced chemorefractory colorectal cancer (CRC) and MGMT promoter methylation. *Ann Oncol* 2014; **25**: 14-104 [DOI: 10.1093/annonc/mdl165]
  - 27 **Fine RL**, Gulati AP, Krantz BA, Moss RA, Schreibman S, Tsushima DA, Mowatt KB, Dinnen RD, Mao Y, Stevens PD, Schroppe B, Allendorf J, Lee JA, Sherman WH, Chabot JA. Capecitabine and temozolomide (CAPTEM) for metastatic, well-differentiated neuroendocrine cancers: The Pancreas Center at Columbia University experience. *Cancer Chemother Pharmacol* 2013; **71**: 663-670 [PMID: 23370660 DOI: 10.1007/s00280-012-2055-z]
  - 28 **Balmaceda C**, Peereboom D, Pannullo S, Cheung YK, Fisher PG, Alavi J, Sisti M, Chen J, Fine RL. Multi-institutional phase II study of temozolomide administered twice daily in the treatment of recurrent high-grade gliomas. *Cancer* 2008; **112**: 1139-1146 [PMID: 18246536 DOI: 10.1002/cncr.23167]
  - 29 **Reynés G**, Balañá C, Gallego O, Iglesias L, Pérez P, García JL. A phase I study of irinotecan in combination with metronomic temozolomide in patients with recurrent glioblastoma. *Anticancer Drugs* 2014; **25**: 717-722 [PMID: 24322542 DOI: 10.1097/CAD.000000000000059]

**P- Reviewer:** Persano L, Sulkowski S **S- Editor:** Tian YL

**L- Editor:** A **E- Editor:** Wu HL



## Acute necrotizing pancreatitis: Surgical indications and technical procedures

José Manuel Aranda-Narváez, Antonio Jesús González-Sánchez, María Custodia Montiel-Casado, Alberto Titos-García, Julio Santoyo-Santoyo

José Manuel Aranda-Narváez, Antonio Jesús González-Sánchez, María Custodia Montiel-Casado, Alberto Titos-García, Julio Santoyo-Santoyo, General, Digestive and Transplantation Surgery Department, University Regional Hospital, 29010 Málaga, Spain

Author contributions: All authors contributed to this manuscript.

Correspondence to: José Manuel Aranda Narváez, MD, PhD, Professor of Surgery, General, Digestive and Transplantation Surgery Department, University Regional Hospital, Carlos Haya Av s/n, 29010 Málaga, Spain. [josearanda68@telefonica.net](mailto:josearanda68@telefonica.net)  
Telephone: +34-60-7544071

Received: July 4, 2014 Revised: October 7, 2014

Accepted: October 23, 2014

Published online: December 16, 2014

### Abstract

Necrosis of pancreatic parenchyma or extrapancreatic tissues is present in 10%-20% of patients with acute pancreatitis, defining the necrotizing presentation frequently associated with high morbidity and mortality rates. During the initial phase of acute necrotizing pancreatitis the most important pillars of medical treatment are fluid resuscitation, early enteral nutrition, endoscopic retrograde colangiopancreatography if associated cholangitis and intensive care unit support. When infection of pancreatic or extrapancreatic necrosis occurs, surgical approach constitutes the most accepted therapeutic option. In this context, we have recently assisted to changes in time for surgery (delaying the indication if possible to around 4 wk to deal with "walled-off" necrosis) and type of access for necrosectomy: from a classical open approach (with closure over large-bore drains for continued postoperative lavage or semiopen techniques with scheduled relaparotomies), trends have changed to a "step-up" philosophy with initial percutaneous drainage and posterior minimally invasive or endoscopic access to the retroperitoneal cavity for necrosectomy if no improvement has been previously achieved. These approaches are progres-

sively gaining popularity and morbidity and mortality rates have decreased significantly. Therefore, a staged, multidisciplinary, step-up approach with minimally invasive or endoscopic access for necrosectomy is widely accepted nowadays for management of pancreatic necrosis.

© 2014 Baishideng Publishing Group Inc. All rights reserved.

**Key words:** Acute pancreatitis; Necrotizing pancreatitis; Surgery; Open necrosectomy; Minimal access retroperitoneal pancreatic necrosectomy; Video-assisted retroperitoneal debridement

**Core tip:** We have recently assisted to a significant change in surgical approach to acute pancreatitis. Infection continues as the most important pillar where surgical indication is established. Nevertheless, from an early consideration for surgery frequently performed by classical open approach, today we have moved to delay the indication and the procedure as much as possible with step-up philosophies trying to deal with "walled-off" necrosis and considering minimally invasive access like video-assisted retroperitoneal or endoscopic. In this paper, most recent therapeutic trends for acute necrotizing pancreatitis are reviewed.

Aranda-Narváez JM, González-Sánchez AJ, Montiel-Casado MC, Titos-García A, Santoyo-Santoyo J. Acute necrotizing pancreatitis: Surgical indications and technical procedures. *World J Clin Cases* 2014; 2(12): 840-845 Available from: URL: <http://www.wjgnet.com/2307-8960/full/v2/i12/840.htm> DOI: <http://dx.doi.org/10.12998/wjcc.v2.i12.840>

### INTRODUCTION

Gallstones and alcohol are still the most frequent causes of Acute Pancreatitis (AP), a disease with an increasing

**Table 1 Revised definitions of acute pancreatitis (2012)<sup>[1,2]</sup>**

Types	
Interstitial edematous	Inflammation of pancreatic parenchyma and peripancreatic tissue, without necrosis
Necrotizing	Inflammation with pancreatic parenchymal and/or peripancreatic necrosis
Grades of severity	
Mild	No organ failure
Moderate	Lack of local or systemic complications
	Transient organ failure (< 48 h) and/or Local or systemic complications without persistent organ failure
Severe	Persistent single or multiple organ failure (> 48 h)

incidence in recent decades. Diagnosis is based on the presence of two of the following criteria: (1) characteristic upper abdominal pain radiating in a belt-shaped fashion; (2) amylase or lipase values three times above normal levels; and (3) demonstrative radiologic imaging.

Due to the confusion created by certain terminology derived from the Atlanta classification of AP, a recent revision of the terminology has been developed from an International Consensus, which currently constitutes the reference of the conceptual definition of AP (Table 1). AP is classified into its two forms of presentation (Interstitial Edematous Pancreatitis and Necrotizing Pancreatitis), and according to the severity of the clinical course (mild, moderate and severe). Most AP episodes occur as an interstitial edematous form (80%-90%), usually associated to a mild clinical course, while more clinical severity is frequently associated to the characteristic that defines acute necrotizing pancreatitis (ANP): necrosis, pancreatic or peripancreatic, or a mix of both<sup>[1,2]</sup>.

Local complications associated to the edematous form are defined depending on whether they have or not a well-defined wall and on the time of their arising. Acute fluid collections arise within the first 4 wk of the clinical course and lack a well-defined wall, while pseudocysts are circumscribed fluid collections that occur more than 4 wk after the onset of AP and have a well-defined wall. These complications are out of the scope of the current revision, since their surgical management is not necessary or it is included among elective treatments. On the other part, necrotizing forms may be associated to acute necrotic collections (intra- or extra-pancreatic solid-liquid heterogeneous collection with no defined wall, diagnosed during the first 4 wk of the clinical course) or walled-off necrosis (with similar characteristics but with well-defined wall and with a later diagnosis, above 4 wk). This later concept gathers all previous terms (necroma, pancreatic sequestrum, subacute pancreatic necrosis or pancreatic pseudocyst with necrosis) into a common terminology. Other local complications associated to AP include splenic/portal thrombosis, colon necrosis, retroperitoneal hemorrhage or delayed gastric emptying<sup>[1,2]</sup>.

Physiopathologically, two events may determine the severity of the clinical course. The first of them is the associated Systemic Inflammatory Response Syndrome

(SIRS), which involves a complex inflammatory cascade, which can finally cause the characteristic single- or multiorgan failure. Respiratory, renal and cardiovascular are the most frequent organic failures associated to AP. The second event is infection of necrosis, which is usually associated to phenomena of bacteria translocation. Both events constitute critical factors determining the clinical course of AP and they establish even the current indications for surgery in AP; thus, they will be expounded in detail later on<sup>[3]</sup>.

## SURGICAL IMPLICATIONS DURING THE FIRST WEEK

During the first week after the onset of AP, treatment is medical. Frequently, surgeons on duty are called to evaluate patients with AP without response to medical treatment during the initial phase of the disease. For decision making in this context it must be assumed that the reason for lack of response in these patients is based more in the presence and progression of SIRS than in the potential necrosis or pancreatic infection. Thus, surgery is not indicated during this phase, unless a suspicion of ischemia or perforation as a secondary complication arises. Surgery during this first phase aggravates the multiorgan failure and results in a greater rate of complications, such as intestinal hemorrhage or fistula<sup>[4]</sup>.

In this phase, fluid resuscitation is essential during the first 12-24 h, having to be reduced later on trying to avoid intra abdominal hypertension (IAH), frequently associated to AP. A recent review could not find any difference between fluid resuscitation with colloid or crystalloid solutions<sup>[5]</sup>. Prophylactic antibiotics are not indicated, since they have not shown a clear benefit in previous studies and metaanalysis, and thus, they should not be used until an associated infection is clearly demonstrated<sup>[4]</sup>. Early (on the first 72 h) Endoscopic Retrograde Cholangiopancreatography has not shown benefits when performed systematically in AP in the absence of cholangitis, although an ongoing clinical trial is analyzing this approach again (APEC trial; ISRCTN97372133). However, in presence of bile duct obstruction it is clearly indicated<sup>[6]</sup>.

During this first week, surgeons are occasionally requested to evaluate patients with AP and IAH, present in 61% of episodes of AP. IAH is the precursor of the Abdominal Compartment Syndrome (ACS) and, thus, of multiorgan failure. Although the beneficial effect of decompression to alleviate ACS is clear in other situations, in AP the ACS seems to be closer related to massive resuscitation, ascites or retroperitoneal fluid accumulation and, thus, treatment strategies with decompressive laparotomy have not shown a clear benefit in terms of morbidity and mortality. Currently, management strategies for AP-associated ACS are directed towards medical support (negative fluid balance, enteral decompression, pharmacological increase of the abdominal wall compliance) and even towards percutaneous drainage of fluid collections (with a related ongoing clinical trial, the DECOMPRESS

**Table 2** Modified Marshall scoring system for organ or multiorgan failure<sup>[2,7]</sup>

Organ system	0	1	2	3	4
Respiratory (PaO <sub>2</sub> /FiO <sub>2</sub> )	> 400	300-400	200-300	100-200	< 100
Renal (Creatinine, mg/dL)	< 1.4	1.4-1.8	1.8-3.6	3.6-5	> 5
Cardiovascular (mmHg)	> 90	< 90, fluid responsive	< 90, not fluid responsive	< 90, pH < 7.3	< 90, pH < 7.2

Study; ClinicalTrials.gov NCT00793715). In case abdominal surgical decompression had to be performed during this first phase, in absence of infected necrosis, the retroperitoneum should not be opened<sup>[4]</sup>.

## SURGICAL IMPLICATIONS AFTER THE FIRST WEEK

This is the moment to consider the necessity and indication for surgery of the pancreatic necrosis, on which we will expound extensively. Other local complications may occur at this phase but they are much less frequent and will be mentioned at the end of the chapter.

## SURGERY FOR PANCREATIC NECROSIS

### Indications

Most common indications for surgery of pancreatic necrosis are the following: (1) infection. It is a rare event during the first week of clinical course. The diagnosis is based on the association of sepsis signs with compatible radiologic imaging (extraluminal air in intra- or extra-pancreatic necrotic areas in CT imaging) and on the occasional support of vascular radiologists with percutaneous fine-needle aspiration for Gram staining and culture. There is universal consensus that a need for therapeutic action exists; (2) single- or multiorgan failure. Organ failure is classified as transient or persistent based on whether it lasts less or more than 48 h, respectively. The most recommended system for its definition (even above the Sepsis-related Organ Failure Assessment -SOFA-) is the Marshall score<sup>[7]</sup> (Table 2), which is easy and repeatable along the clinical course of AP. It evaluates the three most commonly SIRS-affected systems (respiratory, renal and cardiovascular) and defines organ failure as a score of 2 or more.

A persistent single- or multiorgan failure refractory to support treatment may constitute an indication for surgery. Numerous studies have shown that in this context, oppositely to what happens when infection constitutes the indication for surgery, necrosectomy does not provide a significant benefit regarding mortality, and thus, it must be considered as the last resource in a patient in whom maximum medical support does not result in clear improvement. We can assert the same statements when surgical indication is established on a patient with ANP with no clinical improvement after 4-6 wk of intensive medical treatment.

We must consider that the indication for surgery in the context of AP must derive more from the need to control complications than from the inflammatory pro-

cess itself. Regarding this, every necrotic and infected tissue must be removed, and pus drained. Material viscosity, as well as the number and localizations of potentially drainable regions constitute determining factors for the selection of the best therapeutic approach. Morbidity associated to pancreatic debridement includes pancreatic fistula (50%), endo- and exocrine pancreatic failure (20%), intestinal fistula (10%) and the common prolonged hospitalization and delay in the incorporation to daily life activities<sup>[3,4]</sup>.

It is important to underline some important concepts before describing the different surgical options: (1) debridement is preferred over resection for two reasons: first, as an attempt to conserve the maximum quantity of functional pancreatic tissue, and second, due to the frequent technical impossibility of pancreatic resection and its associated morbidity in the context of AP<sup>[3,4]</sup>; (2) unless evident infection of necrosis exists, survival improves as the surgical indication gets delayed. The best results are obtained when the indication may be delayed up to one month after the onset of the clinical symptoms. A better demarcation of necrosis (conversion to “walled-off” pancreatic necrosis) involves less bleeding and less removal of viable tissues<sup>[3,4]</sup>; and (3) Two different philosophies define the timing of the surgical approach for a patient with AP. “Step-down” consists on the classical immediate surgical approach when there is an established indication, and, later on, a more conservative treatment for the residual disease. However, there is a trend in the most recent medical literature towards a “step-up” type of concept, where more conservative procedures (percutaneous, laparoscopic or endoscopic procedures) constitute the initial treatment of patients with ANP and a final technique is performed later on if necessary, based on poor clinical evolution<sup>[8]</sup>.

### Options

**Open necrosectomy:** Open necrosectomy (ON) was considered as the gold standard treatment for decades, and it was usually associated to a therapeutic “step-down” type of approach. Classical ON consists on debridement of the necrotic pancreatic tissue through a midline or subcostal bilateral incision and the access to the pancreatic area through the lesser sac, the gastrocolic omentum or by a transmesenteric access through the transverse mesocolon, depending on necrosis extension and localization. Once the necrosectomy has been performed, the options are: (1) usual closure over drains and relaparotomy depending on clinical course; (2) scheduled laparotomies, usually every 48 h, until debridement has been completed. Open abdomen techniques are recommended if this



approach is selected, but scheduled laparotomies closing the abdomen after each revision have also been reported; and (3) closed technique with abdominal closure over lavage system with large-bore drains in the pancreatic area.

The last one constitutes the most recommended option based on a mortality < 10%, significantly inferior to those associated to the rest of the techniques. Nevertheless, an effective comparison between the different methods is difficult because of the heterogeneity of patients and surgeons<sup>[3,4,9]</sup>.

**Percutaneous drainage:** Several series of patients have reported that management of infected pancreatic necrosis with percutaneous drainage (PD) obtains a high success rate and mortality similar to that of ON treatment. In a systematic review<sup>[10]</sup>, the success rate of PD (defined as survival with no need for additional surgical necrosectomy) was 55%, mortality 17% and morbidity 21%, showing pancreaticocutaneous and pancreaticoenteric fistulas as the most frequent complications associated to the procedure. Although PD constitutes a tempting and efficient therapeutic alternative as a minimally aggressive approach, the truth is that frequently success depends on the availability of large caliber catheters and often repeated procedures are needed. For selected patients, like those with AP and easily accessible single infected necrosis, or as a transient step to surgery in unstable patients, this therapeutic option must be considered. However, PD is not accepted as a useful tool when an extensive necrosectomy is needed<sup>[3,4,9]</sup>.

**Endoscopic approach:** A promising approach for pancreatic necrosis is the transgastric or transduodenal endoscopic approach (EA) under direct vision or with ultrasound support. Very diverse types of instruments are later used to maintain opened the communication between the digestive lumen and the necrosis and to perform the necrosectomy, and frequently repeated procedures are needed. Several series have reported promising results with EA, some as important as the German multicenter GEPARD Study<sup>[11]</sup> with 93 patients, 81% of clinical success and only 7.5% mortality. The results of EA for necrotizing AP have been recently summarized in a systematic review<sup>[12]</sup>, which reports a success rate of 75% on 260 patients; however, it must be pointed out that data derive from non-randomized studies on selected patients in reference centers.

**Laparoscopic approach:** Laparoscopic approach (LA) for ANP may result particularly attractive because of its potential of obtaining all the advantages of a minimally invasive approach while maintaining access to the whole abdominal cavity (perirenal and retroduodenal spaces and mesenteric root, as well as both paracolic gutters) and the technical possibility of indicating additional techniques (cholecystectomy or jejunostomy). However, the extension of LA in ANP among professionals is still scarce, since its advantages are overpassed by its limitations: infection dissemination, need for pneumoperitoneum in

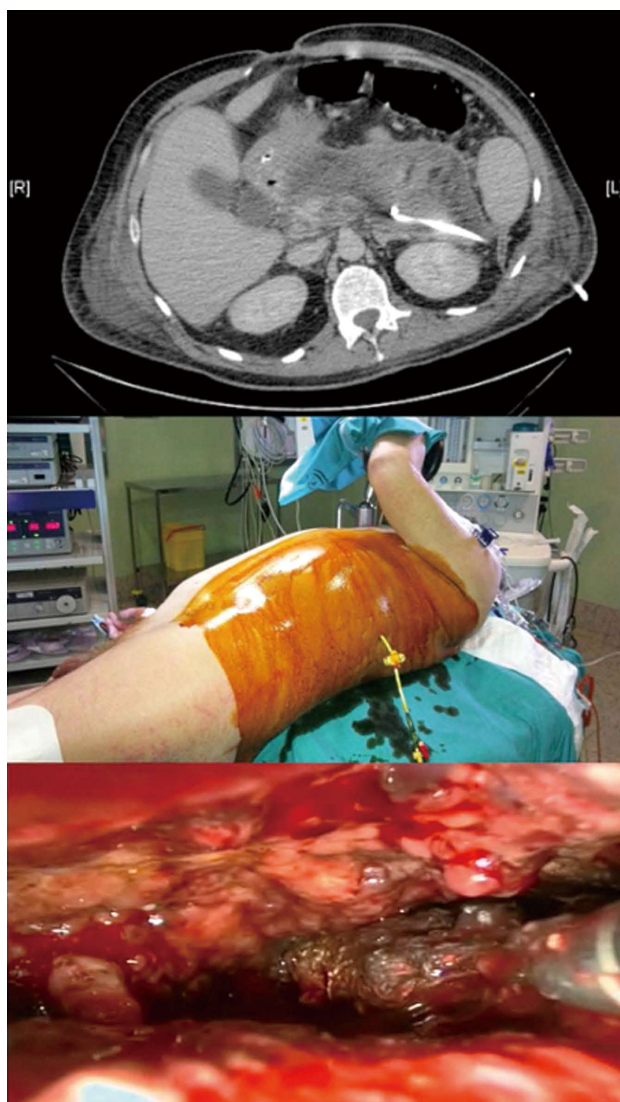
unstable patients, or the possibility of iatrogenic intestinal perforations. Published series of patients have a scarce number of cases and it is still soon to recommend this approach<sup>[3,4]</sup>.

**Retroperitoneal approach:** It constitutes the maximum example of Minimally Invasive Necrosectomy. Retroperitoneal approach (RA) of the necrosis is performed through small incisions and the use of endoscopic material, guided by a percutaneous drainage previously and strategically indicated, placed laterally, avoiding access to the abdominal cavity and providing all the advantages of the minimally invasive approach. Diverse methods for its performance have been described but the most widely accepted are Minimal Access Retroperitoneal Pancreatic Necrosectomy (MARPN) and Video-Assisted Retroperitoneal Debridement (VARD) (Figure 1). This last one consists in the introduction of a laparoscopic camera, through a 5 cm incision, and after the first liquid and solid debris have been removed a vigorous debridement of the necrotic cavity may be performed with the maintenance of a low-pressure pneumoperitoneum. The number of repeated necrosectomies needed later on is significantly lower with VARD than with MARPN.

In a systematic review, incidence of multiorgan failure, incisional hernia and endo- and exocrine failure was significantly lower with RA than with ON, although mortality was similar and no differences were observed regarding local complications, such as intraabdominal bleeding or pancreatic fistula<sup>[13]</sup>.

**Combined approaches with “step-up” philosophy:** Probably, management of pancreatic necrosis in an immediate future will not be based only in one of the methods already mentioned. A combination of them with a decision making based on characteristics of the patient, necrosis grade, extension and localization will be the key for defining the best therapeutic option in ANP. The most illustrative of these approaches is the Dutch PANT-ER<sup>[14]</sup> (PANcreatitis, Necrosectomy *vs* sTEp up appRoach) study, a randomized, multicenter, clinical trial in which 88 patients with necrotizing AP who met inclusion criteria, and in whom the need to perform an invasive procedure was established (delayed whenever as possible up to 4 wk from the onset of the clinical symptoms) were divided into two groups: 45 with ON and 43 with “step-up” type minimally invasive approach. Such an approach consisted in placing a percutaneous drainage as the first step (40 retroperitoneal, 1 abdominal and 2 endoscopic), assessing the placement of a second drainage or the performance of RA in the absence of improvement after 72 h, based on clinical and radiologic findings. The morbi-mortality rate of the “step-up” type of approach was significantly lower than that of the ON group (40% *vs* 69%,  $P < 0.006$ ), and so was the multiorgan failure (12% *vs* 40%,  $P < 0.002$ ). In addition, it was defined that more than 30% of patients in the “step-up” group did not need necrosectomy after the percutaneous or endoscopic drainage.

On the same line of therapeutic combination, the on-



**Figure 1** Video-assisted retroperitoneal debridement: Computed tomography scan with percutaneous drainage into an infected pancreatic necrosis (above); patient's position for necrosectomy (middle); endoscopic view of necrotic pancreatic tissue (below).

going TENSION study (ISRCTN 09186711) randomizes 98 patients with ANP to receive step-up type endoscopic approach vs surgical approach.

## OTHER SURGICAL INDICATIONS

Disruptions of the main pancreatic duct may derive in internal or external fistulas, pancreatic ascites or pleural effusion. Treatment constitutes an important challenge and, depending on location and clinical manifestation, it can require from PD as the only procedure up to pancreatic resection or Roux-en-Y derivation for what is called the Disconnected Pancreatic Duct Syndrome, although a CPRE approach and transpapillar drainage is usually sufficient<sup>[3]</sup>.

Vascular complications occur in 2.4%-10% of patients with AP, and they derive from bleeding into the peritoneal cavity or into the gastrointestinal tract from pseudoaneurysms of vessels close to the inflammatory

process, such as the gastroduodenal or pancreaticoduodenal arteries. Nowadays, embolization is the therapeutic method of choice<sup>[3,4]</sup>.

Colonic complications associated with pancreatitis are infrequent (1% of cases). From reactive ileus to most severe forms with obstruction, necrosis or perforation are associated to poor prognosis and mortality increase. For the majority of cases, resection with proximal ostomy and mucous fistula constitutes the treatment for these complications.

Maybe out of the emergency context but of necessary mention, it must be underlined that there is an indication for cholecystectomy in the first admission after the first mild gallstones pancreatitis. A systematic review reported up to 18% readmissions in patients with mild AP if an early cholecystectomy is not indicated and performed<sup>[15]</sup>. In severe AP, however, cholecystectomy should be deferred until complete resolution of inflammation<sup>[16]</sup>.

## CONCLUSION

In recent years we have witnessed a change in the management of patients with ANP: from a prematurely indicated surgery, performed open, we are moving to less aggressive procedures, indicated later and with "step-up" strategies, performing first PD, preferably retroperitoneal, and continuing with surgical (considering new access routes) or endoscopic necrosectomy in case of absence of improvement. These concepts require a multidisciplinary approach to ANP with implication of surgeons, gastroenterologists, radiologists, and intensive care unit doctors, and the need for contemplating the referral of patients to reference centers when the needed logistic is not available. Trauma and Emergency Surgery Units in the Departments of General and Digestive Surgery constitute, thus, the ideal setting for the early diagnosis, indication, intervention and follow-up of these patients.

## REFERENCES

- 1 **Banks PA**, Bollen TL, Dervenis C, Gooszen HG, Johnson CD, Sarr MG, Tsotos GG, Vege SS. Classification of acute pancreatitis—2012: revision of the Atlanta classification and definitions by international consensus. *Gut* 2013; **62**: 102-111 [PMID: 23100216 DOI: 10.1136/gutjnl-2012-302779]
- 2 **Sarr MG**, Banks PA, Bollen TL, Dervenis C, Gooszen HG, Johnson CD, Tsotos GG, Vege SS. The new revised classification of acute pancreatitis 2012. *Surg Clin North Am* 2013; **93**: 549-562 [PMID: 23632143 DOI: 10.1016/j.suc.2013.02.012]
- 3 **Martin RF**, Hein AR. Operative management of acute pancreatitis. *Surg Clin North Am* 2013; **93**: 595-610 [PMID: 23632146 DOI: 10.1016/j.suc.2013.02.007]
- 4 **da Costa DW**, Boerma D, van Santvoort HC, Horvath KD, Werner J, Carter CR, Bollen TL, Gooszen HG, Besselink MG, Bakker OJ. Staged multidisciplinary step-up management for necrotizing pancreatitis. *Br J Surg* 2014; **101**: e65-e79 [PMID: 24272964 DOI: 10.1002/bjs.9346]
- 5 **Haydock MD**, Mittal A, Wilms HR, Phillips A, Petrov MS, Windsor JA. Fluid therapy in acute pancreatitis: anybody's guess. *Ann Surg* 2013; **257**: 182-188 [PMID: 23207241 DOI: 10.1097/SLA.0b013e31827773ff]
- 6 **Tse F**, Yuan Y. Early routine endoscopic retrograde cholan-

- giopancreatography strategy versus early conservative management strategy in acute gallstone pancreatitis. *Cochrane Database Syst Rev* 2012; **5**: CD009779 [PMID: 22592743 DOI: 10.1002/14651858.CD009779.pub2]
- 7 **Marshall JC**, Cook DJ, Christou NV, Bernard GR, Sprung CL, Sibbald WJ. Multiple organ dysfunction score: a reliable descriptor of a complex clinical outcome. *Crit Care Med* 1995; **23**: 1638-1652 [PMID: 7587228]
  - 8 **Windsor JA**. Minimally invasive pancreatic necrosectomy. *Br J Surg* 2007; **94**: 132-133 [PMID: 17256812]
  - 9 **Schneider L**, Büchler MW, Werner J. Acute pancreatitis with an emphasis on infection. *Infect Dis Clin North Am* 2010; **24**: 921-941, viii [PMID: 20937458 DOI: 10.1016/j.idc.2010.07.011]
  - 10 **van Baal MC**, van Santvoort HC, Bollen TL, Bakker OJ, Besselink MG, Gooszen HG. Systematic review of percutaneous catheter drainage as primary treatment for necrotizing pancreatitis. *Br J Surg* 2011; **98**: 18-27 [PMID: 21136562 DOI: 10.1002/bjs.7304]
  - 11 **Seifert H**, Biermer M, Schmitt W, Jürgensen C, Will U, Gerlach R, Kreitmair C, Meining A, Wehrmann T, Rösch T. Transluminal endoscopic necrosectomy after acute pancreatitis: a multicentre study with long-term follow-up (the GEPARD Study). *Gut* 2009; **58**: 1260-1266 [PMID: 19282306 DOI: 10.1136/gut.2008.163733]
  - 12 **Haghsheenasakshani A**, Laurence JM, Kwan V, Johnston E, Hollands MJ, Richardson AJ, Pleass HC, Lam VW. Endoscopic necrosectomy of pancreatic necrosis: a systematic review. *Surg Endosc* 2011; **25**: 3724-3730 [PMID: 21656324 DOI: 10.1007/s00464-011-1795-x]
  - 13 **Cirocchi R**, Trastulli S, Desiderio J, Boselli C, Parisi A, Noya G, Falconi M. Minimally invasive necrosectomy versus conventional surgery in the treatment of infected pancreatic necrosis: a systematic review and a meta-analysis of comparative studies. *Surg Laparosc Endosc Percutan Tech* 2013; **23**: 8-20 [PMID: 23386143 DOI: 10.1097/SLE.0b013e3182754bca]
  - 14 **van Santvoort HC**, Besselink MG, Bakker OJ, Hofker HS, Boermeester MA, Dejong CH, van Goor H, Schaapherder AF, van Eijck CH, Bollen TL, van Ramshorst B, Nieuwenhuijs VB, Timmer R, Laméris JS, Kruij PM, Manusama ER, van der Harst E, van der Schelling GP, Karsten T, Hesselink EJ, van Laarhoven CJ, Rosman C, Bosscha K, de Wit RJ, Houdijk AP, van Leeuwen MS, Buskens E, Gooszen HG. A step-up approach or open necrosectomy for necrotizing pancreatitis. *N Engl J Med* 2010; **362**: 1491-1502 [PMID: 20410514 DOI: 10.1056/NEJMoa0908821]
  - 15 **van Baal MC**, Besselink MG, Bakker OJ, van Santvoort HC, Schaapherder AF, Nieuwenhuijs VB, Gooszen HG, van Ramshorst B, Boerma D. Timing of cholecystectomy after mild biliary pancreatitis: a systematic review. *Ann Surg* 2012; **255**: 860-866 [PMID: 22470079 DOI: 10.1097/SLA.0b013e3182507646]
  - 16 **Working Group IAP/APA Acute Pancreatitis Guidelines**. IAP/APA evidence-based guidelines for the management of acute pancreatitis. *Pancreatology* 2013; **13**: e1-15 [PMID: 24054878 DOI: 10.1016/j.pan.2013.07.063]

**P- Reviewer:** Bradley EL, Cochior D **S- Editor:** Ji FF  
**L- Editor:** A **E- Editor:** Wu HL



## Large bowel injuries during gynecological laparoscopy

Kahraman Ülker, Turgut Anuk, Murat Bozkurt, Yetkin Karasu

Kahraman Ülker, Murat Bozkurt, Yetkin Karasu, Department of Obstetrics and Gynecology, Kafkas University School of Medicine, 36000 Kars, Turkey

Turgut Anuk, Department of General Surgery, Kafkas University School of Medicine, 36000 Kars, Turkey

**Author contributions:** Ülker K, Anuk T, Bozkurt M and Karasu Y contributed to this paper; all the authors read and approved the final version of the manuscript before submission; In addition, they also contributed to the revision process.

**Correspondence to:** Kahraman Ülker, MD, Associate Professor, Department of Obstetrics and Gynecology, Kafkas University School of Medicine, Bülbül Mahallesi Kombine Yolu Üzeri Merkez Kars, 36000 Kars, Turkey. [kahramanulker@hotmail.com](mailto:kahramanulker@hotmail.com)  
Telephone: +90-505-5700574 Fax: +90-474-2251193

Received: July 22, 2014 Revised: September 4, 2014

Accepted: September 16, 2014

Published online: December 16, 2014

### Abstract

Laparoscopy is one of the most frequently preferred surgical options in gynecological surgery and has advantages over laparotomy, including smaller surgical scars, faster recovery, less pain and earlier return of bowel functions. Generally, it is also accepted as safe and effective and patients tolerate it well. However, it is still an intra-abdominal procedure and has the similar potential risks of laparotomy, including injury of a vital structure, bleeding and infection. Besides the well-known risks of open surgery, laparoscopy also has its own unique risks related to abdominal access methods, pneumoperitoneum created to provide adequate operative space and the energy modalities used during the procedures. Bowel, bladder or major blood vessel injuries and passage of gas into the intravascular space may result from laparoscopic surgical technique. In addition, the risks of aspiration, respiratory dysfunction and cardiovascular dysfunction increase during laparoscopy. Large bowel injuries during laparoscopy are serious complications because 50% of bowel injuries and 60% of visceral injuries are undiagnosed at the time of primary surgery. A missed or delayed diagnosis increases the risk of bowel perforation and consequently

sepsis and even death. In this paper, we aim to focus on large bowel injuries that happen during gynecological laparoscopy and review their diagnostic and management options.

© 2014 Baishideng Publishing Group Inc. All rights reserved.

**Key words:** Colon; Gynecology; Intraoperative complications; Laparoscopy; Wounds and injuries

**Core tip:** Large bowel injury during laparoscopy is a serious complication because 50% and 66% of bowel and visceral injuries are undiagnosed at the time of primary surgery. A missed or delayed diagnosis increases the risk of bowel perforation and consequently sepsis and death.

Ülker K, Anuk T, Bozkurt M, Karasu Y. Large bowel injuries during gynecological laparoscopy. *World J Clin Cases* 2014; 2(12): 846-851 Available from: URL: <http://www.wjgnet.com/2307-8960/full/v2/i12/846.htm> DOI: <http://dx.doi.org/10.12998/wjcc.v2.i12.846>

### INTRODUCTION

Four decades ago, laparoscopic surgery was being performed by a limited number of surgeons and most of the procedures were limited to diagnostic laparoscopy and tubal sterilization. However, through the years laparoscopy has evolved and become one of the major management choices for many surgical diseases. Cameras and hand instruments with improved visual quality and better manipulation capabilities, respectively, along with the accumulation of the data obtained from previous studies and case reports have contributed to the evolvement of laparoscopy.

Today, laparoscopy is one of the most frequently preferred surgical options in gynecological surgery. In the United States, roughly 350000 bilateral tubal sterilizations and 200000 hysterectomies are performed using



laparoscopy each year. The popularity of laparoscopy has increased around the world and many gynecologists, including inexperienced and junior surgeons in training, have begun to perform laparoscopic procedures. Thus, the number of patients prone to complications during laparoscopy has increased<sup>[1]</sup>.

Laparoscopy has advantages over laparotomy, including smaller surgical scars, faster recovery from surgery, less pain and earlier return of bowel functions. Generally, it is also accepted as safe and effective and patients tolerate it well<sup>[2]</sup>. However, it is still an intra-abdominal procedure and has the similar potential risks of laparotomy, including injury of a vital structure, bleeding and infection<sup>[3-6]</sup>. Intra and postoperative complications are below 1% and 4 to 8 patients are lost per 100000 laparoscopic procedures.

Besides the well-known risks of open surgery, laparoscopy also has its own unique risks related to abdominal access methods, pneumoperitoneum created to provide adequate operative space and the energy modalities used during the procedures. Bowel, bladder or major blood vessel injuries and passage of gas into the intravascular space may result from laparoscopic surgical technique. In addition, the risks of aspiration, respiratory dysfunction and cardiovascular dysfunction increase during laparoscopy<sup>[5-9]</sup>. Blood loss is generally lower than in open surgery; however, in some cases, massive blood loss necessitates immediate laparotomy.

Because of its advantages over laparotomy, such as less pain, hospital stay and recovery time, laparoscopy is generally perceived as a minor surgical procedure by patients. Thus, the medico legal aspects of the complications of laparoscopy are prone to exaggeration. In order to minimize complications and their unavoidable consequences, surgeons should learn the probable complications and their management. In this paper, we aim to focus on large bowel injuries that happen during gynecological laparoscopy and review their diagnostic and management options.

## CLASSIFICATION, EPIDEMIOLOGY AND RISK FACTORS

Complications related to laparoscopic surgery can occur during either intra or postoperative phases. Intraoperative complications can further be divided into complications of access and complications of the operative procedure. More than half of complications occur at the setting up phase, particularly during the creation of the abdominal access pathways necessary for the telescope and trocars<sup>[10,11]</sup>.

The complication rate during the placement of the initial abdominal access port is less than 1%. Complications following the initial access are also rare. In contrast, port site hernia as a late complication can affect 6% of patients<sup>[12-14]</sup>. Although rare, severe complications including vascular and bowel injuries, may cause serious morbidity and even result in the death of the patient.

The study conducted by Chandler *et al*<sup>[10]</sup> in 2001 showed that the incidence of injury during abdominal access varied between 5 and 30 per 10000 procedures. Large bowel was the third most frequent injury site after the small bowel and iliac artery, with 12% of all injuries at the large bowel. In their review published in 2012, Jansen *et al*<sup>[15]</sup> reported that access related bowel injury was seen in 4.4 per 10000 gynecological procedures. In addition, Hasson's open abdominal access technique did not significantly lower the complication rates compared to the closed technique.

Bhoirul *et al*<sup>[16]</sup> studied 32 deaths following 629 trocar injuries and found that six patients died following bowel injury. Delay in the diagnosis of gastrointestinal perforation resulted in a mortality rate of 21%.

A history of previous intra-abdominal surgery, vertical incision, endometriosis and pelvic infection increases the risk of bowel injury. Extensive bowel distension obscuring the operative field, large abdominal or pelvic mass (in the case of hysterectomy, uterine size over 500 g) and diaphragmatic hernia increase the risk of complications. In addition, major operative laparoscopy, extensive adhesiolysis and concomitant major surgery are the other factors that increase the risk of complications. Moreover, surgeon experience and the type and the difficulty of the cases also contribute to complication rates<sup>[17-21]</sup>.

## LARGE BOWEL INJURIES DURING THE SETTING UP PHASE OF GYNECOLOGICAL LAPAROSCOPY

Bowel injury may be encountered at any stage of laparoscopic surgery, beginning from abdominal access until the end of port site closure. It is the third most frequent mortal complication of laparoscopy, following anesthesia and major vessel injuries<sup>[22]</sup>. Gastrointestinal tract injury during laparoscopy ranged between 0.03 and 0.18%<sup>[6,23-26]</sup> and its incidence was 0.13% in the meta-analysis performed by van der Voort *et al*<sup>[27]</sup>.

Before the study performed by Levy *et al*<sup>[28]</sup>, energy modalities used in laparoscopic surgery were mistakenly considered to be the leading cause of gastrointestinal injuries. However, 30% to 50% of the bowel injuries occur during Veress needle or trocar insertion into the abdominal cavity<sup>[6,11,29-31]</sup>. Gastrointestinal injuries occur more often at the small bowel; however, other intra-abdominal organs, including the large bowel and stomach, may also be injured. Preoperative bowel preparation and decompression of the stomach with an orogastric or nasogastric tube may prevent potential injuries occurring during abdominal access.

In the retrospective case review study conducted by Chapron *et al*<sup>[5]</sup>, 32.1% of the gastrointestinal injuries occurred during the initial set up procedure. Pneumoperitoneum needle, umbilical trocar and suprapubic trocar were isolated as the causes of injuries in 10.7%, 16.1% and 5.3% of the cases, respectively. Of the 62 gastrointestinal injuries of the 56 patients, 57.2% occurred during the

operative phase of the procedure, and electrosurgery and sharp dissection were the causes of injuries with the rates of 10.7% and 46.5%, respectively. The authors could not define whether the injuries occurred during initial set up or operative phases in 10.7% of the cases.

Of the 62 gastrointestinal injuries of the 56 patients reviewed by Chapron *et al*<sup>[5]</sup>, 30 (48.4%) injuries involving the large intestine had the highest frequency and were followed by the 21 (33.9%) small bowel and 10 (16.1%) epiploon injuries. Of the 30 large bowel injuries, 18 injuries were at the sigmoid colon, followed by four cecum, four rectum and four colon injuries.

It is not clear whether the frequency of bowel injury during abdominal access is affected by the complexity of the operative phase. Some studies reported higher rates of bowel injury during access in diagnostic laparoscopy and laparoscopic tubal sterilizations<sup>[30]</sup>, in contrast to others reporting higher injury rates in major laparoscopic surgeries<sup>[6]</sup>.

The surgeon's experience affects the rate of injury; however, the frequency of injuries during abdominal access is still high for more experienced surgeons<sup>[32]</sup>. Depending on the fact, investigators are trying to improve the outcomes of abdominal access during laparoscopy by using various access techniques. Blind Veress introduction followed by pneumoperitoneum and the primary trocar, direct trocar insertion and open access techniques are examples. In addition, investigators are trying to improve the already known techniques. As an example, in their recently published study, Ozdemir *et al*<sup>[33]</sup> used umbilical stalk elevation (USE) technique to improve the success rate of Veress needle insertion in obese patients and concluded that the USE technique seemed safe and required a significantly fewer number of attempts to create pneumoperitoneum.

Excellency in Veress needle and trocar use may prevent some major complications. Although wiggling of the needle movements to ascertain intra-abdominal entry may enlarge the diameter of an injury<sup>[32]</sup>, the correct placement of the needle is usually checked by most surgeons. In addition to the classical safety checks, foul smell, observation of the gastrointestinal contents and asymmetrical abdominal distention due to insufflation of the bowel should raise the suspicion of bowel injury<sup>[34]</sup>. Moreover, passage of flatus may be a sign of intra-intestinal insufflation.

Although Hasson's open technique did not lower the total complication rates, theoretically open techniques may decrease the risk of life threatening major vascular injuries during abdominal access. In addition, the chance of an earlier diagnosis is higher. In contrast to the theoretical advantages of an open technique, there are articles reporting a higher incidence of bowel injury with an open technique<sup>[29,35,36]</sup>. However, many surgeons prefer open access techniques for patients with anticipated risks. Thus, in order to avoid selection bias, final judgment will be appropriate after randomized prospective studies.

In addition to their theoretical advantages, open techniques are also used during gasless laparoscopies and may help in lowering the CO<sub>2</sub> related risks of laparo-

scopic surgery. Thus, gasless laparoscopy may decrease some risks of laparoscopic surgery that occur during abdominal access. In our practice, we have experienced the single incision, gasless technique called keyless abdominal rope-lifting surgery (KARS)<sup>[37-40]</sup> and did not observe any internal organ injury. However, among the various access techniques, the best probably is the one in which the surgeon has more experience and advanced skills.

## LARGE BOWEL INJURIES DURING THE OPERATIVE PHASE OF GYNECOLOGICAL LAPAROSCOPY

During the operative phase of laparoscopy, bowel injury may occur as a result of trauma secondary to tissue dissection and manipulation or electrosurgical energy use. It is a serious complication because 50% and 66% of bowel or visceral injuries are undiagnosed at the time of primary surgery<sup>[41]</sup>. A missed or delayed diagnosis increases the risk of bowel perforation and consequently sepsis, and even death<sup>[6]</sup>.

In the study conducted by Chapron *et al*<sup>[5]</sup>, of the 56 patients suffering from gastrointestinal injury, 32 had injuries at the operative phase of the procedures and 26 injuries were due to sharp dissections. Thus, experienced surgeons with advanced surgical skills are expected to have lower complication rates. Not surprisingly, experience significantly decreases the complication rates of the operative phase and the surgeon's advanced skills in fine adhesiolysis also decreases the complication rates<sup>[6]</sup>.

Brummer *et al*<sup>[42]</sup> compared the incidence of injuries of laparoscopy performed between 1992 and 1999 with the injury incidence of 2000 and 2005, emphasizing the importance of the learning curve in laparoscopic and vaginal hysterectomies. The incidence of all kinds of injuries was significantly lower between 2000 and 2005. Similarly, bowel injuries during laparoscopic hysterectomies decreased from 0.14% to 0.09% during the same period and large bowel injuries involved half of all bowel injuries<sup>[42]</sup>. The use of proper hand instruments while manipulating and dissecting the tissues may decrease the injury rates.

The use of electrosurgical energy during operative laparoscopy causes injury of the target tissue. The injured tissue may become necrotic or heal slowly during the postoperative period<sup>[43]</sup>. In addition to the target tissue, increased local temperature may cause injury of the nearby vital structures, *e.g.*, the large bowel. Thus, the surgeon should be familiar with the used energy modality. A monopolar current travels through the tissues of the patient; however, a bipolar current passes between the two electrodes of the instrument and thus influences only the tissue between electrodes.

Monopolar energy causes more lateral thermal spread and produces the highest temperatures compared to bipolar electrocautery, the Harmonic scalpel and LigaSure<sup>[44]</sup>. The degree of lateral thermal spread varies with various energy modalities and is as follows: 2-22 mm for

traditional bipolar, 0-3 mm for ultrasonic cutting and coagulation, 1.1 mm for the Enseal, 1.8 mm for LigaSure and 6.3 mm for Gyrus Plasma Trisector<sup>[45-48]</sup>. In addition, the monopolar electrosurgical instrument insulating layer is not foolproof and the current may spread to the adjacent tissue<sup>[49]</sup>. Thus, in a case where the operative field is close to the bowel, the risk of bowel injury increases and the unnoticed injury may present postoperatively.

## PREVENTION, DIAGNOSIS AND MANAGEMENT

Most gynecologists learn traditional gynecological procedures during residency; however, they generally gain skills required for laparoscopic procedures during their postgraduate clinical practice without supervision. The learning curve is lengthy and becomes longer with the advancement of new techniques and instruments. The complication risk is highest during the initial stages of a surgeon's laparoscopic experience<sup>[50]</sup>.

A comprehensive preoperative evaluation, proper consultations, patient selection and risk assessment help lessen the risk of complications. Besides a gynecologist having the required skills for laparoscopic surgery, the operating room staff and assistants should also be properly trained. The operating room should be ready for an emergency laparotomy. The infrastructure required for a multidisciplinary surgical approach should be maintained during the laparoscopic procedures.

During the initial stages of the experience of laparoscopy, it is better for a surgeon to perform minor procedures. Previous studies reported that the complication rates were higher in the first 100 procedures of surgeons beginning to perform laparoscopy.

Sudden and uncontrolled Veress needle and trocar entry can lacerate the rectum and sigmoid colon. The transverse colon may be displaced by the distended stomach and become vulnerable to injuries. A nasogastric tube helps to eliminate this potential risk.

Obliteration of the pouch of Douglas and the presence of dense adhesions between the rectum and uterus increase the chance of bowel injury. In these circumstances, blunt dissection may increase the chance of rectal laceration and thus sharp dissection with scissors or CO<sub>2</sub> laser should be preferred. Placement of a probe or finger in both the vagina and the rectum helps to identify the tissue planes. Nezhat *et al*<sup>[51]</sup> and Redwine<sup>[52]</sup> advise beginning the dissection lateral to the uterosacral ligaments and proceeding toward the obliterated cul-de-sac. In addition, preoperative bowel preparation may help in cases with high risks for bowel injury.

One to two thirds of bowel injuries can be detected intraoperatively<sup>[5]</sup> and half of the injuries can be identified between first and seventh postoperative days. Most patients do not have the typical symptoms of bowel injury, such as low-grade fever, nausea, vomiting, ileus, severe abdominal pain, leucopenia or a normal leukocyte count, and the diagnosis is delayed. Thus, in many cases, patients

present with peritonitis and the situation increases the rates of morbidity and mortality<sup>[10,16]</sup>. Sepsis and acute abdominal pain are typically observed 1-2 d after surgery.

Brownish fluid in a saline aspiration test may sometimes diagnose large bowel perforation. In addition, fecal smell strengthens the suspicion. In cases where the suspicion of bowel perforation arises, the Veress needle should be replaced with a sterile one and the field beneath the primary entrance should be examined after the introduction of the telescope. Intraoperative sigmoidoscopy may be helpful in identifying the injury site<sup>[53]</sup>. Recently, in an experimental study conducted by Ülker *et al*<sup>[54]</sup>, insertion of a rectal catheter attached to a urine bag was recommended to identify large bowel injuries. It was suggested that the accumulation of gas in the connected bag would signal small and hardly demonstrable large bowel injuries. A computerized tomography examination can reveal fecal material outside the large bowel and/or free air in the abdominal viscera. Additional imaging work up, including imaging with a gastrografin enema, can also help to detect an injury site.

Large bowel injuries should be managed at the time when they are recognized, if possible, at the same operative section. Small injuries secondary to a Veress needle may be managed conservatively with close observation in hospital, intravenous hyperalimentation and antibiotics<sup>[55]</sup>. However, 6% of cases with superficial electrocautery bowel injuries require open exploration due to acute perforation during the observation period and thus intraoperative repair of the damaged bowel is significantly safer and should be performed in every suspicious electrocautery bowel injury.

Most trocar injuries need a primary closure in one or two layers. However, larger injuries with an ambiguous tissue injury may necessitate colostomy. In these conditions, incorporation of a general surgeon experienced with bowel surgery is advisable. Depending on the skills of the surgical team, bowel repair may be performed laparoscopically<sup>[56]</sup>. Extensive intra-abdominal lavage, use of combined broad-spectrum antibiotics and drainage may decrease the infection risk.

Injury at the right ascending colon generally requires resection of the injured section and a primary anastomosis. Ileostomy with diversion of the intestinal contents speeds up healing. In a case where the bowel is not prepared preoperatively and the descending colon, sigmoid or rectum is injured, primary closure or resection with primary anastomosis are not good treatment options. In these circumstances, a diverting colostomy with resection of the injured portion is recommended. Colonic lacerations of preoperatively prepared bowel can be repaired laparoscopically<sup>[50]</sup>.

## CONCLUSION

Large bowel injuries during gynecological laparoscopy are rare but serious complications. Approximately one third can be diagnosed intraoperatively and delayed diagnosis increases the rates of morbidity and mortality. They



should be managed immediately when recognized, if possible, at the same operative section.

## REFERENCES

- Philips PA, Amaral JF. Abdominal access complications in laparoscopic surgery. *J Am Coll Surg* 2001; **192**: 525-536 [PMID: 11294410 DOI: 10.1016/S1072-7515(01)00768-2]
- Bongard F, Dubecz S, Klein S. Complications of therapeutic laparoscopy. *Curr Probl Surg* 1994; **31**: 857-924 [PMID: 7956322 DOI: 10.1016/0011-3840(94)90060-4]
- Vagenas K, Spyrapopoulos P, Karanikolas M, Sakelaropoulos G, Maroulis I, Karavias D. Mini-laparotomy cholecystectomy versus laparoscopic cholecystectomy: which way to go? *Surg Laparosc Endosc Percutan Tech* 2006; **16**: 321-324 [PMID: 17057572 DOI: 10.1097/01.sle.0000213720.42215.7b]
- Busacca M, Fedele L, Bianchi S, Candiani M, Agnoli B, Raffaelli R, Vignali M. Surgical treatment of recurrent endometriosis: laparotomy versus laparoscopy. *Hum Reprod* 1998; **13**: 2271-2274 [PMID: 9756309 DOI: 10.1093/humrep/13.8.2271]
- Chapron C, Pierre F, Harchaoui Y, Lacroix S, Béguin S, Querleu D, Lansac J, Dubuisson JB. Gastrointestinal injuries during gynaecological laparoscopy. *Hum Reprod* 1999; **14**: 333-337 [PMID: 10099974 DOI: 10.1093/humrep/14.2.333]
- Chapron C, Querleu D, Bruhat MA, Madelenat P, Fernandez H, Pierre F, Dubuisson JB. Surgical complications of diagnostic and operative gynaecological laparoscopy: a series of 29,966 cases. *Hum Reprod* 1998; **13**: 867-872 [PMID: 9619539 DOI: 10.1093/humrep/13.4.867]
- Schulze S, Lyng KM, Bugge K, Perner A, Bendtsen A, Thorup J, Nielsen HJ, Rasmussen V, Rosenberg J. Cardiovascular and respiratory changes and convalescence in laparoscopic colonic surgery: comparison between carbon dioxide pneumoperitoneum and gasless laparoscopy. *Arch Surg* 1999; **134**: 1112-1118 [PMID: 10522857 DOI: 10.1001/archsurg.134.10.1112]
- Bouvy ND, Giuffrida MC, Tseng LN, Steyerberg EW, Marquet RL, Jeekel H, Bonjer HJ. Effects of carbon dioxide pneumoperitoneum, air pneumoperitoneum, and gasless laparoscopy on body weight and tumor growth. *Arch Surg* 1998; **133**: 652-656 [PMID: 9637466 DOI: 10.1001/archsurg.133.6.652]
- Joris JL, Hinue VL, Laurent PE, Desai CJ, Lamy ML. Pulmonary function and pain after gastropasty performed via laparotomy or laparoscopy in morbidly obese patients. *Br J Anaesth* 1998; **80**: 283-288 [PMID: 9623424 DOI: 10.1093/bja/80.3.283]
- Chandler JG, Corson SL, Way LW. Three spectra of laparoscopic entry access injuries. *J Am Coll Surg* 2001; **192**: 478-490; discussion 490-491 [PMID: 11294405 DOI: 10.1016/S1072-7515(01)00820-1]
- Magrina JF. Complications of laparoscopic surgery. *Clin Obstet Gynecol* 2002; **45**: 469-480 [PMID: 12048405 DOI: 10.1097/00003081-200206000-00018]
- Ahmad G, O'Flynn H, Duffy JM, Phillips K, Watson A. Laparoscopic entry techniques. *Cochrane Database Syst Rev* 2012; **2**: CD006583 [PMID: 22336819 DOI: 10.1002/14651858.CD006583.pub3]
- Jiang X, Anderson C, Schnatz PF. The safety of direct trocar versus Veress needle for laparoscopic entry: a meta-analysis of randomized clinical trials. *J Laparoendosc Adv Surg Tech A* 2012; **22**: 362-370 [PMID: 22423957 DOI: 10.1089/lap.2011.0432]
- Kirchhoff P, Dincler S, Buchmann P. A multivariate analysis of potential risk factors for intra- and postoperative complications in 1316 elective laparoscopic colorectal procedures. *Ann Surg* 2008; **248**: 259-265 [PMID: 18650636 DOI: 10.1097/SLA.0b013e31817bbe3a]
- Jansen FW, Kolkman W, Bakum EA, de Kroon CD, Trimbos-Kemper TC, Trimbos JB. Complications of laparoscopy: an inquiry about closed- versus open-entry technique. *Am J Obstet Gynecol* 2004; **190**: 634-638 [PMID: 15041992 DOI: 10.1016/j.ajog.2003.09.035]
- Bhoyrul S, Vierra MA, Nezhat CR, Krummel TM, Way LW. Trocar injuries in laparoscopic surgery. *J Am Coll Surg* 2001; **192**: 677-683 [PMID: 11400960 DOI: 10.1016/S1072-7515(01)00913-9]
- Chapron C, Pierre F, Querleu D, Dubuisson JB. Complications of laparoscopy in gynecology. *Gynecol Obstet Fertil* 2001; **29**: 605-612 [PMID: 11680949 DOI: 10.1016/S1297-9589(01)00193-X]
- Cadeddu JA, Wolfe JS, Nakada S, Chen R, Shalhav A, Bishoff JT, Hamilton B, Schulam PG, Dunn M, Hoenig D, Fabrizio M, Hedican S, Averch TD. Complications of laparoscopic procedures after concentrated training in urological laparoscopy. *J Urol* 2001; **166**: 2109-2111 [PMID: 11696716 DOI: 10.1097/00005392-200112000-00021]
- Birkmeyer JD, Stukel TA, Siewers AE, Goodney PP, Wennberg DE, Lucas FL. Surgeon volume and operative mortality in the United States. *N Engl J Med* 2003; **349**: 2117-2127 [PMID: 14645640 DOI: 10.1056/NEJMsa035205]
- See WA, Cooper CS, Fisher RJ. Predictors of laparoscopic complications after formal training in laparoscopic surgery. *JAMA* 1993; **270**: 2689-2692 [PMID: 8133586 DOI: 10.1001/jama.1993.03510220045032]
- Wright JD, Hershman DL, Burke WM, Lu YS, Neugut AI, Lewin SN, Herzog TJ. Influence of surgical volume on outcome for laparoscopic hysterectomy for endometrial cancer. *Ann Surg Oncol* 2012; **19**: 948-958 [PMID: 21989660 DOI: 10.1245/s10434-011-2090-8]
- Nordestgaard AG, Bodily KC, Osborne RW, Buttorff JD. Major vascular injuries during laparoscopic procedures. *Am J Surg* 1995; **169**: 543-545 [PMID: 7747836 DOI: 10.1016/S0002-9610(99)80214-1]
- Ahmad G, Duffy JM, Phillips K, Watson A. Laparoscopic entry techniques. *Cochrane Database Syst Rev* 2008; **(2)**: CD006583 [PMID: 18425957 DOI: 10.1002/14651858.CD006583.pub2]
- Peterson HB, Hulka JF, Phillips JM. American Association of Gynecologic Laparoscopists' 1988 membership survey on operative laparoscopy. *J Reprod Med* 1990; **35**: 587-589 [PMID: 2141640]
- Riedel HH, Lehmann-Willenbrock E, Conrad P, Semm K. German pelviscopic statistics for the years 1978-1982. *Endoscopy* 1986; **18**: 219-222 [PMID: 2947799 DOI: 10.1055/s-2007-1018383]
- Yuzpe AA. Pneumoperitoneum needle and trocar injuries in laparoscopy. A survey on possible contributing factors and prevention. *J Reprod Med* 1990; **35**: 485-490 [PMID: 2141083]
- van der Voort M, Heijnsdijk EA, Gouma DJ. Bowel injury as a complication of laparoscopy. *Br J Obstet Gynaecol* 2004; **91**: 1253-1258 [PMID: 15376204 DOI: 10.1002/bjs.4716]
- Levy BS, Soderstrom RM, Dail DH. Bowel injuries during laparoscopy. Gross anatomy and histology. *J Reprod Med* 1985; **30**: 168-172 [PMID: 3158738]
- Sigman HH, Fried GM, Garzon J, Hinchey EJ, Wexler MJ, Meakins JL, Barkun JS. Risks of blind versus open approach to celiotomy for laparoscopic surgery. *Surg Laparosc Endosc* 1993; **3**: 296-299 [PMID: 8269247]
- Jansen FW, Kapiteyn K, Trimbos-Kemper T, Hermans J, Trimbos JB. Complications of laparoscopy: a prospective multicentre observational study. *Br J Obstet Gynaecol* 1997; **104**: 595-600 [PMID: 9166204 DOI: 10.1111/j.1471-0528.1997.tb11539.x]
- Härkki-Siren P, Sjöberg J, Kurki T. Major complications of laparoscopy: a follow-up Finnish study. *Obstet Gynecol* 1999; **94**: 94-98 [PMID: 10389725 DOI: 10.1016/S0029-7844(98)00566-3]
- Brosens I, Gordon A. Bowel injuries during gynaecological laparoscopy: a multinational survey. *Gynaecol Endosc* 2001; **10**: 141-145 [DOI: 10.1046/j.1365-2508.2001.00432.x]
- Ozdemir A, Gungorduk K, Ülker K, Yasar L, Ertas IE, Gokcu M, Solmaz U, Sanci M. Umbilical stalk elevation technique for safer Veress needle insertion in obese patients: a case-



- control study. *Eur J Obstet Gynecol Reprod Biol* 2014; **180**: 168-171 [PMID: 25027266 DOI: 10.1016/j.ejogrb.2014.06.012]
- 34 **Jadoul P**, Donnez J. Complications of laparoscopic surgery in gynecology. In: Donnez J. Atlas of operative laparoscopy and hysteroscopy. 3rd ed. Oxon: Informa Healthcare, 2007: 425-449
- 35 **Bonjer HJ**, Hazebroek EJ, Kazemier G, Giuffrida MC, Meijer WS, Lange JF. Open versus closed establishment of pneumoperitoneum in laparoscopic surgery. *Br J Surg* 1997; **84**: 599-602 [PMID: 9171741 DOI: 10.1002/bjs.1800840506]
- 36 **Bateman BG**, Kolp LA, Hoeger K. Complications of laparoscopy--operative and diagnostic. *Fertil Steril* 1996; **66**: 30-35 [PMID: 8752607]
- 37 **Ülker K**. Keyless Abdominal Rope-lifting Surgery (KARS). *Surgery: Current Research* 2013; **S12**: 2-5 [DOI: 10.4172/2161-1076.S12-007]
- 38 **Ülker K**, Ersöz M, Hüseyinoğlu Ü. Management of a giant ovarian cyst by keyless abdominal rope-lifting surgery (KARS). *Kafkas J Med Sci* 2011; **1**: 25-29 [DOI: 10.5505/kjms.2011.21931]
- 39 **Ülker K**, Hüseyinoğlu U. Comparison of tubal sterilization procedures performed by keyless abdominal rope-lifting surgery and conventional CO2 laparoscopy: a case controlled clinical study. *ScientificWorldJournal* 2013; **2013**: 963615 [PMID: 24453932 DOI: 10.1155/2013/963615]
- 40 **Ülker K**, Hüseyinoğlu Ü, Kılıç N. Management of benign ovarian cysts by a novel, gasless, single-incision laparoscopic technique: keyless abdominal rope-lifting surgery (KARS). *Surg Endosc* 2013; **27**: 189-198 [PMID: 22733196 DOI: 10.1007/s00464-012-2419-9]
- 41 **Rosen DM**, Lam AM, Chapman M, Carlton M, Cario GM. Methods of creating pneumoperitoneum: a review of techniques and complications. *Obstet Gynecol Surv* 1998; **53**: 167-174 [PMID: 9513987 DOI: 10.1097/00006254-199803000-00022]
- 42 **Brummer TH**, Seppälä TT, Härkki PS. National learning curve for laparoscopic hysterectomy and trends in hysterectomy in Finland 2000-2005. *Hum Reprod* 2008; **23**: 840-845 [PMID: 18238905 DOI: 10.1093/humrep/den006]
- 43 **Lu S**, Xiang J, Qing C, Jin S, Liao Z, Shi J. Effect of necrotic tissue on progressive injury in deep partial thickness burn wounds. *Chin Med J (Engl)* 2002; **115**: 323-325 [PMID: 11940355]
- 44 **Sutton PA**, Awad S, Perkins AC, Lobo DN. Comparison of lateral thermal spread using monopolar and bipolar diathermy, the Harmonic Scalpel and the Ligasure. *Br J Surg* 2010; **97**: 428-433 [PMID: 20101674 DOI: 10.1002/bjs.6901]
- 45 **Landman J**, Kerbl K, Rehman J, Andreoni C, Humphrey PA, Collyer W, Olweny E, Sundaram C, Clayman RV. Evaluation of a vessel sealing system, bipolar electrosurgery, harmonic scalpel, titanium clips, endoscopic gastrointestinal anastomosis vascular staples and sutures for arterial and venous ligation in a porcine model. *J Urol* 2003; **169**: 697-700 [PMID: 12544345 DOI: 10.1097/01.ju.0000045160.87700.32]
- 46 **Hefermehl LJ**, Largo RA, Hermanns T, Poyet C, Sulser T, Eberli D. Lateral temperature spread of monopolar, bipolar and ultrasonic instruments for robot-assisted laparoscopic surgery. *BJU Int* 2014; **114**: 245-252 [PMID: 24127773 DOI: 10.1111/bju.12498]
- 47 **Phillips CK**, Hruby GW, Durak E, Lehman DS, Humphrey PA, Mansukhani MM, Landman J. Tissue response to surgical energy devices. *Urology* 2008; **71**: 744-748 [PMID: 18289646 DOI: 10.1016/j.urology.2007.11.035]
- 48 **Campbell PA**, Cresswell AB, Frank TG, Cuschieri A. Real-time thermography during energized vessel sealing and dissection. *Surg Endosc* 2003; **17**: 1640-1645 [PMID: 12874690 DOI: 10.1007/s00464-002-8781-2]
- 49 **LeBlanc KA**. Laparoscopic incisional and ventral hernia repair: complications-how to avoid and handle. *Hernia* 2004; **8**: 323-331 [PMID: 15235939 DOI: 10.1007/s10029-004-0250-5]
- 50 **Nezhat C**, Nezhat F, Nezhat C. Overview of complications. In: Nezhat C, Nezhat F, Nezhat C. Nezhat's operative gynecologic laparoscopy and hysteroscopy. New York: Cambridge University Press, 2008: 582-600 [DOI: 10.1017/CBO9780511547362.027]
- 51 **Nezhat C**, Nezhat F, Pennington E. Laparoscopic treatment of infiltrative rectosigmoid colon and rectovaginal septum endometriosis by the technique of videolaparoscopy and the CO2 laser. *Br J Obstet Gynaecol* 1992; **99**: 664-667 [PMID: 1390472 DOI: 10.1111/j.1471-0528.1992.tb13851.x]
- 52 **Redwine DB**. Laparoscopic en bloc resection for treatment of the obliterated cul-de-sac in endometriosis. *J Reprod Med* 1992; **37**: 695-698 [PMID: 1432985]
- 53 **Mohr C**, Nezhat FR, Nezhat CH, Seidman DS, Nezhat CR. Fertility considerations in laparoscopic treatment of infiltrative bowel endometriosis. *JSLs* 2005; **9**: 16-24 [PMID: 15791964]
- 54 **Ülker K**, Aksoy Ö, Hüseyinoğlu Ü, Ermutlu CS, Sülü B, Kılıç E. Rectal Catheterization for the Diagnosis of Iatrogenic Descending Colon Injuries During CO2 Laparoscopy: An Experimental Study. *Kafkas Üniversitesi Veteriner Fakültesi Dergisi* 2013; **19**: A111-A116 [DOI: 10.9775/kvfd.2012.8118]
- 55 **Thompson BH**, Wheeler CR. Gastrointestinal complications of laparoscopy sterilization. *Obstet Gynecol* 1973; **41**: 669-676 [PMID: 4266773]
- 56 **Kirkpatrick JR**, Rajpal SG. The injured colon: therapeutic considerations. *Am J Surg* 1975; **129**: 187-191 [PMID: 1119679 DOI: 10.1016/0002-9610(75)90296-2]

**P- Reviewer:** Agresta F, Sandblom G, Sonoda K

**S- Editor:** Tian YL **L- Editor:** A **E- Editor:** Wu HL



## Aetiology of idiopathic granulomatous mastitis

Fatih Altintoprak, Taner Kivilcim, Orhan Veli Ozkan

Fatih Altintoprak, Orhan Veli Ozkan, Department of General Surgery, Sakarya University Faculty of Medicine, 54100 Sakarya, Turkey

Taner Kivilcim, Department of General Surgery, Sakarya University Research and Educational Hospital, 54100 Sakarya, Turkey

**Author contributions:** Altintoprak F and Kivilcim T contributed equally to this work and generated the figures and wrote the manuscript; Ozkan OV designed the aim of the editorial and wrote the manuscript.

**Correspondence to:** Orhan Veli Ozkan, MD, Associate Professor, Department of General Surgery, Faculty of Medicine, Sakarya University, Adnan Menderes Caddesi, Saglik Sokak No. 193, 54100 Sakarya, Turkey. [veliorhan@hotmail.com](mailto:veliorhan@hotmail.com)  
 Telephone: +90-532-3417440 Fax: +90-264-255210

Received: May 1, 2014 Revised: July 7, 2014

Accepted: October 1, 2014

Published online: December 16, 2014

### Abstract

Idiopathic granulomatous mastitis is a rare chronic inflammatory lesion of the breast that can clinically and radiographically mimic breast carcinoma. The most common clinical presentation is an unilateral, discrete breast mass, nipple retraction and even a sinus formation often associated with an inflammation of the overlying skin. The etiology of idiopathic granulomatous mastitis is still obscure. Its treatment remains controversial. The cause may be the autoimmune process, infection, a chemical reaction associated with oral contraceptive pills, or even lactation. Various factors, including hormonal imbalance, autoimmunity, unknown microbiological agents, smoking and  $\alpha$  1-antitrypsin deficiency have been suggested to play a role in disease aetiology. In this review, causing factors in the aetiology of idiopathic granulomatous mastitis are reviewed in detail.

© 2014 Baishideng Publishing Group Inc. All rights reserved.

**Key words:** Mastitis; Granulomatous mastitis; Idiopathic granulomatous mastitis; Granulomatous lobular mastitis; Inflammation

**Core tip:** Aetiology of idiopathic granulomatous mastitis has not been fully elucidated. In this article, possible aetiological factors mentioned in the literature are discussed in detail. Additionally, ethnicity factor which is briefly mentioned previously in the literature are detailed.

Altintoprak F, Kivilcim T, Ozkan OV. Aetiology of idiopathic granulomatous mastitis. *World J Clin Cases* 2014; 2(12): 852-858  
 Available from: URL: <http://www.wjgnet.com/2307-8960/full/v2/i12/852.htm> DOI: <http://dx.doi.org/10.12998/wjcc.v2.i12.852>

### INTRODUCTION

Inflammatory events are frequently seen in the breast, and its can appear in a manner that clinically mimics malignancy, but they are usually benign. In addition, aetiological factors (trauma and breast-feeding) are generally identified after a detailed anamnesis. In cases where the aetiology is defined, it is easy to practice treatment algorithms starting with “limiting or removing the aetiological factor”. In cases where the aetiological factor is unknown, the diagnosis, differential diagnosis and treatment steps can become more complicated.

Since idiopathic granulomatous mastitis (IGM) was defined as a distinct clinical entity among benign breast diseases in 1972<sup>[1]</sup>, it has attracted clinicians’ attention, particularly those interested in breast diseases.

The differential diagnosis of IGM with breast cancer only clinically without histopathological examination is almost impossible. Therefore, presence of some complaints which can be seen in both disease (like palpable breast mass, nipple retraction, nipple skin hyperemia, erosion and fistula formation) would be more accurate to think of the first diagnosis of malignancy. In histopathological examination, presence of granulomatous inflammation and no malignancy is require performing other tests for the aetiology. Failure various factors which may result in granulomatous reaction in the breast (tuberculosis, certain

**Table 1 Causes for granulomatous inflammatory reaction in the breasts**

Infectious	Mycobacterium tuberculosis Blastomycosis Cryptococcosis Histoplasmosis Actinomycosis Filarial infection Corynebacterium
Autoimmune process	Wegener granulomatosis Giant cell arteritis Foreign body reaction
Duct ectasis	Plasma cell mastitis Subareolar granuloma Periductal mastitis
Diabetes mellitus	
Sarcoidosis	
Fat necrosis	
Idiopathic	

parasitic and fungal infections, Wegener's granulomatosis, giant-cell arthritis, polyarthritis nodosum, sarcoidosis, foreign body reaction, *etc.*) will support the diagnosis of IGM.

In this article, we discuss factors that may play a role in the aetiology of IGM.

## DEFINITION

Idiopathic granulomatous mastitis (GM) is a rare, benign, chronic, inflammatory lesion of the breast, and its aetiology has not been fully elucidated. It was defined for the first time in 1972 by Kessler and Woollock and was described in detail in 1977 with a five-case series by Cohen<sup>[1,2]</sup>.

GM is generally divided into two main groups of specific and non-specific. The term "specific GM" refers to conditions for which the aetiological factor can be identified, whether an isolated inflammatory event only applies to the breast, or the breast is involved in a systemic inflammatory event. Nonspecific GM is also known as idiopathic granulomatous mastitis or granulomatous lobular mastitis, which generally refers to conditions that can lead to a granulomatous reaction in the breast or conditions for which the aetiological factors cannot be determined.

Chronic granulomatous inflammation constitutes 24% of all inflammatory events of the breast that are histopathologically defined<sup>[3]</sup>. All factors that lead to granulomatous inflammation in the breasts are presented in Table 1<sup>[4]</sup>.

## GENERAL REMINDERS

While IGM mostly emerges in young-middle age women (third and fourth decades), the age range that has been reported in the literature (11-83 years) is considerably wider<sup>[5-7]</sup>. IGM is usually seen within a couple of years after giving birth, and the majority of patients have a history of at least one live birth and breast feeding<sup>[8]</sup>. In con-

trast, specific GM is frequently seen in Asian and African countries and can be detected at any age<sup>[9]</sup>.

IGM may present with clinical findings that mimic the two endpoints of breast diseases such as breast abscess and breast cancer<sup>[8]</sup>. A palpable mass in the breast is the most common complaint, but nipple retraction, hyperaemia in breast skin, oedema, ulceration and fistule development during the chronic period are also potential complaints<sup>[9]</sup>. Systemic symptoms such as fever are generally not present<sup>[6]</sup>. While the incidence is the same in both breasts, the lesion is usually unilateral and cases with bilateral involvement have been reported only rarely<sup>[8,10,11]</sup>.

## PATHOGENESIS

The pathogenesis of IGM is not exactly known, but different steps occur in the disease pathogenesis. One of these steps is nonspecific lobulitis, which involves multiple lobules, and causes reactive lymphoplasmocytic infiltration. A granulomatous formation with central suppurative necrosis occasionally occurs because of lobule deformation. Abscesses develop because of an increase in the number of these foci<sup>[12]</sup>.

Some studies have indicated the similarity between IGM and granulomatous inflammation of the testicles or the thyroid gland when IGM was defined for the first time<sup>[1]</sup>. Considering that mechanical factors are responsible for the formation of granulomas of the thyroid gland in multifocal granulomatous thyroiditis (palpation thyroiditis), the possibility that trauma represents another stage in IGM pathogenesis should not be disregarded<sup>[12]</sup>.

A process starting with non-puerperal secretion has been proposed as the most rational theory for the pathogenesis of IGM. A hormonal imbalance due to a deviation in the oestrogen-progesterone ratio or hyperprolactinemia is believed to cause this secretion and inflammation. Ductal ectasia occurs due to the intra-ductal accumulation of a protein-rich secretion. Permanent inflammation occurs following perforation of the ducti and contact between the secretion and stromal cells. The accumulation of secretion, ductal ectasia, galactoporitis (intraductal inflammation) and chronic GM are steps in the pathophysiological process. Autoimmunity against a secretion that is extravasated from the lobules is also considered to cause this event<sup>[6,13,14]</sup>.

## Aetiology

The aetiology of IGM remains unclear. Various factors, including hormonal imbalance, autoimmunity, unknown microbiological agents, smoking and  $\alpha$ 1-antitrypsin deficiency have been suggested to play a role in disease aetiology.

### $\alpha$ 1-antitrypsin deficiency

$\alpha$ 1-antitrypsin (AAT) is a glycoprotein synthesised by hepatic cells. Similar to anti-thrombin 3, ovalalbumin and thyroid-binding globulin, AAT is a member of the serine-protease inhibitor family. Its primary function is to

prevent the destructive effects of proteases secreted from activated neutrophils (proteinase 3, elastin and cathepsin G). Because AAT level is elevated during inflammation, it is also accepted as an acute phase reactant. Deficiency in AAT leads primarily to lung and liver pathologies<sup>[15]</sup>. In their case presentation in 2001, Schelfout *et al*<sup>[16]</sup> demonstrated AAT deficiency in a 37-year-old female patient diagnosed with IGM. According to that study, the authors did not determine any other aetiological factors, and suggested that AAT deficiency could be the aetiological factor; however, further studies were not performed.

### Oral contraceptives

The secretion theory has an important place in the pathophysiology of IGM. Oral contraceptives (OCS) have been considered a potential aetiological factor, as they increase breast secretion<sup>[12]</sup>. However, a significant association between OCS and IGM has not been determined. Oran *et al*<sup>[17]</sup> found 10 cases (10/46; 21.7%) that had a history of OCS use; Gurleyik *et al*<sup>[18]</sup> found eight cases (8/19, 42.1%) that had a history of OCS use; and Al-Khaffaf *et al*<sup>[19]</sup> found five cases (5/18, 27.7%) that had a history of OCS use. In contrast, Baslaim *et al*<sup>[20]</sup> reported that none of 20 patients had a history of OCS use. Bani-Hani *et al*<sup>[7]</sup> found that only two of 24 cases (8.3%) had a history of OCS use, and Asoglu *et al*<sup>[21]</sup> found that only two of 18 cases (11.1%) had a history of OCS use. In conclusion, the association between IGM and OCS use has been reported to range between 0%-42%.

### Gestation, birth, and breast-feeding

Given that IGM is usually detected in women < 50 years of age, and frequently involves a recent history of birth or breast-feeding, these factors have been considered in the disease aetiology. Hormonal alterations during these processes, secretion, and inflammation have an effect on disease pathophysiology<sup>[19,21-28]</sup>. Bani-Hani *et al*<sup>[7]</sup> carried out a study on 24 cases, and found that four had active gestation, four had a history of birth and breast-feeding within 6 months and only two cases did not have a history of gestation. According to a study by Baslaim *et al*<sup>[20]</sup>, all cases had a history of gestation and breast-feeding, whereas two cases were actively breast-feeding, and one case had an active gestation. Similarly, Gurleyik *et al*<sup>[18]</sup> determined that four of 19 cases had a history of active breast-feeding, and the remaining 15 cases had a history of breast-feeding. Moreover, Oran *et al*<sup>[17]</sup> reported that only three of 46 cases were nulliparous. Gautier *et al*<sup>[14]</sup> conducted a case series study on 11 cases and emphasised that all cases except one male case had a history of birth and lactation within the past 5 years.

While almost all studies reported a history of parity, various studies have failed to explain the timing of the parity. It is expected that cases with IGM, which is a reproductive age disorder, have a history of gestation and breast feeding, as gestation occurs between the ages of 20-40 years. In addition to the male case, cases with a wide age range (11-83 years) in the literature make it

difficult to hold only gestation, birth and breast feeding responsible for the aetiology of IGM<sup>[4,5,14]</sup>.

### Hyperprolactinemia

Considering the secretion theory, hyperprolactinemia has also been considered responsible for the pathogenesis of IGM, similar to other hormonal disorders<sup>[12,29,30]</sup>. In a case presentation in 1984, Rowe<sup>[29]</sup> determined co-morbid prolactinoma in an IGM case. However, future studies did not provide prolactin levels in detail. Bani-Hani *et al*<sup>[7]</sup> analysed prolactin levels in seven of 24 cases and found elevated prolactin levels in one patient (4.1%). Erhan *et al*<sup>[10]</sup> carried out a case-series study on 18 women and reported recurrence in three cases (16%), and identified hyperprolactinemia in two of these patients.

### Smoking

While smoking is among the factors considered in the disease aetiology, a definitive association between smoking and IGM has not yet been established. According to a study by Asoglu *et al*<sup>[21]</sup>, 14 of 18 cases (77.8%) had a history of smoking, whereas Baslaim *et al*<sup>[20]</sup> reported that none of their 20 cases had a history of smoking. In addition, the smoking rate was 34.8% according to Oran *et al*<sup>[17]</sup>, 16.7% according to Al-Khaffaf *et al*<sup>[19]</sup>, and 50% according to Ozel *et al*<sup>[31]</sup>.

### Autoimmunity

A hypothesis that suggests an immunological basis for IGM has received considerable attention. Literature findings, including a good response to steroid and immunosuppressive treatment, patients who had recurrence after surgery showing a good response to steroid treatment, patients with extramammary involvement (such as erythema nodosum, or arthritis) and the demonstration of T-lymphocyte dominance in immunohistochemical studies support the autoimmunity hypothesis<sup>[1,2,11-14,32]</sup>. Ozel *et al*<sup>[31]</sup> conducted a study on eight cases and found that six were positive for rheumatoid factor (RF), and two were positive for anti-nuclear antibody (ANA) and anti-double stranded DNA (anti-dsDNA). In that study, surgery was the preferred treatment option for all patients, and the authors reported recurrence in two patients who were RF-, ANA- and anti-dsDNA-positive, but obtained a positive response after steroid treatment. Erhan *et al*<sup>[10]</sup> conducted an immunohistochemical evaluation, and determined that 14 of 18 cases had T-cell dominance, and this finding was interpreted as an autoimmune pathophysiological outcome that progressed with reactive T-cell-mediated inflammation and centrilobular granulomas against ductal damage. Furthermore, two IGM cases with erythema nodosum, one IGM case with erythema nodosum and arthritis, one IGM case with Weber-Christian disease and one IGM case with Sjögren's syndrome have been reported in the literature<sup>[33-36]</sup>. However, cases with a co-morbid autoimmune disorder constitute only a minor fraction of all cases. In contrast to these studies that support the autoimmune hypothesis, classical serological tests, which are used for au-



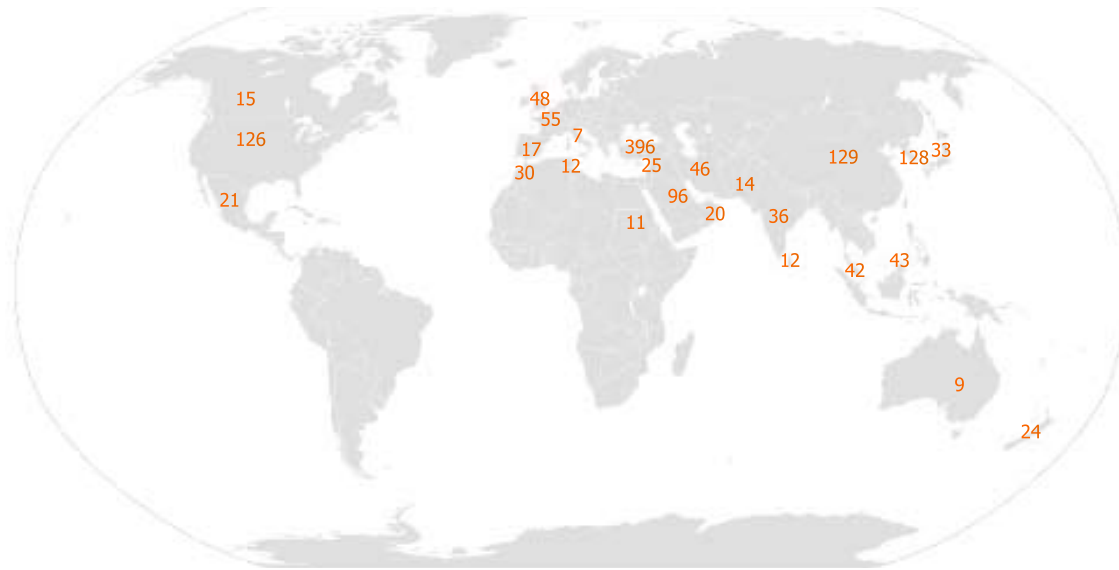


Figure 1 The distribution of idiopathic granulomatous mastitis cases that were reported in PubMed since 1995 according to country.

to immune disorders such as ANA and RF, reveal different results in patients with IGM. Asoglu *et al.*<sup>[21]</sup> conducted a case-series study on 18 cases and determined that all cases were negative for ANA and RF. We conducted a study in our clinic to investigate the autoimmunity hypothesis for IGM aetiology, and evaluated ANA and extractable nuclear antibody levels in 26 cases, but we did not obtain results to support the autoimmunity hypothesis<sup>[37]</sup>.

### Microbiological agents

The normal endogenous bacteria flora of the breast is similar to the skin flora. Dominant organisms include coagulase-negative *streptococci*, *Propionibacterium sp.* and *Corynebacterium sp.* These findings have been proven through nipple discharge and breast tissue cultures that were collected during mammoplasty<sup>[38]</sup>. These bacteria are considered to go deeper into the breast tissue *via* the ductal system<sup>[13]</sup>.

*Corynebacteria* cause mastitis in livestock. However, these bacteria are not expected pathogens in humans<sup>[13]</sup>. These bacteria became the centre of attention in 2003, with detection of corynebacteria in 34 IGM cases by Taylor *et al.*<sup>[39]</sup>.

*Corynebacteria* are Gram-positive bacteria and members of the skin flora. It is hard to distinguish whether these organisms cause infection, colonisation or contamination<sup>[40]</sup>. Despite the difficulty in distinguishing outcome, it is significant to detect purulent matter in an abscess or > 10<sup>4</sup> CFU/mL dominant *Corynebacterium sp.*<sup>[41]</sup>. According to a study by Funke *et al.*<sup>[42]</sup>, these bacteria could be a possible factor if: (1) a Gram-positive bacillus accompanying polymorphonuclear leukocytes is present; or (2) a *Corynebacterium sp.* is detected in a tissue that is expected to be sterile under normal conditions.

Four different *Corynebacterium* species have been detected in IGM cases. *Corynebacterium kroppenstedtii* (*C. kroppenstedtii*) is the most frequently observed species, and

is different from other corynebacteria due to its lipophilic nature and positive esculin test<sup>[39,40]</sup>.

Taylor *et al.*<sup>[39]</sup> conducted a study of 62 patients who were histologically diagnosed with GM, and detected *Corynebacterium* in 34 patients (54.8%). A comparison among the remaining 28 cases showed that fever and neutrophilia were more frequently observed in cases that were bacteria-positive, and they had more frequent fistule formation. *C. kroppenstedtii* was the most frequently observed species (14 patients; 41.1%) in that study.

Paviour *et al.*<sup>[40]</sup> isolated *Corynebacterium* from breast tissue in 24 cases, carried out a histopathological evaluation in 12 of these cases and diagnosed nine cases with IGM. Similarly, *C. kroppenstedtii* was the most frequently isolated species in that study; *C. amycolatum* and *C. tuberculoostearicum* were other identified species. In that study, a 3-week intravenous penicillin treatment was tested on one patient; however, when the expected benefit was not observed, the treatment was switched to doxycycline (100 mg, oral), which has better fat solubility. The authors reported that there was no need for surgery after this treatment.

Case presentations in which *Corynebacterium sp.* have been detected are also present in the literature<sup>[41,43,44]</sup>. A specific species was not reported in two of these studies, whereas Ang *et al.*<sup>[41]</sup> reported that they isolated *C. accolens*. All three studies stated that antibiotherapy was effective for treatment.

In our clinic, we carried out a study on 45 patients with IGM and 34 bacteria using a universal DNA primer, but we did not detect positivity for any microbiological agent (unpublished data).

### Ethnicity

During our search of GM in the PubMed database (1995-2014), we searched the terms “idiopathic granulomatous mastitis”, “granulomatous lobular mastitis” and

**Table 2** The distribution of idiopathic granulomatous mastitis cases that were reported in PubMed since 1995 according to country

> 100 cases	20-100 cases	5-20 cases	< 5 cases
Turkey: > 200	Saudi Arabia: 96	Spain:17	Netherlands: 4
China: 129	France: 55	Canada: 15	Israel: 4
South Korea: 128	United Kingdom: 48	Pakistan: 14	Austria: 3
United States: 126	Iran: 46	Sri Lanka: 12	Belgium: 3
	Brunei: 43	Tunis: 12	Taiwan: 2
	Malaysia: 42	Sudan: 11	Caribbean: 2
	India: 36	Australia: 9	Peru: 1
	Japan: 33	Italy: 7	Nigeria: 1
	Morocco:30		Kuwait: 1
	Jordan: 25		Jamaica: 1
	New Zealand: 24		Greece: 1
	Mexico: 21		Norway: 1
	Oman: 20		

“granulomatous mastitis” and found approximately 200 articles. We hypothesised that an evaluation based on the location of the centres in which the authors worked would provide a rough estimate of the distribution of the cases. While most of these studies were case presentations, we found that larger case series frequently originated from the Mediterranean region and the developing countries in Asia. Some authors have considered that undiagnosed tuberculosis cases might lead to GM<sup>[15,45-48]</sup>.

According to our search on the PubMed database, the highest number of cases has been reported in Turkey (> 200 cases). This is followed by China (129 cases) and South Korea (128 cases). France had the highest number of cases (55 cases) among European countries, and no other country exceeded 50 cases. In contrast, we found 126 cases in the United States. The total number of cases recorded per country is presented in Table 2 and Figure 1.

According to a Centers for Disease Control and Prevention report, which was published in Morbidity and Mortality Weekly Report in 2009, seven cases were detected in Indiana between 2006 and 2008, and six of these cases were born in Mexico and had a Hispanic. According to the report, this series was the most comprehensive case series reported in the United States<sup>[49]</sup>. However, Larsen *et al.* published a study on 54 cases in the same year, but the authors did not evaluate ethnicity<sup>[50]</sup>. Gautier *et al.*<sup>[15]</sup> carried out a study on 11 cases in Canada and reported that three cases were French, two cases were Canadian of French origin, two cases were Canadian of British origin, two cases were Latin American and one case was Russian. Furthermore, Omranipour *et al.*<sup>[50]</sup> reported a series of 43 cases in Iran, Bani-Hani *et al.*<sup>[7]</sup> reported a series of 24 cases in Jordan and Baslaim *et al.*<sup>[20]</sup> reported a series of 20 cases in Saudi Arabia. In Turkey, different IGM series have been reported by Asoglu *et al.*<sup>[21]</sup> (18 cases), Ozel *et al.*<sup>[31]</sup> (8 cases), Gurleyik *et al.*<sup>[18]</sup>, Oran *et al.*<sup>[17]</sup> (46 cases) and Altintoprak *et al.*<sup>[37]</sup> (26 cases). These findings indicate that a previous comprehensive evaluation of ethnicity does not exist, and that more elaborate studies on this topic are required.

## CONCLUSION

In conclusion, while several factors have been considered as potential aetiological factors, these factors are not ‘the primary aetiological factors, but rather “secondary factors” that can accompany the process once the primary factor triggers the event, or contribute to the acceleration’ of the ongoing process. Given that: (1) a higher number of cases are being reported from certain geographical locations; and (2) patients respond positively to steroid treatment, we believe that the “ethnicity and autoimmunity hypotheses” are the major subjects to focus on. It is possible that our failure in searching for a single aetiological factor will become more evident as details are elucidated; however, the disease is likely to continue to carry the “idiopathic” prefix for a long time.

## REFERENCES

- Kessler E, Wolloch Y. Granulomatous mastitis: a lesion clinically simulating carcinoma. *Am J Clin Pathol* 1972; **58**: 642-646 [PMID: 4674439]
- Cohen C. Granulomatous mastitis. A review of 5 cases. *S Afr Med J* 1977; **52**: 14-16 [PMID: 560723]
- Ozmen V, Cantürk Z, Celik V, Güler N, Kapkaç M, Koyuncu A, Müslümanoğlu M, Utkan Z. Breast Disease. Federation of Breast Diseases Society, Ankara: Güneş Medical Publishing, 2012: 55-65
- Bakaris S, Yuksel M, Ciragil P, Guven MA, Ezberci F, Bulbuloglu E. Granulomatous mastitis including breast tuberculosis and idiopathic lobular granulomatous mastitis. *Can J Surg* 2006; **49**: 427-430 [PMID: 17234073]
- Akbulut S, Yilmaz D, Bakir S. Methotrexate in the management of idiopathic granulomatous mastitis: review of 108 published cases and report of four cases. *Breast J* 2011; **17**: 661-668 [PMID: 21951547 DOI: 10.1111/j.1524-4741.2011.01162.x]
- Tuli R, O'Hara BJ, Hines J, Rosenberg AL. Idiopathic granulomatous mastitis masquerading as carcinoma of the breast: a case report and review of the literature. *Int Semin Surg Oncol* 2007; **4**: 21 [PMID: 17662130]
- Bani-Hani KE, Yaghan RJ, Matalka II, Shatnawi NJ. Idiopathic granulomatous mastitis: time to avoid unnecessary mastectomies. *Breast J* 2004; **10**: 318-322 [PMID: 15239790 DOI: 10.1111/j.1075-122X.2004.21336.x]
- Azlin AF, Ariza Z, Arni T, Hisham AN. Chronic granulomatous mastitis: diagnostic and therapeutic considerations. *World J Surg* 2003; **27**: 515-518 [PMID: 12715214 DOI: 10.1007/s00268-003-6806-1]
- Diesing D, Axt-Flidner R, Hornung D, Weiss JM, Diedrich K, Friedrich M. Granulomatous mastitis. *Arch Gynecol Obstet* 2004; **269**: 233-236 [PMID: 15205978 DOI: 10.1007/s00404-003-0561-2]
- Erhan Y, Veral A, Kara E, Ozdemir N, Kapkac M, Ozdedeli E, Yilmaz R, Koyuncu A, Erhan Y, Ozbal O. A clinicopathologic study of a rare clinical entity mimicking breast carcinoma: idiopathic granulomatous mastitis. *Breast* 2000; **9**: 52-56 [PMID: 14731585 DOI: 10.1016/j.bbr.2011.03.031]
- Tavassoli FA. Pathology of the Breast, 2nd ed. New York: McGraw-Hill, 1999: 1099-1116
- Cserni G, Szajki K. Granulomatous Lobular Mastitis Following Drug-Induced Galactorrhoea and Blunt Trauma. *Breast J* 1999; **5**: 398-403 [PMID: 11348321 DOI: 10.1046/j.1524-4741.1999.97040.x]
- Pereira FA, Mudgil AV, Macias ES, Karsif K. Idiopathic granulomatous lobular mastitis. *Int J Dermatol* 2012; **51**: 142-151 [PMID: 22250621 DOI: 10.1111/j.1365-4632.2011.05168.x]
- Gautier N, Lalonde L, Tran-Thanh D, El Khoury M, David

- J, Labelle M, Patocskai E, Trop I. Chronic granulomatous mastitis: Imaging, pathology and management. *Eur J Radiol* 2013; **82**: e165-e175 [PMID: 23200627 DOI: 10.1016/j.ejrad.2012.11.010]
- 15 **Altınbas A**, Ekiz F, Coban S, Yuksel O. Alfa 1 Antitripsin Eksikliği. *Yeni Tıp Dergisi* 2012; **29**: 138-141
  - 16 **Schelfout K**, Tjalma WA, Cooremans ID, Coeman DC, Colpaert CG, Buytaert PM. Observations of an idiopathic granulomatous mastitis. *Eur J Obstet Gynecol Reprod Biol* 2001; **97**: 260-262 [PMID: 11451563 DOI: 10.1016/S0301-2115(00)00546-7]
  - 17 **Oran EŞ**, Gürdal SÖ, Yankol Y, Öznur M, Calay Z, Tunacı M, Soybir GR. Management of idiopathic granulomatous mastitis diagnosed by core biopsy: a retrospective multicenter study. *Breast J* 2013; **19**: 411-418 [PMID: 23663101 DOI: 10.1111/tbj.12123]
  - 18 **Gurleyik G**, Aktekin A, Aker F, Karagulle H, Saglamc A. Medical and surgical treatment of idiopathic granulomatous lobular mastitis: a benign inflammatory disease mimicking invasive carcinoma. *J Breast Cancer* 2012; **15**: 119-123 [PMID: 22493638 DOI: 10.4048/jbc.2012.15.1.119]
  - 19 **Al-Khaffaf B**, Knox F, Bundred NJ. Idiopathic granulomatous mastitis: a 25-year experience. *J Am Coll Surg* 2008; **206**: 269-273 [PMID: 18222379 DOI: 10.1016/j.jamcollsurg.2007.07.041]
  - 20 **Baslaım MM**, Khayat HA, Al-Amoudi SA. Idiopathic granulomatous mastitis: a heterogeneous disease with variable clinical presentation. *World J Surg* 2007; **31**: 1677-1681 [PMID: 17541683 DOI: 10.1007/s00268-007-9116-1]
  - 21 **Asoglu O**, Ozmen V, Karanlık H, Tunaci M, Cabioglu N, Igci A, Selcuk UE, Kecer M. Feasibility of surgical management in patients with granulomatous mastitis. *Breast J* 2005; **11**: 108-114 [PMID: 15730456 DOI: 10.1111/j.1075-122X.2005.21576.x]
  - 22 **Goldberg J**, Baute L, Storey L, Park P. Granulomatous mastitis in pregnancy. *Obstet Gynecol* 2000; **96**: 813-815 [PMID: 11094217 DOI: 10.1016/S0029-7844(00)01051-6]
  - 23 **Sakurai K**, Fujisaki S, Enomoto K, Amano S, Sugitani M. Evaluation of follow-up strategies for corticosteroid therapy of idiopathic granulomatous mastitis. *Surg Today* 2011; **41**: 333-337 [PMID: 21365412 DOI: 10.1007/s00595-009-4292-2]
  - 24 **Gal-Gombos EC**, Esserman LE, Odzer SL, Weisberg S, Wilson C, Poppiti RJ. Granulomatous mastitis: diagnosis by ultrasound-guided core biopsy. *Breast J* 2001; **7**: 129-130 [PMID: 11328323 DOI: 10.1046/j.1524-4741.2001.007002129.x]
  - 25 **Han BK**, Choe YH, Park JM, Moon WK, Ko YH, Yang JH, Nam SJ. Granulomatous mastitis: mammographic and sonographic appearances. *AJR Am J Roentgenol* 1999; **173**: 317-320 [PMID: 10430126 DOI: 10.2214/ajr.173.2.10430126]
  - 26 **Jorgensen MB**, Nielsen DM. Diagnosis and treatment of granulomatous mastitis. *Am J Med* 1992; **93**: 97-101 [PMID: 1626579 DOI: 10.1016/0002-9343(92)90688-8]
  - 27 **Salam IM**, Alhomsı MF, Daniel MF, Sim AJ. Diagnosis and treatment of granulomatous mastitis. *Br J Surg* 1995; **82**: 214 [PMID: 7749695 DOI: 10.1002/bjs.1800820227]
  - 28 **Sato N**, Yamashita H, Kozaki N, Watanabe Y, Ohtsuka T, Kuroki S, Nakafusa Y, Ota M, Chijiwa K, Tanaka M. Granulomatous mastitis diagnosed and followed up by fine-needle aspiration cytology, and successfully treated by corticosteroid therapy: report of a case. *Surg Today* 1996; **26**: 730-733 [PMID: 8883249 DOI: 10.1007/BF00312095]
  - 29 **Rowe PH**. Granulomatous mastitis associated with a pituitary prolactinoma. *Br J Clin Pract* 1984; **38**: 32-34 [PMID: 6538433]
  - 30 **Going JJ**, Anderson TJ, Wilkinson S, Chetty U. Granulomatous lobular mastitis. *J Clin Pathol* 1987; **40**: 535-540 [PMID: 3584506 DOI: 10.1136/jcp.40.5.535]
  - 31 **Ozel L**, Unal A, Unal E, Kara M, Erdoğdu E, Krando O, Güneş P, Karagül H, Demiral S, Titiz Mİ. Granulomatous mastitis: is it an autoimmune disease? Diagnostic and therapeutic dilemmas. *Surg Today* 2012; **42**: 729-733 [PMID: 22068681 DOI: 10.1007/s00595-011-0046-z]
  - 32 **Coskun T**, Kara E, Kaya Y, Guler Y, Kandiloglu AR, Goktan C. Granulomatöz Mastit: Cerrahi Tedavi-Rekürrens İlişkisi. *Meme Sağlığı Dergisi* 2006; **2**: 26-30
  - 33 **Bes C**, Soy M, Vardi S, Sengul N, Yilmaz F. Erythema nodosum associated with granulomatous mastitis: report of two cases. *Rheumatol Int* 2010; **30**: 1523-1525 [PMID: 19701754 DOI: 10.1007/s00296-009-1109-y]
  - 34 **Salesi M**, Karimifar M, Salimi F, Mahzouni P. A case of granulomatous mastitis with erythema nodosum and arthritis. *Rheumatol Int* 2011; **31**: 1093-1095 [PMID: 20012050 DOI: 10.1007/s00296-009-1273-0]
  - 35 **Taniguchi Y**, Kagawa T, Ishibashi A, Horino T, Kumon Y, Terada Y. Weber-Christian disease associated with granulomatous mastitis: a variant type of Weber-Christian disease? *Mod Rheumatol* 2011; **21**: 228-231 [PMID: 20922452 DOI: 10.1007/s10165-010-0363-x]
  - 36 **Letourneux C**, Diemunsch P, Korganow AS, Akladios CY, Bellocq JP, Mathelin C. First report of granulomatous mastitis associated with Sjögren's syndrome. *World J Surg Oncol* 2013; **11**: 268 [PMID: 24112140 DOI: 10.1186/1477-7819-11-268]
  - 37 **Altintoprak F**, Karakece E, Kivilcim T, Dikicier E, Cakmak G, Celebi F, Ciftci IH. Idiopathic granulomatous mastitis: an autoimmune disease? *ScientificWorldJournal* 2013; **2013**: 148727 [PMID: 24082849 DOI: 10.1155/2013/148727]
  - 38 **Thornton JW**, Argenta LC, McClatchey KD, Marks MW. Studies on the endogenous flora of the human breast. *Ann Plast Surg* 1988; **20**: 39-42 [PMID: 3341714 DOI: 10.1097/0000-0637-198801000-00008]
  - 39 **Taylor GB**, Paviour SD, Musaad S, Jones WO, Holland DJ. A clinicopathological review of 34 cases of inflammatory breast disease showing an association between corynebacteria infection and granulomatous mastitis. *Pathology* 2003; **35**: 109-119 [PMID: 12745457]
  - 40 **Paviour S**, Musaad S, Roberts S, Taylor G, Taylor S, Shore K, Lang S, Holland D. Corynebacterium species isolated from patients with mastitis. *Clin Infect Dis* 2002; **35**: 1434-1440 [PMID: 12439810 DOI: 10.1086/344463]
  - 41 **Ang LM**, Brown H. Corynebacterium accolens isolated from breast abscess: possible association with granulomatous mastitis. *J Clin Microbiol* 2007; **45**: 1666-1668 [PMID: 17344355 DOI: 10.1128/JCM.02160-06]
  - 42 **Funke G**, von Graevenitz A, Clarridge JE, Bernard KA. Clinical microbiology of coryneform bacteria. *Clin Microbiol Rev* 1997; **10**: 125-159 [PMID: 8993861]
  - 43 **Stary CM**, Lee YS, Balfour J. Idiopathic granulomatous mastitis associated with corynebacterium sp. Infection. *Hawaii Med J* 2011; **70**: 99-101 [PMID: 21857740]
  - 44 **Mathelin C**, Riegel P, Chenard MP, Tomasetto C, Brettes JP. Granulomatous mastitis and corynebacteria: clinical and pathologic correlations. *Breast J* 2005; **11**: 357 [PMID: 16174160 DOI: 10.1111/j.1075-122X.2005.21562.x]
  - 45 **Ocal K**, Dag A, Turkmenoglu O, Kara T, Seyit H, Konca K. Granulomatous mastitis: clinical, pathological features, and management. *Breast J* 2010; **16**: 176-182 [PMID: 20030652 DOI: 10.1111/j.1524-4741.2009.00879.x]
  - 46 **Akcan A**, Akyildiz H, Deneme MA, Akgun H, Arıtas Y. Granulomatous lobular mastitis: a complex diagnostic and therapeutic problem. *World J Surg* 2006; **30**: 1403-1409 [PMID: 16847715 DOI: 10.1007/s00268-005-0476-0]
  - 47 **Al-Khawari HA**, Al-Manfouhi HA, Madda JP, Kovacs A, Sheikh M, Roberts O. Radiologic features of granulomatous mastitis. *Breast J* 2011; **17**: 645-650 [PMID: 21929558 DOI: 10.1111/j.1524-4741.2011.01154.x]
  - 48 **Centers for Disease Control and Prevention (CDC)**. Idiopathic granulomatous mastitis in Hispanic women - Indiana, 2006-2008. *MMWR Morb Mortal Wkly Rep* 2009; **58**: 1317-1321 [PMID: 19959984]
  - 49 **Hovanessian Larsen LJ**, Peyvandi B, Klipfel N, Grant E,

Iyengar G. Granulomatous lobular mastitis: imaging, diagnosis, and treatment. *AJR Am J Roentgenol* 2009; **193**: 574-581 [PMID: 19620458 DOI: 10.2214/AJR.08.1528]

50 **Omranipour R**, Mohammadi SF, Samimi P. Idiopathic

granulomatous lobular mastitis - report of 43 cases from iran; introducing a preliminary clinical practice guideline. *Breast Care (Basel)* 2013; **8**: 439-443 [PMID: 24550752 DOI: 10.1159/000357320]

**P- Reviewer:** Naito Y, Oda I, Tohda G **S- Editor:** Tian YL

**L- Editor:** A **E- Editor:** Wu HL





## Role of immunotherapy in the treatment of allergic asthma

Ayfer Yukselen, Seval Guneser Kendirli

Ayfer Yukselen, Clinic of Pediatric Allergy and Immunology, Gaziantep Children Hospital, Sehitkamil, 27310 Gaziantep, Turkey

Seval Guneser Kendirli, Division of Pediatric Allergy and Immunology, Cukurova University Faculty of Medicine, Balcali, 01150 Adana, Turkey

Author contributions: Yukselen A wrote the paper; and Kendirli SV reviewed the paper.

Correspondence to: Ayfer Yukselen, MD, Associate Professor of Pediatrics, Clinic of Pediatric Allergy and Immunology, Gaziantep Children Hospital, Sehitkamil, 27560 Gaziantep, Turkey. [ayfyukselen@gmail.com](mailto:ayfyukselen@gmail.com)

Telephone: +90-342-2200072

Received: July 27, 2014 Revised: August 27, 2014

Accepted: October 14, 2014

Published online: December 16, 2014

### Abstract

Allergen-specific immunotherapy (SIT) induces clinical and immunological tolerance as defined by persistence of clinical benefit and associated long-term immunological parameters after cessation of treatment. Although the efficacy of SIT has been shown in terms of reducing symptoms, medication consumption and ameliorating quality of life in both allergic rhinitis and asthma, there has long been some controversies about effectiveness of SIT in the treatment of allergic asthma. The type of allergen, the dose and protocol of immunotherapy, patient selection criteria, the severity and control of asthma, all are significant contributors to the power of efficacy in allergic asthma. The initiation of SIT in allergic asthma should be considered in case of coexisting of other allergic diseases such as allergic rhinitis, unacceptable adverse effects of medications, patient's preference to avoid long-term pharmacotherapy. Steroid sparing effect of SIT in allergic asthma is also an important benefit particularly in patients who have to use these drugs in high doses for a long-time. Symptomatic asthma is a risk factor for systemic reactions and asthma should be controlled at the time of administration of SIT. Both subcutaneous immunotherapy (SCIT) and sublingual immunotherapy (SLIT) have been found to

be effective in patients with allergic asthma. Although the safety profile of SLIT seems to be better than SCIT, the results of some studies and meta-analyses suggest that the efficacy of SCIT may appear better and earlier than SLIT in children with allergic asthma.

© 2014 Baishideng Publishing Group Inc. All rights reserved.

**Key words:** Asthma; Efficacy; Safety; Subcutaneous immunotherapy; Sublingual immunotherapy

**Core tip:** Allergen specific immunotherapy is the only therapeutic approach that can change the immunologic response to allergens and thus can alter the natural evolution of allergic diseases. Both subcutaneous immunotherapy (SCIT) and sublingual immunotherapy (SLIT) have been demonstrated to be beneficial in reducing of symptoms and drug intake, improving quality of life and preventing patients from possible side effects of high doses of steroids. This review examines the clinical effectiveness and safety of both SCIT and SLIT in patients with asthma by discussing recent studies.

Yukselen A, Kendirli SG. Role of immunotherapy in the treatment of allergic asthma. *World J Clin Cases* 2014; 2(12): 859-865 Available from: URL: <http://www.wjgnet.com/2307-8960/full/v2/i12/859.htm> DOI: <http://dx.doi.org/10.12998/wjcc.v2.i12.859>

### INTRODUCTION

Asthma is one of the most prevalent chronic conditions affecting roughly 300 million people in the world. It is supposed that asthma will affect an additional 100 million people by 2025<sup>[1]</sup>.

According to data of health statistics in United States, current asthma prevalence is 9.3% and 8%, in children and adults, respectively<sup>[2]</sup>. This increment in the prevalence of asthma has been accompanied by an increment in other allergic disorders like rhinitis and eczema.

Asthma is characterized by chronic inflammation,

which result in recurrent attacks of cough, wheezing, sometimes chest tightness and variable airflow obstruction. As time progresses, this airflow obstruction may become irreversible due to airway remodelling. Since many years, asthma has been supposed as mainly a Th2 cell-mediated disorder<sup>[3,4]</sup>. Nevertheless, in recent years, it is also discovered that many other cell types such as Treg, Th1 and Th17 are also involved in pathological process of asthma<sup>[3,4]</sup>.

Drugs, such as inhaled corticosteroids, long-acting beta agonists and montelukast can effectively control asthma symptoms and attacks. However, it is known that, pharmacotherapy can not affect the underlying immune response; when these medications are stopped the symptoms may recur.

Specific allergen immunotherapy (SIT) is a unique therapy which capable to change the natural evolution of allergic diseases<sup>[5]</sup>. With this treatment mode, allergens are given to patients in repeated and increasing doses to provide immune tolerance<sup>[6]</sup>.

The effectiveness of both subcutaneous (SCIT) and sublingual (SLIT) immunotherapy is documented for both perennial and seasonal allergic respiratory disease by systematic reviews and meta-analyses<sup>[6-11]</sup>. For almost 100 years now, subcutaneous route has been used to treat allergic diseases; however, there are many studies to confirm the administration of SLIT because of discomfort of repeated injections and higher risk of adverse reactions.

In most published studies, effectiveness of SIT has been assessed primarily in patients with allergic rhinitis, and the results concerning asthma mostly were given as secondary outcome. Thus, there are a few studies which were organised to evaluate the efficacy of SIT specifically in asthma alone.

In this paper we will review primarily the clinical efficacy and safety of both SCIT and SLIT in patients with allergic asthma in the light of the literature.

## CLINICAL EFFICACY OF SCIT IN ASTHMA

The first of the studies which evaluate the efficacy of SCIT in asthmatic patients published by Abramson in 1995<sup>[12]</sup>.

In the meta-analysis carried out by Ross *et al*<sup>[13]</sup>, 24 prospective, randomized, studies involving 962 asthmatic patients were evaluated. They reported significant amelioration in symptoms and drug intake related with asthma as well as in pulmonary function in the SCIT group in comparison to the placebo. It was deduced that immunotherapy was beneficial in 17 (71%) studies, inefficacious in 4 (17%) studies, and equivocal in 3 (12%) studies. Similar to the previous meta-analyses, the authors concluded that SIT is effective in patients suffering from allergic asthma.

In a study of Basomba *et al*<sup>[14]</sup>, 55 mild and moderate asthmatic patients (aged 14-50 years) allergic to house dust mites (HDM) were treated with *D pteronyssinus* ex-

tract encapsulated in liposomes, in a double-blind placebo-controlled manner. At the end of one year, 45.8% of the patients treated with SCIT decreased symptom and medication scores by at the minimum 60%. There were also notable improvements in results of skin test and allergen-specific bronchial challenge.

In another study, fifteen children aged 6-14 years with asthma due to HDM were treated with SCIT for three years; the results were remarkable reduction in the number of asthma exacerbations and marked decrease in drug intake<sup>[15]</sup>. Additionally, significant improvement in lung functions and non-specific bronchial hyperreactivity (BHR) were observed.

García-Robaina *et al*<sup>[16]</sup> administered SIT with HDM in 64 adult asthmatic patients and they observed notable amelioration in the active group over placebo in terms of symptom (53.8 %) and medication scores (58%) in addition to improvement in allergen-specific BHR.

Roberts *et al*<sup>[17]</sup> studied the efficacy of grass pollen SIT in 35 asthmatic patients (aged 3-16 years) over 2 pollen season in a double-blind manner. They found that SIT provided significant decreases in asthma symptom and medication scores, marked improvements in cutaneous ( $P = 0.002$ ), conjunctival ( $P = 0.02$ ), and bronchial ( $P = 0.01$ ) reactivity to allergen.

In the study of Zielen *et al*<sup>[18]</sup>, 65 mite allergic children aged 6-17 years were treated with subcutaneous allergoid immunotherapy plus fluticasone propionate (FP) or FP therapy alone for 2 years. Before starting SIT, asthma control was achieved using inhaled corticosteroids for 5 mo follow-up. Children treated with SCIT plus FP were able to markedly decrease the FP dose, in comparison to the control group given only FP. After 2 years of treatment, the mean daily FP dose decreased from 330.3 µg to 151.5 µg in the immunotherapy group while there was no significant reduction in the control group.

In a recent Cochrane review of SCIT, 88 studies on 3459 subjects with asthma were evaluated; there were 42 trials for dust mites, 27 for pollen, 10 for animal dander, two for molds, two for latex, and six for multiple allergens<sup>[19]</sup>. It was reported that SCIT improved asthma symptoms, reduced medication use, and diminished BHR. The conclusion of this review was summarized as: "it would require treating three subjects to prevent an exacerbation for one individual, four subjects to improve medication use in one, and four subjects to avoid nonspecific or allergen-specific BHR in one patient, respectively". Additionally, mite and pollen immunotherapy were found more effective on symptom scores.

There are several studies of SCIT (particularly with mites<sup>[20,21]</sup> or mixed-allergen up to seven aeroallergens<sup>[22]</sup>) which demonstrated the improvement in asthma symptom and medication scores to a lesser degree than the other published studies. Nevertheless, significant steroid-sparing effect of immunotherapy was shown in moderate persistent asthmatics included in those studies. Thus, it should be kept in mind that the maintenance of asthma control is very important before and during the study in order to obtain optimal benefit of the immunotherapy.

## CLINICAL EFFICACY OF SLIT IN ASTHMA

World Allergy Organization Position Paper on Sublingual Immunotherapy declared that SLIT is effective in the treatment of allergic rhinitis in adults and in allergic rhinitis and asthma in children<sup>[23]</sup>. However, it is also stated the presence of some important points about current status of SLIT effectiveness. It is known that there are significant heterogeneity between studies included in SLIT meta-analyses, and this may bring significant limitation on the conclusion of them.

The first meta-analysis on SLIT in asthma was conducted by Olaguibel *et al.*<sup>[24]</sup> and comprised of seven studies in 256 children aged up to 14 years. This study showed marked improvements in symptom scores (SMD: -1.42) and medication requirement scores (SMD: -1.01) related with asthma.

In 2006, a meta-analysis about SLIT in asthma included 25 trials and involved 1706 adults and children<sup>[25]</sup>. This meta-analysis reported a significant efficacy of SLIT for symptoms and medication use in seven studies, and improvement in pulmonary function in four studies. But, when asthma symptoms and drug intake were analysed as ongoing parameters, the reductions were not significant.

Penagos *et al.*<sup>[26]</sup> evaluated the efficacy of SLIT by conducting a meta-analysis which included nine studies on 441 asthmatic children. Six of these studies were with mites and three of them with pollen. The authors found significant decrease in symptom and medication scores with SLIT in comparison to placebo.

In 2009, Compalati *et al.*<sup>[10]</sup> published a meta-analysis which evaluate nine studies in 452 patients treated with SLIT in HDM-allergic asthma. They reported marked improvement in symptom and medication scores related with asthma. As in SCIT, the steroid sparing effect of SLIT was also demonstrated in some recent published studies<sup>[27,28]</sup>.

In the study of Marogna *et al.*<sup>[28]</sup>, 84 asthmatics were randomized to four treatment arms for three years: first group received budesonide 800 µg/d; second group received budesonide 1600 µg/d; third group treated with budesonide 400 µg/d plus montelukast 10 µg/d; and fourth group was given budesonide 400 µg/d plus allergoid of betulaceae pre-coseasonally. Low-dose inhaled corticosteroids plus SLIT provided a marked advantage over the other options on symptoms plus medications decrease, FEV1 increase, rescue medications usage, and was comparable to low-dose inhaled corticosteroids plus montelukast on MEF25 and BHR.

Similarly, in a study involving 602 mite allergic asthmatic patients, it was shown that daily treatment with SLIT tablet reduced inhaled budesonide more than 80 µg/d in comparison to placebo after 1 year<sup>[27]</sup>.

## HEAD-TO HEAD STUDIES

There are 4 randomized controlled trials with 171 participants which compare SCIT with SLIT directly in asthmatic patients. All these studies enrolled mite allergic

patients with rhinitis and/or asthma. Efficacy of SIT was investigated by evaluating the clinical outcomes for both rhinitis and asthma.

In the first of these studies, Mungan *et al.*<sup>[29]</sup>, randomized 36 adults with HDM-allergic rhinitis and asthma to receive SCIT, SLIT or placebo. They found that one-year of SCIT improved symptom scores of both rhinitis and asthma while SLIT had benefit only on symptoms of rhinitis. However, medication scores of both rhinitis and asthma decreased significantly in both actively treated groups. After 1 year of immunotherapy, it was also shown marked rises in specific IgG4 concentrations in comparison to the baseline both in SLIT and SCIT groups.

Eifan *et al.*<sup>[30]</sup> evaluated the effectiveness of SCIT and SLIT in children with asthma/rhinitis sensitized to mites. Forty eight children were randomized to treat either SCIT, SLIT or pharmacotherapy. This study demonstrated that both SLIT and SCIT have a significant positive effect on symptoms and medication usage related with both rhinitis and asthma in comparison to the pharmacotherapy group. Additionally, after 1 year of treatment, Der p 1-driven IL-10 significantly increased in SLIT in comparison to pharmacotherapy, whereas Bet v 1-driven TGF-β increased significantly in SLIT only.

In the study of Keles *et al.*<sup>[31]</sup>, 48 patients (aged 5-10 years) with mild persistent asthma and rhinitis mono-sensitized to mites were randomized to three treatment arms: they received either SLIT ( $n = 16$ ), SCIT ( $n = 16$ ) or pharmacotherapy alone ( $n = 16$ ). After 12-mo of treatment, total asthma symptom scores ( $P = 0.02$ ) and visual analog scores ( $P = 0.02$ ) decreased markedly in SLIT when compared with the pharmacotherapy group. Similarly, SCIT also reduced both total asthma symptom-scores ( $P = 0.04$ ) and visual analog scores ( $P = 0.001$ ) when compared with the pharmacotherapy group. The percentage of improvement was 100% and 93% in SLIT and SCIT group respectively, in comparison to the pharmacotherapy group. A marked increment was seen in the levels of regulatory and Th1 cytokines both in the SCIT and SLIT groups. Antigen-specific IgG4 levels increased in the SCIT and SCIT plus SLIT groups but not in the SLIT group.

In a recent randomized, placebo-controlled and double-dummy study we investigated the effectiveness of SCIT and SLIT in HDM-allergic children with asthma and/or rhinitis<sup>[32]</sup>. We showed that one-year SCIT had significant effect on symptom and medication scores related with both rhinitis and asthma. An important observation in this study was the better effect of only SCIT over placebo on reduction of rhinitis and asthma symptoms at the end of one-year-treatment. Bronchial challenge doses and sputum eosinophil increments after bronchial challenge decreased only with SCIT. There was no change in terms of IFN-γ levels in both immunotherapy groups. Serum sIgG4 levels increased significantly only in the SCIT group. This study then carried on one subsequent year in an open scheme and the placebo group was randomized to treat SCIT or SLIT. Thus, all patients

received active treatment with SCIT or SLIT during one subsequent year<sup>[33]</sup>. We observed that the effect of SLIT on asthma symptoms and drug intake was less eminent than SCIT in the first year; however this effect was more pronounced in the second year of SLIT. With this study, we concluded that both clinical and immunologic improvement starts earlier with SCIT in comparison to the SLIT in mite-allergic children with rhinitis and asthma.

The summary of these 4 head-to-head studies was shown in Table 1. Recently, a systematic review of studies with head-to-head comparison of SCIT and SLIT in the treatment of allergic rhinoconjunctivitis and asthma was published<sup>[34]</sup>. Four trials conducted in patients with rhinitis and/or asthma<sup>[29-32]</sup>. This review demonstrated that low-grade evidence confirms more efficacy of SCIT than SLIT regarding reduction of asthma symptoms and combined measure of rhinitis symptoms and drug intake; moderate-grade evidence confirms more efficacy of SCIT than SLIT for nasal and/or eye symptom reduction. It was deduced that low-grade evidence confirms that SCIT is more beneficial than SLIT for reduction in asthma symptoms and moderate-grade evidence for reduction of allergic rhinoconjunctivitis. Further studies are required to support this results for clinical decision making.

## SAFETY OF SCIT AND SLIT

It is known that SCIT has a risk for both local and systemic adverse reactions but, in most of the cases, symptoms are reversible if they are diagnosed early and treated rapidly. All allergen preparations (standardized extracts<sup>[35]</sup>, allergoids<sup>[36]</sup> or recombinant allergens<sup>[37]</sup> can cause these side effects.

The incidence of systemic reactions of SCIT varies between 0.06% and 1.01% in those receiving injections<sup>[38]</sup>.

A recent multicenter study suggested that systemic reactions were slightly more frequent in rhinitis with asthma than rhinitis patients alone<sup>[39]</sup>. Some reports have been suggested that asthma may be a risk factor for severe systemic reactions due to SCIT, notably in patients with uncontrolled asthma. Conversely, another retrospective study reported no significant association between systemic reactions and the presence of asthma<sup>[40]</sup>. As noted by official documents, the patients's general condition and pulmonary functions should be assessed before injection in order to reduce the risk of anaphylaxis<sup>[41]</sup>.

The safety of SLIT seems better than subcutaneous therapy regarding severe systemic reactions. Local side effects (oral itching or mild swelling) may be encountered in three-fourths of patients especially in the early phase of SLIT.

In the study of Dahl *et al*<sup>[42]</sup> the safety of SLIT investigated specifically in grass pollen allergic patients with asthma. They evaluated side effects which may be related with asthma, *e.g.*, cough, wheezing, and they found no difference in the number of such effects between active and placebo group. Additionally, no asthma exacerbation

related with SLIT was reported in this study.

There are also some recommendations about administering of SLIT in patients with systemic reactions after subcutaneous immunotherapy<sup>[43]</sup>. Nonetheless, some patients suffering from these adverse reactions with subcutaneous route may entertain the same risk for sublingual route of immunotherapy<sup>[44]</sup>. Thus, our recommendation is that immunotherapy should be customized to each patient on the basis of the degree of sensitization, concomitant allergies, exposures and patient's preference.

## PREVENTIVE CAPACITY OF SIT

SIT builds up clinical and immunological tolerance as shown by persistence of improvement both in clinical and immunologic parameters after the cessation of treatment. Additional long-term benefits of SIT include prevention of new sensitizations and progression from rhinitis to asthma.

There are some studies which demonstrated the preventive effect of SIT in pediatric population. At the 10-year follow-up (7 years after cessation of immunotherapy) the children in the immunotherapy group had significantly less asthma in comparison to the control group: 16/64 (25%) with asthma in the immunotherapy group compared with 24/53 (45%) of the untreated control group<sup>[45]</sup>. The authors concluded that immunotherapy for 3 years with grass and/or birch allergen extracts provides long-term preventive effect on the development of asthma in children with only seasonal rhinoconjunctivitis.

A similar preventive effect was also shown with SLIT in a 3-year open study of 113 children (aged 5-14 years) having grass pollen rhinitis<sup>[46]</sup>. This study demonstrated that asthma development was 3.8 times more frequent in the control subjects.

There is another study which show no significant difference in symptom and medication scores in the subsequent three pollen seasons after 3-4 years of grass-pollen SCIT<sup>[47]</sup>.

Marogna *et al*<sup>[48]</sup> have noted that clinical benefit persists for 8 years after SLIT treatment is given for a 4- to 5-year duration; new sensitizations were also reduced in SLIT group.

It has been documented that SCIT with a single allergen has a preventive effect against sensitization to different inhalant allergens<sup>[49-52]</sup>. There are some studies which reported significantly lower rate of the development of new allergen sensitizations in monosensitized patients who received SCIT in comparison to the controls<sup>[49-52]</sup>. In these studies, the percentage of the development of new sensitizations were 23%, 24%, 24.7% and 54% in patients treated with SCIT while 68%, 67%, 53.3% and 100% in untreated monosensitized patients.

Recent studies have shown such effects with SLIT<sup>[48,53-55]</sup>. In a 3-year open study, 5.9 % of 511 patients with allergic rhinitis and asthma treated with SLIT showed new allergen sensitizations, while this rate was 38% in the control patients<sup>[55]</sup>.



**Table 1** Head-to-head studies which included patients with asthma treated by subcutaneous and sublingual immunotherapy<sup>1</sup>

Ref.	Year	Study Design	Age	No of patients	Asthma symptom score				Medication score				Findings
					Before SIT		After SIT		Before SIT		After SIT		
					SCIT	SLIT	SCIT	SLIT	LSCIT	SLIT	SCIT	SLIT	
Mungan <i>et al</i> <sup>[29]</sup>	1999	Single-blind, placebo controlled	Adults	SCIT ( <i>n</i> = 10) SLIT ( <i>n</i> =15) Placebo ( <i>n</i> = 11)	1.2	0.63	0.59	0.41	6.8	4.93	3.9	1.97	Reduction in symptom scores with only SCIT Reduction in medication scores with both SCIT and SLIT
Eifan <i>et al</i> <sup>[30]</sup>	2010	Open label, randomized, controlled	5-10	SCIT ( <i>n</i> = 16) SLIT ( <i>n</i> = 16) Pharmacotherapy ( <i>n</i> = 16)	0.9 ± 0.7	1.4 ± 1.5	0.4 ± 0.6	0.2 ± 0.4	2.4 ± 1.4	2.8 ± 1.2	1.7 ± 1.4	1.2 ± 0.9	Reduction in symptom and medication scores and visual analog scores with both SCIT and SLIT
Keles <i>et al</i> <sup>[31]</sup>	2011	Open label, randomized, controlled	5-12	SCIT ( <i>n</i> = 11) SLIT ( <i>n</i> = 13) SCIT plus SLIT ( <i>n</i> = 14) Pharmacotherapy ( <i>n</i> = 12)	0.25	0.12	0	0	0.52	0.69	0.06	0.23	Reduction in symptom scores and visual analog scores with both SCIT and SLIT
Yukselen <i>et al</i> <sup>[32]</sup>	2012	Randomized, double-blind, double-dummy, placebo-controlled	6-14	SCIT ( <i>n</i> = 10) SLIT ( <i>n</i> = 11) Placebo ( <i>n</i> =10 )	2.4	3.7	1	2.7	2.3	2.3	1	1.7	Only SCIT was found superior to placebo on reduction of symptom and medication scores

<sup>1</sup>All studies used HDM immunotherapy. SCIT : Subcutaneous immunotherapy; SLIT: Sublingual immunotherapy; SIT: Specific immunotherapy.

## CONCLUSION

SIT is the only therapeutic approach which capable to modify the natural evolution of allergic respiratory diseases. However, there are some shortcomings in trials conducted in patients with allergic asthma. In most of these studies, efficacy of SIT was not evaluated specifically in allergic asthma alone. Additionally, many of these trials had significant limitations such as low number of patients, difference in treatment protocols and doses, inadequate evaluation of pulmonary functions or absence of a placebo group. Moreover, there is a great heterogeneity between studies included in meta-analyses; the most important point in this respect is the assessment of results of SIT with different allergens in the same meta-analysis.

Despite these shortcomings, the clinical efficacy of SIT has been established in allergic asthma in objective and subjective parameters such as titrated skin tests, allergen-specific bronchial hyperreactivity, and symptom and medications scores.

Steroid sparing effect of SIT gives an important advantage for patients who have to use these drugs in high doses in order to control their asthma symptoms for many years.

SIT should be considered in asthmatic patients who experience side effects of medications, to reduce or avoid long-term pharmacotherapy and the economic burden of medications and in the presence of allergic rhinitis and/or other comorbid allergic conditions<sup>[41]</sup>.

Official documents recommend that SIT should not be started in patients with unstable asthma; in these cases, SIT can be initiated after well asthma control with appropriate pharmacotherapy.

Although both SCIT and SLIT have been reported to be effective on allergic asthma, the results of some studies or meta-analyses suggested that the efficacy of SCIT may be better and start earlier than SLIT.

Further studies are needed to discover patients who will benefit more from immunotherapy, novel vaccines and new routes of administration to increase efficacy and safety.

## REFERENCES

- 1 Bateman ED, Hurd SS, Barnes PJ, Bousquet J, Drazen JM, FitzGerald M, Gibson P, Ohta K, O'Byrne P, Pedersen SE, Pizzichini E, Sullivan SD, Wenzel SE, Zar HJ. Global strategy for asthma management and prevention: GINA executive summary. *Eur Respir J* 2008; **31**: 143-178 [PMID: 18166595 DOI: 10.1183/09031936.00138707]
- 2 Blackwell DL, Lucas JW, Clarke TC. Summary health statistics for U.S. adults: national health interview survey, 2012. *Vital Health Stat* 10 2014; **(260)**: 1-161 [PMID: 24819891]
- 3 Agache I, Akdis C, Jutel M, Virchow JC. Untangling asthma phenotypes and endotypes. *Allergy* 2012; **67**: 835-846 [PMID: 22594878 DOI: 10.1111/j.1398-9995.2012.02832.x]
- 4 Jutel M, Akdis CA. T-cell subset regulation in atopy. *Curr Allergy Asthma Rep* 2011; **11**: 139-145 [PMID: 21271314 DOI: 10.1007/s11882-011-0178-7]
- 5 Akdis CA, Akdis M. Mechanisms of allergen-specific immunotherapy. *J Allergy Clin Immunol* 2011; **127**: 18-27; quiz 28-29 [PMID: 21211639 DOI: 10.1016/j.jaci.2010.11.030]

- 6 Akdis CA. Therapies for allergic inflammation: refining strategies to induce tolerance. *Nat Med* 2012; **18**: 736-749 [PMID: 22561837 DOI: 10.1038/nm.2754]
- 7 Möller C, Dreborg S, Ferdousi HA, Halken S, Høst A, Jacobsen L, Koivikko A, Koller DY, Niggemann B, Norberg LA, Urbanek R, Valovirta E, Wahn U. Pollen immunotherapy reduces the development of asthma in children with seasonal rhinoconjunctivitis (the PAT-study). *J Allergy Clin Immunol* 2002; **109**: 251-256 [PMID: 11842293 DOI: 10.1067/mai.2002.121317]
- 8 Calderon MA, Alves B, Jacobson M, Hurwitz B, Sheikh A, Durham S. Allergen injection immunotherapy for seasonal allergic rhinitis. *Cochrane Database Syst Rev* 2007; **(1)**: CD001936 [PMID: 17253469]
- 9 Radulovic S, Calderon MA, Wilson D, Durham S. Sublingual immunotherapy for allergic rhinitis. *Cochrane Database Syst Rev* 2010; **(12)**: CD002893 [PMID: 21154351]
- 10 Compalati E, Passalacqua G, Bonini M, Canonica GW. The efficacy of sublingual immunotherapy for house dust mites respiratory allergy: results of a GA2LEN meta-analysis. *Allergy* 2009; **64**: 1570-1579 [PMID: 19796205 DOI: 10.1111/j.1398-9995.2009.02129]
- 11 Burks AW, Calderon MA, Casale T, Cox L, Demoly P, Jutel M, Nelson H, Akdis CA. Update on allergy immunotherapy: American Academy of Allergy, Asthma & Immunology/European Academy of Allergy and Clinical Immunology/PRACTALL consensus report. *J Allergy Clin Immunol* 2013; **131**: 1288-1296.e3 [PMID: 23498595 DOI: 10.1016/j.jaci.2013.01.049]
- 12 Abramson MJ, Puy RM, Weiner JM. Is allergen immunotherapy effective in asthma? A meta-analysis of randomized controlled trials. *Am J Respir Crit Care Med* 1995; **151**: 969-974 [PMID: 7697274 DOI: 10.1164/ajrccm/151.4.969]
- 13 Ross RN, Nelson HS, Finegold I. Effectiveness of specific immunotherapy in the treatment of asthma: a meta-analysis of prospective, randomized, double-blind, placebo-controlled studies. *Clin Ther* 2000; **22**: 329-341 [PMID: 10963287 DOI: 10.1016/S0149-2918(00)80037-5]
- 14 Basomba A, Tabar AI, de Rojas DH, García BE, Alamar R, Olaguibel JM, del Prado JM, Martín S, Rico P. Allergen vaccination with a liposome-encapsulated extract of *Dermatophagoides pteronyssinus*: a randomized, double-blind, placebo-controlled trial in asthmatic patients. *J Allergy Clin Immunol* 2002; **109**: 943-948 [PMID: 12063522 DOI: 10.1067/mai.2002.124465]
- 15 Pifferi M, Baldini G, Marrazzini G, Baldini M, Ragazzo V, Pietrobelli A, Boner AL. Benefits of immunotherapy with a standardized *Dermatophagoides pteronyssinus* extract in asthmatic children: a three-year prospective study. *Allergy* 2002; **57**: 785-790 [PMID: 12169173 DOI: 10.1034/j.1398-9995.2002.23498]
- 16 García-Robaina JC, Sánchez I, de la Torre F, Fernández-Caldas E, Casanovas M. Successful management of mite-allergic asthma with modified extracts of *Dermatophagoides pteronyssinus* and *Dermatophagoides farinae* in a double-blind, placebo-controlled study. *J Allergy Clin Immunol* 2006; **118**: 1026-1032 [PMID: 17088125 DOI: 10.1016/j.jaci.2006.07.043]
- 17 Roberts G, Hurley C, Turcanu V, Lack G. Grass pollen immunotherapy as an effective therapy for childhood seasonal allergic asthma. *J Allergy Clin Immunol* 2006; **117**: 263-268 [PMID: 16461125 DOI: 10.1016/j.jaci.2005.09.054]
- 18 Zielen S, Kardos P, Madonini E. Steroid-sparing effects with allergen-specific immunotherapy in children with asthma: a randomized controlled trial. *J Allergy Clin Immunol* 2010; **126**: 942-949 [PMID: 20624650 DOI: 10.1016/j.jaci.2010.06.002]
- 19 Abramson MJ, Puy RM, Weiner JM. Injection allergen immunotherapy for asthma. *Cochrane Database Syst Rev* 2010; **(8)**: CD001186 [PMID: 20687065 DOI: 10.1002/14651858.CD001186.pub2]
- 20 Blumberg G, Groes L, Haugaard L, Dahl R. Steroid-sparing effect of subcutaneous SQ-standardised specific immunotherapy in moderate and severe house dust mite allergic asthmatics. *Allergy* 2006; **61**: 843-848 [PMID: 16792582 DOI: 10.1111/j.1398-9995.2006.01088]
- 21 Maestrelli P, Zanolla L, Pozzan M, Fabbri LM. Effect of specific immunotherapy added to pharmacologic treatment and allergen avoidance in asthmatic patients allergic to house dust mite. *J Allergy Clin Immunol* 2004; **113**: 643-649 [PMID: 15100667 DOI: 10.1016/j.jaci.2003.12.586]
- 22 Adkinson NF, Eggleston PA, Eney D, Goldstein EO, Schuberth KC, Bacon JR, Hamilton RG, Weiss ME, Arshad H, Meinert CL, Tonascia J, Wheeler B. A controlled trial of immunotherapy for asthma in allergic children. *N Engl J Med* 1997; **336**: 324-331 [PMID: 9011784 DOI: 10.1056/NEJM199701303360502]
- 23 Canonica GW, Bousquet J, Casale T, Lockey RF, Baena-Cagnani CE, Pawankar R, Potter PC, Bousquet PJ, Cox LS, Durham SR, Nelson HS, Passalacqua G, Ryan DP, Brozek JL, Compalati E, Dahl R, Delgado L, van Wijk RG, Gower RG, Ledford DK, Filho NR, Valovirta EJ, Yusuf OM, Zuberbier T, Akhanda W, Almarales RC, Ansotegui I, Bonifazi F, Ceuppens J, Chivato T, Dimova D, Dumitrescu D, Fontana L, Katelaris CH, Kaulsay R, Kuna P, Larenas-Linnemann D, Manoussakis M, Nekam K, Nunes C, O'Hehir R, Olaguibel JM, Onder NB, Park JW, Priftanji A, Puy R, Sarmiento L, Scadding G, Schmid-Grendelmeier P, Seberova E, Sepiashevili R, Solé D, Togias A, Tomino C, Toskala E, Van Beever H, Vieths S. Sub-lingual immunotherapy: World Allergy Organization Position Paper 2009. *Allergy* 2009; **64** Suppl 91: 1-59 [PMID: 20041860 DOI: 10.1097/VOX.0b013e3181c6c379]
- 24 Olaguibel JM, Alvarez Puebla MJ. Efficacy of sublingual allergen vaccination for respiratory allergy in children. Conclusions from one meta-analysis. *J Invest Allergol Clin Immunol* 2005; **15**: 9-16 [PMID: 15864877]
- 25 Calamita Z, Saconato H, Pelá AB, Atallah AN. Efficacy of sublingual immunotherapy in asthma: systematic review of randomized-clinical trials using the Cochrane Collaboration method. *Allergy* 2006; **61**: 1162-1172 [PMID: 16942563 DOI: 10.1111/j.1398-9995.2006.01205]
- 26 Penagos M, Passalacqua G, Compalati E, Baena-Cagnani CE, Orozco S, Pedroza A, Canonica GW. Metaanalysis of the efficacy of sublingual immunotherapy in the treatment of allergic asthma in pediatric patients, 3 to 18 years of age. *Chest* 2008; **133**: 599-609 [PMID: 17951626 DOI: 10.1097/01.VOX.0000301999.54398.13]
- 27 Mosbech H. Tolerability and efficacy of house dust mite AIT. *Allergy* 2011; **66** Suppl 95: 55-56 [PMID: 21668857 DOI: 10.1111/j.1398-9995.2011.02641]
- 28 Marogna M, Braidì C, Bruno ME, Colombo C, Colombo F, Massolo A, Palumbo L, Compalati E. The contribution of sublingual immunotherapy to the achievement of control in birch-related mild persistent asthma: a real-life randomised trial. *Allergol Immunopathol (Madr)* 2013; **41**: 216-224 [PMID: 23141837 DOI: 10.1016/j.aller.2012.07.004]
- 29 Mungan D, Misirligil Z, Gürbüz L. Comparison of the efficacy of subcutaneous and sublingual immunotherapy in mite-sensitive patients with rhinitis and asthma—a placebo controlled study. *Ann Allergy Asthma Immunol* 1999; **82**: 485-490 [PMID: 10353581 DOI: 10.1016/S1081-1206(10)62726-3]
- 30 Eifan AO, Akkoc T, Yildiz A, Keles S, Ozdemir C, Bahceciler NN, Barlan IB. Clinical efficacy and immunological mechanisms of sublingual and subcutaneous immunotherapy in asthmatic/rhinitis children sensitized to house dust mite: an open randomized controlled trial. *Clin Exp Allergy* 2010; **40**: 922-932 [PMID: 20100188 DOI: 10.1111/j.1365-2222.2009.03448]
- 31 Keles S, Karakoc-Aydiner E, Ozen A, Izgi AG, Tevetoglu A, Akkoc T, Bahceciler NN, Barlan I. A novel approach in allergen-specific immunotherapy: combination of sublingual and subcutaneous routes. *J Allergy Clin Immunol* 2011; **128**: 808-815.e7 [PMID: 21641635 DOI: 10.1016/j.jaci.2011.04.033]

- 32 **Yukselen A**, Kendirli SG, Yilmaz M, Altintas DU, Karakoc GB. Effect of one-year subcutaneous and sublingual immunotherapy on clinical and laboratory parameters in children with rhinitis and asthma: a randomized, placebo-controlled, double-blind, double-dummy study. *Int Arch Allergy Immunol* 2012; **157**: 288-298 [PMID: 22041501 DOI: 10.1159/000327566]
- 33 **Yukselen A**, Kendirli SG, Yilmaz M, Altintas DU, Karakoc GB. Two year follow-up of clinical and inflammation parameters in children monosensitized to mites undergoing subcutaneous and sublingual immunotherapy. *Asian Pac J Allergy Immunol* 2013; **31**: 233-241 [PMID: 24053706 DOI: 10.12932/AP0276.31.3.2013]
- 34 **Chelladurai Y**, Suarez-Cuervo C, Erekesima N, Kim JM, Ramanathan M, Segal JB, Lin SY. Effectiveness of subcutaneous versus sublingual immunotherapy for the treatment of allergic rhinoconjunctivitis and asthma: a systematic review. *J Allergy Clin Immunol Pract* 2013; **1**: 361-369 [PMID: 24565541 DOI: 10.1016/j.jaip.2013.04.005]
- 35 **Passalacqua G**, Durham SR. Allergic rhinitis and its impact on asthma update: allergen immunotherapy. *J Allergy Clin Immunol* 2007; **119**: 881-891 [PMID: 17418661 DOI: 10.1016/j.jaci.2007.01.045]
- 36 **Corrigan CJ**, Kettner J, Doemer C, Cromwell O, Narkus A. Efficacy and safety of preseasonal-specific immunotherapy with an aluminium-adsorbed six-grass pollen allergoid. *Allergy* 2005; **60**: 801-807 [PMID: 15876311 DOI: 10.1111/j.1398-9995.2005.00790]
- 37 **Jutel M**, Jaeger L, Suck R, Meyer H, Fiebig H, Cromwell O. Allergen-specific immunotherapy with recombinant grass pollen allergens. *J Allergy Clin Immunol* 2005; **116**: 608-613 [PMID: 16159631 DOI: 10.1016/j.jaci.]
- 38 **Bernstein DI**, Epstein T, Murphy-Berendts K, Liss GM. Surveillance of systemic reactions to subcutaneous immunotherapy injections: year 1 outcomes of the ACAAI and AAAAI collaborative study. *Ann Allergy Asthma Immunol* 2010; **104**: 530-535 [PMID: 20568387 DOI: 10.1016/j.anai.2010.04.008]
- 39 **Schiappoli M**, Ridolo E, Senna G, Alesina R, Antonicelli L, Asero R, Costantino MT, Longo R, Musarra A, Nettis E, Crivellaro M, Savi E, Massolo A, Passalacqua G. A prospective Italian survey on the safety of subcutaneous immunotherapy for respiratory allergy. *Clin Exp Allergy* 2009; **39**: 1569-1574 [PMID: 19486027 DOI: 10.1111/j.1365-2222.2009.03286.x]
- 40 **Rank MA**, Oslie CL, Krogman JL, Park MA, Li JT. Allergen immunotherapy safety: characterizing systemic reactions and identifying risk factors. *Allergy Asthma Proc* 2008; **29**: 400-405 [PMID: 18702889 DOI: 10.2500/aap.2008.29.3141]
- 41 **Joint Task Force on Practice Parameters**, American Academy of Allergy, Asthma and Immunology; American College of Allergy, Asthma and Immunology; Joint Council of Allergy, Asthma and Immunology. Allergen immunotherapy: a practice parameter second update. *J Allergy Clin Immunol* 2007; **120**: S25-S85 [PMID: 17765078 DOI: 10.1016/j.jaci.2007.06.019]
- 42 **Dahl R**, Stender A, Rak S. Specific immunotherapy with SQ standardized grass allergen tablets in asthmatics with rhinoconjunctivitis. *Allergy* 2006; **61**: 185-190 [PMID: 16409194 DOI: 10.1111/j.1398-9995.2005.00949.x]
- 43 **Alvarez-Cuesta E**, Bousquet J, Canonica GW, Durham SR, Malling HJ, Valovirta E. Standards for practical allergen-specific immunotherapy. *Allergy* 2006; **61** Suppl 82: 1-20 [PMID: 16930249 DOI: 10.1111/j.1398-9995.2006.01219]
- 44 **Burastero S**. Regarding Gidaro GB, Marcucci F, Sensi L, Incorvaia C, Frati F, Ciprandi G. The safety of sublingual-swallow immunotherapy: an analysis of published studies. *Clin Exp Allergy* 2005; **35**: 565-571. *Clin Exp Allergy* 2005; **35**: 1407-1408; author reply 1409 [PMID: 16238803 DOI: 10.1111/j.1365-2222.2005.02366]
- 45 **Jacobsen L**, Niggemann B, Dreborg S, Ferdousi HA, Halken S, Høst A, Koivikko A, Norberg LA, Valovirta E, Wahn U, Möller C. Specific immunotherapy has long-term preventive effect of seasonal and perennial asthma: 10-year follow-up on the PAT study. *Allergy* 2007; **62**: 943-948 [PMID: 17620073 DOI: 10.1111/j.1398-9995.2007.01451.x]
- 46 **Novembre E**, Galli E, Landi F, Caffarelli C, Pifferi M, De Marco E, Burastero SE, Calori G, Benetti L, Bonazza P, Puccinelli P, Parmiani S, Bernardini R, Vierucci A. Coseasonal sublingual immunotherapy reduces the development of asthma in children with allergic rhinoconjunctivitis. *J Allergy Clin Immunol* 2004; **114**: 851-857 [PMID: 15480326 DOI: 10.1016/j.jaci.2004.07.012]
- 47 **Durham SR**, Walker SM, Varga EM, Jacobson MR, O'Brien F, Noble W, Till SJ, Hamid QA, Nouri-Aria KT. Long-term clinical efficacy of grass-pollen immunotherapy. *N Engl J Med* 1999; **341**: 468-475 [PMID: 10441602 DOI: 10.1056/NEJM199908123410702]
- 48 **Marogna M**, Spadolini I, Massolo A, Canonica GW, Passalacqua G. Long-lasting effects of sublingual immunotherapy according to its duration: a 15-year prospective study. *J Allergy Clin Immunol* 2010; **126**: 969-975 [PMID: 20934206 DOI: 10.1016/j.jaci.2010.08.030]
- 49 **Des Roches A**, Paradis L, Menardo JL, Bouges S, Daurès JP, Bousquet J. Immunotherapy with a standardized Dermatophagoides pteronyssinus extract. VI. Specific immunotherapy prevents the onset of new sensitizations in children. *J Allergy Clin Immunol* 1997; **99**: 450-453 [PMID: 9111487 DOI: 10.1016/S0091-6749(97)70069-1]
- 50 **Pajno GB**, Barberio G, De Luca F, Morabito L, Parmiani S. Prevention of new sensitizations in asthmatic children monosensitized to house dust mite by specific immunotherapy. A six-year follow-up study. *Clin Exp Allergy* 2001; **31**: 1392-1397 [PMID: 11591189 DOI: 10.1046/j.1365-2222.2001.01161]
- 51 **Purello-D'Ambrosio F**, Gangemi S, Merendino RA, Isola S, Puccinelli P, Parmiani S, Ricciardi L. Prevention of new sensitizations in monosensitized subjects submitted to specific immunotherapy or not. A retrospective study. *Clin Exp Allergy* 2001; **31**: 1295-1302 [PMID: 11529901 DOI: 10.1046/j.1365-2222.2001.01027]
- 52 **Inal A**, Altintas DU, Yilmaz M, Karakoc GB, Kendirli SG, Sertdemir Y. Prevention of new sensitizations by specific immunotherapy in children with rhinitis and/or asthma monosensitized to house dust mite. *J Invest Allergol Clin Immunol* 2007; **17**: 85-91 [PMID: 17460946]
- 53 **Marogna M**, Tomassetti D, Bernasconi A, Colombo F, Massolo A, Businco AD, Canonica GW, Passalacqua G, Tripodi S. Preventive effects of sublingual immunotherapy in childhood: an open randomized controlled study. *Ann Allergy Asthma Immunol* 2008; **101**: 206-211 [PMID: 18727478 DOI: 10.1016/S1081-1206(10)60211-6]
- 54 **Durham SR**, Emminger W, Kapp A, Colombo G, de Monchy JG, Rak S, Scadding GK, Andersen JS, Riis B, Dahl R. Long-term clinical efficacy in grass pollen-induced rhinoconjunctivitis after treatment with SQ-standardized grass allergy immunotherapy tablet. *J Allergy Clin Immunol* 2010; **125**: 131-138.e1-8.e7 [PMID: 20109743 DOI: 10.1016/j.jaci.2009.10.035]
- 55 **Marogna M**, Spadolini I, Massolo A, Canonica GW, Passalacqua G. Randomized controlled open study of sublingual immunotherapy for respiratory allergy in real-life: clinical efficacy and more. *Allergy* 2004; **59**: 1205-1210 [PMID: 15461603 DOI: 10.1111/j.13989995.2004.00508.x]

P- Reviewer: Hattori N, Lee SH S- Editor: Tian YL  
L- Editor: A E- Editor: Wu HL





## Precancerous lesions of oral mucosa

Gurkan Yardimci, Zekayi Kutlubay, Burhan Engin, Yalcin Tuzun

Gurkan Yardimci, Department of Dermatology, Muş State Hospital, 49100 Muş, Turkey

Zekayi Kutlubay, Burhan Engin, Yalcin Tuzun, Department of Dermatology, Cerrahpaşa Medical Faculty, Istanbul University, 34098 Istanbul, Turkey

**Author contributions:** Kutlubay Z designed research; Yardimci G performed research; Tuzun Y contributed new reagents or analytic tools; Engin B analyzed data; Yardimci G wrote the paper.

**Correspondence to:** Zekayi Kutlubay, MD, Department of Dermatology, Cerrahpaşa Medical Faculty, Istanbul University, Cerrah Paşa Mh., 34098 Istanbul,

Turkey. [zekayikutlubay@hotmail.com](mailto:zekayikutlubay@hotmail.com)

Telephone: +90-212-4143120 Fax: +90-212-4147156

Received: July 22, 2014 Revised: August 28, 2014

Accepted: September 23, 2014

Published online: December 16, 2014

alternatives such as corticosteroids, calcineurin inhibitors, and retinoids are widely used.

© 2014 Baishideng Publishing Group Inc. All rights reserved.

**Key words:** Oral premalignant lesions; Leukoplakia; Erythroplakia; Submucous fibrosis; Lichen planus; Malignant transformation

**Core tip:** Precancerous lesions of oral mucosa are the diseases that have malignant transformation risk at different ratios. Clinically, these diseases may sometimes resemble each other. Thus, the diagnosis should be confirmed by biopsy. In early stages, histopathological findings are distinctive, but if malignant transformation occurs, identical histological features with oral carcinoma are seen. If these diseases left untreated, they can cause many problems, which may affect a patient's social and daily life.

### Abstract

Precancerous lesions of oral mucosa, known as potentially malignant disorders in recent years, are consists of a group of diseases, which should be diagnosed in the early stage. Oral leukoplakia, oral submucous fibrosis, and oral erythroplakia are the most common oral mucosal diseases that have a very high malignant transformation rate. Oral lichen planus is one of the potentially malignant disorders that may be seen in six different subtypes including papular, reticular, plaque-like, atrophic, erosive, and bullous type, clinically. Atrophic and erosive subtypes have the greater increased malignant transformation risk compared to another subtypes. Although there are various etiological studies, the etiology of almost all these diseases is not fully understood. Geographically, etiologic factors may vary. The most frequently reported possible factors are tobacco use, alcohol drinking, chewing of betel quid containing areca nut, and solar rays. Early diagnosis is very important and can be lifesaving, because in late stages, they may be progressed to severe dysplasia and even carcinoma *in situ* and/or squamous cell carcinoma. For most diseases, treatment results are not satisfactory in spite of miscellaneous therapies. While at the forefront of surgical intervention, topical and systemic treatment

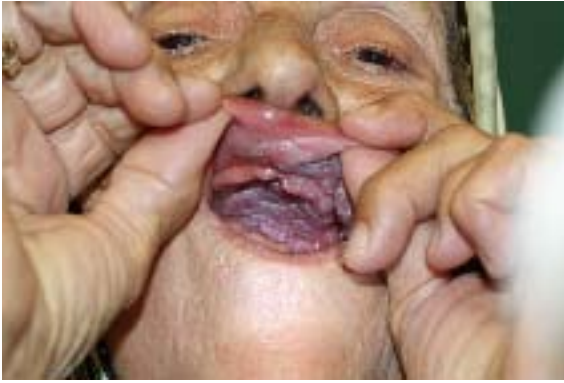Yardimci G, Kutlubay Z, Engin B, Tuzun Y. Precancerous lesions of oral mucosa. *World J Clin Cases* 2014; 2(12): 866-872 Available from: URL: <http://www.wjgnet.com/2307-8960/full/v2/i12/866.htm> DOI: <http://dx.doi.org/10.12998/wjcc.v2.i12.866>

### INTRODUCTION

In a World Health Organization Workshop, held in 2005, the terminology, definitions and classifications of oral lesions with a predisposition to malignant transformation have been discussed and recommended to use the term “potentially malignant disorders” to eliminate terminological confusion<sup>[1]</sup>.

The most common oral precancerous lesions are oral leukoplakia, oral submucous fibrosis (OSMF), and oral erythroplakia. Actinic cheilitis, some miscellaneous inherited diseases such as xeroderma pigmentosum and Fanconi's anemia, and immunodeficiency are another potentially malignant disorders for oral carcinoma as well as these three diseases<sup>[1,2]</sup>. In a clinicopathological study





**Figure 1** White and red lesions known as erythroleukoplakia are seen.

designed by Phookan *et al.*<sup>[3]</sup>, different oral premalignant lesions were observed in 70 of 320 patients with lower or middle socioeconomic group. Leukoplakia was the most common premalignant disorder (20.65% of patients), while percentages of lichen planus and OSMF were reported equally (0.62% of patients)<sup>[3]</sup>.

The etiology of precancerous lesions of oral mucosa is not well-known<sup>[4]</sup>. Some risk factors such as tobacco chewing, tobacco smoking, and alcohol play an important role in development of potentially malignant oral conditions. While tobacco chewing is a major risk factor for oral leukoplakia, OSMF, and erythroplakia, tobacco smoking may be a risk factor for oral leukoplakia. Alcohol drinking may increase the risk by 1.5-fold for oral leukoplakia, by 2-fold for OSMF, and 3-fold for erythroplakia. According to Thomas *et al.*<sup>[2]</sup>, while alcohol drinking and tobacco chewing may possibly be risk factors for multiple oral premalignant lesions, smoking was not associated with the risk of multiple oral premalignant lesions.

Various studies reported about etiopathogenesis of precancerous lesions of oral mucosa. Vlková *et al.*<sup>[4]</sup> analyzed saliva markers of oxidative stress and reported that salivary thiobarbituric acid reacting substances and advanced glycation endproducts were significantly higher in patients than in control. They also reported that no significant differences were found in salivary advanced oxidation protein products, vascular endothelial growth factor, sialotransferase, and neuraminidase. Total antioxidant capacity and expression of superoxide dismutase were lower in patients than in age-matched controls. Nanda *et al.*<sup>[5]</sup> investigated expression of CK8 and CK18 in potentially malignant disorders such as oral leukoplakia, OSMF, and oral squamous cell carcinoma and they reported that expression of CK8 and CK18 were statistically significant higher than controls. Feng *et al.*<sup>[6]</sup> reported that expression of podoplanin and ABCG2 in oral erythroplakia correlate with oral cancer development. Qin *et al.*<sup>[7]</sup> reported a high prevalence of p53 mutations in premalignant oral erythroplakia. Human papilloma virus (HPV) has been suggested to play a role in the etiopathogenesis of precancerous lesions of oral mucosa<sup>[8]</sup>. Punyani *et al.*<sup>[9]</sup> reported that there was no statistically significant in salivary IL-8 concentrations among the precancer group and controls.

**Table 1** Risk factors of malignant transformation

Female gender
Long duration of leukoplakia
Leukoplakia in non-smokers
Location on the tongue and/or floor of the mouth
Size > 200 mm <sup>2</sup>
Non-homogenous type
Presence of epithelial dysplasia

Early detection of premalignant lesions and oral cancer is very important. Therefore, miscellaneous modalities such as oral cavity examination, supravital staining, oral cytology and optical technologies including spectroscopy, fluorescence spectroscopy, elastic scattering (reflectance) spectroscopy, Raman spectroscopy, fluorescence imaging, optical coherence tomography, narrow-band imaging, and multimodal optical imaging may be used<sup>[10]</sup>.

We think that the following criteria should be taken into consideration in terms of the importance of early diagnosis: (1) symptomatic and/or non-symptomatic non-healing lesions of oral mucosa; (2) history of smoking, chewing tobacco, alcohol consumption, oral HPV infection, drug use, long-term exposure to sunlight; (3) advanced age; (4) the presence of immunodeficiency; (5) the presence of genetic disease; and (6) poor oral hygiene.

## ORAL LEUKOPLAKIA

Leukoplaki is defined as “A white plaque of questionable risk having excluded (other) known diseases or disorders that carry no increased risk for cancer”<sup>[1]</sup>. In studies reported in recent years, the prevalence of oral leukoplakia varies between 1.1% and 11.7%, with a mean value of 2.9%<sup>[11]</sup>. Although leukoplakia can occur at any age, it often occurs in individuals under the age of 40<sup>[12]</sup>. Leukoplakia is seen six times more among smokers than among non-smokers<sup>[1]</sup>.

Clinically, leukoplakia may be affect any part of the oral and oropharyngeal cavity and can be divided into two subtypes including homogeneous and non-homogeneous types<sup>[1]</sup>. Homogenous lesions are characterized by uniformly flat, thin, uniformly white in colour and shows shallow cracks of the surface keratin<sup>[1,13]</sup>. Non-homogenous lesions have been defined as a white and red lesion (known as *erythroleukoplakia*) that may be either irregularly flat (speckled) or nodular (Figure 1). Verrucous leukoplakia is yet another type of non-homogenous leukoplakia<sup>[14]</sup>.

Proliferative verrucous leukoplakia, which is a form of verrucous leukoplakia, was first described by Hansen *et al.*<sup>[14,15]</sup> in 1985 and characterized by multifocal presentation. It has a strong potential for malignant transformation and is resistance to treatment.

Histopathologically, two distinct appearances may be seen as dysplastic or non-dysplastic leukoplakia. Risk factors of malignant transformation are shown in Table 1<sup>[14]</sup>.

Oral leukoplakia should be distinguished from miscellaneous benign and/or potentially malignant disorders

that may be seen white or predominantly white diseases of the oral mucosa. The diseases should be considered in the differential diagnosis including aspirin burn, chemical injury, oral pseudomembranous and hyperplastic candidiasis, frictional lesions, oral hairy leukoplakia, leukoedema, linea alba, lupus erythematosus, morsicatio buccarum, papilloma and allied lesions, mucous patches in secondary syphilis, tobacco-induced lesions, smoker's palate (nicotinic stomatitis), stuff-induced lesion, white sponge nevus, oral lichen planus (OLP), and lichenoid reaction<sup>[1,13]</sup>.

Oral leukoplakia should be confirmed by mucosal biopsy. But before biopsy, some staining methods may be used as a diagnostic aid. Chen *et al*<sup>[16]</sup> used methylene blue in fifty-eight patients with suspicious oral cavity lesions. They reported that the overall sensitivity of methylene blue uptake in cases with suspected lesions was 90%, specificity 69%, and accuracy 79%. They also reported that the positive predictive value was 74% and the negative predictive value 87%<sup>[16]</sup>.

The most commonly preferred treatment options are surgical excision or CO<sub>2</sub> laser therapy. In widespread lesions, photodynamic therapy may be considered<sup>[14]</sup>. Cryotherapy is another preferred destructive method<sup>[17]</sup>. Non-surgical treatment modalities might be considered in selected patients. Carotenoids ( $\beta$ -carotene, lycopene), vitamins [L-ascorbic acid (vitamin C),  $\alpha$ -tocopherol (vitamin E), retinoic acid (vitamin A), and fenretinide], and bleomycin may be used in patients with oral leukoplakia<sup>[18]</sup>.

Surgical excision should be recommended in the presence of moderate and severe epithelial dysplasia. Reported recurrence ratios after surgery treatment have been varied between 10% and 35%<sup>[18]</sup>. Kawczyk-Krupka *et al*<sup>[19]</sup> compared to efficacy of cryotherapy and photodynamic treatment and reported that complete responses were obtained in 72.9% and 89.2% of patients in groups treated by photodynamic treatment and cryotherapy, respectively. Recurrence ratios were reported as 27.1% and 24.3% in groups treated by photodynamic treatment and cryotherapy, respectively<sup>[19]</sup>. Pietruska *et al*<sup>[20]</sup> reported significant reduction (on average by 53.8%) of leukoplakia lesions sizes after photodynamic therapy. Among patients treated by topical retinoic acid, while complete response ratio was reported between 10% and 27% of patients, partial response ratio was reported between 54% and 90% of patients. Recurrence of leukoplakia was reported as approximately 50% after withdrawing the topical retinoic acid<sup>[21]</sup>.

## ORAL ERYTHROPLAKIA

Erythroplakia is defined as "A fiery red patch that cannot be characterized clinically or pathologically as any other definable disease". Clinical appearance is characterized by flat or even depressed erythematous change of the mucosa without a patch lesion. Both red and white changes in the same lesion refer to as "*erythroleukoplakia*". Prevalence of erythroplakia varies between 0.02% and 0.83%. It mainly occurs in the middle aged and the elderly. Male gender is most frequently affected. Mostly, a solitary le-

sion occurs over the surface of any part of the oral cavity. But the most commonly affected areas were reported as the soft palate, the floor of the mouth, and the buccal mucosa<sup>[14,22]</sup>.

Etiopathogenesis is not known exactly<sup>[22]</sup>. Chewing tobacco and alcohol use are the possible etiologic factors for the development erythroplakia. Hashibe *et al*<sup>[23]</sup> reported that chewing tobacco and alcohol drinking are strong risk factors for erythroplakia in the Indian population. High prevalence of p53 mutations in premalignant oral erythroplakia was reported in a study designed by Qin *et al*<sup>[7]</sup>.

Clinically, typical lesion of oral erythroplakia is less than 1.5 cm in diameter, but it also be less than 1 cm and larger than 4 cm<sup>[22]</sup>. Histopathologically, moderate or severe dysplasia was usually seen in lesion with erythroplakia. Malignant transformation rates is very high (vary from 14% to 50%), so it needs to be treated expeditiously<sup>[14,22]</sup>.

Oral erythroplakia should be diminished from any disease which clinically appears red colour in oral cavity. Oral candidiasis, oral histoplasmosis, oral tuberculosis, atrophic OLP, lupus erythematosus, pemphigus, pemphigoids, amelanotic melanoma, haemangioma, telangiectasia, lingual varices, Kaposi's sarcoma, early squamous cell carcinoma, local irritation, mucositis, drug reaction, median rhomboid glossitis, and oral purpura may be confused with oral erythroplakia<sup>[22,24]</sup>.

Owing to the high malignant transformation rate, early effective treatment is mandatory<sup>[22]</sup>. Surgery, either by cold knife or by laser, is the recommended therapy<sup>[1]</sup>. Surgical excision may be used in lesions with severe epithelial dysplasia or carcinoma *in situ*<sup>[22]</sup>.

## OLP

Lichen planus was first described by Erasmus Wilson in 1869<sup>[25]</sup>. The disease is a chronic, autoimmune, inflammatory disease which may affect skin, oral mucosa, genital mucosa, scalp, and nails<sup>[26]</sup>. Prevalence of OLP varies from 0.5% to 3%<sup>[25]</sup>. It mainly occurs among female gender and the age of onset is usually between third and sixth decade<sup>[25,27]</sup>.

Although it is believed that OLP is a T-cell mediated autoimmune disease, its cause is partially understood in most cases<sup>[28]</sup>. Several factors have been proposed for the etiology including genetic background, dental materials (amalgam, metals, gold, and composite restorations), drugs (especially antimalarials, cardiovascular agents, gold salts, non-steroidal anti-inflammatory drugs, hypoglysemics), infectious agents (herpes simplex virus, Epstein-Barr virus, cytomegalovirus, herpes virus-6, hepatitis-C virus, and human papilloma virus), autoimmunity, immunodeficiency, food allergies, stress, habits, trauma, diabetes and hypertension, malignant neoplasms, and bowel disease<sup>[26,29,30]</sup>.

Even though OLP may affect any part of the oral mucosa, most commonly affected areas are dorsum of the tongue (Figure 2), buccal mucosa (Figure 3), and gin-

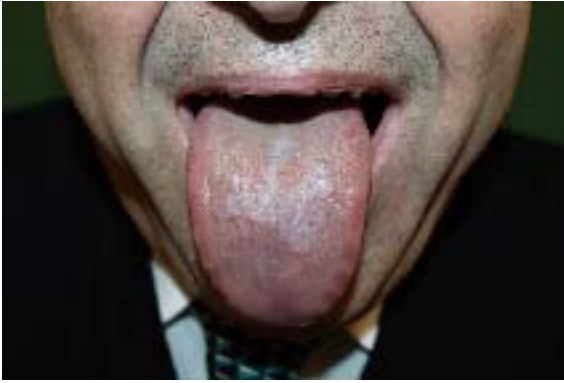

Figure 2 Liken planus lesions on the dorsum of the tongue.

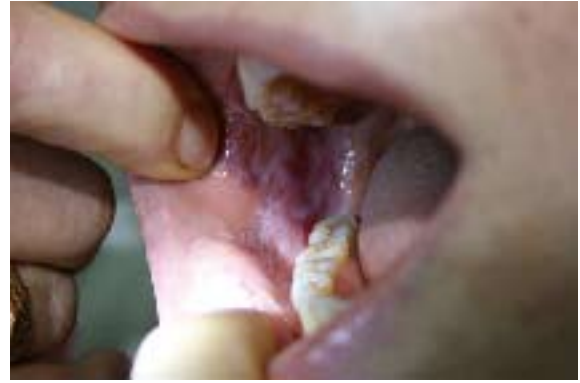

Figure 3 Reticular pattern lesions on the buccal mucosa.

giva<sup>[26]</sup>. Clinically, OLP may be seen as six types including papular, reticular, plaque-like, atrophic, erosive, and bullous type<sup>[25]</sup>. The most common type is the reticular pattern which present as fine white striae known as “*Wickham's striae*”. Typically, lesions present symmetrically and bilaterally, and usually asymptomatic. Atrophic pattern presents as a red lesion. Erosive pattern is usually seen as irregular erosion or ulceration covered with a fibrinous plaque or pseudomembrane. Both atrophic and erosive pattern are generally associated with a burning sensation and pain that exacerbated by trauma and hot, spicy or acidic foods. Plaque type clinically resembles leukoplakia because of its homogenous white nature. The dorsum of the tongue and buccal mucosa are the most affected areas in the oral cavity of patients with plaque type OLP. Multifocal plaque type lesions may be seen. This subtype is more common among tobacco smokers. The papular pattern, which is rarely seen, is characterized by small, white, raised papules with fine white striation at the periphery of the lesion. Bullous pattern is the least common type of OLP that characterized by bullae formation range from a few millimeters to several centimeters in diameter<sup>[26]</sup>.

In 1906, Dubrell first described the histologic features of OLP, but within the next years, it has been revised. Diagnostic histologic features include liquefactive degeneration of the basal cells, colloid bodies (known as *Civatte* bodies), homogenous infiltrate of lymphocytes in a dense, band-like pattern along the epithelium-connective tissue interface in the superficial dermis, cytologically normal maturation of the epithelium, sawtooth rete ridges, and hyperkeratosis. In erosive lichen planus, ulceration may be seen in the surface epithelium<sup>[31]</sup>.

The first case of OLP-related oral carcinoma was reported by François Henri Hallopeau in 1910. Malignant transformation ratio has been reported in 0% to 10% of patients, according to the sample's characteristics and study design, after mean follow-up of 1.5 to 10 years<sup>[25]</sup>. Increased malignant transformation risk occurs greater in erosive and atrophic forms and in cases of lesions of lateral border of the tongue<sup>[27]</sup>.

If there are Wickham's striae typically, the diagnosis is easy and can be made clinically, especially reticular

pattern of OLP. But erosive or atrophic pattern need to be confirmed by biopsy in order to make the correct diagnosis<sup>[32]</sup>. Direct immunofluorescence may be useful to distinguish from some bullous diseases such as pemphigus vulgaris, benign mucous membrane pemphigoid, and linear immunoglobulin A (IgA) bullous dermatitis<sup>[31]</sup>. IgA, IgG, IgM or C3 deposition throughout the basement membrane and irregular fibrinogen deposition in the basement membrane are the diagnostic immunofluorescence findings in OLP and positivity rate is 65.8% of the patients with OLP<sup>[33]</sup>. Indirect immunofluorescence studies are not useful in terms of diagnosis<sup>[32]</sup>.

Patients with reticular and other asymptomatic OLP can be followed without treatment. But if there are any symptoms and/or potential malignant risk, lesions should be treated. Both topical and systemic treatment modalities have been reported for OLP, shown in Table 2<sup>[31,34-36]</sup>.

## ORAL SUBMUCOUS FIBROSIS

Oral submucous fibrosis, was first described by Schwartz in 1952, is chronic and potentially malignant disorder characterized by juxtaepithelial fibrosis of the oral cavity. Fibroelastic change of the lamina propria and epithelial atrophy occur in consequence of juxta epithelial inflammatory reaction, and eventually, stiffness of oral mucosa, trismus and an inability to eat develops<sup>[37]</sup>.

OSMF is usually seen in Asians population (particularly Indians) from the southern states and Taiwanese. Predominantly, it occurs in the second and third decade, and both sexes may be affected<sup>[37]</sup>. But in patients with pediatric age group were rarely seen<sup>[38-40]</sup>. Paymaster firstly described its premalignant nature in 1956. This malignant transformation rate was reported 7%-30%<sup>[37]</sup>.

Its etiology is not well-known and thought to be multifactorial<sup>[37]</sup>. The strongest risk factor for OSMF is the chewing of betel quid containing areca nut. Other factors like genetic and immunologic predisposition also play a role in OSMF because of reported in families whose members are not in the habit of chewing betel quid or areca nut<sup>[41]</sup>. Ranganathan *et al.*<sup>[42]</sup> designed a case-control study consisting of 185 patients in Chennai, South India and reported strong association between areca nut



**Table 2** Miscellaneous treatment regimens for oral lichen planus

Topical treatments	Systemic treatments	Surgery
Corticosteroids (triamcinolone, fluocinolone acetoneide, fluocinonide, clobetasol, fluticasone propionate, betamethasone sodium phosphate, mometasone furoate)	Corticosteroids Acitretin Azathioprine Basiliximab Cyclosporin Dapsone Eiconol Enoxaparin Glycyrrhizin	Resection Cryotherapy Lasers (CO <sub>2</sub> , excimer laser)
Cyclosporin Tacrolimus Pimekrolimus Rapamycin (sirolimus) Retinoids (tretinoin, isotretinoin) Aloe vera Hyaluronic acid 0.2% gel	Hydroxychloroquine Interferon alpha Levamisole Mycophenolate mofetil Thalidomide Tetracycline Mesalazine Phenytoin Griseofulvin	

use and OSMF. Mehrotra *et al*<sup>[43]</sup> firstly investigated lipid profile in Indian patients with OSMF, and they observed a significant decrease in plasma total cholesterol, high-density lipoprotein cholesterol (HDL) cholesterol and Apo-A1 in patients with OSMF as compared to the controls. Similarly, Kumar *et al*<sup>[44]</sup> reported a statistically significant decrease in plasma total cholesterol, LDL and HDL cholesterol in patients with OSMF as compared to controls. Arakeri *et al*<sup>[45,46]</sup> observed that the mean concentration of copper in the home drinking water of patients with OSMF was significantly higher than in controls. Patients with OSMF also had a significantly higher copper concentration in serum and saliva, and serum ceruloplasmin than controls<sup>[45,46]</sup>. Aggarwal *et al*<sup>[47]</sup> reported that the serum beta carotene levels was significantly lower in patients with OSMF than in the controls. From these results, authors suggested that beta carotene plays an important role in the pathogenesis of OSMF and should be treated with a diet rich in beta carotene in order to reduce disease severity and progression towards malignancy<sup>[47]</sup>. Higher mast cell density as another possible pathogenic factor in patients with OSMF was suggested by Del Vecchio *et al*<sup>[48]</sup>.

Symptoms such as burning sensation and/or intolerance to spicy food are the most common symptoms in the initial phase of the disease. Over time, it gradually progresses and fibrosis develops that can affect mouth opening<sup>[37]</sup>. Haider *et al*<sup>[49]</sup> proposed clinical and functional staging of OSMF, shown in Table 3.

Isaac *et al*<sup>[50]</sup> investigated histopathologic features of OSMF and observed some mucosal and submucosal changes. Mucosal changes such as atrophic changes, pigment incontinence, ulceration with granulation tissue, hyperplastic changes, dysplasia, and carcinoma were seen 74.3%, 62.8%, 40%, 25.7%, 8.6% and 0%, respectively. Submucosal changes such as fibrosis, diffuse chronic inflammatory infiltrate, atrophy of minor salivary glands, skeletal muscle atrophy, bandlike infiltrate, edema and

**Table 3** Clinical and functional staging

Clinical stage	Functional stage
Faucial bands only	Mouth opening $\geq$ 20 mm
Faucial and buccal bands	Mouth opening 11-19 mm
Faucial, buccal, and labial bands	Mouth opening $\leq$ 10 mm

congestion, and vesicle formation were observed 100%, 100%, 85.7%, 57.1%, 45.7%, 22.8%, and 2.8%, respectively<sup>[50]</sup>.

Three current treatment modalities including surgical, physical, and medical are available for the management of OSMF. Surgical treatments may be used to improve mouth opening and movements. Physical treatment including physical exercise regimen, splints or other mouth opening devices, and microwave diathermy may be useful in some patients with OSMF. There are numerous medical therapy alternatives such as steroids, interferon gamma, placental extracts, immunized milk, pentoxifylline, buflomedil hydrochloride, nyldrin, isoxsuprine,  $\beta$ -carotene, lycopene, vitamins, micronutrients, collagenase, hyaluronidase, chymotrypsin, and aloe vera<sup>[37,51-57]</sup>.

## ACTINIC CHEILITIS

Actinic cheilitis is a potentially malignant disease of the lip caused by exposure solar radiation. It is commonly seen the surface area of the lower lip due to the anatomic proximity. In addition to solar rays, tobacco use, lip irritation, poor oral hygiene, and ill-fitting dentures may play a role in the development of actinic cheilitis. The disease predominantly occurs in men compared to the women<sup>[58]</sup>. Martins-Filho *et al*<sup>[59]</sup> reported that the prevalence of actinic cheilitis in farmers in a semi-arid area of Brasil was 16.7%.

While actinic cheilitis shows erythema and edema in the early stages of the disease, diffuse scaling, thickened epithelium with small greyish-white plaques (known as *leukoplakia*), inflammatory areas (known as *erythroleukoplakia*), and linear fissures may present in the late stages of the disease<sup>[58]</sup>. Malignant transformation rate has been estimated ranging from 1.4% to 36% at an interval of 1 to 30 years<sup>[60]</sup>. Diagnosis should be confirmed by biopsy to evaluate the degree of dysplasia. Histopathologically, hyperplasia, acanthosis or atrophy of the epithelium, thickening of the keratin layer, and/or dysplasia, which may range from mild to severe, may be shown. In addition to these epithelial changes, in connective tissue, basophilic degeneration of collagen fibers, known as solar elastosis, is usually detected<sup>[61]</sup>.

In treatment, 5-fluorouracil, scalpel vermilionectomy, chemical peel, electrosurgery, cryosurgery, CO<sub>2</sub> laser, imiquimod, photodynamic treatment, diclofenac 0.3% gel can be preferred<sup>[58,60,62]</sup>.

## SOME INHERITED CANCER SYNDROMES

In patients with xeroderma pigmentosum and Fanconi's anemia, incidence of oral cancer has increased<sup>[1]</sup>.



## IMMUNODEFICIENCY

In patients with prolonged use of immunosuppressive drugs after solid organ transplants, human immunodeficiency virus-patients, and chronic graft versus host disease after stem cell transplantation are the patients in risk group for oral cancer development<sup>[1]</sup>.

## REFERENCES

- 1 **van der Waal I.** Potentially malignant disorders of the oral and oropharyngeal mucosa; terminology, classification and present concepts of management. *Oral Oncol* 2009; **45**: 317-323 [PMID: 18674954 DOI: 10.1016/j.oraloncology.2008.05.016]
- 2 **Thomas G,** Hashibe M, Jacob BJ, Ramadas K, Mathew B, Sankaranarayanan R, Zhang ZF. Risk factors for multiple oral premalignant lesions. *Int J Cancer* 2003; **107**: 285-291 [PMID: 12949809]
- 3 **Phookan J,** Saikia KP. A clinicopathological study of the premalignant conditions of oral cavity. *Indian J Otolaryngol Head Neck Surg* 1998; **50**: 246-249 [PMID: 23119427 DOI: 10.1007/BF03007000]
- 4 **Vlková B,** Stanko P, Minárik G, Tóthová L, Szemes T, Baňasová L, Novotnáková D, Hodosy J, Celec P. Salivary markers of oxidative stress in patients with oral premalignant lesions. *Arch Oral Biol* 2012; **57**: 1651-1656 [PMID: 23092610 DOI: 10.1016/j.archoralbio.2012.09.003]
- 5 **Nanda KD,** Ranganathan K, Devi U, Joshua E. Increased expression of CK8 and CK18 in leukoplakia, oral submucous fibrosis, and oral squamous cell carcinoma: an immunohistochemistry study. *Oral Surg Oral Med Oral Pathol Oral Radiol* 2012; **113**: 245-253 [PMID: 22677743 DOI: 10.1016/j.tripleo.2011.05.034]
- 6 **Feng JQ,** Mi JG, Wu L, Ma LW, Shi LJ, Yang X, Liu W, Zhang CP, Zhou ZT. Expression of podoplanin and ABCG2 in oral erythroplakia correlate with oral cancer development. *Oral Oncol* 2012; **48**: 848-852 [PMID: 22525603 DOI: 10.1016/j.oraloncology.2012.03.015]
- 7 **Qin GZ,** Park JY, Chen SY, Lazarus P. A high prevalence of p53 mutations in pre-malignant oral erythroplakia. *Int J Cancer* 1999; **80**: 345-348 [PMID: 9935172]
- 8 **Sciubba JJ.** Oral leukoplakia. *Crit Rev Oral Biol Med* 1995; **6**: 147-160 [PMID: 7548621]
- 9 **Punyani SR,** Sathawane RS. Salivary level of interleukin-8 in oral precancer and oral squamous cell carcinoma. *Clin Oral Investig* 2013; **17**: 517-524 [PMID: 22526890 DOI: 10.1007/s00784-012-0723-3]
- 10 **Steele TO,** Meyers A. Early detection of premalignant lesions and oral cancer. *Otolaryngol Clin North Am* 2011; **44**: 221-229, vii [PMID: 21093631 DOI: 10.1016/j.otc.2010.10.002]
- 11 **Bánóczy J,** Gintner Z, Dombi C. Tobacco use and oral leukoplakia. *J Dent Educ* 2001; **65**: 322-327 [PMID: 11336117]
- 12 **Greer RO.** Pathology of malignant and premalignant oral epithelial lesions. *Otolaryngol Clin North Am* 2006; **39**: 249-275, v [PMID: 16580910]
- 13 **Warnakulasuriya S,** Johnson NW, van der Waal I. Nomenclature and classification of potentially malignant disorders of the oral mucosa. *J Oral Pathol Med* 2007; **36**: 575-580 [PMID: 17944749]
- 14 **van der Waal I.** Potentially malignant disorders of the oral and oropharyngeal mucosa; present concepts of management. *Oral Oncol* 2010; **46**: 423-425 [PMID: 20308005 DOI: 10.1016/j.oraloncology.2010.02.016]
- 15 **Batsakis JG,** Suarez P, el-Naggar AK. Proliferative verrucous leukoplakia and its related lesions. *Oral Oncol* 1999; **35**: 354-359 [PMID: 10645398]
- 16 **Chen YW,** Lin JS, Fong JH, Wang IK, Chou SJ, Wu CH, Lui MT, Chang CS, Kao SY. Use of methylene blue as a diagnostic aid in early detection of oral cancer and precancerous lesions. *Br J Oral Maxillofac Surg* 2007; **45**: 590-591 [PMID: 17081665]
- 17 **Krahl D,** Altenburg A, Zouboulis CC. Reactive hyperplasia as, precancerous and malignant lesions of the oral mucosa. *J Dtsch Dermatol Ges* 2008; **6**: 217-232 [PMID: 18315622 DOI: 10.1111/j.1610-0387.2007.06625.x]
- 18 **Ribeiro AS,** Salles PR, da Silva TA, Mesquita RA. A review of the nonsurgical treatment of oral leukoplakia. *Int J Dent* 2010; **2010**: 186018 [PMID: 20339486 DOI: 10.1155/2010/186018]
- 19 **Kawczyk-Krupka A,** Waśkowska J, Raczkowska-Siostrzonek A, Kościarz-Grzesiok A, Kwiatek S, Straszak D, Latos W, Koszowski R, Sieroń A. Comparison of cryotherapy and photodynamic therapy in treatment of oral leukoplakia. *Photodiagnosis Photodyn Ther* 2012; **9**: 148-155 [PMID: 22594985 DOI: 10.1016/j.pdpdt.2011.12.007]
- 20 **Pietruska M,** Sobaniec S, Bernaczyk P, Cholewa M, Pietruski JK, Dolińska E, Skurska A, Duraj E, Tokajuk G. Clinical evaluation of photodynamic therapy efficacy in the treatment of oral leukoplakia. *Photodiagnosis Photodyn Ther* 2014; **11**: 34-40 [PMID: 24211597 DOI: 10.1016/j.pdpdt.2013.10.003]
- 21 **Gorsky M,** Epstein JB. The effect of retinoids on premalignant oral lesions: focus on topical therapy. *Cancer* 2002; **95**: 1258-1264 [PMID: 12216093]
- 22 **Reichart PA,** Philipsen HP. Oral erythroplakia--a review. *Oral Oncol* 2005; **41**: 551-561 [PMID: 15975518]
- 23 **Hashibe M,** Mathew B, Kuruvilla B, Thomas G, Sankaranarayanan R, Parkin DM, Zhang ZF. Chewing tobacco, alcohol, and the risk of erythroplakia. *Cancer Epidemiol Biomarkers Prev* 2000; **9**: 639-645 [PMID: 10919731]
- 24 **Villa A,** Villa C, Abati S. Oral cancer and oral erythroplakia: an update and implication for clinicians. *Aust Dent J* 2011; **56**: 253-256 [PMID: 21884139 DOI: 10.1111/j.1834-7819.2011.01337.x]
- 25 **Farhi D,** Dupin N. Pathophysiology, etiologic factors, and clinical management of oral lichen planus, part I: facts and controversies. *Clin Dermatol* 2010; **28**: 100-108 [PMID: 20082959 DOI: 10.1016/j.clindermatol.2009.03.004]
- 26 **Ismail SB,** Kumar SK, Zain RB. Oral lichen planus and lichenoid reactions: etiopathogenesis, diagnosis, management and malignant transformation. *J Oral Sci* 2007; **49**: 89-106 [PMID: 17634721]
- 27 **Edwards PC,** Kelsch R. Oral lichen planus: clinical presentation and management. *J Can Dent Assoc* 2002; **68**: 494-499 [PMID: 12323106]
- 28 **Nico MM,** Fernandes JD, Lourenço SV. Oral lichen planus. *An Bras Dermatol* 2011; **86**: 633-641; quiz 642-643 [PMID: 21987126]
- 29 **Roopashree MR,** Gondhalekar RV, Shashikanth MC, George J, Thippeswamy SH, Shukla A. Pathogenesis of oral lichen planus--a review. *J Oral Pathol Med* 2010; **39**: 729-734 [PMID: 20923445 DOI: 10.1111/j.1600-0714.2010.00946.x]
- 30 **Payeras MR,** Cherubini K, Figueiredo MA, Salum FG. Oral lichen planus: focus on etiopathogenesis. *Arch Oral Biol* 2013; **58**: 1057-1069 [PMID: 23660124 DOI: 10.1016/j.archoralbio.2013.04.004]
- 31 **Parashar P.** Oral lichen planus. *Otolaryngol Clin North Am* 2011; **44**: 89-107, vi [PMID: 21093625 DOI: 10.1016/j.otc.2010.09.004]
- 32 **Huber MA.** White oral lesions, actinic cheilitis, and leukoplakia: confusions in terminology and definition: facts and controversies. *Clin Dermatol* 2010; **28**: 262-268 [PMID: 20541677 DOI: 10.1016/j.clindermatol.2009.06.011]
- 33 **Canto AM,** Müller H, Freitas RR, Santos PS. Oral lichen planus (OLP): clinical and complementary diagnosis. *An Bras Dermatol* 2010; **85**: 669-675 [PMID: 21152791]
- 34 **Scully C,** Carrozzo M. Oral mucosal disease: Lichen planus. *Br J Oral Maxillofac Surg* 2008; **46**: 15-21 [PMID: 17822813]
- 35 **Radwan-Oczko M.** Topical application of drugs used in treatment of oral lichen planus lesions. *Adv Clin Exp Med* 2013; **22**: 893-898 [PMID: 24431320]
- 36 **Lodi G,** Scully C, Carrozzo M, Griffiths M, Sugerman PB, Thongprasom K. Current controversies in oral lichen planus: report of an international consensus meeting. Part 2. Clinical management and malignant transformation. *Oral Surg Oral*

- Med Oral Pathol Oral Radiol Endod* 2005; **100**: 164-178 [PMID: 16037774]
- 37 **Arakeri G**, Brennan PA. Oral submucous fibrosis: an overview of the aetiology, pathogenesis, classification, and principles of management. *Br J Oral Maxillofac Surg* 2013; **51**: 587-593 [PMID: 23107623 DOI: 10.1016/j.bjoms.2012.08.014]
  - 38 **Mundra RK**, Gupta SK, Gupta Y. Oral submucous fibrosis in paediatric age group. *Indian J Otolaryngol Head Neck Surg* 1999; **51**: 60-62 [PMID: 23119548 DOI: 10.1007/BF02996533]
  - 39 **Gupta VK**, Malhotra S, Patil R, Tripathi A. Oral submucous fibrosis at pediatric age, now time to think: Series of two cases. *Indian J Med Paediatr Oncol* 2013; **34**: 107-110 [PMID: 24049299 DOI: 10.4103/0971-5851.116194]
  - 40 **Dhariwal R**, Ray JG, Pattanayak SM, Swain N. Oral submucous fibrosis: a report of two pediatric cases and a brief review. *J Indian Soc Pediatr Prev Dent* 2012; **30**: 85-88 [PMID: 22565524 DOI: 10.4103/0970-4388.95592]
  - 41 **Auluck A**, Rosin MP, Zhang L, Sumanth KN. Oral submucous fibrosis, a clinically benign but potentially malignant disease: report of 3 cases and review of the literature. *J Can Dent Assoc* 2008; **74**: 735-740 [PMID: 18845065]
  - 42 **Ranganathan K**, Devi MU, Joshua E, Kirankumar K, Saraswathi TR. Oral submucous fibrosis: a case-control study in Chennai, South India. *J Oral Pathol Med* 2004; **33**: 274-277 [PMID: 15078487]
  - 43 **Mehrotra R**, Pandya S, Chaudhary AK, Singh HP, Jaiswal RK, Singh M, Gupta SC, Singh M. Lipid profile in oral submucous fibrosis. *Lipids Health Dis* 2009; **8**: 29 [PMID: 19630946 DOI: 10.1186/1476-511X-8-29]
  - 44 **Kumar P**, Singh A, Sankhla B, Naraniya A. Alteration in plasma lipid profile in oral submucous fibrosis patients: A case control study. *South Asian J Cancer* 2013; **2**: 147-149 [PMID: 24455599 DOI: 10.4103/2278-330X.114134]
  - 45 **Arakeri G**, Patil SG, Ramesh DN, Hunasgi S, Brennan PA. Evaluation of the possible role of copper ions in drinking water in the pathogenesis of oral submucous fibrosis: a pilot study. *Br J Oral Maxillofac Surg* 2014; **52**: 24-28 [PMID: 23434268 DOI: 10.1016/j.bjoms.2013.01.010]
  - 46 **Arakeri G**, Hunasgi S, Colbert S, Merckx MA, Brennan PA. Role of drinking water copper in pathogenesis of oral submucous fibrosis: a prospective case control study. *Br J Oral Maxillofac Surg* 2014; **52**: 507-512 [PMID: 24812020 DOI: 10.1016/j.bjoms.2014.03.023]
  - 47 **Aggarwal A**, Shetti A, Keluskar V, Bagewadi A. Estimation of serum beta carotene levels in patients with oral submucous fibrosis in India. *J Oral Sci* 2011; **53**: 427-431 [PMID: 22167026]
  - 48 **Del Vecchio A**, Palaia G, Tenore G, Russo N, Romeo U. The photodynamical treatment of oral verrucous proliferative leukoplakia. Case report at 18 months follow up. *Ann Stomatol (Roma)* 2013; **4**: 13-14 [PMID: 24353771]
  - 49 **Haider SM**, Merchant AT, Fikree FF, Rahbar MH. Clinical and functional staging of oral submucous fibrosis. *Br J Oral Maxillofac Surg* 2000; **38**: 12-15 [PMID: 10783440]
  - 50 **Isaac U**, Issac JS, Ahmed Khoso N. Histopathologic features of oral submucous fibrosis: a study of 35 biopsy specimens. *Oral Surg Oral Med Oral Pathol Oral Radiol Endod* 2008; **106**: 556-560 [PMID: 18718788 DOI: 10.1016/j.tripleo.2006.11.045]
  - 51 **Mehrotra R**, Singh HP, Gupta SC, Singh M, Jain S. Pentoxifylline therapy in the management of oral submucous fibrosis. *Asian Pac J Cancer Prev* 2011; **12**: 971-974 [PMID: 21790236]
  - 52 **Bhadage CJ**, Umarji HR, Shah K, Vålímáa H. Vasodilator isoxsuprine alleviates symptoms of oral submucous fibrosis. *Clin Oral Investig* 2013; **17**: 1375-1382 [PMID: 22893038 DOI: 10.1007/s00784-012-0824-z]
  - 53 **Angadi PV**, Rao S. Management of oral submucous fibrosis: an overview. *Oral Maxillofac Surg* 2010; **14**: 133-142 [PMID: 20177949 DOI: 10.1007/s10006-010-0209-x]
  - 54 **Haque MF**, Meghji S, Nazir R, Harris M. Interferon gamma (IFN-gamma) may reverse oral submucous fibrosis. *J Oral Pathol Med* 2001; **30**: 12-21 [PMID: 11140895]
  - 55 **Sudarshan R**, Annigeri RG, Sree Vijayabala G. Aloe vera in the treatment for oral submucous fibrosis - a preliminary study. *J Oral Pathol Med* 2012; **41**: 755-761 [PMID: 22650317 DOI: 10.1111/j.1600-0714.2012.01168.x]
  - 56 **Kumar A**, Bagewadi A, Keluskar V, Singh M. Efficacy of lycopene in the management of oral submucous fibrosis. *Oral Surg Oral Med Oral Pathol Oral Radiol Endod* 2007; **103**: 207-213 [PMID: 17234537]
  - 57 **Alam S**, Ali I, Giri KY, Gokkulakrishnan S, Natu SS, Faisal M, Agarwal A, Sharma H. Efficacy of aloe vera gel as an adjuvant treatment of oral submucous fibrosis. *Oral Surg Oral Med Oral Pathol Oral Radiol* 2013; **116**: 717-724 [PMID: 24237724 DOI: 10.1016/j.oooo.2013.08.003]
  - 58 **Dufresne RG**, Curlin MU. Actinic cheilitis. A treatment review. *Dermatol Surg* 1997; **23**: 15-21 [PMID: 9107289]
  - 59 **Martins-Filho PR**, Da Silva LC, Piva MR. The prevalence of actinic cheilitis in farmers in a semi-arid northeastern region of Brazil. *Int J Dermatol* 2011; **50**: 1109-1114 [PMID: 22126872 DOI: 10.1111/j.1365-4632.2010.04802.x]
  - 60 **Vieira RA**, Minicucci EM, Marques ME, Marques SA. Actinic cheilitis and squamous cell carcinoma of the lip: clinical, histopathological and immunogenetic aspects. *An Bras Dermatol* 2012; **87**: 105-114 [PMID: 22481658]
  - 61 **de Santana Sarmiento DJ**, da Costa Miguel MC, Queiroz LM, Godoy GP, da Silveira EJ. Actinic cheilitis: clinicopathologic profile and association with degree of dysplasia. *Int J Dermatol* 2014; **53**: 466-472 [PMID: 24320079 DOI: 10.1111/ijd.12332]
  - 62 **Shah AY**, Doherty SD, Rosen T. Actinic cheilitis: a treatment review. *Int J Dermatol* 2010; **49**: 1225-1234 [PMID: 20964646 DOI: 10.1111/j.1365-4632.2010.04580.x]

**P-Reviewer:** Galiatsatos AA, Tomofuji T **S-Editor:** Tian YL  
**L-Editor:** A **E-Editor:** Wu HL



## Eosinophilic chronic rhinosinusitis in East Asians

En-Tong Wang, Yan Zheng, Peng-Fei Liu, Li-Juan Guo

En-Tong Wang, Yan Zheng, Peng-Fei Liu, Li-Juan Guo, Department of Otolaryngology, Head and Neck Surgery, Air Force General Hospital, Beijing 100142, China

**Author contributions:** Wang ET contributed to the study design and wrote the review; Zheng Y, Liu PF and Guo LJ were involved in the acquisition, analysis and interpretation of data.

**Correspondence to:** En-Tong Wang, MD, PhD, Department of Otolaryngology, Head and Neck Surgery, Air Force General Hospital, 30 Fucheng Road, Beijing 100142, China. [wang\\_entong@sina.com](mailto:wang_entong@sina.com)

Telephone: +86-10-88420757 Fax: +86-10-88420757

Received: June 25, 2014 Revised: August 28, 2014

Accepted: September 16, 2014

Published online: December 16, 2014

© 2014 Baishideng Publishing Group Inc. All rights reserved.

**Key words:** Chronic rhinosinusitis; Eosinophilic chronic rhinosinusitis; Eosinophils; Chronic rhinosinusitis with nasal polyps; Nasal polyps

**Core tip:** Chronic rhinosinusitis (CRS) is a common disease and currently classified into two types based on presence or absence of nasal polyps. CRS may also be subtyped into eosinophilic CRS (ECRS) and non-ECRS according to the presence of predominant tissue eosinophilic infiltration or not. ECRS differs significantly from non-ECRS in clinical characteristics, treatment outcomes and strategies, and underlying pathogenic mechanisms. ECRS is considered a special and recalcitrant subtype of CRS. The identification of ECRS is helpful to develop treatment strategies for this CRS subtype. Herein we review the clinical features, diagnosis, treatment and prognosis of ECRS in East Asians.

### Abstract

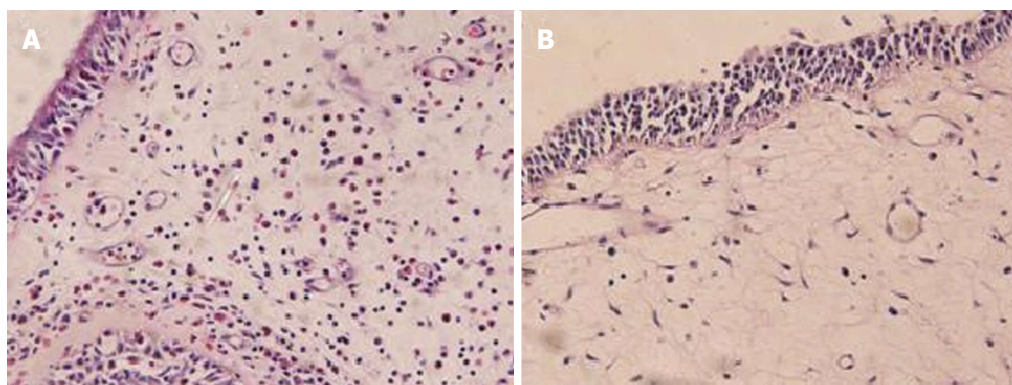
Chronic rhinosinusitis (CRS) is a common disease worldwide, with a prevalence rate of 5%-15% in the general population. CRS is currently classified into two types: CRS with and without nasal polyps. CRS may also be divided into eosinophilic CRS (ECRS) and non-ECRS subtypes based on the presence of tissue eosinophilic infiltration or not. There are significant geographic and ethnic differences in the tissue eosinophilic infiltration, which is predominant in Western white patients and less common in East Asians, despite an increasing tendency for its prevalence in East Asia countries. ECRS differs significantly from non-ECRS in clinical characteristics, treatment outcomes and strategies, and underlying pathogenic mechanisms. ECRS commonly demonstrates more severe symptoms, polyp diseases with a higher incidence of bilateral polyps and sinonasal diseases on computed tomography, and the increase in blood eosinophils. ECRS is considered a special and recalcitrant subtype of CRS, commonly with poor treatment outcomes compared to non-ECRS. The differentiation of specific subtypes and clinical features of CRS will be important for developing novel treatment strategies and improving treatment outcomes for individual phenotypes of CRS. This review discusses clinical features, diagnosis, treatment and prognosis of ECRS in East Asians.

Wang ET, Zheng Y, Liu PF, Guo LJ. Eosinophilic chronic rhinosinusitis in East Asians. *World J Clin Cases* 2014; 2(12): 873-882  
Available from: URL: <http://www.wjgnet.com/2307-8960/full/v2/i12/873.htm> DOI: <http://dx.doi.org/10.12998/wjcc.v2.i12.873>

### INTRODUCTION

Chronic rhinosinusitis (CRS) is one of the most common chronic diseases worldwide, with a prevalence rate of 5%-15% in the general population in Europe and the United States<sup>[1]</sup> and 7% in South Korea<sup>[2]</sup>. CRS remains a significant public health problem with a considerable socioeconomic burden<sup>[3]</sup>. In the current practice guidelines of Europe, the United States and China, CRS is classified into two types based on the presence or absence of nasal polyps: CRS with nasal polyps (CRSwNP) and CRS without nasal polyps (CRSSNP)<sup>[1,4,5]</sup>. Eosinophilic inflammation is considered a major pathologic hallmark of CRS. Histological studies demonstrate the predominant tissue eosinophilic infiltration with a high proportion of CRS





**Figure 1 Hematoxylin and eosin staining for nasal polyp tissues.** Predominant eosinophil infiltration is showed in the subtype of eosinophilic chronic rhinosinusitis with nasal polyps (A), but other forms of inflammatory cell infiltration in the subtype of non-eosinophilic chronic rhinosinusitis with nasal polyps (B) ( $\times 400$ ).

cases, most prominently with CRSwNP cases<sup>[1]</sup>. Thus, CRS may be classified into two subtypes: eosinophilic CRS (ECRS) and non-eosinophilic CRS (NECRS). Similarly, CRSwNP may also be subclassified into ECRSwNP and NECRSwNP<sup>[6-19]</sup>. However, the tissue eosinophilic infiltration in CRS shows significant geographic and ethnic differences. Eosinophilic infiltration is predominantly observed in Western white patients with CRS, accounting for more than 80% of CRS cases<sup>[1,4,18]</sup>, while the eosinophilic phenotype is less than 50% of CRS cases in East Asia countries including Japan<sup>[13-15,20]</sup>, South Korea<sup>[17,21,22]</sup> and China<sup>[11,16,23,24]</sup>. However, recent studies indicate an increasing tendency for the prevalence of ECRS in these Asia countries<sup>[12,13,15,20,21,25]</sup>. Studies show that ECRS differs significantly from NECRS in clinical characteristics, underlying pathogenic mechanisms, treatment outcomes and strategies<sup>[1,6,10,11,13,15,16,20,26-28]</sup>. ECRS is considered a special subtype of CRS<sup>[10,13,15]</sup> and also a subtype of recalcitrant CRS, which commonly has worse disease severity<sup>[8,18,19,29]</sup> and poorer treatment outcomes<sup>[19,28,30]</sup> compared to NECRS. For example, ECRSwNP is refractory to the combined treatments of endoscopic sinus surgery (ESS) and macrolide therapy and shows a strong tendency for recurrence after surgery but responds to systemic steroid therapy<sup>[13-15]</sup>. Thus, identifying specific subtypes of CRS and underlying pathogenic mechanisms will be important for developing novel treatment strategies and improving treatment outcomes for individual phenotypes of CRS<sup>[10,29]</sup>.

## ROLES OF EOSINOPHILS IN ECRS

CRS is a heterogeneous disease to which numerous etiologies contributed. Although intensive investigations have been performed, the etiology, pathogenesis and underlying mechanisms of CRS are not fully understood<sup>[1,15,31,32]</sup>. The dominant eosinophilic inflammation for CRS indicates that eosinophils play a key role in the pathogenesis of CRS, especially in CRSwNP<sup>[1]</sup>, although many kinds of other inflammatory cells including neutrophils, mast cells, lymphocytes and plasma cells also have important roles in the pathogenesis of CRS<sup>[27,33]</sup> (Figure 1).

Eosinophils develop from CD34<sup>+</sup> progenitors in the

bone marrow and migrate into the bloodstream, and they are recruited to disease sites by chemokines or cytokines, where eosinophils can perform and participate in a variety of functions, including antigen presentation, cytokine or chemokine production, and secretion of granule mediators<sup>[34-36]</sup>. The ability of eosinophils to process and present antigens has been generally underestimated and this function can be added to the growing list of mechanisms by which eosinophils regulate the immune system<sup>[34]</sup>. Eosinophils store preformed cytokines in granules that can be released rapidly upon antigenic provocation<sup>[36]</sup>. These eosinophil-derived cytokines can be T helper 2 (Th2) cytokines such as interleukin (IL)-13 that act directly on T cells, as well as other inflammatory cytokines that can prime antigen presenting cells and the vascular endothelium to secrete chemokines and cytokines that recruit and activate T cells<sup>[34]</sup>.

Studies indicate significant roles of T cell regulation in CRS. CRS appears to be a disease mediated by CD4<sup>+</sup> T cells that can be functionally divided into Th1 or Th2 phenotype based on their patterns of cytokine secretion. It is found that among West white patients with CRS, CRSsNP is characterized by Th1 polarization, whereas CRSwNP by predominant Th2, with high levels of Th2-type cytokines including IL-4, IL-5 and IL-13<sup>[37]</sup>. CRSwNP also is characterized by a Th2-driven eosinophilic inflammation in tissue<sup>[37,38]</sup>. However, studies suggest that East Asians with CRSwNP present different immunopathologic features compared with West white patients<sup>[17,24,39]</sup>. For example, CRSwNP in Chinese demonstrates a Th1/Th17 cell pattern with minor eosinophilic inflammation<sup>[24]</sup>. Th2-dominated reactions can only be found in ECRSwNP instead of all CRSwNP cases, suggesting that Th cell responses may exert different impacts on the pathogenesis of ECRSwNP and NECRSwNP<sup>[16,17,24]</sup>. There are interactions between T cells and eosinophils. It is conventionally viewed that the T cell–eosinophil interactions are primarily based on the activation of eosinophils by T cells *via* cytokines, but it is suggested that eosinophils also have the capacity to activate T cells to produce cytokines<sup>[40,41]</sup>. Eosinophils by secreting specific cytokines or chemokines have a more central role in Th2 responses in CRS<sup>[34]</sup>.



**Table 1** Demographic and clinical characteristics of eosinophilic chronic rhinosinusitis with nasal polyps and non-eosinophilic chronic rhinosinusitis with nasal polyps

	ECRSwNP	NECRSwNP
n (%)	27 (45%)	33 (55%)
Age (yr), mean $\pm$ SD	46.93 $\pm$ 12.35	40.27 $\pm$ 13.47
M/F	20/7	24/9
With AR (%)	74.10%	48.5%
With asthma (%)	18.50%	12.1%
Duration of symptom (yr)	5.50 $\pm$ 3.92	8.55 $\pm$ 6.93
VAS	4.04 $\pm$ 1.01	3.99 $\pm$ 1.09
Score of olfactory dysfunction	5.59 $\pm$ 2.54	5.21 $\pm$ 2.66
Score of polyps	3.59 $\pm$ 1.11 <sup>b</sup>	2.06 $\pm$ 0.82
Incidence of bilateral polyps	92.6% <sup>b</sup>	39.9%
Score of disease on CT	14.42 $\pm$ 3.84 <sup>b</sup>	9.64 $\pm$ 3.37
Serum IgE (kU/L)	236.72 $\pm$ 157.77	167.97 $\pm$ 176.77
Blood eosinophil count ( $\times 10^9$ /L)	0.44 $\pm$ 0.24 <sup>b</sup>	0.21 $\pm$ 0.11
Blood eosinophil percentage (%)	6.49 $\pm$ 3.27 <sup>b</sup>	3.42 $\pm$ 1.87
Tissue eosinophil count/HPF	31.56 $\pm$ 21.37 <sup>b</sup>	0.91 $\pm$ 0.80

<sup>b</sup>*P* < 0.01 vs NECRSwNP. ECRSwNP: Eosinophilic chronic rhinosinusitis with nasal polyps; NECRSwNP: Non-eosinophilic chronic rhinosinusitis with nasal polyps; M/F: Male/female; AR: Allergic rhinitis; VAS: Visual analogue scale; HPF: High power field; CT: Computed tomography.

## CLINICAL FEATURES OF ECRS

Many studies have shown that ECRS differs from NECRS in clinical features<sup>[13,14,15]</sup>: (1) ECRS often shows the symptom of olfactory dysfunction in its early stage; (2) ECRS commonly demonstrates multiple and bilateral nasal polyps, with highly viscous mucus secretion, while NECRS mostly with mucopurulent discharge; (3) ECRS tends to have bilateral sinus diseases on sinonasal computed tomography (CT), with a predominant disease in the ethmoid sinus especially in early stage, while NECRS in the maxillary sinus; (4) Co-existence of asthma is more common in ECRS; (5) Most of ECRS cases show the increase of peripheral blood eosinophils; (6) ECRS demonstrates dominant tissue eosinophilic infiltration; (7) In medical treatments, local or systemic steroid therapy is more effective for ECRS compared to macrolide therapy, while macrolide is effective for NECRS; and (8) ECRS shows strong tendency for nasal polyp recurrence after surgery, but systemic steroid is effective for the recurrent nasal polyps.

### Symptoms of ECRS

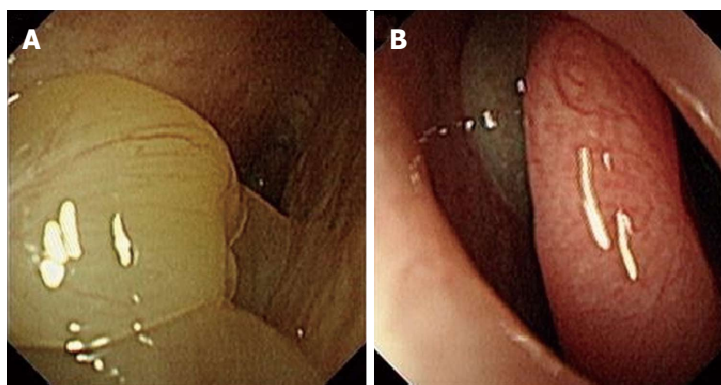
Many studies indicate that ECRS commonly has more severe disease and higher symptom score compared to NECRS<sup>[8,18,19,29]</sup>. A recent study shows the mean severity score of symptoms including olfactory dysfunction, nasal obstruction, and nasal discharge in ECRS is significantly higher than that in NECRS<sup>[42]</sup>. Previous studies have shown that there is a close correlation between symptoms and tissue eosinophil infiltration in CRS<sup>[18,43]</sup>. However, a recent study shows no significant differences in the symptom severities of nasal obstruction, nasal discharge, and facial pain aside from smell dysfunction between ECRS and NECRS cases<sup>[10]</sup>. Another study also shows no difference in visual analogue scale (VAS) score or duration of symptoms between ECRSwNP and NECRSwNP

patients<sup>[11]</sup>, suggesting that the two subtypes may have an equivalent severity of symptoms. Similarly, ECRSwNP and NECRSwNP patients may present with comparable symptom scores<sup>[44]</sup>. In our recent study, a significant difference in the mean VAS score of symptoms between the ECRSwNP and NECRSwNP patients was also not found (Table 1).

CRS is one of the most frequent causes of olfactory dysfunction (reduction or loss of smell) and accounts for 21%-25% of cases with smell loss<sup>[45-48]</sup>. Meanwhile, olfactory dysfunction affects about 60% of CRS patients<sup>[4]</sup>. Olfactory dysfunction is related to the severity of CRS, especially when with nasal polyps<sup>[49]</sup>. A study shows that 38% of CRS patients present with olfactory dysfunction, which is affected by nasal polyps, and the prevalence of olfactory dysfunction is 57% in CRSwNP and 13.7% in CRSsNP, respectively<sup>[20]</sup>. A recent report indicates that smell dysfunction is a very common symptom in CRSwNP, even accounting for 96.5% of cases<sup>[41]</sup>. Olfactory dysfunction is a more predominant and characteristic symptom of ECRS and tends to occur in the early stage of ECRS<sup>[10,13-15,20,50]</sup>. This symptom is more severe and common in ECRS compared to NECRS<sup>[42]</sup>. A study shows that there is a high prevalence of olfactory dysfunction in ECRS (78.9%) compared to NECRS (25.9%)<sup>[20]</sup>. Olfactory dysfunction is reported to be associated with olfactory cleft opacification on CT images<sup>[51]</sup>. Nasal polyps occur more commonly in the olfactory cleft in ECRS compared to NECRS<sup>[42]</sup>. Edematous swelling or polyposis of the middle turbinate, which is often observed in ECRS patients, increases the opacification of the olfactory cleft and causes olfactory impairments<sup>[13]</sup>. Studies indicate that olfaction score is influenced by mucosal eosinophilic infiltration, with lower olfaction score in ECRSwNP as compared to NECRSwNP<sup>[29,52]</sup>. A study shows that there are no statistically significant differences in the VAS scores of nasal obstruction, nasal discharge, headache or overall symptoms, but a statistically significant difference is found in relation to problems of smell between the patients with high and low infiltration of eosinophils in the ethmoidal sinus mucosa<sup>[50]</sup>. But in our recent study, no statistically significant difference in olfactory dysfunction scores was found between ECRSwNP and NECRSwNP (Table 1). The patients with ECRSwNP seemed to have a shorter duration of symptoms than NECRSwNP patients although this difference was not significant statistically (Table 1).

### Polyps in ECRS

ECRS commonly exhibits multiple and bilateral nasal polyps compared to NECRS<sup>[13-15]</sup>, and the polyps commonly exist in the olfactory cleft<sup>[42]</sup>. Although a previous study shows that there is not a significant difference in endoscopic scores of nasal polyps between ECRSwNP and NECRSwNP subtypes<sup>[29]</sup>, many studies demonstrate that ECRSwNP often present with a higher endoscopic score of nasal polyps compared with NECRSwNP<sup>[10,18]</sup>. Our recent study showed that ECRSwNP presented with a higher score of nasal polyps and a higher incidence of



**Figure 2 Nasal endoscopic findings.** Polyps in eosinophilic chronic rhinosinusitis with nasal polyps (A) and in non-eosinophilic chronic rhinosinusitis with nasal polyps (B).

**Table 2 Computed tomography features of eosinophilic chronic rhinosinusitis with nasal polyps and non-eosinophilic chronic rhinosinusitis with nasal polyps**

	ECRSwNP (n = 27)	NECRSwNP (n = 33)
Total disease score of sinuses	14.42 ± 3.84 <sup>b</sup>	9.64 ± 3.37
Number of involved sinuses	7.88 ± 1.22 <sup>b</sup>	5.64 ± 1.49
Percentage of involvement in all sinuses	23.1% <sup>a</sup>	3.0%
Incidence of bilateral diseases in individual sinuses		
Frontal	53.8% <sup>b</sup>	12.1%
Sphenoid	38.5% <sup>a</sup>	9.1%
Anterior ethmoid	53.8% <sup>a</sup>	12.1%
Posterior ethmoid	100.0% <sup>b</sup>	75.8%
Maxillary	96.2% <sup>a</sup>	69.7%
OMC	69.2% <sup>a</sup>	36.4%
Score of diseases in individual sinuses		
Frontal	1.81 ± 1.51 <sup>a</sup>	0.88 ± 0.91
Sphenoid	1.23 ± 1.28 <sup>a</sup>	0.55 ± 0.76
Anterior ethmoid	3.27 ± 0.90 <sup>b</sup>	2.27 ± 0.87
Posterior ethmoid	3.04 ± 1.04 <sup>b</sup>	1.52 ± 0.95
Maxillary	2.23 ± 0.43	2.15 ± 0.69
OMC	2.85 ± 1.60	2.27 ± 1.20

<sup>a</sup> $P < 0.05$ , <sup>b</sup> $P < 0.01$  vs NECRSwNP. Scoring for sinus diseases on computed tomography (CT): 0 = normal, 1 = partial opacification, and 2 = total opacification; these points are applied to individual sinuses on each side; OMC is graded as 0 = not occluded, or 2 = occluded; deriving a maximum score of 12 per side. ECRSwNP: Eosinophilic chronic rhinosinusitis with nasal polyps; NECRSwNP: Non-eosinophilic chronic rhinosinusitis with nasal polyps; OMC: Ostiomeatal complex.

bilateral nasal polyps when compared with NECRSwNP (Table 1 and Figure 2).

In addition, endoscopic examination indicates that most of patients with ECRS demonstrate sinonasal mucus secretion with high viscosity, while NECRS is common with mucopurulent discharge<sup>[13-15]</sup>. It was found in our recent study that more than half (55.6%) of 27 ECRSwNP patients showed highly viscous mucus secretion, but less than a third (30.3%) of 33 NECRSwNP patients presented with this condition.

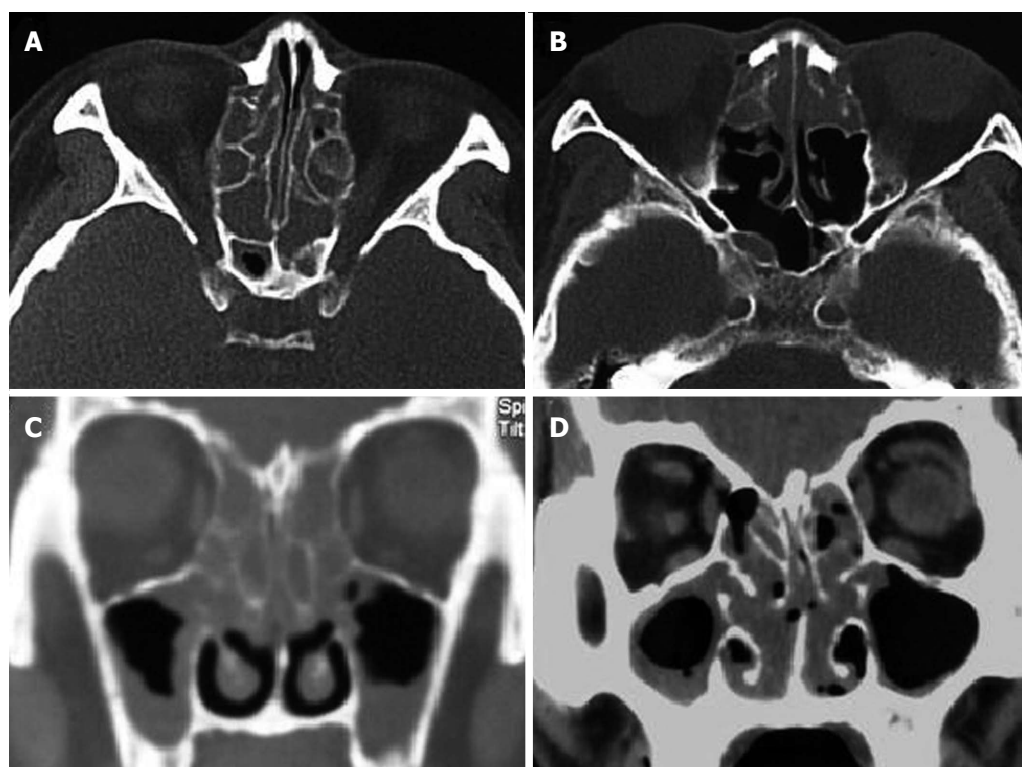
### CT findings in ECRS

The Lund-Mackay scoring system is widely used to evaluate the disease severity of CRS on sinonasal CT<sup>[1,4,53,54]</sup>. CRSwNP tends to have a higher score of disease on CT compared with CRSsNP<sup>[41]</sup>. CT imaging also is a powerful tool to differentiate ECRS from NECRS<sup>[13]</sup>. Studies show

that there are significant differences in the disease scores of most sinuses aside from maxillary sinus between ECRS and NECRS<sup>[13,15]</sup>. ECRSwNP presents with higher disease scores on CT compared to NECRSwNP<sup>[18,27]</sup>, although an obvious difference in CT scores between ECRSwNP and NECRSwNP subtypes is not found in some studies<sup>[11,29]</sup>. In addition, CT studies show that sinus diseases commonly occur bilaterally in ECRS compared to NECRS<sup>[13-15]</sup>. Our recent study showed significant differences in the mean score of total diseases in all sinuses, the mean number of involved sinuses, the percentage of cases with involvement of all sinuses, and the incidence of bilateral diseases in individual sinuses between ECRSwNP and NECRSwNP (Table 2 and Figure 3).

In terms of individual sinuses, ECRS patients especially in their early stages often have predominant diseases in the ethmoid sinuses<sup>[13-15,20,42]</sup>. A previous study shows that there is a significant correlation between the severity of eosinophilic infiltration in the ethmoidal mucosa and the disease on CT<sup>[55]</sup>. Ethmoidal sinus lesions are readily detected by CT in patients with CRS accompanied by severe eosinophil infiltration<sup>[50]</sup>. Involvement of the posterior ethmoid sinus is one of the most apparent differences in CT images between ECRS and NECRS. In the early stage of ECRS, CT images can demonstrate the opacification of the posterior ethmoid sinus<sup>[15]</sup>. A study shows that the posterior ethmoid sinus is more commonly involved in ECRSwNP compared to NECRSwNP, whereas both the anterior and posterior ethmoid sinuses are similarly involved in NECRSwNP, and CT score of the posterior ethmoid has a good accuracy as a predictor of ECRSwNP in a Japanese population<sup>[13]</sup>. Our recent study showed that ECRSwNP had a higher incidence of bilateral diseases and a higher disease score in the anterior or posterior ethmoid sinus compared to NECRS, but ECRSwNP had similar disease scores in its anterior and posterior ethmoid sinuses, while NECRS showed a higher disease score in the anterior ethmoid sinus compared with the posterior ethmoid sinus (Table 2).

The maxillary sinus is most often involved in CRS. The middle meatus or ostiomeatal complex (OMC) has a fundamental role in the pathogenesis of CRS<sup>[1]</sup>. As the drainage from the sinus to the middle meatus or OMC is impaired, the sinus becomes secondarily involved. According to this pathogenesis, sinuses that are most likely



**Figure 3 Computed tomography findings.** Axial and frontal sections in the subtypes of eosinophilic chronic rhinosinusitis with nasal polyps (ECRSwNP) (A and C) and non-eosinophilic chronic rhinosinusitis with nasal polyps (NECRSwNP) (B and D). Predominant diseases in bilateral anterior and posterior ethmoid sinuses are showed in ECRSwNP, while predominant diseases in anterior ethmoid sinuses in NECRSwNP.

to be affected are the maxillary sinus and anterior ethmoid sinus that connect to the middle meatus or OMC through the small ostia. However, ECRS has predominant disease in the ethmoid sinus, while NECRS in the maxillary sinus<sup>[13-15,20]</sup>, and the posterior ethmoid sinus that does not directly connect with the middle meatus is involved in similar to the anterior ethmoid sinus even in the early stage for ECRS patients. This suggests that pathological changes in the middle meatus or OMC may be of less importance for the pathogenesis of ECRS, namely, the pathogenesis of ECRS is different from that of NECRS<sup>[15]</sup>. A recent study reveals that OMC obstruction is correlated with sinus disease only for patients with CRSsNP but not CRSwNP<sup>[56]</sup>. It is thought that ECRS may not be associated with OMC occlusion<sup>[8]</sup>.

In contrast to NECRS patients who have often a predominant disease in the maxillary sinus, patients with ECRS have commonly a predominant disease in the ethmoid sinus especially in the early stage<sup>[9,13-15,20]</sup>. Our recent study showed that ECRSwNP had higher disease scores in frontal, sphenoid, anterior and posterior ethmoid sinuses than NECRSwNP, but there was not a significant difference in maxillary or OMC disease score between ECRSwNP and NECRSwNP (Table 2), which indicated that ECRSwNP had predominant disease in the ethmoid sinus including the anterior and posterior ethmoid sinuses, while NECRSwNP had similar involvement of the anterior ethmoid and maxillary sinuses but with less involvement in the posterior ethmoid sinus.

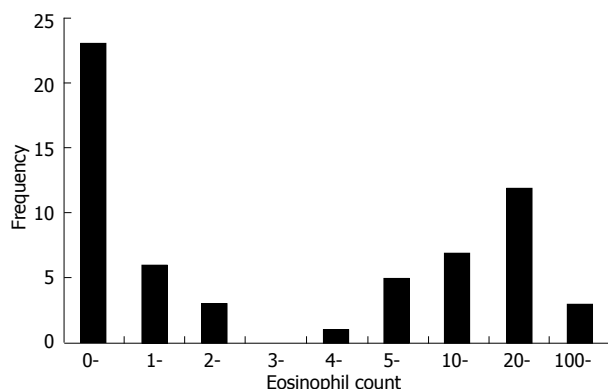
### Co-morbid allergic rhinitis or asthma in ECRS

Inflammation in the upper respiratory tract affects the lower respiratory tract and *vice versa*. The concept of the unified airway is proposed based on evidence from epidemiological, pathophysiological, and treatment outcome studies, indicating the existence of similar inflammatory responses and the shared pathophysiological mechanisms between allergic rhinitis (AR), asthma and CRS<sup>[20,57,58]</sup>.

Some studies demonstrate that 25%-58% of individuals with CRS have AR<sup>[59,60]</sup>. A recent study shows that 67.2% of 418 patients with CRS have AR, and 76.8% of 190 patients with ECRS and 59.2% of 228 patients with NECRS have AR<sup>[42]</sup>. However, some studies show that there is not a statistically significant difference in the coexistent rate of AR between ECRSwNP and NECRSwNP<sup>[11,22]</sup>, and a similar finding was also found in our case cohort (Table 1).

The clinical relationship between CRS and asthma has been known for many years. CRS and asthma coexist often clinically and they share some histopathologic features such as chronic eosinophilic inflammation, epithelial damage, and basement membrane thickening of the airway mucosa<sup>[61]</sup>. It is reported that the prevalence of asthma in CRS patients is 20%-50%<sup>[13,18,20,41,42,62,63]</sup> and even more than 50%<sup>[61]</sup>. However, there is a lower prevalence of asthma (2%-3%) in CRS patients in China compared with the Western population<sup>[64]</sup>. This difference may result from distinct immunopathologic characteristics of CRS in Chinese patients, specifically from lower levels of eosinophilic inflammation<sup>[16,24,64-66]</sup>. CRS espe-





**Figure 4** Frequency distribution and range of tissue eosinophil count per high power field for 60 patients with chronic rhinosinusitis with nasal polyps.

cially CRSwNP is commonly associated with asthma<sup>[31]</sup>. The association of CRSwNP and asthma is well established, and CRSwNP in white population of Europe and the United States represents often a form of severe and difficult-to-treat eosinophilic airway inflammation, which frequently is linked to co-morbid asthma<sup>[1]</sup>. Eosinophilic inflammation is considered a common mechanism in both CRSwNP and asthma<sup>[67]</sup>. It is reported that among 2176 cases with CRSwNP, 37.5% present with asthma<sup>[68]</sup>. A recent study shows that among 182 patients with CRSwNP, the percentage of patients with asthma is as high as 94%<sup>[69]</sup>. Asthma is known to be often concurrent with ECRS<sup>[14,42,70]</sup>. A study shows that 34.7% of 190 patients with ECRS, but only 9.6% of 228 patients with NECRS, present the coexistence with asthma<sup>[42]</sup>. Co-morbid asthma is one of typical features for ECRS<sup>[13]</sup>. Association of ECRSwNP with asthma is widely accepted<sup>[12]</sup>. Some authors believe that ECRS and asthma share similar histopathologic features and are the same inflammatory process demonstrating in different sites of the respiratory tract<sup>[61,67]</sup>.

A study shows that in Chinese patients with CRSwNP, the incidence of asthma (15.9%) in ECRSwNP is higher than that (3.6%) in NECRSwNP<sup>[9]</sup>. Another study shows that the prevalence of asthma in ECRSwNP is higher than that in NECRSwNP, but the difference does not reach statistical significance<sup>[11]</sup>. And also, there are the studies showing no significant difference in the prevalence of asthma between ECRSwNP and NECRSwNP patients<sup>[11,22]</sup>, which may be due to the low prevalence of asthma among CRS patients in China<sup>[64]</sup>. A statistically significant difference in the incidence of asthma between ECRSwNP and NECRSwNP patients was also not found in our recent study (Table 1). Although asthma is often seen in patients with ECRS, co-morbidity with asthma may not be a diagnostic criterion for ECRS because about half of ECRS cases are not associated with asthma<sup>[15]</sup>.

### IgE and ECRS

CRS is a form of eosinophil-dominated inflammation. Some factors result in local production of IgE, which may contribute to severe eosinophilic inflammation.

There is a significant correlation between the concentration of IgE and the number of eosinophils in nasal polyp tissue<sup>[38]</sup>. Some ECRS patients show the elevation of total or specific IgE level<sup>[6,15,44]</sup>. ECRSwNP patients demonstrate increased blood IgE levels compared with NECRSwNP<sup>[11,27]</sup>. A study shows that the amount of tissue eosinophils in CRSwNP is related to eosinophilia of the peripheral blood, but no significant correlation exists between elevated serum IgE and the increase of tissue or blood eosinophils, indicating that atopic conditions may play a minor role in the pathogenesis of CRSwNP in Koreans<sup>[17]</sup>. It is showed that only less than half of CRS patients present with the increased blood IgE and thus eosinophilic inflammation is not likely driven by an IgE mechanism<sup>[61]</sup>. A study shows the absence of a significant difference in total serum IgE levels between ECRS and NECRS patients, suggesting that systemic IgE does not greatly contribute to the pathophysiology of ECRS<sup>[13]</sup>. Also, a recent study shows that although total serum IgE in ECRS is higher than that in NECRS (120.3 *vs* 48.0 kU/L), the difference is not statistically significant<sup>[10]</sup>. Similarly, a significant difference in serum IgE levels between ECRSwNP and NECRSwNP was not found in our recent study (Table 1).

### DEFINITION OR DIAGNOSIS OF ECRS

Currently ECRS is determined primarily based on tissue eosinophilic infiltration, but there is not a well-defined criterion of the tissue eosinophilic infiltration for diagnosis of ECRS. In some studies, ECRS including ECRSwNP is defined as tissue eosinophil count per high power field (HPF) more than 5 eosinophils<sup>[18,21,29,64]</sup>, 10 eosinophils<sup>[8,30]</sup>, or 20 eosinophils<sup>[9]</sup>, even more than 100 eosinophils<sup>[27,42]</sup>, as well as the percentage of eosinophils in tissue-infiltrated inflammatory cells exceeding 5%<sup>[17]</sup>, 10%<sup>[16,66,71]</sup> or 15%<sup>[20]</sup>. In our recent study tissue eosinophil count more than 5 eosinophils/HPF was used as a criterion for ECRSwNP based on the frequency of cases with individual eosinophil counts in nasal polyp tissues (Figure 4).

Tissue eosinophilic infiltration, based on which ECRS is determined, is commonly identified after surgery by histopathological examination. Therefore, this approach may be quite impractical because it is difficult to obtain the diagnostic information before surgery or from the patients treated only with medicines. While peripheral blood eosinophilia has a certain diagnostic value for ECRS<sup>[15]</sup>, because the close correlation between the number of peripheral blood and tissue-infiltrated eosinophils has been shown in several studies<sup>[9-11,15,17,18,27,42]</sup>. It is easy to understand the close association of blood eosinophils with ECRS because the tissue-infiltrated eosinophils are recruited *via* bloodstream to disease sites of ECRS. Many studies have shown that ECRSwNP presents with a significant increase in the peripheral blood eosinophil count or percentage compared to NECRSwNP<sup>[9,11,13,52]</sup>. Our recent study also showed the existence of a close correlation between tissue eosinophil count and blood eosino-



**Table 3** Diagnostic sensitivity and specificity of blood eosinophil count or percentage for eosinophilic chronic rhinosinusitis

Ref.	Blood eosinophil count				Blood eosinophil percentage			
	AUC	Cutoff value	Sensitivity	Specificity	AUC	Cutoff value	Sensitivity	Specificity
Zuo <i>et al</i> <sup>[52]</sup>	0.873	$0.16 \times 10^9/L$	84.9%	84.4%	0.863	2.05%	89.0%	84.4%
Wang <i>et al</i> <sup>[9]</sup>	-	-	-	-	0.818	5.65%	79.0%	78.2%
Hu <i>et al</i> <sup>[11]</sup>	0.871	$0.22 \times 10^9/L$	74.2%	86.5%	0.864	3.05%	80.3%	75.3%
Sakuma <i>et al</i> <sup>[13]</sup>	-	-	-	-	0.880	6.00%	97.4%	70.7%

ECRS: Eosinophilic chronic rhinosinusitis; AUC: Area under receiver operating characteristic curve.

phil count or percentage in ECRSwNP patients, but not in NECRSwNP patients. Thus, the increased peripheral blood eosinophil count or percentage is considered a good marker or predictor of ECRSwNP<sup>[9,11,13,52]</sup>. Some studies show that blood eosinophil count or percentage in ECRS subtype is significantly higher than that in NECRS subtype<sup>[9,11,13,52]</sup>. It is found by receiver operating characteristic curve analysis that blood eosinophil count or percentage has high sensitivity and specificity for the diagnosis of ECRS<sup>[9,11,13,52]</sup> (Table 3).

Our recent study also showed that there was a statistically significant difference in mean blood eosinophil count or percentage between ECRSwNP and NECRSwNP patients (Table 1). However, it was notable that neither all patients with ECRSwNP had the increased circulating eosinophils nor all patients with NECRSwNP showed a normal level of blood eosinophil count. For example, only 10 of 27 patients with ECRSwNP showed blood eosinophil counts more than normal range and 2 of 33 patients with NECRSwNP had the increase of eosinophil count. Therefore, ECRS or NECRS can not be determined only based on if blood eosinophils increase.

The definition or diagnostic criterion for ECRS is very important since ECRS differs from NECRS in treatment strategy. However, there is not yet a clear definition or diagnostic criterion to differentiate ECRS and NECRS subtypes. Recently, new diagnostic criteria for ECRS have been proposed<sup>[13]</sup>, in which the diagnosis of ECRS is finally determined by the clinical symptoms, nasal endoscopy, sinonasal CT imaging, peripheral blood test, and histological examination<sup>[13,15]</sup>.

## TREATMENT AND PROGNOSIS FOR ECRS

ESS has been used widely for the treatment of CRS. Outstanding short- and long-term results of ESS in CRS have previously been reported in the literature<sup>[41,68,72-75]</sup>. The impact of ESS on the improvement in CRS-related symptoms postoperatively is remarkable. However, some of CRS patients are inadequately controlled despite receiving combination of maximal medical therapy and ESS<sup>[1]</sup>. A wide variety of factors contribute to poor disease control, including patient-related factors such as ECRS<sup>[76]</sup>. It is believed that NECRS can be relatively well controlled with a combination of ESS and macrolide therapy, whereas ECRS is unresponsive to macrolide therapy<sup>[13]</sup>. Many studies indicate that ECRS commonly has poorer

treatment outcomes compared to NECRS<sup>[14,19,28,30,76,77]</sup>. For example, ECRSwNP is refractory to the combined treatment of ESS and macrolide therapy and shows a strong tendency for recurrence after surgery<sup>[13-15,27]</sup>.

However, a recent study suggests that eosinophilic inflammation in CRS may not be related to the surgical outcome in South Koreans<sup>[22]</sup>. Another study also shows that the presence or absence of tissue eosinophilic infiltration does not impact significantly on the time interval to revision surgery<sup>[78]</sup>. Our recent study showed that in terms of the short-term efficacy of ESS in CRSwNP, both ECRSwNP and NECRSwNP patients had significant improvement in symptoms aside from smell dysfunction at one-week follow-up after ESS, but there was no significant difference in symptom improvement between the two subgroups.

## CONCLUSION

In conclusion, CRS can be subclassified into two subtypes: ECRS and NECRS. The prevalence of ECRS is increasing in East Asians in the recent years. ECRS differs from NECRS in clinical features and treatment outcomes; however, there is not yet a universally accepted definition or diagnostic criterion for ECRS, and also the underlying pathogenic mechanisms of ECRS are not well-understood. Identification of ECRS subtypes and underlying pathogenic mechanisms is key to developing treatment strategies for the phenotypes of CRS.

## REFERENCES

- 1 Fokkens WJ, Lund VJ, Mullol J, Bachert C, Alobid I, Baroody F, Cohen N, Cervin A, Douglas R, Gevaert P, Georgalas C, Goossens H, Harvey R, Hellings P, Hopkins C, Jones N, Joos G, Kalogjera L, Kern B, Kowalski M, Price D, Riechelmann H, Schlosser R, Senior B, Thomas M, Toskala E, Voegels R, Wang de Y, Wormald PJ. European Position Paper on Rhinosinusitis and Nasal Polyps 2012. *Rhinol Suppl* 2012; (23): 3 preceding table of contents, 1-298 [PMID: 22764607]
- 2 Kim YS, Kim NH, Seong SY, Kim KR, Lee GB, Kim KS. Prevalence and risk factors of chronic rhinosinusitis in Korea. *Am J Rhinol Allergy* 2011; 25: 117-121 [PMID: 21679523 DOI: 10.2500/ajra.2011.25.3630]
- 3 Bhattacharyya N, Orlandi RR, Grebner J, Martinson M. Cost burden of chronic rhinosinusitis: a claims-based study. *Otolaryngol Head Neck Surg* 2011; 144: 440-445 [PMID: 21493210 DOI: 10.1177/0194599810391852]
- 4 Rosenfeld RM, Andes D, Bhattacharyya N, Cheung D, Eisenberg S, Ganiats TG, Gelzer A, Hamilos D, Haydon RC, Hudgins PA, Jones S, Krouse HJ, Lee LH, Mahoney MC, Marple BF, Mitchell CJ, Nathan R, Shiffman RN, Smith TL,

- Witsell DL. Clinical practice guideline: adult sinusitis. *Otolaryngol Head Neck Surg* 2007; **137**: S1-S31 [PMID: 17761281 DOI: 10.1016/j.otohns.2007.06.726]
- 5 **Subspecialty Group of Rhinology**, Editorial Board of Chinese Journal of Otorhinolaryngology Head and Neck Surgery, Subspecialty Group of Rhinology, Society of Otorhinolaryngology Head and Neck Surgery, Chinese Medical Association. Guidelines for diagnosis and treatment of chronic rhinosinusitis (2012, Kunming). *Zhonghua Erbiyan Houtoujing Waike Zazhi* 2013; **48**: 92-94 [PMID: 23710847 DOI: 10.3760/cma.j.issn.1673-0860.2013.02.002]
  - 6 **Cao PP**, Zhang YN, Liao B, Ma J, Wang BF, Wang H, Zeng M, Liu WH, Schleimer RP, Liu Z. Increased local IgE production induced by common aeroallergens and phenotypic alteration of mast cells in Chinese eosinophilic, but not non-eosinophilic, chronic rhinosinusitis with nasal polyps. *Clin Exp Allergy* 2014; **44**: 690-700 [PMID: 24597471 DOI: 10.1111/cea.12304]
  - 7 **Czerny MS**, Namin A, Gratton MA, Antisdel JL. Histopathological and clinical analysis of chronic rhinosinusitis by subtype. *Int Forum Allergy Rhinol* 2014; **4**: 463-469 [PMID: 24574266 DOI: 10.1002/alr.21304]
  - 8 **Snidvongs K**, Chin D, Sacks R, Earls P, Harvey RJ. Eosinophilic rhinosinusitis is not a disease of ostiomeatal occlusion. *Laryngoscope* 2013; **123**: 1070-1074 [PMID: 23553255 DOI: 10.1002/lary.23721]
  - 9 **Wang MJ**, Zhou B, Li YC, Huang Q. The role of peripheral blood eosinophil percentage in classification of chronic rhinosinusitis with nasal polyps. *Zhonghua Erbiyan Houtoujing Waike Zazhi* 2013; **48**: 650-653 [PMID: 24195821 DOI: 10.3760/ema.j.issn.1673-0860.2013.08.008]
  - 10 **Ouyang Y**, Fan E, Li Y, Wang X, Zhang L. Clinical characteristics and expression of thymic stromal lymphopoietin in eosinophilic and non-eosinophilic chronic rhinosinusitis. *ORL J Otorhinolaryngol Relat Spec* 2013; **75**: 37-45 [PMID: 23571727 DOI: 10.1159/000346929]
  - 11 **Hu Y**, Cao PP, Liang GT, Cui YH, Liu Z. Diagnostic significance of blood eosinophil count in eosinophilic chronic rhinosinusitis with nasal polyps in Chinese adults. *Laryngoscope* 2012; **122**: 498-503 [PMID: 22252861 DOI: 10.1002/lary.22507]
  - 12 **Jeong WJ**, Lee CH, Cho SH, Rhee CS. Eosinophilic allergic polyp: a clinically oriented concept of nasal polyp. *Otolaryngol Head Neck Surg* 2011; **144**: 241-246 [PMID: 21493424 DOI: 10.1177/0194599810391738]
  - 13 **Sakuma Y**, Ishitoya J, Komatsu M, Shiono O, Hiram M, Yamashita Y, Kaneko T, Morita S, Tsukuda M. New clinical diagnostic criteria for eosinophilic chronic rhinosinusitis. *Auris Nasus Larynx* 2011; **38**: 583-588 [PMID: 21371840 DOI: 10.1016/j.arl.2011.01.007]
  - 14 **Takeno S**, Hirakawa K, Ishino T. Pathological mechanisms and clinical features of eosinophilic chronic rhinosinusitis in the Japanese population. *Allergol Int* 2010; **59**: 247-256 [PMID: 20567131 DOI: 10.2332/allergolint.10-RAI-0202]
  - 15 **Ishitoya J**, Sakuma Y, Tsukuda M. Eosinophilic chronic rhinosinusitis in Japan. *Allergol Int* 2010; **59**: 239-245 [PMID: 20657162 DOI: 10.2332/allergolint.10-RAI-0231]
  - 16 **Cao PP**, Li HB, Wang BF, Wang SB, You XJ, Cui YH, Wang DY, Desrosiers M, Liu Z. Distinct immunopathologic characteristics of various types of chronic rhinosinusitis in adult Chinese. *J Allergy Clin Immunol* 2009; **124**: 478-484, 484.e1-e2 [PMID: 19541359 DOI: 10.1016/j.jaci.2009.05.017]
  - 17 **Kim JW**, Hong SL, Kim YK, Lee CH, Min YG, Rhee CS. Histological and immunological features of non-eosinophilic nasal polyps. *Otolaryngol Head Neck Surg* 2007; **137**: 925-930 [PMID: 18036422 DOI: 10.1016/j.otohns.2007.07.036]
  - 18 **Kountakis SE**, Arango P, Bradley D, Wade ZK, Borish L. Molecular and cellular staging for the severity of chronic rhinosinusitis. *Laryngoscope* 2004; **114**: 1895-1905 [PMID: 15510011 DOI: 10.1097/01.mlg.0000147917.43615.c0]
  - 19 **Ferguson BJ**. Categorization of eosinophilic chronic rhinosinusitis. *Curr Opin Otolaryngol Head Neck Surg* 2004; **12**: 237-242 [PMID: 15167036]
  - 20 **Yoshimura K**, Kawata R, Haruna S, Moriyama H, Hirakawa K, Fujieda S, Masuyama K, Takenaka H. Clinical epidemiological study of 553 patients with chronic rhinosinusitis in Japan. *Allergol Int* 2011; **60**: 491-496 [PMID: 21778815 DOI: 10.2332/allergolint.10-OA-0234]
  - 21 **Kim SJ**, Lee KH, Kim SW, Cho JS, Park YK, Shin SY. Changes in histological features of nasal polyps in a Korean population over a 17-year period. *Otolaryngol Head Neck Surg* 2013; **149**: 431-437 [PMID: 23812744 DOI: 10.1177/0194599813495363]
  - 22 **Kim SY**, Park JH, Rhee CS, Chung JH, Kim JW. Does eosinophilic inflammation affect the outcome of endoscopic sinus surgery in chronic rhinosinusitis in Koreans? *Am J Rhinol Allergy* 2013; **27**: e166-e169 [PMID: 24274208 DOI: 10.2500/ajra.2013.27.3959]
  - 23 **Zhang N**, Holtappels G, Claeys C, Huang G, van Cauwenberge P, Bachert C. Pattern of inflammation and impact of *Staphylococcus aureus* enterotoxins in nasal polyps from southern China. *Am J Rhinol* 2013; **20**: 445-450 [PMID: 16955777]
  - 24 **Zhang N**, Van Zele T, Perez-Novo C, Van Bruaene N, Holtappels G, DeRuyck N, Van Cauwenberge P, Bachert C. Different types of T-effector cells orchestrate mucosal inflammation in chronic sinus disease. *J Allergy Clin Immunol* 2008; **122**: 961-968 [PMID: 18804271 DOI: 10.1016/j.jaci.2008.07.008]
  - 25 **Shin SH**, Ye MK, Kim JK, Cho CH. Histological characteristics of chronic rhinosinusitis with nasal polyps: Recent 10-year experience of a single center in Daegu, Korea. *Am J Rhinol Allergy* 2014; **28**: 95-98 [PMID: 24717942 DOI: 10.2500/ajra.2014.28.4003]
  - 26 **Wei Y**, Xia W, Ye X, Fan Y, Shi J, Wen W, Yang P, Li H. The antimicrobial protein short palate, lung, and nasal epithelium clone 1 (SPLUNC1) is differentially modulated in eosinophilic and noneosinophilic chronic rhinosinusitis with nasal polyps. *J Allergy Clin Immunol* 2014; **133**: 420-428 [PMID: 24342548 DOI: 10.1016/j.jaci.2013.09.052]
  - 27 **Ikedo K**, Shiozawa A, Ono N, Kusunoki T, Hirotsu M, Homma H, Saitoh T, Murata J. Subclassification of chronic rhinosinusitis with nasal polyp based on eosinophil and neutrophil. *Laryngoscope* 2013; **123**: E1-E9 [PMID: 23670893 DOI: 10.1002/lary.24154]
  - 28 **Haruna S**, Shimada C, Ozawa M, Fukami S, Moriyama H. A study of poor responders for long-term, low-dose macrolide administration for chronic sinusitis. *Rhinology* 2009; **47**: 66-71 [PMID: 19382498]
  - 29 **Soler ZM**, Sauer DA, Mace J, Smith TL. Relationship between clinical measures and histopathologic findings in chronic rhinosinusitis. *Otolaryngol Head Neck Surg* 2009; **141**: 454-461 [PMID: 19786212 DOI: 10.1016/j.otohns.2009.06.085]
  - 30 **Soler ZM**, Sauer D, Mace J, Smith TL. Impact of mucosal eosinophilia and nasal polyposis on quality-of-life outcomes after sinus surgery. *Otolaryngol Head Neck Surg* 2010; **142**: 64-71 [PMID: 20096225 DOI: 10.1016/j.otohns.2009.10.005]
  - 31 **Tan BK**, Chandra RK, Pollak J, Kato A, Conley DB, Peters AT, Grammer LC, Avila PC, Kern RC, Stewart WF, Schleimer RP, Schwartz BS. Incidence and associated pre-morbid diagnoses of patients with chronic rhinosinusitis. *J Allergy Clin Immunol* 2013; **131**: 1350-1360 [PMID: 23541327 DOI: 10.1016/j.jaci.2013.02.002]
  - 32 **Van Crombruggen K**, Zhang N, Gevaert P, Tomassen P, Bachert C. Pathogenesis of chronic rhinosinusitis: inflammation. *J Allergy Clin Immunol* 2011; **128**: 728-732 [PMID: 21868076 DOI: 10.1016/j.jaci.2011.07.049]
  - 33 **Nguyen LH**, Fakhri S, Frenkiel S, Hamid QA. Molecular immunology and immunotherapy for chronic sinusitis. *Curr Allergy Asthma Rep* 2003; **3**: 505-512 [PMID: 14531972]
  - 34 **Walsh ER**, August A. Eosinophils and allergic airway disease: there is more to the story. *Trends Immunol* 2010; **31**: 39-44 [PMID: 19926338 DOI: 10.1016/j.it.2009.10.001]

- 35 **Akuthota P**, Wang HB, Spencer LA, Weller PF. Immuno-regulatory roles of eosinophils: a new look at a familiar cell. *Clin Exp Allergy* 2008; **38**: 1254-1263 [PMID: 18727793 DOI: 10.1111/j.1365-2222.2008.03037.x]
- 36 **Rothenberg ME**, Hogan SP. The eosinophil. *Annu Rev Immunol* 2006; **24**: 147-174 [PMID: 16551246]
- 37 **Van Bruaene N**, Pérez-Novoa CA, Basinski TM, Van Zele T, Holtappels G, De Ruyck N, Schmidt-Weber C, Akdis C, Van Cauwenberge P, Bachert C, Gevaert P. T-cell regulation in chronic paranasal sinus disease. *J Allergy Clin Immunol* 2008; **121**: 1435-1441, 1441e1-3 [PMID: 18423831 DOI: 10.1016/j.jaci.2008.02.018]
- 38 **Bachert C**, Gevaert P, Holtappels G, Johansson SG, van Cauwenberge P. Total and specific IgE in nasal polyps is related to local eosinophilic inflammation. *J Allergy Clin Immunol* 2001; **107**: 607-614 [PMID: 11295647 DOI: 10.1067/mai.2001.112374]
- 39 **Sejima T**, Holtappels G, Kikuchi H, Imayoshi S, Ichimura K, Bachert C. Cytokine profiles in Japanese patients with chronic rhinosinusitis. *Allergol Int* 2012; **61**: 115-122 [PMID: 22377524 DOI: 10.2332/allergolint.10-OA-0290]
- 40 **Zimmermann N**, Hershey GK, Foster PS, Rothenberg ME. Chemokines in asthma: cooperative interaction between chemokines and IL-13. *J Allergy Clin Immunol* 2003; **111**: 227-242; quiz 243 [PMID: 12589338 DOI: 10.1067/mai.2003.139]
- 41 **Abdalla S**, Alreefy H, Hopkins C. Prevalence of sinonasal outcome test (SNOT-22) symptoms in patients undergoing surgery for chronic rhinosinusitis in the England and Wales National prospective audit. *Clin Otolaryngol* 2012; **37**: 276-282 [PMID: 22776038 DOI: 10.1111/j.1749-4486.2012.02527.x]
- 42 **Mori E**, Matsuwaki Y, Mitsuyama C, Okushi T, Nakajima T, Moriyama H. Risk factors for olfactory dysfunction in chronic rhinosinusitis. *Auris Nasus Larynx* 2013; **40**: 465-469 [PMID: 23422234 DOI: 10.1016/j.anl.2012.12.005]
- 43 **Baudoin T**, Cupić H, Geber G, Vagić D, Grgić M, Kalogjera L. Histopathologic parameters as predictors of response to endoscopic sinus surgery in nonallergic patients with chronic rhinosinusitis. *Otolaryngol Head Neck Surg* 2006; **134**: 761-766 [PMID: 16647531 DOI: 10.1016/j.otohns.2005.12.026]
- 44 **Zhang XH**, Lu X, Long XB, You XJ, Gao QX, Cui YH, Liu Z. Chronic rhinosinusitis with and without nasal polyps is associated with decreased expression of glucocorticoid-induced leucine zipper. *Clin Exp Allergy* 2009; **39**: 647-654 [PMID: 19260870 DOI: 10.1111/j.1365-2222.2008.03198.x]
- 45 **Konstantinidis I**, Triaridis S, Printza A, Vital V, Ferekidis E, Constantinidis J. Olfactory dysfunction in nasal polyposis: correlation with computed tomography findings. *ORL J Otorhinolaryngol Relat Spec* 2007; **69**: 226-232 [PMID: 17409781 DOI: 10.1159/000101543]
- 46 **Raviv JR**, Kern RC. Chronic rhinosinusitis and olfactory dysfunction. *Adv Otorhinolaryngol* 2006; **63**: 108-124 [PMID: 16733336]
- 47 **Landis BN**, Konnerth CG, Hummel T. A study on the frequency of olfactory dysfunction. *Laryngoscope* 2004; **114**: 1764-1769 [PMID: 15454769]
- 48 **Temmel AF**, Quint C, Schickinger-Fischer B, Klimek L, Stoller E, Hummel T. Characteristics of olfactory disorders in relation to major causes of olfactory loss. *Arch Otolaryngol Head Neck Surg* 2002; **128**: 635-641 [PMID: 12049556]
- 49 **Litvack JR**, Fong K, Mace J, James KE, Smith TL. Predictors of olfactory dysfunction in patients with chronic rhinosinusitis. *Laryngoscope* 2008; **118**: 2225-2230 [PMID: 19029858 DOI: 10.1097/MLG.0b013e318184e216]
- 50 **Haruna S**, Otori N, Moriyama H, Nakanishi M. Olfactory dysfunction in sinusitis with infiltration of numerous activated eosinophils. *Auris Nasus Larynx* 2006; **33**: 23-30 [PMID: 16293387 DOI: 10.1016/j.anl.2005.09.005]
- 51 **Chang H**, Lee HJ, Mo JH, Lee CH, Kim JW. Clinical implication of the olfactory cleft in patients with chronic rhinosinusitis and olfactory loss. *Arch Otolaryngol Head Neck Surg* 2009; **135**: 988-992 [PMID: 19841336 DOI: 10.1001/archoto.2009.140]
- 52 **Zuo K**, Guo J, Chen F, Xu R, Xu G, Shi J, Li H. Clinical characteristics and surrogate markers of eosinophilic chronic rhinosinusitis in Southern China. *Eur Arch Otorhinolaryngol* 2014; **271**: 2461-2468 [PMID: 24493563 DOI: 10.1007/s00405-014-2910-0]
- 53 **Lund VJ**, Mackay IS. Staging in rhinosinusitis. *Rhinology* 1993; **31**: 183-184 [PMID: 8140385]
- 54 **Okushi T**, Nakayama T, Morimoto S, Arai C, Omura K, Asaka D, Matsuwaki Y, Yoshikawa M, Moriyama H, Otori N. A modified Lund-Mackay system for radiological evaluation of chronic rhinosinusitis. *Auris Nasus Larynx* 2013; **40**: 548-553 [PMID: 23751774 DOI: 10.1016/j.anl.2013.04.010]
- 55 **Szucs E**, Ravandi S, Goossens A, Beel M, Clement PA. Eosinophilia in the ethmoid mucosa and its relationship to the severity of inflammation in chronic rhinosinusitis. *Am J Rhinol* 2002; **16**: 131-134 [PMID: 12141768]
- 56 **Leung RM**, Kern RC, Conley DB, Tan BK, Chandra RK. Osteomeatal complex obstruction is not associated with adjacent sinus disease in chronic rhinosinusitis with polyps. *Am J Rhinol Allergy* 2011; **25**: 401-403 [PMID: 22185744 DOI: 10.2500/ajra.2011.25.3672]
- 57 **Krouse JH**. The unified airway--conceptual framework. *Otolaryngol Clin North Am* 2008; **41**: 257-266, v [PMID: 18328366 DOI: 10.1016/j.otc.2007.11.002]
- 58 **Bachert C**, Vignola AM, Gevaert P, Leynaert B, Van Cauwenberge P, Bousquet J. Allergic rhinitis, rhinosinusitis, and asthma: one airway disease. *Immunol Allergy Clin North Am* 2004; **24**: 19-43 [PMID: 15062425]
- 59 **Gutman M**, Torres A, Keen KJ, Houser SM. Prevalence of allergy in patients with chronic rhinosinusitis. *Otolaryngol Head Neck Surg* 2004; **130**: 545-552 [PMID: 15138418 DOI: 10.1016/j.otohns.2004.02.007]
- 60 **Emanuel IA**, Shah SB. Chronic rhinosinusitis: allergy and sinus computed tomography relationships. *Otolaryngol Head Neck Surg* 2000; **123**: 687-691 [PMID: 11112958 DOI: 10.1067/mhn.2000.110961]
- 61 **Ponikau JU**, Sherris DA, Kephart GM, Kern EB, Gaffey TA, Tarara JE, Kita H. Features of airway remodeling and eosinophilic inflammation in chronic rhinosinusitis: is the histopathology similar to asthma? *J Allergy Clin Immunol* 2003; **112**: 877-882 [PMID: 14610473 DOI: 10.1067/mai.2003.1790]
- 62 **Seybt MW**, McMains KC, Kountakis SE. The prevalence and effect of asthma on adults with chronic rhinosinusitis. *Ear Nose Throat J* 2007; **86**: 409-411 [PMID: 17702323]
- 63 **Bousquet J**, Vignola AM, Demoly P. Links between rhinitis and asthma. *Allergy* 2003; **58**: 691-706 [PMID: 12859545]
- 64 **Fan Y**, Chen S, Qu X, Zuo K, Li X, Huang J, Xu G, Mi J, Li H. A lower prevalence of asthma among patients with chronic rhinosinusitis in southern China. *J Allergy Clin Immunol* 2011; **127**: 520-522.e1-5 [PMID: 21093031 DOI: 10.1016/j.jaci.2010.09.023]
- 65 **Shi J**, Fan Y, Xu R, Zuo K, Cheng L, Xu G, Li H. Characterizing T-cell phenotypes in nasal polyposis in Chinese patients. *J Invest Allergol Clin Immunol* 2009; **19**: 276-282 [PMID: 19639723]
- 66 **Hao J**, Pang YT, Wang DY. Diffuse mucosal inflammation in nasal polyps and adjacent middle turbinate. *Otolaryngol Head Neck Surg* 2006; **134**: 267-275 [PMID: 16455376 DOI: 10.1016/j.otohns.2005.09.026]
- 67 **Rinia AB**, Kostamo K, Ebbens FA, van Drunen CM, Fokkens WJ. Nasal polyposis: a cellular-based approach to answering questions. *Allergy* 2007; **62**: 348-358 [PMID: 17362244]
- 68 **Hopkins C**, Browne JP, Slack R, Lund V, Topham J, Reeves B, Copley L, Brown P, van der Meulen J. The national comparative audit of surgery for nasal polyposis and chronic rhinosinusitis. *Clin Otolaryngol* 2006; **31**: 390-398 [PMID: 17014448]
- 69 **Fountain CR**, Mudd PA, Ramakrishnan VR, Sillau SH, Kingdom TT, Katial RK. Characterization and treatment of patients with chronic rhinosinusitis and nasal polyps. *Ann Allergy Asthma Immunol* 2013; **111**: 337-341 [PMID: 24125137]

- 70 **Bachert C**, Patou J, Van Cauwenberge P. The role of sinus disease in asthma. *Curr Opin Allergy Clin Immunol* 2006; **6**: 29-36 [PMID: 16505609]
- 71 **Zhang XH**, Zhang YN, Li HB, Hu CY, Wang N, Cao PP, Liao B, Lu X, Cui YH, Liu Z. Overexpression of miR-125b, a novel regulator of innate immunity, in eosinophilic chronic rhinosinusitis with nasal polyps. *Am J Respir Crit Care Med* 2012; **185**: 140-151 [PMID: 22071331 DOI: 10.1164/rccm.201103-0456OC]
- 72 **Bhattacharyya N**. Symptom outcomes after endoscopic sinus surgery for chronic rhinosinusitis. *Arch Otolaryngol Head Neck Surg* 2004; **130**: 329-333 [PMID: 15023842]
- 73 **Damm M**, Quante G, Jungehuelsing M, Stennert E. Impact of functional endoscopic sinus surgery on symptoms and quality of life in chronic rhinosinusitis. *Laryngoscope* 2002; **112**: 310-315 [PMID: 11889389]
- 74 **Deal RT**, Kountakis SE. Significance of nasal polyps in chronic rhinosinusitis: symptoms and surgical outcomes. *Laryngoscope* 2004; **114**: 1932-1935 [PMID: 15510016 DOI: 10.1097/01.mlg.0000147922.12228.1f]
- 75 **Rudmik L**, Mace J, Soler ZM, Smith TL. Long-term utility outcomes in patients undergoing endoscopic sinus surgery. *Laryngoscope* 2014; **124**: 19-23 [PMID: 23670699 DOI: 10.1002/lary.24135]
- 76 **Snidvongs K**, Lam M, Sacks R, Earls P, Kalish L, Phillips PS, Pratt E, Harvey RJ. Structured histopathology profiling of chronic rhinosinusitis in routine practice. *Int Forum Allergy Rhinol* 2012; **2**: 376-385 [PMID: 22419386 DOI: 10.1002/alr.21032]
- 77 **Scadding GK**. Medical management of chronic rhinosinusitis. *Immunol Allergy Clin North Am* 2004; **24**: 103-118 [PMID: 15062430]
- 78 **Wu AW**, Ting JY, Platt MP, Tierney HT, Metson R. Factors affecting time to revision sinus surgery for nasal polyps: a 25-year experience. *Laryngoscope* 2014; **124**: 29-33 [PMID: 23712679 DOI: 10.1002/lary.24213]

**P- Reviewer:** Di Lorenzo G, (William) Wan YL, Xavier-Elsas P  
**S- Editor:** Ji FF **L- Editor:** Wang TQ **E- Editor:** Wu HL





## Spectrum of magnetic resonance imaging findings in congenital lumbar spinal stenosis

Theodoros Soldatos, Majid Chalian, Shrey Thawait, Alan J Belzberg, John Eng, John A Carrino, Avneesh Chhabra

Theodoros Soldatos, Majid Chalian, Shrey Thawait, John Eng, John A Carrino, Avneesh Chhabra, Russell H Morgan  
Department of Radiology and Radiological Science, the Johns Hopkins Hospital, Baltimore, MD 21287, United States  
Alan J Belzberg, Department of Neurosurgery, the Johns Hopkins Hospital, Baltimore, MD 21287, United States

Avneesh Chhabra, Department of Radiology and Orthopaedic Surgery, University of Texas Southwestern Medical Center, Dallas, TX 75390-9178, United States

Author contributions: All the authors solely contributed to this paper.

Correspondence to: Avneesh Chhabra, MD, Associate Professor, Section Chief, Department of Radiology and Orthopaedic Surgery, University of Texas Southwestern Medical Center, 5323 Harry Hines Blvd, Dallas, TX 75390-9178, United States. [avneesh.chhabra@utsouthwestern.edu](mailto:avneesh.chhabra@utsouthwestern.edu)

Telephone: +1-214-6482122

Received: May 15, 2014 Revised: October 30, 2014

Accepted: November 17, 2014

Published online: December 16, 2014

### Abstract

**AIM:** To investigate whether congenital lumbar spinal stenosis (CLSS) is associated with a specific degenerative changes of the lumbar spine.

**METHODS:** The lumbar spine magnetic resonance imaging studies of 52 subjects with CLSS and 48 control subjects were retrospectively evaluated. In each examination, the five lumbar levels were assessed for the presence or absence of circumferential or shallow annular bulges, annular tears, anterior or posterior disc herniations, epidural lipomatosis, Schmorl's nodes, spondylolisthesis, pars defects, and stress reactions of the posterior vertebral elements.

**RESULTS:** Compared to control individuals, subjects with CLSS exhibited increased incidence of circumferential and shallow annular bulges, annular tears, disc

herniations and spondylolisthesis ( $P < 0.05$ ).

**CONCLUSION:** CLSS is associated with increased incidence of degenerative changes in specific osseous and soft-tissue elements of the lumbar spine.

© 2014 Baishideng Publishing Group Inc. All rights reserved.

**Key words:** Congenital lumbar spinal stenosis; Magnetic resonance imaging; Imaging findings; Degenerative changes; Low back pain

**Core tip:** Congenital lumbar spinal stenosis is associated with increased incidence of degenerative changes in specific osseous and soft-tissue elements of the lumbar spine. Describing the spectrum of the respective imaging findings, this article can assist radiologists in providing more detailed magnetic resonance imaging reports.

Soldatos T, Chalian M, Thawait S, Belzberg AJ, Eng J, Carrino JA, Chhabra A. Spectrum of magnetic resonance imaging findings in congenital lumbar spinal stenosis. *World J Clin Cases* 2014; 2(12): 883-887 Available from: URL: <http://www.wjgnet.com/2307-8960/full/v2/i12/883.htm> DOI: <http://dx.doi.org/10.12998/wjcc.v2.i12.883>

### INTRODUCTION

Since the first reports describing congenital (or developmental) lumbar spinal stenosis (CLSS), the clinical implications of this entity have been the subject of several scientific studies<sup>[1-3]</sup>. Based on the original etiological classification described by Arnoldi *et al*<sup>[4]</sup>, CLSS is a developmental narrowing of the spinal canal, which is secondary to a bone dysplasia. Radiographically, the respective subjects have a shorter pedicular length and as a result a smaller cross-sectional spinal canal area<sup>[5]</sup>. In

usual practice, the above subjects tend to present clinically in the fourth or fifth decade of life with various neurogenic complications and relatively few radiographically evident degenerative spondylotic changes<sup>[5]</sup>. Except for scattered articles reporting radiographic and cross-sectional measurements to define CLSS, there have been no studies evaluating whether the entity is associated with degenerative changes in specific osseous and soft-tissue elements of the lumbar spine. In our practice with magnetic resonance imaging (MRI) studies of the lumbar spine, we have experienced that individuals with CLSS tend to exhibit an increased incidence of specific imaging features, including foraminal disc protrusions, as well as a particular type of annular disc bulge, in which the posterior concavity of the intervertebral discs is preserved. To validate our observations and potentially extend our understanding of CLSS from an imaging point of view, we investigated the association between CLSS and degenerative changes in various osseous and soft-tissue elements of the lumbar spine.

## MATERIALS AND METHODS

### Study population

Institutional review board approval was granted and informed consent was waived for this HIPAA-compliant study. The MRI database of our institution was searched for examinations of the lumbar spine performed in adults of less than or equal to 50 years of age, an age limit arbitrarily employed to limit the inclusion of subjects with age-related degenerative spine changes. Two radiologists with 16 (A.C.) and 6 (T.S.) years of radiology experience, respectively, who were blinded to the original reports of the MRI studies, evaluated the examinations in consensus on a picture archiving and communication system workstation (Ultravision, Emageon, AL, United States). All examinations were performed on 1.5T or 3.0T MR scanners and included axial and sagittal T1- and T2-weighted images, as well as sagittal STIR images of the lumbar spine.

In each study, the T2-weighted images were used to calculate the mid-sagittal spinal canal diameter and mid-sagittal thecal sac diameter at the mid-vertebral levels of all five lumbar vertebrae. Subjects with mid-sagittal spinal canal diameter of less than 14 mm on at least one level were considered as having CLSS and were included in the study group, whereas subjects with mid-sagittal spinal canal diameter of equal or greater than 14 mm at all five levels were included in the control group. Examinations were consecutively evaluated until a study group of 52 subjects and a control group of 48 subjects were formed. Patients with achondroplasia or a known history of spinal surgery, trauma, infection and/or tumor were excluded.

### Image analysis

In each study, the average value of mid-sagittal thecal sac diameter was calculated, and thereafter, the intervertebral levels from L1-L2 to L5-S1 were evaluated for the presence or absence of (1) circumferential annular bulge,

defined as generalized extension of greater than 50% of the outer boundary of the intervertebral disc beyond the border of the adjacent bone, with loss of posterior disc concavity; (2) shallow annular bulge, defined as the extension of the intervertebral disc by greater than 50% from the outer boundary of the adjacent bone, with preservation of the posterior disc concavity; (3) annular tear(s), defined as focal area(s) of increased signal intensity within the outer layer of the intervertebral disc on fluid-sensitive images; (4) uni- or bilateral foraminal disc herniation(s), defined as extension(s) of less than 50% of the outer boundary of the intervertebral disc beyond the border of the adjacent bone, centered on one or both foramina; (5) central or paracentral disc herniation, defined as extension of less than 50% of the outer boundary of the intervertebral disc beyond the border of the adjacent bone, protruding centrally or subarticularly within the spinal canal, respectively; (6) epidural lipomatosis, registered when the epidural adipose tissue assumed an anteriorly convex border and a thickness of greater than 7 mm<sup>[6]</sup>; (7) Schmorl's node(s); (8) spondylolisthesis (antero- or retrolisthesis), registered when the vertebral body exhibited anterior or posterior displacement of equal or greater than 1 mm over the vertebral body below; (9) uni- or bilateral pars defect(s); (10) anterior disc herniation; and (11) stress reaction (increased signal intensity on fluid-sensitive images) of the posterior vertebral elements. For each of the above features, the total incidence observed throughout the five intervertebral levels was documented for each subject.

### Statistical analysis

For all evaluated quantitative parameters, the difference between the study and control groups was assessed using Student's *t* test, whereas sex distribution was evaluated using  $\chi^2$  test. A probability level of 0.05 was accepted as statistically significant. All data were stored on a spreadsheet (Excel 2010, Microsoft, Seattle, WA, United States) and analysis was performed using a commercially available statistical package (MedCalc 8.0, Mariakerke, Belgium).

## RESULTS

Table 1 summarizes the demographics of the study population, the incidences of the features evaluated, as well as the results of the various statistical comparisons between the study and control groups. The two groups were similar in terms of age and sex distribution. Subjects with CLSS exhibited increased incidence of circumferential and shallow annular bulges, foraminal and anterior disc herniations, annular tears, and spondylolisthesis. There was no difference between the two groups regarding the incidences of central and paracentral disc herniations, epidural lipomatosis, Schmorl's nodes, pars defects, and stress reaction of the posterior vertebral elements.

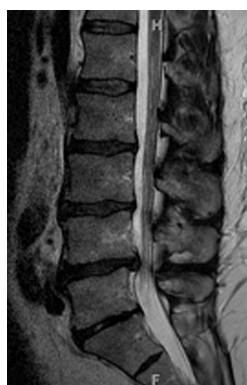## DISCUSSION

CLSS has been attributed to an abnormal anatomic de-

**Table 1** Demographics of the 100 patients of the study along with the imaging features which were evaluated on the respective magnetic resonance imaging studies

Parameter	Subjects with CLSS	Control subjects	P
Subjects	52	48	-
Age	38 ± 10	38 ± 8	0.4930
Sex (males/females)	28/24	22/26	0.2742
Average mid-sagittal thecal sac diameter	1.31 ± 0.13	1.51 ± 0.18	-
Circumferential annular bulges	59 (1.13 ± 0.95)	35 (0.73 ± 0.79)	0.0116 <sup>1</sup>
Shallow annular bulges	80 (1.54 ± 1.06)	47 (0.98 ± 0.93)	0.0031 <sup>1</sup>
Foraminal disc herniations	31 (0.60 ± 0.82)	13 (0.27 ± 0.54)	0.0111 <sup>1</sup>
Central/paracentral disc herniations	22 (0.42 ± 0.70)	15 (0.31 ± 0.55)	0.1917
Epidural lipomatosis	33 (0.63 ± 1.09)	17 (0.35 ± 0.76)	0.0701
Schmorl's nodes	24 (0.46 ± 1.00)	13 (0.27 ± 0.68)	0.1352
Spondylolisthesis	53 (1.02 ± 0.96)	29 (0.60 ± 0.71)	0.0081 <sup>1</sup>
Pars defects	0 (0.00 ± 0.00)	2 (0.04 ± 0.20)	0.0699
Annular tears	56 (1.08 ± 1.01)	25 (0.52 ± 0.80)	0.0004 <sup>1</sup>
Anterior disc herniation	63 (1.21 ± 1.16)	25 (1.51 ± 0.18)	< 0.0001 <sup>1</sup>
Posterior elements stress reaction	4 (0.08 ± 0.33)	2 (0.04 ± 0.20)	0.2644

Subjects and sex are expressed as number of cases, age as yr ± SD, and spinal and thecal sac diameters as average value in cm ± SD. All imaging parameters are presented as total incidence (average incidence ± SD). Features marked with an asterisk (\*) indicate significant difference between the two groups. CLSS: Congenital lumbar spinal stenosis.

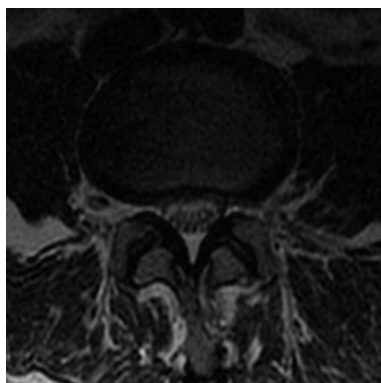


**Figure 1** Mid-sagittal T2-weighted (3230, 120) image of the lumbar spine in a 50-year-old male with congenital lumbar spinal stenosis. The lumbar spine shows loss of the lordotic curve, multilevel spondylolisthesis, and degenerative disc disease manifested as loss of disc height, circumferential disc bulges, anterior disc herniations, Schmorl's nodes and a central disc protrusion. In this subject, the mid-sagittal spinal canal diameter ranged from 1.45 cm at the L1 level to 1.03 cm at L4 level. The average mid-spinal canal diameter was 1.26 cm.

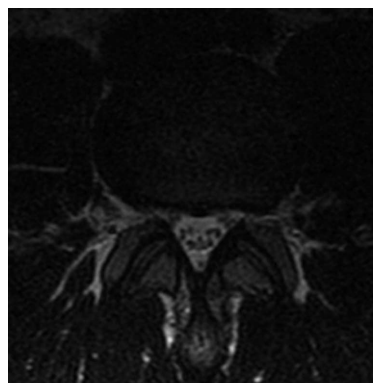
velopment of the spinal canal. The etiology of the entity is unknown, except from some cases which are induced by achondroplasia<sup>[5,7]</sup>. CLSS differs from degenerative lumbar spinal stenosis in that the spinal canal stenosis is not limited to one or two intervertebral levels, but is uniformly distributed throughout the lumbar spine (Figure 1). As a result, the surgical treatment of CLSS commonly necessitates multi-level intervention, as opposed to degenerative lumbar spinal stenosis, which requires more focal procedures<sup>[5]</sup>. Subjects with CLSS are vulnerable to even minimal degenerative changes that compromise the already narrowed spinal canal, and tend to experience symptoms in the fourth and fifth decades of life, as opposed to patients with degenerative lumbar spinal stenosis, who demonstrate symptoms primarily after the sixth decade of life<sup>[5,7]</sup>.

Although the incidence of CLSS in the general popu-

lation is unknown and probably varies among different races and ethnic groups, MRI readers commonly encounter this entity in studies of the lumbar spine. CLSS has been described as early as the 1950s<sup>[3]</sup>, however the imaging evaluation of this entity has been limited to delineating radiographic and cross-sectional criteria for its definition, and reporting limited degenerative spondylotic changes as a typical radiographic feature of the respective subjects. The definition of CLSS is not uniform across authors, with studies suggesting cut-off values of mid-sagittal spinal canal diameter varying between 10 and 17 mm, and not clarifying whether spinal canal narrowing needs to be documented on at least one or more spinal levels<sup>[4,7-10]</sup>. Some authors consider the cross-sectional area of the spinal canal as the criterion to define CLSS, a measurement, probably more accurate, but also time-consuming and impractical for everyday use. In addition, all previous studies have been limited in the vague description of osseous degenerative changes, and mostly using radiographs<sup>[1-3,5,7]</sup>. This study focused on specific osseous and soft tissue elements of the lumbar spine and employed a mid-sagittal spinal canal diameter of less than 14 mm on at least one mid-vertebral level to define CLSS. The latter value “summates” previous reports, has been illustrated in a large previous study by Singh *et al*<sup>[5]</sup> and is the one used by radiologists and orthopaedic surgeons in our institution. A recent study which compared subjects with and without CLSS by means of MRI and anteroposterior radiographs of the lumbar spine, reported that, in the CLSS cohort, global pathology and multilevel involvement with L3, L4, and L5 segments were involved more commonly and severely, whereas severe stenosis, at L1, L2, and S1 occurred infrequently. The authors also described three spinal canal morphologies in the CLSS group: (1) “flattened” canal with predominantly reduced spinal canal AP diameter; (2) spinal canal with predominantly reduced interlaminar angle; and (3) global reduction of all canal parameters<sup>[11]</sup>.



**Figure 2** Axial T2-weighted (5000, 102) images of the lumbar spine in a 48-year-old female with congenital lumbar spinal stenosis exhibits a shallow annular disc bulge.



**Figure 3** Axial T2-weighted (3516, 115) image of the lumbar spine in a 29-year-old male with congenital lumbar spinal stenosis demonstrates a circumferential disc bulge with a superimposed left foraminal disc protrusion.

We found that young and middle-aged individuals with CLSS demonstrate increased incidence of degenerative changes in the specific osseous and soft-tissue elements of the lumbar spine. In particular, these subjects exhibit increased incidence of “shallow annular bulges”, a term which has not been previously established, but has been used in our practice to describe a particular type of disc bulge, which involves greater than 50% of the disc boundary, but does not meet the strict definition of circumferential bulge, in which a loss of the posterior disc concavity is also present (Figure 2). Shallow annular bulges preferentially narrow the neural foramina, similar to foraminal herniations. It may be speculated that, in CLSS, the thecal sac becomes less pliable due to the uniformly narrowed spinal canal, as well as less compressible due to the opposing intrinsic pressure of the cerebrospinal fluid. As a result, the thecal sac demonstrates increased resistance against posterior disc bulges or herniations in the initial stages of degenerative disc disease. In the above setting, a degenerated disc, acquiring the path of least resistance, tends to project into the foramina rather than the spinal canal. Consequently, the disc potentially maintains its posterior concavity and a shallow annular bulge is established. The above hypothesis could also explain the increased incidence of foraminal protrusions and anterior disc herniations in CLSS. The spectrum of findings is completed with increased incidence of circumferential annular bulges and spondylolisthesis (Figure 3).

Knowledge of the spectrum of MRI findings in CLSS could not only extend our understanding of the latter entity, but also assist radiologists in providing more detailed lumbar spine MRI reports. In most situations, radiologists begin the assessment of lumbar spine MRI studies from a quick evaluation of the mid-sagittal image, therefore establishing CLSS could alert readers for the presence of the aforementioned features.

This study has certain limitations. First, all studied subjects reported back pain, therefore the incidence of degenerative disc disease was probably high in this biased group, and may have affected the results. Second, all MRI examinations were evaluated in consensus by the two readers, therefore the inter-observer variability could

not be estimated. Third, due to the absence of a widely accepted cut-off value of mid-sagittal canal diameter to define CLSS, we used a cut-off value that “summates” previous reports, and probably provides a good trade-off between specificity and sensitivity for detecting CLSS. However, the use of an absolute dividing line between subjects with and without CLSS is probably arbitrary, and a continuous zone between the two groups most likely exists.

In conclusion, CLSS is associated with early development of degenerative changes in specific osseous and soft-tissue elements of the lumbar spine, which could reflect altered spinal biomechanics. The spectrum of imaging findings includes the shallow annular bulge, in which the posterior concavity of the intervertebral disc is preserved. Knowledge of the above spectrum could extend our understanding of CLSS, and assist radiologists in providing more detailed lumbar spine MRI reports.

## COMMENTS

### Background

Congenital lumbar spinal stenosis (CLSS) is a developmental narrowing of the spinal canal, which is associated with early neurogenic complications and relatively few radiographically evident degenerative spondylotic changes. This article investigates the association between CLSS and degenerative changes in various osseous and soft-tissue elements of the lumbar spine.

### Research frontiers

Evaluation of subjects with CLSS by means of magnetic resonance imaging to investigate the spectrum of early degenerative changes of the lumbar spine in the respective entity.

### Innovations and breakthroughs

This is the first article to describe the spectrum of early degenerative changes of the lumbar spine in subjects with CLSS.

### Applications

Providing knowledge of the spectrum of early degenerative changes of the lumbar spine in subjects with CLSS this article extends our understanding of the entity and may assist radiologists in providing more detailed MRI reports.

### Peer review

This is a very interesting article describing uncertain entity as congenital lumbar stenosis is.

## REFERENCES

- 1 Verbiest H. Primary stenosis of the lumbar spinal canal



- in adults, a new syndrome. *Ned Tijdschr Geneesk* 1950; **94**: 2415-2433 [PMID: 14775758]
- 2 **Verbiest H.** Further reports on primary stenosis of the lumbar spinal canal in adults. *Ned Tijdschr Geneesk* 1951; **95**: 1965-1970 [PMID: 14863442]
  - 3 **Verbiest H.** A radicular syndrome from developmental narrowing of the lumbar vertebral canal. *J Bone Joint Surg Br* 1954; **36-B**: 230-237 [PMID: 13163105]
  - 4 **Arnoldi CC, Brodsky AE, Cauchoix J, Crock HV, Dommissie GF, Edgar MA, Gargano FP, Jacobson RE, Kirkaldy-Willis WH, Kurihara A, Langenskiöld A, Macnab I, McIvor GW, Newman PH, Paine KW, Russin LA, Sheldon J, Tile M, Urist MR, Wilson WE, Wiltse LL.** Lumbar spinal stenosis and nerve root entrapment syndromes. Definition and classification. *Clin Orthop Relat Res* 1976; **(115)**: 4-5 [PMID: 1253495]
  - 5 **Singh K, Samartzis D, Vaccaro AR, Nassr A, Andersson GB, Yoon ST, Phillips FM, Goldberg EJ, An HS.** Congenital lumbar spinal stenosis: a prospective, control-matched, cohort radiographic analysis. *Spine J* 2005; **5**: 615-622 [PMID: 16291100 DOI: 10.1016/j.spinee.2005.05.385]
  - 6 **Robertson SC, Traynelis VC, Follett KA, Menezes AH.** Idiopathic spinal epidural lipomatosis. *Neurosurgery* 1997; **41**: 68-74; discussion 74-75 [PMID: 9218297 DOI: 10.1097/00006123-199707000-00015]
  - 7 **Dai LY, Ni B, Jia LS, Liu HK.** Lumbar disc herniation in patients with developmental spinal stenosis. *Eur Spine J* 1996; **5**: 308-311 [PMID: 8915635 DOI: 10.1007/BF00304345]
  - 8 **Verbiest H.** Results of surgical treatment of idiopathic developmental stenosis of the lumbar vertebral canal. A review of twenty-seven years' experience. *J Bone Joint Surg Br* 1977; **59**: 181-188 [PMID: 141452]
  - 9 **Eisenstein S.** The morphometry and pathological anatomy of the lumbar spine in South African negroes and caucasoids with specific reference to spinal stenosis. *J Bone Joint Surg Br* 1977; **59**: 173-180 [PMID: 873978]
  - 10 **Vanharanta H, Korpi J, Heliövaara M, Troup JD.** Radiographic measurements of lumbar spinal canal size and their relation to back mobility. *Spine (Phila Pa 1976)* 1985; **10**: 461-466 [PMID: 2931835]
  - 11 **Kitab SA, Alsulaiman AM, Benzel EC.** Anatomic radiological variations in developmental lumbar spinal stenosis: a prospective, control-matched comparative analysis. *Spine J* 2014; **14**: 808-815 [PMID: 24314904 DOI: 10.1016/j.spinee.2013.09.012]

**P- Reviewer:** Afzal M, Bludovsky D, Nagashima H, Panchal R  
**S- Editor:** Song XX **L- Editor:** A **E- Editor:** Wu HL



## Appendiceal Crohn's disease clinically presenting as acute appendicitis

Hulin Han, Hyunsung Kim, Abdul Rehman, Se Min Jang, Seung Sam Paik

Hulin Han, Hyunsung Kim, Abdul Rehman, Se Min Jang, Seung Sam Paik, Department of Pathology, College of Medicine, Hanyang University, Seoul 133-792, South Korea  
Author contributions: Kim H and Rehman A contributed to acquisition of data, the literature search and improved manuscript's English; Jang SM revised the manuscript critically for important intellectual content; Han H and Paik SS designed and wrote this paper.

Correspondence to: Seung Sam Paik, MD, Department of Pathology, College of Medicine, Hanyang University, 222 Wangsimri-ro, Sungdong-ku, Seoul 133-792, South Korea. [sspaik@hanyang.ac.kr](mailto:sspaik@hanyang.ac.kr)  
Telephone: +82-2-22908252 Fax: +82-2-22967502  
Received: July 24, 2014 Revised: August 19, 2014  
Accepted: October 28, 2014  
Published online: December 16, 2014

### Abstract

**AIM:** To determine the incidence of appendiceal Crohn's disease (CD) and to summarize the characteristic histologic features of appendiceal CD.

**METHODS:** We reviewed the pathology files of 2179 appendectomy specimens from January 2007 to May 2013. The computer-assisted retrieval search facility was utilized to collect specimens. We selected those cases that were diagnosed as CD or chronic granulomatous inflammation and defined the final diagnosis according to the histologic findings of CD, including transmural lymphocytic inflammation, non-caseating epithelioid granulomas, thickening of the appendiceal wall secondary to hypertrophy of muscularis mucosa, mucosal ulceration with crypt abscesses, mucosal fissures, and fistula formation.

**RESULTS:** We found 12 cases (7 male and 5 female patients, with an average age of 29.8 years) of appendiceal CD. The incidence of appendiceal CD was 0.55%. The chief complaints were right lower quadrant pain, abdominal pain, lower abdominal pain, and diarrhea. The duration of symptom varied from 2 d to 5 mo.

The histologic review revealed appendiceal wall thickening in 11 cases (92%), transmural inflammation in all cases (100%), lymphoid aggregates in all cases (100%), epithelioid granulomas in all cases (100%), mucosal ulceration in 11 cases (92%), crypt abscesses in 5 cases (42%), perforation in 2 cases (17%), muscular hypertrophy in 1 case (8%), neural hyperplasia in 5 cases (42%), and perpendicular serosal fibrosis in 8 cases (67%).

**CONCLUSION:** A typical and protracted clinical course, unusual gross features of the appendix and the characteristic histologic features are a clue in the diagnosis of appendiceal CD.

© 2014 Baishideng Publishing Group Inc. All rights reserved.

**Key words:** Appendix; Appendectomy; Acute appendicitis; Crohn's disease; Prognosis

**Core tip:** Appendiceal Crohn's disease (CD) is relatively rare and is indistinguishable from acute appendicitis. Appendiceal CD shows a favorable clinical outcome with a low recurrence rate. The differential diagnosis includes intestinal tuberculosis, foreign body reaction, diverticulitis of the appendix, sarcoidosis, actinomycosis, and *Yersinia* infection. Atypical and protracted clinical course, unusual gross features of the appendix and the characteristic histologic features are a clue in the diagnosis of appendiceal CD.

Han H, Kim H, Rehman A, Jang SM, Paik SS. Appendiceal Crohn's disease clinically presenting as acute appendicitis. *World J Clin Cases* 2014; 2(12): 888-892 Available from: URL: <http://www.wjgnet.com/2307-8960/full/v2/i12/888.htm> DOI: <http://dx.doi.org/10.12998/wjcc.v2.i12.888>

### INTRODUCTION

Crohn's disease (CD) is a chronic inflammatory bowel

disorder characterized by a transmural inflammatory reaction and non-caseating small granulomas and may involve all parts of the gastrointestinal (GI) tract from the mouth to the anus<sup>[1-7]</sup>. The most common sites of involvement are the ileum and colon<sup>[8]</sup>. Appendiceal CD is a rare disease but has been well summarized in the various reports<sup>[9-14]</sup>. The incidence of appendicitis with granulomatous reaction varies from 0.1% to 2.0%<sup>[15]</sup>. Since Meyerding *et al*<sup>[16]</sup> had reported an interesting case of appendiceal CD without demonstrable involvement of the adjacent GI tract in 1953, many additional cases of appendiceal CD have been demonstrated in the literature to date.

The purpose of this retrospective review study was to determine the exact incidence of appendiceal CD in patients who underwent appendectomy and to summarize the common characteristic histologic findings along with a review of the literature.

## MATERIALS AND METHODS

### Ethics

The materials used in our study are human appendix tissue samples, which are products of surgical procedures. Our study contains no private information relating to the patients, and so ensures their anonymity. Therefore, our study has no problems in causing any ethical issue or encroachment of human rights.

### Patient tissue

A retrospective review of 2179 appendectomy specimens from January 2007 to May 2013 was conducted. All patients underwent appendectomy at the Hanyang University Hospital (Seoul, South Korea). The computer-assisted retrieval search facility was utilized to collect appendectomy specimens. Appendices resected for acute appendicitis and those removed as a part of right hemicolectomy and gynecology procedures were collected and reviewed. We selected those cases that were diagnosed as CD or chronic granulomatous inflammation and defined the final diagnosis according to the common histologic findings of CD, including transmural lymphocytic inflammation, non-caseating small epithelioid granulomas, thickening of the appendiceal wall secondary to hypertrophy of muscularis mucosa, mucosal ulceration with crypt abscesses, mucosal fissures, and fistula formation. No evidence of parasitic, fungal and mycobacterial disease, foreign body, or systemic sarcoidosis was found in any patient. The clinical information including age, gender, clinical data, and data about the surgical procedure for each case as well as follow-up data including colonoscopic evaluation was collected. The special staining technique such as Ziehl-Neelsen staining and special molecular technique such as tuberculosis polymerase chain reaction (Tb-PCR) were performed to rule out *Mycobacterium tuberculosis*.

## RESULTS

Out of these 2179 appendectomy specimens, 12 cases

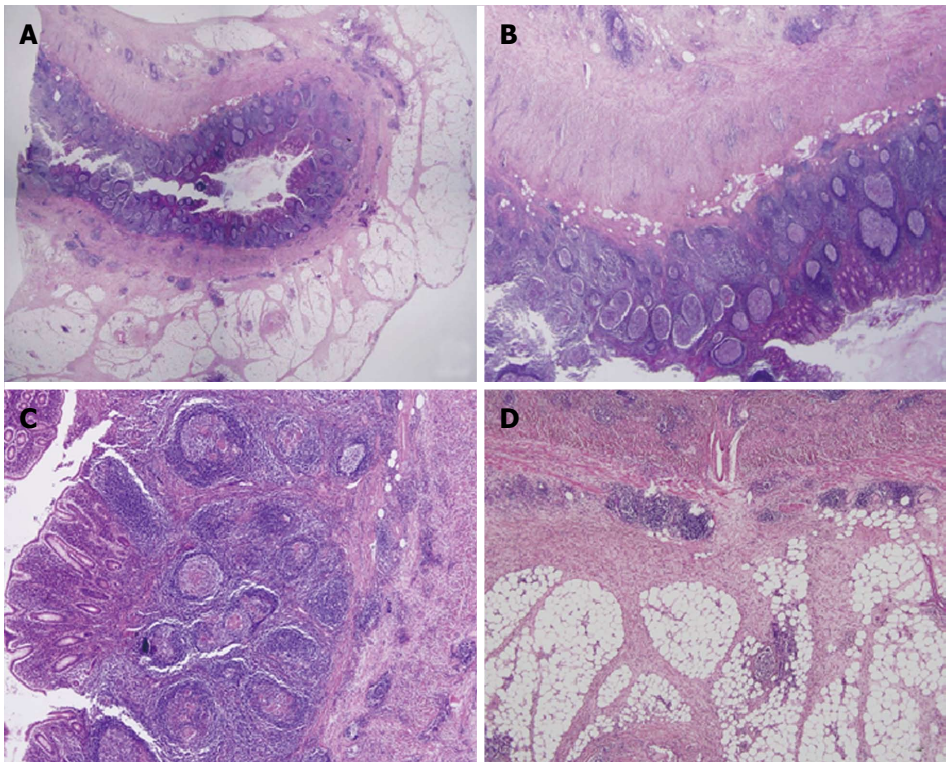
(0.55%) were classified as appendiceal CD. The clinicopathologic characteristics of the appendiceal CD patients are summarized in Tables 1 and 2. Out of these 12 patients, there were 7 male and 5 female patients. The age of patients ranged from 11 to 51 years (average age of 29.8 years). The chief complaints of patients were right lower quadrant (RLQ) pain, abdominal pain, lower abdominal pain, and diarrhea. The duration of symptom with which patients presented varied from 2 d to 5 mo. There was no systemic clinical manifestation such as arthralgia, uveitis, or arthritis. No history of tuberculosis of any organ was found in these patients. There was also no clinical evidence of systemic sarcoidosis. The initial clinical impression was acute appendicitis in all of these 12 patients along with perforation in 2 among these 12 patients. All patients underwent appendectomy. The final pathologic report was CD in all of these 12 cases. All cases showed a negative result for *Mycobacterium tuberculosis* in Ziehl-Neelsen staining and Tb-PCR. The histologic review of these 12 cases revealed appendiceal wall thickening in 11 cases (92%), transmural inflammation in all cases (100%), lymphoid aggregates in all cases (100%), epithelioid granulomas in all cases (100%), mucosal ulceration in 11 cases (92%), crypt abscesses in 5 cases (42%), perforation with abscess formation in 2 cases (17%), muscular hypertrophy in 1 case (8%), neural hyperplasia in 5 cases (42%), and perpendicular serosal fibrosis in 8 cases (67%). The representative microphotographs are shown in Figure 1. There is no evidence of disease recurrence in these 12 patients to date.

## DISCUSSION

Crohn first described that CD stops at the ileocecal valve with sparing of the colon and appendix. However, this theory was disproved as patients with CD often have involvement of the colon and appendix<sup>[5]</sup>. The first isolated appendiceal CD was reported by Meyerding *et al*<sup>[16]</sup> in 1953. Since Meyerding *et al*<sup>[16]</sup> had reported a case of CD arising in the appendix, many case reports and some collective reviews have been reported in the literature. The incidence of appendiceal CD is variable<sup>[17-21]</sup>. Prieto-Nieto *et al*<sup>[4]</sup> described that approximately 0.2% of patients (10 out of 4468 appendectomies performed during 20 years) had appendiceal CD. In our review, 12 cases (0.55%) out of 2179 appendectomy specimens were revealed as appendiceal CD.

Appendiceal CD is usually found among young patients, however, it can occur at any age<sup>[3,12]</sup>. Yang *et al*<sup>[14]</sup> described the age with onset of disease in 14 patients with appendiceal CD, ranged from 10 to 45 years (average age of 21.1 years). Prieto-Nieto *et al*<sup>[4]</sup> reported the disease onset-age in 10 patients with appendiceal CD, ranged from 10 to 33 years (average age of 29 years). The difference in incidence of disease in males and females has been reported, with male predominance<sup>[4,14]</sup>. In our study, the age ranged from 11 to 51 years, with an average age of 29.8 years. Among 12 patients, 7 were male, reflecting more male patients with the disease described





**Figure 1 Appendiceal Crohn's disease.** A: The appendix with Crohn's disease shows transmural inflammation with markedly thickened wall; B: There is a prominent lymphoid hyperplasia in the mucosa and serosa; C: The mucosa shows many small non-caseating granulomas; D: The serosa shows creeping fat with perpendicular thick fibrous bands.

**Table 1 Summary of the patients with appendiceal Crohn's disease**

Case No.	Sex	Age (yr)	c/c	SD	Clinical impressions	AFB	Tb-PCR
1	F	30	RLQ pain	None	Acute appendicitis	Negative	Negative
2	M	38	RLQ pain	14 d	Acute appendicitis	Negative	Negative
3	M	26	RLQ pain	None	Acute appendicitis	Negative	Negative
4	M	28	RLQ pain	7 d	Acute appendicitis	Negative	Negative
5	F	25	RLQ pain	14 d	Acute appendicitis	Negative	Negative
6	F	29	RLQ pain	7 d	Acute appendicitis	Negative	Negative
7	M	51	RLQ pain	5 mo	Acute appendicitis, perforation	Negative	Negative
8	F	49	RLQ pain	8 d	Acute appendicitis	Negative	Negative
9	M	30	Abdominal pain	10 d	Acute appendicitis, perforation	Negative	Negative
10	M	23	Lower abdominal pain	2 d	Acute appendicitis	Negative	Negative
11	M	18	Lower abdominal pain, diarrhea	3 d	Acute appendicitis	Negative	Negative
12	F	11	RLQ pain	7 d	Acute appendicitis	Negative	Negative

F: Female; M: Male; c/c: Chief complaint; RLQ: Right lower quadrant; SD: Symptom duration; AFB: Acid-fast bacillus; Tb-PCR: Tuberculosis polymerase chain reaction.

previously.

The clinical presentation of appendiceal CD is variable. The most common presenting symptom is acute lower abdominal pain especially in the RLQ, which is very similar to the lower abdominal pain presented in patients with acute appendicitis<sup>[4,13,22]</sup>. Approximately 25% of appendiceal CD patients show chronic abdominal pain in the right lower abdomen<sup>[13]</sup>. The symptoms may be more protracted or recurrent than in the usual case of acute suppurative appendicitis. Appendiceal CD should be suspected when the patients show atypical or protracted unusual clinical course<sup>[2,13]</sup>. In our study, most patients presented with the pain in the RLQ. The initial clinical

impression was acute appendicitis in all 12 patients. Most patients had symptoms for two or more days, and 8 patients (67%) presented with these symptoms for over a week.

Appendiceal CD usually shows an enlarged appendix with marked thickening of the appendiceal wall and fibrous adhesion to the periappendiceal soft tissue<sup>[2,22,23]</sup>. Microscopically, the histologic features are characterized by transmural chronic inflammation with marked fibrous thickening of the wall, lymphoid aggregates, small non-caseating granulomas, ulcerative mucosal change, crypt abscesses, muscular hypertrophy, and neural hyperplasia<sup>[13,24-26]</sup>. In our study, the features were similar to the



**Table 2 Summary of histologic features of appendiceal Crohn's disease**

Histologic features	Number of cases	%
Wall thickening	11/12	92
Transmural inflammation	12/12	100
Lymphoid aggregates	12/12	100
Epithelioid granulomas	12/12	100
Mucosal ulceration	11/12	92
Crypt abscess	5/12	42
Perforation	2/12	17
Muscular hypertrophy	1/12	8
Neural hyperplasia	5/12	42
Perpendicular serosal fibrosis	8/12	67

previously described histologic characteristics. Interestingly, we found that appendiceal CD had the characteristic perpendicular serosal fibrous band formation in 8 out of 12 cases.

The differential diagnosis includes intestinal tuberculosis, foreign body reaction, diverticulitis of the appendix, sarcoidosis, actinomycosis, and *Yersinia* infection<sup>[10,13,22,24,25]</sup>. Appendiceal tuberculosis results in the formation of epithelioid granulomas, however, the granulomas in tuberculosis are larger with a central caseous necrosis and less discrete than those in Crohn's disease<sup>[10,27-29]</sup>. If a foreign body is present, histologic examination should reveal the offending material and diverticular disease may be excluded via careful examination<sup>[14,27]</sup>. Intestinal sarcoidosis is extremely rare and does not occur as an isolated finding<sup>[13,30]</sup>. Actinomycosis also results in a vague granulomatous tissue reaction, however, actinomycosis shows neutrophilic abscess formation with floating bacterial colonies (sulphur granules)<sup>[31-34]</sup>. *Yersinia* infection results in necrotizing granulomatous reaction in the appendiceal mucosa or submucosa and shows microabscess formation<sup>[35,36]</sup>.

The treatment of choice for appendiceal CD is appendectomy<sup>[30]</sup>. Appendiceal CD shows lower recurrence rate compared with CD arising in other parts of the intestine<sup>[25]</sup>. The prognosis of appendiceal CD seems to be much better than that of CD arising in the small or large bowel<sup>[14]</sup>.

In conclusion, we described the incidence of appendiceal CD in patients who underwent appendectomy and summarized the common characteristic histologic findings along with a review of the literature. Atypical and protracted clinical course, unusual gross features of the appendix and the characteristic features are a clue in the diagnosis of appendiceal CD.

## COMMENTS

### Background

Appendiceal Crohn's disease (CD) is a rare disease. Since Meyerding *et al* had reported an interesting case of appendiceal CD without demonstrable involvement of the adjacent gastrointestinal tract in 1953, many additional cases of appendiceal CD have been demonstrated in the literature to date.

### Research frontiers

The incidence of appendicitis with granulomatous reaction varies from 0.1% to

2.0%. The incidence of appendiceal CD is variable. The purpose of this study was to determine the exact incidence of appendiceal CD in patients who underwent appendectomy and to summarize the common characteristic histologic findings along with a review of the literature.

### Innovations and breakthroughs

The histologic features are characterized by transmural chronic inflammation with marked fibrous thickening of the wall, lymphoid aggregates, small non-caseating granulomas, ulcerative mucosal change, crypt abscesses, muscular hypertrophy, and neural hyperplasia. In this study, the features were similar to the previously described histologic characteristics. However, the authors found that appendiceal CD had the characteristic perpendicular serosal fibrous band formation in 8 out of 12 cases.

### Applications

With the characteristic clinical presentation and the typical pathologic findings, the clinicians and pathologists can consider the possibility of appendiceal CD. Atypical and protracted clinical course, unusual gross features of the appendix and the characteristic histologic features are a clue in the diagnosis of appendiceal CD.

### Terminology

CD is a chronic inflammatory bowel disorder characterized by a transmural inflammatory reaction and non-caseating small granulomas and may involve all parts of the gastrointestinal tract from the mouth to the anus.

### Peer review

The authors described appendiceal CD clinically presenting as acute appendicitis. This is an interesting review and CD in appendix is a rare condition. Whenever it is encountered, the surgeon must know what to do and be aware of its prognosis. This paper will lead surgeons to this condition.

## REFERENCES

- 1 Stangl PC, Herbst F, Birner P, Oberhuber G. Crohn's disease of the appendix. *Virchows Arch* 2002; **440**: 397-403 [PMID: 11956821 DOI: 10.1007/s004280100532]
- 2 Vanek VW, Spirtos G, Awad M, Badjatia N, Bernat D. Isolated Crohn's disease of the appendix. Two case reports and a review of the literature. *Arch Surg* 1988; **123**: 85-87 [PMID: 3276297 DOI: 10.1001/archsurg.1988.01400250095017]
- 3 Haddad M, Azim F, Koren A, Stelman E, Mor C, Zelikovski A. Crohn's disease of the appendix. *Eur J Surg* 1993; **159**: 191-192 [PMID: 8102900]
- 4 Prieto-Nieto I, Perez-Robledo JP, Hardisson D, Rodriguez-Montes JA, Larrauri-Martinez J, Garcia-Sancho-Martin L. Crohn's disease limited to the appendix. *Am J Surg* 2001; **182**: 531-533 [PMID: 11754865 DOI: 10.1016/S0002-9610(01)00811-X]
- 5 Crohn BB, Ginzburg L, Oppenheimer GD. Regional ileitis: a pathologic and clinical entity. 1932. *Mt Sinai J Med* 2000; **67**: 263-268 [PMID: 10828911 DOI: 10.1001/jama.1932.02740680019005]
- 6 Kahn E, Markowitz J, Daum F. The appendix in inflammatory bowel disease in children. *Mod Pathol* 1992; **5**: 380-383 [PMID: 1495944]
- 7 Kovalcik P, Simstein L, Weiss M, Mullen J. The dilemma of Crohn's disease: Crohn's disease and appendectomy. *Dis Colon Rectum* 1977; **20**: 377-380 [PMID: 872706 DOI: 10.1007/BF02587363]
- 8 Nivatvongs S. Crohn's disease of the appendix: report of a case and review of the literature. *Dis Colon Rectum* 1978; **21**: 361-363 [PMID: 699727 DOI: 10.1007/BF02586668]
- 9 Zager JS, Gusani NJ, Derubertis BG, Shaw JP, Kaufman JP, DeNoto G. Laparoscopic appendectomy for Crohn's disease of the appendix presenting as acute appendicitis. *J Laparoendosc Adv Surg Tech A* 2001; **11**: 255-258 [PMID: 11569518 DOI: 10.1089/109264201750539808]
- 10 Lindhagen T, Ekelund G, Leandroer L, Hildell J, Lindström C, Wenckert A. Crohn's disease confined to the appendix. *Dis Colon Rectum* 1982; **25**: 805-808 [PMID: 6756829 DOI: 10.1007/BF02553319]
- 11 Agha FP, Ghahremani GG, Panella JS, Kaufman MW. Appendicitis as the initial manifestation of Crohn's disease:

- radiologic features and prognosis. *AJR Am J Roentgenol* 1987; **149**: 515-518 [PMID: 3497535 DOI: 10.2214/ajr.149.3.515]
- 12 **Ruiz V**, Unger SW, Morgan J, Wallack MK. Crohn's disease of the appendix. *Surgery* 1990; **107**: 113-117 [PMID: 2404347]
- 13 **McCue J**, Coppen MJ, Rasbridge SA, Lock MR. Crohn's disease of the appendix. *Ann R Coll Surg Engl* 1988; **70**: 300-303 [PMID: 3056207]
- 14 **Yang SS**, Gibson P, McCaughey RS, Arcari FA, Bernstein J. Primary Crohn's disease of the appendix: report of 14 cases and review of the literature. *Ann Surg* 1979; **189**: 334-339 [PMID: 426564 DOI: 10.1097/0000658-197903000-00014]
- 15 **AbdullGaffar B**. Granulomatous diseases and granulomas of the appendix. *Int J Surg Pathol* 2010; **18**: 14-20 [PMID: 20106828 DOI: 10.1177/1066896909349246]
- 16 **Meyerding EV**, Bertram HF. Nonspecific granulomatous inflammation (Crohn's disease) of the appendix; a case report. *Surgery* 1953; **34**: 891-894 [PMID: 13113513]
- 17 **Larsen E**, Axelsson C, Johansen A. The pathology of the appendix in morbus Crohn and ulcerative colitis. *Acta Pathol Microbiol Scand Suppl* 1970; **212**: Suppl 212: 161+ [PMID: 5267086]
- 18 **Lennard-Jones JE**, Morson BC. Changing concepts in Crohn's disease. *Dis Mon* 1969; **Aug**: 1-37 [PMID: 4309015]
- 19 **Lockhart-mummery HE**, Morson BC. Crohn's disease of the large intestine. *Gut* 1964; **5**: 493-509 [PMID: 14244023 DOI: 10.1136/gut.5.6.493]
- 20 **Rappaport H**, Burgoyne FH, Smetana HF. The pathology of regional enteritis. *Mil Surg* 1951; **109**: 463-502 [PMID: 14874971]
- 21 **Warren S**, Sommers SC. Cicatrizing enteritis as a pathologic entity; analysis of 120 cases. *Am J Pathol* 1948; **24**: 475-501 [PMID: 18859355]
- 22 **Cerdán FJ**, Balsa T, Torres-Melero J, García MC, Remezal M, Balibrea JL. Appendiceal Crohn's disease. *Rev Esp Enferm Dig* 1995; **87**: 331-334 [PMID: 7794643]
- 23 **Wettergren A**, Munkholm P, Larsen LG, Meinecke B, Langholz E, Jess P, Binder V. Granulomas of the appendix: is it Crohn's disease? *Scand J Gastroenterol* 1991; **26**: 961-964 [PMID: 1947789 DOI: 10.3109/00365529108996249]
- 24 **Kosakowski C**, Thompson JE, Feinberg MJ. Coexistence of primary Crohn's disease and carcinoid tumor isolated to the appendix. A case report. *Acta Chir Scand* 1986; **152**: 233-236 [PMID: 3716745]
- 25 **Ariel I**, Vinograd I, Hershlag A, Olsha O, Argov S, Klausner JM, Rabau MY, Freund U, Rosenmann E. Crohn's disease isolated to the appendix: truths and fallacies. *Hum Pathol* 1986; **17**: 1116-1121 [PMID: 3770730 DOI: 10.1016/S0046-8177(86)80416-6]
- 26 **Early CK**, Kouri S. Granulomatous disease of the appendix manifesting as a cecal mass: report of a case. *Dis Colon Rectum* 1980; **23**: 421-422 [PMID: 7418581 DOI: 10.1007/BF02586793]
- 27 **Allen DC**, Biggart JD. Granulomatous disease in the vermiform appendix. *J Clin Pathol* 1983; **36**: 632-638 [PMID: 6853730 DOI: 10.1136/jcp.36.6.632]
- 28 **Wang TK**, Tolnai G, Campbell JS, Sirois J, Liepa E. Crohn's disease of the appendix. *Can Med Assoc J* 1972; **106**: 233-236 [PMID: 5057957]
- 29 **Weiss Y**, Durst AL. Crohn's disease of the appendix. Presentation of a case with review of the literature. *Am J Gastroenterol* 1975; **63**: 333-339 [PMID: 1130399]
- 30 **Bak M**, Andersen JC. Crohn's disease limited to the vermiform appendix. *Acta Chir Scand* 1987; **153**: 441-446 [PMID: 3673453]
- 31 **Liu V**, Val S, Kang K, Velcek F. Case report: actinomycosis of the appendix--an unusual cause of acute appendicitis in children. *J Pediatr Surg* 2010; **45**: 2050-2052 [PMID: 20920728 DOI: 10.1016/j.jpedsurg.2010.06.015]
- 32 **Lee SY**, Kwon HJ, Cho JH, Oh JY, Nam KJ, Lee JH, Yoon SK, Kang MJ, Jeong JS. Actinomycosis of the appendix mimicking appendiceal tumor: a case report. *World J Gastroenterol* 2010; **16**: 395-397 [PMID: 20082489 DOI: 10.3748/wjg.v16.i3.395]
- 33 **Altanis E**. Actinomycosis of the appendix and pelvis. *J Reprod Med* 2009; **54**: 411-412; author reply 412 [PMID: 19642234]
- 34 **Yigiter M**, Kiyici H, Arda IS, Hiçsönmez A. Actinomycosis: a differential diagnosis for appendicitis. A case report and review of the literature. *J Pediatr Surg* 2007; **42**: E23-E26 [PMID: 17560191 DOI: 10.1016/j.jpedsurg.2007.03.057]
- 35 **Kojima M**, Morita Y, Shimizu K, Yoshida T, Yamada I, Togo T, Johshita T. Immunohistological findings of suppurative granulomas of *Yersinia enterocolitica* appendicitis: a report of two cases. *Pathol Res Pract* 2007; **203**: 115-119 [PMID: 17189675 DOI: 10.1016/j.prp.2006.10.004]
- 36 **Bronner MP**. Granulomatous appendicitis and the appendix in idiopathic inflammatory bowel disease. *Semin Diagn Pathol* 2004; **21**: 98-107 [PMID: 15807470 DOI: 10.1053/j.semdp.2004.12.001]

**P- Reviewer:** Cetinkunar S, Matsumoto S, Sartelli M  
**S- Editor:** Tian YL **L- Editor:** A **E- Editor:** Wu HL



## Tranexamic acid for the management of uterine fibroid tumors: A systematic review of the current evidence

Panagiotis Peitsidis, Anna Koukoulomati

Panagiotis Peitsidis, Department of Obstetrics and Gynecology, Southend University Hospital, Essex SS0 0RY, United Kingdom  
Panagiotis Peitsidis, Department of Obstetrics and Gynecology, Iaso Maternity Hospital, 17123 Athens, Greece

Anna Koukoulomati, Department of Obstetrics and Gynecology, Didymoteichon General Hospital, 68300 Didymoteicho, Greece  
Author contributions: All authors generated the ideas and contributed to the writing of this paper.

Correspondence to: Dr. Panagiotis Peitsidis, Department of Obstetrics and Gynecology, Iaso Maternity Hospital, Proussis 22, 17123 Athens, Greece. [panagiotis\\_pp@yahoo.com](mailto:panagiotis_pp@yahoo.com)

Telephone: +30-21-07473793 Fax: +30-21-07473793

Received: March 26, 2014 Revised: October 28, 2014

Accepted: October 31, 2014

Published online: December 16, 2014

© 2014 Baishideng Publishing Group Inc. All rights reserved.

**Key words:** Tranexamic acid; Uterine fibroids; Fibrinolysis; Menorrhagia; Myomectomy

**Core tip:** Uterine fibroid tumors are the most common gynecologic causes for menorrhagia. Tranexamic acid is a safe non-hormonal medication that significantly reduces abnormal menstrual bleeding. We conducted a systematic review of the contemporary evidence on the administration and efficacy of tranexamic acid in patients with menorrhagia associated with fibroid tumors of the uterus. Antifibrinolytic treatment may reduce blood loss perioperatively in myomectomies, and reduce menorrhagia in patients with fibroids. More double randomized studies with larger numbers of participants are necessary to reach more precise and safe conclusions.

### Abstract

**AIM:** To conduct a detailed systematic review of the current evidence on the administration and efficacy of tranexamic acid in patients with menorrhagia due to uterine fibroids.

**METHODS:** We conducted an electronic search on the following databases PubMed and Medline (1950-2013); (1980-2013); Cochrane library (1993-2013).

**RESULTS:** A total of 36 articles were retrieved after the initial electronic search. Careful assessment of the retrieved studies led to the final selection of 5 articles for inclusion in the review.

**CONCLUSION:** Tranexamic acid may reduce blood loss perioperatively in myomectomies. It may reduce the menorrhagia in patients with fibroids, however a stratification of fibroids by size and location is required to define the responses. It is safe in general, with mild adverse effects observed in some cases. More studies with a double-blind randomized design and larger numbers of participants are necessary to reach more precise and safe conclusions.

Peitsidis P, Koukoulomati A. Tranexamic acid for the management of uterine fibroid tumors: A systematic review of the current evidence. *World J Clin Cases* 2014; 2(12): 893-898 Available from: URL: <http://www.wjgnet.com/2307-8960/full/v2/i12/893.htm> DOI: <http://dx.doi.org/10.12998/wjcc.v2.i12.893>

### INTRODUCTION

Worldwide, approximately 235 million women are affected by uterine fibroids and about 20%-40% of women will be diagnosed with leiomyomas at some point in their life, though only a fraction of those will cause problems or require treatment<sup>[1]</sup>. Uterine fibroid tumors or leiomyomas very often lead to abnormal menstrual bleeding or menorrhagia<sup>[2]</sup>. Menorrhagia is abnormal extensive menstrual bleeding in cases where the quantity of the overall blood loss exceeds 80 mL in every menses<sup>[3]</sup>.

The treatment of uterine leiomyoma may be surgical or conservative. Surgical management consists of total

or subtotal hysterectomy and myomectomy, but in some cases less invasive procedures, such as uterine artery embolization are successful<sup>[3]</sup>.

Data show the presence of extensive fibrinolysis in the menstrual blood of women suffering from menorrhagia, and this has triggered the use of antifibrinolytic drugs as a therapeutic option<sup>[4]</sup>. Tranexamic acid (cyklokapron) is a non-hormonal medication that decreases menstrual hemorrhage and it is an excellent therapeutic option in patients with menorrhagia who opt for nonhormonal management<sup>[5]</sup>. Tranexamic acid achieves hemostasis and elicits its antifibrinolytic action by reversible block of the locus that connects with lysine on plasminogen molecules. It inactivates the plasminogen activator of the endometrium and thus stops fibrinolysis and degradation of the clotting complexes<sup>[6]</sup>. Tranexamic acid has been administered on a daily basis to reduce excessive hemorrhaging and the need for transfusion during and after major cardiac or orthopedic surgeries<sup>[7]</sup>.

In the international literature, several randomized clinical trials have been published which have evaluated and reviewed the efficacy of tranexamic acid in the management of abnormal gynecological hemorrhagic conditions. It is not certain how efficient tranexamic acid is in treating women with normal reproductive function and diagnosed with abnormal bleeding caused by uterine fibroids<sup>[8]</sup>.

### Aim

The aim of the study was to conduct a systematic review of the current evidence on the administration and efficacy of tranexamic acid in patients with menorrhagia caused by uterine myomas. The administration of tranexamic acid during the preoperative and postoperative period as a method of reducing blood loss is also reviewed. No previous systematic review of the use of tranexamic acid in women with fibroids has been reported.

## MATERIALS AND METHODS

### Search strategy

We conducted an electronic search on the following databases PubMed and Medline (1950-2014); EMBASE (1980-2013); Cochrane library (1993-2014). The *Medical Subject Headings* which were utilized were as follows: “tranexamic acid” and “fibroids” and “myomas” and “leiomyomas” and “myomectomy”.

Manuscripts written in English or French languages were selected for inclusion in the study. The retrieved studies were scrutinized and their references were examined carefully in order to reveal any relevant studies not identified initially by the electronic search. The included studies were reviewed independently by two authors (PP and AK). In cases of discrepancy and lack of evidence, the corresponding authors of the studies were contacted to provide further information and clarification. Studies from conferences and scientific meetings were also searched.

From each study, we gathered the following clinical data: author and year of publication; country of origin of

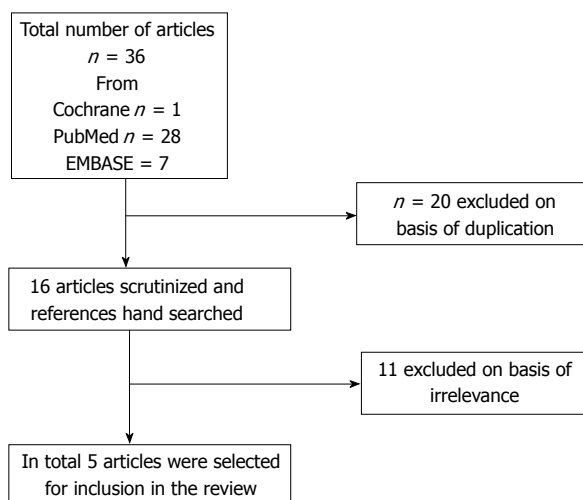


Figure 1 Flowchart of the selection of studies.

study; type of study; number of participants in the study; aim of the study; dosage, type and length of administration of tranexamic acid; data about adverse effects and the conclusion of study results. The clinical data were collected and presented in a table according to chronological order of publication.

### Inclusion criteria

All the studies reported the administration of tranexamic acid for treatment of hemorrhage in women of reproductive age with symptomatic fibroids. In addition, studies that reported the administration of tranexamic acid preoperatively or postoperatively to myomectomy procedures were selected for inclusion.

### Exclusion criteria

Studies that reported the use of tranexamic acid in pregnant women and in women diagnosed with malignant gynecological disease were excluded. Also studies in women with non-symptomatic fibroids, postmenopausal women and women with hemorrhage related to reasons other than fibroids (dysfunctional uterine bleeding; hematological disorders) were not included in the review.

### Quality assessment of studies

The quality assessment of studies was performed according to the guidelines reported from The Scottish Intercollegiate Guidelines Network (SIGN)<sup>[9]</sup>.

## RESULTS

A total of 36 articles were retrieved after the initial electronic search. These 36 articles were scrutinized for duplicate results. The flowchart diagram of the selection process is shown in Figure 1. Eleven articles were excluded because they were not concerned with management of menorrhagia in women with fibroid tumors. Careful assessment of the retrieved studies led to the final selection of 5 articles to be included in the study. A summary of the selected articles is presented in Table 1<sup>[10-14]</sup>. The



Table 1 Summary of the selected studies

Ref.	Country	Type of study	Mean age	Symptomatology	Participants	Aim of the study	Regimen administration	Results	Adverse effects	Comment
Lakhani <i>et al</i> <sup>[10]</sup>	United Kingdom	Longitudinal Prospective	42.8	Menorrhagia Pelvic pain	<i>n</i> = 12	Ultrasound assesment of PI and RI of UA in women with TA administration	Tranexamic acid P.O. 1 g x 3 for 2 cycles	No significant changes in blood loss or PI and RI	Not reported	No changes in UA-PI resistance in women with fibroids
Caglar <i>et al</i> <sup>[11]</sup>	Turkey	Prospective randomized double-blind placebo	34.2	Menorrhagia Pelvic pain	<i>n</i> = 50 (TA) <i>n</i> = 50 (Placebo)	To compare the perioperative blood loss in patients undergoing myomectomy and taking TA with patients not taking TA	Tranexamic acid 10 mg/kg <i>iv</i> (max 1 g) 15 min before incision	Significant statistical differences in two groups postoperative, total blood loss and duration of surgery ( <i>P</i> < 0.01) in favor of TA	Not reported	TA does not reduce perioperative blood loss nor Hb levels. It reduces postoperative and total blood loss and surgery time in correlation with myoma size. However further investigations required
Ip <i>et al</i> <sup>[12]</sup>	Hong Kong	Observational	43.8 ± 25	Menorrhagia Pelvic pain	<i>n</i> = 22	Pathology assesment of fibroid specimen in women receiving TA	Tranexamic acid Per os dosage not reported	Necrosis and infarcts in resected fibroids. Larger diameter fibroids more prone to necrosis changes. Size is an independent factor	Not reported	Authors emphasize the necrosis and thrombosis in fibroids but suggest precaution for complications
Lukes <i>et al</i> <sup>[14]</sup>	United States	Randomized double-blind placebo	36.5	Menorrhagia Pelvic pain	<i>n</i> = 42 (TA) <i>n</i> = 26 (Placebo)	To assess the efficacy and safety of TA for heavy menstrual bleeding	Tranexamic acid Per os 1.3 g daily for 5 d up to 6 cycles	Reduction in menstrual blood loss in women receiving TA compared to placebo. No statistically significant changes in blood loss in patients with fibroids	Mild adverse effects Menstrual cramps Gastrointestinal allergies	TA was effective in the treatment of heavy menstrual bleeding regardless of the presence or absence of fibroids
Eder <i>et al</i> <sup>[13]</sup>	United States	Randomized double-blind placebo	38	Menorrhagia Pelvic pain	<i>n</i> = 96 (TA) <i>n</i> = 51 (Placebo)	To compare the menstrual blood loss in women with fibroids and TA and women with fibroids not taking TA. consisting placebo group	Tranexamic acid Per os 3.9 g/d for 5 d up to 6 menstrual cycles	Menstrual blood loss reduced in women receiving TA ( <i>P</i> < 0.001)	3 patients in TA group and 3 in placebo group reported headache	TA was well tolerated and reduced menstrual blood loss

TA: Tranexamic acid; UA: Umbilical artery; UA-PI: Umbilical artery pulsatility index.

reviewed studies originated from Europe<sup>[10,11]</sup>, Asia<sup>[12]</sup> and America<sup>[13,14]</sup>. All articles were written in English. The studies were published between 1998 and 2013. The total study population from the 5 studies was 349 women; 206 patients were treated with tranexamic acid and 101 patients were allocated to the placebo groups. All patients were premenopausal with a mean age of  $37.65 \pm 3.2$  years. All patients in the study groups presented with menorrhagia and pelvic pain due to uterine fibroids. Three studies had a double-blind randomized design<sup>[11,13,14]</sup>, one had an observational design<sup>[12]</sup> and one had a prospective longitudinal design<sup>[10]</sup>. Tranexamic acid was administered orally in four studies<sup>[10,12-14]</sup>, and intravenously in one study<sup>[11]</sup>. Tranexamic acid reduced the blood loss perioperatively in women undergoing myomectomy in comparison to women not receiving tranexamic acid according to the authors<sup>[11]</sup>. Management of excessive bleeding during the menstrual cycle with tranexamic acid decreased hemorrhage despite the existence of myomas<sup>[13]</sup>.

Furthermore, tranexamic acid reduced the quantity of bleeding in patients with menorrhagia in a pivotal phase III randomized double blind study<sup>[14]</sup>. The authors reported that they estimated the quantity of blood *via* a validated alkaline hematin method in patients with sonographically confirmed fibroids<sup>[14]</sup>. Tranexamic acid did not alter the pulsatility index during ultrasound assessment of women with fibroids<sup>[10]</sup>. Significant pathologic changes were noted in specimens from women who received tranexamic acid and underwent myomectomy. Very mild complications of treatment were seen in 2 studies<sup>[13,14]</sup>, and 3 women in a single study reported headache<sup>[14]</sup>.

### Quality of the studies

The quality assessment of the selected studies according to SIGN criteria is shown in Table 2. Three studies were graded 2++ (high quality studies)<sup>[11,13,14]</sup> and 2 studies were graded 2+ (well conducted studies)<sup>[10,12]</sup>. All studies were conducted in University teaching hospitals<sup>[10-14]</sup>, 3 were conducted in a single setting<sup>[10-12]</sup>, and 2 were conducted in multicenter settings<sup>[13,14]</sup>. Three studies received financial support from pharmaceutical companies<sup>[10,13,14]</sup>.

## DISCUSSION

In practice, tranexamic acid has been administered in many clinical situations in which the inhibition of fibrinolysis has shown beneficial effects in managing hemorrhage. The use of tranexamic acid in Obstetrics and Gynecology as a conservative method for reducing blood loss has been extensive<sup>[15]</sup>. TA provides a non-hormonal, treatment for patients with excessive hemorrhage during the menstrual period<sup>[13]</sup>. How tranexamic acid manages menorrhagia provoked by leiomyoma is still unclear and unknown due to the limited data.

In the current review, according to the reported studies, tranexamic acid is a safe treatment and may reduce menorrhagia in women with fibroids. It reduces the blood loss perioperatively with no adverse effects in women un-

dergoing laparotomy and myomectomy. Tranexamic acid causes necrosis in myomas but does not alter pulsatility indices in ultrasound assessment. However, the current review has some limitations because of the quantity and quality of studies published in the literature and the presence of bias related to the size and location of fibroids.

Despite the fact that tranexamic acid administration has shown a risk for complications like thrombosis and embolism due to its antifibrinolytic effect, thromboembolic events were not been reported in the selected studies. Only mild headaches, allergies and discomfort were reported in a small population of patients<sup>[13,14]</sup>. In the study by Lukes *et al.*<sup>[14]</sup>, the authors did not specify the exact type and number of adverse effects in patients with fibroids, and stated that the most common adverse effect was menstrual discomfort.

Tranexamic acid has been administered widely in Scandinavian and European countries in general as a first-line management option for menorrhagia since the 1970s, and data have shown no increase in the frequency of adverse clotting disorders<sup>[16,17]</sup>. However, the optimal dose and duration of treatment with tranexamic acid has not been established<sup>[18]</sup>.

The efficacy and safety of tranexamic acid when given intravenously for peri- and postoperative hemorrhage has been investigated more in orthopedic and cardiovascular surgical interventions<sup>[19]</sup>. In the study by Caglar *et al.*<sup>[11]</sup>, the authors reported that tranexamic acid succeeded in decreasing perioperative blood loss during excision of myomas; however, they emphasized the importance of various parameters such as type of surgery, surgical skills, and duration of surgery for perioperative blood loss. In the same study, the location and type of myoma (subserous, intramural, submucous) were highlighted and also the number and size of fibroid tumors. Multiple fibroid tumors may increase the duration of surgery in contrast to a single large myoma  $> 6$  cm<sup>[12]</sup>.

Ip *et al.*<sup>[12]</sup> concluded that tranexamic acid induced necrosis of fibroids. Larger fibroids were more prone to necrosis. The authors emphasized the significance of tranexamic acid in conservative management of fibroids, thus sparing unnecessary surgical interventions. However possible complications such as pelvic pain and low grade fever maybe present in these patients<sup>[12]</sup>.

It has been reported in clinical studies that the levels of plasminogen activator are elevated 30 min after the initiation of surgery, and this mechanism may elicit a reduction in bleeding in surgical patients<sup>[11,19]</sup>.

One randomized study investigated whether tranexamic acid was effective in comparison with placebo for the management of menorrhagia in patients with no pathological findings in the pelvis<sup>[13]</sup>. The factual limitations of this study were that in women diagnosed with fibroid tumors, myomas were not found in large numbers and their size was not significant to justify surgical removal. Although the goal of this trial was not to assess the effect of tranexamic acid on abnormal vaginal bleeding caused by myomas, outcomes showed that tranexamic acid was effective in treating heavy menorrhagia, and this was not related

**Table 2** Quality assessment of the studies according to Scottish Intercollegiate Guidelines Network guidelines

Ref.	Setting	Sign grade	Interpretation
Lakhani <i>et al</i> <sup>[10]</sup>	University teaching hospital	2+	Well conducted study
Caglar <i>et al</i> <sup>[11]</sup>	University teaching hospital	2++	High quality study
Ip <i>et al</i> <sup>[12]</sup>	University teaching hospital	2+	Well conducted study
Lukes <i>et al</i> <sup>[14]</sup>	University teaching hospital	2++	High quality study
Eder <i>et al</i> <sup>[13]</sup>	Private research institution and University teaching hospital	2++	High quality study

to the presence of absence of myomas. However, based on the design of the study, it is hard to postulate that treatment with tranexamic acid is influenced by the size and type of the fibroids<sup>[18]</sup>. In the study by Lakhani *et al*<sup>[10]</sup>, women with fibroids were found to have no significant changes in various sonographic parameters. However, these findings may exhibit bias and limitations because the women were not divided into different groups with different sizes and types of myomas<sup>[18]</sup>.

The Food and Drug Administration approved tranexamic acid 650 mg (Lysteda-Ferring) in November 2009. Treatment with tranexamic acid while using hormonal contraceptives may increase the risk of developing thrombosis, cardiac complications, and stroke<sup>[20]</sup>.

Tranexamic acid has been used extensively in patients with heavy menstrual bleeding with good results, and enough evidence is available to support its use. Tranexamic acid may reduce blood loss perioperatively in myomectomies, and may reduce menorrhagia in patients with fibroids, but stratification of fibroids by size and location is required to define the responses to tranexamic acid. Physicians should be aware that tranexamic acid may cause drug-induced necrosis of fibroids and surgical management can be avoided, but complications such as pelvic pain and low grade fever can be present in these patients. It is safe in general, and mild adverse effects are observed in some cases. More studies of a double-blind randomized design and larger numbers of participants are required to reach clearer conclusions about the use of tranexamic acid in patients with fibroids.

## COMMENTS

### Background

Menorrhagia due to fibroid tumors of the uterus is one the leading causes of abnormal menstrual bleeding. Tranexamic acid is non-hormonal and has been used previously for the treatment of dysfunctional uterine bleeding. The role of tranexamic acid in the treatment of abnormal menstrual bleeding due to uterine fibroid tumors is unclear. The authors have reviewed the literature and demonstrated that tranexamic acid may reduce bleeding in myomectomies and also may reduce the amount of bleeding in patients with menorrhagia caused by uterine fibroids.

### Research frontiers

Tranexamic acid may reduce blood loss in patients with menorrhagia due to

fibroids. It may cause drug-induced necrosis of fibroids and surgical management can be avoided, but complications such as pelvic pain and low grade fever can be present in these patients.

### Innovations and breakthroughs

The study showed that tranexamic acid reduced blood loss in patients undergoing myomectomy. It may cause necrosis in fibroids and may reduce the menorrhagia due to fibroids. Tranexamic acid has shown mild adverse effects during its administration. It may be used in patients who do not want hormonal treatment.

### Applications

To ensure that tranexamic acid can be used in patients with menorrhagia caused by uterine fibroids, further double-blind randomized studies are required in order to ensure that the regimen is safe, efficient and does not cause severe effects.

### Terminology

Tranexamic acid is a hemostatic agent that elicits its antifibrinolytic action by reversibly blocking the lysine-binding sites on plasminogen molecules. It inactivates the plasminogen activator in endometrial cells and thus stops fibrinolysis and degradation of the clotting complexes. A number of studies have reported the use of tranexamic in reducing blood loss in cardiac and orthopedic operations. Tranexamic acid has been used to decrease blood loss in patients with menorrhagia. Menorrhagia is abnormal extensive menstrual bleeding where the quantity of overall blood loss exceeds 80 mL in every menses.

### Peer review

The authors here performed a systematic review of the current evidence on the administration and efficacy of Tranexamic acid for these patients.

## REFERENCES

- Wallach EE, Vlahos NF. Uterine myomas: an overview of development, clinical features, and management. *Obstet Gynecol* 2004; **104**: 393-406 [PMID: 15292018]
- Oehler MK, Rees MC. Menorrhagia: an update. *Acta Obstet Gynecol Scand* 2003; **82**: 405-422 [PMID: 12752071]
- Committee on Gynecologic Practice, American College of Obstetricians and Gynecologists. ACOG Committee Opinion. Uterine artery embolization. *Obstet Gynecol* 2004; **103**: 403-404 [PMID: 14754718]
- Dockeray CJ, Sheppard BL, Daly L, Bonnar J. The fibrinolytic enzyme system in normal menstruation and excessive uterine bleeding and the effect of tranexamic acid. *Eur J Obstet Gynecol Reprod Biol* 1987; **24**: 309-318 [PMID: 2953634 DOI: 10.1016/0028-2243(87)90156-0]
- Bodner K, Bodner-Adler B, Kimberger O, Czerwenka K, Mayerhofer K. Estrogen and progesterone receptor expression in patients with uterine smooth muscle tumors. *Fertil Steril* 2004; **81**: 1062-1066 [PMID: 15066464 DOI: 10.1016/j.fertnstert.2003.08.043]
- Callender ST, Warner GT, Cope E. Treatment of menorrhagia with tranexamic acid. A double-blind trial. *Br Med J* 1970; **4**: 214-216 [PMID: 4919554 DOI: 10.1136/bmj.4.5729.214]
- Ido K, Neo M, Asada Y, Kondo K, Morita T, Sakamoto T, Hayashi R, Kuriyama S. Reduction of blood loss using tranexamic acid in total knee and hip arthroplasties. *Arch Orthop Trauma Surg* 2000; **120**: 518-520 [PMID: 11011672 DOI: 10.1007/s004029900132]
- Stein K, Ascher-Walsh C. A comprehensive approach to the treatment of uterine leiomyomata. *Mt Sinai J Med* 2009; **76**: 546-556 [PMID: 20014416 DOI: 10.1002/msj.20145]
- Scottish Intercollegiate Guidelines Network. SIGN 50: a guideline developers' handbook. Edinburgh: SIGN, 2001
- Lakhani KP, Marsh MS, Purcell W, Hardiman P. Uterine artery blood flow parameters in women with dysfunctional uterine bleeding and uterine fibroids: the effects of tranexamic acid. *Ultrasound Obstet Gynecol* 1998; **11**: 283-285 [PMID: 9618854 DOI: 10.1046/j.1469-0705.1998.11040283.x]
- Caglar GS, Tasci Y, Kayikcioglu F, Haberal A. Intravenous tranexamic acid use in myomectomy: a prospective randomized double-blind placebo controlled study. *Eur J Obstet Gynecol Reprod Biol* 2008; **137**: 227-231 [PMID: 17499419 DOI:

- 10.1016/j.ejogrb.2007.04.003]
- 12 **Ip PP**, Lam KW, Cheung CL, Yeung MC, Pun TC, Chan QK, Cheung AN. Tranexamic acid-associated necrosis and intralesional thrombosis of uterine leiomyomas: a clinico-pathologic study of 147 cases emphasizing the importance of drug-induced necrosis and early infarcts in leiomyomas. *Am J Surg Pathol* 2007; **31**: 1215-1224 [PMID: 17667546]
- 13 **Eder S**, Baker J, Gersten J, Mabey RG, Adomako TL. Efficacy and safety of oral tranexamic acid in women with heavy menstrual bleeding and fibroids. *Womens Health (Lond Engl)* 2013; **9**: 397-403 [PMID: 23656203 DOI: 10.2217/whe.13.28]
- 14 **Lukes AS**, Moore KA, Muse KN, Gersten JK, Hecht BR, Edlund M, Richter HE, Eder SE, Attia GR, Patrick DL, Rubin A, Shangold GA. Tranexamic acid treatment for heavy menstrual bleeding: a randomized controlled trial. *Obstet Gynecol* 2010; **116**: 865-875 [PMID: 20859150 DOI: 10.1097/AOG.0b013e3181f20177]
- 15 **Peitsidis P**, Kadir RA. Antifibrinolytic therapy with tranexamic acid in pregnancy and postpartum. *Expert Opin Pharmacother* 2011; **12**: 503-516 [PMID: 21294602 DOI: 10.1517/14656566.2011.545818]
- 16 **Berntorp E**, Follrud C, Lethagen S. No increased risk of venous thrombosis in women taking tranexamic acid. *Thromb Haemost* 2001; **86**: 714-715 [PMID: 11522029]
- 17 **Rybo G**. Tranexamic acid therapy: effective treatment in heavy menstrual bleeding: clinical update on safety. *Therapeutic Advances* 1991; **4**: 1-8
- 18 **Naoulou B**, Tsai MC. Efficacy of tranexamic acid in the treatment of idiopathic and non-functional heavy menstrual bleeding: a systematic review. *Acta Obstet Gynecol Scand* 2012; **91**: 529-537 [PMID: 22229782 DOI: 10.1111/j.1600-0412.2012.01361.x]
- 19 **Dunn CJ**, Goa KL. Tranexamic acid: a review of its use in surgery and other indications. *Drugs* 1999; **57**: 1005-1032 [PMID: 10400410 DOI: 10.2165/00003495-199957060-00017]
- 20 Tranexamic acid (Lysteda) for treating menorrhagia [updated 2011 April]. Available from: URL: [http://www.accessdata.fda.gov/drugsatfda\\_docs/label/2011/022430s002lbl.pdf](http://www.accessdata.fda.gov/drugsatfda_docs/label/2011/022430s002lbl.pdf)

**P- Reviewer:** Mais V, Sonoda K, Wang PH **S- Editor:** Ji FF  
**L- Editor:** A **E- Editor:** Wu HL





## Reconstruction using a pedicled upper arm fillet flap after excision of a malignant peripheral nerve sheath tumor: A case report

Parteek Singla, Swapnil D Kachare, Timothy L Fitzgerald, Richard S Zeri, Enamul Haque

Parteek Singla, Brody School of Medicine, East Carolina University, Greenville, NC 27834, United States

Swapnil D Kachare, Timothy L Fitzgerald, Richard S Zeri, Enamul Haque, Department of Surgery, The Brody School of Medicine, East Carolina University, Greenville, NC 27834, United States

Author contributions: Singla P, Kachare SD, Fitzgerald TL, Zeri RS, Haque E all made equal and substantial contributions to the conception, design, drafting, and revisions of the manuscript.

Correspondence to: Parteek Singla, BS, Medical Student IV, Brody School of Medicine, East Carolina University, 600 Moye Boulevard, Greenville, NC 27834,

United States. [singlap07@students.ecu.edu](mailto:singlap07@students.ecu.edu)

Telephone: +1-252-5615537 Fax: +1-252-7445777

Received: July 25, 2014 Revised: August 29, 2014

Accepted: October 14, 2014

Published online: December 16, 2014

**Key words:** Reconstruction; Flaps; Neurofibromatosis; Malignant Peripheral Nerve Sheath Tumor; Sarcoma

**Core tip:** Here we present a rare case on the use of a pedicled fillet flap of the upper arm for chest wall reconstruction after excision of a malignant peripheral nerve sheath tumor in a patient with neurofibromatosis. This case report describes a reconstructive procedure that is rarely described in the literature as a viable option for soft tissue coverage of shoulder and chest wall defects after an oncologic resection.

Singla P, Kachare SD, Fitzgerald TL, Zeri RS, Haque E. Reconstruction using a pedicled upper arm fillet flap after excision of a malignant peripheral nerve sheath tumor: A case report. *World J Clin Cases* 2014; 2(12): 899-902 Available from: URL: <http://www.wjgnet.com/2307-8960/full/v2/i12/899.htm> DOI: <http://dx.doi.org/10.12998/wjcc.v2.i12.899>

### Abstract

Non-salvageable extremities have been utilized for harvesting fillet flaps as part of the "spare parts" concept in traumatic and oncologic settings. Here we report on the use of a pedicled fillet flap of the upper arm for chest wall reconstruction after excision of a malignant peripheral nerve sheath tumor in a patient with neurofibromatosis. Pedicled flaps as part of the "spare parts" concept provide the advantage of reduced donor-site morbidity, immediate closure, intact vasculature, and adequate soft tissue coverage of large defects. Malignant peripheral nerve sheath tumor is a rare aggressive tumor with a poor prognosis that may result in large defects post resection. Limited data describes the use of pedicled fillet flaps of the upper extremity. We report the use of a pedicled fillet flap of the upper arm as a viable option that can be successfully used for coverage of soft tissue defects of the shoulder and chest wall post complex resections in an oncologic setting.

© 2014 Baishideng Publishing Group Inc. All rights reserved.

### INTRODUCTION

The use of non-salvageable extremities for harvesting fillet flaps has been utilized for reconstruction as part of the "spare parts" concept in traumatic and oncologic settings. Fillet flaps have been extensively characterized based on their clinical value and can be used as pedicled or free flaps<sup>[1]</sup>, however there is limited data describing the use of fillet flaps of the upper extremity<sup>[2]</sup>. Here we report a rare case of harvesting a pedicled fillet flap of the upper arm for chest wall reconstruction after excision of a malignant peripheral nerve sheath tumor (MPNST) in a patient with neurofibromatosis.

### CASE REPORT

A 42-year-old female with a history of neurofibromatosis presented to plastic surgery clinic with complaints

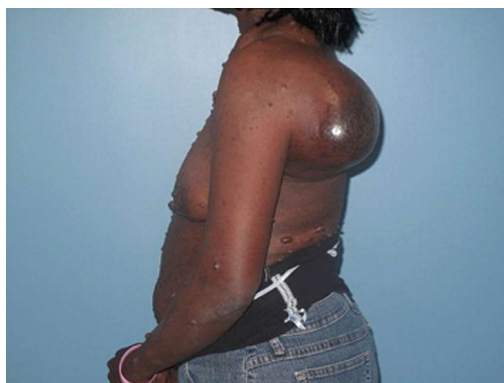


Figure 1 Left shoulder mass at initial presentation.

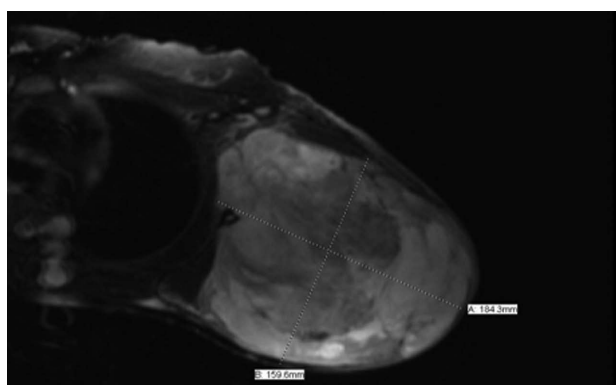


Figure 2 Magnetic resonance imaging of left shoulder, Mass: 18.4 cm × 15.9 cm × 20 cm.

of a left shoulder mass growing for the past two years that caused significant pain with movement (Figure 1). Magnetic resonance imaging (MRI) revealed 18.4 cm × 15.9 cm × 20 cm mass concerning for possible malignant degeneration of a neurofibroma based on size and clinical history (Figure 2). Neoadjuvant chemoradiation per National Comprehensive Cancer Network guidelines for resectable soft tissue sarcomas with potential for adverse functional outcomes<sup>[3]</sup> was discussed. Patient was lost to follow up after initial planning and when she returned, she was unable to lay supine secondary to pain from the tumor, which had obvious necrosis with bleeding. Chest computerized tomography (CT) revealed a left large axillary mass with scapular erosion as well as small pulmonary nodules suggestive but not diagnostic of metastatic disease. A decision was made to abandon neoadjuvant therapy and surgically resect the axillary mass followed by adjuvant therapy with close observation of pulmonary lesions.

After the scapula was disarticulated and the tumor excised, it became clear that the arm would be of limited functional use and a modified forequarter amputation with vascular preservation of the upper extremity was performed. A regional flap could not be done due to the wide defect and need for post-operative radiotherapy. Use of a pedicled latissimus dorsi was contraindicated due to tumor invasion, therefore in order to provide immediate closure, without the added time and risk of performing

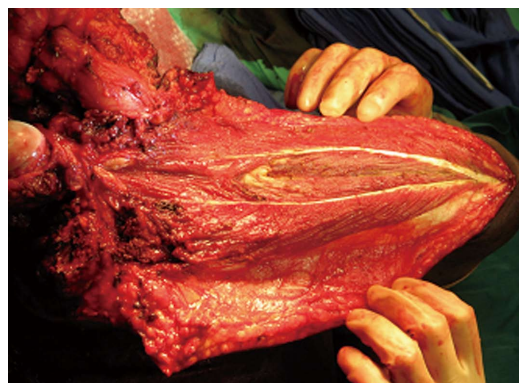


Figure 3 Fillet flap of the upper arm post subperiosteal dissection and removal of the humerus.

a free flap, a musculocutaneous pedicled fillet flap of the left upper arm was chosen for reconstruction.

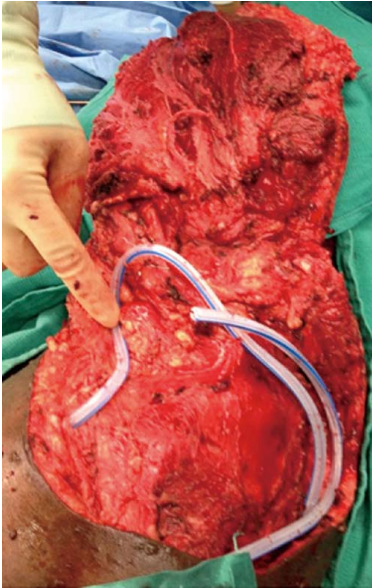
An incision was made on the posterior aspect of the left upper extremity starting at the shoulder joint and extending below the elbow. Skin and triceps muscles were dissected in the midline and then a subperiosteal dissection was performed (Figure 3). Next, the humerus was removed and the arm transected just below the elbow after identifying and ligating the neural and vascular structures. The flap was rotated into the defect without any tension (Figure 4).

Post-operative pathology report demonstrated a T2bN0 grade 2 or stage II b<sup>[3]</sup> MPNST. The tumor was 24 cm × 24 cm × 19 cm in size with focally positive margins. After meeting with radiation and medical oncology, the patient agreed to undergo adjuvant chemoradiation. The patient was initiated on a chemotherapy regimen consisting of doxorubicin and ifosfamide and scheduled for radiation therapy. However, three months after surgery, patient had local recurrence of a mass at her left shoulder. Patient was referred to an outside facility closer to home for adjuvant therapy and this was delayed secondary to patient compliance. CT of the chest and shoulder revealed large recurrent solid and cystic mass in the left shoulder region and left upper anterolateral chest wall. The patient died 5 mo postoperatively from hemorrhagic conversion of metastatic lesions in the brain.

## DISCUSSION

The use of fillet flaps from non-salvageable or amputated extremities has been successfully used for reconstruction as part of the “spare parts” concept<sup>[1]</sup>. Pedicled musculocutaneous flaps are commonly used for reconstruction; however, the use of a pedicled fillet flap of the upper arm has not been well reported in the literature<sup>[2]</sup>.

Forequarter amputations may be necessary for locally aggressive bone and soft tissue tumors invading the axilla, shoulder or scapula<sup>[4]</sup>. However, multiple variables, such as size and location of the defect, exposure of nerves, tendons, vessels and bones, as well as need for post-operative radiation, must be taken into consideration when deciding on type of reconstruction. Skin grafts do not



**Figure 4** Fillet flap with drains, prior to closure.

provide adequate coverage for large, deep wounds, and are not durable in patients needing post-operative radiation. Therefore, flap coverage with either a pedicled or free flaps are the appropriate choice to provide adequate, immediate coverage post-resection in order to initiate adjuvant radiation therapy<sup>[5]</sup>. In patients undergoing an amputation, the use of fillet flaps as part of the “spare parts” concept provides these similar advantages with the added benefit of reduced donor-site morbidity<sup>[1,5]</sup>.

Previous studies describe the use of free forearm fillet flaps in patients who underwent an upper extremity amputation for cancer, however the use of an upper arm pedicled fillet flap has not been well reported<sup>[2,6]</sup>. The use of an upper arm flap may have been contraindicated due to local invasion of the tumor<sup>[2]</sup>. However, in our patient, the lack of tumor invasion into the upper arm or into the vascular inflow in the axilla allowed the opportunity to perform a pedicled fillet flap. Not only did the upper extremity flap allow for adequate, tension free coverage, it reduced the risks associated with a free flap. Chao and colleagues demonstrated that patients who received adjuvant radiotherapy after free fillet flaps were significantly more likely to have graft loss as compared to those who received neo-adjuvant radiation<sup>[7]</sup>. Since our patient was not appropriate for neo-adjuvant radiation, performing an upper-extremity pedicled fillet flap allowed us to reduce the risk of post-operative wound complications associated with adjuvant radiation therapy. Pedicled latissimus dorsi flaps for reconstruction after forequarter amputations have also been described<sup>[8]</sup>, but due to tumor invasion in our patient as well as added donor site morbidity, an upper arm fillet flap was decided to be the most appropriate choice for reconstruction.

MPNST is a rare primary chest wall tumor with an incidence of 0.001% in the general population. It commonly presents as an enlarging painful mass and arises from Schwann cells or neural crest cells in a peripheral

nerve or its sheath. Patients with NF-1 are at increased risk of developing MPNST through malignant degeneration of plexiform neurofibromas<sup>[9]</sup>. MPNSTs are considered highly malignant, associated with a poor prognosis, have a high risk of local recurrence, and are associated with distant metastasis, most commonly to the lungs<sup>[9,10]</sup>. MRI remains the gold standard for diagnosis after which the treatment of choice is surgical resection<sup>[9]</sup>. Definite wide excision, negative surgical margins, with neo-adjuvant or adjuvant radiotherapy is currently recommended for treatment of resectable tumors in patients with MPNSTs<sup>[3,9]</sup>. Poor prognostic indicators include tumor size greater than 5 cm, local recurrence, high tumor grade, positive surgical margins, association with neurofibromatosis type I (NF-1), and truncal location<sup>[9]</sup>. Patients with NF-1 should be educated about the increased risk for developing MPNST and be advised to contact their physician should rapidly enlarging masses, pain, or neurologic changes occur. Given the poor prognosis for MPNST, early initiation of treatment provides the best chance for survival<sup>[9]</sup>.

Overall, this case represents a rare description of the use of a pedicled musculocutaneous flap from the upper arm for reconstruction after resection of MPNST. Given that MPNST is an aggressive tumor that may present with large defects post resection, the use of a pedicled fillet flap of the upper arm is a viable option that can be successfully used for coverage of soft tissue defects of the shoulder and chest wall<sup>[9]</sup>. The advantage of immediate wound closure, avoidance of donor-site morbidity, and reduced operative time over a free flap makes this procedure a reliable method for complex reconstructions in an oncologic setting<sup>[1]</sup>.

## COMMENTS

### Case characteristics

A 42-year-old female with a history of neurofibromatosis presented to plastic surgery clinic with complaints of a left shoulder mass growing for the past two years that caused significant pain with movement.

### Clinical diagnosis

Patient has a tense, large, protruding mass over her left scapula that is excruciatingly tender with intact flexor and extensor function of the hand and elbow and gross sensation but limited shoulder function secondary to significant pain.

### Differential diagnosis

Malignant peripheral nerve sheath tumor, cellular schwannoma, fibrosarcoma, synovial sarcoma.

### Laboratory diagnosis

White blood cell: 9.80 k/ $\mu$ L; hemoglobin: 9.9 g/dL.

### Imaging diagnosis

Magnetic resonance imaging revealed 18.4 cm  $\times$  15.9 cm  $\times$  20 cm mass concerning for possible malignant degeneration of a neurofibroma based on size and clinical history and chest computerized tomography revealed a left large axillary mass with scapular erosion.

### Pathological diagnosis

Post-operative pathology report demonstrated a T2bN0 grade 2 or stage IIb malignant peripheral nerve sheath tumor and the tumor was 24 cm  $\times$  24 cm  $\times$  19 cm in size with focally positive margins.

### Treatment

Surgical resection of the mass using a pedicled upper arm fillet flap was performed and post operatively, the patient was initiated on a chemotherapy regimen consisting of doxorubicin and ifosfamide and scheduled for radiation

therapy.

### Related reports

Pedicled musculocutaneous flaps are commonly used for reconstruction; however, the use of a pedicled fillet flap of the upper arm has not been well reported in the literature.

### Term explanation

A pedicled flap contains tissue that remains attached to the original donor site with intact vasculature and is transposed to a new location which is in contrast to a free flap where tissue is detached from its original donor site and transferred to another location.

### Experiences and lessons

The advantage of immediate wound closure, avoidance of donor-site morbidity, and reduced operative time over a free flap makes the use of a pedicled fillet flap of the upper arm a viable option that can be successfully used for coverage of soft tissue defects of the shoulder and chest wall for complex reconstructions in an oncologic setting.

### Peer review

This case report describes a novel reconstructive procedure that can be used to cover the amputated upper arm with a pedicled fillet flap.

## REFERENCES

- 1 Küntschner MV, Erdmann D, Homann HH, Steinau HU, Levin SL, Germann G. The concept of fillet flaps: classification, indications, and analysis of their clinical value. *Plast Reconstr Surg* 2001; **108**: 885-896 [PMID: 11547143 DOI: 10.1097/00006534-200109150-00011]
- 2 Lee G, Mohan S. Complex reconstruction of a massive shoulder and chest wall defect: de-bone appétit flap. *J Surg Case Rep* 2010; **2010**: 1 [PMID: 24946171]
- 3 Soft Tissue Sarcoma. NCCN Clinical Practice Guidelines in Oncology (NCCN Guidelines®). Available from: URL: [http://www.nccn.org/professionals/physician\\_gls/pdf/sarcoma.pdf](http://www.nccn.org/professionals/physician_gls/pdf/sarcoma.pdf)
- 4 Kuhn JA, Wagman LD, Lorant JA, Grannis FW, Dunst M, Dougherty WR, Jacobs DI. Radical forequarter amputation with hemithoracectomy and free extended forearm flap: technical and physiologic considerations. *Ann Surg Oncol* 1994; **1**: 353-359 [PMID: 7850535 DOI: 10.1007/bf02303573]
- 5 Moreira-Gonzalez A, Djohan R, Lohman R. Considerations surrounding reconstruction after resection of musculoskeletal sarcomas. *Cleve Clin J Med* 2010; **77** Suppl 1: S18-S22 [PMID: 20179182 DOI: 10.3949/ccjm.77.s1.04]
- 6 Ver Halen JP, Yu P, Skoracki RJ, Chang DW. Reconstruction of massive oncologic defects using free fillet flaps. *Plast Reconstr Surg* 2010; **125**: 913-922 [PMID: 20195119 DOI: 10.1097/prs.0b013e3181cb6548]
- 7 Chao AH, Chang DW, Shuaib SW, Hanasono MM. The effect of neoadjuvant versus adjuvant irradiation on microvascular free flap reconstruction in sarcoma patients. *Plast Reconstr Surg* 2012; **129**: 675-682 [PMID: 22373973 DOI: 10.1097/prs.0b013e3182412a39]
- 8 Tukiainen E. Chest wall reconstruction after oncological resections. *Scand J Surg* 2013; **102**: 9-13 [PMID: 23628630 DOI: 10.1177/145749691310200103]
- 9 Gupta G, Mammis A, Maniker A. Malignant peripheral nerve sheath tumors. *Neurosurg Clin N Am* 2008; **19**: 533-543, v [PMID: 19010279 DOI: 10.1016/j.nec.2008.07.004]
- 10 Hsu CC, Huang TW, Hsu JY, Shin N, Chang H. Malignant peripheral nerve sheath tumor of the chest wall associated with neurofibromatosis: a case report. *J Thorac Dis* 2013; **5**: E78-E82 [PMID: 23825788]

P- Reviewer: Chen GS, Rapidis AD, Vernimmen FJ  
S- Editor: Tian YL L- Editor: A E- Editor: Wu HL





## Cecal bascule herniation into the lesser sac

Tafadzwa Makarawo, Francisco Igor Macedo, Michael J Jacobs

Tafadzwa Makarawo, Francisco Igor Macedo, Michael J Jacobs, Department of Surgery, Providence Hospital and Medical Centers, Southfield, MI 48075, United States

Author contributions: Jacobs MJ designed and reviewed the study; Makarawo T and Macedo FI collected the data, and wrote the paper.

Correspondence to: Francisco Igor Macedo, MD, Department of Surgery, Providence Hospital and Medical Centers, 16001 W Nine Mile Road, Southfield, MI 48075, United States. [igormacedo1@hotmail.com](mailto:igormacedo1@hotmail.com)

Telephone: +1-248-8497638 Fax: +1-248-8495380

Received: July 10, 2014 Revised: August 17, 2014

Accepted: September 29, 2014

Published online: December 16, 2014

© 2014 Baishideng Publishing Group Inc. All rights reserved.

**Key words:** Cecal; Bascule; Hernia; Internal; Foramen; Winslow

**Core tip:** Cecal bascule is a rare and overlooked cause of large bowel obstruction in which a mobile cecum folds anteriorly and superiorly leading to obstruction of ascending colon. Although cecal bascule has been described in association with mechanical bowel obstruction in the literature, its association with this type of internal hernia has never been described before. The management of internal herniation of a cecal bascule is always surgical even in the absence of peritonitis, either cecopexy or right hemicolectomy depending on the viability of the bowel segment involved.

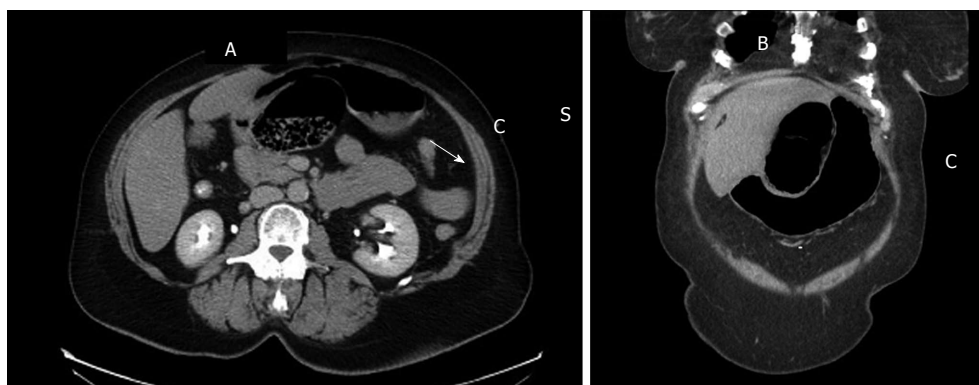
### Abstract

Cecal bascule is a rare cause of bowel obstruction in which a mobile cecum folds anteriorly and superiorly over the ascending colon. Herein, we present the first case of internal herniation of a cecal bascule into the lesser sac through the foramen of Winslow, aiming at discussing radiological findings, differential diagnosis, and surgical management of this uncommon condition. A 75-year-old female presented to the emergency room with an 18-h history of sudden onset sharp, progressively worsening abdominal pain associated with vomiting. Physical exam revealed abdominal distention and epigastric tenderness while initial laboratory tests were unremarkable. Computed tomography of her abdomen and pelvis showed a loop of distended colon within lesser sac without signs of bowel ischemia or perforation. On exploratory laparotomy, a cecal bascule was found herniating into lesser sac *via* foramen of Winslow. Upon reduction, the cecum appeared viable therefore a cecopexy was performed without bowel resection. Unlike cecal volvulus, cecal bascule consists of no axial rotation of the bowel with no mesenteric vascular compromise and therefore ischemia would only occur from intraluminal tension or extraluminal compression from the borders of foramen of Winslow. The management of internal herniation of a cecal bascule is always surgical including anatomic resection or cecopexy.

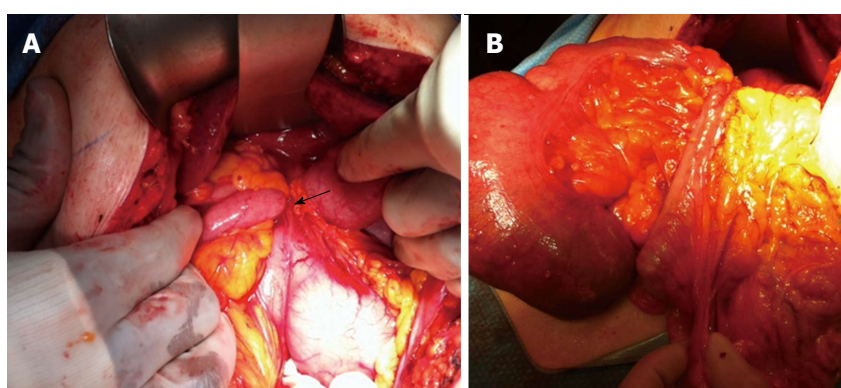
Makarawo T, Macedo FI, Jacobs MJ. Cecal bascule herniation into the lesser sac. *World J Clin Cases* 2014; 2(12): 903-906 Available from: URL: <http://www.wjgnet.com/2307-8960/full/v2/i12/903.htm> DOI: <http://dx.doi.org/10.12998/wjcc.v2.i12.903>

### INTRODUCTION

Cecal bascule is an extremely rare condition in which the bowel folds anteriorly and superiorly over the ascending colon<sup>[1]</sup>. Its similarity with cecal volvulus has led to misdiagnosis, although the absence of axial rotation of the bowel in cecal bascule is an importance difference that influences presentation. In cecal bascule, patients usually present with less critical illness than those with cecal volvulus as there is no torsion of the mesenteric vasculature<sup>[2]</sup>. Symptoms are therefore mostly related to bowel obstruction, particularly in the presence of a functional ileocecal valve causing a closed-loop obstruction. Diagnosis is often challenging because of equivocal image findings in addition to its rare occurrence. We, herein, present a rare case of cecal bascule herniating into the lesser sac in a patient with obstructive signs, and discuss the diagnosis, and operative management of this rare



**Figure 1** Computed tomography of abdomen and pelvis showing a loop of distended colon within lesser sac without bowel ischemia or perforation. Radiological features include: (1) the cecum herniated (C) into the lesser sac behind the stomach (S) (A and B); (2) the presence of mesentery (white arrow) between the portal vein and inferior vena cava (A); and (3) the presence of gas or fluid in the lesser sac with its 'beak' directed toward the foramen of Winslow (B).



**Figure 2** Intraoperatively, a cecal bascule was found herniating into lesser sac via foramen of Winslow (A). Upon reduction, the cecum appeared viable (B).

condition.

## CASE REPORT

A 75-year-old female presented to the emergency room with an 18-h history of sudden onset, progressively worsening abdominal pain associated with vomiting. The patient had a previous history of hiatal hernia with gastroesophageal reflux symptoms and previous hysterectomy and tonsillectomy. The patient presented with abdominal distention and epigastric tenderness without diffuse peritoneal signs. Laboratory tests were unremarkable, with no leukocytosis but computed tomography (CT) of the abdomen and pelvis showed a loop of distended colon within lesser sac with no signs of bowel ischemia or perforation (Figure 1).

The patient underwent exploratory laparotomy during which the cecum was noted to be folded anteriorly over the ascending colon and herniating into lesser sac *via* the foramen of Winslow (Figure 2A) resulting in colonic obstruction. To reduce the internal hernia, the lesser omentum was incised revealing the absence of underlying adhesive bands tethering the cecum in place, hence allowing the gentle withdrawal of the bowel back through foramen of Winslow. Upon reduction, the cecum and terminal ileum appeared viable (Figure 2B). Therefore,

lysis of a single adhesive band to the terminal ileum was performed prior to cecopexy with fixation of the cecum inferolaterally to the right lateral abdominal wall, negating the need for bowel resection.

The patient made an uneventful post-operative recovery, tolerating full oral intake within 48 h of the surgery and being discharged on post-operative day four. The patient has had no further episodes of bowel obstruction, remaining symptom-free after almost a year of follow-up.

## DISCUSSION

Cecal bascule is a rare and overlooked cause of large bowel obstruction in which a mobile cecum folds anteriorly and superiorly leading to obstruction of ascending colon. It has been estimated that approximately 10% to 15% of labeled "cecal volvulus" episodes were actually cecal bascules<sup>[3]</sup>. The formation of a cecal bascule is secondary to hypermobility of the cecum and intestinal distention<sup>[4,5]</sup>. This excessive mobility can occur as a result of defective retroperitoneal fixation of the cecum due to incomplete intestinal rotation during embryogenesis, or the persistence of ascending mesocolon. It may also occur postoperatively after dissection of peritoneal attachments<sup>[6]</sup>. The formation of adhesions may also play a role by creating a point of fixation, allowing the formation of

the bascule.

The clinical presentation of cecal bascule is usually similar to postoperative ileus including nausea, vomiting and abdominal distention and pain. However, unlike in cecal volvulus, the patients are not as critically ill because there is no axial torsion of the mesenteric vasculature, which leads to bowel ischemia. However, it must be noted that delay in diagnosis with unrelieved bowel obstruction causing increased intraluminal tension or extraluminal compression from an internal hernia would ultimately result in bowel ischemia and eventual perforation. Diagnosis is often challenging due to its rare nature. Plain abdominal X-rays may show a dilated cecum in the right upper quadrant with or without small bowel obstruction. CT scan of the abdomen, which is more helpful, may demonstrate a dilated cecum anterior to the ascending colon and an ileocecal valve located in the right upper quadrant<sup>[4]</sup>. In our case, the CT scan did show an internal hernia containing a loop of distended colon within lesser sac, although it was unclear whether it was transverse colon or ascending colon that had herniated through the foramen of Winslow.

Herniation of abdominal viscera through the foramen of Winslow into the lesser sac occurs rarely, accounting for 8% of all internal hernias<sup>[7]</sup>. Hernias through this foramen have been described as containing small bowel, right colon, and rarely, gallbladder or transverse colon. Potential predisposing factors include hypermobile mesentery, enlargement of the foramen of Winslow, or absence of fusion of the ascending colon to the posterior abdominal wall<sup>[7,8]</sup>. Although cecal bascule has been described in association with mechanical bowel obstruction in literature, its association with this type of internal hernia has never been described before<sup>[8-14]</sup>. Indeed, it is possible that the term 'bascule' which is derived from a French word meaning "a bridge with a movable section hinged about a horizontal axis", is not widely applied, and therefore underdiagnosed as a cause for cecal herniation.

The management of bowel obstruction secondary to cecal bascule should be surgical. In this case, simple reduction and cecopexy was technically feasible, safe, and had a satisfactory outcome. Although right hemicolectomy has also been advocated even with the cecum being viable to prevent recurrence<sup>[9]</sup>, there are no reported cases of recurrence of cecal bascule following cecopexy only<sup>[10-12]</sup>. Therefore, we would recommend that segmental resection be reserved for cases with associated ischemia or perforation. Closure of the foramen has also not been advocated due to increased risk of portal vein thrombosis or hepatic artery and/or bile ducts injury<sup>[13,14]</sup>.

In conclusion, we presented a rare case of an internal hernia containing a cecal bascule into the lesser sac through the foramen of Winslow. Despite its rare occurrence, cecal bascule should be in the differential diagnosis armamentarium of bowel obstruction, especially in patients with a markedly distended cecum in the absence of peritoneal signs. The management of internal herniation of a cecal bascule is always surgical even in the absence

of peritonitis, and includes either cecopexy if the cecum is viable or right hemicolectomy if it appears ischemic or non-viable.

## COMMENTS

### Case characteristics

A 75-year-old female presented to the emergency room with an 18-h history of sudden onset, progressively worsening abdominal pain associated with vomiting.

### Clinical diagnosis

On physical examination, she had abdominal distention and epigastric tenderness without diffuse peritoneal signs.

### Differential diagnosis

Mechanical obstruction due to adhesions, ileus, cecal volvulus, cecal bascule.

### Imaging diagnosis

Computed tomography of abdomen and pelvis showing a loop of distended colon within lesser sac without bowel ischemia or perforation.

### Treatment

The patient underwent exploratory laparotomy, reduction of cecal herniation into the lesser omentum and cecopexy.

### Term explanation

Cecal bascule occurs when a mobile cecum folds anteriorly and superiorly leading to obstruction of ascending colon. The term "bascule" is derived from a French word meaning "a bridge with a movable section hinged about a horizontal axis", is not widely applied, and therefore may be underdiagnosed.

### Experience and lessons

This is the first case in the literature describing a hernia into the lesser sac from a cecal bascule. The management of bowel obstruction secondary to cecal bascule should be surgical.

### Peer review

This manuscript highlights the clinical presentation of a rare cause of large bowel obstruction and provides insights into the management of cecal bascule.

## REFERENCES

- 1 Bobroff LM, Messinger NH, Subbarao K, Beneventano TC. The cecal bascule. *Am J Roentgenol Radium Ther Nucl Med* 1972; **115**: 249-252 [PMID: 5037783 DOI: 10.2214/ajr.115.2.249]
- 2 Consorti ET, Liu TH. Diagnosis and treatment of caecal volvulus. *Postgrad Med J* 2005; **81**: 772-776 [PMID: 16344301 DOI: 10.1136/pgmj.2005.035311]
- 3 Madiba TE, Thomson SR. The management of cecal volvulus. *Dis Colon Rectum* 2002; **45**: 264-267 [PMID: 11852342 DOI: 10.1007/s10350-004-6158-4]
- 4 Lazar DA, Cohen SA, Evora DK, Losasso BE, Bickler SW. Cecal bascule in a child: an unusual cause of postoperative bowel obstruction. *J Pediatr Surg* 2012; **47**: 609-611 [PMID: 22424364 DOI: 10.1016/j.jpedsurg.2011.12.026]
- 5 Rozycki GS. Special feature: Image of the month. Cecal bascule. *Arch Surg* 2001; **136**: 835-836 [PMID: 11448401]
- 6 Kim J, Nguyen S, Leung P, Divino C. Cecal bascule after laparoscopic ventral hernia repair. *JSLs* 2013; **17**: 484-486 [PMID: 24018093 DOI: 10.4293/108680813X13693422521917]
- 7 Da Costa G, Ng B, Kociumbas I, Wong S. Herniation of caecum through the foramen of Winslow. *Australas Radiol* 2007; **51** Spec No.: B152-B154 [PMID: 17875141 DOI: 10.1111/j.1440-1673.2007.01772.x]
- 8 Erskine JM. Hernia through the foramen of Winslow. *Surg Gynecol Obstet* 1967; **125**: 1093-1109 [PMID: 4864553]
- 9 Samson TD, Tercero FM, Sato K, Awad ZT, Filipi CJ. Cecal herniation through the foramen of Winslow after laparoscopic Nissen fundoplication. *Surg Endosc* 2001; **15**: 1490 [PMID: 11965478 DOI: 10.1007/s004640041027]
- 10 Cohen DJ, Schoolnik ML. Herniation through the foramen of Winslow. *Dis Colon Rectum* 1982; **25**: 820-822 [PMID: 7172954 DOI: 10.1007/BF02553325]

- 11 **Evrard V**, Vielle G, Buyck A, Merchez M. Herniation through the foramen of Winslow. Report of two cases. *Dis Colon Rectum* 1996; **39**: 1055-1057 [PMID: 8797659 DOI: 10.1007/BF02054699]
- 12 **Puig CA**, Lillegard JB, Fisher JE, Schiller HJ. Hernia of cecum and ascending colon through the foramen of Winslow. *Int J Surg Case Rep* 2013; **4**: 879-881 [PMID: 23973900 DOI: 10.1016/j.ijscr.2013.07.014]
- 13 **Tjandra JJ**, Collier N. Obstructive jaundice due to foramen of Winslow hernia: a case report. *Aust N Z J Surg* 1991; **61**: 467-469 [PMID: 2059182 DOI: 10.1111/j.1445-2197.1991.tb00266.x]
- 14 **Dorian AL**, STEIN GN. Hernia through foramen of Winslow: report of a case with preoperative roentgen diagnosis and successful surgical management. *Surgery* 1954; **35**: 795-801 [PMID: 13156898]

**P- Reviewer:** Bjornsson B, Dhiman RK, Fabozzi M  
**S- Editor:** Ma YJ   **L- Editor:** A   **E- Editor:** Wu HL





## Tentorial dural arteriovenous fistula presenting as myelopathy: Case series and review of literature

Robert Gross, Rushna Ali, Max Kole, Curtis Dorbeistein, Mahesh V Jayaraman, Muhib Khan

Robert Gross, Muhib Khan, Department of Neurology, Warren Alpert Medical School of Brown University, Providence, RI 02903, United States

Rushna Ali, Department of Neurosurgery, Henry Ford Hospital, Detroit, MI 48202, United States

Max Kole, Departments of Neurosurgery and Radiology, Henry Ford Hospital, Detroit, MI 48202, United States

Curtis Dorbeistein, Department of Neurosurgery, Warren Alpert Medical School of Brown University, Providence, RI 02903, United States

Mahesh V Jayaraman, Departments of Diagnostic Imaging and Neurosurgery, Warren Alpert Medical School of Brown University, Providence, RI 02903, United States

Author contributions: Kole M, Dorbeistein C, Jayaraman MV, Gross R and Khan M developed the idea and contributed the cases for the manuscript; Ali R and Khan M performed the literature search and wrote the manuscript.

Correspondence to: Muhib Khan, MD, Department of Neurology, Warren Alpert Medical School of Brown University, Providence, RI 02903,

United States. [mkhan2@lifespan.org](mailto:mkhan2@lifespan.org)

Telephone: +1-401-4445055 Fax: +1-401-4448781

Received: June 20, 2014 Revised: August 10, 2014

Accepted: September 23, 2014

Published online: December 16, 2014

### Abstract

Dural arteriovenous fistula (DAVF) is a rare type of cerebral arteriovenous malformation. Common presenting symptoms are related to hemorrhage. However, rarely these patients may present with myelopathy. We present two cases of DAVF presenting as rapidly progressive myelopathy. Two treatment options are available: microsurgical interruption of the fistula and endovascular embolization. These treatment options of DAVFs have improved significantly in the last decade. The optimal treatment of DAVFs remains controversial, and there is an ongoing debate as to whether primary endovascular or primary microsurgical treatment is the optimal management for these lesions. However, despite treatment a high percentage of patients are still left with severe

disability. The potential for functional ambulation in patients with DAVF is related to the time of intervention. This emphasizes the importance of early diagnosis and early intervention in DAVF. The eventual outcome may depend on several factors, such as the duration of symptoms, the degree of disability before treatment, and the success of the initial procedure to close the fistula. The usage of magnetic resonance imaging and selective angiography has significantly improved the ability to characterize DAVFs, however, these lesions remain inefficiently diagnosed. If intervention is delayed even prolonged time in rehabilitation does not change the grave prognosis. This review outlines the presentation, classification and management of DAVF as well as discussing patient outcomes.

© 2014 Baishideng Publishing Group Inc. All rights reserved.

**Key words:** Dural arteriovenous fistula; Myelopathy; Vascular malformation; Cognard classification; Microsurgery; Onyx embolization

**Core tip:** Tentorial dural arteriovenous fistulas (DAVF) are an uncommon entity, and myelopathy as a result of these AV fistulas is even more uncommon. We present two cases of myelopathy as a result of dural AV fistulas. This review highlights the classification of dural AV fistulas, the various diagnostic modalities available for diagnosis and management strategies employed for the treatment of DAVF. We also stress the importance of a timely diagnosis and its impact on patient outcomes and recovery.

Gross R, Ali R, Kole M, Dorbeistein C, Jayaraman MV, Khan M. Tentorial dural arteriovenous fistula presenting as myelopathy: Case series and review of literature. *World J Clin Cases* 2014; 2(12): 907-911 Available from: URL: <http://www.wjgnet.com/2307-8960/full/v2/i12/907.htm> DOI: <http://dx.doi.org/10.12998/wjcc.v2.i12.907>

## INTRODUCTION

Dural arteriovenous fistulas (DAVF) constitute 10% to 15% of all intracranial vascular malformations<sup>[1,2]</sup>. Tentorial DAVFs account for 8.4% of intracranial DAVFs<sup>[3]</sup>. Cranial dural arteriovenous fistulas may give rise to myelopathy due to spinal perimedullary venous drainage causing intramedullary venous hypertension<sup>[4]</sup>. However, this is very uncommon, with only 38 cases reported in the literature<sup>[5]</sup>. We describe two cases of tentorial dural AV fistulas causing significant myelopathy.

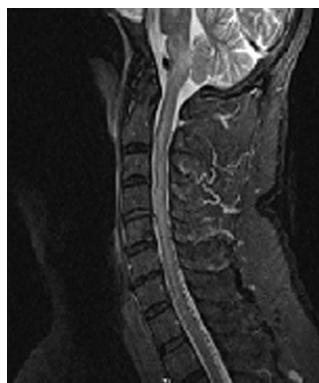## CASE REPORT

### Case 1

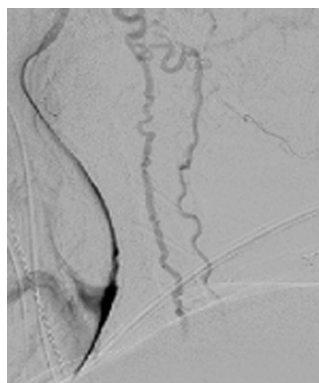
A 69-year-old male presented to our institution with 3 d of progressively worsening bilateral lower extremity weakness and urinary retention. These symptoms had been preceded by bilateral hand and forearm pain that lasted for 2 d. The patient was presumptively diagnosed with Guillian-Barre Syndrome and treatment started. Magnetic resonance imaging of the brain and of the cervical, thoracic, and lumbar spine showed increased T2/STIR signal intensity in the pons, medulla, and upper cervical spine and multiple small flow voids in the dorsal cervicothoracic spine suggestive of dural arteriovenous malformation (Figure 1). Neurological exam revealed significant weakness in bilateral lower extremities, most pronounced in bilateral hamstrings and in the left tibialis anterior. The upper extremity strength testing was normal. There were no sensory abnormalities. Deep tendon reflexes were increased in the lower extremities. This presentation was thought to be consistent with myelopathy from venous congestion related to a DAVF. He underwent angiography, which confirmed a Cognard V tentorial dAVF fed by the left middle meningeal, tentorial branch of the left ICA, and dural branches of the occipital and posterior auricular arteries, with drainage into cervical spinal veins (Figure 2). The AVF was successfully embolized with Onyx (Covidien Inc., Mansfield, MA) without any residual filling seen following embolization (Figure 3). The patient was discharged to rehab on hospital day 5. He was seen in follow-up 10 wk later, at which point he was noted to be walking independently, without urinary symptoms and only mild proximal lower extremity weakness bilaterally with manual muscle testing grade of 4 out of 5 in bilateral iliopsoas and hamstrings. The Aminoff-logue scale changed from 6 preintervention, to 1 after embolization of dural AV fistula.

### Case 2

A 34-year old woman presented with progressively worsening bilateral upper and lower extremity weakness over 1 wk. Past medical history was significant for temporal pilocytic astrocytoma resection with subsequent whole brain radiation at age 12. Examination revealed quadriplegia and hyperreflexia in all 4 extremities. Initial presumptive diagnosis made was transverse myelitis with high cervical cord involvement, and the patient was started on steroid



**Figure 1** Magnetic resonance imaging of the cervical spine showing increased T2/STIR signal intensity in the pons, medulla, and upper cervical spine and multiple small flow voids in the dorsal cervicothoracic spine suggestive of dural arteriovenous malformation.



**Figure 2** Angiogram showing a Cognard V tentorial dural arteriovenous fistula fed by the left middle meningeal, tentorial branch of the left ICA, and dural branches of the occipital and posterior auricular arteries, with drainage into cervical spinal veins.

therapy. MRI Brain revealed dilated tortuous vessels posterior to the spinal cord between the foramen magnum and the upper thoracic spine. It also showed asymmetric expansion and T2/FLAIR signal abnormality of the left side of the brainstem at the cervicomedullary junction, as well as diffuse expansion and mild diffuse T2 signal abnormality within the cervical and upper thoracic spinal cord (Figure 4).

Cerebral angiogram showed a left transverse sigmoid junction dAVF fed by the left occipital artery (Figure 5). This fistula drained into the superior petrosal sinus, going to the tributaries of the petrosal vein and to the anterior medullary vein. From the anterior medullary vein it then drained down to the anterior spinal and cervicomedullary veins. This venous drainage was thought to be responsible for venous hypertension and the subsequent quadriplegia that the patient was experiencing. This DAVF was successfully embolized with Onyx (Covidien Inc., Mansfield, MA). Three month follow-up angiogram revealed no opacification of the fistula with left occipital artery injection (Figure 6). Clinically the patient had regained complete strength in all 4 extremities and was back at work performing manual labor. The Aminoff-logue scale changed from 7 preintervention, to 0 after embolization

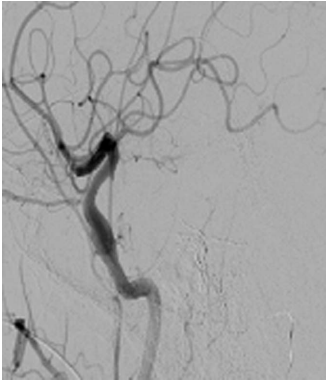


Figure 3 Arteriovenous fistula shown in Figure 2 now successfully embolized with Onyx without any residual filling seen following embolization.

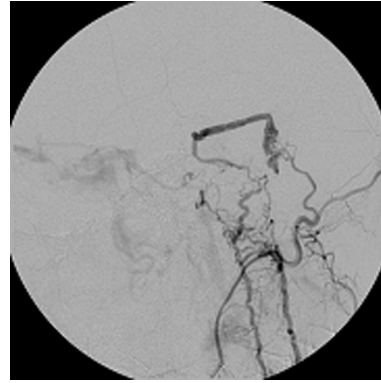


Figure 5 Cerebral angiogram showed a left transverse sigmoid junction dural arteriovenous fistula fed by the left occipital artery.

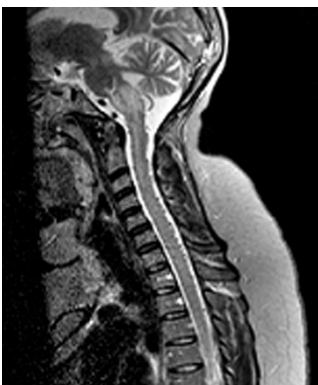

Figure 4 Magnetic resonance imaging brain and cervical spine showing asymmetric expansion and T2/FLAIR signal abnormality of the left side of the brainstem at the cervicomedullary junction, as well as diffuse expansion and mild diffuse T2 signal abnormality within the cervical and upper thoracic spinal cord.

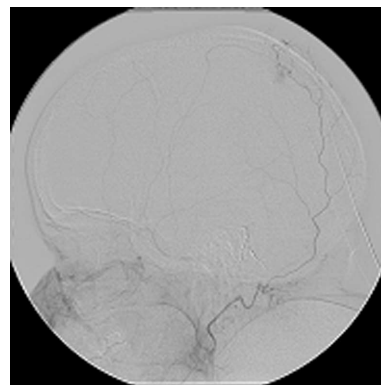


Figure 6 Post onyx embolization angiogram shows no persistent opacification of the fistula with left occipital artery injection.

of dural AV fistula.

## DISCUSSION

dAVFs are rare vascular lesions that can come to clinical attention as either intracranial hemorrhage (intraparenchymal, subarachnoid, subdural) or as a consequence of venous hypertension. In the latter situation, presenting symptoms are varied and can include pulsatile tinnitus, dementia, seizures, encephalopathy, parkinsonism, intracranial hypertension, and myelopathy<sup>[4]</sup>. Here we have presented two cases of rapidly progressive myelopathy related to dAVFs. All fistulas have one or more feeding arteries, derived from the dural arteries or meningeal branches of cerebral arteries, with venous drainage into a venous sinus, leptomeningeal, or spinal veins.

The classification of intracranial DAVFs has evolved over time, based on venous drainage, natural history, and arterial feeders. Cognard classification divides DAVFs in 5 types (I-V). This classification is based on the direction of dural sinus drainage (antegrade or retrograde), the presence or absence of cortical venous drainage, and venous outflow architecture (nonectatic cortical vein, ectatic cortical vein, or spinal perimedullary vein)<sup>[6,7]</sup>.

The higher the type, the more likely the DAVF is to be symptomatic as a result of increased venous congestion. Both our cases were classified as Cognard Type V lesions. Type V DAVF usually have aggressive symptoms with progressive myelopathy due to spinal cord venous hypertension. The perimedullary venous drainage can extend down to the thoracic or lumbar levels.

The etiology of DAVFs is not entirely clear. It is generally accepted that DAVFs in adults are acquired. Trauma, prior surgery, sinus thrombosis, and stenosis have been proposed as possible etiologies<sup>[3,4,8,9]</sup>. An atypical presentation can lead to delays in accurate diagnosis, as clinicians may first think of other causes of rapidly progressive weakness, such as Guillain Barre syndrome and transverse myelitis. Both the cases we have presented were suspected to be suffering from similar neurological ailments. Only after failure to improve with standard therapy were further investigations conducted and the dAVF discovered on MRI imaging. This goes to underscore the importance of an accurate and timely diagnosis and the value of MRI in the acute setting since delayed diagnosis leads to grave neurologic and functional prognosis<sup>[10]</sup>.

MRI findings can be subtle and difficult to interpret. These include prominent perimedullary flow voids as well as T2 signal intensity in the brainstem and spinal cord



indicating the presence of venous congestion and edema. Diffuse signal change in the brainstem and spinal cord, with dilated perimedullary veins combined with a presentation of progressive myelopathy should always raise the suspicion of a DAVF<sup>[8]</sup>. Cerebral angiography is the gold standard for diagnosis. Arterial feeders to DAVFs can originate from branches of the external carotid artery such as the occipital artery, posterior meningeal artery, middle meningeal artery, as well as meningeal branches of pial arteries<sup>[9,11,12]</sup>. When the arterial phase of spinal angiography is negative, an extended observation of the venous phase should be performed looking for venous stagnation which is a sign of venous hypertension.

The optimal management strategy for DAVF is still controversial. It is recommended that DAVF be managed at a center with multidisciplinary experience in endovascular therapy, microsurgery and radiosurgery. Although both of our patients were successfully treated endovascularly, there is still a major role of conventional microsurgery in selected patients. Surgical therapy involves ligation and disruption of the arterio-venous fistulous connection, with success rates of 87.5% to 100% reported in literature<sup>[1-3,12]</sup>. Embolization with Onyx can be used as a first line therapy in many patients, with reportedly high rates of durable cure and low rates of complications<sup>[13,14]</sup>. There is some evidence to suggest that surgical ligation may offer permanent cure without any recurrence compared to endovascular therapy where recurrence may occur<sup>[15]</sup>.

Endovascular and surgical therapies are associated with significantly improved symptoms once the definitive diagnosis of SDAVF is made, with studies showing significant improvement in patient outcomes measured on the Aminoff-Logue scale. The Aminoff-Logue scale is a disability scale comprising of three subcategories which score the patient on their gait, micturition and bowel control. Literature supports post-treatment improvement particularly in the subcategories of micturition and gait<sup>[16]</sup>.

In conclusion, DAVFs are rare but aggressive and potentially fatal vascular malformations. Atypical presentation can mimic other more common neurologic disorders delaying diagnosis. Early diagnosis is important in these cases as a prompt intervention can result in great functional outcomes as evidenced by our cases.

## COMMENTS

### Case characteristics

The authors present two cases of dural arteriovenous fistula presenting as rapidly progressive myelopathy.

### Clinical diagnosis

In one instance the patient demonstrated bilateral lower extremity weakness, whereas the second patient had quadraparesis with significant weakness of all 4 extremities.

### Differential diagnosis

Differential diagnosis includes Guillian Barre syndrome, transverse myelitis and various other demyelinating illnesses.

### Imaging diagnosis

MRI showed T2 signal change in the spinal cord as well as prominent dorsal flow voids. Cerebral angiogram showed the presence of a dural arteriovenous fistula in both cases.

## Treatment

Both patients were treated with Onyx embolization that resulted in complete resolution of the dural AV fistula.

## Related reports

This is an unusual presentation of tentorial dural AV fistulas which normally present as hemorrhage and not many cases have been reported in the literature.

## Term explanation

Dural arteriovenous fistulas are abnormal connection between arteries within the dura mater and veins that normally drain brain tissue.

## Experience and lessons

Dural AV fistulas are rare vascular lesions and can be classified using the Cognard classification. This case report highlights two cases of tentorial dural AV fistulas presenting as progressive myelopathy and discusses treatment options available.

## Peer review

Very interesting case reports. It is worth to publish.

## REFERENCES

- 1 **Kim MS**, Han DH, Kwon OK, Oh CW, Han MH. Clinical characteristics of dural arteriovenous fistula. *J Clin Neurosci* 2002; **9**: 147-155 [PMID: 11922702 DOI: 10.1054/jocn.2001.1029]
- 2 **Zhou LE**, Chen L, Song DL, Gu YX, Leng B. Tentorial dural arteriovenous fistulas. *Surg Neurol* 2007; **67**: 472-481; discussion 481-482 [PMID: 17445607 DOI: 10.1016/j.surneu.2006.08.078]
- 3 **Awad EW**, Anctil M. Positive coupling of beta-like adrenergic receptors with adenylate cyclase in the cnidarian *Renilla koellikeri*. *J Exp Biol* 1993; **182**: 131-146 [PMID: 7901317]
- 4 **Khan S**, Polston DW, Shields RW, Rasmussen P, Gupta R. Tentorial dural arteriovenous fistula presenting with quadriplegia: case report and review of the literature. *J Stroke Cerebrovasc Dis* 2009; **18**: 428-434 [PMID: 19900644 DOI: 10.1016/j.jstrokecerebrovasdis.2008.12.007]
- 5 **Renner C**, Helm J, Roth H, Meixensberger J. Intracranial dural arteriovenous fistula associated with progressive cervical myelopathy and normal venous drainage of the thoracolumbar cord: case report and review of the literature. *Surg Neurol* 2006; **65**: 506-510 [PMID: 16630919 DOI: 10.1016/j.surneu.2005.06.022]
- 6 **Zipfel GJ**, Shah MN, Refai D, Dacey RG, Derdeyn CP. Cranial dural arteriovenous fistulas: modification of angiographic classification scales based on new natural history data. *Neurosurg Focus* 2009; **26**: E14 [PMID: 19408992 DOI: 10.3171/2009.2.FOCUS0928]
- 7 **Cognard C**, Gobin YP, Pierot L, Bailly AL, Houdart E, Casasco A, Chiras J, Merland JJ. Cerebral dural arteriovenous fistulas: clinical and angiographic correlation with a revised classification of venous drainage. *Radiology* 1995; **194**: 671-680 [PMID: 7862961 DOI: 10.1148/radiology.194.3.7862961]
- 8 **Versari PP**, D'Aliberti G, Talamonti G, Branca V, Boccardi E, Collice M. Progressive myelopathy caused by intracranial dural arteriovenous fistula: report of two cases and review of the literature. *Neurosurgery* 1993; **33**: 914-918; discussion 918-919 [PMID: 8264894 DOI: 10.1097/00006123-199311000-00023]
- 9 **Lewis AI**, Tomsick TA, Tew JM. Management of tentorial dural arteriovenous malformations: transarterial embolization combined with stereotactic radiation or surgery. *J Neurosurg* 1994; **81**: 851-859 [PMID: 7965115 DOI: 10.3171/jns.1994.81.6.0851]
- 10 **Iovtchev I**, Hiller N, Ofra Y, Schwartz I, Cohen J, Rubin SA, Meiner Z. Late diagnosis of spinal dural arteriovenous fistulas resulting in severe lower-extremity weakness: a case series. *Spine J* 2013 Oct 2; Epub ahead of print [PMID: 24246747 DOI: 10.1016/j.spinee.2013.08.029]
- 11 **Gobin YP**, Rogopoulos A, Aymard A, Khayata M, Reizine D, Chiras J, Merland JJ. Endovascular treatment of intracranial dural arteriovenous fistulas with spinal perimedullary venous drainage. *J Neurosurg* 1992; **77**: 718-723 [PMID: 1403113 DOI: 10.3171/jns.1992.77.5.0718]
- 12 **Lawton MT**, Sanchez-Mejia RO, Pham D, Tan J, Halbach



- VV. Tentorial dural arteriovenous fistulae: operative strategies and microsurgical results for six types. *Neurosurgery* 2008; **62**: 110-124; discussion 124-125 [PMID: 18424975 DOI: 10.1227/01.neu.0000317381.68561.b0]
- 13 **Rangel-Castilla L**, Barber SM, Klucznik R, Diaz O. Mid and long term outcomes of dural arteriovenous fistula endovascular management with Onyx. Experience of a single tertiary center. *J Neurointerv Surg* 2014; **6**: 607-613 [PMID: 24062253 DOI: 10.1136/neurintsurg-2013-010894]
  - 14 **Natarajan SK**, Ghodke B, Kim LJ, Hallam DK, Britz GW, Sekhar LN. Multimodality treatment of intracranial dural arteriovenous fistulas in the Onyx era: a single center experience. *World Neurosurg* 2010; **73**: 365-379 [PMID: 20849795 DOI: 10.1016/j.wneu.2010.01.009]
  - 15 **Gokhale S**, Khan SA, McDonagh DL, Britz G. Comparison of surgical and endovascular approach in management of spinal dural arteriovenous fistulas: A single center experience of 27 patients. *Surg Neurol Int* 2014; **5**: 7 [PMID: 24575322 DOI: 10.4103/2152-7806.125628]
  - 16 **Narvid J**, Hetts SW, Larsen D, Neuhaus J, Singh TP, McSwain H, Lawton MT, Dowd CF, Higashida RT, Halbach VV. Spinal dural arteriovenous fistulae: clinical features and long-term results. *Neurosurgery* 2008; **62**: 159-166; discussion 166-167 [PMID: 18300903 DOI: 10.1227/01.NEU.0000311073.71733.C4]

**P- Reviewer:** Paholpak P **S- Editor:** Ji FF **L- Editor:** A  
**E- Editor:** Wu HL



## Relapsing polychondritis with p-ANCA associated vasculitis: Which triggers the other?

Ibolya File, Csilla Trinn, Zsolt Mátyus, László Ujhelyi, József Balla, János Mátyus

Ibolya File, Csilla Trinn, László Ujhelyi, József Balla, János Mátyus, Institute of Internal Medicine, University of Debrecen, Clinical Centre, H-4032 Debrecen, Hungary

Zsolt Mátyus, Borsod-Abaúj-Zemplén County and University Teaching Hospital, 2<sup>nd</sup> Department of Internal Medicine, H-3526 Miskolc, Hungary

**Author contributions:** Mátyus J designed the report; Ujhelyi L performed the renal biopsies; File I, Trinn C, Mátyus Z, Balla J and Mátyus J collected the patient's clinical data; File I, Trinn Cs, and Mátyus J analyzed the data and wrote the paper.

**Supported by** Department of Nephrology, University of Debrecen, Clinical Centre, Debrecen, Hungary; The project implemented through the New Hungary Development Plan, co-financed by the European Union and the European Social Fund, No. TÁMOP-4.2.2.A-11/1/KONV-2012-0045

**Correspondence to:** Ibolya File, MD, Institute of Internal Medicine, University of Debrecen, Clinical Centre, 98 Nagyterdei bld., H-4032 Debrecen, Hungary. [fileibolya@gmail.com](mailto:fileibolya@gmail.com)  
Telephone: +36-20-5145005

Received: July 28, 2014 Revised: October 2, 2014

Accepted: October 23, 2014

Published online: December 16, 2014

which raises the possibility of associated hemophagocytic syndrome. In the setting of RP or AAV physicians should always be aware of the possibility of sudden or insidious appearance of the other disease.

© 2014 Baishideng Publishing Group Inc. All rights reserved.

**Key words:** Relapsing polychondritis; Anti-neutrophil cytoplasmic antibody; Anti-neutrophil cytoplasmic antibody-associated vasculitis; Rapidly progressive glomerulonephritis; Immunosuppressive treatment

**Core tip:** Relapsing polychondritis (RP) is a rare disease usually diagnosed late when serious symptoms occur. Appearance of renal symptoms significantly increases the possibility of associated associated vasculitis (AAV). We present three cases of RP in whom AAV occurred at different times during the illness. AAV caused rapidly progressive glomerulonephritis (RPGN) in the second and third patient. Aggressive immunosuppression resulted in remission of both RP and AAV. In the RPGN cases dialysis could be discontinued.

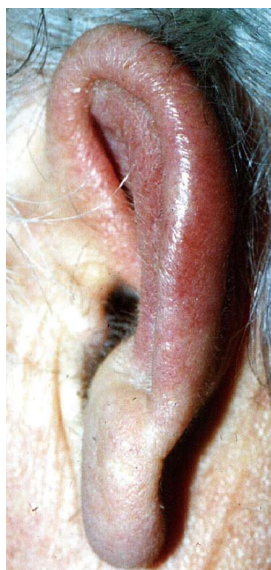### Abstract

Relapsing polychondritis (RP) is a rare autoimmune disease with chronic inflammatory/destructive lesions of the cartilaginous tissues. In one third of the cases it is associated with other autoimmune disorders, mostly with anti-neutrophil cytoplasmic antibody (ANCA) associated vasculitis (AAV). We report three cases of RP with p-ANCA positive AAV. In the first patient RP developed 1.5 years after the onset of AAV. In the others the signs of RP were present before the onset of severe crescent glomerulonephritis. Patients responded well on steroid and cyclophosphamide. In dialysis dependent cases plasmapheresis was also used successfully. During the 2 and 1.5 years of follow up, they were symptom-free, and had stable glomerular filtration rate. The first patient died after four years of follow-up due to the complications of sudden onset pancytopenia,

File I, Trinn C, Mátyus Z, Ujhelyi L, Balla J, Mátyus J. Relapsing polychondritis with p-ANCA associated vasculitis: Which triggers the other? *World J Clin Cases* 2014; 2(12): 912-917 Available from: URL: <http://www.wjgnet.com/2307-8960/full/v2/i12/912.htm> DOI: <http://dx.doi.org/10.12998/wjcc.v2.i12.912>

### INTRODUCTION

Relapsing polychondritis (RP) is a rare disease characterized by recurrent inflammatory flares of cartilaginous structures of ear, nose, joints, larynx and tracheobronchial tree<sup>[1-4]</sup>. The aetiology of RP is not clearly defined, but the pathogenesis should involve an autoimmune response to cartilage<sup>[5]</sup>. About one third of RP cases can be associated with other multi-system diseases, of which



**Figure 1** Red and swollen ear of patient 1. The inflammation spares the lobule.

primary systemic vasculitides are the most common. anti-neutrophil cytoplasmic antibody (ANCA) may be present in up to 25% of patients with RP<sup>[6]</sup>. Some of these patients show a classical clinical picture of one of the ANCA associated vasculitides (AAV) and polychondritis is usually thought to be a secondary phenomenon<sup>[7-9]</sup>. However many RP patients with ANCA positivity do not have any, or only limited, vasculitic symptoms<sup>[6]</sup> and the occurrence of RP may precede AAV<sup>[10-12]</sup>. It is possible that the development of ANCA could be provoked by RP, as it was seen by us in rheumatoid arthritis patients<sup>[13]</sup>.

Whatever is the sequence of disease manifestations, the occurrence of renal symptoms significantly raise the possibility of (underlying or secondary) AAV, the need for more aggressive treatment, and indicates worse prognosis<sup>[14-17]</sup>. We present three cases of RP in whom AAV occurred at different times during the illness. Two patients developed rapidly progressive glomerulonephritis (RPGN). The aggressive treatment resulted in dialysis independence in both cases.

## CASE REPORT

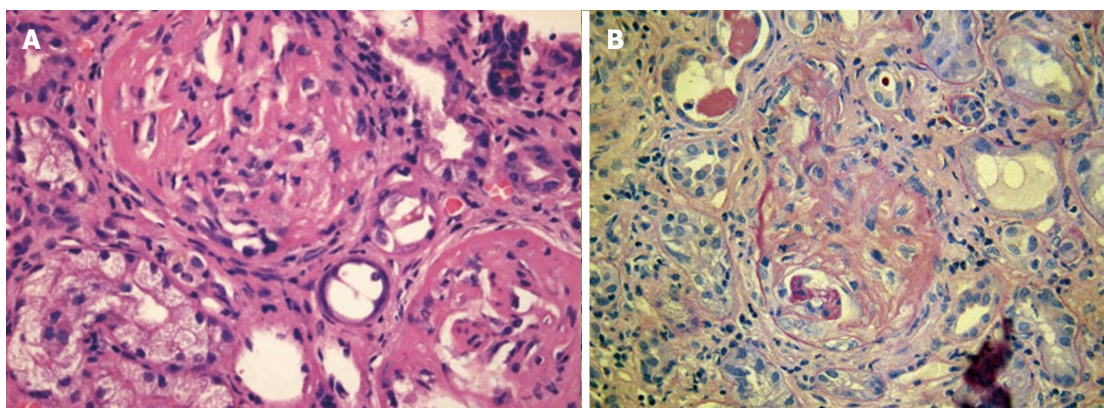
### Case report 1

In March 1998 microscopic polyangiitis was diagnosed in a 58 years old male, based on four weeks' history of fever, anaemia, purpura, arthralgia, episcleritis, axonal neuropathia, and p-ANCA positivity of 38 U/mL (normal < 3 U/mL). Glomerular haematuria, granular casts and mild proteinuria were also present. The serum creatinine was normal, therefore a kidney biopsy was not performed. Renal angiography did not find any aneurysms. Skin biopsy verified small vessel vasculitis. Per os treatment with 1 mg/kg steroid and 2 mg/kg cyclophosphamide resulted in quick resolution of symptoms and p-ANCA negativity, but 2 mo later severe leucopenia and herpes in-

fection of the skin developed, therefore cyclophosphamide was withdrawn. The patient was well on a low dose steroid, but after tapering the dose to 4 mg/d in November 1999 episcleritis reoccurred. Painful swelling and redness of both auricles with sparing of the ear lobe had also developed (Figure 1). Auricular polychondritis spontaneously diminished, but in the next months it relapsed twice. Less severe inflammation of the nose bridge was also present. Based on these clinical symptoms the diagnosis of relapsing polychondritis was established. ANCA remained negative and no other signs of systemic vasculitis reoccurred. Increased steroid dose and azathioprine resulted in remission of polychondritis, therefore six month later azathioprine was withdrawn and only 4-8 mg of methylprednisolone was applied. In June of 2002 fever, weakness and purpura reoccurred. Severe thrombocytopenia (24 G/L), leucopenia (1,2 G/L) and anaemia (Hb 78 g/L) were also present. Bone marrow biopsy showed hyperregenerative cell lines but also a delay in cell maturation thus leading to pancytopenia. Occasionally macrophages containing red blood cell fragments within their cytoplasm were also present. No primary haematological disease was seen and ANCA was negative. Pulse steroid treatment was given resulting in quick improvement of pancytopenia. In August 2002 pancytopenia suddenly reoccurred and the patient died within 24 h after admission into another institution. No autopsy was performed.

### Case report 2

A 63-year old woman was admitted to our Department in July 2012 with two months' history of 6 kg weight loss, fatigue, subfebrility, elevated C-reactive protein and normocytic anaemia. She had renal failure as well and needed urgent haemodialysis (serum creatinine 1040  $\mu$ mol/L). Urinalysis disclosed proteinuria and glomerular haematuria, ultrasound showed normal size kidneys. Rapidly progressive glomerulonephritis was suspected. The renal biopsy demonstrated pauci-immune necrotizing glomerulonephritis with fibrocellular crescents being present in 70% of glomeruli (Figure 2). She had elevated anti-MPO titer: 21 U/mL (normal < 5 U/mL). The diagnosis of ANCA associated systemic vasculitis was established. Typical signs of auricular chondritis were also present, her ears were tender and had cauliflower appearance. She complained of dizziness, hearing loss, and compromised smell. Her bilateral mixed hearing loss was diagnosed 8 years earlier. In the recent years she had migrating transient polyarthralgia, recurrent nasal obstruction and red eyes, but medical consultation was not sought except due to hypertension in 2010. These signs and symptoms led to the diagnosis of relapsing polychondritis. Pulse steroid of 3  $\times$  1 g was given and five sessions of plasmapheresis were performed. Treatment resulted in immediate resolution of the inflammatory symptoms. Maintenance immunosuppression was continued in a dose of 0.5 mg/kg per day prednisolone and 1.5 mg/kg per day cyclophosphamide per os. Renal function improved, in February 2013 dialysis could be discontinued, cyclophosphamide was



**Figure 2** Renal biopsy of the second patient: extensive fibrocellular crescents in the glomeruli. A: Haematoxylin-eosin  $\times 40$ ; B: Periodic acid-Schiff  $\times 40$ .

withdrawn. Prednisolone was stopped in June 2014 (estimate GFR 20 mL/min per 1.73 m<sup>2</sup>, proteinuria 0.5 g/L). During the 2 years of follow-up, no relapse of vasculitis or polychondritis was observed. Anti-MPO level remained negative, her hearing and the shape of her ears returned to normal.

### Case report 3

A 56-year-old woman - with a ten year history of hypertension - was referred to our Department in October 2012 due to RPGN requiring dialysis. ANCA associated glomerulonephritis was established based on  $> 100$  U/mL anti-MPO (normal  $< 5$  U/mL) and pauci-immune glomerulonephritis (fibrocellular crescents in 10 of 32 of glomeruli) seen in the kidney biopsy. In recent years she repeatedly experienced hoarseness, sore throat, laryngotracheal pain, swollen, tender, painful ears and low grade fever. Symptoms sometimes disappeared spontaneously, sometimes she was treated with antibiotics and analgesics. She also had migrating arthralgia. Based on these signs preceding polychondritis was also diagnosed. Before the start of her complaints she punctured her finger while vaccinating rabbits against myxomatosis. At that time (September 2011) laboratory tests revealed normal renal function without proteinuria and haematuria. In September 2012 her throat and ear complaints reoccurred accompanied by fever, fatigue, weight loss, macroscopic haematuria and oliguria. Considering this acute episode she was started on the following therapy: pulse prednisolone ( $4 \times 0.5$  g), plasmapheresis (5 session), and 1.5 mg/kg oral cyclophosphamide. The treatment resulted in resolution of the inflammatory symptoms, renal function improved, and dialysis could be discontinued. Anti-MPO level decreased to 16 U/mL. The patient was discharged in good condition with 0.8 mg/kg per day methylprednisolone and 1.5 mg/kg per day cyclophosphamide. After three weeks she needed admission to our intensive care unit due to high fever, repeated convulsions, agitation and unconsciousness. ANCA titer was normal, renal function has not deteriorated, and her ears and throat did not show signs of inflammation. Therefore cerebral symptoms were suspected not caused by a vasculitic

episode but rather by an immunosuppression-related cerebral infection. Herpes encephalitis was diagnosed by liquor herpes simplex virus polymerase chain reaction positivity. Intravenous acyclovir and immunoglobulin was administered, the steroid dose increased and cyclophosphamide discontinued. This therapy resulted in a slow but full recovery regarding cerebral symptoms. The steroid was gradually tapered and stopped after 1 year. There was no relapse of polychondritis or vasculitis during the 18 mo follow-up, eGFR stabilized about 20 mL/min per 1.73 m<sup>2</sup>, there was no proteinuria, and ANCA tests were negative.

The most important laboratory findings are presented in the Table 1.

## DISCUSSION

We present three cases of ANCA associated vasculitis, who also merit the diagnostic criteria for RP. They are not exceptional cases, because vasculitis can be seen in 14% of RP patients<sup>[1]</sup>, ANCA positivity in up to 25% of RP patients<sup>[6]</sup>. The annual incidence of AAV and RP (which is about 10-30/million and 3.5/million population respectively) makes it unlikely that these cases represent simple coincidence.

About one third of RP cases can be associated with other autoimmune diseases, of which vasculitis is the most common<sup>[1-4]</sup>. All types of vasculitis were already reported with RP, including microscopic polyangiitis<sup>[10,14]</sup>, polyangiitis with granulomatosis<sup>[18]</sup>, eosinophil granulomatosis with polyangiitis<sup>[19]</sup>, among them most frequently AAV. In our three cases microscopic polyangiitis was diagnosed based on the general and renal signs of systemic vasculitis, the absence of eosinophilia, allergic rhinitis/asthma or sinusitis/otitis. The p-ANCA, anti-MPO positivity is also characteristic for MPA.

There are no specific clinically applicable tests to confirm the diagnosis of RP. Antibodies against type II collagen and matrilin-1 (cartilage matrix protein prominent in tracheal, auricular, and nasal cartilages) can be detected in sera of patients with RP, however their sensitivity and specificity is very low<sup>[5]</sup>. Therefore the diagnosis of RP is based on clinical signs<sup>[20]</sup>. Currently the diagnosis of



**Table 1 Laboratory findings in relapsing polychondritis patients with systemic vasculitis**

	Case 1, male 58 yr 03, 1998	Case 2 female 56 yr 7, 2012	Case 3, female 63 yr 10, 2012
Proteinuria (g/d)	0.2	1.03	4.7
Haematuria (vvt/hpf)	15	516	107
Hb (g/L)	95	63	69
CRP (mg/L)	209	101	103
UN (mmol/L)	6.3	41	28
Creatinine (μmol/L)	105	1040	534
GFR (mL/min per 1.73 m <sup>2</sup> )	> 60	3	7
Anti-MPO ab (U/mL)	38 (normal < 3)	21.8 (normal < 5)	> 100 (normal < 5)

CRP: C-reactive protein; GFR: Glomerular filtration rate.

RP requires the presence of a proven inflammation in at least 2 of 3 of the auricular, nasal, or laryngotracheal cartilages, alternatively, a proven inflammation in one of the above cartilages and two other signs including ocular inflammation, hearing loss, vestibular dysfunction, or seronegative arthritis<sup>[21]</sup>.

In our cases the auricular chondritis was the diagnosis-raising sign, but there were other signs in every case to meet the diagnostic criteria of RP. In the first patient recurrent polychondritis developed 1.5 years after the onset of typical vasculitis (neuropathy, purpura, haematuria) when the steroid dose was tapered off. This supports the concept, that RP is a secondary phenomenon of underlying AAV. However, at that time vasculitis was not active, furthermore ANCA was negative. This observation is counter to the findings outlined in a recent case report<sup>[9]</sup>.

In Case 3 the ear and throat symptoms preceded the vasculitis by one year. Her symptoms started after an accidental needle-puncture while vaccinating rabbits against myxomatosis. It is possible that the attenuated *Myxoma virus* was the trigger activating the immune system by molecular mimicry. In Case 2 AAV and auricular chondritis occurred at the same time, but her hearing loss preceded them by eight years. From that time she had recurrent auricular, nasal and ophthalmological symptoms, which raises the possibility of RP. The diagnosis of RP is difficult in the early stage because the incidence of each symptom is less than 50% at the onset<sup>[1]</sup>. The diagnosis is usually delayed by 3 years<sup>[22]</sup> but the delay can be as long as 10 years<sup>[23]</sup>. Extremely precise case history and clinical evaluation is needed. In this case the biopsy of an involved cartilage could help. Biopsies, however, often show only nonspecific granulation tissue, so the pathognomonic findings for RP may be not be easy to obtain<sup>[24]</sup>.

In spite of the fact that glomeruli do not contain type II collagen, renal involvement was reported in 29/129 cases in the Mayo Clinic study<sup>[17]</sup>. Haematuria was the most frequent abnormality occurring in 26% of 337 patients<sup>[1]</sup>. It was observed in all our cases, indicating a proliferative glomerulonephritis. Rapid decline in glomerular filtration rate (GFR) was seen in two cases raising the sus-

picion of pauci-immune crescentic glomerulonephritis, which was verified by a kidney biopsy. This type of glomerular lesion is diagnostic for AAV-s, even if ANCA is not present. In the early phase of kidney damage only focal segmental glomerular necrosis can be present. These lesions were the most frequently observed pathological finding in RP and rose the suspicion of vasculitis even decades earlier when ANCA was not yet available<sup>[14-17]</sup>. Less frequently other types of glomerulonephritides, such as IgA nephropathy<sup>[25]</sup>, membranous nephropathy<sup>[26]</sup> had also been reported. We think that these lesions could not to be linked to RP. When renal signs appear it is very important to differentiate renal vasculitis from other causes: e.g., membranous nephropathy could be caused by non-steroid anti-inflammatory drugs, used for the treatment of arthralgia in RP.

Renal vasculitis indicates a worse prognosis and the need for more aggressive immunosuppressive treatment. Due to the poor response of AAV to steroids alone, first-line regimes used in patients with RP/AAV overlap should include additional cyclophosphamide or other immunosuppression. Our patients responded well on steroid and cyclophosphamide treatment. In dialysis-dependent cases we combined it with plasmapheresis. This regime resulted in dialysis independence in spite of the advanced histological picture. The patients became symptom-free both regarding RP and AAV. They have severely decreased GFR, which could have been prevented had they been referred to us earlier. The first patient died after four years of follow-up due to the complications of sudden onset pancytopenia. No primary haematological disease was seen on bone marrow biopsy. Therefore it was thought to be a result of a flare of the underlying autoimmune disease, which was supported by the fact that pulse steroid treatment had been effective. The presence of hemophagocytosis and the recurrence of pancytopenia with sudden respiratory failure raise the possibility of hemophagocytic syndrome. Its association with adult onset autoimmune disease has recently gained attention<sup>[27,28]</sup>. The association of RP and AAV can lead to critical conditions and treatment needs to be initiated promptly and undertaken by an experienced team. RP patients need a regular and prolonged follow up for renal symptoms and ANCA-s as well.

### Recommendation

In any case of RP or AAV physicians should be aware of sudden or insidious appearance of the other disease.

## COMMENTS

### Cases characteristics

A 58-year-old male diagnosed with microscopic polyangiitis experienced painful swelling and redness of both auricles, a 63-year-old woman had renal failure, tender and cauliflower-like ears, a 56-year-old woman -with a history of relapsing polychondritis-presented with rapidly progressive glomerulonephritis.

### Clinical diagnosis

Swelling and redness of both ears, arthralgia, red eyes, hearing loss, tracheo-bronchial pain pointed to relapsing polychondritis, while purpura, general (fever,

fatigue, weight loss), and renal (haematuria, oliguria) symptoms to vasculitis.

### Differential diagnosis

Microscopic polyangiitis, polyangiitis with granulomatosis, eosinophil granulomatosis with polyangiitis, other vasculitides, systemic lupus erythematoses, other causes of rapidly progressive glomerulonephritis (RPGN) can be considered.

### Laboratory diagnosis

High C-reactive protein, anaemia, p-anti-neutrophil cytoplasmic antibody/anti-MPO positivity, haematuria, proteinuria, elevated serum creatinine, decreased glomerular filtration rate (Table).

### Imaging diagnosis

Chest X-ray was unremarkable, abdominal ultrasound showed normal size kidneys.

### Pathological diagnosis

Skin biopsy of the first patient showed small vessel vasculitis, renal biopsy of the other two patients was consistent with pauci-immune crescentic glomerulonephritis.

### Treatment

Immunosuppressive treatment with steroid, cyclophosphamide, azathioprine; in the RPGN cases plasmapheresis was the specific medication.

### Related reports

There are only scattered case reports about the association of relapsing polychondritis (RP) and associated vasculitides (AAV).

### Term explanation

Pauci-immune glomerulonephritis is diagnosed based on extensive extracapillary proliferation (leading to crescent formation) and necrotic lesions in the capillary tuft with negative immunofluorescent and electron microscopic finding.

### Experiences and lessons

In any case of RP or AAV physicians should be aware of sudden or insidious appearance of the other disease.

### Peer review

It is properly written article on case series of relapsing polychondritis and vasculitis.

## REFERENCES

- Kent PD, Michet CJ, Luthra HS. Relapsing polychondritis. *Curr Opin Rheumatol* 2004; **16**: 56-61 [PMID: 14673390]
- Gergely P, Poór G. Relapsing polychondritis. *Best Pract Res Clin Rheumatol* 2004; **18**: 723-738 [PMID: 15454129 DOI: 10.1016/j.berh.2004.05.012]
- Lahmer T, Treiber M, von Werder A, Foerger F, Knopf A, Heemann U, Thuermel K. Relapsing polychondritis: An autoimmune disease with many faces. *Autoimmun Rev* 2010; **9**: 540-546 [PMID: 20215048 DOI: 10.1016/j.autrev.2010.02.016]
- Cantarini L, Vitale A, Brizi MG, Caso F, Frediani B, Punzi L, Galeazzi M, Rigante D. Diagnosis and classification of relapsing polychondritis. *J Autoimmun* 2014; **48-49**: 53-59 [PMID: 24461536 DOI: 10.1016/j.jaut.2014.01.026]
- Arnaud L, Mathian A, Haroche J, Gorochoy G, Amoura Z. Pathogenesis of relapsing polychondritis: a 2013 update. *Autoimmun Rev* 2014; **13**: 90-95 [PMID: 24051104 DOI: 10.1016/j.autrev.2013.07.005]
- Papo T, Piette JC, Le Thi Huong Du, Godeau P, Meyer O, Kahn MF, Bourgeois P. Antineutrophil cytoplasmic antibodies in polychondritis. *Ann Rheum Dis* 1993; **52**: 384-385 [PMID: 8323388 DOI: 10.1136/ard.52.5.384-b]
- Handrock K, Gross WL. Relapsing polychondritis as a secondary phenomenon of primary systemic vasculitis. *Ann Rheum Dis* 1993; **52**: 895-897 [PMID: 8311544 DOI: 10.1136/ard.52.12.895-c]
- Schina M, Karsaliakos P, Apostolou T, Mousoulis G. Relapsing polychondritis as a secondary phenomenon of primary systemic vasculitis. *Clin Nephrol* 2008; **70**: 446-449 [PMID: 19000549]
- Mattiassich G, Egger M, Semlitsch G, Rainer F. Occurrence of relapsing polychondritis with a rising cANCA titre in a cANCA-positive systemic and cerebral vasculitis patient. *BMJ Case Rep* 2013; **2013**: [PMID: 23417970 DOI: 10.1136/bcr-2013-008717]
- Weber F, Kowald E, Schmuth M, Sepp N. Microscopic polyangiitis in a patient with relapsing polychondritis. *Rheumatology (Oxford)* 2001; **40**: 233-235 [PMID: 11257169 DOI: 10.1093/rheumatology/40.2.233]
- Masterson R, Sheerin N, Abbs I, Goldsmith D. Late allograft loss due to recurrence of p-ANCA-associated systemic vasculitis in a patient with relapsing polychondritis. *Nephrol Dial Transplant* 2001; **16**: 1705-1707 [PMID: 11477180 DOI: 10.1093/ndt/16.8.1705]
- Barzegar C, Vrtovnik F, Devars JF, Mignon F, Pradalier A. Vasculitis with mesangial IgA deposits complicating relapsing polychondritis. *Clin Exp Rheumatol* 2002; **20**: 89-91 [PMID: 11892718]
- Szilasi M, Mátyus J, File I, Szücs G, Rákóczi E, Pfliegler G, Szabó Z, Végh E, Szekanecz Z. Association of ANCA-associated vasculitis-rheumatoid arthritis overlap syndrome in four patients: rituximab may be the right choice? *Autoimmunity* 2012; **45**: 304-309 [PMID: 22443800 DOI: 10.3109/08916934.2012.677078]
- Neild GH, Cameron JS, Lessof MH, Ogg CS, Turner DR. Relapsing polychondritis with crescentic glomerulonephritis. *Br Med J* 1978; **1**: 743-745 [PMID: 630326]
- Ruhlen JL, Huston KA, Wood WG. Relapsing polychondritis with glomerulonephritis. Improvement with prednisone and cyclophosphamide. *JAMA* 1981; **245**: 847-848 [PMID: 7463678 DOI: 10.1001/jama.1981.03310330037021]
- Botey A, Navasa M, del Olmo A, Montoliu J, Ferrer O, Cardesa A, Darnell A, Revert L. Relapsing polychondritis with segmental necrotizing glomerulonephritis. *Am J Nephrol* 1984; **4**: 375-378 [PMID: 6517117]
- Chang-Miller A, Okamura M, Torres VE, Michet CJ, Waggoner RD, Donadio JV, Offord KP, Holley KE. Renal involvement in relapsing polychondritis. *Medicine (Baltimore)* 1987; **66**: 202-217 [PMID: 3574118]
- Small P, Black M, Davidman M, de Champlain ML, Kapusta MA, Kreisman H. Wegener's granulomatosis and relapsing polychondritis: a case report. *J Rheumatol* 1980; **7**: 915-918 [PMID: 7205833]
- Conn DL, Dickson ER, Carpenter HA. The association of Churg-Strauss vasculitis with temporal artery involvement, primary biliary cirrhosis, and polychondritis in a single patient. *J Rheumatol* 1982; **9**: 744-748 [PMID: 7175848]
- McAdam LP, O'Hanlan MA, Bluestone R, Pearson CM. Relapsing polychondritis: prospective study of 23 patients and a review of the literature. *Medicine (Baltimore)* 1976; **55**: 193-215 [PMID: 775252]
- Michet CJ, McKenna CH, Luthra HS, O'Fallon WM. Relapsing polychondritis. Survival and predictive role of early disease manifestations. *Ann Intern Med* 1986; **104**: 74-78 [PMID: 3484422 DOI: 10.7326/0003-4819-104-1-74]
- Trentham DE, Le CH. Relapsing polychondritis. *Ann Intern Med* 1998; **129**: 114-122 [PMID: 9669970 DOI: 10.7326/0003-4819-129-2-199807150-00011]
- Paroli MP, Priori R, Spinucci G, Abicca I, Valesini G. Uveitis with retinal occlusive vasculitis and sensorineural hypoacusia as first symptoms of relapsing polychondritis. *Clin Exp Rheumatol* 2012; **30**: S101-S103 [PMID: 22410282]
- Tsuda T, Nakajima A, Baba S, Tanohara K, Masuda I, Yamada T, Takagi K, Yamakawa T, Kamatani N, Hara M. A case of relapsing polychondritis with bilateral sensorineural hearing loss and perforation of the nasal septum at the onset. *Mod Rheumatol* 2007; **17**: 148-152 [PMID: 17437171]
- Dalal BI, Wallace AC, Slinger RP. IgA nephropathy in relapsing polychondritis. *Pathology* 1988; **20**: 85-89 [PMID: 3287308]
- Lee J, Lee EK. A case of membranous nephropathy associated with relapsing polychondritis. *Kidney Res Clin Pract* 2012; **31**: 253-256 [DOI: 10.1016/j.krcp.2012.10.004]

- 27 **Tabata R**, Tabata C, Terada M, Nagai T. Hemophagocytic syndrome in elderly patients with underlying autoimmune diseases. *Clin Rheumatol* 2009; **28**: 461-464 [PMID: 19165558 DOI: 10.1007/s10067-009-1086-2]
- 28 **Kumakura S**, Murakawa Y. Clinical characteristics and treatment outcomes of autoimmune-associated hemophagocytic syndrome in adults. *Arthritis Rheumatol* 2014; **66**: 2297-2307 [PMID: 24756912 DOI: 10.1002/art.38672]

**P- Reviewer:** Espinoza LR, Kuzstal M **S- Editor:** Ji FF  
**L- Editor:** A **E- Editor:** Wu HL



## Gastric trichobezoar associated with perforated peptic ulcer and *Candida glabrata* infection

Héctor Losada Morales, Cecilia Huenchullán Catalán, Rodrigo Arriagada Demetrio,  
Macarena Espinoza Rivas, Natalia Castagnoli Parraguez, Martín Alanis Alvarez

Héctor Losada Morales, Cirugía Hepato-pancreática y Biliar, Departamento de Cirugía, Clínica Alemana de Temuco, Temuco 4810297, Chile

Héctor Losada Morales, Martín Alanis Alvarez, Cirugía Hepato-pancreática y Biliar, Departamento de Cirugía y Traumatología, Universidad de La Frontera, Temuco 4781218, Chile

Cecilia Huenchullán Catalán, Departamento de Imágenes, Clínica Alemana de Temuco, Temuco 4810297, Chile

Rodrigo Arriagada Demetrio, Macarena Espinoza Rivas, Natalia Castagnoli Parraguez, Departamento de Ginecología y Obstetricia, Clínica Alemana de Temuco, Temuco 4810297, Chile

**Author contributions:** Losada Morales H contributed to design the paper, review clinical issues, images and histopathology and to write the paper; Huenchullán Catalán C contributed to review of images and to write the paper; Arriagada Demetrio R, Espinoza Rivas M, Castagnoli Parraguez N and Alanis Alvarez M contributed to review the clinical issues, to write the paper; all authors of this research paper have directly participated in the planning, execution, or analysis of this study; all authors of this paper have read and approved the final version submitted.

**Correspondence to:** Héctor Losada Morales, MD, MSc in Clinical Epidemiology, Cirugía Hepato-pancreática y Biliar, Departamento de Cirugía y Traumatología, Universidad de La Frontera, Claro Solar 115, Región de la Araucanía, Temuco 4781218, Chile. [hector.losada@ufrontera.cl](mailto:hector.losada@ufrontera.cl)

Telephone: +56-45-2325760 Fax: +56-45-2325761

Received: July 6, 2014 Revised: August 24, 2014

Accepted: September 16, 2014

Published online: December 16, 2014

picture, at no point was the presence of a giant bezoar at gastric level suspected, specifically a trichobezoar. The emergency abdominal and pelvic ultrasound revealed only unspecific signs of perforated hollow viscus. Diagnosis was therefore made intraoperatively. A complete gastric trichobezoar was found with gastric perforation and secondary peritonitis. The peritoneal fluid culture revealed *Candida glabrata*.

© 2014 Baishideng Publishing Group Inc. All rights reserved.

**Key words:** Bezoar; Postpartum period; Acute abdomen

**Core tip:** This case report describes the presentation of a gastric trichobezoar as an acute abdomen in puerperal woman with a detailed clinical description and images. The discussion provides an extensive analysis on the various types of treatments that exist today and their results, as well as evaluating its association with specific psychiatric diseases, and the finding of *Candida* infection in the patient evolution.

Losada Morales H, Huenchullán Catalán C, Arriagada Demetrio R, Espinoza Rivas M, Castagnoli Parraguez N, Alanis Alvarez M. Gastric trichobezoar associated with perforated peptic ulcer and *Candida glabrata* infection. *World J Clin Cases* 2014; 2(12): 918-923 Available from: URL: <http://www.wjgnet.com/2307-8960/full/v2/i12/918.htm> DOI: <http://dx.doi.org/10.12998/wjcc.v2.i12.918>

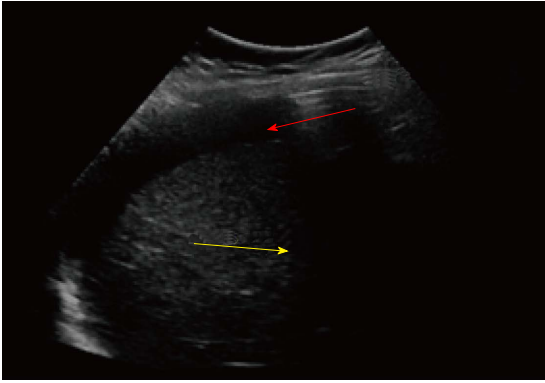
### Abstract

Bezoars are accumulations of human or plant fiber located in the gastrointestinal tract of both humans and animals. Patients remain asymptomatic for several years, and the symptoms develop as these accumulations increase in size to the point of obstruction or perforation. We report the case of a 21-year-old patient at 10 d postpartum, who presented with acute abdomen associated with sepsis. Given the urgency of the clinical

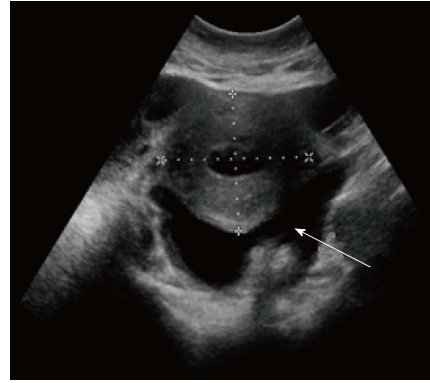
### INTRODUCTION

The trichobezoar is a rare medical condition composed of a mass of hair in the proximal gastrointestinal tract, which can cause obstruction, and almost exclusively affects young women<sup>[1,2]</sup>. Its prevalence ranges from 0.06% to 4% in the general population<sup>[3]</sup>. It is considered a re-





**Figure 1** Abdominal ultrasound at epigastric level shows moderate amount of free fluid (yellow arrow) and reverberation artifact immediately under the abdominal wall compatible with intraperitoneal free air (red arrow).



**Figure 2** At pelvic level, enlarged uterus is observed associated with free fluid, which presents echogenic material within suggestive of pus (white arrow).

sult of trichotillomania, a psychiatric disorder linked to compulsively removing hair from the head and body in general<sup>[4]</sup>. When hair is ingested, it resists digestion and peristalsis, which is why it accumulates in the folds of the gastric mucosa. Mostly it remains confined to this level; but on some occasions it passes the pylorus, reaching the jejunum, ileum and even the colon. This condition was described for the first time by Vaughan *et al*<sup>[5]</sup> in 1968, and was called Rapunzel syndrome. The aim of this work is to report the clinical case of a patient with acute abdomen involving perforated hollow viscus associated with sepsis during the post-Cesarean period, who presented with a giant trichobezoar intraoperatively, and to review the clinical presentation, study through imaging, risk factors, complications and treatment.

## CASE REPORT

Patient, 21 years of age, female, with a history of insulin resistance with no current pharmacological treatment. She came to the emergency room of the Clínica Alemana Temuco, Chile ten days after an uneventful Cesarean section, referred from the hospital in Angol due to acute pain in her left side with 24 h of evolution, colicky in nature and with an intensity of 10/10 on the pain scale, without radiation, associated with sweating and involvement of her general state. In the initial evaluation, she was described as endomorph (BMI: 26), with altered vital signs in the range of systemic inflammatory response syndrome: blood pressure 124/80 mmHg; mean blood pressure 87 mmHg; heart rate 150 beats per minute in sinus rhythm; temperature 36 °C; respiratory rate 21 breaths per minute; oxygen saturation 98% with 3 L/min of oxygen *via* nasal prongs. On physical examination she was alert, focused and responsive (Glasgow Scale: 15 points), pale in skin and mucosa, vesicular murmur reduced in both lung fields, and abdomen distended with no sounds, yielding to the touch with diffuse tenderness with signs of peritoneal irritation. The laboratory examinations on admittance were as follows: hematocrit 34.7%; leukocyte count: 16100 K/uL; platelets: 984000

K/uL; erythro sedimentation rate: 41 mm/h; C-reactive protein: 502 mg/L; creatinine: 1.52 mg/dL; uremia: 64 mg/dL; prothrombin percentage/thromboplastin time: 55.7%/42.1 s; INR: 1.3; sodium: 134 mmol/L; potassium: 5.5 mmol/L; chlorine: 105 mmol/L. The abdominal-pelvic ultrasound taken in the emergency room revealed a moderate amount of free fluid and pneumoperitoneum; the uterus was enlarged due to purulent fluid at the bottom of the Pouch of Douglas (Figures 1 and 2). The patient was admitted to the ICU with diagnoses of: (1) Acute abdomen; (2) Systemic inflammatory response syndrome (SIRS); (3) Early postpartum 10<sup>th</sup> day Cesarean section; and (4) Acute renal dysfunction.

Support began with conservative therapy: zero regimen, oxygen therapy and resuscitation with fluids. Follow-up tests 3 h later: hematocrit: 23.5; leukocytes: 10500; platelets: 735000. The patient received antibiotic prophylaxis (2 g ceftriaxone and 500 mg metronidazole) and a transfusion of 2 UI of deep frozen fresh plasma. Through imaging, the patient was considered to be in post-Cesarean period with acute abdomen, abdominal sepsis and possible perforated hollow viscus. An exploratory laparotomy was performed, which found purulent fluid in 4 quadrants, a left subphrenic abscess, cecal appendix with the end phlegmonous and ulcerated, two perforated gastric ulcers, one in the anterior wall and another in the posterior wall, with a collection of gastric fluid in the omental bursa, and complete gastric trichobezoar involving the stomach and duodenum (weight: 1090 g) (Figure 3). The technique used was an anterior gastrotomy and bezoar extraction (Figures 4-6), closing the wound, including the ulcer, with a running stitch of 3-0 polydioxanone, single-layer suture and running stitch with 2-0 silk. Closing the ulcer in the posterior wall was done with 3-0 polydioxanone and an omental patch, fixing it with 3-0 silk.

The patient evolved favorably in the early postoperative phase, but at 3 d she began with a fever up to 38.9 °C, for which empirical antibiotic treatment was introduced. She remained hospitalized 25 d and in total and four days in intensive care unit. Peritoneal fluid culture



Figure 3 Trichobezoar extracted weighing 1.09 kg.

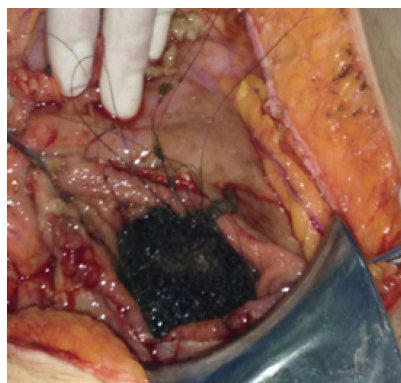


Figure 5 Gastric opening for extraction of trichobezoar.

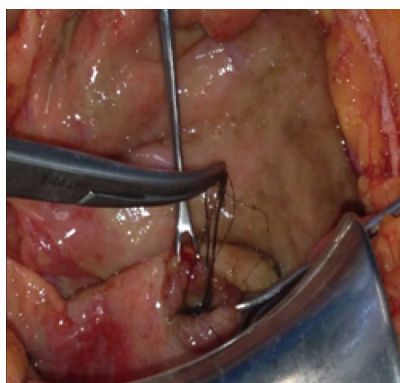

Figure 4 Finding of hair through perforated ulcer.

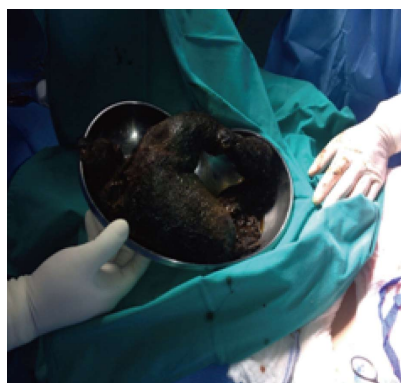

Figure 6 Trichobezoar mass taking the shape of the stomach and part of the duodenum.

was positive for *Candida Glabrata*; therefore, infectology assessed the case and decided to initiate anti-fungal drugs due to the presentation in the case of a hollow viscus rupture in conjunction with a bezoar. During hospitalization a psychiatric evaluation, during an interview of the patient and her mother, revealed that she had exhibited trichotillomania and trichophagia daily since the age of 12. The behavior decreased during pregnancy, and she was therefore diagnosed with moderate anxiety disorder with trichotillomania and inactive trichophagia. The methylene blue test was negative on the seventh postoperative day. Antibiotic therapy with ertapenem in addition to caspofungin was completed after two weeks. Evolution was good, with a good response, so discharge was given, completing oral anti-fungal treatment with voriconazole for three weeks.

## DISCUSSION

A bezoar is defined as a mass of ingested foreign material accumulated in the digestive tract. It means “protection against poison” or antidote, given its use for curative purposes and even superstitions associated with good luck<sup>[6,7]</sup>. The first recorded case was in 1779, when Baudamant described the presentation in a woman<sup>[8]</sup>. Bezoars are classified into 5 groups according to the substance that comprises it: phytobezoar, pharmaco-bezoar, trichobezoar, lactobezoar and foreign body bezoar<sup>[9]</sup>.

Bezoars are described as occurring in 1% of the population, associated mainly with gastric disorders such as hypomotility, hyposecretion with hypochlorhydria, and a history of resection<sup>[10]</sup>. In one retrospective study, 87 cases of intestinal bezoars were presented, in which diagnosis was made using the clinical history plus an endoscopy. The results included the presence of a prior surgery in 76 of the cases. In 3% of the cases, the most widely used technique was the bilateral truncal vagotomy with a pyloroplasty (75.8%). Other factors to consider would be an excess of plant fiber ingestion in 39.5%, and alterations in teething and chewing in 24%<sup>[11]</sup>.

In our case it was more important specifically to investigate the presence of trichotillomania, a disorder listed in the fifth edition of the Diagnostic and Statistical Manual of Mental Disorders, in the section on Obsessive-Compulsive and Related Disorders<sup>[12]</sup>. Although its prevalence and comorbidity have not been clearly determined, different series of cases describe from 5% to 30% of patients with trichotillomania as having associated trichophagia<sup>[13-15]</sup>, while 1% to 37.5% of these will develop a trichobezoar<sup>[13,15-17]</sup>.

The clinical presentation generally occurs with symptoms and signs of acute abdomen and intestinal obstruction. This includes abdominal pain, nausea, bilious vomiting, hematemesis, anorexia, early satiety, weakness, weight loss and an abdominal mass<sup>[18-20]</sup>. Associated systemic

complications include anemia, due either to nutritional deficit or gastrointestinal bleeding, and gastric ulcers have been documented in cases of gastric bezoars<sup>[21]</sup>. Imaging, such as ultrasound, can be useful in the detection of an abdominal mass, although computed tomography is more precise in assessing the characteristics of a bezoar and will allow the additional identification of bezoars in other places in the gastrointestinal tract. The diagnosis is established by endoscopy<sup>[2,18,22]</sup>, and sometimes this can be effective as a treatment as we will analyze later.

In terms of surgical approach, this is where most of the debate lies with respect to management. Laparotomy, laparoscopy, endoscopic removal and even chemical dissolution in the case of phytobezoars have all been proposed. The choice is made on the basis of the size and composition of the bezoar<sup>[6,23]</sup>.

The endoscopic removal of a trichobezoar has not been standardized, and a variety of techniques have been described in the literature, among which the following have been emphasized: fragmentation and removal with forceps, polypectomy snare, hydrolysis, neodymium-doped yttrium aluminum garnet laser, mechanical lithotripsy, electrohydraulic lithotripsy or extracorporeal shock wave lithotripsy<sup>[9,24-27]</sup>. The first report of the successful endoscopic removal of a trichobezoar was for one that weighed 55 g<sup>[28]</sup>. An analysis of case reports where endoscopy was used as a first approach revealed a success rate of only 5%<sup>[29]</sup>. The difficulties of this technique are due to an unsuccessful fragmentation that might be explained by the size trichobezoars can reach, as well as by the density and hardness of the formed mass<sup>[30,31]</sup>. The repeated introduction of the endoscopy to achieve removal of all the fragments can cause esophagitis, pressure ulcers and even esophageal perforation<sup>[32]</sup>. Even in cases like ours of large trichobezoars, the attempt at fragmentation may allow the bezoars to migrate beyond they pylorus and cause an intestinal obstruction. The search for satellites in the intestine is not optimal with endoscopy, and their removal is impossible. Thus the role of endoscopy has advanced more towards diagnostic management than treatment. It allows us to differentiate, in the context of a gastric mass of an unknown nature, between a trichobezoar and foreign bodies that can be extracted or fragmented *via* endoscopy<sup>[33]</sup>.

As far as surgical removal is concerned, it is important to differentiate between the classic and the laparoscopic approaches. The first report of a successful result of laparoscopy for a trichobezoar was published in 1998 regarding a 7-year-old girl<sup>[21]</sup>. To date the case reports endorsing this technique have been few, mainly in the pediatric population, limited mainly by the size and the presence of satellites in the intestine<sup>[29,30,32,34-37]</sup>. The combination of techniques has been used, implementing fragmentation laparoscopically and removal endoscopically<sup>[38]</sup>. The advantages of laparoscopy as it relates to a trichobezoar are a lower rate of postoperative complications, a reduced hospital stay, and a better cosmetic result. The disadvantages are a longer operating time, greater

complexity in the review of the intestine in search of satellites, and the risk of contaminating the abdominal cavity with hair fragments<sup>[39]</sup>.

The laparotomy has been successful in most cases: over 100 cases of successful results with this technique have been described<sup>[40]</sup>. Complications with this technique are described in 12% of the cases<sup>[40]</sup>, and these include intestinal perforation during removal of the trichobezoar<sup>[41,42]</sup>, infection of the surgical wound<sup>[43]</sup>, pneumonia, and paralytic ileum<sup>[44]</sup>.

Another interesting point to analyze in our case is the *Candida Glabrata* infection. One study reported on the cases presented for one year with a diagnosis of peritonitis due to a perforated peptic ulcer. There were 62 cases in all, of which 23 (37.09%) had peritoneal fluid cultures that tested positive for *Candida*, ten (16.12%) for isolated bacteria and the rest were negative. That analysis concluded there were no significant risk factors for developing the different species. In addition, they marked an important prognostic factor with an up to 21.7% likelihood of mortality for the case of *Candida* peritonitis, compared to the results for bacterial peritonitis and negative cultures, which were 0% and 3.4% respectively. The specific case of *Candida Glabrata* peritonitis was second in frequency (13.04%) in this series, surpassed by *Candida Albicans* peritonitis with 78.26%<sup>[45]</sup>. Other reports associate the gastric mycotic infection as a factor related to gastric perforation<sup>[46]</sup>. This point emphasizes the importance of taking a peritoneal fluid culture in patients with secondary peritonitis.

After the anti-fungal treatment, the patient in our report presented a good clinical evolution and was discharged with no associated morbidity.

## COMMENTS

### Case characteristics

Abdominal pain in a puerperal woman associated with systemic inflammatory response syndrome.

### Clinical diagnosis

Acute abdomen.

### Differential diagnosis

The principal differential diagnosis was the complications of previous cesarean section, as an uterine rupture or large bowel perforation.

### Laboratory diagnosis

Laboratory signs of systemic response.

### Imaging diagnosis

Pneumoperitoneum and free fluid suggestive of pus.

### Pathological diagnosis

Trichobezoar.

### Treatment

Anterior gastrotomy and bezoar extraction.

### Related reports

Psychiatric diseases in relation with trichobezoar.

### Term explanation

Association with *Candida Glabrata* infection.

### Experiences and lessons

The authors need a high level of diagnostic suspicion, and use the anamnesis to find trichotillomania in antecedents to supply our diagnosis.

### Peer review

The case-report is interesting and so is the complication and super infection.



## REFERENCES

- 1 **Diefenbach GJ**, Reitman D, Williamson DA. Trichotillomania: a challenge to research and practice. *Clin Psychol Rev* 2000; **20**: 289-309 [PMID: 10779896 DOI: 10.1016/S0272-7358(98)00083-X]
- 2 **Carr JR**, Sholevar EH, Baron DA. Trichotillomania and trichobezoar: a clinical practice insight with report of illustrative case. *J Am Osteopath Assoc* 2006; **106**: 647-652 [PMID: 17192451]
- 3 **Duke DC**, Keeley ML, Geffken GR, Storch EA. Trichotillomania: A current review. *Clin Psychol Rev* 2010; **30**: 181-193 [PMID: 19926375 DOI: 10.1016/j.cpr.2009.10.008]
- 4 **American Psychiatric Association**. Diagnostic and Statistical Manual of Mental Disorders, Fourth Edition, Text Revision (DSM-IV-TR). Washington, DC: American Psychiatric Association, 2000
- 5 **Vaughan ED**, Sawyers JL, Scott HW. The Rapunzel syndrome. An unusual complication of intestinal bezoar. *Surgery* 1968; **63**: 339-343 [PMID: 5638179]
- 6 **Andrus CH**, Ponsky JL. Bezoars: classification, pathophysiology, and treatment. *Am J Gastroenterol* 1988; **83**: 476-478 [PMID: 3284334]
- 7 **Barbosa AL**, Bromberg SH, Amorim FC, Gonçalves JE, Godoy AC. Obstrução intestinal por tricobezoar: Relato de caso e revisão da literatura. *Rev Bras Coloproct* 1998; **18**: 190-193. Available from: URL: [http://www.jcol.org.br/pdfs/18\\_3/07.pdf](http://www.jcol.org.br/pdfs/18_3/07.pdf)
- 8 **Koulas SG**, Zikos N, Charalampous C, Christodoulou K, Sakkas L, Katsamakakis N. Management of gastrointestinal bezoars: an analysis of 23 cases. *Int Surg* 2008; **93**: 95-98 [PMID: 18998288]
- 9 **Hall JD**, Shami VM. Rapunzel's syndrome: gastric bezoars and endoscopic management. *Gastrointest Endosc Clin N Am* 2006; **16**: 111-119 [PMID: 16546027]
- 10 **Hewitt AN**, Levine MS, Rubesin SE, Laufer I. Gastric bezoars: reassessment of clinical and radiographic findings in 19 patients. *Br J Radiol* 2009; **82**: 901-907 [PMID: 19433488 DOI: 10.1259/bjr/15256968]
- 11 **Escamilla C**, Robles-Campos R, Parrilla-Paricio P, Lujan-Mompean J, Liron-Ruiz R, Torralba-Martinez JA. Intestinal obstruction and bezoars. *J Am Coll Surg* 1994; **179**: 285-288 [PMID: 8069423]
- 12 **Stein DJ**, Grant JE, Franklin ME, Keuthen N, Lochner C, Singer HS, Woods DW. Trichotillomania (hair pulling disorder), skin picking disorder, and stereotypic movement disorder: toward DSM-V. *Depress Anxiety* 2010; **27**: 611-626 [PMID: 20533371 DOI: 10.1002/da.20700]
- 13 **Bouwer C**, Stein DJ. Trichobezoars in trichotillomania: case report and literature overview. *Psychosom Med* 1998; **60**: 658-660 [PMID: 9773774]
- 14 **Frey AS**, McKee M, King RA, Martin A. Hair apparent: Rapunzel syndrome. *Am J Psychiatry* 2005; **162**: 242-248 [PMID: 15677585]
- 15 **Salaam K**, Carr J, Grewal H, Sholevar E, Baron D. Untreated trichotillomania and trichophagia: surgical emergency in a teenage girl. *Psychosomatics* 2005; **46**: 362-366 [PMID: 16000680]
- 16 **Christenson GA**, Mackenzie TB, Mitchell JE. Characteristics of 60 adult chronic hair pullers. *Am J Psychiatry* 1991; **148**: 365-370 [PMID: 1992841]
- 17 **Christenson GA**, Crow SJ. The characterization and treatment of trichotillomania. *J Clin Psychiatry* 1996; **57** Suppl 8: 42-47; discussion 48-49 [PMID: 8698680]
- 18 **Sehgal VN**, Srivastava G. Trichotillomania +/- trichobezoar: revisited. *J Eur Acad Dermatol Venereol* 2006; **20**: 911-915 [PMID: 16922936]
- 19 **Pérez E**, Santana JR, García G, Mesa J, Hernández JR, Betancort N, Núñez V. Gastric perforation due to trichobezoar in an adult (Rapunzel syndrome). *Cir Esp* 2005; **78**: 268-270 [PMID: 16420838]
- 20 **Deslypere JP**, Praet M, Verdonk G. An unusual case of the trichobezoar: the Rapunzel syndrome. *Am J Gastroenterol* 1982; **77**: 467-470 [PMID: 7091135]
- 21 **Nirasawa Y**, Mori T, Ito Y, Tanaka H, Seki N, Atomi Y. Laparoscopic removal of a large gastric trichobezoar. *J Pediatr Surg* 1998; **33**: 663-665 [PMID: 9574777 DOI: 10.1016/S0022-3468(98)90342-6]
- 22 **Coulter R**, Antony MT, Bhuta P, Memon MA. Large gastric trichobezoar in a normal healthy woman: case report and review of pertinent literature. *South Med J* 2005; **98**: 1042-1044 [PMID: 16295823]
- 23 **Lee J**. Bezoars and foreign bodies of the stomach. *Gastrointest Endosc Clin N Am* 1996; **6**: 605-619 [PMID: 8803570]
- 24 **O'Sullivan MJ**, McGreal G, Walsh JG, Redmond HP. Trichobezoar. *J R Soc Med* 2001; **94**: 68-70 [PMID: 11234202]
- 25 **Muguruma N**, Okamura S, Okahisa T, Yasuda M, Hayashi S, Shibata H, Ito S. Electrohydraulic lithotripsy treatment for persimmon bezoars. *Endoscopy* 1998; **30**: S60 [PMID: 9693910]
- 26 **Wang YG**, Seitz U, Li ZL, Soehendra N, Qiao XA. Endoscopic management of huge bezoars. *Endoscopy* 1998; **30**: 371-374 [PMID: 9689511]
- 27 **Kuo JY**, Mo LR, Tsai CC, Chou CY, Lin RC, Chang KK. Nonoperative treatment of gastric bezoars using electrohydraulic lithotripsy. *Endoscopy* 1999; **31**: 386-388 [PMID: 10433049]
- 28 **Saeed ZA**, Ramirez FC, Hepps KS, Dixon WB. A method for the endoscopic retrieval of trichobezoars. *Gastrointest Endosc* 1993; **39**: 698-700 [PMID: 8224696 DOI: 10.1016/S0016-5107(93)70226-6]
- 29 **Pogorelić Z**, Jurić I, Zitko V, Britvić-Pavlov S, Biocić M. Unusual cause of palpable mass in upper abdomen--giant gastric trichobezoar: report of a case. *Acta Chir Belg* 2012; **112**: 160-163 [PMID: 22571081]
- 30 **Tudor EC**, Clark MC. Laparoscopic-assisted removal of gastric trichobezoar; a novel technique to reduce operative complications and time. *J Pediatr Surg* 2013; **48**: e13-e15 [PMID: 23480941 DOI: 10.1016/j.jpedsurg.2012.12.028]
- 31 **Tiago S**, Nuno M, João A, Carla V, Gonçalo M, Joana N. Trichophagia and trichobezoar: case report. *Clin Pract Epidemiol Ment Health* 2012; **8**: 43-45 [PMID: 22675398 DOI: 10.2174/1745017901208010043]
- 32 **Kanetaka K**, Azuma T, Ito S, Matsuo S, Yamaguchi S, Shirono K, Kanematsu T. Two-channel method for retrieval of gastric trichobezoar: report of a case. *J Pediatr Surg* 2003; **38**: e7 [PMID: 12596127]
- 33 **Gaia E**, Gallo M, Caronna S, Angeli A. Endoscopic diagnosis and treatment of gastric bezoars. *Gastrointest Endosc* 1998; **48**: 113-114 [PMID: 9684687]
- 34 **Cintolo J**, Telem DA, Divino CM, Chin EH, Midulla P. Laparoscopic removal of a large gastric trichobezoar in a 4-year-old girl. *JSLs* 2009; **13**: 608-611 [PMID: 20202404 DOI: 10.4293/108680809X1258999538110]
- 35 **Meyer-Rochow GY**, Grunewald B. Laparoscopic removal of a gastric trichobezoar in a pregnant woman. *Surg Laparosc Endosc Percutan Tech* 2007; **17**: 129-132 [PMID: 17450096 DOI: 10.1097/SLE.0b013e31802f9ffa]
- 36 **Hernández-Peredo-Rezk G**, Escárcega-Fujigaki P, Campillo-Ojeda ZV, Sánchez-Martínez ME, Rodríguez-Santibáñez MA, Angel-Aguilar AD, Rodríguez-Gutiérrez C. Trichobezoar can be treated laparoscopically. *J Laparoendosc Adv Surg Tech A* 2009; **19**: 111-113 [PMID: 18991522 DOI: 10.1089/lap.2008.0068]
- 37 **Levy RM**, Komanduri S. Images in clinical medicine. Trichobezoar. *N Engl J Med* 2007; **357**: e23 [PMID: 18032760 DOI: 10.1056/NEJMc067796]
- 38 **Yau KK**, Siu WT, Law BK, Cheung HY, Ha JP, Li MK. Laparoscopic approach compared with conventional open approach for bezoar-induced small-bowel obstruction. *Arch Surg* 2005; **140**: 972-975 [PMID: 16230547 DOI: 10.1001/archsurg.140.10.972]
- 39 **Memon SA**, Mandhan P, Qureshi JN, Shairani AJ. Recur-



- rent Rapunzel syndrome - a case report. *Med Sci Monit* 2003; **9**: CS92-CS94 [PMID: 12960933]
- 40 **Al-Janabi IS**, Al-Sharbaty MA, Al-Sharbaty MM, Al-Sharifi LA, Ouhtit A. Unusual trichobezoar of the stomach and the intestine: a case report. *J Med Case Rep* 2014; **8**: 79 [PMID: 24580892 DOI: 10.1186/1752-1947-8-79]
- 41 **Perera BJ**, Romanie Rodrigo BK, de Silva TU, Ragunathan IR. A case of trichobezoar. *Ceylon Med J* 2005; **50**: 168-169 [PMID: 16538914]
- 42 **Larsson LT**, Nivenius K, Wettrell G. Trichobezoar in a child with concomitant coeliac disease: a case report. *Acta Paediatr* 2004; **93**: 278-280 [PMID: 15046290 DOI: 10.1111/j.1651-2227.2004.tb00722.x]
- 43 **Zent RM**, Cothren CC, Moore EE. Gastric trichobezoar and Rapunzel syndrome. *J Am Coll Surg* 2004; **199**: 990 [PMID: 15555984 DOI: 10.1016/j.jamcollsurg.2004.03.030]
- 44 **Varma A**, Sudhindra BK. Trichobezoar with small bowel obstruction. *Indian J Pediatr* 1998; **65**: 761-763 [PMID: 10773935 DOI: 10.1007/BF02731062]
- 45 **Lee SC**, Fung CP, Chen HY, Li CT, Jwo SC, Hung YB, See LC, Liao HC, Loke SS, Wang FL, Lee JC. Candida peritonitis due to peptic ulcer perforation: incidence rate, risk factors, prognosis and susceptibility to fluconazole and amphotericin B. *Diagn Microbiol Infect Dis* 2002; **44**: 23-27 [PMID: 12376027]
- 46 **Gupta N**. A rare cause of gastric perforation-Candida infection: a case report and review of the literature. *J Clin Diagn Res* 2012; **6**: 1564-1565 [PMID: 23285460 DOI: 10.7860/JCDR/2012/4632.2563]

**P-Reviewer:** Coskun A, Zamir DL **S-Editor:** Ji FF

**L-Editor:** A **E-Editor:** Lu YJ



## Rare entity: Ectopic liver tissue in the wall of the gallbladder - A case report

Yusuf Arslan, Fatih Altintoprak, Kursat R Serin, Taner Kivilcim, Omer Yalkin, Orhan V Ozkan, Fehmi Celebi

Yusuf Arslan, Fatih Altintoprak, Taner Kivilcim, Omer Yalkin, Orhan V Ozkan, Fehmi Celebi, Department of General Surgery, Faculty of Medicine, Sakarya University, 54100 Sakarya, Turkey  
Kursat R Serin, Department of General Surgery, LIV Hospital, 34340 Istanbul, Turkey

Author contributions: Arslan Y, Altintoprak F, Kivilcim T and Yalkin O designed the report; Arslan Y, Serin KR and Ozkan OV collected the patient's clinical data; Arslan Y, Altintoprak F and Ozkan OV analyzed the data and wrote the paper.

Correspondence to: Orhan V Ozkan, Associate Professor of General Surgery, Department of General Surgery, Faculty of Medicine, Sakarya University, Adnan Menderes Caddesi, Saglik Sokak No:193, 54100 Sakarya, Turkey. [veliorhan@hotmail.com](mailto:veliorhan@hotmail.com)  
Telephone: +90-264-2552106 Fax: +90-264-2552106

Received: May 2, 2014 Revised: August 30, 2014

Accepted: September 23, 2014

Published online: December 16, 2014

bladder, gastrohepatic ligament, adrenal glands, and esophagus. It is usually clinically silent and found incidentally. Ectopic hepatic tissue carries an increased risk of malignant degeneration to hepatocellular carcinoma. It should be discovered and removed by the surgeon to prevent a higher risk of complications and malignant transformation.

Arslan Y, Altintoprak F, Serin KR, Kivilcim T, Yalkin O, Ozkan OV, Celebi F. Rare entity: Ectopic liver tissue in the wall of the gallbladder - A case report. *World J Clin Cases* 2014; 2(12): 924-926 Available from: URL: <http://www.wjgnet.com/2307-8960/full/v2/i12/924.htm> DOI: <http://dx.doi.org/10.12998/wjcc.v2.i12.924>

### Abstract

Ectopic liver tissue (ELT) is a rare condition, which is usually not diagnosed preoperatively, but coincidentally during abdominal surgery. While the location of ELT can vary, it is usually localized on the gallbladder wall or in close proximity. ELT is associated with various complications, a major complication being extrahepatic hepatocellular carcinoma. A 59-year-old female underwent elective surgery for chronic cholecystitis with stones. During laparoscopic exploration, a 2-cm-diameter ELT was detected in the anterior gallbladder wall and a laparoscopic cholecystectomy was performed. The case is presented due to the rare nature of ELT and as a reminder of ELT-related complications.

© 2014 Baishideng Publishing Group Inc. All rights reserved.

**Key words:** Ectopic liver tissue; Laparoscopic cholecystectomy; Hepatocellular carcinoma

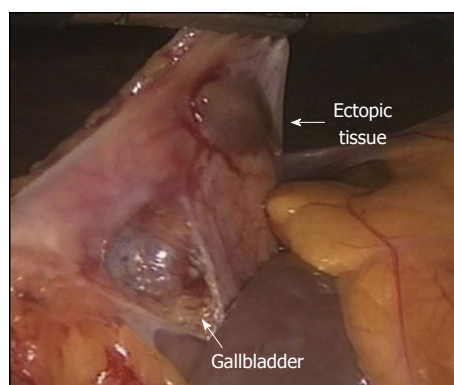
**Core tip:** Ectopic hepatic tissue is a rare condition and it has been reported in several sites, such as the gall-

### INTRODUCTION

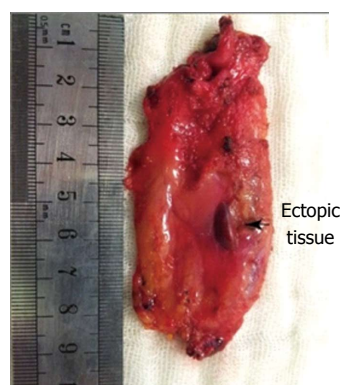Congenital localization anomalies of the liver are rare, and can be classified into two major subgroups: those that are connected to the main liver tissue mechanically, and those that are not<sup>[1]</sup>. Ectopic liver tissue (ELT) is a subtype that is not connected to the main liver tissue, and it can be present in any intra-abdominal or supradia-phragmatic location. The most frequent intra-abdominal location is the gallbladder, and ELT is generally identified by recognizing extra tissue on the gallbladder wall that is of the same color as liver tissue<sup>[2]</sup>.

First defined in 1922, ELT can vary in size, from microscopic scales to 3 cm in diameter. Despite its small size, since it is liver tissue histopathologically, it is prone to parenchymal diseases of the liver, including carcinoma development. Due to its small size, ELT is generally not noticed during routine radiological examinations; however, when noticed, it might be necessary to differentiate it from various conditions, including gallbladder cancer<sup>[3]</sup>.

Here, we present a case of ELT on the gallbladder wall, which was detected during surgery, and review the relevant literature.



**Figure 1** Laparoscopic exploration: A 2 cm × 1 cm tissue mass located at the gallbladder wall, which had the same color as the liver.



**Figure 2** Laparoscopic cholecystectomy material with ectopic tissue.

## CASE REPORT

A 59-year-old female presented to the general surgery clinic with occasional epigastric pain and dyspeptic complaints for 2 mo. She had no history of systemic disease, previous abdominal surgery, or regular medication use, and her physical examination and laboratory tests were normal. Abdominal ultrasonography (USG) revealed a large number of millimeter-size stones in the gallbladder lumen, and she was scheduled to undergo an elective cholecystectomy. Laparoscopic exploration revealed a 2 cm × 1 cm tissue mass located in the fundus of the anterior gallbladder wall, which had the same color as the liver (Figure 1). The patient was diagnosed as having ELT on the gallbladder wall, and underwent a laparoscopic cholecystectomy (Figure 2). She did not have any postoperative problems, and was discharged on the second day. Following histopathological examination, the tissue attached to the gallbladder wall was confirmed to be ELT. The specimen examination showed that it was a truly ectopic liver and was not connected to the mother liver. The patient has been followed without any problems for 5 mo.

## DISCUSSION

Ectopic liver tissue is a rare condition that is usually detected coincidentally during a post-mortem examination or abdominal surgery. According to the literature, the incidence of ELT at laparoscopy or laparotomy is 0.24%-0.47%<sup>[4]</sup>. In a 5500-case autopsy series, the incidence of ELT was 0.05%<sup>[5]</sup>, while its incidence was 0.47% in a 1060-case laparoscopic surgery series<sup>[6]</sup>. During the past 5 years, 5000 patients underwent abdominal surgery at our clinic for various reasons and ELT was observed in a single patient (0.02%), the case presented here.

The most frequent localization of ELT is the gallbladder, although other sites have been reported, including the adrenal glands, pancreas, spleen, falciform ligament, pylorus, umbilicus, retroperitoneum, thorax (intrapleural/extrapleural), and pericardium<sup>[2]</sup>. ELT is generally asymptomatic, but it can present with recurrent abdominal pain due to torsion, hemorrhagic necrosis, or rupture, or with pressure symptoms due to mass formation as a conse-

quence of malignant degeneration<sup>[7]</sup>. We believe that our patient's non-specific complaints were due to cholecystopathy, and not associated with the ELT, because there was not pathological appearance of ELT such as torsion, necrosis.

Various theories have been presented to explain the development of ELT at different sites, and ELT can be seen together with biliary atresia, caudate lobe agenesis, omphalocele, and certain congenital cardiac anomalies<sup>[8]</sup>. We did not observe any comorbid anomalies in our case. It is a truly ectopic liver and is not connected to the mother liver. The ectopic liver tissue presents resulting from liver tissue migration to fundus of gallbladder during embryogenesis.

Ectopic liver tissue is not noticed during radiological examinations, as it is generally asymptomatic, rare, small in size, or the examiner is not aware of this entity. The diagnosis of ELT should be considered when a soft-tissue mass is detected on the gallbladder wall using USG or computed tomography. Color Doppler USG and angiography can show the blood vessel feeding the liver. However, the incidence of radiological detection is low, and the number of reported cases for which a preoperative diagnosis has been made is very limited<sup>[2,3]</sup>. When noted radiologically, the exact diagnosis is made by showing the presence of hepatic tissue in a percutaneous biopsy; however, this is not a suggested method for diagnosis, due to the bleeding risk and malignant degeneration<sup>[4]</sup>.

The normal progression of ELT is not known. Since it is liver tissue, it is affected by the same risk factors affecting the liver, and lipid infiltration, cirrhotic changes, chronic active hepatitis, hemosiderosis, metastatic tumors, and hepatocellular carcinoma (HCC) have been reported to develop in ELT<sup>[8]</sup>. The development of HCC is the most important condition, and involves a higher risk of neoplastic transformation that is independent of the main liver tissue. The lack of complete functional structure for neoplastic transformation in small ELT, absence of vascular and ductal systems, and possible metabolic insufficiency are believed to contribute to the carcinogenetic process<sup>[4,9]</sup>.

In conclusion, ELT is a rare condition, and it is difficult to make a radiological diagnosis. When seen during

a surgical intervention, it should be excised because of the possibility of developing a malignancy.

## COMMENTS

### Case characteristics

Patient presented to the general surgery clinic with occasional epigastric pain and dyspeptic complaints for 2 mo.

### Clinical diagnosis

Patient had no history of systemic disease, previous abdominal surgery, or regular medication use, and her physical examination was normal.

### Laboratory diagnosis

Laboratory tests were normal.

### Imaging diagnosis

Abdominal ultrasonography revealed a large number of millimeter-size stones in the gallbladder lumen.

### Pathological diagnosis

Following histopathological examination, the tissue attached to the gallbladder wall was confirmed to be liver tissue.

### Treatment

The patient was underwent a laparoscopic cholecystectomy.

### Related reports

Laparoscopic exploration revealed a 2 cm × 1 cm tissue mass located in the fundus of the anterior gallbladder wall.

### Experiences and lessons

Ectopic liver tissue is a rare condition, and it is difficult to make a radiological diagnosis. When seen during a surgical intervention, it should be excised because of the possibility of developing a malignancy.

### Peer review

This paper was concise and well-written.

## REFERENCES

- 1 **Collan Y**, Hakkiluoto A, Hästbacka J. Ectopic liver. *Ann Chir Gynaecol* 1978; **67**: 27-29 [PMID: 637502]
- 2 **Lundy J**, Johnson E, Edwards K, Rivera D. Laparoscopic management of gallbladder-associated ectopic liver. *JSLs* 2005; **9**: 485-487 [PMID: 16381374]
- 3 **Hamdani SD**, Baron RL. Ectopic liver simulating a mass in the gallbladder wall: imaging findings. *AJR Am J Roentgenol* 1994; **162**: 647-648 [PMID: 8109514]
- 4 **Martinez CA**, de Resende HC, Rodrigues MR, Sato DT, Brunialti CV, Palma RT. Gallbladder-associated ectopic liver: A rare finding during a laparoscopic cholecystectomy. *Int J Surg Case Rep* 2013; **4**: 312-315 [PMID: 23399516 DOI: 10.1016/j.ijscr.2013.01.006]
- 5 **Eisnerth P**. Beiträge zur Kenntnis der Nebenlebern. *Virchows Arch A Pathol Anat Histopathol* 1940; **307**: 307-313
- 6 **Watanabe M**, Matsura T, Takatori Y, Ueki K, Kobatake T, Hidaka M, Hirakawa H, Fukukimoto S, Shimada Y. Five cases of ectopic liver and a case of accessory lobe of the liver. *Endoscopy* 1989; **21**: 39-42 [PMID: 2917536 DOI: 10.1055/s-2007-1012892]
- 7 **Nagar S**, Koffron A, Raofi V. A Case of Hemorrhagic Necrosis of Ectopic Liver Tissue within the Gallbladder Wall. *HPB Surg* 2011; **2011**: 389381 [PMID: 21860541 DOI: 10.1155/2011/389381]
- 8 **Griniatsos J**, Riaz AA, Isla AM. Two cases of ectopic liver attached to the gallbladder wall. *HPB (Oxford)* 2002; **4**: 191-194 [PMID: 18332954 DOI: 10.1080/13651820260503873]
- 9 **Beltran MA**, Barria C, Pujado B, Barrera R, Mendez P, Pozo C. Hepatic heterotopic tissue on the gallbladder wall: an incidental finding with pathological potential. *J Gastrointest Liver Dis* 2007; **16**: 347-349 [PMID: 17925935]

**P- Reviewer:** Lau WY, Murata A, Tagaya N **S- Editor:** Ji FF  
**L- Editor:** A **E- Editor:** Wu HL





## Rare multiple fistulas with large saccular aneurysms originating from left anterior descending artery and left main coronary artery

Ender Emre, Mujdat Aktas, Tayfun Sahin, Ertan Ural, Dilek Ural

Ender Emre, Mujdat Aktas, Tayfun Sahin, Ertan Ural, Dilek Ural, Department of Cardiology, Faculty of Medicine, Kocaeli University, Kocaeli 41060, Turkey

Author contributions: All authors contributed to this paper.

Correspondence to: Ender Emre, MD, Department of Cardiology, Faculty of Medicine, Kocaeli University, Cedit Mh., Kocaeli 41300, Turkey. [dr.enderemre@hotmail.com](mailto:dr.enderemre@hotmail.com)

Telephone: +90-26-23037370 Fax: +90-26-23038738

Received: June 24, 2014 Revised: September 18, 2014

Accepted: October 1, 2014

Published online: December 16, 2014

### Abstract

A 49-year-old female patient consulted us for a cardiac evaluation before undergoing colon adenocarcinoma surgery. Three years prior, the patient underwent coronary angiography for dyspnea. The coronary angiography examination revealed a fistula originating from the left anterior descending artery and left main coronary artery, which had soft aneurysmal sacs and most likely drained into the pulmonary artery. Parasternal short axis echocardiography revealed a color flow that could be related to the fistula, but the other echocardiographic findings were normal. The patient did not accept the proposed examination and invasive treatment.

© 2014 Baishideng Publishing Group Inc. All rights reserved.

**Key words:** Left main coronary artery; Left anterior descending; Fistula; Swinging aneurysmal sacs

**Core tip:** (1) Acquire technical and surgical skills; (2) Learn the coronary anatomy and its variations; and (3) Learn the methodology of for treating coronary anomalies.

Emre E, Aktas M, Sahin T, Ural E, Ural D. Rare multiple fistu-

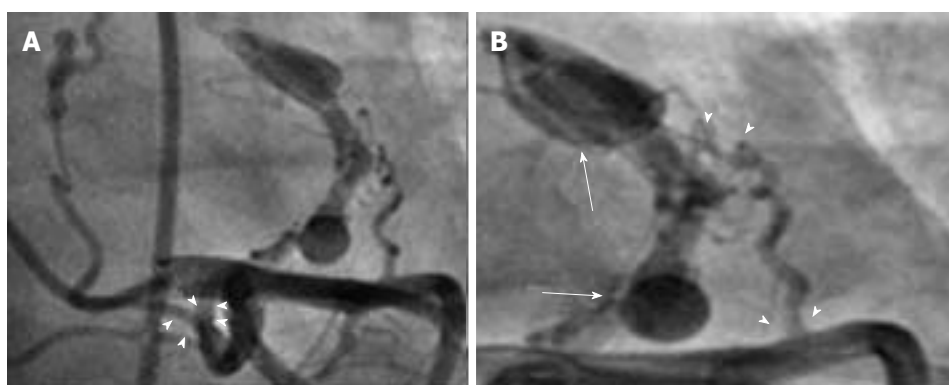las with large saccular aneurysms originating from left anterior descending artery and left main coronary artery. *World J Clin Cases* 2014; 2(12): 927-929 Available from: URL: <http://www.wjgnet.com/2307-8960/full/v2/i12/927.htm> DOI: <http://dx.doi.org/10.12998/wjcc.v2.i12.927>

### INTRODUCTION

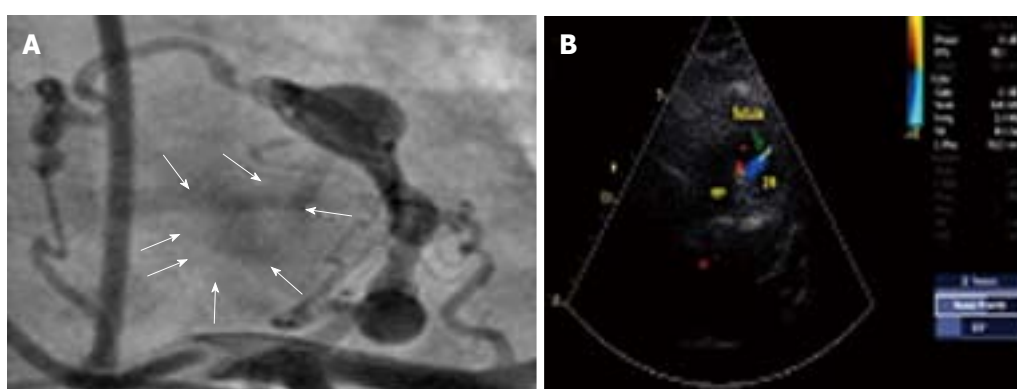
Coronary artery fistulas are rare anomalies that open into the heart chambers, large vessels and other structures by bypassing the myocardial capillary network. Coronary artery fistula is detected in 1.21%-5.60% of all patients undergoing coronary angiography<sup>[1]</sup>. Left main coronary artery fistula is extremely rare<sup>[2]</sup>. Not all coronary-pulmonary artery fistulas are hemodynamically significant, however some may cause myocardial ischemia, myocardial infarction, congestive heart failure, pulmonary arterial hypertension, aneurysmal fistula rupture and sudden death<sup>[3]</sup>. Here we present a case with an angiographically documented coronary artery fistula that originating from the left main coronary artery (LMCA) and dividing into two branches. In addition, another fistula that originated from the left anterior descending artery (LAD) combined with the LMCA fistula and created a new line of fistula, with large saccular coronary sacs, that drained into the pulmonary artery. This type of coronary artery fistula is most rares.

### CASE REPORT

A 49-year-old female patient consulted us for a cardiac evaluation before undergoing colon adenocarcinoma surgery. Three years prior, the patient underwent coronary angiography for dyspnea. The coronary angiography examination revealed, a fistula originating from the LMCA which could be interpreted as draining into the pulmonary artery. Upon examining the coronary angiography in detail, in addition to the LMCA fistula, another fistula



**Figure 1** A: The fistula emerging from the left main coronary artery is divided into two branches after the fold (arrowhead); B: An angiographic view showing the combination of a small fistula emerging from left anterior descending artery, the fistula from left main coronary artery (arrowhead) and large sacular sacs on the fistula line (arrow).



**Figure 2** The passage of the contrast agent formed by the fistula (A), parasternal short axis echocardiography revealed the color flow associated with the fistula (B).

emerged from the LAD combined with the LMCA fistula and there was an aneurysmal sac swinging on fistula line (Figure 1). It was thought that the fistula was draining into the pulmonary artery (Figure 2A). Parasternal short axis echocardiography revealed a flow that was most likely caused by the fistula (Figure 2B). There were no regional wall motion abnormalities or systolic dysfunction. Because of excessive fatigue, the stress test was terminated at the end of step 3. The target heart rate and blood pressure were reached and there were no arrhythmia or ST-T wave changes. After further investigations and evaluations were performed, the patient was informed about the possibility of a cardiac operation. The patient did not accept the treatment proposals and further investigation was not planned. The medical risks were explained to the patient and outpatient follow-up was scheduled with full oral medical treatment.

## DISCUSSION

Coronary artery fistulas are rare anomalies that open into the heart chambers, large vessels and other structures by bypassing the myocardial capillary network<sup>[1]</sup>. The first case of coronary arteriovenous fistula was reported by Krause<sup>[4]</sup> in 1865. Coronary artery fistula is detected in 1.21%-5.60% of all patients undergoing coronary an-

giography<sup>[5]</sup>. A fistula from the coronary arteries to the pulmonary artery is observed in 0.1%-0.2% of coronary angiographies<sup>[6]</sup>. Atotal of 92% of coronary artery fistulas drain into the right heart chambers and 8% drains into the left heart chambers. The origins of the fistulae are vary, as follows: right coronary artery (50%-60%), left anterior descending artery (25%-42%), both coronary arteries (5%), circumflex artery (18%), diagonal artery (1.9%), marginal arteries (0.7%). Left main coronary artery fistula is extremely rare<sup>[2]</sup>. Although coronary artery fistulas are often congenital, they may occur after chest trauma, angiography and bypass surgery<sup>[7]</sup>.

Coronary artery anomalies often affect hemodynamic parameters. Not all coronary-pulmonary artery fistulas are hemodynamically significant, However some may cause myocardial ischemia, myocardial infarction, congestive heart failure, pulmonary arterial hypertension, aneurysmal fistula rupture and sudden death<sup>[3]</sup>.

Although two-dimensional echocardiography (transesophageal echocardiography complements two-dimensional echocardiography) is valuable in revealing the fistula, it is operator dependent and because it does not have a good acoustic window, determining the fistula location may be insufficient<sup>[8]</sup>.

Until recently, using conventional coronary angiography to detect coronary anomalies was the preferred diag-

nostic method. However invasiveness, acquisition plane images, the lack of angiographic projection angle and concerns about the contrast load limit this method<sup>[9]</sup>. Multislice computed tomography (MSCT) can better reveal aneurysms, occlusion; as well as the direction of the fistula and its relationship with the cardiovascular structures along the fistula compared with coronary angiography<sup>[8]</sup>. MSCT imaging is the recommended technique for the diagnosis and follow up of coronary artery anomalies<sup>[10]</sup>.

The treatment of asymptomatic patients without significant shunts is still a matter of debate<sup>[11]</sup>. The presence of ischemic symptoms or a positive stress test, aneurysmal dilatation with or without mural thrombus and overload of heart chambers due to excessive blood flow are the indications for fistula closure<sup>[12]</sup>. In the literature, similar early efficiency, mortality and morbidity rates are observed for both the surgical and transcatheter approaches<sup>[13]</sup>.

In this case, although the fistula did not affect the hemodynamic parameters and the exercise test for ischemia was negative and because there was a large thrombosed aneurysm sac on the fistula line, transcatheter closure of the fistula was considered. The patient did not accept any attempt at surgical treatment, thus, further examination and treatment could not be performed. The patient was discharged with full oral medical treatment and recommendations. The patient has the risk of sudden death due to aneurysmal sac rupture and thromboembolic event due to aneurysm sac thrombus. Because of progression in the shunt system, a reduction in functional capacity and heart failure may develop. Coronary artery fistula is a possibility because of the degree of shunt or the patient's symptoms; in addition, aneurysmal sacs and thrombus in the fistula line are possible<sup>[5,12]</sup>.

## COMMENTS

### Case characteristics

The main symptom of the patient was exertional dyspnea.

### Differential diagnosis

The authors took into consideration the diseases, comorbidities and patient's age which causes exertional dyspnea (e.g., coronary artery disease, pulmonary diseases, structural heart diseases, endocrine disorders).

### Laboratory diagnosis

The authors made routine laboratory tests including BNP, pro-BNP, serum creatinine, urea, electrolytes, aspartate aminotransferase, alanine aminotransferase, complete blood count.

### Imaging diagnosis

Color doppler echocardiography and coronary angiography.

### Treatment

Transcatheter and surgical closure; Heart failure treatment; Nitrates, Acetylsalicylic acid, angiotensin converting enzyme inhibitor.

### Term explanation

**Coronary artery fistula:** a sizable communication between a coronary artery

and a chamber of the heart (coronary-cameral fistula) or any segment of the systemic or pulmonary circulation (coronary arteriovenous fistula).

### Experiences and lessons

The authors have learned how to diagnose a coronary fistula, manage its complications and treatment and searched the literature about its frequency and treatment modalities.

### Peer review

Interesting case report of a rare congenital coronary artery anomaly. This case represents the dilemmas of diagnosis, treatment and follow up of this rare cases.

## REFERENCES

- 1 **Vavuranakis M**, Bush CA, Boudoulas H. Coronary artery fistulas in adults: incidence, angiographic characteristics, natural history. *Cathet Cardiovasc Diagn* 1995; **35**: 116-120 [PMID: 7656302 DOI: 10.1002/ccd.1810350207]
- 2 **Chowdhury UK**, Rizhvi A, Sheil A, Jagia P, Mittal CM, Govindappa RM, Malhotra P. Successful surgical correction of a patient with congenital coronary arteriovenous fistula between left main coronary artery and right superior cavo-atrial junction. *Hellenic J Cardiol* 2009; **50**: 73-78 [PMID: 19196625]
- 3 **Levin DC**, Fellows KE, Abrams HL. Hemodynamically significant primary anomalies of the coronary arteries. Angiographic aspects. *Circulation* 1978; **58**: 25-34 [PMID: 348342 DOI: 10.1161/01.CIR.58.1.25]
- 4 **Angelini P**. Normal and anomalous coronary arteries: definitions and classification. *Am Heart J* 1989; **117**: 418-434 [PMID: 2644796 DOI: 10.1016/0002-8703(89)90789-8]
- 5 **Rigatelli G**, Docali G, Rossi P, Bovolon D, Rossi D, Bandello A, Lonardi G, Rigatelli G. Congenital coronary artery anomalies angiographic classification revisited. *Int J Cardiovasc Imaging* 2003; **19**: 361-366 [PMID: 14609183]
- 6 **Ata Y**, Turk T, Bicer M, Yalcin M, Ata F, Yavuz S. Coronary arteriovenous fistulas in the adults: natural history and management strategies. *J Cardiothorac Surg* 2009; **4**: 62 [PMID: 19891792 DOI: 10.1186/1749-8090-4-62]
- 7 **Hsieh KS**, Huang TC, Lee CL. Coronary artery fistulas in neonates, infants, and children: clinical findings and outcome. *Pediatr Cardiol* 2002; **23**: 415-419 [PMID: 12170358]
- 8 **Jagia P**, Goswami KC, Sharma S, Gulati GS. 16-MDCT in the evaluation of coronary cameral fistula. *AJR Am J Roentgenol* 2006; **187**: W227-W228 [PMID: 16861516]
- 9 **Chan MS**, Chan IY, Fung KH, Lee G, Tsui KL, Leung TC. Demonstration of complex coronary-pulmonary artery fistula by MDCT and correlation with coronary angiography. *AJR Am J Roentgenol* 2005; **184**: S28-S32 [PMID: 15728013]
- 10 **Utsunomiya D**, Nishi haru T, Urata J, Ino M, Nakao K, Awai K, Yamashita Y. Coronary arterial malformation depicted at multi-slice CT angiography. *Int J Cardiovasc Imaging* 2006; **22**: 547-551 [PMID: 16502020 DOI: 10.1007/s10554-005-9072-5]
- 11 **Hong GJ**, Lin CY, Lee CY, Loh SH, Yang HS, Liu KY, Tsai YT, Tsai CS. Congenital coronary artery fistulas: clinical considerations and surgical treatment. *ANZ J Surg* 2004; **74**: 350-355 [PMID: 15144256 DOI: 10.1111/j.1445-1433.2004.02980.x]
- 12 **Angelini P**. Questions on coronary fistulae and microfistulae. *Tex Heart Inst J* 2005; **32**: 53-55 [PMID: 15902823]
- 13 **Armsby LR**, Keane JF, Sherwood MC, Forbess JM, Perry SB, Lock JE. Management of coronary artery fistulae. Patient selection and results of transcatheter closure. *J Am Coll Cardiol* 2002; **39**: 1026-1032 [PMID: 11897446 DOI: 10.1016/S0735-1097(02)01742-4]

**P- Reviewer:** Cademartiri F, Castillo R, Celik T, Peteiro J, Vijayvergiya R **S- Editor:** Ji FF **L- Editor:** A **E- Editor:** Wu HL



## Case of cannabinoid hyperemesis syndrome with long-term follow-up

Jae Myung Cha, Richard A Kozarek, Otto S Lin

Jae Myung Cha, Gastroenterology Division, Department of Internal Medicine, Kyung Hee University Hospital at Gang Dong, Kyung Hee University School of Medicine, Seoul 134-727, South Korea

Richard A Kozarek, Otto S Lin, Digestive Disease Institute, Virginia Mason Medical Center, Seattle, WA 98101, United States

Author contributions: Cha JM designed the case report and provided discussion of the clinical implication; Cha JM, Kozarek RA and Lin OS contributed to the writing of the manuscript; all authors approved the final version to be published.

Correspondence to: Otto S Lin, MD, PhD, Digestive Disease Institute, Virginia Mason Medical Center, C3-Gas, 1100 Ninth Avenue, Seattle, WA 98101, United States. [otto.lin@vmmc.org](mailto:otto.lin@vmmc.org)  
Telephone: +1-425-6257373

Received: May 20, 2014 Revised: July 24, 2014

Accepted: September 23, 2014

Published online: December 16, 2014

**Key words:** Cannabinoids; Hyperemesis; Prognosis; Abdominal pain; Adverse drug effect

**Core tip:** Cannabinoid hyperemesis syndrome (CHS) can be diagnosed with characteristic clinical features, including long-term cannabis use, severe cyclical abdominal pain, nausea and vomiting, and temporary relief of symptoms with hot showers or baths. Excellent long-term prognosis of CHS can be achieved when abstinence from cannabinoid is maintained. Physicians should have a high index of suspicion in patients with unexplained chronic abdominal pain and vomiting.

Cha JM, Kozarek RA, Lin OS. Case of cannabinoid hyperemesis syndrome with long-term follow-up. *World J Clin Cases* 2014; 2(12): 930-933 Available from: URL: <http://www.wjgnet.com/2307-8960/full/v2/i12/930.htm> DOI: <http://dx.doi.org/10.12998/wjcc.v2.i12.930>

### Abstract

Long-term cannabis use may be associated with attacks of severe nausea and vomiting, and a characteristic learned behavior of compulsive hot bathing, termed cannabinoid hyperemesis syndrome (CHS). Long-term follow-up and prognosis of CHS have not been reported previously. A 44-year-old Caucasian man with a long history of addiction to marijuana presented with chronic abdominal pain complicated by attacks of uncontrollable vomiting for 16 years. He had a compulsion to take scalding hot showers, as many as 15 times a day, to relieve his symptoms. All previous therapies had been ineffective. However, abstinence from marijuana led to rapid and complete resolution of all symptoms and his compulsive hot showering behavior. He has been followed for nine years, and is still doing well without recurrence of symptoms. Physicians should have a high index of suspicion for this under-recognized condition, as excellent long-term prognosis of CHS can be achieved when abstinence is maintained.

© 2014 Baishideng Publishing Group Inc. All rights reserved.

### INTRODUCTION

According to the World Health Organization, drug abuse remains prevalent around the globe, and about 27 million individuals worldwide are addicts<sup>[1]</sup>. Although legal recreational drugs, such as tobacco and alcohol, boast higher rates of consumption, cannabis is the most commonly used illegal recreational drug in the world<sup>[2,3]</sup>. In some patients, long-term cannabis use is associated with severe episodes of nausea and vomiting, and a characteristic learned behavior of compulsive hot bathing. So-called cannabinoid hyperemesis syndrome (CHS) was first described in 2004 by Allen *et al*<sup>[4]</sup> and its features were confirmed by several other subsequent reports<sup>[5,6]</sup>. This condition may be underdiagnosed because of relatively recent recognition and lack of awareness. Physicians should be vigilant for this unique cluster of symptoms to avoid misdiagnosis even after a protracted, invasive and costly workup. Long-term follow-up and prognosis of



CHS has not been previously reported, therefore we now present a case of CHS with follow-up of nine years.

## CASE REPORT

A 44-year-old Caucasian man with a long history of marijuana use presented to our clinic with chronic episodic abdominal pain complicated by attacks of uncontrollable vomiting for the past 16 years. His abdominal pain centered in the epigastrium or periumbilical region, occurred abruptly without provocation, was often aggravated by eating in the morning, and lasted anywhere from three hours to two days. Because of his abdominal pain, his weight fluctuated between 50–68 kg. In recent years, all his symptoms had increased in intensity and frequency. He had a compulsion to take scalding hot showers, as many as 15 times a day, to relieve his symptoms. When he ran out of hot water at home, he would drive to his mother's house, his sister's house, or visit his neighbors, even in the middle of night. Four years prior to his presentation to us, he had been hospitalized with second degree burns on his back because of the showers. In the last few years, he had undergone a massive workup from five previous gastroenterologists, and had visited the emergency room more than 20 times. He denied tobacco, alcohol or illegal drug use, with the exception of regular marijuana use for the past 20 years, consuming at least 4–8 marijuana doses ("joints") per day. He had no specific family history, except for Crohn's disease in a cousin.

His previous gastrointestinal workup had been extensive, including numerous abdominal and pelvic computerized tomographs (CTs), at least two small bowel follow-through studies, multiple abdominal ultrasounds, and a barium swallow and head CT. All were negative. Twenty-four hour urine porphyrin levels were normal and urinalysis did not show occult blood. Three years ago, he underwent upper endoscopy and colonoscopy, which were also unremarkable. In the past, treatment attempts had been made with psychotropic and neuromodulatory medications (including amitriptyline, paroxetine hydrochloride, sertraline and tegaserod), dietary manipulation, and alternative medical therapies. However, all of these efforts had been ineffective. This condition adversely affected all aspects of his life, including his relationship with family, friends and peers, making him unemployable. His workup was estimated to have cost tens of thousands of dollars.

He was thin with a weight of 50 kg, and his physical examination was otherwise unremarkable. His laboratory and radiological tests were within normal limits. Blood tests showed no abnormalities, including a liver functional panel, amylase and lipase. Stool occult blood tests were negative. Repeat abdominal ultrasound and abdomen and pelvic CT were normal. A repeat small bowel follow-through and capsule endoscopy were performed to exclude small bowel Crohn's disease, as he had a history of unexplained perirectal fistulae as well as a distant relative with Crohn's disease. The small bowel follow-through was negative, but multiple small ulcerations

scattered throughout the small intestine were noted on capsule endoscopy. However, the mucosa did not appear to be inflamed, and there were no strictures, masses, or signs of bleeding, therefore the small ulcers were considered an incidental finding. The gastric emptying time for the capsule was only three minutes. A urine toxicology screen was done to rule out other recreational drugs, and was negative.

He was asked to stop marijuana use because of the concern for CHS. Abstinence led to a dramatic improvement within one week, with complete resolution of all symptoms and compulsive hot showering behaviors. Since then, he has gained 20 kg, completed a college degree, found employment, gotten married and started a family. We have had 9 years of follow-up so far, and he is still doing well without recurrence of symptoms. He speaks at educational events on the impact of marijuana on his life.

## DISCUSSION

Large, population-based surveys suggest that illicit drug use is relatively common in the population, with initial use typically starting in mid to late adolescence: cannabinoids are the most commonly used illegal substances<sup>[7,8]</sup>. Cannabinoids have also been used for the treatment of nausea, vomiting, anorexia and anxiety<sup>[5]</sup>. Its mechanism of action for inhibiting nausea and vomiting is not precisely known, but is probably related to stimulation of cannabinoid receptors in the brain. Given the nationwide increase in cannabinoid use for recreational and medical reasons, adverse drug effects associated with cannabinoid have become more prominent.

Chronic use of cannabinoids in some individuals can paradoxically cause severe episodic abdominal pain, nausea and vomiting<sup>[4]</sup>. Recently, Simonetto proposed clinical criteria for CHS<sup>[6]</sup>. Major diagnostic features include long-term cannabis use, severe cyclical abdominal pain, nausea and vomiting, resolution with cannabis cessation, and temporary relief of symptoms with hot showers or baths. The patient in our case report demonstrated all these features; in particular, he indulged in compulsive hot bathing behavior during acute attacks, a phenomenon prominently seen in almost all prior reports in the literature<sup>[9–14]</sup>. Supportive diagnostic features include age younger than 50 years, weight loss of greater than 5 kg, morning predominance of symptoms, normal bowel habits and negative findings on diagnostic testing. Our case also showed all the secondary features, with his social and work life severely affected by CHS. In the past, long-term follow-up and prognosis for this condition have not been reported because CHS has only recently been recognized and the recidivism rate is high in patients who are not determined to get better. It should be noted that some patients are psychologically addicted to marijuana and exhibit considerable denial when confronted with the possibility that marijuana, which has purported anti-nausea properties, may be the cause of their chronic nausea and abdominal pain symptoms. Patients who are not determined to get

better may have difficulty maintaining abstinence from marijuana for long periods of time. Our case demonstrates that prolonged abstinence leads to sustainable improvements in all symptoms over a period as long as nine years.

The mechanism of CHS is still unknown. Most cannabinoids act through two receptors, CB1 and CB2, which reduce anterior pituitary hormone and increase corticotrophin release<sup>[15]</sup>. Disturbances of the hypothalamic-pituitary-adrenal axis and the presence of autonomic instability have been proposed as possible mechanisms of CHS<sup>[6]</sup>. The central effect of long-term cannabis use is thought to be similar to that seen in cyclic vomiting syndrome, which is characterized by the increased secretion and activation of corticotrophin-releasing factor<sup>[16]</sup>. In addition, relief of symptoms with compulsive hot bathing might be due to impairment of physiologic thermoregulatory mechanisms by cannabinoids<sup>[6]</sup>, as CB1 receptors of the preoptic area have been reported to be involved in the hypothermic effects of cannabinoids<sup>[17,18]</sup>. As peripheral CB1 receptors in the gastrointestinal tract have also been implicated in slowing gastrointestinal transit<sup>[19]</sup>, it is suggested that slowed gastric emptying might be responsible for the severe vomiting seen in CHS<sup>[4]</sup>. However, only 30% of CHS patients had delayed gastric transit, with the majority having either normal or increased gastric transit on gastric scintigraphy<sup>[6]</sup>.

The diagnosis of CHS can be made if there is a high index of suspicion; the pathognomonic feature of compulsive bathing is particularly useful because this phenomenon is not seen in any other condition. As diagnosis of CHS is based on only clinical criteria<sup>[6]</sup>, laboratory or radiological data are not required for its diagnosis except to rule out other gastrointestinal conditions. Although blood or urine cannabinoid metabolites were not measured in our case, they may be helpful in ruling out the use of other recreational drugs. The correct diagnosis can often prevent an extensive and fruitless medical workup and lead to complete resolution of symptoms once abstinence from marijuana is achieved. Therefore, the index of suspicion amongst the medical profession should be raised, as this may be only the tip of the iceberg given the increasing use of marijuana associated with its legalization in several American states<sup>[1]</sup>.

In conclusion, physicians should have a high index of suspicion in patients with unexplained chronic abdominal pain and vomiting, because an excellent long-term prognosis of CHS can be achieved when abstinence is maintained. Since the mechanism by which cannabis induces hyperemesis is unknown, further research is required in patients with CHS.

## COMMENTS

### Case characteristics

A 44-year-old man with a history of marijuana use presented with chronic abdominal pain complicated by attacks of uncontrolled vomiting for 16 years.

### Differential diagnosis

Cyclic vomiting syndrome or small bowel inflammatory bowel disease.

### Laboratory diagnosis

All laboratory findings were unremarkable, including normal 24-h urine porphyrin levels and urinalysis.

### Imaging diagnosis

Repeat abdominal ultrasound, abdomen and pelvic computerized tomograph as well as small bowel follow-through were all normal.

### Treatment

All previous treatments were ineffective, including psychotropic and neuro-modulatory medications (amitriptyline, paroxetine hydrochloride, sertraline, and tegaserod), dietary manipulation, and alternative medical therapies, however, abstinence of marijuana led to a dramatic improvement of all symptoms within one week.

### Related reports

Cannabinoid hyperemesis syndrome (CHS), which is caused by chronic use of cannabis, may be associated with severe episodes of nausea and vomiting, and a characteristic learned behavior of compulsive hot bathing. This condition may be underdiagnosed because of relatively recent recognition and lack of awareness. Physicians should be aware of this unique cluster of symptoms to avoid misdiagnosis even after a protracted, invasive and costly workup.

### Term explanation

CHS can be diagnosed based on major clinical features including long-term cannabis use, severe cyclical abdominal pain, nausea and vomiting, resolution with cannabis cessation, and temporary relief of symptoms with hot showers or baths.

### Experiences and lessons

This case report highlights the excellent prognosis of CHS when abstinence from cannabis is maintained. Physicians should have a high index of suspicion for this rare condition in patients with unexplained chronic abdominal pain and vomiting. This report provides useful information on a rare disease as the cause of chronic abdominal pain and vomiting.

### Peer review

This is an interesting case study of cannabinoid hyperemesis syndrome, which is characterized by chronic, heavy use of cannabis, recurrent episodes of severe nausea and intractable vomiting, and abdominal pain. Overall, the paper is well written.

## REFERENCES

- 1 Kuehn BM. WHO documents worldwide need for better drug abuse treatment--and access to it. *JAMA* 2012; **308**: 442-443 [PMID: 22851093 DOI: 10.1001/jama.2012.8882]
- 2 Leggett T. A review of the world cannabis situation. *Bull Narc* 2006; **58**: 1-155 [PMID: 19066071]
- 3 Degenhardt L, Chiu WT, Sampson N, Kessler RC, Anthony JC, Angermeyer M, Bruffaerts R, de Girolamo G, Gureje O, Huang Y, Karam A, Kostyuchenko S, Lepine JP, Mora ME, Neumark Y, Ormel JH, Pinto-Meza A, Posada-Villa J, Stein DJ, Takeshima T, Wells JE. Toward a global view of alcohol, tobacco, cannabis, and cocaine use: findings from the WHO World Mental Health Surveys. *PLoS Med* 2008; **5**: e141 [PMID: 18597549 DOI: 10.1371/journal.pmed.0050141]
- 4 Allen JH, de Moore GM, Heddl R, Twartz JC. Cannabinoid hyperemesis: cyclical hyperemesis in association with chronic cannabis abuse. *Gut* 2004; **53**: 1566-1570 [PMID: 15479672]
- 5 Sontineni SP, Chaudhary S, Sontineni V, Lanspa SJ. Cannabinoid hyperemesis syndrome: clinical diagnosis of an underrecognized manifestation of chronic cannabis abuse. *World J Gastroenterol* 2009; **15**: 1264-1266 [PMID: 19291829]
- 6 Simonetto DA, Oxentenko AS, Herman ML, Szostek JH. Cannabinoid hyperemesis: a case series of 98 patients. *Mayo Clin Proc* 2012; **87**: 114-119 [PMID: 22305024 DOI: 10.1016/j.mayocp.2011.10.005]
- 7 Merikangas KR, McClair VL. Epidemiology of substance use disorders. *Hum Genet* 2012; **131**: 779-789 [PMID: 22543841 DOI: 10.1007/s00439-012-1168-0]
- 8 Aldworth J, Colpe LJ, Gfroerer JC, Novak SP, Chromy JR, Barker PR, Barnett-Walker K, Karg RS, Morton KB, Spagnola K. The National Survey on Drug Use and Health Mental Health Surveillance Study: calibration analysis. *Int J Methods Psychiatr Res* 2010; **19** Suppl 1: 61-87 [PMID: 20527006 DOI: 10.1002/mpr.312]

- 9 **Chang YH**, Windish DM. Cannabinoid hyperemesis relieved by compulsive bathing. *Mayo Clin Proc* 2009; **84**: 76-78 [PMID: 19121257 DOI: 10.1016/S0025-6196(11)60811-2]
  - 10 **Chepyala P**, Olden KW. Cyclic vomiting and compulsive bathing with chronic cannabis abuse. *Clin Gastroenterol Hepatol* 2008; **6**: 710-712 [PMID: 18456571 DOI: 10.1016/j.cgh.2008.01.017]
  - 11 **Donnino MW**, Cocchi MN, Miller J, Fisher J. Cannabinoid hyperemesis: a case series. *J Emerg Med* 2011; **40**: e63-e66 [PMID: 19765941 DOI: 10.1016/j.jemermed.2009.07.033]
  - 12 **Soriano-Co M**, Batke M, Cappell MS. The cannabis hyperemesis syndrome characterized by persistent nausea and vomiting, abdominal pain, and compulsive bathing associated with chronic marijuana use: a report of eight cases in the United States. *Dig Dis Sci* 2010; **55**: 3113-3119 [PMID: 20130993 DOI: 10.1007/s10620-010-1131-7]
  - 13 **Wallace D**, Martin AL, Park B. Cannabinoid hyperemesis: marijuana puts patients in hot water. *Australas Psychiatry* 2007; **15**: 156-158 [PMID: 17464661]
  - 14 **Watts M**. Cannabinoid hyperemesis presenting to a New Zealand hospital. *N Z Med J* 2009; **122**: 116-118 [PMID: 19319174]
  - 15 **Wenger T**, Moldrich G. The role of endocannabinoids in the hypothalamic regulation of visceral function. *Prostaglandins Leukot Essent Fatty Acids* 2002; **66**: 301-307 [PMID: 12052044]
  - 16 **Taché Y**. Cyclic vomiting syndrome: the corticotropin-releasing-factor hypothesis. *Dig Dis Sci* 1999; **44**: 79S-86S [PMID: 10490044]
  - 17 **Hayakawa K**, Mishima K, Nozako M, Hazekawa M, Ogata A, Fujioka M, Harada K, Mishima S, Orito K, Egashira N, Iwasaki K, Fujiwara M. Delta9-tetrahydrocannabinol (Delta9-THC) prevents cerebral infarction via hypothalamic-independent hypothermia. *Life Sci* 2007; **80**: 1466-1471 [PMID: 17289082]
  - 18 **Sim-Selley LJ**. Regulation of cannabinoid CB1 receptors in the central nervous system by chronic cannabinoids. *Crit Rev Neurobiol* 2003; **15**: 91-119 [PMID: 14977366]
  - 19 **Izzo AA**, Sharkey KA. Cannabinoids and the gut: new developments and emerging concepts. *Pharmacol Ther* 2010; **126**: 21-38 [PMID: 20117132 DOI: 10.1016/j.pharmthera.2009.12.005]
- P- Reviewer:** Galve-Roperh I, Panagis G, Prather PL, Trigo JM  
**S- Editor:** Song XX **L- Editor:** A **E- Editor:** Wu HL



## Scalp block for brain abscess drainage in a patient with uncorrected tetralogy of Fallot

Sameer Sethi, Sonia Kapil

Sameer Sethi, Sonia Kapil, Department of Anesthesia, Post Graduate Institute of Medical Education And Research, Chandigarh 160012, India

**Author contributions:** Both authors contributed in the preparation of the manuscript.

**Correspondence to:** Dr. Sameer Sethi, Department of Anesthesia, Post Graduate Institute of Medical Education And Research, Sector 12, Chandigarh 160012, India. [sethi.sameer@rediffmail.com](mailto:sethi.sameer@rediffmail.com)

Telephone: +91-99-14208491 Fax: +91-01-72274401

Received: May 23, 2014 Revised: September 20, 2014

Accepted: October 14, 2014

Published online: December 16, 2014

<http://www.wjgnet.com/2307-8960/full/v2/i12/934.htm> DOI: <http://dx.doi.org/10.12998/wjcc.v2.i12.934>

### INTRODUCTION

Tetralogy of Fallot (TOF), with an incidence of 10% of all congenital heart diseases<sup>[1]</sup>, is the commonest cyanotic congenital heart disease<sup>[1]</sup> and has a dilated aorta which overrides the large ventricular septal defect along with right ventricular outflow tract (RVOT) obstruction and hypertrophy of right ventricle. RVOT can be valvular, infundibular or both<sup>[2]</sup>. There have been several case reports of successful management of TOF presenting for brain abscess drainage, cesarean section and major abdominal surgeries<sup>[3-5]</sup>. We present a case report describing the use of scalp block combined with sedation for brain abscess drainage in a child with uncorrected TOF.

### CASE REPORT

An 11-year-old male child weighing 44 kg presented to us in the emergency department with a history of fever up to 102 °F, headache and vomiting for 10 d. The child was a known case of TOF but had not undergone any surgical repair. His effort tolerance was poor. He had a history of cyanotic spells since childhood but was not on any medication. On examination, the child was conscious, irritable and crying. The child did not show any signs of raised intracranial pressure. Central cyanosis and clubbing were present. He had a pulse rate of 76 per minute with a blood pressure of 110/60 mmHg. On examination of the cardiovascular system, the apex beat was found in the left 5th intercostal space in the midclavicular line and was associated with a left parasternal heave. 1<sup>st</sup> and 2<sup>nd</sup> heart sounds and a loud pulmonary component of the 2<sup>nd</sup> heart sound were audible, along with a pansystolic murmur (Grade 4/6) at the left lower sternal border. No focal deficit was found on neurological examination. The

### Abstract

We report a case of an 11-year-old boy with diagnosed but uncorrected tetralogy of Fallot presented to us for brain abscess drainage. The child was managed successfully with scalp block with sedation.

© 2014 Baishideng Publishing Group Inc. All rights reserved.

**Key words:** Tetralogy of Fallot; Brain abscess; Ketamine; Scalp block; Congenital heart disease

**Core tip:** We present a case report describing the use of scalp block combined with sedation for brain abscess drainage in a child with uncorrected tetralogy of Fallot. The goal should be to maintain hemodynamic stability and avoid any increase of a right to left shunt. Therefore, we decided to perform scalp block combined with sedation in this child. We used O<sub>2</sub> inhalation, analgesia and sedation with fentanyl, midazolam and ketamine to alleviate anxiety and increase systemic vascular resistance, pulmonary perfusion and oxygenation.

Sethi S, Kapil S. Scalp block for brain abscess drainage in a patient with uncorrected tetralogy of Fallot. *World J Clin Cases* 2014; 2(12): 934-937 Available from: URL: <http://www.wjgnet.com>



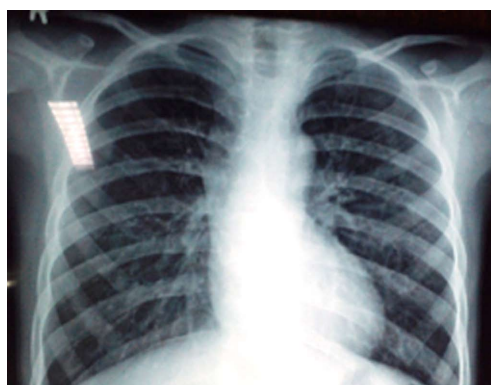

Figure 1 Chest X-ray of the patient showing enlarged cardiac silhouette.

respiratory and gastrointestinal systems were normal on examination.

Chest X-ray (Figure 1) showed an enlarged cardiac shadow with left ventricular hypertrophy and dilated pulmonary arteries. Electrocardiogram (ECG) revealed sinus rhythm with right ventricular hypertrophy. Echocardiography (ECHO) showed a large ventricular septal defect (VSD) of 13 mm, 60% overriding of the aorta, right ventricular hypertrophy and right ventricular tract outflow obstruction and ejection fraction of 0.6. Cardiac catheterization was not done. Contrast-enhanced computed tomography (Figure 2) showed a left temporo-parietal abscess with no uncal herniation, along with a midline shift of 2 mm. His hematocrit was 58% with a platelet count of  $105 \times 10^9/L$ . The child's serum electrolytes, coagulation studies and renal function tests were within normal limits. The baseline Arterial Blood Gas analysis revealed pH 7.419,  $P_{O_2}$  35.5 mmHg,  $P_{CO_2}$  31.8 mmHg,  $HCO_3^-$  20.1 mEq/L,  $SPO_2$  68.7% and base excess -3.3. The child received infective endocarditis prophylaxis prior to the surgery, was allowed oral intake of fluids up to 2 h before surgery and normal saline was used as the maintenance fluid thereafter in the ward. In the operation theater, standard monitoring was done with noninvasive blood pressure, pulse oximetry, ECG and temperature. A NeoStar™ triple lumen central venous catheter was in situ as it was inserted when the child presented to us in the emergency department. A 20 G arterial cannula (Becton Dickinson Critical Care Systems, Singapore) was inserted into the radial artery under local anesthesia. The baseline heart rate was 70 beats per minute with an invasive blood pressure of 116/68 mmHg and a central venous pressure (CVP) of 10 cm of  $H_2O$ . The child had 64%  $SPO_2$  with 50%  $O_2$  with a Venturi face mask. Normal saline was used as maintenance fluid with the dose of 4 mL/kg per hour.

The scalp block was given with 20 mL of 0.75% ropivacaine without adrenaline (3–4 mL for each nerve) to block the supratrochlear, supraorbital, zygomaticotemporal, auriculotemporal, greater and lesser occipital nerve. The block was supplemented with fentanyl 20  $\mu g$  *iv*, followed by ketamine 20 mg *iv* and midazolam 0.2 mg *iv* at the time of the burr hole. The child was kept on spontaneous respiration throughout the procedure with a 50% oxygen and air mixture. At the time of dural opening, intra-

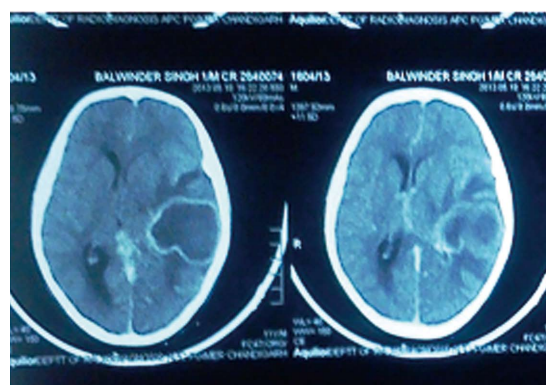


Figure 2 Contrast-enhanced computed tomography of the patient showing left temporo-parietal abscess.

venous ketamine 20 mg was repeated. Normal saline was administered to keep CVP in range of 14–16 cm of  $H_2O$ . The procedure lasted for 30 min and the intraoperative course was uneventful, with maintenance of hemodynamic parameters and acid base status within normal limits and a  $SPO_2$  of 69.5%.

## DISCUSSION

For the anesthetic management of these patients, one should be careful about the drugs and events that may increase the R-L shunt<sup>[6]</sup>. The severity of the disease directly correlates with the size of VSD, severity of pulmonary stenosis and functional status of the right ventricle<sup>[7]</sup>. Complications of right to left shunts include chronic hypoxia leading to pulmonary vasoconstriction, altered acid base status, polycythemia, coagulopathy, infective endocarditis and cerebral abscess due to increased risk of paradoxical emboli. The reported incidence of brain abscess in patients with cyanotic heart disease is between 5% and 18.7%<sup>[8]</sup>.

Anesthetic management of these patients is always a challenge for the anesthetists because of the cardiopulmonary and coagulation abnormalities, dehydration and electrolyte imbalance, along with abscess-induced complications of seizures, meningitis and raised intracranial pressure<sup>[4]</sup>.

General anesthesia with controlled ventilation has the advantage of better oxygenation but can be associated with the risk of hemodynamic instability, along with compression of pulmonary vessels, impaired gas exchange and acidemia<sup>[9]</sup>.

Most of the agents used for induction and maintenance of general anesthesia may also lead to myocardial depression, along with reduction of SVR.

The goal should be to maintain hemodynamic stability and avoid the changes that would increase the right to left shunt. Therefore, we decided to perform scalp block combined with sedation in this child.

Factors such as thorough preoperative examination, ECHO, treatment of any chest infections, cardiologist consultation, documentation of preoperative cardiac and neurological status and correction of any coagulopathy were necessary and taken care of in our child.

Prolonged fasting is better avoided in these patients and intake of clear fluids up to two hours prior to the surgery should be allowed. We followed the same guidelines in our patient with normal saline as a maintenance fluid in the ward. Prevention of dehydration is also important as these patients have an increased hematocrit. Patients with a hematocrit  $\geq 60\%$  are susceptible to develop coagulopathy and preoperative phlebotomy is beneficial in such cases. Our child had a hematocrit of 58% and preoperative phlebotomy was not performed as it was an emergency procedure, but adequate precautions to prevent dehydration and liberal fluid administration were done to keep the CVP in the range of 14-16 cm of H<sub>2</sub>O. Fluid boluses of 20 mL/kg may be required to increase the blood pressure and RV preload<sup>[10]</sup>.

Air bubbles are also a preventable cause of perioperative morbidity in patients with shunting as air or particulate matter may be shunted directly into the arterial bed<sup>[11,12]</sup> and we took measures to prevent this.

We used O<sub>2</sub> inhalation, analgesia and sedation with fentanyl, midazolam and ketamine to alleviate anxiety and increase SVR, pulmonary perfusion and oxygenation. Although O<sub>2</sub> inhalation, fentanyl and midazolam cannot increase SVR, they avoid increasing PVR. Ketamine may increase SVR at some level or more importantly can prevent lowering of SVR and it helped our patient by decreasing the left to right shunt.

Ketamine has also been shown to be better in children with pulmonary hypertension<sup>[13,14]</sup> although this is not the cause of cyanosis in these patients but it is the fall in SVR leading to left-right shunt which causes hypoxia. In one study of 18 neonates who had complex cardiac defects, ketamine was used most commonly when intubation was not required for surgery<sup>[15]</sup>. Anesthetic agents like sevoflurane, isoflurane and fentanyl/midazolam infusions have no effect on the shunt fraction of children with shunts<sup>[16-18]</sup>.

Scalp block is a well-established technique for craniotomy, increasingly being used for epilepsy surgery, temporal lobectomy where the excision encroaches on eloquent cortex areas<sup>[19]</sup>.

Scalp block may be given preoperatively to reduce the hemodynamic response to pin holder application and postoperatively before the emergence to decrease the severity of postoperative pain. They also decrease intra and postoperative opioid requirement<sup>[20,21]</sup>.

We used 0.75% ropivacaine without adrenaline for administering scalp block as the addition of adrenaline may cause tachycardia which is very dangerous in patients with uncorrected TOF because it may cause infundibular spasm and a cyanotic spell.

Scalp block along with sedation is being used successfully in our institute for patients with chronic subdural hemorrhage. Since the patient we encountered had to undergo an emergency procedure with no time for cardiac catheterization and medical optimization of the patient, we decided to proceed with regional anesthesia with sedation and invasive monitoring in the patient.

The avoidance of general anesthesia due to medical

reasons in selected patients and with the thorough anatomical knowledge of nerve blocks, this underestimated regional technique of scalp block with sedation may be considered as an alternative technique in selective patients with unrepaired TOF and has proved to be an extremely rewarding procedure for the neuroanesthetist whilst offering the best possible outcome for the patient.

## COMMENTS

### Case characteristics

An 11-year-old male, a known case of tetralogy of Fallot (TOF), presented with fever (up to 102 °F), headache and vomiting for the past 10 d.

### Clinical diagnosis

On examination, the child had central cyanosis, clubbing, loud P2 and grade IV pansystolic murmur but there were no signs of raised intracranial pressure and no neurological focal deficit.

### Differential diagnosis

A known case of TOF who had not undergone any surgical repair and presented with brain abscess.

### Laboratory diagnosis

The patient had a high hematocrit with a normal coagulation profile. The baseline Arterial Blood Gas analysis revealed pH 7.419, Po<sub>2</sub> 35.5 mmHg, Pco<sub>2</sub> 31.8 mmHg, HCO<sub>3</sub> 20.1 mEq/L, SPO<sub>2</sub> 68.7% and BE -3.3.

### Imaging diagnosis

Echocardiography revealed a large ventricular septal defect of 13 mm, 60% overriding of aorta, right ventricular tract outflow obstruction and ejection fraction of 0.6, while contrast-enhanced computed tomography (Figure 2) showed a left temporoparietal abscess with no uncal herniation and a midline shift of 2 mm.

### Pathological diagnosis

The patient was diagnosed as a brain abscess with uncorrected TOF.

### Treatment

Child was not on any medication and presented to us in the emergency department. The child received infective endocarditis prophylaxis prior to the surgery.

### Experiences and lessons

Uncorrected TOF presents as a challenge to anesthetists and a thorough knowledge about the physiological and pathological changes occurring with the disease is essential for the safe management of the patient in the perioperative period. Regional anaesthesia should be considered as an alternative to general anesthesia when feasible.

### Peer review

A good paper that can be accepted.

## REFERENCES

- 1 Moller JH, Neal WA. Fetal, neonatal and infant cardiac disease. Norwalk: Appleton and Lange, 1990. Available from: URL: <http://www.amazon.com/Fetal-Neonatal-Infant-Cardiac-Disease/dp/083852575X>
- 2 Behram RE, Kleigman RM, Nelson WE, Vaughan VC. Congenital cardiac disease with cyanosis. In: Nelson Textbook of Pediatrics. Philadelphia: WB Saunders, 1992: 1149-1153
- 3 Katsetos CP, Kontoyannis MB, Koumoussidis A, Petropoulou O, Delos C, Katsoulis M. Uncorrected tetralogy of Fallot and pregnancy: a case report. *Clin Exp Obstet Gynecol* 2012; **39**: 382-383 [PMID: 23157051]
- 4 Raha A, Ganjoo P, Singh A, Tandon MS, Singh D. Surgery for brain abscess in children with cyanotic heart disease: An anesthetic challenge. *J Pediatr Neurosci* 2012; **7**: 23-26 [PMID: 22837772 DOI: 10.4103/1817-1745.97617]
- 5 Haack M, Machotta A, Boemke W, Höhne C. Anesthesia in an infant with uncorrected tetralogy of Fallot for transanal pull-through for Hirschsprung's disease. *Paediatr Anaesth* 2006; **16**: 95-96 [PMID: 16409542 DOI: 10.1111/j.1460-9592.2005.01749.x]
- 6 Stoelting Robert K. Congenital heart disease. In: Anaesthesia and coexisting disease. 3rd ed. Churchill livingstone:

- 42-45
- 7 **Webb GD**, Smallhorn JF, Therrien J, Redington AN. Congenital heart disease. In: Zipes DP, LibbyP, Bonow RO, Braunwald E, editors. Braunwald's heart disease: a textbook of cardiovascular medicine. 7th ed. Philadelphia: W. B. Saunders, 2005: 1489-1552
  - 8 **Fischbein CA**, Rosenthal A, Fischer EG, Nadas AS, Welch K. Risk factors of brain abscess in patients with congenital heart disease. *Am J Cardiol* 1974; **34**: 97-102 [PMID: 4835759 DOI: 10.1016/0002-9149(74)90099-X]
  - 9 **Ahmed I**. Tetralogy of Fallot and pregnancy. *RMJ* 2004; **29**: 76-79
  - 10 **Twite MD**, Ing RJ. Tetralogy of Fallot: perioperative anesthetic management of children and adults. *Semin Cardiothorac Vasc Anesth* 2012; **16**: 97-105 [PMID: 22275349 DOI: 10.1177/1089253211434749]
  - 11 **Hickey PR**. Anaesthesia for treatment of congenital heart disease. In: Rouges MC, Tinker JH, Covino BG, Longnecker DE eds. Principles and Practice of Anaesthesiology. St. Louis, Missouri: Mosby Year Book, 1993: 1681-1718
  - 12 **Moore RA**. Anaesthetizing the child with congenital heart disease for non-cardiac surgery. In: Barash PG ed. Philadelphia: Lippincott Williams & Wilkins, 1994: 211-226
  - 13 **Williams GD**, Maan H, Ramamoorthy C, Kamra K, Bratton SL, Bair E, Kuan CC, Hammer GB, Feinstein JA. Perioperative complications in children with pulmonary hypertension undergoing general anesthesia with ketamine. *Paediatr Anaesth* 2010; **20**: 28-37 [PMID: 20078799 DOI: 10.1111/j.1460-9592.2009.03166.x]
  - 14 **Williams GD**, Philip BM, Chu LF, Boltz MG, Kamra K, Terwey H, Hammer GB, Perry SB, Feinstein JA, Ramamoorthy C. Ketamine does not increase pulmonary vascular resistance in children with pulmonary hypertension undergoing sevoflurane anesthesia and spontaneous ventilation. *Anesth Analg* 2007; **105**: 1578-1584, table of contents [PMID: 18042853 DOI: 10.1213/01.ane.0000287656.29064.89]
  - 15 **Walker A**, Stokes M, Moriarty A. Anesthesia for major general surgery in neonates with complex cardiac defects. *Paediatr Anaesth* 2009; **19**: 119-125 [PMID: 19207897 DOI: 10.1111/j.1460-9592.2008.02801.x]
  - 16 **Ikemba CM**, Su JT, Stayer SA, Miller-Hance WC, Eidem BW, Bezold LI, Hall SR, Havemann LM, Andropoulos DB. Myocardial performance index with sevoflurane-pancuronium versus fentanyl-midazolam-pancuronium in infants with a functional single ventricle. *Anesthesiology* 2004; **101**: 1298-1305 [PMID: 15564936 DOI: 10.1097/00000542-200412000-00009]
  - 17 **Laird TH**, Stayer SA, Rivenes SM, Lewin MB, McKenzie ED, Fraser CD, Andropoulos DB. Pulmonary-to-systemic blood flow ratio effects of sevoflurane, isoflurane, halothane, and fentanyl/midazolam with 100% oxygen in children with congenital heart disease. *Anesth Analg* 2002; **95**: 1200-1206, table of contents [PMID: 12401594 DOI: 10.1097/00000539-200211000-00016]
  - 18 **Rivenes SM**, Lewin MB, Stayer SA, Bent ST, Schoenig HM, McKenzie ED, Fraser CD, Andropoulos DB. Cardiovascular effects of sevoflurane, isoflurane, halothane, and fentanyl-midazolam in children with congenital heart disease: an echocardiographic study of myocardial contractility and hemodynamics. *Anesthesiology* 2001; **94**: 223-229 [PMID: 11176085 DOI: 10.1097/00000542-200102000-00010]
  - 19 **Herrick IA**, Gelb AW. Anesthesia for temporal lobe epilepsy surgery. *Can J Neurol Sci* 2000; **27** Suppl 1: S64-S67; discussion S92-S97 [PMID: 10830330]
  - 20 **Nguyen A**, Girard F, Boudreault D, Fugère F, Ruel M, Moumdjian R, Bouthilier A, Caron JL, Bojanowski MW, Girard DC. Scalp nerve blocks decrease the severity of pain after craniotomy. *Anesth Analg* 2001; **93**: 1272-1276 [PMID: 11682413 DOI: 10.1097/00000539-200111000-00048]
  - 21 **Pinosky ML**, Fishman RL, Reeves ST, Harvey SC, Patel S, Palesch Y, Dorman BH. The effect of bupivacaine skull block on the hemodynamic response to craniotomy. *Anesth Analg* 1996; **83**: 1256-1261 [PMID: 8942596 DOI: 10.1213/00000539-199612000-00022]

**P- Reviewer:** Ong HT, Ozcengiz D, Nagashima G

**S- Editor:** Ji FF **L- Editor:** Roemmele A **E- Editor:** Wu HL



## Complete oral rehabilitation in a case with severe dental fluorosis

Nikhil Joshi, Jayant Palaskar, Mahasweta Joshi, Rahul Kathariya

Nikhil Joshi, Jayant Palaskar, Department of Prosthodontics, Crown, Bridge and Implantology, Sinhgad Dental College and Hospital, STES campus, Vadgaon (Budruk), Pune 411041, Maharashtra, India

Mahasweta Joshi, Department of Public Health Dentistry, Sinhgad Dental College and Hospital, STES Campus, Vadgaon (Budruk), Pune 411041, Maharashtra, India

Rahul Kathariya, Dr. D.Y Patil Dental College and Hospital, Dr. D.Y Vidyapeeth (Deemed University), Pune 411018, Maharashtra, India

Author contributions: All the authors solely contributed to this paper.

Correspondence to: Dr. Rahul Kathariya, MDS, PhD, Dr. D.Y Patil Dental College and Hospital, Dr. D.Y Vidyapeeth (Deemed University), Pune 411018, Maharashtra, India. [rkathariya@gmail.com](mailto:rkathariya@gmail.com)

Telephone: +91-89-83370741

Received: May 19, 2014 Revised: August 21, 2014

Accepted: September 23, 2014

Published online: December 16, 2014

plane

**Core tip:** A novel technique of full occlusal rehabilitation is illustrated here. It is a simple procedure which adheres to all the principles of occlusal rehabilitation. Rehabilitation of dental fluorosis using the treatment protocol suggested here will systematize and streamline the clinical technique and it is hoped that this approach will benefit the patients and act as a guide for dentists. Although the technique described here is skill sensitive, it is the author's belief that it is a new paradigm in full mouth occlusal rehabilitation.

Joshi N, Palaskar J, Joshi M, Kathariya R. Complete oral rehabilitation in a case with severe dental fluorosis. *World J Clin Cases* 2014; 2(12): 938-942 Available from: URL: <http://www.wjgnet.com/2307-8960/full/v2/i12/938.htm> DOI: <http://dx.doi.org/10.12998/wjcc.v2.i12.938>

### Abstract

The authors have presented a technique of full occlusal rehabilitation in a case of severe dental fluorosis. In this technique, maxillary and mandibular anterior teeth were simultaneously prepared and restored first. This was followed by simultaneous preparation of maxillary and mandibular posterior teeth that were restored in canine guided occlusion. The technique and sequence followed here is unique and is not available in dental literature. This technique reduces number of appointments while fulfilling all objectives. Periodontal follow-up over 3 years was satisfactory. A restorative treatment protocol has been devised for fluorosis which will act as a guide for the dental practitioners.

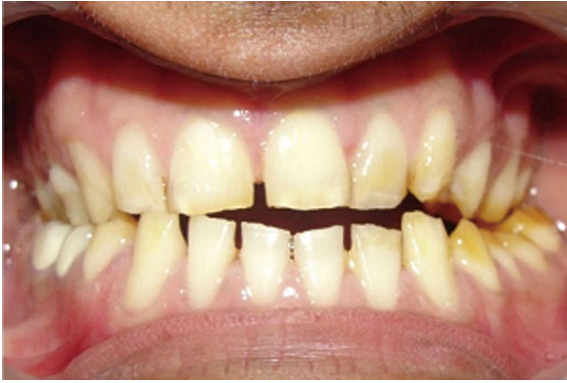© 2014 Baishideng Publishing Group Inc. All rights reserved.

**Key words:** Occlusal rehabilitation; Dental fluorosis; Treatment protocol; Restorative management; Occlusal

### INTRODUCTION

There are hardly any documented cases in dental literature where dental fluorosis is treated by full occlusal rehabilitation. Restoration of dentitions affected by dental fluorosis is a challenging prospect. The presence of dental hypoplasia, the severity of discoloration, associated symptoms like hypersensitivity and attrition makes treatment planning extremely critical. The majority of fluorosis patients usually have mild to moderate fluorosis<sup>[1,2]</sup> wherein the main symptoms are discoloration and/or very mild hypoplasia<sup>[3,4]</sup>. These may be managed by simple restorative procedures like bleaching or composite filling. Some patients have moderate fluorosis which requires veneers or an occasional crown<sup>[5-8]</sup>. Very rarely, patients with severe fluorosis require full occlusal rehabilitation. The protocol for treatment of dental fluorosis has been formulated in this article.



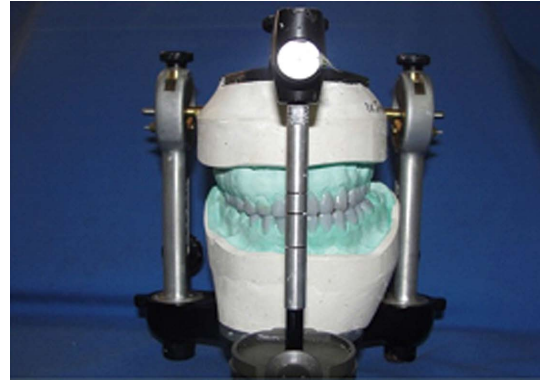


**Figure 1** Baseline pre-treatment intraoral photograph.

This article documents a case of severe dental fluorosis with intraoral findings such as severe attrition, anterior open bite and unilateral cross bite, which was treated by full occlusal rehabilitation. Novel clinical and technical modifications were employed which may help to simplify the procedure of full occlusal rehabilitation.

## CASE REPORT

A 28-year male patient reported to the Department of Prosthodontics, with a chief complaint of inability to chew food and discoloration of teeth. A detailed personal history revealed that the patient belonged to one of the fluoride belts of India. Clinical findings included protruded mandible, concave facial profile, severe dental fluorosis (Level 4 on Dean's Modified Index)<sup>[9]</sup>, maxillary midline not coinciding with mandibular midline, anterior open bite, unilateral crossbite with a few centric stops on left side, generalized severe attrition of teeth with moderate sensitivity (Figure 1). However, there was no loss of vertical dimension which could be attributed to passive eruption to compensate for the attrition. Diagnostic impressions were made using irreversible hydrocolloid (Zelgan 2002, Dentsply, India) and casts poured using dental stone (Kalabhai Karson Pvt. Ltd., India). Face bow (Hanau Springbow, Waterpik Technologies, United States) transfer was done and the casts were mounted using a centric relation record on a semi-adjustable articulator (Hanau H2, Whip Mix Corp, United States). All the clinical findings were confirmed by diagnostic mounting of the casts. Diagnostic wax up was done based on findings of clinical examination, diagnostic mounting and diagnostic wax up. Full occlusal rehabilitation using ceramometal crowns [Meta Cast (V), United States], without changing the vertical dimension at occlusion, was decided as the treatment of choice. The limitations of this treatment option viz., inability to coincide the maxillary and mandibular midline, inability to improve the facial profile and persistence of crossbite on left side were explained to the patient and his approval was obtained for the treatment plan. Maxillary and mandibular anterior teeth were prepared simultaneously to receive individual ceramometal crowns. Impressions were made using Vinyl Polysiloxane (GC America Inc, Made in Japan) by the putty-

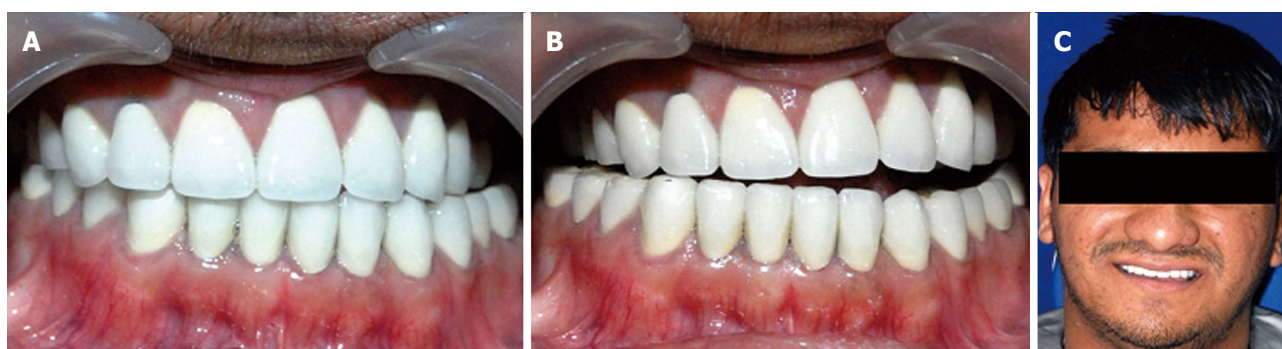


**Figure 2** Centric relation and centric occlusion was verified in a semi adjustable Hanau articulator.

wash technique<sup>[10]</sup>. Individual temporary crowns (DPI, India) were fabricated using the indirect technique<sup>[11]</sup> and were used to establish the anterior guidance in the patient's mouth in such a way that anterior temporaries provided canine guided occlusion. This was transferred to the semi-adjustable articulator and a custom incisal table was fabricated. The anterior metal try-in was carried out and ceramic (Vita VMK 95, Germany) build up was done according to the anterior guidance obtained from the patient. These definitive anterior restorations were seated in the patient's mouth, the canine guided occlusion verified and finally the anterior individual crowns were cemented using glass ionomer luting cement (Ketac Cem, 3M ESPE, Germany). The maxillary and mandibular midlines got close but could not be coincided. In the next phase of treatment, all the posterior teeth (maxillary and mandibular) were prepared simultaneously in a single appointment and a centric relation record was obtained. Impressions were made and master casts poured using die stone (Kalrock, Kalabhai Karson Pvt Ltd, India). The casts obtained were mounted on the semi-adjustable articulator. The horizontal and lateral condylar guidances were set arbitrarily at 20° and 15° respectively<sup>[12]</sup>. The metal copings were fabricated and tried in the patient. Before the ceramic build up was started, the occlusal plane had to be established. This was set at the midpoint between the prepared maxillary and mandibular posterior teeth. After ceramic build up, the definitive restorations were tried in the patient, harmony of centric relation and centric occlusion was verified (Figure 2), canine guided occlusion was confirmed and the restorations were cemented.

## Follow up

Follow up of the restorations and surrounding tissues was done for 3 years. Gingival and Periodontal component of Periodontal Disease Index (PDI)<sup>[13]</sup> and Plaque component of PDI (Shick and Ash modification) was recorded at the beginning of treatment, every 3 mo for 1 year post treatment and every 6 mo for next 2 years (Figure 3). The Gingival and Periodontal component of PDI score before treatment was 2, in the first year post treatment it was 1 and for the next two years it was 0. Plaque



**Figure 3** Follow up of the restorations and surrounding tissues. A: One year post-treatment intraoral photograph; B: Two year post-treatment intraoral photograph; C: Three years post-treatment extra oral photograph.

**Table 1** Restorative treatment protocol for dental fluorosis of varied severity

Modified dean's fluorosis index score	Clinical findings	Suggested treatment options
Normal (0)	Enamel represents usual transparency, semi-vitriform type of structure. The surface appears smooth, glossy and usually of a pale, creamy white colour	No treatment
Questionable (0.5)	Few flecks to occasional white spots	No treatment/bleaching
Very Mild (1)	Small, opaque, paper white areas scattered over < 25% of the tooth surface	No treatment /bleaching
Mild (2)	White opaque areas in enamel of the teeth are more extensive, but do not involve as much as 50% of the tooth	Bleaching/ composite restoration
Moderate (3)	All enamel surfaces of the teeth are affected and surfaces subject to attrition show wear. Brown stain is frequently a disfiguring feature	If discolorations accompanied by wear: Full coverage If only discoloration without any wear: 1 Bleaching or 2 Veneers (Direct or indirect) or 3 Bleaching followed by Veneers (Direct or indirect)
Severe (4)	All enamel surfaces affected, severe hypoplasia, discrete or confluent pitting. Brown stains are widespread and teeth often present a corroded-like appearance	Full coverage

component of PDI score before treatment was 2 and for the next three years it was 1. This indicated high compliance of oral hygiene instructions post-treatment by the patient and successful integration of the restorations in harmony with the periodontal apparatus. The patient expressed satisfaction with treatment and esthetics and restorations were sound and asymptomatic (no sensitivity to heat or cold, no pain/tenderness) at the follow-up visits. This three year follow up has reinforced that the treatment plan was sound and objectives of full occlusal rehabilitation were fulfilled while addressing all the pre-treatment problems of the patient.

## DISCUSSION

Dental fluorosis is seldom so severe<sup>[14-16]</sup> as to warrant full occlusal rehabilitation. In addition, complexities such as unilateral cross bite on left side, minimum occlusal contacts on right side, anterior open bite (as found in the present case) makes the prosthetic rehabilitation of such a patient challenging. Every attempt was made in this case to provide the best possible functional and aesthetic rehabilitation of the patient.

The dentition in full occlusal rehabilitation cases are restored variously following different principles and phi-

losophies. The canine guided occlusion is the favoured occlusal scheme, most often adopted in full occlusal rehabilitation<sup>[17-24]</sup>. In this technique, the posterior teeth contact only in centric relation, the incisors are the only teeth contacting in protrusion and the canines are the only teeth contacting in mandibular lateral movements. In this patient, the canine guided occlusal scheme was implemented.

In canine guided occlusion the orientation and location of occlusal plane is not critical as long as it allows the anterior guidance to do its job. In this case, the occlusal plane was planned to be located midway between the prepared posterior teeth. This concept was relatively easy to apply as both the maxillary and mandibular posteriors were prepared at the same time and made the technician's job much easier. Since the technician received both maxillary and mandibular final casts with prepared posterior teeth, it was easier for her to establish proper contours and height of opposing restorations making optimum use of the available space. This technique is especially advantageous in cases of full occlusal rehabilitation restored using canine guided occlusion. In the present case, a technique has been attempted which simplifies the clinical and laboratory procedures of full occlusal rehabilitation while fulfilling all its objectives<sup>[12,25]</sup>.

The restorative procedures were divided into two components: anterior segment restoration followed by posterior segment restoration. The maxillary and mandibular anterior restorations were fabricated at the same time. Establishing the anterior guidance was also easier. Any adjustments and trimming could be done easily. When the posterior restorations were fabricated, developing the occlusal plane was greatly simplified as both the maxillary and mandibular segments were simultaneously prepared. The occlusal level was then set at the midpoint between the prepared maxillary and mandibular posterior teeth on the articulated casts.

Some occlusal rehabilitation philosophies recommend the restoration of posterior teeth prior to that of anterior teeth (*e.g.*, Hobo Twin-Stage procedure<sup>[26]</sup> -Conditions 1 and 2). Other philosophies of full occlusal rehabilitation, including the Panky-Mann-Schuyler concept modified by Dawson<sup>[12]</sup> recommend the sequential restoration of mandibular anterior segment, maxillary anterior segment, mandibular posterior and finally the maxillary posterior segment. The approach discussed in this article is unlike any other philosophies of full occlusal rehabilitation, is simple, requires least number of appointments, is unique and novel, and yet it fulfils all the requirements of full occlusal rehabilitation.

Hence clinical work is greatly simplified and patient appointments are limited to just 6 as follows: Appointment 1: Diagnostic impression, face bow transfer. Appointment 2: Preparation of maxillary and mandibular anterior teeth, impressions, temporization of anteriors. Appointment 3: Anterior metal try-in. Appointment 4: Cementation of anterior ceramometal crowns, selective grinding, finishing, polishing; preparation of all posterior teeth; impressions, face bow transfer, temporization of all posterior teeth. Appointment 5: Metal try-in of posterior restorations; Appointment 6: Cementation of posterior ceramometal crowns selective grinding, finishing, and polishing. Appointment 4 may be split into two depending on convenience of operator and/or patient.

Depending on the Modified Dean's Fluorosis Index<sup>[9]</sup> which is the gold standard for quantifying dental fluorosis, a treatment protocol is herewith suggested (Table 1) which is meant as a guide; the operator may follow any treatment modality given in the protocol depending upon the skill-philosophy-convenience-preference.

The technique of full occlusal rehabilitation illustrated here simplifies the procedures while adhering to all its principles. Rehabilitation of dental fluorosis using the treatment protocol suggested here will systematize and streamline the clinical procedure and it is hoped that this approach will benefit the patient and act as a guideline for dentists.

## COMMENTS

### Case characteristics

This is a report of a case of severely discolored teeth, secondary to dental fluorosis; with generalized sensitivity, inability to chew food from both sides and deformed esthetics due to anterior open bite.

### Clinical diagnosis

The patient had a concave facial profile with severe dental fluorosis (level 4 on Dean's Modified Index), with prognathic mandible, maxillary midline not coinciding with mandibular midline, anterior open bite, unilateral cross bite with a few centric stops on left side, and severe generalized attrition with moderate sensitivity.

### Differential diagnosis

The differential diagnosis can be hypoplasia secondary to trauma to the teeth and jaws, any infections during pregnancy or infancy, poor pre-natal and post-natal nutrition, hypoxia, exposure to toxic chemicals and a variety of hereditary disorders, irregular vitamin D metabolism (vitamin D-resistant rickets) or chronic kidney failure at the time of tooth development.

### Laboratory diagnosis

The tests included intra oral periapical and extra oral panoramic radiographs, diagnostic model mounting, pulp vitality testing of all teeth that confirmed the clinical findings of permanent hypoplastic teeth with sensitivity that were severely attrited and in malocclusion.

### Imaging diagnosis

Imaging techniques used were orthopantomograph and intraoral periapical radiographs which showed generalized hypoplastic teeth, malocclusion, and anterior open bite.

### Treatment

The treatment given was a full mouth rehabilitation using a specialized, simplified technique which is novel.

### Term explanation

All terms are standard and established which have been used empirically.

### Experiences and lessons

The approach to a full mouth rehabilitation case has to be holistic, patient specific and should fulfill all the criteria of scientific treatment protocol.

### Peer review

This is an interesting and well written article. Methods are appropriate. Results are clearly presented. Discussion and Conclusions are really interesting.

## REFERENCES

1. **Tabari ED**, Ellwood R, Rugg-Gunn AJ, Evans DJ, Davies RM. Dental fluorosis in permanent incisor teeth in relation to water fluoridation, social deprivation and toothpaste use in infancy. *Br Dent J* 2000; **189**: 216-220 [PMID: 11036750 DOI: 10.1038/sj.bdj.4800726]
2. **Catani DB**, Hugo FN, Cypriano S, Sousa Mda L, Cury JA. Relationship between fluoride levels in the public water supply and dental fluorosis. *Rev Saude Publica* 2007; **41**: 732-739 [PMID: 17923894 DOI: 10.1590/S0034-89102007000500007]
3. **Fluoridation facts**. Chicago (Illinois): American Dental Association, 2005:29. Available from: URL: [http://www.ada.org/sections/newsAndEvents/pdfs/fluorodiation\\_facts.pdf](http://www.ada.org/sections/newsAndEvents/pdfs/fluorodiation_facts.pdf)
4. **Beltrán-Aguilar ED**, Barker LK, Canto MT, Dye BA, Gooch BF, Griffin SO, Hyman J, Jaramillo F, Kingman A, Nowjack-Raymer R, Selwitz RH, Wu T. Surveillance for dental caries, dental sealants, tooth retention, edentulism, and enamel fluorosis--United States, 1988-1994 and 1999-2002. *MMWR Surveill Summ* 2005; **54**: 1-43 [PMID: 16121123]
5. **Akpata ES**. Occurrence and management of dental fluorosis. *Int Dent J* 2001; **51**: 325-333 [PMID: 11697585 DOI: 10.1002/j.1875-595X.2001.tb00845.x]
6. **Bertassoni LE**, Martin JM, Torno V, Vieira S, Rached RN, Mazur RF. In-office dental bleaching and enamel micro-abrasion for fluorosis treatment. *J Clin Pediatr Dent* 2008; **32**: 185-187 [PMID: 18524266]
7. **Ardu S**, Stavridakis M, Krejci I. A minimally invasive treatment of severe dental fluorosis. *Quintessence Int* 2007; **38**: 455-458 [PMID: 17625627]
8. **Loyola-Rodriguez JP**, Pozos-Guillen Ade J, Hernandez-Hernandez F, Berumen-Maldonado R, Patiño-Marin N. Effectiveness of treatment with carbamide peroxide and hydrogen peroxide in subjects affected by dental fluorosis: a clinical trial. *J Clin Pediatr Dent* 2003; **28**: 63-67 [PMID: 14604145]
9. **World health organization**. Oral health surveys- basic meth-



- ods. 4<sup>ed</sup>. Geneva: World Health Organization, 1997: 35-36
- 10 **Anusavice KL.** Phillips' science of dental materials, 11th ed. WB: Saunders Company, 2003
- 11 **Rosenstiel SF,** Fujimoto J, Land MF. Contemporary Fixed Prosthodontics. 4th ed. St. Louis: Elsevier Health Sciences, 2006
- 12 **Dawson PE.** Evaluation, diagnosis and treatment of occlusal problems. 2nd ed. CV: Mosby Company, 1989
- 13 **Ramfjord SP.** The Periodontal Disease Index (PDI). *J Periodontol* 1967; **38**: Suppl: Suppl:602-610 [PMID: 5237683 DOI: 10.1902/jop.1967.38.6.602]
- 14 **Clark DC.** Trends in prevalence of dental fluorosis in North America. *Community Dent Oral Epidemiol* 1994; **22**: 148-152 [PMID: 8070241 DOI: 10.1111/j.1600-0528.1994.tb01832.x]
- 15 **Driscoll WS,** Horowitz HS, Meyers RJ, Heifetz SB, Kingman A, Zimmerman ER. Prevalence of dental caries and dental fluorosis in areas with negligible, optimal, and above-optimal fluoride concentrations in drinking water. *J Am Dent Assoc* 1986; **113**: 29-33 [PMID: 3461057]
- 16 **Osuji OO,** Leake JL, Chipman ML, Nikiforuk G, Locker D, Levine N. Risk factors for dental fluorosis in a fluoridated community. *J Dent Res* 1988; **67**: 1488-1492 [PMID: 3198847 DOI: 10.1177/00220345880670120901]
- 17 **Amico D.** Functional occlusion of the natural teeth in man. *J Prosthet Dent* 1961; **11**: 899-915 [DOI: 10.1016/0022-3913(61)90148-2]
- 18 **Scaife RR.** Holt JE: Natural occurrence of cuspid guidance. *J Prosthet Dent* 1969; **22**: 225-229 [PMID: 5256070 DOI: 10.1016/0022-3913(69)90249-2]
- 19 **Stuart CE.** Good occlusion for natural teeth. *J Prosthet Dent* 1964; **14**: 716-724 [DOI: 10.1016/0022-3913(64)90207-0]
- 20 **McAdam DB.** Tooth loading and cuspal guidance in canine and group-function occlusions. *J Prosthet Dent* 1976; **35**: 283-290 [PMID: 1062598 DOI: 10.1016/0022-3913(76)90252-3]
- 21 **DiPietro GJ.** A study of occlusion as related to the Frankfort-mandibular plane angle. *J Prosthet Dent* 1977; **38**: 452-458 [PMID: 269281 DOI: 10.1016/0022-3913(77)90100-7]
- 22 **Goldstein GR.** The relationship of canine-protected occlusion to a periodontal index. *J Prosthet Dent* 1979; **41**: 277-283 [PMID: 283227 DOI: 10.1016/0022-3913(79)90007-6]
- 23 **Siebert G.** Recent results concerning physiological tooth movement and anterior guidance. *J Oral Rehabil* 1981; **8**: 479-493 [PMID: 6947080 DOI: 10.1111/j.1365-2842.1981.tb00523.x]
- 24 **Belser UC,** Hannam AG. The influence of altered working-side occlusal guidance on masticatory muscles and related jaw movement. *J Prosthet Dent* 1985; **53**: 406-413 [PMID: 3857338 DOI: 10.1016/0022-3913(85)90523-2]
- 25 **Michael DW.** Failure in the Restored Dentition: Management and Treatment. Tokyo: Quintessence Publishing Company, 1995
- 26 **Hobo S,** Takayama H. Oral rehabilitation clinical determination of occlusion, 1st ed. Tokyo: Quintessence Publishing Company, 1997

**P- Reviewer:** Boffano P, Gokul S **S- Editor:** Song XX

**L- Editor:** A **E- Editor:** Wu HL







Published by **Baishideng Publishing Group Inc**

8226 Regency Drive, Pleasanton, CA 94588, USA

Telephone: +1-925-223-8242

Fax: +1-925-223-8243

E-mail: [bpgoffice@wjgnet.com](mailto:bpgoffice@wjgnet.com)

Help Desk: <http://www.wjgnet.com/esps/helpdesk.aspx>

<http://www.wjgnet.com>

